Injuries of the eye : diagnosis and treatment, forensic procedures and visual economics / by Harry Vanderbilt Würdemann.

Contributors

Würdemann, Harry Vanderbilt.

Publication/Creation

London : Henry Kimpton, 1932.

Persistent URL

https://wellcomecollection.org/works/n9t2gmch

License and attribution

This work has been identified as being free of known restrictions under copyright law, including all related and neighbouring rights and is being made available under the Creative Commons, Public Domain Mark.

You can copy, modify, distribute and perform the work, even for commercial purposes, without asking permission.

wellcome collection

Wellcome Collection
183 Euston Road
London NW1 2BE UK
T +44 (0)20 7611 8722
E library@wellcomecollection.org
https://wellcomecollection.org

BOSTON
MEDICAL LIBRARY
8 THE FENWAY

Edward R. Williams.

23 Oct. 1911.

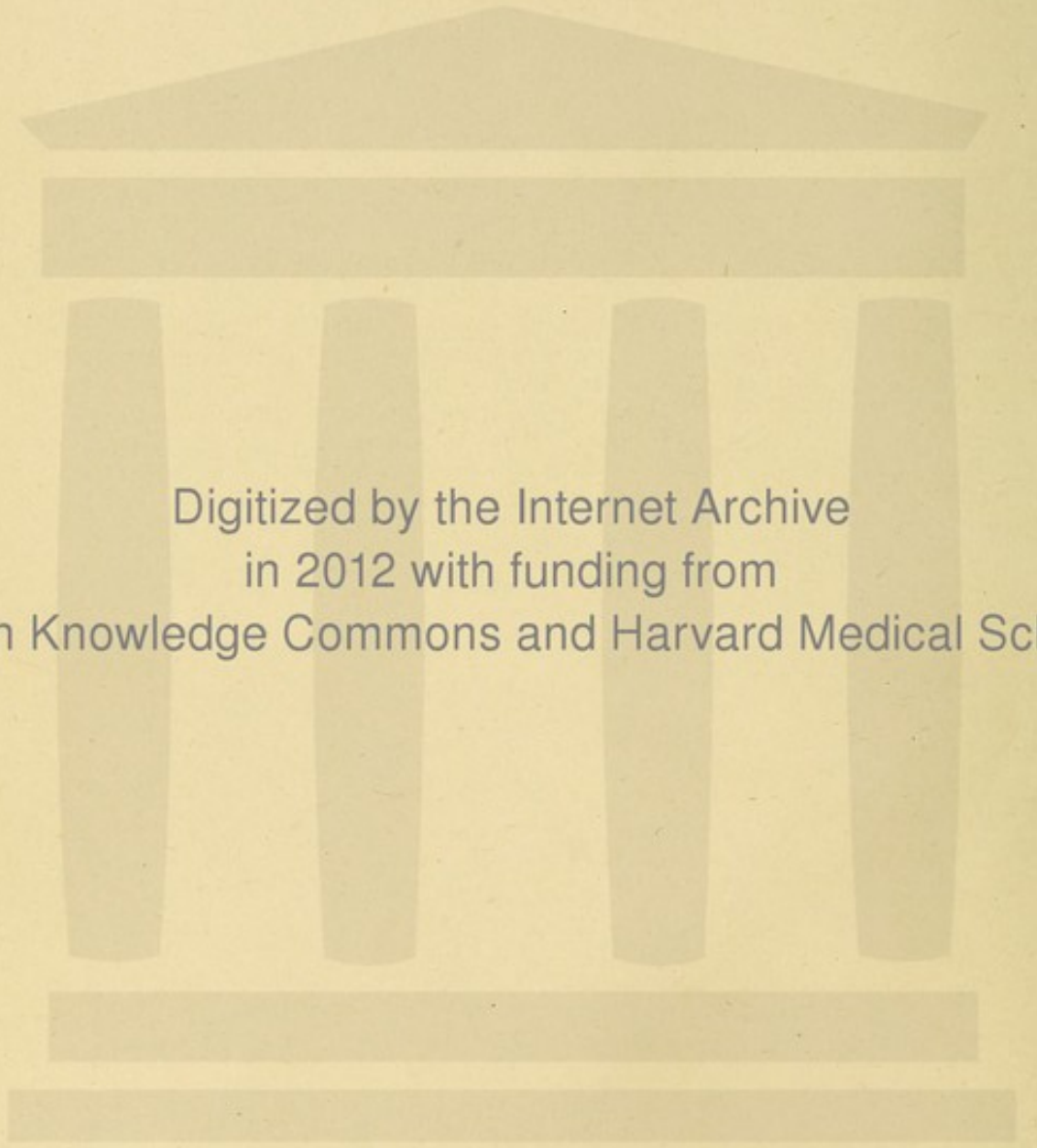

Digitized by the Internet Archive
in 2012 with funding from
Open Knowledge Commons and Harvard Medical School

http://www.archive.org/details/injuriesofeyepra00wrde

INJURIES OF THE EYE

A Practical Handbook of Diagnosis and Treatment with Special References to Forensic Procedures and Visual Economics.

BY

HARRY VANDERBILT WÜRDEMANN, M. D.

Managing Editor *Ophthalmology;* Associate Editor *Ophthalmic Record;* Member of American Medical Association; Chairman, Section on Ophthalmology, 1901; Member Washington State Medical Society; King County Medical Society; Philosophical Society; Fellow American Academy Ophthalmology and Oto-Laryngology; Honorary Member Chicago Ophthalmological Society; Northwest Wisconsin Medical Society; Sociedad Cientifica, Mexico; Formerly Professor of Ophthalmology, Marquette University, Milwaukee: of Ophthalmology, Chicago Eye, Ear, Nose and Throat College, etc.

IN ONE VOLUME

THOROUGHLY ILLUSTRATED WITH ORIGINAL DRAWINGS, PHOTOGRAPHS AND COLORED PLATES

CHICAGO:
CLEVELAND PRESS
1912

28 2036 5

Copyright by the
CLEVELAND PRESS
1911

TO

THE MEDICAL PROFESSION OF AMERICA THIS BOOK IS DEDICATED. MAY THE MEMBERS THEREOF BY THIS MEANS BE SOMEWHAT HELPED IN THE RECOGNITION, ALLEVIATION AND CONSERVATION OF WOUNDED EYES.

Sapere Aude

FOREWORD.

The lack of an authoritative book in the English language upon Injuries of the Eye has been unfilled for a generation. Although the medical journals have been replete with articles, nowhere in American or English ophthalmic literature has the subject been brought up to the requirements of the twentieth century.

This work represents, as far as possible, the personal experience of the author, during twenty-two years in a large manufacturing community where accidents were very common. It is the result of compiling, collecting, writing and lectures delivered upon Injuries of the Eye during this period.

The author does not quote all the literature, for much is hoary with antiquity, but uses such as may elucidate the present aspects of the subject. He has thus restricted his quotations mostly to those authorities who have written during the last decade.

He presents the subject from the practical, clinical and therapeutic standpoint, rather than from the pathological side, but enough of the latter is given for elucidation of any of its phases.

Credit is freely given to other authors, but as the limitations of the English language do not admit of originality in phraseology, where the subject is one of common knowledge, and where his own experience has been the foundation, quotations are not made.

Chapter X, on Radiography, has been written by an expert on this subject, a colleague, Dr. Arthur Morgan MacWhinnie, supervised and edited by the author.

Finally the author has endeavored to present the work so that the reader may find, in most cases a duplicate history and illustration, together with the pathology, medical and operative therapeutics, of every form of ocular accident.

HARRY VANDERBILT WÜRDEMANN.

604-612 Leary Bldg., Seattle, Washington, U. S. A.

SOURCES OF LITERATURE.

The list of journals, books, and separate reprints which the author has consulted is so voluminous that space cannot be here granted for their enumeration. Suffice it to say that during the last score of years they amount to many thousands. No intention has been made in this book to completely cover the literature. Where the author's experiences have not supplied him with illustrative cases, theories, or facts, he has taken characteristic examples from other authors.

Of the separate books on the subject there are but three in the English language: White-Cooper on "Wounds and Injuries of the Eye," in 1859, and George Lawson on "Injuries to the Eye, Orbit and Eyelids," in 1867, both so excellent that it seems that we have been satisfied with them for these many years!

A. Maitland Ramsey, in 1907, published a well-illustrated book covering a portion of the subject, being a reprint of lectures delivered by him before his classes, and addresses before general medical societies.

The ancient literature begins with Fallopius, of Venice, in 1589, followed by St. Yves, Taylor, Scarpa, Beer, MacKenzie, Desmarres, von Arlt, Cooper, Zander and Geissler, up to 1864. Then came Lawson, 1867, Galezowsky, 1872, von Arlt, 1875, Bergmeister, 1880, Yvert, 1880, Vossius, 1884, Hock and Schirmer, 1886, Grand Clement, 1888, Baudry, 1896.

But few references will be found to general text-books on the eye published in America or Great Britain, as this subject is therein treated in a very general way. The text-books of Noyes, Norris and Oliver, Fox and Casey A. Wood are most often quoted.

In American and English literature very many articles have recently appeared, more particularly in the special journals, which are quoted largely from *Ophthalmology;* the *Archives of Ophthalmology;* the *Ophthalmic Record;* the *American Journal of Ophthalmology;* the *Journal of Ophthalmology and Oto-Laryngology;* the *Transactions of the American Medical Association, Section on Ophthalmology;* the *Transactions of the American Ophthalmological Society;* the *Ophthalmic Review;* the *Ophthalmoscope;* the *Transactions of the Ophthalmological Society of the United Kingdom;* and the *Transactions of the Ophthalmic Section of the British Medical Association.*

Of the general journals recourse has been had to the *Journal of the American Medical Association;* the *Medical Record;* the *Medical News;* the *New York and Philadelphia Medical Journals;* the various *State Medical Journals;* and many others. The *London Lancet; British Medical*

Journal; Edinburgh Medical Journal; and others; the various Canadian, Australian, and Indian Journals; the *Transactions of the Pan-American Congress and International Congresses,* etc., have been consulted.

No attempt has been made to refer exhaustively to medico-legal, insurance, and economic literature. The author's previously published writings, more especially Magnus and Würdemann on *Visual Economics,* have been abstracted for this purpose. Protective legislation in America has been largely abstracted from the work of Lindley D. Clark, *Bulletin U. S. Bureau of Labor,* No. 74.

Of publications in other languages the author has liberally quoted and excerpted the magnificent work of Praun, *"Die Verletzungen des Auges,"* 1899, and Wagenmann, *Graefe-Saemisch,* Nos. 176-177-130-134 on *Injuries to the Eye in Reference to Accident Insurance,* 1907-1908, for which he is mostly indebted for literary references to which he has not had immediate recourse; but he may be allowed to say that for a work of this class he has enjoyed exceptional advantages to consult, quote and corroborate his references principally at first hand. The various editions of Fuchs' text-book and hand-book of Graefe-Saemisch, *Jahresbericht* Nagel-Michel, Schmidt's *Jahrbuch,* Haab's, Vossius', and Oeller's *Atlases;* the various numbers of Magnus' *Augenärtzliche Unterrichtstafeln,* Czermak and Elschnig's *Augenärtzlichen Operationen,* Magnus and other writers on *Unfallsbeschädigungen der Augen,* the Separat Abdruck from Giessen, Heidelberg, Berlin, and other German Universities, have been freely referred to.

Among the German journals are the *Archiv für Ophthalmologie, Archiv für Augenheilkunde, Wochenschrift für Therapie und Hygiene des Auges, Klinische Monatsblätter für Augenheilkunde, Zeitschrift für Augenheilkunde, Centralblatt für Praktische Augenheilkunde;* the French are *Archives d'ophtalmologie, L'ophtalmologie provinciale, Annales d'oculistique, La clinique ophthalmologique, Revue general d'ophtalmologie, Recueil d'ophtalmologie;* in Italian, *La clinica oculistica, Annali di ottalmolgia and Bolletino d'oculistica;* in Spanish, *Archivos de Oftalmologia Hispano-Americano* and *Anales de Oftalmologia;* the Holland, *Tydschrift von Geneesk;* and in Polish the *Postep Okulistyczny;* also abstracts from general English, German, French, Spanish, Polish, Oriental, and other foreign medical journals.

ILLUSTRATIONS.

The illustrations are nearly all original; the reader will note the absence of the old, familiar, stereotyped cuts of the text-books. An attempt at uniformity in style and size of the illustrations has been made for the artistic and educational effect.

The colored plates have been drawn directly from patients.

The photographic reproductions of eye sections are all from the author's collection, being reproduced in twice the natural size to show the details. The photographic reproductions of microscopic specimens are from the author's collection, with the exception of nine from photographs loaned by Drs. Tooke and Roy.

The photographs of patients are mainly from the author's practice. They mostly have been made 2x3 inches, as this size shows the general conditions as well as if larger.

A number of illustrations of cases, instruments, and apparatus have been reproduced from recent articles appearing principally in *Ophthalmology* and in the *Ophthalmic Record*.

The drawings are all original, made by the author from actual cases. Those of the anterior portion of the globe illustrating corneal, iridic, and lenticular injuries have been reproduced magnified five diameters, as if seen under the binocular loupe, or with about +20.00 D with the ophthalmoscope, in order to show the details. Where for proper orientation the lids or surroundings have been depicted the drawings are reproduced in the natural size.

TABLE OF CONTENTS.

PART I.

GENERAL INJURIES.

CHAPTER I.

TYPES OF OCULAR INJURIES.

Definition, divisions of the subject.

A. Wounds.

B. Foreign bodies.

Chemical effects of metal and glass within the eyeball.

Siderosis bulbi.

C. Contusions, concussions, ruptures and dislocations.

D. Thermal injuries.

a. Burns, Domestic and industrial accidents.

b. Injuries by glowing metals.

c. Complications and sequelæ.

d. Freezing.

e. Electric burns.

1. Commercial current, Short-circuiting.
2. Roentgen ray.
3. Photo-therapy.
4. Lightning.
5. Sun-light and electric light, Violet light, Tropical light, High intensity, Chemical and heat rays, Glare, Snow-blindness.

f. Burns from acids and alkalies.

1. Acids.
2. Alkalies.
3. Injuries from lime.

E. Combined injuries.

a. Explosions of gunpowder and dynamite.

1. Gunpowder and fireworks, Fire-arm explosions and hunting accidents.
2. Dynamite and other high explosives.

F. Gunshot wounds.

a. Non-perforating injuries, Crushing and contusion, Direct and indirect rupture, Violent concussion of the bony skeleton, Contusions from air pressure.

b. Penetrating wounds.

1. Small shot.
2. Bullets.
3. Particles of shell and other foreign bodies, Wounds of orbit, Injuries during war.

G. Infections.

CHAPTER II.

ETIOLOGY OF INJURIES TO THE EYE.

A. Injuries to the eyes in domestic life.

B. Industrial injuries, Trades in which injuries occur, Etiology of Industrial accidents, Relation of eye accidents to the community, Iron workers, The mote remover, Infections, Glass and bottling workers.

C. The predilection of certain forms of injury for certain parts of the eye.

D. Objects causing ocular injuries.

E. Bacteriology.

CHAPTER III.

THE MECHANISM OF OCULAR INJURIES.

A. The protection afforded by Nature.

B. Disposition of diseased and abnormal eyes to injury.

C. Traumatism as an exciting cause of constitutional eye diseases.

D. Mechanism of special types of injuries.

CHAPTER IV.

COMPLICATIONS OCCURRING DURING AND AFTER OCULAR INJURIES.

I. Infections.

A. Suppurative Infection of the uvea, Panophthalmitis, Infection through corneal cicatrices, Phthisis bulbi, Atrophia bulbi.

B. Irido-cyclitis traumatica, Keratitis punctata, Panel-like keratitis.

II. Sympathetic ophthalmitis, History.

a. Pathology, Rarity of sympathetic inflammation and panophthalmitis, Proliferation, Uveitis and endophthalmitis.

b. Theories of transmission.

1. The ciliary nerve theory.
2. The migration theory.
3. The predisposition and malnutrition theory.
4. The intoxication theory.
5. Criticism of theories of transmission.

c. Conditions of the exciting eye.

1. Sympathetic inflammation.
2. Sympathetic irritation.

d. Duration and incubation.

e. Symptoms and course.

1. Sympathetic irritation.
2. Sympathetic inflammation of the exciting eye.

f. The sympathizing eye.

1. The disease in the sympathizing eye, Clinical types, Irido-cyclitis plastica, Chorioiditis plastica, Irido-cyclitis serosa, Chorioiditis serosa, Neuroretinitis sympathetica, Mixed form or indifferently described cases of sympathetic ophthalmitis.

g. Diagnosis.

h. Prognosis.

i. Prophylaxis.

j. Therapy, Local treatment of exciting eye, General dietetics, Hygienic and medical treatment, Dangerous conservation, Rules for enucleation.
k. Sympathetic ophthalmitis occurring after substitutes for enucleation.
l. Post-sympathetic operation, Treatment of the sympathizing eye and the exciting eye.
m. Sympathetic ophthalmitis after shot wounds in war.

CHAPTER V.

COMPLICATIONS OCCURRING DURING AND AFTER OCULAR IN-INJURIES (Continued).

A. Traumatic glaucoma.
B. Wound infection in injuries of the lids and soft parts of the orbit, Penetrating wounds, Erysipelas, Abscess, Clinical course, Tetanus, Syphilis.
C. Surgical diseases following orbital and lid injuries.
D. Tumor formation after injuries.
E. Traumatic necrosis, Keratalgia, Cicatrix dolorosa, Ciliary Neuralgia, Hysteric blindness.
F. Psychoses, Post-operative mania, Suicide.
G. Errors of refraction produced by trauma, Myopia, Hyperopia, Astigmia.

CHAPTER VI.

OPERATIVE INJURIES.

A. Abrasion of the cornea, Tearing of conjunctiva.
B. Cataract operation accidents and injuries, Loss of vitreous, Infection, Statistics of results obtained, Collapse of cornea, Detachment of chorioid and retina.
C. Propulsive hemorrhage after cataract operation and iridectomy, hemorrhagic glaucoma.
D. Disturbances in healing, Keratitis bullosa, Keratitis striata, Kerato-iritis, Delayed union, Astigmia.
E. Kyanopia.
F. Other operative accidents and dangers, Operation for high myopia, Injury to the lens in iridectomy, Subconjunctival injections, Cautery, Operations on nose and sinuses, Fracture of inner wall of the orbit, Paraffin injections about eye or nose, Spinal anesthesia, Portions of instruments or threads broken off or left in wound, Miscellaneous accidents.

CHAPTER VII.

INJURIES FROM CHILDBIRTH.

A. Fractures.
B. Injuries to the soft parts and the lids.
C. Exophthalmus and evulsion.
D. Paralysis of the ocular muscles.
E. Injuries to the globe, Opacity of the cornea, Rupture of Descemet's membrane, Retinal hemorrhage.

CHAPTER VIII.

INJURIES OF THE EYES FROM ACCIDENTAL OR MEDICINAL APPLICATIONS OF CERTAIN DRUGS, EXCLUSIVE OF ACIDS AND ALKALIES.

Complaints of patients regarding "strong" applications, Ignorance, Idiosyncrasy, Mydriatics, Cycloplegics and myotics, Iodoform, Naphthalin, Argyrosis, Blindness following injection of protargol, Leucoma from subacetate of lead, Methyl violet, Formalin, Potassium permanganate, Miscellaneous.

CHAPTER IX.

DIAGNOSIS OF INJURIES OF THE EYE.

History, Inspection, Eversion of lids and retrotarsal folds, Fluorescein, Magnification, Focal illumination, Ophthalmoscopy, Diaphanoscopy, Ophthalmodiaphanoscopy, Ophthalmofundoscopy, Sideroscopy, Metallophon, Magnets.

CHAPTER X.

DIAGNOSIS (Continued). RADIOGRAPHY.

Value of ophthalmoscope, Dangers following magnet operation, Copper in eyeball, Size of average adult globe and variations, Foreign bodies in anterior surface of lens and iris, Sweet's series of 420 cases, Occurrence of foreign bodies in the right eye of right-handed individuals.

Kinds of X-ray tubes, Position of tube in taking radiographs, Coil of greatest usefulness, Time of exposure, Table of permeability, Position of patient, Fox's method, Sweet's method (improved), Carman's method, Vard Hulen's method, Dixon's method.

CHAPTER XI.

PROGNOSIS OF INJURIES OF THE EYE.

CHAPTER XII.

PROPHYLAXIS OF INJURIES OF THE EYE.

Domestic life, Agriculture, Trades, Safety appliances, Screens, Goggles and spectacles obligatory in Germany, Investigation of injury from protective apparatus.

CHAPTER XIII.

THE CONSERVATION OF THE WOUNDED EYE.

A. General therapy.

B. Asepsis, Preparation for operation, Rules, Sources of infection, Dissection of the lacrimal sac in suppuration of tear passages, Tying off canaliculi.

C. Surgical technique of wound, Cleansing of conjunctival cul-de-sac, lids and surroundings, Lacrimal passages.

D. Surgical treatment of wound, Kuhnt conjunctival flap, Argyrol, Iodoform rod, Cauterization.

E. Infected wounds, Cauterization, Subconjunctival injections.

F. After-treatment, Bandaging, Leeching, Hot and cold applications, Dressings after operations or accident, Mydriasis and analgesia.

CHAPTER XIV.

THE RADICAL TREATMENT OF OCULAR INJURIES.

Radical operations, Enucleation and its substitutes.

A. Indications.

B. Anesthesia for radical operations.
   a. General anesthesia, Ether, Chloroform, Scopolamin-morphine.
   b. Local anesthesia, Cocain, Infiltration anesthesia.

C. Enucleation, Preliminary treatment, Care to operate on the proper eye, Canthotomy, Simple enucleation, Arlt or Vienna method, French method, Author's or American method with pouch suture.

D. Evisceration or exenteration.

E. Mules' or implantation method.

F. Transplantation of animals' eyes.

G. Optico-ciliary neurectomy.

H. Keratectomy or abscission.

CHAPTER XV.

THE PROTHESIS. ARTIFICIAL EYES.

Uses, Statistics of one-eyed individuals, History, Kinds of eyes, Interim prothesis, Manufacture, Socket, Relative movement of eye after abscission, exenteration and enucleation, Sinking in of upper lid, Correction, Care of the prothesis, Method of insertion and removal, Care of the eye, Inconveniences, Dangers, Ordering of the prothesis, Advantages of the Snellen full-backed reform eye.

CHAPTER XVI.

OPERATIONS FOR RESTORATION OF THE CUL-DE-SAC AFTER REMOVAL OF AN EYE.

Fat implantation, Cutaneous adipose graft, Thiersch graft, Paraffin injections, Semi-solid paraffin, Solid paraffin, Ectropion, Plastic operations, Keratoplasty, Autoplasty with and without pedicles, Thiersch and Wolff grafts, Various operations.

CHAPTER XVII.

CONSERVATIVE OPERATIONS. THE REMOVAL OF FOREIGN BODIES FROM THE EYE.

A. a. Foreign bodies in the anterior segment, Cornea, Anterior chamber, Lens.
   b. Foreign bodies within the globe, Dangers of retained foreign bodies, General description.

B. Magnet operations, Constitution of steels, Character of magnets, Hirschberg's, Haab's giant, Victor magnet, Inner-pole magnet of Mellinger, Classification of magnet operations, Rules for giant magnet, Rules for hand magnet, Technic with large magnet, Complications, Precautions, Reasons for failure, Technic with hand magnets, Modifications, results.

C. Removal of non-magnetizable bodies, Powder, Wood, Copper, Glass, Stone, etc.

PART II.

INJURIES TO THE SPECIAL STRUCTURES OF THE EYE.

CHAPTER XVIII.

I. INJURIES OF THE CONJUNCTIVA.

A. Abrasions and wounds, Pathology, Infections, Tuberculosis, Opening of Tenon's capsule, Traumatic conjunctivitis, Occupational, Treatment.

B. Foreign bodies.

C. Ophthalmia nodosa.

D. Injuries by blunt objects.
   a. Conjunctival ecchymosis, Hematoma.
   b. Serous effusion, Edema, Chemosis, Emphysema.

E. Pigmentation of conjunctiva.
   a. Argyrosis.
   b. Siderosis.
   c. Blood pigment.
   d. Methyl violet.

F. Burns and cauterizations.

G. Tumor formation.

H. Injuries from firearms.

II. OPERATIONS WITH THE CONJUNCTIVA.

History.

A. Plastics for defects of cornea, Single and double peduncles, Two flaps, Implantation without flaps, Ulcers, Prolapse of iris, Fistula, Keratocele, Staphyloma.

B. Ocular injuries, Operative Procedures, Temporary covering, Flaps, Lattice suturing, Miscellaneous.

CHAPTER XIX.

INJURIES OF THE CORNEA.

A. Wounds.
   a. Erosions, Abrasions, Indirect Erosion, Symptoms and Pathology, Cicatrix dolorosa.
   b. Non-perforating wounds.
   c. Perforating wounds, Infection, Iritis, Cornea, Staphyloma, Conical Cornea, Fistula, Astigmia, Reopening of cicatrix, Corneal suture.

B. Foreign bodies.

C. Injuries from blunt objects.
   a. Contusions, Infraction.
   b. Rupture.

D. Burns and cauterizations.
E. Gun-shot injuries, Contusions, Perforating wounds, Rupture, Foreign bodies.
F. Changes in cornea following injuries, Healing of corneal wounds, uncomplicated, Complicated, Striate opacity, Edema, Opacities, Clearing of corneal cicatrices, Anterior synechia, Staphyloma, Keratectasia. Keratoconus.
G. Special types of corneal diseases following injury.
a. Keratitis striata, Filaform, Panel-like, Band, Calcareous film, Ribbon, Filamentary, Hemorrhage, Blood-staining.
b. Metallic oxides in the cornea, Iron, Copper, Lead.
c. Cysts.
d. Therapy of complications, Corneal grafting.
H. a. Keratitis traumatica interstitialis.
b. Keratitis disciformis.
I. Suppurative keratitis, Etiology.
a. Hypopion ulcer.
b. Peripheral annular infiltration.
c. Ulcer rodens.
d. Mycotic keratitis, Ulceration.
e. Neuro-paralytic keratitis.
f. Prophylaxis, Cauterization, Chemical and actual, Keratomy or Saemisch section, General constitutional treatment, Subconjunctival injections.

CHAPTER XX.

INJURIES OF THE SCLERA AND CORNEO-SCLERAL MARGIN.

A. Wounds.
a. Non-perforating wounds.
b. Perforating wounds, Complications, Conservative treatment, Ectasia, Scleral sutures, Mattress, Nuel's, Cystoid cicatrix.
B. Foreign bodies.
C. Injuries through blunt objects, Pigment deposition, Posterior rupture, Partial rupture, Rupture of canal of Schlemm.
D. Thermal injuries.
E. Injuries from firearms, Foreign bodies, Contusions and rupture, Direct rupture.

CHAPTER XXI.

INJURIES OF THE UVEA, THE IRIS, CILIARY BODY AND CHORIOID.

A. Wounds.
a. Wounds of the iris.
b. Wounds of the ciliary body.
c. Wounds of the chorioid.
B. Prolapse of the uvea.
a. Prolapse and incarceration of the iris.
b. Prolapse of the ciliary body and chorioid.
c. Operations for prolapse of the iris.
C. Foreign bodies in the uvea.
a. Foreign bodies in the iris, The anterior and posterior chambers, Long-

retained foreign bodies, Siderosis, Silver wire, Shot, Mydsis, Cilia in anterior chamber.

b. Changes in the iris due to the entrance of foreign bodies.
1. Traumatic iritis.
2. Iritis nodosa.
3. Cysts.
4. Granulation tissues of the iris.
5. Sarcoma.
6. Tuberculosis.

c. Foreign bodies in the ciliary body.

d. Foreign bodies in the chorioid.

D. Injuries to the uvea from blows.

a. Iris.
1. Hyphema.
2. Iridodialysis, Direct and indirect dialysis, Objective symptoms, Subjective symptoms.
3. Traumatic aniridia or irideremia.
4. Inversion.
5. Laceration of the sphincter.
6. Rhexis iridis.
7. Dehiscences between pupillary edge and ciliary processes.
8. Pigment dehiscences.
9. Anterior synechia after contusion.
10. Mydriasis and myosis traumatica, Iridoplegia.
11. Atrophy after contusion.

b. Injuries to the ciliary body from blows.
1. Cyclitis traumatica.
2. Accommodation cramp and paralysis.
3. Rupture.

c. Injuries to the chorioid from blows.
1. Hemorrhage.
2. Rupture of the ciliary arteries.
3. Hemorrhagic dislocation.
4. Indirect rupture, Types, Ophthalmoscopic examination, Atypical conditions, Single, Double, Multiple ruptures, Fork-shaped, Horizontal, Large ruptures, Functional disturbances.
5. Direct ruptures.

E. Tumor formation.

F. Injuries from firearms.
1. Iris and anterior chamber, Wounds, Prolapse, Foreign bodies, Contusion, Concussion.
2. Ciliary body, Wounds, Foreign bodies, Contusions.
3. Chorioid, Wounds, Contusions, Rupture.

CHAPTER XXII.

INJURIES OF THE LENS AND ZONULA.

I. Injuries to the lens.

A. Direct wounds and traumatic cataract, Absorption, Complications, Therapy, Medicinal, Atropin, Dionin, Bandage, Iced and hot applications,

Leeches, Operation, Discission, Linear extraction, Extraction and expression, Sympathetic ophthalmitis.

B. Foreign bodies, Etiology, Long retention, Iron, Copper, Glass.

C. Injuries from contusion, Indirect traumatic cataract, Glass blowers, Electric cataract.

D. Thermal and light injuries from electricity, Glass blowers, electric.

E. Injuries to the lens from firearms, Wounds, Foreign bodies, Contusions.

II. Injuries to the zonula and dislocations.

A. Wounds.

B. Lacerations.

a. Relaxation.

b. Partial laceration with subluxation of the lens.

c. Partial laceration without displacement of the lens.

d. Total laceration with dislocation.

1. Complete luxation, Anterior luxation.
2. Incomplete anterior luxation.
3. Posterior luxation.
4. Wandering lens, Complications of lens luxation.
5. Laceration of the zonula and luxation of the lens in rupture of the sclera and cornea, Dislocation under conjunctiva and extrusion from globe.

CHAPTER XXIII.

INJURIES OF THE VITREOUS.

A. Wounds and prolapse.

B. Foreign bodies, Iron in the vitreous, Copper, Lead and glass, Stone, Wood, Coal and other particles.

C. Injuries from contusions, Hemorrhage into the vitreous.

D. Gunshot injuries.

E. Infections.

F. Degeneration following injuries, Opacities, Shrinking, Detachment, Blood staining.

CHAPTER XXIV.

INJURIES OF THE RETINA.

A. Wounds and prolapse.

a. Wounds.

b. Prolapse.

B. Foreign bodies, Iron and copper chips, Dangers.

C. Injuries from blunt objects.

a. Contusions, Commotio retinæ, Berlin's traumatic edema.

b. Traumatic excavation of the macula, Holes in the macula, Spontaneous hole at the fovea.

c. Haab's traumatic macular disease, Electric macular disease.

d. Hemorrhage into the retina and of the retinal vessels, Embolism of vessels, Air embolism.

e. Retinal vessel aneurysm,

D. I. Rupture, dialysis and detachment of the retina.
a. Isolated rupture.
b. Rupture accompanying rupture of chorioid.
c. Accompanying rupture of globe.
II. a. Traumatic retinal detachment, Statistics in myopia.
b. Striæ retinalis, Retinitis striata.
E. Blinding or dazzling.
F. Injuries from firearms.

CHAPTER XXV.

INJURIES OF THE VISUAL NERVOUS SYSTEM, THE VISUAL SPHERE AND OPTIC NERVE.

Medico-legal significance, Amblyopia, Amaurosis.
A. Injuries to the cerebro-visual sphere, Anatomy and physiology, Physical, cortical, psychical, verbal blindness, Gun-shot injuries of the visual centers, Aphasia, Ideographic blindness, Anatomy, Hemianopsia, Statistics.
B. Injuries to the optic nerves, Blindness without direct injury, Tearing of nerve from chiasm, Pressure blindness, Hemianopsia.
C. Injuries to the optic nerve within the optic canal.
a. Wounds and foreign bodies.
b. Hemorrhage.
c. Direct laceration and contusion in fracture of optic foramen, Sequence of symptoms, Optic nerve atrophy, Nature of traumatism, Statistics.
D. Injuries to the optic nerve in the orbit between the foramen opticum and the bulb.
a. Wounds, Ophthalmoscopic signs, Gunshot injuries.
b. Foreign bodies.
c. Injuries from blunt objects, Cubic contents of orbit, Evulsio nervi optici.
d. Gunshot injuries.
E. The ophthalmoscopic signs of injury to the optic nerve.
F. Injuries to the optic papilla, Wounds, Foreign bodies, Optic neuritis after blows on head.

CHAPTER XXVI.

INJURIES OF THE LIDS.

A. Wounds.
a. Incised wounds.
b. Punctured wounds.
c. Stabs.
d. Lacerations and contused wounds, Infections, Erysipelas, Gangrene. Syphilis, Plastic operations.
B. Foreign bodies.
C. Injuries from blunt objects.
a. Extravasation or suggulation.

b. Emphysema.
c. Contusions.
d. Burns and cauterizations.

D. Injuries from firearms.

E. Tumor formation after injury.

CHAPTER XXVII.

INJURIES OF THE ORBITAL CONTENTS, AND WALLS.

A. Wounds.
1. Superficial wounds of soft parts and rim.
2. Deep wounds.

B. Foreign bodies.

C. Injuries from blunt objects.
1. Exophthalmus from orbital hemorrhage.
2. Contusions of the soft parts.
3. Contused and lacerated wounds of the soft parts of the orbital rim, Complications, Inoculation by syphilis, Tetanus, Enophthalmus, Supra-orbital neuralgia, Supra-orbital amaurosis and amblyopia.
4. Contusion and isolated fracture of the orbital margins.
5. Fracture of the orbital walls and the facial bones.
a. Fracture of the roof.
b. Fracture of the outer wall.
c. Fracture of the inner wall, Orbital emphysema.
d. Fracture of the floor.
e. Fracture of the malar bone.
f. Fracture of the superior maxilla.

D. Injuries from firearms.
1. Injuries to the orbital margins, Surgical treatment of fractures complicating foreign bodies, Simple, Complicated, Inner, outer, upper walls, Floor, Zygoma, Old healed fractures, Direct of rim and walls.
2. Injuries to the walls and contents.
a. Roof.
b. Floor.
c. Temporal wall.
d. Inner wall.
e. Injuries from behind.
f. Injuries of contents without injury of the walls

E. Tumor formation in the orbit after traumatism.

CHAPTER XXVIII.

INJURIES INVOLVING THE ENTIRE EYEBALL.

A. Contusion without rupture.

B. Traumatic exophthalmus.

C. Traumatic enophthalmus, Types, Tropho-neurotic, Cicatricial, Mechanical.

D. Luxation and evulsion, Injuries from firearms.

CHAPTER XXIX.

TRAUMATIC DISTURBANCES OF THE MOTILITY OF THE EYE.

I. Muscles.
a. Wounds.
b. Injuries from blunt objects.
c. Secondary disease.

II. Injuries and paralysis of the motor nerves.
a. Paralysis due to lesion in orbit.
b. Base of brain.
c. Cerebral centers.
d. Cases illustrating injury and paralysis of ocular nerves.
1. Abducens.
a. Orbital.
b. Basal.
c. Cerebral.
2. Oculomotor.
a. Orbital.
b. Basal.
c. Central.
3. Trigeminus.
4. Facialis.

CHAPTER XXX.

INJURIES OF THE LACRIMAL APPARATUS.

A. Wounds and dislocations.
B. Foreign bodies, Abscess of gland.
C. Blows from blunt objects, Rupture, Adenitis of gland.
D. Thermal injuries.
E. Tumor formation.

PART III.

FORENSIC MEDICINE.

CHAPTER XXXI.

MEDICO LEGAL.

A. The physical examination of injury cases.

B. The relation between accidental injuries and previously existing, intercurrent, and post-traumatic changes in the eye.

C. The prognosis in medicō-legal cases, The responsibility of the physician.

D. Malingering, Self-inflicted damage, Simulation and aggravation, Hysteria, Previously existing lesions.

E. The physician in court.

1. His rights, contracts.
2. Malpractice.
3. Legal compensation for damage in the United States of America.
4. Measure of damages, Nominal, Substantial or Compensatory, Exemplary, Punitive or vindictive damages.
5 Recent judgments in appellate and supreme courts.

CHAPTER XXXII.

PROTECTIVE LEGISLATION, PENSIONS AND ACCIDENT INSURANCE.

A. Protective legislation.

1. Legal liability of employers, Duties of employers, Place and instrumentalities, New devices, Intended use, Customary methods, Inspection, Ownership of appliances, Hiring co-servants, Rules, Instructions and warnings, Restrictions and employes' rights to recover, Defenses of employes, Assumption of risks, Ordinary risks, Extraordinary risks, Forgetfulness caused by pressure of duties, Contributory negligence, Cause of injury, What negligence bars recovery, Remaining in place of danger, Emergencies, Fellow-servant rule, Common employment, Factors modifying liability, Promise to repair, Contributory negligence.
2. Protective legislation in England.
3. Canadian industrial disputes investigation act of 1907.
4. Summary of compensation acts.

B. Pensions.

1. United States Government.
2. German Accident Insurance Law.

C. Accident insurance, Tables.

CHAPTER XXXIII.

VISUAL ECONOMICS.

Determination of the relation to and amount of economic damage resulting from injuries to the eyes and vision.

A. Status of the physician in relation to estimation of economic damage and indemnity.
1. The proper position of the physician.
2. Present status in Europe.
3. Empiricism and precedent of present judge and jury methods in America and British countries.

B. 1. Methods for scientific estimation of economic damage.
2. Recent comments upon ocular accidents and indemnity.

C. The Magnus and Würdemann method for mathematical estimation of economic damage.
1. Relationship of vision to the earning ability.
2. Economic value equivalent to wages.
3. Factors in economic vision.
4. Estimation of damages to economic vision.
5. The formula of Magnus.
6. Examples.
7. Estimation of the pecuniary loss to the individual by reason of visual imperfections.
8. Examples.
9. Resume.

Afterword.

Index of authors.

Index.

PART I

GENERAL INJURIES

CHAPTER I.

TYPES OF OCULAR INJURIES.

Definition—Divisions of the subject—A. Wounds—B. Foreign bodies— Chemical effects of metals and glass within the eyeball—Siderosis bulbi—C. Contusions, concussions, ruptures and dislocations—D. Thermal injuries—Etiology, a. Burns, Domestic and industrial accidents. b. Injuries by glowing metals. c. Complications and sequelæ. d. Freezing. e. Electric burns, 1. The commercial current—Short circuiting. 2. Roentgen ray. 3. Phototherapy. 4. Lightning. 5. Sunlight and electric light—Violet light—Tropical light—High intensity—Chemical and heat rays—Glare—Snow-blindness—Literature, D. Burns from acids and alkalies. 1. Acids. 2. Alkalies—Literature. 3. Injuries from lime—Etiology and mechanism—Therapy—Literature. E. Combined injuries. a. Explosions from gunpowder and dynamite—1. Gunpowder and fireworks—Etiology and mechanism—Firearm explosions and hunting accidents—2. Dynamite and other high explosives—Etiology and mechanism—Diagnosis—Prognosis—Complications—Prophylaxis and Therapy—Literature. F. Gunshot wounds—Character—a. Non-perforating injuries—Crushing and contusion—Direct and indirect rupture—Violent concussion of the bony skeleton—Contusions from air pressure—b. Penetrating wounds—1. Small shot. 2. Bullets. 3. Particles of shell and other foreign bodies—Wounds of orbit Therapy—Injuries during war—Literature. G. Infections.

Definition.

By injuries of the eye is understood all changes in this organ and adnexa that may be caused by traumatism which may affect its function and appearance through mechanical, thermal, chemical, or electrical forces.

Divisions of the Subject.

We may approach our subject by two methods: By the etiologic or by the anatomic route. Both have certain advantages and are equally important, the one for general and the other for exact description of special cases and their treatment. By such handling of the subject some reiteration will be necessary for clearness, continuity and completeness.

It will be recognized that but few injuries are confined to one membrane or part of the eye, and that injury to one portion may be felt in another, the whole affecting the function or the cosmetics of the organ, and that the injury to sight in many instances affects deleteriously the whole organism, its function, and the place of the person in society.

In the course of our argument we will take up, both under the general headings and the special descriptions, the definition, etiology, mechanism, surgical diseases or infections, diagnosis, prognosis, prophylaxis and therapy of the various injuries.

TYPES OF EYE INJURIES.

(A) Wounds without retention of foreign bodies.
(B) Wounds with retention of foreign bodies.
(C) Contusions, concussions, ruptures and dislocations.
(D) Thermal injuries, including the effects of heat, light, electric and chemical burns.
(E) The effects of explosions.
(F) Gunshot injuries.
(G) Infected wounds.

(A) WOUNDS.

A wound is a solution of continuity, occasioned by extraneous force. Simple wounds of the ocular structures occur only to the lids and lacrimal passages, to the conjunctiva and cornea. Wounds of the sclera, of the lens, iris, and ciliary body and deeper structures occur through the cornea and anterior chamber, or through the conjunctiva and sclera.

Complicated wounds of the orbit pass first through the lids or the eyeball to the contents of the orbit, the lacrimal glands, the orbital fat, extra-ocular muscles, Tenon's capsule, the nerves and blood vessels, and the optic nerve; these may be further complicated by simultaneous injury to, and resultant disease of, the bony walls of the orbit, the contiguous sinuses, and the cerebrum.

A clinical classification of wounds of the eye is: Anterior wounds through the cornea, lateral wounds through the ciliary region, and posterior wounds through the conjunctiva and sclera. These wounds are also characterized as non-penetrating and penetrating, depending upon whether the eyeball be opened or not. As to their nature they may be incised, pierced, flapped, lacerated, contused, and infected or poisoned. The entrance of micro-organisms causes infection; bites and claws of animals, beaks and claws or talons of birds may produce special infective disease, and the bites of serpents and stings of insects may give rise to a chemical poisoning. The retention of foreign bodies and the effects of concussion and heat further complicate such injuries.

We may likewise differentiate clean cut and piercing wounds from those whose edges are lacerated and bruised. To the first group belong the incisions, stabs, and flap wounds; to the second the contused, lacerated, and bite wounds. Firearms and explosions cause both forms of injuries,

and in addition to the wound there is concussion and burn as well as retention of foreign bodies. These wounds may or may not be accompanied by a loss of tissue, and may be characterized by the formation of a flap.

Perforating wounds are those in which the ball is opened, by which the aqueous or vitreous is tapped. Non-perforating wounds are those in which the external tissues are injured, but the eyeball is not penetrated. This differentiation is of importance, as the possibility of infection is greater by a perforating than by a non-perforating wound.

In practice it is necessary to note the length, breadth, and depth of wounds, their form and direction, and if or not accompanied by loss of substance. In shape the wounds may be linear, fork-like, bow-, sickle-, or flap-like; in direction, perpendicular or tangental to the surface of the globe. Their position relative to the pupil and the limbus should be estimated. Their character, whether cleanly incised, torn, bruised, or infected, and in the case of fine piercing wounds the direction of the canal should be noted.

(B) RETAINED FOREIGN BODIES.

Foreign bodies occur in the lids, orbit, ocular tissues, and within the ocular globe. In the special chapters we shall treat of those in the individual ocular structures.

It is of the greatest importance clinically to determine whether or not an injury be complicated by the retention of a foreign body. Until the advent of aseptic surgery the removal of an eyeball so injured was deemed imperative, and eyes in which a foreign body had been retained a long time without causing blindness to the injured eye and sympathetic disease in the other were looked upon as pathologic curiosities.

Until the use of the magnet for the removal of magnetizable objects was taken up it was the rule to enucleate such injured eyes, and until the advent of the X-ray a definite diagnosis was in most cases impossible.

Thus in former years many eyes were sacrificed to the bugbear of sympathetic ophthalmitis, and others were allowed, through ultra-conservatism or through ignorance and neglect, to go on to sympathetic disease and blindness.

Only an aseptic and chemically indifferent body can be retained in the globe without causing irritation and inflammation. Feebly chemical substances, as iron, copper, glass, and stone, may cause but slight local exudation and become encapsulated, but contraction of the new-formed tissue, with further changes in the anatomical relations of the structures, ultimate in opacities and dislocations, interfering with vision or causing blindness.

It is also possible from the irritation and proliferation of tissue cells

that a foreign body may be carried away from its original position of impaction and be spontaneously extruded.

A foreign body to be retained within the globe must have been aseptic and have carried no germs with it in its passage, and tolerance of the tissues must have developed. The chorioid and ciliary body most easily become irritated, the vitreous and retina next, but the lens is specially tolerant, for it is derived from epithelium and mostly composed of albumen, tolerating foreign bodies as well as other epithelial structures.

The size and shape of the foreign body have much to do with its retention, small, rounded intruders being tolerated much more readily than large, sharp, or pointed objects. The length of time in which a foreign body has been retained and the longer it remains, the greater the possibility of full tolerance being reached. The chemical nature of the particle is of importance. Inert substances are not apt to cause irritation.

Chemical effects of metals and glass within the eyeball.

Leber[1] experimented by placing organic and inorganic substances under aseptic precautions in rabbits' eyes. Among these were the following: A piece of gold wire remained 269 days in the anterior chamber without causing reaction; gold and silver in the vitreous for a year did not cause any inflammation, but proliferative changes in the retina and vitreous with partial atrophy of the nerve elements resulted. Such substances are very slowly acted upon by the tissues, but may ultimately become absorbed. Glass may remain in the anterior chamber for a long time, but becomes dull and the edges rounded, and if in the vitreous it may ultimately cause changes in the nerve elements of the retina.

Iron and steel in the anterior chamber soon become rusty, are covered by fibrin and discolor the tissues. In one case a needle point remained 527 days in the cornea, causing, however, rust and stain in this location. Iron particles are well tolerated in the lens, but color it by rust. Iron particles in the anterior portion of the eye do not cause hypopion formation. In contradistinction to the effects of iron in the iris and anterior chamber are the severe changes produced in the vitreous and retina, where a hyalitis and shrinking of the vitreous occurs from the irritation, with ultimate siderosis, detachment and atrophy of the retina from the formation of an iron carbonate caused by the combination of the albumen of the tissues and the oxide of iron from the rust, causing chemical irritation.

Kipp[2] writes that he has seen cases in which the cornea was stained brownish for some distance around a fragment of iron which had been lodged in it for weeks, but never from iron located in the lens or deeper

in the eye. The change in color of the iris was seen only in cases in which the yellowish-brown dots arranged in the form of a wreath under the anterior capsule of the lens were present at the same time; both a yellowish-brown and a greenish-brown discoloration were observed, but the first more frequently. A similar discoloration appears after hemorrhage into the vitreous and sometimes after such in the anterior chamber. The yellowish-brown discoloration is of greater practical importance. Round, less than mm. diameter, yellowish-brown spots appear at intervals of a mm. or two, in a circle, in or about the capsule of the lens. There are often spots on the anterior capsule, situated nearer to the anterior pole—the remains of broken posterior synechiæ. The spots behind the capsule are seen only after nearly ad maximum dilatation of the pupil. They are repeatedly seen in eyes in which the lens was still transparent and in which the capsule has not been ruptured. In all cases in which they are present iron is found back of the lens. He does not hesitate to operate if these appearances exist, together with discoloration of the iris, if both Roentgen ray and sideroscope are negative.

Among other symptoms of siderosis bulbi are ochre coloring of adhesions between iris and lens, spontaneous mydriasis, subluxation, torpor of retina, concentric contraction of the visual field and defective color perception. (Also Haab's macular disease.) In all of Kipp's cases the iron had entered at least six months before. The first appearance of the outward signs of siderosis varied greatly.

Copper particles give rise to even more severe chemical reactions. Pieces of copper put into the anterior chamber of rabbits' eyes cause a local purulent exudate so that within twenty-four hours they become fully covered. If removed the eye recovers, so it is not a microbic but a chemical purulent process. After a while the severe inflammatory process ceases, but hypopion forms, the cornea ulcerates, and the foreign body is extruded, or the particle becomes enveloped by a fibrinous capsule. Copper chips in the lens cause opacity, but are tolerated therein. This difference is due to the copper going into solution in the aqueous and not being absorbed so rapidly when in the lens. Copper in the cornea does not cause reaction as within the globe. Copper particles in the vitreous act like iron, leading to necrosis and detachment of the retina.

Hirschberg[3] says that copper in the conjunctiva and outer layers of the eye is not dangerous. Usually small splinters are seen and are readily removed. In the iris the splinter usually sticks into the lens and offers no difficulty in removal.

Copper particles have remained in the lens for months and years without causing full clouding, but a sudden swelling with formation of cataract later occurs. Removal with the lens is indicated. When in the

vitreous copper particles usually cause acute suppuration, seldom chemical irritation, and proliferation of the connective tissues. The eye is usually lost and has to be removed.

In the fundus the changes are due to purulent inflammation as in the vitreous, seldom with connective tissue formation and detachment of the retina.

LITERATURE.

1. Leber, Die Entstehung der Entzündung und die Wirkung der entzündungserregenden Schädlichkeiten, Leipzig, 1891.
2. Kipp, *Amer. Journ. Ophth.*, Aug., 1906.
3. Hirschberg, *Deut. Med. Woch.*, No. 14, 1894.

(C) CONTUSIONS, CONCUSSIONS, RUPTURES AND DISLOCATIONS.

The effects of blunt force upon the eye.

Injuries from large and blunt objects produce contusions, concussions, and ruptures, with dislocation of the ocular structures, in contradistinction to those from sharp or pointed objects which cause wounds. The effect of these may be local, upon one or more tunics or structures, but as a rule affect several of the tunics or tissues. In wounds the injury is produced directly by the object, but by blunt force the effects are both direct and indirect. In the former the effect is directly upon the structure impinged, in the latter by transmitted inertia or counter-stroke, due to a rebound of the globe from the orbital tissues or its walls.

According to Gussenbauer[1] Contusions express themselves pathologically in three grades. In the lighter forms there is more or less tearing of the perivascular tissues of the finer structures. In the medium forms this is combined with laceration of the inter-cellular substance, and in the severe forms with destruction of tissue and breaking of blood vessel walls. Pathologically these injuries are expressed by changes in the vessels and tissues. In the lighter forms by changes in the tunics of the vessels, and in severe types by interruption of the contiguity and continuity of the blood vessels and tissues.

Paralysis of the vaso-motor nerves with edema of tissue with transudation from the vessels occurs; in severe cases accompanied by bleeding into the structures, rupture of continuity, and dislocations.

The lighter grades of paralysis of the vaso-motor nerves are followed by edema, as shown in commotio retinæ, and in paralysis of the pupil and accommodation. Various authors have likewise attributed these pathologic conditions to bleeding within the tissues, but the edema about the nerve endings is sufficient to explain the paralysis. The pupil does not fully dilate to atropine or contract to eserine after contusion. Disturbances of the circulation give rise to opacification of the lens after the capsule is broken. Bleeding follows severe contusion; in the lids

causing severe ecchymosis or suggulation—the ordinary "black eye;" in the orbit a blood-tumor; under the conjunctiva ecchymosis; and in severe types a hematoma or blood tumor.

Bleeding from the iris or within the anterior chamber is called hyphema. In rare cases the blood extravasates within the corneal lamellæ. From the retina the blood may show in the vitreous or as a subretinal hemorrhage. From the chorioid as a subretinal or a subchorioidal hemorrhage, in the latter case producing discoloration of the chorioid and retina.

In Concussion the transmitted force jars the structures, disassociating the connections of the elements. In Rupture there is also solution of the continuity of a tissue or structure.

Rupture occurs most often to the ocular capsule, especially the sclera, less often the cornea, then the chorioid, iris, and but seldom the ciliary body or zonule. The chorioid is often affected alone, but sometimes in connection with the retina. The iris may be torn away from its insertion, producing irido-dialysis, or more seldom radial tears, here causing sphincter paralysis and mydriasis. Isolated tears of the retina seldom occur. The optic nerve or its sheath may be thus torn when atrophy results. Rupture of the zonula allows of dislocation of the lens, and here the hyaloid membrane is also usually broken.

Dissassociation of the continuity of the intraocular structures occurs, the most common of which is detachment of the retina and partial or complete luxation of the lens. But this form of accident likewise occurs to the chorioid, vitreous, and iris. Dislocation of the entire globe occurs only from direct force, as in gouging.

LITERATURE.

1. Gussenbauer, ref. Praun, l. c. p. 11.

(D) THERMAL INJURIES.

Burns, flame, glowing metals, hot fluids, solar, electrical, lightning injuries and freezing.

These injuries come so largely under the heading of general injury to the eyes, affecting as they do several structures at once, that they are discussed in full under this heading, additional references being made under the anatomic chapters.

Etiology and classification.

Such injuries are comprised under the title of burns, scalds, chemical and electrical destructions of tissue, caused by dry and moist heat by the effect of chemical irritants or electricity in its various forms, as well as injuries from the sun and lightning.

Most of such injuries affect the skin of the face and lids primarily,

with or without the implication of the globe. Those of the skin may be divided into the classical forms of burns:

First Degree—Hyperemia of the skin.

Second Degree—A superficial inflammation resulting in the formation of vesicles.

Third Degree—Partial or complete carbonization of the part.

We may further classify these forms of injuries under the heading of burns which are caused by substances raised to a high degree of heat, scalds by heated fluids, and cauterizations caused by the entrance of chemical substances within the eye or on the eyelids. These injuries almost invariably involve the face and lids as well as the eye, and vary from trivial burns of the first degree to those causing destruction of tissue with subsequent loss of function and disfigurement.

a. Burns, domestic and industrial accidents.

They may be divided into those occurring mainly in domestic life, and which are largely caused by heated fluids, such as boiling water, soap, fat or lard, which are as a rule not serious and confined to the skin of the lids and outer coats of the eye; and industrial accidents occurring in trades. Burns from flame occur largely from furnaces and gas ranges, and occasionally as the result of an explosion. They are usually only of the first degree, as the patient is able to get away speedily from the cause, although occasionally more serious injuries are met with. The eyelashes and brow and hair are usually involved, but seldom the cornea. The lids close so quickly and thus protect the globe so that few of such cases afford serious burns of the globe. Burns from bursting boilers and steam pipes and hot liquids used in the arts afford more serious cases. Hot blasts of air from furnaces or fires are found both in domestic and professional life.

Besides these casual factors, occurring in domestic life, there are burns from lighted ends of cigars, cigarettes, shreds of tobacco blown from pipes; the ends of sulphur matches, heated curling irons. One might go on to detail a number of cases of superficial injuries from heated water or soup getting into the eyes, but these are inconsequential. Accidents from the blowing up of boilers of steam engines, if they do not kill, sometimes give rise to great disfigurements when the steam comes in contact with the face and eyes. Although we read of such cases constantly in the newspapers, yet I have seen but one such case and that some years after the accident, when ectropion and leucoma of the cornea was the most pronounced effect to be observed. As a rule such cases are attended by wounds of the face, eyelids and globe, and are treated under the subject of explosives and wounds.

A mild case of burn from flame may be perhaps duplicated by every physician. A householder opened the door of his furnace, whereupon the gaseous flame shot out, burning his hair, face, lids, and searing the epithelium of the cornea superficially. Cleansing by soap and water, boric acid solution, dionin, and a bland ointment secured a recovery in forty-eight hours.

An extremely severe case was as follows: A janitor opened the furnace door, when the flames shot out, producing a burn of the third degree on the left side of his face, destroying one eye which I had to enucleate, the subsequent ulceration laying bare the base of the skull, which was covered by Thiersh grafts, he making subsequent recovery,

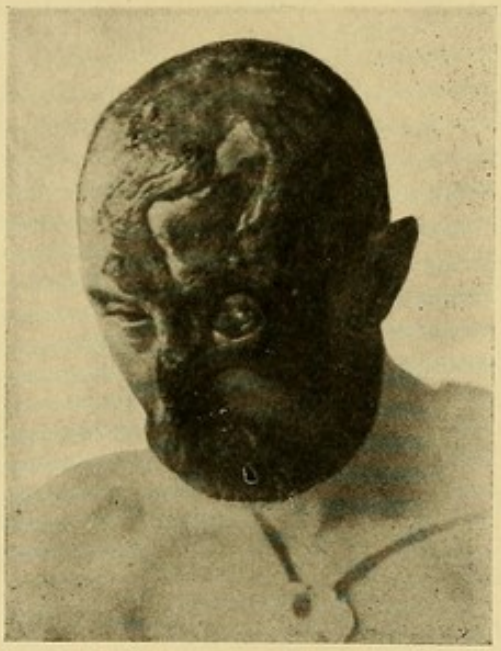

Fig. 1.
Severe burn of eyes, face and scalp from burning gas.

with one eye and a badly seared countenance, under 5 per cent picric acid application.

Holocausts at theaters, such as the horrible Iroquois fire in Chicago and at the San Francisco earthquake and fire, and railway accidents afford more serious cases which, however, do not live to exhibit their scars and the results of treatment. Many such extensive burns of the face, as a rule are fatal, as they are usually complicated by injury elsewhere.

The therapy of facial burns belongs to the general surgeon. Aside from gunpowder explosions it consists of the application of carron oil, or 5 per cent picric acid, to the burnt skin. Treatment of the eyes is as directed under treatment of burns by acids.

The complications and sequelæ of burns vary from infection (which is considered elsewhere), contusions, wounds or injuries to parts of the

eye with loss of function, and require operations of various forms on the lids, conjunctiva, cornea, iris and lens which may have to be made for relief of sight or cosmetic injuries. (See special chapters.)

A serious case of domestic injury from fluids was a boy who was watching his mother making jelly. The boiling jelly was spilled and spattered into his face and eyes, producing corneal erosion, followed by extensive leucoma. V=objects; improved later by massage and dionin and high frequency electric treatments.

b. Injuries to the eyes by glowing metals, particularly glowing iron, slag, solder and lead.

Etiology and Mechanism. Masses which have been subjected to great heat during the process of manufacture—i. e., in industrial injuries from coal and iron, molten lead, heated pitch or tar.

Physicians living in a manufacturing community will occasionally be consulted in regard to injuries happening from the splashing of solder in the case of plumbers; from glowing iron and slag in the case of metal workers. At first sight it would seem that such injuries must necessarily be very severe, taking in conjunction the effect of the foreign body and of the intense heat. But as a rule injuries received from such substances are of moderate severity for the reason that they remain in contact with the parts but a fraction of a second, and during that time there is interposed between the glowing melted metal and the part upon which it falls, a thin stroma of watery vapor which arises from the skin or the eye, and materially protects it by reason of the physical law that "rapid evaporation produces cold."

Ferrier[1] explains this by the physical phenomena of calefaction, the tissues being separated from the metal by a sudden evaporation of the fluids on the surface of the eye, and are no longer exposed to the heat, which cools off rapidly in the case of metals as lead, zinc, tin and antimony, which fuse at a low temperature.

Burns by iron dross, wrought iron, fused brass and steel, slag and glass, however, whose temperatures are above 1000° C., are ordinarily quite deep and lead to loss of the eye or extensive cicatrization.

The foreign body as a rule falls off the eyelids or out of the eye immediately. A marked example of this physical phenomenon is the fact that a person can plunge his hand into a pot of melted lead and withdraw it without receiving an injury. A story is related by the present Emperor of Germany that he was told by his tutor that this could be done, and as he had supreme confidence in his advisor, he immediately tried it and without injury.

I have a number of times attended eyes injured by splashing of molten lead or iron, the damage of which was confined to a trivial burn

of much less severity than would have happened from the same amount of boiling water getting into the eye. In the eye clinic and in the polyclinic at Giessen, Germany, during eight years there were 106 persons treated for injuries of the eye produced by glowing metal, which was 0.37 per cent. of the whole number; of these there were 65 by glowing iron; 7 by fluid lead or zinc; 34 by glowing slag. The latter were much more severe than the former, because the glowing slag sticks to the place of impact, retains the heat longer and thus causes a more deeply penetrating combustion and necrosis. Almost all patients could pursue their former occupations, but a considerable number—i. e., 9 of the burns from glowing iron and 12 of those from slag—were totally blinded on the injured side; in only one case was the vision of both eyes much injured. In 33 per cent. of injuries from iron and 45 per cent. of injuries from glowing slag, pterygium, local cicatricial symblepharon, entropion, trichiasis or ankyloblepharon occurred. Quite a number of patients injured from glowing slag had to give up their former work and rely on their accident insurance.

Superficial combustion of the corneal epithelium by hot iron, cigars, etc., may heal without the least impairment of sight, as the nutrient vessels which supply the cornea are not usually injured. It is noted that even if the cornea be not injured a purulent chorioiditis may develop when the conjunctiva and sclera are burned as far as the limbus. Very severe burns of the sclera may lead to purulent affections of the uveal tract and vitreous and terminate in panophthalmitis.

In my own work I do not see so much damage from melted metals as I do from hot chips of iron which may have a high temperature when they strike the face or eyes, and as these usually strike with considerable velocity, there is added to the effect of their burning powers the damage done by the force of the blow, which is usually of more moment than the burn. The fact that the foreign body is a heated one usually makes the injury aseptic, and such wounds go on to more favorable resolution than others where the blow is received from a more or less dirty instrument. Of course, many workmen immediately take their dirty handkerchiefs, upon which they have blown their noses, wiped their hands or polished objects, and apply it to the part and thus infect with naturally deleterious consequences what might otherwise have remained an aseptic wound.

A plumber came to me with a moderate burn of bulbar and tarsal conjunctiva and eyelids, stating that a few hours before he had upset a pot of solder, some of which had splashed in his eyes and face. A large piece had been picked out of the corner of his eye by a fellow workman and he had brought the piece to me for examination. This was found to be three-quarters of an inch long and weighed about four grams,

it was curved and fitted the side of the nose and between the aperture of the lids. The injury was comparatively trivial, involving but a superficial burn of the skin of the nose and of the conjunctiva immediately under the cornea and that of the lower lid. A few beads of solder clinging to the lashes of the lids were picked off without difficulty. Healing took place within a few days under boric acid wash and iodoform ointment.

A worker at the Bay View rolling mills, one of the largest in America, came with an injury to the eyelids and eye from molten iron metal which had spurted into his eyes while he was pouring the same into a mold. This adhered firmly into the charred tissues, but was removed in part by a fellow workman and in part by a physician to whom he immediately applied. The latter described the appearance of the foreign body to be as sticking between the eyeball and the lids, but when I saw the case resolution had almost entirely taken place and only some adhesions between the globe and lower lid resulted, which did not cause any great deformity or occasion much inconvenience.

A man from the C., M. & St. P. R. R. shops came to me with a severe burn of the eye and both lids, with perforation of the sclerotic, he having been struck a few hours before in the right eye with a piece of rivet which he was hammering while hot into the side of a boiler; this cut both lids and the sclerotic over the insertion of the external rectus. The burn, however, was comparatively trivial and the injury was mainly confined to the wound of the lids and sclerotic; the latter was stitched, while the lid wounds coapted nicely, and both healed with resultant normal appearance and good vision.

A man employed in the Milwaukee Street Railway shops came to me with severe injury to the eye from a large, hot steel fragment. While welding rails his co-workman knocked off a piece of the welding rail, which struck his eye, cutting the lids, cornea and sclera; the piece remained in the eye and was removed by the company's surgeon, he being sent immediately to me, whereupon I stitched up the wound and sent him to the hospital, but was obliged to enucleate the eye within a couple of weeks on account of resultant inflammation.

C. A. Oliver[2] describes a case of evisceration of an eyeball by a single mass of heated metal. A fellow workman, while striking some red-hot chisel forging, dislodged a piece 2 centimeters long, 1 7/10 centimeters wide, and 7/10 and 5/10 of a centimeter thick, which flew with great violence into the eye of a bystander, completely destroying the cornea, iris, lens, and vitreous. The edges of the eyelids were badly burned. The remaining sclera was excised and the eyelids were repaired by skin grafts. Repair was uneventful and rapid.

Cases of accidents of this character might be described by the doz-

ens, but such are sufficient to show their relations. The majority of such cases, however, are better described under the subject of Penetrating Wounds of the Eyeball. From the fact that they have been subjected to intense heat, they are usually aseptic unless the workman himself or some other person has infected them by means of a dirty pocket handkerchief, pen-knives, dirty water, or other tools or applications used to treat the wound before the surgeon is consulted.

c. The complications and sequelæ.

Burns vary from the common infection, contusions, wounds or injuries of other parts with loss of function to cicatricial changes in healing causing severe deformities of the lids and face.

T h e r a p y. Treatment of cases that involve simple burns consists in immediate removal of the foreign bodies, antiseptic washes, preferably of boric acid or weak sublimate solution, holocaine, dionin, vaseline or iodoform vaseline, iced compresses at first to subdue the swelling arising from the immediate effects, hot compressing afterwards to stimulate nutrition of the injured parts; atropine may be used in severe injuries to open the pupil, and holocaine and dionin for the relief of pain, general analgesics, such as morphine, may be necessary. The lids must be kept from growing to the eyeball by passing a probe and the interposition of ointment, and sometimes general anesthesia is necessary for this procedure; if such occurs or if cases are seen afterwards, surgical methods may be necessary for the relief of the subsequent deformities and adhesions.

LITERATURE.

1. Ferrier, Soc. d'anat. et physiol. de Bordeux, 1883.
2. C. A. Oliver, *Ophthalmoscope,* Apr., 1907.

d. Freezing.

Freezing of the eyes or even the lids occurs but seldom. The blood supply is so rich and the parts so sensitive that the patient quickly protects them from further exposure. Even Arctic explorers, while reporting freezing of the cheeks, hands and feet, and farmers on the great plains, do not seem to have suffered such injury to the eyes, and there are no cases reported in ophthalmic literature.

The nearest approach to such a case that I have seen is in the person of an Indian girl who as an infant of a few months was left exposed for several days and nights in below zero weather on the battlefield of Wounded Knee, some twenty years ago. At present writing she has maculæ of the corneæ, but this, although ascribed to an ophthalmia resulting from the exposure, may more likely be due to the usual form of

infection. Praun,[1] however, says the cornea has been frozen during life.

I have, however, seen gangrene of the lids produced by continuous iced compresses applied at the order of an embryonic oculist for about one week in a case of a small girl with ophthalmia.

LITERATURE.

1. Praun, l. c. p. 11.

e. Electric burns.

Etiology and Mechanism. Burns from electric flashes usually obtain from short circuiting, are due to the burning of iron instruments and are becoming more common. They are of the same character as ordinary burns and are treated in a similar manner. Electric light flashes may likewise produce a burn of the macula, the light being focused by the refractive media of the eye strongly upon the macula and thereby destroying the retinal elements. These always cause irreparable damage to vision.

1. The commercial current.

The electric current is attended by thermic effects which, if of sufficient severity, burns the lids and hairs, then causes katalytic changes in the albumen of the tissues, later causing changes in the nutrition of the lens and cataract through changes in the tonicity of the vessels. (Praun.[1])

Rout[2] makes the point with Terrien that these ocular troubles are the result of intense light at a short distance, and not of the short circuit through the patient's body. The absence of progression of the opacities, which are partial cataracts, and mostly confined to the anterior capsule, is noteworthy. The changes consist of linear and punctate spots scattered over the surface, being capsular and non-capsular, the posterior surface being free from opacities.

It is not the ultra-violet rays nor the ill-defined action of the heat, but a special electrolytic action that produces the opacities. The intense irido-ciliary hyperemia following causes osmotic interchanges between the vitreous and the lens, and the current produces, as shown by Hess,[3] a sub-epithelial albumic degeneration of the epithelium, followed by penetration of aqueous, changing the aqueous so that it is unfit for osmosis. Still another hypothesis is that the current acts traumatically.

Symptoms. Externally combustions at the places of entrance and exit, edema of the lids, conjunctivitis and chemosis are noticed. Haab[4] saw a slight milky opacity of the whole macular region and along the upper border of the fovea numerous whitish-yellowish spots of irregular

form and various sizes, with corresponding defects of the visual fields. The affection healed. In no other case are changes of the macula mentioned, perhaps due to the fact that patients consult the physician after the development of opacities of the lens.

Lundsgaard[5] reports two cases of injury to the eye by a short circuit. The first case was that of a motorman of an electric car; he lost consciousness for a few moments; his vision was diminished three or four days, when it was improved, but the eye was very sensitive to light and watered readily. About four months later his vision diminished to 1/x. In the interior of the eye, white streaks, like folds of retina, and maculæ of various colors were seen on the temporal side of the papilla; later on detachment of the retina with headaches and sensitiveness over the supra-orbital region made their appearance.

In the second case the short circuit caused a singeing of the hair of the head and of the ciliæ; a small opacity in the center of the right cornea, of the size of a lenticule, made its appearance, and it could not be colored with fluorescein.

Ellett's[6] patient received a shock from a direct flash, but in an hour his vision was 20/lx, which in a few days came up to 20/xx. Three months later V.=20/cc. Small white spots in lens beneath capsule. Two months later it was entirely opaque.

Desbrieres and Bourgg's[7] case was that of a workman who received the discharge of an alternating current of 20,000 volts. In the lens there were patches of opacity consisting of numerous spots scattered over the surface. Visual acuity 8/x, although patient saw objects as if through a mist. A year later there had been no change. (As stated, this absence of progression is a characteristic of electrical cataracts.)

In Le Roux' case[8] a man was shocked by a current of 2,800 volts. In addition to burns and loss of consciousness there appeared, after three months, a cataract of the left eye which went on to full maturation. The right eye was not affected.

These cases may be trivial, as in the following:[9] A workman was fixing a dynamo with a pen-knife which made a short circuit, causing a large spark with intense light, which not only superficially burned the lids but the intense light disorganized the retinal elements of the fovea. Regeneration with restoration of vision did not take place for several weeks thereafter.

A more severe case has been seen by me—the same being first reported by Stillson.[10] A man, age 19, one year previously had received an electric shock from an alternating current of 30,000 volts. The current entered his left temple, leaving a scar at points of entrance and exit. He was rendered unconscious. Examination showed cloudiness of anterior portion of each lens resembling small dust particles just un-

der the anterior capsule. I saw this case twenty-six months after the accident, when the scar of left temple and the capsular cataracts had apparently further advanced. The sore on the leg had healed under skin-grafting. V.R.=6/xv, with —0, 25, 90°=6/xv. L.x 6/ix with +0.75, combined with 0.75, 90°=6/ix. Visual fields full. Fundus normal. The appearances on ophthalmoscopic, and especially focal, illumination were characteristic. There were seven small, dense-white, punctate spots under the capsule, and a diffuse cortical annular opacity of the true lens substance in the right eye. In the left, the capsular opacity was an irregularly-shaped central mass, quite apparent on superficial examination. The opacity of the lenticular substance was of the same character as that of the right. This case was awarded $16,666.00 damages in the superior court of Seattle.

Stillson quotes Karibuchi.[11] who produced such changes in the lens experimentally, observing that the current caused sub-epithelial albuminous coagulation, followed by degeneration of the neighboring fibers and penetration of the aqueous through the capsule.

De Haas[12] describes a workman who had his face burned by a strong electric spark through a short circuit. Eyelids swollen, conjunctiva red, perception of light in one, blind in other eye. Five weeks after accident corneal opacities, disks white, V.=5/x, L. 5/xxx. Visual field narrowed, contracted, no color vision on one side. Seven weeks later further atrophy. V.=3.m, L. 0.5. Much photophobia.

2. The Roentgen rays.

The Roentgen ray produces an erythema dematitis which is to be avoided by current dosage, shields, grounded screens, proper regulation of exposure, state of tube. The dermatitis in some cases is destructive and has produced severe ulceration and cicatrization, ectropion and entropion. No damage to vision has been reported, as well as no damage to the operator from the use of fluorescein screens. The action of the rays is culminative. (Monell.[13])

Alphonse[14] made experimental researches on the influence of Roentgen rays on the lens of three groups of guinea pigs, rabbits, and dogs: 1. On pregnant. 2. New-born. 3. Full-grown animals with an exposure of from three to ninety minutes. The anatomical and histological changes are given in detail, with the following resumé: More or less degeneration of the capsular epithelium and the cortex, which was most marked at the equator and the posterior cortex. Active processes of regeneration in the epithelium of the lens with formation of cell complexes, "pseudo-epithelial strata," and degenerative changes in the new-formed tissue.

These typical changes may be due to damage to the epithelium and

cortex as a direct consequence of the radiation. This is more marked at the equator and the posterior cortex, as here probably the youngest elements are more exposed. The proliferation of the epithelia may be from direct irritation of the cells by the rays, and may be an attempt at self-healing.

Roentgen rays are injurious for the lens of the young and adult animals. Exact relations between radiation and biological action cannot be established. Generally it may be said that Roentgen rays are more detrimental the younger the cells are. It is a well-known fact that the cells of the lens up to the highest age possess the functions of growing cells with formative power, and have not only nutritive tasks. These investigations confirm the pernicious influence of Roentgen rays on young cells by proving that the lens elements of the full-grown animals are also subject to it.

Alphonse further observed the inhibitory action of Roentgen rays on the growth of the eye, orbit, teeth, etc.—i. e., on the young tissues.

Burns by static machines are reported. (Monell.[13])

Conjunctivitis and incipient retinitis may be produced from X-rays. Operators subject to long-continued exposures suffer from irritability of the eyes which may develop into inflammation with sufficiently intense exposure.

Sherer[15] reports such a case in a physician who had been daily exposed to the action of the X-rays for three and a half years. He first suffered from photophobia and eye-fatigue. Later conjunctivitis developed. The histories of several similar cases have been given. (Read also our report of case exposed to intense arc-light in section on Phototherapy.)

The obvious protection for operators using X-rays and finding trouble with their eyes is the same as that employed in phototherapy. The chemical rays are nearly stopped by plain clear white glass, and the physician who does not wear glasses for visual defects can avoid irritation during X-ray work by wearing a pair of large plain glasses without focus.

William Rollins[16] mentions numerous cases of permanent injury to the eyes, and even blindness due to X-rays, and details the extreme precaution to be taken by operators. This applies to radium rays and also to the violet and ultra-violet.

Birch-Hirschfeld[17] reports the anatomical findings in an eye which had been exposed to prolonged radiation during the treatment of carcinoma of the temple with the X-ray. The principal changes were degeneration of the endothelium and vacuolization, solution of chromatin, shrinking of the nuclei and cell degeneration. The cells were especially marked in the macular region, where there was pronounced cystoid de-

generation. There were no signs of inflammation. He reports other cases, and says that in animal experimentation he noted the slow development of such changes.

Selenkowsky,[18] also in experiments with rabbits, has demonstrated the danger of excessive or careless use of the X-rays.

3. Phototherapy.

Monell[13] says this has produced no deleterious effects on the eyes, but slight "running" has been observed.

4. Injuries from lightning.

Injuries to the eyes have been observed after lightning strokes which caused superficial burns of the lids and cornea with singeing of the hairs and the face. Gruening[19] says cataract is not an infrequent result which has been attributed to electrolytic action similar to that which produces curdling of the milk in a storm. He thinks, however, it is due to the irido-chorioiditis from injury and is a secondary consideration. In the case of lightning stroke or severe electric shock some of this may be directly due to the severe jarring of the entire body. Birch-Hirschfeld[17] says the cataract from lightning is not due to glaring, but to a mechanical lesion of the lens, and the glass-blower's cataract is not merely caused by ultra-violet rays, but also by other elements. From his investigations in the regulation department of factories of arc-lights, he never found cataract and contends that the dangers of acquiring cataract by frequent glaring through short-waved light is very slight. Cataract has never been observed from mere glaring by lightning or short circuit.

I have seen several cases of cataract produced by lightning, of which the following is a type: A young woman was standing under a tree in a pasture during a thunderstorm. The tree was struck and the electric spark traveled to her head, rendering her unconscious, burning the left side of her face and a streak along the body to the feet, which showed ten years later in reddish-colored scar tissue. When I saw her at that time the left cornea had a macula, both eyes had peculiar, spotted, anterior capsular cataract (similar to the illustration depicted under electric flash), with zonular radiations. V.R=movement of objects, V.L.= fingers at 3 m. She had learned to read despite this poor vision. I extracted both lenses with resultant good vision, 6/xx and 6/xii with correcting lenses.

Another case in a young man there was no scarring and the lightning had caused cataract in one eye only. Accident three years before. Expression operation of cataract was done with resultant vision 6/vi.

Pfahl[20] reports nine cases. In all injuries through lightning the patients lost consciousness, and showed, except one, organic lesions for

some time after the accident. In five the eyes were affected; disturbances of the circulation of the disc, extravasation of blood into the cornea, insufficiency of accommodation, sensitiveness to light; in one case detachment of the retina. He urgently advises early examination of the eyes in all cases of injury from lightning and electricity.

Ayres[21] reports a case in which there was pain in the eye and eyelids; the latter were red, swollen and edematous. The upper half of the cornea was hazy; there was no iritis and no abnormal tension. Cold applications and cocaine were ordered. Two days later there was deep injection of the scleral vessels and adrenalin was prescribed. Three days later leeches were applied and these relieved the pain which cocaine and hypnotics failed to do. The swelling of the lids subsided and the cornea cleared up. A month later the vision was practically perfect.

Hilbert[22] records two instances of injury to the eye from lightning flash occurring to two fellow telegraph workmen who, during a storm, sat by their instruments and were stricken by the lightning entering the wires. Both were of middle age. The one was rendered unconscious for about ten minutes, and when seen by the author on the following day complained of headache, pain in the limbs, vomiting, of a blinding sensation and of lacrimation. Examination showed merely a mild catarrhal conjunctivitis. All of the symptoms except the pain in the limbs rapidly subsided.

In the second case, when the lightning entered the instrument the patient's entire visual field was filled with "fire;" this was followed by dilation of the pupil, which was sluggish. There was haze of the cornea, ciliary injection and stony tension. Subjectively there was pain and halos. Under pilocarpin the condition subsided in the course of a few weeks.

5. Injuries from sunlight and electric light.

The action of the sun's rays and of electric light is at first a thermic change of the outer portions, later followed by chemical and atrophic changes which destroy the finer structures of the rods and cones of the retina with resultant atrophy, even to the percipient cells of the brain. These cause disturbances of function from opacities of the cornea or media, to destruction of the retinal cells, the fibers of the optic nerves and tracts, and atrophy of the visual centers. (Parsons.[23])

The *Medical Review* is quoted by Sisson[24] as stating that Fermè has found "that exposure to the sun's rays produces symptoms of many diseases which persist for days after the exposures. This congeries of symptoms seems not very formidable, yet it induces the author to conclude, from the observed coincidences of meteorological conditions and certain diseases, that exposure to the sun's rays is a predisposing factor

in coryza, influenza, hay fever, and epidemic meningitis. A curious element is the fact that only 53 per cent. of the persons under experiment found the exposure disagreeable, while the others, notwithstanding the subsequent ill effects, enjoyed it."

Violet light.

Schanz and Stockhausen[25] show that ultra-violet rays produce erythropsy and electric ophthalmia. There is a tendency to constantly increase the intensity of the light by this amount of ultra-violet rays, and the injurious effect of artificial light is also increased.

Common glass, out of which the eye-glasses and lamp globes are made, absorb only the very short rays (0-300 u.u.) ; these rays, however, do not penetrate the eye; they produce only irritation of the external parts of the eye. Rays of 300-350 u.u. in length are absorbed by the lens; rays 350-400 u.u. long cause fluorescence of the lens and reach the retina.

The authors were able to make a glass (euphosglass) which absorbed all ultra-violet rays up to 400 u.u. and the visible spectrum became dimmer only 5 per cent.

Their investigations show that the greatest amount of light that the human eye can stand is a surface brightness of 0.75 of a Hefner candle to the square centimeter.

Experimenting with the ultra-violet or chemic rays, Stroebel[26] found that the media of the eye allow them free passage. It is possible with them to induce a circumscribed inflammation of the retina. Under their influence the iris became hyperemic, inflamed and pigmented, but it is stated that the iris is able to exclude their influence from the deeper tissues.

C. Hess[27] tried the effect of the uviol lamp upon the lens and found degenerative changes in the epithelium of the lens capsule, with proliferation of the cells near the equator. These changes were observed in frogs, rabbits, guinea-pigs, and monkeys. While the degenerative changes did not set in more rapidly in the warm-blooded animals than in the cold-blooded ones, in the former they seemed to be followed by more active proliferation of the cells. The author discusses the bearings which these observations have upon the etiology of glass-blowers' cataract. He thinks it possible that the long exposure of the eyes of these men to rays of short-wave length leads to degeneration and proliferation of the cells of the lens capsule; that ultimately the degenerative changes are not able to keep pace with the degenerative processes, and so cataract formation begins. He observed that the changes described above did not appear when an ordinary sheet of glass was placed between the animal and the lamp, and so he suggested that glass-blowers' cataract might be prevented by suitable spectacles.

Tropical light.

Woodruff[28] states that eye diseases cause 15.47 admissions per 1,000 to our sick report in the United States, but in the Philippines it is 18.89. In speaking of the effect of tropical light on the eyes, he says: "We have a disease in the tropics similar to snow blindness, but it is mild, as we never have the great radiance from the ground, such as we receive from the snow. We also have an affection similar to vernal conjunctivitis, which, of course, is merely a mild form of what, in winter, we call snow-blindness. In both extremes of temperature, then, either the arctic cold or the tropic heat, it is due to the light, and we can have every conceivable grade of the affection, from simple conjunctivitis to paresis of the optic nerve and retina (night-blindness), or paralysis and atrophy with permanent blindness. I have examined a case of chronic pigmentary retinitis due to exposure to excessive light in the tropics and a severe case in a signal officer due to work with sun's rays in the heliograph mirror in the United States Army."

He also says that hemeralopia is often due to overstrain from excessive light, and it is not uncommon in the spring in northern climates when the sunshine becomes intense. He has seen limited epidemics of it in volunteers in the Philippines, and it occurs in our Southern States among the badly nourished. Press reports apparently indicate that in the recent British invasion of Thibet many soldiers were stricken with snow-blindness—a country where the natives are so brunette. In Manchuria the same conditions are said to confront the Russians, for the snow-glare is so fierce that even the yellow native is sometimes affected, and the need for smoked glasses for the Russian soldier is receiving attention. The Japanese, on the other hand, seem to be amply protected by Nature.

Birch-Hirschfeld[17] opposes the statement of Best, that the ultra-violet rays of our artificial sources of light are perfectly irrevelant for the eye, and maintains that, besides the luminous, the ultra-violet rays may injure the retina, not only in intensities which can only be employed in experiments, but also under ordinary conditions. The smoke-colored coquilles are sufficient for most practical purposes, but not the blue ones, which Best ranks in the same order, not only because their absorption of short-waved rays is less than that of the smoke-colored, but also because they transmit the very active luminous blue rays. He says the authors who attribute senile cataract to the detrimental influence of ultra-violet light go much too far, lacking any proof. The etiological part of ultra-violet rays in inflammations of the anterior segment of the eye (ophthalmia-electrica) is undoubted. For the disturbances of the retina (central and peri-central scotomas, impairment of color sense), through glaring by lightning, short circuit, arc light, light of mercurial vapors, etc., besides the ultra-violet rays between 400, 350,

and 330 mm., the violet and blue rays play a part, as well as in erythropsia. Against this former opinion Birch-Hirschfeld opposes the one-sided view, that only the ultra-violet rays be detrimental to the eye.

High intensity chemical and heat rays.

Monell[13] says the following involuntary contribution to a physiological study of high intensity chemical and heat rays was reported from Niagara Falls, December 29, 1901. Compare the intensity of action of Finsen's seventy-ampere arc, giving 40,000 candle power, with this arc of 350 amperes at 220 volts giving 308,000 candle power, the highest on record.

In the Furnace Company's works a method of burning holes in "salamander" with an electric arc was substituted for the usual and slower drill. The carbon was six feet long and two inches in diameter; the rheostat was immersed in a barrel of running water to keep it cool; when the current of 350 amperes at 220 volts was turned on an arc was made that could be extended to six inches, and the light equaled about 308,000 candle power. It was equal to 160 street arc lamps. Everyone who looked at the arc for even a very few minutes had a severe inflammation of the eyes with the exception of two men who wore plain white glass spectacles, and they suffered no inconvenience whatever, although one of them looked at the light a great deal.

Sisson[24] says every now and then a physician has to call attention to the damage done to babies' eyes by exposing them to brilliant sunlight. We find the modern mother actually strapping the poor little sufferer into its carriage and torturing it with the direct rays of the sun pouring down into the face. A short exposure to diffused light, the head being shaded from the direct rays, might be allowed, for this stimulation is undoubtedly beneficial.

Some physicians contend that our school-rooms, which are modern "light-baths," explain the headaches and nerve storms which the children have after a few hours' exposure, as well as errors of refraction.

Glare.

J. Herbert Parsons[23] says that the fundamental point of glare is physiological, it being largely an uncomfortable sensation. There is a wonderful adaptability of the eye to varying degrees of light, and if conditions are favorable small print can be read with ease by strong or feeble light. It has been demonstrated by experiment that the sensitiveness of the retina to impressions of light can be very greatly increased by protecting the eye for a time. This sensitiveness reaches its maximum in about half an hour after an eye has been bandaged so as to exclude all light, a glimmer of light being recognized then that could

not be seen under ordinary conditions. On the other hand, exposure to bright light lessens the sensibility of the retina. This constant variation in the sensibility of the retina is termed retinal adaptation and it serves a most useful purpose. When the retina is very sensitive, as in dark adaptation, bright light produces discomfort and even pain. The condition of adaptation of the retina, therefore, must be considered an important factor in the production of glare, although it is not the only one.

The effects of glare may be classified under two groups. In the one the effects are slight and of brief duration; in the other they are more severe, last longer and may even be permanent. With moderately intense illumination dazzling results, which, while it produces discomfort and if continued too long even pain, does not cause any serious trouble. The pain is due to excessive action of an inadequate protective mechanism. In the second group of cases the serious effects are usually due to the intensity of the stimulus, which often is exceedingly rapid in its action, as when a powerful electric current is short-circuited.

The visual defects caused by intense stimulus are of different grades. When the blurred spot is quite transient it may be considered physiologic, while if the intensity of the light was greater or of longer duration the blurred spot persists and may last permanently, when it is known as a scotoma. These scotomata are associated later with anatomical changes in the retina—pigmentation in the macular region, etc.—when they are caused by the greatest degrees of intensity. Such conditions are not infrequently found in cases of visual defects following observations of eclipses of the sun with unprotected eyes. Prolonged exposure to the sun at sea and in the tropics is sometimes followed by night-blindness. As these cases present in a marked degree the effects of retinal exhaustion they are of considerable interest.

Sisson,[24] Kreibich,[29] Dimmer,[30] Schieck[31] ascribe spring catarrh to the effects of the sun's rays.

Prophylaxis and Therapy. The question as to the protection of the eyes against the evil effects of short-waved light cannot be unconditionally answered as long as we are not sufficiently familiar with this. It greatly depends upon the kind of light. If this contains an abundance of intense ultra-violet rays, as the arc lamp, mercurial vapor lamp, etc., globes of euphos glass are recommended, the intensity of the blue and violet rays must be subdued by yellowish-green or frosted globes, or by indirect illumination. If these precautions are not feasible, persons exposed to these lights must wear protective glasses of euphos glass (which for the absorption of violet and blue rays must be made darker), enixanthos or Hallauer glass, which also suffice for tours on glaciers and as protection against snow-blindness. Against light which contains

less ultra-violet rays (daylight, sunlight on plains), amethyst, amber or smoke-colored are better than blue glasses for sensitive and diseased eyes.

Snow-blindness.

This condition is more particularly an ophthalmia produced by the action of light on the skin of the face, lids, conjunctiva and cornea, though it has been ascribed as well to irritation of the retina from prolonged exposure to light.

L. Webster Fox[32] says: "There is no definite period of exposure; persons going out well in the morning have returned snow-blind at night. The pain is aggravated by heat of any kind. Wet compresses (neither extremes of temperature) afford most relief. Blacking of the skin of and around the lids has been found superior, in some cases, to

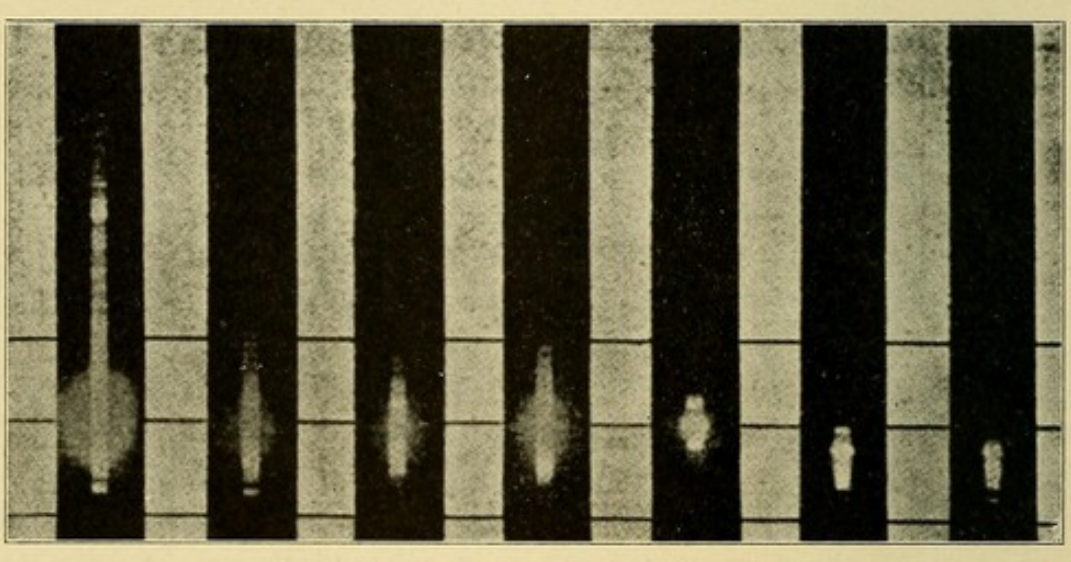

Fig. 2.
Absorption of Light of Electric Arc. (Schanz and Stockhausen.)
1. Open light, 5 sec. exposure. 2. Clear globe, 10 sec. exposure. 3. Opal globe, 1 min. exposure. 4. Frosted globe, 5 min. exposure. 5. Red-violet glass, 10 sec. exposure. 6. "Euphos" glass, 10 sec. exposure. 7. "Euphos" glass, 20 sec. exposure.

any other kind of protection." I have myself observed that cow-punchers and plains workers often blacken the face around the eyes in winter and in summer to prevent this form of ophthalmia.

Best[33] says the results are summed up as follows: The erythropsia after exposure to snow is the consequence of glaring by luminous rays, as well as the diminution of the red-green sensation after glaring and the destruction of the retina by direct sunlight. The sun can be fixated, for ten seconds, through an uviol glass, 3 mm. thick, without damage to the eye, whereby the whole of the ultra-violet radiation of the sun acts upon the retina, as far as it can reach it. The ultra-violet rays under 400 mm., under general conditions of life, are perfectly indifferent to the

retina, while the luminous rays in excess may damage the retina. The possibility to produce cataract by momentous concentration of ultra-violet rays does not prove anything for the chronic injurious effect of ultra-violet rays, assumed by some authors. The percentage of ultra-violet rays in modern sources of light is irrelevant (except while working in direct proximity of electric arc light, in which the deleterious influence of the quantity of light is prevalent). Distressing symptoms in working under bright artificial sources of light are the consequences of faulty ar-



Fig. 3.
Goggles for snow blindness used by the native Alaskans and prospectors. (S. Mitchell[34]).

rangements (indirect illumination, avoiding too strong contrasts between dark and light).

Prophylaxis. Wearing tinted glasses, especially euphos and amber, effectually prevents this affection. The Eskimos and Alaskans wear goggles with a horizontal slit, made from white pine wood and blackened on the inside. An interesting observation regarding this has been made by Arctic explorers.

Stradler[35] finds that there is a corneal lesion in cases of snow-blindness, which corresponds to the size of the palpebral aperture when the lids are almost closed from the glare of the bright light. This corneal lesion he describes as a sort of sunburn of this corneal epithelium. It

is very likely to be overlooked unless fluorescein is used, when this narrow area across the cornea will be found to have taken the stain.

Diagnosis. From the blepharitis and conjunctivitis, with history of exposure.

Prognosis. Complete recovery.

Therapy. The therapy is prophylactic, consisting in the use of amber, amethyst, or even plain glass protecting spectacles. In Alaska wooden goggles with slots or holes in them, the inside blackened, are much used for snow-blindness. Cowboys black a space under each eye with wood charcoal, which is an effective protection. Treatment of the conjunctivitis is by mild astringents, boric acid, zinc, cold compresses; of the retinitis by rest and protective glasses.

LITERATURE.

1. Praun, l. c. p. 394.
2. Rout, *Arch. d'ophtal.*, Nov., 1904.
3. C. Hess, *Pathology and Therapy of the Lens System.* 1905.
4. Haab, Beitr. z. Aug. xxii; p. 8, 1888.
5. Lundsgaard, *Wien. Med. Woch.*, Feb. 2, 1907.
6. Ellet, *Ophth. Record*, Jan., 1906.
7. Desbrieres and Bourgg, *Ann. d'oculist.*, Feb., 1905.
8. Le Roux, *Arch. d'opht.*, Aug., 1909.
9. Würdemann, *Ophth. Record.*
10. Stillson, *N. W. Med.*, Feb., 1907.
11. Karibuchi, ref. Stillson.
12. De Haas, *Tydschr. v. Geneesk.*, Feb. 24, 1906.
13. Monell, *X-Ray Methods and Medical Uses of Light, Hot Air Vibration, and High Frequency Currents*, 1902.
14. Alphonse, *Arch. F. Aug.* lxiv, 3, 1909, p. 277.
15. Sherer, *N. Y. Med. Jour.*, Sept. 21, 1901.
16. Rollins, Wm., *Elec. Rev.*, Jan. 5, 1898.
17. Birch-Hirschfeld, *Zeitschr. f. Aug.*, May, 1909.
18. Selenkowsky, *Arch. F. Aug.* lx. 1, 1908, p. 63.
19. Gruening, in *System Dis. of Eye*, Norris and Oliver, 199 p. 718.
20. Pfahl, *Deut. Med. Woch.* No. 29, 1908, p. 1267.
21. Ayres, *Amer. Journ. Ophth.*, Apr., 1907.
22. Hilbert, *Woch. f. Ther. u. Hyg. d. Aug.*, Feb. 27, 1908.
23. J. H. Parsons, *The Lancet*, Jan. 22, 1910.
24. Sisson, *Ophthalmology*, Jan., 1909.
25. Schanz and Stockhausen, *Woch. f. Ther. u. Hyg. d. Aug.*, Oct. 3, 1907.
26. Stroebel, *Ophth. Yearbook*, 1904.
27. C. Hess, *Arch. f. Aug.*, May, 1907.
28. Woodruff, *Effect of Tropical Light on White Men*, 1908.
29. Kreibich, *Wien. Klin. Woch.*, 1904, p. 1459.
30. Dimmer, ref. Sisson
31. Schieck, *Klin. Mon. f. Aug.*, May, 1909.
32. L. Webster Fox, *Textbook of Ophth.*, 1910, p. 299.
33. Best, *Klin. Mon. f. Aug.*, May, 1909.
34. S. Mitchell, *Ophth. Record*, March, 1900.
35. Stradler, *Ophth. Record*, Nov., 1908.

D. BURNS FROM ACIDS AND ALKALIES.

1. Acids.

Sulphuric, hydrochloric, nitric and acetic are the most common acids that lead to injury to the eyes.

Etiology and Mechanism. Villard[1] experimented with rabbits. Commercial sulphuric acid was dropped into the open eye, which was washed immediately afterward under the tap. Sixteen of the rabbits were killed from three hours to one hundred days after the experiments. The findings were classified under four heads: First, the stage of chemical fixation; second, the stage of leucocytic reaction; third, the stage of ulceration and corneal perforation; and fourth, the stage of cicatrization and reparation.

The first stage is characterized by death of the cellular elements of the cornea, with a swelling of the corneal lamella similar to that which is noted in the laboratory when connective tissue is treated with acid. From the earliest hour, therefore, the cornea is deprived of active life, although it retains its shape.

The second stage shows invasion into the cornea, the anterior chamber and the iris by leucocytes, which may also infiltrate the eyelids. The subepithelial layers are especially involved, while the destruction of the epithelium increases in abundant and mucopurulent discharge.

In the third stage corneal perforation occurs, not as in ordinary cases, however, but from destruction of the corneal tissues by the acids. The lips of the ulcer are swollen and infiltrated by leucocytes, while from the limbus there is an advance of rapidly multiplying epithelial cells. The palpebral epithelium is replaced by epithelium of the pavement type. The subepithelial area is deeply infiltrated by leucocytes.

In the last stage, or stage of cicatrization and reparation, the corneal opening may be closed by protruding iris, over which epithelium from adjacent conjunctiva has grown. In other cases the opening may be closed by a union of the lids to the border of the ulcer—i. e., if the latter is peripheral and not too broad. Finally, in advanced cases, or in those in which the tissue loss has been great, the perforation may be closed by a complete union of the palpebral lips to the remains of the eyeball.

Ovio[2] states that burns with acids are less dangerous than with alkalies. Ammonia is an exception to this rule. One drop of nitric or sulphuric acid is sufficient to destroy the eye. A drop of sulphuric acid with an equal quantity of water causes an indelible cloudiness. Caustic potash has a more powerful action than acids. Diluted with water it still destroys the eye.

If the burn be only of the first degree, speedy resolution may take place, but if the true skin be affected or the cauterization extend deeper, suppuration may take place, and the resultant healing is then attended by great disfigurement from scar tissue which produces severe ectropion, and if the eye be not destroyed, leucoma of the cornea at last, or symblepharon, may result, necessitating plastic operations later for partial

restoration of the defects. In some cases there is a complication of the injury from cuts due to breakage or explosion of the vessel containing the acid.

Burns from acids largely affect the skin of the face, lids, conjunctiva, and cornea, and may be so deep as to involve the sclera. Such may be followed, as in the case of lime burns, by leucoma or even destruction of the globe. As a rule more extensive cicatrices form, leading to great cosmetic damage and loss of function from symblepharon, entropion, and ectropion.

Trivial cases need not be described. Serious ones are apt to be

Fig. 4.
Sulphuric acid burns of face and eyes. (Vail).

complicated by wounds from bursting of glass vessels, as in the following:

A professor of chemistry in one of the High Schools in Milwaukee was changing metallic sodium from a jar to another which was supposed to contain naphtha, which must have been mixed with water, for an explosion took place, burning his face, hands, and clothes. The lids and cornea were burned by the flame to the first degree, the whole of the corneal epithelium came away, but several days later was completely restored. A number of bits of glass were removed from the face and one from the orbit. Complete recovery with good vision.

A physician was examining urine in the laboratory when a bottle of dilute acetic acid from a shelf above was knocked over, falling on his

head. The bottle broke, the acid staining his clothes but not badly burning his face or lids. One upper lid, almost torn away, was sutured by a physician, later by me, with good cosmetic results.

I have recently been obliged to enucleate an eye which was blinded many years ago from explosion of a glass vessel containing vitriol, which produced great disfigurement of that side of the face and ectropion, which was partially relieved by an operation done by the elder Snellen in Copenhagen forty years ago.

Photographers and workers in acids sometimes complain of smarting of the eyes and conjunctiva from the effect of the fumes of acids used



Fig. 5.
Cicatricial contraction of skin, lids, and orbit following sulphuric acid burn. (Vail).

in their trades. These can hardly be classed under the head of injuries, but may be mentioned in passing.

Physicians and chemists have at times burned their eyes by flakes of corrosive sublimate, acids, or other corrosive chemicals getting into their eyes in mixing preparations or in the laboratory.

Of forensic importance are those injuries caused by homicidal intent or to mar the countenance of some lover or hated person. The most important of these are injuries from sulphuric or nitric acid (vitriol), the favorite weapon of the jealous woman against the beauty of her rival. This naturally produces extensive destruction of the soft parts and, when entering the eye, may destroy it. At any rate, disfigurement is always

produced, depending upon the amount of acid touching the parts and the length of time it is allowed to remain.

I have seen and attended three cases where vitriol was thrown into the face with criminal intent. This resulted in one in moderate degree of disfigurement from ectropion, and partial blindness from leucomata of both corneæ, in the others total blindness with great disfigurement of face, and almost total closure of the palpebral tissues followed.

Vail[3] reports a very extensive burn of the face from half a pint of sulphuric acid having been thrown into a young man's face by a woman. There was extensive cauterization of the second degree of the skin of face and lids. Right eye completely destroyed. Complete symblepharon despite treatment, the lids growing completely shut. Ectropion of lower lid of left eye, corrected by Arlt's operation. Extensive leucoma of the cornea to inner half. V.=20/xxxv; later with +6, cyl. 170° V.=20/xx.

Kramsztyk[4] has seen two cases of sulphuric acid burns of the eye clinically, and in each the conjunctivæ were at first much involved, the cornea remaining clear. A few days later the cornea was broken down, the result, the author believes, of the destruction of the conjunctival vessels.

2. Alkalies.

Soda and potash lye and ammonia are the more common strong alkalies.

Stieren[5] reports four cases in which either the vapor or water of ammonia was accidentally forced into the eye, causing in each instance severe pain which soon subsided. The corneæ were clouded, wholly or in part, remaining the same for several days, then gradually became more and more opaque until becoming chalky white. One case went on to staphyloma. Only one case recovered without total corneal opacity. The treatment consisted in the use of atropine, hot fomentations, subconjunctival injections of salt solution, olive oil by instillation between the lids. In the one case that recovered, dionin only was used. The author believes that ammonia causes an occlusion of the canal of Schlemm and the spaces of Fontana. Interchange of fluids into the cornea is sometimes checked, and a dense chalky deposit results.

Alonzo[6] reports a burn with caustic potash that produced myopia from general weakening of the tissues.

The deleterious action of ammonia on the eye is due to its affinity for water, which is extracted from the tissues, and to the formation of an albuminate. Thus the molecular structure of the epithelium and the upper layer of cells are destroyed so that they become necrotic. The dead tissue, as foreign body, causes an inflammatory irritation of the

deeper tissues. This may be aggravated if the ammonia gas, as from exploded ice engine, strikes the eye under high pressure, or if watery solutions of a higher temperature are squirted into the eye.

Denig[7] discusses the concentration of ammonia solution, the time of exposure, and the extent to which the cornea is affected. He reports cases of Trousseau's of injuries by the gas, two of Abadie's, all ending in blindness, and three observed by himself, caused from explosion of liquid ammonia in an ice factory. In one case the inflammation disappeared after eight days, in one the cornea was seriously damaged, and in one vision was destroyed. The clinical histories show how grave even slight injuries of the cornea are, and may prove more serious in the course of the disease than at first expected. For the treatment flushing the eyes with water is recommended. A chemist injected a solution of magnesia dust into the eyes of an employe after an explosion of ammonia, with the result that the eyes were well three days later.

The Diagnosis will be made from the history and character of the burns.

The Prognosis depends upon the amount of destruction of tissue, the length of time the acids or alkali were in contact, the degree of the cicatrization of the conjunctiva and lids producing symblepharon, entropion, and ectropion, the formation of leucoma of the cornea.

If the cornea be injured a diffuse haziness develops or purulent sloughing with perforation, complicated by iritis and hypopion, sometimes ending in panophthalmitis. A very protracted course is characteristic, and the apparently at first benign prognosis may become very doubtful, as the inflammation of the iris and cornea may set in very late. Therefore anesthesia and haziness of the cornea are very ominous signs.

Therapy. a. Acids. First the use of large quantities of water to wash away the excess of acid, neutralization of the remainder by instillations of alkaline solution, bicarbonate of soda or potash, lime-water or milk; iced compresses followed by hot compresses; after this a bland ointment such as 5 per cent iodoform in vaseline or carron-oil (equal parts of linseed oil and lime-water) may be used for dressings and the case treated on general principles. Dionin in 5 to 10 per cent. solutions at first for pain, later in powder form to assist in the absorption of scar tissue, for which thiosinamine may be used as well in 10 or 20 per cent. ointment or given t. i. d. internally. Atropinization to keep pupil open and prevent iritis.

b. Alkalies. Similar to that of acids, except, if seen within a few moments, dilute acetic acid may be first used to neutralize the alkali. Pichler[8] recommends immediate paracentesis of the cornea in

ammonia injuries, as experiments show that soon after the injary ammonia is found in the aqueous.

LITERATURE.

1. Villard, *Arch. d'opht.*, June, 1904.
2. Ovio, *La clin. oculist.*, Aug., 1905.
3. Vail, *Cincinnati Lancet-Clinic*, May 31, 1902.
4. Kramsztyk, *Arch. d'opht.*, Nov., 1904.
5. Stieren, *Ophth. Record*, Nov., 1904.
6. Alonso, *Ann. de oftal.*, June, 1903.
7. Denig, *Zeitschr. f. Aug.*, xl, 1904.
8. Pichler, *Zeitschr. f. Aug.*, Apr., 1910.

3. Injuries from lime.

Etiology and Mechanism. Injuries from lime are of great importance; contrary to the usual belief, the injury is not caused by the heat of the lime, for the effect of slacked lime is quite as disastrous. It is a chemical burn followed by infiltration of insoluble calcium into the tissues. Such are usually combined with other foreign bodies, as the impaction of sand from the mortar in which it is usually mixed. From the deposit of chalk in the cornea with resultant leucoma, these offer the most serious cases to vision.

During the last few years there has appeared considerable literature upon this subject (mainly brought out by the work of Andreae[1] in 1899, who gave the results of two years' study with the material of the Bonn Eye Clinic and the experiments upon live rabbits' and dead pigs' eyes). I agree with his opinion that the nature of injuries from lime, their consequences, and the therapeutic measures heretofore held were quite erroneous. There is a distinction betwen burns from thermal action and cauterization by chemical agents. The process of mortification produced by the former is different from the latter. Injuries by chemicals give a most unfavorable prognosis, and foremost among these are cauterizations by lime.

v. Gouvea[2] experimented upon rabbits, finding that the lime destroyed the epithelium of the cornea, the thinned epithelium formed masses with the particles of lime, collecting in the conjunctival sac, migrating through the interstices of the epithelium into the corneal tissue, burning and infiltrating, forming a cicatricial tissue in which particles of chalk are retained. This forms a white cicatrix or leucoma.

v. Guhmann[3] put lime-water into rabbits' eyes for seven minutes, when the cornea became dull and gray-looking like milk-glass. In an hour it became white and looked like porcelain. In twenty-four hours the epithelium came off in spots, the color remaining unchanged. In four days the cornea was grayish and uneven. In fifteen days perforation at the limbus occurred. The other eye was treated likewise and bound up for fifteen days, when it was found to have perforated and become a stump. He thought that the chemical action was enough to ac-

count for the results without the entrance of micro-organisms to produce panophthalmitis. The microscopic examination showed nuclear swelling and shrinking with desquamation of the epithelium from the stratum propium, which was permeated with a net of crossing lines. The connections of the cells to each other, as well as to the basal cells, were so broken that the lime penetrated and altered the corneal tissue proper. The imbibition of lime by the epithelial cells was irregular. In spots it was intense and these were dark gray, in other places less pronounced, in a few places entirely filled by the chalk. In stratum propium the chalk had infiltrated between the fibrillæ and the lymph spaces were filled. This infiltration reached to the membrana elastica posterior, which confined it.

The whiteness of the lime burns in the cornea is due to the mixture of the lime with the albumen of the tissues; in burns from glowing metals and from acids it is due to the coagulation of the albumen, together with the necrosis of the outer layers. The burning by unslacked lime is in part due to coagulation of albumen and in part to the imbibition of chalk. Guhman further said that the deposit is not calcium hydrate but the chloride of calcium, combined with the phosphate and chloride. While calcium hydrate is a most effective corrosive, yet the last named salts are not. The chemical change occurs in the lime at the time of its entrance into the tissue. If the lime keeps up its caustic action then perforation of the cornea occurs.

Stroschein[4] states that the lime forms an albuminate with the substance of the cells which is soluble and thus is readily diffused into the tissues.

The use of a sugar solution to neutralize the lime was first advised by Gosselin[5] in 1855 and, taken up in recent years by others, is inadvisable on account of the heat produced. While water assists in the diffusing of the lime into the tissues, yet it is best to remove the lime particles by its mechanical action. It may be well to enter somewhat into the mechanism of burns by lime and its compound.

Most derivatives of calcium are soluble in water and are dangerous. Calcium carbide, extensively used in the manufacture of acetylene gas, if brought into contact with water is decomposed into acetylene gas and hydrate of calcium, and if done suddenly the temperature may rise to about 500° C., so that an actual explosion may result.

Oxide of calcium, or unslacked lime, obtained by the burning phosphate of lime, is the chief ingredient of mortar. The process of slacking consists of pouring water over it, by which it is converted into hydrate of calcium. The temperature does not rise immediately. There are therefore four stages to the slacking process: 1. Hygroscopic intussusception of water with rise of temperature from 10 to 15 degrees within the first

two to four minutes. 2. Chemical absorption of water for several minutes, in which the temperature remains stationary. 3. Chemical action then takes place, in which the temperature rises slowly and then rapidly. 4. Gradual cooling off. In Andrae's experiments blood temperature was first reached after nine minutes; it then took ten minutes before it rose to 40°, and the maximum of 82.5° occurred after nineteen minutes, and the heat cannot be raised above 100° C. except in closed vessels; evaporation is prevented if, instead of water, acids are used, or water charged with carbonic acid, fresh or sour milk, solutions of salt and sugar, the temperature rapidly increases above 100° and may even reach 121° C. With oil, oxide of calcium forms a thick paste without producing heat, if water be added afterwards.

Hydrate of calcium, or slacked lime, is a grayish-white powder, which when dry is not caustic, but is very much so when moistened by water. It is extensively used in the form of mortar, and milk and lime. The older the hydrate of calcium, the more dangerous it is. Solutions in glycerine, sugar water or in milk are much stronger caustics than the water solutions. If only small quantities of oxide or hydrate of calcium strike the moist globe, the profusely discharged tears will immediately develop almost concentrated lime-water with deleterious effects.

Hydrate of calcium is much more detrimental to the eye than is the oxide; this is opposed to the general belief. Vienna lime, hyperoxide of calcium, chloride of lime, chloride of calcium, sulphite, bisulphite, and nitrate of calcium are very injurious. They are used in plastering, in cement and in hydraulic lime. Solutions of the calcium salts act temporarily and slowly upon the eye, the paste acting strongly and lasting for days, the dry preparations less rapidly, but on the moist eyeball the dry preparations soon assume the actions of the moist.

Lime affects the eyes in the following ways: 1. As a foreign body. 2. Physical and chemical alteration of the tissues; (a) caused by hygroscopic absorption of water; (b) by thermal exsiccation and combustion; (c) by chemical loosening of the tissues with destruction of their elements; (d) immigration of calcium into the tissues and precipitation of the original or new-formed substances. 3. The oxide of calcium in contact with water and the fluids of the eye does not become so heated as to produce thermal injury because it does not reach 40° within ten minutes, and if this should occur the constant discharge of the eye would cool it off.

Emil May[6] gave the results of observation at the eye clinic of Giessen from 25,045 patients in whom there were 109 cases of injury by lime (0.43 per cent.).

The lids were affected in 1.8 per cent., the conjunctiva or both in 17 per cent., the cornea and the conjunctiva in the remaining cases. The

results of treatment were generally good. Impairment of vision in all cases was due to opacities of the cornea. The injuries were produced by slacked or unslacked lime, cement, mortar and plaster of paris. Of these unslacked lime was the most deleterious, owing to its chemical property of absorbing water from the tissues, development of heat and coagulation of albumen. Treatment consisted of removal of particles by forceps, spoon or cotton sponge impregnated with vaseline. The conjunctival sac was washed out with oil; cocain or atropin salve applied and followed by cold applications. In affections of the cornea moist pressure bandage and warm applications were used. Agglutinations of the lids to globe were daily severed by probe or spatula; most cases were obstinate and symblepharon could not always be prevented.

Guillery[7] studied the chemical processes by which fertilizers exert their cauterizing effect on the eye, with regard to prognosis and means of treatment. He corrects the erroneous views of the harmlessness of Thomas flour by showing the deleterious influence through its content of unslackened lime. The opacities of the cornea which he produced experimentally by Thomas flour were the same as those caused by lime, and cleared up as these after applying eyebaths of 10 per cent. chlorate of ammonia with an admixture of 0.1 per cent tartaric acid, a method devised by him for the treatment of opacities created by lime.

The dangerous substance in the superphosphate of lime is the primary phosphate of calcium which in contact with the eye develops phosphoric anhydrid and metaphosphoric acid. Both have the same cauterizing effect on the eye as other mineralic acids. Phosphoric acid attacks the mucoid layer of the cornea, causing an opacity, which gradually clears up in the fluids of the eye, so that the prognosis is not unfavorable.

Kainit also causes opacities of the cornea by its content of sulphate of potash, but only temporarily.

Chili saltpeter is not very injurious. It produces superficial opacities of the cornea which soon disappear.

Several cases of varying severity will illustrate: A man while throwing unslacked lime into water received a chip of the lime in his right eye. This was immediately attended by severe burning and lacrimation. As he was only a few blocks from my office he came immediately; I instilled cocain and picked out a number of small lime particles from the ocular and inferior conjunctiva, then washed the eye out with boric acid solution and filled the eye with 5 per cent iodoform ointment. At the points where the particles of lime had lodged the caustic action had been quite complete, eating entirely through the conjunctiva and through the underlying tissue of the lids, the places looking as if they had been thoroughly cauterized with a solid stick of nitrate of silver. The resulting eschar was hard and brownish, and it came off after a few days leaving

excoriated surfaces which, being in apposition between the lower lid and inferior surface of the bulb, would have healed together but were kept apart by borated vaseline and daily passage of the probe with resultant normal movement and no diminution of vision or motility. As the cornea had not been injured, symblepharon had not occurred. The course of treatment was extended for about two weeks.

A man was carrying mortar when, by some mischance, a quantity splashed in his face. This was partly removed by his dirty handkerchief and he was not seen till several days afterwards, when he came with a badly inflamed eye, the cornea showing whitish excoriation over the whole of the inferior half. The conjunctiva of the lower half of the globe and of the lower lid was badly cauterized and a quantity of sand remained in the superior cul-de-sac. The eye was cocainized, washed out thoroughly and dressed with iodoform ointment. During the subsequent month of treatment the patient applied at irregular intervals, at which times the probe was passed around the circumference of the globe, to relieve the adhesions of the lids and bulb which constantly formed, but the patient finally disappeared after claiming the treatment was "too severe"—and I suppose the ultimate result was more or less symblepharon of the upper and lower lid.

A man of 45 had splashed some whitewash in his eye some years before; the result was a small symblepharon of the semilunar fold of the caruncle of the right eye which impeded outward rotation and produced double vision when in extreme right fixation. This was dissected loose, making small flaps of the ocular conjunctiva above and below, sewing them together; the result was decided improvement of rotation and loss of the double vision.

Several months before a man had gotten a quantity of whitewash in his eye, which was treated by a local practitioner. He finally came to the city for surgical relief of extensive symblepharon, which I removed under local anesthesia by detaching the adhesion of the lower lid from the eyeball, using the symblepharon to cover the defect in the lower and placing a Thiersch graft on the denuded conjunctival surface of the globe. The denuded cornea was allowed to granulate, the graft grew well, and the lower lid healed with resultant free action of the globe.

A young man had received injury by getting a quantity of mortar into the eye some months before. He had not sought professional services until after the eye had become badly inflamed and secondary suppuration had ensued. He was treated for six months by a physician and when he came to me had a painful atrophic eyeball, the conjunctival sac being practically obliterated from adhesions. In order to make a prothesis I dissected out the eyeball and put in a number of Thiersch grafts. Partial restoration of the orbit was effected, so much so that he was able

to wear an artificial eye, but this was never satisfactory either to the patient or myself and he finally left me. I later heard he had gone elsewhere, being operated upon again with unsatisfactory results.

A man, aged 20, while mixing whitewash, composed of about three pounds of slacked lime and three ounces of carbolic acid to six quarts of water, overturned the pail from a table, splashing the mixture into his face and eyes. He was almost immediately seen by a physician, who douched his eyes with olive oil and sent him to Dr. Elwood, of Menominee, who washed out the eyes, and afterwards picked out some solid pieces of lime, instilled saturated sugar solution, dressed the eyes with vaseline and applied iced compresses. He remained under care about twenty-four hours in the hospital, and was then sent to me for further treatment. I found the entire bulbar and tarsal conjunctivæ, and the whole of the cornea of both eyes involved in the caustic action of the hydrate of lime. I do not think the carbolic acid was in sufficiently concentrated solution to cause any of the burning. Both corneæ were white, the epithelium being almost entirely destroyed and the deposit of albuminate of lime infiltrating the tissues both of the cornea and of the conjunctiva, the main damage being to the lower parts. The eyes were under the influence of atropine, but the injury was so severe that the pupils could not be made out. He was received into the hospital, the eyes washed out every two hours with boric acid solution, holocaine instilled and then 2 per cent. chloride of ammonium used freely as a wash every two hours after the hot applications, after which 5 per cent. boric acid ointment was put in the eyes, hot applications were used several times a day. Improvement in the case was very rapid; the epithelium of the conjunctivæ and the corneæ becoming restored and the eyes showed only a slight damage of the corneæ, the pupillary area and the retinal reflex being readily made out by direct examination and by the ophthalmoscope. There was intense photophobia and blepharospasm at first which later disappeared; the lids were kept from growing to the bulb by daily passage of a hard rolled cotton pledget smeared with vaseline.

Stronger solutions of ammonium chloride have been used, and this case well shows the dissolvent action of ammonium muriate in the opaque albuminate of lime.

Diagnosis from history, finding of lime particles in the eye, peculiar whitish appearance of cornea, both in fresh and ancient cases.

Prognosis very bad as to sight in most cases unless lime be speedily removed, loss of entire cornea, loss of globe, entropion, ectropion and symblepharon occur.

Therapy. The therapy of lime burns is extensive douching with water, the first that comes to hand, picking and wiping out of the lime, later using ammonium chloride solution.

It is only lately that we have been able to remove opacities of the cornea from lime injuries by any method. Stutzer[8] recommends ammonium chloride in weak solutions—i. e., 2 per cent. applied for considerable length of time. Guillery[9] uses 2 per cent. the first few days applied as a wash, and both from half to three-quarters of an hour; afterward he uses stronger solutions, even up to 20 per cent.; after twenty-two days cocain or holocain should be instilled in such cases. Holocain solution or ointment is probably the best at first dressing, followed by dionin to relieve the pain. The stronger solutions of muriate of ammonium are indicated only after complete cicatrization has taken place and should not be used, on account of the irritant action, while the injury is fresh.

LITERATURE.

1. Andreae, Die Verletzungen des Sehorganes mit Kalk und ähnlichen Substanzen, Leipzig, 1889.
2. v. Gouvea, *Arch. f. Aug.*, I. 1. p. 106.
3. v. Guhmann, *Inaug. Dissert.*, Breslau, 1884.
4. Stroschein, *Zeitschr. f. aertzl. Landpraxis*, 1892, p. 149.
5. Goesselin, *Arch. Gen. de Med.*, Nov., 1855.
6. Emil May, *Inaug. Dissert.*, Giessen, 1899.
7. Guillery, *Klin. Mon. f. Aug.*, xlviii, supplement, p. 75.
8. Stutzer, *Deut. Med. Woch.*, 1900, No. 37, p. 594.
9. Guillery, *Arch. f. Aug.*, lviii, p. 77.

E. COMBINED INJURIES.

a. Explosions from gunpowder and dynamite.

Explosives cause complicated injuries attended by wounds, with or without retention of foreign bodies, bruising and shock to the tissues, burns and subsequent infections. As noted by Stoewer[1] at the explosion of the Roburet factory the main effect of the more serious injuries is from contusion and flying foreign bodies. In this section the effect of the burn will be mainly dealt with, leaving gunshot wounds and their aspects to other parts.

Practically all these accidents are preventable and come from the most foolish performances. They are of forensic importance, not only to the patient but also to the physician. The effects upon the former are readily surmised; upon the latter they are not so evident, but as many of these accident cases have some reason to blame either the party responsible for the accident, or some physician who may have handled the case before it reached the specialist, it is always a duty to protect the family practitioner or the previous consultant.

These cases give rise to an endless amount of anxiety, as no matter how well or how skillfully the services are applied, the patient or relatives are seldom content with less vision and less cosmetic results than were originally vouchsafed the patient by his Creator. Therefore, many of these cases lead the physician into courts of law, sometimes as defend-

ant, more often as witness as to the amount of damage, and, sad to say, even more often as a complainant in the endeavor to secure a reasonable reward for the services rendered. Be this as it may, it is our duty to help the public and we cannot well turn away an injury case if we are in a position to take care of it. The position of professional attendant upon accidents of this kind is not a source of pleasure or of profit. Therefore, in all cases it is well for the attendant, unless he be a man of national reputation, to call in as consultant some brother practitioner in order to protect himself from any charge of damages, as thereby the responsibility is divided and the family made to appreciate the gravity of the case and the purpose of the attendant to do the best.

1. Burns and injuries from gunpowder explosions.

Etiology and Mechanism. The exuberant spirit of the American youth on Independence Day shows itself in the promulgation of an epidemic of noise, largely made manifest by the force of combustion and explosion. Accidents involving burns, penetration of the face, eyelids, cornea and conjunctiva by explosions of powder are very common around our memorial day, even though the publicity campaign of the newspapers tends to render parents and the public more careful in the use of these explosives for joyous celebration. It is said that America alone offers as a sacrifice to jubilation and noise on or about July 4th as many victims as were dedicated to Mars during the whole of the Hispano-American War, and of these injuries a large proportion are of the eyes. Wiser municipal laws regulating the sale and use of fireworks now obtain, in consequence of which we hope for a relative decrease in this type of accidents.

Randolph[2] speaks pertinently to this point, saying "How singular, not to say preposterous, is the spectacle of this country celebrating the anniversary of its independence at the expense of 466 lives, 10 persons totally blind, 95 eyes lost, and 500 other individuals maimed and disfigured. This is the record of July 4th, 1903, a record which eclipses in its death list the losses in killed on the American side in the battle of Bunker Hill, where the Americans lost 449 killed." Fiske.[3]

"Better by far than the negative methods of restricting or prohibiting the use of destructive methods of celebration this year was the more general adoption of positive methods of reform. Our national Independence Day is ceasing to be a day of destruction and a new patriotism has been brought forth. From every section of the country, from city, town and hamlet comes the news that, in place of the senseless din of former years, more truly patriotic methods have been employed. The music of bands, the marching of soldiers, the flying of flags and banners, the children's parade, the witnessing of historic floats, and after-

ward the picnics, the trips to the parks or the visiting of friends—these methods were employed more than ever before. And the result is very evident: The smallest number of lockjaw cases and other deaths is reported this year; there were fewer destroyed eyes, fewer maimed bodies and an astonishing reduction in the number of injuries. Surely, the new methods have been worth while!"[4]

"There were 2,792 non-fatal injuries this year (1910), a little more than half (55 per cent.) of the total reported last year. Only 7 persons were totally blinded this year, but 33 lost one eye each, 26 lost legs, arms or hands, and 114 lost one or more fingers."[5]

These powder injuries vary from burns of the most superficial character of the eyelids and face, and a slight searing of the conjunctiva and cornea, to complicated injuries of the most serious nature. They are caused as a rule by boys making a "fizzer" out of a cannon cracker or a firecracker, by putting loose powder in a can or glass bottle, by the premature or delayed explosions of toy cannon or firecrackers, rockets and other fireworks. Many an American youth has cause to remember the firecracker that "wouldn't go off" until he had raised it to his optic to find out the reason why. At the very least these injuries from fireworks cause a burn of the first degree of the face, lids, conjunctiva and cornea, with the impaction of grains of powder, which, if not removed, leave lasting tattoo marks and permanent disfigurements.

A few cases from my experience are illustrative of this.

A soldier went into a comrade's room and helped himself to a particularly fat-looking Havana cigar, which he smoked but a short time when it burst with a loud report. Particles of the powder with which it was filled entered one eye, being impacted into the cornea and conjunctiva. In this case the "loaded" cigar was evidently laid as a trap for thieving. In other cases they have been prepared as a very dangerous and criminal practical joke.

A boy of eleven was playing with fire crackers by cutting them in two, thereby making "fizzers" or "fusees" out of them two days before the Fourth, and was brought to me about one hour after, one had fizzed into his face, causing a superficial burn of the eyelids, searing the eyelashes and eyebrow and superficially burning the conjunctiva and anterior epithelium of the cornea between the border of the lids; the space being well marked by staining with 2 per cent. fluorescein solution, which stains the abraded cornea a brilliant green, thus marking out the injured area. This injury was of course attended by considerable pain, which was speedily relieved by instillations of holocaine 1 per cent., the eye washed out with 3 per cent. boric acid solution, the palpebral border filled with 5 per cent. iodoform ointment, the eye bandaged and dressed again in twenty-four hours. The next day on the bandage being re-

moved treatment was suspended, as the anterior epithelium of the cornea had entirely regenerated.

An eleven-year-old boy while making a fuse with a dynamite cracker was burned about the face and both eyes. He was attended to shortly after the accident by a physician who washed out the eyes, put in atropin and covered the face with cloths wet with peroxide of hydrogen solution. I was called in consultation two days later, finding superficial burn of face, involving nose and both eyelids, with impaction of a few powder grains in the face, cornea and conjunctiva. By this time the nitrate of potash of the powder had been absorbed, leaving only the carbon stains; those of the face were so slight that they were left undisturbed, but those in the cornea and conjunctiva were picked out after local anesthesia by 1 per cent holocain solution, and orders given for the eyes to be kept washed out once every three hours with 3 per cent. boric acid solution and a 5 per cent. iodoform ointment put in. The face was kept well greased by 5 per cent. boric acid ointment. Full recovery resulted.

A boy, aged 17, was brought to me six hours after the accident by his physician from his home 200 miles away. He had filled a bottle with powder and endeavored to set it off by a paper fuse; the explosion not taking place in the calculated time, he had investigated the reason thereof, with disastrous results, as the explosion took place while he was stooping over the bottle and had knocked him senseless. In this case I first produced local anesthesia of the cornea by holocain solution, picked out the grains of powder, which were not yet solid, as the nitrate had not been absorbed, cut out some from the conjunctiva by scissors and forceps, washed out the eyes with boric solution and filled them with iodoform ointment. Chloroform was then administered, the face well scrubbed with a stiff brush, soft soap and water, then peroxide of hydrogen applied, the effect of which was immediately made manifest in the small wounds about the face, allowed gauze applications to remain on for three hours, and the face then covered with boric acid ointment. The same treatment, with the exception of digging out a few of the powder stains which were yet evident in the skin of the face, was pursued on the subsequent dressings. After the second day the eyes were washed out regularly with boric acid solution and kept bandaged. Full recovery without loss of function or cosmetic damage.

A boy, age 14, had put some powder in an empty can and lighted it with a match while stooping over it. He was brought to the hospital from a little town some 150 miles away. He had been attended by a local physician, who put antiphlogistine on the face, which was a horrible sight; the eyes both full of secretion, the right full of pus. He received immediate attention at the hospital by having the eyes washed out with boric acid solution and wet cloths laid upon the face. I did

not see him until twenty-four hours afterward, or about forty-eight hours after the injury. The case was treated as in the preceding instances, the brushing of the face being thoroughly done under chloroform anesthesia; the subsequent dressings being the same with the exception that the right cornea having been badly injured was infected, and hot compressing had to be resorted to to stimulate the nutrition of the cornea, while atropine was instilled into the eyes. Later the right eye had to be enucleated. The burn of the face was of the second degree, the epithelium sloughing off; recovery ensued with normal vision in the left eye.

A man aged 28 had filled a tin can with powder and had heaped over it several other tin vessels; he endeavored to set fire to the powder but was not successful until after several attempts, the last taking place while he was immediately over the pile of cans. His clothing took fire, his face being in about the center of the sheet of flame was badly burned, his hair was burned, also his eyelashes and lids severely. One of the cans struck his eye, cutting it and wounding the sclera. I saw him within an hour after the accident, sewed up the sclerotic wound, and, except as to the powder wounds of the face, treated him much the same as in the preceding cases. The result was partial detachment of the retina of the injured eye, with loss of sight, but no inflammation or sympathetic irritation ensued. Recovery took place after about ten days. I observed the case for nearly eighteen years afterwards, the foreign bodies being gradually absorbed, siderosis bulbi for five years, then clearing with partial vision. Cosmetic results poor, large amount of tattooing.

A boy, aged 15, had many grains of powder penetrate deeply into the face and into one eye, producing thereby severe inflammatory reaction with resultant blindness; in the other eye the cornea was partly destroyed by ulceration, but after tedious treatment of two months vision 6/xxvi was obtained. I paid dozens of visits to this case in the hospital and at the house, but was finally blamed as the author of the boy's blindness, which should have been ascribed to his own foolishness. A number of consultants were called in this case and in all instances the treatment was declared proper and no changes advised. I finally had to sue for my very moderate fee, which was never obtained, as the father was irresponsible.

Hunting accidents may likewise occasion the same character of injury.

A man, aged 45, while hunting deer in Alabama had a jammed shell in his rifle which he tried to dig out; it exploded, filling his eyes and face full of powder; the face being a couple of feet away from the gun, the injury was mainly that of a large number of foreign bodies. The case came to me in Milwaukee four days after the injury, when

the nitrate of potash had been absorbed, leaving only the powder stains, the little wounds of the face having practically healed up. In this case, I had to individually pick out the powder grains and stains from the face with a spud, under chloroform anesthesia, followed by 15 per cent. papoid solution. The stains of the cornea were treated in the same way while those of the conjunctiva were cut out by scissors. The results were ultimately very good, there being only a few tattoo marks left in the face.

2. Dynamite and other high explosives.

Etiology and Mechanism. The various compounds made from nitro-glycerine and the like used for blasting and in the manufacture of ammunition for large guns contain not only the substance producing gas but other solid bodies, which, together with the flame, the contusion and the chemical action, cause myriad wounds and retention of foreign bodies in the tissues. Thus dynamite contains clay, the cartridge may be wrapped in papier maché and be encased in a wire gauze and have solid copper or brass ends. Explosions of such substances affecting the eye almost invariably damage other portions of the head or body, and as a rule are either fatal or extremely severe. This subject is dealt with in other chapters, but in so far as the burning by the flame is one of the immediate results, is in part treated here.

Donovan[7] gives the following causes of accident: 1. Careless handling of powder; it may drop or catch fire from candle or pipe; it may or may not explode; thawing powder too near a fire; keeping it too near electric terminals, etc. 2. Careless jamming into the hole. 3. Packing with metal instead of wood, the contact with rock producing sparks. 4. Carelessness with the highly explosive caps; cigar ashes; hot candle grease, or a little concussion may explode the box. 5. Fuses cut too short or lit by mistake before longer ones, or unusual delay in lighting after others have been lit. 6. Error in counting and returning before last blast explodes. 7. Missed hole, fuse burned out but powder did not explode, new men coming on shift unknowingly pick it, causing explosion. 8. Faulty or frozen powder, several pieces in a hole, some failing to explode until picked later. 9. Caps left where children find and play with them with resultant explosion. This is frequently cause of such injuries in children and most frequently seen by the oculist.

Occasionally a youth will find and explode a dynamite cartridge, with disastrous results to himself, as in the following: A young man, age 18, had found a dynamite cartridge and had put it away to help celebrate the glorious Fourth. Some time before the day he was playing with the cartridge in his mother's kitchen when it unexpectedly exploded, blowing out the side of the house and along with it the right

hand and part of the left of the patient, and burning his face and eyes, thereby causing immediate blindness. I was called to him at the hospital and found him on the operating table surrounded by several surgeons, who took off his hand and turned his head over to me. I removed a large number of scraps of wire from his face, dressed the burns with carron-oil, the eyes with iodoform ointment and atropine, and, examining his ears, found that both drumheads had been ruptured by the shock; these were dressed antiseptically and healed several days later. The injured cornea of the left eye speedily healed, leaving leucoma, but then detachment of the retina was seen, the right eye was badly cut in the ciliary region and after some days of dressings, compressings, etc., I advised its removal. The trouble then began. First one consultant and then another, and so on until they had had all the talent in the city. He was taken to his home, and despite my express orders that he should be kept quiet, was twice bundled into a hack and taken to other doctors in consultation. As there had been so many consultants a certain difference of opinion was discernible and I finally withdrew from the case, one of the several consultants later removing the injured eye. In this instance, too, I was apparently esteemed the author of all the evil. I sued for the fee to forestall a malpractice suit and won judgment in a number of courts, the case being finally taken to the Supreme Court of Wisconsin, where it was awarded the fee and costs.

Farmers clearing land by the blasting of stumps with giant powder, nitro-glycerine and dynamite occasionally find that the fuse does not burn quickly, whereupon examination may result in explosion with loss of life, limb, or sight.

A farmer under these circumstances badly burned his face, had detachment of the retina in one, and total loss of the other eye from it being ruptured from the force of the explosion.

A young man had the same experience with one eye, the other acquiring sympathetic iridocyclitis with occlusion of the pupil and cataract, from which he was blind for six years. Recently I opened the pupil and removed the cataract with resultant vision of 6/xxx.

A copper miner tamped a new charge over an old one which had not gone off and had been forgotten, with the result of loss of hands, bursted ear-drums, consequent partial deafness, and the loss of both eyes.

A mining engineer unwittingly happened along in the gallery of a mine just before a blast occurred, which left him without hands, legs, or eyes, the sight of the latter being destroyed by total detachment of the retina and corneal leucoma following, with subsequent inflammation.

Kerry[7] had a severe dynamite explosion case in a man, aged 70, who lost the left eye completely, the orbit being lacerated and wounds discharging pus freely. Right eye wounded at limbus. Pupil occluded

by opaque lens. Light perception good. Patient had gone without treatment two weeks, without consultation, and was in a pitiable condition. In the left eye, which was completely destroyed, the patient maintained he could see light, although all tests were negative, and examination after enucleation showed practically nothing left of the retina and uvea. After enucleation there was no sense of light perception.

Diagnosis. The diagnosis of all these cases is evident from the history and appearance.

Prognosis. The prognosis in gunpowder and dynamite explosions depends (1) upon the severity of the damage; if the burn be of the first degree and no other injury be done, full restoration of function and appearance may be expected; if of the second degree, partial restoration of function with cosmetic damage; and if of third degree, total loss. If the burn be very extensive, even though but of the second degree, and covers a considerable portion of the head (or one-fourth of the body), exitus lethalis is to be expected.

The prognosis as to sight depends upon the concomitant wounding, loss of tissue and subsequent infections. Maculæ and leucomata of the cornea following will prevent good vision. Iritis and occlusion of the pupil will blind the eye. Perforating injuries, and in particular injuries in the ciliary region, and retained foreign bodies which may implicate the ocular structures will cause panophthalmitis, irido-cyclitis, sympathetic ophthalmia, and blindness of one or both eyes.

Complications. In addition to the injury to the eyes and lids, the face is usually badly burned, the skull may be broken and intracranial hemorrhage may result, the hands may be torn off and other parts of the body damaged, followed by imperfect general recovery, or death.

Prophylaxis. Donovan[6] says that with but few exceptions blasting injuries result from want of care on the part of the patient, associates, or predecessors at work. In careful hands and with those familiar with the dangers these accidents should not occur. The same may be said of gunpowder explosions. Fireworks and firearms should only be handled by those of mature years.

Therapy. Treatment of such cases is based upon general surgical principles. Burns of the face of this character are usually of the first degree—i. e., superficial, only involving the epidermis; when its vitality has been destroyed and the true skin or corium cooked by the heat, the burn is then that of the second degree. Application of carron-oil, which is a mixture of linseed oil and lime-water, picric acid 3 per cent., 5 per cent. boric acid ointment is the treatment.

The use of a stiff brush with soap and water renders it unnecessary to pick out each individual powder granule or powder stain, for the

nitrate of potash becomes absorbed a few hours after the injury, leaving only the carbon of the powder in the wounds. The brushing in severe cases should be done under general anesthesia, as it is extremely painful. The application of hydrogen peroxide, which forces out the stains, the application of papoid, which is a digestant and attacks the injured tissue only, thus aiding in the exfoliation of the dead tissue and with it the carbon stains, are valuable. After-treatment with antiseptic ointment is all that is necessary. Very few cases should be left with their faces disfigured by the tattoo marks of the powder explosion.

As regards the eyes, they are to be treated on general surgical principles, the foreign bodies removed by a spud after the use of holocain, not cocain, as cocain diminishes the vitality of the parts, and the application of antiseptic ointment, use of boric acid washes, and, if ulceration ensues, hot applications which are preferably given one-third hour every three hours, dionin, atropin and bandages. Even if the eyeball has been penetrated, if it is only the cornea or only the sclera, sight may be saved; if detachment of the retina has occurred from the force of the explosion, or suppuration ensues or if the ciliary region has been injured, blindness or even loss of the eyeball may occur. Severe injuries of the skull may lead to death. Enucleation may have to be resorted to, and plastic procedures on the lids for subsequent contraction are at times demanded.

Donovan[6] advises conservative treatment in blasting injuries. Remove large foreign bodies, use antiseptics and atropin until subsidence of reaction, then remove foreign bodies as soon as located. Never operate simply to restore vision until every inflammatory sign and all active changes have ceased. Better wait even a few years.

Koller[8] saw a man of 22 years whose face and eyes were burned by an explosion of fireworks, but who had the powder removed immediately after the injury by competent surgeons. Koller did not see him until twelve days later, when it was observed that the lids were much swollen, and that there was a moderate chemosis and profuse purulent discharge. Corneæ were intact and transparent except at the limbus, which was occupied by a complete circular ulcer. Bacteriologic examination proved negative for gonococci. The nutrition of the cornea suffered, resulting in corneal swelling and opacity with gradual encroachment of the ring ulcer until in one eye the destructive process was complete, while in the other it was arrested before the central area was destroyed. Vision was greatly impaired, but made some improvement under the use of dionin.

LITERATURE.

1. Stoewer, *Klin. Mon. f. Aug.*, March, Apr., 1907.
2. Randolph, *Trans. Sec. Ophth. A. M. A.*, 1904.
3. Fiske, *The American Revolution*, Vol. I, p. 139.

4. Editorial, *Journ. A. M. A.*, Sept. 3, 1910.
5. Würdemann, Editorial, *N. W. Med.*, Oct., 1910.
6. Donovan, *Journ. A. M. A.*, Aug. 5, 1905.
7. Kerry, *Ophthalmology*, July, 1910.
8. Koller, *Ophthalmoscope*, March, 1907.

(F) GUNSHOT WOUNDS.

Injuries from explosives and their missiles are not, obviously, usually confined to any portion of the eye, and combine wounds, contusions, ruptures, and, in near shots, bruises of the globe and adnexa. They usually cause perforating or lacerating wounds, attended by impaction of foreign bodies either from the shot itself or from the wadding, gunpowder, splinters from the bones from the skull, from wood, stone or other material through which the shot may have passed, or which may have been shattered and carried along by the effect of the explosion. The explosion may cause such a contusion and crushing as to injure the softer structures of the eye ball, causing as much damage as the wound itself, and in cases without perforation is the principal effect of the injury.

Etiology. Gunshot injuries may come from large or small arms, from birdshot, bullets, shells, broken parts of firearm, explosives, lead and iron projectiles, metal particles or fragments, wadding, etc., from the cartridge, pieces of stone, sand, iron, earth, wood, bone from the skull, etc. Cannon shells, bombs, rifles and revolvers, shot-guns, the air rifle and sling shot are the weapons. The injuries happen either through carelessness in handling at home or in the field, mistakes in aiming or observation of objects, glancing shots and spent balls, attempts at murder and suicide, and during war.

During peace, accidents to the eyes are largely through small shot, during war, through bullets and pieces of shells. The projectile either pierces the eye—when its shape is preserved, or totally destroys it. The injuries are mostly direct, except from artillery projectiles when broken bone from the orbital walls, or the skull, may also cause injury to the globe.

Explosions of gunpowder occur from bursting shells and firearms, fireworks, powder explosions in mills, factories, storehouses, carelessness and foolish handling, in blasting in mines, quarries, clearing the land of stumps and stones in agriculture. Explosions of dynamite result from carelessness and in mercantile carrying, or use in mines, quarries, and farms, most of which are complicated injuries, attended by loss of life or limb, as well as severe burns and wounds of the face and eyes, followed by infection.

Wounds of the eye ball are either direct from the projectile itself, from bone splinters, wadding, covering or packing, papier maché,

wire gauze, sand, pieces of wood, copper or nickel cartridge jackets, and, in former years, the copper from the percussion caps; or indirect from the concussion and crushing.

The anterior portions of the eye are most usually affected by portions of the projectile or its cartridge. The posterior portions and the contents of the orbit from bone splinters.

It is often impossible to estimate the amount of damage to the eye in the case of bullet wounds of the skull, and later changes may take place from injury behind the globe. The diagnosis of injury from splinters of bone from the rim of the orbit is most easy to make, but for those of the deeper portions developments must be awaited.

The direction of the projectile wound should be estimated from the way from which it came and the position of the head. It is seldom directly forward, but usually to one side.

The amount of damage done by the wound to the eye depends upon the nature and the force of the projectile, and the portion of the eye affected. Large projectiles, of course, immediately ruin the organ. Bird shot injuries are more in the nature of penetrating and perforating wounds.

We may distinguish superficial, penetrating, rebounding, slipping, or tangental blows, caused by small shot, or even by bullets, and those of the same nature which cause irregular, crushing or lacerating wounds, as well as those which utterly destroy the globe, even tearing it out of the orbit. Tangental blows upon the eyeball cause less damage than those which come perpendicular to its surface. Rebounding blows may be perpendicular or tangental, but come with less force than those which penetrate the globe. There is usually considerable crushing, with severe changes in the interior of the eye, so that the effect of the injury cannot be immediately estimated.

A. Non-penetrating injuries.

Small shot, portions of bullets and objects struck by them may rebound from the eyeball, causing a more or less high degree of concussion and crushing. They may even slip off the eye without lacerating the tissues, as when they come tangental to the eyeball, but as a rule at first pass through the lids or surrounding tissues. Such shots may lacerate the tissues, the projectile remaining in or on the conjunctiva, under the lids or in the orbit.

In one case a boy was playing with an air-gun, using bb shot, one of which was accidentally projected against the ciliary region of the eye, causing immediate irido-dialysis with some abrasion of the cornea, the shot remaining between the closed lids from whence it was picked out and the eye did well for a few years. Ultimate detachment of the

retina was, however, made out some years afterwards, followed by a low grade of irido-cyclitis and resulting in blindness from lenticular and vitreous opacities. I saw the case at the time of the accident, and likewise eleven years later.

A young man of 17 had put some powder in a can and dropped in a lighted match, the explosion took place, as usual, while his head was over the can, which struck him upon the eyebrow, cutting the brow and lid, producing blindness after a couple of days, as the force of the blow had ruptured the ligament of the lens, causing traumatic cataract, and had likewise invaded a small portion of the iris to the upper and outer part. He was attended by another oculist, but came to me a month later for removal of the cataract, which was done by discission, with the effect of also removing the iris inversion.

A similar instance to the one above mentioned was attended by cutting of the eyebrow and lid, but more severe tearing of the iris. Treatment by discission of the traumatic cataract had not restored the round contour of the pupil, the iris remaining torn and the pupil dilated.

Crushing and contusion of the eye ball.

Direct from the projectile, or indirect from the shock to the body, or from the concussion of the air from the explosion. P r a u n[1] says ocular injuries from firearms which do not pierce the eyeball cause crushing. It is very apparent, both in the case of bodies which penetrate and in those which rebound.

Direct crushing and contusion of the eye ball.

Injuries not only of the tissues, but blood vessels, from which latter effect disturbances of nutrition arise, which lead to disorganization and atrophy. Most of these blows occur upon the lids or through the orbit, and may follow lacerating wounds or contusions of the latter.

I n d i r e c t r u p t u r e is not often seen following an injury from firearms, as it usually occurs from larger objects and projectiles, which are not so apt to burst the eye as to bore through it. Some times the cornea may be torn, or even torn off, but as a rule only the posterior membrana elastica is torn.

Indirect contusions of the eye ball.

These occur through contrecoup, the force being propagated through the bones of the skull as when the projectile or splinters of a shell strike the head, and in a few cases from the force of the air during an explosion. For a description of these indirect injuries we have to thank von Ettingen. They are not to be confused with indirect shot wounds. These indirect shots come from the projectile or portion of same, as

well as from stone, wood, and splinters of matter which have been carried from surrounding objects by the shot striking them first.

Injuries from violent concussion on the bony skeleton.

A projectile or portion of a shell striking the head in the neighborhood of the eye may cause crushing of the globe, with bleeding into its interior, tearing of its membranes, especially the chorioid, detachment of portions, most commonly the retina, as well as circulation disturbances, commotio retinæ, changes in the iris, mydriasis or myosis, dislocation of the lens or tearing of its capsule and traumatic cataract.

The heavier the blow upon the orbit or its surroundings, the greater the effect upon the eye ball. Spent balls, or portions of projectiles or bodies that have been struck by them, may cause rebounding blows which affect the eye.

Papillitis is found rather commonly after shots which have entered the orbit. Atrophy of the optic nerve follows from rupture of the canal at the base of the skull and from injury to the orbital walls. This may, in some cases, be due to indirect injury of the organ of sight from the eyeball to the nerve centers. Optic nerve atrophy after rupture of the optic canal is a secondary retrobulbar process, due to neuritis descendens.

Contusions of the eye from air pressure.

Just as large foreign bodies may so jar the eye, as above noted, to cause injury, explosions from dynamite, powder, and even the force of a heavy stream of air may cause such injury. A minor example is the effect of wind upon the eyes.

Pick[2] noticed small hemorrhages into the vitreous from the effect of wind on the eyes, causing increased extra and intra-ocular pressure.

Stoewer,[3] at the explosion of the Roburit factory where there had been a first explosion followed by a second, between which a large concourse of people had gathered, had 34 cases under treatment. The explosion was so terrific that spectators were thrown through the air, many being killed and injured, and for miles around great damage was done to property. Many patients had their drumheads ruptured by the air pressure. The air enclosed under the upper lids in some cases tore them. At first the eye balls were pressed into the sockets, the suction following pulled them forwards, causing intraocular hemorrhages, iridodialysis, dislocation of the lens, rupture of the capsule and traumatic cataract, tears of Descemet's membrane with subsequent deep-seated opacities of the cornea, acute glaucoma ascribed to obstruction of the sinus of the anterior chamber by edema of the ciliary body in consequence of paralysis of the vaso-motor nerves.

b. Penetrating wounds.

These appear, in the majority of cases, as irregular crushing and lacerating wounds, depending upon the form of the injuring body, it most commonly being a portion rather than the whole of the projectile. They may remain in the eye, and as a rule in the posterior portion, or may pass entirely through into the orbit. Bullets open the eyeball with wide lacerating wounds with loss of substance and general damage, and hence we do not see clean perforating injuries, as are observed in cases of small shot wound which may even cause a double perforation or remain within the eye. As before noted, explosions may carry other foreign bodies which cause similar injuries to that of the projectile.

1. Injury from small shot.

The effect of pellets of shot on the eye depend upon their size, the force by which they may be projected and the location of the wound. If the impact be light they may remain in the skin of the face or lids, in or under the conjunctiva, cornea or sclera. They may penetrate the various coats, going through the eye, remaining therein, causing damage in their passage to the ciliary body, lens, vitreous, retina. Some may remain in or next to the retina and chorioid, or pass through into the capsule of Tenon into the orbit, and may be found therein; or they may pass through the walls of the orbit into the brain. In other cases shot may spring back from a glancing or rebounding blow, causing erosion, or wounds and injury from the contusion.

Both Tornatolu[4] and Ovio[5] experimented with small shot contaminated with pyogenic germs. They fired at rabbits and vessels containing nutritive gelatin. In the animals the wound remained aseptic, and in the gelatin no pyogenic germs developed. Small shot carried into the eyes of animals under aseptic precautions caused no reaction, the eye remaining quiet many months.

The character of the wound depends upon the size and shape of the shot. If it be round it causes a fine perforation, the edges of which may be smooth or angular. If the shot be mal-formed the eye may be torn or bruised. The wound of entrance is usually found in the sclera near the ciliary body, more seldom in the cornea, when it usually passes through the lens. It is very seldom confined to the anterior portion of the eye. The injury is usually confined to one eye. Very unfortunate cases have both eyes injured.

With the danger of infection eliminated, the seat of the wound is of more importance than the form of the penetrating object.

Valois[6] admits the localized value of radiography in such cases, but he insists on the great importance of wounds in the ciliary region, and whether the foreign body is situated within or without the eye; this

being true, since the former type of wound is almost always followed by cyclitis or even sympathetic ophthalmitis.

The course and result depend upon the character of the damage and position of the wound. Superficial injuries may occur with full return to sight, although some of these are followed later by opacities of the media in the retina, media, or ciliary body.

Penetrating wounds vary according to their size and the injury to the iris and ciliary body, the formation of cataract, and the bleeding into and opacity of the vitreous, and damage to the chorioid and retina.

Contusions from small shot are commonly due to glancing or rebounding particles, and do not usually cause irreparable damage, although rupture of the chorioid and detachment of the retina may follow, or a low grade of iridocyclitis with atrophia bulbi may be the result. The pupil is greatly enlarged from the shock, but may return to normal. Bleeding into the anterior chamber, vitreous and retina may occur, upon reabsorption of which the sight returns, but not usually to full extent. Heavy contusions cause severe damage. The capsule of the lens may rupture or the lens itself become cataractous, the chorioid and retina may be torn or become detached. The subjective symptoms are those of the injury at the moment of receiving the shock, followed by immediate or gradual blindness from bleeding into parts of the eye and opacity of the media.

Hunting injuries from small arms..

In shot-gun or air-gun injuries usually the whole of the shot penetrates the eye. Such injuries are far too common in America, a nation of marksmen, where most of the boys have their air-guns or small rifles, and many of the men are huntsmen. I could many times duplicate instances like the following from my own experience.

A crowd of young boys gathered around one of their companions who had an air-gun, taking turns shooting at marks varying from targets to small birds. In passing the gun from one to another the trigger released, hitting one of the boys in the eye, penetrating the globe and causing immediate blindness. Consultation showed wound through ciliary region, X-ray (when taken) showed foreign body. Enucleation and examination of specimen, bb shot was found.

Sportsmen were shooting at wild fowl in the canes or high grass. Thousands of shot are so fired at some of our duck lakes in one evening. A gunner a hundred yards away received a charge of No. 5 shot, unintended for him, in the face and through one eye, immediately blinding him. In this instance the shot passed through the eyelids and double wound of the sclera into the orbit, not injuring the lens, so the globe

was saved with impaired vision, 6/lx, under antiseptic treatment, the shot being allowed to remain in the orbit.

A farmer stepped out of his door one night to shoot a wild animal that was molesting his cattle. Seeing a grayish object he fired. It proved to be his son, who received a charge of shot in his body, luckily at long range. Two shots passed into one eye, one into the other. One eye enucleated, other retained V. = 6/xxx

Two boys, with one 22 calibre rifle between them, in the outskirts of a city sent promiscuous shots in various directions. On of them passed through a window, striking a young lady in the eye and blinding her, the ball passing through the cornea and lodged in the apex of the orbit, from which it was removed upon enucleation of the eye.

Hunters came upon an object in the woods looking like a grouse, and, firing, blew off the feathered hat of a young lady; one of the shot striking her eye remained and caused blindness, rendering enucleation necessary.

Valois[6] reports two cases of ocular injury by lead shot in which they, after passing through the ciliary region, lodged in the orbit. The immediate effect of treatment was good, both eyes becoming quiet. In each case, however, an irido-chorioiditis developed in a few weeks' time, for which it became necessary to perform an enucleation. In such cases he tells us that Yvert has urged against enucleation, as well as any attempts for removal through a scleral opening.

Marple[7] reports two double perforations of the eye with bird shot, and says there is no question but that a considerable number of eyes were removed in cases in which, on enucleation, no shot was found in the globe, but a second perforation in the sclera behind.

Aseptic foreign bodies, such as occur from these accidents, may remain in the eye for a long time. (See also my case under Powder Explosions).

Alvarado[8] saw a case of a gun-cap which had been in the iris, following discharge of a fowling piece, for thirty-two years with good acuity and no irritation.

A youth was injured by a ricochetting 22 calibre ball from a rifle, destroying the globe by an anterior corneal and posterior scleral wound. When I saw him the lens and vitreous had escaped and on enucleation of the collapsed globe the bullet was found impacted in the apex of the orbit.

Berlin[9] describes the case of an attempted suicide with a pocket revolver. Blindness in both eyes, right, from injury to nerve of the orbit with bleeding into the vitreous, the left from rupture of the globe by the ball, which was extracted from under the lower lid. Total blindness.

2. Bullet wounds.

In comparison to small shot injury we find here more heavy injuries and complications, as a rule through injury to the cranium, particularly the orbit. The brain is often injured and the facies badly damaged. The ball seldom enters the eye directly. The damage is generally to the orbit and secondarily to the eye. Rifle and pistol balls cause large sized wounds with loss of substance and shattering of the orbit and the entire eye, which usually collapses. Examination generally shows a large bloody mass behind the lids, and it is thus difficult to estimate the parts that are damaged. Large splinters of bone tear against the globe, and thus very few eyes retain their form when so injured. The great factor in these cases is that both eyes may be affected from the ball passing through the other orbit, which is especially the case in attempted suicide; according to Hirschberg[10] but 50 per cent. of such actually accomplish their death, damage to the eye or nerve only thereby resulting. A few bullets have been removed from the orbit, as a rule these being spent balls. These injuries occur largely in war or in hunting large game. With them may be found other foreign bodies, as where the injured person has worn glasses. In a few cases, such as one reported by Keller,[11] the ball had not penetrated, but caused severe contusion.

The subsequent course of bullet wounds depends upon the amount of damage, and they obviously vary from minor cases to those in which the function and the globe is entirely lost.

Sympathetic inflammation has been found in a large number of cases, especially those occurring during war.

Therapy is that of wounds from foreign bodies, and as a rule enucleation of the stump to prevent sympathetic inflammation.

3. Injuries from particles of shell and other foreign bodies, caused by firearms.

Pieces of shell from large guns come with such force that, as a rule, when striking the head in the neighborhood of the eye, they are immediately fatal. In a few cases very small pieces have been found in the eye or the orbit, one of which was reported by Stall.

Soldiers may be struck by pieces of stone, brick, etc., from the impact of shells. Treatment is on general surgical principles.

Wide opening of the globe and crushing of the parts by the projectile or from the force of the explosion causes total destruction.

Most commonly we find the whole shot or portions of the projectile, or the various constituents of the cartridge, i. e., wadding, pieces of metal, powder grains, remaining in the globe or passing through to the orbit. Portions of firearms, such as the breech-block, from bursting of the gun itself, have been reported.

Noyes[12] quotes the famous original breech-pin case. A boy, aged 19, was injured by the explosion of his gun, and the butt of the barrel, known as the breech-pin, broke through the nose and went in out of sight. It was not known that a foreign body had lodged, the wounds healed except some sinuses, and N. saw him five months afterward. Exploration discovered the foreign body. Extensive incisions and dissection were required to trace its situation and its form was totally unknown. By using large pliers, it was brought out through the nasal cavity and found to have penetrated the roof of the orbit and the frontal lobe of the brain. Its presence in the brain had not been indicated by any symptoms whatever. On the fourteenth day evidence of abscess in the brain led to an operation for evacuating pus by enlarging the opening in the orbital roof. Pus was found outside of the dura mater and in the brain tissue. On the sixteenth day beginning paralysis of the opposite arm and leg showed that full relief was not secured against cerebral pressure. The skull was trephined and an exploring needle introduced, and at the depth of 1¾ inches pus was found. A drainage tube was passed from the trephine hole to the orbital opening to give vent to pus.

From the beginning of treatment assiduous efforts were made to secure free vent to secretions and these efforts were not relaxed up to the end of the case. Death took place on the thirty-ninth day after removal of foreign body.

Wounds of the orbit from firearms are fairly common. Williams,[13] in describing bullet wounds of the orbit and its surrounding parts reports ten cases. In three cases both eyes were wounded and complete blindness followed. In one case one eye only was injured and became blind. In four cases of non-penetrating wounds of one eye, more or less complete blindness followed in that eye. In two cases wounding of one eye caused only temporary blindness.

Posey[14] reports a case of gun-shot wound of the orbit in which the bullet, located by a skiagraph in the apex of the orbit, was removed after division of the internal and inferior rectus. The globe was saved.

Newolina[15] reports a case of a shot through the orbit. There was instantaneous blindness without ophthalmoscopic changes, which gradually developed into atrophy of the optic nerve and narrowing of blood vessels. From the symptoms and Röentgen photographs, the shot apparently entered the orbit between its inner wall and eyeball, to the superior orbital fissure, along the osseous septum between this and the optic foramen, the cavernous sinus, above the Gasserian ganglion to the upper face of the temporal pyramid, where it became lodged. It injured the optic nerve, most likely the upper portion, in its avascular part, the

ophthalmic branch of the fifth nerve, grazed its ciliary twigs, and contused the oculomotor and trochlear nerves.

Sometimes such foreign bodies being aseptic may remain in the orbit for long periods of time.

Fernandez[16] describes the case of a nail from a shotgun cartridge, which spontaneously came out from under the eyelid where it had been lodged for eight years, without any damage to the patient. The nail from the cartridge entered the upper lid near the outer canthus. The entrance of the foreign body was not suspected and the patient complained of no discomfort during the eight years that the foreign body remained imbedded. Shortly before the spontaneous expulsion of the cartridge nail the patient had a feeling of uneasiness and slight pain in the upper lid. No inflammatory reaction followed.

Gifford[17] reports the case of a breech-pin, located by a skiagraph in and below the orbit, which was removed through the orbital opening.

Ledbetter[18] reports a case of a breech-pin striking a man in the eye, destroying it. Three years later it was removed.

Attempts at suicide or murder sometimes fail, as in the following. It is characteristic of suicides to shoot through the temple, as a rule forward of the vital centers.

Hirschberg[10] reports the case of a man who had fired a bullet into his right temple. He was totally blind, but showed no other disturbances. The wound of entrance was 2 cm. behind the outer angle of the lids in the right temple. The right eye was of normal tension, without irritation, pupil dilated ad maximum. Red ophthalmoscopic reflex, towards the temple grayish; no details could be distinguished. Left eye; slight ptosis, eyeball protruded, soft, red, cornea, smoky, covered with dark spots and short bundles of fine blood vessels, running toward the center. Iris thickened, pupil irregular with laceration of the sphincter and synechiæ. Capsule of lens showed vertical folds; vitreous red, no details of fundus visible. The Röentgen photograph revealed the seat of the bullet in the left orbit, surrounded by very small pieces. As Hirschberg observed in similar cases, the bullet had apparently lacerated the optic nerve of the proximal eye and penetrated the sclera of the distal eye.

Feb. 11, 1909, V. R. = motions of hand. The eye looked normal, tension slightly diminished, the very wide pupil responded a little to light. The vitreous was filled with dark, streaky opacities. A white tent-like mass with a crater, partly covered with blood, projected from the background.

The left upper lid drooped, left eyeball shrunken. Cornea clear, pupil medium wide, indented, anterior capsule wavy. In the depth white masses with hemorrhages.

Harlan[19] reports myosis and ptosis from paralysis of cervical

sympathetic from gun-shot wound of neck at about the level of cricoid cartilage.

Stoewer[3] describes a case injured at the Roburit factory explosion in which there was a wound over the eyebrow, lid suffused by blood, eyeball not injured. Paralysis of abducens, lack of pupillary reaction, fundus normal. V. = o. Frontal sinus open, inner wall fracture with exposure of brain, posterior ethmoid cells and orbit fractured and optic nerve found injured by lesion of bone at post mortem two weeks later.

Injuries to the eyes from explosions of coal dust or fire damp are noted by Simeon Snell[20] or Thos. Oliver,[21] in which 46 per cent. were injured by burns.

Complications. Gunshot and explosive injuries to the eye are generally associated with severe lesions of the neighboring parts. The brain, the face, or the cranial bones may receive an injury involving the eyeball and orbit.

Sattler[22] says pulsating exophthalmus due to traumatic aneurysm of the orbital artery or carotid and sinus may occur.

Frequently particles of extraneous matter, such as stone, gravel, cloth, parts of eye-glasses, are carried into the eye with the ball, and thus the already grave injury may be rendered more serious by the forcible entrance of foreign bodies. Furthermore, the injury may be complicated with burns of the eye and surrounding parts. Thus, contusion, penetration with retention of foreign substances, and burns may be associated with gunshot injuries, and the whole gamut of traumatic possibilities may be exhausted. (Gruening[23]).

The great danger of these wounds is from secondary infection and from sympathetic ophthalmitis, and the resulting atrophy of the bulb. The shots are usually aseptic, rendered so by the heat of the discharge from the gun, except in an air-gun or sling-shot injury, and unless the wound be infected by meddlesome handling, it may close. The danger is from sympathetic inflammation and from iridocyclitis setting in the first eye, but this too, must be a secondary infection. Tornatola had only one case of sympathetic ophthalmitis in twenty-one such injuries. He found that shot that had not been fired carried staphylococci.

Valois[6] says wounds of the eye by grains of lead do not differ essentially from those which are produced by other foreign bodies. As a rule, however, infection is less frequent, since grains of lead fired from a gun are usually sterile. The oxide of lead which rapidly forms produces chemical changes within the eye.

Prognosis. As a rule the eye is blinded, but the form is retained. In infection, iridocyclitis occurs as the eye becomes blind and atrophic, and here is the danger of sympathetic infection. If the shot

be small and cause double perforation of the globe, penetrating the orbit, it may be allowed to remain in some cases, with good resultant vision.

Lodato,[24] in ten cases of shot wounds of the globe, preserved seven eyes in good shape, and in six with some sight. Panophthalmitis did not occur in any, and only one was enucleated. In two atrophy of the globe occurred.

Prognosis of bullet wounds and injuries as related to the globe itself is, in the majority of instances, governed by the one word, enucleation. The removal of lead from the interior of the eye with preservation of vision, or even retention of the globe is, as a rule, impossible. Other materials, especially iron, offer a better prognosis.

Therapy. Conservative measures should be used in all cases where no infection occurs, for the shot may have passed entirely through the eye. If it be found later to have remained therein, upon examination by the ophthalmoscope after the media have cleared, or by the X-ray examination which should be immediately made, the eye should be enucleated. Removal of shot is only possible from the lids, conjunctiva, capsule, or when it can be seen or felt, i. e., in the anterior chamber or lens, but so far, eyes have not been preserved in which the shot was in the vitreous or posterior portion of the eye.

Indiscriminate sounding for foreign bodies should not be practised. In a few cases the foreign body may be located by inspection, palpation, the ophthalmoscope or the diaphanoscope, and in others by the X-ray, the latter of which should be habitually used whenever there is a possibility of preserving the globe.

If a shot be small and cause double penetration, entering the orbit, it may be allowed to remain and the external wound sewed and treated antiseptically. Conjunctival flaps may be sutured over the scleral or corneal wound, atropin, dionin, cold applications at first, followed by hot. As a rule do not attempt immediate removal of deeply-imbedded foreign bodies, either in the globe or orbit.

Burns should be treated by picric acid 5 per cent., carron oil, 5 per cent., boric acid ointments, antiseptic powders, etc.

Witalinski[25] says if a foreign body is iron or steel, removal may be accomplished without danger. Our task is much more difficult if a piece of copper or lead enter the eye. In such cases it is more advisable to abstain from any procedure, as the changes which develop in the eye may facilitate and simplify matters.

A piece of cap had penetrated the sclera above the cornea into the anterior chamber. At first it was covered by a dense infiltration which extended towards the pupil. After the infiltration had become smaller, under atropin, thigenol salve and alcohol dressings, the piece of copper

was seen at the lower sinus, whence it was easily removed through a small section at the sclero-corneal junction.

LITERATURE.

1. Praun, l. c. p. 14.
2. Pick, *Centralbl. f. prak. Aug.*, 1906, p. 177.
3. Stoewer, *Klin. Mon. f. Aug.*, March, Apr., 1907.
4. Tornatolu, *Arch. d'ottal.* III, p. 350.
5. Ovio, *Arch. d'ottal.* xxiv, p. 14.
6. Valois, *Rec. d'opht.*, July, Aug., 1902.
7. Marple, *Journ. A. M. A.*, Aug., 11, 1906.
8. Alvarado, *Arch. d. oftal.*, Apr., 1905.
9. Berlin, J., *Inaug. Dissert.*, Giessen, 1908.
10. Hirschberg, *Centralbl. f. prak. Aug.*, March, 1907.
11. Keller, *Inaug. Dissert.* Darmstadt, 1895.
12. Noyes, *Dis of Eye*, 1890, p. 697, and *Amer. Journ. Med. Scien.*, July, 1882.
13. C. H. Williams, *Ophth. Record*, June, 1908.
14. Posey, *Ophth. Record*, March, 1905.
15. Newolina, *Beitr. z. Aug.*, lxx, 1908, p. 584.
16. Santos Fernandez, *Arch. Ophth.*, March, 1908.
17. Gifford, *Ophth. Record*, March, 1905.
18. Ledbetter, *Ophth. Record*, March, 1905.
19. Harlan, *Ann. Ophth.*, April, 1901.
20. Simeon Snell, in *Dangerous Trades*, (Oliver).
21. Thos. Oliver, *Dangerous Trades*, London, 1902.
22. Sattler, *Wien. Med. Woch.*, March 3, 1906.
23. Gruening, in Norris and Oliver's *Sys. Dis. of Eye*, III, 1898, p. 714.
24. Lodato, *Arch. d'ottal*, ii, p. 9.
25. Witalinski, *Postep okulist.* 1, 1907.

Injuries to the eye during war.

From Praun[1] and J. Berlin[2] we find that 92.2 per cent. of these are due to firearms, and 3.8 to sword and bayonet injuries, being 0.86 per cent of all wounds, and 8.5 per cent. of all head injuries. Owing to the high-powered, long range rifles head injuries were more common in the Russo-Japanese and Spanish-American wars.

During the Franco-German war Herman Cohn[3] observed thirty-one cases of gunshot wounds affecting the eye. In two cases the projectile pierced the brain, in nine the face, in four the cranial bones, and in sixteen the eye directly. He enumerates seventy different pathological conditions found in the injured eyes.

Among the large numbers of pensioners from the Civil and Hispano-American wars examined, I have seen none whose eyes were injured by bullet or shell wounds. Such, as a rule, are so severe as to cause death—few survive to give statistics.

A good many wounds are due to the man's comrade in the front rank when in double rank formation. Cohn[2] describes one due to the bayonet of another man tearing the upper lid. The most common complication is infection, and after that sympathetic ophthalmitis, of which latter there were 99 cases observed in the Franco-Prussian war, and 41 cases out of 254 eye injuries reported in the war of the rebellion of

America. (See Sympathetic Ophthalmitis after Gun-shot Wounds in War).

Treatment. Naturally, the treatment on the field is the first-aid bandage, in the field hospital treatment is largely restricted to suture of the wounds of the lids, the removal of foreign bodies and the use of antiseptics. The indiscriminate sounding of wounds of the globe or the orbit in order to extract foreign bodies is to be depreciated, as it is not always possible in the emergencies of the field hospital to have special and aseptic instruments. The most common operation would naturally be enucleation of a badly injured bulb in order to prevent sympathetic inflammation.

So many of these cases need the special attention of an ophthalmic surgeon that it is to be regretted that such surgeons have not heretofore been available in most of the military establishments. The results of these injuries, where the eye is not immediately destroyed, are apparent in after years and may for a long time need special attention.

So far as I can gather from the literature, but few ophthalmic surgeons have had the opportunity to make any extensive observations of injuries received during war, among these, however, are Baer,[4] von Oettingen,[5] and Cohn[3] in the Franco-Prussian War; Reich,[6] Talco,[7] Oettingen[5] in the Russo-Turkish War; Girard[8] in the Hispano-American War; von Merz[9] and Tatsuji Inouye[10] in the Russo-Japanese War. (The Medical and Surgical History of our Civil War is bare of any valuable references to the eyes). Should the unhappy circumstances of war again arise it is to be hoped that ophthalmic surgeons in connection with the armies will make more full reports in regard to the injuries and results than have heretofore been obtained.

A. von Merz,[8] St. Petersburg, reports gunshot injuries of the eye and clinical observations from the Russo-Japanese War, arranged in tabular form. In all observations of von Merz of severe injuries with total blindness of one eye, the other eye remained intact, but its vision decreased immediately to such a degree that sometimes only perception of light remained, with ophthalmoscopic changes. He attributes this to physical shock, and paralytic expansion of the chorioidal vessels with transudation between pigment epithelium and elastic membrane of the chorioid. This causes detachment of the retina and vision may remain destroyed even after absorption, so that no ophthalmoscopic changes are visible. The term commotion of the retina is to be applied only in those cases in which immediately after the injury vision is deteriorated for a short time from the shock.

LITERATURE.

1. Praun, l. c. p. 428.
2. H. Cohn, *Schussverletzungen des Auges*, Erglangen, 1872.
3. Johannes Berlin, *Inaug. Dissert.*, Giessen, 1908.

4. Baer, *Handbuch der Kreigschirurgie,* Fischer, II, p. 925.
5. von Oettingen, *Die Indirekten Schussläsionen des Auges,* Stuttgart, 1897.
6. Reich, ref. Praun, p. 429.
7. Talco, ref. Praun, p. 429.
8. Girard. *The Use of the Roentgen Ray by the Medical Dept. of the U. S. A. in the War with Spain,* 1898.
9. von Merz, *Klin. Mon. f. Aug.,* Supplement, xlv, 1907.
10. Tatsuji Inouye. *Die Sehstörungen bei Schussverletzungen der corticalen Sekphaäre, nach Beobachtungen an Verwundeten der letzen Japanischen Kriege,* Leipzig, 1909.

(G) INFECTIONS.

Infection may be described under two types. That of the cornea, causing corneal ulceration or keratitis suppurativa traumatica, and of the uvea, under uveitis suppurativa traumatica, or panophthalmitis. These are taken up under the following headings:

Inflammation of the eye, the specific infection of which has not been discovered, which causes sympathetic disease in the other eye is called irido-cyclitis traumatica, and is described under sympathetic ophthalmitis.

Infection of corneal wounds is described under the heading of Cornea.

Suppurative infection of the uvea is described elsewhere.

CHAPTER II.

ETIOLOGY OF INJURIES TO THE EYE.

A. Injuries to the eyes in domestic life—B. Industrial injuries—Trades in which injuries occur—Etiology of industrial accidents—Relation of eye accidents to the community—Iron workers—The mote remover—Infections—Glass and bottling workers—C. The predilection of certain forms of injury for certain parts of the eye—D. Objects causing ocular injuries —E. Bacteriology.

(A) INJURIES TO THE EYES IN DOMESTIC LIFE.

The objects causing these injuries and the nature of such accidents are very numerous. Amongst the common or important are motes and objects flying into the eye while on the street or railway cars, injuries from finger nails, pins, needles, hat pins, broken spectacle lenses, pocket knives and scissors, the two latter particularly common to children; also from table utensils, as forks; from carpenters tools, flying nails or pieces of wood; burning fire-brands, hot cigar ashes or ends; burns by hot irons, curling irons, whitewash, lime, powder burns, gas explosions, acids, etc. Blows during rough sports as boxing, la Savatte, foot-ball, base-ball, la crosse, hockey, and even croquet and tennis are responsible for some injuries to the eyes; blows in fist fights or in falls, contusions from stones, pencils, etc., occasionally destruction of the eye from severe blows, from sharp instruments or gun-shot injuries. Mistakes in eye medicines or application; even the leech has been known to migrate during application to the globe or cornea and cause ulceration. Malpractice of irregulars, also attempted suicides and murders swell the quota of the severe cases. Self-inflicted injuries to escape conscription for military duties, or even to gain damages for alleged accidents, are known. Accidents during, or from ill-performed, surgical operations may occur.

(B) INDUSTRIAL INJURIES.

Trades in which injuries occur.

In the so-called dangerous trades, particularly those dealing with the iron and steel industries, workers in machinery, butchering work, and building trades, occur the larger number of ocular injuries. Among these are the miners of iron, copper and coal, the smelters and machine builders. Those that are most subject to flying foreign bodies causing wounds of the eye are foundrymen, machinists, turners, borers, boiler-

makers, fettlers, smiths, and polishers. Workers by fire and heat, puddlers, casters, glass-workers, etc., are burned by fire, ashes, or iron and slag. Contusions of the eyes from falls, blows and thrusts come to all classes. In agricultural pursuits there are many kinds of injuries, especially from foreign bodies. In lands where the ground is tilled largely by hoes, as in the stony country of Switzerland, the breaking of these instruments against rocks causes many such injuries. Wounds from straws, pieces of wood, and instrument handles are common.

Eschenauer[1] examined 1,409 cases of accidental injuries to the eyes in farming occupations. He found an extraordinary frequency of



Fig. 6.
Edge tool grinding. (Simeon Snell.)

accidents in hot months, especially in the harvest months (July, August and September). The causes were injuries by straws, by branches in the woods, in working about cattle and by farming implements. There were injuries from foreign bodies in the cornea and conjunctiva, perforating wounds, contusions from sharp or pointed objects, injuries from lime or dung, burns and insect stings. Fifty-nine retained only l. p., and four were completely blinded. Forty-three eyes were enucleated or eviscerated for phthisis bulbi or danger of sympathetic inflammation. In one case sympathetic inflammation occurred, and in one metastatic inflammation. In reference to compensation, the author considers it difficult to arrive at a formula as so many factors enter into the question, such as condition of the remaining eye, general conditions, age, constitution, calling, disfigurement, etc., all of which must be taken into account.

In the building trades there are injuries from iron, stone particles, and splinters of wood, and from instruments used in work; in quarries and mines explosions of powder and dynamite. Injuries from lime are common among painters. In laboratory workers foreign bodies, burns and scalds, and splinters of glass; in glass-blowing, burns and formation of cataract; in cabinet workers injuries from the materials they work with, steel, wood, and bone; in turners, injuries from wood, bone, ivory, and stone, blows from sharp knives, etc.

S. C. Ayres[2] has studied the character and condition of the tools used by mechanics and the manner in which penetrating wounds of the



Fig. 7.
Workmen smoothing at wheel. (Simeon Snell.)

eye were received. He found that generally the injury was inflicted by fragments flying off while the mechanic was striking a chisel or piece of metal, or a hatchet with a hammer; that the hammer was usually a cheap one, and that the purchase of hammers of better quality would prevent such accidents to a considerable degree.

An all-steel hammer costs about $1.25. The kind usually purchased costs about 35 cents and is made from a low carbon tool steel the outside of which is hardened or tempered to the extent of about a sixteenth of an inch; the metal beneath the outside casing is soft and porous; repeated blows on the face of this hammer drive away this softer metal from the outside shell, thus leaving a space, and allowing the shell to crack and chip off from the edge of the hammer-face.

Wilson Johnston,[3] speaking of eye injuries in his locality, divides them into the following classes:

I. Those occurring as the result of handling high explosives in mining and railroad construction.

II. Those occurring from the bursting of locomotive oil and water gauges.

III. Those occurring in mills, foundries, machine shops, and the building trades.

IV. Those occurring in the agricultural pursuits.

He ascribes the breaking of water and oil gauges to the vibration of the engine, which subjects that portion of the glass of oil and water



Fig. 8.
Chipping or fettling. (Simeon Snell.)

gauges which is inserted into the metal caps or holders to constant friction, causing the inequality in the thickness of the glass and rendering it unable to stand the required pressure of 200 pounds to the square inch. In water gauges, the friction of the water alone is sufficient to wear little seams in the glass and render it unsafe, in some instances even after a few days.

Conkey[4] reports a series of four cases from the bursting of water and oil gauges, some of which eyes had to be enucleated, and others were saved by conservative treatment.

Hanke[5] says: Accident may be due to disease caused by noxious influences, connected with certain occupations, as an acute or a chronic affection. Hanke gives a synopsis of the latter under three groups: 1.

Direct lesions by solid or gaseous substances, as conjunctivitis of people exposed to the inclemencies of weather, stone impregnation of the cornea in stonecutters, ribbon-shaped keratitis of hatmakers, masons, steel-grinders, opacities of cornea due to nitronaphthalin and analin, keratitis of oyster openers and caisson laborers, cataract of glassblowers.

The second group is caused by indirect lesion through circulation or direct toxic lesion of the optic nerve from carbosulphide, nitro-amidobenzol, lead; and the third consist in neuropathies, as nystagmus of miners, spasms of the orbicularis of watchmakers and spasms of the ocular muscles from military drilling. It is very useful to have such a collection of practically important facts.



Fig. 9.
Crucible steel melting. (Simeon Snell.)

Twenty years of my professional life were passed in Milwaukee, a manufacturing city in which there are some of the largest iron and steel works, railroad shops and other metal trades, breweries, bottling works, leather and lumber industries, in consequence of which I have seen a large number of ocular accidents and of varied character. My practice showed that 25 per cent. of the eye cases in that locality were admitted for accident. In Seattle the percentage is about 5.

That occupation bears a peculiar relation to the number of eye accidents illustrated, is shown particularly in the case of women, the percentage being six times as great for women as for men, corresponding with Simeon Snell's[6] figures.

As regards the trades in which eye accidents are common, we may probably give the most prominent place to grinders or to workmen in factories who are either constantly employed in grinding edged tools, or, as is common in this district, care for their own tools and find occasion to go to the grindstone or emery wheel a number of times daily. In such trades foreign bodies are very prone to become lodged in the cornea. In the course of a day a grinder may get several foreign bodies in his cornea or many days may elapse without so doing. If the cornea of an old grinder be examined carefully with a magnifying glass, it will



Fig. 10.

View of miners working with drills 1,900 feet under the city of Butte, Mont. (Donovan.)

be frequently found studded over with little nebulæ caused by damage from getting motes in the eye which, by frequent repetition, will dull the cornea and after awhile will diminish the acuteness of vision. I have, however, seen many workmen with such scars who possess normal visual acuity. These nebulæ have been caused by small fragments of emery, or, more rarely, stone or pieces of iron. In localities where emery is used for glazing cutlery such accidents are very common. To those who have watched a grinder at work it is remarkable how any one can remain at the wheel without getting foreign bodies into the eye every few minutes. The shower of sparks which proceeds from the dry grinding wheel shows the large number of foreign bodies that come away. Dry

grinding is certainly more dangerous as regards the eyes than wet grinding, as in the former the sparks fly freely and it is a chance whether they hit the man's eye or scatter about the room. The pneumatic fans which are required in many of the United States and in England, in consequence of the deleterious effect of the dust upon the health of the operators, protect the workman's eyes by drawing into it the sparks and particles flying from the wheel. In wet grinding the particles do not fly about so much; still the workman's face becomes bespattered.

In the great majority of cases the damage occasioned by mishaps of

Fig. 11.
Miners ready to light fuses for blasting. (Donovan.)

this character is not serious unless ulceration follows. Other accidents, of course, may follow upon the injury to the eye on account of the disability and lessened protection that is thereby produced. In the case of workmen who frequently get injuries to their eyes, and always where a workman or patient has lost an eye, I advise the securing of an accident policy on account of the greater danger of injury from the lessened functional ability. Snell remarks upon the cleaning or sharpening of the stone when it gets blunted, its holes becoming filled with pieces of hard steel, then the stone is cleaned by reversing it, a bar of soft iron, or another stone or a piece of steel being held against the stone in order to smooth the surface. The dust is tremendous and flies in all directions. It

is during this process that stones are apt to crack and fly so that accidents occur entailing serious results to life and limb.

By far the most serious eye accidents happen to men engaged in working in iron or steel. Particularly in iron manufacturing districts the majority of serious eye accidents occur from chipping or fettling iron and steel and the following from Simeon Snell[6a] appropriately expresses my own experience:

"The opportunity for the infliction of severe injuries to iron and steel workers is multitudinous. They occur in all branches of the trade,



Fig. 12.
After the Blast. (Donovan.)

in the lighter iron and steel industries as well as in the heavy trades, where armour plates are made and heavy castings of scores of tons. A very large proportion of the accidents are occasioned by what is called 'chipping' and 'fettling.' 'Dressing' is the name given in some parts to this process. This work consists in chipping the rough edges from steel and iron castings, ingots, and all kinds of iron and steel work, and, among other things, even the large armour plates. I append a short list, which a patient, himself badly injured when passing men engaged in 'chipping,' has furnished me with, of the articles in connection with locomotive work, as an example, of the number of objects in which 'chipping' is required.

Rolled Steel.—The frame plates for locomotives re-chipping for the hornblocks or axlebox slides.

Cast Iron.—The saddle casting which is placed under the front end of the boiler and between the frames to which it is bolted. This casting wants chipping to the radius of the boiler.

Cast Iron.—The dragbox, which is placed between the frames at the back of the engine.

Cast Steel.—The hornblocks or axlebox slides sometimes require chipping and facing. The platform plates (of mild steel), which are the plates round the engine, require chipping on the edges.

Steel.—The boiler has to be chipped and faced in various places for the mountings.

Cast Iron.—The chimney, if a casting, requires chipping and bedding to the boiler.

Steel.—The clothing plates for the boiler. These plates are rolled to the radius of the boiler, and then laid over a block, and pieces from 1 to 4 or 5 inches in diameter are chipped out to clear different mountings, etc., on the boiler.

Castings of either iron, steel, or brass are the most dangerous to work upon, because the chippings fly about on account of the metal being brittle. It is very dangerous chipping castings in corners or where the chipping strikes the metal and rebounds. Chippings from the castings are about ¼ inch to ¾ inch long and very sharp. When chipping thin plates on the edges, the chippings are sometimes 1, 2, and 3 inches long before they break off. All castings are fettled at the foundry, that is, the runners are cut off, and the plates where the metal has run at the joint of the moulding boxes are trimmed off.

Whatever be the special kind of metal or steel to be fettled, the manner in which it is done is practically the same. A hammer and chisel or sate are used, and with these the roughnesses are removed. Frequently, also, whilst one man places the chisel, another, or even two others, will use the hammer and are called strikers. I understand that at works where, say, 1,000 men are employed, 200 or more will be occupied more or less in chipping. Many men are frequently working close to each other, so that the danger is not only to the worker himself, but to those around. Passers-by are by no means infrequently the victims, and many blinded in this way have come under my notice. The chipper himself is often hit by the rebound of the splinter after it has struck perhaps the narrow angle of steel or iron upon which he may have been working, or some other object. It must be recollected, also, that in the process spoken of the danger is not merely from the iron or steel which is being operated upon, but there are three other places from which splinters may

be, and actually are, given off and cause injury—namely, the hammer-head, the chisel-head, and the chisel-point.

It is obvious that men engaged in work which causes the splinters to fly about so freely should be so arranged as not to be chipping against their fellow workmen, or in a direction from which passers-by may approach. This is managed in some works by getting the men to chip against a wall, though not too close to it, or again by interposing a canvas screen between sets of workmen.

The sizes of the splinters spoken of vary from the most minute to others measuring some inches in length, and they may be thick or thin. The injury inflicted differs, of course, in accordance with the size of the

Fig. 13.
The "mote remover." (Simeon Snell.)

missile and the force with which it is projected. The small fragments may be thrown off with such velocity that they penetrate the eyeball and become imbedded in its interior, in some instances passing through the eye-lid before reaching the globe. The destruction to sight in this way is very large.

"The mote remover."

"In the various trades in which iron and steel are used the operatives are liable, though to a less degree than the grinder, to get these 'motes' into their eyes. Many workmen are skilled in removing 'motes' from their comrades' eyes. In all the large works there are men who have a reputation in this way. It is, besides, not an infrequent sight, even in the

streets, to see a man with his head pressed against a wall and a fellow workman endeavoring to remove a foreign body from his eye. The number of foreign bodies some of these men remove in the course of a day is very large. One man, a time-keeper at works where 1,000 men, besides outworkers, were employed, told me he had for fifteen years at least been recognized as a skillful remover of 'motes.' Sometimes he had extracted a score or more a day; sometimes the number was much less, but he had not for many years passed a day without at least one case.

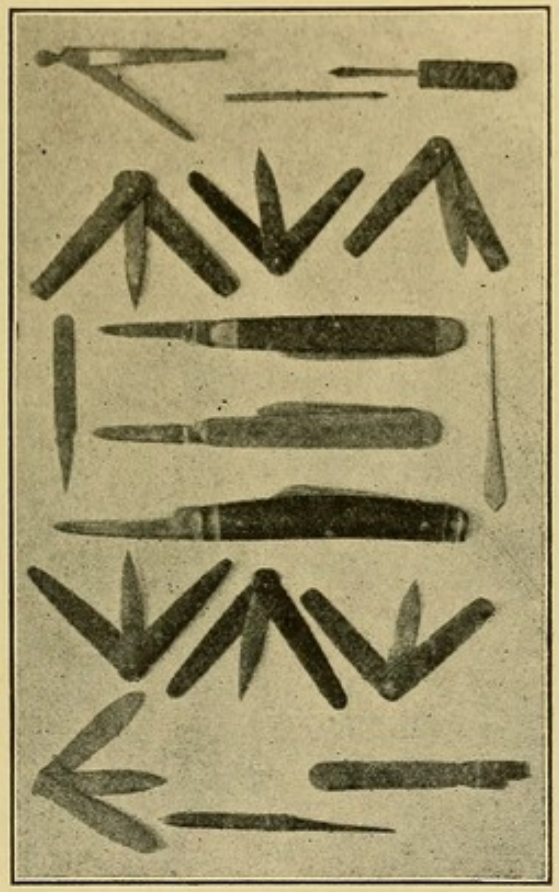

Fig. 14.
Instruments used in Sheffield Iron Works by "mote removers." (Simeon Snell.)

He was not the only man with a reputation at these works, for grinders, and others, also removed motes. He used a lancet with the end blunted. It was quite clean, and he kept it so by either putting it on a strop or a wet stone. For the same purpose other men would use a lancet, pocket-knife blade, or even a pin, etc. The knife would very possibly be the same used at the man's lunch, and the pin not infrequently is put into the mouth to wet it before being used, and is very likely kept stuck in the man's waistcoat, where it comes in contact with the dirt collected in the clothing."

Infection in corneal wounds.

"With doubt, in many instances, these motes are skillfully removed; in others there is a good deal of bungling. The instruments generally used are unsuitable. Not infrequently cases come under observation in which sloughing corneal ulcers have resulted from the efforts made to remove a 'mote.' It seemed to me not unlikely that a septic condition was set up in consequence of the uncleanly instruments which were so often employed. Dr. Sherman, of Edinburgh, kindly undertook a bacteriological examination of some of these instruments for me. I collected 22 tools used by different men; 17 of these were got together for me by the skillful timekeeper I have already mentioned; the other 5 were obtained at a large engine works. The photograph shows these instruments except two pins which were accidentally omitted. Some of the tools were fairly clean, but others were in a dirty state; two or three were magnetic. Dr. Sherman examined the majority of these tools. Taking all in all, he found nothing pathogenic excepting the staphylococcus pyogenes albus, whose virulence is comparatively slight. The other organisms found were chiefly sarcinæ of the more common varieites, and bacilli of the 'subtilis' (hay bacillus) group.

"In the case of breweries and bottling works, particularly of bottling of aërated water, there is a comparative frequency of accidents from the breaking of the containers. A firm in Sheffield having several different factories employing from 2,500 to 4,200 hands states that in spite of the most careful enforcement of the use of masks, gauntlets, etc., in one year there were nearly 400 accidents. The number of bottles that burst in one year is very considerable; new bottles or syphons are twice as liable to break as the old ones. About 1 per cent. of the new and old bottles break when filled. Syphons burst less frequently but the explosion and danger is greater; about one in 5,000 break in winter, while the percentage is greater in hot weather. The greatest number of bottles break in the filling machines but there is practically no work in any part of the factory which may be regarded as free from danger."

Simeon Snell[6b] gives the following points associated with the dangers incidental to the filling of bottles with aërated water:

1. The Machines.—It is a prominent feature of present day bottling machines that they should be so constructed that the filler is freed as much as possible from the danger occasioned by bottles bursting during the filling. The machines I have seen at work answer this object with varying degrees of success, but generally speaking it seems that those now in use could be materially improved in this respect. It may be mentioned that one of the firms using the most modern patterns of machines has removed the door which should enclose the bottle and in its place has fixed the machine round with a wooden arrangement of their

own device, which, in their opinion, affords better protection to the filler, as it does also to those working in the vicinity. The cases of injury to eyesight which have been cited indicate the danger from the bursting of bottles in the filling machines to others than those actually engaged in bottling, and this sometimes even at a great distance. This is a matter of some moment and deserves consideration.

Some firms have recognized the dangers just referred to, and to obviate the risks they have erected wooden boards on either side of the filling machines. The filler sits on his stool facing the machine, and is in an enclosed space open only at the back. Any portions of bottles fly-



Fig. 15.
Bottling Aërated waters; showing screens. (Simeon Snell.)

ing, laterally, will be stopped by these boards, which, to prevent any rebound of fragments, are further covered with blanket. The wirers, labellers, etc., work on benches outside this enclosure, and as the bottle is charged the filler passes it through a hole, over which a curtain drops, onto the bench at which the wiring, labelling, etc., is done.

2. In the case of cork bottles a further danger is added in the liability of the corks to fly between the bottling and the wiring.

3. Sighting.—It is a frequent and perhaps general practice in sighting for two bottles to be held up at the same time. They may be knocked together and burst in this way. A further danger is attendant

on the knocking of the bottles in withdrawing, or replacing, them in the case.

4. It will be noted that serious accidents have resulted from the bursting of the bottles in the crates, or when stacked or moved about on the trolleys. A simple means to diminish this risk, adopted by one firm, was to cover the cases or crates with a cloth or sacking.

LITERATURE.

1. Eschenauer, *Muench. Med. Woch.*, 19, 1904.
2. S. C. Ayres, *Amer. Journ. Ophth.*, May, 1908.
3. Wilson Johnston, *Ophthalmology*, July, 1909.
4. Conkey, *Ophth. Record*, May, 1905.
5. Hanke, *Dis. of Eyes due to Certain Trades*, Halle, 1904.
6. Simeon Snell. a. *On the prevention of eye accidents occurring in trades.* London, 1899. b. *Special rules for bottling of aërated waters.* Form 701, Home Office Inspector of Factories. London, Sept., 1901.

C. THE PREDILECTION OF CERTAIN FORMS OF INJURY FOR CERTAIN PARTS OF THE EYE.

Certain forms of injury are more apt to happen to some parts of the eye than others. Cuts and gashes occur mostly upon the anterior portion of the eye and its protecting organs, the lids, globe, cornea, ciliary region. Perforating wounds may go from the cornea and sclera through the bulb into the orbit and the optic nerve. Lacerations, tears, and the wounds from the bites of animals, are upon the more exposed parts, while shot wounds affect all portions of the eye. Flying foreign bodies or motes are usually found under the lids, though they may be impacted in the outer part of the bulb, especially the cornea. These consist of cinders, iron and copper splinters, the latter of which are often imbedded in the anterior, or even go to the posterior portion of the eye, remaining in the iris, vitreous, or the coats. The cornea most often contains foreign bodies, less often the conjunctiva and sclera. The effect is most apparent upon the outer portions, the lids, brow, and then the bulb. In the eye itself they cause tearing of the retina and chorioid, the blow indenting the eye and may push the lens away, causing detachment. Burns and cauterizations, as a rule, affect only the outer structures, the lids, cornea, and conjunctiva. The same may be said of burns from flame, the effect of lightning, electricity and sunlight, which may affect the lens and later the retina.

(D) OBJECTS CAUSING OCULAR INJURIES.

W o u n d s. On account of the great sensitiveness of the cornea, the formation of scar tissue and the danger of infection, a very small solution of continuity of this membrane is of great importance. All substances which come in contact with the surface of the cornea are apt to cause erosions. These may occur from the fingernail, pieces of straw, and

twigs. Cuts of the eye obtain from sharp instruments, such as knives, shears, glass; thin points of metal such as tin, and all cutting substances. Piercing wounds from sharp points of metal, wood, and glass, which are round and thin, such as needles, pins, awls, nails, pieces of wire, forks and other table instruments, thorns, styles, or animals' claws; or those pointed, but not specially sharp instruments, as daggers, poinards, swords, sabers, bayonets, knives, steel pens, or those long, triangular or irregular, as the points of compasses, sharp-pointed pieces of wood, pencils, sticks, parasols, walking canes, and umbrellas. Gashes are formed by axes, sabers, daggers, etc.

Contused wounds are caused by either sharp or blunt objects of iron, wood and other stuff. Flying pieces of such substances as iron, nails, pieces of horse-shoes, and all substances used in iron works; files, pieces of wood, sticks, stone, shell, etc. Such may also occur by the horns and hoofs of cattle, the beaks of birds, which cause combined tearing and contusion. A large number of cases of whip-lash injuries have been reported. Lacerating wounds obtain through the above objects but are not particularly due to injuries by machinery, hooks, nails, or to the teeth and claws of dogs and cats. Bite-wounds, however, are generally due to dogs, except the rare cases of hunting accidents, where they occur from boars, bears, and wildcats.

Foreign bodies either remain superficial or go deep into the eye or orbit. They are either carried by the air or wind, falling upon the eye, or cinders, particles of stone, coal or wood ashes, pieces of grain or sawdust, the so-called domestic accidents.

Industrial injuries are due to machinery or hand work, and as a rule are from pieces broken loose from objects and go more deeply into the structure of the eye or into its interior. These are particles of iron, coal, copper, slate, stone, wood, bone, and those foreign bodies which are driven by explosions, such as glass splinters from exploding retorts, pieces of copper from caps or cartridges, etc.

Contusions occur from blunt or round objects, as a rule of large size; from falls on furniture, blows of fists, instrument handles, etc., or from objects which have been thrown with force, as stones, base-balls, tennis-balls, snow-balls, potatoes, apples, etc.; also from corks, glasses, concentric tops of bottles from explosion of the same.

Burns are caused by the flame itself, by the sun or electric light, from glowing rods and glass, by hot but not melted metal, by hot ashes, grains of powder, burns of the hair, from burning gas and hot steam, from hot water, oil, petroleum, pitch, etc. Cauterization due to acids, such as sulphuric, nitric, hydrochloric, phenol, vitriol, and to alkalies and caustics, as soda and potash, and to lime burns, and to methyl violet pencils, and other substances.

Shot wounds come from shot and bullets, pieces of shell and portions of fire-arms, and in many cases are complicated by burns, wounds and the impaction of foreign bodies of various materials.

Simeon Snells' figures for 359 eye injuries in the Sheffield infirmary show the kind of objects in manufacturing localities that produce ocular injuries.

STEEL AND IRON.	
Steel and iron splinters, rivets, chips, pieces of drill, file, wire, etc.	173
Nail	5
BURNS.	
Metal sparks, flashes, etc.	43
Lime	9
Gas explosion	1
Ammonia	1
Gunpowder	4
Cinder	1
Poker	1
MISCELLANEOUS.	
Dynamite and dynamite explosion, and cartridge	6
Wood, sticks, and pegs	13
Knife	8
Glass, soda water bottles, etc.	15
Pick	5
Stone	25
Fork	7
Pin	1
Fist	3
Branch of tree	1
Crane handle	1
Cork	2
Cinder	4
Coal	11
Straw	1
Cat's claw	1
Sand	1
Pen	2
Firework	1
Boiling oil	1
Tin	2
Band strap	2
Band buckle	2
Chain	1
Kick	1
Brick	1
Thorn	2
Elastic, piece of	1
Total	359

(E) BACTERIOLOGY.

The aspergillus fumigatus is the only mold that has been found to cause infection of ocular wounds. The micrococci occur in the following order: the diplo-pneumococcus, streptococcus pyogenes, staphylococcus pyogenes, aureus and albus. The ozena bacillus, gonococcus, bacillus pyocyaneus, bacillus pyogenes, staphylococcus pyogenes, citreus and fe-

tidus, micrococcus cereus, tetragenus prodigiosus, and bacillus of tetanus are less often found. To these perhaps may be later added the presently unknown micro-organism producing sympathetic ophthalmitis.

Staphylococci are constantly found in the skin at the edge of the lid and sometimes in the normal conjunctival sac, streptococci and pneumococci are never found in the normal eye according to Parsons[1] and others.

Uhthoff[2] found streptococci rarely, and other authors comparatively frequently.

McKee[3] reports 140 cases examined, of which 40 gave negative results. The organisms isolated in the 100 positive cases were as follows:

Staphylococcus pyogenes albus	28 times.
Staphylococcus epidermis albus	9 times.
Staphylococcus pyogenes aureus	2 times.
Streptococcus pyogenes	16 times.
Bacillus xerosis	42 times.
Bacillus of diphtheria group	1 time.
Sarcina lutea	1 time.

His experience has been that in the great majority of normal conjunctivæ the ordinary pyogenic bacteria and the bacillus xerosis are present.

Kuffler[4] reports on the systematic bacteriological examinations of all clinical and polyclinical cases of conjunctivitis from January 1, 1908, 727 in all. 64 per cent. yielded positive, 36 per cent. negative results, viz.: diplobacilli 306 = 42 per cent., diplobacilli and pneumococci 26 = 4 per cent., pneumococci 55 = 8 per cent., xerosis 41 = 6 per cent., staphylococci 13 = 2 per cent., gonococci 7 = 1 per cent., diphtheria 5 = 1 per cent., pneumobacillus 1, negative 274 = 36 per cent. The clinical findings in the negative cases were: acute simple conjunctivitis, chronic conjunctivitis apparently caused by chemical, thermic or mechanical irritations, follicular catarrh.

The majority of the 40 cases of dacryocystitis showed, in concordance with other authors, pneumococci as the cause of infection.

In three cases of panophthalmitis, bacillus subtilis was found—i. e., in 2 exclusively and in one with pneumococci, 3 were caused by pneumococci and 1 by streptococcus mitior, which is described in detail.

Wirtz[5] in describing a case of total suppuration of the cornea from a squint operation done shortly after an attack of angina found the streptococcus longus, which is very rare on the normal conjunctiva, but frequent in the pharyngeal secretions, and is found in enormous quantities in inflammations. The mode of infection apparently was the following: During the angina streptococci were conveyed from the pharynx to the conjunctiva, on which they lived without danger to the

normal conjunctiva. As soon as the mucous membrane, by the operation and the constricting knot of the suture, lost its normal condition and the virulence of the germs was increased on the albuminous substrata, mixed with cast-off epithelia, they could exert their pathogenic faculties. They produced blenorrheic inflammation, infected the operative wounds and invaded the cornea through blood and lymph currents.

The case teaches: In angina the streptococci, always present in the pharynx, may spread to the conjunctiva, without causing clinical disturbances.

They become pathogenic and dangerous to the eye if by an operation the vitality of the tissues has been lowered. Therefore special caution is necessary before an operation in cases recovering from recent angina. The mere subsidence of the clinical symptoms or the integrity of the conjunctiva do not allow it, but the existence of germs on the conjunctiva must be investigated by culture and if streptococci are found disinfecting treatment must be instituted.

Uhthoff and Axenfeld[6] found, in 1896, the pneumococcus to be the cause of the typical hypopion ulcer, ulcus cornea serpens, and their results have been confirmed by investigations in all parts of the world.

In 50 cases they found pneumococci only in 26, and mixed with other organisms 7 times, other bacteria only 13, no bacteria 4.

Is it possible for an infection to spread through an uninjured conjunctiva? Stock[7] and Hirota[8] answered this important question after experimenting in this direction. The former allowed colonies of the bacterium pyocyaneus prodigiosus and staphylococcus to set on the healthy conjunctiva for one hour, and no infection followed; he then showed that when the lacrimal canaliculi were closed no germs passed into the eye from the nose. Hirota proved that the bacillus of mouse septicemia, the pneumococcus and the germ of chicken cholera, can produce a general infection of the body through the uninjured conjunctiva. The effect of the anthrax bacillus could not be determined, but the author showed that after closing the lacrimal passages general infection was absent. These experiments, therefore, prove positively that the road of infection is by way of the lacrimal passages, and that no bacteria can penetrate through the healthy conjunctiva.

Vollaro[9] made a bacteriologic study of the conjunctiva after operations in eyes left open to the air and in others treated with occlusive dressings. In the first instance only a few folds of gauze were placed over the eye under a wire shield fastened to the brow, nose and cheeks. He concludes that in the cases treated by the "open" method there is an increase in the number of germs in the conjunctiva a certain number of hours after the operation, but this increase is much less in

eyes treated with an occlusive bandage. It is also noticeable that the germs found are the same species several hours after the operation as immediately before it.

Bietti[10] recalls the interesting researches of Ulbrich, who, from numerous experiments, arrived at the conclusion that a part, at least, of the post-operative infections were caused by saprophytes. He experimented with oidium albicans, sarcina gallia, bacillus violaceus, bacillus radiciform and bacillus megatherium. Dilute cultures were injected into the eye and strong cultures introduced from the platinum point. The oidium albicans and sarcina gallia, inoculated in emulsion, gave an intense reaction, in dilute solution a less virulent reaction. Usually with these germs there was formation of an exudate, occupying the pupil only partially, which was absorbed in from one to two weeks without leaving posterior synechiæ. A reaction of the same, or only slightly less, intensity was obtained with sterile broth with which the cultures had been diluted. With bacillus violaceus a true plastic iritis followed in one-third of the cases, which was conducive to the formation of an ectasia of the cornea and the anterior segment of the eye through increase of tension. Bacillus radiciform and bacillus megatherium determined not only plastic iritis with occlusion and seclusion of the pupil, but a true panophthalmitis with perforation of the cornea and the sclera, followed by phthisis bulbi. The introduction into the anterior chamber of the germs on a platinum point caused generally an insignificant reaction. Once the bacillus radiciform produced occlusion and seclusion of the pupil, and another time the bacillus megatherium caused ectasia of the cornea and the anterior segment of the eye. Bacteriologic examination of the aqueous of the inoculated eyes showed that the oidium albicans and sarcina gallia were not alive three hours afterward in the strong cultures. The bacillus violaceus, bacillus radiciform and bacillus megatherium showed a greater resistance, numerous colonies developing twenty-four hours after inoculation of dilute cultures.

Clinically it is necessary to differentiate between spongy iritis and the condition of actual infection of the wound. In iritis the upper section of the cornea becomes hazy, the anterior chamber shallow, the iris swollen and hyperemic and the anterior chamber is partly filled with a dark mass of spongy exudation. Infection appears as a white point in the line of incision, rapidly spreading until the whole cut is a dense white line, sharply outlined against the comparatively clear cornea. The anterior chamber is at first clear and later occupied by a dull white mass suspended in its upper section, or protruding through the pupil.

LITERATURE.

1. Parsons, *Pathology of the Eye*, Vol. I, 1905.
2. Uhthoff, ref. Parsons, Vol. I, p. 38.

3. Hanford McKee, *Montreal Med. Journ.,* Jan., 1906.
4. Kuffler, *Zeitschr. f. Aug.,* xxii. 1909, p. 405.
5. Wirtz, *Zeitschr. f. Aug.,* Jan., 1910.
6. Uhthoff and Axenfeld, *Ach. f. Aug.,* xliii, 1, 1896.
7. Stock, *Klin. Mon. f. Aug.,* xli, 1903.
8. Hirota, *Wein. Med. Woch.,* May 21, 1904.
9. Vollaro, *Arch. di ottal,* Nos. 7-8. 1905.
10. Bietti, *Ann. di ottal.* Nos. 11-12, 1905.

CHAPTER III.

THE MECHANISM OF OCULAR INJURIES.

A. The protection afforded by Nature—B. Disposition of diseases and abnormal eyes to injury—C. Traumatism as an exciting cause of constitutional eye diseases—Literature—D. Mechanism of special types of injuries.

(A) THE PROTECTION AFFORDED BY NATURE.

The ocular globe is suspended and held in place by elastic and muscular bands, and rests upon a cushion of fat. It glides within a slippery capsule and is protected from flying objects, that can be seen, by the rapid reflex closure of the lids and the quick movements of the globe; from large objects by the protection afforded by the bony case of the orbit, by the projections of the brow, cheek and nose on all sides, except outwards and downwards, and by the rapid movements of the head, by which the approach of large objects may be dodged. Thus it is that the myriad of moving objects coming in the direction of the head and eyes in daily life are escaped, and only unforeseen or accidental injuries occur, and this to but a small percentage of the population. Even after the impact of a foreign body the reflex closing of the lids, the copious lacrimation and rolling of the globe assist in some cases in the extrusion of the intruder.

(B) DISPOSITION OF DISEASED AND ABNORMAL EYES TO INJURY.

Weak sight disposes to injury because of the individual not seeing well enough to escape accidents, as well as specific injuries, to the eyes.

Diseased and abnormal eyes, as in those suffering from senile degeneration and weakened walls of the blood vessels, are predisposed to bleeding into the tissues from contusions and concussions, and to this condition persons suffering from arterio-sclerosis, glaucoma, diabetes, leukemia, and renal disease are likewise subject.

High grades of myopia—i. e., over 10.00 D.—are subject to retinal detachment, which is estimated to occur in 5 per cent. of the cases (Mooren,[1] Leber.[2])[3]

The exciting cause of this may be ascribed to some slight local injury. Rupture of the sclera is predisposed by posterior staphyloma, due to myopia, and rupture of the cornea from anterior staphyloma.

Congenital ectopia lentis may be caused by a weak zonule, and oc-

casioned by injury to the maternal abdomen before delivery, or by pressure an the maternal tract during delivery.

Scrofula, tuberculosis, and syphilis predispose to weakened tissues and poor resistance to injury as well as to poor restitution. In the case of bruising of the rim of the orbit periostitis, caries and necrosis may follow.

Injury to the cornea in syphilitic subjects may give rise to typical interstitial keratitis, or inflammation of the iris and ciliary body.

LITERATURE.

1. Mooren, *Centralbl. f. prak. Aug.*, Jan., 1897.
2. Leber. *Arch. f. Ophth.*, xlii, pp. 218-251.
3. Würdemann, a. *Ann. Ophth.*, Apr., 1899; b. *Journ. A. M. A.*, Nov. 28, 1903.

(C) TRAUMATISM AS AN EXCITING CAUSE OF CONSTITUTIONAL EYE DISEASES.

Guillery[1] discusses the question whether parenchymatous keratitis can be elicited by traumatism in an individual of hereditary tuberculosis or syphilitic predisposition, and answers it in the affirmative. He shows that the predisposition in tuberculosis and syphilis consists in a circulating metabolic poison, as in other infectious diseases, influenza, malaria, etc. The poison in hereditary lues shows itself in a predilection for establishing its action in the cornea, and more so if the resistance of the latter is weakened by traumatism. The development of parenchymatous keratitis in the other eye in a case under consideration is also explained by a toxic action on the cornea of the second eye, prepared for it by the sympathetic (not in the usual sense) influence of the traumatism affecting the first eye. We know that after injury of one cornea, the pericorneal and other blood vessels of the anterior segment of the second eye are frequently injected, which cannot be without influence on the consistency of the aqueous and the nutrition of the tissues, even if they do not lead to marked inflammation. In hereditary lues it is not the sympathetic irritation as such which produces keratitis in the second eye, but its combination with the enzymatous poison of hereditary lues.

If we knew a poison which had the same bio-chemical relations to the uveal tract as the poison of syphilis must have to the cornea, and were we allowed to suppose that in typical sympathetic ophthalmia it circulated in the body, the understanding of the former would meet with no obstacles, and we would not need to search any longer for bacteria. (See also Cornea.)

Aubineau[2] says traumatism may be the exciting cause of syphilitic iritis and it is possible that a corneal wound may be the point of entrance for an exogenous infection, or a syphilitic iritis may be superimposed on an iritis from other cause.

Not only may a trauma develop benign growths in the conjunctiva, cornea, and iris, such as granulation tissue and polypi of the conjunctiva, cysts of the cornea and iris, but it may likewise be the exciting cause or point of entrance for tuberculosis and sarcoma, and a differential diagnosis is essential. This may be made by the microscope and bacteriologic cultures.

Wound of the conjunctiva from a bite, according to Stutzer,[3] has produced conjunctival tuberculosis (epithelioma of the conjunctiva by Chapman[4]).

Granuloma of the iris has been observed after abscission of the cornea for staphyloma by Knapp,[5] by de Wecker[6] after a blow on the eye in the case of a weakly child, in which the eyeball became phthisical by Hirschberg and Steinheim[7] in the case of a piece of wood in the iris.

Tubercle bacilli may enter the iris after trauma, as has been many times experimentally produced in rabbits for laboratory diagnosis in suspected cases.

Treitel[8] reported the case of a girl 12 years old who four months before had injured the eye with a straw. A small tumor developed in the iris, and, removed by iridectomy, the miscroscopic examination showed tuberculosis.

LITERATURE.

1. Guillery, *Klin. Mon. f. Aug.*, 1, 1905, p. 630.
2. Aubineau, *Ann. d'oculist*, Aug., 1905.
3. Stutzer, *Beitr. z. Aug.*, xxx, p. 10.
4. Chapman, *Arch. f. Aug.*, iv. 1, p. 197.
5. H. Knapp, *De intraocularen Geschwulste*, 1868.
6. de Wecker, *Graefe-Saemisch*, IV, p. 540.
7. Hirschberg and Steinheim, *Arch. f. Aug.*, I, 2, p. 144.
8. Treitel, *Berl. Klin. Woch.*, 1885, p. 445.

(D) MECHANISM OF SPECIAL TYPES OF INJURIES.

Wounds. Incised, piercing, and flap wounds are produced by sharp instruments or objects applied with more or less force, while contused, lacerated, and bite wounds are more often of the nature of tears produced by blunter instruments.

Foreign Bodies. Small objects, as motes, may be borne by the wind, carried to the eyes, stick to the conjunctiva, and become impacted therein, or are carried under the lids and by rubbing may be impacted into the cornea. Others come with force from the breaking of an object and are impacted directly, or if hot burn themselves a place in the tissues. Such are hot coals and chips of iron, stone, wood, etc., happening in the case of industrial workers. Large foreign bodies from metal, such as iron, copper and stone, usually occur in the course of trades, from chipping, grinding, fettling and the like. Glass, from the bursting

of bottles and glass vessels, steam gauges, etc. Explosions of fire-arms, powder and dynamite result in the impaction of foreign bodies, not only from the exploding compound, but from surrounding objects.

Contusions and Rupture. Contusions cause both direct and indirect damage, the direct, by impaction of the object, and indirect, from rebound of the tissues from the elastic contents of the orbit and its bony walls. Ruptures occur through compression and inward pressure, which, when the coefficient of resistance of the structure is reached, causes disassociation of contiguity and bursting. If the structure gives under the force it breaks away from its surroundings and direct rupture with dislocation results.

Rupture of the cornea or sclera is produced by the pressure of the foreign body being so distributed that there is no place for the globe to go and it thus bursts.

In direct rupture the break occurs at the point of pressure in another part of the globe. The mechanism of corneal, scleral, iridic and chorioidal ruptures are under the anatomic headings.

Thermal, Solar and Electric Injuries. The mechanism of these injuries is, in thermal causes, mostly that of burning, in solar, that of burning combined with the electro-chemic effects of ultra-violet light. In electric injuries burning, light, and electrolysis, and in some instances the effect of concussion.

Combined Injuries. The effect of explosions of gunpowder and dynamite, and of fire-arms, causes, through a combination of wounds, with and without penetration of foreign bodies, contusion, concussion, ruptures, burning, and infection.

Infected Wounds. Infected wounds have the characteristics of other wounds, combined with loss of tissue from ulceration due to necrosis, following the development of micro-organisms within the orbit. The infection may be carried by the object producing the injury, by accompanying foreign bodies, exposure to the air, or by contact with fingers, unclean instruments, medicaments, or bandages.

CHAPTER IV.

COMPLICATIONS OCCURRING DURING AND AFTER OCULAR INJURIES.

I. Infections. A. Suppurative infection of the Uvea—Panophthalmitis, definition, etiology—Infection through corneal cicatrices, symptoms and course—Phthisis bulbi—Atrophia bulbi, diagnosis, prophylaxis, therapy—Literature. B. Iridocyclitis traumatica—Keratitis punctata—Panel-like keratitis, etiology, symptoms, course, diagnosis, prognosis, prophylaxis, therapy—Literature. II. Sympathetic ophthalmitis, synonyms, definition, history—(a) Pathology, rarity of sympathetic inflammation and panophthalmitis, proliferation, uveitis and endophthalmitis—(b) Theories of transmission—1. The ciliary nerve theory—2. The migration theory—3. The predisposition and malnutrition theory—4. The intoxication theory—5. Criticisms of theories of transmission. (c) Conditions of the exciting eye—1. Sympathetic inflammation—2. Sympathetic irritation—(d) Duration and incubation—(e) Symptoms and course—1. Sympathetic irritation—2. Sympathetic inflammation in the exciting eye—(f) The sympathizing eye—1. The disease in the sympathizing eye, Clinical types, Iridocyclitis plastica, Chorioiditis plastica, Iridocyclitis serosa, Chorioiditis serosa, Neuroretinitis sympathetica. Mixed forms or indifferently described cases of sympathetic ophthalmitis—(g) Diagnosis—(h) Prognosis—(i) Prophylaxis—(j) Therapy, Local treatment of exciting eye, General dietetic, hygienic and medical treatment, Dangerous conservation, Rules for enucleation—(k) Sympathetic ophthalmitis occurring after substitutes for enucleation—(l) Post-sympathetic operation, Treatment of the sympathizing eye and upon the exciting eye—(m) Sympathetic ophthalmitis after shot wounds in war—Literature.

Wound infections, inflammation of the injured and the fellow eye, surgical diseases, tumor formations, psychoses, neuralgia and the traumatic neuroses.

(I) INFECTIONS.

Infection seldom occurs from injury to the lids or conjunctiva, but commonly by both perforating and non-perforating wounds of the globe, especially of the cornea, and in perforating wounds of the uvea in the following order: the ciliary region, iris, and chorioid.

Infections of the cornea will be mostly found described under Cornea.

(A) SUPPURATIVE INFECTION OF THE UVEA.

Panophthalmitis.

Definition. From the entrance of the virulent germs into the interior of the eye suppuration of the uveal tract arises, which, when

limited mostly to one structure, is known as purulent iritis, chorioiditis, cyclitis, etc. Usually, however, the disease affects the whole uvea, being known as uveitis suppurativa traumatica, and when, as it usually does, proceeds to involve the vitreous, retina, and extend through the sclera to Tenon's capsule, it is denominated panophthalmitis.

Etiology. The infection arises in three ways: Either through primary or secondary infection of the uvea by perforating wounds with or without retention of foreign bodies; through perforating or non-perforating infected wounds or ulcers of the cornea and migration of

Fig. 16.
Incised wound of sclero-corneal margin, infected and giving rise to panophthalmitis with edema and protruding conjunctiva.

pus germs into the interior of the eye; through late infection of thin cicatrices, as cystoid cicatrix, or, more seldom, staphylomatous or leucomatous corneæ, or in metastatic non-traumatic ophthalmitis from a nidus in other parts of the body. The infection is either carried by the object producing the injury or already resides in the eye, as in staphylococci, on the edges of the lids, streptococci, pneumococci, and other germs in the conjunctival cul-de-sac, or most frequently from suppurative tear-sac disease, or is carried there by fingers, medicaments, instruments or bandages.

Creste[1] reports penetrating wound of globe by whiplash followed

by severe panophthalmitis, due to infection by bacillus refringens and b. subtilis. The second case on record since that of Vigier.

Infection of the uveal tract through corneal cicatrices has been studied by Leber,[2] Wagenmann,[3] Dolganoff and Sokaloff,[4] the latter of whom have recently so thoroughly elucidated the subject that I here give their conclusions:

"A purulent infection which begins in a corneal cicatrix quickly spreads to the deeper parts of the eye.

The clinical course of this disease is typical, and its characteristic symptoms seem to be a remarkable disproportion between the insignificant injury with which it is started and its rapidity and violence.

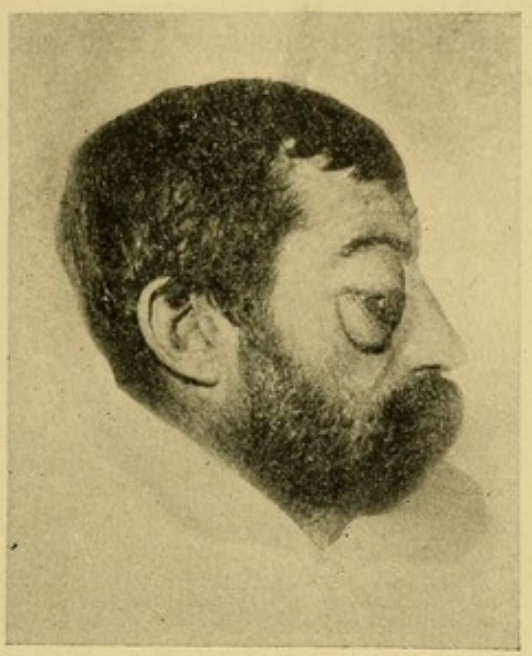

Fig. 17.
Panophthalmitis and cellulitis of orbit.

With very rare exceptions the disease is uninfluenced by treatment and results in the loss of the eye.

No explanation of its characteristic course can be obtained clinically. The existing theories fail to explain all symptoms and seem to be disputable.

The epithelium of the cicatricial cornea, while intact, serves as a protection against the entrance of infective germs from the conjunctival sac into the deeper tissues.

Very virulent cultures of streptococci and staphylococci in the conjunctival sac cause only an acute catarrh of the mucous membrane, which rapidly passes away without producing any injury to the eye.

The introduction of a pure bouillon culture of staphylococci into the

superficial layers of a leucoma is productive of a typical corneal ulcer, with a precedent abscess.

The characteristic points of these ulcers appear to be the fixed course, the ring-like arrangement, and the tendency to hypopion.

The virulence of the culture is an important feature.

The introduction of a pure bouillon culture of streptococci is productive of an infiltration, which quickly changes to an abscess and, on the second day, to an ulcer with hypopion. No clinical difference exists between a hypopion caused by streptococci and one due to staphylococci.

After the inoculation of a culture of either staphylococci or streptococci into both the normal and the cicatricial cornea of the same animal, there is a much more rapid development of symptoms in the eye with cicatricial cornea than in the other.

The cicatricial cornea also melts away much more rapidly than the normal under the influence of these cultures.

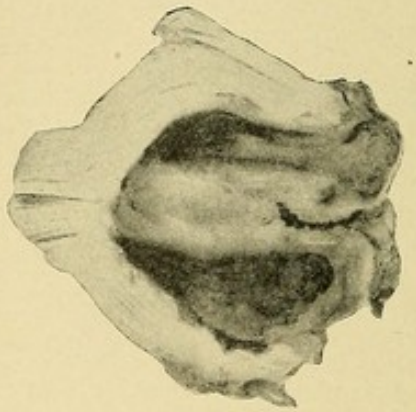

Fig. 18.
Section of panophthalmitic eye.

After the introduction of cultures of staphylococci into the normal cornea there is to be observed, in addition to a superficial ulceration at the point of inoculation, a ring-shaped ulcer with a characteristic deposit at the periphery of the cornea. Streptococci do not produce a similar ulcer in the normal cornea.

The ulceration produced by the inoculation of staphylococci and streptococci in the superficial layers of the cornea extends in the leucoma chiefly into the depth of the scar, while in the normal, after an equal lapse of time, it is confined to the superficial layers without involvement of the deeper.

The micro-organisms have passed through the corneal cicatrix into the anterior chamber at a time when the ulceration has only just involved the most superficial layers of the leucoma; therefore, the destruction of the cicatrix is not necessary for their passage through it, but only a solution of continuity in its epithelial covering.

Colonies of staphylococci of the virulence used in these experiments have passed through the leucoma into the anterior chamber at the end of the second day after inoculation.

Two days after inoculation of the normal cornea with staphylococci of the same virulence the colonies have not penetrated deeper than its middle layers, and this proves that their movement is restricted in the normal as compared with the cicatricial cornea.

Colonies of streptococci have passed through the cicatricial cornea into the anterior chamber ten hours after their superficial inoculation.

In the normal cornea the colonies of streptococci are still limited to the place of inoculation after ten hours.

A defect in Descemet's membrane, at a point corresponding to the place of inoculation in the superficial layer of the leucoma, appears to be an indispensable condition for the passage of the micro-organisms through the cicatrix into the deeper parts of the eye.

If the inoculation is made at a point not corresponding to the defect in Descemet's membrane, but at some distance away, the microbes cannot penetrate into the deeper parts of the eyeball, even after they have become well developed in the leucomatous tissue, and so a general infection is not brought about.

This restraint of the micro-organisms appears to be exercised by the ring of infiltration which is formed between the colonies of microbes and the place in the cicatrix which corresponds to the defect in Descemet's membrane.

A passage of the microbes into the anterior chamber could not be demonstrated when, though the leucomata were extensive, Descemet's membrane was uninjured, but the leucomatous tissue ulcerated much more rapidly than the normal.

The density of the cicatrix and the absence of a fistula afforded no hindrance to the passage of the micro-organisms.

The entanglement of the iris in the cicatrix does not influence the general course of the disease.

The iris plays an important part in the formation of the hypopion."

Schoeler[5] reports the case of a man, aged 43, morphine fiend, and orderly at the eye clinic of Prof. Schoeler, infected his right index finger with pus of a blennoerrhic child, and suffered severe pain during the night. The next day he was admitted to the surgical clinic. The finger was very much swollen and discharged thin pus from an erosion which microscopically looked gonorrheic and contained Gram negative diplococci in form of gonococci, especially in the leucocytes, but no cultures were made. He was treated by passive congestion, but after about a week an abscess formed on the dorsal surface of the hand, which was incised. Then an abscess formed on the left thigh after an injection of

morphine. The wound of the hand had a bad appearance. Two weeks later the patient became septic, was icteric, had chills and fever of 40° C. His feet swelled and an abscess formed under the left toe. The examination of the blood was negative. He died about four weeks after the infection.

In his review on gonorrheic general infection and metastases C. von Hofmann[6] collected 400 cases from 1890 to 1903, out of which only one was not metastatic. On the other hand, Schleich[7] published eight cases of severe and protracted infections of wounds of the fingers with gonorrheic secretions. Seven of these occurred in physicians, and the affection was therefore called "physicians' disease." As the possibility cannot be denied that the infection in Schoeler's case, terminating fatally, was due to gonococci, he considered it his duty to publish this case to warn against this danger.

Symptoms and Course. Purulent infection of the bulb is usually a true panophthalmitis characterized by a violent inflammation of all the tissues.

Twelve to twenty-four hours after the injury the patient complains of headache, and a pressing or boring pain in the eye. Fever, rigors, and a tendency to vomiting occur. The fever may reach 105° Fahr., but is usually 102-103. The lids, especially the upper, are swollen and edematous, the conjunctiva is chemosed and protrudes through the aperture of the lids, through which a purulent secretion extrudes, so that the veriest tyro in medicine could diagnose suppuration.

On lifting the lid the edges of the wound are found to be infiltrated and a yellowish exudate protrudes. Radial infiltrations proceed toward the center of the cornea, and on further course of the complaint, onyx or ring infiltration and collection of pus within the layers appears. A purulent exudate is found in the pupil where iritis has already resulted in synechiæ formation. Hypopion is usually present, which may fill the anterior chamber. The aqueous is turbid and may be entirely replaced by the purulent exudate.

The swelling of the conjunctiva and the pain and inflammatory symptoms become greater, the eye protrudes from the swelling of the sclera, Tenon's capsule and the orbital tissues. The sight is lost and the pain becomes fearful, until perforation occurs at the equator in the zone between it and the limbus. Through this the pus flows and the symptoms abate, usually with recidives, and the eye shrinks more and more to the size of a marble, cherry, or even a bean in the course of four to six weeks. There may be recurrent pain, but ultimately the stump becomes insensitive.

In the very beginning, before opacity of the media occurs, the oph-

thalmoscope may show fine hemorrhages into the retina, and reflex of the light shows a yellowish exudate into the vitreous.

In but few cases the infection is largely limited to the iris, and a subacute infection with resultant filling in of the pupil by exudate.

In a few cases, especially those of chemical irritation from particles of copper within the eye, the general symptoms and ocular signs of severe type do not occur and the eye may be saved with vision by appropriate treatment.

Beginning infection in operative cases may likewise be combated by cauterization of the wound and antiseptic treatment. These cases, however, usually result in blindness and phthisis bulbi.

The distinction between phthisis bulbi from suppurative disease and atrophia bulbi from plastic inflammation is that after panophthalmitis

Fig. 19.
Atrophia bulbi.

the suppurating vitreous and contents of the globe come out, immediately resulting in a smaller eye which rapidly shrinks to a small stump. Atrophy of the globe is a gradual process from the contraction of exudates after iridocyclitis by which the globe becomes somewhat smaller than normal, but never results in the small stump of phthisis bulbi.

D i a g n o s i s. The diagnosis is apparent to the most inexpert from the history of accident and the severe local and general suppurative symptoms.

In a few cases when the suppuration begins in the posterior part of the globe, the so-called chorioiditis suppurativa, where at the first the anterior portion and the media are clear, the ophthalmoscope aids the exhibition of the purulent exudate, which appears as a yellowish mass in the vitreous behind the pupil.

The so-called pseudo-glioma, or new-tissue formation in the vitreous from circumscribed purulent disease, may, however, have the appearance

of intra-ocular new-growth from which it is to be differentiated by the history of the wound, its yellowish gloss, and no increase of tension, together with, in the case of tumor, the size, shape, blood vessel formation, and as a rule, at first no inflammation.

Prophylaxis. The prophylaxis of infection, with the immediate care of infected wounds, may prevent the development of panophthalmitis. The prophylactic treatment is at first that of infected wounds, with galvano- and actual cautery, carbolic acid, or injection of salt sublimate or cyanide of mercury subconjunctivally or iodoform discs or solution of 50 per cent. argyrol into the anterior chamber.

Hirschberg[8] reports two cases of cystoid scars after cataract extraction which commenced to suppurate five and one-half years later. The scar was purulent, the pupil covered by a purulent membrane and hypopion. Hirschberg cauterized the scar and cornea with galvano-cautery, opened the anterior chamber at the lower limbus and removed the

Fig. 20.
Phthisis bulbi.

hypopion and purulent membrane with a pair of forceps. In both cases the eyes, which had seemed completely lost, were saved. It is of the greatest importance that this treatment be commenced at once.

Therapy. The treatment of panophthalmitis itself is symptomatic. Constant lukewarm antiseptic wet compresses, 5 per cent. dionin locally, and morphine hypodermically, or chloreton internally for analgesia. Frequent instillations of 10 per cent. argyrol or 5 per cent. protargol, or keeping the lid aperture filled by 1 :3000 sublimate of mercury ointment, and the secretions wiped or washed away, constitute the medicinal treatment.

Just as soon as the vitreous chamber is determined to be filled with pus and the intraocular tension is increased, the globe should be kept open by a 1½ cm. incision through the sclera between the insertion of the external and inferior recti tendons, a drain of iodoform gauze inserted, and the eye kept clean by boric acid solution every two hours. If the pus apparently points at another place incision may be made there, or the opening may be enlarged to permit of free drainage. Secondary incisions may

have to be made. As a rule, however, the symptoms abate after free incision and drainage.

The enucleation of an eye in the active stage of panophthalmitis is not to be undertaken except where cellulitis with apparent pus formation in the orbit has occurred in which, after incisions into the eye and orbit have been made, the symptoms do not abate; otherwise pus germs may get into the opened lymph and blood channels of the orbital tissues and be carried to the brain, producing meningitis and death. Even so has exenteration or evisceration of the globe been reported by Schuleck[9] to have caused meningitis. Becker[10] collected the histories of 43 cases of meningitis and death after enucleation. Praun,[11] however, recommends exenteration in uveitis suppurativa where Tenon's space has not yet been affected, and cites his experience covering 60 such operations.

If the disease has been apparently cured, yet after a couple of months the stump becomes recurrently painful it had better be removed to avoid sympathetic disease, which is not absolutely excluded, as was formerly thought to be the case, by plastic closure of the lymph spaces and vessels following a panophthalmitis.

LITERATURE.

1. Creste, *Ann. d'oculist.*, Jan., 1910.
2. Leber, *Arch. f. Ophth.*, xiv, 1, p. 284.
3. Wagenmann, *Arch. f. Ophth.*, xxv, 4, 5.
4. Dolganoff and Sokaloff, *Arch. Ophth.*, July, 1905.
5. Schoeler, *Klin. Mon. f. Aug.*, xlvi, 11, 1908, p. 58.
6. Von Hoffmann, ref. Schoeler.
7. Schleich, *Centralbl. f. prak. Aug.*, 1905, p. 193.
8. Schulek, ref. Praun, p. 63.
9. Hirschberg, *Central* 61, *F. prak. Aug.*, 1889, p. 267.
10. Becker, *Univ. Augenklinik.*, Heidelberg, 1888.
11. Praun, l. c. p. 65.

(B) IRIDO-CYCLITIS TRAUMATICA.

Definition. A chronic, severe and plastic inflammation of the injured eyeball which affects most of the intra-ocular structures, being marked in the uveal tract, and ultimately leading to atrophy, is here called irido-cyclitis.

Such cases have been described as chronic plastic irido-cyclitis, irido-chorioiditis, irido-cycle-chorioiditis, or as cyclitis, depending upon the portion of the uveal tract mostly affected. We here give a general description, leaving the details to the special chapters on the injuries to the uvea.

Etiology. All forms of injuries to the ciliary region may give rise to irido-cyclitis, but of special importance and frequency are perforating wounds of the limbus and foreign bodies within the globe. An originally purulent process seldom changes to the plastic type, but such is seen in corneal suppuration and in late infection through cicatrices and iris pro-

lapse. Such injured eyes lead to sympathetic irritation or inflammation in the fellow eye.

The irritation or inflammation may be due to a mechanical injury to the tissues, as seen in irido-cyclitis following lens luxation, which was the

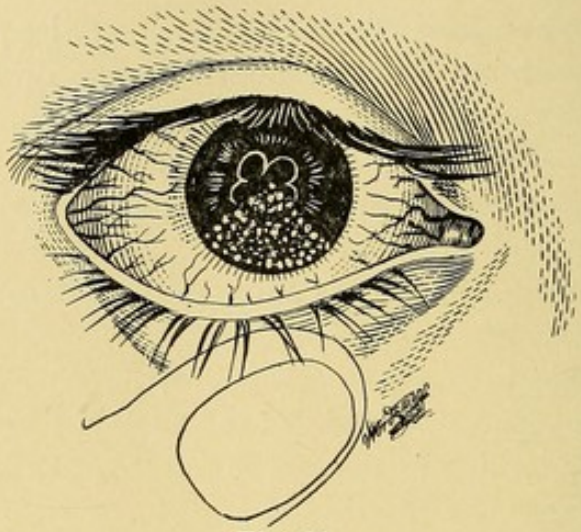

Fig. 21.
Keratitis punctata.

ultimate end of cataractous eyes operated upon by reclination in previous centuries.

It may be a chemical irritation, as from retained iron or copper foreign bodies. The latter may remain in place for months or years and then cause inflammation from further laceration due to movement of the

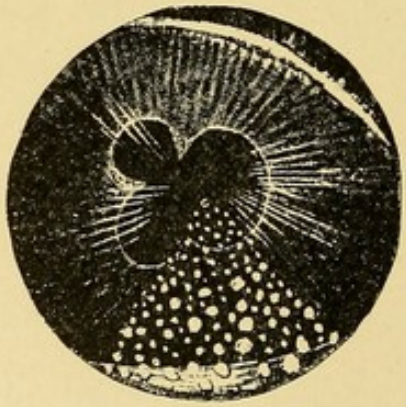

Fig. 22.
Keratitis punctata and small hypopion in irido-cyclitis traumatica. Healed cicatrix of cornea.

object, or pulling away of tissues from contraction of plastic exudate, or to chemical irritation through solution.

The production of irritation or inflammation may be due to germs themselves or the products of their metabolism, a subject which is discussed under Sympathetic Ophthalmitis. While we have not yet isolated

such micro-organisms, various authors, as Leber,[1] Deutschmann,[2] Schirmer,[3] have supposed that the spores may lie dormant for months or years and then acquire a new virulence, setting up inflammation.

Endogenous infection of the cicatrix has been supposed (Praun[4]). Late infection of the scars has been proven.

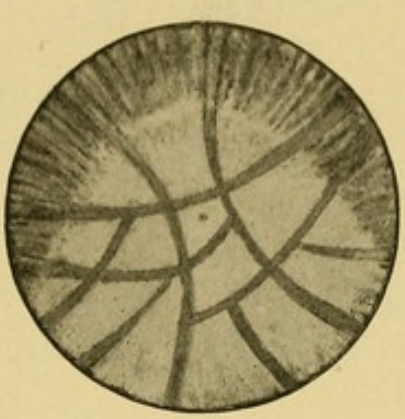

Fig. 23.
Panel-like keratitis.

Symptoms and Course. The patient gives a history of injury, and in a slight and early case complains of photophobia, lacrimation and irritation of the globe. There is pericorneal injection and some swelling of the lids and conjunctiva. The region of the injury is usually sensitive and there may be slight or piercing pains on use of the eye. The tension is diminished and the visual acuity is lowered; the visual field is

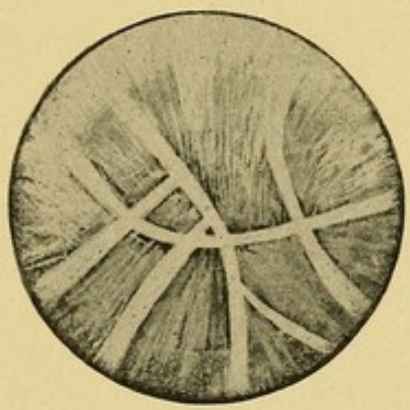

Fig. 24.
Panel-like keratitis.

contracted. The cicatrix is red or dark-violet colored with surrounding congestion. In early cases the aqueous is turbid and there may be opacities in the anterior portion of the vitreous. The iris is discolored and its finer texture not as plain as in the fellow eye. Posterior synechiæ are seen and maybe a small hypopion.

Keratitis punctata is a pathogonomonic sign of serious cyclitis. It is characterized by precipitates appearing as minute greyish dots scattered irregularly upon Descemet's membrane but mostly irregularly over a triangular portion of the lower part, the base of the trianglee corresponding to the lower corneal margin, the apex to about the center of the cornea. The larger deposits are usually below, the more numerous fine ones above. The spots are frequently pigmented, looking brown or reddish. The movements of the eyes are a factor in determining their arrangement and are shown by v. Arlt,[5] deposited centrifugally upon the cornea, and in the positions in which they occur the endothelium of Descemet's membrane is irritated and becomes sticky, so the leucocytes readily adhere to it. Larger aggregations occur in older cases and often assume a yellowish, gelatinous appearance. Fuchs in 1884[6] found that they consist in aggregations of leucocytes, many of which contain

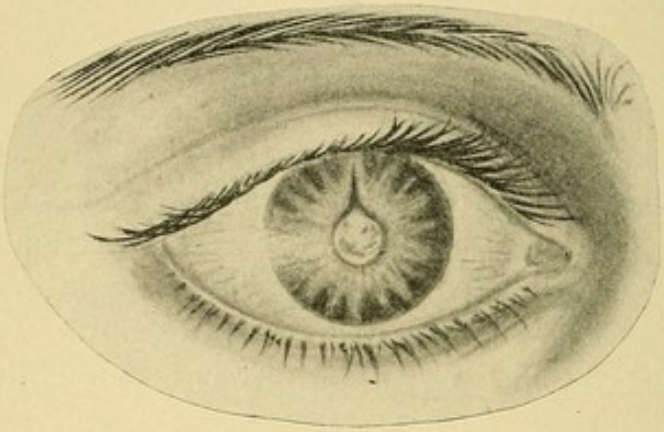

Fig. 25.
Iris bombé from sympathetic irido-cyclitis.

pigment granules and are derived from the uveal tract, mostly from the ciliary body. Proliferation of endothelium may occur, as shown by Uhthoff and Axenfeld.[7] The larger deposits show a hyaline degeneration of the cells. (Parsons[8]). These deposits may likewise be found upon the lens capsule.

As the case progresses the cornea becomes grayish and may be striped (panel-like). Then follows development of a large fibro-plastic exudate in the pupil, between its edges, between the iris and lens, ciliary body and lens, and in the vitreous. The visual acuity is lost, the light projection becomes more and more uncertain and blindness results. If the pupil fills up with exudate the condition is known as occlusion; if a complete posterior synechia forms, as seclusion; if only the rim of the iris adheres to the anterior capsule of the lens, the pupil is secluded but the posterior chamber is enlarged from the iris bulging forwards in a ring. This condition is known as iris bombé. The lens becomes

opaque and the vitreous opacities further develop. As a rule the tension is very much diminished, so that the globe becomes very soft. However, in a few cases glaucomatous increase of tension may arise, but the disease usually eventuates in contraction of the exudate, atrophy of all the structures and atrophia bulbi.

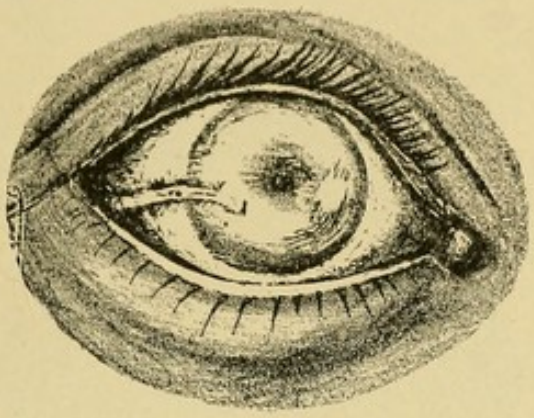

Fig. 26.
Atrophia bulbi with extensive opacity of the cornea in an exciting eye, which many years later caused sympathetic irritation in the other.

Villard[9] reports a case resulting from a minute wound in the ciliary region by a fragment of steel which was removed immediately after the accident. There was nothing remarkable in the progress of the case until the twenty-fifth day, when the patient, without any warning, suddenly fell back upon his bed and died instantly. There was no autopsy.

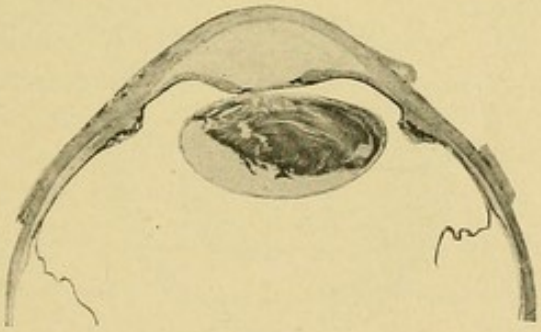

Fig. 27.
Section of eye with irido-cyclitis showing iris bombé.

The author thinks that the cause of death was a cerebral embolus originating in the veins of the orbit, but it seems more likely that the man died of heart disease.

Atrophia bulbi.

From the shrinking of the exudate the vitreous chamber becomes smaller, the retina becomes detached in a funnel-like form, the cornea becomes smaller, and the whole globe diminishes in size. The cornea may

or may not become totally opaque but the lens always does; the whole uveal tract becomes atrophied, the retinal elements disappear, and the optic nerve atrophies with consequent total blindness. As a rule the atrophic eye remains larger than the so-called phthisic bulb, as the atrophic process may stop. The eye usually retains a globular form.

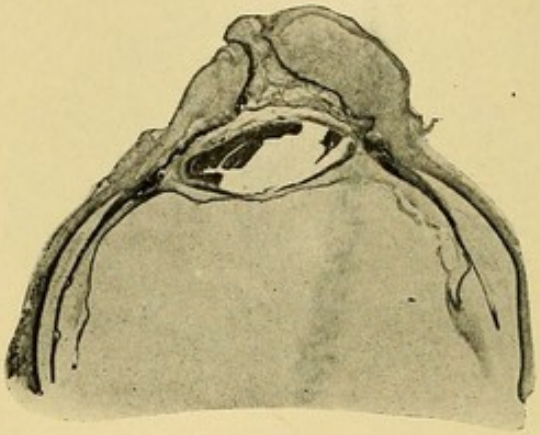

Fig. 28.
Perforating wound of cornea with ulceration and thickening. Prolapse of iris.

The cicatrix usually sinks inwards, indenting the spherical surface of the globe.

If the eye remain soft the effect of the recti muscles may cause it to assume a quadrilateral cone shape and squint also results. The lids do not come well in contact with the bulb so that the conjunctival sac

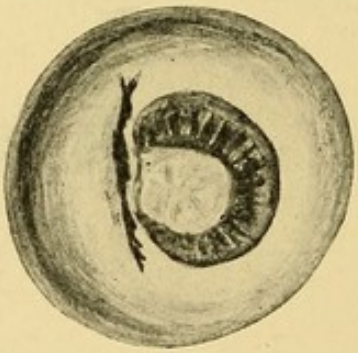

Fig. 29.
Lacerated wound of ciliary region; the injury inviting enucleation as a conservative operation against sympathetic ophthalmitis.

does not retain the normal form, the eye appears sunken and the lower lid may turn in, forming entropion.

Inflammatory and painful attacks of moderate severity vary the chronic process, especially if a foreign body be retained within the globe.

Prognosis. The prognosis is always unfavorable. The best that we can hope for is the retention of a small and not painful eye after several years of inflammatory disease. As a rule such eyes are enucle-

ated to cut short the period of economic loss, to remove the cause of irritation and to prevent sympathetic disease in the fellow eye.

Prophylaxis. Proper treatment of wounded eyes by the removal of foreign bodies; prevention of infection by the use of antiseptics; of iritis by atropine; immediate post-accidental operations, as the Kalt conjunctival flap, sutures, iridectomy; removal of traumatic cataract may prevent the development of irido-cyclitis and the resultant atrophy of the globe as well as sympathetic ophthalmitis.

Therapy. In the beginning of irido-cyclitis, besides care of the wound, subconjunctival injection of mercurial solutions, mercurial inunctions, intra-gluteal injections and general care are indicated. Atropine and hot compresses and high frequency electric applications locally and for many weeks. The visual acuity and field should be often taken, examination by the magnifier made and the ophthalmoscope should be often used. As a rule blinded and atrophic globes should be enucleated.

LITERATURE.

1. Leber, *Arch. f. Ophth.*, xxvii, 1.
2. Deutschmann, *Arch. f. Ophth.* xxviii, 2, xxix, 4, xxx, 3, xxxi, 2, *Beitrag*, 3 *Aug.* x, and *Trans. X Internat. Cong.*, 1890.
3. Schirmer, *Graefe Saemisch*, 1900.
4. Praun, l. c. p. 65.
5. V. Arlt, *V. Internat. Cong.*, 1876.
6. Fuchs, *Arch. f. Ophth.*, xxx, 3, 1884.
7. Uthoff and Axenfeld, *Arch. f. Ophth.*, xlii, 1.
8. Parsons, *Pathol. of Eye*, Vol. I, p. 349.
9. Villard, *Ann. d'oculist.*, May, 1908.

(II) SYMPATHETIC OPHTHALMITIS.

Synonyms.—Inflammation of the eye following an injury to the fellow eye, sympathetic ophthalmitis, sympathetic ophthalmia, sympathetic irritation and inflammation, ophthalmia migratoria, infective cyclitis, transferred ophthalmitis, et al.

Definition. Certain forms of traumatism in one eye may induce a disease in the other. The one originally infected is called the exciting eye, and that secondarily involved the sympathizing eye. Sympathetic ophthalmitis, or ophthalmia, has been long classified as either irritation and inflammation, and it is of the greatest importance that the clinical difference between the two should be properly diagnosed, as in one there is simple irritation and neurosis which produces alarming, although slight, loss of function; while the other is a true inflammation with exudation, which almost invariably results in blindness, which may be more complete than that in the originally injured or exciting eye. Dunn[1] claims that the term "sympathetic" is meaningless, in view of the modern theories as to the etiology of this affection, that it is caused by a specific micro-organism, and that the micro-organism creates a toxin which is conveyed, presumably by the lymph channels, to the

ciliary region of the healthy eye. There is nothing ethereal, spiritual, emotional—sympathetic—in an inflammatory process which is directly excited by the irritation of the bacterial product. The term "infective cyclitis" is more accurate and more in accord with the pathology of the disease.

History. Georg Bartisch[2] in 1583 was probably the first to write upon the subject, followed by Bartolinus[3] in 1696 and Bildoo[4] in 1649, Beers[5] in 1802, Demours[6] in 1818, von Ammon[7] in 1835, Himley[8] in 1843. Tavignol[9] in 1845 first gave detailed descriptions of this disease. Mackenzie[10] in 1844, in the earliest detailed study, refers to the seriousness of the disease, and gives a succinct and accurate account of the kind of injury to an eye which would be likely to cause harm to the fellow organ. He discusses the limits of time during which the incidence of the disease may be anticipated, and describes the local symptoms as those of "iritis passing rapidly into amaurosis and atrophy of the eye," considers the prognosis so

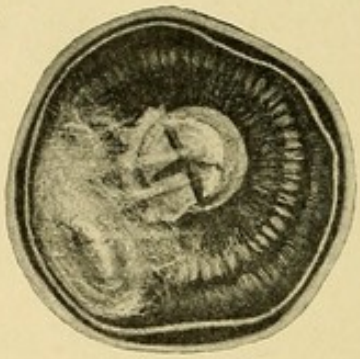

Fig. 30.
Infected penetrating injury to ciliary region. Traumatic cataract exudate. Posterior view.

unfavorable that it is our duty to guard the patient who has suffered any severe injury of one eye against the exciting causes of sympathetic ophthalmia from the very first. The treatment upon which he relied was "rest," antiphlogistic measures and the use of mercury. Eight years later White Cooper[11] suggested the enucleation of the injured eye. His efforts and those of Pritchard established the urgency of early operative intervention.

Mackenzie[10] advanced three probabilities for carrying of the disease from one eye to the other; viz., the extension of the inflammation through the blood vessels by means of their connections in the brain; extension through the ciliary nerves; and extension through the optic nerve and retina, the latter being the generally accepted theory until the conclusion of Heinrich Müller[12]—based on pathologico-anatomic observations—published in 1858. This view, which had been suggested

by Mackenzie as an alternative but improbable explanation of the phenomena of sympathetic inflammation, had been advanced previously by Tavignol, in 1845. The doctrine of Mackenzie that the optic nerve played the chief rôle in the transference of the inflammation from the exciting to the sympathizing eye, had been universally abandoned and the view that the pathologic changes in the secondarily affected eye were the product of an influence—an influence of a reflex character—transmitted to it through the ciliary nerves, was as universally accepted. This theory gained converts rapidly, and among those who accepted it and who became its ardent advocates were von Graefe, Donders, Arlt and Bowman. To them it seemed all sufficient, and through their labors it was fortified and strengthened. Numerous pathologic observations by Donders[13] and many other competent observers, based on careful dissections of eyes enucleated because of sympathetic irritation or inflammation of the fellow eye, and innumerable clinical facts were brought forward to sus-

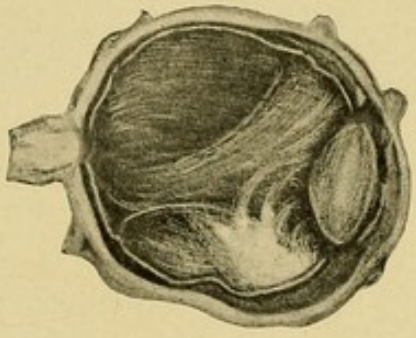

Fig. 31.
Perforating injury of ciliary region. Exudate.

tain it, and before long it seemed that if there was one question in ophthalmology settled beyond peradventure that question was the genesis of sympathetic ophthalmitis. Thirty years ago, it is safe to say, there was but this one view held as to the origin of sympathetic ophthalmitis. But time works many changes, and now, after the lapse of thirty years, it may be truthfully said, if there is one question in ophthalmology, seemingly, farthest from determination, and as to which least definite views are held, that question is the genesis of sympathetic ophthalmitis, as the precise etiology is yet an insoluble problem.

To those interested in ancient history we refer to the most valuable work of Hirschberg[14] on the History of Ophthalmology, and to the article of Theobald.[15] We have all we can do in this work to condense it into a practicable and readable one for the twentieth century, and therefore now take up our present knowledge of the subject, referring, when need be, to works dating before our era, but limiting our discussions as much as possible to the present time.

a. Etiology and pathology.

The kind of eye most likely to be excited to sympathetic inflammation is one in which the acute symptoms have become quiescent, but which is tender on pressure and beginning to shrink. If such an eye be enucleated, and, after hardening in preservative fluid, be bisected, it will be seen that there has been a great outpouring of exudate from the iris and ciliary region, and that this has distributed itself behind the lens capsule to form in some cases a complete partition between the aqueous and the vitreous chamber. The terminations of the ciliary nerves are imbedded in this exudate, which, as time goes on begins to organize, and, contracting, compresses and drags not only on the imbedded nerves but also on

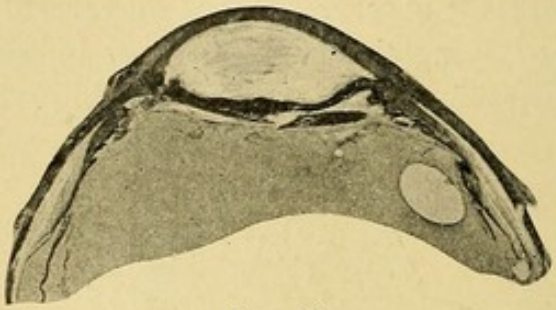

Fig. 32.
Irido-cyclitis in exciting eye.

the ciliary body and the anterior part of the chorioid and retina. In very acute cases the retina becomes detached completely, and extends like a fibrous cord between the inflammatory exudate in front and the optic nerve entrance behind. In some cases the ciliary nerves themselves show signs of neuritis, and on all a constant irritation is kept up by the traction produced by the shrinking exudate. As a result of this, vaso-motor disturbance is set up, and maintained, in the second eye, and this renders it all the more vulnerable. The "exciter" produces this disturbance in the "sympathiser" partly through ciliary neuritis, but mostly through reflex action; and the destruction of the ciliary nerves in panophthalmitis explains why such change rarely occurs after acute suppurative inflammations.

However, in abscesses of the orbit, where both optic nerve and its lymphatics are implicated, sympathetic inflammation never occurs. Panophthalmitis does not always cause a connective tissue formation that stops the pus germs from migrating from the injured eye to its fellow, and does not always cause such an intense local inflammatory action in the original eye as to cut off the nerve connection.

Several theories have been advanced to explain the extreme rarity with which panophthalmitis and sympathetic inflammation are associated. The earliest was that of Leber[16] and Deutschmann,[17]

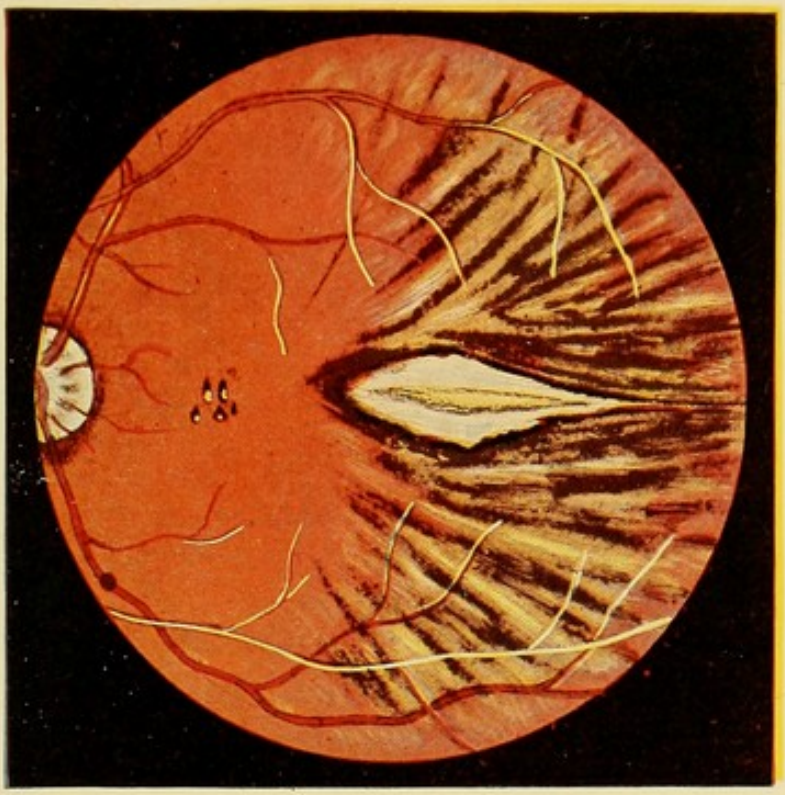

PLATE I

Instrumental operative wound through capsule, resulting in large cicatrix of the chorioid and retina, atrophy of the optic nerve, retina, chorioid and vessel walls, pigmentary deposits in retina and striate retinal changes.

who reasoned that the micro-organisms were, in part, extruded with the pus when the globe perforates, and in a measure rendered harmless by the large quantities of pus. Gifford[18] found, in experimentally produced panophthalmitis, blocking of the lymphatics as the result of inflammation, and considered that this offered a mechanical obstruction to the migration of the organisms.

Exceptions, however, are noted, as in Schirmer's[19] two cases, in one of which infection from an insect flying into the eye, ending in panophthalmitis, enucleation then being made, sympathetic uveitis was found some four months after the accident and the resultant panophthalmitis. In his other case there was panophthalmitis resulting from perforated corneal ulcer after an attack of measles. Two weeks after the panophthalmitis there was a well-developed iritis, which went into iridocyclitis.

Schirmer's explanation is that it is due to the fact that panophthalmitic eyes contain only the micro-organisms of suppuration, and that these are incapable of migration, and that where the mixed affection does occur the exciters of pus, being the more virulent, overcome and destroy the other organisms.

Ahlström[20] describes another case ending in blindness. The original affection consisted in serpent ulcer of the cornea. The bacteriological examination of the enucleated sympathizing globe revealed numerous staphylococci in vitreous, retina and chorioid, but none in the blood vessels, optic nerve and intravaginal space.

In my case,[21] reported thirteen years ago, there was cataract in each eye. The eye operated upon became cataractous from an injury sustained six months before. The operation was uneventful, and was performed under the usual aseptic precautions. Notwithstanding, in forty-eight hours the wound was discharging pus in large quantities, and the eye went from bad to worse, ending in panophthalmitis. The patient left the hospital without permission and did not return until a month later, when he was found to have active sympathetic ophthalmitis going on in the fellow eye, which ended in total blindness.

Zentmayer[22] has succeeded in finding the records of fifteen cases of panophthalmitis followed by sympathetic inflammation. In eight of these there is an anatomic description of the eye. In five there is also a report of the microscopic findings. In three the data are insufficient for a critical consideration.

1. While the occurrence is one of extreme rarity, eyes that present the clinical picture of panophthalmitis may excite sympathetic inflammation.

2. Such eyes, however, usually present microscopic changes analagous to those found in other exciting eyes.

3. With few exceptions in the cases of literature of sympathetic inflammation following phthisis bulbi, the eyes were of the class described by Fuchs as atrophied eyes.

4. Usually it is, clinically, the mild form of purulent uveitis which excites.

5. It is only after panophthalmitis of a virulent type that the resultant shrunken globe should be considered harmless.

6. Where from the nature of the infection the panophthalmitis has

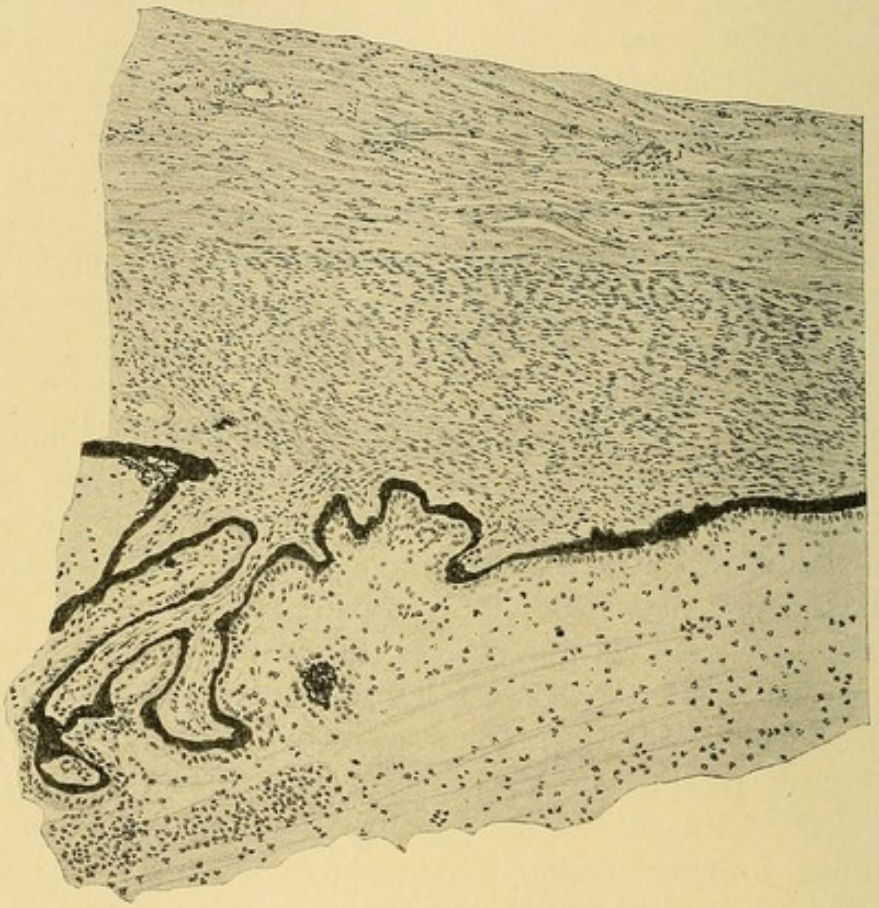

Fig. 33.

Nonsympathetic endophthalmitis. The inflammatory products are dominated by the polymorphonuclear leucocytes and appear outside of the ciliary body. Low magnification. (Roy.)

been of a low grade, or where as a result of treatment the inflammation has not assumed a virulent type, the eye should be considered a dangerous one and should be enucleated.

7. That in some cases where the purulent panophthalmitis has been considered the exciting cause the original injury or disease may have been responsible.

8. Whether the histiologic findings in most panophthalmitic eyes are to be considered the terminal stage of the inflammation or the evi-

dence of a mixed infection is still undecided, but the evidence points strongly to the correctness of the latter assumption.

9. Several factors contribute to lend panophahalmitic eyes innocuous. When the globe perforates many of the micro-organisms are extruded along with the pus, those retained within the globe becoming inactive through the enormous pus formation. This active pyogenesis, by blocking the posterior lymph spaces, serves to prevent migration of

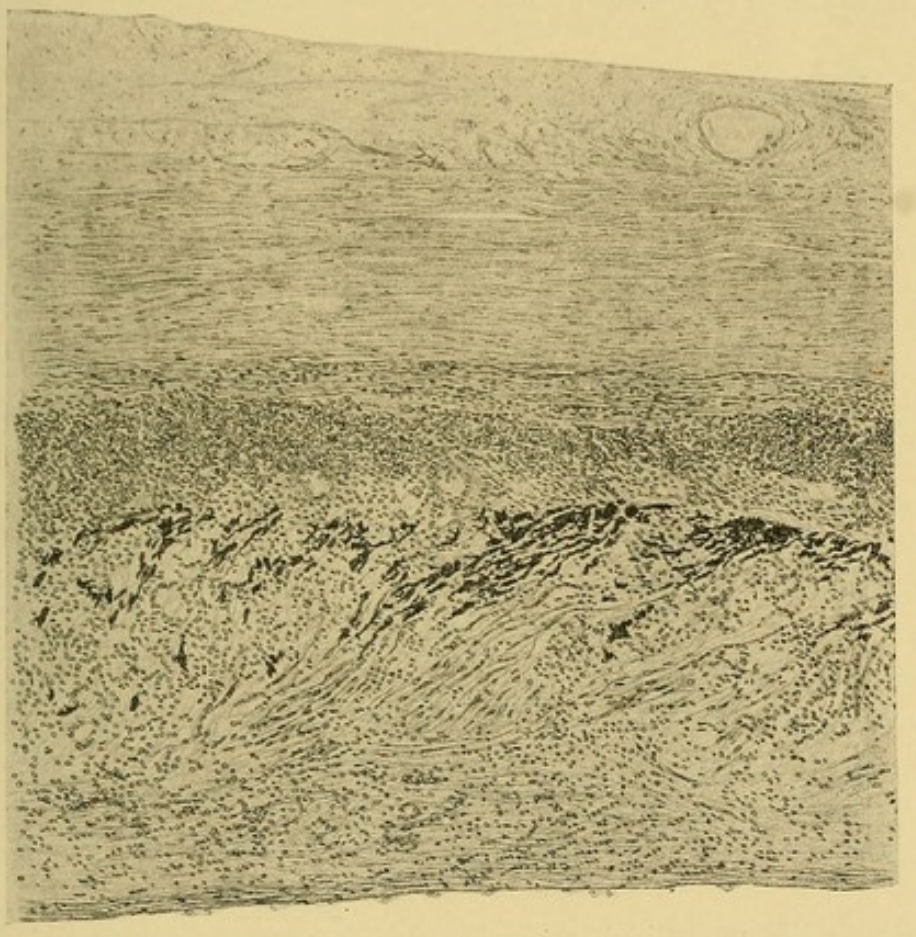

Fig. 34.

Deposit, characteristic of sympathetic ophthalmitis, situated within the ciliary body. It has burst through the pigment epithelium and formed an exuberant mass within the eye. The normal structure of the ciliary body has been replaced by a new formation consisting of lymphocytes, a few giant cells and epithelioid cells. The latter form a layer in the ciliary body adjacent to the pigmented epithelium. Low magnification. (Roy.)

the toxic agents. Finally, the panophthalmitis may have been excited by organisms probably incapable of inducing sympathetic inflammation, such as staphylococci and pneumococci.

The findings of Fuchs,[23] who described proliferative uveitis, which he found constantly present in diseased eyes which cause sympathetic inflammation of the fellow eye, while they do not, except by post-enuclea-

tion, give us any different diagnosis, are pathologically of value. He found this to be an infiltration of lymphocytes, giant cells and epitheloid cells within the uvea. His miscroscopical diagnosis, in 24 cases, was confirmed by the clinical histories, all the cases showing a sympathetic ophthalmitis.

Dunbar Roy[24] says the only possible practical value of these observations is on the assumption that a certain micro-organism is responsible for these peculiar epitheloid changes, and if so, the possibility of discovering the organism may tell us when and where not to operate.

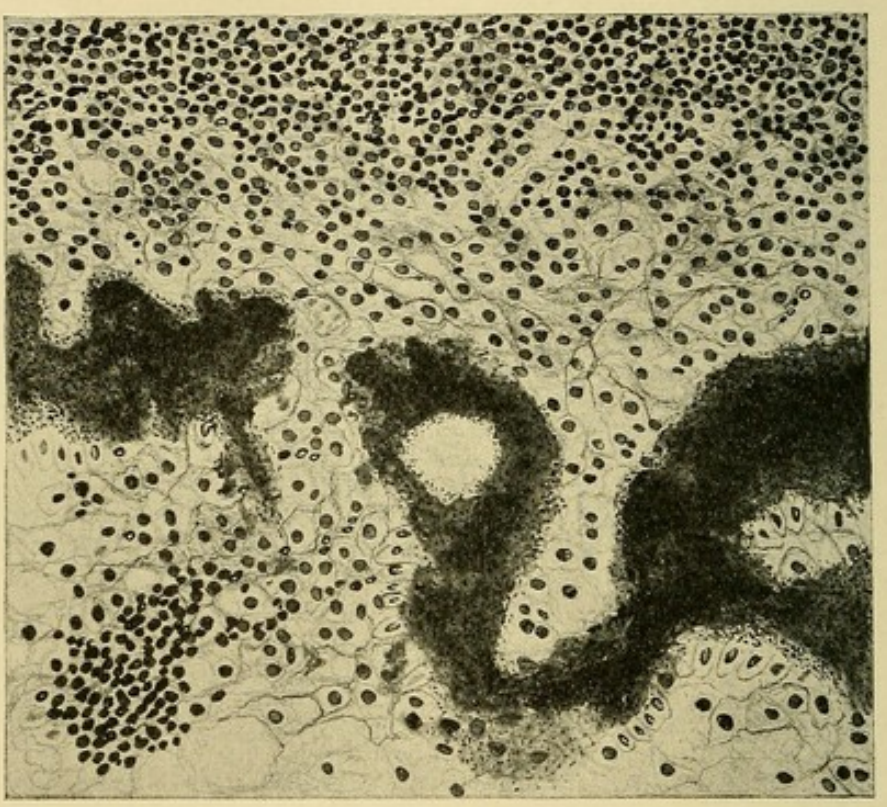

Fig. 35.

Shows details, under high magnification, of the deposit characteristic of sympathetic ophthalmitis. At this point the endothelioid cells and lymphocytes are breaking through the pigment endothelium. (Roy.)

Under the title "Endophthalmitis Septica" Fuchs[23b] groups what was formerly termed fibrino-plastic or purulent irido-cyclitis or irido-chorioiditis, including panophthalmitis.

In all but one of the eyes examined sympathetic inflammation existed in the fellow eye. He endeavored to determine in what percentage of severe traumatic inflammations sympathetic inflammation followed. Conscious of the great possibility of error, he calculates that it follows in 14 per cent. The characteristics of exciting inflammation are the cellular elements and the distribution of the infiltration in the several tissues of the eye. Lymphocytes, epithelioid cells and giant cells were present in

one-half of the cases. Polynuclear leucocytes were rare, but mast cells and Russell bodies frequent. Bacterial staining always gave negative results. In general the iris was least, the ciliary body more, and the chorioid most, involved. The findings in the iris and ciliary bodies are alike in that the inflammation begins in the layers nearest the interior of the eye, in the iris posteriorly and the inner aspect of the ciliary body. The outer layers of the uvea are spared the longest. Plastic exudate is usually absent. In the above respects exciting inflammation differs from endophthalmitis, as in the latter the primary exudate (mostly polynuclear leucocytes) is found in the inner surface of the retina and between the cells of pigment layers, whereas the outer pigment layer and the stroma of the ciliary body, in the beginning, is free from exudate. In the chorioid the inflammation begins in the posterior segment. The anterior portion shows but little tendency to exciting inflammation, probably because of the circulatory conditions. The primary foci appear in the walls of the large vessels, while the corio-capillaries are long unaffected. The lymphocytes probably first occur outside of the vessels, but gradually penetrate the walls and block the lumen of the vessels. The arteries succumb last. The vascular layer of the chorioid is the least involved portion of the uvea, but superficial exudate, however, is rarely absent. Only rarely does superficial exudate appear on the chorioid; in general the exudate does not extend beyond the lamina vitrea. The peripheral yellow spots, considered by Dalen[25] as the anatomic substrata of chorioiditis, were found but four times. Fuchs has found them in non-exciting inflammations and believes that they have no relation to exciting inflammation. The inflammation usually extends outwardly from the chorioid by way of the large ciliary vessels, the venæ vorticosæ and the ciliary nerves. Penetrating nodes are found in the sclera. The retina always shows infiltration of the vessels, especially the veins. The optic nerve shows even less typical involvement.

Exciting inflamamtion shows a tendency toward organization and not toward suppuration. The cells increase, the epithelioid and giant cells disappear, and large, long, pale nuclei within a homogenous substance, and later a striated stretched-ground substance, takes its place. Embryonic connective tissue forms from the epitheloid cells. The original uveal cells disappear. Those found in the remnants of the uvea are new-formed. The suprachorioidea is frequently obliterated. The process of recession is slower than in endophthalmic plastic inflammation. In one case fresh infiltration was found in the cicatricially shrunken chorioid seven years after the primary inflammation. This is analogous to trachomatous inflammation.

Plastic exudate may be entirely wanting and when present is probably an accidental complication, due to mixed infection.

The contrast between endophthalmitis and exciting ophthalmia is interesting. The former sets in earlier and is in the superficial layers (pars ciliaris retinæ). The latter involves the stroma of the uvea, the pars ciliaris retinæ often remaining free. The former exudate consists of fibrin and leucocytes, the latter of lymphocytes. Fibrin is absent. Both forms of inflammation may be combined.

In sympathetic irritation the exciting eye showed no characteristic changes, consequently sympathetic irritation must be considered as an independent affection. The typical findings in the exciting eye may be considered diagnostic. In three cases of so-called traumatic serous iritis the findings were different from those in exciting eyes. The chorioid was uninvolved and epitheloid cells were absent.

The method of migration to the other eye was probably of the same nature as that which takes place in tumor metastasis. If this is correct, then optico-ciliary neurotomy can give no protection. Evisceration is not safe, because of the eventual penetration of the sclera, and enucleation gives no absolute security because of the occasional presence of extrascleral growths of the process.

As to the diagnosis during life, Fuchs considers it impossible. The danger of error is less the more frank the inflammation in the first affected eye. Perhaps serum therapy may solve the difficulty.

E. V. L. Brown[26] gives the clinical histories and pathological findings in three cases and agrees with Fuchs that there is present a cell proliferation within the uvea in the exciting eye. His cases showed a relation between the severity of the sympathizing eye and the intensity of the proliferative uveitis. The author reviews similar findings in literature, taking "one thing only as an absolute and final criterion of uveitis proliferativa, namely, a proliferation of epithelioid cells in clusters, or singly, within the confines of the uvea in eyes which have caused actual sympathetic inflammation of their fellows."

Brown makes a differential diagnosis between proliferative and infiltrative uveitis of sympathetic ophthalmia and that of syphilis and tuberculosis, and in summarizing the cases noted by Fuchs and others he states that "proliferative uveitis is in no way pathognomonic of sympathetic ophthalmia," because: "1. Typical sympathetic inflammation occurred in one case without any proliferative uveitis in the exciting eye. 2. Typical proliferative uveitis was present in one case presenting only symptoms of sympathetic irritation of the fellow eye. 3. Typical infiltrative uveitis with epithelioid-cell proliferation occurred in one case of spontaneous irido-cyclitis. 4. Typical infiltrative uveitis, though without epithelioid-cell proliferation, occurred in three cases of 'serous' irido-cyclitis. 5. Only one case of proliferative uveitis absolutely uncomplicated by fibrino-plastic uveitis has been reported, and the sym-

pathizing eye of this case showed 'some synechiæ.' 6. Epithelioid-cell proliferation has been specifically noted in but one of the ten sympathizing eyes studied. 7. Epithelioid-cell proliferation is not found in the last stages of sympathetic inflammation."

From a study of his three cases, Brown corroborates the findings of Fuchs, that "proliferative uveitis is the essential anatomic condition present in the eye which causes sympathetic inflammation of its fellow."

Ruge[27] gives the following to convey the difference which exists between his and Fuchs' view concerning sympathetic inflammation: According to Fuchs, a perforating infected injury to the eye can cause: 1, acute purulent inflammation (ophthalmia septica); 2, exciting inflamamtion. The two together: mixed infection—the result of simultaneous infection with the inflammatory excitors of both of these types.

According to Ruge, a perforating infected injury may cause: 1, acute purulent inflammation; 2, primary chronic fibrino-plastic inflammation, the latter occurring in two forms: (a) simple fibrino-plastic, (b) exciting inflammation, mixed infection resulting from simultaneous infection with inflammatory excitors of both types, 1 and 2.

Ruge believes, with Fuchs, in the three kinds of cells—round, epithelioid and giant; the latter existing in 50 per cent of all exciting eyes. He states that in a vast majority of cases where epithelioid cells were found, giant cells were present. If they were not found, it would not be conclusive that they were not present, as they might be hidden by the round cells; and that a given case was not one of exciting inflammation because of their non-discovery.

As to round cells, he found these always present in traumatic, fibrino-plastic inflammation. He denies that epithelioid and giant cells are pathognomonic of exciting eyes. He says that he is far from asserting that it is impossible to differentiate a high-grade, exciting inflammation from a low-grade, chronic, fibrino-plastic uveitis following trauma, but believes that there are such gradations between these extremes that border-line cases exist that cannot with certainty be differentiated.

On the whole, Fuchs' findings in the iris correspond with the author's, only he is unable to confirm the observation of the protrusion of the cell proliferation beyond the plane of the iris.

He does not consider characteristic inflammation in which the chorioidal changes are to be found principally at the posterior pole, as he has at times found that region entirely free, whereas anteriorly it was strongly infiltrated. As to the absence of superficial exudate in the iris and ciliary body, the author believes with Schirmer,[28] that there is a pure sympathetic plastic exudate without denying that the plastic exudate in many cases is to be traced to mixed infection.

Heefordt[29] draws the following conclusions, some of which he considers hypothetical: 1, Sympathetic ophthalmitis is characterized by a specific inflammation (described especially by Schirmer, Ruge and Fuchs). 2, This without doubt is caused by a specific microbe which has an elective effect upon the uvea, is sometimes present in the conjunctiva and possesses marked penetrative powers (a spirochætan form with spontaneous movement). 3, The infection usually has a period of incubation of about 14 days. As a rule the second eye is infected from the uveal inflammation of the injured eye, in rare cases, however, direct from the point of injury. On this account it is possible, within limits, that the infection may originate elsewhere, especially from other mucous membranes (particularly, perhaps the mucous membrane of the genito-urinary organs). The infection is carried along the usual lymph and blood channels. It has not been entirely excluded that, under certain conditions, the lymph passages along the optic nerve may play a part in the transmission. The lesion existing in one eye is pathogenic for the other, and occurs soon after the outbreak of the inflammation in the first. These cases of sympathetic uveitis which occur late after a perforating injury are excited by a later infection (through the traumatic cicatrix).

The optic neuritis which occurs so frequently in cases of sympathetic uveitis occurs, under certain circumstances also (how often is unknown), as the first demonstrable symptom of the uveitis in the sympathizing eye.

Fuchs[23a] reports a group of cases bearing on the pathology of this affection. In the first case the points of interest were: 1, The outbreak of an attack of sympathetic ophthalmitis where the exciting eye had remained entirely free from irritation 29 years. 2, The fresh exciting infiltration of the chorioid. This could easily be distinguished from the products of the original inflammation resulting from the perforation of a corneal ulcer. 3, The type of sympathetic inflammation. In the beginning the iris was not affected. The precipitate came from the ciliary body, the cells passing from the angle of the anterior chamber into the aqueous. The vitreous opacities also came from the ciliary body. The chorioid next the ciliary body was affected, the yellow foci in the chorioid being an expression of small foci of inflammation. Here the chorioid was so thickly infiltrated with leucocytes that the vessels were entirely covered. Such foci must appear yellow, especially if the overlying pigment epithelium is unchanged. The retina being normal cannot hide the foci.

Two cases are reported in which sympathetic ophthalmitis developed in the absence of plastic inflammation in the injured eye. The author states that he would not report these cases, as they are of such

frequent occurrence, except to emphasize that plastic inflammations of end-ophthalmitis do not belong to the class of exciting inflammations. When it occurs in a high grade type it is likely to intercept exciting inflammation.

A case is added to those reported in the author's first contribution on this subject in which the sympathetic ophthalmitis developed in the absence of plastic inflammation, in which an anatomic examination was made. The exciting inflammation was found to be so slight that it was surprising that a sympathetic inflammation could result; while the latter was so severe that the anatomical changes in this eye might well be more than in the exciting eye. The points of interest were, 1. The outbreak of the sympathetic ophthalmitis after enucleation; 2. The slight grade of the endophthalmitis; 3. The still milder grade of the exciting infiltration with quite severe sympathetic ophthalmitis.

These are the cases in which he believes the term may be rightly used as representing a stage coming under microscopic examination before the sympathetic ophthalmitis has developed in the other eye. The points of interest are:

In contrast with the former there was severe endophthalmitis and severe exciting inflammation but no sympathetic ophthalmitis.

The last case is one in which Fuchs thinks there was the beginning stage of exciting inflammation. His belief for this rested on the following facts: The retinal inflammation was greatest in the inner layers and quite insignificant in the outer. In many places none at all. There was no relation as to locality between the chorioidal and retinal areas of inflammation. The first was diffuse; the latter focal. The exudate in the outer layers of the retina was in part polynuclear leucocytes; in the chorioid entirely lymphocytes. These were found not in the capillary layer, where in severe endophthalmitis the pus collects under the vitreous layer of the chorioid, but on the contrary more in the outer layers of the chorioid.

Trousseau[30a] in 1897 and again in 1909,[30b] Gifford in 1897[31a] and 1910[31b] report sympathetic ophthalmitis following cauterization of iridic prolapses.

b. Theories of transmission.

The principal theories of the production of sympathetic ophthalmitis that are yet under consideration are the ciliary nerve theory, the migration theory, and the intoxication theory, to which may be added the Schmidt-Rimpler hypothesis, none of which, as we have had occasion to remark, fully explains the pathological and clinical manifestations. A brief resumé of the various theories is herewith given, but

in this connection it is not deemed necessary to go fully into the literature.

1. The ciliary nerve theory.

As remarked in our brief history, MacKenzie[10] in 1844, favored the extension of inflammation directly through the optic nerves, yet he also suggested that the pathological changes were due to the influence of a reflex character, transmitted along the ciliary nerves. This theory depends upon the clinical observation that in irritation of one eye, for instance, by a foreign body, its fellow is affected, becomes congested and the tears flow. Such reflex changes are due to the irritation of trophic, motor, sensory, and blood vessel nerve filaments, as are contained in the ciliary nerves.

Certain experiments by Mooren and Rumpf,[32] and by L. Bach,[33] upon eyes of rabbits, seem to show that the first eye sends a centripetal irritation through the ciliary nerves to the ganglion, then through the radix sympathetica to the carotid plexus of the sympathetic nerve, through the circulus arteriosis Willisii to the sympathetic of the other side, and then centrifugally to its ciliary ganglion and through the ciliary nerve to the sympathizing eye.

Experiments upon the sympathetic by Joseph[34] and others show that such trophic changes may be produced. The literature contains many cases in which the color of the lashes of the sympathizing eye changed. Motor changes of a sympathetic nature, as clonic and tonic spasms of the lids, loss of accommodation, etc., are reported. Secondary changes in the anterior chamber of the second eye and pain in the first twig of the trigeminus have been reported. The changes which are generally spoken of in sympathetic irritation, are those of pericorneal injection, lacrimation and photophobia.

2. The migration theory.

Deutschmann,[17] following Leber,[16] stated that sympathetic irritation was a reflex neurosis and had nothing to do with sympathetic inflammation. The latter always goes on to a severe plastic cyclitis and cannot be influenced by a removal of the original focus of infection, i. e., the originally injured eye, while sympathetic irritation is always cured by removal of the injured eye. By bacteriologic and animal experiments, he was able to cause similar changes in the eyes of animals. His theory is that sympathetic inflammation is the result of a septic infection process in the injured eye, and that the micro-organisms travel along the optic nerve to the sound eye. He experimented by injecting fluid containing the spores of the aspergillus fumigatus, and later staphylococcus pyogenes aureus and albus into the vitreous body and into the

sheath of the optic nerve, tracing the micro-organisms across the chiasm in their course through the optic nerve of one eye to the optic nerve of the other, in which they set up a typical sympathetic inflammation.

For a time the difficulty of explaining the origin of ophthalmia migratoria, as the disease was called, seemed to be ended, but unfortunately, subsequent investigations failed completely to verify Deutschmann's observations.

Limbourg[35] has recently repeated such experiments in which sections of the optic nerve showed a continuous infiltration of the optic sheath from the eye to the brain, and he thinks that his experiments greatly support the optic nerve theory of sympathetic ophthalmitis. Unfortunately for these observations the infection in sympathetic ophthalmitis is usually found to be of a mixed type. If we could find a special germ, as it may prove to be, and as Dunn[1] has remarked, which either passes, or whose toxin is conveyed, to the other eye, the pathology would be rendered clear.

3. The predisposition and malnutrition theory.

Schmidt-Rimpler,[36] on account of the objections to these several theories, which will be entered into later, advanced an opinion that the irritation of the ciliary nerves in the injured eye was caused by changes in the circulation of the blood and nutrition, and that this is all that is necessary to cause sympathetic inflammation in the other eye. The longer these changes obtained, and the more severe they were, the more ground was there for an inflammatory process which would cause the same, which could be either bacterial or chemical. If such conditions did not develop no sympathetic ophthalmitis followed. An eye must have the disposition toward sympathetic disease and be irritated by external causes as a blow or wound upon the eye. The entrance of micro-organisms and the production of metabolic changes are a secondary effect.

4. The intoxication theory.

This was brought forward by V. Rothmond and Eversbusch[37] in 1882, and has received considerable support. By this theory the products of metabolism in the first injured eye are supposed to be carried to the sympathizing eye in one of the following ways: (1) Either the products of metabolism pass through the lymph stream into the second eye and cause inflammatory changes; or (2) these products pass through the blood into the circulation and cause changes in the second eye; or (3) the damage is caused by toxalbumins in the vaso-motor centers and in the ganglion; or (4) the products of metabolism may remain in the originally injured eye setting up there chemical irritation,

which is an analogue of mechanical irritation and in a reflex way damages the other eye and causes inflammation.

L. Bach[33] and Bacchi[36] give credence to the fourth hypothesis.

5. Criticisms of theories of transmission.

Against these several theories there have been many pathologic and clinical facts arranged. Against the ciliary nerve theory clinical experience has shown that infection must always have occurred in order to have caused sympathetic inflammation in the other eye; that every day operation wounds are made in the eye, and if these be aseptic they heal without the slightest trouble and give rise to no risk of sympathetic inflammation; that even such wounds as are made in the region of the ciliary body as iridectomies, irodesis, cataract operations and others, if they be not infected heal properly, but if they be infected an operation wound is as liable as any other to set up destructive sympathetic disease in the other eye. Further, very painful diseases in which the uvea is affected, particularly panophthalmitis and glaucoma, do not give rise to irritation or sympathetic inflammation. Again, clinically we find that the largest number of cases of sympathetic inflammation have occurred within four weeks after enucleation of the first injured or diseased eye, when certainly there can be no irritation from the ciliary nerves of the other eye. Here we must suppose at least an ascending neuritis of the ciliary nerves, and pathologico-anatomical examination has not shown this condition. Again, optico-ciliary neurectomy has not prevented the occurrence of, nor stopped the progress of, sympathetic inflammation or irritation.

Against the migration theory is advanced the fact that although Leber[16] and Deutschmann[17] claimed to have followed the micro-organisms from one eye along the nerves to the other, yet this has not been fully substantiated by other observers, indeed, many reporters since that time have negative findings. Clinically we find that resection of a portion of the optic nerve does not prevent sympathetic inflammation. Even the view that the inflammation closes up the passages by which the germs might pass along the optic nerve in a case of panophthalmitis, which is rarely followed by inflammation in the other eye, is overthrown by undoubted cases of true sympathetic ophthalmitis occurring after panophthalmitis. Such cases have been reported by Schirmer,[19] Ahlstrom,[20] and myself.[21] Again, if the migration theory be correct we must commonly observe a neuritis or neuro-retinitis in the sympathizing eye, which is not the case.

Against the theory of Schmidt-Rimpler there is little to be said except that it may be a background upon which the intoxication theory

may be built, and one of the factors in its production. Yet it may be said here that the severity of a sympathetic inflammation or irritation in the sympathizing eye depends by no means upon the amount of destruction of tissue or inflammation in the exciting eye.

The intoxication theory seems to afford the most reasonable hypothesis, particularly the combination of the four propositions heretofore described; that the products of metabolism pass through either the lymph stream or the blood vessels to the other eye and that the vaso-motor centers and the ganglia are irritated by these products and set up a true sympathetic irritation. The objection to the theory is that the analogy does not hold, especially as to post-sympathetic paralysis. The beginning of sympathetic ophthalmia is not characterized by paralysis of accommodation. The disease is one affecting the uvea and not the nerves. The intoxication is not apparent in other portions of the body, and where panophthalmitis has preceded, sympathetic inflammation of the other eye seldom occurs unless through an operation the blood and the lymph streams have been opened.

While these several theories have not rendered clear the pathogenesis of sympathetic ophthalmitis, yet we hope that in the future such work as has been done recently by Fuchs,[23] Schirmer,[19] Ruge,[27] and E. V. L. Brown,[26] may ultimately establish us upon firm ground, and the pathology may ultimately be understood.

None of the theories fully explain the pathology of all cases. It is likely that sympathetic irritation is due to disturbance of the ciliary nerves, while true sympathetic ophthalmitis is a combination of several or all of the factors. Whatever be the pathogenesis, clinical evidence shows that certain affections of one eye are the exciting cause of transient recurrent irritation and disturbance of function in the other eye, and where there has been infection, a distinct inflammation of the uveal tract of the other eye may occur. In the latter the organic changes are of so serious a nature that vision is greatly injured and usually entirely destroyed.

This clinical subdivision was generally accepted for some years, then given up and again adopted, and now seems to be corroborated by the anatomico-pathologic findings of Fuchs, Schirmer, Ruge, Brown, Oatman and others, although other authors from time to time as Oliver, Dunn,[1] et al., deny the entity of the two clinical pictures.

c. Conditions of the exciting eye.

Etiology. The morbid changes in the exciting eye which are likely to give rise to sympathetic disease may be classified as follows:

1. Sympathetic inflammation.

(1) Penetrating wounds of the ciliary region, accompanied by prolapse of the iris and ciliary body, are, above all others, the most likely to cause sympathetic disturbance, and all the more readily should the wound be lacerated and should the instrument with which it was inflicted have been unclean.

(2) Foreign bodies lodged within the eyeball, more particularly if they lie near the ciliary processes, are a constant source of danger, since they keep up inflammatory reaction in the whole uveal tract.

(3) Corneal ulcers which have perforated may form the starting point for a sympathetic ophthalmitis, but it is interesting to remember that an eye which has burst from within is not nearly so dangerous as one in which perforation has occurred from without. Moreover, all clinical experience goes to prove that after panophthalmitis the danger of a transference of infection from one side to the other is very slight.

2. Sympathetic irritation.

In addition to 1, 2, 3, the following etiologic factors may give rise to sympathetic irritation.

(4) Sarcoma of the chorioid, or dislocation of the lens, accompanied by plastic irido-cyclitis.

(5) Degenerative changes in an eye previously injured are always accompanied by a certain amount of irido-cyclitis, and consequently an atrophied globe, tender and irritable through calcification of the lens and ossification of the chorioid, is invariably a menace to the sound eye. The wearing of an artificial eye over such a phthisical stump has given rise to sympathetic irritation. These are probably the only instances in which the disease arises apart from the existence of a perforating lesion of the "exciter."

d. Duration and incubation.

The incubation period elapsing between the time of the injury and s y m p a t h e t i c i r r i t a t i o n in the other eye is extremely variable. I have seen one case in which it developed three weeks after the accident, and in another there was 60 years difference in time. In s y m p a t h e t i c i n f l a m m a t i o n the shortest recorded interval is ten days, the longest about thirty years. The usual period of incubation or interval after most cases is six weeks in sympathetic inflamamtion, and three months in sympathetic irritation. It is conceded that if no symptoms develop within two years the danger line is passed as far as true sympathetic inflammation goes, yet, as far as noted, sympathetic irritation may result in cases where there is degeneration of the injured eye, producing a metamorphosis of the tissues, such as calcification, ossification

of the chorioid, etc., in which the irritability of the other eye may not begin for years afterwards. von Michel[40] states that 90 per cent. of all cases of sympathetic ophthalmia develop within three years after the injury, of which about 30 per cent. were during the first six months, 30 per cent. from six to twelve months, 30 per cent. in the next year, and the rest, or about 10 per cent., in the next ten years.

Hubbell[41] reports a case of foreign body lodged within the cornea and removed 18 years after the injury. Sympathetic inflammation three times in the other eye without loss of vision, that is, there were three or more attacks of inflammation or irritation in this eye up to the time it was removed by Hubbell. The foreign body was a small piece of iron considerably oxidized. Two days after an attack of inflammation with reduction of V. to 5/xxiv, and recovery in two weeks to V. 5/v under salicylates.

Heefordt[29] reports an interesting case, in which the features were the occurrence in the injured eye of a decided neuritis and a beginning cyclitis on the thirteenth day; two months later cyclitis gone, the neuritis unchanged; four months later the neuritis gradually disappearing; in five months a slight iritis; between the fifth and tenth month a slight chorioiditis with vitreous opacities, the optic neuritis unchanged or slightly increased. In the sympathizing eye: on the thirteenth day a beginning neuritis; in eighteen days a cyclitis and in two months rapidly subsiding relapse; five months, a slight iritis, and between the fifth and tenth months of chorioiditis.

Mathewson[42] reports case of a man of 42 years. Left eye penetrated 21 years before by flying particle of brass. History of previous attacks of corneal ulceration resulting in corneal staphyloma and finally of panophthalmitis. Enucleation was performed. Thirty-one days later the fellow eye was attacked with an anterior uveitis. The treatment used was mercurial inunctions and pilocarpine with local use of atropin. Hot baths were soon substituted for the pilocarpin. A perfect recovery followed.

Deshogues[43] reported two cases of sympathetic ophthalmia from ancient trauma. In the first case an atrophic eye, which had tolerated a foreign body for twenty years, became inflamed, and ciliary irritation, photophobia and slight papillitis with visual reduction (⅓ to ¼) appeared in the other eye. In the second case sympathetic iridocyclitis with reduced vision dependent on trauma twenty-four years previous. Enucleation brought relief in each instance. The globe in the first case was found to contain pus.

Sulzer[44] reports a case in which the patient's left eye was atrophied as the result of a wound with scissors in early childhood. The globe was reduced to half the normal size, but was not inflamed, pain-

ful or tender to the touch. In the right eye there was iritis, deposits upon Descemet's membrane and cloudiness of the vitreous. Later there was a peripheric patch of exudative chorioiditis. The atrophied ball was enucleated and the case was treated with atropin, quinin and subcutaneous injections of cyanid of mercury, and the "sympathized" eye was restored to normal conditions.

The sympathetic character of this case seems very doubtful, but, as the author says, any atrophied globe, even if painless, may become dangerous at any moment, as the very fact of the atrophy indicates the former existence of irido-cyclitis, and it is well to give the patient the benefit of the doubt.

The author concludes that "enucleators" are not so often in the wrong as de Wecker[5] has maintained.

Symptoms and course. Sympathetic irritation.

Sympathetic irritation is always an early symptom of true ophthalmitis, and some cases may not proceed further, being caused only by irritation of the ciliary nerves. It is characterized by symptoms in the sympathizing eye suggestive of hyperemia of the uvea and retina, with anesthesia of the latter. The earliest symptom in most cases is a failure of accommodation, especially emphasized in persons who have uncorrected refractive errors. The patient has asthenopia, difficulty in reading small print, and after prolonged work suffers from transitory attacks of dimness of vision for both near and distance, or maybe from momentary total blindness.

A. Maitland Ramsey[46] notes low degree of transitory myopia and says in these cases the spindle-shaped enlargement of the blind spot is a valuable sign, denoting active congestion of the optic disc—the shape being determined by increased size and turgescence in the superior and inferior branches of the retinal artery and vein. "If, then, in a case of infected wound, or of degenerative changes, in one eye, its fellow began to give trouble, no matter how slight, and careful examination showed a congested disc with characteristic enlargement of the blind spot, the sign would, in our opinion, go far to determine the questions of the immediate enucleation of the exciter."

There is photophobia in bright light which may cause neuralgic pains to dart through the head and induce injection of the conjunctiva, accompanied by copious lacrimation; there is conjunctival congestion and slight pericorneal hyperemia and a slow reaction of the pupil to light and accommodation. On pressing in the region of the ciliary body there is sensitiveness. These symptoms are aggravated by near use of the eyes and by exposure to light, and subside upon relaxation of the eyes from close work and protection from light. The symptoms show periodicity,

occurring for a few days and then disappearing, coming back after an interval of days or weeks. These symptoms are somewhat similar to those from errors of refraction, particularly hyperopic astigmatism, and should not be confounded with them.

I have seen many cases of sympathetic irritation in eyes whose fellows were previously injured by accident.

A girl of 17, eight years before, had penetrating wound of the left cornea from scissors, followed by anterior synechia. Two weeks ago penetrating wound of the other eye from hat pin, lens injured, anterior chamber obliterated. Had on a dirty cotton handkerchief for bandage. Was under oculist's care and was making visits to doctor's office two to three times a day, having drops put in. Eye sightless and in great pain. Changed physician March 14, and I immediately made enucleation of the last injured eye as other eye was painful, crying, and vision lowered to —6/xviii. Examined specimen, which showed much infiltration of vitreous and ciliary region. Sympathetic irritation cleared up in two weeks. Patient has been under observation ever since and has full use of the left eye with—1.00 180°. V. = 6/vi.

A man, age 30, had piece of steel extracted by local physician from left eye six weeks before, from scleral wound in an eye which became blind three years ago from cataract. Now irido-chorioiditis in the left, and right very sensitive. Optico-ciliary neurectomy was performed on the left eye. Relieved both eyes but left became absolutely insensible and was always congested. Nine years later he returned with the left eye atrophic and sensitive during wearing of prothesis. Uncomfortable vision with right eye for years. Was wearing presbyopic glasses, though 38 years of age and refraction —25, +75, 90°. V. = 6/vi. Enucleation and prothesis. Other eye stronger afterwards.

Fejer[47] notes a case in which the right eye of a woman, aged 28, became blind at the age of 1½ years from smallpox, as she stated, although she had no scars on her face. On May 10, 1909, she came to F., on account of inflammation and pain in the right eye, for the last two weeks, headache and rapidly failing sight of left eye. The right eye was shrunken and stone hard, chemotic and very painful to the touch. The left eye was without irritation, conjunctiva, cornea, media, fundus were perfectly normal, V. 1/lxx, visual field very much contracted. On May 12, the right eye was enucleated, under local cocain anesthesia by retrobulbar injections. At the change of dressing the next day, the patient could see much better, and on May 17 vision had risen to 7/v, visual field and accommodation were normal.

The sclera of the enucleated eyeball was thickened, the shrunken lens and ciliary body surrounded by a shell of bone and the intraocular tunics

totally degenerated. The intense shrinkage and ossification around the ciliary body may have been the cause of the sympathetic irritation, i. e., of the amblyopia, as some authors have described the formation of bone as the cause of sympathetic inflammation.

Such cases demonstrate the probability of the ciliary theory and seem to prove that the irritation travels by reflex through the ciliary nerves from one eye to the other, because no objective changes are found in the sympathetically affected eye and the functional disturbance disappears immediately after enucleation, with restoration of normal vision.

Symptoms and course of sympathetic inflammation.

Sympathetic inflammation is an acute or chronic inflammation of the uveal tract of the sympathizing eye, and is attended with secondary inflammation in nearly all the other tissues. It may begin with symptoms of sympathetic irritation, but in some cases comes on like a thunderbolt out of a clear sky. It may begin as a low grade inflammation of a serous or plastic type. The connection between sympathetic irritation and sympathetic inflammation is undetermined. Some writers believe that irritation is essentially a neurosis and never leads to inflammation, and I believe that many cases are of this type. Others assert that it is the first stage of sympathetic inflammation, and here I likewise believe the latter to be usually preceded by the former.

Symptoms of true inflammation. The exciting eye.

The eye is injected, painful, and sensitive, and gives every indication of an active and destructive inflammation of the uveal tract extending to the other structures of the eye, i. e., a suppurative irido-cyclitis with implication of the chorioid, retina and vitreous. Vision is in most cases entirely abolished, but there may remain some perception of light. The eye is constantly painful, and this is increased by light or use of the other eye. Where the ciliary, the conjunctival, and other vessels are engorged, lacrimation is profuse. The ciliary region is usually sensitive to pressure. Where the media are sufficiently clear for the ophthalmoscope, vitreous opacities, hyperemia of the retina, the veins tortuous and overfilled (the arteries not appreciably affected), may be observed, but sympathetic inflammation is rarely seen with such an eye as the exciter.

The sympathizing eye.

The symptoms are usually those of a chronic serous iritis, i. e., a true uveitis. Very few cases are known to have a violent inflammatory

reaction. The conjunctiva is injected, sometimes swollen; the cornea dull, the lower half of the posterior surface being dotted over with small masses of exudation, triangular in form, with the base of the triangle downward near the iris periphery. Some of the dots are connected with each other by fine opaque lines lying on the posterior layers of the cornea, i. e., on Descemet's membrane; the descemetitis of the old and the keratitis punctata, of the modern writers. The true corneal tissue may later become affected. The anterior chamber appears deeper and the aqueous is turbid. The iris is discolored, hyperemic and thickened, the pupil contracted, and the ciliary body infiltrated and extremely painful on pressure, particularly in an area corresponding to a similarly situated sensitive point in the exciting eye. The vitreous body contains many opacities, derived in part from the ciliary body and in part from connective tissue changes. As this inflammation advances the iris becomes adherent to the lens—posterior synechia; capsulitis and exudate in the pupil forms, and the whole uveal tract becomes in a state of active inflammation. In a few cases the signs of vision in it disappear when the sympathizing eye becomes totally blind.

A marked instance of this was one of my earliest cases.[48] A blacksmith three years before had received an infected wound of the ciliary region of the right eye, which after three months had caused sympathetic inflammation in the other eye. This might certainly have been prevented by removal of the originally injured eye within the first week or so, but an attempt was made to save it by the attending surgeon. The patient left the hospital against advice and did not return until the other eye had become affected. This ran a most violent and acute course, resulting in atrophy within three months. About a year later he was led to me and I found that there was good light perception in the originally injured eye, while the sympathizer was blind. There was total occlusion of the pupil from membraneous cataract and posterior synechia, producing the peculiar condition of iris bombé. I first made a wide iridectomy, finding it necessary to tear the iris away; and as the patient was only 26 years of age I secured absorption of the lens and opening of the pupil by a number of discissions and by the de Wecker operation for membranous cataract. Resultant vision with correcting lens was sufficiently good for him to go to work again at his trade of blacksmithing, although, of course, he was only able to do the coarser kinds of work.

f. The disease in the sympathizing eye. Clinical types.

Clinical forms of ophthalmitis are observed in several distinct types, although it must be said that these merge into each other, as the disease is an affection of the whole uvea.

(1) Irido-cyclitis plastica.

In this form of the affection the inflammation is largely limited to the anterior portion of the globe. There is pericorneal injection, the aqueous becomes turbid, the pupil small, and it fills up with a grayish exudate. The iris is discolored, dull-looking and thick, but there is no formation of hypopion. The vision deteriorates gradually. The anterior chamber becomes deeper, especially the periphery, as the root becomes drawn towards the ciliary body. The intra-ocular tension diminishes, although where the communication between the anterior and the posterior chambers is cut off from seclusion or occlusion of the pupil the tension may increase. There is not much pain, although the eye is tender to the touch, especially in the same place where the other eye seems to be most tender. Such eyes go on to atrophy, becoming softer and softer, and cornea becomes opaque, the iris atrophic, and the anterior chamber deeper. The pupil is more or less filled with exudate, the lens becomes opaque, the vitreous shrinks, and the retina detaches. The eye gets totally blind. From time to time there is a pause in the atrophic process, but it gradually becomes a true atrophy. There are very few cases in which the inflammation stops by treatment, or through the efforts of Nature, the eye making a partial recovery, and in which the disease does not produce so much damage that some sight may remain.

Most cases of sympathetic inflammation are unfortunately of this type and lead on to total blindness.

A most unfortunate instance was in the case of a gentleman of 60 years who received a foreign body in his eye while in a railway depot, and upon going to an oculist it was not found and some eye drops given. Several days later an intractable corneal ulcer, probably ulcus corneæ serpens, set in and the eye perforated, being enucleated by another surgeon five weeks after the injury, and when the second eye was already irritable. This speedily went on to irido-cyclitis which persisted for a year or more. The eye then becoming quiet about two years after the injury, I made a large iridectomy and delivered the cataractous lens. Degeneration, however, was thereby further excited and the eye went on to atrophy with total blindness.

Chorioiditis plastica.

In this form of the disease the inflammation begins in the posterior portion of the globe, in the chorioid; the symptoms appearing about the optic nerve and the papilla, those in the anterior portion of the bulb being slight. They may entirely fail in the anterior chamber, or they may later appear there. In the beginning the sight is diminished, there is redness, opacity, and swelling of the papilla and enlargement of the retinal vessels. The vitreous becomes dull and opacities form therein.

The course of cases of chorioiditis plastica is much more favorable than in inflammation of the anterior portion of the globe, and it is such cases in which the inflammation may be stopped by treatment. When, however, the inflammatory changes attack the anterior portion of the eye the result is usually unfavorable. Personally, I have not diagnosed such a case, so append an example from P r a u n.[49]

A shoemaker, 19 years old, had an epileptic fit, fell from his stool and pierced his right eye. Was attended by a physician in the vicinity. The eye became blind, was quiet for six months, then became painful. One year later, on examination, the right was found atrophic with a 6 mm. scar, one-half in the cornea and half in the sclera. The left eye was photophobic and painful, pericorneal injection, pupil partially dilated to atropin; synechiæ; papilla hyperemic; small vitreal opacities. Patient refused operation on the blind eye, was treated by mercurials—and on account of the epileptic fits with bromides. In six weeks eye apparently normal. Two months later again painful. Four months later, iris atrophic. One year later V. = fingers at three meters. Iridectomy and vertical discission of lens. Lens substance resorbed after several discissions. Ultimate result, with +16 could read large print. As in the case I previously reported, the eye stood the several operations well without marked reaction.

Irido-cyclitis serosa.

In this condition the inflammatory changes are limited largely to the anterior portion of the globe and the exudate is serous in character. There is pericorneal redness, lacrimation, photophobia, and hazy sight. The characteristic objective sign is the appearance of fine, point-like opacities in the membrana elastica, on the posterior layer of the cornea (keratitis punctata). These are deposits of lymph on Descemet's membrane—the so-called descemetitis. The pupil is usually large and reacts slowly. A few opacities of the vitreous occur. There is seldom any formation of synechiæ. The course may be so light that complete healing occurs after a considerable space of time, or the serous exudate may become plastic, synechiæ occur, and the pupil fills up. The course is then that of plastic inflammation. This form may likewise come to a halt and the sight be retained.

A simple case in my experience was the following: Child, aged 3, cut right eye, ciliary region, with pen-knife. Clean cut, only in sclera and cornea, believed not to involve ciliary region; iridectomy made through wound of incision on account of irreducible iris prolapse. Lens not injured, prompt healing. Four months later returned with irido-cyclitis serosa of injured eye, said to have been of only one week standing. Lacrimation, pain, photophobia, congested optic disc of left eye.

Enucleation of originally injured and inflamed eye stopped irritation within 48 hours. Two months afterwards she was fitted with Snellen eye and no symptoms since.

A complicated case of a double injury, unique on account of this and for the possibility that the first injury, which caused an irido-dialysis, may perhaps have been the salvation of sight, was the following: A boy was injured in the right eye by a whiplash, causing irido-dialysis, when he was about five years of age. In his sixteenth year he was struck in the left eye by a sliver of wood. This became badly inflamed and painful, but being on a farm and very poor he was not taken to a physician in a neighboring town until six weeks thereafter. The physician immediately enucleated the left eye. The right, however, within a few days became photophobic, some iritis developed and about six months after the accident he was brought to see me, practically blind, with only perception of large objects. The anterior chamber and vitreous were too turbid to allow of further examination. Massive doses of sodium salicylate, one grain to the pound of the patient, i. e., 125 grains a day, atropin, hot compresses were used for two weeks with rapid subsidence of the symptoms, clearing of the media and improvement of vision. Several courses of the salicylate were given and about two dozen pilocarpin sweats (12 at a course, dose .001 to .003), with the result after three months of V. full 6/vi and restitutio ad integram.

Chorioiditis serosa.

If the inflamamtion is largely or entirely limited to the posterior portion of the globe the symptoms of serous inflammation are definite. There are no synechiæ nor anterior irritation, and the punctiform opacity of Descemet's membrane does not appear. Through the ophthalmoscope the inflammation at first seems in the form of small hemorrhagic spots, later becoming yellowish-white, simulating chorioiditis disseminata. These changes spread and later occupy a large portion of the fundus. Opacities of the vitreous appear, the optic papilla and the retina become hyperemic. The course of the affection is long but mild, if the inflammation does not proceed to the anterior chamber of the globe where anterior synechiæ and Descemet's spots, opacities of the vitreous, and further chorioidal degeneration sets in.

Under this title we place the sympathetic macular changes described by H a a b,[50] which he says are common from the retention of foreign bodies in the vitreous of the other eye. The macula is particularly vulnerable to the effects of the toxic products of metabolism. Such cases aid in the intoxication theory of the disease. The appearance in the retina is that of fine red lines about the macula, which anastomose with capillaries, the macula itself being covered by small red dots.

In this category we also place the so-called chorioiditis disseminata sympathetica of Hirschberg[51] and Caspar.[52] Anatomico-pathological examination shows that the histologic changes in both the serous and the plastic forms of the disease are quite the same, and that in most cases all three portions of the uveal tract are affected by the inflammation.

In most cases of chorioiditis serosa the inflammation goes from the anterior to the posterior portion of the globe, but those cases where it has proceeded from the posterior segment offer a better prognosis.

Chorioiditis serosa has not been seen by me as a sympathetic manifestation. The following case observed by Rothmund and Eversbusch[37] is illustrative.

A 22-year-old girl had an injury to the right eye which went on the phthisis bulbi. Six weeks after the injury the sight diminshed in the other, V.=6/xxiv. The optic disc was a little swollen, and its edges indistinct. Retina about the nerve stripingly opaque, arteries and veins full and tortuous. The chorioid in the middle and lateral zones had many roundish plaques, point-like, of 1/20 papillary diameter wide. Visual field normal. Photophobia present. Seven weeks after the accident the eye was enucleated, and within three weeks the vision of the sympathetic became normal, the V.=6/vi. Within three months the spots in the chorioid and the swelling of the disc had disappeared.

Neuro-retinitis sympathetica.

Limitation of the inflammation to the optic nerve and retina is said by Braun and other authors to be a rare form of the affection, and it is possible that the appearances in the optic nerve are only part of a posterior plastic or serous chorioiditis. However, there has been described a series of cases in which the changes were apparently limited to the optic nerve and retina. I have noted congestion of the optic disc in a number of my own cases in the opposite eye to the one injured, and upon enucleation the congestion has disappeared. No anatomico-pathologic examination has been made after enucleation of such a type of the affection, so that this remains a plausible supposition.

Pooley[58] saw a 30 year old man who had lost his left eye several years before from trauma. The phthisical stump had been quiet up to a few months before examination, it was then injected and tender. The right eye was normal externally, V. = 2/vii. Heavy papillitis and retinal thickening. After enucleation this rapidly disappeared, the vision being in fourteen days 2/3 normal. Section of the enucleated stump showed bone formation in anterior portion of the chorioid, atrophy of the lens, and neuroretinitis which extended in the nerve back of the eyeball. The lymph spaces were much occluded.

It is possible that some of these so-called cases of neuro-retinitis

sympathetica have proceeded from an undiagnosed disease of the sphenoid, for instance, as in the following case which is even now under my care:

A man was injured by a dynamite blasting explosion six years ago, losing the sight of the left eye, for which at that time enucleation was strongly urged by the attending oculist.

About one year later he removed to another city, when the other eye became inflamed and he had halo symptoms which subsided upon enucleation, which was done about one year after the accident. The second eye remained quiet until about three months ago, when the sight of the right eye became much reduced and it became inflamed and a keratitis punctata developed. The sight varied and there was some pain. He was sent to me, with a diagnosis of glaucoma, for operation of iridectomy, but as I found the optic nerve congested and not cupped, no increase of tension, and a ring scotoma of the visual field I sought further, and on examination of the nose found the sphenoidal walls necrosed, the cavity filled with granulation tissue. Removal of the anterior wall of the sphenoid and curettement of the cavity removed his symptoms after a few days and the sight returned to normal. The optic disc became of a natural color and all his symptoms disappeared.

Mixed forms or indifferently described cases of sympathetic ophthalmitis.

Besides these typical forms various authors have described conjunctivitis, keratitis, scleritis, cataract, detachment of the retina, and atrophy of the optic nerve. Deutschmann[17] thinks that the conjunctivitis in such an instance is either due to the patient carrying some of the secretion from one eye to the other with his hand, or from rubbing the eye.

Keratitis sympathetica has been described but it is usually due to some intercurrent disease. The appearance of scleritis is probably of the same nature.

The opacities of the lens, appearing without any other sympathetic symptoms, are probably due to primary cataract, and have nothing to do with sympathetic ophthalmitis. Secondary cataract, however, is common in eyes that are sympathetically inflamed.

Detachment of the retina and atrophy of the optic nerve are degenerative processes.

Abadie[54] describes a case where a woman, 25 years of age, was injured in the left eye by a fragment of glass from a bottle of lemonade which exploded. A country physician dressed the eye and sent her to an oculist who found an extensive triangular wound of the sclerotic, the apex in the ciliary region, making a large opening in the globe. The oculist sutured the wound with a sterile silk thread, disinfected the wound

as far as possible and made an antiseptic dressing with compress bandage, using cocain as the anesthetic; patient was placed in a hospital and dressings changed twice a day. No pain or photophobia. So far as the trauma was concerned the result was good. September 26 the vision of the right eye became cloudy and black and yellow circles appeared in the visual field. Patient consulted Abadie October 8, 1906, complaining of vision in right eye. The wounded eye was not irritated, slight congestion, no pain, no photophobia, tension slightly subnormal without being soft, motility intact, media clear enough to discover a retinal detachment; vision allowed counting fingers at one meter. Externally the right eye appeared absolutely normal, neither pain nor photophobia, pupil slightly dilated, but reacted feebly to light, visual acuity only one-half. Patient stated that the sight of the right eye had been excellent. Ophthalmoscope demonstrated that the media were clear, the papilla injected, giving a uniformly red aspect, the distinction of arteries from veins could not be readily made. There was no serous exudation and no swelling of the papilla, and the appearance of the latter was not that of the ordinary neuro-retinitis. The retina near the disc was slightly gray, which shaded off to normal shades towards the equator.

Notwithstanding the unusual condition of the right eye, Abadie at once pronounced the change in it as due to sympathy and forthwith prescribed mercurial inunctions. On October 9 the black and yellow circles increased and vision fell to ¼. From ophthalmoscopic examination it was found that optic papilla was injected and the peripapillary gray infiltration more accentuated. October 10 vision 1/10. October 11 vision 1/20. Enucleation of left eye. October 13 vision 1/10, October 15 vision 1/4, October 20 vision 1/10, and notwithstanding the mercurial inunctions continued to lessen. Now one centigram of cyanid of mercury was given intra-venously, and after the second dose vision became ⅓. The aspect of the fundus improved and after twenty of the injections, given every second day, sight was normal. Ophthalmoscopic examination demonstrated that with the exception of a slight white tint in the retina, the fundus was normal. Abadie states that his case is of especial clinical merit and that it should receive attention from several points of view; the form of sympathetic evolution being unusual; the complete absence of pain and of the phenomena of irritation in the injured and also in the sympathizing eye; the transparency of the optic media; the aspect of the optic papilla and of a surrounding retinal zone of gray in the sympathizing eye; the rapid lowering of vision which was out of proportion with the apparent fundus change; and especially the effect of the treatment; the failure of the general and local treatment until the intravenous injections were tried, when success came.

In similar cases Abadie would inject 5 or 6 drops of a sublimate so-

lution (1:100) into the deep orbital tissue from whence the eye had been removed, and this should be carried to the vicinity of the optic nerve stump.

g. Diagnosis.

The diagnosis is determined from the form of the affection of the first, or exciting, eye. There is an incubation period or interval between the injury of the first and the disease of the second eye. The disease in the first eye ordinarily takes the form of an infective traumatic irido-cyclitis and causes a similar affection of the uvea in the other.

The interval is, as a rule, from three weeks to six months after the disease of the first eye. The characteristic inflammation in the second eye is that of a plastic, or, more seldom, a serous irido-cyclitis.

The subjective symptoms of the second eye are photophobia, lacrimation, loss of accommodation, pericorneal injection, tenderness, etc. When a case appears with the three objective symptoms above described, together with the subjective symptoms and the history of an accident, the diagnosis cannot be confused with any other affection.

h. Prognosis.

The prognosis is not good in sympathetic inflammation except when enucleation has been made within the first two weeks after the accident to the exciting eye. In sympathetic irritation the prognosis is always good. The symptoms abate immediately after enucleation, no matter at what time it may be done. The serous types of inflammation, especially those of the posterior portion of the globe, are much more favorable than those which affect the anterior portion.

i. Prophylaxis.

This is the same as that of injuries to the eye in general, together with proper technique in handling of wounded eyes, particularly in perforating injuries of the ciliary region.

C. A. Oliver[55] pleads for reforms in the construction of factories and shops; compulsory employment of protective devices by workmen; personal cleanliness; prompt treatment of ocular injuries; immediate attention to first-aid; and the best possible instrumental equipment of hospitals and dispensaries. Direct causes are to be reached by increased certainty in the use of the X-ray for localization; the prompt removal of foreign bodies from the interior of the eye; early enucleation of hopelessly injured globes; better preparation of the patient for aseptic operation; continuance of control therapy; and better facilities for keeping the patient under prolonged observation.

Arnold Lawson[56] summarizes the preventive treatment in the form of five questions. Though he admits that it is not possible to give a completely satisfactory solution to any of them, he believes that their consideration may lead to a plan of campaign which would prepare the surgeon when confronted with a difficult case of perforating wound of the globe. These questions are answered from his own point of view.

1. Can it be definitely stated of any wound of the globe that it will inevitably produce sympathetic ophthalmia in the other eye? This is answered in the negative. One sees so many shrivelled stumps which are the result of terrible lacerations in bygone years, and which have not in the past and do not at the present cause any inconvenience, that one is inevitably led to the conclusion that sympathetic ophthalmia is an accident to be dreaded and not a certainty to be foretold.

2. If not, what are the lines upon which a surgeon should decide upon immediate removal of the globe? Complete destruction of the globe would be an answer in some cases; secondly, the presence of suppuration in or about the globe; thirdly, the presence of a foreign body which cannot be removed and about the ascepticity of which grave doubts exist; fourthly, extensive and lacerated wounds of the ciliary body, accompanied by prolapse and leakage of the vitreous, especially if not seen within twenty-four hours of the injury, and especially also in cases where the other eye is healthy and visually good.

3. What are the considerations which may decide him to attempt to save the eye? In the last three examples given, if some sight be still retained and the other eye is unsound or visually defective, it may be advisable to attempt to save the injured eye, provided (a) that the wound be seen immediately or shortly after the injury; (b) that it shows reasonable probability of being amenable to aseptic surgical measures and that it can be satisfactorily closed without entanglement of ciliary body or vitreous; (c) that when it is impossible to extract a foreign body the latter is known to be aseptic.

4. In the later history of a case, short of definite history of commencing sympathetic ophthalmia, what symptoms, if any, should decide the surgeon in advising enucleation? This is a difficult question to answer. First, when an injured eye will not quiet down after prolonged treatment or available surgical methods, and is the subject of continued irido-cyclitis, with or without the addition of glaucomatous tension, the danger of supervention of sympathetic ophthalmia becomes a steadily increasing one. Secondly, the injured eye may become more or less quiescent, but the other eye continue exhibiting the signs of sympathetic irritation; this will justify enucleation. Thirdly, in hospital practice, and more rarely in private practice, the question of time that convalescence must occupy becomes one of great importance to the patient.

5. Are there any premonitory symptoms which may accurately be described as heralding the approach of sympathetic ophthalmia, and upon the advent of which a surgeon by immediate enucleation may prevent the onset of the disease? Unfortunately there are no symptoms that can be thus accurately described; the advent of any of the usual clinical signs is sure evidence that the disease is already present; the very insidious character of its onset may cause the earliest signs to pass unnoticed.

1. Therapy.

The Local Treatment of the injured or exciting eye is that of perforating, infected wounds of the ciliary region. In recent cases galvano-cauterization of the wound and covering it by conjunctival flaps after the manner of Kuhnt[57]; immediate cleansing, reposition of iris or iridectomy, antiseptics. I have saved many eyes by the injection of 25 per cent. or 50 per cent. argyrol solution into the anterior chamber, and by the use of iodoform—gelatin rods in the anterior chamber, as advocated by Haab, and 1:3000 sublimate salve of White. Bandage, rest, leeching, subconjunctival injection of sublimate or mercury solution, atropin and dionin in infected or very badly injured eyes.

The local treatment of a sympathizing eye is rest, atropin, dionin, subconjunctival injections of normal saline solutions, sublimate or mercurial salicylate.

General dietetic, hygienic and medicinal treatment. It is very important during this severe antiphlogistic treatment to attend carefully to the patient's general health. He must be well fed, and the appetite promoted by tonics, especially those containing quinine and iron. Formerly one drug to rely on was mercury, and this must be given until its physiological effects become apparent. It may be administered by the mouth, by subcutaneous or subconjunctival injections, by the calomel-vapor bath, or by inunction. Of all these the last is probably the best, and a half to two drams of mercurial ointment should be rubbed well into the skin of the temple and brow every night, or on the arms and legs. The action of the mercury is intensified by iodid of potassium, which may be given in ten or twenty grain doses once a day, after meals.

A course of five to ten pilocarpin sweats (.01 to .02 hypodermically) patient to be wrapped in wet sheet and drink two pints of hot lemonade, followed an hour or so after with an alcohol rub, in the exudative cases secures some absorption of fluid or semifluid exudates and assists elimination.

The effect of the mercurial treatment is rather uncertain. In a few cases recovery of sight may take place as a result of this treatment, but

as a rule the most that can be hoped for is that the active symptoms will subside.

The value of the administration of large doses of salicylate of sodium demands especial mention, and corroborates the experience of Gifford and others who have given the remedy a trial. One grain to the pound of the patient, per diem, is the dose. During its administration the patient should be well clothed and not be exposed to cold or draughts. Even the salicylate of soda treatment was favorable in doses of from four to six grains per diem at the hands of Lindahl.[58]

With Veasey[59] my experience fully concurs with that of Gifford,[60] that the drug must be administered in large doses to be of value (1.00 gram of salicylate for each 6.5 kilos of weight body (10.00 to 13.00 for an adult), the remedy being stopped every 6 or 7 days for one day), and, should I have under my care a patient whose stomach would not tolerate such doses, I would attempt, as he has suggested, its administration by rectum, or perhaps by inunction. Should there be any heart or nephritic disease, smaller doses must be given at first, and the effect carefully noted, but it is my belief that these small doses will not be found sufficient to control the sympathetic affection. The addition of a teaspoonful of brandy, as suggested by Gifford, or a few drops of the tincture of nux vomica, or aromatic spirits of ammonia, to each dose has appeared of value, not only in increasing tolerance of the stomach to the drug, but in relieving, to some extent, the more or less depressant effect on the heart. It acts more rapidly and is safer than the treatment by inunction; it does not, however, prevent relapses and is not effectual from the standpoint of prophylaxis, but it has a favorable effect upon the iridocyclitis in this disease.

Widmark[61] reports 12 cases of sympathetic ophthalmitis, 8 of which were treated with sodium salicylate 4 to 9 gms. per diem, with excellent results. In nine cases the eye was removed.

C. R. Baker[62] advocates methyl salicylate and colchicin. Aspirin is advocated by Brose[63] and Edgar Thompson.[64]

Gifford[60a] says that in view of the possible causation of sympathetic ophthalmitis by a protozoa he tried atoxyl in two cases, and apparently with success. In one case, however, its value was questionable because of the simultaneous administration of large doses of sodium salicylate. The author gave 30 minims of a 10 per cent. solution injected subcutaneously, at first twice a week, then every other day, until 180 grains in all had been given.

As noted in the foregoing some cases of either anterior or posterior serous sympathetic irritation and inflammation may be relieved by medicinal treatment, several cases from recent literature following.

Sourdille[65] reports four cases of sympathetic ophthalmitis (or

irritation). In the first there had been a burn of the left eye by a caustic. This was followed by an inflammation of the corneal nerves, accompanied by pain, photophobia and anesthesia.

The fellow eye developed an ulcerating keratitis which refused to heal until after two subconjunctival injections of bichlorid of mercury had been made into the eye which was first affected.

The second case evidenced an acute attack of iritis in one eye four weeks after a slight injury, followed by a bullous form of keratitis in the fellow. Relief followed the use of bichloride of mercury injections into the eye which was first affected.

In case 3 there developed an iritis with vitreous haze and reduction of vision on the opposite side nine months following a slight peripheral corneal wound with an iris prolapse, which had been excised. The injured eye had remained quiet.

In the last case there was an atrophic globe of 35 years' standing which was associated with a superficial form of punctate keratitis on the opposite side. This yielded only to enucleation of the atrophic stump.

Edgar Thompson[64] reports the case of a man of 71 years who developed a pseudo-membranous conjunctivitis. The cornea became necrotic early, the cornea cicatrized with the iris included in the scar. Three months later he developed sympathetic inflammation in the other eye. The exciting eye was removed. Under large doses of aspirin he made a splendid recovery with normal vision.

The second case was in a man of 62 years who had his eye injured in a fight by a finger thrust. Severe kerato-hypopion followed with corneal ulceration. Saemisch section was performed. The eye finally healed with a large corneal cicatrix which included the iris. In two months time he developed sympathetic inflammation. The exciting eye was removed. Under mercurial inunctions and large doses of aspirin he recovered with V. = 20/xl. The author emphasizes the importance of keeping such patients in bed with eyes bandaged. Atropin should be used in moderation.

Simeon Snell[66] gives details of a case of this affection in which normal vision was restored in the exciting and sympathizing eye. The patient was a man aged 38, whose left eye was wounded on September 8, 1904, and when seen for the first time, 11 days later, there was a wound of the cornea extending into the ciliary region, with a prolapse of the iris. The prolapse was at once excised, and the eye healed without further trouble. On October 12 the right eye was noticed to be red, and five days later there was iritis, and then it was noticed as being a severe case of sympathetic ophthalmia. About a month later the pupil began to react, and the eye to whiten. Since then recovery has been perfect and vision is now 6/5 and J. 1 in each eye. Snell also recorded three cases

in which sympathetic ophthalmitis had come on after excision of the eyeball, and referred to one published by him in 1882, in which the disease showed itself 32 days after the excision, and 106 days after the injury. Of these four cases, one was mild and recovered, three were severe, and two of them became totally blind.

C. R. Baker[62] reports an eye operated upon for senile cataract which developed irido-cyclitis on the third day, which ran a protracted course. The eye finally became quiet with a closed pupil. Some four months later sympathetic ophthalmitis developed in the fellow eye. The exciting eye was not removed. The sympathizing eye ran a tedious course and finally became quiet. The exciting eye was then operated upon, and a good pupil obtained by making an iridectomy with Steven's punch. Vision of 10/cc. was obtained, but soon failed, the eye becoming soft and blind. It was enucleated and the pathological findings are reported at length. The sympathetic eye being quiet, a preliminary iridectomy was performed and later the lens was successfully removed. Vision of 5/cc. was obtained, but it is rapidly failing and will probably follow the course of its fellow. Sodium salicylate was pushed to toleration several times, without apparent benefit except relief of pain. Better results were obtained from methyl-salicylate and colchicin. Apparently more benefit was obtained from the use of mercury, which was given more or less continuously for three years.

Case 2 was that of a man, aged 46, who was suffering from an ophthalmitis induced by a piece of steel in the eye. The fellow eye was photophobic, irritable, watery and asthenopic. All symptoms of sympathetic irritation soon disappeared in the sympathizing eye.

An example of a natural cure, perhaps from the development of an antitoxin, is given by Ahlström.[20] An engineer, age 25, came with sympathetic ophthalmia three months after an injury of the other eye by a boiler explosion. The latter was atrophic and painful, and was at once enucleated. It contained a piece of manometer glass. The enucleation and inunctions did not retard the progress of the violent sympathetic irido-cyclitis. After a week and a half there was only perception of light. Then the patient had a severe attack of fever, to which he was subject during his sojourn in Africa. With the subsiding fever, after taking quinin, the condition of the eye showed marked improvement, which was still greater after a second attack three weeks later. Another relapse occurred after four weeks and left the eye in a still better condition. The synechiæ were torn, except one, and the vitreous had cleared up considerably. V.=6/xviii, rose within a month to 6/ix and remained so up to the last report, seven years later. The patient was able to work as draughtsman in a machine shop. Apparently the healing influence of the fever was due to an action of toxins, analogous to the favorable

course of some eye affections after inter-current erysipelas of the face.

The only point worth discussion now is what procedure it is best to follow in cases in which sympathetic trouble is threatened when the injured eye is still capable of useful vision.

It is not possible, of course, to prescribe a formula for all cases. As Coppez has said: "To enucleate a sympathizing (injured) eye still capable of vision when we are not sure of preserving the vision of the other ("sympathizer") is assuming a grave responsibility."

There is a prudent medium betwen the abuse of enucleation and the dangerous conservatism which tends to result from the reaction against it. It is good surgery to sacrifice eyes in which good vision is manifestly lost, particularly if they contain foreign bodies. It can no longer be denied that when enucleation is performed, even at the earliest appearance of the slightest subjective symptom of sympathetic affection, it may be, and nearly always is, already too late. Enucleation is of but little benefit when sympathetic ophthalmia is once established, and it is better to sacrifice a useless eye before the first signs of sympathetic inflammation appear, when it may be too late, though, even then, it is well to enucleate.

Valude[67] believes, though, that an injured and sympathizing eye still capable of useful vision, should be retained when the other is involved, in view of the uncertain effects of enucleation after sympathetic ophthalmia is once established.

Abadie[54] says if the traumatism has destroyed all hopes of vision or even of preserving the form of the globe, enucleation is unavoidable. If, on the contrary, the wound is small, if a little vision remains and the form of the globe is preserved in almost normal dimensions, this author maintains that an attempt should be made to save the eye.

He advocates the thorough application of the galvano-cautery to the wound and covering it with conjunctiva. If sympathetic disease should still threaten he has recourse to mercurial inunctions or injections. If the worst comes, enucleation is still available (if not too late).

Even in the presence of declared sympathetic ophthalmia, he does not despair, but cauterizes the wound vigorously and makes deep mercurial injections in the orbit of the injured eye.

Dunbar Roy[24] says it is the consensus of opinion that if there is an active sympathetic inflammation in the uninjured eye the removal of the injured member in no wise retards the inflammatory process, and in many cases it is better to try to save vision in the offending eye, and he cites a case where the injured eye was quiet, yet had caused sympathetic inflammation (irritation?) when sight was saved in the sympathizing eye, V.=20/lxx, by medicinal treatment.

The one operation on the injured or exciting eye indicated in most cases is enucleation, for which Ramsay[68] gives the following rules. In

many cases enucleation is inevitable, and the following may serve as a guide:

1. Enucleate at once when the injury is so severe that the exciting eye is destroyed hopelessly from the beginning.

2. Enucleate at once on the slightest sign of sympathetic irritation, should the vision of the exciting eye only equal a perception of light and darkness.

3. Enucleate at once if a foreign body is present in, and cannot be removed from, the exciting eye.

4. Enucleate at once when an injured eye is blind and suffering from recurrent attacks of acute inflammation, or when it is tender and irritable as a result of the onset of degenerative changes—e. g., ossification of the chorioid.

5. Do not enucleate when there is still sight in the injured eye, and when there is no sign of disturbance in its fellow.

6. Do not enucleate when sympathetic inflammation is in progress and there is still sight in the injured eye, for under these circumstances the removal of an "exciter" will have no beneficial influence, and the probability is that in the end all the sight the patient will possess will be in the primarily injured eye.

Optico-ciliary neurotomy, simple evisceration, and as suggested by Mules, exisceration and the implantation of a glass or gold ball within the sclerotic or Tenon's capsule, as done by Fox, Allport and others. The immediate filling in of the stump by melted paraffin or a ball of the same substance, as done by Ramsay with suturing of the recti and conjunctiva, offer no cosmetic advantages over the purse-string suture of Tenon's capsule and conjunctiva, which I described in 1893, and the fitting of a full back or Snellen reform artificial eye; and they surely do not afford the protection that has been found to be given by complete enucleation of the injured eye. Any depression of the sulcus of the upper lid may be later remedied by injection of solid paraffin by a special screw syringe.

Many unfortunate cases of sympathetic ophthalmitis have been reported, even when all due care has been taken and speedy enucleation made of the injured eye. Several such have been seen by me.

A boy was struck by a portion of a ten-penny nail, which he was trying to cut in two with a hatchet. He was treated by a general physician for about four days when he was taken in consultation to an oculist who advised immediate enucleation, which, however, was not accepted for several days, and in ten days the other eye became weak. Enucleation was then done, but despite this a chronic irido-cyclitis developed in the second eye, which later led to total blindness about six months after the accident, when I saw him in consultation.

A gentleman while out driving got a foreign body in the eye. He

immediately went to an oculist, but not finding him in his office followed him to the railway station as he was about setting out on a trip. A hurried examination was made and nothing found. A few days later an ulcer of the cornea developed and was treated by the same man, but progressed badly and a change was made to another oculist, who found the eye in such a bad condition from almost complete ulceration of the cornea that he enucleated it. About three months after the accident the other eye commenced to be weak and went on to irido-cyclitis. Two years after this occurrence there was complete occlusion of the pupil with cataractous lens and increased tension. I saw this case in consultation and was prevailed upon to operate, first making an iridectomy, which promptly closed. Later, on remembering a previous experience with a case, and others of a similar nature, I extracted the lens but found that the pupil filled up and our work was for nought, as the eye later went on to atrophy.

In a boy who was injured by a stone the eye became inflamed and was treated for over three months by a general practitioner. At the end of the second month the other eye became inflamed and the boy had very poor vision. At the end of the third month the originally injured eye was enucleated by the same practitioner. The sight went on from bad to worse, and when I saw him several months later the eye was soft and atrophic and there was but feeble sense of light.

k. Sympathetic ophthalmitis occurring after substitutes for enucleation.

The substitutes for enucleation, as evisceration, Mules' operation, optico-ciliary neurectomy, are absolutely worthless to prevent sympathetic ophthalmitis, as the following from the literature will show:

Trousseau[69] reports sympathetic ophthalmia after ablation of the anterior segment of the eye. A chronic cyclitis had followed an unsuccessful operation for complicated cataract of the right eye two years before the patient was seen by Trousseau, and later an abscission had been performed.

Seven weeks after this last operation the left eye was weak and watering and vision was so much impaired that the patient had difficulty in going about. The eye was congested, there was pericorneal injection, the iris was changed in color and adherent in places, there were points of exudation on the membrane of Descemet, and the vitreous was hazy. The stump of the right eye was injected and tender to pressure.

The stump was enucleated and atropia, mercurial inunctions and laxatives were ordered. The symptoms improved and the patient was finally discharged with vision equal to one-third.

Readers of French, German and Italian literature will note that the injured eye is called the "sympathizing" eye; the opposite reading from the English.

The author considers it indisputable that when sympathetic ophthalmia has commenced nothing should be done for the sympathizing (injured) eye but to remove it. Any other intervention promotes sympathetic ophthalmia. He has known of cases in which resection of the optic nerve, the use of the galvano-cautery, iridectomy, the removal of a foreign body and abscission have had this effect.

Byers[70] notes a case of sympathetic ophthalmia which followed a Mules' operation and ended in recovery. The fact that a sympathetic ophthalmia, occurring after enucleation of the eye, usually runs a favorable course is well known. From the five cases already recorded it would appear that the same rule applies to Mules' operation. The writer gives an interesting account of such a sequel. A young lady presented a serious injury of the right globe as a result of the explosion of a bottle of peroxide of hydrogen; there were two large, irregular, gaping wounds in the right cornea extending well beyond the ciliary region, protrusion of the iris, collapse of the globe, and vision reduced to p. l. The accident was followed by very little reaction. After conservative treatment for forty days, a Mules' operation was performed. Two weeks after the operation a typical serous cyclitis had developed, and two months later a mild neuro-retinitis was added; the cyclitis ran its course in 18 months and the neuro-retinitis a few months later. Excepting an increase of the patient's error of refraction during the first three years following her recovery, there has been little change in the eye for now over four years; a few posterior synechiæ and a little atrophy of the iris. V=6/ix with correction; the eye is comfortable and capable of considerable work.

Brobst[71] reports a case in which the eye of a boy was destroyed by an extensive cut with a knife, and ten hours after the accident a Mules operation was performed. Sixty days later he developed sympathetic optic neuritis. The stump of the exciting eye was painful to touch and congested. It was enucleated and deep injections of cyanide of mercury were made into the stump of the optic nerve and this was repeated three days later. The sympathizing eye made a speedy recovery.

Emmerson[72] reports a case of sympathetic irritation following a Mules operation. The glass ball had to be removed, when a few drops of straw-colored fluid escaped. Relief was prompt.

Don M. Campbell[73] says post-operative sympathetic ophthalmitis is not an extremely rare occurrence. Second. There is a special anatomic-pathologic condition, the occurrence of which in an injured eye will surely produce sympathetic ophthalmitis in the other eye. Third. The search for a special route of passage from one eye to the other is fruitless and unimportant. Fourth. The evidence of a general systemic

infection being at the bottom of the difficulty is fairly conclusive. Fifth. There is a train of symptoms—objective and subjective—which are farily convincing of the immediate probability of an impending sympathetic ophthalmitis; there are violent inflammatory disturbances in the injured eye accompanied by the evidence of infiltration in the uveal tract; clinically this is best shown by muddiness, thickening of the iris and tenderness over the ciliary region, great pain, a prickling or numb feeling over the distribution of the ophthalmic division of the fifth nerve, especially the sub-orbital branch; constitutional infection, with general depression, malaise, loss of appetite, moderate elevation of the bodily temperature and pulse rate, and later on the well-known signs of inflammation in the fellow eye.

Modern treatment is superior to that of fifteen years ago. Six cases are reported, in three of which sympathetic inflammation developed in from three to four weeks after operative procedures upon the eye, which involved opening the anterior chamber. In the other three cases, two followed enucleation after an interval of three weeks and one followed a Mules' operation in a child after an interval of three years. The first two cases were treated by mercury and terminated badly. The other four were given heroic doses of sodium salicylate after the method of Gifford and all made perfect recoveries.

Gifford[60a] reports a case in which a man of 45 sustained a penetrating wound of the sclera from a sunflower stump. A Mules' operation was performed six weeks later. The glass ball was introduced through a scleral wound, the cornea being left in place. Six months later he developed an active sympathetic inflammation of the usual type. There were no signs of irritation in the exciting ocular stump. It was enucleated at once and the patient placed upon the sodium salicylate treatment and he made a splendid recovery. Eighteen months later he had an attack of acute glaucoma. Iridectomy reduced tension and improved sight. Six months later tension went up again, when a sclerotomy was performed. Three months later another sclerotomy was performed, but the eye remained congested, and a solid, immovable exudate collected in the anterior chamber, and the lens gradually became opaque. In spite of all treatment the exudate increased and the cornea was nearly all of a yellowish hue. The globe became small and soft, with doubtful light perception. Gifford has collected all the cases reported of sympathetic inflammation which have followed Mules' operation, 14 in all, 9 after ordinary evisceration, and 3 after Frost's operation. He mentions incidentally that 35 cases have followed enucleation. A study of the cases presented suggests the possibility of many of them being coincident diseases of the unoperated eye. Credit is given to removal of the supposedly offending stump when the seeming sympathetic process in the other eye

possibly would have recovered under the treatment used without this surgical interference.

C. A. Oliver[39] gives the clinical history and histiologic study of a case of transferred ophthalmitis following the insertion of a gold ball into the scleral cavity. A middle-aged miner lost an eye from a penetrating wound of the cornea from a piece of coal. A Mules' operation was performed. Seven weeks later a typical sympathetic inflammation developed in the other eye. The offending stump was enucleated and the patient put upon the sodium salicylate treatment. He recovered with iritic adhesions and cataract. A preliminary iridectomy was performed and the lens was removed two weeks later. The patient regained useful sight. An examination of the enucleated stump did not reveal the presence of bacteria. The sclera was found to be much thickened and its tissues infiltrated with leucocytes. The optic nerve was much swollen and its fibres atrophic. It was thickly infiltrated with leucocytes. The sheath was thickened and the lymph spaces packed with mononuclear leucocytes. The central artery was plugged with leucocytes.

1. Post-sympathetic operative treatment of the sympathizing eye, and upon the exciting eye.

No operation should be attempted upon the sympathizing eye until all acute symptoms have subsided for several months, for any attempt to perform an iridectomy, to open the pupil, to extract or divide a cataract, or to even do a cauterization of the cornea or a sclerotomy, even if successful at the time of operation, will be followed by accentuation of the symptoms and increased inflammatory exudation, with reclosure of the pupil.

After a sufficient time—a year or eighteen months—has elapsed, and if, during that interval, there has been no recurrence of inflammation, the intra-ocular tension has not diminished, and the patient's perception of light is satisfactory, operative interference may be considered.

Should it be resolved on, the iris should as far as possible be let alone. The lens must be got rid of, either by needling in the manner suggested by Critchett, or, in more favorable cases by drawing it out with a curette after the toughened capsule has been divided with a knife. Once the cataract has been removed, an iridotomy may open up the pupil sufficiently to allow light to enter the eye, and enable the patient to see as well as the damaged state of the retina will permit. In operating on such eyes, it must always be remembered that the vitreous is quite fluid and escapes readily, therefore it is important that all incisions be as small as possible and be made wholly in the cornea. After operation the eye must be carefully bandaged and the patient kept quiet in bed in a dark room, while the local application of ice, and the administration of sed-

atives internally, will do much to prevent the occurrence of inflammatory reaction.

In operating on sympathetic soft cataract Hirschberg[74] makes an operation consisting in section of lower limbus, and, carefully avoiding the iris, in removing the capsule with the four-toothed forceps. The pupil at once enlarges and lens matter oozes which is removed by irrigation and partly by outward pressure.

In another case Hirschberg cut the capsule with Knapp's knife, which to be repeated, as the lens matter was not sufficiently removed by the first operation. If in such cases the pupil should close again, Hirschberg advocates opening with Knapp's knife through the iris. He considers this preferable to the method of Wenzel, in which the cataract knife penetrates cornea, iris and lens.

Borghetti[75] suggests a sclero-corneal incision on the first day made with a Graefe knife on each side, leaving a bridge of cornea above and below. The iris is cut all along this incision close to its base, leaving a bit of it at the top and bottom. The lens is now needled or its elements disintegrated by pressure. The next day the capsule is removed and the lens is removed by suction.

m. Sympathetic ophthalmitis after shot wounds in war.

According to Praun,[76] the German War Office reports 99 cases of sympathetic inflammation of the eye after injuries received in war, most of them being due to shot wounds. In the American War of the Rebellion there were 41 cases of sympathetic inflammation in 254 cases of eye injuries. From the fact that the army surgeon's duty is, as a rule, to immediately remove badly injured eyes received during war, the prognosis of such is against the development of sympathetic ophthalmitis, and is perhaps better than wounds of the eye received during civil life.

Cohn[77] says among the principal lesions noted are: Total destruction of the globe; atrophy of the globe; wounds of the globe with or without retention of foreign substance; iridodialysis; mydriasis; hemorrhage into the vitreous; rupture of the chorioid; detachment of the retina; atrophy of the optic nerve; and paresis of the rectus internus muscle. It is easily understood how this variety of lesions is produced. In passing through the osseous walls of the orbit the bullet imparts motion to the bone fragments, which, together with the projectile, constitute crushing, lacerating, cutting, and stretching agents.

LITERATURE.

1. Dunn, *Lancet*, Aug. 10, 1904.
2. Georg Bartisch *(Eye Practise)*, Dresden, 1583, p. 205.
3. Bartolinus, ref. Brondeau, *Des affectiones sympathetiques*, Paris, 1858.
4. Bildoo, ref. Brondeau.

5. Beers, ref. Pagenstecher, *Klin. Beobach. a. d. Augenheilanstadt,* Weisbaden, No. 2.
6. Demours, *Traite des maladies des yeux,* Paris, 1818, p. 368.
7. von Ammon, ref. Hirschberg, *Arch. f. Ophth.* V, p. 209.
8. Himley, Textbook, ref. Praun, l. c. p. 66.
9. Tavignol, ref. Theobold, *Journ. A. M. A.,* Jan. 28, 1905.
10. MacKenzie, Textbook, 11th Ed., 1844.
11. White-Cooper, Textbook, 1852.
12. Heinrich Müller, *Arch. f. Ophth.* IV, p. 367.
13. Donders, ref. Praun, l. c. p. 68.
14. Hirschberg, *History of Ophthalmology.*
15. Theobald, *Journ. A. M. A.,* Jan. 28, 1905.
16. Leber, *Arch. f. Ophth.,* XXVII, 1.
17. Deutschmann, *Arch. f. Ophth.,* XXVIII, 2, XXIX, 4, XXX, 3 XXXI, 2. *Beitr. z. Aug.* X, and *Trans. X Internat. Cong.,* 1890.
18. Gifford, ref. Zentmayer, *Trans. Sec. Ophth. A. M. A.,* 1905, p. 123.
19. Schirmer, *Arch. f. Ophth.,* xxxviii, 4, 1892.
20. Ahlström, *Centralbl. f. Aug.,* July, 1904, p. 193.
21. Würdemann, *Ophth. Record,* Nov., 1905.
22. Zentmayer, *Trans. Sec. Ophth. A. M. A.,* 1905, p. 123.
23. E. Fuchs, (a) *Arch. f. Ophth,* LXI, 2, 1906, and (b) May, 1909.
24. Dunbar Roy, *Ophthalmology,* Jan., 1910.
25. Dalen, ref. Fuchs, 236.
26. E. V. L. Brown, *Arch. Ophth.,* March, 1907.
27. Ruge, *Arch. f. Ophth.,* Dec., 1906.
28. Schirmer, ref. Ruge, 27.
29. Heefordt, *Arch. f. Ophth.* LXXIX, 3, Jan., 1907.
30. Trousseau, (a) *Rec. d'oph.,* 1897, p. 249. (b) *Arch. d'opht.,* Nov., 1909.
31. Gifford, (a) *Ophth. Record,* 1897, p. 673. (b) *Journ. A. M. A.,* July, 1910.
32. Mooren and Rumpf, *Centralbl. f. Med.,* Wissensch. 1880, No. 19.
33. L. Bach, (a) *Arch. f. Ophth.,* XLII, 1, p. 241. (b) Bericht ad. d. XXIV *Versaml. d. Ophth. Gesell.,* Heidelberg, 1895.
34. Joseph, ref. Praun, p. 72.
35. Limbourg, *Arch. f. Aug.,* LCII, p. 82.
36. Schmidt-Rimpler, *Arch. f. Ophth.,* XXXVIII, 1, 1892.
37. Rothmund and Eversbusch, *Mitteil, a. d. Augenklinik,* München, I, 1882, p. 329.
38. Bacchi, ref. Praun, p. 82.
39. C. A. Oliver, *Ophth. Record,* Nov., 1905.
40. von Michel, ref. Praun, p. 88.
41. Hubbell, *Ophth. Record,* Oct., 1901.
42. Mathewson, *Ophth. Record,* Nov., 1908.
43. Deshogues, *Rev. d. Med. y Cirurg.* d. l. Habana, 1905.
44. Sulzer, *Ann. d'oculist.,* Feb., 1907.
45. de Wecker, ref. Sulzer.
46. A. Maitland Ramsay, *Eye Injuries and Their Treatment,* 1907.
47. Fejer, *Centralbl. f. prak., Aug.,* Aug., 1909.
48. Würdemann, *Am. Journ. Ophth.,* June, 1889.
49. Praun, l. c. p. 92.
50. Haab, *Beitr. z. Aug.,* XI, p. 330.
51. Hirschberg, *Centralbl. f. prak. Aug.,* 1895, p. 82.
52. Caspar, *Klin. Mon. f. Aug.,* 1905, p. 179.
53. Pooley, *Amer. Jour. Ophth.,* 1884, p. 69.
54. Abadie, *La. Clin. Opht.,* Dec. 25, 1906.
55. C. A. Oliver, *Journ. A. M. A.,* July 27, 1907.
56. Arnold Lawson, *Brit. Med. Journ.,* Dec. 29, 1906.
57. Kuhnt, *Die Verwerthbarkeit der Bindehaut, etc.,* 1898.
58. Lindahl, *Wien. Med. Woch.,* Oct. 7, 1905.
59. Veasey, *Journ. A. M. A.,* Jan. 28, 1905.
60. Gifford, (a) *Ophth. Record,* Nov., 1908. (b) *Klin. Mon. f. Aug.* XLVIII, 1, p. 588, and 31, a, 31, b.
61. Widmark, *Wien. Med. Woch.,* May 15, 1909.
62. C. R. Baker, *Ophth. Record,* March, 1909.
63. Brose, *Lancet Clinic,* July 18, 1908.

64. Edgar Thompson, *Ann. Ophth.*, Oct., 1908.
65. Sourdille, *Arch. d'opht.*, June, 1904.
66. Simeon Snell, *Brit. Med. Journ.*, July 15, 1908.
67. Valude, *Ann. d'oculist.*, July, 1908.
68. A. Maitland Ramsay, *Ann. Ophth.*, Jan. 1904.
69. Trousseau, *Ann. d'oculist.*, July, 1908.
70. Byers, *Brit. Med. Journ.*, Dec. 29, 1906.
71. Brobst, *Ophth. Record*, Nov., 1907.
72. Emmerson, *Ophth. Record*, Nov., 1907.
73. Don M. Campbell, *Ophth. Record*, Nov., 1908.
74. Hirschberg, *Centralbl. f. Aug.*, 1905, p. 97.
75. Borghetti, *Ann. Ophth.*, Apr., 1908.
76. Praun, l. c. p. 104.
77. H. Cohn, *Klin. Mon. f. Aug.*, p. 466, 187.

CHAPTER V

COMPLICATIONS OCCURRING DURING AND AFTER OCULAR INJURIES—(Continued.)

A. Traumatic glaucoma, Etiology, Therapy, Literature—B. Wound infection in injuries of the lids and soft parts of the orbit, Penetrating wounds, Erysipelas, Abscess, Clinical course, Therapy, Tetanus, Syphilis, Literature—C. Surgical diseases following orbital and lid injuries—D. Tumor formation after injuries—E. Traumatic neoroses, Keratalgia, Cicatrix dolorosa, Ciliary neuralgia, Hysteric blindness, Literature—F. Psychoses, Postoperative mania, Suicide, Literature—G. Errors of refraction produced by trauma, Myopia, Hyperopia, Astigmia, Literature.

III. (A) TRAUMATIC GLAUCOMA.

Typical Glaucoma may be produced by trauma. So-called Hemorrhagic Glaucoma following operations is discussed under Operative Accidents.

Eyes with glaucoma and arterio-sclerosis are predisposed to hemorrhage from the brittleness of their vessels. The affection is rare and it is not peculiar to old age. The ages of the patients vary from 6 to 66, and there have been more instances in young subjects than in old.

Villard[1] reports three cases of typical acute glaucoma following contusions of the eye, and refers to twenty-four others, which are all that he has been able to find after a careful search in literature.

In all the cases reported, traumatic glaucoma had been a primary affection, occurring suddenly in subjects who before the accidents had never presented any symptoms of glaucoma.

The time after the traumatism at which it appears varies from a few hours to several days. In one case it appeared nine days and in another nineteen days after the injury.

It may be preceded by intraocular hemorrhage, but this is often absent. Rather frequently it has been accompanied by a subluxation of the lens.

The pathogeny of traumatic glaucoma has not been definitely determined. According to some authors the hypertension is of nervous origin; according to others, the mechanism of the glaucoma should be sought principally in the modification which the aqueous humor undergoes in consequence of violent contusions of the globe. The aqueous humor is charged with a high proportion of albumin which transudes through the

walls of the vessels of the ciliary body paralyzed by the traumatism, and this albumin obstructs the normal paths of ocular excretion. Others maintain that the increased tension is the result of a traumatic cyclitis which obstructs the angle of filtration by causing a swelling of the ciliary body, and at the same time a hypersecretion of aqueous humor more or less altered in its chemical composition. According to still others, the obstruction of the paths of excretion, in cases accompanied by intra-ocular hemorrhage, may be caused by pigmentary débris, or fibrin from the extravasated blood.

Kriener[2] says following injury to the zonula or swelling of the ciliary body with pressure upon the filtration angle glaucoma has been produced.

Praun[3] says that where atropin is not used in traumatic cataract the swollen lens presses upon the iris, and with the increase in the sp. gr. of the aqueous closes the communication between the anterior and posterior chamber and causes increased tension. In young people the eye capsule yields, which it does not do in older persons with hard sclera and secondary glaucoma, when excavation of the papilla arises.

Luxation of the lens into the vitreous, in case of the accident of reclination, produces increased tension, as it surely does in forward dislocation. Some authors think that glaucoma is consecutive to a slight subluxation of the lens which, pressing at a point on the ciliary zone, provokes a reflex hyperemia of the whole uveal tract and a mechanical obstruction of the paths of excretion, but this explanation is not applicable to all cases, since in some there was an entire absence of luxation.

Buchanan[4] says rupture of the pectinate ligament allows the ciliary body to slip backward, at the same time drawing upon the iris, then causing pupillary distortion and a deepening of the anterior chamber in the region of the pectinate rupture. The lesion is usually caused by a blow on the eye from a blunt instrument without rupture of the globe. An hyphema usually follows at once, which, after absorption, presents the above picture. The canal of Schlemm usually becomes obliterated and increased tension is a symptom which finally develops and ultimately demands excision of the eye.

Finally some claim that traumatic glaucoma is to be explained, not by an obstruction of the paths of excretion, but rather by an obstruction of the suprachorioidal lymphatic spaces following a hyperemia and serous exudation of the chorioid. This last explanation has the support of the only histologic examination that has been made.

Each of these diverse pathogenic explanations may contain a certain degree of truth, or be applicable to a particular case. The question of pathogeny therefore remains obscure.

In all cases the classic picture of acute glaucoma has been observed.

Traumatic glaucoma had occurred in all degrees of severity, from a simple transient increase of tension to a well-developed and malignant attack.

The prognosis is very variable. In a large proportion of the cases a complete and lasting cure has been obtained, while in many a loss of vision has been reported.

The medical treatment includes strong myotics, hot compresses, local bleeding and dionin, and generally bromids, chloral, antipyrin, quinin, etc., may be given.

In the surgical treatment, iridectomy is the operation of choice, though it appears from reported cases that sclerotomy or even simple paracentesis acts more decidedly in traumatic glaucoma than in the spontaneous form.

Traumatic glaucoma occurs from inflammation, swelling and edema of the ciliary body in closing the space between it and the lens.

Peters[5] says the etiology of glaucoma after contusions is to be attributed to mechanical interference in the circulation of the sinus of the anterior chamber by the gelatinous, colloidal consistency imparted to the aqueous by admixture of blood, lens matter or albumin from paralysis of the blood vessels. This view is supported by the therapeutic success obtained by puncture of the cornea, which influences the circulation beneficially by changing the intraocular pressure and emptying the anterior chamber of coagulating albumin. Peters, therefore, advocates paracentesis in this kind of glaucoma in preference to iridectomy.

In the study of the relation between anterior synechia and hypertony Fuchs[6] examined 70 eyes, including instances of spontaneous irido-cyclitis, recent and old corneal injuries, ectasic corneal scars with increased tension. The results were surprising to Fuchs, as he states that it is usual to find in these cases of anterior synechia, with simultaneous increase of tension, the anterior chamber in great extent obliterated. He had expected where there had been no increase in tension to find such obliteration absent, or at least limited to that portion corresponding to the position of the anterior synechia, but on the contrary he found that a very extensive adhesion of the base of the iris to the periphery of the cornea could exist without necessarily producing an increase in tension. The adhesion simply predisposes to hypertony, and why in some cases it is present, and others not, is still to be determined. The therapeutic lesson taught is to prevent the peripheral adhesion of the iris.

A Jewish boy of 18 had been struck in the eye by a stone several months previous to the time he came to see me. Tension +3, dilated pupil and congested ciliary vessels; pain; vision reduced to 6/lx. This was relieved within a week by myotics and the case lost for several

months, until he returned the day after All Hallows' Eve, stating that on the previous evening he had been struck in the eye by a loaf of bread thrown by one of his playmates, while skylarking. This attack of glaucoma was likewise relieved by myotics and digital massage, the case again being lost sight of after several weeks, so its outcome is unknown.

Moretti[7] reports a patient, 34 years old, without apparent cause, began to have pain in the right eye, with slight redness of the conjunctiva, intense headache in the right fronto-temporal region and cloudy vision. Shortly afterward she noticed redness and swelling of the lids. When she came to the hospital the lids were slightly swollen, the conjunctiva showed ciliary injection and the infiltrated cornea projected like keratoconus. The iris was discolored, immobile and showed masses of exudate in its inferior segment. The lens occupied the pupillary field and adhered by its anterior surface to the posterior surface of the cornea. Tension was much increased. In the left eye the lens was luxated below and internally. The papilla appeared double, one image being larger than the other. The lens was removed from the diseased eye, with the result that all symptoms of tension were relieved. From the fact that the lens in the left eye was luxated with no history of traumatism the writer concluded that the glaucoma was the result of the spontaneous luxation of the lens into the anterior chamber.

Hoor[8] describes a very rare complication of glaucoma in retinal detachment, in which the tension is usually lowered.

A workman was struck in the eye by a piece of iron; ciliary impaction; floating opacities in the vitreous; redness of the papilla; arterial and venous pulse; and a flat retinal detachment with pigment migration. Pilocarpin, locally and by injection; rest in bed on back; bandage; and later eserin. Three months later the retina in place but not functionating. Glaucomatous excavation and loss of visual field. Iridectomy relieved glaucoma but caused temporary detachment of retina.

Ferber[9] saw glaucoma in a woman who had a piece of iron band strike the eye.

Garnier[10] saw anterior glaucoma with staphyloma follow a blow on the eye in a boy.

Stoewer[11] saw glaucoma follow severe compression of the eyes from the effect of the powder-mill explosion at Robirut.

Praun[12] notes glaucoma from artillery fire.

Glaucoma after cataract extraction, even with iridectomy, occasionally occurs, although more often when simple extraction is done. It is due to the faulty technique or to prolapse of the iris after operation.

Mechanism. There is some interference with the patency of the infiltration angle, due to the iris or the capsule in the scar, or some obstruction of the pupil by membrane or inflammatory exudation.

Glaucoma following discission for secondary cataract is not infrequent. It is due not only to pressure upon the filtration angle resulting from the traction of the swollen ciliary processes, but also to the altered character of the aqueous humor, which contains more albumin and minute particles which tend to accumulate in the tissues and clog the spaces.

Bartells[13] thinks the probable cause of glaucoma lies in disturbed anterior ciliary venous circulation, and that it can occur in the absence of obstruction of the filtration angle.

The symptoms and course are similar to acute glaucoma and need not be entered into here.

Therapy. The medicinal treatment is by pilocarpin and eserin locally, free purging by salines.

The surgical treatment should be adapted to the conditions present, among which are paracentesis of the cornea, anterior sclerotomy supplemented by posterior sclerotomy, and iridectomy in suitable cases.

Above all is the prophylactic treatment, the proper technique in the toilette of the anterior chamber, and selection of the proper operation for the cases, the ideal operation being removal of the anterior capsule for extraction, and expression of the lens in its capsule.

In the days in which I was doing cataract extraction without an iridectomy I had several cases of glaucoma following such operations, all of which fortunately were relieved by myotics or by iridectomy. In several instances in which I have made, perhaps, a too free discission of the lens, glaucoma has followed which necessitated immediate iridectomy.

LITERATURE.

1. Villard, *Ann. d'oculist.*, Oct., 1905.
2. Krienes, Festschr. z. 100 *Jahr. Stiftungsfeier d. Fr. Wm. Inst.*, Berlin, 1895.
3. Praun, l. c., p. 306.
4. Buchanan, *Ophthalmoscope*, Nov., 1907.
5. A. Peters, *Klin. Mon. f. Aug.*, ii, 1904.
6. Fuchs, *Arch. f. Ophth.*, Nov., 1909.
7. Moretti, *Ann. di ottal.*, Nos. 11-12, 1905.
8. Hoor, *Wien. Klin. Woch.*, No. 10, 1888.
9. Ferber, *Inaug. Diss.*, Berlin, 1887.
10. Garnier, *Vratsch*, No. 27, 1891.
11. Stoewer, *Klin. Mon. F. Aug.*, March-Apr., 1907.
12. Praun, l. c. p. 421.
13. Bartells, ref. Bulson.
14. Bulson, *Ophth. Record*, Nov., 1907.

(B) WOUND INFECTION IN INJURIES OF THE LIDS AND SOFT PARTS OF THE ORBIT.

Infection of the skin of the lids is not common, and considering the proportion of injuries and operative procedures thereon, heal well, the circulation being free and the nutrition plentiful.

Penetrating wounds of the orbital tissues, however, are apt to be-

come infected, causing orbital cellulitis and phlegmon, and if so give rise to serious disturbances, septicemia and pyemia, anthrax, glanders, and lyssa.

Erysipelas is common, and phlegmon occurs from infected lesions of the lids and orbital margins. Deeply penetrating wounds of the orbit may give rise to phlegmon, followed by meningitis, sinus thrombosis, encephalitis and exitus lethalis.

Abscess of the orbit or retrobulbar phlegmon also comes from entrance of foreign bodies, or secondary infection of the wound by the streptococcus or staphylococcus; or periostitis, caries or necrosis may occur, followed by infection of the orbit or surrounding nasal sinuses; and yet aseptic bodies have been retained therein for many years.

The clinical course begins with symptoms of septicemia, fever, pain, then come heavy local symptoms, exophthalmos and immovability of the globe, which differentiates it from a panophthalmitis beginning within the eye.

The exophthalmos is caused by many smaller collections of pus situated in the cellular fatty tissues and the ocular muscles, which accounts for the loss of ocular nutrition. This also accounts for those cases where deep incisions may not evacuate pus, yet the relief of the tension by the free bleeding thus produced gives much relief to the symptoms. When a large pus cavity forms it may push the globe to the opposite side and fluctuation be felt.

The principal danger of orbital cellulitis and phlegmon is from passage of the inflammation to the brain, causing meningitis and encephalitis, or a septic thrombus beginning in the ophthalmic vein and continuing to the carotid sinus. Such cases may likewise cause an optic neuritis with resultant optic nerve atrophy.

The Therapy consists in general antiphlogistic treatment, especially by quinin, antistreptococcic serum injections, retrobulbar injections of 1:5000 mercurial sublimate or oxycyanide, free and early incisions to relieve the chemosis and aid the pointing of the pus cavities, hot compresses, 5 per cent. phenol injections at margins of inflamed areas in erysipelas. Where fluctuation is felt, deep incisions and gauze or tube drainage may be established. In only exceptional instances may it be advisable to enucleate a panophthalmitic eye attended by orbital cellulitis.

Tetanus may develop from injuries to the orbit, especially with retention of foreign bodies, from contused and lacerated wounds of the lids or even from retention of a foreign body in the conjunctival sac, as reported by Praun.[1] The Therapy is antitetanic serum and chloral.

Ramsay[2] reports a woman who had a suppurating wound of the

external canthus, inflicted four days previously by a walking stick. Stiffness of the lower jaw began three days after admission, and four days later the stiffness was so great as to excite suspicion of tetanus. The following day the trapezius became involved. Bacteriologic examination of the discharges from the wound showed tetanus bacilli in large numbers. Injection of antitetanic serum was begun at once. Laryngeal spasm set in, and, in addition to the serum, chloral was prescribed in large doses. Gradual improvement took place. She was discharged as cured fifty days after the beginning of the treatment. The serum was administered seven times, a total of 150 cubic centimeters being injected. Three thousand grains of chloral was given during this time to secure rest and sleep. Special attention was given to the nourishment of the patient and the bowels were kept active.

The occurrence of a minor wound of the lids may be the starting point for infection by syphilis. As reported by Marlow[3-4] in 1880 and many authors since, the last case up to present writing being by Ellett.[5]

LITERATURE.

1. Praun, l. c. p. 106.
2. A. Maitland Ramsay, *Ophthamoscope*, Nov., 1905.
3. Marlow, (a) *Amer. Journ. Ophth.*, May, 1890, (b) *Ophth. Record*, March, 1894.
4. Würdemann, *Trans. Wis. State Med. Soc.*, 1891.
5. Ellett, *Ophth. Record*, June, 1899.

(C) SURGICAL DISEASES FOLLOWING ORBITAL AND LID INJURIES.

Aside from the infections, the blood vessels and the orbital walls may acquire certain surgical affections following an injury. After some contusions gangrene of the lids may occur, after blows upon the bony parts, periostitis, osteitis, caries, and necrosis. After injuries to the blood vessels an aneurysm may develop in the orbit, causing pulsating exophthalmos. Praun[1] says aneurysms of the retina may likewise develop from blows upon the orbit. Emphysema of the orbit and lids may be seen after fracture of the ethmoids, causing air to enter the tissues.

(D) TUMOR FORMATION AFTER INJURIES.

The development of tumors, more particularly epithelioma, sarcoma, and carcinoma, after contusion of the part has been recognized for ages. Even yet, however, we do not know the reason therefor unless the attractive theory of Cohnheim is substantiated. By this theory a trauma releases and sets to growing slumbering embryonal elements and these grow into a mass which we call tumor. Laboratory and clinical experiments have not yet proven this theory. Be this as it may, many patients with tumors remember a previous accidental injury to which they as-

cribe the development of the disease. I have had a number of such in my own experience, among which are the following:

A woman with a circumscribed, round leuco-sarcoma of the chorioid[1a] ascribed the inception of the growth to an injury by a lead pencil point. The eye was enucleated, no recurrence in ten years.

A man with a large epithelioma of the lower lid and nose ascribed his trouble to the irritation of an ill-fitting pair of eyeglasses. Plastic operation and subsequent X-ray treatment with no recurrence in five years.

A man with a carcinoma of the orbit was struck by a wagon shaft on the temporal edge of the orbit where the tumor first began. Exenteration of the orbit with X-ray treatment, no recurrence in nine years.[1b]

LITERATURE.

1. Würdemann, (a) *Ann. Ophth.*, (b) *Trans. Sec. Ophth. A. M. A.*, 1906.

(E) TRAUMATIC NEUROSES.

These are observed after injuries to the eyes as after other bodily injuries, but with the exception of so-called hysterical blindness and changes in the visual field are less often seen. It is difficult to distinguish between hypochondria, hysteria and actual malingering in cases which appear and claim damages at law following alleged accident. (See Malingering.)

Following erosions and small wounds of the cornea severe pain lasting for weeks or months may be complained of in the seat of the scar called by v. Arlt[1] and by Fuchs[2] keratalgia and cicatrix dolorosa. Brailey[3] considers the symptoms to be hysteric. Grandclement[4] and Markwort[5] think that this symptom is due to bacteria remaining in the depths of the tissues, and my experience agrees with this, for following the suggestions of Bronner[6] and Nettleship,[7] I have either excised the scar or used the galvano-cautery in these cases, with happy results, and in one case under consideration, in a neurasthenic school teacher, found mycosis.

Ciliary neuralgia may be due to the development of a small neuroma in the wounded ciliary nerves or be reflex from an impacted iris. An example of the former is seen in those eyes which cause sympathetic irritation and of the latter in prolapse of the iris. Eversbusch[8] saw it after a wound from a needle, White-Cooper[9] from a leucomatous cicatrix. The irritation may cause clonic and tonic reflex spasms as in Beer's[10] case where, after a wound from a sewing needle in the ciliary region, convulsive rolling of the eyeballs with trismus and tetanus occurred, the attacks lasting one and a half to two days.

Of special importance is hysteric blindness, of which I have seen six true cases in which there was total blindness. In all of these there was

a local exciting defect or trauma which caused accommodative cramp and pain, the impression remaining so vividly that the patients forcibly closed their eyes, resulting in blepharospasm, lost their will to open them and finally failed to recognize objects by sight, although in no case was there an actual permanent lesion. Every one of these was cured by suggestive therapeutics, combined with visual training, within a few hours, even though the blindness had lasted for days and in one instance for nearly a year.

Holden[11] says that the ocular symptoms of traumatic neurasthenia and hysteria do not differ particularly from those of the non-traumatic varieties. He gives the following: "The cornea and conjunctiva may be anesthetic or hyperesthetic; the eye muscles relaxed from fatigue, or be in a state of spasmodic contracture; the visual perceptive apparatus may show fatigue, while there may be also psychical perversions of visual perceptions.

Subjective complaints are mostly of pain and paresthesia in various parts of the head after using the eyes, of spots before the eyes, of apparent increase or decrease in size of objects seen, blurred vision after close work dependent upon fatigue of the muscles of accommodation, doubling of print due to inability to maintain convergence, and of fluttering and confusion of print on account of abnormal duration of after-images in the fatigued retinas.

A fine tremor of the lids is always noticeable when they are gently closed. There may be lacrimation without inflammation, and photophobia causing drooping of the upper lids; this droop occurs also as a symptom of fatigue as the examination proceeds. The patient not only may fail to raise the lid when directed to do so, but may also forcibly resist the examiner's effort to raise the lid with his finger.

Reflex closure of the lids when the cornea or conjunctiva is touched is frequently slow or wanting, indicating anesthesia of these parts; and this anesthesia is likely to be more pronounced in the eye having the more marked disturbances of vision on the side corresponding to a general hemianesthesia.

The pupil is usually normal in size and in reaction, although in cases of hysterical blindness it may be large and unresponsive.

The extraocular muscles often exhibit a lack of balance and particularly a varying latent divergence of exophoria, which may be regarded as a sign of fatigue from convergence. Again, a spasm of any of these muscles may give rise to diplopia, which might suggest an actual paralysis, but the anomalous behavior of the double images in different directions of the gaze, and the presence of corroborative symptoms, lead us to the diagnosis of a purely functional disturbance.

Diplopia of another sort and of a purely physical nature is absolutely

characteristic of hysteria, and is a very valuable diagnostic sign when it exists. This is uniocular diplopia. With one eye closed the patient sees a light double, when it is carried a certain distance away from the eye, and when asked to count fingers he sees double the number presented.

The acuteness of vision is usually normal, but the patient usually reads the distant letters slowly, and with an effort, and only after considerable urging. There may be even more difficulty is reading print near by, and the patient will hold the test-card close to his face, or far away or to one side, assuming cramped positions, and even repeated urging may not make him read the smallest print. But if an indifferent glass, plain, smoked, or weakly refracting, is held before the eye the psychical effort is such that both distant and near vision at once become normal, or as nearly normal as the patient's refractive condition will permit.

In rarer cases vision in one eye is very poor or the patient may be unable to see at all. But if we employ any of the tests for detecting simulated blindness, which consists in arranging lenses, prisms or colored glasses in such a manner that the patient uses the eye with supposed poor vision while believing that he is using only the eye with good vision—we find that the sight of the poor eye is in fact normal.

For the still rarer cases in which there is apparent blindness in both eyes we have no test to reveal the actual amount of vision, but the diagnosis can usually be made from the presence of other hysterical symptoms, the previous history of aphonia and the like, and the lack of organic changes in the eyes. The patient, however, finds it too difficult to maintain this fiction long, and usually the vision which was lost suddenly, after a few days as suddenly returns.

Anomalies of the visual fields are the most frequent and the most characteristic eye disturbances in neurasthenia and hysteria. The typical condition, if the examination is made deftly without over-fatiguing the patient, is a normal field for the usual white test object, a concentric contraction of the color fields in their regular order, and a diminution of central color perception in that a small area of color is not recognized as far away as by the normal eye. These anomalies of color perception are to be regarded as evidences of fatigue of the retina or of the psychical centers, or of both. If the examination is tediously made or purposely long-continued, evidence of increased fatigue is manifest in further narrowing of the fields, giving them the watch-spring or spiral type. That is, if the limits of the field are plotted a number of times continuously, the boundary line recorded will be a diminishing spiral.

Besides the typical concentric contraction of the color fields in their regular sequence, there is occasionally a reversal of their sequence, the field for red being larger than that for blue, and occasionally a contrac-

tion of the field for white. But rarely is there a central defect in the field or a defect of a hemianopic type. The contraction of the field is often more pronounced in the eye of the side which is more anesthetic. Size of fields varies from day to day; forms of color fields are bizarre. These functional eye disturbances are not only common to young women, but most marked and persistent disturbances are found in strong men with hysteria following injury or nervous shock."

Wolffberg[12] says a field taken in ordinary daylight, which, in its limits for white and colors, corresponds to those obtained with a normal eye in diminished illumination, is typical of diminished excitability of the neuroptic apparatus and of abnormal fatigue, thus of traumatic neurosis.

Traumatic neurosis consists in an abnormal fatigue not of the retina but of the neuroptic apparatus, including its cerebral centers. The fatigue found in the field as a whole also exists for the macula and is shown by the condition of quantitative perception of color.

Henderson[13] recognizes two forms, one simulated amaurosis, and the other true amaurosis, hysterical in origin. In the former the patient sees and knows that he sees; in the latter the patient does not see, if he does, he is not conscious of it.

Bocci[14] remarks that amblyopia is comparatively frequent, while total bilateral amaurosis is extremely rare. It is liable to occur in persons debilitated from any cause, and even in previously robust subjects.

A thin little woman weighing about 90 pounds, whose husband was a big over-bearing fellow, weighing about 225 pounds, was brought to me with her eyes bandaged, and in addition a couple of heavy veils swathed about her head, with the history that early before she had been driving with her husband and got dust in her eyes, followed by some inflammation; whereupon she took to her room and bed, had it kept dark and had her head and eyes bandaged for all that time. The entrance of light into her room gave her agony, even though the eyes were occluded. The demeanor and walk of the patient were characteristic. After persuasion failed to allow of an examination, my command to open her eyes in the dark room was obeyed and then the reflected light from the ophthalmoscopic mirror was used as a therapeutic treatment, followed by rather strong faradic applications. She was then told that she could see and each time recognized the objects; after about an hour of suggestion could read small print, recognize all colors, and by the Snellen letter test V. = full 6/vi.

Herderson[13] reported the case of a healthy man who was suddenly stricken with blindness in both eyes. The history obtained of the man's temperament and actions placed him in the hysterical class. He sat with fixed, staring gaze, and would not look toward any one ad-

dressing him, nor would he look toward his own hand when held in front of his face. His actions all betokened simulation, and the progress of the case bore this out. He finally recovered when he found it more convenient to bear with the restrictions and privations which were imposed upon him than to pursue his vocation of railroading.

Westphal[15] reports a case of traumatic hysteria, presenting the aspect of ophthalmoplegia exterior. A miner, aged 46, suffered from traumatic neurosis after an injury of his head. He was depressed, hypochondriac, discouraged, bad headache, vertigo (objectively and subjectively), tachycardia, increase of mechanical, muscular and vasomotor irritability, tremor and shaking of the whole body following psychical irritations and influencing his gait. The first impression conveyed by the motor disturbances of the eyes was a complete bilateral ophthalmoplegia (not affecting the levator and iris muscles). On close examination this bilateral external ophthalmoplegia was not constant, but disappeared partially or totally by diverting the attention of the patient from his condition. This could be especially observed in monocular fixation or during ophthalmoscopic examination. The affection was psychical and the mobility or immobility of the eyes depended on psychogenous influences of which the distraction of attention was the most important. The changeable, apparently lawless aspect of the paralysis, full of contradictory symptoms, is explained by the assumption of an hysterical functional disturbance of the ocular muscles. The rapid change of total immobility and of the possibility of moving the eyes, especially the jerking movements, suggested conditions of contractures in the ocular muscles, which the author found in former observations characteristic of hysteria. Westphal considers in this case psychical disturbances of innervation dependent on attention, as the cause of these abnormal conditions of mobility (contractures) of the exterior ocular muscles.

Gaupillat and Regnault[16] report a case of a young soldier at Saint Cyr, who was struck in the inner angle of the eye by a bayonet while fencing, making a very slight tear of the conjunctiva. Patient was much depressed, fearing loss of sight; eye immovable; pupil dilated; accommodation absent; ophthaloscopic examination negative; light perception only. All unfavorable symptoms passed away and the question arose as to whether hysteria was the factor to the symptoms.

LITERATURE.

1. von Arlt, *Ueber Verletzungen des Auges*, Wien, 1875.
2. Fuchs, *Arch. F. Aug.*, xl, 4, p. 272.
3. Brailey, *Ophth. Rev.*, July, 1889.
4. Grand-Clement, *Arch. d'opht*, viii, p. 257.
5. Markwort, *Arch. f. Aug.*, xxi, 1, p. 153.
6. Bronner, *Ophth. Rev.*, July, 1889.
7. Nettleship, *Ophth. Rev.*, July, 1889.
8. Eversbusch, *Munch. Med. Woch.*, 1890, p. 901.

9. White-Cooper, *Injuries of the Eye.*
10. Beer, ref. Praun, l. c. p. 109.
11. Ward Holden, *Med. News,* July 30, 1904.
12. Wolffberg, *Arch. Ophth.,* Nov., 1904.
13. Henderson, *Ann. Ophth.,* July, 1906.
14. Bocci, *La clin. oculist.,* Apr., 1904.
15. Westphal, *Deut. Med. Woch.,* No. 22, 1905.
16. Guapillat and Regnault, *La clin. oculist.,* Feb. 25, 1908.

(F) PSYCHOSES.

Outbreaks of mania and production of insanity are occasionally observed after surgical operations, especially those upon the head and eyes. These psychoses are usually hallucinations and due to worry and are largely in chronic alcoholics, or due to somatic diseases, or perhaps in some cases to the systemic effects of atropin.

Post-operative mania after cataract extraction is not so uncommon. I have had a number of such experiences.

A man of 78 years, from whom I had successfully extracted a cataract from one eye was operated upon a few months later in the other. Bearing in mind my experience of his developing irritability and hallucinations, his clothes were removed from his room and he was supposed to be carefully watched, but despite that fact, he made a rope out of his sheets, climbed out of the second story window at two o'clock in the morning, and when I was called found him in his night clothes several blocks from the hospital sitting on the curbing with several nurses around him. He insisted on going to the depot to catch an early train "to go fishing," and was with great difficulty persuaded to go back to the hospital. He recovered in a few days from the hallucinations.

Another old man, from whom I had successfully removed cataract, the second night after the operation developed mania which lasted a few days. He imagined himself to be dead and in his coffin. Recovery ensued in a few days.

A very large, powerful man, from whom I had also successfully removed cataract, on the fifth day was sitting in his room fully dressed, and on my refusal to allow him to leave the hospital that day became violently enraged, and shortly after my departure tore off his bandage and left the hospital, and being called to a hotel that afternoon I found him in great pain from having burst open the eye, which he had likewise infected and which was later lost from panophthalmitis. It took large doses of sedative for several days to quiet him and relieve the acute mania.

While but few cases of psychoses due to ocular accidents have been reported, yet the etiology is similar, and occurs from the fretting and worry of the patient over the pain, other symptoms and especially as to the ultimate outcome of the injury, the loss of time and money

and the necessary confinement. The long waiting for a cataract to ripen, with the gradual loss of vision and the doubts as to the favorable outcome (in the patient's mind), together with the introspection common to the aged are wanting in the usual run of ocular injuries which generally occur in younger and non-neuropathic individuals.

Fabian[1] saw an outbreak of suicidal mania and kleptomania in a man 40 years old, with hereditary predisposition towards insanity, with perforating wound of the sclera and prolapse of iris.

Szumann[2] in a 37 year old, nervous, irritable, easily flustrated and willful woman, with cicatricial healed ulcer of the cornea and long period of pain, saw symptoms of dementia acuta, and mental failure, but recovery ensued in a few months.

Nägeli[3] saw hallucinations of vision in a case of burn of the cornea.

H. B. Young[4] reports a man, aged 48, of nervous temperament, who was successfully operated upon with the giant magnet for a piece of steel in his eye. His recovery was satisfactory. Five weeks after the injury he became wildly excited along religious lines, and recalling the scriptural injunction "If your right eye offend you, pluck it out," etc., would have obeyed had he not been forcibly prevented. He then became maniacal and violent, and was sent to a hospital and died in six days.

Suicide after accidents to the eye has not been noted to my knowledge, however, psychoses may arise from unfavorable prognosis, from the fear of incapacity, from blindness, and from the worry incident to the waiting for an operation; a number of instances having occurred in my own practice. Therefore it behooves the physician to be careful in expressing an unfavorable prognosis directly to the patient.

Some twenty years ago a man received an unfavorable prognosis from me on account of optic nerve atrophy from brain tumor; he left my consulting room and fifteen minutes later dropped into the Milwaukee river, his body being found some days afterwards.

An old man being prepared for cataract operation threw himself over the balustrade of a stair-case in a hospital, falling five stories to immediate death.

A man who had acute mastoiditis endeavored to commit suicide, the day before operation, by cutting his throat. He was taken to the hospital, and while arrangements were being made for the operation tore himself away from the custody of two strong nurses, and went out of a fourth floor window of the hospital, jumping through and breaking the closed glass of the window. He was picked up from the pavement below, dead.

An assistant professor in a state university found out my prognosis of further loss of vision from detachment of the retina due to malignant

myopia. He went to a hotel; took a poisonous dose of morphine; turned on the gas; and then shot himself through the head.

LITERATURE.

1. Fabian, *Inaug. Diss.*, Koenigsberg, 1893.
2. Szumann, *Münch. Med. Woch.*, 1, 1897.
3. Nägeli, Sitzungsber. d. *Münch. Acad. d. Wissensch.*, I, p. 503.
4. H. B. Young, *Ophth. Record*, Sept., 1906.

(G) ERRORS OF REFRACTION PRODUCED BY TRAUMA.

Pressure behind the globe, in the case of traumatic exophthalmos and alterations in the orbital walls from fracture, may produce shortening of the optic axis and hyperopia or irregular pressure astigmia.

Leplat[1] reports three cases of contusion of the globe in which a transient hyperopia with a deepening of the anterior chamber existed. In these cases it seems logical to him to believe that the flattening of the crystalline lens forces an increased amount of fluid into the anterior chamber.

Hyperopia and astigmia have been produced from pressure from behind the eyeball.

Luxation of the lens into the vitreous produces hyperopic astigmia if partial, and hyperopia if complete, if the lens remains clear. In Andrew's[2] case of a stone-bruise there was one-half (each system) hyperopia produced.

Myopic eyes are predisposed to detachment of the retina and intra-ocular hemorrhages from the weakness of their walls, a slight, direct blow, or the effects of contre coup, being more apt to cause injury than in the case of emmetropic or hyperopic eyes. Temporary myopia from spasm of the accommodation and miosis traumatica may occur. Myopia likewise occurs in commotio retinæ, the cause in each case being perhaps the complete filling of the bloodvessels or bleeding into the ciliary muscle which causes the cramp. These cases are usually acute and disappear after a few days' use of atropin.

A. Maitland Ramsey[3] reports the presence of a low degree of transitory myopia in four of the five cases described, and which disappeared when the injured eye was removed. It seemed to afford confirmation of the diagnosis of impending sympathetic inflammation. In some of these cases this was probably due to spasm; but in one case when it persisted under atropin, it could be explained only by supposing that the congestive changes brought about an altered state of the media whereby the refractive index was increased.

Szili[4] found myopia of —2.00 D. one month after contusion of an eye by a nail. In two days' use of atropin and rest the eye became emmetropic.

Deschamps[5] states that subconjunctival injections, no matter

what the fluid, set up an active irritation, and when repeated result in union of the conjunctiva with the sclera, the conjunctival mucosa ceasing to be mobile on the globe surface and becoming practically cicatricial, causing a modification of the conjunctiva in the corneal region due to contraction and a change in the corneal curve. One of the first cases to attract Deschamps' attention was in a patient with corneal ulcer, who had been treated with a series of subconjunctival injections—a complete cure following. Patient had been examined several months previously as to his refraction, and then there was found hyperopia, 0.50 D. After the injections there was a hypermetropia of 2 D. This was of great inconvenience to the man, for now anisometropia existed and an asthenopia resulted from the difference in accommodative efforts of each eye. After a series of observations, Deschamps became convinced that the cornea was drawn upon by the conjunctival retraction and by the partial adhesion between sclera and conjunctiva, the hyperopia resulting.

A second case, with both eyes emmetropic, as shown by a careful examination with ophthalmometer and by retinoscopy, was wounded in one eye by a large piece of iron, which penetrated the globe but was extracted by electro-magnet. Unfortunately, in the fellow eye sympathetic ophthalmia developed, and it became necessary to enucleate the injured eye and employ active treatment of the sympathizing organ, subconjunctival injections of cyanid of mercury being given, though not more than four—two in the region of the superior rectus and two in the region of the inferior rectus—and though this arrested the sympathetic trouble, the patient developed an astigmatism of nearly 2 D. against the rule—the correcting glass making V. normal, while without it V. was notably lessened. Guided by these observations, Deschamps has considered as to the treatment of slight regular astigmatism by the method of subconjunctival injections, and, while his experience is not great, his results are encouraging. The cases chosen were of regular astigmatism, axis vertical; and Deschamps made, as a minimum, four injections, two above and two below the cornea, as a maximum, eight injections. The amount used at each injection was five or six drops, but this may be reduced if the action is to be limited, and at the third injection not more than two drops may be needed. At first cyanid of mercury (1/5000) was tried, but, this proving painful, a 4 per cent. sodium chlorid solution was employed, which is not very painful.

V. Grolmann[6] saw —3.00 D. myopia and cyclitis follow contusion from a large piece of metal, and in which the myopia persisted for 9½ months, but was restored to emmetropia by atropin.

Dislocation of the lens forward produces a temporary myopia from stretching of the zonula, interfering with its elasticity, and of the ciliary muscle fibres. If the dislocation be complete into the anterior chamber

the myopia is permanent and caused by the lengthened posterior focus; if partial, accompanied by tilting of one edge of the lens into the vitreous, or forwards into the anterior chamber, lenticular astigmia is produced.

Schiess[7] saw a man who had been hit in the eye by a large cork three weeks before, who came with M. —4.25 D. which in five weeks more became —4.75 D. Five months afterwards under use of atropin the myopia was reduced to —.75 D.

In Rampoldi's case[8] of subluxation of a clear lens in a previously emmetropic eye, the anterior surface of the lens touched the cornea; myopia of 4 to 5 D. was produced, the patient having full visual acuity with correction.

Bourgeois[9] reports three cases of traumatic myopia, which differ from the usual examples of this class of disease because of their chronic condition. He discusses the forward form of displacement of the lens with the mechanism causing the same, and believes that not enough attention has been paid to the aqueous humor as a causative factor. He says, because of the suddenness of the accident, the aqueous humor cannot escape by its natural route, and hence its only other channel would be in the posterior chamber or in perilenticular space, where it exerts a certain force in advancing the lens and changing the curvature of the lens body.

In the chronic cases the zonula is unable to retract the lens, and the imprisoned aqueous keeps the lens pushed forward, causing increase of the lens power from lengthening of the posterior focus.

The beginnings of traumatic cataract from contusion are characterized by swelling of the lens and temporary increase or production of myopia.

The effects of wounds of the cornea in the healing by scar tissue may leave regular astigmatism if the wound be clean cut as in the astigmatism after cataract and glaucoma operations, or if the healing be attended by much loss of tissue, as following ulcerations, irregular astigmatism is produced. Occurrences of this sort are too common to render examples necessary.

LITERATURE.

1. Leplat, ref. Bourgeois.
2. Andrews, *Brit. Med. Journ.*, Dec. 30, 1882.
3. A. Maitland Ramsay, *Ophth. Rev.*, Jan., 1906.
4. Szili, *Arch. f. Aug.*, No. 1, xiii.
5. Deschamps, *La clin. opht.*, May 25, 1905.
6. von Grolmann, *Monatschr. f. Unfallheilk.*, No. 6, 1896.
7. Schiess, *Klin. Mon. f. Aug.*, 1881, p. 384.
8. Rampoldi, ref. Praun, p. 333.
9. Bourgeois, *Ann. d'oculist.*, Oct., 1904.

CHAPTER VI.

OPERATIVE INJURIES.

A. Abrasion of the cornea—Tearing of Conjunctiva—B. Cataract operation accidents and injuries—Loss of vitreous—Infection—Statistics of results obtained—Collapse of cornea—Detachment of retina and chorioid—Literature—C. Propulsive hemorrhage after cataract operation and iridectomy—Hemorrhagic glaucoma—Literature.—D. Disturbances in healing—Keratitis bullosa—Keratitis striata—Kerato-iritis—Delayed union—Astigmia—Literature. E. Kyanopia—Literature. F. Other operative accidents and dangers—Operation for high myopia—Injury to the lens in iridectomy—Subconjunctival injections—Cautery—Operations on nose and sinuses—Fracture of inner wall of the orbit—Paraffin injections about eye or nose—Spinal anesthesia—Portions of instruments or threads broken off or left in wound—Miscellaneous accidents—Literature.

INJURIES TO THE EYES OCCURRING DURING OR AS THE SEQUELAE OF OCULAR AND OTHER OPERATIONS.

During the last decade or two the lesson that truth will prevail has been thoroughly learned by medical writers, and we have had many truthful accounts of untoward accidents and complications, occurring from operations. Surgeons now no longer confine their reports of cases to the successful ones, but, fortunately for the advance of our art, have little hesitancy in also reporting their failures, thus recognizing the didactic value of the publication of cases complicated by contrary or unlooked for results.

a. Abrasions.

It quite frequently happens that the c o r n e a i s a b r a d e d by the anesthetist in testing the lid closure reflex by the finger during the giving of an anesthetic, or a drop of ether or chloroform may enter the eyes and give rise to irritation. The lethargy induced by the anesthetic, for twenty-four hours afterwards, as a rule does not permit of much complaint from this source from patients, and by that time restoration of epithelium has usually occurred. Occasionally, however, the oculist is called to see such a patient. Only the other day I was sent for to prescribe for such a condition in a young man who had broken his leg that morning and who had already quite recovered from the anesthetic. Dessication of the corneal epithelium from drying and strong cocain solutions is common. A boric acid wash or sedative collyrium is all that is usually indicated.

In old patients the conjunctiva may be very friable and tear on fixation by forceps. This event, however, is of little moment as repair always and speedily ensues. Occasionally also instrumental injury of the cornea occurs.

(B) CATARACT OPERATION ACCIDENTS AND INJURIES.

Naturally, as we consider the cataract operation to be the summum bonum of our work, the majority of these reports refer to the accidents and dangers of this operation.

I have several times been called to finish a cataract operation after some tyro had incised the cornea and could not deliver the lens; fortunately for the patient, in each instance the fear of loss of the eye prevented very rough handling and brought the call for assistance.

In a number of instances I have obtained the history of such an attempt at extraction, which had been given up after incision and trial at delivery, in which I have subsequently extracted the cataract.

In one such instance, however, the attempt at extraction was disastrous, in that an iritis followed, with subsequent closure of the pupil and resultant glaucoma, for which I had ultimately to enucleate the globe.

de Schweinitz[1] gives the following accidents that may occur during the performance of a cataract extraction:

"1. The knife may be introduced with the cutting-edge turned in the wrong direction. If this somewhat inexcusable mistake should occur, the knife must be withdrawn and inserted properly. If this cannot be done, owing to the escape of the aqueous, postponement of the operation until the anterior chamber is refilled is necessary.

2. The conjunctiva in the neighborhood of the counter-puncture may become distended with aqueous humor. This produces an elevation resembling a bleb. The section should be completed as if the accident had not happened.

3. The iris may fall before the knife. The incision should be completed in the ordinary way. An irregular coloboma will result, which may be remedied by seizing the jagged edges with the iris forceps and trimming them with the scissors.

4. Free hemorrhage may occur if a conjunctival flap is made or in performing the iridectomy. Under pressure the bleeding will sometimes cease, and the operator should then endeavor to get rid of the blood in the manner already described. If success does not follow the maneuver, the cystotome must be introduced, even though everything is obscured by the blood, the capsule lacerated, and the lens expelled. During its expulsion sufficient blood will often come away to clear the pupillary space.

5. The wound may be too small. This is a very unfortunate oc-

currence, and can be remedied only by enlarging the incision, which is best done with a small pair of probe-pointed scissors.

6. Undue pressure of the cystotome may cause the lens to be partially or completely dislocated. If the dislocation is partial, the eyes should be closed and gentle pressure should be made with a bandage, when the lens probably will right itself and can be delivered. If the dislocation is complete and the lens slips back into the vitreous, it must be removed by means of the scoop or wire loop.

7. The vitreous may escape before or after the expulsion of the lens. If before the expulsion of the lens, the operator should at once remove the cataract with the wire loop, which is gently inserted behind the lens. At the same time all pressure upon the eye must be removed. If vitreous escapes after the lens has been extracted, the wound should be cleared of protruding vitreous as gently and rapidly as possible and a bandage applied. Although escape of vitreous is an undesirable accident, its consequences are not always serious and good visual results may be obtained. If the escape of vitreous has been great, particularly if the vitreous is thin and there is tendency for the eyeball to collapse, a tepid, sterile, physiologic salt solution should be injected into the vitreous chamber until the globe assumes its proper contour, as has been recommended by J. A. Andrews and Herman Knapp.

8. Occasionally the corneal flap is everted because it has been caught by the margin of the lid, owing to a sudden movement of the patient. It must be replaced and a bandage quickly applied. Sometimes immediately at the conclusion of the section, or directly after the delivery of the lens, especially in old and feeble subjects, there is great collapse of the cornea, which, instead of keeping its proper curve, looks like a wrinkled membrane. Under these circumstances the anterior chamber should be filled with physiologic salt solution, which will not only aid in making proper coaptation of the lips of the wound, but will prevent the sucking in of the conjunctival juices which might lead to infection.

9. Capsulotomy may not have been sufficient and pressure upon the inferior half of the cornea fails to cause the lens to present. In such a case the cystotome must be reintroduced and the laceration enlarged, or if the obstruction is due to the presence of a tenacious center in the capsule, this may be removed with capsule forceps."

The complete extrusion of the lens in its capsule after incision of the cornea, particularly in hypermature cataracts, is an event that has happened to every surgeon of experience. In one such case immediately after incision the lens popped out with such force, together with a quantity of vitreous, that it passed over the patient's head, falling on the floor of the operating room. Bungling op-

erators or unskilled assistants have occasionally spoiled what would otherwise have been a most successful operation, and have prevented the return of sight to the patient by unskillful manipulation, as when the assistant's thumb or finger slips, striking the eye and causing a rupture of the lamina vitrea with extensive loss of vitreous. Such has unfortunately been my experience on several occasions. Claiborne[2] refers to such a case.

References have been made to the infection of the eye by the patient's fingers, after successful operation. I have seen a number of such unfortunate cases, and others in which the wound has only been broken open and more or less loss of vitreous and prolapse of the iris thereby caused. It is to be noted that most such cases, in my experience, have happened either as a result of post-operative mania, intoxication from atropin, or feeble-mindedness.

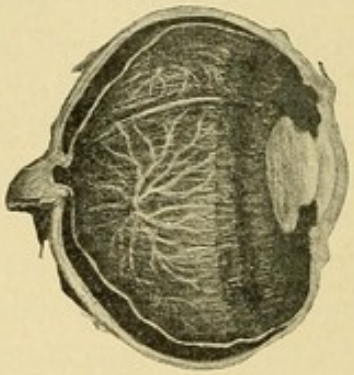

Fig. 36.
Traumatic cataract with secondary glaucoma, following unskilled attempt at cataract extraction.

Our Indian confreres and their visitors state that very often these East Indian subjects will remove the bandage shortly after operation, and in a few instances, no doubt, break open the eye or infect it.

It has been already noted that careful eye surgeons no longer infect patients, and thus lose by suppuration the eyes that have been cut—for the loss from cataract operation is now less than ½ per cent., compared to the 5 or 10 per cent. of the early operators, and this small percentage is probably in most cases of endogenous origin.

Regarding the loss of vitreous Theobald[3] states that there can be little question that appreciably better results are obtained at the present time from cataract extraction than thirty years ago, and much better than fifty years ago. During the first half of the last century the most skillful surgeons were content if their failures did not exceed 12 per cent. During the two decades following introduction of von Graefe's operation there was a definite improvement in the results secured, though 8

to 10 per cent. of failures were not uncommon. At present an excess of 4 or 5 per cent. in failures would be considered a poor showing. In a compilation of the results of over 2,000 extractions by well-known ophthalmic surgeons of this country and Europe, made by Ring in 1895, the percentage of failures was estimated at 3.87; a similar result is given in about 200 cases operated by Theobald.

The causes for the better showing, as compared with fifty years ago, are given as (1) the improvement in method introduced by von Graefe; (2) the use of cocain; (3) the application of the principles of antiseptic surgery; (4) skillful nursing; (5) improved hospital facilities; (6) provision against post-operative accidents afforded by contrivances such as protective shields; and (7) the more definite specialization of eye surgery.

In view of these many factors tending to promote success in cataract extractions, the pertinent question suggests itself: Why do we not obtain still better results? Why should there be a failure in every twenty or twenty-five operations for cataract? Why should there be, in addition to these failures, 6 or 7 per cent. of only partial success—in cases in which vision less than one-tenth is secured?

The answers are that, in spite of the most careful antiseptic precautions, about 2 per cent. of the eyes operated upon are lost by pyogenic infection; that a not inconsiderable proportion of cataractous eyes are unsound in other respects and, therefore, not capable of withstanding the shock of operation as they otherwise would; that, as cataract is peculiarly a disease of advanced life, the subjects of it are often not in the best condition for surgical procedures, 1 per cent. of them being glycosuric, 6 per cent. albuminuric, and a much larger proportion having atheromatous arteries; and, finally, that the temperment of the patient plays a not inconsiderable part in the outcome of every operation for cataract.

J. M. Ray[4] finds much diversity of opinion as to the effect and prognostic significance of this accident. In his experience, one of the most frequent causes is an improperly fitting or badly constructed speculum. Resort to a lid retractor, immediately after removal of the lens, would obviate it in many cases.

Loss of vitreous at operation adds to the danger of primary infection, irrespective of the quantity lost, but depending on the care used in the preparation of the field; while the danger of irido-cyclitis during the stage of healing is always greatly increased. Hyalitis with closure of the pupillary space is a frequent result of the cyclitis irritation. Floating opacities develop and may organize into bands which cause detachment in later years. Attention was called to the factor of intractability of the patient, and stress laid on the importance of a good speculum and the advantages of removing it at an early stage of the extraction operation.

The use of saline solution to restore normal tone and shape to the globe after loss of large amounts of vitreous has been advised. When the vitreous is fluid, loss seems to be less deleterious than otherwise, as the prolapsed portion does not separate the lips of the corneal section and there is no increased danger of infection of the wound.

The remote effects are always worse than the immediate sequelæ.

A small bead of vitreous may be snipped off with good results, but often there is repeated prolapse. This interferes with replacement of the iris, the removal of cortical remnants and the toilet of the anterior chamber and wound, and in this way, by preventing a complete and tidy operation, does the most mischief. It may even prevent extraction of the lens, due to its sinking into the deeper part of the eye when there is sudden prolapse of vitreous early in the operation.

Drake-Brockman[5] says the revival of the operation for extraction of cataract in its capsule (formerly known as Pagenstecher's operation), and the remarkably favorable results which have lately been reported by some operators, have led him to look more critically into the subject. He therefore, refers to his past record of cases extending over many years, dealt with in this manner, and has contrasted these results with an equal number of extractions by, firstly, the 3 mm. flap operation with iridectomy and, secondly, by the 3 mm. flap without iridectomy. The results are as follows:

1. Pagenstecher's operation.

Recoveries	Good vision	194	or 66.21 per cent
	Fair vision	83	or 28.32 per cent.
Failures		16	or 5.45 per cent.
Total		293	
Loss of vitreous		84	or 28.67 per cent.

2. 3 mm. Flap extraction with iridectomy.

Recoveries	Good vision	191	or 65.18 per cent.
	Fair vision	84	or 28.65 per cent.
Failures		18	or 6.81 per cent.
Total		293	
Loss of vitreous		17	or 5.80 per cent.

3. 3 mm. Flap extraction without iridectomy.

Recoveries	Good vision	220	or 65.08 per cent.
	Fair vision	60	or 20.81 per cent.
Failures		13	or 4.43 per cent.
Total		293	
Loss of vitreous		3	or 1.02 per cent.

Major Smith[6] has made over 20,000 expressions in the capsule. In his last report of 2,600 cases the loss of vitreous is given as 6 per cent. According to W. F. Ring,[7] in 3,400 extractions made by operators of note in this country and abroad, vitreous loss was 7.23 per cent., so that Major Smith's loss of vitreous was better than that obtained by the best operators in this country and Europe.

D. W. Greene[8] notes that the Pagenstechers record their experience in six hundred cases in which they extracted the lens in the capsule. They state that loss of vitreous was never a source of failure, even up to one-third of its volume, and only one case of detachment of the retina occurred in the six hundred extractions in the capsule. Loss of vitreous occurred in 5.2 per cent. of cases. In the 125 operations made by the writer he does not recall ever having lost normal vitreous.

R. Jamieson[9] says that extraction of the lens in the capsule is the ideal method. He is a pupil of Major Smith of Jullunder, "commencing as an absolute beginner at cataract extraction by any method," working under the personal supervision of Smith, he very modestly reports and comments upon 260 cases in which he did the intra-capsular operation, in which he has had the very remarkable result of 95.8 per cent. of successes. He had vitreous escape in 14 (5.1 per cent.)

Elschnig[10] reports that out of the 34 simple expressions the capsule ruptured in 5, in 3 the lens had to be extracted with the spoon, in 6 vitreous prolapsed, in 2 vitreous entered the anterior chamber after expression of the lens; i. e., prolapse of vitreous occurred in 17.6 per cent. rhexis of the hyaloid membrane in 23.5 per cent.

My own experience[11] is about 10 per cent. loss of vitreous in either extraction or expression. The loss is in no way dangerous, providing that not more than a bead up to 20 per cent. escapes.

Sirieys[12] says collapse of the sclera without loss of vitreous during the operation of cataract extraction is an accident not mentioned in the majority of recent works or in the encyclopedias. Terrien[13] gives a short note of two cases. Le Roux[14] gives the report of a case, and Sirieys details two cases in his paper, in both of which, just after completing the incision, the sclera was found to be collapsed, so that it was impossible to extract the lens by the ordinary pressure maneuver. In both the cases the loop was passed behind the cataract and thus delivered. There was in neither case any loss of vitreous, and both patients made a good recovery with useful vision.

Le Roux notes that while corneal collapse during cataract extraction is not infrequent, collapse of the sclera is rare.

The patient was 32 years old, myopic, antecedents normal and whose health has always been good. Operation of extraction May 11, 1907. Incision and iridectomy normal; during cystotomy, cornea became depressed and an air bubble entered the anterior chamber; no loss of vitreous; the whole eye was soft; the sclera became sunken and folded as if the eye contents had been expelled; cataract delivered by aid of curette. At first dressing it was found that the corneal wound had healed without iritic hernia and all trace of collapse gone.

Chodin[15] reported two similar cases.

O'Connor[16] reports a case of double senile hypermature cataract in a Filipino, about 60 years of age. Operation was done upon left eye first. Upon completion of corneal incision an unusually large amount of aqueous escaped and the eye collapsed to such an extent that the insertion of instruments for iridectomy and capsulotomy was very difficult.

The important, practical deduction from this theoretical consideration of the relation of the lips of the cataract incision is that pressure upon the eyeball should be carefully avoided after cataract extraction. Even harmful pressure cannot secure, or greatly assist, fixation of the eyeball.

Fuchs[17] seven years ago called attention to the fact that, following cataract extraction or excision of the iris, there could sometimes be noted a serous detachment of the chorioid, which was considered a great rarity. To see the detachment it was necessary to examine the eye with the ophthalmoscope the first few days following the operation. All eyes should be examined, the external appearance of which would lead to the supposition of a detached chorioid; that is to say, when the anterior chamber, already re-established, shows blood extravasation, or the margins of the wound without any visible opening, are swollen. The ophthalmoscopic examination shows detachment of the chorioid under the form of an obscure swelling, with smooth surface situated at the periphery of the fundus. Small detachments at the periphery and slightly prominent are difficult to see; large detachments projecting into the vitreous can be seen by simply illuminating the pupil with the ophthalmoscope. Retinal vessels rise with a marked curvature from the posterior margin of the detachment. From the detached retina, the detached chorioid is distinguished by its smooth surface, its brown color and by the absence of fluctuation; while detached retina is most frequently localized below, detached chorioid is found usually on the temporal or nasal side and only exceptionally above or below. The detachment of the chorioid diminishes gradually in size after a few days and finally disappears, and at the same time the anterior chamber becomes deeper and the bulbus, which was soft during the attachment, acquires normal tension. The prognosis is, therefore, good. Detached chorioid is rarely seen because the operated eyes are not examined with the ophthalmoscope until the patient is well, by which time the detachment has disappeared. The probable manner of the production of the detachment is as fdllows: During the operation it is easy to produce a small laceration of the ligamentum pectinatum, which covers superficially the ciliary body corresponding to the anterior chamber and the root of the iris. The aqueous humor then filters into the space under the chorioid, traversing the laceration on the side of the anterior chamber and pushing the chorioid towards the vitreous.

Blumenthal[18] reports a case in which the small yellowish, almost white, nucleus disappeared, upon pressure on the lower portion of the cornea, through the coloboma of the iris, backwards and he considered extraction by spoon too dangerous. There was no irritation for five days, when tension increased, chemosis and slight swelling of iris with one posterior synechia developed, which were treated with antiphlogistics. Six weeks after the operation the nucleus of 3 to 4 mm. diameter, was easily extracted with Pagenstecher's spoon, with moderate loss of liquefied vitreous. V. = 8/v with + 10.00.

Blumenthal believes that in hypermature cataracts with atrophy of the zonula the extraction of the nucleus immediately after cystotomy without attempt at expression with the spoon is preferable to the method of Pagenstecher, of extracting the lens within its capsule.

LITERATURE.

1. deSchweinitz, *Dis. of Eye,* 1910, p. 852.
2. Claiborne, *Ophthalmology,* July, 1910.
3. Theobald, *Am. Journ. Med. Scien.,* Jan., 1906.
4. J. M. Ray, *Journ. A. M. A.,* July 6, 1906.
5. Drake-Brockman, *Ophthalmoscope,* March, 1906.
6. Henry Smith, *The Cataract Operation,* Calcutta, 1910, and essays.
7. W. F. Ring, ref. Drake-Brockman.
8. D. W. Greene, *Lancet-Clinic,* June 12, 1909.
9. R. Jamieson, *Trans. Bombay Med. Cong.,* 1909.
10. Elschnig, *Arch. f. Aug.,* lxiii, 1909.
11. Würdemann (a) *Journ. A. M. A.,* (b) *Ophthalmology,* Oct., 1909.
12. Sirieys, *La clin. opht.,* Feb. 10, 1908.
13. Terrien, *Chirurg. d. l'oeil.*
14. Le Roux, *La clin. opht.,* Jan. 16, 1908.
15. Chodin, *Trans. St. Petersburg Med. Cong.,* 1893.
16. O'Connor, *Ophthalmology,* July, 1909.
17. Fuchs, *La clin. oculist.,* May, 1907.
18. Blumenthal, *Beitr. z. Aug.,* lxx., 1908.

(C) PROPULSIVE HEMORRHAGE AFTER EXTRACTION.

Blok[1] first saw a patient after her family physician had treated her for glaucoma with atropin. The left eye had been operated on 20 years previously for glaucoma and her vision was 5/xv after correction; the media were clear, a small excavation of the disc and a small typical narrowing of the field were present. Tension normal. Eserin and a broad iridectomy had the usual good results in the right eye. After clearing of the cornea the retina showed many hemorrhages, which slowly disappeared; a typical excavation remained. Six days after the operation the wound opened again without any apparent cause; little pain in and around the eye, radiating to the nose, pointed to a recurrence of the glaucoma. However, the eye became quiet, but vision was reduced to motions of the hand eccentrically to the temporal side.

The patient came back with a cataract in each eye, which had progressed so far in two years that she wished to be operated upon. Urine

normal; cornea normal; little arterio-sclerosis. She was now 75 years old. Previously eserin was instilled, and before the operation 1 per cent. cocain with adrenalin three times. Tension was, and remained normal, but directly after a normal section the cataractous lens presented itself and came out spontaneously, followed by vitreous. Direct removal of the speculum could not prevent the escape of the entirely normal vitreous, so that the eye was closed with a compress bandage. Patient complained of great pain in and around the eye, the bandage was colored red and patient vomited.

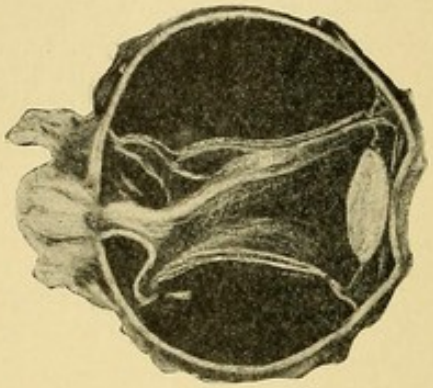

Fig. 37.
Subchorioidal hemorrhage after iridectomy.

Ice was used over the eye and in the mouth. Pulse was tense, quite fast and slightly irregular. After an hour the pain disappeared, the bleeding stopped and the pulse slowly became normal. Four hours later, changing the bandage, a big coagulum mixed with vitreous body protruded from the corneal wound. This being removed the wound closed. The bulb was then still full of blood. Tension not raised. The eye became atrophic, with total loss of vision.

Three weeks later, during the night, the patient became oppressed, coughed and expectorated a great deal of bright-red blood. This was repeated five days later. The cause of these two hemoptyses was evidently the same as of the propulsive hemorrhage, i. e., rupture of arteries under the influence of increased heart action and increased arterial pressure. The increased heart action during the operation was probably due to nervous influence, perhaps anxiety as regards pain. It is not clear if the adrenalin had any influence for good or evil. However, Blok thinks it is better in such cases not to use it. The strong vessel tonus caused by adrenalin may favor the bursting of brittle vessel walls under existing or provoked higher arterial tension.

I[2] have a similar experience to relate. After a perfectly successful and uneventful extraction of cataract in a woman, aged 65, the patient

was attacked the following night with violent sneezing and coughing, followed by vomiting. There did not seem to be any reason for this outbreak except that the patient remembered having had a similar attack some years before. In spite of all efforts on the part of the nurses and house surgeon to stop the emesis, it continued and was followed by complete extrusion of the vitreous through the sclero-corneal wound. Toward morning bleeding set in and the eye was totally lost. I do not see what influence adrenalin could have in the case detailed by Blok, nor how the bursting of brittle, intraocular vessels can be avoided unless the violence of the coughing, sneezing and vomiting can be limited.

Becker[3] reports a case of serious hemorrhage lasting four weeks resulting from the extraction of a senile cataract. The patient was a man 73 years of age, with no history of a hemorrhagic diathesis, myopia, glaucoma or syphilis. The urine did not contain either sugar or albumin. The bright-red hemorrhage began as soon as the iris was grasped by forceps. All means of controlling the hemorrhage failing, evisceration of the globe was performed. But this did not arrest the hemorrhage nor did cauterization of the arteria centralis retinæ. Bleeding was finally arrested by dropping sterile gelatin into the scleral cavity. Becker thinks that the cause was an anomalous distribution of the ophthalmic artery with general arterio-sclerosis.

Braav[4] says post-operative intraocular hemorrhage always results in total blindness and maybe also destruction of the eyeball. There have been but 75 cases of post-operative intraocular hemorrhage reported. In the 75 cases found in literature it occurred mostly within one hour after the operation; some occurred as soon as the corneal incision was completed, even before the removal of the cataract; some 24 hours after the operation; while others occurred three days after the operation. Only in two cases did the hemorrhage follow iridectomy for the relief of glaucoma, a fact that speaks against the theory that the hemorrhage is caused by a sudden reduction of a high intraocular pressure. The cause is undetermined.

McNabb,[5] in speaking of this contention, says that the hemorrhage may occur immediately after the corneal section, later, before the dressings are applied, or some few hours or a day after the operation, and it seems to be independent of the method of extraction employed, though favorable results were obtained by preliminary iridectomy.

The records of the Manchester Royal Eye Hospital for the last twenty years show that chorioidal hemorrhage occurred in three instances out of a total of 4,422 extractions. The writer gives the history of a patient in whom this complication occurred, together with the macroscopical and microscopical examination of the eyeball.

He concludes that hemorrhage from the chorioid after extraction is very rare. If there is a chorioidal hemorrhage in one eye it does not follow that the other eye will suffer in like manner. The most frequent cause is probably atheromatous or fatty disease of the vessels, and sudden reduction in the tension of the eye following the incision of the cornea and the escape of the aqueous. In cases where there is increased tension, or in the decrepit, or when there are marked vascular changes evident, it seems advisable to perform a preliminary iridectomy, or, as some advise, a discission of the senile lens.

Quackenboss[6] reports three cases of chorioidal hemorrhage occurring in a series of 3,624 extractions for uncomplicated senile cataract at the Massachusetts Eye and Ear Infirmary. He gives the clinical history and pathologic findings in his cases, and adds that "We may conclude that chorioidal hemorrhage, in uncomplicated cataract operations, is a rare occurrence, happening at the infirmary about once in 1,200 cases; that its exact cause is unknown, but I think we may safely say it is due to some degenerative process either in the chorioid or in the chorioidal vessels; that the two eyes are not always involved."

Puccini[7] reports a case of severe hemorrhage following cataract extraction. The patient, 65 years old, had a mature, senile cataract in the O. S. There were no local contra-indications to an operation. The urine contained a small quantity of albumin and some hyaline casts. After placing the patient on a milk diet to diminish the albumin, the cataract was removed. The excision of the iris gave place to a slight hemorrhage which did not disturb the operation. On the third day the dressing was saturated with blood and eye lost.

Braav[4] reports the case of a weak, nervous woman suffering from pain in the joints, headache and gastric disturbance; left eye blind for forty years from some inflammatory condition; right eye, linear corneal opacity 4 mm. in length, situated horizontally below the pupil; eye quiet; pupil dilated; does not react to ordinary light, but reacts to concentrated light; anterior chamber well preserved; cornea hazy, tension +2, slight greenish lenticular reflex. Ophthalmoscopic examination revealed an entire opaque lens in the right eye; no view of fundus light; projection good. Diagnosis, hypermature cataract, extraction advised. Some preliminary treatment was given to tone up her general condition and a weak solution of eserin instilled into the eye twice daily.

Immediately upon making the corneal section the lens was forced out by intraocular pressure, some vitreous escaped, and the anterior chamber collapsed. The vitreous was somewhat liquefied. No iridectomy was done, but the speculum was at once removed and the eye bandaged. A little pain was then complained of in the supraorbital region, which,

seven hours later, had become severe; the patient was restless, nauseated, had vomited several times, and the bandage was soaked with blood. The eyeball was found filled with blood, but the wound had not opened. The bandage was reapplied and a hypodermic of morphine given. The next morning the bandage was clean, but eye still painful. Two hours later the patient attempted to go downstairs and was seized with vomiting and acute pain. Severe hemorrhage again occurred, the wound gaping with dark clots of blood separating its edges. The patient went to the hospital and panophthalmitis developed.

Sudden attacks of nausea, vomiting and severe pain in the eye with the appearance of blood on the dressing is the characteristic clinical picture.

Santos Fernandez[8] says that in his practice of more than twenty-nine years bleeding after cataract operations had occurred only once, but recently he had seen it follow an iridectomy for glaucoma in both eyes, so that he thinks that it may happen more frequently than is usually reported. A woman, 48 years old, myope, slowly developed glaucoma with vitreous opacities. Finally an iridectomy was done with perfect success at the time of the operation, but after the bandage was applied she felt a sudden pain in the eye and blood was noticed. In spite of all treatment hemorrhage continued for eight days, and when the eye finally healed light perception alone remained. A year later the other eye was operated in the same manner, except that the precaution was taken to keep the patient continually recumbent, and there was no iridectomy, but a simple extraction of the lens, which was of a dark color. This time hemorrhage did not take place, and the eye healed normally. The best explanation of such a hemorrhage is that it comes from the ciliary arteries, which are stiffened by sclerosis.

A. E. Bulson[9] reports two cases in elderly subjects who were operated for cataract, with iridectomy, who developed glaucoma in about a month after the operation. The eyes were lost and had to be removed. In both cases the immediate results were satisfactory and good vision was obtained. The pupillary spaces were clear, and the colobomas normal and large. No incarcerations. Miscroscopic examination showed this to be true. The glaucoma was accounted for by cyclitis and changes in the fluids of the eye, which could not be eliminated at the excreting angle.

LITERATURE.

1. Blok, *Tydschr. v. Geneesk.*, Jan. 26, 1907.
2. Würdemann, vide Posey and Wright, *Dis. Eye, Ear, Nose and Throat*, 1903, p. 384.
3. Becker, *Woch. f. Ther. u. Hyg. d. Aug.*, No. 1, 1905.
4. A. Braav, *Amer. Med.*, May, 1907.
5. McNabb, *Ophth. Rev.*, Nov., 1906.
6. Quackenboss, *Arch. Ophth.*, July, 1904.

7. Puccini, *La clin. oculist.*, Feb., 1908.
8. Santos-Fernandez, *Ann. d. oftal.*, Aug., 1904.
9. A. E. Bulson, Jr., *Ophth. Record*, Nov., 1907.

(D) DISTURBANCES IN HEALING.

Peters[1] notes some disturbances in the course of healing after cataract operations. I. Keratitis bullosa through degeneration of the endothelium. On the second day after a cataract extraction in a man aged 70, a striped keratitis developed, which after two weeks was complicated by relapsing formation of vesicles, which finally subsided under a pressure bandage. He assumed a globular degeneration of the endothelium (Drüsen), which probably was damaged by the somewhat laborious extraction of the lens, so that an opacity of the cornea was caused by inbibition with aqueous. He mentions the recent experiments of Erdmann, who produced in rabbits changes of the endothelium with dimethyl sulphate, followed by typical bullous keratitis.

II. Kerato-iritis by too high a percentage of alkali in solutions of oxycyanide of mercury. After eight cataract operations and three iridectomies he observed kerato-iritis complications which could not very well be due to infection. Finally he found that the cyclitis irritation was due to the alkali contained in the oxycyanide solutions which were made of tablets containing 1.03 oxycyanide of mercury and 1.04 carbonate of potash, giving a concentration of 1:1000. As soon as this solution was made merely of oxycyanide of mercury 1:3000 no further post-operative cyclitis was observed.

III. Headache after cataract operations. Ciliary pains in the forehead and eye, like those in iritis, are sometimes observed after cataract extractions. If, after a careful inspection of the eye, iritis can be excluded, he advises to palpate the exit of the supraorbital nerve, which may show a sensitiveness like an asthenopia of various causes. This may be due to predisposition to headaches after excitement, constipation or gouty neuralgia. In such cases the usual nervina, as antifebrin, etc., or quinin and iron, generally give relief.

Berka[2] reports a case of failure of closure of an extraction wound due to exfoliation of epithelium, in support of the view of Wagenmann that most cases of late infection after cataract extraction or injury to the globe are not of endogenous origin, but due to porosity of the scar and secondary invasion of bacteria.

The astigmia following delayed union of corneal wounds is apt to be large. I have personally noted a number of cases of delayed healing of the corneal wound, but in no case have had infection therefrom.

A typical instance is that of a nervous woman on whom I had successfully expressed the lens in its capsule, on account of the importuni-

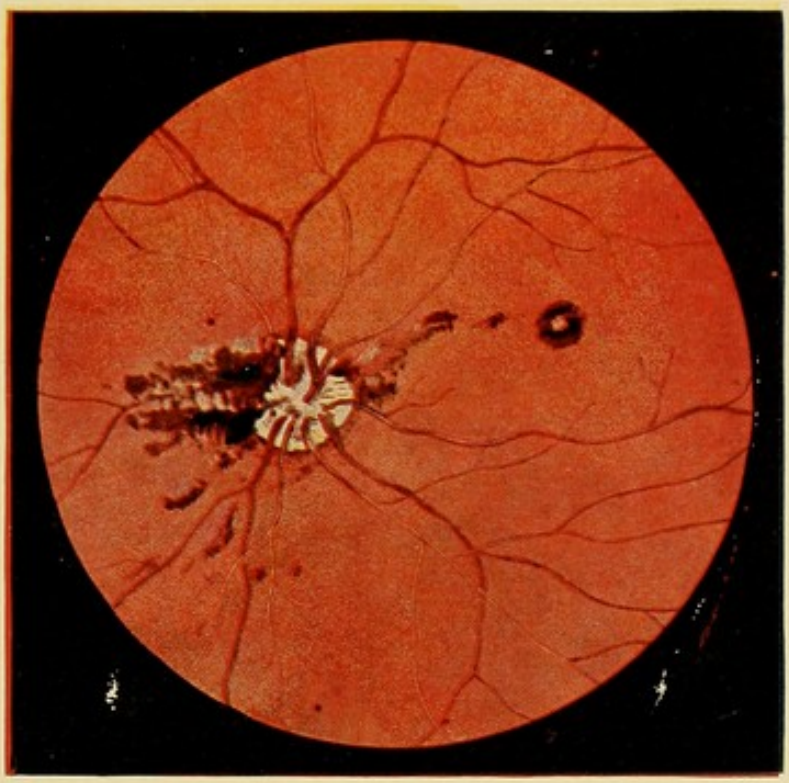

PLATE II

Birth injury 2 weeks after forceps delivery. Bleeding from vessels in optic sheath into retina and vitreous.

ties allowing her to leave the hospital on the fifth day thereafter. The wound was then coapted, but twenty-four hours after leaving the hospital it broke open, followed by extensive iris prolapse and delayed union for nearly two months. V.+6.00=+6, 150°=6/xviii.

In another case, a nervous man, sitting up in bed on the second day, or perhaps fumbling by the patient's fingers, disturbed the wound, followed by iridic prolapse and delayed union. Cauterization closed the wound after one month. Resultant good vision, 6/vi with correction.

LITERATURE.

1. A. Peters, *Zeitschr. f. Aug.*, xx, 1908.
2. Berka, *Arch. f. Aug.*, liii, I.

(E) KYANOPIA.

Major Elliot[1] says a large number of patients operated on in Madras for cataract are in the habit of complaining that everything they see appears colored after operation. Rarely a patient complains of seeing red or green, but every week one hears from a number of those operated on: "I see everything as it were blue." During 100 days he operated on 250 cases, all of whom were discharged from the hospital within five days after the operation; hence the observations of chromatopsia were made during this time. One hundred and ten did not have colored vision, while 140 had colored vision, 130 of which saw blue.

Hilbert[2] collected 27 cases of color vision after injuries of various parts of the body, viz.: erythropsia 6, xanthopsia 10, kyanopsia 5, chlosopsia 4, and ianthinopsia 2. Either the whole visual field appeared in the color, and this was more frequent, or colored spots were seen in irregular arrangement, whether occupying a constant position in the visual field or movable. The predominance of the warm colors, red and yellow, over the cold colors of the spectrum corresponds with the fact that red and yellow leave a more intense impression in the sensorium than green and blue; are first recognized by children; and play a chief part in the ornaments of non-civilized people.

Enslin[3] observed kyanopia in numerous cases immediately after extraction of cataract, mostly nuclear cataracts. It gradually decreased and disappeared after one or two weeks, and was never seen later than one month after the operation. He explains the phenomenon by the theory of contrast. The human crystalline lens has, from childhood on, a yellowish hue, which increases with advancing age and is more pronounced in cataract, particularly nuclear cataract. In such eyes yellow rays have been acting on the retina for years, while the blue rays were absorbed by the yellow lens. After removal of the latter the contrast-

ing blue rays suddenly gain entrance to the retina and arouse intense blue vision. This very rarely occurs if much cortical matter remains in the eye, which at first admits little light, gradually more by being absorbed, thus preventing the action of contrast. The few cases of kyanopia published are quoted, but, being of cerebral etiology, have no bearing on kyanopia after cataract extraction.

LITERATURE.

1. R. H. Elliot, *Ophthalmoscope*, Jan., 1906.
2. Hilbert, *Klin. Mon. f. Aug.*, Sept., 1907.
3. Enslin, *Zeitschr. f. Aug.*, xv, 1906.

(F) OTHER OPERATIVE ACCIDENTS AND DANGERS.

The dangers of the operation for removal of the lens in high myopia are as follows: (1) Hemorrhage and loss of vitreous; (2) detachment of the retina; (3) incarceration of the iris or capsule; (4) glaucoma; (5) iritis; (6) infection. The liability to hemorrhage, etc., seems to be slight. Detachment of the retina occurs in only 3 to 5 per cent. of the cases; the same ratio as without the operation. (Fröhlich.[1])[27-28]

In the making of an iridectomy, particularly if the corneal incision be made by the lance, the tip of the instrument may scratch or cut the anterior capsule of the lens, in most instances producing subsequent cataract. This is only unfortunate in instances where the iris is excised for optical purposes or where the vision is yet good, as in the early stages of glaucoma.

One such unfortunate event I well remember in the case of an old soldier, whose violent contortions during the operation led to the injury of the lens capsule. Complete cataract occurred within a few months, which was subsequently delivered by me with full 6/vi vision after correction, but the patient was never satisfied and haunted me for years thereafter with complaint of the necessity of wearing glasses even though his glaucoma had been fully cured.

S. Klein[2] reports a case of perforation of the cornea and capsule of the lens with subsequent traumatic cataract which was completely absorbed after three months, with V 6/vi. In seven cases of iridectomy, accidental injuries to the lens capsule had no permanent bad effect. The lens was either absorbed as in discission, or extracted without damage to vision, so far as it was left intact by the original glaucomatous process. When the result was unfortunate, it was due to the glaucomatous process, and the injury to the lens was irrelevant. From those experiences Klein does not much dread injuries of the capsule.

Marshall[3] makes a strong plea for removal of suppu-

rating eyes. He does not see any reason for evisceration of the scleral contents, leaving behind the infected sclera. He does not believe that removal of the sclera with its suppurating contents involves as much danger as leaving it, nor as much danger as incising and draining it, not even as much danger as evisceration. He thinks suppurating eyes should be removed early, and that great care should be exercised in their removal not to rupture them, thereby causing infection of the wound by the escaping contents.

Kindermann[4] reports an eye enucleated on account of an injury with a piece of iron. Three years later epileptic seizures made their appearance; the stump of the optic nerve was then resected, and after an examination, it was found to be imbedded with some remnants of sclera, chorioid, and retina in the form of a solid scar. Operation was followed by immediate improvement.

The author is of the opinion that the particles of retina which were left in the scar produced the attacks similar to cortical epilepsy. His attention was directed to the orbit because the patient complained of hyperalgesia in the region of the external nasal nerve during an attack.

Wirtz[5] saw a girl February 13, 1909, aged 16, who on that day was discharged as cured from another hospital, where she had been treated for three weeks for angina. She came to be operated on for squint. As her recovery seemed to be complete and the conjunctival sacs normal, a tenotomy of left internal, and advancement of external, rectus were performed on February 16. During the first 24 hours she felt well, then she complained of slight burning in the eye so that the bandage was removed in 48 hours. Wirtz was surprised to find an intense blennorrheic conjunctivitis, with the aspect of gonoblennhorrea, diphtheric inflammation of the wound and total purulent infiltration of the cornea. The purulent conjunctivitis healed under profuse irrigations in about two weeks, the cornea sloughed completely within three days, with ensuing phthisis of the eyeball.

The bacteriological examination explained the unfortunate result: The pus contained abundant cocci, chiefly diplococci and streptococcus longus.

Subconjunctival injections.

Villard[6] reports a case of a man 59 years of age, who was myopic and in whom there was retinal detachment. The day following the injection of 10 per cent salt solution the upper eyelid was found to be much swollen, with inability of the patient to raise it. In two weeks the palpebral paralysis had disappeared.

Alexander[7] gives the following objections to the use of subconjunctival injections of bichlorid:

1. It was shown that subconjunctical injections of bichlorid were often badly borne. Eyes which were thus treated often remained in an irritable condition after complete cure of the condition for which treatment was instituted.

2. There has been no positive proof that in subconjunctical injections the bichlorid reaches the interior of the eye, to act there as a disinfecting agent.

3. Numerous observations on the eye of the lower animals and of the human being show that bichlorid acts upon the energy of the lymph currents only in its capacity as a salt by exciting currents of diffusion.

These observations led to the substitution of NaCl for the bichlorid, and equally good results were reported, with fewer complications.

The author gives the clinical histories of three cases in which complications followed the injection of NaCl. In the first case adhesions occurred between the conjunctiva and sclera at the site of puncture. In the second case there was extensive necrosis of the bulbar conjunctiva, followed by peculiar changes in the cornea and lens. The third case also showed peculiar opacities in the cornea and lens, which later disappeared.

Verderame[8] says subconjunctival injections with concentrated solutions of sodium chlorid are harmless; on the other hand, injections with solutions of hydrargyrum cynatum or hydrargyrum oxycyanatum, 1:5000, show a partial obliteration of the subconjunctival space, necrosis of the conjunctiva at the point of injection and shrinkage, followed by an entropium of the upper lid; the addition of sodium chlorid to the mercurial solutions diminishes their irritating effect.

F. Park Lewis[9] reports a case of a woman of 50 years, having about passed through an attack of acute dacryocystitis, a 25 per cent. solution of protargol was injected into the sac and was repeated on the day following. Shortly after going home great pain developed, with orbital cellulitis and protopsis, followed by optic atrophy.

A woman was being treated for dacryocystitis by one of my assistants. Unfortunately a false passage was made by probing, and still more unhappily 25 per cent. argyrol was injected into the lacrymal sac. This was followed by a permanent dark discoloration and by a lawsuit.

Dangers from cauterization.

Aside from accidental injuries, the cauterization of the cornea for curative purposes may proceed too far and the cornea be perforated, with injuries to the iris and lens; or the albumen of the lens

may be coagulated by the heat of the electrode and cataract ultimate.

Two such cases I saw some years ago, the one from an unqualified specialist and the other from a cauterization enthusiast.

In 1897 Trousseau[10] reported three cases of sympathetic ophthalmitis (two of his own and one of Kalt's) following the use of the galvanocautery in treating prolapse of the iris. In 1909 Trousseau reported two additional cases.

In 1897 Gifford[17] reported such a case and in 1910 collates the literature with report of an additional case. He found seven cases of sympathetic ophthalmitis in which the authors mentioned incidentally that a wound of an iris prolapse had been cauterized a suitable length of time before the outbreak of the disease in the second eye. These cases were reported by the following authors: Alexander,[11] Darier,[12] Alberti,[13] Dimmer[14] and Fuchs,[15] who each report a case occurring after cauterization of an iris prolapse of a cystoid scar; and Cohn[16] mentions two cases from the clinic of Silex in which a wound was cauterized before the sympathetic ophthalmitis broke out.

Operations on the nose and sinuses.

Laas[18] reports two cases of contralateral visual disturbances after operation on the nasal septum. A man, aged 33, complained of flickering and impairment of vision of his right eye 15 minutes after a spina at the left side of the nasal septum had been removed with the chisel. The next day the pupil was larger than the left, showed sluggish, direct, prompt, consensual reactions. Almost the whole upper half of the visual field was lacking, with the lower half only motion of hand was seen. After a few weeks V.=5/xv, the optic disc was paler than left, after two months atrophic, except the upper nasal portion. Hemianopic reaction of the pupil upon illumination of the lower half of the retina. The left eye was perfectly normal.

Laas assumes as the cause of the partial optic nerve atrophy a laceration of the optic nerve by a fracture of the wall of the right optic canal, caused and propagated by the chiseling of the spina on the right side of the septum, on account of the special anatomic conditions, to which Onodi first called attention. Laas thinks either the left sphenoidal sinus and the last ethmoidal cell formed the wall of the right optic canal, or the right sphenoidal sinus or last ethmoidal cell formed the wall of the right optic canal and extended beyond the median line and perhaps between the lamellæ of the perpendicular lamina. In both cases the chiseling of the spina, reaching very far backwards and upwards, could produce a fracture of the wall of the neighboring accessory cavity and a fissure up to the wall of the right optic canal.

According to the anatomico-pathological researches of von Hoelder, who found in 53 out of 86 fractures of the cranial base fractures of the walls of the optic canal, the visual disturbances after injuries of the skull, either total amaurosis or defects of the visual field, as in this case, and the ophthalmoscopic conditions are due to fractures or fissures of the optic canal.

A similar explanation is given in the second case by Professor Kuttner. After removal of an exostosis from the posterior portion of the left side of the nasal septum, with the saw, driven by an electromotor, the patient could not see with his left eye, had fever and was drowsy. The fundus was normal in both eyes, but the left eye completely blind, the right showed temporal hemianopia. An injury of the anterior angle of the chiasm was surmised by a fracture propagated from the wound to the optic canal.

From these observations Laas advocates discretion in operation in deviations of the septum far backwards and upwards.

Arnold Knapp[19] gives the history of a case of sudden blindness following operation for empyema of the right frontal sinus. Sinus was operated and the entire anterior and inferior walls removed. Perforation was found at inner third of junction of anterior and inferior walls. Second day after operation there was edema of upper lid and slight exophthalmos. No vision present. Ophthalmoscopic picture was similar to an embolic process; retina hazy and edematous; arteries small, and at one point the inferior temporal artery appeared obliterated; no swelling of the disc; small hemorrhages about the macula. Final result was atrophy of the disc and the patient remained blind.

Fracture or perforation of the inner wall of the orbit has been observed by me several times in my own practice, and in that of others, from ablation of the middle turbinate whereby a fracture was produced, and from free curettement of the posterior ethmoidal cells from perforation. In three cases immediate emphysema of the orbit occurred from the patient blowing his nose. In one case a localized abscess of the orbit and lower lid developed which had to be opened externally and drained. In the three cases no other effects followed, the emphysema disappearing within 24 hours under pressure bandage.

Paraffin injections about eyes or nose.

Rohmer[20] reports a case of "saddle" nose, where the attending physician was ignorant of the injection of paraffin, the cosmetic effect was much worse after the injection, because not only did the "saddle" nose retain its original shape, but there also appeared two paraffin tumors on both sides of the root of the nose, and besides this the power

of vision with one eye was entirely lost. An oculist who examined the patient found an embolus of the arteria centralis retinæ. The author, however, could not corroborate the diagnosis, because he found a clear picture of a thrombosis of the vein. He does not consider an embolus of the central artery the cause of blindness after paraffin injection, but he thinks that in these cases there is always a thrombosis of the central vein, which can easily be explained anatomically, inasmuch as in the inner angle of the eye there are always extensive communications between the nose, facial and orbital veins.

In order to avoid accidents in this connection the following precautions must be taken:

1. Paraffin which melts at a low degree of 41° or 42° only should be employed.

2. Pressure during the injection is to be avoided.

3. The injection is to be made through a thick canula, so that piercing of a vein should be rendered more difficult.

4. An assistant should exercise strong compression at the angles of both eyes, thus preventing the injection of paraffin into the orbital veins.

5. A very small amount should be injected at one time; only from 1 to 1.5 c.c.

Rohmer attributes the accident to thrombosis of the ophthalmic vein, though some cases have been supposed to be due to embolus of the retinal artery. The latter would require an open foramen ovale, as otherwise the embolus would be arrested in the lungs, while there is a free current by way of the internal angle of the eyelids and a large branch of the facial vein to the ophthalmic vein.

The author thinks that the danger of the accident can be reduced to a minimum by using paraffin of not too high a fusion point—not more than 41° or 42°; injecting slowly not more than a centimeter and a half at a time; and limiting its diffusion by pressure with the fingers of an assistant.

A review of the cases of "embolism," observed after injections of paraffin, shows that after such injections into the nasal organ only one eye was damaged and never embolisms of other organs, especially of the lungs, occurred, and that, on the other hand, after the numerous injections into the urogenital region embolism of the lungs, but never a simultaneous embolism of the central retinal artery was ascertained. This strongly suggests that between the place of injection at the nasal region and the interruption of the blood current in the central retinal artery certain direct relations must exist. In future attention should be given to the fact whether the homolateral eye is always affected or not.

The fate of the paraffin injection is problematic. It is probably ultimately replaced by tissue similar to that in which it is injected, the paraffin serving as a framework upon which new tissue is built, being ultimately absorbed. In one case where I injected paraffin into the stump after enucleation a tumor formed which had to be excised. The pathologic report is as follows:

The tissue consists mainly of white, rather dense, tough substance, surrounded and interspersed with patches of muscular tissue. Upon pressure minute particles of paraffin can be squeezed out. The microscope shows the following:

The predominant constituent is moderately young connective tissue with bands of older connective tissue running through it. There are numerous areas of connective tissue. There are numerous areas of connective tissue cells of fibroplastic character containing giant cells such as are found after the introduction of sterile foreign bodies into human or animal tissue. These clusters of endothelial cells, in most instances, are found surrounding small cysts. These cysts are found to be lined by proliferated endothelium and the above mentioned endothelial cells have undoubtedly originated from this lining endothelium. The cysts are lymph clefts which have been dilated by the forcibly injected paraffin. Some of these dilated lymph clefts contain moderately numerous polymorpho-nuclear leucocytes, showing that some slight infection, perhaps lurking in the skin tissue, was carried in with the paraffin.

Uhthoff[21] reports two cases of injuries to the eye following paraffin injection of the nose. The first, a woman, had saddle nose either from injury or syphilis. Three injections of paraffin were made at intervals of eight and five months. The paraffin used had a melting point of 43° C. and was injected at 46° to 47°. During the third injection of a quantity somewhat over a gram, the patient noticed suddenly that the left eye had become blind. There was no pain, but some lacrimation and several attacks of vertigo on her way home. The ophthalmic picture was of embolism of the central artery of the retina. Uhthoff thinks it certain that the occlusion of the artery was caused by a small particle of paraffin, and it must be assumed that the particle went through the pulmonary circulation first. He does not accept the explanation of Hurd and Holden, who presuppose a persistent foramen ovale permitting direct access to the arterial circulation, nor of Elschnig, who thinks that during the injection paraffin might find its way into a peripheral branch of the corresponding ophthalmic artery, taking its way centripetally at first and then entering the central artery. Embolism, especially pulmonary embolism, has been observed a number of times after the use

of soft paraffin with melting point up to 45°. The use of hard paraffin, even with melting point above 50°, has some danger also.

The second case reported is that of a man, age 57, with saddle nose from the kick of a horse. Three injections of paraffin, probably soft, were made near the end of 1904. The result was satisfactory up to the end of the following February, when the patient, in a profuse perspiration, felt a sudden itching and pressure in the eyes which he, therefore, rubbed. The lids and surrounding portions of the face became swollen and inflamed and there was an utter inability to open the eyes. It was proved by microscopic examination that inflammatory proliferation was caused by penetration of the paraffin into the eyelids. Only by strong pulling on two lid retractors could it be seen that the eyes were intact and movable. At various sittings small pieces were cut from the lids, and he was by this enabled to use his eyes. The firm growths in the lids were found to extend in various directions into the surrounding tissue, and the superficial strata of the epidermis were found firmly adherent to them. Microscopically there were no large masses of paraffin found, but only drops or somewhat larger vacuoles, around which were dense inflammatory cell infiltrations, giving the tissue a retiform appearance. The inflammatory infiltrated mass contained many polynuclear giant cells. The enormous swelling of the lids then was caused not by the quantity of paraffin, per se, but by the inflammatory new formation of tissue secondary to the migration of the paraffin into the lids. Uhthoff considers that were hard paraffin used the process would be much more slow and much less extensive.

Erwin Zahn[22] cites the case of a woman, aged 41, on awakening from narcosis, in which a third injection of paraffin had been made, for correcting a saddle nose, could not see out of the previously normal left eye. The next day revealed amaurosis, no pupillary reaction and typical picture of embolism of the central retinal artery. Paracentesis of the anterior chamber was of no avail. Nine months later, direct reaction of the pupil abolished, the consensual and that on convergence prompt, the disc very pale, glaucomatous excavation and chorio-retinitis changes. He ascribes the affection not to an embolism, which would require the rather impossible assumption that a particle of paraffin passed through the capillaries of the lungs, but to an interruption of the blood supply to the central retinal artery on a direct way from the place of injection.

Vossius[23] observed a very distressing paralysis of the abducens in a woman, aged 60, on the sixth day after herniotomy, performed with stovain anesthesia of the spinal cord. The diplopia had not yet disap-

peared at the time of this report, half a year later. A weakness of the left leg had also developed, lasting for several weeks.

Portions of instruments, as ends of knives and needles or buried threads, may inadvertently be left in the ocular tissues. Sooner or later these give rise to irritation, as would any other foreign body, and have to be removed. Such has occurred in my own experience. The breaking of knife or needle points in tissues during operation is due to their becoming brittle through sterilization. I have never had this happen in the case of new, well-made instruments.

Rockcliffe[24] gives a brief review history of a patient upon whom he had operated for cataract; the extraction was smooth and uncomplicated; two days later panophthalmitis developed. Before excision a bright foreign body was noticed, during an irrigation, floating away with the lotion; this was found to be a piece of plating 1.5 mm. by 1 mm. and had come from the de Wecker's scissors used during the iridectomy and had dropped unseen into the anterior chamber.

Investigation showed that the separation of the plate was due to a fault in the copper-nickel plating in the presence of a saline solution, setting up galvanic action; it seemed probable that pieces of double metal like this would very much strengthen electrolytic action if they got into the saline fluids of the eye.

The writer warns ophthalmic surgeons to carefully examine instruments prior to use, and suggests an accident like that just described as a possible cause of panophthalmitis after cataract extraction for which no other explanation can be found.

Berard[25] says infection of the lacrimal passages may occur from injections and probing. Of all the modes of treatment indicated, of all the instrumentation advised, those recognized by all as efficacious, are catheterization by Bowman's probes and washing the lacrimal sac by the aid of Anel's syringe. He refers to Puech of Bordeaux, who, in 1896, urged the correct treatment for the condition, his mode of procedure for the treatment of blennorrhea of the lacrimal sac; and in regard to the dilatation of the canal says it is a maneuver almost indispensable in order to permit liquids destined to come in contact with the mucous membrane throughout the canal, but it is a means the use of which should not be prolonged beyond a certain time, and should not be renewed unless absolutely necessary. He regards blennorrhea of the sac as amenable to extirpation, but the latter is not to be tried in simple dacryocystitis.

Jocqs[26] observed this sequel in a 52-year-old woman who had suffered from empyema of the antrum for six years previous to the operation. Four days later a sero-purulent catarrh of the tear sac, without

other inflammatory symptoms, made its appearance. The duct was found to be impervious, as injected salt solution returned contaminated by way of the upper punctum. After probing, the duct became patulous. About one month later there occurred a very painful swelling in the region of the tear sac, which quickly subsided, leaving the duct free again. He gives two possible explanations for this result: 1. Extension of the sinus infection by way of the nose. 2. Closure of the mouth of the tear canal with consecutive inflammation of the canal through retention of the secretions.

Amongst other damages to eyes occurring from the practices of quacks and irregulars was the following:

A man went to a Chicago irregular who claimed to cure diabetes by operating upon the recti muscles. He consulted me in regard to loss of vision in the right eye following such an operation. Such, however, was the hypnotic influence of the quack that he did not blame him for the result. Such an incident in the practise of a qualified practitioner would undoubtedly have given rise to a malpractice suit, and infliction of heavy damages.

The visual acuity was 6/lx; the visual field contracted to the nasal side. Ophthalmoscopic examination showed optic retinal and chorioidal atrophy, due to instrumental operative wound through the capsule, resulting in a large cicatrix of the chorioid and retina, atrophy of vessel walls, pigmentary deposits in retina and striate retinal changes.

LITERATURE.

1. Frölich, *Arch. f. Aug.*, xxviii, 1, 1908.
2. S. Klein, *Centralbl. f. prak. Aug.*, March, 1910.
3. Devereaux Marshall, *Ophthalmoscope*, Dec., 1905.
4. Kindermann, *Wien. Med. Woch.*, July 3, 1909.
5. Wirtz, *Zeitschr. f. Aug.*, Jan., 1910.
6. Villard, *La clin. opht.*, June 10, 1908.
7. L. Alexander, *Arch. Ophth.*, Jan., 1906.
8. Verderame, *Wien. Med. Presse*, Sept. 30, 1906.
9. F. Park Lewis, *Ophth. Record*, Dec., 1907.
10. Trousseau, a. *Rec. d'opht.*, 1897, p. 249, b. *Arch. d'opht.*, Nov., 1909.
11. A. Alexander, *Ophth. Klin.*, Apr. 5, 1900.
12. Darier, *Ophth. Klin.*, Aug. 5, 1900.
13. Alberti, *Beitr. z. Aug.*, v, p. 743.
14. Dimmer, *Zeitschr. f. Aug.*, Aug., 1901.
15. Fuchs, *Arch. f. Ophth.*, lxx, p. 469.
16. Cohn, *Zeitschr. f. Aug.*, Jan., 1905.
17. Gifford, a. *Ophth. Record*, 1897, p. 673; b. *Journ. A. M. A.*, July 30, 1910.
19. Arnold Knapp, *Arch. Ophth.*, Nov., 1906.
20. Rohmer, a. *Wien. klin. Woch.*, Jan. 28, 1906; b. *Ann. d'oculist.*, Sept., 1905.
21. Uhthoff, *Berl. klin. Woch.*, Nov. 27, 1905.
22. Erwin Zahn, *Klin. Mon. f. Aug.*, March, 1910.
23. Vossius, ref. Uhthoff.
24. Rockcliffe, *Brit. Med. Journ.*, July 3, 1909.
25. Berard, *La Clin. ophthal.*, July 10, 1904.
26. Jocqs, *Die Ophth. Klinik*, No. 21, 1905.
27. Würdemann and Murray, *Ann. Ophth.*, April, 1899.
28. Würdemann and Black, *Journ. A. M. A.*, Nov. 28, 1903.

CHAPTER VII.

INJURIES FROM CHILDBIRTH.

Etiology—A. Fractures—B. Injuries to the soft parts and the lids—C. Exophthalmus and evulsion—D. Paralysis of the ocular muscles—E. Injuries to the globe—Opacity of the cornea—Ruptures of Descemet's membrane—Retinal hemorrhage—Prophylaxis and Therapy—Literature.

Injuries during childbirth, with the exception of ophthalmia neonatorum produced by infection during or after labor, occur during spontaneous or instrumental delivery from mechanical causes, mostly coming under the head of injuries from blunt force, being due to compression, contusion, and rupture. Here we differentiate: 1, Fractures of the skull, especially of the orbital walls; 2, Injuries to the soft parts of the orbit, and particularly the lids; 3, Evulsion of the eyeball; 4, Paralysis of the ocular muscles; 5, Injuries to the eyeball.

Under normal conditions the eye of the child is not exposed during labor, although some cases of severe injuries have been reported, mostly produced by operations with the forceps.

A study of the one hundred and twelve cases cited by Wolff[1] shows that thirty-two of them were corneal injuries, which form of injury is the most frequent of all ocular injuries occurring during the act of birth.

It is seen from a study of Wolff's statistics that the great preponderance of injuries are incident to forceps deliveries. (Ninety-three cases out of one hundred and eight in which details of the labor were available.) Furthermore, eye accidents occur in the larger number of cases only when difficult obstetrical operations, with the head still high, have been performed. This is especially true when the pelvis is contracted. According to Wolff, the action of the forceps in producing eye injuries may be direct or indirect.

"A direct pressure of the forceps on the eye, with its harmful results as regards the orbit, the soft part surrounding the eye, and the globe itself, is especially to be feared when the forceps are applied to the head above the brim. In this position of the head the skull would be grasped, as a rule, exactly, or almost exactly, in the fronto-occipital diameter and consequently the eye may easily come to lie directly beneath the forceps blade. Indirectly the forceps may lead to eye injuries; first, in that they cause fractures or depressions in neighboring skull bones, which extend

to the orbit and eventually affect the eye itself. Second, through production of intracranial or intraorbital hemorrhages, and finally through an increase in the intracranial pressure due to the compression of the skull."

A. FRACTURES.

Fractures of the skull occur mostly from the application of forceps in the new-born, but occasionally from natural birth. They are either linear or flap-shaped and show as depressions on the parietal or frontal bones. Berlin[2] describes them as occurring perpendicular to the line of

Fig. 38.
Abscess of orbit and lids from forceps delivery. (James Moores Ball.)

force and due to compression at this point, both from the application of forceps and from the uterine pressure on engaging the rim of the pelvis. Such compressions may fracture the orbital walls, producing a diminution of the size of the orbital cavity and rupture of the blood vessels, causing hematoma of the orbit with exophthalmus.

Somer[3] found in 27 fractures caused by forceps deliveries, ten of the frontal bone and four of the orbit. The old authors, as Dangan,[4] described such fractures from natural birth, but as delayed deliveries are now exceedingly rare there have been no recent cases reported. v. Hofmann,[5] Schröder,[6] Bloch[7] consider that bleeding into the men-

inges is thus produced and may be accountable for some of the cases of muscular paralysis, ocular and otherwise, and for optic nerve atrophy found on further development of the child.

I have seen several instances of monocular and binocular blindness from optic nerve atrophy in children who had been delivered by forceps and who showed evidence of fracture of the skull at that time, in which optic nerve atrophy existed, but it has never been my fortune to see a fresh case, nor has such come under my observation in the literature.

LITERATURE.

1. Bruno Wolff, *Ophthalmoscope,* 1907-1909.
2. Berlin, *Graefe-Saemisch,* VI, p. 567.
3. Somer, *Bericht. d. Berl. gynak. Gesell.,* Dec., 1883.
4. Dangan, *Schmidt's Jahrbuch,* 1844.
5. v. Hoffman, *Lehrbuch d. gerichtl. Med.,* 1891.
6. Schröder, *Lehrbuch d. Geburtshulfe,* 1884.
7. Bloch, *Centralbl. f. prak. Aug.,* 1891.

B. INJURIES TO THE SOFT PARTS AND THE LIDS.

Should the presentation be facial, the caput succedaneum may be situated over an eye and great swelling and ecchymosis result. This soon passes away in the majority of cases. The lids may be bruised, cut, torn, or even the globe gouged out. I have seen quite a number of bruises, edema and ecchymosis of the lids and chemosis of the conjunctiva, as well as wounds of the lids, from forceps or examination methods during or previous to full delivery. P r a u n[1] notes that pressure of the forceps in the neighborhood of the ear may produce facial paralysis, lagophthalmus and drying of the cornea.

In one instance I saw the eyelid torn away in a delivery by a midwife. Suturing of same left practically no deformity. In another forceps delivery there was facial paralysis, ulcer of the cornea from lagophthalmus. In several cases so-called congenital closure of the lacrimal passages was seen. In all of these children there was a flattening of the brow and a history of forceps delivery.

In the case of a woman who tried to conceal her condition, being unmarried, by a surcingle pulled tight around her abdomen, the child had marasmus and was born with a keratitis which within a few days proceeded to necrosis of the cornea, but luckily death ensued.

LITERATURE.

Praun, l. c. p. 472.

C. EXOPHTHALMUS AND EVULSION OF THE EYEBALL.

Traumatic exophthalmus and evulsion of the eyeball at birth occur only from forceps delivery, and are due to unscientific application of the forceps blades. Exophthalmus may be caused by compression of the

skull or by a direct backward pressure of forceps, acting like a speculum which dislocates the globe in enucleation. Such has been reported by Thompson and Buchanan.[1] The eyeball was forced out of the orbit and was lying on the cheek. It was immediately replaced, but the muscles were all found to have been torn loose, as well as a large part of the blood supply destroyed, which conditions demanded subsequent enucleation.

In Servel's[2] case the left eye was found lying partly outside the orbit and with dense corneal opacity. The delivery was effected after high application of forceps. The pelvis was narrow.

Veasey[3] reports case of a boy, forty-eight hours old; at birth the nurse noticed left eye to be larger than the right. Eleven hours later there was considerable proptosis, but some movement of the eyeball. At end of second day, when the author saw the case, exophthalmus marked; portion of cornea exposed between the lids; eyeball fixed; chemosis of the eyelids and conjunctiva; pupil normal; proptosis not reduced by pressure. Following day slight hemorrhages from the conjunctiva and mucous membrane of mouth; next day hemorrhages beneath the skin over the entire body. One drop of a 1-10,000 solution of adrenalin chloride and two drops of ovoferrin, given internally, every four hours, boric acid solution and cold compresses used locally. Hemorrhages ceased, but exophthalmus increased, conjunctiva became chemotic, pus appeared in anterior chamber, and pupil showed a grayish reflex from the interior of the eye. Enucleation done, followed by recovery of the patient; large clot was found behind the eyeball. Section of the eyeball showed slight purulent infiltration of the chorioid. The author believes the condition of the uveal tract to be due to the passage of a septic embolus from the umbilicus to the chorioid.

Pick[4] reports a child under his treatment, one week after birth, having suggulations of the lids and exophthalmus, 4 to 5 mm., with preserved motility, but total, milk-white opacity of the cornea of the left eye. The course was favorable and the cornea was clearing up.

The injury was caused by pressure of one blade of the forceps on the orbit (infraction) and the eyeball, which produced edema of the cornea and rupture of Descemet's membrane. The prognosis must be guarded, as occasionally hydrophthalmus may develop in such cases.

Fage[5] saw a case of luxation of the eyeball in a new-born infant. The delivery had been natural, without the use of instruments or force, and the dislocation was attributed to a contusion by the end of a shaft in the lower abdominal region, that the mother had received the day before the birth of the child.

Turnbull[6] reports an example of evulsion of the eyeball during the confinement of a woman with contracted pelvis, forceps having been used, but without any excessive force. The rest of the labor was normal. On examining the child the right eyeball was found completely dislocated from the orbit, lying on the cheek below, the optic nerve having been torn across; there was nothing to do but to remove the eyeball. The child's face was scarcely marked by the forceps and there was no displacement of the bones.

LITERATURE.

1. Thompson and Buchanan (a) *Trans. Ophth. Soc. Un. King.*, 1903; (b) *Ophthalmoscope*, June, 1905; (c) *ibid.*, Apr., 1907; (d) *ibid.*, Aug., 1907.
2. Servell, ref. Green, *Interstate Med. Journ.*, Apr., 1908.
3. Veasey, *Ophth. Record*, May, 1904.
4. Pick, *Deut. Med. Woch.*, No. 24, 1908.
5. Fage, *Arch. d'opht.*, Aug., 1907.
6. Turnbull, *Brit. Med. Journ.*, Nov. 27, 1909.

D. PARALYSIS OF THE OCULAR MUSCLES.

Küstner[1] says that central paralysis of the ocular muscles is caused by damage during birth from bleeding in the base of the brain caused by fracture of the skull, and that such paralyses offer a bad prognosis for normal function. Praun[2] says, however, that most cases coming under observation show a direct rupture or contusion of the muscles or nerves, first at the orbital ends, secondly at the base of the skull or optic foramen, so that they are either basal or orbital injuries.

Thompson and Buchanan[3] report a case of convergent strabismus and nystagmus caused by some injury to the external rectus at birth.

Perhaps some of the cases of congenital external rectus palsy I have seen have been caused by childbirth injuries, but at the time my attention had not been called to this cause and therefore no inquiry was made. I have under care at present writing a child 22 months old who has had abducens paralysis since birth (an over-term child and delayed delivery).

Sidler Huguenin[4] considered that facial paralysis occurring from birth-injury was due to bleeding at the base of the brain, and this was substantiated by Peters.[5] Serial sections of the enucleated eye showed that Descemet's membrane was torn in several places.

LITERATURE.

1. Küstner, Müller's *Handbuch d. Geburtshülfe*, 1888.
2. Praun, l. c. p. 473.
3. Thompson and Buchanan, l. c. p.
4. Sidler-Huguenin, *Corespondenzbl. f. Schweiz. Aertze*, 1903, p. 205.
5. A. Peters, *Arch. f. Aug.*, lvi, 4, 1906.

E. INJURIES TO THE GLOBE.

By far the greater number of ocular injuries following birth are not reported or even considered.

John Green, Jr.[1] says not over 25 per cent. of recorded cases can be considered as severe. Many injuries are found to have occurred in non-instrumental delivery, as after version, in face presentations, spontaneous deliveries, breech presentations, and so on. Considering that it is frequently a question of losing or saving two lives, a possible injury to the child's eyes can hardly weigh as a serious contra-indication to the use of forceps, but the grave possibilities should always be borne in mind.

One of the most frequent forms of obstetrical injury is an opacity of the cornea. This may be diffuse and transitory, or of a linear or irregularly striped aspect, and permanent, depending on edema of the cornea, due to tears of Descemet's membrane. Buchanan has suggested that unilateral high grade astigmatism may be traumatic in origin.

Braav[2] records an instance of traumatic edema of the cornea in the new-born infant which was with difficulty distinguished from (1) congenital corneal opacities resulting from a keratitis in utero; (2) anomalies of the cornea due to faulty embryonic development; (3) keratitis superficialis; and (4) hydrophthalmus.

Thompson and Buchanan[3] think the disease is rare in localities other than Glasgow, and this localization is dependent on the frequency of rickets, with marked pelvic deformity and consequent necessity for forced delivery. These corneal lesions are divided into two classes: (1) A diffuse opacity which is temporary; (2) a permanent opacity which takes a linear form and passes vertically, obliquely, or horizontally across the whole or a part of the cornea, in a straight or curved manner or concentrically with the limbus. In most cases there is more than one linear opacity. The first form occurs with comparative frequency and is due to edema. It may occur alone or in conjunction with the second form. The second form is due to rupture of the posterior elastic lamina of the cornea and the subsequent formation of fibrous tissue. It is usually associated, during the first days or weeks after birth, with a general corneal edema (first form), which may cause a uniform opacity sufficiently marked to mask the appearances due to rupture of the elastic lamina. In the total number (15) of cases which have been observed a linear opacity occurred in all. The authors are unable to determine the line of pressure which causes rupture in any particular direction in the cornea. "In nearly every instance the progress of the corneal change is almost identical with that described in connection with the earlier cases, namely, (1) general haze, with indications of strip-

ping; (2) increase of the general opacity, sometimes to an absolutely impenetrable degree, and often obscuring the striping; (3) gradual diminution of the former, which is due to edema, and increasing visibility of the latter, which is due to the scar tissue. The ophthalmologist should remember that if he sees the case early the eye will probably look worse before it begins to mend, whereas if he sees it late it is probably on the mend so far as the general opacity is concerned." Regarding prognosis, evidence is accumulating that the persistence of these corneal scars, or at any rate their effect on the vision, is very considerable. It is manifest that the opacities become indistinct in the course of the years, but one that has become almost invisible may still give rise to much distortion of the corneal curvature and consequent astigmatism. They may be found to account for certain cases of high monocular astigmatism.

A study of the recorded cases shows an agreement in the following particulars: First, that practically all have followed a difficult instrumental delivery; second, that one eye alone is generally affected; third, that they are associated with other signs of traumatism, as abrasions and bruises of the skin, subconjunctival or retinal hemorrhages, hyphemia, etc.; and fourth, that a more or less characteristic form of corneal opacity is usually present.

John Green, Jr.[4] reports a case of transient complete opacity of the cornea following use of obstetric forceps.

In Truc's[5] case the opacity persisted, there being marked leucoma of the cornea with convergent strabismus.

Ruptures of Descemet's membrane have been described in various processes, which produce increase of intraocular tension or stretching of the eyeball, as hydrophthalmus, intraocular tumors, keratoconus, high myopia, peripheral ectasia of the cornea in gerontoxin and traumatism through obstetrical forceps. Stock[6] clinically found ruptures of Descemet's membrane in a new-born infant as a consequence of delivery with forceps. There was severe parenchymatous keratitis which disappeared after two months, but typical keratoconus developed.

Most of the fifteen cases reported by the various authors show band-like opacity. In one case reported by Thompson and Buchanan[3] from their series, the microscopic examination of an eye injured during craniotomy showed edema and tearing of Descemet's membrane, the torn edges being rolled up.

Rupprecht[7] says isolated ruptures of Descemet's membrane have been described in various processes, which produce increase of intraocular tension or stretching of the eyeball, as hydrophthalmus, intraocular tumors, keratoconus, high myopia, peripheral ectasia of the cornea in

gernotoxon, traumatism through the obstetrical forceps. Stock clinically assumed ruptures of Descemet's membrane in a new-born as a consequence of delivery with forceps. There was severe parenchymatous keratitis, which disappeared after two months, but typical keratoconus developed. Rupprecht saw a slight diffuse parenchymatous haziness of the cornea with impressions above the eye of a new-born, delivered with forceps (narrow pelvis of the mother). Apparently the right blade of the forceps had been applied to the right eye. The child died the next day and Rupprecht gives a historic description with illustrations. Descemet's membrane presented two dehiscences, ⅓ and ⅔ mm. wide. and there were extensive hemorrhages between the chorioid and sclera, within and in front of the retina. The forceps apparently had pressed the cornea into the interior of the eye like a rubber ball, causing ruptures of the new convex inner surface of Descemet's membrane.

E. von Hippel[8] found in the eye of a new-born small ruptures of Descemet's membrane and hemorrhages at the fovea and in the vitreous, which perhaps had also been produced by the forceps.

Thompson and Buchanan[3] obtained several eyes for pathologic investigation from babies born dead, and these findings showed rupture of the posterior elastic lamina of the cornea.

Peters[9] had an opportunity of morphologic examination of an eye injury by forceps delivery, enucleated one-half hour after death. The previous history showed band-like keratitis for 23 days, two stripes particularly prominent. Stained by fluorescein. Facial paralysis same side. Post-mortem showed thickening of the pia mater at the base of the brain in the neighborhood of the left half of the pons. At the macular region there was found a sort of hemorrhage between the pigment and the layer of rods and cones, reaching to the papilla. On the papilla there was a small extravasation of blood and pigment.

In the optic nerve there were found lumps of pigment. Peters showed that the origin of the injury was from compression of the globe against the upper wall of the orbit, indenting the horizontal medium, thus causing vertical tearing of Descemet's membrane and the corneal tissue.

I have noted several cases of keratitis with linear opacities of the cornea following forceps delivery.

One very complicated late result of such an injury was seen in a boy of four years, who had been delivered by forceps. The face and lids were greatly swollen, external strabismus and partial upward dislocation of the lens was later made out. A brown line extended across the lens, evidently remains of a blood-stain from a hyphema which was present after birth. There was a lineal scar of the eyebrow and a lineal white

line on the cornea. At the age of four years hypertension and pain ensued. Iridectomy and myotics relieved the symptoms but the eye became blind.

In 1905 Thompson and Buchanan[3a] reported 15 cases of corneal opacity, and in two other papers[3b,c,d] report 7 more. Two of these cases, immediately following forceps delivery, presented evidences of pressure by the forceps upon the eye. The corneæ in these two cases showed evidences of rupture of Descemet's membrane by linear opacities. By the next day the linear opacities were obscured by a general corneal haze. The two other cases were not of this type; one showed evidences of corneal contusion with diffused opacity and blood in the anterior chamber, with complete recovery in a short time.

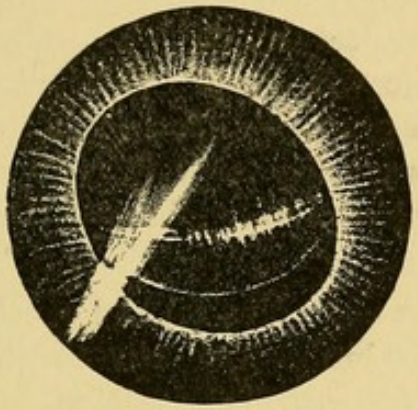

Fig. 39.

Linear scar of cornea; upward dislocation of the lens; linear pigment deposit on lens capsule; glaucoma. Four years after forceps delivery.

Three cases are reported of linear opacities on the posterior surfaces of corneæ, caused by forceps injuries at birth. Two of these cases had high degrees of astigmatism and very poor vision. One case is cited in point where traumatic keratitis developed in a child whose delivery was difficult because of its head, arm and cord being crowded into the passages together. Forceps were not used.

Three cases were all forceps deliveries. The exception was that of a four-months-old baby whose eyes were rotated upward and to the left, with jerking movements at intervals. Optic discs were pale. Contraction of arms developed. A year later the child was seen and found to have improved. This case was supposed to have sustained a cerebral birth-injury causing several foci of hemorrhage.

Traumatic opacity is a rare complication of assisted labor. It results from pressure during a prolonged second stage, which pressure is due either to some form of obstruction in the maternal passages, to compression by forceps, or to both factors combined.

Fejer[9] reports the following case, seen by him three days after delivery with forceps: The surrounding tissues of the left eye and lids were swollen and there were abrasions of the epidermis and suffusions of the ocular conjunctiva. The whole cornea showed a milky opacity, so that the pupil could scarcely be discerned. The epithelium was preserved except at the external margin of the limbus. Under warm applications the cornea cleared up entirely within eight days. Fejer attributes the opacity to edema between the anterior strata of the cornea, or below Bowman's membrane, brought about by direct pressure of the forceps.

John Green[4] notes a forceps delivery where a long and strong pull was required. One blade of the forceps was applied over the outer angle of the left orbit. Immediately after birth much bruising was noticed about the left frontal bone, and the eyelids on that side were considerably swollen. The next day the left cornea was found to be universally steamy, and there was found a marked subconjunctival hemorrhage. The conditions gradually improved until only a small linear opacity remained, which was lying vertically in the outer part of the cornea. Three months after birth the condition of the cornea remained unchanged.

In a second case there was linear corneal opacity in a child 12 years that had been present since birth. The delivery was prolonged, and was terminated by the use of forceps. The eyelids were swollen and bruised, and there were abrasions of the forehead and scalp.

Sydney Stephenson[8] reports the case of an infant that had been delivered with forceps and seen by him 36 hours after birth. There was slight discoloration of the upper lid of the affected eye and a small laceration at the external angle. The eyeball appeared markedly enlarged and was bulging. There was a small area of subconjunctival hemorrhage below the cornea, but no evidences of inflammation and no edema of the conjunctiva. The eyeball appeared larger, the cornea was manifestly larger than in the corresponding eye, and the eyeball was markedly proptosed. The cornea had a conical shape with the summit in the center, was smooth and of shining luster, but nearly the entire surface was covered with a bluish white opacity, excepting the periphery, where the clear cornea was seen about 3 mm. through the entire circumference. The opacity was most dense in the center, shading toward the margin; it was circular in shape, covering the entire pupillary area. The iris could be seen through the clear periphery and responded to light, but the fundus reflex was not obtainable. Six days later the cornea was clear, the eyeball assumed the normal shape and position, fundus reflex was well seen, the cornea was of good luster, the opacity

had entirely disappeared. The treatment employed was 1 per cent solution of dionin.

Hemorrhage into the retina and vitreous has been reported by several authors, Haab and de Schweinitz[12] depicting two such in their atlas, one being similar to a case that I saw several weeks after birth in which hemorrhage of the retina was present.

In A. Peters' case of birth injury,[9] there was found a spot of bleeding at the macular region between the pigment and the layer of rods and cones, reaching to the papilla. On the papilla there was a small extravasation of blood and pigment.

In one case I observed upward partial dislocation of the lens, with secondary glaucoma happening therefrom six years after a severe birth with forceps delivery.

Wendell Reber[13] says that obstetric injuries account for many cases of interrupted binocular vision from retinal hemorrhages.

H. Fisher[14] points out that some cases of congenital word blindness, or inability to learn to read, are due to obstetric injuries from limited meningeal hemorrhage over the left angular gyrus, resulting in failure of development.

Prophylaxis and Therapy. Proper accouchment prevents the majority of these accidents; the therapy is that of the lesion, for which see special chapters.

Bruno Wolff,[15] while recognizing the technical necessity of applying the forceps to the head at the pelvic brim in the fronto-occipital diameter of the skull, suggests that, "Under the guidance of the hand, the endeavor should be made to apply the blades as exactly as possible, so as to avoid placing them directly over the eye. If the head, grasped in the forceps, enters the pelvis in a transverse position without rotating, it is advisable, bearing in mind the possibility of injuries to the eye, to take them off and apply them again obliquely. In case of a deep transverse position, it is proper, for other reasons, as well as to avoid pressure on the eyes, to apply the instruments in the oblique diameter."

These suggestions are presented by Wolff for what they are worth, although he recognizes that we do not possess a certain means of absolutely avoiding eye injuries in forceps deliveries. Such traumas occur to the most skillful.

LITERATURE.

1. John Green, Jr., *Interstate Med. Journ.*, Apr., 1908.
2. Braav, *N. Y. Med. Journ.*, Sept. 14, 1907.
3. Thompson and Buchanan, l. c. (d).
4. John Green, Jr., *Ophth. Record*, July, 1910.
5. Truc, *Ann. d'oculist.* cxix, 1898.
6. Stock, ref. Rupprecht.
7. Rupprecht, *Klin. Mon. f. Aug.*, 1908, p. 134.

8. von Hippel, ref. Rupprecht.
9. A. Peters, *Arch. f. Aug.* lvi. 4, 1906.
10. Fejer, *Centralbl. f. prak. Aug.,* 1904, p. 235.
11. Sydney Stephenson, *Ophthalmoscope,* Jan., 1905.
12. Haab and deSchweinitz, *Atlas Ophth.,* Amer. Ed., 1909.
13. Wendell Reber, *Trans. Sec. Ophth. A. M. A.,* 1910.
14. H. Fisher, *Med. Press,* May 18, 1910.
15. Bruno Wolff, *Ophthalmoscope,* 1907-1909.

CHAPTER VIII.

INJURIES TO THE EYES FROM ACCIDENTAL OR MEDICINAL APPLICATIONS OF CERTAIN DRUGS, EXCLUSIVE OF ACIDS AND ALKALIES.

Complaints of patients regarding "strong" applications—Ignorance—Idiosyncrasy—Mydriatics—Cycloplegics and myotics—Iodoform — Naphthalin — Argyrosis—Blindness following injection of protargol—Leucoma from subacetate of lead—Methyl violet—Formalin—Potassium permanganate—Miscellaneous—Literature.

Drugs used for medicinal purposes may cause injury to the eyes locally or internally. Accidental or purposeful instillation of certain remedies into the eyes may, if wrongfully or too freely used, produce not only unpleasant symptoms but in some cases permanent injury. The quantity used; the appropriateness of the place chosen for its use; the absorption; the power of resistance of the individual sometimes make a drug poisonous, whereas in others it is a medicant.

It is a common complaint of the dissatisfied patient that the last doctor he went to used too strong a remedy for the eye, and thereby aggravated the previous existing disease or damaged the eye thereby. In the vast majority of cases there is no cause for such complaint, therefore the physician should ever be careful to disabuse the patient's mind of such a delusion, and in no case to give rise to further criticism of the previous consultant.

Occasionally, however, either from accident, idiosyncrasy or actual ignorance, damage is done to the eyes from such applications. Both idiosyncrasy of the patient and toxicity of the medicament may cause untoward symptoms of, or damage to, the eyes from drugs administered internally in therapeutic or toxic doses. Inhalation also claims its victims, as in the optic nerve atrophy following the fumes of wood alcohol.

Of local applications the most common complaint is from the use of mydriatics and cycloplegics for measuring the refraction, to which even yet in this enlightened age some persons ascribe damage, needless to say without cause. The effects of cocain and homatropin usually pass away within 24 hours, and rarely exceeding 48 hours. Full cycloplegia by atropin may last as long as 14 days, but usually disappears within 10 days. Instillations of eserin or pilocarpin relieve the mydriasis and cycloplegia. Systemic toxic symptoms are often produced, but are not to

be discussed in this connection. Continuous use of atropin for a long time locally produces a chronic conjunctivitis. The same may be said of many other applications.

The instillation of even the feebler mydriatics may, however, precipitate an attack of glaucoma, or cause it in eyes predisposed to the affection, and hence should be used with caution in patients after middle life. The mistaken application of atropin in glaucoma may produce fulminating symptoms and cause permanent blindness.

In a woman of 55, a tyro at the art of refraction used a solution of atropin to produce cycloplegia for the purpose of measurement; she was brought to me three days later with typical fulminating glaucoma in both eyes. Immediate iridectomy relieved the attack.

In a man of 60, a general practitioner had been instilling atropin in one eye for several weeks under the mistaken diagnosis of iritis. The case, however, was one of glaucoma, and when brought to me there was tension + 3, inflammation and no light perception. Iridectomy was made, but an intraocular subchorioidal hemorrhage followed one week later and the eye had to be enucleated.

The myotics, eserin, pilocarpin and morphine used locally, however, have no evil effects, although used internally to toxicity they may produce amblyopia.

When iodoform is used locally, as in dressing wounds of other parts of the body, by injection of emulsions, as well as internally by pills, untoward symptoms may be caused in the eyes, a form of descending atrophy of the optic nerve from the toxemia developed. There is failing sight, central color scotoma and normal outer boundaries of the visual field, the temporal side of the pupil is often paler in these cases—symptoms we group under the title of retrobulbar neuritis. Retinal hemorrhages, with or without a neuroretinitis, are occasionally observed. The poisonous effect of iodoform depends chiefly upon the free iodin. It seems that the volatile products of the iodoform (acetylene, C_2H_2), or the resorbed iodoform, as such, must be made accountable for the poisonous symptoms. Some of the iodoform is absorbed unchanged, for the nervous (cerebral) symptoms are not produced by iodin or iodids. (Blaauw[1]).

In the reported cases of ocular poisoning, iodoform was used for at least three months. In one exception, 65 grams were administered internally in only 14 days (Priestley Smith[2]). However, in all cases the simple stopping of the drug was followed by a return of vision, which in a few cases was reported as normal (Russell[3]), once it was 2/3 and 1/2 (Hutchinson[4]), once 1/2 (Hirschberg,[5] who reported the first case in 1882), once 6/8 (Priestley Smith[2]). Valude[6] and Terson[7] reported cases where a connection of the failing sight

with the use of iodoform—for burns—was not recognized, and atrophy of the optic nerve resulted but with some restoration of vision.

Naphthalin ($C_{10}H_8$) produces changes in the retina and corpus vitreum in the form of small exudates and crystalline precipitations, and consecutively the lens becomes opaque (cataract) and the chorioidal tract shows important changes, as hemorrhages in the ciliary processes and fibrinous exudates in the chorioid. Changes in the superficial layers of the cornea, chiefly within the ocular cleft, are found in workmen who handle this substance in factories.

Argyrosis, a staining of the conjunctiva from the long-continued use of nitrate of silver, is often seen. I had ample opportunity to observe many such cases following treatment by a certain popular, but not professionally well qualified, oculist. Argyrosis of the conjunctiva and even of the cornea from protargol and argyrol have been reported.

Spengler[8] in 1906 was one of the first to warn against argyrol argyrosis, especially in lacrimal affections.

An example of this rather common form of staining by the organic compounds of silver is reported by Krauss.[9] A child of four years who had purulent dacryocystitis was given a 20 per cent solution of argyrol to drop in the eye twice daily. It was used 20 months. The ocular and palpebral conjunctiva became colored a bluish-green tint.

It is strange that almost every case of prolonged argyrosis from the use of argyrol or protargol results from its employment in lacrimal diseases. In most other cases only superficial staining, or a temporary discoloration, is produced. No doubt the cellular inflammation that so often follows diffusion into the tissues is largely responsible for its permanency.

I had occasion to note a pronounced case of argyrol argyrosis happening in the practice of one of my assistants, who injected a 25 per cent. solution of argyrol into the lacrimal passage of a woman, after using a probe and thus having caused some solution of continuity of the canal. The whole lower lid infiltrated and later became black, which lasted for several years, and was the cause of forensic procedure.

Treatment. Sol. hyposulphite of soda, ½ to 2 per cent.

Park Lewis[10] had a case of blindness following the injection of protargol into the lacrimal sac of a woman of 50, who was suffering from an acute phlegmon of the sac which had ruptured on the face; she was treated in the usual manner until inflammatory symptoms subsided somewhat, when probing was begun and the passage syringed with 25 per cent. protargol. No reaction followed until this was done the second time. Two days later she 'phoned that great pain came on shortly after leaving the office and that the eye was blind. She was at once

directed to return, when the eye was found proptosed from an orbital cellulitis. Pupil was dilated and immobile. No light perception. The soreness and swelling gradually disappeared, leaving the eye blind from optic atrophy. It is presumed that the cellulitis was induced by some of the protargol escaping from the sac into the orbital tissues.

Formerly leucoma from the use of acetate of lead, which causes a deposit of insoluble oxide of lead as a whitish leucoma when the cornea has been abraded or ulcerated, was common. The treatment is curettement of the anterior surface of the cornea, thereby removing the deposit.

A marked case was that of a physician who in childhood had been treated for ophthalmia by a solution of sugar of lead. Very many maculæ under the epithelium, not infiltrating the corneal tissue proper, were observed. I scraped off the deposit in part and greatly improved the visual acuity.

Iodoform used locally in the form of powder or ointment may produce irritation of the conjunctiva and a dermatitis of the lids, and orthoform is very apt so to do.

Recently a number of instances of staining and injury to the conjunctiva and cornea by methyl violet, mainly from ink pencils, have been reported. Methyl-violet, or pyoktanin, is used occasionally as an ophthalmic application. Although the pieces may cause a mechanical erosion, the chief action of the aniline pencil is chemical, resulting in cauterization or severe chemical, not bacteric, suppuration. This has also been proven by experiments on animals.

It has not been explained why in the majority of cases a cauterization took place, in the minority a suppuration. Enslin[11] attributes this to the different reactions of the cornea at different ages, since the suppurations always occurred in youthful individuals or children. The same difference exists between the corneæ of the human adult and the rabbit. In the rabbit the quantity of methyl violet which produces only a slight conjunctivitis in man, sets up a violent suppuration, ring abscess and panophthalmia.

Vogt[12] experimented on rabbits' eyes, finding that the severity of the conjunctival inflammation depends upon the chemical nature of the aniline producing violent inflammation or panophthalmia.

Morrison[13] reports two cases, in one of which edema of the lids and conjunctiva occurred. The pencil point stayed in ten days. Inspection of the upper cul-de-sac only after that time on account of great swelling. V. = 6/xv followed. In the second case pencil point imbedded in the cornea was removed the following day. Corneal stain remained thirty days later.

Enslin[11] reports three cases in which dust and pieces of methyl violet of ink pencils had entered the conjunctival sac. In two adults, recovery with normal vision took place, while in a boy, aged 9, diffuse keratitis, ulcer with hypopion, developed. The bacteriologic examination was negative, and the ulcer healed with a dense macula. V. = 6/xviii.

Mellinghoff[14] reports a case in which dust of pure methyl violet was placed into the left eye of a patient. The eye was at once washed out with water and a weak sublimate solution, but severe keratitis with anterior uveitis, lasting opacities and final V. = 6/xv followed, requiring treatment for months.

Natanson[15] reported two cases, one in which the pencil point remained two days, staining and irritation remained three days longer. In the other dried violet ink flew into the eye, and staining and irritation remained after removal.

A. C. Snell[16] reports the case of a child who had a point of an indelible pencil fly into the eye. She was seen one hour after the accident when there was a marked swelling of the lids, spasm of the orbicularis, photophobia, profuse lacrimation, tarsal and bulbar conjunctivitis, edema, stained deep purple. Cornea steamy, lustreless, rough, and slightly stained. Pencil point found buried deep in swollen conjunctiva midway between limbus and caruncle. Pain severe. Vision reduced to fingers 10 feet. Piece of aniline pencil 6 mm. long removed from wound with forceps. Crescent of darkly stained fluid in the anterior chamber from aqueous stained by absorption of aniline color getting to bottom of anterior chamber. Inflammatory symptoms severe for three days. Recovery with no trace of color after two weeks.

John Dunn[17] reports two cases of enucleation of the eye as a result of the presence in the conjunctival sac of a piece of analine pencil. In both cases the piece of analine lead had remained under the lid for four days before being removed. That part of the conjunctiva and sclera that had been in contact with the pencil was necrotic and the reaction and pain so severe as to necessitate enucleation.

Diagnosis. From appearances, the blue tears, burning and history.

Prognosis is generally good. A few have recovered with leucoma of the cornea if the cornea ulcerated.

Treatment. Removal of the pieces of the intruding substance; boric acid wash; cold compresses; antiseptic ointments.

I have seen no cases of severe injury to the eyes from formalin, although one of the servants of the health department came to me some time ago complaining of great smarting of the eyelids and conjunctiva which resulted from his using formalin in disinfecting houses.

Sager[18] states that one drop of a 40 per cent. solution was accidentally dropped into the eye of a patient. It was washed out with water within fifteen seconds. No pain experienced until six hours afterward, when eye became very painful and much inflamed. The cornea was steamy. Six months later cornea was still slightly opaque with vision reduced more than one-half. Therapy as in acids.

Powell[19] had two cases of burn of the eye and eyelids with potassium permanganate crystals. In each case the lids were ecchymotic. Therapy: Large quantities of water; then as in acids.

Stieren[20] reported three cases of phenol burns, all of which made perfect recoveries. The feature of these cases was that the corneal opacities sloughed off, leaving the cornea clear.

Carter[21] reports the case of a woman who dropped this strong escharotic into her eyes by mistake. She was seen in less than five minutes. The lids were so edematous that the eye could hardly be opened. The lower half of the cornea was found to be perfectly white; the eyeball burned considerably. Alcohol was instilled, followed by 2 per cent. cocain, and atropin, gr. 3 to the ounce. Both eyes were kept bandaged, but irrigated twice daily. The film of an egg was used to prevent adhesion of the lids to the globe, together with a small amount of antiseptic ointment. A narcotic was necessary to relieve the pain. The patient recovered with 20/xx vision; no adhesion and no deformity.

The ingestion, inhalation, epidermic, hypodermic, endermic, intramuscular, or any other method by which certain toxic substances may get into, or be developed within, the system, induces changes in the tissues of the eye by which diverse effects are produced, denominated under the term of Toxic Amblyopia.

Among the commonest drugs and poisons thus affecting the eye are alcohol, tobacco, iodoform, naphthalin, caffein, acetanilid, salicylic acid, atoxyl, arsenic, felix mas, santonin, and pomegranate, to which some persons have an idiosyncrasy, particularly as regards damage to vision and the eyes, even in medicinal doses.

For the further elucidation of this subject I must refer to the well-known publications of de Schweinitz,[22] Casey A. Wood,[23] Emil Berger,[24] and Max Knies.[25]

LITERATURE.

1. Blaauw, *Ophthalmology,* Apr., 1906.
2. Priestley-Smith, *Ophth. Rev.* xii, 1893.
3. Russell, ref. Blaauw.
4. Hutchinson, *N. Y. Med. Journ.,* xliii, 1886.
5. Hirschberg, *Centralbl. f. prak. Aug.,* vi, 1882.
6. Valude, *Ann. d'oculist.,* cix, 1893.
7. Terson, ref. Blaauw.
8. Spengler, *Zeitschr. f. Aug.,* xv, 1906, p. 441.

9. Krauss, *Ophth. Record,* March, 1908.
10. F. Park Lewis, *Ophth. Record,* June, 1908.
11. Enslin, *Zeitschr. f. Aug.,* xv, 1906, p. 441.
12. Vogt, *Arch. f. Ophth.,* Apr., 1906.
13. Morrison, *Ophth. Record,* Jan., 1905.
14. Mellinghoff, *Klin. Mon. f. Aug.,* xiv, ii, 1906, p. 34.
15. Natanson, *Zeitschr. f. Aug.,* xi, p. 312.
16. A. C. Snell, *Ophthalmology,* Jan., 1910.
17. John Dunn, *Arch. Ophth.,* March, 1910.
18. Sager, *Ophthalmoscope,* Feb., 1906.
19. Powell, *Ophthalmoscope,* July, 1905.
20. Stieren, *Ophth. Record,* Nov., 1904.
21. Carter, *Journ. A. M. A.,* July 7, 1909.
22. de Schweinitz, *The Toxic Amblyopias,* Phila., 1896.
23. Casey A. Wood, *The Toxic Amblyopias,* Chicago, 1892.
24. Emil Berger, *Les maladies des yeux, dans leurs rapports avec la pathologie generale,* Paris, 1893.
25. Max Knies, *Die Beziehungen d. Sehorganes u. seiner Erkrankungen z. d. übrigen Krankheiten d. Körpers u seiner Organe.* Weisbaden, 1892.

CHAPTER IX.

DIAGNOSIS OF INJURIES TO THE EYE.

History—Inspection—Eversion of lids and retrotarsal folds—Fluorescein—Magnification—Focal illumination—Ophthalmoscopy—Diaphanoscopy—Ophthalmodiaphanoscopy—Ophthalmofundoscopy—Sideroscopy—Metallophon—Magnets—Literature.

The diagnosis of injuries to the eye is made by subjective and objective examination, of which the history, symptomology, and the visual acuity, field, condition of the ocular musculature and the refraction are given their proper consideration.

Objective examination by direct and focal illumination, the ophthalmoscope, diaphanoscope, sideroscope, magnetic attraction and the X-ray offer exact means of diagnosis.

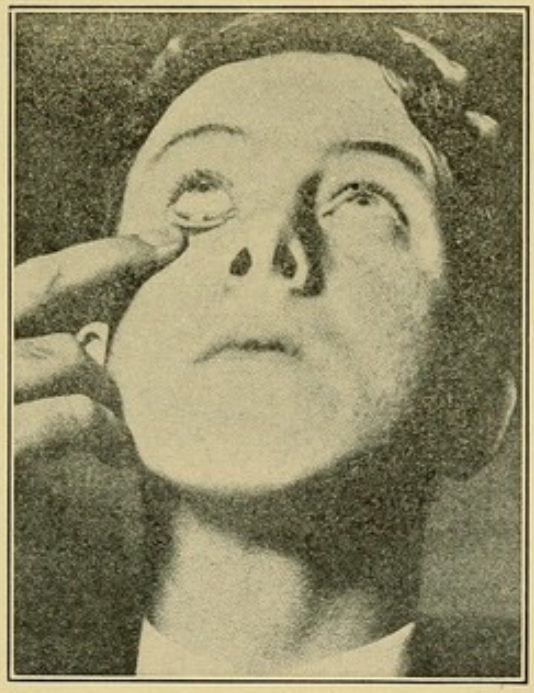

Fig. 40.
Everting the lower lid.

A careful history should be obtained, giving the date and hour of the accident, the character of the work and surroundings, the instrument concerned, object or foreign body causing the lesion, and, in special cases, the names of the witnesses to the accident; also the character of attempts

to remove a foreign body, and whether or not the case has been attended by a physician, are facts that should be elicited. Remember that while the interests of the patient are of prime importance, yet we should be guarded in our prognosis, as it depends very largely upon previous injuries and the character of the first dressing. We should never give an opinion reflecting upon the first consultant, or as to the liability of the employer, for these are theories that the lawyers may be allowed to fight about and the courts to decide. The less we have to do with the legalized human parasites who are in the habit of soliciting personal damage suits, the better it is for the physician, and we should not

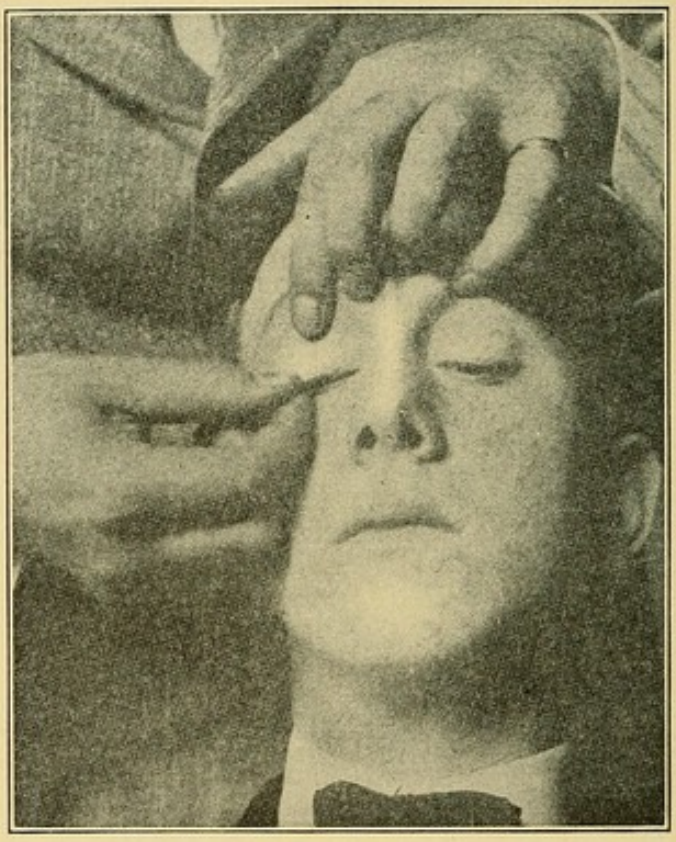

Fig. 41.
Everting the upper lid; first act.

furnish information in advance upon which a personal damage or malpractice suit might be based.

Usually an examination may be conducted without a local anesthetic, as cocain or holocain, but such are frequently needed to subdue irritability; adrenalin to lessen congestion, and cocain, homatropin, euphthalmin, or atropin for mydriasis. The visual acuity, and in some cases the visual field, muscle balance, duction and versions, the refraction, etc., should be ascertained. In fact, in medico-legal cases a full examination should always be made, and sketch drawings or water colors may be made, as well as

full notes taken. The literature of the subject should be looked up, as then the medical examiner, as a medical witness, will be fully prepared for his own answers in court. The demeanor, willingness of the patient

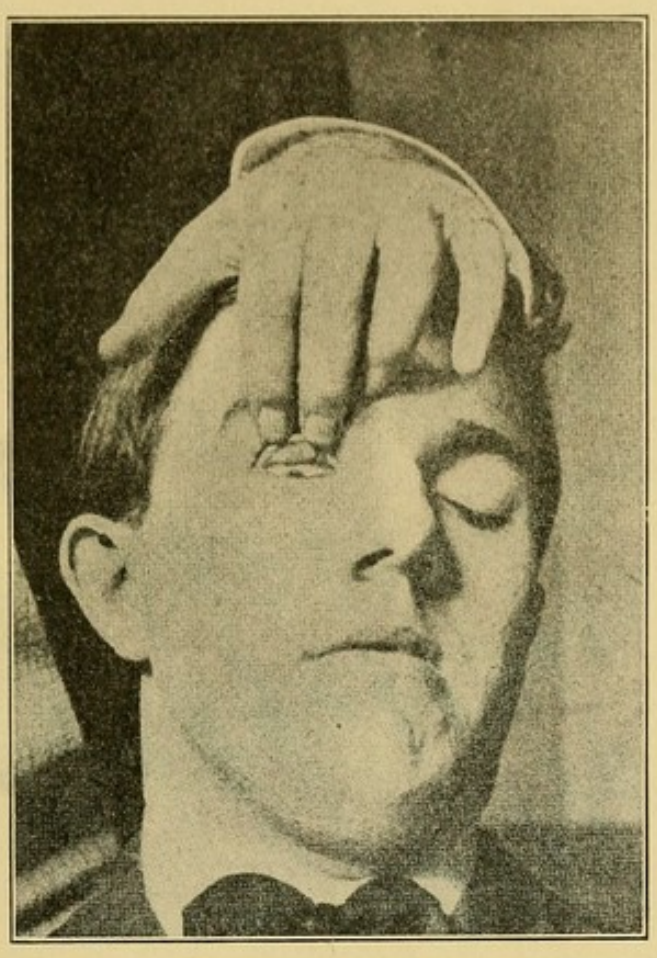

Fig. 42.
Complete eversion of the upper lid.

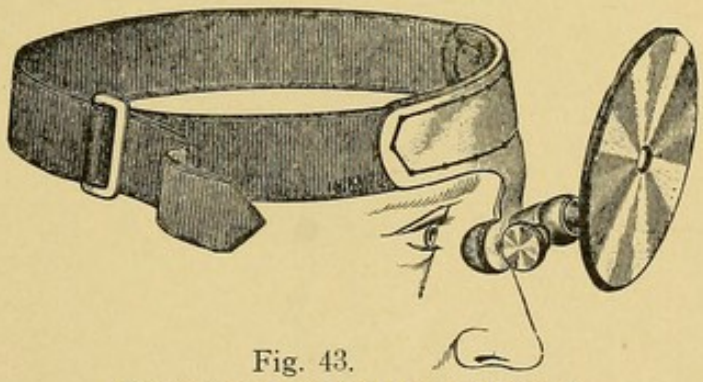

Fig. 43.
Reflecting head mirror with band.

and actions of his companions should be noted as thereby hints as to malingering may be obtained.

Owing to the transparency, translucency, and delicacy of the ocular structures a number of special methods of examination are of help, of

which general inspection by direct and reflected light should first be used.

Objective examination. Inspection by direct illumination by day light, electric light or reflecting mirror is first

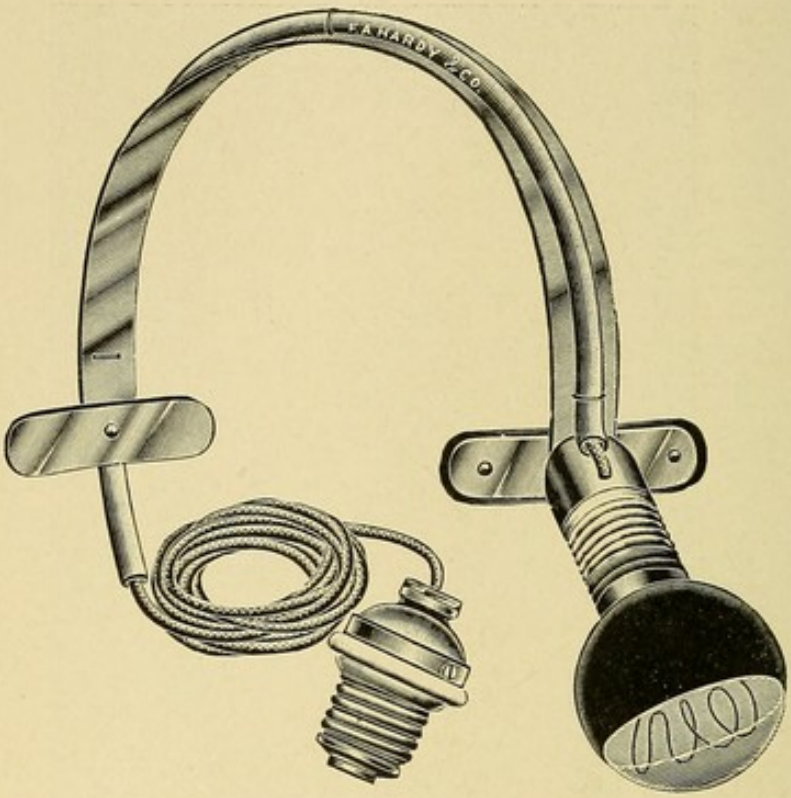

Fig. 44.
Stucky's head light.

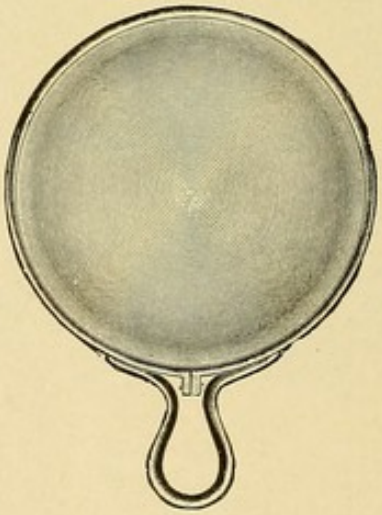

Fig. 45.
Condensing lens.

made. The skin, lids, cornea, conjunctiva, puncta lacrimalia, etc., are observed. Then the retro-bulbar folds and under surface of the lids are brought into view by eversion with the fingers, but preferably by pushing

down the retrotarsal folds by a smooth instrument, as a small glass rod, handle of an instrument, or cotton-tipped stick, as it is here that most diseases of the conjunctiva are prominent and foreign bodies may be impacted therein.

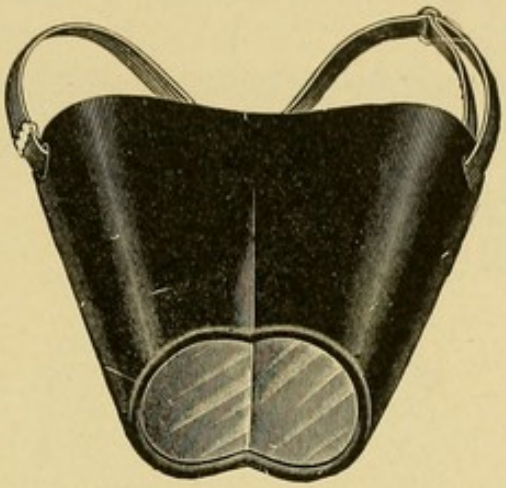

Fig. 46.
Berger binocular loupe.

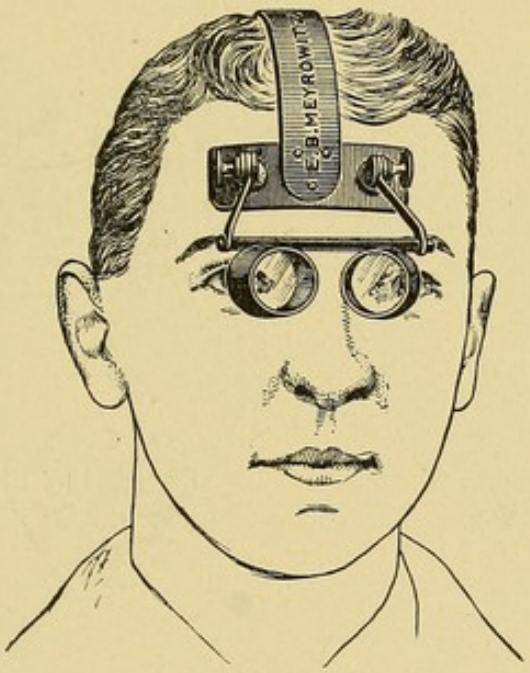

Fig. 47.
Jackson's binocular loupe.

Many small and otherwise almost indistinguishable abrasions of the corneal epithelium, wounds and small foreign bodies in the cornea, may be brought into view by the staining of the tissues by a 2 per cent. fluorescein and 2 per cent. bicarbonate of soda solution. This aniline dye will

not stain the intact corneal epithelium, but readily passes into the subjacent parenchyma and abraded epithelial cells, forming a bright green background upon which foreign bodies are readily perceived.

Magnification of the eye by a lens, preferably by the Berger or Jackson binocular loupe, is of great value.



Fig. 48.

Würdemann transilluminator and focal lamp.

Focal illumination in the dark room is ordinarily carried out by focusing the light upon the eye by a large loupe. The use of the diaphanoscope for this purpose gives, however, a much better illumination, as the light is confined to a narrow beam. The author's transilluminator is the size of an ordinary fountain pen and is as readily handled.

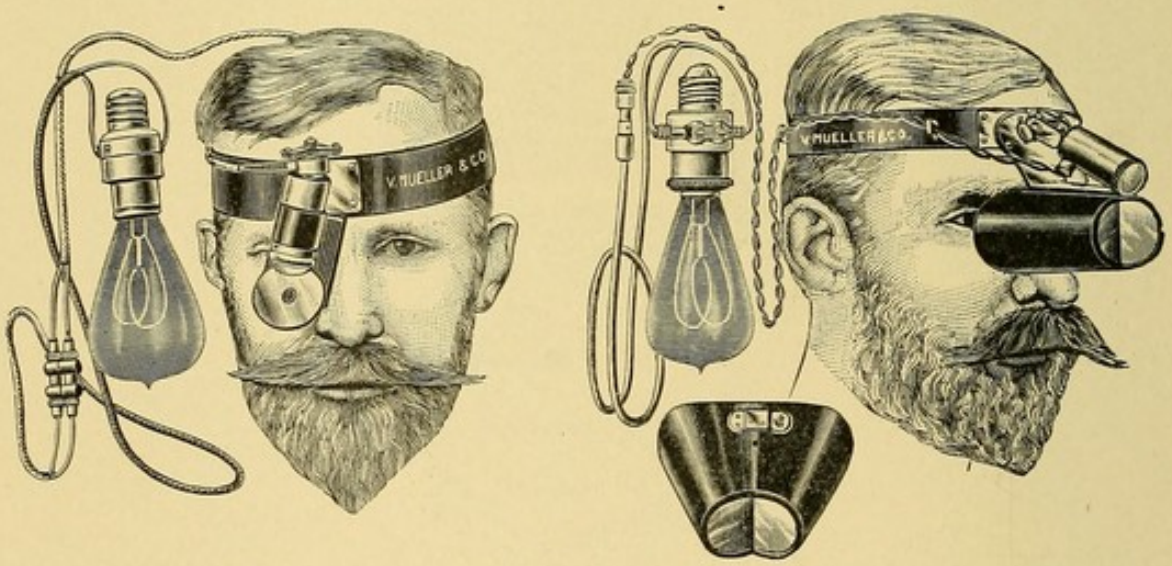

Figs. 49-50.

Kierstein's electric headlight combined with ophthalmoscope mirror for use in intraocular operations and combined with the Berger loupe for corneal and anterior chamber operations.

The opthalmoscope should first be used at a distance of a couple of feet from the eyes and magnification obtained by use of a +3.00 to +16.00 lens in the instrument, the patient being directed to look in various directions, whereby a foreign body may be brought into view against the red background of the fundus; approaching closer to the eyes,

after the cornea and anterior chamber have been examined in this manner, the lens, vitreous, and fundus are then successively investigated. The electric ophthalmoscope with light regulated by a rheostat gives the most elastic means of such examination.

Trantas[1] says, according to Groenouw[2] and Dimmer,[3] ophthalmoscopic examination of the ciliary region is practicable only to

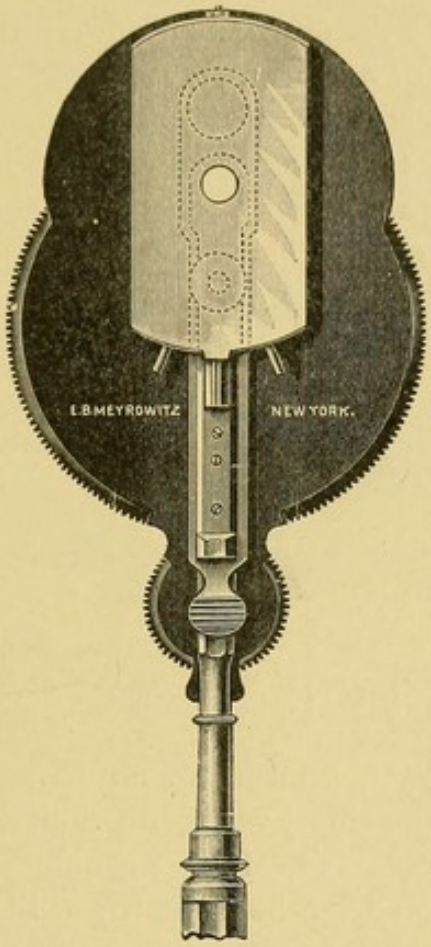

Fig. 51.
Roth modification of the Loring ophthalmoscope.

within 8 mm. or 8½ mm. of the limbus; therefore, not only the ciliary region, but the ora serrata and a part of the chorioid and retina of 1 mm. to 1½ mm. are considered invisible. He claims that by digital pressure of the region, from the equator to the root of the iris, while examining by the direct image with a + 4 D. to + 8 D. glass, it is possible to see perfectly not only the extreme periphery of the chorioid and retina, but the ora serrata and the ciliary arch even to the ends of the ciliary processes.

Next to the posterior pole this region is the most vulnerable part of the fundus, as it is most important in the nutrition of the eye, and it comprises nearly a quarter of the whole fundus.

Hirschberg[4] says not much attention has ben paid in ophthalmoscopic atlases to these conditions, although they are of great practical importance. He gives in detail the clinical history of two cases, representing the two chief types of cicatrices remaining after successful extraction of foreign bodies, viz., the simple and the one characterized by a bluish-white pyramid in the vitreous spreading towards the point of entrance.

The third case showed in a classical form the progressing changes of pigment, subsequent to the obstruction of retinal arteries by the entering piece of iron in spite of its uncomplicated extraction, with hemeralopia due to the pigment degeneration, not to toxic action on the ganglion cells. The nasal retinal arteries were converted into bluish-white streaks and the vitreous contained opacities interwoven with threads and membranes. He emphasizes that the effused blood was not absorbed eighteen months after the accident and that the changes of the fundus were not yet completed.



Fig. 52.
DeZeng modification of the Loring ophthalmoscope. Electric lighted.

Diaphanoscopy is a means of rendering the eyeball luminous, whereby the shadow of the ciliary body, iris, tumor, or large foreign body within the eye may be observed. I have a number of times determined the presence of foreign bodies behind the iris in the lens or in the fundus by this method, which were at first indiscernable by other methods.

Lange[5] claims to have devised the trans-illlumination of the sclerotic for differential diagnosis between intraocular tumor and simple serous detachment of the retina or chorioid, and a number of lamps have been built for that purpose by several observers, but they are all heavy, heating, and expensive except the author's lamp, which is now in common use.[6] The entire instrument is about the size of a fountain pen. The source of light is a miniature lens-tipped, five-candle-power electric bulb. The light is conveyed to the eye through a cylinder of glass, which runs from the lamp through a cone-shaped rubber tip 2½ cm. long. The lamp is connected by cords running through and out of the handle to a small storage battery, or connected with the commercial lighting circuit through a rheostat. The instrument which he devised had the advantage over

others already known in being very light and handy and being made almost entirely of a slowly-heating material, an advantage not possessed by the instruments of Leber and Sachs. In injuries the lamp may show the foreign body or the course it has taken in an eye; in irido-dialysis the extent of the affection. In secondary cataract the different thickness of various parts is indicated by the brightness of the strata; secondary mem-

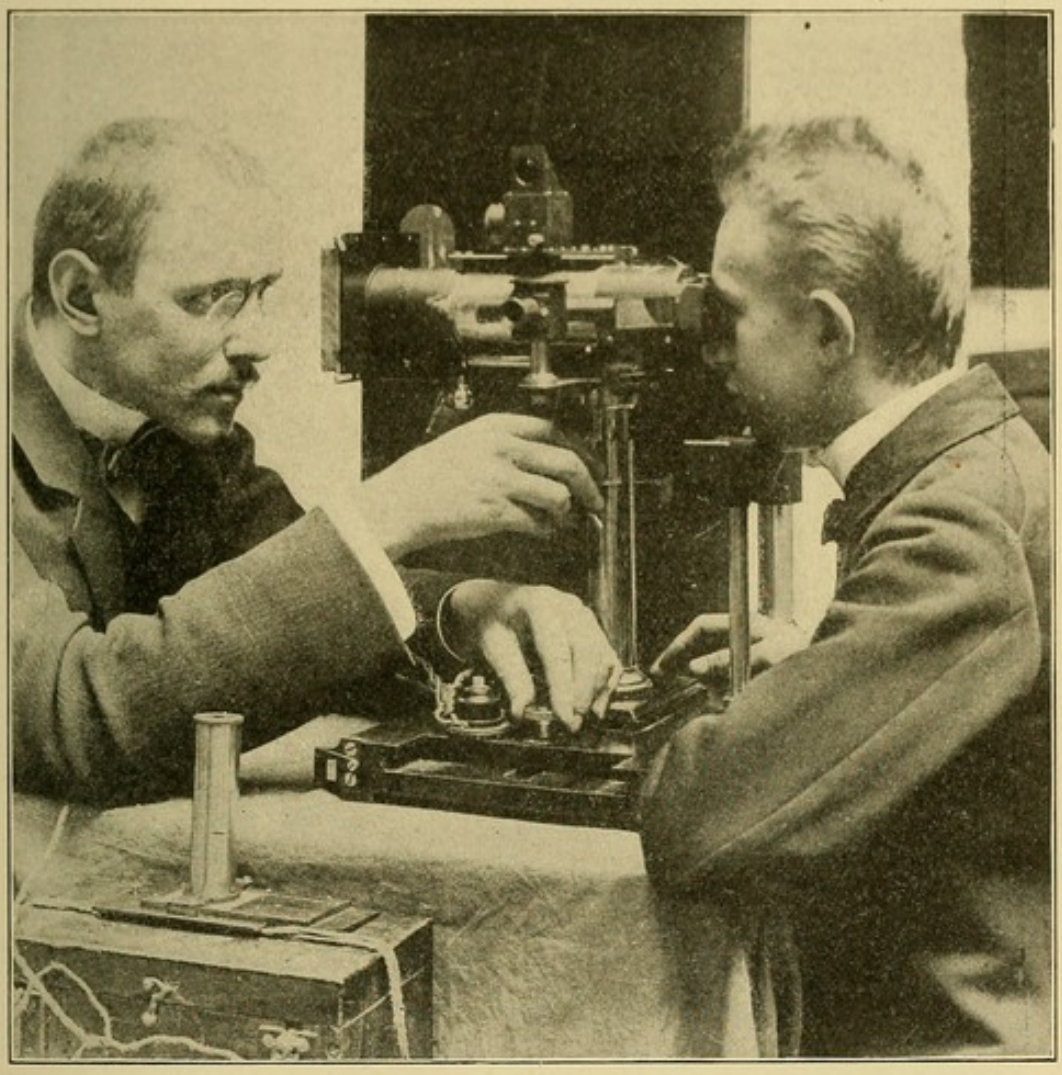

Fig. 53.
Max Thorner's stationary ophthalmoscope.

branes are made visible in the pupil or vitreous; and the shadow of foreign bodies may be seen, even though the pupil be opaque.

Ophthalmo-diaphanoscopy is a modification of diaphanoscopy lately introduced by Hertzell[7] for inspection of the fundus of the eye and of objects behind the globe in transmitted light by transillumination of the orbit from the naso-pharynx. The Hertzell ophthalmodiaphanoscope is introduced into the mouth and gives a light of 50 candle power, the effect of which is increased by suitably arranged re-

flectors. The face, except the eyes, is covered by a black mask. An ophthalmoscopic view is obtained by direct inspection without other means. Cases of ametropia necessitate correcting glasses for the observer. Its object is to test the fundus for differences of transparency. Opaque objects on the surface of the fundus appear perfectly distinct. Those behind



Fig. 54.

DeZeng set of electric ophthalmoscope, skiascope and Würdemann's transilluminator.

the eyeball are noticeable by shadows proportional to their size, so foreign bodies in and behind the globe may sometimes be diagnosed by this method.

Baum[8] describes the ophthalmo-fundoscope, his new instrument for the examination of the fundus with a magnifying power of over 70, not attained before, and giving pictures without reflexes. It consists of a tube similar to that of a telescope, 10 cm. long. The anterior

part is separated in two sections, one for the elctric lamp, the other for the objective lens, which receives no reflected rays from the cornea, so that the ophthalmoscopic picture is not disturbed by reflexes. The posterior portion has an ocular lens just like a microscope. The adjustment for the eye of the observer is obtained by moving the ocular lens in the same fashion as in a telescope. By removing the objective lens the instrument can be used as an ordinary ophthalmoscope and, by adding a Recoss' disc, also for the determination of refraction. Examination of the inverted image is possible by inserting a small conic tube with a lens + 13.00, with the advantage, however, that the corneal reflex is excluded.

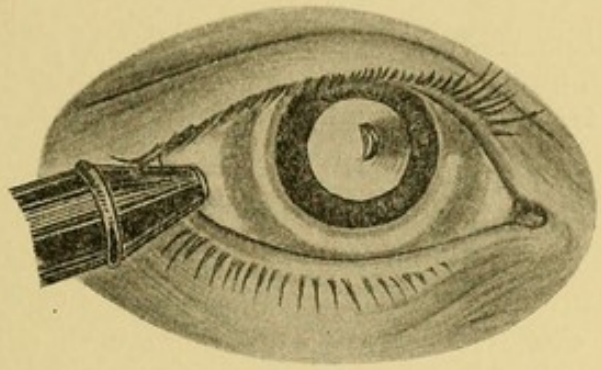

Fig. 55.

Diaphanoscopy of the eye, showing a foreign body in the vitreous, its shadow, and the circumlental space. The pupil is shown moderately dilated, the root of the iris shows as a dark ring about the limbus, then a clear ring is seen, which is the circumlental space, surrounded by another dark ring caused by the shadow of the ciliary processes, outside of this ring the sclera is brilliantly illuminated. In the drawing the differences in illumination are slightly emphasized and the lighting of both sides of the globe are equalized. In practice the conditions are best observed on the opposite side to that which the tip of the transilluminator is applied. The drawing is semi-diagrammatic.

K ü m m e l[9] describes several cases examined with the new instrument and thinks that its greater magnifying power will reveal finer changes of the background than the ordinary ophthalmoscope.

The S i d e r o s c o p e, devised by A s m u s,[10] if properly made and mounted, will determine the presence of a foreign body, but it must be magnetic, and the accuracy with which you are able to locate foreign bodies within the eye often varies from 1 to 3 cm. It is obvious that this is not accurate enough when we are dealing with such a structure as the eye. Then we must exclude any magnetic influences around it that would cause an error.

The range of its influence is therefore so small that it is far superceded by the use of the Röentgen-rays. So many foreign bodies are non-

magnetizable, as manganese and some of the alloys of iron and steel, that the sideroscope has outlived its usefulness. It is said that even small particles of iron dust which are apt to be in the workman's hair, will affect the sideroscope's precision. Proximity of electrical currents or a telephone system will also affect its reliability.

Jung[11] says the diagnosis of intraocular pieces of iron by siderоscopy requires a great deal of patience and is subject to certain sources of error which, if ignored, may lead to wrong diagnosis.

This fact he illustrates by two cases. In the first, a piece of iron, lodged in the cheek from a former injury, caused a misleading reaction from the sideroscope, but was detected by Röentgen rays. In the second case the sideroscope indicated that a large foreign body in the eye, disclosed by Röentgen rays, must be iron, whereas all attempts to extract it with giant and hand magnets failed. The eye was later on enucleated on account of cyclitis, and the foreign body proved to be an arrow of copper and zinc, which frequently contains iron.

Jung shows the great value of the sideroscope in cases in which the giant magnet failed, for giving negative proof of iron in the eye. The most dangerous cases in that respect are those in which the foreign body enters laterally through the sclera, and which do not come at once under treatment. Jung saw five cases of blindness with siderosis in which a foreign body had been overlooked. This would have been avoided if sideroscopy had been employed. If the registrations of the sideroscope are too indefinite, the Röentgen ray must be resorted to.

The writer gives the history of an instance in which a scale of metal, 0.5 by 2.5 mm. in size, had entered an eye, and yet there was no deflection of the sideroscope, although a few days later the deflection was very positive. The patient was seen forty-eight hours after the injury; there was a clean, perforating wound of the cornea and anterior capsule of the lens; the latter was opaque, the anterior chamber was shallow; pupil dilated and irregular at its lower temporal margin. Repeated trials with a 500-volt magnet gave negative results and many careful trials with the sideroscope in every position were also negative. A radiograph showed a foreign body within the eye a little anterior to the equator. Several days later, the sideroscope was again used and there was always marked deflection when the region about the temporal margin of the inferior rectus was approached. An attempt to bring the foreign body into the anterior chamber having failed, it was removed by a scleral incision and the use of a small 50-volt magnet; healing progressed favorably, the lens was absorbed, and the V.=20/xxxviii with correction.

The explanation of the negative result must be that the foreign body was in a firm clot of blood, or in a mass of exudate, and beyond the field

of the magnet. My conclusion is that when a Röentgen-ray picture cannot be obtained, a single examination with the sideroscope, if negative, should not be relied upon, but that at intervals of a few days there should be several successive examinations. Kanzel[12] says it is absolutely necessary to examine every suspected case with the sideroscope!

Ewing,[13] in several trials with the sideroscope, knowledge being obtained by the subsequent removal of the fragment from the eye, demonstrated that the instrument could be depended upon at a distance of from five to six millimeters. Asmus[10b] localized a piece of brass with-



Fig. 56.
The sideroscope of Asmus.

in the eye by the sideroscope. This piece must certainly have contained traces of iron.

Perlmann[14] reports a new method devised to read the deviations of the magnet on a screen, doing away with the telescope, which is laborious and time-consuming. To render the image of the flame brighter and more distinct the lamp is provided with a lens in an adjustable tube, which is placed near the mirror in the sideroscope, upon which its rays

are directed. The image is reflected on a screen 1 m. distant from the mirror, cut on the screen are the tangents of the single angles. Therefore, the tangents of the single angles are registered on the screen as the measures of deviation.

The sideroscope or magnetic needle is not applicable in large cities on account of the constant vibration of buildings from passing traffic, as well as the vagaries of vagrant electric currents. As H. Knapp[15] and Haab[16] remark "The instrument is a marvel of delicacy, but to handle it requires the patience of a saint."

Asmus[10a] gives the following directions in order to obtain reliable registrations of the sideroscope: "The apparatus must be well fixed. The magnetic needle must always be hung free; it must be magnetized every year. The foreign body must be made magnetic by influence in the right sense. The cocainized eye must be skillfully approached to the glass tube of the needle. For localization of intensely magnetic pieces the damp needle must be employed. If maximal deviation is lacking, the examination must be made with the telescope."

Asmus considers the sideroscope, kept in good order, indispensable for the diagnosis of the presence of iron hidden in the interior of the eye.

Koster[17] has invented an apparatus to prevent the disturbing influence of electric street cars on sideroscopes. Observing that the north pole of the sideroscope was always attracted by the street current he, therefore, kept this pole turned toward the street current by hanging the magnetic needle of the sideroscope vertically to the current by means of a small artificial magnet, and thus produced an artificial magnetic meridian vertical to the street current. This meridian is the result of the forces of the artificial magnet and the earth magnetism. The influence of the street current was removed and the reaction of the sideroscope intensified, as a piece of steel of 3 mg., 9.75 cm. distant, caused a deviation of 20 points.

Ewing[13] esteems the instrument dependable, but cites an instance where the foreign body was in a firm clot of blood and gave negative reactions to both the 500-volt magnet and the sideroscope.

The Metallophon of Weiss[18] is an apparatus for the detection of metallic (also other than iron) foreign bodies in the eye. The apparatus is practically a Wheatstone bridge which measures the electric resistance of the tissues of the eye between two electrodes applied on the sclera at different points. A relatively small piece of metal placed between the electrodes increases the resistance and is indicated by the ringing of a telephone bell connected with the wire measure. Only very weak currents are to be employed.

The giant magnet of Haab, the large Victor mag-



PLATE III

Lens—Direct ophthalmoscopy.

A. Steel chip in capsule; capsular cataract.

B. Steel chips in lens; opacity of lens.

C. Injury to capsule from end of keratome in iridectomy for glaucoma, two weeks after.

D. Partial dialysis of iris; posterior capsular and lamellar cataract. Injury from handle of file, one year after.

net, the Interpole magnet of Mellinger, and other large magnets will reveal the presence of magnetizable pieces of steel and iron by causing traction within the eye, varying from a drawing sensation to decided pain on approach of the eye to the magnet. The foreign body may likewise be drawn into view, or the eye may adhere or curve forwards towards the magnet if the body be sufficiently large. Such a method of examination is, however, somewhat dangerous, on account of the foreign body while approaching the magnet acting as a missile and tearing structures that might not have been previously injured. In such examination the eye, needless to say, should not be anesthetized.

Hirschberg[4] and most authorities oppose the practice of bringing a freshly injured eye, in which the presence of a piece of iron is suspected, immediately before a giant magnet for diagnostic purposes; the supposition that when the patient feels no pain during the action of the giant magnet there is no iron in the eye, is erroneous.

The increasing use of magnesium and nickel steel renders the number of non-magnetizable foreign bodies somewhat larger in proportion than previously.

Asmus[10a] says, that as much as the general introduction of the giant magnet is to be hailed as a therapeutic progress, the superficiality in using it for diagnostic purposes is to be regretted. Forty-three of his patients felt pain when the giant magnet was employed, while 14 showed not the least reaction. Therefore a negative reaction to the giant magnet does not indicate that there is no foreign body in the eye. In all these 14 cases the Asmus' sideroscope revealed distinctly the presence of iron, which was extracted.

One tragic case is reported in detail, in which Röentgen rays, giant magnet and sideroscope in a large clinic gave negative results. After a year, when the patient came to Asmus, vision was reduced to 6/xxiv. Asmus located the seat of a piece of iron with his sideroscope and extracted it.

The differential diagnosis in the case of contusions of the soft parts of the lids and orbital tissues is of supreme importance, for in the one case a simple black eye may be the sole lesion, and yet in another this may be but a symptom of serious fracture of the orbital bones or base of the skull.

A general differential diagnosis between certain ocular diseases, conditions, and injuries cannot always be made, but suffice it to say that many ocular diseases have their exciting element in trauma; most of such are made worse by an injury; and in others disease predisposes towards injuries. This subject is further handled more particularly under the special chapters.

LITERATURE.

1. Trantas, *Arch. d'ophtal.*, Sept., 1907.
2. Groenouw, ref. Trantas.
3. Dimmer, ref. Trantas.
4. Hirschberg (a) *Centrbl. f. prak Aug.*, April, 1907; (b) *Med. Blaetter*, Sept., 1907.
5. Lange, *Klin. Mon. f. Aug.*, p. 410, 1884, and p. 362, 1906.
6. Würdemann, (a) *Ophth. Record*, Nov., 1906; (b) *Jour. A. M. A.*, June, 1906; (c) *Ophth. Rec.*, Jan., 1908; (d) *Ophth. Rec.*, Apr., 1908; (e) *Ophth. Rec.*, July, 1908.
7. Hertzell, *Berl. Klin. Woch.*, 47, 1907, and 24, 1908.
8. Baum, *Klin. Mon. f. Aug.*, 1909.
9. Kümmel, *Klin. Mon. f. Aug.*, p. 271, 1908.
10. Asmus, (a) *Klin. Mon. f. Aug.*, 1, 1908; (b) *Klin. Mon. f. Aug.*, Apr., 1910, p. 444.
11. Jung, *Klin. Mon. f. Aug.*, p. 271, 1908.
12. Kanzel, *Klin. Mon. f. Aug.*, Supplement, Feb. 1910, p. 174.
13. Ewing, A., *Amer. Journ. Ophth.*, May, 1904.
14. Pelmar, *Zeitschr. f. Aug.*, Dec., 1904.
15. Knapp, H., ref. Haab.
16. Haab, O., *Trans. Sec. Ophth. A. M. A.*, 1902.
17. Koster, *Arch. f. Aug.*, IIX, p. 49.
18. Weiss, K. E., *Centrbl. f. Aug.*, p. 100, 1906.

CHAPTER X.

DIAGONSIS (CONTINUED). RADIOGRAPHY.

Value of ophthalmoscope—Dangers following magnet application—Copper in eyeball—Size of average adult globe and variations—Foreign bodies in anterior surface of lens and iris—Sweet's series of 420 cases—Occurrence of foreign body of the right eye in right-handed individuals—Kinds of X-ray tubes—Position of tube in taking radiographs—Coil of greatest usefulness—Time of exposure—Table of permeability—Position of patient—Fox's method—Sweet's method (improved)—Carman's method—Vard Hulen's method—Dixon's method.

THE LOCALIZATION OF FOREIGN BODIES WITHIN THE EYE AND ORBIT BY MEANS OF THE X-RAYS. BY A. MORGAN MACWHINNIE, SEATTLE, WASH, U. S. A.

The exact determination of the existence, position and size of foreign bodies within the globe has only become possible since the advent of the Röentgen rays. Formerly entire reliance was placed upon the ophthalmoscope to determine whether a foreign body was present or not. This answered very well for cases that were easily seen, and especially for foreign bodies located in the anterior part of the globe. So many cases are seen by the oculist several days after the original injury that cataract formation from injury to the lens and cloudy media, in the majority of instances, precludes the use of the ophthalmoscope. Assumption that there was or was not a foreign body in the globe seemed to be a matter of intuition until the advent of the X-rays. Granted that a foreign body was in the globe, its exact position, whether in the ciliary processes, vitreous, lens, or the sclerotic, or even in the orbital tissue, was not known, and its removal was a difficult task. Incisions were made and forceps blindly inserted in the vitreous to grasp the foreign body. More failures than successes were naturally recorded.

This was followed by the use of the magnet, the smaller one of Hirschberg's first, and later by the giant magnet of Haab. As a means of diagnosis this method was a dismal failure in many cases, while in others irreparable injury to the structures of the eye resulted from drawing the metal through the globe. A negative magnet reaction did not preclude the possibility of a piece of steel being present in the eye, for many are the cases that are recorded where the magnet reaction failed

and the radiograph has shown the actual size and position of the foreign body.

As the frequency of injuries to the eye from flying copper increase in number each year, due to more extended use of that metal, largely from the increased use of electricity, the value of accurate radiographs becomes more apparent.

Injuries to the deeper portion of the eye by copper are considered to be of evil prognosis, and the observations of Leber[1] have shown that copper is very apt to arouse suppuration in the vascular parts of the eye, even without the introduction of bacteria. On the other hand, copper, when imbedded in the avascular parts, e. g., lens, may be borne. Early localization and removal is therefore imperative, although Caspar[2] reports a case of a piece of copper which entered the vitreous, at first being tolerated with the preservation of good vision. A year later a very painful irido-cyclitis made it necessary to remove the copper by grasping with iris forceps.

It is evident that radiography is essential for the complete examination in every case of penetrating ocular injury from foreign bodies, except in those rare instances where the media remain clear and the internal opening or foreign body is visible by the ophthalmoscope. In no other way is it possible for the surgeon at the time of injury to determine perforation of the posterior scleral wall.

With proper care of the fixed points of measurement, the X-ray operator should be able in every case to indicate whether or not a body has penetrated partly or completely through an eyeball, which corresponds in its dimensions with the average adult globe of 24 mm. in its antero-posterior diameter, the size employed in the diagrammatic charts used for localization. Any variation in the size of the eyeball under examination will, however, affect the relative position of the metal to the posterior scleral wall as indicated on the chart, although there is always a possibility of error in localization from inaccuracy in measuring the distance separating the indicator and the center of the cornea. High degrees of refractive error must influence the size of the eyeball, as has been pointed out by Hansell.[3] Moreover, Stilling,[4] from studies of the size of normal eyes of adults, shows that, irrespective of the refraction, considerable variation is present. From a large number of eyes examined he found that the longitudinal diameter varied from 20 to 25 mm., the transverse diameter from 20 to 26 mm., and the vertical from 20 to 24 mm. In three eyes, one of which was myopic (4.0 D.), one hyperopic and a third emmetropic, the length was the same, i.e., 24.5 mm., and the transverse and vertical diameters were nearly equal.

When the foreign body exists in the anterior surface of the iris or

lens it is manifest that it can be easily observed and extraction by means of the magnet is easily made, but 80 per cent. of the foreign bodies are so placed that they cannot be seen, and many are non-magnetic, due to the various carbon steels now so much in use.

de Schweinitz[5] reported several cases of traumatic cataract coming under his care during the last few years, the X-ray revealing a foreign body in the eye, of which the patient was totally unaware, the foreign body being removed before extracting the cataract.

I have had two patients who called at the office with a foreign body in their hand and were quite positive that there was no more present in the eye, requesting only treatment. In both cases the radiographs demonstrated that there was a foreign body within the eye, in the vitreous in one case and the posterior ciliary region in the other. The time necessary for radiographing is so short, and the structure of the eye of such importance, that the loss of an eye from the non-removal, or at least attempt thereto after proper radiographing and plotting, to me is a prima faciæ evidence of neglect on the part of the surgeon, and in these days of suit might constitute action for damages.

The results that we may expect are shown by a series of 420 cases reported by Sweet[6] in the following tables:

Position of foreign body.	First series.	Present series.
In the eyelid	1	2
In the lens	3	14
In iris, or posterior chamber	1	4
In the ciliary region	24	27
Near the equator	21	69
Posterior part of eyeball	12	46
In the orbit	3	11
No body found by X-ray	37	145
Total	102	138

The result of magnet extractions in 65 cases reported by Sweet is as follows:

Eyeballs enucleated.	First series.	Present series.
Extraction not attempted or failed	14	19
Extraction successful—enucleated later	8	26
Eyeballs not enucleated.		
No operation attempted	7	13
Bodies in the orbit or eyelid	4	9
Extraction failed	2	6
Extraction successful.		
Vision, between 6/6 and 6/12	7	20
Vision, between 6/15 and 6/60	4	13
Fingers or hand movements	0	7
Eyeballs enucleated.		
Good light projection	9	27
Light perception	6	21
No light perception, eye normal size	0	6
Eyeball shrunken	4	6
No bodies shown by X-rays	37	145
Total	102	318

Dixon[7] during a period of fourteen months examined 125 cases with 67 positive and 58 negative, the injuries being 6.8 per cent. more frequent on the right than on the left, probably due to the inclination of the head in right-handed individuals when working with a hammer.

This emphasized the importance of first examining an injury or traumatic cataract with the X-ray so as to determine whether or not a foreign body is in the interior of the eye. After localization by means of the rays and the chart system the foreign body is extracted by making an incision through the sclerotic as near as possible to the foreign body.

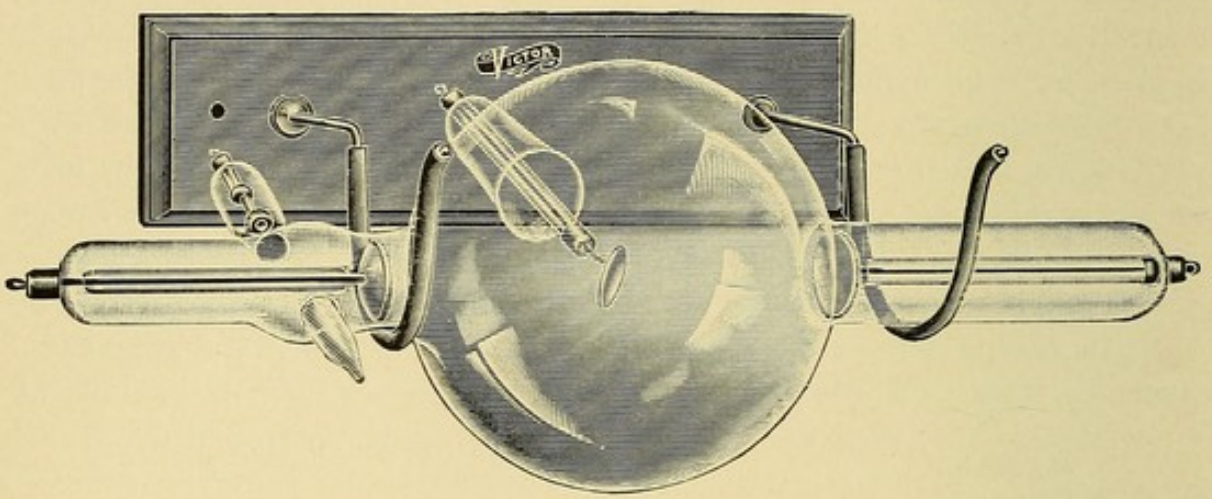

Fig. 57.
X-ray tube, self-regulating.

In the vast majority of instances the small magnet suffices where the foreign body has been properly located and the incision made over its site. The sooner the extraction the better the chance for useful vision.

There are practically two styles of tubes, one in which the vacuum is stationary and cannot be lowered except by puncturing and repumping. This tube is adapted for the low amperage found in the static form of current, heavy anodes being impracticable. The liability of the vacuum of this tube to vary, whether in use or not, puncturing often taking place when the vacuum was high, make its period of usefulness short.

The self-regulating tube is a larger type, consisting of a tube in which the vacuum can be either changed by the operator or automatically, and with a very heavy anode. It is so constructed that a smaller tube is connected to the larger bulb at the positive end, in which a somewhat smaller tube is enclosed. In this smaller one is placed any of several chemical substances (caustic potash, potassium permanganate, palladium, etc.), which will generate a gas upon applying heat, and reabsorb them

when cool. This is the type of tube which is now generally in use. The best results are obtained with a heavy anode and a medium hard tube.

Tubes are classified as soft, medium, or hard, according to the character of the rays which they give off. While this is not an accurate method, it is of practical use to the experienced operator. Really, we have not at present an accurate method of estimating the amount of rays, the degree of penetrability that any given tube will bring forth on excitation. The essential feature in using a tube is to have the anodal axis so placed that its rays are projected directly upon the part to be radiographed. These are the only rays to be reckoned with. The dispersion rays are of such a small amount, that they do not enter into consideration. When the anodal axis is placed as above, there is less time of exposure and a clearer and sharper radiograph results.

Due regard must be given to the distance at which the tube be set from the object to be radiographed, for we know that the elementary laws of physics in regard to light and shadows are to be here applied. If the tube is placed too close there will be an enlargement of the object, but it will lack a definite outline. It is therefore essential that for accuracy as to the size of the object, and for definite outline, the tube should be so placed that the actual size of the foreign body will be shown in the radiograph and aid us in acurate plotting of same.

Improvements in the manufacture of tubes have been made, but no accurate method of estimating the amount of rays and their penetration has been brought forth. The vacuum of a tube changes through use or after use so frequently that accurate estimation is not feasible. Using the fluoroscope to estimate the penetration by looking at the bones of the hand is bad and dangerous practice. The current, coil and interrupter make such a difference that it is only by experience with a combination of these that we are able to make good radiographs. Whether we use a coil or a static machine to excite our tube is immaterial, so far as actual results are concerned, but the added length of time over that of the coil, which is necessary with the static machine, is such that it is possible for a movement of the patient to take place during the exposures. The modern coil reduces the time from minutes to seconds.

Coil.

To obtain radiographs showing sharp details, requires a coil having a large secondary current output at a voltage sufficient to break down the resistance of the X-ray tube and send the sub-atoms against the target with sufficient force to give the proper quality of light for penetration.

For diagnostic or fluoroscopic work the current volume need not be so large, but the penetration must be greater because the fluoroscopic screen is not as sensitive as the photographic plate.

To obtain the best results possible, the coil should be so constructed that it will fulfill both of these conditions, but it is rarely that we can



Fig. 58.

Interrupterless X-ray and high frequency apparatus.

see foreign bodies in the globe with any degre of accuracy by the fluoroscope. Even if the foreign body can be seen, it is imperative that two radiographs be taken in order to make a proper plat.

To obtain the first, the cross sections of the secondary wire should be as large as possible, because with a lower secondary resistance there will be less drop of the potential in the circuit when a low vacuum X-ray tube is used, and consequently there will be less variation in the penetration of the X-rays if the vacuum does drop.

The best results in fluoroscopy are obtained with a small quantity of current used and a high voltage by which the necessary penetration is secured. The secondary winding must be so proportioned that the resistance is a direct ratio to the current generated at that electro-motive force.

This will result in an economical consumption of primary current and a greater saving in X-ray tubes than is possible if the primary current were large. One of the best that fills the above requirements is the Wappler coil from which most excellent results can be obtained when used with proper X-ray tubes.

Time of exposure.

The time of exposure will vary according to the kind of coil or static machine and the vacuum in the tube. I have made very good radiographs with an exposure of two minutes with a 12-plate machine of 32″ plates and a medium hard, self-regulating tube at 15″. With a good coil and a medium hard tube this time is reduced from minutes to seconds. Due consideration must always be allowed for the density of the patient's head, size of the object to be radiographed and the resistance the foreign body offers to the passage of the rays.

Table of Permeability of Röentgen rays. Bortello and Garbasso.[8]

Material.	Sp. gr.	Transparency.
Pinewood	0.56	2.21
Walnut	0.66	1.50
Paraffin	0.874	1.12
Bones	1.90	0.56
Glass	2.60	0.34
Tin	7.28	0.118
Zinc	7.20	0.116
Iron	7.87	0.101
Nickel	8.67	0.095
Brass	8.70	0.093
Gold	19.36	0.030
Platinum	22.07	0.020
Water	1.00	1.00

The prevailing opinion that stone, granite, glass and the like could not be shown by radiographs was dispelled by Mackenzie-Davidson,[9] who was the first to prove that the size and shape, as well as location, of a piece of glass in the eye could be shown by X-ray. This case was reported by Nettleship,[9] who saw the young man in January, 1899, six months after his eye was injured by the explosion of a chemical retort flask. The eye was subsequently enucleated and the findings of the radiograph verified.

Wm. Sweet[10] successfully radiographed and removed a piece of

glass from the left eye of an engineer struck by a splinter from an exploded lubricating glass. The foreign body measured 2 x 4 mm., being removed by iris forceps.

In a series of experiments to determine the degree of penetration of the X-rays to various substances, as glass, marble, granite, cement, etc., Sweet[10] placed particles of these substances in the inner canthus of a cocanized eye. The size of each was approximately 2 x 2½ mm. The result shows that all of these substances can be made visible if proper technique be followed. The figures show the density of shadows of each materials, the exposure being the same for all materials, coal being the only one used that failed to demonstrate a shadow of any usefulness.

Spratt[11] successfully located by the radiograph a piece of steel weighing less than a milligram, removing same by a magnet after incision, and resulting in normal vision.

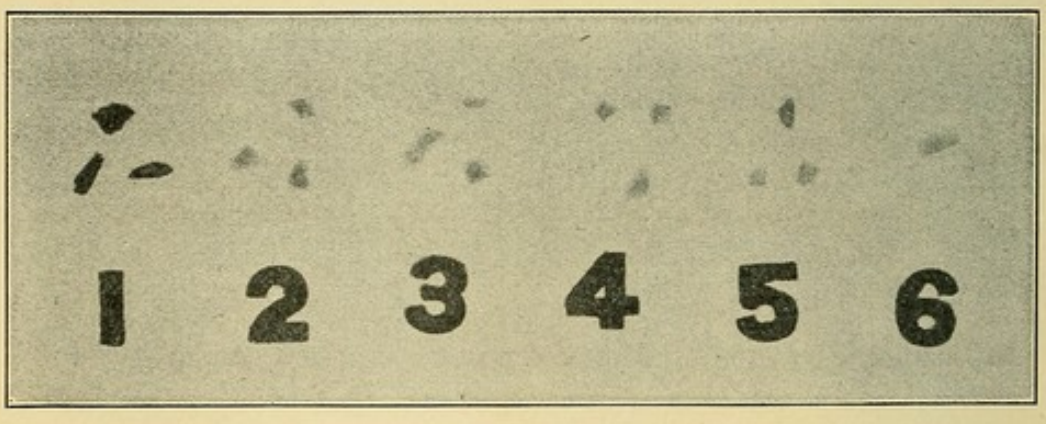

Fig. 59.

Skiagraph of various varieties of glass. 1. Lead glass. 2. Piece of lens. 3. Piece of chemical flask. 4. Piece of soda water bottle. 5. Druggist's green bottle. 6. Locomotive glass gauge. (One-half inch board between particles and plate. Exposure fifteen seconds.) (Sweet).

The belief existed before Davidson's[9] and Sweet's[11] demonstrations that it was impossible to reproduce radiographs showing shadows of other substances than metal. This was due to the fact that these objects offered very little resistance to the rays, and on account of the frequency with which the glass, stone, etc., might be broken into more than one piece. The plate showing only one shadow does not signify that there is no other present. Several plates should be taken with various timed exposures, which will show the larger as well as the smaller pieces, if more than one foreign body be present.

Position of patient.

The position of the patient is exceedingly important in the taking of a radiograph for the location of a foreign body, and should be one in



PLATE IV

Diaphanoscopic pictures.

A. Glass chip in vitreous.

B. Iron chip in lens; wound of iris.

C. Radial tears of posterior surface of iris: traumatic mydriasis.

D. Capsular opacity; dehiscences of posterior surface of iris; iridectomy with impaction of iris.

which there is but little chance of movement. It therefore becomes imperative that the head rest and guiding points, as well as the tube and plate holder, should be such as to insure perfect immobility during the exposures that are necessary in radiographing a foreign body.

Mackenzie-Davidson[12] and Vard Hulen[13] employ an apparatus in which the patient is in a sitting posture. This is open to criticism, for the patient may be in an uncomfortable position, and the breathing, whether abdominal or chest, may alter the relative positions of the head, plate and tube, either after all the adjustments have been made, before the first exposure, or between exposures one and two. Then again, there may be a sagging of the whole body. Dixon observed these errors and was the first to call attention to this fact, and as a result all of his exposures are now made with the patient in a recumbent posture, which permits of almost perfect relaxation, and very little chance of change in the position of the patient. This position was quickly adopted by Sweet, Weeks, and Carman. The majority of the radiographers at the present time are making their skiagrams with the patient recumbent.

Many small foreign bodies located in the vitreous may change their position after localization on the patient assuming the upright position. It follows that the advisable course to pursue is to keep the patient in the same position until the plate is developed and the chart made, requiring but a few minutes. Immediate removal, maintaining the same position, precludes the possibility of this occurring.

Method.

The method of Fox is very ingenious, but the defect in this method is that if the foreign body is very small and lies directly below the shadow of the localizer it cannot be seen. It is possible that the cornea may become abraded from the presence of the localizer, which is made of metal. In order to minimize the difficulty that has been experienced in detailing the exact position of the foreign body by a finder or localizer, which is opaque to the Röentgen rays and is placed outside of the eye, he has devised a localizer of his own which comes in direct contact with the anterior half of the eye and its geometrical shadow thrown on photographic plates aids in localizing a foreign body in the orbit or the eyeball.

This is especially so since the outside rim of the localizer is formed of an opaque substance, so that if care be taken the position of the eye will be clearly determined by the geometrical shadow of the localizer.

The apparent position of the foreign body will, of course, depend upon its distance from the photographic plate, and it is absolutely necessary that the direction of the rays and the position of the plate be borne

in mind in estimating the location of the body by means of the Röentgen-graph.

The localizing device consists of an oval band of gold or silver about 0.75 mm. in width, so shaped as to conform to the outline of the eye. It is provided with two gold strands crossing in front at right angles, thus dividing the instrument into quadrants.

In his latest form of localizer there are two nearly concentric bands

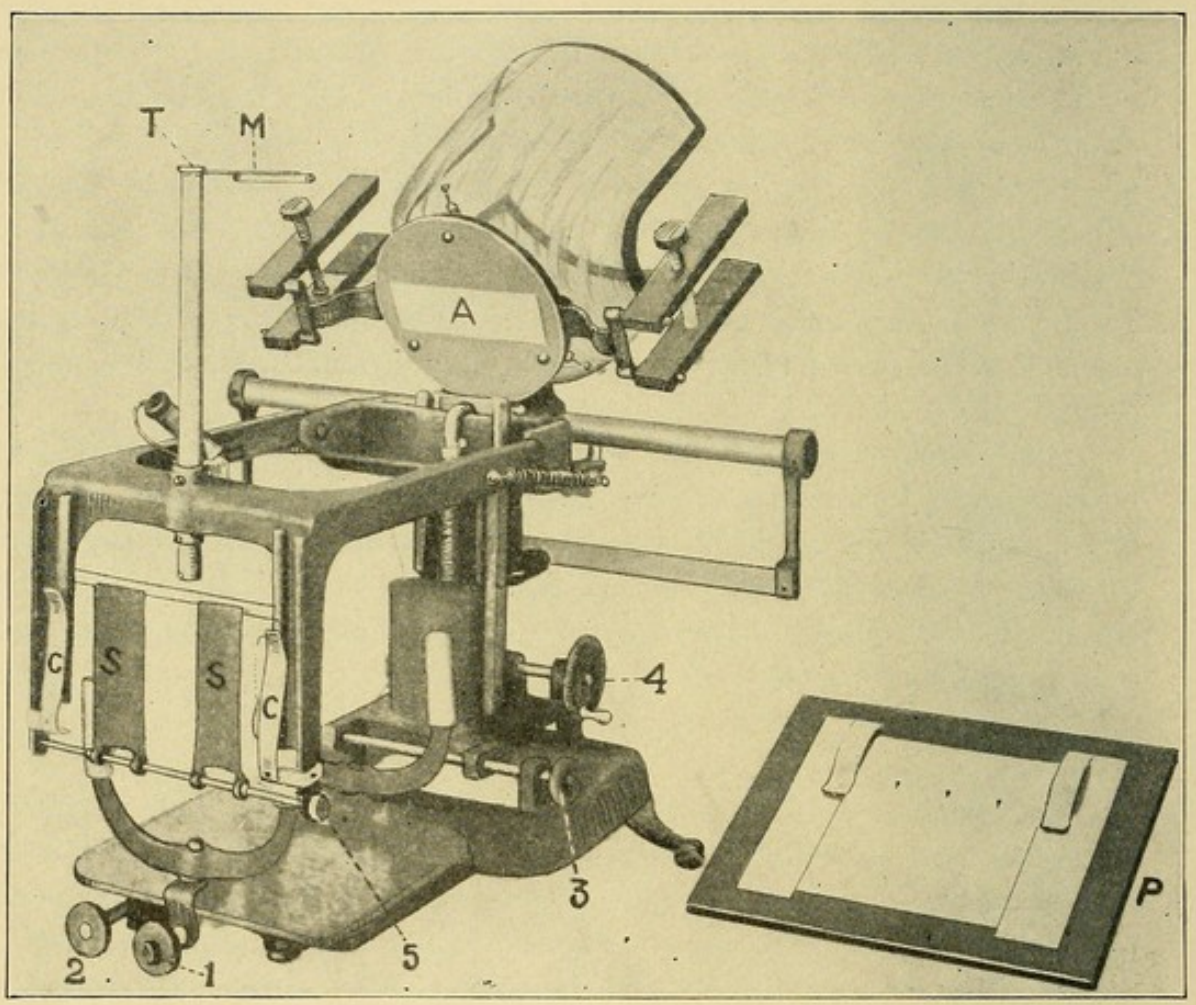

Fig. 60.
Sweet's new localizer.

of silver cross wires connected thereto, leaving larger clear space for the cornea. The latest modification consists in substituting for the outer band one of the smaller diameter. This device accomplishes the same amount of localization with less shadow. The foreign body must be very small to be eclipsed by the shadow made by this localizer.

When in use the localizer is adjusted directly on the surface of the eye to be examined, a solution of cocain having been previously applied to the cornea and the lids, thus permitting the instrument to remain in

place long enough to make one or two exposures without inconvenience to the patient. The localizer adjusts itself to the eyeball, but does not prevent the eye to which it is attached from rotating or following the other eye. In order to bring the cross wires directly over the center of the cornea of the eye to be photographed, it is necessary to direct the other eye to a fixed point, the photographic plate being adjusted on the side of the temple of the injured eye. The tube is then adjusted so that the rays, as nearly as possible, fall perpendicularly on the photographic plate. If the foreign body lies within the shadow of the localizer it must be in front of the equator of the eyeball. Its distance beyond the shadow of the instrument also determines the location, either in the posterior portion of the globe or the orbit. The second occipital-frontal exposure is made, which at once identifies the quadrant in which the foreign body lies. In taking the second picture the plate is placed in front of the eye, with the X-ray passing through the head antero-posteriorly. The usual time of exposure for the temporal photograph is one to two seconds, and the occipito-frontal photograph, five to ten seconds.

S w e e t was probably the first to devise an accurate method of localization of foreign bodies within the globe. His method is still in vogue by most X-ray operators, with slight modifications. The description that he gives is based upon triangulation of the planes of the shadow of the foreign body at two exposures, with the tube in different positions, and suited in relation to the shadows cast by one or more prints of new positions near to the eyeball. The apparatus consists of a light metal frame for holding the photographic plate, and is provided with a movable arm supporting the pointed rods. These rods are parallel to each other and to the plate, the center of each ball being at a fixed distance apart. He has since decidedly improved the method, which is as follows:

In this new apparatus the principles of the shadow of the foreign body is accurately determined by the instrument without the necessity on the part of the operator of taking measurements from the patient, or in drawing lines on the chart. The tube holder, indicating ball and plate holder are upon a movable stage, and therefore preserve a known relation to each other which does not vary. The angle of the rays with the eyeball and the distance of the tube from the plate are always the same so that one indicator is sufficient, and this consists of a small steel ball supported in a ring of transparent celluloid. The setting of this ball opposite the center of the cornea is made by means of adjusting screws conveniently placed on the frame of the instrument.

Accuracy in the measurement of the indicating ball from the center of the cornea is secured by means of a telescope and reflecting mirror. The mirror gives an image of a cross wire and a lateral image of the cor-

nea. From the telescope the observer adjusts the instrument until the image of the cross wire is in direct contact with the image of the summit of the cornea.

When the adjustment is made, the indicating ball is exactly 10 mm. from the center of the cornea. A miniature incandescent lamp, mounted in an adjustable shade illuminates the side of the nose of the patient, insuring a well-lighted image of the cornea and cross wires.

Instead of a ball of cotton or other object for fixation as in the older methods, a circular mirror is placed at a distance of 12″ above the injured eye. The patient gazes into the mirror and sees a reflected



Fig. 61.
Patient in position (Sweet).

image of the injured eye and the circular celluloid disc with the steel indicating ball in its centre. After the ball has been adjusted to a point opposite to the centre of the cornea of the injured eye, the patient, by fixing the ball with the seeing eye, prevents any movement of the eye during the exposure, and holding the visual line of the injured eye parallel with the plate.

In order to shorten the time of making the radiographs and lessen the possibility of any movement of the patient or apparatus in changing plates, the two exposures in the new apparatus are made upon one plate,

metallic shutters protecting those portions of the plate which are not to be exposed to the rays.

The tube holder holds the usual cylindrical lead-glass shield for protecting the operator from the action of the rays, with the customary lead diaphragm. The central orifice of the diaphragm is covered with aluminum, which offers little obstruction to the rays, but lessens the risk of any unfavorable action of the rays upon the patient and guards against possible damage to the eye in the event of breakage of the tube. The

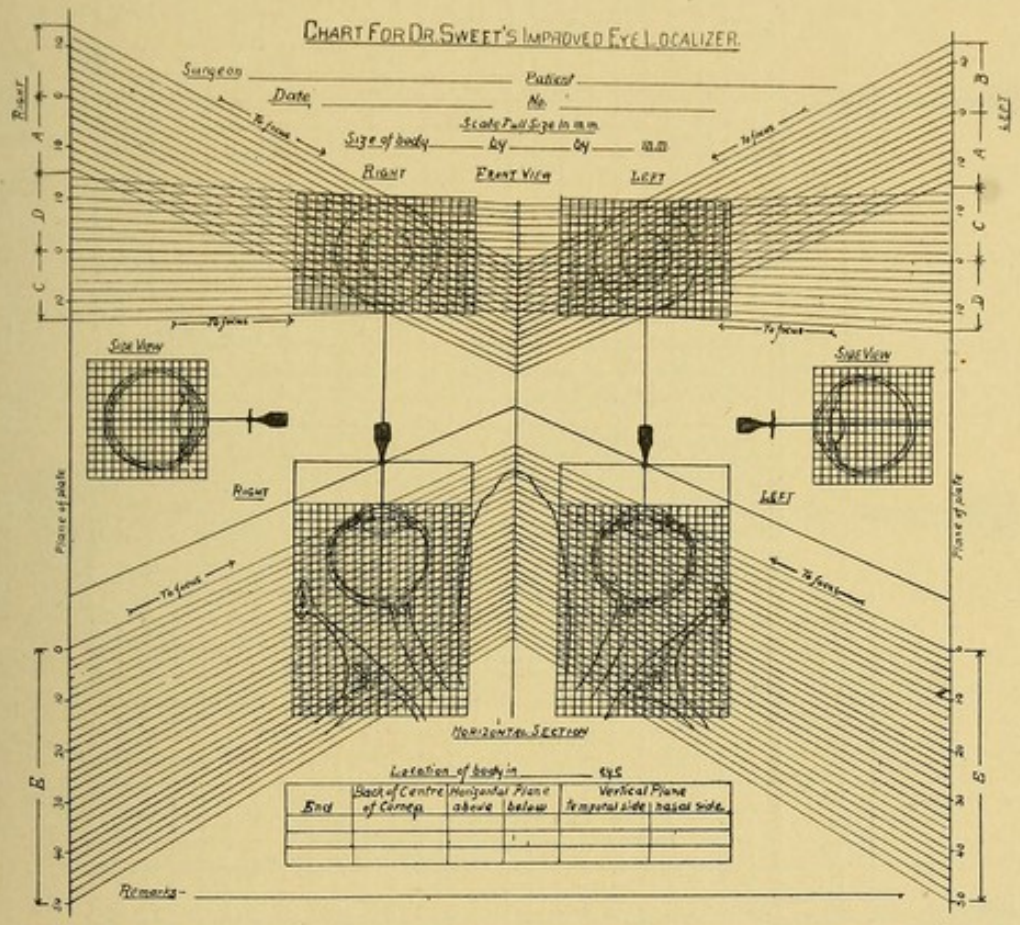

Fig. 62.

Localization chart, with lines representing course of the X-rays (one-half actual size).

tube holder slides upon a graduated rod, and the first exposure is made with the indicator at zero, in which position the rays pass in a direction corresponding to the horizontal plane of the eyeball. The second exposure is made with the tube at its farthest point to the right or left of the first position, depending upon which eye is to be examined. The illustration gives a view of the complete apparatus.

Since the relative position of the tube in reference to the indicating ball and the photographic plate remains fixed and known, it is readily seen that the direction of the X-rays in passing through the eyeball must

follow a definite course, which is always the same for the two separate exposures. It is, therefore, possible to indicate on the localization chart the direction of the rays at the two exposures, and this has been done in the

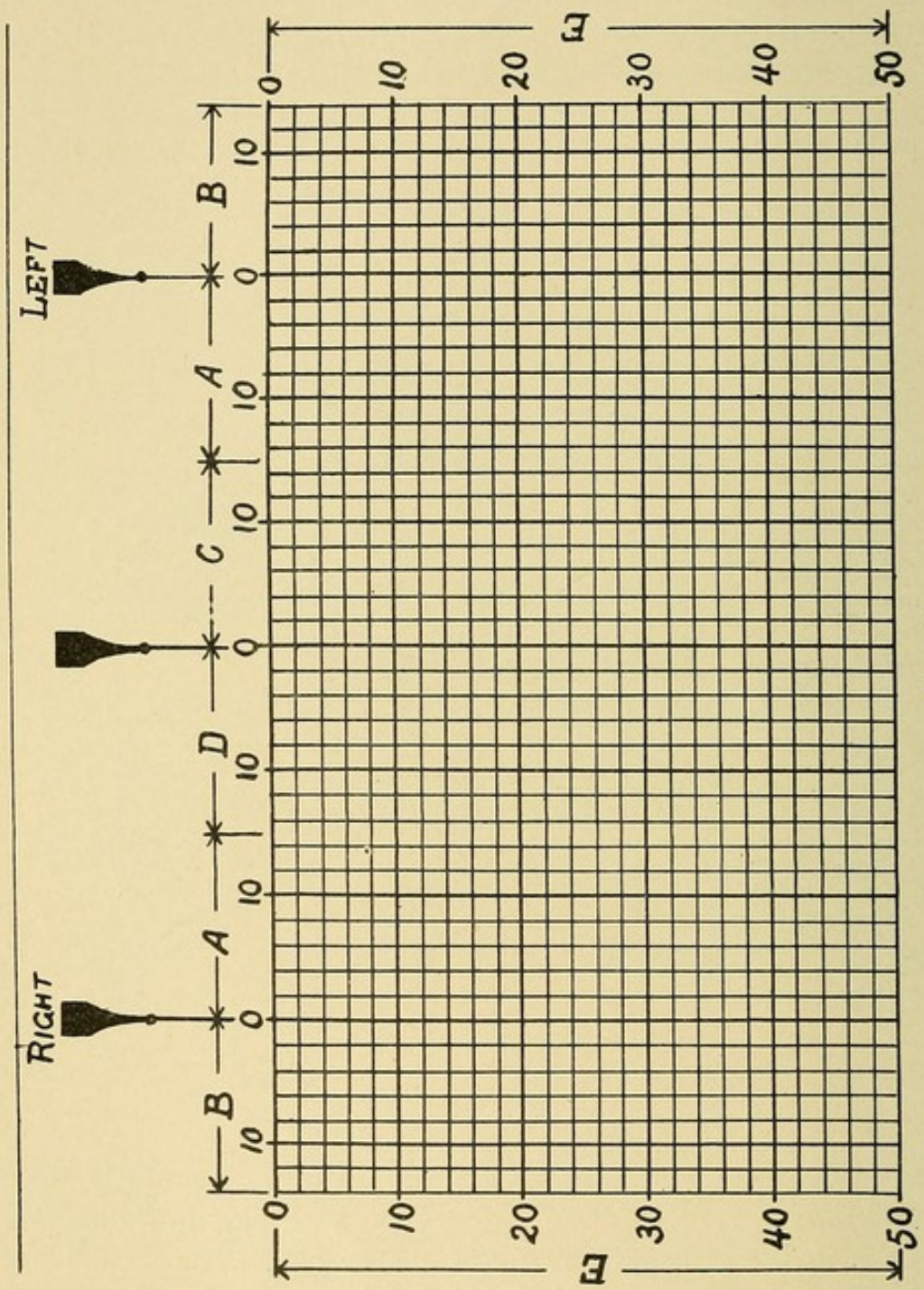

Fig. 63.
Plate showing focal coördinates (three fourths actual size).

chart, a copy of which is reproduced herewith, reduced in size one-half. Only those lines representing rays 2 mm. apart are reproduced, but each line is drawn with the required amount of divergence to indicate the rays as coming from a point the distance of the tube from the photographic plate.

Method of employing the new localizer.

The apparatus is arranged as shown in figure. The patient lies with the head on a platform of hard fibre, with a pillow beneath the shoulders and a small sand-bag under the head and neck. The upright supports for holding the head are now adjusted by means of the wheel 1, and the jointed part of the apparatus J, containing the indicator, is brought down in position. The indicating ball, G, is now roughly adjusted until it is opposite the center of the cornea and about 12 or 15 mm. distant. The patient looks with the injured eye into the mirror, or, better, upon the indicating ball in the center of the indicating disc. The indicating ball is now carefully adjusted directly over the corneal center by means of wheels 2 and 3, and the correctness of the position verified by observation through an opening in the mirror, M. The operator then adjusts the light of the small electric lamp so that the side of the nose



Fig. 64.
Localizing apparatus of Carman.

next the injured eye is illuminated, but the light is not thrown into the eye. With this area lighted it is possible to see clearly through the telescope, T, when the cross wire is exactly tangent with the summit of the cornea. The movement necessary to secure this position of the wire is made by means of the adjusting wheel 4. When the image of the cross wire touches the image of the corneal summit, the indicating ball is exactly 10 mm. from the eyeball.

The photographic plate is inserted beneath the spring clips, C.C., the shutters, S.S., moved so that the center area is open, and the tube holder adjusted to the zero point on the sliding scale. The current is turned on and one exposure made. The tube carriage is then moved to the limit of the sliding rod, always in the direction of the chin of the recumbent patient (to the end marked R if the radiographs are made of the right eye, and to L if of the left eye). The upper shut-

ter is moved to cover the exposed central portion of the plate and uncover the upper exposed portion. The current is again turned on and the second exposure made. The time of exposure for the second pic-

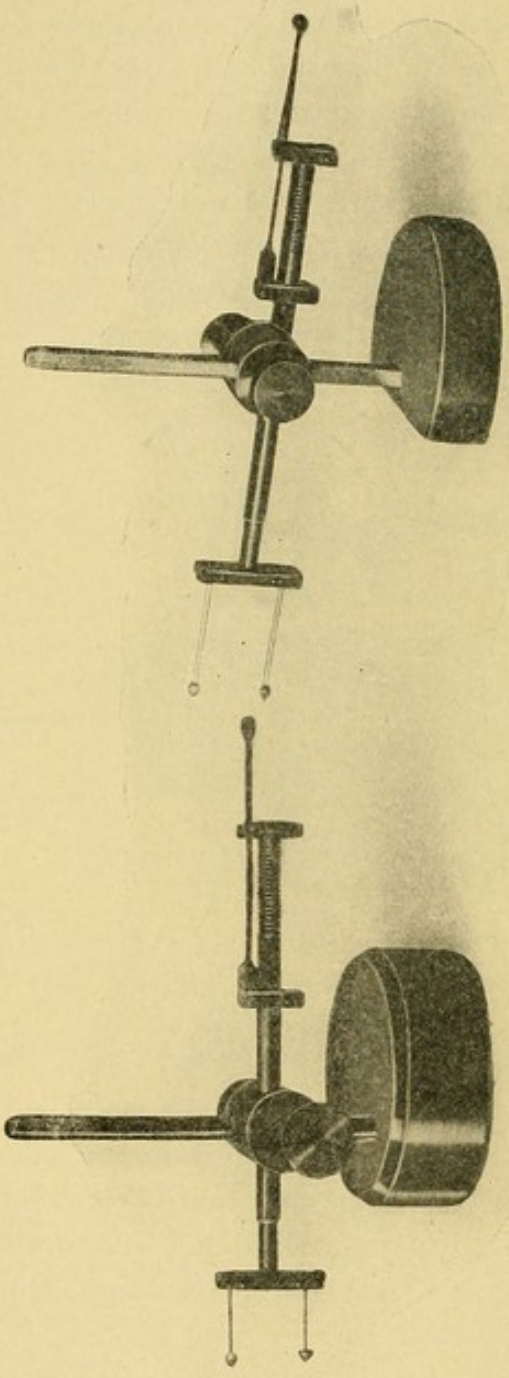

Fig. 65.
Localizing apparatus of Carman.

ture should be about one and a half times that of the first to allow for the increased distance of the tube from the eye.

After the plate is developed, it is placed in the frame, P, containing the key-plate or focal coördinates, with the film side of the radiograph next the key-plate. The radiograph is moved

until the shadow of the indicating ball of the first exposure is in apposition with the middle ball on the key-plate and the heavy horizontal line of the radiograph parallel with the horizontal line on the plate. Hold-

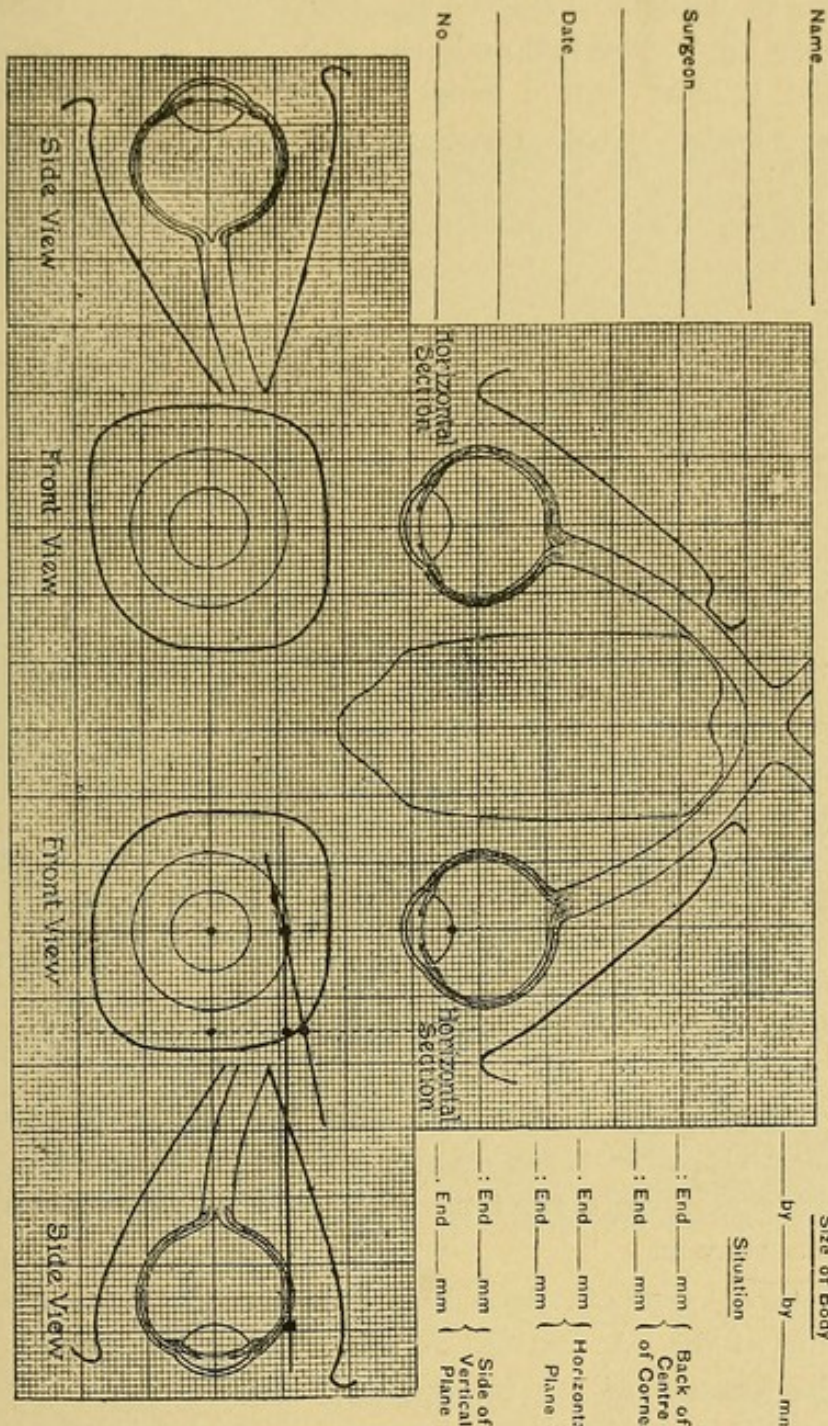

Fig. 66.

Chart used by Carman for localizing foreign bodies in the eye and orbit.

ing the frame to the light, there is noted the position occupied by the shadow of the foreign body with respect to the vertical lines of C and D. A reading is made of the line or lines which pass through the body, and this is transferred to the corresponding lines of the "C" or "D" scale of

the chart, to the right or left side, depending on which eye is under examination. Without moving the plate the "E" reading is similarly made and transferred to the chart. To take the "A" or "B" reading, the plate is shifted slightly until the image of the indicating ball on the second exposure coincides with the "Right" or "Left" ball of the vertical coordinates "A" or "B." The line or lines of the "A" or "B" coördinates which cross the shadow of the body are noted and indicated on the "A" or "B" lines of the chart. The horizontal coördinate "E" should be the same in both readings. If the focus point on the anode of the tube was accurately set by the cross-lines on the lead-glass shield of

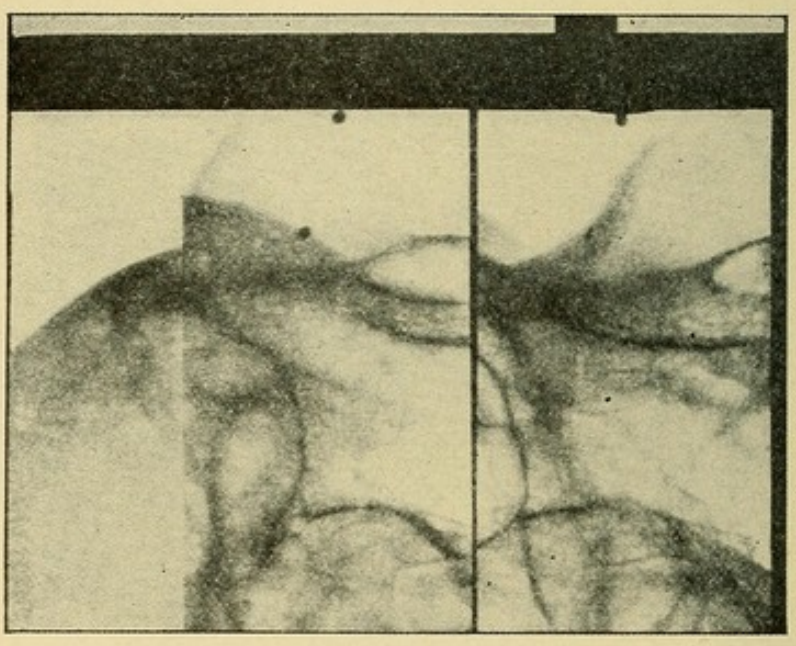

Fig. 67.
Radiograph of foreign body in eye (three-fourths actual size).

the tube-holder, the images of the indicating ball on the plate will coincide simultaneously with those on the transparent key-plate, and it will then not be necessary to reset the plate to read the position of the "A" and "B" coördinates.

After the three readings have been transferred to the chart, the point of crossing of the "A" or "B" and the "C" or "D" lines is found, which gives the location of the foreign body in reference to the front view of the eyeball, indicating its situation above or below the center of the cornea and to the nasal or temporal side of the vertical plane. Where a vertical line from this point crosses the "E" reading on the horizontal section of the globe it gives the depth of the body in the eyeball or orbit. In bodies of large size both ends should be localized to give the position in which the body rests in the globe. The situation of the body on the

side view is determined by transferring its measured depth from the horizontal section and its distance above or below the horizontal plane from the front view localization.

The new apparatus is based upon the same general principles as was the old, but the mechanical features eliminate some of the errors that may occur in the use of the instrument through carelessness of the op-

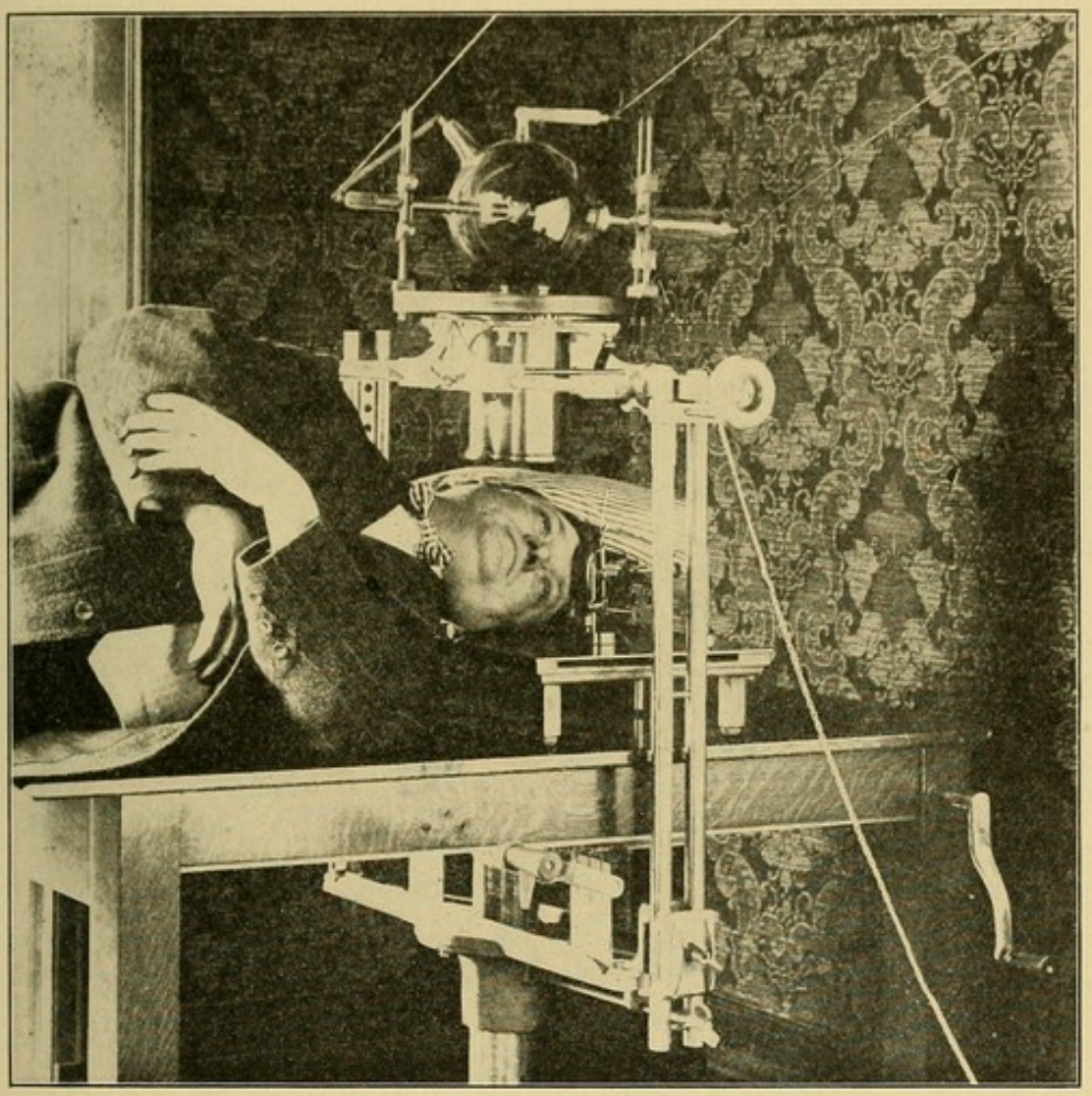

Fig. 68.
Position of patient for one exposure.

erator in making the measurements and transferring them to the chart. The inexperienced worker in eye localization is also relieved of the necessity of studying out the position of the tube and the direction of the lines of shadow at the two exposures. The construction of the new apparatus insures that these factors are positively determined and recorded. The accuracy of the localization depends only upon the care with which the operator adjusts the indicating ball opposite the center

of the cornea and at the definite and fixed distance from it. After the exposures are made and the plate developed, the determination of the situation of the foreign body is simply a question of reading from a key-plate and transcribing these readings to a chart.

The method of Carman[15] has triangulation as its basic principle. The apparatus is a modification of the Sweet-Bowman apparatus, in

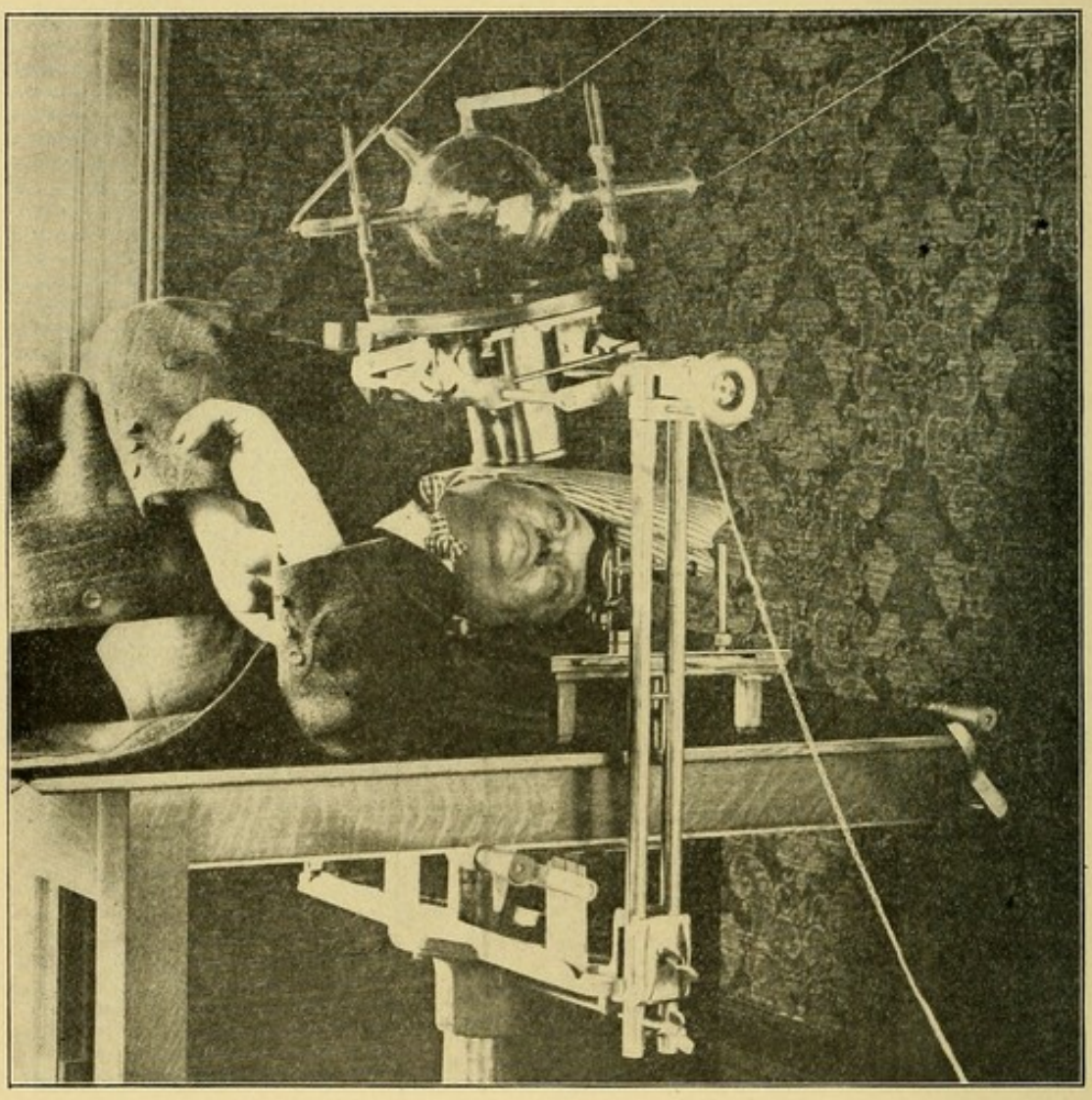

Fig. 69.
Position of patient for second exposure.

which the rods have been lengthened one inch, causing extension of the shadows to be more exactly located, as seen in the figure.

Two pictures are taken in slightly different planes, and from the shadows of the ball and cone, whose positions are known, measurements to the foreign body are made and recorded upon a chart, whereby the position of the latter is graphically shown at once without any intricate mathematical calculations.

The patient is requested to lie upon the regular compression diaphragm table, the head resting upon the localizing stand with the af-

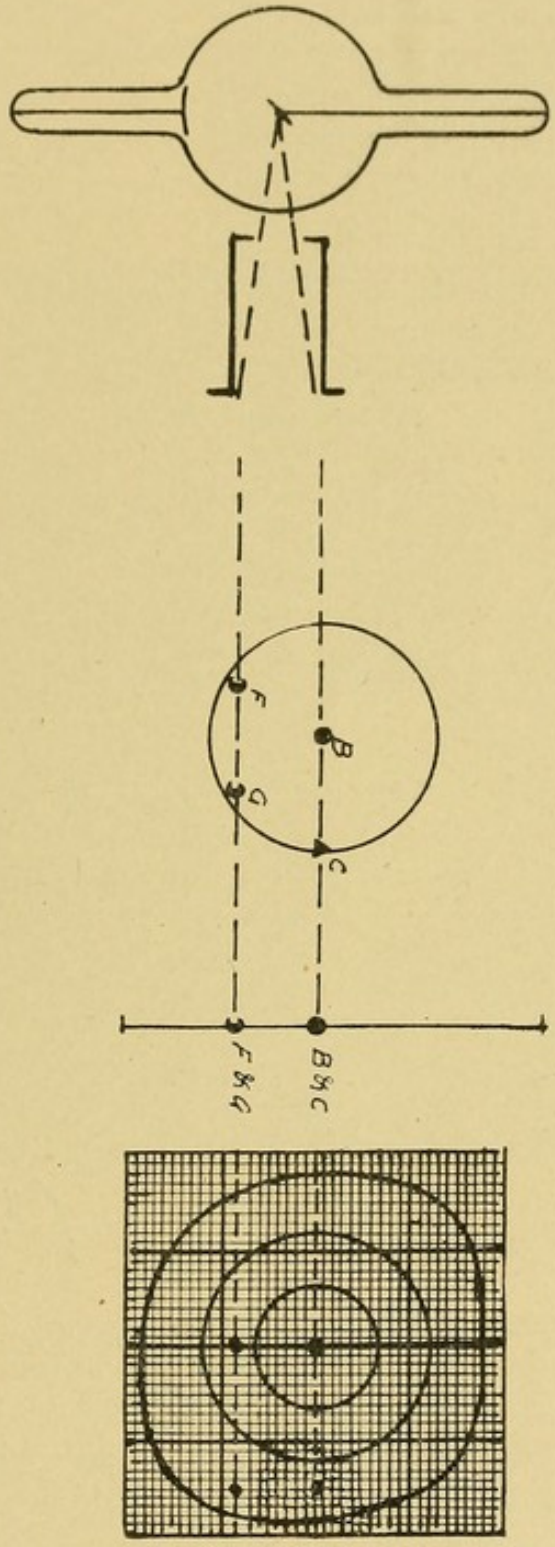

Fig. 70.
Showing direction of rays and method of marking in first exposure.

fected eye next to the plate, clamped and steadied with sand bags to prevent motion.

The visual axis of the eye should be parallel to the plane of the

plate, and the eyes fixed upon some object, as a candle flame, 15 feet away and an inch or two above the level of the localizing stand.

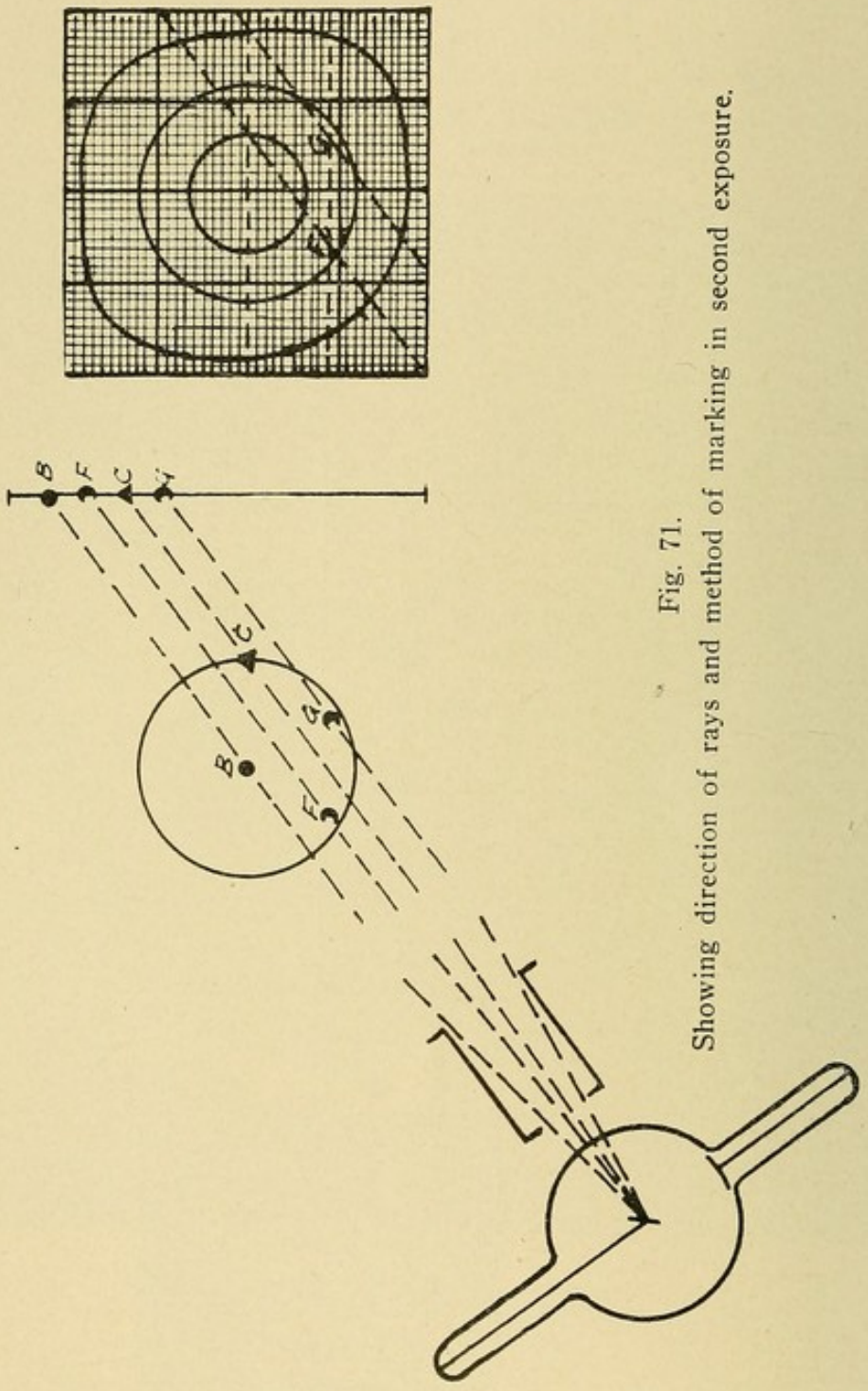

Fig. 71.
Showing direction of rays and method of marking in second exposure.

By this method the visual axes are rendered approximately parallel to the plate. The ball and the cone are 15 mm. apart, the cone being to the temporal side of the head. The trigger is set and the ball placed

in the center of the cornea so as to exactly indicate the visual axis of the eyeball, being aided in this improved instrument by a notched sight similar to that used on a rifle.

The patient is then asked to close the eyes and the ball is pushed into the lids about the lids' thickness and the trigger released, when the ball drops back to 10 mm. The patient is then instructed to open the eyes and to look at the candle, and if everything is in proper position, he continues to look at the candle until the exposures are made.

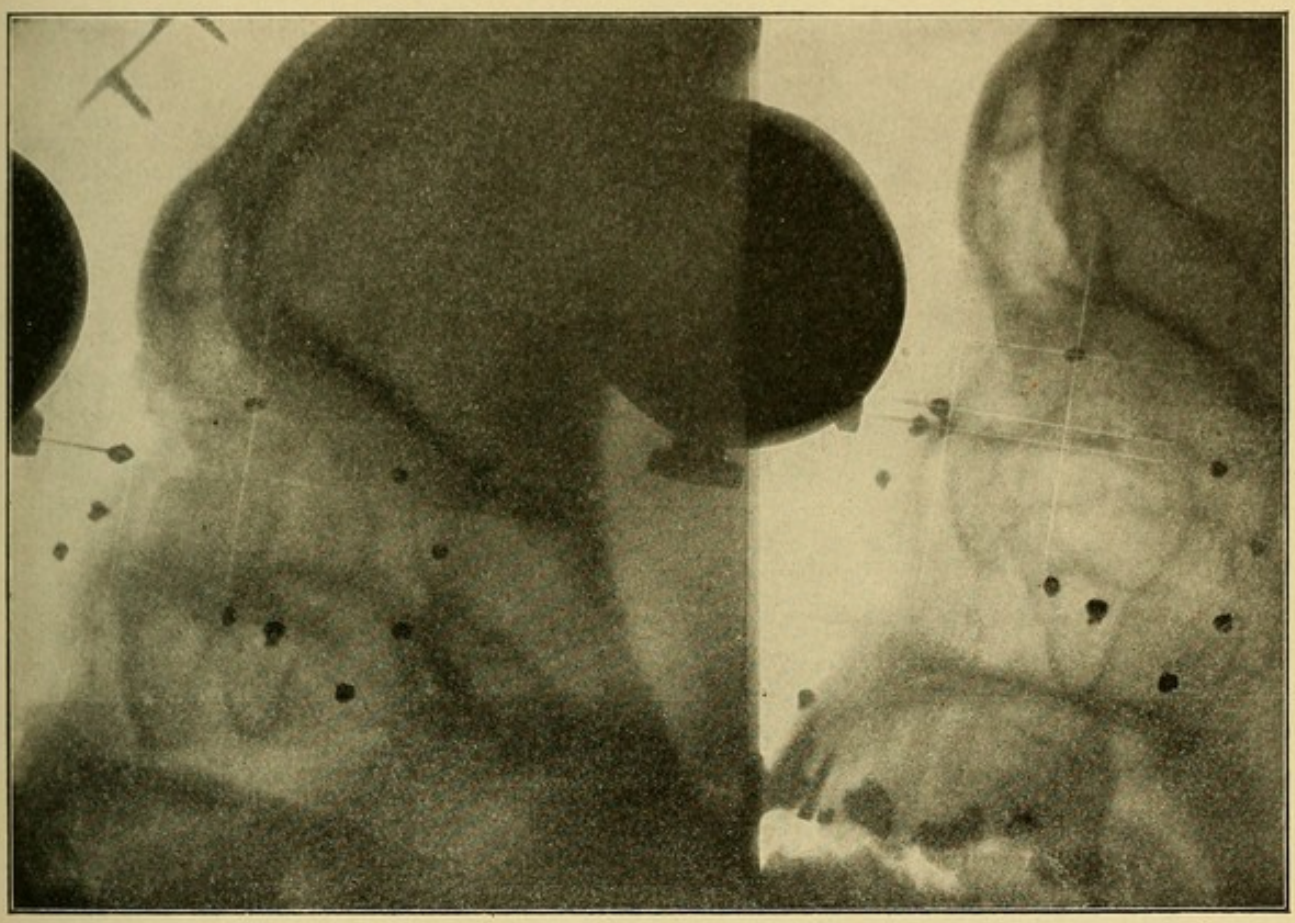

Fig. 72.
Radiograph of bullet imbedded in the sclera. (See text.)

In this position the first exposure is made with the rays perpendicular to the plate and parallel to the indicators, securing our first negative. The tube is then shifted toward the patient's feet four or five inches and tilted slightly. The plate is changed and without moving the ball or cone or anything else the second exposure is made, giving us our second negative.

Upon the first negative a line is drawn in the axis of the rod and ball, which are here superimposed, and the visual axis of the eye is thus established. A line is also drawn perpendicular to this and through

the center of the foreign body's shadow. With a millimeter rule the distance from the foreign body is measured above or below the visual axis, and said distance in millimeters is laid off upon the front view of the chart, either above or below the center of the cornea, and above or below the point representing the position of the cone. A line is drawn through these indicated points on the chart.

Likewise upon the second negative lines are drawn through the axis of the ball and the cone, and perpendicular to these through the foreign body. Then with the millimeter rule the distance of the foreign body above or below the prolonged axis is measured.

These distances are also recorded in the front view upon the chart, at the proper points a line is drawn through these points.

The intersection of this line with that made from the first negative will represent the location of a foreign body as viewed from the front, whether above or below the center of the cornea, and whether on the temporal or nasal side. (See footnote.)

(Footnote.—Figs. 00 and 00 show a radiograph and chart of a bullet imbedded in the sclera. The wound of entrance was 3 mm. below the scleral corneal margin, about the middle of the lower half of the eyeball. The bulging of the membranes at this point accounts for the bullet appearing to be outside the eyeball in the chart. After X-ray examination the bullet was extracted. Patient now counts fingers at 10 feet. The case is regarded as unique by the oculist.

Anyone who has a knowledge of the higher branches of mathematics fresh in mind will readily comprehend the principle underlying this method. There are others who can understand how the first negative will indicate the distance of the foreign body back of and above or below the centre of the cornea, but they will ask, as I have been asked, if the two negatives together will always show whether the foreign body is in the temporal or nasal half of the eyeball.

Such persons may, perhaps, derive benefit from the study of the above diagrams, which are intended to represent the left eye containing two foreign bodies, one in the temporal half and one in the nasal half, each the same distance below and back of the centre of the cornea.

B is the ball; C the cone; F and G are the two foreign bodies.

In the first negative B and C coincide upon the negative, likewise F and G. Both F and G are 8 mm. below B and C, and a horizontal line is accordingly drawn on the chart 8 mm. below the horizontal lines passing through the centre of the cornea.

In the second negative F is 13 mm. below B and 5 mm. above C. These measurements are applied upon the chart and a line drawn through these points. This line intersects the line obtained from the first negative in the lower nasal quadrant and shows the location of F. G is shown on the second negative to be 13 mm. below B and 2 mm below C. These measurements are made upon the chart and a line drawn through the points.

This line intersects the line made from the first negative in the lower temporal quadrant, and this shows the location of G.

The reader may also get a heightened conception by holding the illustrated page with the edge toward him, slightly below the level of vision and looking at it glancingly, so to speak, along the lines representing the direction of the rays.

Again the reader must be reminded that these drawings are only diagrammatic; and the ball, cone, and foreign bodies are thus shown in the same vertical plane. In the actual negative they will appear in different planes, hence the necessity of extending lines through the axes of the ball and cone, and making measurements in the plane vertical thereto.)

These lines represent the direction of the rays of each exposure.

Again, upon the first negative the distance of the foreign body from the anterior surface of the cornea is determined from measuring the ball along its axis, to the perpendicular through the foreign body, and deducting 10 mm. for the rebound of the ball when the trigger is released. Upon the chart a line is then drawn through the point of intersection in the front view, parallel to the line going through the center of the cornea to the horizontal section, and the distance from the front of the cornea measured and indicated.

In like manner a line is drawn through the point of intersection in



Fig. 73.
Vard Hulen's localizing apparatus. Patient in position.

the front view parallel to the chart line going through the center of the cornea into the side view, and the distance measured from the center of the cornea.

In making the lines and measureents upon the negatives and charts extreme accuracy should be sought for. To this end the lines upon the negatives and charts should be made with a draughtsman's pen and using red ink for a greater contrast.

The method of Dr. Vard H. Hulen, which he has employed since August, 1902, is original with him. He says, "my 'localizer' apparatus can be made by any carpenter from the specifications and mechanism; the tube clamp may be purchased at any supply house. All requirements

will be fulfilled if the tube can be properly placed, and easily and accurately displaced three inches or so in a perpendicular line. As the head must be absolutely immovable, I have arranged for the patient to fix with the teeth."

The method of procedure is as follows: A piece of lead of suitable size and shape is securely fastened with adhesive plaster to the margin of the lower lid of the injured eye directly under the center of the pupil. Then the distance from the upper extremity of this "marker" to the center of the cornea, and also the distance the marker is anteriorly or posteriorly to the apex of the cornea is taken and recorded. My experience is that these measurements are more accurately taken by the

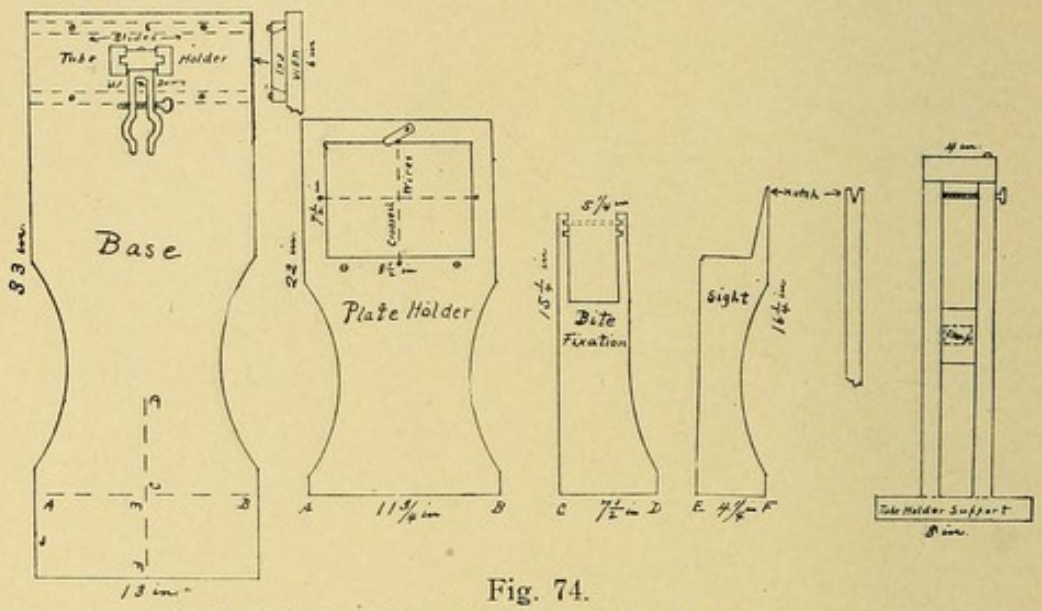

Fig. 74.
Vard Hulen's disseminated localization apparatus.

use of the compasses. A Crookes tube is next adjusted vertically in the holder of the localizer so that the luminous point of the anode and the point where the wires cross and the V-shaped sight are in a horizontal line. Then the distance from the anode to the crossed wires is measured and recorded. The patient is placed with the injured eye next to crossed wires, the other fixing an object located so as to bring the injured member into a straight ahead position, a photographic plate is put in the frame and photo. 1 is taken. The patient remains in the same position, but the tube is raised a definite distance, usually three inches, and photo. 2 is taken, and both pictures are sent to the dark-room to be developed. The marker on the patient's lid is again inspected to be sure it has not shifted its position since first measured.

With these two plates and the accurate measurements one can quickly determine the exact position the foreign body occupies in relation to the eye.

The necessary implements are a pair of compasses, a straight edge, a very hard lead pencil, and a sheet of 18″ smooth surface drawing paper. On the paper make two vertical lines, the distance between them being that recorded for the distance between the anode and crossed wires. Cross each of these lines near the bottom with a horizontal line, and mark the point of crossing of left line "1." Then mark a point "2" on this left vertical line, the same distance above as the tube was dis-

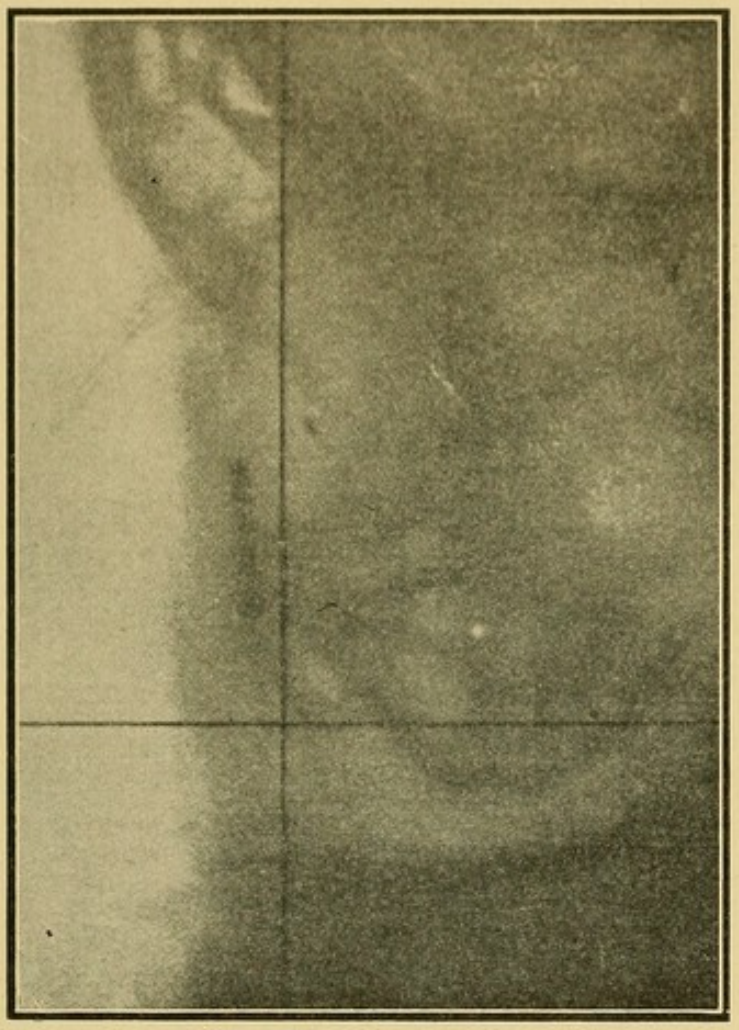

Fig. 75.
Showing relation of cross line in first exposure.

placed vertically when taking the second picture. Then in photo. 1 measure with compass the vertical distance from the shadow of the horizontal wire to the upper extremity of the shadow of the marker, and on the right vertical line in the diagram beginning at the point crossed by horizontal lines measure vertically this distance, designating that point "O, 1." In the same way measure and mark the vertical distance from shadow of horizontal wire to center of shadow of foreign body, "X, 1." Now take photo. 2, measure and mark shadows of the foreign body and

marker on same vertical line as with photo. 1, designating the point of the foreign body "X, 2," and that of the marker "O, 2," then connect by a continuous straight line point "1" on left vertical line with point "X, 1" on right vertical line, also by a broken line with point "O, 1;" connect point "2" in a similar way to "X, 2" and "O, 2."

It is evident that the point where the continuous lines cross represents the location of the "marker," and that the point where the broken

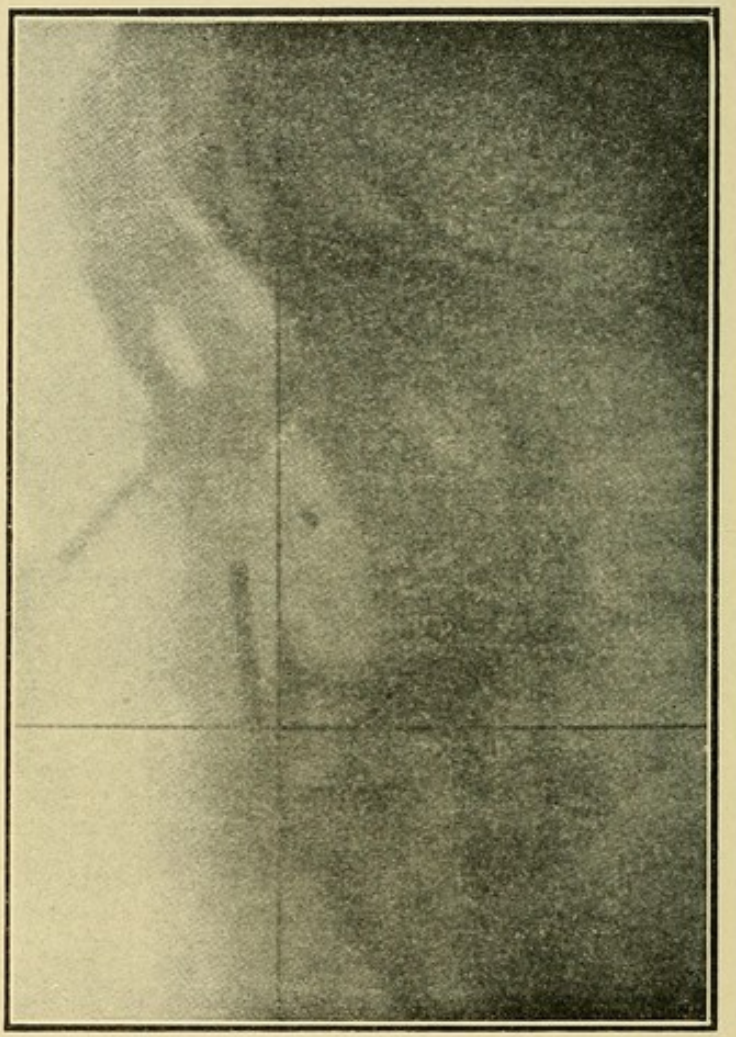

Fig. 76.
Showing relation of cross lines in second exposure.

lines cross is the exact location of the foreign body in the vertical plane. As the relation between the eye and the marker is known, draw schematically an eye according to its anatomic measurements in its correct position, using the vertical measurement previously made from the center of the cornea to the upper extremity of the marker. The location of the foreign body to the eye in the vertical and lateral meridians is thus made plain by our diagram.

Now for the upper part of the figure. Mark a point on the left

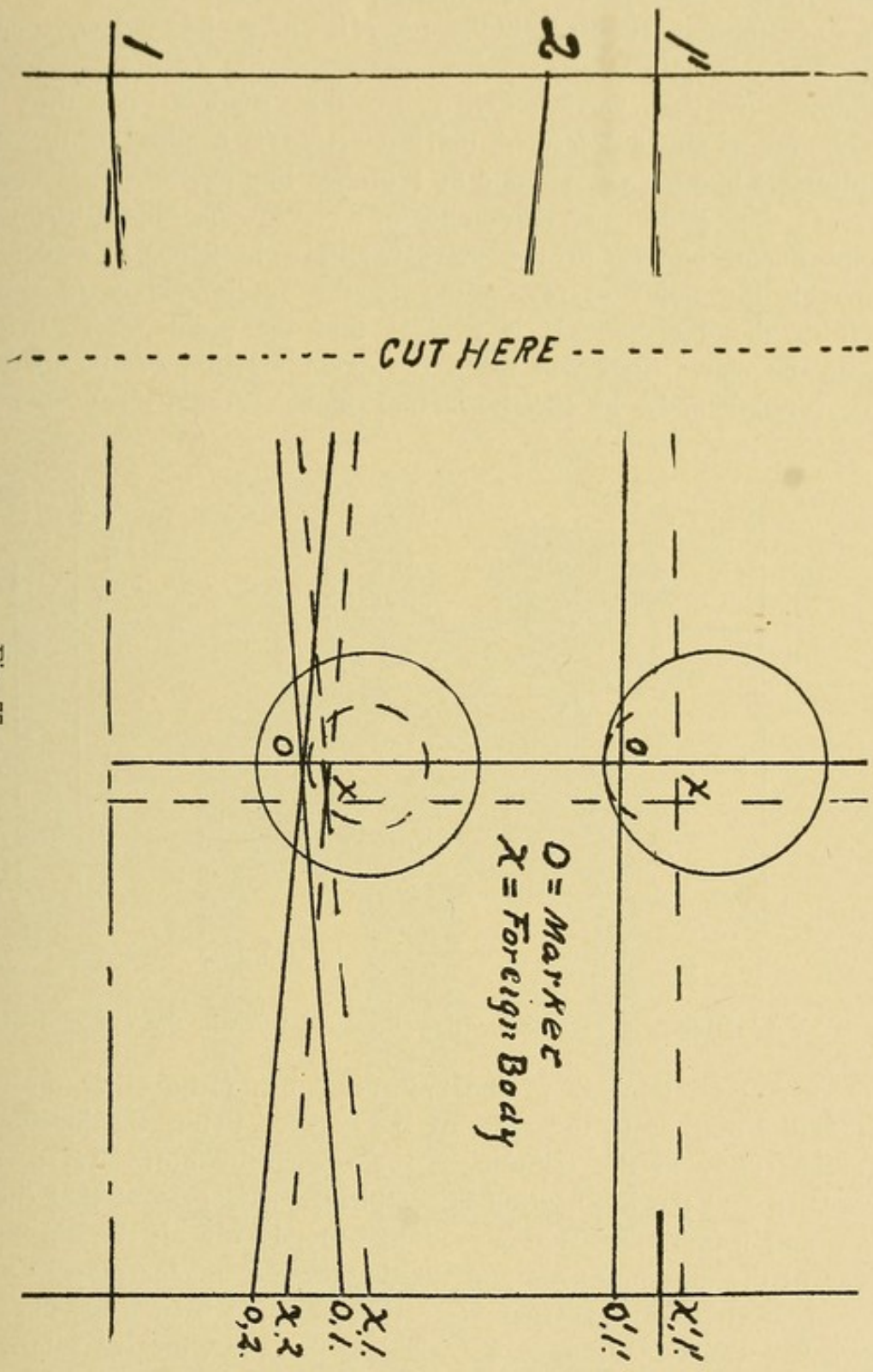

Fig. 77.
Vard Hulen's method of locating foreign bodies. (Illustrating a case.)

vertical line 1′″ and also a short line at the corresponding horizontal point on the right vertical line. Then in photo. 1 measure the distance from the shadow of the vertical wire to the shadow of the "marker"

and mark the point of that measurement above the crossing of the short line "O′, 1‴" (it may be below, depending upon the relationship); also measure the distance from the shadow of the vertical wire to the shadow of the foreign body, and, as above described, mark it "X′, 1." Connect point "1‴" by a continuous line to "O′, 1‴" and by a broken line to "X′, 1′." Then erect across the paper a perpendicular continuous line through the point corresponding to the marker and a broken perpendicular line through the point corresponding to the foreign body in the lower part of the diagram. It is evident that the point where these lines cross the above lines will mark the exact location of the marker and the foreign body in the horizontal plane. Again draw the eye in

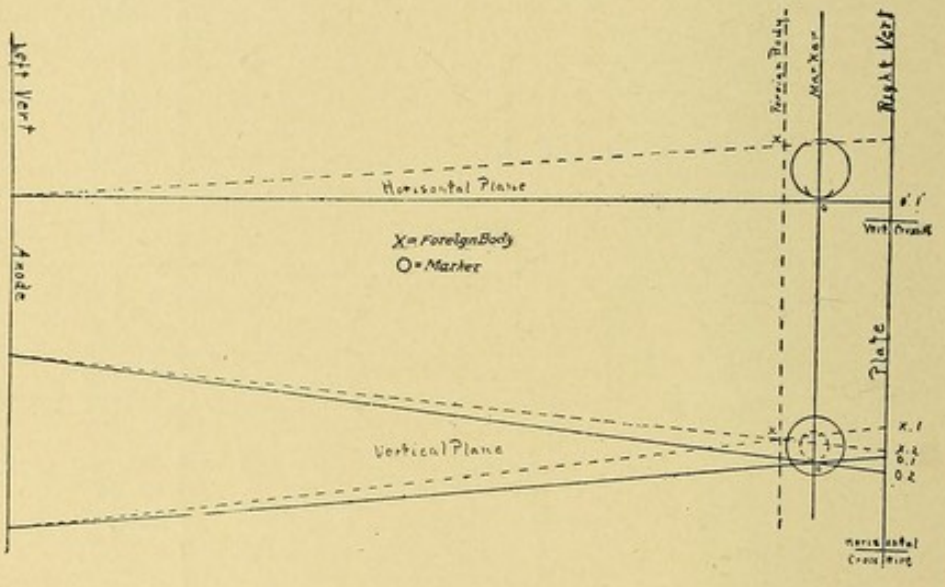

Fig. 78.
Vard Hulen's chart for locating foreign bodies in the eye and orbit.

its correct relationship to the "marker," using the other measurement from the marker to the apex of the cornea. Thus the location of the foreign body in the relation to the eye in its horizontal meridian is revealed and the localization is complete. It is evident that the perfection and infallibility of this method depend only on the absolute accuracy of the measurements and the drawings made therefrom.

I need hardly say that after the idea had been grasped, which is, in a few words, to represent with lines in a drawing the relative conditions existing when using an X-ray, one can draw this complete diagram unhesitatingly in less time than it takes to read the description of how it is done. It is suggested that the reader follow the description, using the accompanying figures, and in this case for localizing, upper extremity of marker was placed 8 mm. below and 1 mm. posterior to apex of cornea.



Fig. 79.
Dixon's table, head rest, and localizer.

The anode was set 14¾″ from the crossed wires (or plate). Two X-ray photographs were taken with coil exposure of 15 seconds each. The tube was raised two inches for the second picture. For result see figure. The photographs are here reproduced without the slightest

change, the drawing is made actual size, cutting vertically through the figure, as indicated thereon, paste the two pieces on a sheet of drawing paper in the same relative position, but with the right and left vertical lines precisely 14¾″ apart, then with a pencil and ruler join the ends of the separated lines.

Hulen's method of plotting is at present in use in the New York Eye and Ear Hospital, but with Dixon's modified apparatus for the head, which requires the patient to be in a recumbent position.

The objections to Hulen's localizer apparatus are noted under the paragraph "Position of the Patient."

The method of Dixon is "Draw a line on the side of the head running backward from the outer canthus of the injured eye on a plane approximating the horizontal plane of the globe. Then adjust the head band intended to carry the indicator or marker, but the indicator should be removed to prevent accident during the subsequent manipulation of the patient. In fact, this indicator should never be in position when there is any chance of the patient being able to move.

The tube having been adjusted by centering the anode with the cross wires in the plate frame, the distance of the anode from the plate measured and recorded (about 50 cm. being the best distance), the patient can now be laid on the table, and the head adjusted by means of the squaring apparatus, and fixed with the strap and clamp as described, care being exercised to have the line on the side of the head parallel with the perpendicular cross wire, but sufficiently removed to prevent the shadow of the wire from obscuring the shadow of a small foreign body in the globe. I usually place this wire about the lower margin of the orbit.

The vision is now fixed as described by means of the little woolen ball, and the indicator is slipped onto the pole or rod attached to the headband, and while the patient's vision is steadily fixed on the ball over his head the indicator is brought as near the center of the cornea as is compatible with safety and comfort. The distance of the point of the indicator from the center of the cornea is then carefully measured with a lens and strap gauge and recorded. The tube is now to be racked 3 cm. below the center, the plate is inserted in the plate frame, the patient is directed to fix his vision steadily on the little woolen ball and the first exposure is made. Without allowing the patient to move, or withdraw his gaze from the ball, the tube is racked 3 cm. above the center (making a total displacement of 6 cm.), the exposed plate is replaced by a new one, and the exposure is repeated.

After the plates have been developed he will find the cross wires in the same position on both plates, but everything else will show dis-

placement, and this displacement is the key to the proposition."

The distance of the anode to the surface of the plate, in the case selected for illustration, was 51.5 cm., and the point of the indicator was 3 mm. directly anterior to the center of the cornea. These are all the preliminary measurements required.

To work out the location of the foreign body Hulen's lines are used, as described under Hulen's method. We now have all our measurements and it only remains to transfer them to the chart, so we measure off 10 mm. back from the center of the cornea, 8 mm. below the horizontal plane, and 6 mm. to the temporal side, and thus indicate the point of location of the foreign body in the eye.

LITERATURE.

1. Leber, reported by L. Caspar, *Klin. Monat. f. Aug.*, xlvi, ii, 1908, p. 179.
2. Caspar, *Ibid.*
3. Hansell, *Trans. Col. Physc. of Phila.*, Jan., 1906.
4. Stilling, *Zeitsch. f. Aug.*, No. xii., p. 23.
5. deSchweinitz, *Medical Science*, June, 1904.
6. Sweet, *Trans. Sec. on Ophthal. A. M. A.*, 1906.
7. Dixon, *New York Eye and Ear, Annual Report*, 1906.
8. Bortello and Garbasso, *Bolletino della Soc. Photo Ital.*, 1897.
9. Davidson, *Trans. Brit. Ophth. Soc.*, Vol. xix.
   Nettleship, *Ibid.*
10. Sweet, *Ophthalmology*, July, 1906, p. 592.
    Sweet, *Amer. Ophth. Soc.*, 1909.
11. Spratt, *Ophth. Rec.*, Sept., 1908.
12. Davidson, *Arch. of the Roentgen Ray*, May, 1898.
13. Hulen, *Jour. A. M. A.*, Apr., 1902.
14. Weeks, *Amer. Ophth. Trans.*, 1905.
15. Carman, *St. Louis Med. Review*, March, 1909.
16. Fox, *A Practical Treatise of Ophthalmology*, 1909.

CHAPTER XI.

PROGNOSIS OF INJURIES OF THE EYE.

The Prognosis of ocular injuries depends largely upon the part of the eye that is damaged, more especially that having to do with the function of sight. Of first importance is the central visual acuity; secondly, the visual field; thirdly, the ocular movements; and lastly the light and color sense. To these may be added the cosmetic damage and the ability to use the eyes for work, or, as Magnus[1] puts it, the ability to compete; and the sum of them all results in the economic vision.[2]

No cases can be cited of a simple injury to the light and color sense, and the other elements are of such overpowering importance that this may be neglected in the estimation of damage to vision. The longer the course of healing, the greater the resultant damage to function, other things being equal.

The prognosis depends upon the amount of damage; the size and character of the wound; whether penetrating, perforating or non-perforating; whether foreign bodies are carried in; and whether infected or not.

Trauma acting on the parts of the eye necessary for clear vision, as the visual zone of the cornea, the lens, vitreous, macula lutea, does more damage in proportion than that to one side, and offers a more unfavorable prognosis on account of resultant obstruction to vision. Injuries to the optic nerve and visual sphere are usually followed by atrophy and blindness. Injuries of the ciliary region are provocative of sympathetic ophthalmitis and loss of the other eye as well. As a rule clean-cut wounds heal well if not infected. Infection may, as a rule, be successfully combated if seen in the early stages. Retained foreign bodies are always dangerous. Contusions are generally dangerous, as they lead to secondary degenerative changes and detachment of the retina. Burns of the anterior portion of the globe are always to be feared, lime injuries especially. Electrical injuries result in primary or secondary damage to the lens and retina. Double perforating wounds of the globe, even with retained foreign bodies behind in the orbit, are compatible with comparatively small amount of damage to the function.

Local fractures of the orbital walls are of less moment, quoad vitam, than those which extend along the base of the brain.

For special prognoses it will be necessary to refer to the special chapters.

Schirmer[3] says the prognosis of perforating injuries of the eyeball depends upon the condition of whether the wound is infected or not. Authors are generally too pessimistic with regard to the prognosis, and, from the results of his treatment during the last ten years, he asserts that two-thirds of the injured eyes can be preserved, a considerable percentage of them with useful sight. He lays chief stress upon saturating the body with mercury as early as possible, by inunctions, intramuscular and subconjunctival injections, and upon rest in bed for from four to six weeks. Out of 70 cases of fibrinous uveitis, 80 per cent. were cured; of 81 cases of purulent uveitis, 50 per cent. (59 of these had abscesses of the vitreous, 41 foreign bodies in the interior, mostly iron). of the eyes with foreign bodies, 27 were preserved (66 per cent.); of these, 90 (57 per cent.) with more or less vision. Out of 50 cases of fibrinous uveitis which came under treatment within three days after the injuries, 8 (16 per cent.) were lost, while out of 20 cases coming after the third day 6 (30 per cent.) were lost. This difference is not as striking in purulent uveitis. Twenty-eight were saved, 21 not (42 per cent.), out of 49 with purulent uveitis which were treated within the first three days. After the third day, 32 entered treatment, with 18 (57 per cent.) failures.

LITERATURE.

1. Magnus, *Leitfaden für Begutachtung und Berechnung von Unfallsbeschädigungen der Augen,* Breslau, 1894 and 1897, and other writings.
2. Magnus and Würdemann, *Visual Economies,* Milwaukee, 1902, and other writings of Würdemann.
3. Schirmer, *Deut. Med. Woch.,* No. 31, 1906, p. 1268.

CHAPTER XII.

PROPHYLAXIS OF INJURIES OF THE EYE.

Domestic Life—Agriculture—Trades—Safety Appliances—Screens—Goggles and Spectacles Obligatory in Germany—Investigation of Injury from Protectors—Literature.

While many eye accidents are unavoidable, yet the large majority are preventable by due care of the patient, parents, fellow-workmen or employers.

In domestic life a large proportion happen to children from ignorance or carelessness in playing with dangerous objects, such as gun and dynamite caps, fireworks, firearms, etc., hot and boiling fluids, water, kitchen products, melted lead, sharp and pointed objects of iron, glass and wood, the throwing of sand, dirt and stones, the shooting of arrows and darts, blows with sticks, etc.; teasing of house animals, as dogs and cats, with resultant bites therefrom, about which frequent warnings by parents are necessary.

In agricultural life many accidents occur from carelessness, injuries from baling wire, straw, hooks, branches, splitting wood, horning from cows, kicks from cows, horses, etc., most of which are to be avoided by due care.

Safeguards against accidents to working men have been forced upon the attention of manufacturers, transportation companies and others, not only by legal measures, but by the necessity for conservation of their own goods and machinery, the loss of service and the cost of care and expense in treatment of such working men, as well as protection from damage suits, which give lawyers lots of work. The policy of making factory work safer and more healthful is profitable as well as humane, and it makes the workman more contented. Safety appliances are in use in most dangerous trades and have markedly decreased the proportion of accidents, particularly of the eye. Note the lessened number of blind from accidents within the last ten years, according to the twelfth census. The installation of screens for iron chippers and bottle workers, the pneumatic fan at the grinder's wheel, the forced wearing of masks, spectacles or other eye protection where flying chips of metal, glass, stone, etc., are common, has reduced the number of accidents. But though these materially insure the safety of the work-

man, it is with reluctance that he uses them and will shirk their application unless carefully watched and continuously warned.

Lans[1] says, and those who have looked into the matter corroborate him, "Even if protectors hang alongside of the grindstone they are rarely used."

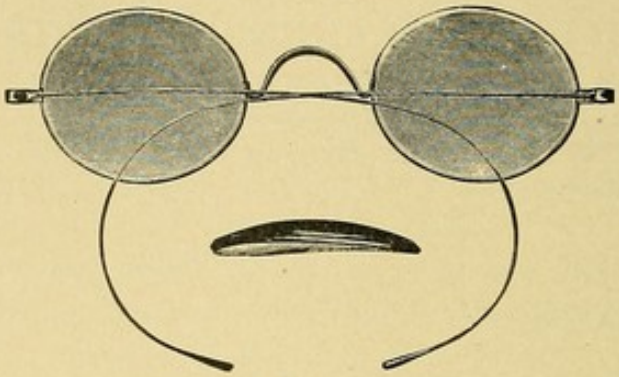

Fig. 80.
Coquilles.

Simeon Snell[2] found that although the workmen generally complained about the wearing of goggles and protectors, which is compulsory in most bottling works in the United Kingdom, there has been no deterioration of vision from their use, although in a number of cases headaches and dizziness were reported on inquiry from the workmen.

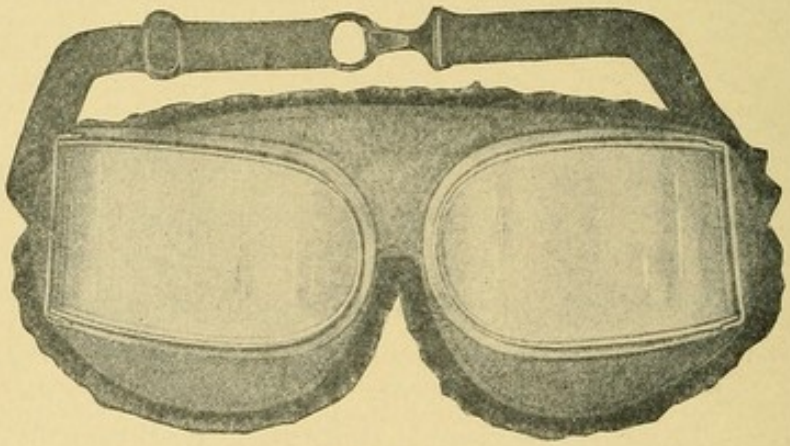

Fig. 81.
Automobile goggles.

Gaylord C. Hall[3] says, "I was surprised at the opposition to glasses until I found that the workmen all complained that the dust and sweat blurred the lenses from the start and later the emery cut the glass so that they were in danger of more serious injury from blurred glasses than would be inflicted on the unprotected eye by the emery.

This opposition seems hard to overcome, and while a foreman or skilled workman, who has to go to the wheel occasionally to sharpen his tools, takes measures to protect his eyes, the average workman is

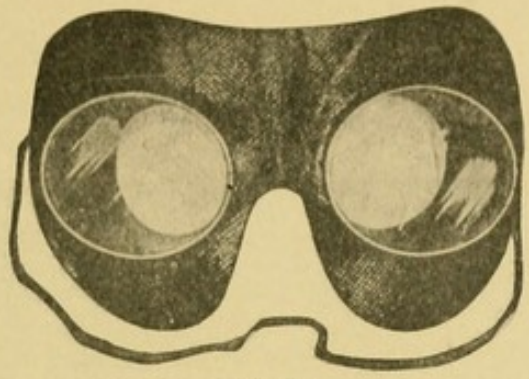

Fig. 82.
Fournier style ventilated leather mask for chemical works.

either too careless and shiftless to take the trouble to keep the lenses clear."

There are a variety of protectors in the market, but they have been little used.

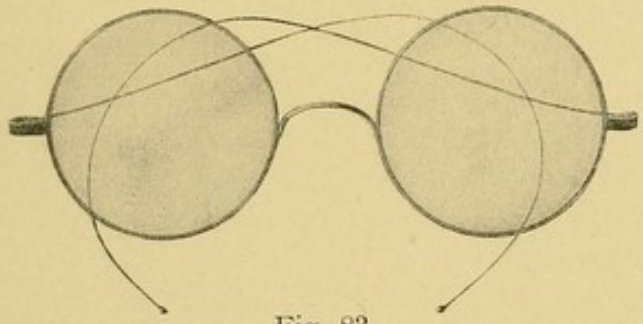

Fig. 83.
Miller's and stone-cutter's spectacles, common clear glass.

Gauze wire, fitting close to the eye like a cup and attached to the head by a string, is employed by stone-breakers and in some iron works. They complain of them as being hot and interfering with sight, but there

Fig. 84.
Bessemer spectacles, in heavy frames with three layers of heavy glass, for blast furnaces. Also made for rolling mills and open-hearth furnaces with heavy blue, amber or euphos glass.

is no question that such protectors do afford considerable immunity from accident. Another practical point about protectors is that they should not be liable to rust. For this reason galvanized iron wire, or,

better, aluminum wire, is of service. The mesh should be sufficiently strong and fine, and sufficiently close to prevent, as far as possible, even small chippings passing through it, and yet to interfere with sight as little as possible.

Large heavy glasses made of plain glass with heavy frames are used



Fig. 85.
Workman chipping, wearing eye protectors. (Simeon Snell.)

by stone-masons; plain glass with leather fittings, for workers in chemicals and in lime works where the acrid fumes may affect the eyes. Automobile protectors are now in common use for out-of-door people using these vehicles.

Amber, euphos, amethyst and even plain white glass (as noted in the chapter on effect of sun's rays and electric light) not only offer protec-

tion from small flying objects, but in a great measure cut off the violet or chemical rays.

Where grinders or workmen in the iron trades sharpen their tools a number of times a day at the wheel, thousands of foreign bodies fly about, many of which strike the person despite safety appliances that may be used. I have in my possession a pair of ordinary spectacles used by a workman in the Allis-Chalmers iron works which are completely studded with hundreds of abrasions caused by flying particles of emery—a not uncommon observation.

If one examine carefully the cornea in the eye of a grinder he may be surprised to find a large number of specks, which are the results of



Fig. 86.
Wire gauze protectors. (Simeon Snell.)

previous injuries. If these be not situated in the visual area they give rise to no inconvenience, but if in the visual axis a very small scar may cause decided lowering of the visual acuity. All such trivial accidents could be prevented by the working-man wearing protection while at such forms of work.

According to Praun[4] good protectors must have the following qualifications: 1. They must be strong and adjusted so that the finest splinters or motes will not pass through them. 2. They should be cheap and easily procured. 3. They must not cut off too much light and should not produce disagreeable effects, as irritation of eyes or vertigo. 4. They must be comfortably adjusted, not press or heat the face and eyes, and acceptable to the worker.



Fig. 87.
Pneumatic chipper. (Simeon Snell.)



Fig. 88.
Chipping against a screen. Men wearing protectors. (Simeon Snell.)

The Berlin Accident Insurance orders of 1890 even go so far as to distinguish and order certain kinds of eye protectors by numbers. (Hillemans.[5])

The use of the pneumatic chipper has, in many cases, almost superseded the hand chipping by sate and hammer, and thus the dangers of chipping are greatly avoided. It accomplishes in one hour what would take six hours by hand, and prevents the flying about of fragments, as it is more like running a scoop over fairly soft cheese than using a tool on hard steel.

The proper arrangement of men at their work and the use of screens, so as to avoid injury to their fellow-workmen and to passers-by, have,



Fig. 89.

Bottling machine, showing screen. A. Iron plate fixed to machine to protect bottler. B. Wood screen to protect passers by. C-c. Blankets to prevent broken bottles rebounding. D. Wood screen to protect wirers. E. Wicket through which bottles are passed to wirers. A curtain hangs from top to bottom of the wicket. Directly the bottle is passed through the curtain again falls into position. (Simeon Snell.)

together with the wearing of proper eye-protectors, conserved the safety of sight in factories where such have been installed and made obligatory.

In an investigation of the bottling works in England S n e l l[2b] found the following:

"1. There is an absence of evidence of injury to eyesight from the use of protectors—on the contrary, there are numerous instances of operatives making no complaint after using protectors for 20, 30 or even 40 years.

2. At a place where complaint had been made, on investigation it was found that no real use had been made of the protectors in the way that was daily the practice in other places which had been visited.

3. The occupation, from the frequency of bottles bursting, is one very prone to accident, the danger not being confined to the fillers. All the workers, or even visitors to the place where bottles are being filled, labeled, etc., or stacked, are liable to injury. Some manufacturers, finding even the best machinery not sufficiently protective, have added devices of their own. Bottles placed in boxes, stacked, or being moved on trolleys, should be covered with cloth or sacking.

4. Eye goggles do not afford sufficient protection. The masks at present in use admit of improvement so as to be worn with more comfort; they should not be of too coarse a mesh, so as to prevent fragments of glass passing through, and in view of the possibility of injury to the vessels of the neck, they should be connected with a leather collar, or be continued downwards to afford protection to the neck and its vessels. They should be as light as possible, and fit without undue pressure. A recently devised shield which, resting on the shoulders leaves the face free behind, is being brought into use, and appears to be an improvement in some ways."

My experience[6] has shown that there is less difficulty in enlisting the support of the employers than the assent of the men to adopt precautionary measures.

LITERATURE.

1. Lans, *Tydschr. v. Gen.*, Dec. 19, 1908.
2. Simeon Snell, (a) *On the Prevention of Eye Accidents Occurring in Trades*, London, 1899; (b) *Special Rules for Bottling of Aerated Water*, Form 701, Inspector of Factories, England, Sept., 1901.
3. Hall, Gaylord C., *Ophthalmology*, Oct., 1910.
4. Praun, l. c., p. 113.
5. Hillemanns, *Arch. f. Aug.*, XXXII, 3.
6. Würdemann, *Northwest Medicine*, April, May, 1909.

CHAPTER XIII.

THE CONSERVATION OF THE WOUNDED EYE.

A. General therapy. B. Asepsis—Preparation for operation—Rules—Sources of infection—Dissection of lacrimal sac in suppuration of tear passages—Tying off canaliculi. C. Surgical technique of wound—Cleansing of conjunctival cul-de-sac—Lids and surroundings—Lacrimal passages. D. Surgical treatment of wound—Kuhnt conjunctival flap—Argyrol—Iodoform rod—Cauterization. E. Infected wounds—Cauterization—Subconjunctival injections. F. After-treatment—Bandaging—Leeching—Hot and cold applications—Dressings after operations or accident. G. Anesthesia—Cycloplegia—Mydriasis and analgesia—Literature.

THE MEDICINAL TREATMENT OF OCULAR INJURIES. ASEPSIS, ANTISEPSIS, AND THE CARE OF THE WOUND.

The handling of an injured eye should be conservative from the first, to keep vision, preserve the appearances, relieve the agony, and even in some cases to save life.

With this maxim in view we consider first those methods of treatment which give the best end results as regards vision; and secondly, as regards the appearance of the globe and its surroundings, bearing in mind always the dread possibilities of sympathetic disease in the other eye, but having ever in mind the operation of enucleation or its substitutes with which to combat this possibility. As has been cited, and will be often noted in this book, a most trivial injury may, through ignorance, neglect, or mismanagement, result in total loss of vision in one or both eyes, disfigurement, or even death; and in all cases with damage to the earning ability, pain and suffering all out of proportion to the same character of injury inflicted upon other structures of the body.

The r a d i c a l t r e a t m e n t of injuries to the eye is practically summed up in the word enucleation, nearly all other procedures being conservative.

True it is that we cannot hope to save an eye, or its vision, when it has been freely opened and considerable of its contents have been extruded; nor one which has been badly infected or where the intraocular structures have suffered loss of contiguity, as in large wounds of the bulb with great loss of vitreous and infection, rupture, detachment of the retina and chorioid, rupture of the sclera and cornea with extensive detachment of the ciliary body, irido-cyclitis traumatica, and beginning

panophthalmitis. Where ciliary wounds threaten sympathetic ophthalmitis, especially in the working classes, it is often advisable to enucleate rather than run the risk. The indications for enucleation are treated of elsewhere. Many minor procedures described in the following pages save eyes and vision that would otherwise be hopelessly lost.

(A) GENERAL THERAPY.

As a rule an injury to the eye immediately incapacitates one from pursuing the employment of the moment, be it business or pleasure, and, in dangerous surroundings, he may be so blinded as to fall into imminent danger of life and limb and so must seek or be led to a place of safety. But few ocular accidents are attended by severe nerve shock, evinced by loss of consciousness, but such as occur are to be treated by fresh air, dashing of water in the face, chafing the hands and by stimulants. Immediate severe pain may be met by narcotics, as a hypodermic of morphia, but as a rule these patients are ambulatory and go to the physician in his office or to a hospital clinic.

The public should be taught that the best first-aid to injured eyes is, as a rule, to let them alone, apply a clean cloth bandage and to immediately seek a physician, more especially an oculist, except where large quantities of foreign material, as sand, dirt or corrosive substances, as lime or chemicals, enter the eye; then the first application is free douching with clean, clear water. The use of house remedies, as tea, milk, honey, urine, beefsteak, poultices of bread and milk, antiphlogistine, chamomile, sage tea, or other applications is to be deprecated, for all of these only foment the growth of germs and act as a poultice. The eye is in no wise a boil to be drawn out!

(B) ASEPSIS.

Horace[1] said in ancient times:—"Quid-quid delirant reges, plectuntur archive!"

The therapy of the wounded eye is based upon general surgical principles, and from beginning to end the watchword is asepsis, or cleanliness.

The surgeon's hands should be clean, his dress neat, and while surgical millinery is superfluous in ophthalmic practice for the most of our work, the clean shirt, the changing of his street coat for the white dressing coat when handling cases, and the absence of beard of the surgeon are details of his personality that prevent, in a measure his infecting his own patients.

His office or treatment-rooms should be devoid of hangings and

dust-catchers. Modern surgeons are coming to have a treatment or dressing-room in connection with their offices, with tiled floors, aseptic white furniture and complete set of instruments and cases, quite as well fitted up as the hospital operating-room.

The proper care of his instruments of examination, the sterilization of metal instruments and of medicaments, cleanliness of towels, bandages, etc., all prevent his carrying infection and lead to confidence on the part of his patients and to successful results.

Though such care is not generally taken, yet it is essential and obligatory for the twentieth century surgeon. Even in the public clinic there is no reason why such elementary personal rules should not be carried out. The day of the doctor with his frock coat, going from the examination room to the operating table is past. In the hospital, with the skilled assistance of the trained nurse, the eye surgeon should have his surroundings as immaculate as those of the abdominal surgeon.

In the operating-room, as remarked, surgical millinery is not so essential. The cap, the gauze veil and the operating gown are necessary, but not, as a rule, the rubber gloves, the extreme antisepsis, the white trousers and shoes of the general surgeon. Our operations are usually quickly done under local anesthesia and our hands seldom touch the parts operated upon, or the portions of the instruments that may come into contact with the wound or its surroundings.

In a hospital the eye patient is usually best attended to in a private room or small ward, away from patients afflicted with general diseases or suffering from other accidents. Quiet as a rule is essential; confinement to bed only in severe cases or where the eyeball has been widely opened. The dark-room, with its necessarily poor ventilation, has largely gone out of use. The patient may be protected from glare by screens, shades and dark glasses.

When a patient with an injured eye enters a hospital a full bath is indicated, as a rule, unless contra-indicated by his class and appearance, or the necessity of preventing a jarring of the eye; and maybe a special preparation of the ocular surroundings by soap and water, 1:5000 sublimate compress and light bandage, unloading of the lower bowel by a saline and a rectal injection is necessary for general anesthesia and if the time warrants, and general care as for other cases, may be deemed necessary.

My preparation for such cases is the following:

Head. Shampoo with green soap the night before the operation.

Face. Wash thoroughly with green soap, and after washing with plain water, use a solution of 1:10,000 bichloride the night before the operation.

Nose. Irrigate with warm Seiler's solution the night before the operation, and again the morning of the operation.

Eye. Wash eyelid and eyebrow carefully with green soap, and after rinsing with hot water use a solution of 1:10,000 bichloride. Wash eye thoroughly with warm boric acid solution and instill argyrol 50 per cent.; a bichloride pad 1:10,000 to be placed over the eye and bandaged all night. Repeat this on morning of operation.

General. Give patient divided doses of calomel, one-fourth grain to a dose, every half hour for four hours the night before the operation, and follow with one-half ounce magnesia sulphate in the morning. Do not allow patient who is to have a general anesthetic any food the morning of the operation.

It must be remembered that as Praun[2] says, "Halbe aseptik ist schlechter als gar keine," for it gives a false security.

As a rule injured eyes occur in ambulatory patients and are seen first by the physician in his office, coming with a more or less clean or dirty bandage applied by the patient, his friends or some other physician, and the after-treatment in most cases is done by the physician at his office.

A general rule in this class of cases is not to allow the injured person or anyone else to touch the eye or make any applications, at least until the external wound has healed and there is no longer danger of infection.

C. S. Bull[3] discusses the various sources of infection following operations on the eye, the most frequent being the edges of the eyelids, the conjunctival sac, and the lacrimal canaliculi and sac. He points out the well-known fact that a normal conjunctival sac, free from noxious bacteria of all kinds, does not exist, citing Gayet's, Rymowicz's and Fick's experiments in proof of this.

He mentions briefly a few of the more common forms of infection of the conjunctiva as a help to deciding when to operate, if at all, in the presence of an infection. His conclusions are:

"I. A careful microscopical and bacteriological examination should be made of the contents of the conjunctival sac in every suspected case, carrying the examination as far as the cultivation of the bacteria in a proper medium, and the subsequent inoculation of the germs.

II. If toxic germs are found in great numbers, no matter what their varieties, no operation on the eyeball should be undertaken until the germs have disappeared, and the conjunctival sac has been rendered as sterile as we can hope to make it.

III. If there be suppurative disease of the lacrimal passages, whether of canaliculi, sac, or nasal duct, all operations upon the eyeball are

positively contra-indicated. The lacrimal sac must be excised, and the lacrimal puncta must be obliterated by the galvano-cautery, before any operation on the eyeball is undertaken. In a case of catarrhal dacryocystitis, or of mucocele of the sac, both canaliculi should be incised, and the sac injected daily with an antiseptic astringent solution, and free irrigation through the nasal duct carried out until all secretion has ceased. Even in cases of great urgency, as, for example, acute inflammatory glaucoma, the writer would not feel himself justified in modifying the above statement.

IV. If the secretion of the conjunctival sac on examination is found to be infected, but the bacteria are few in number and of slight toxic variety, operations may be done on the eyeball when necessary, but these

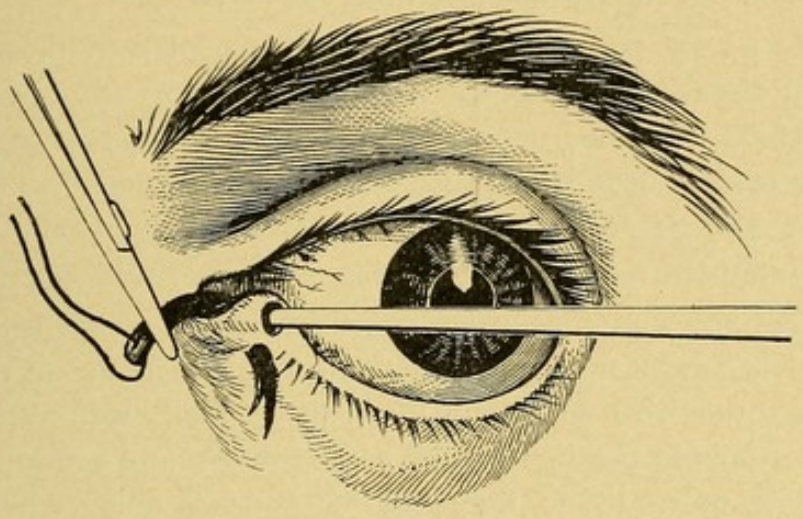

Fig. 90.
Taylor's method of tying off canaliculus in dacryocystitis before operation involving opening eyeball, as adapted by author.

eyes should be opened and examined twice in the twenty-four hours, and the conjunctival sac gently irrigated with warm normal salt solution, or warm sterilized boric acid solution, and then the eye should be immediately rebandaged.

V. In operating upon the eyeball in the presence of an apparently normal, sterile, conjunctival sac, the following steps should be taken:

1st. The forehead, eyebrows, temple, cheek, bridge of the nose, and external surface of the lid should be carefully cleansed with hot water and soap, and dried with aseptic cotton pads.

2nd. The margins of the lids should be carefully but gently rubbed with sterilized, moist, cotton pads, and simultaneously irrigated with a warm, sterilized, physiological salt solution.

3rd. Careful irrigation of the conjunctival sac with the same ster-

ilized, normal salt solution, and then closing the lids with a moist, sterilized cotton pad. The lids should remain closed in this way until the speculum is introduced.

VI. In all cases the bandage should be removed and the eye examined under the strictest aseptic precautions, as strict as those employed at the time of operation.

VII. On the first sign of infection of the wound, the edges of the lids are to be thoroughly cleansed in the same manner as at the time of operation; the conjunctival sac is to be thoroughly irrigated with a sterilized, normal salt solution; the wound is to be reopened and cauterized through its entire length with the galvano-cautery; and the anterior chamber is to be gently but carefully irrigated with a sublimate solution (1:5000); and then the conjunctival sac must be again irrigated, and the lids must be closed simply under a moist sterilized pad.

S. J. Taylor[4] points out that the modern plan of thoroughly dissecting out a diseased lacrimal sac before performing any operation upon the eye in which the globe is opened is the one to be adopted in the vast majority of cases. But this procedure may, at times, be undesirable, especially in old, decrepit patients. In such examples the writer has successfully adopted the plan of ligating the upper and lower canaliculi.

The parts are well cocainised, some powdered cocain being applied, a fine probe is passed into the canaliculus and held by an assistant or nurse against the wall of the nose; then a small, well-curved needle, armed with a double silk ligature, is passed under and around the probe, taking a little more tissue than the canaliculus only, whereupon the probe is withdrawn and the double ligature firmly tied; the same is done to the other canaliculus and communication with the sac is thus entirely shut off, as can be proved by there being no more regurgitation of pus when pressure is made over the sac.

Immediately after the ligatures have been applied, the conjunctival sac is well washed out with sublimate solution and the cataract operation proceeded with. To prevent mydriasis as a result of the cocain, the writer instills a little eserin a few minutes before the use of this anesthetic. It is as well, also, to pass the needles rather near the puncta to leave plenty of room for the repetition of the procedure, should needling of capsule be subsequently required, as occurred in one of my cases. Very little reaction follows the application of the ligatures, the dressings and after-treatment are not in any way modified; the ligatures often cut out or can be removed a few days after insertion, long before which—especially if a conjunctival flap is secured—the wound in the globe is healed and free from risk of infection.

(C) SURGICAL TECHNIQUE OF THE WOUND.

In general we do as follows: (1) Render the conjunctival cul-de-sac, the lacrimal passages and the nose, as well as the lids and skin surrounding the eye, as free from germs as possible. (2) Replace or cut away prolapsed structures. (3) Sew up the wound or coapt its edges in other ways. (4) Use after-treatment by some antiseptic that will prevent the entrance and development of micro-organisms. (5) Keep the wound quiet and occluded by bandaging, the ciliary body at rest, and the pupil open by cycloplegics.

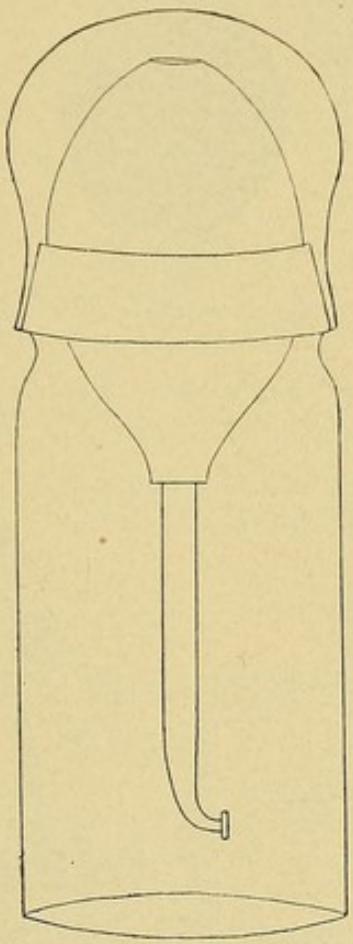

Fig. 91.
Aseptic eye wash bottle.

The conjunctival cul-de-sac.

Since von Graefe[5] produced his statistics to show that cleaning of the conjunctival cul-de-sac reduced the loss of the eye by infection in cataract operations from 5 or 6 per cent. to less than 1 per cent.; and with full asepsis, and attention to other inroads of infection, as the nose, lacrimal sac and skin of the lids, it has been reduced to less than ½ of one per cent. in recent operators' hands; not only asepsis of the op-

erator and his instruments has been the rule, but treatment of cases preliminary to operation and careful cleansing of wounds has resulted in the salvation of eyes that would formerly have been lost.

Fig. 92.
Anterior chamber irrigator.

Recently Elschnig[6] has shown that for absolute protection from infection from operations it is necessary to secure: 1. Normal conditions of the skin of the lids and the lacrimal passages. 2. Absence of inflammatory changes in the conjunctiva. 3. Absence of pathologic

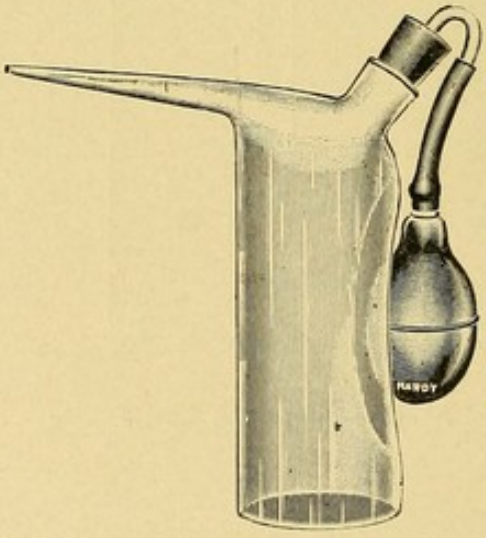

Fig. 93.
Todd's wash bottle.

micro-organisms, especially streptococci and pneumococci in the conjunctival cul-de-sac (diagnosed by culture on serum bouillon). 4. Absence of general and organic diseases, especially angina. 5. Special treatment before the operation of metabolic affections (auto-intoxica-

tion). 6. Careful operative technique, and all operations involving the globe should be subconjunctival or made so by a conjunctival flap.

The technique of asepsis and antisepsis is now well taught in the

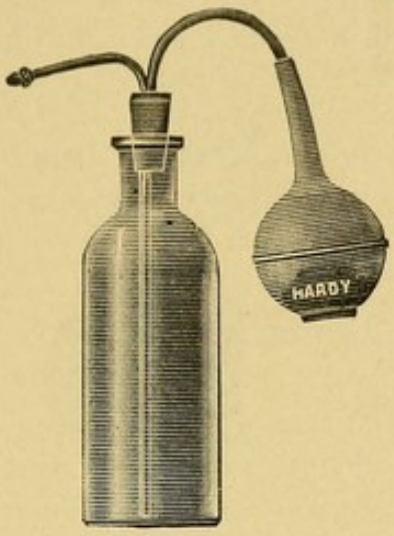

Fig. 94.
Elwood's wash bottle.

schools, and the older practitioners have mostly learned it for themselves.

Sterilization of the conjunctival cul-de-sac is of first importance, then after-care of the cul-de-sac.

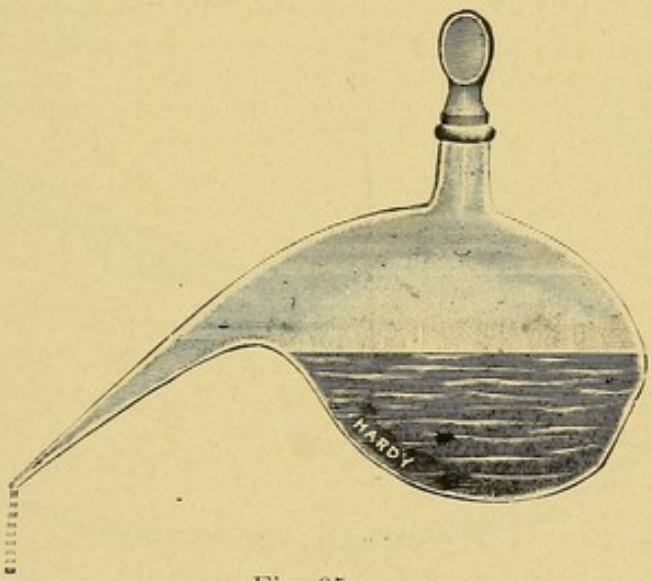

Fig. 95.
Undine.

The cleansing of the cul-de-sac is of course more difficult and has to be accomplished as an emergency procedure more generally in ocular injuries than in cases which are to be prepared for an operation. This should be done with chemically indifferent solutions, as douching with

normal salt solution or 3 per cent. boric acid. These are best injected into the eye by the syphon bottle of Elwood or Todd, which keeps the solution from contact with the air and prevents its contamination: the rubber bulb, glass-ended syringe, or other forms of the eye douche, or in emergencies even a sterile medicine dropper.

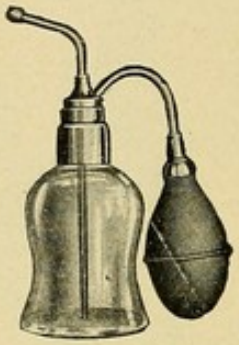

Fig. 96.
De Vilbiss eye irrigator.

Bach[7] and Franke[8] in several articles, and other writers, have claimed from bacterial examinations that "the best method for sterilization of the conjunctival cul-de-sac consists in mechanical cleansing, followed by syringing with an antiseptic solution, especially sublimate

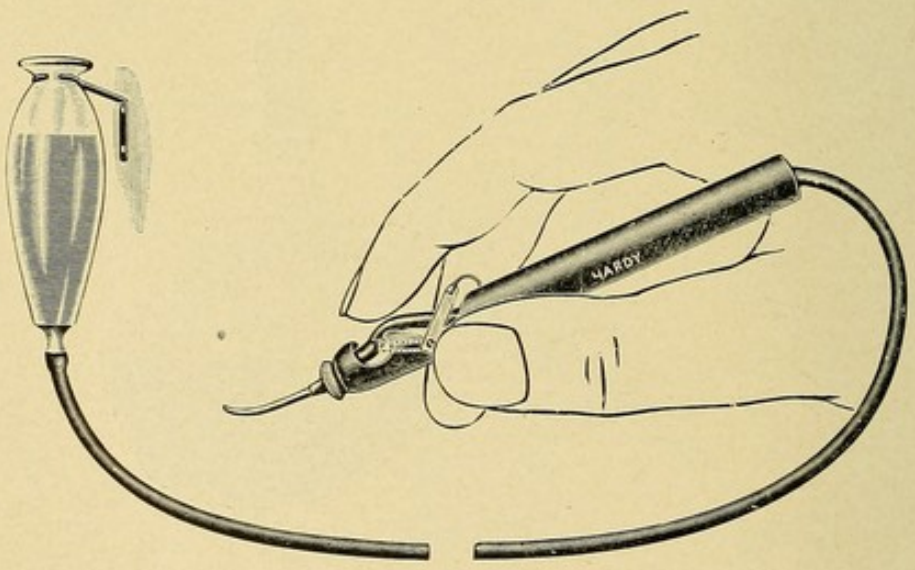

Fig. 97.
Lippincott's irrigator.

1:5000. But the irritation caused by such an application results in the exudation of mucus which is a fertile medium for germs, and hence the chemically indifferent solutions are generally preferable."

In America a specially prepared ointment of 1:3000 sublimate in

petrolatum* has been devised by Jos. White[9] and reported upon favorably by others. I like this too, but only as an application to the lid edges or for after-treatment. Other solutions are mercury oxycyanide, 1:3000; chinosol, 1:1000; hydrogen peroxide, 1:15.

Nitrate of silver is likewise good, but is too irritating and corrosive. The newer silver salts, especially argyrol, protargol, and iatrol, possess the advantages of not being irritating and yet of sufficient germicidal power to prevent further development after the eye has once been cleaned. Of these I have had great delight in argyrol used in strong—i. e., 25 to 50 per cent. solutions.

It has been shown that it is impossible to entirely free the conjunctival sac from germs, yet by the means indicated their number is so reduced and their possibilities of reproduction so hindered that the eye may be made practically free from danger of infection.

The removal of catarrhal nasal secretions by douching, before an operation or surgical treatment of ocular wounds of any gravity, with mild saline, antiseptic solutions as Seiler's, Dobell's or other formulæ, is indicated. For this the rubber bulb syringe or glass nasal douche is used, solution being injected without force and the nose gently blown clear of secretion by the patient.

The lids and surroundings.

The skin of the lids and face is cleaned with green soap and water, then alcohol, and afterwards by 1:5000 sublimate solution; gauze wet with the latter may be laid upon the eye during a half-hour preceding the surgical work, or, if time be given, the full preparation as for an operation. It is seldom necessary to cut the lashes, but often to shave the eyebrows.

Murphy[10] maintains that "As the mucous membrane covering the eye is continuous with that covering the nose, one may be readily infected from the other. Ulcers and injuries to the eyes do not do well because this source of infection is not generally recognized."

The lacrimal passages.

If upon inspection and manipulation the tear sac be found free from pus, evinced by pressure inwards and downwards with the finger tip resulting in no purulent discharge, but the appearance of a small

---

* ℞

Hydrarg. bichlor.	.06
Sod. chlorid	.30
Aquæ	.50
M. tritura et adde petrolatum alb.	200.
S. White's salve	

drop of tear fluid at the canaliculus, it may be left alone. If suspicious or a tear drop does not appear, a weak argyrol or fluorescein solution may be injected by way of the canaliculus to the nose, when upon gentle use of a handkerchief the stain will be found if the passages are patent.

If the tear sac be infected our troubles begin, for here we have the nidus of the pneumococcus, the staphylococcus and the streptococcus, besides the others as before noted. A long previous treatment, as in cataract and other proposed operations, is in the case of injuries manifestly impossible. Casey Wood[11] has tied off the canaliculi temporarily by passing a needle under the lower tube, coming out above the upper, and tying same.

The puncta may be temporarily obliterated by the galvano-cautery, or a radical extirpation of the lacrimal sac may be done. At any rate the puncta should be slit, the lacrimal sac thoroughly syringed with antiseptic solution, and the inner canthus dusted with powdered iodoform, leaving the radical operation to be done later.

(D) SURGICAL TREATMENT OF THE WOUND.

This should be carefully done by mopping with cotton wet with a mild antiseptic solution; all foreign bodies should be removed; the prolapsed iris and portions of the ciliary body cut off; and the wound coapted, if small, without sutures. Scleral wounds may be covered by sliding conjunctival flaps, if large, an additional one or more sutures being taken in the sclera itself. Perforating corneal wounds are best covered at once by the Kuhnt method,[12] by which I have saved many eyes. First, these flaps cover the wound and prevent infection; second, they bring the wound edges together; and third, they cover defects caused by loss of tissue. They may be made with a single or double peduncle, or a part of the whole conjunctiva may be dissected at the limbus and drawn over the cornea by interrupted or a pouch stitch, which may be permitted to remain for five days, and when removed the wound will be found to have coapted under the covering.

It is not only difficult but often impossible to suture corneal wounds, on account of the necessary handling causing prolapse and loss of the ocular contents.

Antisepsis of a wound has best been achieved by me by 50 per cent. freshly prepared argyrol solution with which the eye is flooded upon completion of its toilet. In suspected infection I commonly inject a few drops of this solution into the anterior chamber. This causes no irritation and saves infection. The Haab[13] method of inserting an iodoform rod into the anterior chamber has not been generally adopted. In

former years, and now, in Europe, powdered iodoform is liberally bestrewed on wounds and in the eye, but recently it has been shown that the antiseptic qualities of the chemical are poor and its disagreeable odor and irritative action has caused it to pass into disuse.

Cauterization of the wound is not needed except in the case of infected ulcers.

(E) INFECTED WOUNDS.

Should the wound be found infected after due cleaning a solution of argyrol 50 per cent. should be freely instilled. If hypopion ulcer has

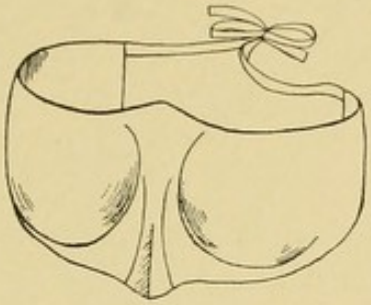

Fig. 98.
Ring's papier maché mask.

formed, a free cauterization should be made and the eye filled with argyrol solution or 1:3000 sublimate ointment, and bandaged; or the open treatment by hot applications one-half hour every three hours, with frequent instillations of argyrol and sublimate 1:3000 douching may be substituted.

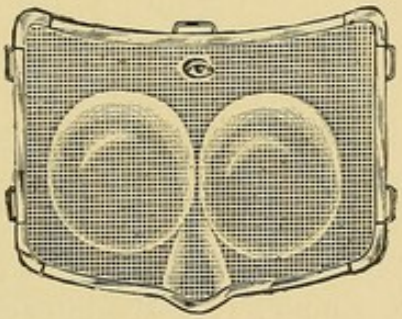

Fig. 99.
Emerson's double wire mask.

Subconjunctival injections of sublimate, oxycyanide and even of normal salt solutions have saved many eyes.

Subconjunctival injections of 1:5000 mercurous chloride or cyanide, as advocated by Darier[14] and others for corneal and

intraocular suppuration, has in my hands been efficacious in preserving many eyes.

After cocainization the lids are held apart by an assistant, the conjunctiva near the limbus seized by a catch forceps, and a half to full hypodermic, preferably a glass Luer model, syringeful injected under the conjunctiva. This is immediately raised into a clear bleb, which

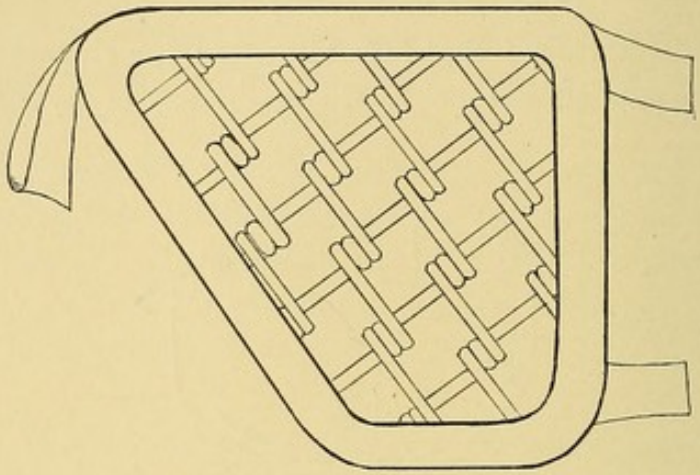

Fig. 100.
Fuchs' wire mask.

passes away in about a half-hour, leaving a slight redness and but little irritation. Several such injections may be repeated after 24 hours interval.

(F) AFTER-TREATMENT.

We well know from the work of Bach[7] that the secretions of the eye which may contain micro-organisms are carried by the lid movements through the tear passages to the nose, and that the ocular secretions are feebly antiseptic. We should not impede these natural safeguards by a pressure bandage. To protect the wound from actual contact with the fingers of the patient and the outer air is all that is essential.

There are all styles, shapes and kinds of occlusive bandages: For trivial injuries, as simple, recently impacted foreign bodies in the conjunctival cul-de-sac, or cornea, it has been my custom for a score of years after removal to secure partial closure of the lids and immovability of the upper lid by applying thereon a semilunar piece of adhesive plaster shaped to the cartilage of the upper lid; also advised by Ziegler.[15] This is removed by the patient the next day. Court plaster slips may be applied over the closed lids. Absorbent cotton behind a pair of smoked or amber glasses makes a light bandage for the

day. The use of absorbent cotton held in place by two strips of adhesive plaster to the forehead and cheek makes an occlusive dressing that may be replaced night and day.

More permanent dressings are afforded by the roller bandage, the two or three-tailed bandage, and that for both eyes by the Moorfield four-tailed bandage. Where protection from the fingers or blows of the patient are needed the single or double wire mask of Fuchs, Frothingham, Emerson, or the author's model, may be used. The papier maché mask of Ring, or bizarre protectors as the cocoanut shield of Westhoff.[16] Necessity led Westhoff to the employment of the cocoanut shell as a protector to the eye after cataract operations. He employs various sizes, perforated for ventilation and attached to the forhead and cheeks by strips of adhesive plaster. They are light, can be boiled and used with any antiseptic fluid. Wolffberg[17] commends them and believes they may serve other useful purposes.



Fig. 101.
Würdemann's base-ball cataract shield.

In all cases where a roller bandage is to be occlusive, and not intended to slip or press upon the eye, it should be held firmly in place by long strips of adhesive plaster wound around the head, rather than trusting to pins.

Compressed cotton, lintine, or a single layer of gauze next to the eye prevents the cotton from getting into the lid aperture. Where

lintine is used it is my custom to apply it moistened with antiseptic solution; drying in a few hours it conforms to the lids and makes a serviceable splint.

In all cases it is my custom to instill 25 per cent or 50 per cent argyrol solution and to apply aseptic petrolatum or the White sublimate ointment to the lids before applying the bandage. As a rule bandages are removed in twenty-four hours and the eye dressed again.

Leeching, and always in these enlightened aseptic days by the artificial leech applied at the temple near the outer canthus, is indicated when there is great pain and chemosis, giving relief by depleting the local circulation and perhaps also by counter-irritation.

Atropin is nearly always indicated, as it puts the pupil in a position where iritis may occur without resultant adhesion of the pupil, or formation of synechiæ, and likewise quiets the ciliary muscle.

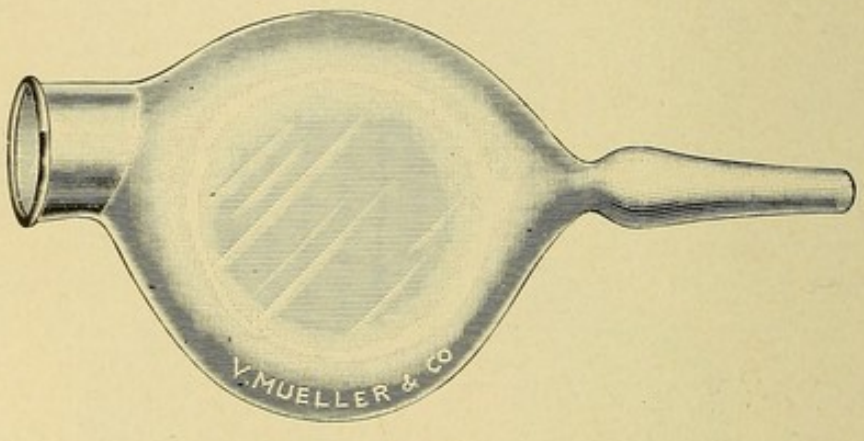

Fig. 102.
MacWhinnie's artificial leech.

Exception is to be made in non-penetrating wounds where the intraocular tension may be raised, when eserin or iridectomy is indicated. Eserin has been disappointing in wounds at the border of the iris, and has only been useful in radial tears.

Argyrol, the White ointment, and antiseptic washes of boric acid, sublimate, oxycyanide and chinosol have been useful in the after-treatment.

Hot compresses made of several layers of cotton cloth or gauze soaked in boiling water and wrung nearly dry, changed every two minutes, one-half hour on during every two hours, applied to the closed lids, which may be greased with petrolatum, are useful to stimulate nutrition, as in ulcers, and to relieve pain, as in iritis. Iced applications of similar materials cooled on block of ice, applied one hour on and one off. deter the development of germs but must be carefully watched to

avoid disturbances of nutrition. A siphon apparatus has been designed by Leiter and Griffin.

Bourgeois,[18] during the past six years, has treated and saved six eyes compromised by infection after operations for cataract. He employs subconjunctival injections of a 1:1,000 strength solution of cyanid of mercury, one-half 1 c. c., together with the usual measures of atropin, cauterization, etc.

He truly avers that there is nothing more disagreeable to the sur-

Fig. 103.
Griffin's syphon eye compress, for hot or cold applications.

geon than finding, when he removes the dressing from an operated cataract, that the eye has been infected. He has made it a rule not to disturb the dressing until the third day, unless pain is complained of; but having had a case in which pus was found, although for three days after operation there had been freedom from pain, he has since made it a rule to change the dressing after the first twenty-four hours, if the least doubt exists, such as might arise from the previous existence of any dacryocystitis.

The important rule to be observed, according to Bourgeois, is to examine the eye the day following the operation if the patient com-

plains of pain, or if there is the least suspicion; and in any case the dressing should be renewed for the first time not later than the third day. The dressing should be changed in the patient's room and in a subdued light. The eyelids are to be opened very cautiously and slowly and a view is to be quickly had if anything unfavorable has occurred. At this time only is it possible that any therapeutic measures to counteract in-

Fig. 104.
Small ice-bag for eye.

fection can be available—later the effect of them, if an infection exists, will be very problematic. It is important, Bourgeois urges, for the surgeon to act at once; that he himself should examine the patient and not entrust the first visit to another.

He insists on thorough asepsis and antisepsis, and that it is from these so few cases of panophthalmitis result. But nevertheless all the

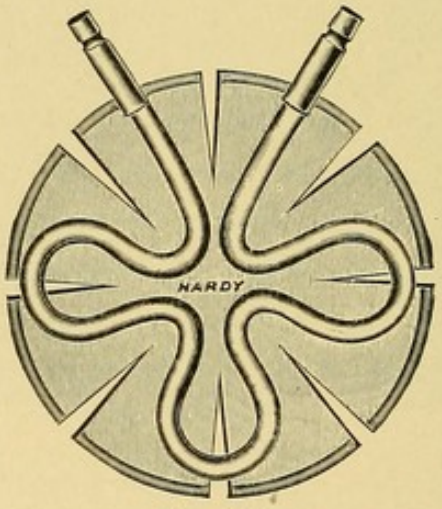

Fig. 105.
Leiter's lead coil for cold or hot applications.

operators may estimate that 1 or 2 per cent. of operations will result in infection; and he fears that this percentage can never be improved.

Bourgeois believes that the site of the infection process is at the eye fundus; and he avers that in six years he has not seen a single case in which suppuration commenced in the cornea, the infection always showing itself deeper. It is admitted that there are two varieties of infection: (1) That beginning in the cornea twenty-four hours after the operation, which is the more grave; (2) that originating in the uveal

tract from the fourth to the eighth day, which is less serious, but which goes on to destroy the eye unless it receives appropriate treatment. The infective cause is the same in all cases, varying only in virulence from the number of colonies and also with their site.

He insists that the only reliable treatment is subconjunctival injection of sublimate (better, however, are the solutions of mercury cyanid). Some years ago he used these solutions sparingly and without effect; now he employs them more boldly. He prepares his solution each week (cyanid of mercury 1:1,000 of distilled water). He first instills cocain and then injects deeply the mercury solution shortly afterwards, carrying the needle under the conjunctiva about a centimeter and a half. If the case is grave half a centigram of the cyanid solution is injected, which is repeated in twelve hours. If the case is not severe, four or five injections suffice. If very severe, seven or eight may be

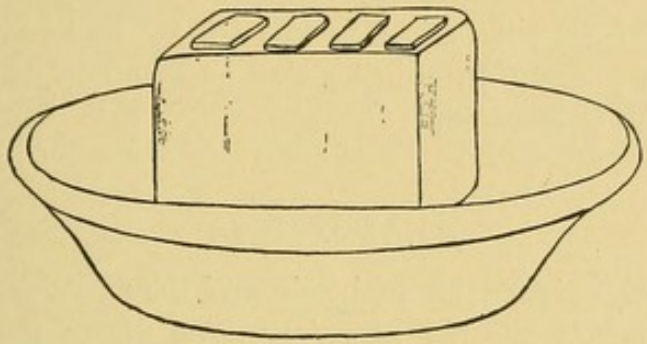

Fig. 106.
Eye pads on ice for application of extreme cold

required. If the patient suffers much from the injections, dionin will relieve the pain. He supplements this treatment with atropin and also with mercurial inunctions. The corneal wound, if necessary, is treated with galvano-cautery, or, better, by currettage. The dressing with aristol and airol is changed twice daily. The general treatment is milk diet, purgatives and antipyretics. He tried in one of his cases the subcutaneous injection of the antistreptococcic serum of Marmorek, without effect.

He gives a brief resumé of six cases in which infection of the operated eye followed cataract extraction, and in each case his claim is an arrest of the infection-process. In three of them the vision was fairly good after an irido-capsulotomy; in none of them was the eye destroyed.

G. ANESTHESIA.

On account of the local pain, photophobia, and lacrimation, it is generally necessary to first apply a local anesthetic to an injured eye, be-

fore the examination can be proceeded with. Of these, solutions of cocain 5 per cent., holocain 1 per cent., eucain 2 per cent., or alypin 2 per cent., are in most common use. In grave cases of injuries to the orbital tissues and lids, or where enucleation is immediately necessary, or in exceptionally hysteric or nervous individuals, a general anesthetic may be necessary.

In no case should a local anesthetic, as cocain, be entrusted to the patient's hands for the relief of pain, for such breeds a false security, pain being Nature's warning of danger and a call for relief; and furthermore all of these solutions, frequently repeated, especially in the case of cocain, cause damage to the tissues.

V o s s i u s gives preference to cocain over stovain, alypin and novocain. He performs extirpation of the lacrimal sac almost always under local anesthesia with cocain and adrenalin, a mixture which may be bought sterilized under the name of eusemin.

The control of the ciliary muscle and iris by cycloplegics and mydriatics is helpful in preventing pain as well as in other ways. Atropin in 1 per cent. solution is efficacious.

ANALGESICS.

Dionin, however, is a true analgesic and may be freely used in 5-10 per cent. solutions. After the first few applications the edema of the conjunctiva caused by it does not recur, but the analgesic effect remains unimpaired, giving more or less relief from acute pain for three to twelve hours after each instillation.

In exceptional instances morphine or other general narcotics may be administered by hypodermic injection in .01 to .02 doses.

LITERATURE.

1. Horace, *Epics*, I, 2, p. 14.
2. Praun, l. c. p. 121.
3. C. S. Bull, *Med. Rec.*, Sept. 24, 1904.
4. S. J. Taylor, *Ophth. Rev.*, Oct., 1909.
5. von Graefe, *Arch. f. Ophth.*, xxv, 3, p. 348.
6. Elschnig, *Med. Klin.*, No. 38.
7. L. Bach, *Arch. f. Ophth.*, xl, 3, and *Arch. f. Aug.*, xxx, 2, 3.
8. Franke, *Arch. f. Ophth.*, xliii, 1.
9. Jos. White, *Trans. sec. Ophth. A. M. A.*
10. Murphy, F. G., *Iowa Med. Journ.*, Nov. 15, 1904.
11. Casey A. Wood, Personal Observation, 1895.
12. Kuhnt, *Die Verwerthbarkeit der Bindehaut*, etc., 1898.
13. Haab, *Journ. A. M. A.*, and *Atlas of Operative Ophth.*
14. Darier, *Thérapeotique Oculaire*, p. 32.
15. Ziegler, Personal communication, 1911.
16. Westhoff, *Woch. f. Therap. u. Hyg. des Auges.*, June 14, 1906.
17. Wolffberg, ref. Westhoff.
18. Bourgeois, *La Clin. Opht.*, Oct. 10, 1904.
19. Vossius, *Deut. Med. Woch.*, No. 49, 1906, p. 2010.

CHAPTER XIV.

THE RADICAL TREATMENT OF OCULAR INJURIES.

A. Indications for enucleation and its substitutes. B. Anesthesia for radical operations—(a) General anesthesia — Ether — Chlorofrom—Scopolamin-morphin—(b) Local anesthesia — Cocain — Infiltration anesthesia. C. Enucleation—Preliminary treatment—Care to operate on the proper eye—Canthotomy—Simple enucleation—Arlt or Vienna method—French method—Author's or American method with pouch suture. D. Evisceration or exenteration. E. Mules' or implantation operation. F. Transplantation of animal's eyes. G. Optico-ciliary neurectomy. H. Keratectomy or abscission.

"Les trois poincts ausquels s'exercent les opérationes de chirurgie sont joindre le séparé, oster le superflu, séperer le continu. Reste en bref le quatriesme qui est adjouster ce qui défaut naturellement on par accident." (Ambroise Paré[1]).

Tendencies in surgery are in the direction of conservatism, and in ophthalmic surgery also we should adopt the same principles, especially in regard to enucleation of the eyeball. We are now able to save many eyes which in earlier times would have been removed. This is due partly to the progress made in the treatment of diseases of the eyes, partly to operative methods adapted to substitute enucleation—to save either the whole globe or parts of it—parts which form a better stump for the prothesis.

Although enucleation or its substitutes is the most radical operation, yet there are a number by which the form of the globe is saved, among which is abscission of staphyloma, iridectomy for iris prolapse; removal of the lens for traumatic cataract, operations for reattachment of the retina and others by which though a portion of the organ is removed, sight may be saved; which may then, together with enucleation and its substitutes, be briefly considered.

(A) ENUCLEATION AND ITS SUBSTITUTES.

The indications for the various radical procedures have been so ably demonstrated by de Schweinitz,[2] that I herewith reprint the resumé of his statistical paper.

"Based upon the opinions of American surgeons and similar to the

one recently published by the Ophthalmological Society of the United Kingdom, enucleation and all its substitutes have been investigated. The writer discusses these various substitutes under the following headings, his deductions being based upon evidence collected by means of letters of inquiry sent to 275 ophthalmic surgeons of the United States and Canada: (1)Abscission; (2) Evisceration; (3) Mules' operation; (4) The implantation of an artificial globe into Tenon's capsule after the removal of the eyeball; (5) Implantation of a sphere of sponge after enucleation; (6) Optico-ciliary neurotomy and neurectomy, sclero-optico neurectomy, eviscero-neurectomy; (7) Methods of preparing the stump after complete enucleation which best secure mobility of the prothesis and cosmetic results; (8) Implantation of glass balls into the orbit after remote enucleation of the eyeball.

The information gathered in this statistical manner has led the writer to the following conclusions:

(1) Eyes so diseased or injured that they have already excited sympathetic ophthalmitis, or eyes which contain malignant growths, should be enucleated.

(2) Eyes in which a suppurative process has begun may be enucleated with safety, provided the process has not involved the surrounding orbital tissues or already begun to extend posteriorly so that it would be difficult to obtain an aseptic socket; otherwise evisceration is the safer operation.

(3) Eyes so wounded that they are likely to excite sympathetic ophthalmitis should be enucleated if two weeks or more have elapsed since the reception of the injury, because under these circumstances enucleation affords a greater security to the patient than any of its substitutes. If the eye is so injured that the sclera is extensively lacerated, enucleation is also indicated.

(4) Eyes so wounded that they are likely to excite sympathetic ophthalmitis, if seen before two weeks have elapsed, need not be enucleated—that is, evisceration or Mules' operation may be performed, because, with perhaps the exception of a single case, there is no positive proof that these operations have of themselves excited sympathetic disease. They may fail to arrest the development of sympathetic ophthalmitis, just as enucleation may meet with a similar failure.

(5) Staphylomatous eyeballs, especially when they occur in children, need not, in fact, should not, be enucleated. When uninflamed, they may be treated by the operation of abscission or complete keratectomy primarily with safety, but it cannot be promised that subsequently, it may be for years afterward, the stump will not undergo calcareous or osseous change, which may excite sympathetic irritation in the other

eye and require enucleation. Staphylomatous eyes are suited to Mules' operation.

(6) Eyes which are greatly shrunken (excessive phthisis bulbi) should be enucleated, as they do not lend themselves with safety either to evisceration or to Mules' operation.

(7) Painful, blind, glaucomatous eyeballs, or eyeballs blind from chronic non-traumatic irido-cyclitis, may be treated by evisceration, with or without the insertion of an artificial vitreous, in the place of enucleation, with safety. They furnish one of the few indications for optico-ciliary neurotomy or neurectomy if enucleation or one of its substitutes should be refused by the patient.

(8) Enucleation is preferable in very old patients, when the time element is important, and when the physical condition is such that the prolongation of convalescence is undesirable.

(9) Evisceration as a substitute for enucleation is a safe operation, and temporarily yields a stump which is better than the stump after ordinary simple enucleation. Subsequent shrinking of this stump, however, ultimately renders the cosmetic effect of the operation no better than ordinary enucleation, while its inconveniences are much greater.

(10) The best cosmetic results among the substitutes for enucleation, if successful abscissions be excluded, are secured by Mules' operation, which is only positively contra-indicated by malignant disease, sympathetic ophthalmitis, extensive laceration of the sclera, and extreme phthisis bulbi. But it should be remembered that the primary excellent cosmetic effect of Mules' operation slowly lessens, owing to atrophy of the tissues of the orbit and sinking in of the artificial globe. This diminution in the volume of the stump is, however, much less marked than after simple evisceration.

(11) Whenever a complete enucleation is performed, there is no objection to the implantation of a glass ball or a piece of sponge into Tenon's capsule, except perhaps after enucleation for sympathetic and malignant disease, but it is doubtful if the ultimate cosmetic advantage of the operation exceeds that of carefully performed enucleation.

(12) There is no perfect substitute for enucleation, and necessarily this operation must continue to be performed in many, if not the majority, of cases. When it is performed according to the rules of improved technic, which includes suture of the severed tendons to the conjunctiva, the cosmetic effect of the operation is, primarily, at least, as good as any of the substitutes, with the exception of Mules' operation and abscission, and is free from the objections which surround them. It seems likely that with further improvement in technic, and particularly in the manufacture of artificial eyes, the cosmetic effect will

be enhanced and rendered less objectionable, the operation of enucleation and less necessary the substitutes for it.

(13) An enucleation which pays no attention to the preservation of the relationship between the conjunctiva, ocular tendons, and capsule of Tenon, is a brutal operation which should not be performed unless the disease of the globe and surrounding orbit is of such a character as to render this precaution impossible.

The foregoing conclusions seem to be warranted by the statistical information gathered in this paper, although I fully realize that some of them will not be acceptable to all of the 117 surgeons who have contributed their experience. For example, a number of operators undoubtedly reject conclusions 2 and 4, although they are in accord with the surgical beliefs of others. So, too, the general sentence in conclusion 5 is in equally direct accord with the views of others. In other words, in these conclusions I have endeavored to epitomize the opinions which have been expressed by the various surgeons, although necessarily it was impossible to construct a series of deductions which would be equally acceptable to all contributors. Personally, they seem to me to represent a safe line of practice. In those cases in which complete enucleation is not demanded—and in my opinion they are in the minority—Mules' operation, when successful, certainly furnished admirable results, but I feel sure that although at the present time, from the cosmetic standpoint, it seems to be one of the best, if not the best, of the substitutes for enucleation, it is not likely to endure as an operative measure in ophthalmic surgery unless the percentage of failure is greatly reduced. I believe, as I have stated in conclusion 12, that improvement in the technic of performing the operation of enucleation and in the manufacture of artificial eyes will probably be so great in the future that this and other substitutes for enucleation will seldom be required."

(B) ANESTHESIA FOR RADICAL OPERATIONS.

a. For nearly all operations upon the bulb cocain, holocain or other local anesthetic is sufficient. In operations involving removal of the globe or the major part thereof, on the lids or orbit, the general anesthetic ether, given by the drop method, is to be preferred as the safest. Chloroform is more easily given, its effects are evanescent and produces less after effects, yet the fear of lethal poisoning has led me practically to abandon its use after an experience with it in more than 2,000 operations. The A. C. E. and other mixtures so popular 20 years ago, are not now in general use among ophthalmologists.

Scopolamin, gr. 1/100, morphin, gr. ¼, by hypodermatic injection

one-half hour before operation either by general or local anesthesia, renders the patient quiet and less sensitive. It is unnecessary here to give the details of such procedures, which are familiar to every medical man.

Stuelp[3] reports his experiences with scopolamin-morphin narcosis, devised by Schneiderlin, in 100 various eye operations. The mixture used was scopolamin hydrochlor. 0.0012, morphin hydrochlor. 0.03, water ad. 2.00, under the name "scopo-morphin" in brown glass ampullæ hermetically sealed, the contents of which are injected in three doses at intervals of one hour. His results were:

1. The effect of the scopo-morphin injections is not always uniform and cannot be foretold. In 45 per cent. the drowsiness was complete; in 26 per cent. insufficient but useful; 29 per cent. the injections failed or had a disturbing influence.

2. The method is to be recommended, as it has decided advantages over inhalation narcosis for the operator as well as for the patient; even if insufficient it influences a subsequent choloroform narcosis favorably.

3. In general affections which may complicate inhalation narcosis, no disturbances occurred.

Stuelp would not like to be denied this method, as in operations in which it might be dispensed with, especially iridectomy in glaucoma, complicated cataract extractions, etc., it helps by quieting the patient, and insures against accidents.

b. Bruns and Robin[4] and others in America, Terrien,[5] Siegrist[6] and others abroad, advocate local anesthesia for such grave operations as enucleation.

Brüns uses a solution composed of ten drops of 4 per cent. cocain, ten drops of adrenalin and twenty drops normal salt solution, injected deeply at the sites of the four recti muscles. Some pain is experienced near the end of the operation and is equivalent to that of drawing a tooth.

Siegrist employs for the purpose a glass syringe holding 2.0 gm. with a slightly bent needle. The conjunctiva is thoroughly anesthetized with three drops of a 2 per cent. cocain solution, to which a few drops of adrenalin have been added. Now he grasps the conjunctiva, together with the capsule, by a forceps or the bent needle with the concavity directed towards the eyeball, and inserts the needle into the folds of mucous membrane; the point of the needle is then pushed between the orbital walls towards the entrance of the optic and ciliary nerves; 0.75 gr. of a 2 per cent. solution of novocain, to which also some adrenalin has been added, is now injected into the upper, lower, temporal and nasal sides of the bulb. The enucleation or exenteration

may be commenced from one to two minutes after the injection, and the patient will experience absolutely no pain.

Novocain is less dangerous than cocain and, therefore, preferable; the author injected in one case 3.0 gm. of novocain without producing any intoxicating symptoms.

Terrien[5] claims that when circumstances make general anesthesia impracticable, enucleation can be performed with very little pain under local anesthesia.

The technic that he uses is substantially the same as that recom-

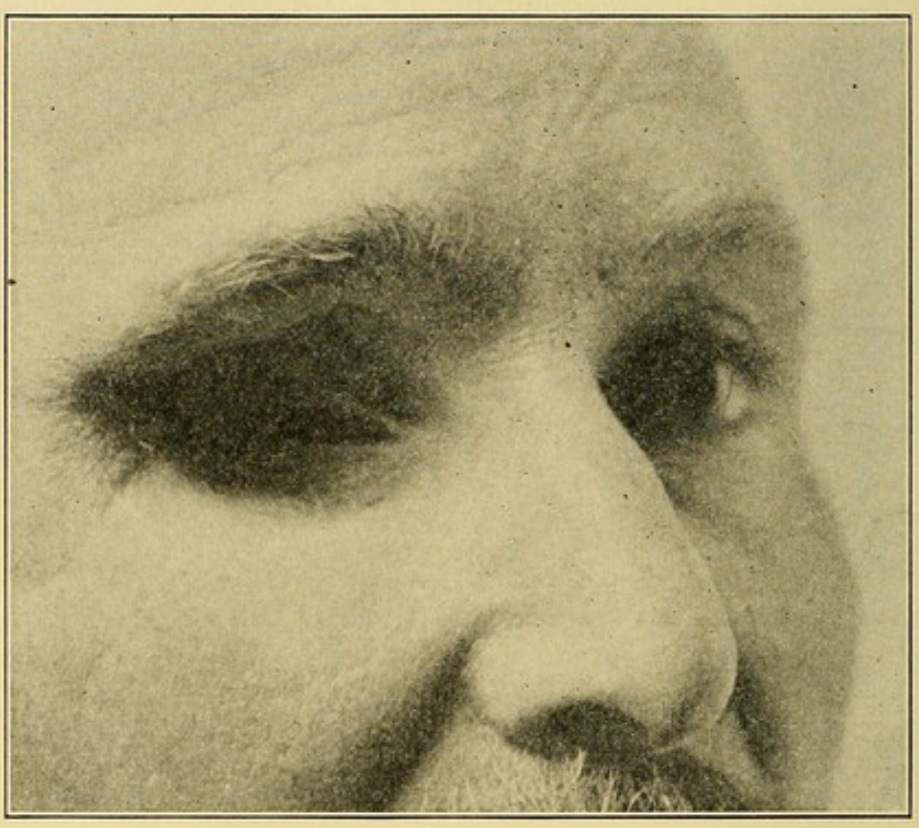

Fig. 107.
Results of exenteration of the orbit for carcinoma of lids and orbit following injury to external canthus.

mended by Weiss and Otto Meyer. After anesthetising the conjunctiva with several applications of a 4 per cent solution of cocain, a solution of 1 to 150 is injected at the extremity of each of the principal meridians—the needle penetrating to the region of the insertions of the straight muscles—which produces a chemosis completely surrounding the limbus. While allowing time for the cocain to act, morphia is injected subcutaneously before commencing the operation. Care is taken not to make unnecessary traction with the strabismus hook. If any pain is felt a few more drops of cocain solution are injected between the conjunctiva and the ball. After the globe is liberated from all adhe-

sions, and before cutting the optic and short ciliary nerves, a solution of cocain, morphia and salt is injected with an Anel syringe into the region of the posterior pole.

Enucleation may be done under infiltration anesthesia, as recommended by Weiss,[7] who reported five cases which were free from pain under the procedure. Infiltration is made by injection of one-half hypodermic syringeful beneath the conjunctiva in several places around the limbus, and by making deep injections toward the optic nerve. Long curved needles are used for infiltrating the nerve sheath. Edema ensues immediately after the injection, but goes down soon after the operation. He thinks this form of anesthesia to be indicated in fresh ocular wounds and intra-ocular tumors.

Local anesthesia for such a shocking operation as removal of an eye seems to me a barbarous procedure and to be indicated only where, on account of the general health of the patient, ether or chloroform cannot be safely administered.

(C) THE OPERATION OF ENUCLEATION.

This may be done by several methods. It was first proposed by Bonner in 1841. Previous to this period, extirpation, which is practically a surgical gouging out of the globe with Tenon's capsule and some of the appendages, as the muscles and some orbital fat, was done. In enucleation the globe is removed from within Tenon's or Bonnet's capsule.

The preliminary steps are those of asepsis, antisepsis, general preparation of the patient and anesthesia. Above all, care must be taken in cases to denote, where the two eyes look somewhat alike, by careful observation and by marking the brow with an aniline pencil, the eye which is to be removed, for there have been a number of instances in which the wrong eye has been taken out by a careless operator.

Haab[8] remarks that this mistake sometimes is due to the fact that the operator changes his position at the patient's head. In one such sad case the operator removed a perfectly sound eye when the other which was proposed for operation was an unsightly staphylomatous globe.

Canthotomy. If the globe is extremely enlarged by staphyloma or buphthalmos or tumor the outer canthus may have to be first cut wide open with a pair of straight scissors, the blunt blade of which is inserted under the outer commisure, which is then divided with one or two snips of the scissors. To prevent slipping, James has devised scissors with overlapping blades curved on the cutting edge, which are useful on occasion of greatly swollen tissues.

The simple Vienna or Arlt operation is done by the operator putting in a blepharostat, or having the lids held apart by two retractors or by the assistant's fingers, seizing the conjunctiva at the

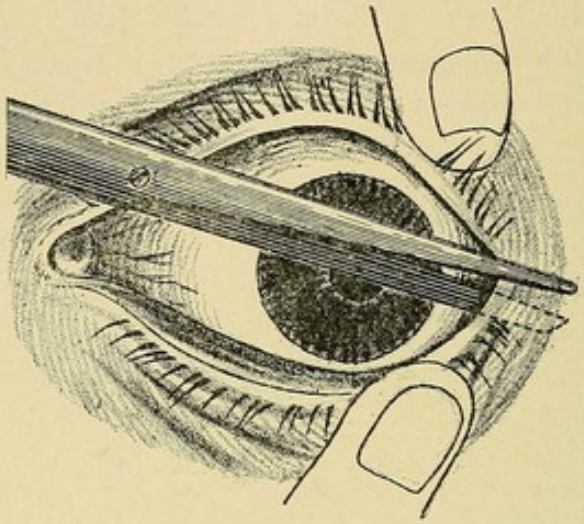

Fig. 108.
Canthotomy.

limbus with a pair of mouse-tooth forceps at the nasal side, dissecting around the limbus with a pair of curved tenotomy scissors, forming a cuff, at the same time stretching the tissue so that the cut conjunctiva

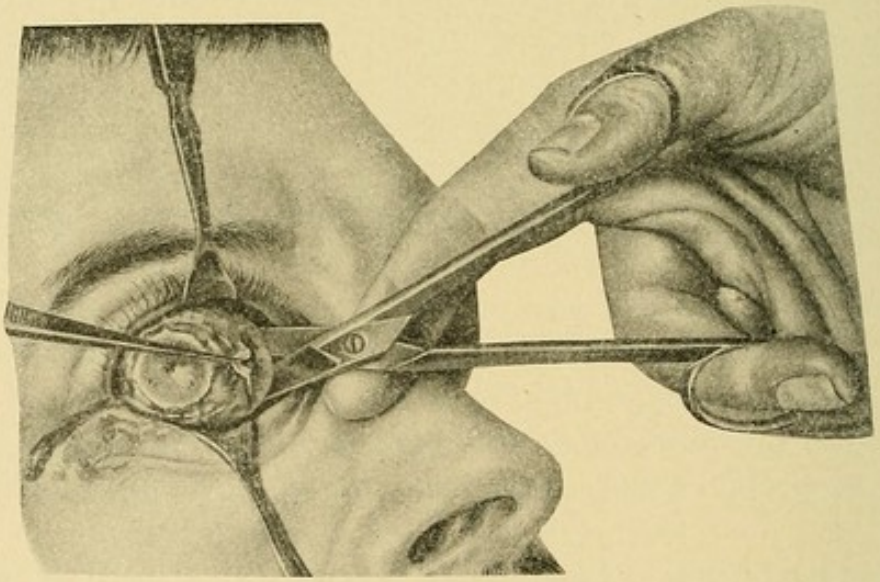

Fig. 109.
Enucleation.

retracts, then seizing the tendons of the recti muscles, dividing by the scissors all except the internus with one cut for each, the externus being cut about 5 mm. away from the globe; then the stump of the tendon of

the internus is seized by the forceps, the eyeball rotated outwards, the closed scissors' points inserted behind the globe until the optic nerve is felt, then slightly withdrawn and opened, the nerve engaged between the open blades and then cut, any adhesions being cut as the globe is extruded and held by the fingers. The bleeding is stopped by adrenalin pledget or piece of ice, the cavity of the orbit packed with iodoform gauze, dressed on the third day and daily thereafter for about ten days to two weeks, when an artificial eye may be fitted, but on account of granulation formation and subsequent shrinkage the prothesis had best be deferred for about two months.

This operation is crude and does not give motility to the stump. Its only advantage is where a very quick operation must be made on account of the general condition of the patient, as it may be done within three minutes.

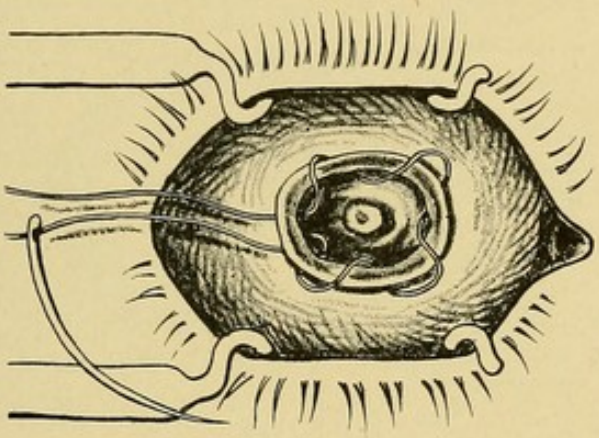

Fig. 110.

Author's simple purse-string suture through conjunctiva, Tenon's capsule, for enucleation.

The French method of enucleation requires one additional instrument, the strabismus hook, and the heavy straight forceps may be substituted by the more delicate conjunctival forceps. The operation is similar, except that the quadruple tenotomy is accomplished with the guidance of the tenotomy hook and the tendons more neatly cut from the globe. The optic nerve is usually cut longer and seized to rotate the ball.

An additional heavier pair of enucleation scissors may be used, the optic nerve may be sought for and held by the von Beer enucleation instrument, which protects the globe when the nerve is cut and by which the bulb is delivered unruptured.

Landolt designed two scissors, curved both on the flat and the edge, one to the right and one to the left, which can be readily intro-

duced under the tendons and aid in the neat formation of the conjunctival cuff. He separates the externus first and then the inferior oblique, dividing the optic nerve from the temporal side.

Monosmith has devised a curved enucleation knife for the same purpose.

In all these operations the cavity is left to granulate up. A much finer procedure anatomically is that practised in America, and I believe first described by me (Snellen,[10] however, gives credit for the "tobacco pouch" suture to Bowman), that of suturing the cut conjunctiva and Tenon's capsule, either by a simple pouch catgut suture run over and in the cavity through the conjunctiva and Tenon's capsule, thereby coapting the cut edges, or a slightly more complicated one which includes the tendons. Suker, Todd, and others pick up the

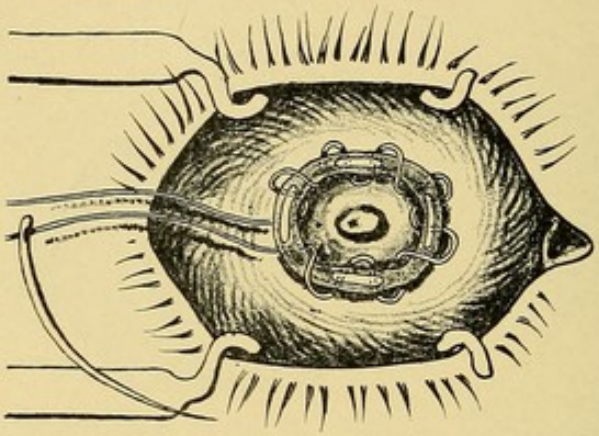

Fig. 111.

Author's purse-string suture through conjunctiva, Tenon's capsule and tendons for enucleation.

tendons before cutting them, each with a separate silk thread, and afterwards use the pouch suture.

These operations allow of union by first intention, one or two after-dressings only being needed, and prothesis within a week, although the artificial eye had best be fitted about one month after the operation.

It is not necessary to put any drainage between the lids, an occlusive roller bandage being applied to be removed for the first dressing on the third day.

Complications.

Hemorrhage.

In arterio-sclerotic individuals the bleeding may be free; a pledget of gauze soaked in adrenalin may be laid into the wound and with compression by the finger stops the bleeding within a few minutes, when the

suture may be applied. Snellen[10] passes a threaded curved needle deeply into the tissues several times and ties the threads tightly. Ice was previously used, but one cannot be sure that ice is free from germs. The tendency to healing after enucleation is great, no sepsis usually resulting, and healing even without a tobacco-pouch, or other suturing, being complete in a week.

There is usually suggulation of the lids with quite a black eye for a couple of weeks after enucleation, and in a few cases a hematoma has formed. One case in particular I remember where after enucleation a blood tumor as large as a hen's egg formed. Incision and leeching, hot applications, speedily reduced the swelling, and, with the exception of discoloration of the lids for nearly a month, the case otherwise progressed satisfactorily.

Collapse of the globe from rupture, or incising or puncturing it during the operation, is due to pressure and may be avoided by using the Beer instrument. This usually occurs as the optic nerve is divided, particularly in soft eyes, in the case of those which have lost part of their contents from injury, or in cyclitis. Large wounds may be closed by a suture or two, and cyclitic eyes may be injected with cocain or normal salt solution.

Failure of the globe to extrude after division of the optic nerve is due to adhesions which may be sought for by the tenotomy hook and divided by the scissors. In some cases a canthotomy may have to be secondarily made in order to get the globe out without bursting.

It is advisable for the surgeon to keep all enucleated eyes, not only for scientific purposes, but for forensic protection, as no matter how plainly indicated at the time of operation, through ill-advised friends, pettifogging practitioners of medicine or law, later question of the necessity for removal of an eye may arise. I had such an event occur, with a threatened suit, nearly eight years after such an operation.

To this purpose it is well to preserve the specimens in 1:20 formalin, or preferably the Kaiserling formula.* Globes which shrink may be filled and rounded by injection into the vitreous chamber of glycerine-gelatin. Macroscopic specimens in glycerine jelly, and microscopic slides, may be made and prove useful not only for the above named purpose, but are instructive and may be often called into use.

---

* ℞

Formalin	200
Potass. nit	15
Potass. acet	30
Aquae ad q. s.	1000

(D) EVISCERATION, OR EXENTERATION OF THE CONTENTS OF THE EYEBALL.

This removes the entire contents of the globe through a circular incision behind the cornea and the resultant stump has been claimed to be more mobile than after enucleation; but this is not so if the suture operations be made in the latter, while the course of healing is more

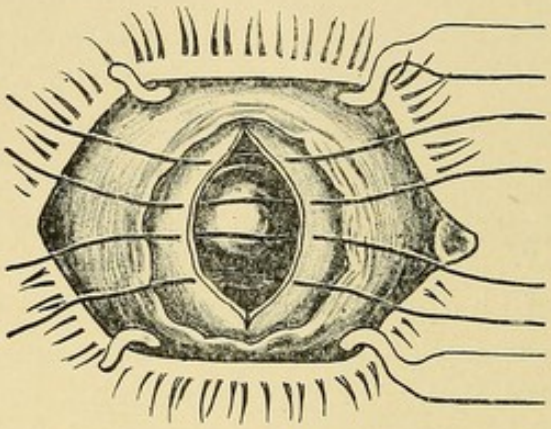

Fig. 112.
Mules' operation, sphere inserted, vertical sutures in place.

severe and protracted. Exenteration should, therefore, be restricted to cases of pan-ophthalmitis where enucleation is forbidden because of the danger of meningitis. It gives much better results than incision of the cornea and sclera. The patient is relieved at once, is healed after five

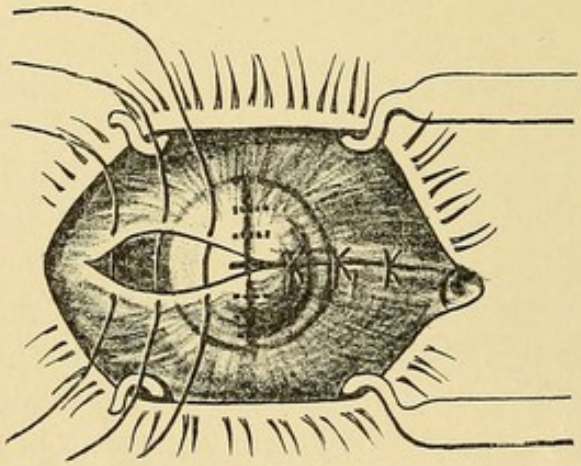

Fig. 113.
Fox implantation of artificial vitreous, vertical stitches of sclera, horizontal sutures of conjunctiva.

to eight days and the artificial eye is more movable and has less displacement backward than after enucleation.

The sclera is divided by a circular incision immediately behind the cornea, the operator seizing the ocular conjunctiva close to the corneal

margin to the right side with conjunctival forceps, the assistant grasping it 5 mm. farther back in the same meridian. Between the two forceps, close to the anterior forceps, the sclera is carefully incised until the ciliary body appears. With thin, straight scissors the incision is then enlarged, one blade being pushed between the ciliary body and the sclera. At each snip of the scissors the two forceps take a new hold when the incision ends. The upper half of the cornea is then cut away and then the lower half. By a scoop the entire contents of the globe are then removed, if possible, in toto. The cavity is then cleansed carefully by scissors, forceps and scoop, wiped out with gauze, washed by an antiseptic solution.

The opening is closed by three to five interrupted sutures, the round opening being made horizontal, or a tobacco-pouch suture may be used. The stitches include both the sclera and the conjunctiva. Bandaging of both eyes. The pain is usually severe and has to be relieved by morphin. Sutures are removed in five to seven days. In about ten days, if cellulitis does not develop, the case may be discharged. Intense headache and fever may occur—occasionally secondary enucleation may have to be made. The stump usually becomes quite small and as a rule the trouble, time and pain are not worth the price.

(E) MULES' OPERATION.

Spherical bodies of glass (Mules), celluloid (Lang), silver (Kuhnt), gold (Fox and Allport), sponge (Belt), sphere of paraffin (Ramsay), have been inserted into the cavity after exenteration, with the object of producing a large stump. Unfortunately my experience, and that of most others, has been that these balls are frequently extruded after a time. de Schweinitz[2] reported 17 extrusions in 317 operations. Fox puts the artificial vitreous into the socket, sews the sclera vertically, and the conjunctiva horizontally, over it by interrupted sutures. The introduction of the spoon into the cavity is facilitated by splitting the sclera vertically about 4 mm. up and down and the artificial vitreous inserted by the Mules instrument. The after treatment, symptoms, and results are much the same as after simple evisceration.

Frost, Lang, and Fox[11] also put in artificial vitreous after enucleation with more or less success, even after remote enucleation of the globe.

Fox[11] performed Mules' operation in 1893 and has been using the operation in all suitable cases since. He finds its cosmetic results exceed those of any other operation. He has performed the operation 385 times and has not had any sympathetic inflammation follow in any instance. In one case the operation was performed in the presence of sympathetic inflammation and the procedure was as effectual as enucleation. The de-

layed implantation is his own operation, and has proven most satisfactory as a substitute for Mules' operation, where enucleation had to be performed. His present method of performing this operation is to make the incision through the orbital tissues in the superior nasal angle. Through this opening a pocket is made in the tissues lying underneath the center of the orbit. Into this pocket a gold ball is inserted, which is from 12 to 14 mm. in diameter. The orbital opening is not sutured, but is pressed together by a conformer which also serves to hold the gold ball in position in the center of the orbit.

(F) TRANSPLANTATION OF ANIMAL'S EYES.

This was first devised by Chibret,[12] who first tried putting a real eye (that of a pig) into Tenon's capsule; then came Rohmer's[13] experiments with rabbit's eyes, beginning by implanting them in the peritoneal cavities of animals; then of Lagrange's more successful ones with the same animal.

Nicolai,[14] directly after extirpation bulbi, inserted a freshly removed rabbit's eye (Lagrange's method). A small conjunctival border is left to the eye; this is sewed to the conjunctiva of the patient, otherwise the rabbit's eye would be too movable. The conjunctiva is closed by a purse-string suture, done to prevent sinking of the upper lid. With closed eyes the patient does not show an anomaly. The transplanted eye shrinks a little in time; there is no danger of infection.

Lagrange,[15] after performing an enucleation, implants the eye of a rabbit into the empty Tenon's capsule. The rabbit's eye must be from a young animal and should not be larger than the enucleated eye. The rabbit's eye is placed into Tenon's capsule with the cornea turned downward and then the several muscles of the patient's eye are sutured to the posterior pole of the rabbit's eye. Rolling up of the muscles can be prevented by flattening them out. This method of implantation should not be used after enucleation on account of irido-cyclitis and panophthalmitis, where the capsule of Tenon is implicated in the process. The implanted eye shrinks in the course of time, but there usually remains enough of a stump for the artificial eye to facilitate its mobility. Out of 11 cases observed, 8 showed a very good result. The longest time of observation was four years.

Wicherkiewicz[16] is not convinced that such cases are free from the danger of sympathetic ophthalmia. He first thought that this rather laborious operation could be recommended for the following cases: 1st. Where appearance is of prime importance. 2d. Where enucleation is urgent and one must, at any cost, obtain authority to operate. 3d. Where one cannot expect an artificial eye to be worn at an early date,

as, for example, in a young child. After having completed his articles, as here abstracted, he had the good judgment and fairness to wait another year in order to better appreciate the ulterior results, ere putting into print. He then adds that while he has nothing further to say relative to operative methods, etc., yet, to be conscientious towards the science he represents he can only publish that which is in accord with his most profound convictions. Hence, he is constrained to avow that his enthusiasm for the operation has calmed since a more extended observation of the cases in question. He finds that it is only in children that one can expect the transplanted eye to permanently retain sufficient volume to fulfill the indications. In consequence of experience, he confines the measure to children, and to those adults who will not part with any sort of an eye unless they are promised that another will be substituted for it, and a better one than that which is given up.

The details of the operation as practised by Wicherkiewicz are: Circumcision of the cornea, pulling up each rectus tendon with sharp hook, catgut suture through capsule and each tendon, severing the tendons from the globe, division of the obliques and the opticus, irrigation of the cavity with cold sterilized salt solution. Next a freshly enucleated rabbit's eye is placed in the cavity, cornea backward, muscle sutures tied, conjunctiva closed by silk purse-string suture. Binocular bandage for three days, when first dressing. Fifth day removal of suture.

In all cases the implanted eye lost volume up to one-third or one-half of its original size, the atrophy being greatest in the older subjects, in whom it apparently disappeared completely. It was not thought prudent to fit the prothesis till all traces of irritation had passed. This in the cases operated under chloroform, was generally after at least one month, and in those made under local, or infiltration anesthesia, still later.

(G) OPTICO-CILIARY NEURECTOMY.

This operation is now seldom done except for painful absolute glaucoma. I have only done it once for an injury case, and then several years afterwards had to enucleate the same eye on account of sympathetic irritation.

This was suggested by Schweigger[17] to take the place of simple division of the optic nerve which had been used before. Incision is made into the conjunctiva and Tenon's capsule 3 mm. behind the insertion of the internus. Two strabismus hooks are introduced, drawn in opposite directions, one rotates the eye outward, the other draws the muscles up out of the orbit. Under the second hook a needle threaded with catgut is passed through muscle and conjunctiva, reinserted close to point of exit, brought back again through conjunctiva and muscle. The

muscle is then divided 5 mm. beyond its insertion and the suture is tied. A second similar suture is introduced through the tendon and conjunctiva and tied at the anterior extremity of the muscle. The wound is then enlarged in the direction of the superior and inferior recti, a small, sharp double hook is inserted into the sclera as far back as possi-

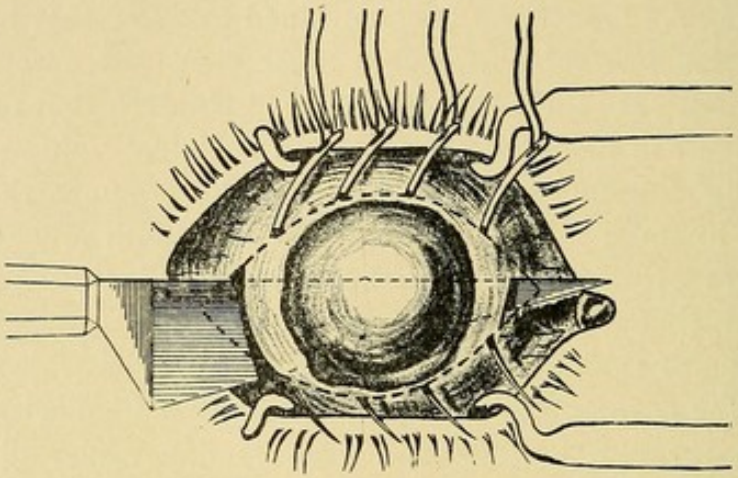

Fig. 114.
Critchett's abscission of staphyloma.

ble, and the eye drawn forward and outward. Flat scissors are introduced into the wound and the optic nerve divided as far back as possible. The globe is rotated by the double hook and a section of the nerve excised. The tendon stump is cut off, the globe replaced and the wound closed by the sutures already in place. The lids are sewed together. The

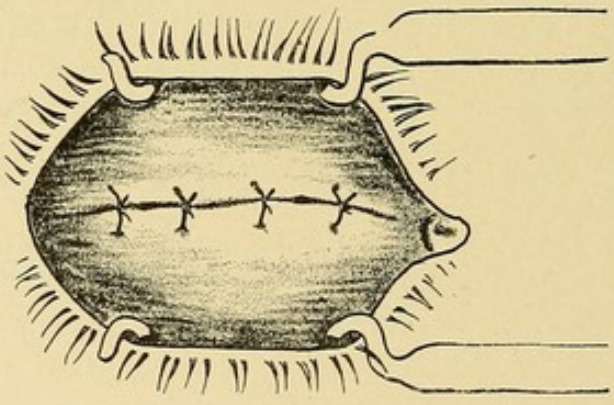

Fig. 115.
Critchett's abscission of staphyloma; result.

bleeding and exophthalmos are controlled by this procedure and by a fine compress bandage. In four days the sutures are removed. De Wecker[18] confines the operation to single resection of the nerve.

H. Of the substitutes for enucleation where the patient is under twelve years of age and the conditions warrant keratoectomy

or abscission may be made. It is inadvisable to enucleate a child's eye, if from the nature of the case no fear of sympathetic ophthalmia exists, as the orbit will not grow proportionately with the other when the eye is removed, and facial asymmetry is thus produced.

I prefer the operation of Critchet.[19] The patient being under a general anesthetic, retractors being inserted, five needles are passsed through the mass behind the apparent limbus anterior to the ciliary body, about equidistant from each other, and left in this position with both head and point projecting. A Beer's knife is then passed through the mass cutting downwards and through, the scissors and forceps are then used to cut away the upper flap, the lens is permitted to escape or is aided by forceps or a hook, the needles carefully passed through one at a time and tied, it being usually necessary to clip off the projecting corners at the ends of the wound to round them. The sutures should be left in ten days

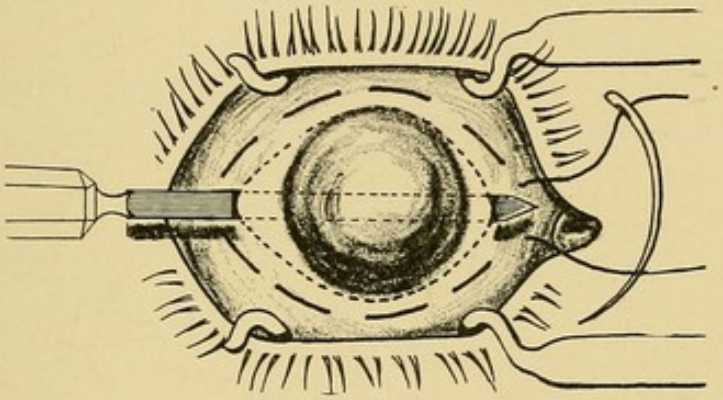

Fig. 116.

H. Knapp's abscission of cornea.

to two weeks, and then cut. After all irritation has passed away, in a couple of months, a movable globe is seen with a flattened anterior surface, traversed by a white line or cicatrix. Upon this an artificial eye can be adapted, which moves to a greater extent than can be obtained by any other operation.

Wicherkiewicz[16] obtained an excellent result in a case of leucomatous staphyloma of the cornea in a child, aged nine months, by the following operation: The staphyloma was punctured with Bowman's needle and the aqueous emptied in a stream. The staphyloma, collapsed in folds, was grasped with a forceps, and an oval piece, almost of the width of the cornea and 4 to 6 mm. high, was cut off with scissors. The wound edges were accurately adapted and healed without sutures. Tension became normal and three months later the eye had the same size as its fellow. This I have likewise done twice with happy results.

LITERATURE.

1. Ambroise Paré *OEuvres,* Paris, 1579.
2. de Schweinitz, *XIII, Internat. Cong., Med. Sec., Ophth.,* Paris, 1900.
3. Stuelp, *Klin. Monatsbl. f. Aug.,* XLVII, 11, July, 1909, p. 74.
4. Bruns and Robin, *Ann. Ophth.,* Oct., 1906.
5. Terrien, *Arch, d'opht.,* Feb., 1906.
6. Siegrist, *Klin. Monatsbl. f. Aug.,* XIV, 1907.
7. Weiss, *Ophth. Klin.,* June 20, 1898.
8. Haab, *Operative Ophthalmology,* Amer. Ed., 1905, p.
9. Würdemann, *Ophth. Record,* Nov., 1893.
10. H. Snellen, *Graefe-Saemisch,* Nos. 48-49, 1902, p. 117.
11. Webster Fox, *Ophthalmoscope, Jan.,* 1909, and text-book, *Diseases of Eye,* 1910.
12. Chibret, ref. LaGrange and Wicherkiewicz.
13. Rohmer, ref. LaGrange.
14. Nicolai, *25th Meeting Ophth. Soc., Netherlands,* May 25th, 1904; March, 1909; (b) *L'ophtal. Provinciale,* March, 1909; (c) *Klin. Mon. f. Aug.,* 1906, XLIV, 11, p. 32.
15. LaGrange, *Wien. Med. Woch.,* Apr. 2, 1906.
16. Wicherkiewicz, *L'ophtal. Provinciale.*
17. Schweigger, ref. de Schweinitz.
18. DeWecker, ref. de Schweinitz.
19. Crichett, *Roy. Lond. Ophth. Hosp. Rep.,* IV. 1.

CHAPTER XV.

THE PROTHESIS—ARTIFICIAL EYES.

Uses—Statistics of one-eyed individuals—History—Kinds of eyes—Interims prothesis—Manufacture—Socket—Relative movement of eye after abscission exenteration and enucleation—Sinking in of upper lid—Correction—Care of the prothesis—Method of insertion and removal—Care of the eye—Inconveniences—Dangers—Ordering of the prothesis—Advantages of the Snellen full-backed reform eye—Literature.

"Il est plus qu'un instrument de luxe et de coquetrie." (Coulomb[1]).

Artificial eyes are used primarily for cosmetic purposes. Esthetics make them indispensable in civilized society. Prothesis is of economic importance, for a one-eyed man labors under disadvantage in contact with other people in business. From a psychical point of view it has an effect upon the wearer in the knowledge he is thereby made less conspicuous.

From the medical standpoint it protects the eye socket from external agents, fills out the cavity, prevents entropion, permits of re-establishment of the lid movements and the direction of the tears and secretions, thus preventing accumulation of fluid in the cavity and production of conjunctivitis. Finally in the case of infants who have lost an eye it assures the symmetrical development of the face.

The prothesis is a professional secret which should be guarded as is any other, although the deception is sooner or later generally known. Many eminent men have been one-eyed and worn a prothesis. Lycurgus, the legislator of Sparta and the author of the Louisades; Antigone was surnamed "the cyclops"; Alexander the Great, according to the portrait of Appele, were monophthalmic. Metternich and Gambella wore protheses.

The proportion of one-eyed individuals, according to the statistics of Boissoneau[2] is as follows:

	Individuals.
England	1 to 162
Austria	1 to 109
Belgium	1 to 144
Denmark	1 to 158
Egypt	1 to 50
France	1 to 160
Russia	1 to 207
Sweden and Norway	1 to 200
Switzerland	1 to 149
United States of America	1 to 145

Fig. 117.
The advantages of prothesis in children. Before. (Coulomb.)

Fig. 118.
The advantages of prothesis in children. After. (Coulomb.)

History. The ancient Egyptian and Grecian documents show that artificial eyes of non-enameled silver were inserted into the sockets of mummies, and such are found in these subjects. The Grecian and Roman sculptors placed artificial eyes in some of their statues; and the

East Indians, Japanese and Chinese also do so in some cases, the eyes being made of precious stones. The Egyptian priests, who practised medicine centuries before the Christian era, made substitutes for eyes. Taking a piece of flesh-colored cloth the size of the empty socket, they attached it to a piece of clay of the size of the human eye. This was painted, and the whole securely fixed over the socket.

Prothesis is mentioned in the Talmud and the mediæval epics. It was not until the sixteenth century that artificial eyes were made to fit into the socket. Previous to that a thin metal band covered with leather was used, the eye being painted on one end, the other end gripping the

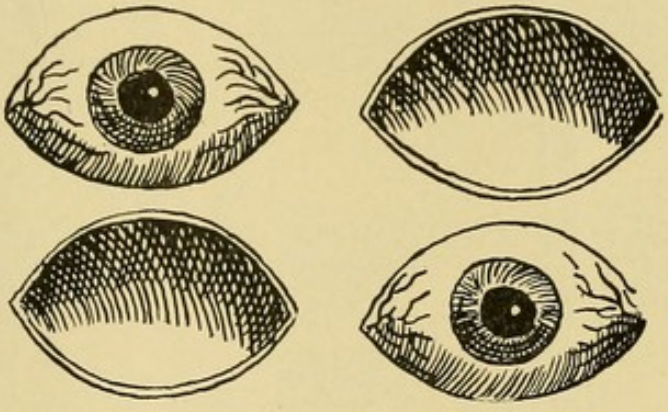

Fig. 119.
Artificial eyes designed and depicted in the work of Ambrose Paré, Paris, 1579. (Anterior and posterior aspect.)

back of the head. In 1561 eyeballs were first made of gold and the iris done in enamel.

Ambroise Paré, 1614, figures these in his book,[3] a most peculiar external prothesis, the "ecblepharon." From the XVII century to the XVIII artificial eyes were made of glass. Porcelain eyes were first made about the beginning of the XIX century.

Even in Shakespeare's day glass eyes were very well made; but, compared with modern specimens, they were crude and easily distinguished.

The Snellen full back or reform eye was devised by J. L. Borsch in 1894,[4] and independently introduced by Snellen[5] a decade ago, having practically displaced the shell eye and rendered most of the substitutes for enucleation unnecessary. Vulcanite and celluloid eyes have been made and possess the advantage of being easily molded or trimmed to fit the individual case, but they are not in general use as they become unsightly through discoloration.

Gallemaerts[6] in 1906 described the Mueller interimprothese,

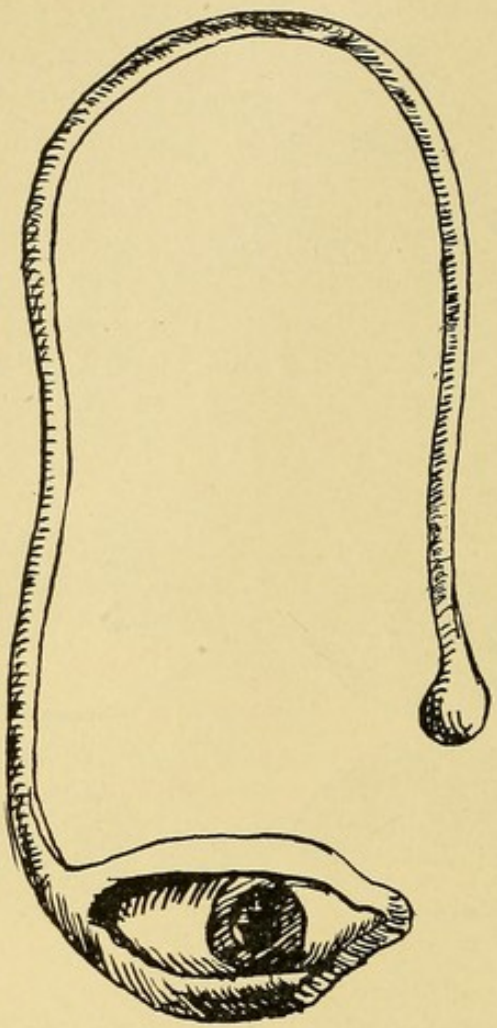

Fig. 120.
The "ecblepharon" of Paré.

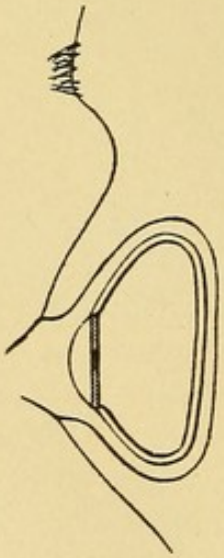

Fig. 121.
The original reform eye.

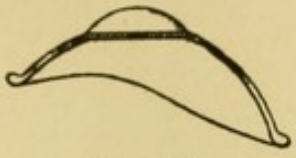

Fig. 122.
The shell eye.

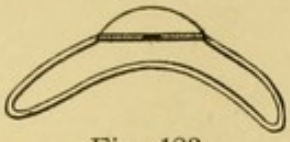

Fig. 123.
The reform eye.

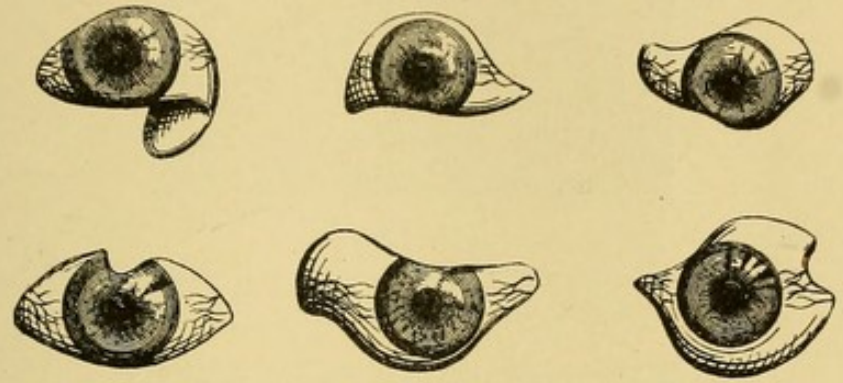

Fig. 124.
Bizarre forms of eye shells. (Coulomb.)

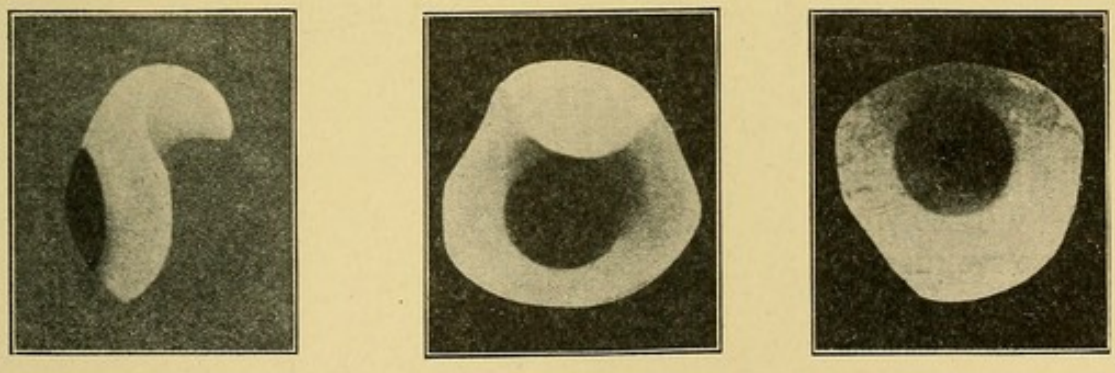

Fig. 125.
Artificial eyes made to give support commissure of upper lid. (Coulomb.)

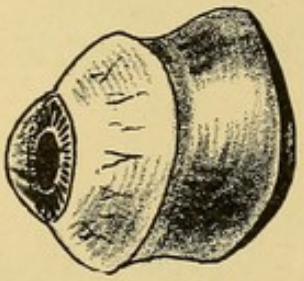

Fig. 126.
Prothesis made by author to fill socket after exenteration of orbit. Eye shell with gold base filled with plaster.

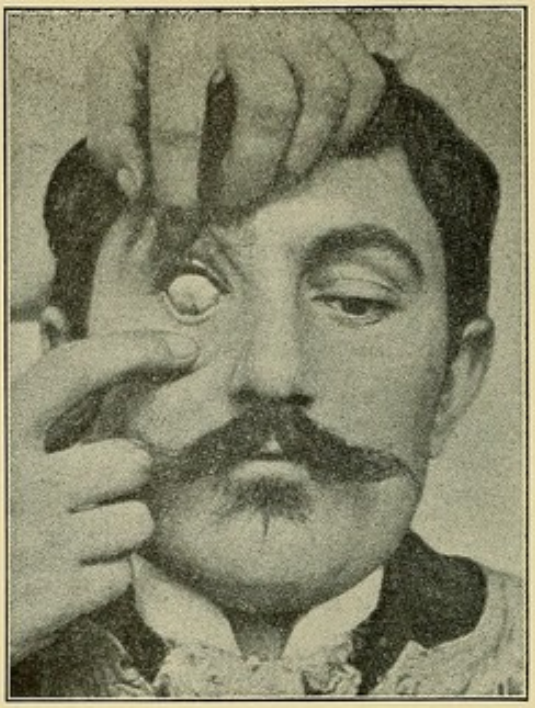

Fig. 127.
Prothesis for staphyloma—keratectomy—showing full rotations of artificial eye. 1. The stump after keratectomy. (Coulomb.)



Fig. 128.
Eye fitted looking forwards.

which consists of a hollow glass body of the form of the conjunctival sac, having in the middle a sagittal canal which gives free drainage to secretions. This is placed in the conjunctival sac very soon after enucleation; there is no retention of secretion. He puts it in the first or



Fig. 129.
Looking up.



Fig. 130.
Looking to right.

second day after operation, some put it in directly after operation, and connect it with the conjunctiva with a few threads. It prevents loss of elasticity of the eyelids, is not disagreeable, and the patient can sooner appear publicly.

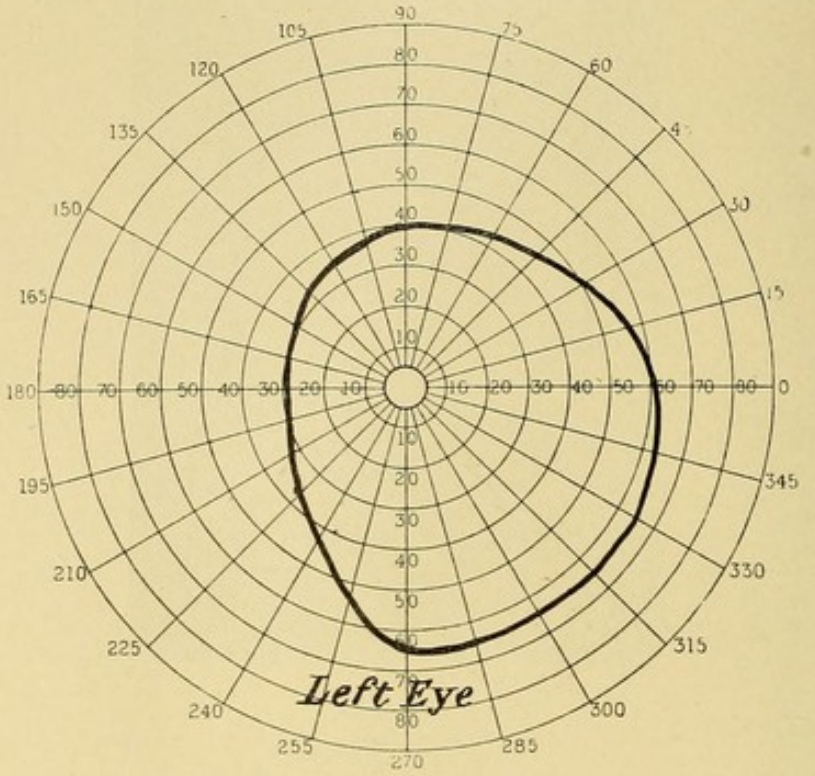

Fig. 131.
Movements of the artificial eye after keratomy.

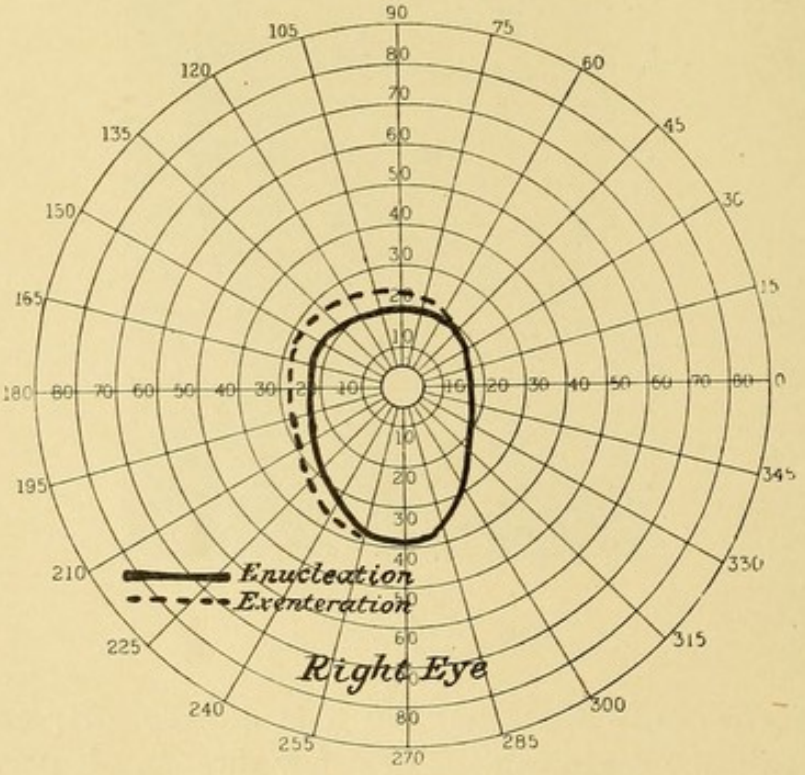

Fig. 132.
Movements of the artificial eye after enucleation and exenteration.

Fenton[7] describes a man of 69 years who had one eye removed in 1892. He was found to be wearing a prothesis made of the half of a prune pit, shaved smooth by a pocket knife on the edges. The cornea was represented by a pearl button being set in the front of the prune pit.

Manufacture.

The porcelain or enamel prothesis is an opaque lead glass, the cornea being made of calcium glass, the iris of lead glass colored by hand with different metallic oxides. It is made in two parts over a lamp, the sclerotic part being molded, the iris then inserted and then the clear glass cornea. The iris is colored by hand, every artificial eye being different, the sclerotic of various cream to white tints and a similitude of

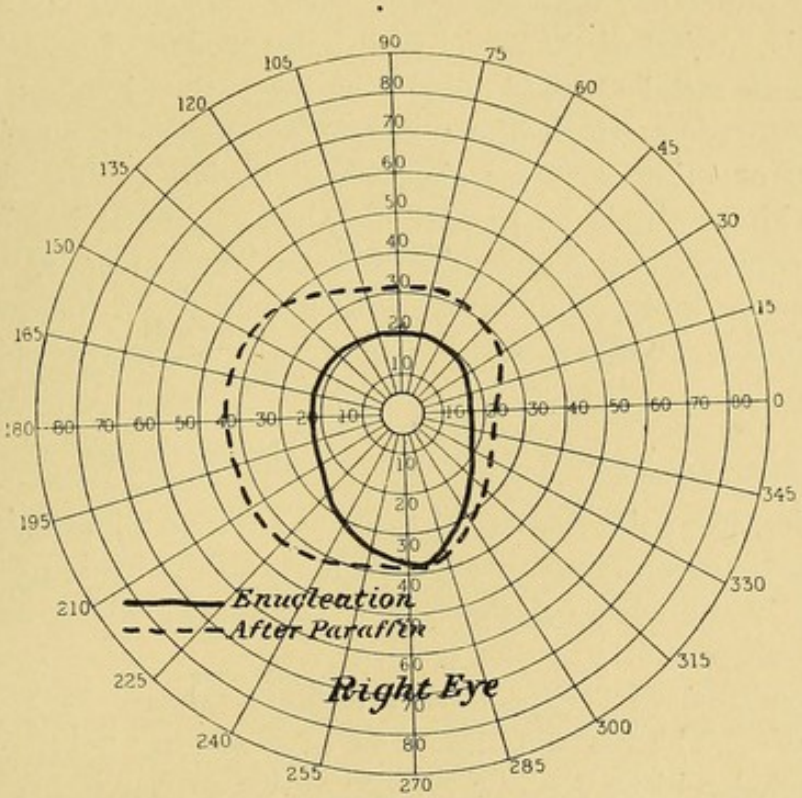

Fig. 133.

Movements of the artificial eye after enucleation and after secondary paraffin injection into the stump.

blood-vessels usually painted thereon. The pupil is made to suit the average degree of daylight. Fastidious persons may carry two eyes, one with a small pupil for the day time and another with a larger for the evening. The pupil is imitated by a black bead of glass. Many shapes are made—typical ones to order. Prosthetic pieces may also be made to mask the deformity of a coloboma of the lid, but this is better remedied by a plastic operation. Even where exenteration of the orbit has been made a prothesis in some cases may be worn.

The Socket.

The orbital cavity should be entirely free, with no symblepharon, and the lids should have been preserved in order to install an artificial eye. If not, plastic operations are necessary and in favorable cases produce the desired results.

The kind of operation, i. e., the resultant stump, has much to do with the well-fitting of a prothesis. While it is not well to put a glass eye over a phthisical or atrophic globe, which should as a rule be enucleated, such a foundation for a prothesis gives the best results, and surgeons have endeavored to simulate this condition by other operations than enucleation.

Partial amputations or abscissions of the anterior portion of the globe, as in the staphyloma operation, gives the largest and most mobile stump. Evisceration of the globe with implantation of an artificial vitreous of glass or metal (Mules' operation) next; then implantation of artificial vitreous after enucleation; simple evisceration; enucleation with purse-string or other sutures; simple enucleation lastly. All of these, however, with prothesis by the ordinary shell eye. It has been my experience, however, that enucleation followed by suture of the tendons, Tenon's capsule and conjunctiva, with a full-backed hollow or reform prothesis gives as good a socket and motility as any of the substitutes for enucleation.

Sinking in of the upper lid.

In falling in of the furrow of the upper lid, so apparent after simple enucleation, from contraction of the stumps and absorption of orbital fat, this is largely remedied by the Snellen prothesis, which may be made in a special shape.

The condition can be eventually entirely relieved by a careful paraffin prothesis. The paraffin should be of a melting point of 120 Fahr. and be injected cold by a screw syringe under antiseptic precautions. It is claimed by the advocates of the artificial vitreous that this sinking in does not happen, but from the cases that I have operated and the many that I have seen, I think the furrow is not any the less than in the enucleation with a suture.

Where the contents of the orbit are completely or partially exenterated, or where there is great destruction of tissue from the accident, of course greater deformity is to be combatted, but specially made artificial eyes may remedy the defect.

The care of the prothesis.

Artificial eyes should be handled carefully on account of their delicacy, and in order that infection be not carried by them to the socket.

Several cases of such infection have been reported, one in my own experience.[8]

A one-eyed man acquired gonorrhea, infected his shell eye by handling it, and from this the socket was infected by a gonorrheal ophthalmia, which pursued a course of several weeks. Luckily for him the sound eye did not become infected, being protected, while under treatment, by the Buller shield. A gonorrheal rheumatism developed during the course of the eye disease.

Morton[9] reported a similar case.

A defective or misfitted prothesis, or one that has lost its polish, will

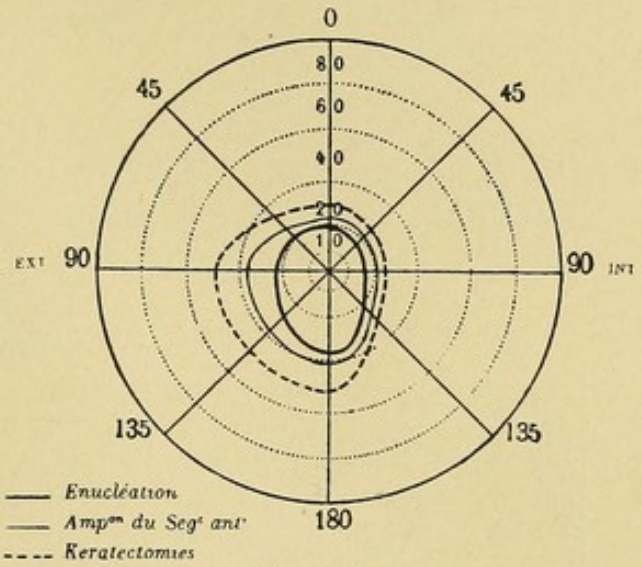

Fig. 134.

Movement of the eye after enucleation, amputation of the anterior segment, and after keratectomy. (Coulomb.)

give rise to irritation of the mucosa, conjunctivitis, excessive secretion and the formation of granulation tissue.

The interval of time that should elapse before an artificial eye may be worn depends upon the form of the operation, the disease of the eye which necessitated its removal, and upon the quickness of healing. As a rule the best results are secured in about one month after enucleation, a second eye to be fitted about three months later, for the cavity of the socket is usually smaller at first and the tissues are tender. The orbital fat absorbs to some extent so that a larger eye can be borne several months after the operation.

To insert the eye.

The upper lid is readily and easily elevated by the finger, putting traction on the skin below the brow and the edge of the shell

introduced under the upper lid and almost in contact with it. The lower lid is now retracted and everted to permit the lower edge of the shell to

Fig. 135. Normal fit.

Fig. 136. Defective fit. The edges of the shell rest on the stump.

Fig. 137. Defective fit. Depression of the stump by the prothesis.

Fig. 138. Defective fit. The artificial eye is too large and consequently non-mobile.

Diagrams showing proper and defective fitting of a prothesis. (Coulomb.)

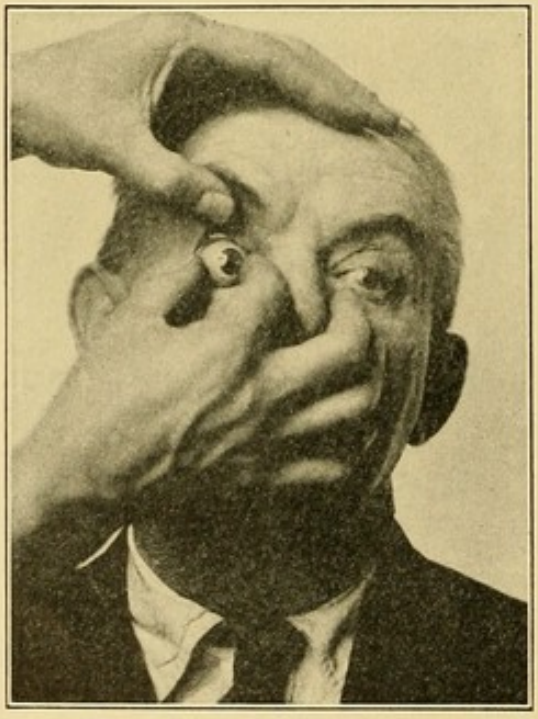

Fig. 139.
Prothesis; insertion of an artificial eye. First step.

pass into the lower cul-de-sac. By gradual pushing upwards and sideways, the eye is placed under the upper lid, and the lower then pushed over it.

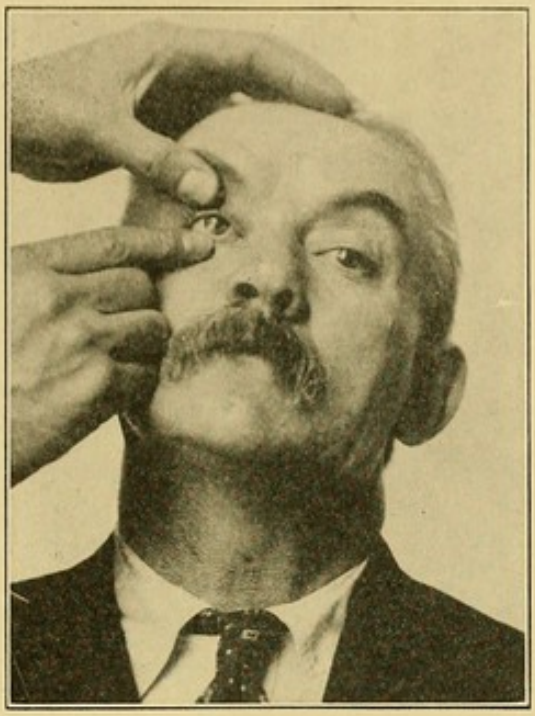

Fig. 140.
Prothesis; insertion of an artificial eye. Second step.

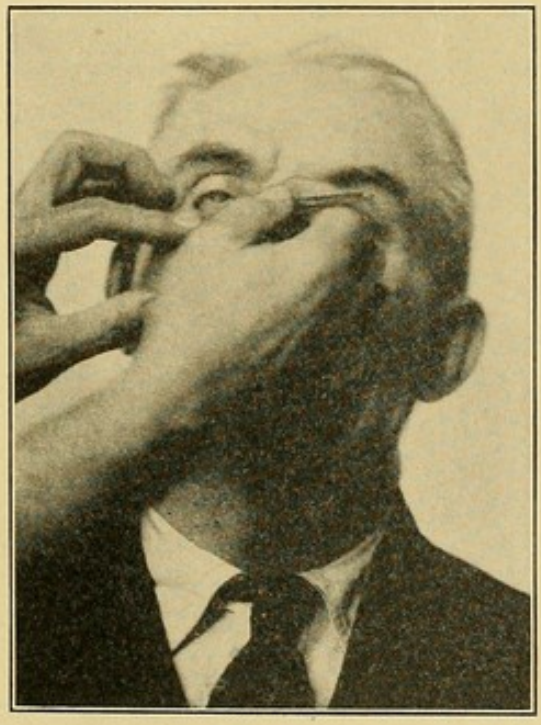

Fig. 141.
Removal of an artificial eye. First step.

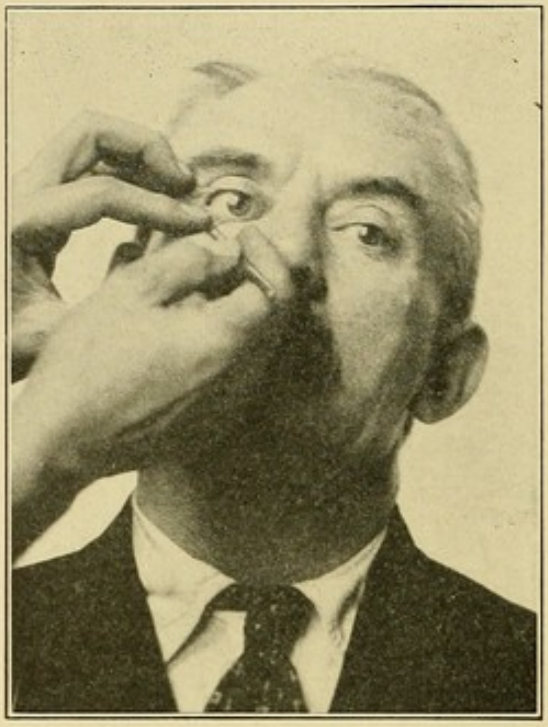

Fig. 142.
Removal of an artificial eye. Second step.

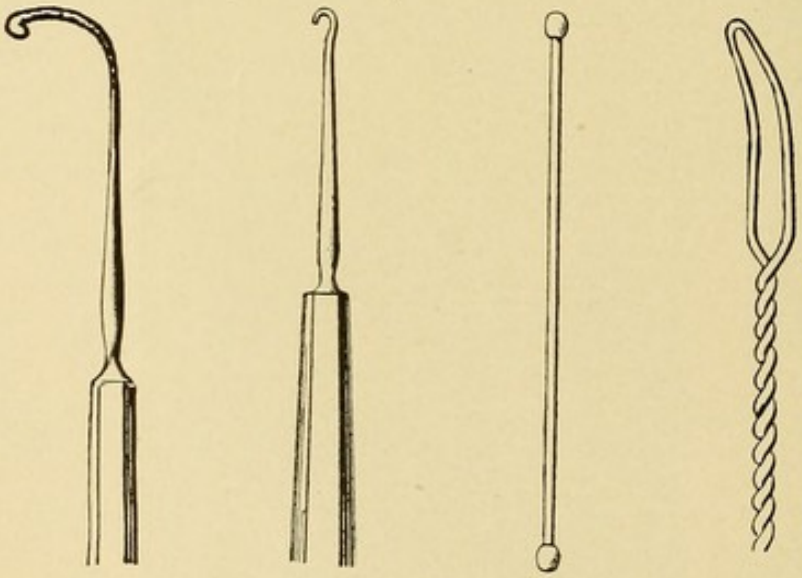

Fig. 143.
Instruments used for extraction of artificial eye.

To remove the eye.

The head of a large pin or some particular form of a special instrument may be used by the patient, some even learning to remove it with the finger. This is inserted under the lower margin while the lower

lid is everted. Thus the prothesis is gently pried out, the lower edge passing over the lower lid, falling into the extended hand, the head being held slightly forwards. After short experience, all patients, even children, learn to easily insert and remove the eye. It should not be worn at night. It is inserted in the morning, removed at night, cleaned with soap and water, dried and polished with a clean cloth, put in a safe place, preferable in a little box in a bureau drawer. As a rule an artificial eye will retain its polish and smoothness for a couple of years, but in cases where conjunctivitis persists it may get rough and dull-looking in a few months. Such eyes may be re-polished or a new one obtained.

Inconvenience of the prothesis.

The artificial eye, being a foreign body, at first causes some irritation of the tissues, but soon toleration is established, so with care and cleanliness a prothesis can usually be worn comfortably.

If the shell be too large or ill-fitted some obstruction of the canaliculi may result, with consequent epiphora. Chronic conjunctivitis may occur.

Should inflammation or irritation of the mucous membrane arise at any time, the wearing of the shell should be stopped for a few days and the usual remedies for conjunctival irritation ordered, of which boric acid solution for bathing the eye, and one-half per cent. sulphate of zinc, are usually indicated.

Should proliferation of tissue occur, producing granulation and polyp formation, these are to be treated by cautery and excision. Ectropion occurs from these causes, and entropion from cicatricial contraction with formation of symblepharon, bands of tissue or diminution of the size of the eye socket. Properly-fitting eyes and care obviate all these troubles, and an ill-fitting or worn prothesis should be exchanged for a new and better one. Several cases of spontaneous bursting of a double-walled artificial eye have been recorded, and in a number of instances doubtless the shell eyes have been broken in situ.

I have had two patients so report and display fragments, the one of a double-walled eye and the other of a shell eye, which they claimed had broken while being worn.

Beal[10] reports a case in which a "reform" artificial eye (one with double-walls enclosing a cavity) burst with quite a loud report without evident cause, and quotes a similar case recorded by Milliken.[11] His explanation of the accident is that the high degree of heat used in the manufacture of the eye produced a vacuum in its cavity and that a crack in the very thin posterior wall, probably the result of a strong contraction of the orbicularis, admitted the external air and caused the explosion. For the prevention of the accident he proposes making a small hole in the posterior wall to equalize the pressure.

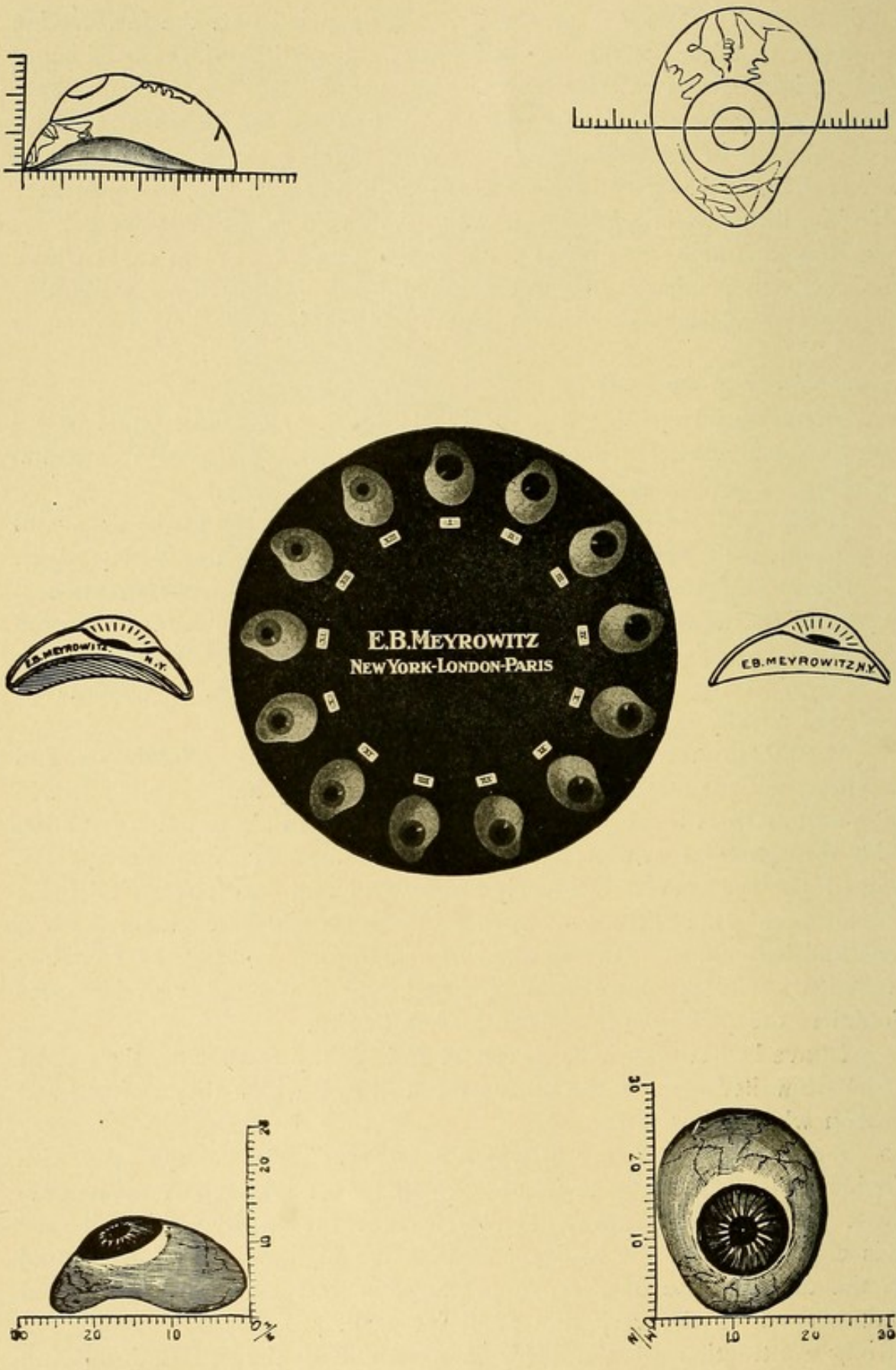

Fig. 144.
Diagrams for ordering of the prothesis.

H e r m[12] reports a case of death from general sepsis following the employment of the Mueller interimsprothese. The right eye had been enucleated for sarcoma of the ciliary body. On the tenth day a purulent inflammation of the left ankle-joint, associated with a bronchitis, developed. The conjunctival sac was well healed, but there was a free discharge. The patient died on the seventeenth day. Post-mortem showed the wound area covered by a thick yellow secretion, but the orbital tissues were free from pus. There was atrophic pancreatitis, steatosis renum, emphysema pulmonum, polyposis ventriculi, carcinoma secundarium glandularium, lymphaticarium regionalium. Bacteriologic examamination of the conjunctival secretion and of the exudate into the joint showed large quantities of streptococci. The author thinks that from these findings there can be but little doubt that the synovitis was due to metastasis from the eye.

U l b r i c h[13] reports the same case.

The ankle-joint became red ten days afterwards, temperature increased, diarrhea and symptoms of general sepsis developed, the patient dying seventeen days after the operation. The conjunctival section and the pus in the ankle-joint contained almost pure culture of the same streptococcus.

G i f f o r d, in reviewing this case, remarks that it is a wonder that any oculist should attempt such a device, since with a normal conjunctiva the difficulty in obtaining a satisfactory prothesis does not come from want of room for the glass eye, but from the sinking back of the orbital tissue which could only be induced by the prothesis.

Ordering of the prothesis.

The following instructions will assure an assortment from which a satisfactory prothesis may usually be selected. In ordering eyes state:

First. Whether for patient's right or left eye.

Second. Color of iris.

Third. Diameter of iris.

Fourth. Pupil large or small.

Fifth. Should the white of eye be blue, white, or yellowish.

Sixth. Measurement in millimeters for width.

Seventh. Measurement in millimeters for length.

Eighth. Measurement in millimeters for height.

In cases where the cavity is of a pecular shape an impression may be made with paraffin wax, paraffin three parts, vaseline one part; or dental wax, which may be molded while warm in the socket; or a leaden pattern may be made and sent to the manufactory. In other cases the patient may himself go where the workman models an eye to fit his order.

The advantages of the Snellen reform eye are as follows:

First. That their use causes much less secretion than the shell type, and thus prevents the accumulation of substance in the cavity, which causes irritation to the conjunctiva and annoyance to the wearer, all substances finding their natural way of discharge.

Second. The reform eye is designed and made so as to lie flat upon the stump.

Third. By the construction of the reform eye, all the sharp edges are dispensed with, a feature that will appeal to all experienced with the trouble caused by rough edges on artificial eyes.

Fourth. The reform eye, being made in the full shape, with closed back, gives a much more natural movement, and thus prevents the wearer from becoming tired of its use; and can also be worn longer without removing.

Fifth. The reform eye is more durable, not only from causes of accidental breakage, but from sudden changes of temperature, to which the ordinary eye is very sensitive. The construction of the eye with an inside chamber of air is responsible for this feature.

LITERATURE.

1. Coulomb, *L'Oeil Artificiale,* Paris, 1908.
2. Boissoneau, ref. Coulomb.
3. Ambroise Paré, *Oeuvres, Paris,* 1579, VII, C, XX, p. 837.
4. Borsch, *Ophth. Record,* May, 1901, Aug., 1899.
5. Snellen, *Internat. Ophth. Cong.,* Holland Ophth. Soc., 1898.
6. Gallemaerts, *Tydschr. v. Gen.,* Oct. 13, 1906.
7. Fenton, R. A., *Ophth. Record,* March, 1909.
8. Würdemann, *Ophth. Record,* Sept., 1892.
9. Morton, *Ophth. Record,* July, 1892.
10. Beal, *Annal. d'oculist.,* Dec., 1907.
11. Milliken, ref. Beal.
12. Herm, *Ophth. Klinik,* Aug. 5, 1905.
13. Ulbrich, *Ophth. Klinik,* Aug. 5, 1905.

CHAPTER XVI.

OPERATIONS FOR RESTORATION OF THE CUL-DE-SAC, AFTER REMOVAL OF AN EYE.

Fat implantation—Cutaneous adipose graft—Thiersch graft—Paraffin injections—Semi-solid paraffin—Solid paraffin—Ectropion—Plastic operations—Keratoplasty—Autoplasty with and without pedicles—Thiersch and Wolff grafts—Various operations—Literature.

Fat implantation.

Velez[1] has presented 15 cases of implantation of fat, either in the cavity of the old enucleation, or after exenteration of the eyeball. Lopez[2] described 6 cases after enucleation and 12 after exenteration. In 4 cases the prosthetic result was very satisfactory after the cicatrization. The author has seen several cases where, even after six

Fig. 145.
Effect of paraffin injection (semi-solid) in small stump after enucleation, right side. Before operation the orbit and artificial eye were greatly sunken.

years, the socket was still full and nourished. He recommends the following precautions: First. Always to take the quantity of fat necessary for filling the cavity from the gluteal region (abdominal wall, Lauber[3]), taking care, when suturing, that the fatty ball be not too

much compressed. Second. To sew with silk; catgut is quickly absorbed. Third. To perform the operation with rigorous asepsis and not to implant too large a volume of fat, so as to avoid strangulation.

This procedure has recently been favorably reported upon by Marx[4] and Lauber,[3] who show that it yields a large stump for a time, although the fat is replaced by connective tissue and is thus not biologically transplanted.

Enucleation "a la Rugine," followed by emplacement of cutaneous-adipose graft of Rollet's,[5] is simply the ordinary one in the first steps of enucleation, viz., after incising the conjunctiva, stripping the muscles from the sclera is done, and the nerve cut in the ordinary way. After this a circular piece of integument, larger than the cornea, is excised from the shoulder and quickly placed in the cavity, and each of the four recti tendons sutured with catgut to the edge of the graft.

Paraffin.

Kuhnt[7] says after enucleation of eyes in shrunken conjunctival sacs (from inveterate trachoma, scars from combustion or cauterization, etc.), the wearing of a prothesis is often impossible. Kuhnt devised the following method to obtain a larger socket for the insertion of the artificial eye: During enucleation the tendons of the recti muscles are fixed by sutures to the conjunctiva. After stopping the hemorrhage a Thiersch graft from the inner surface of the upper arm or thigh is transferred to the wound and tucked as far as possible under the conjunctiva. It is held in position by a ball of wood, 18 to 20 mm. in diameter, or a hydrophile dressing, over which the palpebral fissure is closed by a suture, grasping 2 to 3 mm. of the upper and lower lid margins. This remains for three or four days. Healing takes place without reaction.

Paraffin injections.

Injection of melted paraffin into the stump after enucleation, according to the method of Gersuny-Eckstein,[8] has been followed in my hands by most beneficial cosmetic results, and is constantly pursued in cases where six months or more after enucleation there is sinking in of the upper lid from absorption of orbital fat. There have been cases of blindness reported from paraffin injection for correction of nasal deformities, but if the paraffin be of the melting point of 115° Fahr. or be used cold with a screw syringe through a comparatively thick canula, no damage will result. It will, however, occasionally be extruded, and in one instance a neoplasm formed composed of inflammatory tissue.

The technic is as follows: Local anesthesia, asepsis, slow injection by the Gersuny syringe of cold aseptic paraffin, repeated after about one month. Too much should not be injected at one sitting, and trial of

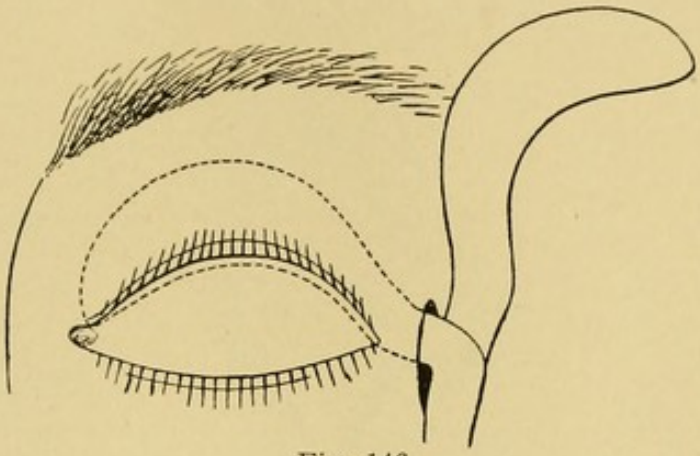

Fig. 146.
Flap with pedicle taken from temple to line upper part of orbit, passing through cutaneous buttonhole. (De Lapersonne.)

the artificial eye, which should always be the full back form, should be made immediately. Instillation of 50 per cent. argyrol, or 1:3000 sublimate ointment, and placing in of the artificial eye is all the dressing required. As a rule there is no reaction.

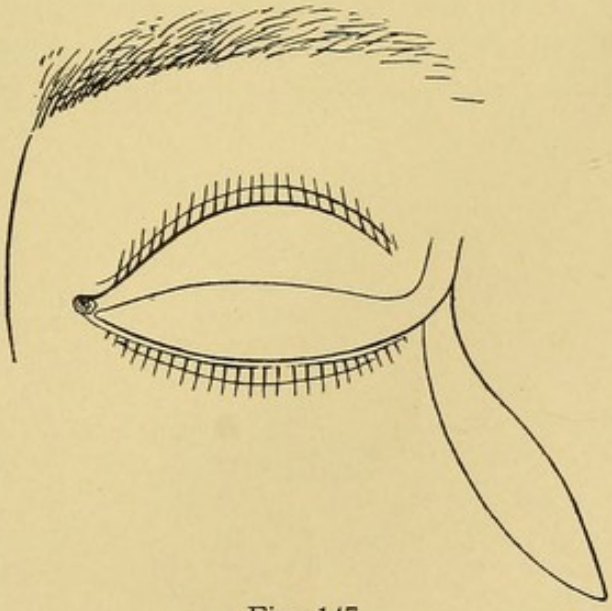

Fig. 147.
Flap with pedicle taken from cheek to line lower part of orbit, passing into external canthus.

Lagleyze[9] has an elaborate article studying the subject of operation, and artificial substitutes for natural eyes. After critically examining Mules' operation, and though admitting its practical advantages, he rejects it as an unsafe surgical procedure.

Semi-solid substances injected beneath the conjunctiva he finds better, though the results are not always permanent. He cites numerous experiments made with various solid and semi-solid substances, absorb-

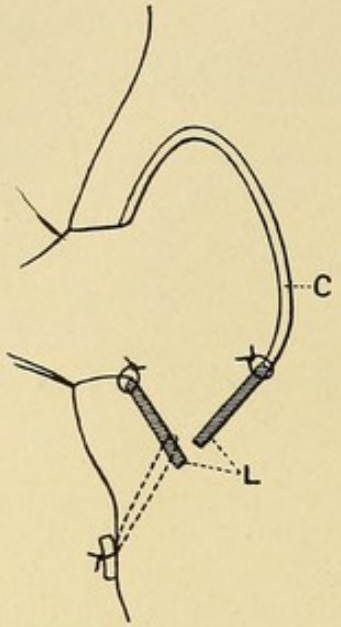

Fig. 148.
Restoration of inferior cul-de-sac for ectropion. (De Lapersonne.)

able or non-absorbable, but he thinks that all injected substances sooner or later undergo absorption.

He comes finally to the experiments of Gersuny-Eckstein with injections of vaseline and paraffin. Immediate injection seems not to

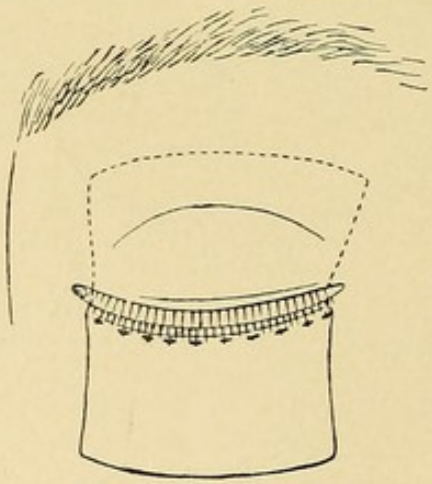

Fig. 149.
Large flap with pedicle to line cavity of orbit, taken from cheek.

give permanent results, but injections practised some days or weeks after enucleation (Rohmer, Dianaux, etc.) are more satisfactory. There is, however, danger of embolism connected with this method. Paraffin gives the best results, used at a fusing point of 60° C. The field of

operation, instruments and paraffin (finest quality) must be sterile; great care must be exercised in both location and quantity of injection.

There are other methods of injection of paraffin into Tenon's cap-

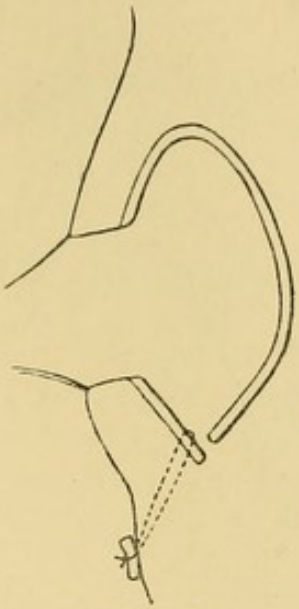

Fig. 150.
Modified Snellen suture operation of De Lapersonne for ectropion.

sule immediately after enucleation, and insertion of a solid paraffin globe. Much of the success of these methods depends upon the careful adaptation by sutures of the opposing recti muscles, and Lagleyze con-

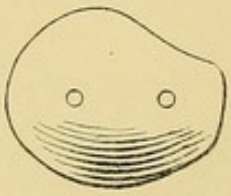

Fig. 151.
Perforated enamel or lead plate.

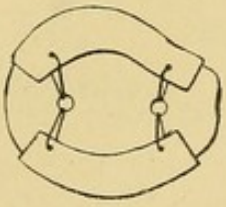

Fig. 152.
Method of holding plate in place, as if seen from behind.

siders this difficult; but with the solid paraffin ball, made in and kept ready for insertion from a special instrument, the prothesis is protected by the usual suture of the conjunctival opening. There is some increase in size after the paraffin is used, and for this and other rea-

sons the glass eye should not be selected till at least fifteen days have passed.

Ectropion of the lower lid is a grave obstacle to prothesis, and surgical intervention is necessary. A modification of the Snellen suture

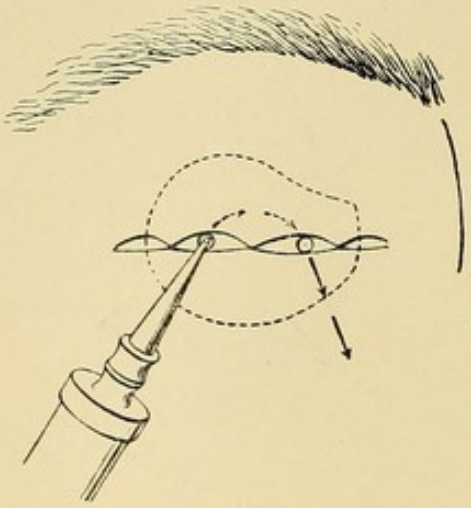

Fig. 153.
The orifice in the plate permits of lavage of the interior of the cavity.

has been proposed by de Lapersonne, which consists in passing the suture in the depths of the cul-de-sac, cutting the conjunctiva about 5 mm. behind the ciliary border from one canthus to the other, and fixation through the skin of the lid. Doyne[10] does a somewhat similar op-

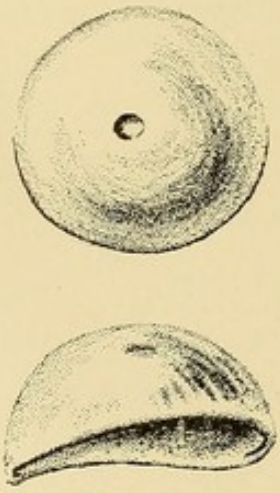

Fig. 154.
The Mueller "interims" prothesis.

eration where the carrying power of the lower lid has been destroyed by wearing an artificial eye which has become rough, or one which has always been a misfit. Under these circumstances the lid has become everted and flattened, while a mass of cicatricial tissue has formed on its surface. The steps of the operation are briefly as follows: A large

needle, threaded with stout silk, is passed from the conjunctiva of the lid beneath the skin and made to emerge in the patient's mouth, between the cheek and the gum at a point opposite the angle of the mouth. The needle is withdrawn and threaded with the other end of the silk and again passed through the conjunctiva about half-an-inch away from the first puncture, and made to emerge in the mouth at the same point as the first puncture. The two ends of the suture are next tied over the end of a match or a piece of rubber tubing, and this is given a twist two or three times a day until the silk cuts out. This generally happens in the course of three weeks, leaving a band of cicatricial tissue which by traction at its base effectually raises the lower lid.

Plastic operations for restoration of the socket.

If from cicatricial contractions, or if the cavity be too small and an eye cannot be retained, or only a very small one, inappropriate to the

Fig. 155.
Large fibro-sarcoma of orbit necessitating exenteration of orbit.

fellow, can be put in, we may have to do plastic operations, after preparation of the cavity by proper dissection, to receive the graft. These may be heteroplastic, using the skin of another person, or animal membrane. Haltenhoff[11] took frog skin; Wolff,[12] Post,[13] Wicherkiewicz,[14] and myself the conjunctiva of a rabbit; Panas[15] that of a dog, and Melville Black[16] the vitelline membrane of a fresh egg.

In 1900 a young man had been badly burned by lime and lost his eye by the trauma and subsequent enucleation, I succeeded in freeing the orbit and transplanting a living rabbit's conjunctiva, so that

ultimately he could wear an artificial eye. I have done this a half dozen times since.

Autoplastic operations may be total transplantations of the mucous membrane of the lips, Illing,[17] Landolt[18] and myself, or that of the vagina, Stellwag.[19] In two cases I have grafted membrane from the lips to the lining of the orbit with success.

Autoplasty without a pedicle has been practised by a numer of authors, either by the dermo-epithelial grafts of Thiersch, or by the full



Fig. 156.
Plastic restoration of orbit. Patient wearing prothesis seven days after operation.

skin grafts of Wolff. Thiersch,[20] 1874, is given credit for the first report on epidermal grafting, and Taylor,[21] 1876, for implantation of the whole thickness of the skin. The literature is quite extensive. May[22] stitches the flap by one suture at each end; Woodruff[23] employs a plate of lead; Weeks[24] takes the flap from the arm, applying next to the flap gutta percha material; Morax[25] uses a porcelain plate; Holth[26] uses the Mueller "interim" prothesis.

Zentmeyer[27] uses Thiersch grafts introduced and spread over a glass ball and thus held in position. In the case of bands, introduce a suture under the band near each end attachment, cut midway between,

then tie sutures over end of band, thus inverting and tucking in, and bring the intervening raw surfaces together with sutures.

The Weeks[24] operation is done by dissecting the lid from the orbital tissue as far as the periosteum, leaving the greater part of the conjunctiva (if it be present) on the orbital surface. The tissue attached to the lid should include the fibers of the orbicularis palpebrarum muscle. Free canthotomy is sometimes required.

The thin skin on the inner aspect of the arm is selected for the flap and folded with the epithelial surfaces in approximation. Three long sutures, each armed with two needles, are now passed through the flap



Fig. 157.

Cicatricial contraction of orbit, subjected to plastic operation with success, patient later wearing prothesis.

at the bottom of the fold, so that each suture forms a loop on the epithelial surface 2 mm. long and at equal distances from each other. The needles of the sutures are carried separately into the bottom of the groove, made to enlarge the periosteum at the margin of the orbit, and pierce the integument. The flap is then drawn down into position, the sutures being tied over small rolls of gauze. The edges of the flap are now sutured to the margins of the defect, a plate of rubber tissue consisting of a dozen or more layers well lubricated by bichloride in petroleum 1:500, maintains the flap in proper position. The wound is inspected on the third or fifth day, but unless sloughing is observed the plate is not disturbed until seven or eight days, when it is taken out,

sutures removed, sac and plate cleaned, replaced and bandage reapplied. An artificial eye may be introduced at the end of two or three weeks.

Autoplasty with a pedicle is done either by the Italian method of a flap from the arm, which is immobilized to the head for 14 to 15 days until the vitality is assured, or the procedure of Lippincott,[28] Harlan,[29] Snellen,[30] and Dianoux,[31] when the flap is taken from the cheek, forehead or temple. They differ somewhat from each other but agree in taking a flap from the temple and passing it through a buttonhole at the outer canthus through the lining of the orbit, where it is fixed by sutures.

Cicatricial bands may develop, causing symblepharon and entropion,

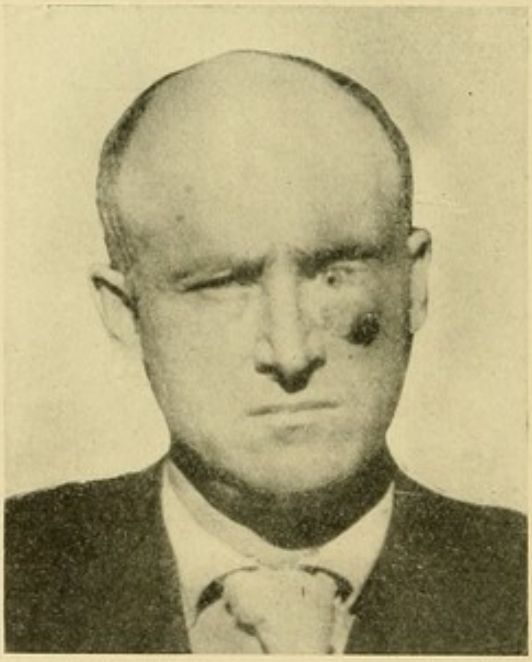

Fig. 158.
Results of plastic operation in orbit after exenteration, showing patient wearing prothesis.

which will heal again, if divided, in the same or a worse condition and demand a plastic operation. Harlan's[29] operation is employed extensively for symblepharon of the lower lid, but is also applicable for the restoration of the orbit for the removal of cicatricial bands. The whole thickness of the lid is incised for its entire length along the lower margin of the orbit, a second incision is made below this to form a pedunculated skin flap. After being carefully dissected away from all its attachments, except the pedicle, it is turned up through the first incision in the lid and sutured to its under surface, the cicatricial bands having been previously severed. The bare surface remaining upon the cheek is covered by a sliding flap taken from its outer extremity.

Samelsohn[32] obtains a large pedicular musculo-cutaneous quadrangular flap from the lower lid and fixes it by inversion to the cavity of the socket. When its adherence is assured the base is cut off and the raw surface on the skin of the lower lid filled in by sliding flaps and grafts.

De Lapersonne[33] takes a large pedicle downwards from the temple, introduces it into the cavity through the external canthus and deepens the inferior cul-de-sac by the Snellen suture.

James Moores Ball[34] reports two cases in which Maxwell's operation was performed with successful results. Before the operations artificial eyes could not be worn, but after, the orbits retained large artificial eyes. The operation consists in making a lower cul-de-sac of the loose skin of the lower lid. In addition to the Maxwell operation it was necessary to use skin grafts to restore the cul-de-sac.

LITERATURE.

1. Velez, *Anales de Oftal.*, May, 1908.
2. Lopez, ref. Valez.
3. Lauber, H., *Zeitsch. f. Aug.*, May, 1910, p. 426.
4. Marx, G., *Arch. f. Aug.* LVI, p. 15.
5. Rollet, *La Clin. Ophthal.*, Dec. 10, 1904.
6. Würdemann, *N. W. Medicine*, March, 1909.
7. Kuhnt, *Zeitschr. f. Aug.* XVIII, p. 152.
8. Gersuny-Eckstein, ref. Lagleyze.
9. Lagleyze, *Anales de Oftal*, Apr., May, June, 1904.
10. Doyne, *Ophthalmoscope*, Nov., 1905.
11. Haltenhoff, *Rev. d. l. Suisse romande*, 1885.
12. Wolff, *Arch. d'ophthal.*, 1890, p. 185.
13. Post, *Medical Review*, 1875, p. 203.
14. Wicherkiewicz, *Ophth. Cong.* Heidelberg, 1892, p. 185.
15. Panas, *Traité des Malad. des yeux*, Vol. II, p. 182.
16. Melville Black, personal communication, 1905.
17. Illing, ref. Coulomb.
18. Landolt, ref. Coulomb.
19. Stellwag, ref. Coulomb.
20. Thiersch, *Berl. Klin. Woch.*, 1874, *Centrallbl. f. Chir.*, 1886-1888.
21. Taylor, *Med. Times and Gazette*, July, 1876.
22. May, *Arch. f. Aug. XL*, 1900, p. 558.
23. Woodruff, *Ann. Ophth.*, Apr., 1903.
24. Weeks, *Trans. Internat. Corg. Ophth.*, Lucerne, 1904.
25. Morax, ref. Coulomb.
26. Holth, *Ophth. Klinik*, No. 19, 1905.
27. Zentmayer, *Ann. Ophth.*, Apr., 1903.
28. Lippincott, ref. Zentmayer.
29. Harlan, *Trans. Amer. Ophth. Soc.*, 1890, p. 651.
30. Snellen, *Trans. Amer. Ophth. Soc.*, 1890, p. 207.
31. Dianoux, *Gaz. Med. de*
32. Samelsohn, *Ophth. Cong. Heidelberg*, 1892, p. 149.
33. De Lapersonne, Lectiere Hotel Dien de Paris, Jan. 30, 1903.
34. James Moores Ball, *Ann. Ophth.*, Oct., 1905.
35. Coulomb, *L'Oeil Artificiale*, Paris, 1908.

CHAPTER XVII.

CONSERVATIVE OPERATIONS—THE REMOVAL OF FOREIGN BODIES FROM THE EYE.

A. (a) Foreign bodies in the anterior segment, cornea, anterior chamber, lens —(b) Foreign bodies within the globe—Dangers of retained foreign bodies—General description—Literature. B. Magnet operations—Constitution of steels—Character of magnets—Hirschberg's—Haab's giant—Victor magnet—Inner-pole magnet of Mellinger—Classification of magnet operations—Rules for giant magnet—Rules for hand magnet—Technic with large magnet—Complications—Precautions—Reasons for failure—Technic with hand magnets—Modifications—Results—Literature. C. Removal of non-magnetizable bodies—Powder—Wood—Copper—Glass—Stone, etc.—Literature.

The various conservative operations are described under the anatomical headings. The subject of foreign bodies, however, implicating as they usually do, several of the ocular structures, is discussed in the following chapter.

REMOVAL OF FOREIGN BODIES FROM THE INTERIOR OF THE EYE.

A large proportion of the cases brought to the ophthalmologist are of traumatic nature and, in manufacturing communities, injuries attended by the entrance of foreign bodies are extremely common. Simeon Snell[1] says that very few persons working at the iron and steel trades escape injury in the course of two years, and there are many more accidents to the eye in the course of this time than the number of men employed.

Clinically we may divide these cases into non-penetrating injuries, with or without impaction of foreign bodies, and these are mostly due to scale or emery, or iron splinters in the cornea; and also foreign bodies which penetrate the eyeball. The large majority of the latter are retained within the ball, but some may pass through both sides and become impacted within the orbit, or, in the case of bullet wounds, pass entirely through.

All these injuries may be infected or non-infected.

Foreign bodies that can be removed from the eye may be classed in two groups: First, those arising from iron splinters, which comprise

about 75 per cent. of all injuries or cuts by foreign bodies penetrating deeply, and the balance of copper, stone, wood and glass particles, which, as a rule, enter the eye more rarely and remain lodged in the anterior portion more often than within. Copper particles, however, may enter with exceeding force, as when resulting from explosions and firearms.

An eye in which a piece of iron, steel, or copper is buried invariably deteriorates, and ultimately becomes blind (siderosis bulbi), if the foreign body is not removed, unless it becomes completely encapsulated. In many cases this degeneration is preceded by the symptoms of hemeralopia.

We may thus anatomically, and with respect to prognosis, differentiate these penetrating bodies into two classes, one in the anterior and one in the posterior segment.

A. FOREIGN BODIES IN THE ANTERIOR SEGMENT OF THE EYE-BALL.

It is universally recognized that when the foreign body is in the anterior segment of the eye, the injury is much less serious than when it has passed on through the lens into the posterior segment, or has entered the vitreous chamber through the ciliary region or the sclera.

Foreign bodies in the cornea are sometimes difficult of removal, being so firmly imbedded that free incision of the corneal tissue about them is required to loosen them before they can be removed. When the anterior chamber is opened, care must be taken not to push the foreign body deeper. Here the large magnet may be useful after the splinter has been partially loosened. When a chip of iron or steel is firmly imbedded the large magnet has no effect whatever.

(Operations for removal of foreign bodies from the external coats of the eye are specifically discussed under the anatomic headings.)

Foreign bodies in the anterior chamber are usually easy of removal. If they are of iron a small peripheral incision, if the original wound be closed, and a Hirschberg magnet will readily accomplish the result; but even a piece of steel thus situated may resist removal and lead to blindness. The particle may fall into the angle of the anterior chamber or pass through the pupil into the posterior chamber, when, if not iron, it may be difficult of removal and may set up an irido-cyclitis with all its dangers.

Foreign bodies within the globe.

Foreign bodies in the iris demand prompt removal, for usually, if allowed to remain, they may set up a severe iritis. If the magnet will not remove it, forceps must, of course, be used. If it cannot readily be disentangled from the iris, we may succeed in so doing by drawing the

portion of the iris containing the foreign body through the wound, so that we can more readily have access to it, and then after its removal replace the iris. Should these measures fail, it might be necessary to perform an iridectomy, removing the portion of the iris containing the foreign body.

A foreign body in the lens is less liable to produce injurious symptoms or sympathetic inflammation than when located in other parts of the eye. On the other hand, these injuries sometimes result very disastrously, as in a case reported by H. Knapp.[2] If the foreign body be in the lens, there is not the same necessity for immediate operation for removal as exists when it is in any other portion of the eye. If the foreign body be allowed to remain in the lens, the opacity is almost sure to increase until the entire lens becomes opaque. If the lens has been only slightly wounded, the cut of the capsule may close up at once so

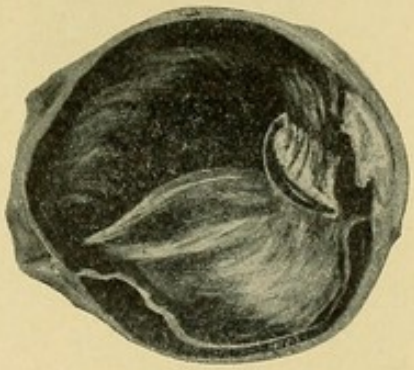

Fig. 159.
Chip of iron in ciliary body. Nearly complete absorption of lens.

that the aqueous cannot get to the lens. Mydriatics, by keeping the lens absolutely quiet and so preventing the wounded fibers from rubbing against one another, or other fibers, in the varying changes in its conformity incident to efforts of accommodation, may prevent the increase of the opacity.

It is to be remembered that such injuries from the traumatism in most cases irreparably damage the eye and that even when a foreign body is successfully extracted the eye may be blinded by later detachment of the retina or subsequent irido-cyclitis or formation of opacities within the vitreous and lens.

These cases are usually seen shortly after the accident, but there are some in which the foreign body has been retained for many years. I have had two cases of small steel splinters in the lens which did not produce full opacification even after several years, which had been allowed to remain on account of the patients absolutely refusing operation for their removal.

In one of my cases a boy was injured by explosion of powder which he had placed in a tin can and lighted. I attended him at the time of accident, and the piece of tin was observed by me for nearly 15 years after. V.=fingers. V. F. contracted.

Dickey[3] reports a case in which the patient had been injured in the eye by a piece of steel seventeen years previous to the time when

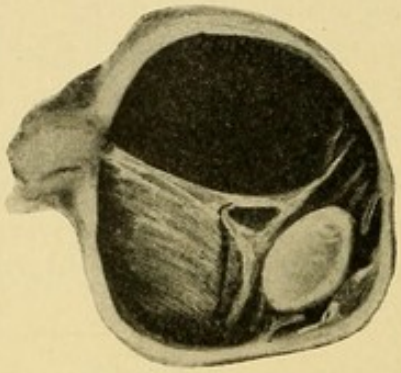

Fig. 160.
Glass splinter in vitreous, causing detachment of retina.

the writer was consulted. The eyeball showed signs of degeneration and was painful and inflamed. Enucleation was done and the eyeball found firmly attached to the orbital tissue, in the region of the optic nerve, by dense bands of adhesions. A piece of steel, the size of a buckshot, was found lying on the floor of the eyeball in the lower anterior quadrant.

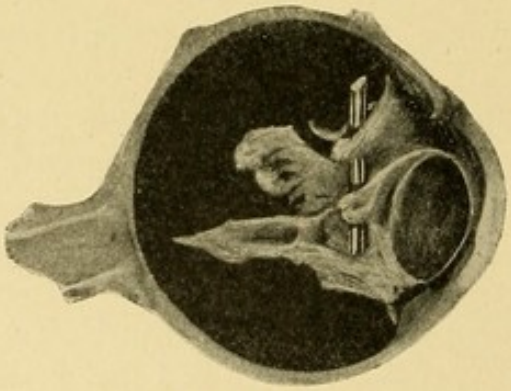

Fig. 161.
Brass wire in vitreous. Extensive chemical reaction with organized exudates. Enucleation one week after injury.

Bruner[14] reports a case of a piece of steel in the iris ten years, removed after corneal incision by iridectomy with iris forceps, recovery with normal vision.

He also reports particle of steel in lens, removal by corneal incision, Haab and Hirschberg magnets, recovery without increase in opacity. V.=3/lxv.

In another case a piece of steel remained in lens without patient even knowing that he was injured. Cataract developed, foreign body not removed on account of patient disappearing.

In Knapp's case[2] the patient was injured by a piece of steel which perforated the eye and lodged in the lens, the foreign body was removed a few hours after the injury, and yet panophthalmitis developed which required enucleation.

Doyne[5] reports a case of a foreign body in the lens thirty years. The patient was injured in the right eye in childhood, later was in the army twelve and in the volunteers nine years. Until twenty-eight years after the accident he could still see to shoot with that eye.

Lewis[6] reports a case of foreign body, probably steel, in the lens

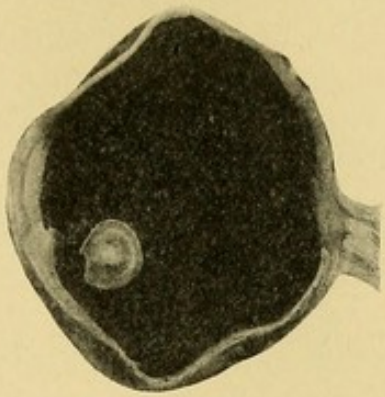

Fig. 162.

B. B. shot in vitreous, eye filled by blood clot. Enucleation twenty-four hours after injury.

for six years, at the end of which time the lens was otherwise perfectly clear and vision was 20/xx.

Sattler's[7] experience was that all cases of iron in the lens for over half a year produced opacity of the lens, and in this he is upheld by Elschnig,[8] who advised extraction of the foreign body in all cases by a lance incision into the capsule and magnet operation up to the age of forty years, after which the lens is too hard.

B. FOREIGN BODIES IN THE POSTERIOR SEGMENT.

A different story of the dangers, damages and results must be told about foreign bodies in the posterior segment of the eye, for as a rule these have flown with much force, have already wounded the anterior structures in their course, and if allowed to remain in the eye not only destroy the sight, cause atrophy of the globe, but may result in sympathetic ophthalmitis.

The results of removal are certainly not as good, for it may be safely said that if the ultimate statistics of cases in which foreign bodies have

been removed from the posterior segment by magnet or otherwise could be obtained, far more than one-half would show blindness from irido-cyclitis, atrophy, detached retina, etc., and in a large proportion enucleation ultimately had to be done.

Immediate treatment is the essential point, as in this way many eyes are saved from sepsis, and the foreign body is more readily extracted before clots and connective tissue enclose it. The shorter the time the magnet is used after the lodgment of a piece of steel in the interior of the eye the better.

Every effort must be promptly made to free an eye from a foreign body, because some time or other retinal detachment or destructive inflammation will probably call for enucleation. Permanent toleration is so exceptional that it should not be considered. The presence of foreign bodies (not iron) in the sinus of the anterior chamber is sometimes very difficult to ascertain, especially when associated with hypopion or granulation tissue in the iris. Then the Roentgen photograph is of inestimable value.

In a critical case where it is questionable if the foreign body be inside or outside the posterior scleral wall, the size of the eyeball should be carefully considered. Eyes vary in their size where high refractive errors exist and are sometimes larger in people who have very large heads.

The diagnosis is of paramount importance, as well as the early removal of a foreign body, especially in recent cases, in which postponement of the operation even to the next morning may mean the loss of an eye. Both Roentgen photograph and sideroscope are necessary in any doubtful case. The sideroscope hardly ever disappointed Hirschberg.

The time intervening between the accident and the operation for the removal is a most important factor, the best results being obtained in those cases which are operated on within the first twenty-four hours following the accident. Any foreign body imbedded in the eye soon becomes surrounded by a plastic exudate which, though quite soft, appears to hold it firmly and offers great resistance to its removal. When the piece of metal or other foreign body has been in the eye some days or weeks, the amount of force necessary to withdraw it drags so much on the neighboring tissues that the subsequent inflammatory reaction, together with that resulting from the original trauma, reduces the possibility of a satisfactory result and undoubtedly, in some cases, brings on a marked irido-cyclitis, with early shrinking of the globe.

The situation of the wound of entry is of considerable interest and importance. In corneal wounds the ultimate result depends on the final position of the metal—when in the lens the results are excellent, when

the metal passes through the lens into the vitreous or was imbedded in the coats of the eye beyond, the results are disastrous.

Wharton[9] states that in wounds of the ciliary body, or further back in the sclera, the results are not usually good and enucleation may be necessary. The danger of sympathetic ophthalmitis is ever present in eyes retained after such accidents, even though the foreign body be successfully removed. Perhaps surgeons are nowadays too conservative in such accidents and some eyes are kept in that might better have been immediately enucleated. Such patients should be kept under observation for several years after apparent recovery.

Regarding the size and shape of the piece of metal the spicules of iron or steel are easiest to withdraw, due to the fact that the poles produced on the metal by the magnet are more apart in the long, narrow pieces of metal, while in the small rounded bits of metal the poles are too clustered.

Concerning the septicity of the wound, all chips of metal entering an eye may be considered as free from organisms, the septic inflammations being produced by the subsequent entry of organisms either through the tract of the wound or during the operation for removal.

LITERATURE.

1. Snell, Simeon, *The Prevention of Eye Accidents in Trades*, London, 1897.
2. Knapp, *Arch. Ophth.*, Jan., 1906, and *Manhattan Eye, Ear and Throat Hosp. Reports*, 1905.
3. Dickey, *West. Virg. Med. Journ.*, July, 1908.
4. Bruner, *Ophthalmology*, Oct., 1906.
5. Doyne, *Trans. Ophth. Soc. Un. King.*, Vol. XIV.
6. Lewis, F. P., *Arch. Ophth.*, Jan., 1906.
7. Sattler, *Internat. Cong. Ophth.*, Utrecht, 1900, p. 433.
8. Elschnig, *Münch. Med. Woch.* No. 15, 1910.
9. Wharton, *Ophth. Review*, Dec., 1905.

B. MAGNET OPERATIONS.

Removal of magnetizable foreign bodies from the interior of the eye by the electric magnet.

The larger proportion of iron splinters are magnetizable, but during recent years steel alloys have been used in certain industries which have altogether different properties than ordinary steel (Simeon Snell[1]). Manganese steel is very hard, containing 12 per cent. manganese, 87 per cent. iron, and 1 per cent. carbon, and is non-magnetizable. Nickel steel contains 4/10 per cent. carbon, 20 per cent. nickel, and 9/10 manganese with iron, and unless tempered in liquid air is non-magnetizable. Chromium steel is fairly magnetizable, but much less so than ordinary steel or iron. The possibility of iron splinters which cause injury to the eye being non-magnetizable should therefore be recognized, and the character of the object making the wound should first be ascer-

tained. Other alloys of iron are highly magnetizable, but not as much so as soft iron.

Mortimer Frank[2] has gone into the subject of magnetic and non-magnetic properties of iron alloys, showing that when manganese in an alloy of iron reaches 13 per cent. its magnetic character is denatured, being as inert to magnetism as zinc or stone.

Nickel steel containing not to exceed 3 per cent. is as good magnetically as very soft iron, and even to 30 per cent. is extremely magnetic. Add 5 per cent. manganese to any of these high percentage nickel steels and they become non-magnetic. When copper or chromium is added to an almost non-magnetic nickel manganese steel the composite alloy has its magnetism perceptibly increased. Excess of carbon in high manganese steel softens them and increases their magnetic susceptibility. Tungsten united with copper in steel possesses remarkable magnetic properties; 2½ per cent. silicon or aluminum in iron increases the magnetism.

Spratt[3] reports the case of a machinist who was struck in the cornea by a very small piece of steel weighing less than a milligram, which pierced through into the vitreous. Extracted with the magnet, which resulted in normal vision.

Sweet[4] made a series of experiments upon the magnetic properties of steel from which he gives the following table:

Specimen.	Total Carbon.	Manganese.	Other Ingredients.	Maximum Induction.
Cast iron, gray	3.45	0.17	.....	9148
Cast iron, mottled	2.58	0.61	.....	10546
Cast iron, white	2.03	0.38	.....	9342
Cast iron, malleable	...	...	.....	12408
Wrought iron	...	...	.....	18251
Bessemer steel	0.04	0.20	.....	18196
Open-hearth steel	0.32	0.43	.....	18736
Hadfield manganese steel	1.00	12.36	.....	310
Manganese steel, forged	1.29	8.74	.....	1985
Chrome steel, forged	0.68	0.02	1.19 Cr.	14680
Manganese steel, annealed	1.29	8.74	.....	1985
Chrome steel, annealed	0.68	0.02	1.19 Cr.	13233
Tungsten steel, forged	1.35	0.03	4.64 W.	15718
Tungsten steel, annealed	1.35	0.03	4.64 W.	16498

The relatively high magnetic induction of chrome and tungsten steels, and the almost total absence of magnetic properties of manganese steel, is well shown by the above figures. Nickel steel is not included in the tables, but is considered separately.

Character of magnets.

The magnets in common use by ophthalmic surgeons vary from the small permanent magnets made of bars of iron, usually "home made affairs," to the secondary or induced magnets, the hand magnet of

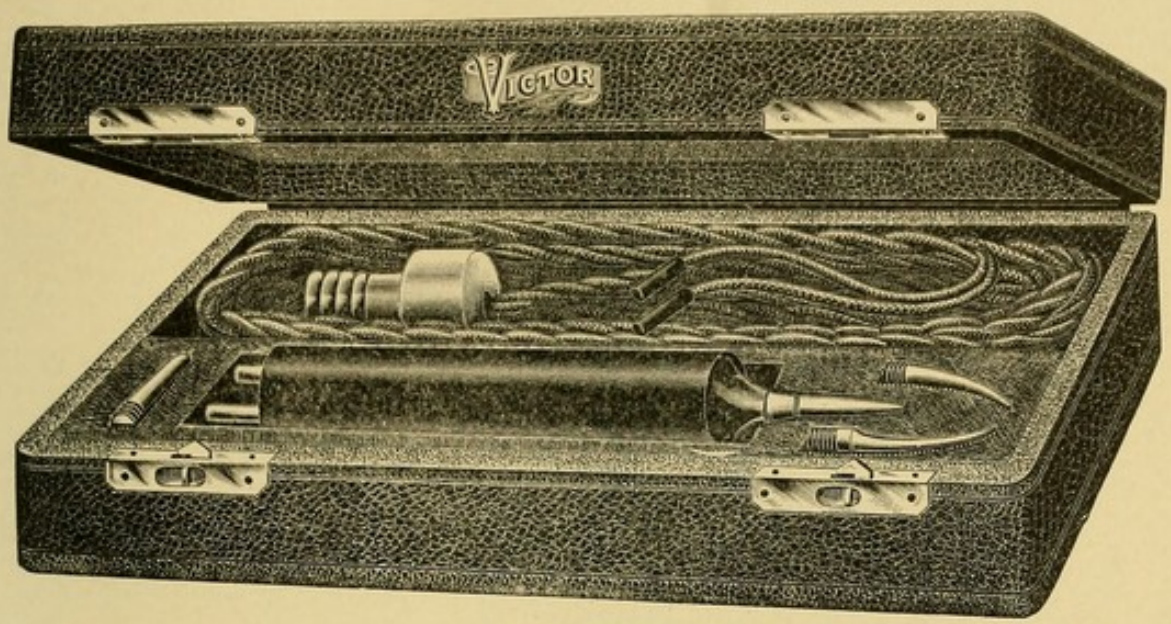

Fig. 163.
Hirschberg's small magnet.

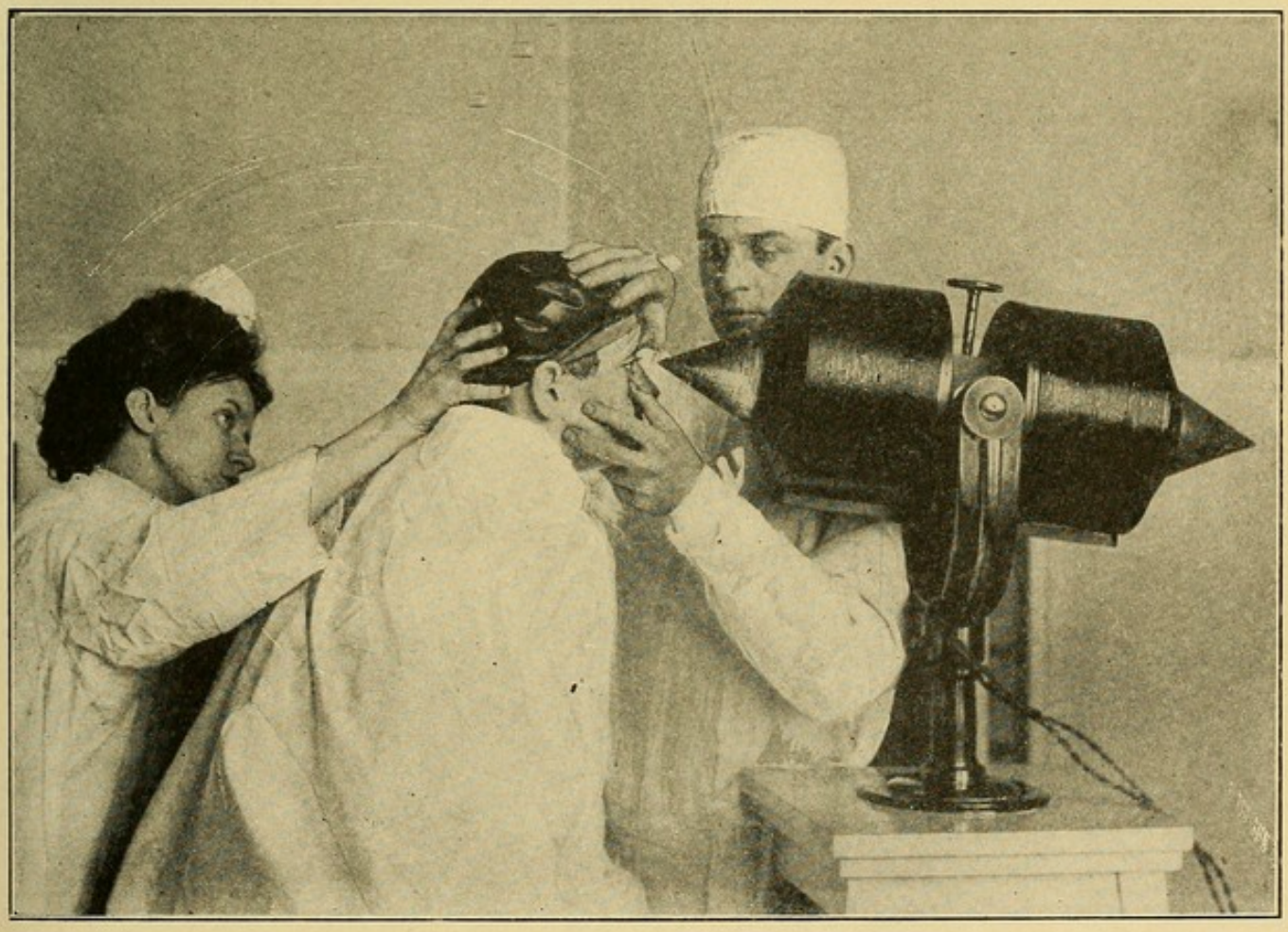

Fig. 164.
Haab's giant magnet.



Fig. 165.

1911 model of Haab's giant magnet.

Hirschberg. All of these are secondary or induced magnets, receiving their power in the case of the small ones from electrical elements, wet or dry cells or storage batteries, and the larger ones from commercial lighting circuits. They are composed of a soft core of iron, covered by a tubular shell of wire. Hirschberg's small apparatus weighs about

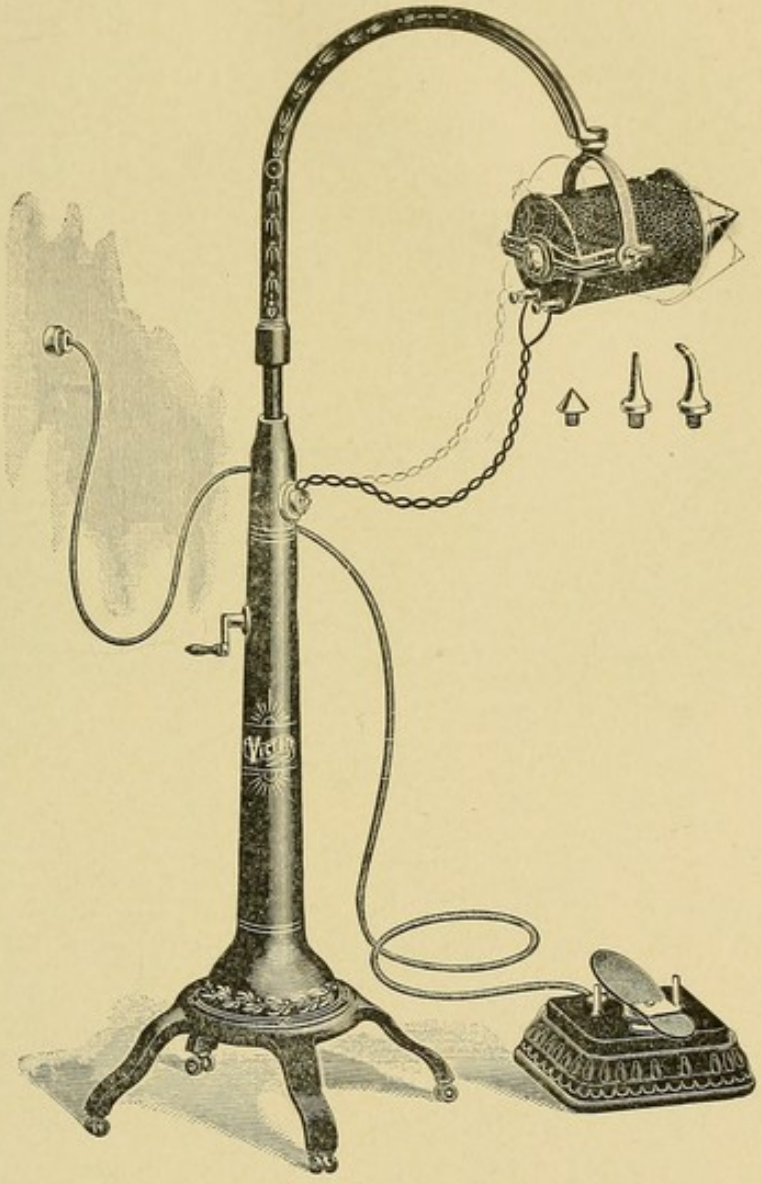

Fig. 166.
Victor giant magnet on crane.

200 grams and costs 30 marks in Berlin; his larger one weighs 570 grams. Those of Sweet, and other American magnets, are of comparatively small cost. The Victor magnet costs about $75.00 and weighs about 150 pounds with its crane. The Haab magnet weighs 30 kilos., takes 50-60 amperes with 40-50 volts, costs 460 francs in Zürich, and almost as many dollars in America.

Jurnitschek[5] states that in the use of all these magnets, which consist of a core of iron encircled by layers of wire, if the piece of iron is situated in the posterior portions of the eye, the magnetization will not be as intensive, since by the divergence of the lines of force (as may be demonstrated by the arrangement of soft iron filings on a sheet of paper placed on the magnet), only a part of them will act on the foreign body. Another disadvantage of these magnets is that they obscure the field of operation by their bulk.

The intra-polar magnet devised by Mellinger and Klingelfuss[6] allows of a better utilization of the lines of force. It has the form of a large ring, which consists of a great number of coils of copper wire surrounded by a ring of iron and acts on the principle of a solenoid. If an electric current passes through a solenoid, a homogenous electric field is generated with its greatest intensity in the point bisecting the axis of the solenoid, and the lines of force are parallel to the axis. A small



Fig. 167.
Victor flexible extension for magnet.

piece of iron, placed in the axis of the solenoid, therefore receives a greater magnetic induction than by the other kinds of magnets. A series of iron rods, of varying thicknesses, which are held in the lumen of the solenoid, serve as armature. The opening of the ring is adapted to the average size of the human head, so that the eye with the foreign body and the iron rods, manipulated by the hand of the operator, are placed in the area of greatest magnetic concentration. None of the rods is so thick as to cover the field of operation.

Klingenfuss found by his experimental measurements that the attraction in the operative field of an interior pole magnet is homogenous all over and that there is no preferred point of force, which establishes the superiority of this magnet. At the same time he proved that in the interior pole magnet the upper limit of the practically attainable attraction for extracting ferro-magnetic foreign bodies had been reached, for beyond the attraction of the magnetically saturated iron, if saturation exists in the foreign body and the extracting rod, nothing more can be attained. The non-dispersion of magnetic lines of force in the operative

zone, in contra-distinction to the intense dispersion at the poles of the ordinary electro-magnet rods, shows that the saturation of the most deep-seated foreign body is complete.

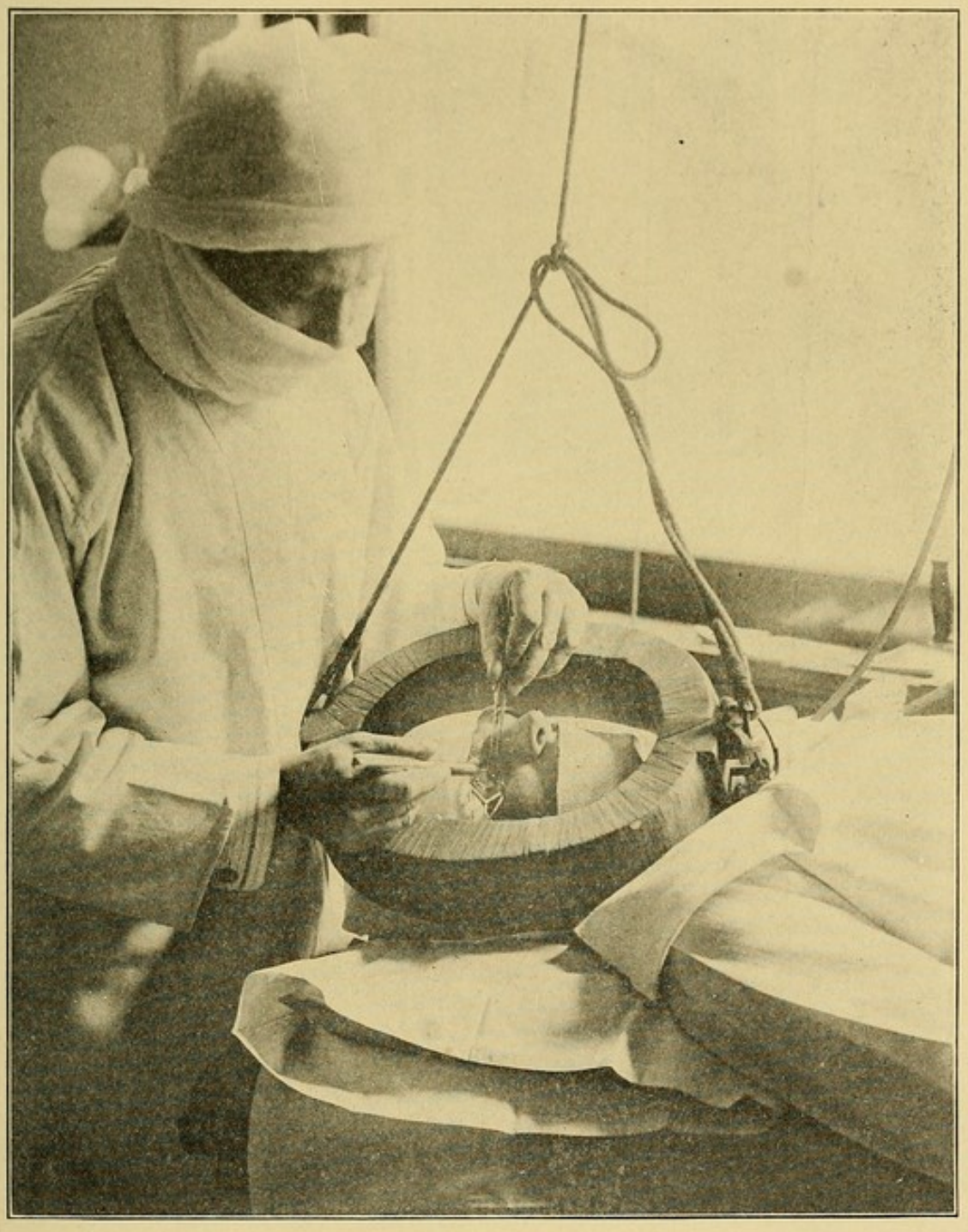

Fig. 168.
Intra-polar magnet (Gifford).

Hallauer[7] describes the new mountings which give the interior pole magnet greater mobility, and allow it to operate on the patient in a recumbent position. The new model can be easily rolled about.

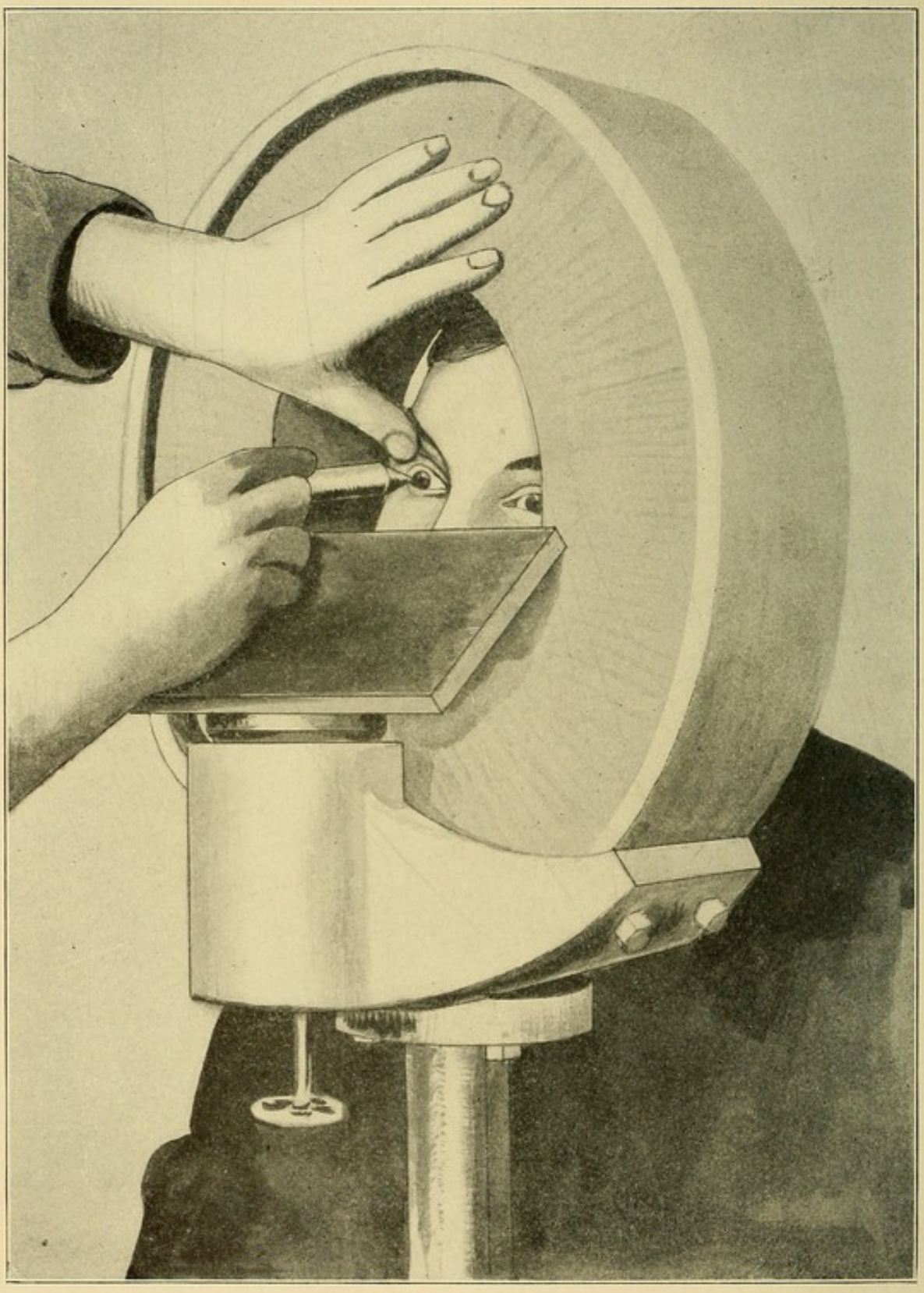

Fig. 169.
Mellinger's intra-polar magnet.

History.

It is only since the extensive development of the iron and steel trades during the last fifty years that iron splinters in the interior of the eye have become common in practice. However, they have been known since the beginning of civilization. The chirurgical use of magnets was mentioned in the Vedas—i. e., a magnet constructed out of a bar of iron. Perhaps the first mention in literature of the use of the magnet on the eye was by Fabricus, of Koeln, Germany, in 1656. Then followed Morgagni, 1779; Milhes, 1745; Meyer, 1842; Dixon, 1858; White Cooper, 1859; McKeown, 1874; Hirschberg, 1875-77-79. Many other forms of magnet have been devised since, such as those of Froelich, Snell, Collins, Parker, Sweet, and others. The large magnets were devised by von Rothmund, 1873; McHardy, 1881; Knies, 1781; Voltemis, 1883; Haab, 1892; Schlösser, 1895; Mellinger and Klingelfuss, 1908. Of these the Hirschberg is the most effective type of the smaller model and the Haab or Victor that of the larger. For a full history see Hirschberg[8] or Praun.[9]

Magnet operations may be divided into two great classes: First, for eyes that positively contain a foreign body. Second, for those that have every appearance of the presence of a foreign body, but in which the magnet gives a negative result. It is not uncommon for the patient to give a positive history, and upon examination for us to find a wound in the cornea and minus tension. What more could we ask to make a diagnosis of a foreign body in the eye? Such histories may be misleading, and upon testing by the sideroscope, the X-ray and the giant magnet, negative results may be given. In such cases the eye may be retained within the head, and some instances result in retained vision.

Upon history and examination, indicating that an object may be supposed to be magnetizable, attempts at removal may be made by either the small, medium, or large-sized magnet. Localization is chiefly needed when the small magnet is used, to bring it into as close contact as possible with the foreign body so as to seize it. In the use of the giant magnet the chief principle is the attraction of the foreign body at a distance. Haab[10] claims that it allows of the removal of foreign bodies from the eye, without disturbance of the vitreous by the entrance of the magnet, and he restricts the use of the small magnet to the removal of iron splinters from the anterior chamber.

Haab[10] says that there are practically no indications for the smaller magnet, and that all foreign bodies can be more safely extracted by the use of the larger magnet. Praun and other authors, however, agree that the Haab magnet finds its best use when the iron splinter is not visible and is very small. Large pieces of iron drawn forward by the great power of this magnet are dangerous, causing rupture of the lens and

opacities in the vitreous. Incision of the sclera, and the use of the Hirschberg magnet with the point is to be preferred in the latter cases. Haab's method should be used with the following:

(1) Small splinters of iron in the retina which are apparently not under 0.02 grams. When smaller than this the Hirschberg magnet should be entered through the original wound or by an incision through the sclera into the vitreous.

(2) In the case of small iron splinters in the vitreous, especially those which are in the posterior portion of the bulb, which, on account of their size, can be drawn into the anterior chamber without injury to the lens and the iris.

(3) In all cases in which the splinters are in the anterior portion of the eye, deep in the cornea, sclera, iris, and lens, when it is possible to remove them through the original wound without causing further damage. In cases where the foreign body is in the lens capsule it is easier to remove by the attraction of the large magnet than by secondary extraction.

(4) When the splinter is not visible but is diagnosed by the feeling of pain produced by the magnet.

The Hirschberg or hand magnet is to be used generally when the splinter is visible, especially when it is quite large, when one does not desire to probe the vitreous body. It is likewise used with very small foreign bodies—i. e., under 0.02 grams—which cannot be extracted by the Haab magnet. When the foreign body is not visible and the wound is quite large and is possible of being closed, probing with the point of the Hirschberg magnet may be used. Sounding by the small magnet tips is likewise to be done in the case of large splinters. In the majority of cases when the splinter cannot be brought into the anterior chamber, and when a secondary wound of the eye cannot be made, a small wound and the smaller magnet are, as a rule, more useful.

The hand magnet is especially recommended in:

(1) Large bodies in the vitreous and retina which may be removed through the original wound or through a scleral incision.

(2) In small foreign bodies which remain near the wound of entrance and which are visible.

(3) Splinters in the retina which have remained in place a considerable length of time and are not attracted by the Haab magnet. These splinters are usually under 0.02 of a gram in weight.

(4) In septic splinters which are surrounded by pus in which the Haab magnet would infect the eye in extraction from the anterior portion of the orbit, and when the Haab method does not work.

(5) After the foreign body has been attracted into the anterior chamber of the eye by the giant magnet, when the splinter remains in the

anterior chamber or under the iris and cannot be drawn further forward.

As a rule it is advisable to try the Haab magnet first and to use the hand magnet later to complete the operation.

A number of various sizes and shapes of end pieces are used on the small magnets, some pointed, rounded, or ovoid, the larger types having the greater drawing power.

The large Victor magnet has a flexible shaft attachment to which small points are fixed and with which the instrument may be used as with the hand magnets. This apparatus, therefore, is a combined large and small magnet.

Technic with the large magnet.

Haab's magnet is so heavy that it is usually solidly and permanently mounted on a stand in a horizontal position and the patient's head manipulated so that the eye is as a rule brought into such a position to the instrument that the point of the magnet is opposite the middle af the cornea. The current circuit is opened and closed by a foot switch.

H a a b[10] says, above all things, we must avoid drawing the splinter into the ciliary body, from whence it is very difficult to bring it further forward. It is only when we must assume that the foreign body is so large that in drawing it toward the middle of the anterior chamber it might closely graze and injure the crystalline lens that we should bring the lateral part of the cornea opposite the magnet. But since in the majority of cases the lens has been already injured by the entrance of the splinter, such consideration for the lens is of no great importance.

It generally occurs, then, that a splinter located in the vitreous body or in the retina is drawn forward either quickly or slowly and slides around the lens. It follows in the direction where it finds the least resistance. It also pierces with the greatest facility the zonula of Zinn and appears behind the iris, which it causes to bulge out a little. This bulging of the iris should be at once noticed by the operator, for he must as quickly as possible open the electric current or rapidly push back the patient's head. The splinter must not penetrate the back side of the iris, but must be drawn obliquely through the pupil into the anterior chamber. If it is, therefore, behind the temporal part of the iris, the patient must look in that direction, and if the pupil has been put under the influence of atropin and cocain before the operation, it is generally possible without much difficulty to draw the splinter from behind the iris and through the pupil. But this part of the operation demands all the skill and attention of the operator and a certain amount of patience. He should never hope or intend to extract the splinter through the iris. It would not succeed at all with small splinters, and large ones would tear the iris too much.

Complications.

If in extracting a splinter it becomes fixed fast behind the peripheric portion of the iris, from whence it is very difficult to draw it to the pupil, a lance incision may be made at the point of the margin of the cornea where the splinter lies, then introduce iris forceps into the anterior chamber and seize the iris as in iridectomy. Do not draw this towards the incision, but rather push it towards the side of the anterior chamber opposite to the foreign body. This results in a small iridodialysis in front of the foreign body through which, when the point of the large magnet is lightly inserted in the wound, it can slip through and reach the magnet. The dialysis heals in a few days.

The cornea may be incised and the point of the smaller magnet pushed behind the iris without the necessity for an iridectomy.

Precautions.

No large chips should be drawn through the iris; one end must at least lie in the anterior chamber; neither the point of the magnet nor the foreign body should injure the lens. Haab prefers in scleral injuries to draw the foreign body into the anterior chamber and extract through a corneal incision.

If the foreign body be attracted in a wrong direction it may be redrawn backwards. If it sticks in the tissues it may be jarred loose by suddenly opening and closing the circuit or the eye may be moved so that the force acts in different directions. Chips often lodge in the retina. In Haab's 165 cases 34 were in the retina, 28 being removed by the magnet. The ophthalmoscope and diaphanoscope may be useful to observe the progress of the foreign body outwards during the operation. My diaphanoscope is here specially serviceable for focal illumination.

H a a b[10] gives the following reasons for failure: "Following these rules you will generally succeed in extracting the splinter from the eye, even if it is lodged in the retina. Of the whole number of 165 cases in my experience the operation only failed 23 times. The operation was successful in 141 cases, or in 86 per cent. If we consider the 134 difficult cases in which the splinter penetrated behind the iris and the lens, we find that in these 134 cases the large magnet only failed 23 times to extract the splinter from the eye, and was successful in 111 cases, or 83 per cent. These failures were due to the following circumstances:

(1) The foreign body was seated too firmly in the back wall of the globe or had pierced it completely.

(2) The splinter was seated in the ciliary body at first, or was drawn there by mistake.

(3) The splinter had produced fibrinous-purulent exudation which, according to my experience, greatly hinders its movability.

(4) The splinter had been healed over in the course of months or years."

Technic with the medium-sized magnets. The Victor, Ramsay and Schloesser types, which are movable about their axes and usually mounted on cranes or suspended by cables, are much the same as the giant magnet of Haab except that they allow of the patients being in a recumbent position and the magnet may be moved instead of the head of the patient.

Technic with the hand magnets of Hirschberg (large and small), Johnson, Sweet, etc. With these instruments the various tips are usually entered into the eye, either through the original wound or through a surgical incision, and the tips brought against or in the neighborhood of the foreign body before the current is turned on, the chip of iron usually adhering to and being brought out of the eye thereon, or being assisted by forceps. The elastic arm, with tips, of the Victor magnet may be used in a similar manner. Forceps may be magnetized by contact with the stronger magnets and used within the eye as advised by Gifford.[11]

Technic with the intra-polar magnet. After instillation of atropin the head of the patient, he being seated on a revolving chair, is brought into the ring and an attempt is made to bring the foreign body into the anterior chamber, from which it is extracted by means of Hirschberg's hand magnet.

Modifications. Sattler[12] says where Haab's method is not successful the sclera is to be incised at a point nearest to the estimated location and the foreign body removed by magnet. In the discussion following this paper the majority of the speakers favored this method of removing foreign bodies, rather than that of Haab. One of the chief objections raised against incision of the sclera, separation of the retina, had not been observed by the majority to follow.

Repeated trials by the giant magnet from day to day are to be deprecated before making a scleral puncture (Kauffmann[13]).

It must also be remembered that a double perforation may occur, as in shot wounds if the flying chips come with sufficient force and the foreign body pass through the eye and into the orbit, as in a case of my own. Sweet,[15] Murray,[16] and Shumway[17] have reported such cases.

Wharton[14] favors the scleral wound for bodies in the vitreous. He regards the giant magnet as inadvisable in cases not seen for several weeks after the injury, confirming the opinion expressed in the second series of cases here reported, that it is

impossible to gauge the amount of traction of the giant magnet upon a body the size and position of which are not known and which has remained in the globe until covered with exudation.

Results. Hirschberg[18] says within the last 27 years in which he has practised the magnet operation, with his small magnet, the medium-sized one of Schloesser, and the giant magnet, he has used it 347 times. From 1896 to 1903, out of 3,018 clinical patients, 64 cases with pieces of iron in the retina and vitreous were operated on with the electro-magnet. Thirty-six (56 per cent.) regained good and lasting vision (23 of these had V.=1/2 to 1), 9 had pieces in the vitreous, 27 in the retina, 22 were recent, 14 old. One-third were extracted with Hirschberg's hand magnet, two-thirds with both giant and hand magnets. In 6 cases out of 64 (9 per cent.) vision was lost and only the shape of the eyeball was preserved. In 22 out of 64 (34½ per cent.) the injured eyeball was enucleated. In the great majority of these 22 the foreign body was too large, or cyclitis or sepsis existed when the patient came under treatment. In 4 out of 64 Hirschberg did not succeed at extraction.

Wm. Fisher's[19] statistics of his own operations are: Total number of cases one hundred and fifty.

Symptoms of metal in eye, but negative result with magnet	49
Metal removed	97
Metal found in eyeball after enucleation—"magnet negative"	4
Good vision	96
Sightless eyes—external appearance good	34
Enucleations	20

Knapp and Stoll[20] reported a series of 22 cases of penetrating injuries to the eye, and now add an additional series. These cases are grouped according to the location of the foreign body, and in this series the authors report 30 cases in which the foreign body could not be seen with the ophthalmoscope, but was extracted from behind the lens. The clinical history, method of removal of the foreign body and after-results are given. In 9 cases the foreign body was removed through the original wound, the remainder of the cases requiring a new incision. The visual results varied from 20/xx to light perception. Ten cases showed evidence of infection on admission to hospital, and of these seven were saved.

Haab[19] says regarding the results obtained in 165 cases the splinters were extracted from 141 eyes: "This number gives us a correct idea of the usefulness of the instrument, and is, obviously, very favorable. The numbers, however, which tell us how many eyes were preserved for use by the operation, or at least were saved from enucleation, are influenced by a factor independent of the method of extraction—that is, by the infection which in some cases followed the injury caused by

the splinter. Consequently, in my 165 cases I had to ultimately remove the eye 39 times because of purulent inflammation of the primary wound. In 9 cases lingering cyclitis set in, generally brought on by the injury and not the operation. Nineteen eyes were preserved—that is, saved from inflammation—but they were sightless. In 71 cases the eye could be used or could be made use of by a cataract operation, and 51 of these 71 eyes healed with good sight."

My own experience and that of other authors is quite similar and bears out Haab's conclusions, except as to No. 6.

1. The size of the splinter of iron or steel, and its approximate position in the eyeball, should be known before an attempt is made to extract it either by the medium-sized or the giant magnet.

2. The X-rays are the most certain method of diagnosis in injuries from all kinds of foreign bodies.

3. The large and medium-sized magnets are of value in determining the presence of iron or steel, but negative findings cannot be accepted as conclusive evidence of the absence of metal in the eyeball.

4. The Haab magnet is superior to all forms of smaller magnets in extracting iron or steel from the vitreous chamber by way of the anterior chamber, but the great power of the instrument requires that it be used with caution.

5. When the body is to be extracted through an opening in the sclera close to the previously determined position of the metal the medium-sized magnets are shown by experience to be as effective as the giant magnet.

6. The entrance of the magnet point into the vitreous is harmful, and should never be attempted except when other means of extraction have failed.

In 1901 Sweet reported a series of 102 cases of injury in 65 cases of which a foreign body was located by the Roentgen rays. A second series of 318 cases, in 173 of which a foreign body was shown by X-rays, was published in 1906.[21]. In the present communication are reported 282 cases of ocular injury, in 157 of which a foreign substance was found to be lodged in the eyeball or orbit. It is interesting to note the location of the foreign bodies in these 702 cases:

	First series.	Second series.	Present series.
In the eyelid	1	2	0
In the lens	3	14	16
In the iris or posterior chamber	1	4	4
In the ciliary region	24	27	12
Near the equator	21	69	52
Posterior part of eyeball	12	46	48
In the orbit	3	11	25
No body shown by X-rays	37	145	125
	102	318	282

The right eye was injured in 308 cases and the left eye in 390.

	First series.	Second series.	Present series.
Eyeballs enucleated:			
Extraction not attempted or failed..	14	23	19
Extraction successful, enucleation later	10	28	39
Eyeballs saved:			
No operation attempted.....	7	11	4
Extraction failed	2	4	9
Bodies in eyelid or orbit.....	4	9	17
Extraction successful:			
Vision 6/12 or better.....	7	20	17
Vision 6/15 to 6/60.....	4	13	11
Fingers or hand movements, etc....	0	7	12
Good light projection.....	9	27	15
Light perception	6	21	9
No light perception, eye normal size	0	6	2
Eyeballs shrunken	2	4	3
No bodies shown by X-rays.....	37	145	125
	102	318	282

Causes for removal of eyeballs are tabulated as follows:

	First series.	Second series	Present series.
Extraction not attempted or failed.....	14	23	19
Irido-cyclitis	5	14	15
Panophthalmitis	1	8	14
Shrunken or lacerated eyeball.....	2	5	7
Sympathetic irritation	0	0	2
Recurring hemorrhage anterior chamber	2	1	1
	24	51	58

Two causes stand out prominently as contributing in a large measure to the loss of eyes injured by foreign bodies: First, the period elapsing between the injury and removal of the body, and, second, the size of the metal entering the globe. A few days may suffice for a firm exudate to surround a body imbedded in the retina or chorioid, and even if the extraction is successful the amount of damage that follows the drag of the magnet upon the tissues in disengaging the metal cannot be estimated. The author believes that the importance of prompt diagnosis of the lodgment of a foreign body in the eyeball and its immediate removal are being more fully recognized even by the workingmen in the larger industrial establishments, and they seek experienced advice rather than accept the opinion of the local physician, who is too often disposed to say that he thinks there is nothing in the eye. It is unfortunate, however, that a certain proportion of injured eyes will be lost from panophthalmitis or irido-cyclitis even though the patient is promptly seen and the steel or iron removed.

Retinal detachment after injuries of foreign bodies is not uncommon, but Sweet has not seen it occur at the point of the scleral incision.

G. Kanzel[21] reports in detail on 145 cases in which pieces of iron or steel were ascertained in the interior of the eye, viz., in the deeper layers of the cornea 15, anterior chamber 8, iris 11, lens 7, vitreous 104. Extraction was attempted in 138 cases, and succeeded in 126—i. e., 91.3 per cent.

Conclusions.

Sweet[22] says: "1. Radiographic examination should be made in every case of ocular injury from a foreign body in which lowered visual acuity is the result of the accident.

2. Extraction of a foreign body through a small meridional incision in the sclera, the magnet point not introduced into the vitreous, causes no greater traumatism than follows drawing the metal through the vitreous into the anterior chamber.

3. Retinal detachment is not a logical result of a scleral incision for the extraction of a body from the vitreous chamber. The exudation associated with a long-retained foreign body is probably a more frequent cause of detachment.

4. Introduction of the magnet point into the vitreous increases the traumatism to the eyeball, encourages retinal detachment and often leads to shrinking of the eyeball and to irido-cyclitis.

5. Bodies located above the horizontal plane of the globe or at the posterior part of the vitreous chamber usually present greater difficulties in extraction, owing to the early formation of a fibrous exudate near the equator, to which position they fall after penetration."

Hirschberg[23] reports a case of a man, aged 39, while hammering on an iron nail, was struck by something in his left eye, on May 11, 1909. May 14th he was sent to Hirschberg, who found a vertical wound 1½ mm. long, at the horizontal meridian of the cornea, 4 mm. from the nasal limbus. A small piece of the pigment layer of the iris was lacking at the nasal border. The pupil was maximally dilated, and a wound of the capsule of the lens could be clearly seen. The lens was opaque, so that an ophthalmoscopic view was prevented. V. = fingers at ½ m. The sideroscope indicated the presence of iron at the inferior region of the ciliary body. The application of Volkmann's and giant magnets elicited pain, but no foreign body. Five further attempts within the next ten days were also in vain. The Röentgen skiagraph was negative. As the meridianal section in the ciliary region is disagreeable on account of hemorrhage, and not without danger on account of the later consequences, especially as the lens was opaque, Hirschberg performed, under deep narcosis, a section in the sclero-corneal junction and iridectomy. At the third introduction of the hand magnet a piece of iron, 1 mm. long, 0.5 mm. wide, not very thick, weighing 4 mgr., was

extracted. The wound was now negative. On June 12th the patient was sent back to his physician.

C. REMOVAL OF NON-MAGNETIZABLE BODIES.

The removal of copper, brass, stone, wood, glass, and lead particles from the interior of the eye.

Particles other than iron or steel, such as glass or copper, are very much more difficult to remove, but fortunately injuries with such particles do not occur at all as frequently, nor is their prolonged sojourn in eye nearly as apt to damage it as a visual organ. With regard to such particles (not of iron or steel), as H a a b[10] says, it is often more advisable to leave them in the eye (unless, of course, they can be seen somewhere in the anterior segment of the globe where they are accessible), than to open up the vitreous and probe around, as it were, in the dark, with forceps and other instruments in search of the foreign body. To endeavor to remove such oftentimes damages the eye more than to leave it untouched. It is, therefore, very fortunate that the great majority of bodies penetrating the globe are of iron or steel.

Fragments of stone, wood and glass enter the eye more rarely than in the case of iron, but they are apt to remain lodged in the front portion of the eye. Copper and brass splinters are as a rule projected with much more force, but since the days of the percussion cap are over, they are less frequently met with. We occasionally find copper splinters that enter the eye in the case of brass workers and copper miners, and from the effect of explosions of powder and dynamite caps and shells.

The d i a g n o s i s is obtained by the history of the accident, by the ophthalmoscope, diaphanoscope, focal illumination and the X-ray. In recent cases ophthalmoscopy may show a red or yellowish foreign body, or in older ones cyclitis or irido-cyclitis. Before or after an operation for removal, a considerable brownish-red opacity of the vitreous and iris may be seen, and very fine deposits of the lens capsule where there are symptoms of chalkosis, to be followed by siderosis, which never disappears.

C a s p a r[25] says injuries of the deeper portions of the eye by copper are considered to be of evil prognosis. Leber shows that copper is very apt to arouse suppuration in the vascular parts of the eye even without introduction of bacteria. On the other hand, copper imbedded in the avascular parts, e. g., the lens, may be well borne. Especially unfavorable are those cases in which the foreign body penetrates into the vitreous, as its extraction may be very difficult or impossible.

M o r r i s o n[26] says notwithstanding the well known tendency of copper to produce suppuration, one case of this sort recovered after having harbored a piece of copper for a whole year.

Weiss[27] says that the prognosis of copper injuries involving the anterior segment of the eye is not unfavorable, provided the metal contains no virulent germs and is removed early; that neither a mydriatic nor myotic should be used, lest the position of the foreign body shift and be lost to view in the anterior chamber. For the same reason attempts at extraction without an anesthetic are dangerous.

Therapy. If it be decided to attempt removal by either the original wound or a new incision Desmarres forceps should be introduced and the object seized and, if possible, withdrawn, followed by antiseptic treatment and bandage. It is exceedingly difficult to grasp such splinters as Haab remarks.[10]

Cases have been reported of copper particles remaining in the eye for years. As a rule, however, enucleation subsequently has to be made.

In Ertl's case[28] (with recovery and vision 3/xxiv) a piece of gun cap penetrating had caused, downward and laterally from the optic disc, wavy and spotted configurations shining like gold, which could be followed up to the macula, which was covered with glittering dots, arranged in the form of a polygon, about one-third of the papillary diameter wide. On oblique illumination a gray opacity, apparently in the anterior strata of the lens, was noticeable, which disappeared when examined with transmitted light. The posterior, and faintly the anterior, images of the lens appeared in vivid rainbow colors.

Weiss[27] reports a case of fragment of copper wire within the eye. The patient was seen the day after the accident. There was a piece of copper wire 5 mm. long and 3 mm. thick in the anterior chamber. The wound had extended to the iris and the anterior capsule of the lens. There was a localized opacity beneath both anterior and posterior capsules. A slight hypopion disappeared after the successful extraction of the foreign body. Vision, later, $= 5/v$; the lenticular opacities were unchanged.

A case of Goldzieher is quoted in which a piece of copper was lodged in the retina for ten years, and which showed similar phenomena, as, e. g., the apparent disc-shaped opacity of the anterior strata of the lens.

Probably these, as well as the changes of the retina, the impairment of vision and anomalies of the color sense, were caused by disturbances of the nutrition of the lens and damage to the inner tunics from the permanent chemical irritation of the copper on the ciliary body and iris, "chalkosis retinæ," according to Goldzieher.

Plitt[29] diagnosed with Röentgen-rays and removed successfully a minimal segment of copper wire from the anterior chamber.

In a boy who was working in a wire shop cutting copper wire with nippers, the piece cut off was projected with great violence and pene-

trated the eye, the wound being through the ciliary region, and from its having caused such great disorganization and complete blindness, it was necessary to enucleate the eye within forty-eight hours. The copper wire was found within the globe.

I once saw a young man with a piece of percussion cap imbedded in the bottom of the vitreous, which had entered more than a year before. The eye was non-irritable and the case was lost sight of.

In a miner from the Lake Superior district, from one of the mines where native metallic copper is chipped out with cold chisels, a sliver passed into the eye and became encysted therein; absolute blindness resulting from irido-cyclitis. Patient refused enucleation and passed out of observation.

A boy aged 15 had picked up a dynamite cartridge, which was covered over with brass wire, and was examining it in the kitchen pantry when it exploded, blowing out the side of the house and taking with it a portion of both hands of the lad, the concussion rupturing both his drumheads, causing detachment of the retina in one eye and immediate blindness in the other from perforation by a portion of the wire gauze covering. A large number of pieces of the fine wire gauze were also imbedded about his face and the face was badly burnt. Enucleation of the injured eye was finally done by another surgeon, after I had given up the case on account of disagreeable nature of family, friend's and a physician's interference.

Particles of glass, stone and coal penetrating the eye and remaining in the vitreous, if aseptic and in a position difficult of removal, may be allowed to remain in hopes of retention without further damage, as they do not cause chemical changes as in the case of iron and copper, or if the wound is not in the ciliary region causing fear of sympathetic ophthalmia.

The diagnosis is made as in the case of copper and iron fragments, by the history, focal and ophthalmoscopic examination, and the X-ray, and by careful probing.

Attempted removal either through the wound or a new incision by aid of forceps.

A stone-cutter received a chip of granite from the hammering of another workman. This penetrated the sclera, was felt by the probe, seized and removed by forceps with resultant good vision.

A quarryman was hit by a flying fragment of stone, which penetrated through a large rupture of the cornea and sclera; he lost most of the vitreous and came to immediate enucleation.

A miner received many particles of sand and chips of stone from a blast in his face and eyes; many small pieces lodging in the cornea were removed. One particle passed into the vitreous through the sclera and

remained impacted in the retina of the other side, with resultant vision of 6/vi. The foreign body became covered by exudate and remained innocuous. In the other eye a particle of sand had passed through the cornea into the lens, causing cataract. Extraction done later with V. = 6/xxiv.

A chemist had a bottle explode because of an unfortunately written recipe which he had compounded and was shaking. A sliver of glass passed through the sclera and into the vitreous, where it could be seen by the ophthalmoscope and diaphanoscope for months later. V. = 6/xii.

Sweet[30] reported several cases of glass and stone in the interior of the eye diagnosed by X-rays and removed by the scoop but with no vision, only preservation of the globe.

Grains of lead are practically only found from shotgun injuries. These are dealt with under the subject of shot and bullet wounds.

Vigier[31] reports a case of panophthalmitis after penetration of a whip lash into the vitreous chamber. There was a perforating wound of the sclerotic with hernia of the ciliary body and the eye soon became violently inflamed and intensely painful. Some days later (why not immediately?) the ball was enucleated and a piece of whip lash four centimeters long was found within it.

A satisfactory method of removing fresh powder stains (as previously stated), is given by Heustis.[24] The patient must first be thoroughly anesthetized. Then with a stiff nail brush, using soap and water rendered antiseptic by carbolic acid, bichloride solution, or any other antiseptic that may please the operator, scrub the part thoroughly. Do not hesitate to draw blood, and do not cease until the grains of powder have been entirely removed and face, hands, or other surface are clean. Should it become necessary to remove the entire cuticle do not hesitate to do so, as it will reform in a few days. It is sometimes impossible to eradicate a deep spot entirely, and in this case a smooth, elliptical incision is to be made, the stain removed, and a light suture inserted. Following the operation of scrubbing, it is only necessary to cut a dressing the shape of the surface denuded, soak it in carbolized oil and apply. The next day the patient may complain of a stiffness of the skin of the affected parts, which passes away in a short time. After the skin has resumed its normal condition it may be necessary, where blue spots may be seen remaining, to remove by the elliptical incision previously mentioned.

Burns of the face of this character are usually of the first degree (i. e., superficial) only involving the epidermis; when its vitality has been destroyed and the true skin or corium cooked by the heat, the burn is then that of the second degree. Application of carron oil (a mixture

of linseed oil and lime water), picric acid 3 per cent. or 5 per cent. boric acid ointment is the treatment.

The use of a stiff brush with soap and water, as above outlined, render it unnecessary to pick out each individual powder granule or powder stain, for the nitrate of potash becomes absorbed a few hours after the injury, leaving only the carbon of the powder in the wounds. In severe cases powder removal should be done under general anesthesia as it is extremely painful. The application of hydrogen peroxide, which forces out the carbon stains; the application of papoid which is a digestant and attacks the injured tissues only, thus aiding in the exfoliation of the dead tissue and with it the carbon stains; and the after treatment with antiseptic ointment, being all that is usually required. Very few cases should be left with their faces disfigured by the tattoo marks of the powder explosion. The eyes are to be treated on general surgical principles; foreign bodies removed by the spud after the use of holocain, not cocain, as cocain diminishes the vitality of the parts, and the application of antiseptic ointment, use of boric acid washes, and if ulceration ensues hot applications, which are preferably used for one-third hour every three hours; dionin, atropin and bandage are the proper procedures. Even if the eyeball has been penetrated, if it is only the cornea or only the sclera, sight may be saved; if detachment of the retina has occurred from the force of explosion, or suppuration ensues, or if the ciliary region has been injured, blindness or even loss of the eyeball may occur. Severe injuries of the skull may lead to death. Enucleation may have to be resorted to and plastic proceedings on the lids for subsequent contraction, are at times needed.

Prognosis. These explosion accidents with copper penetration of the eye have been invariably fatal to the preservation of vision and the eye has in some instances come to enucleation.

The impaction of powder grains in and under the conjunctiva, however, is comparatively often seen, either as the result of powder and firework explosions, or from imperfect breech or backfires in guns. These powder grains are not to be picked out. It is necessary here to remove a small piece of the conjunctiva and subconjunctival tissue, together with the powder stain or grain, with or without a subsequent suture.

LITERATURE.

1. Simeon Snell, *Lancet*, June 20, 1906.
2. Mortimer, Frank, *Ophth. Record*, Dec., 1907.
3. Spratt, *Ophth. Record*, Sept., 1908.
4. Sweet, *Ophth. Record*, June, 1905.
5. Jurnitschek, *Zeitschr. f. Aug.*, 1905, p. 426.
6. Mellinger, *Beitr. z. Phys. v. Path.*, 1908.
7. Hallauer, *Zeitschr. f. Aug.*, XXIII, (Aug., 1909, p. 204, 1909, p. 49.)

8. Hirschberg, (a) *Centralbl. f. prak. Aug.* 1890, p. 110; (b) *Arch. f. Ophth.*, XXXVI, 3; (c) *Der Elektromagnet in der Augenheilkunde*, Leipzig, 1881; (d) *Berl. Klin. Woch.*, 1896, No. 26; (e) 25 *Jähr Bericht. d. Augenheilanstalt, Berlin*, 1895.
9. Praun, *Die Verletzungen des Auges*, p. 341-371.
10. Haab, *Trans. Sec. Ophth., A. M. A.*, 1902.
11. Gifford, *Trans. Sec. on Ophth., A. M. A.*, 1909.
12. Sattler, *Trans. Amer. Ophth. Soc.*, 1905.
13. Kauffman. *Die Ophth. Klinik*, No. 1, 1905.
14. Wharton, *Ophth. Rev.*, Dec., 1905.
15. Sweet, *Ophth. Rec.*, July, 1907.
16. Murray, Wm. R., *Ophth. Rec.*
17. Shumway, *Amn. Ophth.*, Oct., 1907.
18. Hirschberg, *Berl. Klin. Woch.*, No. 8, 1907.
19. Fisher, Wm. A., *Ophth. Record*, Jan., 1903.
20. Knapp and Stoll, *Arch. Ophth.*, July, 1907.
21. Kansel, *Klin. Mon. f. Aug.* supplement, XLVIII, 1910, p. 174.
22. Sweet, *Trans. Sec. of Ophth., A. M. A.*, 1906, p. 370.
23. Hirschberg, *Centralbl. f. prak. Aug.*, 1890, p. 110.
24. Heustis, *Ophth. Record*, Oct., 1898; July, 1909.
25. Caspar, *Klin. Monatsbl. f. Aug.*, XLV, 11, 1908, p. 179.
26. Morrison, *Ind. Med. Jour.*, Vol. XXVI, No. 3.
27. Weiss, *Die Ophth. Klinik*, May 5, 1908.
28. Ertl, *Centralbl. f. prak.* Aug., 1907, p. 322.
29. Plitt, *Klin. Monatsbl. f. Aug.*, 1906, p. 537.
30. Sweet, *Ophthalmology*, July, 1906.
31. Vigier, *Ann. d'oculist.*, Feb., 1907.

PART II

INJURIES OF THE SPECIAL STRUCTURES OF THE EYE

CHAPTER XVIII.

I. INJURIES OF THE CONJUNCTIVA.

A. Abrasions and wounds—Pathology—Infections—Tuberculosis—Opening of Tenon's capsule—Traumatic conjunctivitis—Occupational—Treatment. B. Foreign bodies—Etiology and symptoms—Diagnosis—Prognosis—Examination and therapy. C. Ophthalmia nodosa—Etiology and mechanism—Course—Diagnosis—Prognosis—Therapy. D. Injuries by blunt objects—(a) Conjunctival ecchymosis—Hematoma—(b) Serous effusion—Edema—Chemosis—Emphysema. E. Pigmentation of conjunctiva—(a) Methyl violet—(b) Siderosis—(c) Blood pigment—(d) Argyrosis. F. Burns and cauterizations. G. Tumor formation. H. Injuries from firearms—Literature.

II. OPERATIONS WITH THE CONJUNCTIVA.

History—1. Plastics for defects of cornea—Single and double peduncles—Two flaps—Implantation without flaps—Ulcers—Prolapse of iris—Fistula—Keratocele—Staphyloma. 2. Ocular injuries—Operative procedures—Temporary covering—Flaps—Lattice suturing—Miscellaneous.

Injuries of the conjunctiva are usually combined with injuries of the lids and cornea, or sclera, and, in penetrating wounds, with those of the other parts of the eye. When the conjunctiva alone is affected, with the exception of burns, these injuries come under the head of trivial accidents.

Mark Stevenson[1] says little is seen in ophthalmic literature about these minor injuries to the eye, but much has been written on the use of electro-magnets for the removal of steel from the interior of the eye. He thinks that more eyes are lost, and certainly more damaged through neglect or improper management of the minor injuries, than from those demanding the electro-magnet.

A. WOUNDS.

Abrasions and cuts of the conjunctiva are of comparatively infrequent occurrence, as this membrane gives before the impact of the instrument, sliding over the ball, and is therefore less apt to be abraded or cut than the cornea. Cuts of the ocular conjunctiva are not very painful and soon heal. They but seldom become infected. Abrasions are more painful, as they usually occupy larger areas of the membrane,

more nerve filaments being involved than in incised wounds. The docility of the conjunctiva is well shown in the many operations that may be done upon or through this membrane; thus it may be opened, transplanted or slid to almost any location and stretched or mal-treated in many manners without permanent injury or interference with the functions of the eyeball.

Pathology.

Cuts, stabs, piercing wounds, lacerations and abrasions may be considered with wounds of the same character of the lids or cornea. Isolated cuts are rare and harmless, they gape, the space fills with blood and the edges are reddened. They soon come together whether or not sutures be applied, and heal by primary union.

Stab wounds are usually in connection with those of the lids and orbital contents.

Piercing wounds occur with penetration of the bulb or orbit, with or without retention of foreign bodies. When in connection with those of the lids, the caruncle, plica or lacrimal canaliculi they may be readily seen, but when due to a foreign body piercing the globe the wound of entrance through the conjunctiva may sometimes be observed with difficulty.

Most commonly wounds of the conjunctiva caused by foreign bodies, as flying pieces of iron or shot, passing either first through the lids or between them when the eyes are open, are of the nature of lacerating or contused wounds, and these are more prone to infection, not only caused by the foreign body, but by the patient's fingers, or by dirty bandages, as well as by the pathogenic cocci which are present in the normal conjunctival cul-de-sac.

Indirect rupture of the conjunctiva occurs in scleral rupture and in avulsion of the eyeball.

Infections and complications.

The liability of wounds of the eyeball to infections is readily perceived when we think of the large number of pathogenic germs that float in the atmosphere and that can be found lying upon the surface of all exposed mucous membranes, such as the conjunctiva. A crack in the armor, however, is needed to allow of the entrance of these agents of death and destruction—a solution of continuity is necessary, for live germs cannot penetrate through four or five layers of cells constituting the epithelium of the cornea and conjunctiva. In the mixed secretion of tears and mucus with which the eye is constantly lubricated may be found the streptococcus, the staphylococcus and the pneumococ-

cus, any or all of which are constantly obtained as the cause of ulcerations and of infected wounds. Many other germs, some twenty-one in all, have been detected in the secretions of practically normal eyes.

Conjunctival tuberculosis has been ascribed by Stutzer[2] to a bite.

Praun[3] saw a case in which a suppurating wound near the caruncle occurred after perforation by a piece of wire. This penetrated to Tenon's capsule. Rapid healing followed.

Opening of Tenon's capsule in connection with wounds of the conjunctiva occurs in surgical operations, as for squint, but rapid healing follows.

Accidental opening has been reported by Berger[4] in the case of a boy who had a red-hot piece of iron fly against his eye, burning the cornea and making an irregular tear of the conjunctiva. The probe showed that it communicated with Tenon's capsule.

I saw a similar case in which a flying piece of iron with sharp edges (which was brought to me by the injured man who was cutting railway rails), simply glanced upon the eye stripping the conjunctiva down to Tenon's capsule, which was likewise opened. Several stitches and an antiseptic dressing restored the normal appearance and functions within a few days.

Traumatic conjunctivitis.

Traumatic conjunctivitis is due to the irritation of germs, dust or chemical laden air; to the entrance of small foreign bodies, or to the abrasion of epithelium accompanying wounds and contusions. In the first instance true conjunctival infection producing the characteristic forms of conjunctivitis arises; dust and chemicals give rise to occupational conjunctivitis, shown in the form of a chronic conjunctival catarrh, especially of a follicular type; the irritation attending abrasions and wounds soon passes away. Small foreign bodies entering the conjunctiva usually cause a local irritation and congestion. The mechanical action of wind and the chemical action of light and electricity in the eyes are discussed elsewhere.

Conjunctivitis from dirt is occasionally seen in the lower classes. Gaylord C. Hall[5] reports two such cases, both in children and severe:

"1. Age two years. One week ago had dirt thrown into left eye. Two days later eye became swollen and painful and a purulent discharge developed. Family physician prescribed remedies without effect. Microscopical examination of pus not recorded. When seen there was

a free discharge of pus, eyelids, swollen and edematous. Eye first cleansed carefully; cornea unaffected. Prescribed argyrol 25 per cent. Disease persisted for several weeks, due chiefly to indifference and carelessness at home, the child being cared for by neighbors as the mother was in an advanced stage of tuberculosis.

"2. Nine years. Right eye. Injured last fall by getting some rust from wire screen in it. Sore for several weeks, partially recovered. Since that time has had recurring attacks of inflammation in eye. Eye looks smaller, due to a ptosis. Eye is red and inflamed; considerable lacrimation and photophobia. Says she sees all right. Conjunctiva is red and velvety. Around periphery of cornea are a number of scars from old ulceration, together with a number of fresh ulcers resembling ruptured phlyctenules. Center of cornea is free. Gave argyrol, dionin, hot applications and yellow oxide ung. locally. Syr. iodid of iron internally."

The air we live in is a mixture of its various component gases with a considerable amount of organic matter suspended therein, wafted from place to place, flying as dust. The beam of sunlight passing through a darkened room is an ample and homely illustration showing this condition. The dust of our cities is composed of particles varying in consistency from carbon from smoke to the most composite conglomeration of micro-organisms; the latter cling to the particles formed from animal and vegetable matter, more particularly the former. Thus it is that so many diseases are common to cities where people and animals are crowded together; influenza, pneumonia and other diseases of a contagious type are extremely uncommon in the pure clear air of the wild woods and uninhabited places. In many instances wounds heal without suppuration in wild animals and in dwellers of the woods, whereas the slightest scratch, in some vocations, for instance, that of the surgeon, may be productive of severe infection. Particles of inanimate objects must be of appreciable size to give a sensation as of foreign bodies and often the minutest metallic dust that fills the air of machine shops, file and knife-grinders' places, etc., is borne by the eyes with more or less impunity, being washed away by the tears. The fumes of chemicals, the dust of the road, of flour mills and of factories contribute their quota to the irritation. Hence we may speak of traumatic or irritative conjunctivitis to which some workers are liable, such as horsemen and others who are exposed to much dust, and in this class of cases pterygium is frequently found. If dust, sand, ashes, or other irritative substances remain in the eye for some time, it causes granulation formation, which should be differentiated from trachoma. A change of occupation or environment is the only cure for such cases.

1. Mark Stevenson, *Ther. Gaz.*, Jan., 1905.
2. Stutzer, *Beitr. z. Aug.* XXX, p. 10.
3. Praun, 1, c., p. 503.
4. Berger, *Arch. f. Aug.*, XVII, 3, p. 290.
5. Gaylord, C. Hall, *Ophthalmology*, Oct., 1910.

B. FOREIGN BODIES.

Motes in the eye.

Foreign bodies on or in the conjunctiva or under the lids are of frequent occurrence and happen to every person. They are so frequently impacted in the cornea that some of the phases are discussed together in the following.

Etiology and symptoms. Foreign bodies completely but temporarily produce economic blindness, as such patients are unable to go on with their vocation until the offenders are removed. Most foreign bodies are speedily removed by the tears or by the patient himself.

The amount of irritation caused by a foreign body depends upon the position of its impaction. If it penetrates the sclero-conjunctiva, especially to the nasal or temporal side, the irritation may be very slight and after a short time it may completely cease, the body becoming impacted and remaining there for a long time without causing annoyance. The same may be said of the lower portion of the cornea, which is not completely covered by the upper lid in the act of winking. I have seen many cases of particles of emery, of iron spiculæ or of stone, in the case of iron and stone workers, which have become impacted beneath the ocular conjunctiva and even in the cornea, remaining for weeks without causing trouble after the first few hours had passed away. The retrotarsal fold will often accommodate foreign bodies of a large size, which remain for a long time without causing much discomfort. This is readily seen in the case of so-called eye-stones, flax-seeds and other objects which may have been put in the eye by some self-appointed helper from the laity; or particles of wheat husks, canary seed, corn, beads, etc., all of which I have removed from patients that were unsuspicious of their retention. Their symptoms were very slight compared to the excessive irritation caused by gritty particles on the cornea or inner surface of the upper lid. The lodgment of a foreign body in the conjunctiva lining the upper lid, especially that part of it covering the cornea, and on the upper portion of the cornea produces, on account of the winking, most painful symptoms.

Symptoms. We have all of us had the sensation of getting an appreciable particle on the eye or under the lids: The instant that the hard body is deposited upon the eye, the lacrimal branch of the fifth nerve is stimulated, the tears flow, and if the foreign body be free it is washed to the inner canthus where it will be often found unless it struck

with sufficient force to impact itself in the ocular tunics; this removal would nearly always occur except that the instant a person feels something fly into the eye, the inclination is to rub the part and thereby the particle is impacted into the cornea, or in the conjunctiva usually of the upper lid.

It may be deemed almost trivial to describe the symptoms of a foreign body in the eye with which we are all familiar from personal experience, most of us luckily with those of a slight nature. We can, however, well remember the sensation of burning pain, the copious flow of tears and more or less momentary blindness which accompanies the receipt of even a small particle of grit in the eye. The patient, involuntarily puts his hand, generally with his handkerchief, to his eye and rubs the upper lid over the cornea thereby, with the result above mentioned. The gush of tears in most cases washes away the intruder; to persons who know the procedure the upper lid is seized by its lashes, pulled down over the lower lid, the lashes of which may brush the foreign body away; in other cases, the end of a handkerchief may have been used, rolled into a cone and passed between the lids. If the foreign body abrades or sticks in the cornea, the symptoms continue and the patient is usually disabled from pursuing his vocation until the particle be removed; if in the conjunctival cul-de-sac, the intruder may remain for a long time. I have removed foreign bodies from this locality varying in size from the so-called eye-stones to bee stings, and of divers natures.

On account of the eye being constantly bathed in a current composed of the tears and its own secretions, which flows from above outwards, down and inwards, foreign bodies are usually carried over its surface, some becoming lodged in the cornea and others carried down to the tear passages toward the inner canthus, passing out of the eye upon the face, through or into the lacrimal passages, or lodging on the caruncle. The lacrimal puncta should always be carefully examined for fine hairs, such as cilia, hair clippings, grain beards or caterpillar hairs which may lodge therein.

Etiology. The manner in which small foreign bodies are carried to and impacted in the conjunctiva and cornea is as manifold as their characters. Suffice it to say that motes in the eye come from all manner of domestic and industrial occupations and under all kinds of circumstances.

Cinders, chaff, lint, insects, ashes, etc., are mostly met with in domestic injuries, while in industrial life the foreign bodies are particles of the objects being worked in or upon; particles of iron, copper and metals are rare in the average citizen, while stone is more common. Particles of oyster shell produce a peculiar ulceration of the conjunctiva and cornea according to Randolph[1] and others,

and I have seen several such cases in oyster shuckers. Hairs of caterpillars, spicules from the legs of grasshoppers, and bee-stings, produce the peculiar ophthalmia nodosa. Small shot has been found free in the conjunctival cul-de-sac after fowling-piece shot wounds.

Pieces of rye, wheat, buds of trees, rhizomes, pieces of leaves and, more common than all of these, hayseeds or husks may remain for a

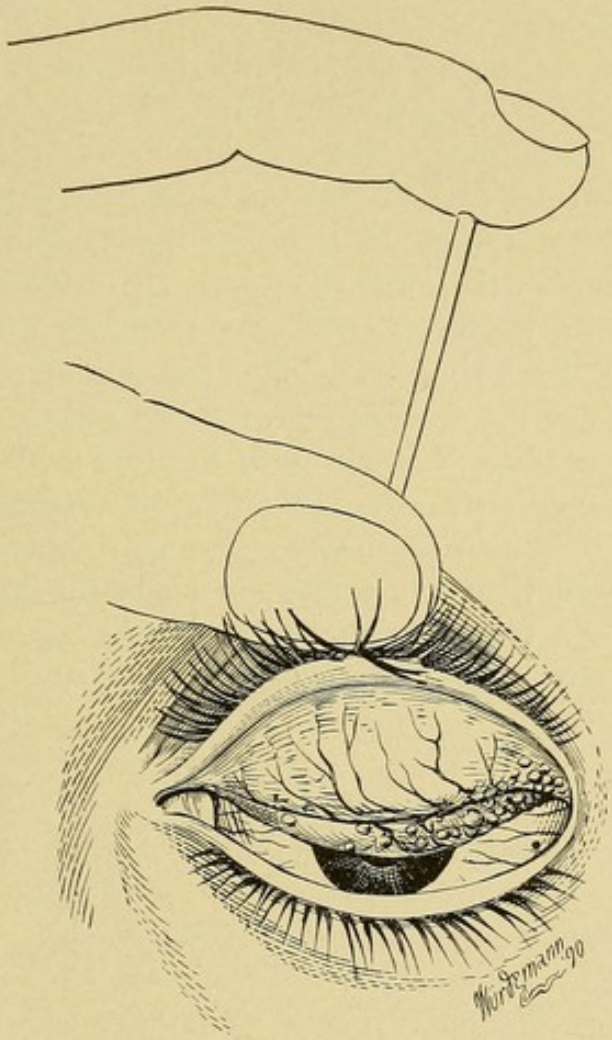

Fig. 170.
Fully exposing the retro-tarsal fold.

long time in this locality without causing much irritation. The husks and calyces of flowers or seeds may fly into the eye and stick on the cornea, and cling "tighter than a brother," for days; such foreign bodies, however, set up more or less ulceration, especially in the cornea. I have a number of times found foreign bodies deeply imbedded in the crater of ulcerations.

The d i a g n o s i s is simple and a careful examination will usually

reveal the presence of the intruder, but it must be remembered that the symptoms often persist for a time after its removal.

The prognosis is always good if the foreign body has not remained too long and severe inflammation and infection has not occurred.

Examination and therapy. To examine an eye which is suspected to have a foreign body on its surface or under its lids, the patient should sit in a chair with his face towards a window so that the eye may be well lighted, or he may sit away from the window or from the light and the surgeon may use his reflecting head mirror. The lower lid should first be turned down, next the cornea should be carefully looked over and then the upper lid should be everted, which may be done by the surgeon standing in front or behind the patient, seizing with his left fore-finger and thumb the lashes of the lid, pulling them slightly away from the globe at the same time pressing in the thumb of his left hand, a probe or small object, such as a toothpick or match stick, on the integument of the lid, pressing downwards and forwards so as to tilt the upper edge of the cartilage downwards and by this everting the lid; one finger of the hand is then made to press gently the tarsal edge of the lid against the upper part, to maintain it everted, and the patient looks down so as to expose as fully as possible the inner surface of the lid. A more thorough eversion may be made by pressing down the retro-tarsal fold by a blunt instrument, such as a glass rod or a cotton tipped probe, whereby all of the retro-tarsal fold may be seen, and the foreign body removed by forceps or a spud.

Foreign bodies too small or too transparent to be observed by the naked eye may be brushed away by a cotton brush and the eye washed out with weak boric acid or salt solution. Oblique illumination should always be made. It is often difficult to detect a fine piece of steel, emery, glass or any minute shining substance when impacted on the cornea. These may be better seen in a darkened room, examining the surface by oblique illumination and with the ophthalmoscope with + 15.00 to + 20.00 D. for magnification; foreign bodies on the cornea then appear as dark objects. If found or not, the eye should be rendered insensitive by the use of 5 per cent. cocain, or preferably 1 per cent. holocain solution, when it may be more readily examined. Since the advent of the local anesthetics, removal of a foreign body from the eye is a comparatively simple procedure to what it was twenty years ago when cocain was worth a dollar or more a grain and we could not afford to use it on anything of less importance than a cataract operation.

A large majority of cases of foreign bodies seen within a few moments, or within a few hours, after entrance, may be brushed away by using a hard-rolled, small, cotton pledget; in other cases I use a sharp-

ened toothpick or match stick; while in still others, particularly those of accidents occurring in trades where particles of stone, emery or metal have been driven with considerable force into the cornea, it is necessary to use instrumental means and to dig out the foreign body either with a sharp spud, the cutting needle or a gouge. Particles of coal, such as cinders, and pieces of vegetable matter, rarely need instrumental means for their removal.

Cases of this character are of daily occurrence in special office or dispensary practice. No matter how trivial they may seem, there is solution of continuity whereby pathogenic germs may gain entrance and cause ulceration and other inflammatory disturbances, which may ultimately lead to injury of sight or even loss of the eyeball. It is, therefore, highly advisable in all cases not only to remove the foreign body but to wash out the eye with an antiseptic solution, and where the corneal epithelium has been in the least abraded to put on an occlusive bandage.

One of the most valuable methods to determine an abrasion of the cornea, and at the same time produce an opaque background whereby the foreign body may be thrown into relief and thereby more easily seen, is to instill a couple of drops of 2 per cent. fluorescein solution; this is a brownish liquid, the coloring matter of which rapidly penetrates the corneal tissue when abraded, staining the part a brilliant light green, but does not freely pass through the healthy epithelium.

A simple method of occluding the eye is to put a semilunar piece of adhesive plaster on the upper lid; this acts as a splint and keeps the eye closed, and may be used for trivial injuries. Many workmen, however, who have previously had foreign bodies in their eyes, will object to an eye bandage and many will not even tolerate the simple application of the lid splint. In other cases absorbent cotton may be put behind a pair of spectacles, or cotton and a bandage, etc., used. Where the injury is trivial, no further treatment is needed, as within twenty-four hours regeneration of the epithelium has usually occurred. Where the corneal epithelium has been wounded, it is advisable to put 5 per cent. iodoform ointment between the lids. It is seldom necessary to give the patient any eye drops as, if the lids are closed, the movements of the ball do not cause such irritation as otherwise. In few instances, where the pain remains severe, it may be advisable to give the patient 1 per cent. holocain solution, or if the eye be greatly congested adrenalin solution in from 1:10,000 to 1:1,000 with chloretone may be dropped into the eye or given the patient to use. The following prescriptions are of considerable benefit and may be used by the patient. In all cases explanation of the simple nature of the accident, but of the serious consequence that may follow infection, should be made.

℞

Holocain 0.30
Aquæ 30.0
M. D. S.—Two drops in eye every hour or two if very painful.

℞

Iodoformi pulv. 1.50
Petrolat. pur. 30.0
M. D. S.—Iodoform ointment 5 per cent.

℞

Sol. adrenalin ..... 3.0 to 10.0
Chloretone 0.06
Sod. bibor. 0.50
Sol. 3 per cent. sod. chlorid. ad. q. s. 30.0.
M. D. S.—Two drops in eyes every hour or two.

℞

Dionine ..... 3.0 to 1.50
Aq. vel petrolat..... 30.0

In a large majority of these trivial injuries it is unnecessary for the surgeon to see the patient again after removing the foreign body and cleansing the eye, as healing regeneration usually takes place promptly.

I have described, with considerable minuteness, in the foregoing, the simple effects of foreign bodies in the eyes. Under Cornea I give histories of a few cases which show their dangers even when the original injuries have been of the most trivial nature. The ordinary cases of foreign bodies in the eyes are of such common occurrence that it is not necessary to report such in detail and I therefore restrict the balance of my remarks to the description of cases more or less uncommon.

A man had a foreign body remain under the upper lid for months; while splitting wood during the winter had felt something fly into his eye. He consulted me two months afterward; I found a foreign body imbedded in the retrotarsal fold, covered over by granulations, which proved to be a piece of bark almost the size of a grain of corn; healing followed within a few days.

A man received a cinder in his eye and an eye-stone had been put in "to hunt up the foreign body, grab it and remove it"; but the eye-stone, which is a part of the anatomy of a crab, was lost and he came to me for its removal. This was found under the upper lid, being readily felt by

the fingers applied to the exterior surface. It was removed and no further treatment was necessary.

A woman had been in a dentist's chair several weeks before and had felt something strike her eye; had suffered from the usual symptoms of foreign body for a few hours, recurrence of which had taken place after several weeks, the eye remaining more or less irritable during that time. On everting the lid I found a piece of metallic gold about the size of an oat. Symptoms disappeared after its removal.

Croskey[3] had a man present himself at the clinic with a "sore eye." He had been chopping wood, in Russia, eight months before, when a fragment struck him in the eye. He came to America by way of Germany and passed the inspections of both countries. The eye gave him little trouble. On everting the lid a piece of wood 18x6x3 mm., weighing dry, 1½ grains, was found under the retrotarsal fold and removed. The entire upper lid was granular and the upper-inner quadrant of the cornea hazy. An astringent wash relieved the traumatic conjunctivitis.

LITERATURE.

1. Randolph, *Trans. Sec. Ophth. A. M. A.*, 188.
2. Wood and Woodruff, *Common Dis. of Eye.*
3. Croskey, *Ophth. Record,* Jan., 1898.

C. OPHTHALMIA NODOSA.

A special type is due to the entrance of the hairs of caterpillars, spines of insect legs, as from grasshoppers, and the stings of bees and wasps.

Etiology and mechanism. These objects produce both mechanical and chemical irritation. Under the microscope they are seen to have a series of barbs projecting in one direction so that on entering the flesh they tend to work inwards. When such an object gains entrance into the eye and becomes impacted in the conjunctiva, it produces, in the lightest forms, an edema of the lids and catarrh of the conjunctiva, and in the gravest forms, formation of nodules in the conjunctiva and in the iris, in the latter causing severe inflammation and loss of vision from irido-cyclitis.

The subjective symptoms are intense photophobia, pain and lacrimation.

The conjunctiva, most often that of the lids, show one or more hard, grain-like, yellowish swellings. When occurring in the ocular conjunctiva they may be movable upon the sclera. The clinical picture is that of a conjunctival tuberculosis. When they enter the iris fine, point-like elevations, or well-defined little grayish nodules with iritis, appear. Examination by the loupe will show fine hairs in the nodules of both the conjunctiva and iris. In severe cases many posterior synechiæ, and seclusion

or occlusion of the pupil, may occur. The cornea may become diseased by ulceration and be followed by leucoma.

The course is four to six months. In one case, reported by Krueger,[1] when the hairs became absorbed the resultant inflammation left corneal opacity and posterior synechiæ. In a few cases more grave damage, as atrophy of the globe, reported by Krueger, and panophthalmitis, by Schoen[2] ensued.

The diagnosis is substantiated in vivo: by finding with aid of the magnifier, the hairs in situ in the nodules. As a rule the history starts with the entrance of caterpillar hairs or other parts of insects into the eye. The differential diagnosis between ocular tuberculosis and nodosa as given by Hanke,[3] is that the nodes in ophthalmia nodosa, in contra-distinction to those of tuberculosis, are hard and never caseate, but may be spontaneously absorbed, which never happens in tuberculosis.

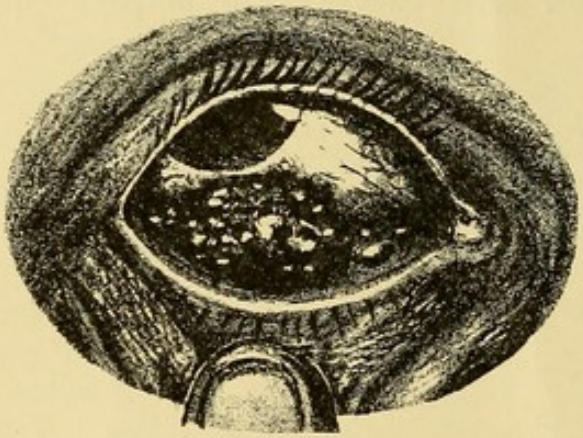

Fig. 171.
Ophthalmia nodosa from bee sting.

The prognosis is good in light cases where only a portion of the conjunctiva is affected and the iris escapes. Where the iris becomes affected the prognosis is always in doubt, as there is great danger of blindness from irido-cyclitis.

Therapy. The whole of the swelling should be excised from the conjunctiva or cornea by scissors, currette and forceps, the nodules from the iris by iridectomy. Atropin and hot compresses are likewise indicated.

I have never seen a caterpillar case, as they are very rare in America, so append one from recent literature. Beweren[4] reports an instance in which there was violent conjunctivitis with irido-cyclitis, developing within a few hours after contact of eye with a crushed caterpillar; seen three days later, when a pea-sized vesicle at lower-inner border of the conjunctiva was seen, with swelling and redness of lids, moderate conjunctival chemosis. No conjunctival discharge; iris greenish and

sluggish; pain and photophobia. Symptoms disappeared 15 days later under "appropriate treatment."

Bayer's[5] case: A black caterpillar, with some hay, was thrown into the eye; great pain immediately followed, remaining some days and eye was red. Examined some days later, when cornea was found cloudy;

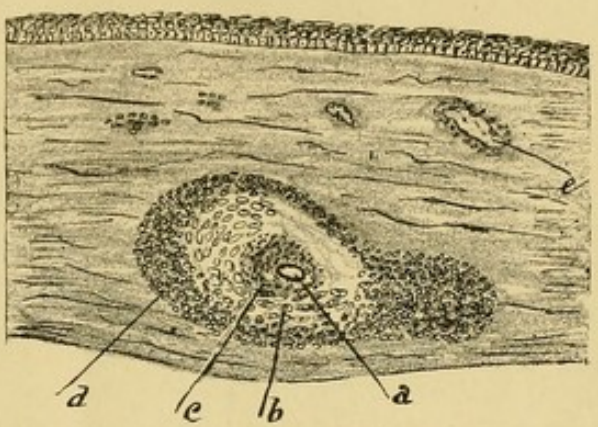

Fig. 172.
Section of conjunctiva in ophthalmia nodosa. (Hanke.) a—section of caterpillar hair. b-c-d—cellular proliferation.

three yellowish-white nodules on cornea about size of pin head; also several on periphery of iris; iritis. Treated with atropin and blood-letting; inflammation subsided after a long time; after the cornea cleared up and in a yellowish spot on the cornea the caterpillar hair was found. This case is rare in that deeper parts of the eye were apparently quickly af-

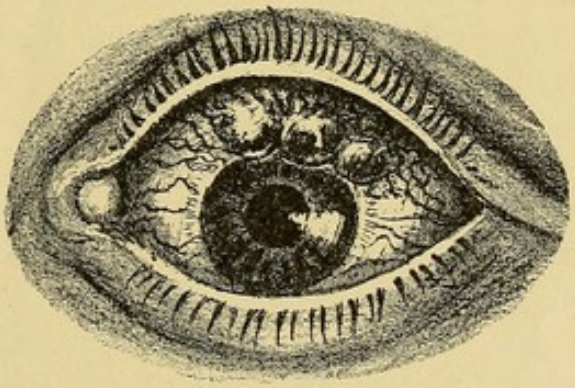

Fig. 173.
Ophthalmia nodosa from grasshopper leg.

fected. As a rule the disease has its seat in the superficial layers of the anterior parts of the eye, and only after a considerable length of time does it pass into the deeper structures, following the course of the hair which works its way (wanders) into the deeper parts of the eye.

A man[6] had been hiving bees in the fall of the year and came to me in the later winter with a peculiar, tumor-like ulcerating swelling of the

fornix of the lower lid. Examination with a magnifying glass showed a small dark object in the center which was pulled out by forceps and examined under a microscope by a low power, which showed it to be a portion of a bee sting. This patient had been treated for several months by eye drops and applications of different remedies by a number of physicians in the country. The disease healed within a few days after removal of the bee sting.

A child was brought to me[6] with a nodular swelling very like episcleritis over the superior rectus muscle. Six months before a grasshopper had flown into the eye and it had been sore since. She had been treated all this time for "granulated lids!" The conjunctiva being snipped a double-jointed, hairy substance was found. Uninterrupted recovery took place.

1. Krueger, (a) *Arch. f. Aug.*, XXIV, 2, p. 147. (b) *ibid*, XXV, 3, p. 357.
2. Schoen, ref. Praun, l. c. p. 257.
3. Hanke, *Beitr. z. Aug.*, XXIII, 1896.
4. Beweren, *La Clin. Opht.*, Dec. 25, 1901.
5. Bayer, *Münch. Med. Woch.*, No. 21, 1900.
6. Würdemann, *Ophth. Record*, Feb., 1905.

D. INJURIES BY BLUNT OBJECTS.

Bruising of the conjunctiva.

Bruising occurs with most wounds, but as a rule is not extensive on account of the great elasticity and movability of the membrane.

a. Conjunctival ecchymosis.

Effusion or blood beneath the ocular conjunctiva is characterized by a patch or deep-red ring more or less surrounding the cornea or occupying the whole of the conjunctiva, which gives to the eye an alarming appearance, although it is not in itself a dangerous occurrence, but may be significant of arterio-sclerosis or following serious injury to the skull. The ecchymosis may be of such extent as to form a blood tumor or hematoma under the conjunctiva, particularly on the inter-tarsal folds, when it extrudes from the eye in a large mass.

Etiology. Operations involving the ocular conjunctiva, blows, lifting heavy weights, vomiting (particularly the strain from the vomiting of whooping cough), cohabitation, the effect of wind on the eyes in bicycling, automobiling, or engine riding, fracture of the orbit and base of the skull.

The predisposing causes are degenerative conditions of the blood vessels, arterio-sclerosis, Bright's disease, diabetes, scurvy, etc.

Course. As with suggulation of the lids (or ordinary black-eye) the absorption is slow, occupying two or three weeks.

The blood usually gravitates to the lower part and in the case of

hematoma makes a decided swelling in the lower fornix. The blood is usually resorbed in two or three weeks and changes in color from red to brown and greenish-yellow.

Therapy. Immediately after the accident ice compresses may hinder further extravasation of blood, afterwards hot compresses and

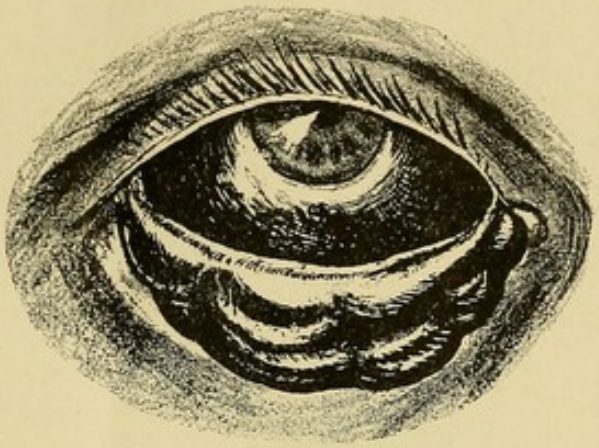

Fig. 174.
Hematoma of lower lid and conjunctiva.

5-10 per cent. dionine solution will hasten its absorption. Lead water and opium applications are of benefit.

Noteworthy cases as follows have been seen by me:

In nearly all cases of operations necessitating incision through the conjunctiva, particularly in squint operations and in nearly all contu-

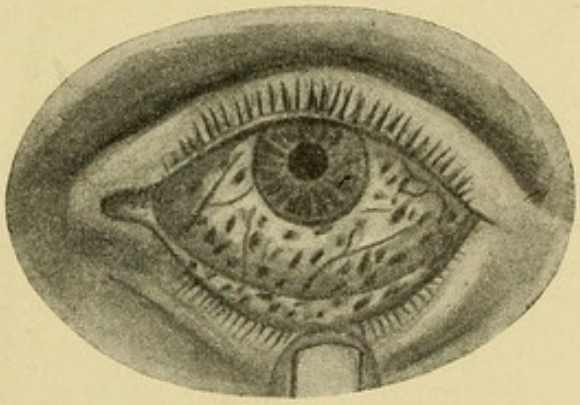

Fig. 175.
H. McI. Morton's case of hemorrhage into the conjunctiva following nitrous oxide.

sions of the lids or region about the eye causing ordinary black eye; in a number of instances of newly-married persons or following a debauch, in practically all cases of fracture of the anterior fossa walls of the cranium. (see Fractures).

One particular instance of a hematoma of the conjunctiva occurred

in a man who had fallen, striking the bridge of his nose and evidently breaking the ethmoid, which was followed by a hematoma of the lower lid and lower conjunctival fornix so prominent and painful that incisions thereon were necessitated. Hot applications for a number of days after-

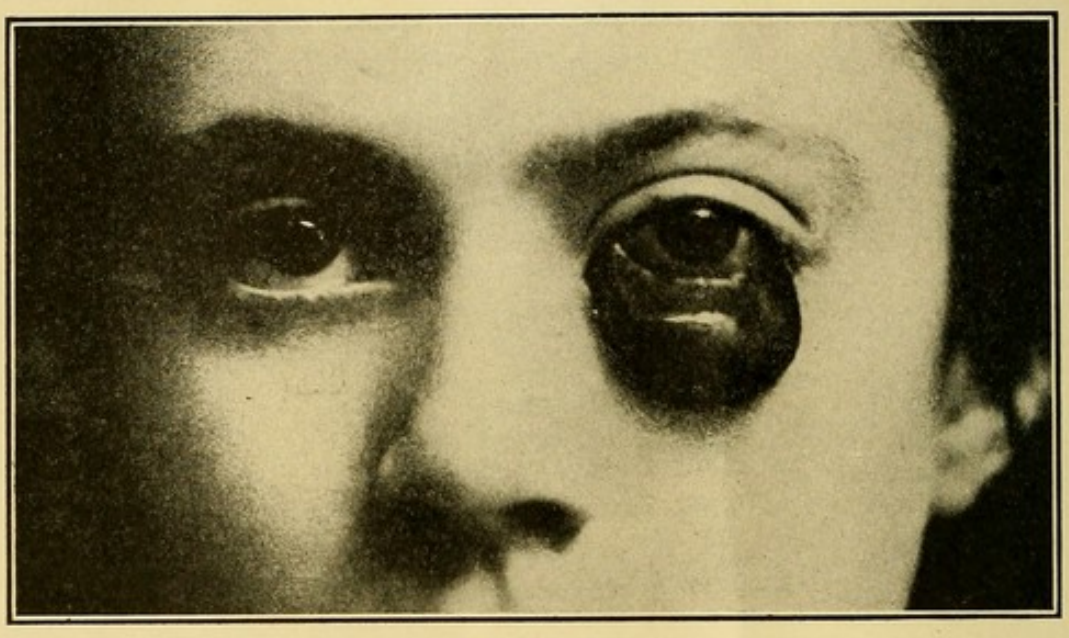

Fig. 176.
Edema of conjunctiva. (Becker.)

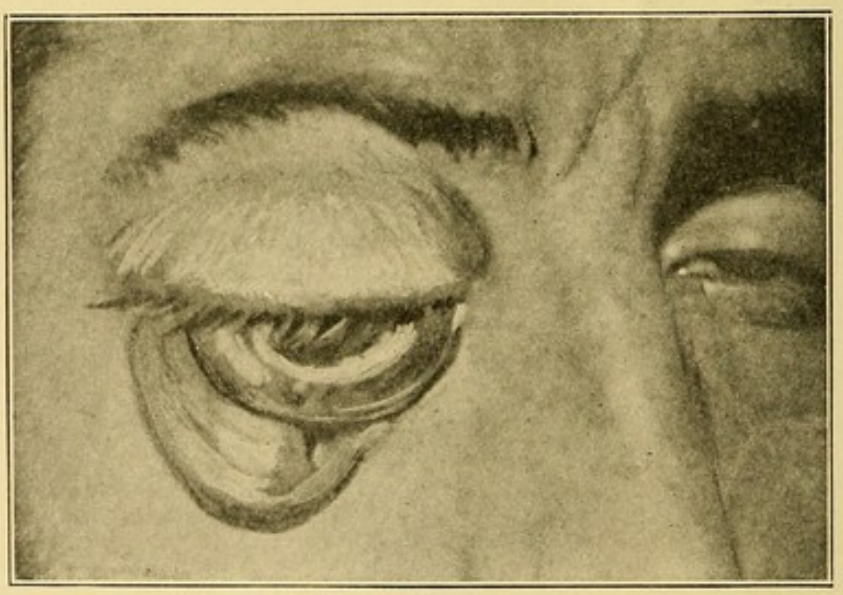

Fig. 177.
Chemosis of conjunctiva and lids following infected wound of the globe.

wards removed the swelling, but the blood stain resulting remained for months.

H. McI. Morton[1] reports many punctate hemorrhages into the bulbar and palpebral conjunctiva following the administration of

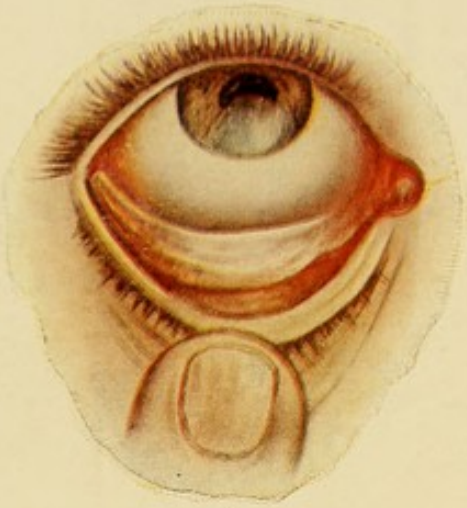

a

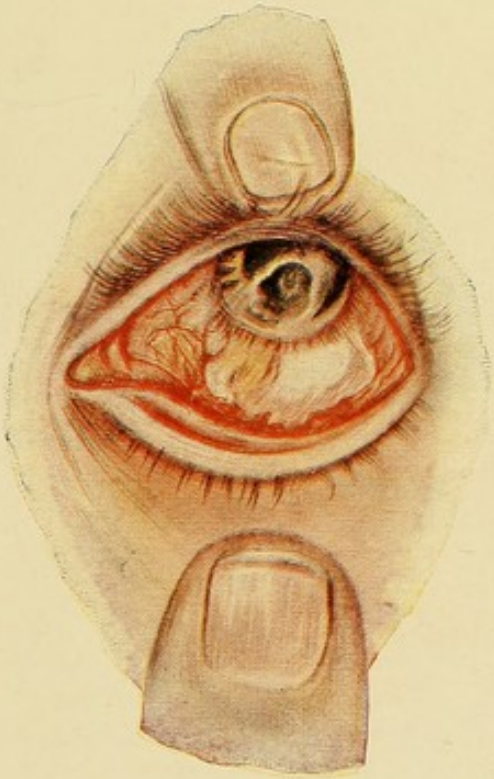

b

PLATE V

A. Recent lime-burn of the conjunctiva and cornea.—(Haab)

B. Lime-burn of the conjunctiva and cornea, of longer standing.—(Haab)

nitrous oxide gas, which the patient had taken preliminary to the removal of a tooth. This was accompanied by itching of the skin and marked redness of the left breast and neck. Morton explains the case by increased capillary pressure and alterations in the blood due to the nitrous oxide.

E. PIGMENTATION OF THE CONJUNCTIVA.

a. Blue stains of the conjunctiva from methyl violet ink or blue pencil have been reported in a number of instances. If the cornea be not affected thereby, causing chemical cauterization, the stain remains for a few days and then disappears. (See Chemical Cauterizations).

Braav[2] gives the history of an instance of this sort in which the conjunctiva of the lower lid as well as the bulbar conjunctiva up to the lower sclero-corneal margin, was of a dark purple color. This change in ' color had been produced by injury of the conjunctiva with a piece of the lead of an indelible pencil, the pigment having been spread by rubbing with the finger. The discoloration disappeared completely in eight hours, nothing having been applied except an alkaline wash.

Kauffmann[3] had a case in which the patient received the contents of a bottle of hectographic ink in the face. The fluid entered the eyes, nose and mouth, staining all these tissues. The lids were but little affected, but the cornea, tarsal and bulbar conjunctiva were uniformly dyed. The surface of the cornea was shagreened, and to the depth of the middle layer was of a deep blue. The eyes were bandaged with a boric acid ointment compress. After a few days the coloring had disappeared from the cornea and conjunctiva, but the epithelium of the cornea began to shed until Bowman's membrane was entirely exposed. Three weeks elapsed before the eyes were again free from irritation.

b. Siderosis of the conjunctiva is a yellowish pigmentation due to long-continued internal use of the sulphate of iron, or to the retention of impacted iron particles or scales in the conjunctiva. I have noted the latter in a number of instances of iron workers.

c. Blood pigment may stain the conjunctiva for a long time as the result of injuries. A number of diseases, such as jaundice or gout, may cause changes in the conjunctiva, but are hardly to be classed under the name of injuries.

Extensive tattooing from powder explosions often results from careless handling of fireworks, firearms and explosives.

Argyrosis. Nitrate of silver, argyrol, protargol, or other preparations of silver applied for a long time, particularly if given into the

hands of the patient for home treatment, may cause a dirty, permanent, gray, slate color, or brownish discoloration of the conjunctiva. The discoloration is permanent, but I have found that a 2 per cent. to 5 per cent. solution of hyposulphate of soda, used for a long time, materially cleared the discoloration. Cases of this sort are seen by every oculist.

Hirschberg[5] reports a case of argyrosis of the white of the eye and the skin. Both eyes of a silver polisher, aged 59, who, for 29 years polished on a revolving disc silver-plated objects with iron oxide, showed below the cornea a bluish, dark-gray discoloration of the white of the eye, more so to the left, because it was more exposed to the disc. Four mm. wide, it extended downward from the lower corneal margin, forming a process towards the temporal angle where it spread into single lines, while towards the nose a blackish, somewhat interrupted, line surrounded the plica. The whole face looked somewhat grayish-violet. The hair, which originally had been blond and then gray, was yellowish-red. After thorough washing it turned white at the occiput, but remained reddish on the vertex.

Undoubtedly the affection was due to the local action of silver dust which was thrown for years against the eye with quite a force. The discoloration of the skin might have been due to a general argyrosis from the introduction of silver dust through the mouth and nose.

LITERATURE.

1. H. McI. Morton, *Ophth. Record,* Feb., 1899.
2. Braav, *N. Y. Med. Journ.,* Jan. 2, 1909.
3. Kauffmann, *Ophth. Klinik,* No. 6, 1904.
4. Becker, *Ophthalmology,* Oct., 1910.
5. Hirschberg, *Centralbl. f. prak.,* Aug., 1909, p. 71.

F. BURNS AND CAUTERIZATIONS.

Burns and cauterizations of the conjunctiva are dealt with quite fully in connection with the general subject of burns and cauterizations. They occur in all grades from the burn of sun-blindness and that of electric light, to extensive destruction of tissue from chemicals and burning iron, and usually involve the lids and cornea as well.

People who work in excessive heat or light, as firemen, glass-blowers, and electric arc workers are subject to an irritative chronic conjunctivitis caused by thermal injuries.

In simple burns of the conjunctiva the burned or cauterized area appears as a grayish-white plaque; if from lime, white from the lime contained in the tissue. The edges of the burn are reddened. There is lacrimation, photophobia, and smarting pain. The wounds granulate, being replaced by scar tissue, which, however, in this situation is difficult to distinguish from conjunctiva. Shrinking of the conjunctiva may occur

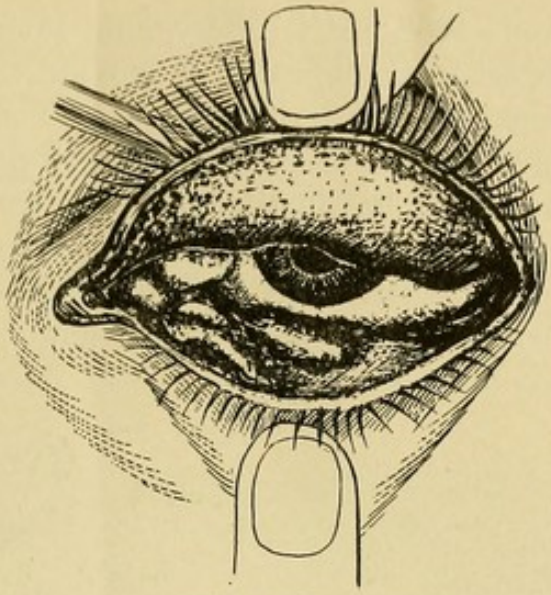

Fig. 178.
Extensive burn of conjunctiva of lids from hot fluid jelly in eye.

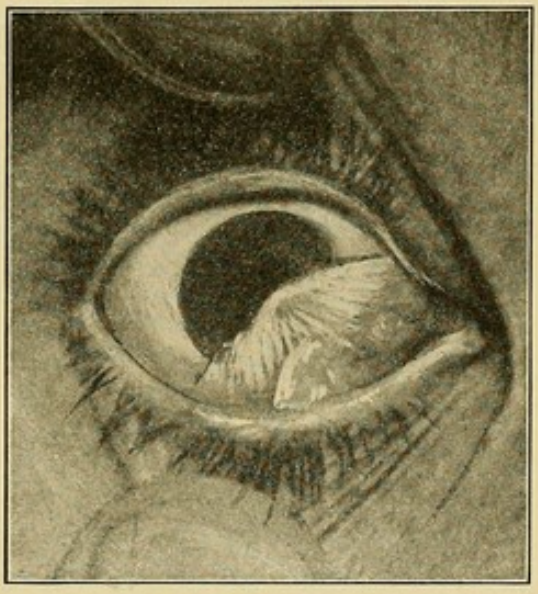

Fig. 179.
Traumatic pterygium following lime injury.

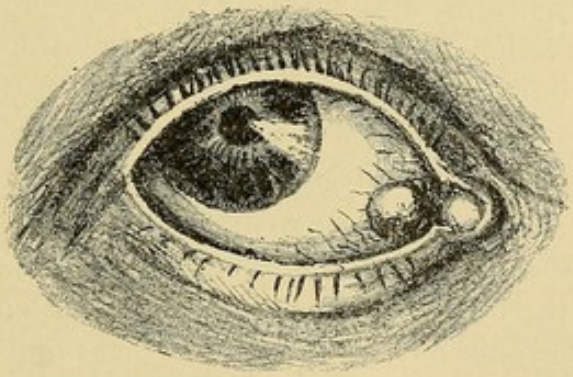

Fig. 180.
Polyp of conjunctiva following injury.

except where it results in cicatricial pterygium. Immediate treatment is by a bland antiseptic analgesic ointment, as iodoform 5 per cent, dionin 5 per cent. and iced compresses.

The great danger is from cicatricial union of the lids to the globe, symblepharon, which is to be guarded against, freely separating the lids by daily probing, conjunctival plastics, use of egg film, etc., to keep the two surfaces apart. When severe the shrinking may cause entropion, trichiasis, lagophthalmus, pterygium, symblepharon, ankyloblepharon, shrinking, etc., which must be dealt with by subsequent operations.

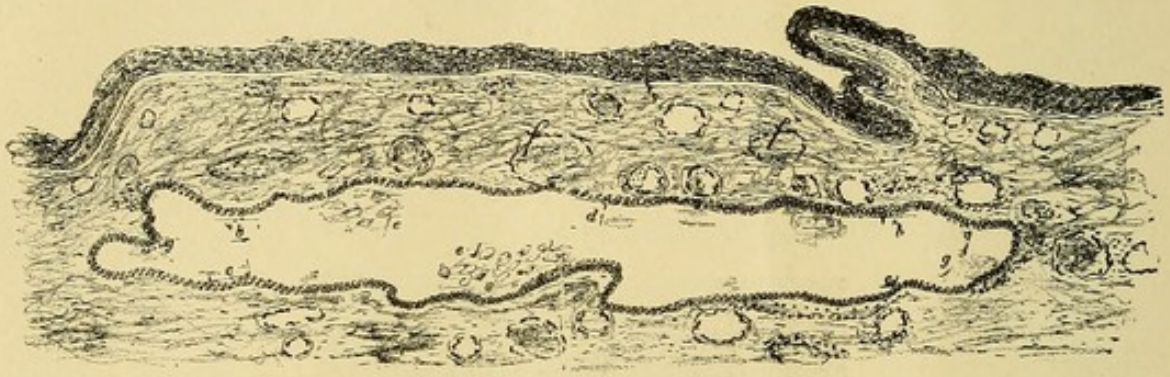

Fig. 181.
Cyst of conjunctiva.

Excessive cicatricial formation from treatment of trachoma by cauteries, as nitrate of silver and sulphate of copper, has often been observed.

G. TUMOR FORMATION.

Polypus of the conjunctiva is the main tumor formation and is apt to result from wounds or injuries that do not heal from first intention. Granulation tissue proliferates and forms polypus, which should be removed by forceps and scissors. No authentic case of sarcoma of the conjunctiva has yet been ascribed to trauma.

One case of epithelioma of the conjunctiva after trauma has been reported by Chapman,[1] and cysts of the conjunctiva by Uhthoff,[2] and Praun[3] likewise reports a cilium imbedded in the conjunctiva causing a cyst. I have seen many cases of polypi of the conjunctiva after burns, and even after operations, as the older forms of advancement. Removal by the scissors has cured all of these.

An odd case of accidental recovery of vision in blindness in a case of epithelioma of the conjunctiva is reported by Dujardin.[4] In a case of epithelioma of the bulbar conjunctiva where the entire anterior aspect of the globe had become buried in a tumor mass and vision with the eye rendered impossible, the sight was accidentally restored by the patient being struck in the affected eye by the branch of a tree, which caused

profuse bleeding from the growth and tore part of it away from its position in front of the cornea. The author says that the case bears out Valude's[5] statement, that limbus epithelioma tends to remain extraocular and almost never perforates the capsule of the eye. Practically it teaches that in similar cases the condition of the cornea should be examined into by exposing the central portion of this membrane, thereby in some cases avoiding the sacrifice of the eye.

1. Chapman, *Arch. f. Aug.*, IV, 1, p. 197.
2. Uhthoff, 506.
3. Praun, l. c. p. 506.
4. Dujardin, *Ophth. Klinik*, Sept. 20, 1907.
5. Valude, ref. Dujardin.

H. INJURIES FROM FIREARMS.

Injuries from firearms isolated to the conjunctiva are seldom seen In one case I extracted a shot pellet from the fornix, and several such have been reported in the literature, though always accompanied by other injuries to the eye.

The impaction of powder grains in and under the conjunctiva, however, is comparatively often seen, either as the result of powder and firework explosions, and from imperfect breech or backfires in guns. These powder grains are not to be picked out. It is necessary here to remove a small piece of the conjunctiva and subconjunctival tissue, together with the powder stain or grain, with or without a subsequent suture.

II. OPERATIONS WITH THE CONJUNCTIVA.

The conjunctiva is essential for certain conservative operations and especially for repair or protection of wounds and other injuries of the

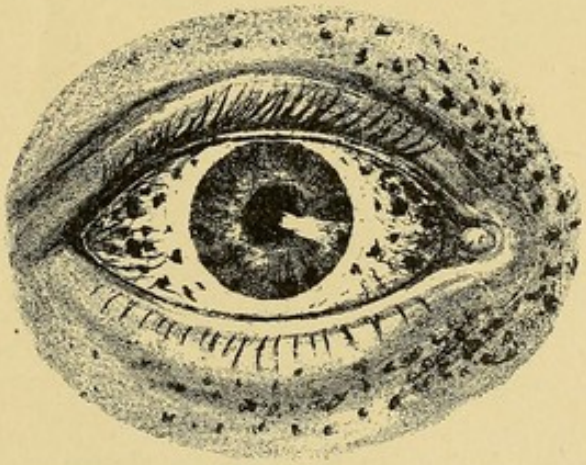

Fig. 182.
Pigmentation of conjunctiva and lids from powder burn.

cornea. (1) Plastic operations with the conjunctiva are applicable for all defects in the cornea and sclera, which may be rapidly and successfully

covered by kerato-plastic and sclero-plastic operations. (2) Protection against prolapses of the ocular contents, especially after excision of iris prolapse and staphyloma. (3) As a temporary or transitory shield after trauma from operation.

Schöler,[1] in 1877, first recommended the use of conjunctival flaps used as grafts, for keratoplasty and the protection of corneal wounds. Kuhnt,[2] since 1883, has been foremost in the exposition of its use for this purpose. Meyer,[3] Snellen,[4] de Wecker,[5] Bourgeois,[6] Antonelli,[7] Weiss,[8] Norman-Hansen,[9] Suker,[10] Byers,[11] and many others have given their experience and advocated this means of protecting and healing the cornea.

Conjunctival plastics for defects of the cornea.

Keratoplasty is best accomplished by the use of the conjunctiva, espe-

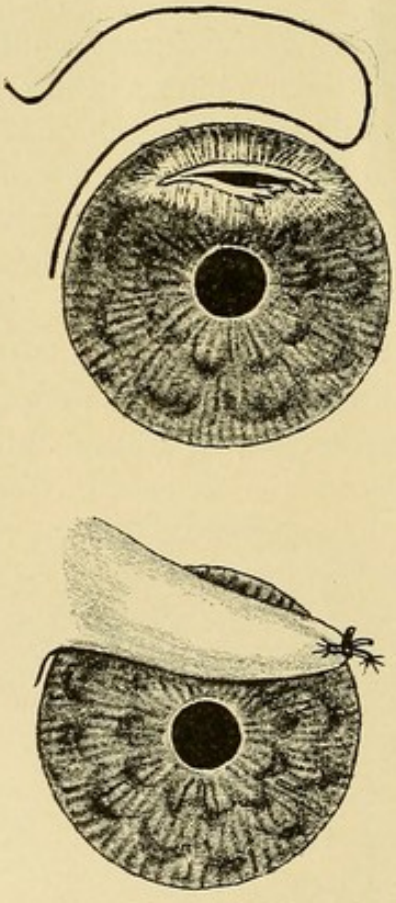

Figs. 183-184.
Kuhnt single pedunculated flap.

cially in non-infected ulcerations which, when covered by conjunctival flaps, tend to rapidly heal and are not apt to be followed by perforation of the cornea.

After thorough currettement and antiseptic chemical or electro-cauterization, the defect is covered over by a single or double pedunculated conjunctival flap.

The single pedunculated flap is made by dissecting the sclero-corneal conjunctival limbus about one-third around. Then the apex of the flap is cut broadly about 1 cm. wide and a cut made parallel upwards, forming a flap which is then laid carefully over the corneal defect, with or without suture, and a pressure bandage put over both eyes,

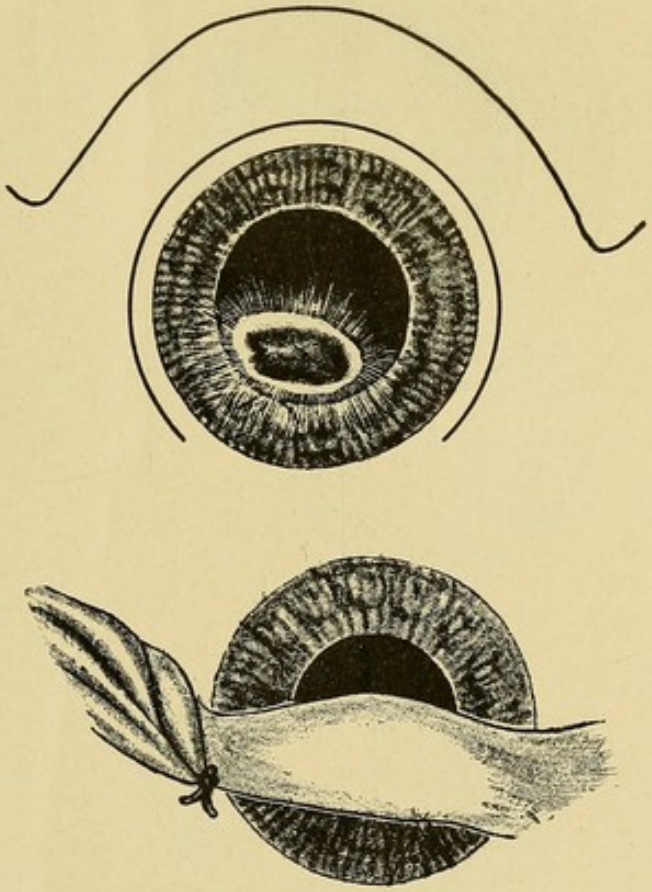

Figs. 185-186.
Kuhnt bi-pedunculated flap.

remaining on two to four days. The pain disappears in two to five hours. If the first dressing be made in twenty-four hours the flap looks like a diphtheritic membrane, on the fifth day becoming intensely red, and in eight to ten days atrophying so that it appears as a diaphanous, thin membrane over the cornea, which speedily disappears, leaving the ulcerated surface healed.

With a double pedunclc the limbus incision is curved about two-thirds of the way around the cornea and the flap brought straight over the corneal defect, the flap being as a rule attached to the limbus. In

every case the raw surface left from the conjunctivo-plasty is permitted to heal spontaneously, which occurs by encroachment of the conjunctiva upon the surface, which covers the surface in about three days.

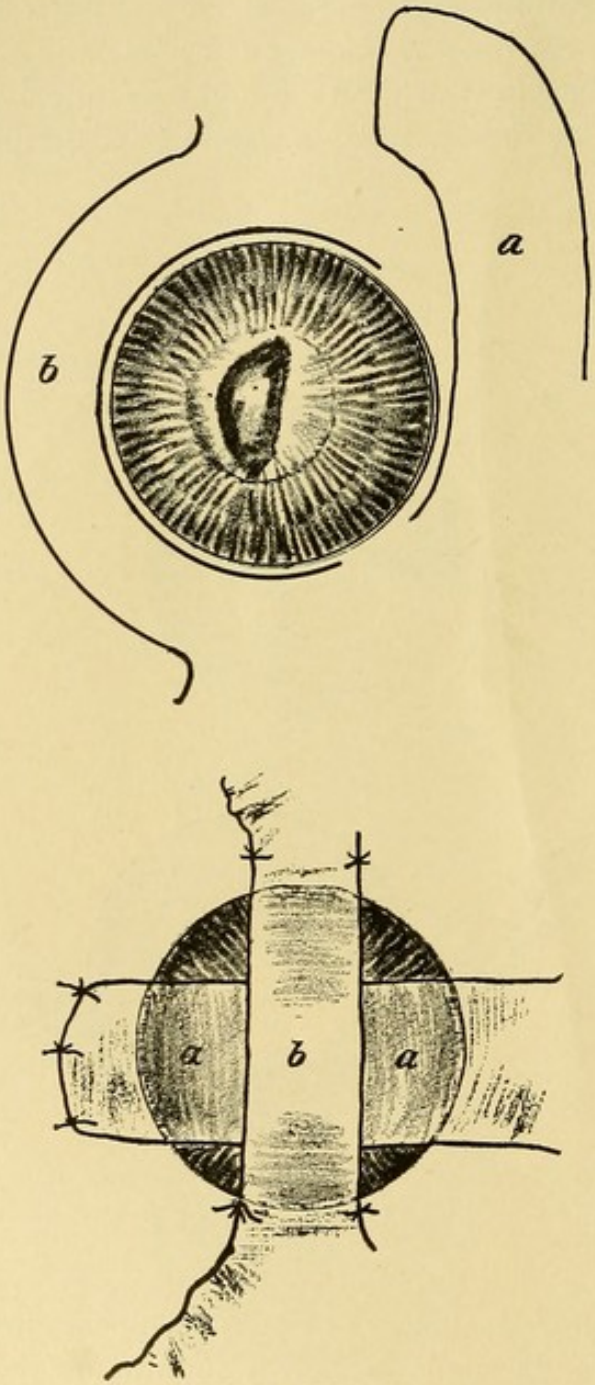

Figs. 187-188.
Kuhnt double conjunctival flaps.

Two flaps may be used for central defects, one with a single peduncle and the other two with bases, as shown in figure, forming a cross over the cornea. These are secured by stitches, which are cut in five to seven days, when the flaps retract to their former

places and heal thereon, or they may be held together in the center by a stitch, the under flap serving for a keratoplasty and the other for a flap.

Conjunctival implantation without flaps has been tried by Kuhnt[2c] and others, but is not as much practised as the method with pedunculated bases. The implantation of conjunctiva, the membrane from the frog's tongue, the vitelline membrane from new-laid eggs, and the mucous membrane from the lip have been used with success by the author in a number of instances for conjunctival defects. The filling in of a large conjunctival defect by Thiersch grafts taken from the skin over the mastoid has been used by many operators with satisfaction.

1. For the healing of ulcers Kuhnt has given this method an extensive trial, having used it 109 times in deep single ulcers, 67 times in perforating ulcers, 7 ulcers of scrofulous nature, 12 staphylo-

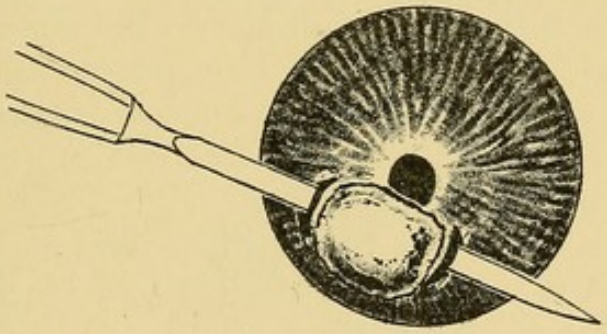

Fig. 189.
Abscission cystoid cicatrix.

coccus and streptococcus ulcers, 5 abscesses of the cornea, and 237 ulcus serpens.

For the covering over of prolapses, fistulæ, and keratocele this method eliminates the danger of intra-ocular infection and prevents ectasiæ.

2. Old prolapses of the iris. It is well known that an infection of the globe resulting in loss of sight, or even of the organ, may occur as early as eight to fourteen days after an iris prolapse, and by secondary infection at any time during the life of the patient.

Kuhnt states that these are best abscised and covered by a conjunctival flap, and that he secured 46 good results in 49 cases, in none of which did evil results follow, and in but three of which did iris prolapse recur.

The operation is conducted by passing a narrow Graefe knife through and under the projection, cutting through the cystoid cicatrix on one side,

then abscising the flap by forceps and scissors or by using the Beer's knife for the same purpose. The true iris tissue is not to be drawn out, but the irido-corneal projection smoothed off on a level with the cornea. Then a keratoplasty is formed by laying over this opening a conjunctival flap as before described.

The author has often performed this operation with success. The reaction is not great. The after-treatment is atropin 1 per cent. in order to secure dilatation of the pupil; argyrol 50 per cent.; oxycyanide of mercury 1:1000 or the White salve 1:3000; or bichloride of mercury for antiseptic purposes. A binocular bandage is then applied and allowed to remain in place four or five days without changing; on the fourth or fifth day healing is found to have occurred, being completed on the twelfth day, when the conjunctival flap withers away.

When the iris prolapse is fresh the conjunctival flap method is used as a protective dressing rather than as a keratoplasty.

(2) Fistula of the cornea. The danger to the lens of opacification, to the iris of prolapse, and to the globe of infection or atrophy and phthisis bulbi from a fistula of the cornea may be obviated by freshening the edges of the ulcer and a double pedunculated keratoplasty done by the conjunctival flap method. Healing and permanent closure occurs in twelve to fourteen days.

(d) Keratocele is to be treated by puncture with the point of a knife, excision by forceps and scissors, and a double pedunculated flap. Healing results in ten to twelve days.

(e) Kuhnt[2c] recommends the operation for incipient staphyloma of the cornea, excising by the corneal trephine or burning the protruding scar tissue with the galvano cautery and then laying over it a conjunctival flap.

B. USE OF THE CONJUNCTIVA IN OCULAR INJURIES.

Covering gaping wounds of the sclera and cornea by means of conjunctival flaps is essential to proper healing. The use of a sclero-conjunctival flap for all operations for cataract or upon the iris is advised by many authorities, and such is my personal preference. Prevention of infection is thus secured by immediate closure of the wound and is essential where a chronic conjunctivitis or lacrimal suppuration has been present, even when the corneal wound is superficial. In penetrating wounds of the sclera after careful exploration and removal of impacted and extruded uvea, and snipping off the protruding vitreous, the sclera may be stitched by one or two interrupted sutures of catgut, and then a conjunctival flap pulled down over the wound so that the cut sclera and cut conjunctiva be not in apposition.

In penetrating corneal wounds the procedure is more difficult, the character of the conjunctival flaps varying from single and double pedunculated or double flaps as above described, to the dissection of a large part or all of the conjunctiva at the limbus and connection of its cut edges by three or four interrupted stitches or a pouch-suture pulled tightly to completely cover the cornea.

This use of the ocular conjunctiva is for protection rather than for keratoplasty. About five days after the corneal wound has sufficiently

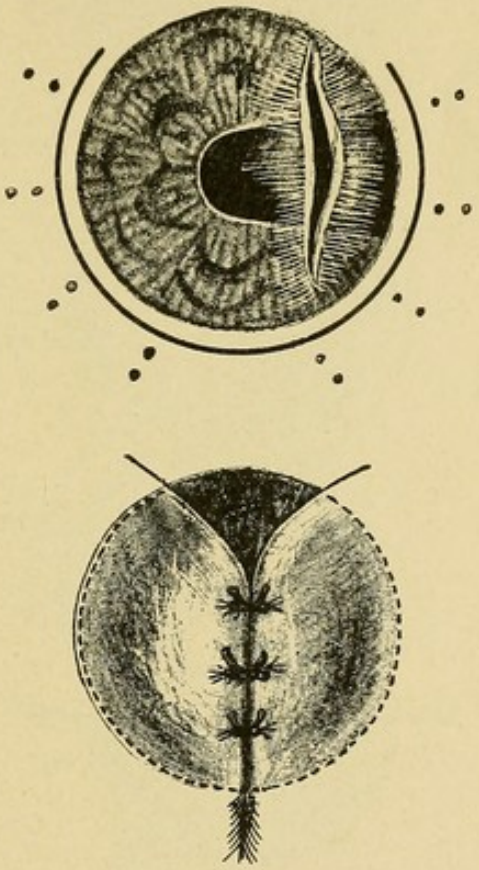

Figs. 190-191.

DeWecker partial temporary covering of corneal wound by conjunctiva.

coapted the sutures may be cut and the conjunctiva allowed to retract to place at the limbus, where it heals, and in a couple of weeks no trace shows of its ever having been divided.

In complicated wounds of the anterior segment the prolapsed iris should be abscised and if the lens capsule be injured and the body of the lens be broken up the lens substance should be released and a careful toilet of the wound made.

In complicated wounds of the sclera the protruding uvea and vitreous must be cut off and the wound cleared of débris before the sclera is sutured.

In operative procedures, especially cataract, Kuhnt first

dissects and loosens a bridge of conjunctiva above the cornea, then performs a corneal incision, completes the delivery of the lens, brings down the conjunctiva over the wound and sutures it by two interrupted stitches at the limbus. The same operation may be made to cover the wound after iridectomy.

Many operators, among them the author, are accustomed to leave a small conjunctival flap at the upper edge of the corneal incision in their cataract and iridectomy operations. This flap becomes immediately applied to the under surface and insures rapid regeneration of the

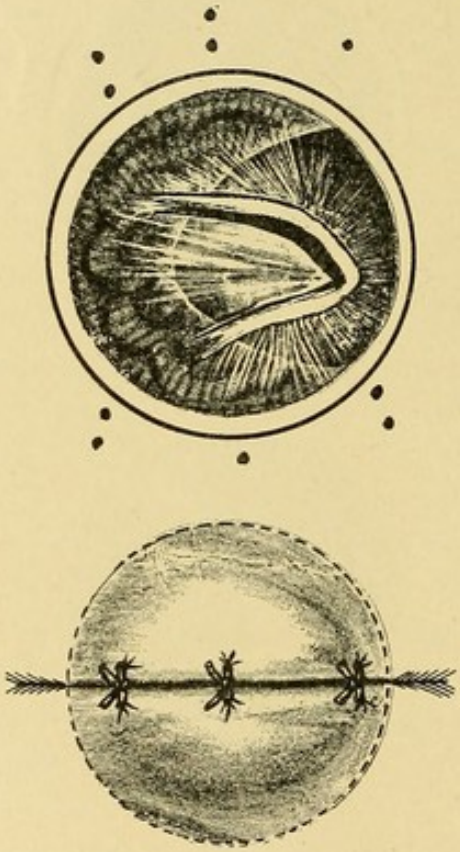

Figs. 192-193.
DeWecker total temporary covering of corneal wound by conjunctiva.

anterior chamber. If loss of vitreous ensue a single interrupted suture may be passed through the flap to the upper part of the conjunctival wound and when tied closes the wound, preventing further prolapse of the ocular contents.

Maddox[12] gives the following modification of the conjunctival flap operation under: Lattice Suturing of the Conjunctiva, after Severe Injuries in the Ciliary Region. "The usual mode of covering wounds of the corneal limbus with conjunctiva is insufficient when a penetrating wound extends far into both the cornea and the sclera. In these cases, after thorough disinfection and removal of any prolapse, and

after also delicately touching any doubtfully aseptic tissue with a fine electro-cautery, I undermine a large flap of conjunctiva beyond the wound, and draw it upwards by means of a long silk suture passed alternately through the conjunctiva above the cornea and the margin of the

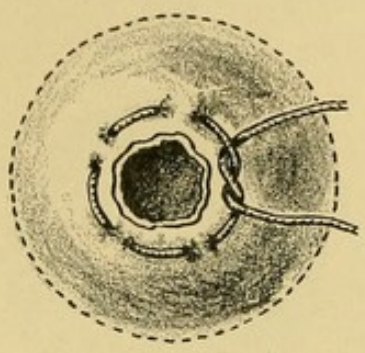

Fig. 194.
Conjunctival pouch suture for temporary covering of cornea.

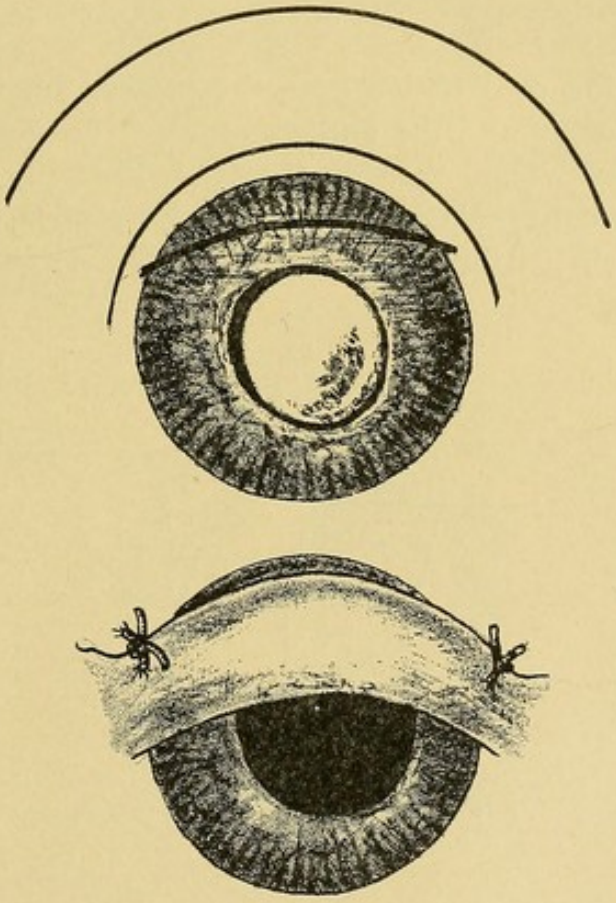

Figs. 195-196.
Kuhnt bi-pendulated flap for cataract extraction.

raised flap, several times. It is remarkable how the cornea tolerates the presence of the sutures and by the multiple strands the tension in each is so much lessened as to be inconsiderable.

The security is immensely greater than that afforded by the usual

plan of stitching up merely the two corners of the flap so as to avoid the cornea. * * * *"

"The direction of the sutures should of course be so planned as to make the best of the flap of conjunctiva. For example, if there be a deep

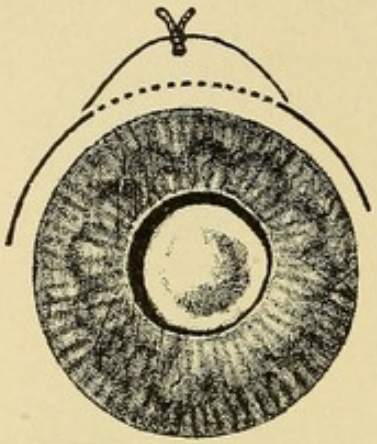

Fig. 197.
Conjunctival flap for cataract extraction.

cut or notch in the conjunctiva over the injury, the sutures should be made to run obliquely and the undermining of the conjunctiva be more on one side of the wound than on the other, that the conjunctival gap should not be radially coincident with the injury. The notch may, if necessary, be itself stitched up first. The silk sutures chosen should

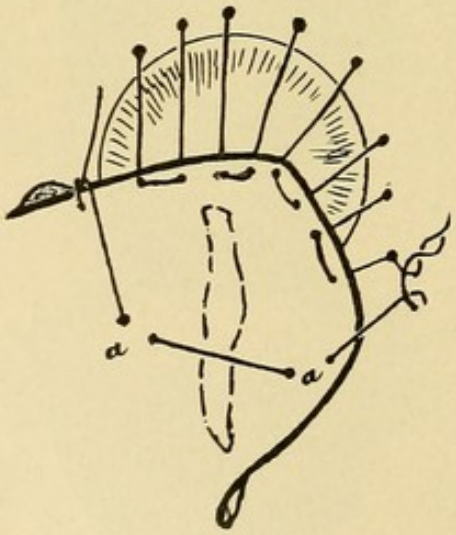

Fig. 198.
Maddox's lattice suturing of conjunctiva.

be soft and not too thin. The strand indicated in the diagram by 'a-a' supports the base of the flap and lessens the traction on its margins."

Koyle[13] describes the following operation for repair of a Descemetocele of the cornea. "After thorough local anesthesia, two incisions with a narrow bridge between them were made in the con-

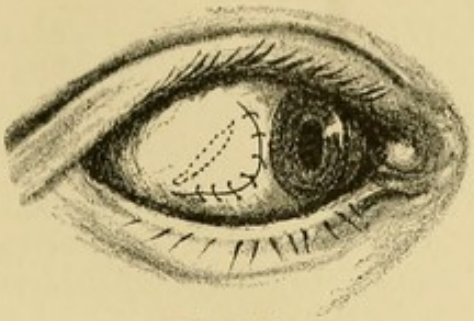

Fig. 199.
Conjunctival flap over scleral wound.

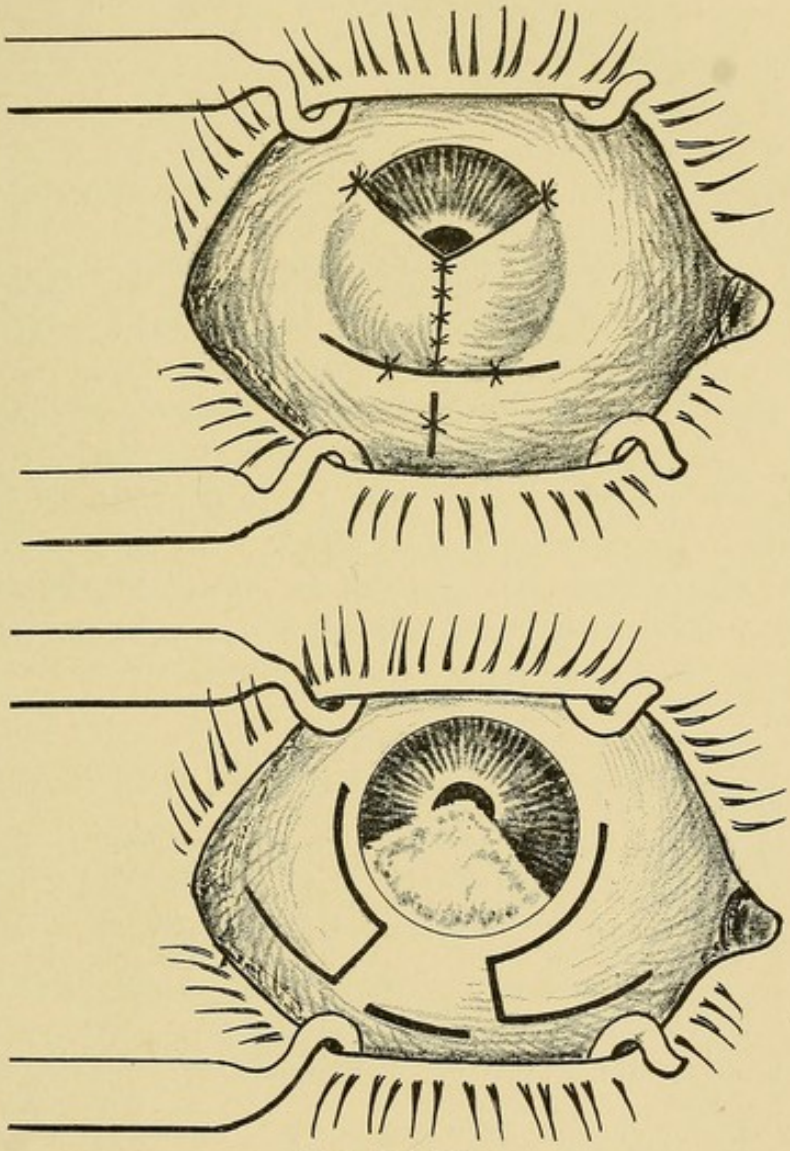

Figs. 200-201.
Koyle's modified Kuhnt keratoplasty.

junctiva about 1½ mm. from the recently repaired corneal margin and extending from below upward to a point a little above the horizontal diameter. The conjunctiva was then dissected back toward the equator to a distance of about 7 or 8 mm., but leaving a triangular portion un-

touched at the lowest point on each side. An elliptical incision was then made at the limit of the dissection, thus affording two long, broad flaps, which were then brought across transversely, trimmed and sutured. In making these flaps great care was taken to secure a proper degree of tension and a perfect approximation of their edges. A longitudinal incision was then made well below, and the conjunctiva above and below loosened. This newly made band was now stitched on either side to the conjunctiva left at the edge of the cornea, and the lower edge of the flaps tacked to the same narrow strip.

"The quadrilateral surface exposed by this procedure was then covered by passing a suture through the lateral angles and drawing them together, thus reversing the line of incision.

"Anchor sutures were then placed on each side of the cornea superiorly, lifting up the upper edge of each flap to a point well beyond the denuded portion of the cornea, care being used to prevent undue tension on the flaps above or below."

J. Edgar Deane[14] writes the editor the following under Double Suture of a Wounded Eye. "I have saved the eyeball where it had been slit open for at least an inch across the cornea and sclera by a flying piece of iron, accompanied with escape of all the aqueous and doubtless half of the vitreous, by making use of a double set of fine catgut sutures; first suturing the sclera and then the conjunctiva separately. Of course the latter could just as well have been done with silk. As in each case the ciliary region was injured, traumatic cataract ensued within a month, although the lens itself seemed uninjured at the time. The result in each case was a natural eye with a linear scar."

LITERATURE.

1. Schöler, H., *Der Binderhautclappen, Tagesbericht, Augenklinik,* Berlin, 1899.
2. Kuhnt, H., (a) *Beiträge zur operativen Augenheilkunde,* Jena, 1883. (b) *Vorschlag einer neuen Therapie bei gewissen Formen von Hornhautgeschwüren,* Wiesbaden, 1884. (c) *Über die Verwerthbarkeit der Bindehaut in der praktischen und operationen augenheilkunde, Wiesbaden,* 1898.
3. Meyer, E., Bericht d. 22 *Versaml. d. ophth. Gesell.,* Heidelberg, 1892, p. 192.
4. Snellen on "The Subconjunctival Treatment of Operative and Traumatic Wounds of the Cornea and Sclerotic," *VIII Internat. Ophth. Cong.,* Edinburgh, Aug. 7, 1894.
5. DeWecker, Traitement des blessures de la cornee par occlusion conjunctovale, *Ann. d'oc.* CXII, p. 293, 1894.
6. Bourgeois, ref. Kuhnt (c).
7. Antonelli, ref. Kuhnt (c).
8. Weiss, L., *Arch. f. Aug.,* XXXIII, p. 311, 1896.
9. Norman-Hansen, ref. Suker.
10. Suker, *Ophthalmology,* July, 1908, p. 650.
11. Byers, G. Gordon, *Ophth. Record,* July, 1910, p. 353.
12. Maddox, L., personal communication, 1910.
13. Koyle, *Ophthalmology,* July, 1910.
14. Deane, J. Edgar, personal communication, 1910.

CHAPTER XIX.

INJURIES OF THE CORNEA.

A. Wounds. (a) Erosions—Abrasions—Etiology—Course. Indirect erosions—Symptoms and pathology—Recurrent erosions—Complications—Cicatrix dolorosa—Therapy. (b) Non-perforating wounds—Definition—Etiology—Symptoms and course—Diagnosis—Prognosis—Therapy. (c) Perforating wounds—Definition—Etiology—Symptoms — Course — Diagnosis — Prognosis—Complications—Infection — Iritis — Corneal staphyloma — Conical cornea—Fistula—Astigmia—Reopening of cicatrix—Medicinal treatment—Surgical treatment—Corneal suture—Literature. B. Foreign bodies—Definition—Etiology—Symptoms—Cases—Objective symptoms—Examination—Course and complications—Diagnosis—Prognosis—Therapy—Method of removal. Literature. C. Injuries from blunt objects. (a) Contusions—Etiology—Symptoms—Course—Diagnosis—Prognosis—Therapy—Cases — Infraction. (b) Rupture—Etiology—Mechanism—Direct Rupture—Indirect—Examination—Diagnosis—Prognosis—Therapy—Pathology. Literature. D. Burns and cauterizations—Pathology—Symptoms and course—Results and complications—Diagnosis—Prognosis—Therapy—Literature. E. Gun shot injuries—Contusions—Perforating wounds—Rupture—Foreign bodies. F. Changes in cornea following injuries—The healing of Corneal wounds—Uncomplicated—Complicated—Striate opacity—Edema—Opacities—Clearing of corneal cicatrices—Anterior synechia—Staphyloma—Keratectasia—Keratoconus—Literature. G. Special types of corneal disease following injury. (a) Keratitis striata—Etiology—Pathology—Filiform—Panel—Band—Calcareous film — Ribbon — Filamentary — Hemorrhage—Blood staining. (b) Metallic oxides in the cornea—Iron—Copper—Lead—Therapy. (c) Cysts—Therapy of complications—Corneal grafting—Literature. H. (a) Keratitis traumatica interstitialis. (b) Keratitis disciformis—Literature. I. Suppurative keratitis—Etiology. (a) Hypopion ulcer—Pathology. (b) Peripheral annular infiltration—Cases. (c) Ulcer rodens. (d) Mycotic keratitis—Pathology—Symptoms and course of ulceration—Diagnosis—Prognosis. (e) Neuro-paralytic keratitis—Prophylaxis—Therapy—Cauterization, chemical and actual—Keratomy or Saemisch section—General constitutional treatment—Subconjunctival injections—Literature.

Frequency of corneal injuries.

Injuries of the cornea are of daily occurrence, not only in the practice of the ophthalmologist, but are frequently seen by the general practitioner. Indeed, most of the so-called trivial injuries, abrasions, motes in the eye and smaller wounds are first attended by the latter. These injuries run the gamut of all the forms of trauma that occur to the exter-

nal tunics of the eye. In many instances they are uncomplicated by injuries of the other structures and generally heal kindly, leaving, however, in all instances where the true corneal tissue is affected, more or less cicatricial tissue which may or may not affect the visual acuity, depending upon the position of the wound. Restoration of the external epithelium, however, may be perfect without scar-formation.

In the optical zone, which is limited by the angular aperture of the pupil, being usually ellipsoidal, extending, as I have measured it[1], about 15° nasally, 20° temporally, and 20° up and down from the visual axis, or about 17° either side of the corneal axis and 20° up and down, any

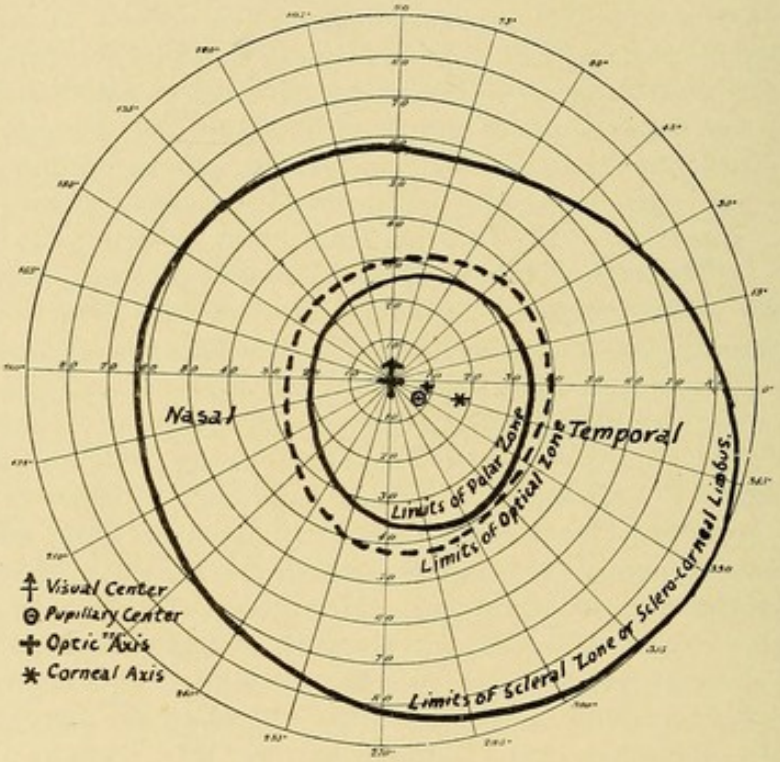

Fig. 202.
The optical and pupillary zones of the cornea.

solution of continuity, or its results in nebula or macula corneæ, naturally diminishes the visual acuity, the amount depending upon the degree of the opacity. The subject of corneal ulcers and infections is only incidentally treated in this chapter, but fully dealt with elsewhere.

A. WOUNDS OF THE CORNEA.

a. Erosions or abrasions.

These injuries consist in a solution of continuity of the anterior layer of epithelium in which the anterior elastic layer is laid bare, exposing the sensory nerves, and are accompanied by distressing symptoms. As a

rule they do not involve Bowman's layer or the substantia propria, and heal most quickly, even in almost complete exfoliation.

Etiology. Direct erosions occur from impact of substances coming with little force, as finger nails, pencils, broom straws, clothing, etc., and small utensils used in domestic life; impact of twigs, straws, etc., in country life, and the same character of objects met with in industrial pursuits. Spatters of hot fluids, water, grease, etc., are likewise responsible. To these causes must be added the effect of strong medicinal applications, as copper sulphate, silver nitrate, and especially the applications of strong cocain solutions, which, however, the profession has learned to use sparingly and not to give into the hands of patients.

Kilkowe[2] mentions ribbon-shaped opacity of the cornea corresponding to the aperture of the lids, which he calls Solaris Exfoliativa.

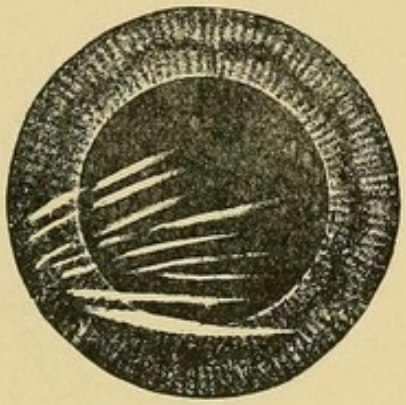

Fig. 203.
Erosion: Scratches of cornea from broom straw.

Strader[3] found that snow blindness was largely due to corneal erosions which are readily stained by fluorescein.

Course. The corneal epithelium regenerates so quickly that within twenty-four hours after an injury, in many cases, the continuity has been restored. Septic infection, however, is not uncommon. Examples of the rapid restoration of the corneal epithelium may be seen after cocain in strong solutions has been applied and the eyelids kept open by the speculum, as happens occasionally from imperfect technic in operations for squint and others in which the lids are kept apart for a considerable length of time.

Such occurrences have been seen by all of us. A marked example was a case I observed where a surgeon was performing an advancement operation for squint, which occupied the exceptional time of over half an hour. Ten per cent. cocain solution was frequently applied and the assistant did not keep the cornea moist during the operation so the entire epithelium came away, but the operator remarked that this was of no

moment, (except as to producing unnecessarily severe after-pain to the patient!). Within 48 hours the entire epithelium had apparently regenerated and there was no irritation except on account of the conjunctival and tendon cutting. I have observed this many times after accidents from other sources.

A brewery employee was sky-larking with a fellow workman one noon, who pushed a broom into the patient's face, making many small punctate wounds of the skin of the face and eyelids and from six to ten long scratches upon the surface of the cornea. The workman came to me within half an hour of the accident, tears streaming copiously out of his eyes, and in great pain; this was immediately relieved by instillation of holocain, and the erosed areas of the cornea were brought into view by staining with 2 per cent. fluorescein solution. The copious flow of

Fig. 204.
Erosion: Burn of cornea from curling iron.

tears had washed out any septic material that might have been carried into the eyes by the broom straw. The eyes were carefully cleansed by boric solution and dressed with 5 per cent. iodoform ointment, bandaged and the patient taken home. On visit to the office the next day the cornea did not stain by the fluorescein solution and he was almost as well as before the accident.

After operations upon the sympathetic a disturbance of the trophic nerves results in neuroparalytic keratitis similar to that observed in corneal disease following facial paralysis.

Köllner[4] reports 12 cases of removal of the Gasserian ganglion, the cornea being affected in ten of them, and in all the cornea had lost its sensitiveness. The disease is not to be considered due to a necrosis but to a lesion of the epithelium of the cornea.

Indirect erosions are of common occurrence from motes in the eye, the particle getting under the upper lid of the eye by being

rubbed by the patient, thereby scratching the anterior surface of the cornea.

Examples of where the foreign body has been removed and the patient returns with irritation are mainly due to this form of trauma.

Symptoms and Pathology. A smaller or larger solution of continuity in the epithelium is observed either by direct or focal illumination. The surface is clear and not opaque, as in the case of an ulcer. The form depends upon the character of the injury, irregular erosions are usually due to the scratching of a foreign body, larger ones to finger nail injuries; scratches to medium sharp small objects, as broom straws, hair brushes, wire, glass, etc.

The subjective symptoms are typically severe pain, photophobia and lacrimation, and feeling of a foreign body. The pain occurs immediately

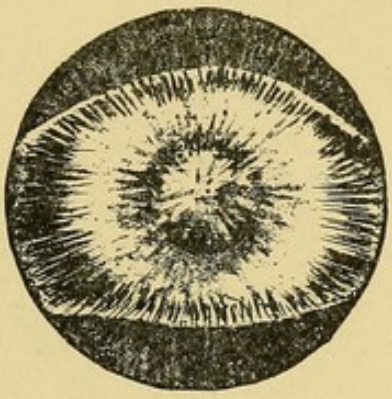

Fig. 205.

Erosion: Edema and desquamation of corneal epithelium from prolonged cocain instillation.

upon the receipt of the injury, is piercing, pressing or burning, and feels as if the whole of the eye was hurt. It is increased by movement of the globe and opening and shutting the lids. Hot tears flow over the cheeks. The patient holds his hand and handkerchief to the eye to keep down the movements of the lids. The other eye tearfully sympathizes and is kept partly closed. The great pain is caused by exposure of the corneal sensory nerves in a mass. Clean-cut wounds do not give as much pain. In very nervous individuals clonic cramp of the side of the face is seen.

Landesberg[5] described a case of epithelial erosion of the cornea which was attended by vaso-motor neurosis of the eye, which became soft and sunken into the orbit. At the same time there was hyperemia and hyperesthesia of the face.

Diagnosis. The diagnosis under inspection is difficult in very small erosions. Small and otherwise almost indistinguishable abrasions of the corneal epithelium, wounds and small foreign bodies in the cornea, may be brought into view by the staining of the tissues by a

2 per cent. fluorescein and 2 per cent. bicarbonate soda solution. This aniline dye will not stain the intact corneal epithelium, but readily passes into the subjacent parenchyma and abraded epithelial cells, forming a bright-green background, upon which foreign bodies are readily perceived. Focal illumination and magnification of the eye by a lens, preferably by the Berger binocular loupe, is of great value.

The Placido keratoscope, or the reflection of the mirror of the ophthalmometer, will show an irregular reflection at the abraded area and the reflex of light from a mirror at the open window may show irregularities.

Prognosis. As a rule the prognosis is good. The defect heals in 24 hours without a scar. All cases where a facet or cicatrices follow have had more than an erosion, and the solution of continuity has gone

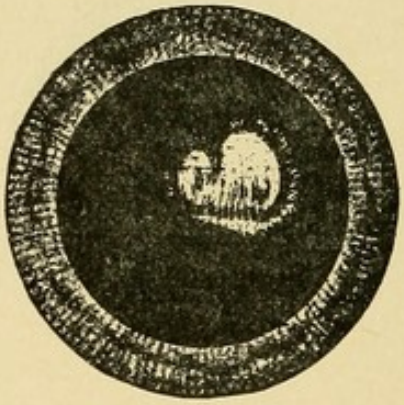

Fig. 206.
Erosion of cornea from finger nail injury.

through Bowman's membrane into the corneal tissue proper.

Complications. Septic infection, however, in some cases leads to corneal ulcerations, abscesses and even to panophthalmitis. The sepsis is not always carried by the foreign body but is frequently brought into the eye after the injury by the patient himself from rubbing the eye with his fingers, a dirty pocket handkerchief, or by the use of house remedies or even by exposure of the injured parts to the air, which, as we all know, contains septic germs. (See Conjunctiva). Examples are of frequent occurrence in large dispensary or private practice.

The presence of a lacrimal sac suppuration of course predisposes to such infection. Baudry[6] believes there is a special disposition to infection of corneal erosions in childbirth and during nursing, especially when these conditions are complicated by diabetes and albuminuria or other constitutional derangements.

Course. As a rule in 12 to 24 hours the pain abates and full healing occurs. However, ulceration, and even loss of the eye from in-

fection may follow. Filamentary, striped or disciform keratitis or bullæ, and blood stain of the cornea, may follow.

An unpleasant sequel is the formation of cicatrix dolorosa, which is either due to a microscopic neuroma or to hysterical keratalgia or to wound infection by the bacteria or the aspergillus.

I saw one such case in a school-teacher in which the scrapings revealed the aspergillus fumigatus. The treatment is curettement or the galvano-cautery.

Recurrent corneal erosions.

In a very few cases the erosion, especially in the morning, may be seen for weeks or months afterwards. Fuchs[7] explains this by the newly-formed epithelium adhering to the conjunctiva of the lids when they are closed, and being stripped away anew each day. Szili[8] says that in these cases the regenerated epithelium is not firmly adherent to its bed and under the action of some injudicious cause is separated and cast off. This separation takes place in the form of a vesicle which, however, ruptures so quickly that we do not see it, but only the consequence of the loss of epithelium. Cases are seen where subsequent attacks occurred several times a year after the primary injury.

Therapy. Treatment of uncomplicated corneal abrasions, or cases which do not perforate through its entire thickness, is antiseptic washing by 3 per cent. boric acid solution, 1:10,000 sublimate or 1:1,000 chinosol solution, or normal salt solution preceded by instillation of cocain or holocain to allow of inspection and to relieve the pain, and argyrol, dionin and application of asceptic bandage. I personally prefer in all cases to put in 5 per cent. iodoform ointment, which seems to be somewhat of a local anesthetic (or the White bichlorid ointment prepared by boiling 1 grain of bichloride of mercury and 5 grains of sodium chlorid in 6 oz. of vaseline). A bandage should be left on for 24 hours and removed by the surgeon himself. If the parts have healed, which is readily seen by the instillation of 2 per cent. flourescein solution, which colors the denuded area green, then a light bandage or not may be put on, as may seem best.

If there is not complete healing, atropin should be used to dilate the pupil and get the edge of the iris away from the lens so that a subsequent iritis may not cause posterior synechia. A bandage is essential to keep the lids closed. If pain be severe, 5 per cent. dionin solution applied once in 6 to 24 hours may be dropped in the eye, but all meddlesome handling, especially with hands unprepared as for surgical operation, should be discouraged; if complications of sepsis have set in the wound may be immediately cauterized by 95 per cent. phenol, or with the galvano-cautery. In my opinion, the cautery is used too little and I can

safely state that the scar from its use is less than that from the ulceration which is present or will ensue.

I would here especially protest against the use of cocain solutions in the patient's hands; they should only be used by the surgeon, and only for surgical operations or to facilitate examination, as cocain interferes with the healing process by cutting off nutrition; the same may be said of suprarenal extract and its active principle, adrenalin, after injuries to the eyes.

Cicatrix dolorosa should be curetted or cauterized. Complications of keratitis or ulceration are to be treated as advised under these headings.

Hirsch[9] advised administration of 5 grains of quinin three times a day for recurrent erosions. These may be locally treated by 1:2,000 sublimate ointment, 1 to 5 per cent. yellow oxide ointment, and massage, and even by the galvano-cautery, as mentioned by Nettleship[10] and Nieden.[11]

B. NON-PERFORATING WOUNDS.

Definition. In these the solution of continuity goes through the lamina elastica anterior into the substantia propria, and in some cases as deeply as the lamina elastica posterior, but in which the anterior chamber may not be opened.

Etiology. Incised, punctured and gashed wounds are more common than lacerating or flap wounds. They occur from flying foreign bodies of iron or other metal; glass and stone which fall away after impact or graze of the cornea; from sharp instruments, as knives (pointed ones), pins, needles, shears; and the impact of sharp or pointed objects as wire, sharp splinters of wood or bone, etc. Flap wounds are usually finger nail accidents.

Symptoms and Course. Soon after the injury the margins become cloudy and swollen from imbibition of fluid, and in irregular lacerated wounds the cornea may become opaque over a large area. As the wound heals the cloudiness disappears, although sometimes a dense opacity remains around the wound area. This opacity is often associated with irregular bulging of the cornea and irregular astigmatism.

The symptoms are much the same as just outlined, except in the case of clean cuts. Here the pain is not at all great and if the wound be in the part of the cornea not covered by the lids but little irritation may be felt. There is some lacrimation and redness but in many cases the patient may not consult his physician until the day's work is done, or perhaps not for several days, during which time there is ample time for infection.

Where, however, the wound is extensive, lacerated or a flap has

formed, the symptoms are more severe. The results depend upon the amount of opacity produced and the astigmatism which always follows wound healing.

Diagnosis. The examination is to be conducted under cocain, in some cases with use of fluorescein, direct and focal illumination, the magnifier and other aids being used.

Prognosis. The prognosis is in doubt, even in seemingly trivial injuries, until the presence of infection can be excluded. Clean cut wounds heal well and speedily. Quick repair of the corneal tissue proper is a daily observation with eye surgeons, as the lips of the wound after cataract extraction are usually gummed together within a few hours after the operation. But even slight injuries infected by unclean instruments, or subjected to secondary infection, may be followed by severe inflammation, eventuating in loss of sight or even the eyeball itself. Of

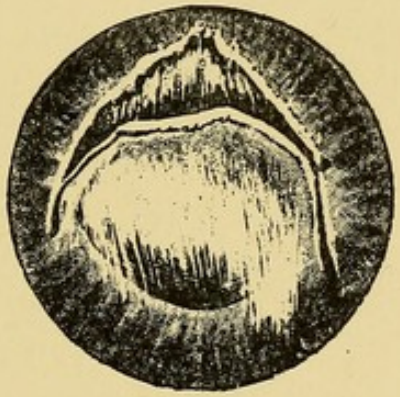

Fig. 207.

Large superficial flap wound of cornea made by finger nail.

these, unclean instruments, the finger nail, hairpin, hatpin, pocket-knife or scissors, are perhaps the most dangerous. Wounds of the cornea which do not penetrate into the anterior chamber, which are characterized by the formation of a flap, are perhaps the most dangerous if caused by septic instruments. The reason for this lies in the fact that the flap may almost immediately fall back into place, becoming gummed at the edges and retaining in the cornea a nidus of septic material. Such an unfortunate instance is told in the following history:—

A young lady was passing the doorway of a downtown building while workmen were chipping an iron door-sill, which had been down for a number of years and therefore trodden by thousands of feet; a small piece of the iron being chipped off struck her in the open eye, causing immediate pain and lacrimation. She went at once to a physician who looked at the eye and put in cocain, but did not find any foreign body and allowed her to go away without antiseptic washing or bandage. The

next day I was called in consultation by the family physician and found a septic wound of the cornea, forming a flap about 3 mm. in length and about the same across. From this wound protruded a viscid exudate. It was immediately cleaned and cauterized with pure carbolic acid; the next day, however, the infiltration had become greater and after consultation the area was thoroughly cauterized with the galvano-cautery. Despite this, hypopion keratitis set in which only ultimately subsided after radical Saemisch sections, twice repeated, for while healing set in after the first section it was followed ten days afterwards by a nidus forming in another part of the cornea, which had to be opened by section. Three weeks later the eye was quiet although staphylomatous. The intra ocular pressure suddenly increased one night and the next day numerous sieve-like openings were found in the staphylomatous cornea and enucleation of the eyeball was then resorted to.

A finger nail injury was seen in a woman who came to me stating that her year old child had scratched her eye that morning; a flap of the cornea was seen to be hanging from a pedicle; the parts were coapted by a stitch and under antiseptic dressings the flap healed, with subsequent small corneal leucoma which did not in the least interfere with vision.

A large finger nail injury was seen in a child who had been injured by one of its playmates several days before, there being a large flap of the cornea extending from the upper limbus to about the corneal apex, of perhaps ¼ the corneal area. This was hanging down and showed no tendency to stick to the underlying surface so it was snipped off with the scissors and under antiseptic precautions the cornea subsequently healed, preserving fair vision but showing large leucoma.

Higgins[12] reports a case of an injury to the cornea from a broken spectacle lens. The lens was broken by a stone thrown by a boy. One of the broken pieces cut into the cornea and produced a triangular flap. A piece of glass was removed from underneath the flap. A solution of argyrol was dropped into the eye and the eye closed. The next day the corneal wound was stained brown. The flap held in position, leaving no scar, but the former wound remains slightly discolored from argyrosis six months after the injury.

Therapy. The treatment is antiseptic and cleansing as in the case of corneal erosions.

C. PERFORATING WOUNDS.

Definition. Perforating wounds of the cornea may be defined as those which completely penetrate all its layers without the retention of a foreign body therein or within the eyeball.

Perforating wounds of the cornea are often complicated by prolapse

of the iris and if the cut extends sufficiently deep, as it commonly does, injury to the lens capsule or lens, or often of deeper structures, complicate the trauma. If septic, to the dangers of the wound itself may be added hypopion keratitis, iritis, infection of the other portions of the eye and panophthalmitis. Wounds of the sclero-corneal margin are especially dangerous on account of injury to the ciliary body, and subsequent sympathetic irritation or inflammation in the other eye, and of the tendency of the iris to prolapse, with subsequent posterior synechia. It is safe to say that wounds of the cornea, per se, and limited to this structure, seldom give rise to sympathetic inflammation or irritation.

These injuries are always emergency cases, and should the general

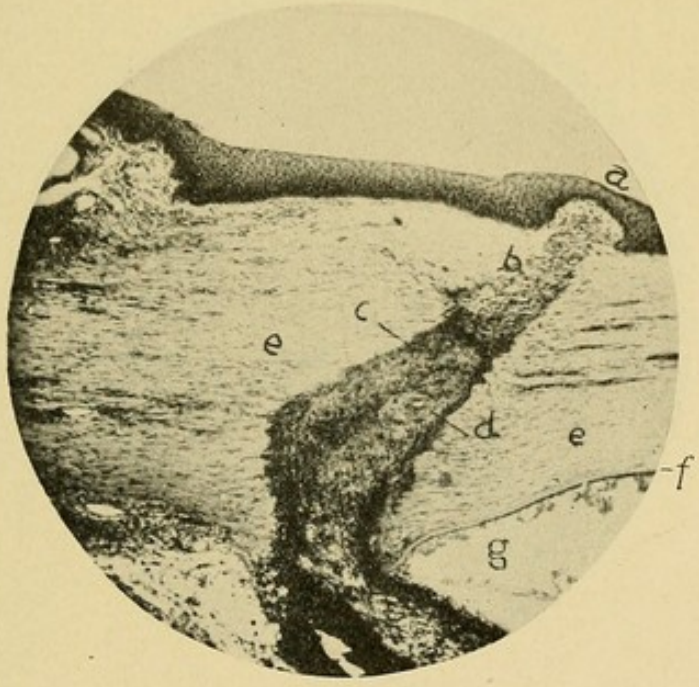

Fig. 208.

Prolapse of iris into corneal wound, filling perforation. a—Regeneration of corneal epithelium over point of perforation. b—Scar tissue. c—Infiltrated iris with scattered pigment cells. d—Blood vessel in iris. e—Clear substantia propria. f—Rupture of Descemet's membrane. g—Absence of pus in anterior chamber. (Tooke.)

practitioner, in whose hands they commonly first fall, not feel that his training and experience have thoroughly prepared him to treat them, he should at once refer to such of his colleagues as he feels can do justice to such cases.

Etiology. Incised and punctured wounds are most often seen; lacerated and contused wounds more seldom, most of such cases being complicated by injury to the iris, lens, and ciliary body.

As a rule the eye has had ample opportunity to become infected before examination by the eye surgeon and where such occurs the infection is

almost invariably communicated by the working man from his finger nails or dirty handkerchief, or by ill-considered operative procedures by fellow-workmen in the factory, or even by physicians.

The objects producing such injuries are manifold and at times bizarre. Perhaps little children are the most common patients, having injured themselves by pen-knives, forks, needles and hat pins. On the farms the act of splitting fire wood; and in the trades, wire, nails, breaking bottles and water gauges. Shot grain wounds generally penetrate.

Tooke[13] shows that in perforating wounds of the cornea prolapse of the iris into the wound is an attempt by nature to avoid infection. Also that the effort on the part of the iris is a suicidal attempt, for

Fig. 209.

Impaction of iris into corneal wound, showing regeneration of corneal epithelium. a—Absence of infiltration near wound in substantia propria. b—Regeneration of corneal epithelium over lip of wound. c—Iris. d—Blood vessel in iris. e—Slough over point of perforation. f—Infected cataractous lens. (Tooke.)

this structure becomes pinched and sooner or later gives rise to irritation, causing irido-cyclitis and sympathetic ophthalmitis, while it prevents the eye from panophthalmitis.

He reminds us that by walling off the infected sides of the incision an effort is made to ward off the entrance of bacteria into the anterior chamber and to avoid subsequent panophthalmitis. Beyond this purely mechanical action the blood vessels of the iris assist in carrying off the localized infection to the general circulation, thus preventing subsequent necrosis of the cornea. A second feature, noted by the presentation of the iris, is that the process of actual healing or of granulation tissue for-

mation is materially assisted; that after draining away the infective agencies the number of leucocytes supplied by the blood vessels of the iris readily assist in the formation of new connective tissue elements. This tends to permanently close the perforation, and allows the reformation of the protective epithelial strata of the cornea. Besides completely filling the gap in the cornea and preventing any escape of the aqueous humor, the anterior chamber is restored and the intraocular circulation re-established.

It cannot be denied that many lamentable results are avoidable by performing an iridectomy, or by releasing the anterior synechia. The author does not advocate Nature's method as being superior to surgical

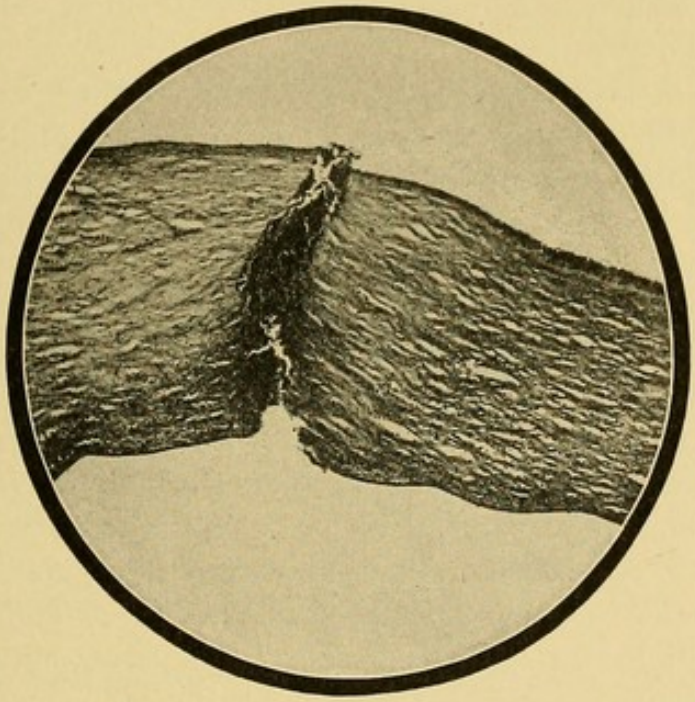

Fig. 210.

Septic wound of cornea. Space between lips of wound occupied by pus. No effort at repair of corneal cells. Contortion of corneal cells. Dilatation of intercellular spaces filled with leucocytes. (Tooke.)

interference, but presents it as the means Nature adopts for closing an infected hole in the cornea in a most effectual manner.

Symptoms. As a rule perforating injuries cause severe pain, burning, lacrimation, photophobia and immediate blindness. There is ciliary congestion, and commonly edema of the lids and conjunctiva. Examination shows a more or less wide open wound involving all the corneal layers; if existent more than a day, its edges macerated, the anterior chamber empty, the iris prolapsed and perhaps impacted in the wound, the pupil drawn to one side, and if the lens be injured, whitish and not allowing of examination of the fundus by the ophthalmoscope.

It is well to ascertain not only the apparent character of the wound but the instrument causing it, and the direction from which the cut or wound came in order to judge of its depth and the amount of injury to the deeper structures of the eye, for it is almost needless to observe that probing of ocular wounds is, as a rule, to be discouraged.

The edges of cuts, gashes, and lacerations are at first sharply defined, but later the lips become swollen and the edges rounded. Proceeding from the wound into the cornea fine grayish stripes are seen. The various layers may be separated so as to be readily distinguished. Sometimes the lips of the wound over-ride, but as a rule they gape.

Simple uncomplicated injuries heal very rapidly, the cornea being soft and pliable and accommodating itself readily to the altered condition, the lips of the wound usually coming quickly together, union taking place within a few hours.

Whiplash injuries often look like incised wounds. Punctures from needles, etc., are often so fine that they are with difficulty observed; under magnification the grayish canal of penetration will be seen in the cornea. Knife and scissor wounds, and those made by other metal objects, are often large and flap-like, so much so that often the lens escapes at the time of the accident and the vitreous is lost. In small wounds the iris comes forwards and attaches to the posterior surface; in larger ones it prolapses.

Vision varies from the normal in small lateral punctures of the cornea, with no loss of aqueous and no injury of other parts of the eye, to complete loss of light perception in cases with great tissue destruction.

Course. All considerations regarding kind, size, location, complications, whether or not infected, nature of the wound, obtain in the course which we have already gone into in discussing abrasions and non-penetrating wounds.

If a clean-cut penetrating wound of the eye has occurred without any prolapse, by a clean and sharp instrument, the prognosis is generally good; such is the case in wounds involving incision of the cornea as for iridectomy, cataract extraction, and of the sclera for glaucoma. The edges of the wound usually coapt; there is some redness in the neighborhood, and under protection from the outer atmosphere the wound heals and the shape of the globe, together with the function of the organ, is usually preserved or restored; if the wound remains open, such as from delayed healing in cataract extraction, the chances for the entrance of pathogenic germs and consequent inflammation are greater.

Diagnosis. The opened eyeball; the lowered tension; the shallowness of the anterior chamber; and perhaps extrusion of a portion of the iris; together with the history and symptoms; speak for the character of the injury. The determination as to whether or not a foreign

body has passed through and remains in the eyeball should always be made, as explained in another chapter.

Prognosis. This depends upon the size and seat of the injury. In seriousness these injuries range from the smallest perforation by an aseptic needle, producing no destruction of tissue, without complications, and which permanently heal in a few hours, to those of great tissue destruction and injury of many parts of the eye, with immediate and permanent destruction of function. Also the small and innocent-looking puncture of the cornea with few immediate symptoms may be the channel through which a foreign body has entered, carrying with it the germs of a destructive inflammation; hence no penetrating wound of the cornea should be considered an insignificant affair, nor should an immediate favorable prognosis be given in any case. The condition of the union soon after the accident should not be used as a positive guide in prognosis. The larger the wound the more the consequent cicatricial opacity

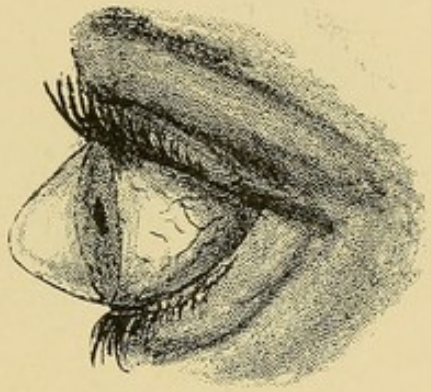

Fig. 211.
Keratoconus following central punctate injury of the cornea.

and distortion of the shape of the globe following the healing, and the worse the resultant vision.

Complications. Aside from injuries to the iris, lens, ciliary body and deeper structures of the eye, and the entrance of infection with its consequences, others occur in the course of the healing.

Iritis with posterior synechiæ is unfavorable. Tetanus with death, has been observed by Pollock[14] and Ramiro-Guedes.[15]

Rust[16] saw a 45 year old woman with perforating corneal wound from a steel over which she was bending. The wound was small and the iris and lens not affected. Iritis developed and in eight days tetanus. Becker[17] and Ziino[18] have reported meningitis.

Corneal staphyloma is common following large wounds. I have not observed many in my practice, as I have either enucleated or saved such eyes by the Kuhnt conjunctival flaps.

Praun[19] reports several cases, amongst them a young patient who had a Y-shaped wound of the cornea with prolapse of iris and loss of part of the injured lens. Two months later staphyloma occurred.

I have seen an almost perfect conical cornea with corneal maculæ follow a central punctate injury of the cornea. Also a most peculiar, clear projection of the cornea from a hat-pin injury; also such an ectasia which was later accidentally improved.[20]

In a woman of 50 there was a congenital corneal ectasia 5 mm. x 7 mm. implanted on the cornea like a clear watch crystal of such high refraction that the subjacent portion of the iris appeared magnified. Seen by me on account of trachoma. (V = fingers at 3 mm.) A couple of months later her child cut the eye while playing with a comb, tearing away the protrusion. Edges were trimmed; antiseptic bandage applied. Small leucoma followed. V greatly improved to 6/xxx.

Fistula of the cornea is not uncommon. One such I ob-

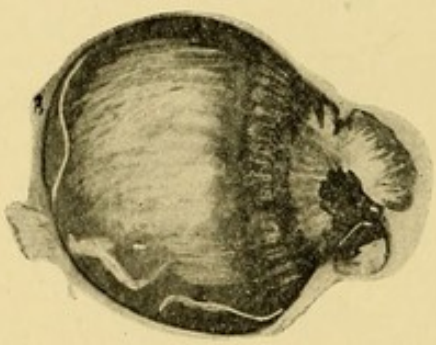

Fig. 212.

Anterior staphyloma of cornea, five years after perforating injury with splinter of wood, ulceration and prolapse of iris following. Enucleated for prothesis.

served in a negro woman following a perforating, and later infected, needle injury. This healed under conical incision, antiseptics and bandage. The Kuhnt method of keratoplasty by conjunctival flap is a more modern method of treatment.

Regular astigmia follows iridectomy and cataract operations, generally against the rule, viz., axis 180°, and greater the more the wound is made in the cornea. It is usually 5-6 D. shortly after an operation, gradually diminishing in amount until in six months it is only about 1.50 D. Cases of 6-10 D. are not rare. Where the cut is in the sclero-cornea and with a conjunctival flap, the astigmia is less and excessive cases are not found. Clean, incised, injury wounds may be followed by regular astigmia. Dolganoff[21] ascribes regular astigmia following wounds to the effect of muscular contraction and intra-ocular pressure.

Irregular astigmia is the consequence of irregular healing,

and greatly diminishes the vision. It is usually combined with extensive scarring and leucoma of the cornea.

Re-opening of the cicatrix. This is a very unpleasant after-complication, which I have not personally observed. Praun[19] records the case of a four-year-old girl who had cut the cornea through and across with a sharp knife. The wound opened wide, the iris pro-

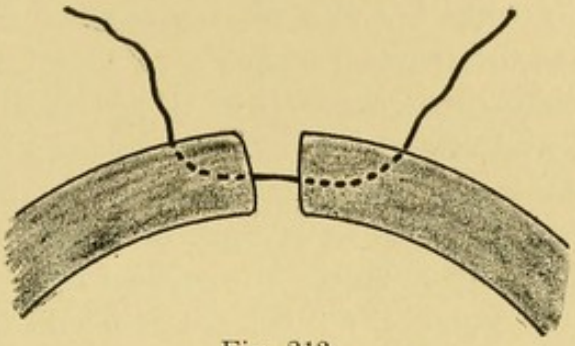

Fig. 213.
Corneal suture.

truded and the lens capsule was opened. Two stitches were taken in the cornea, the iris excised and a bandage put on. In 14 days healing occurred. A regular bandage was worn up to four weeks later, when on leaving it off for three days a ball that had been tossed in playing struck the eye and reopened the wound. This rehealed in a few days.

Medicinal Treatment. In treating these cases the first

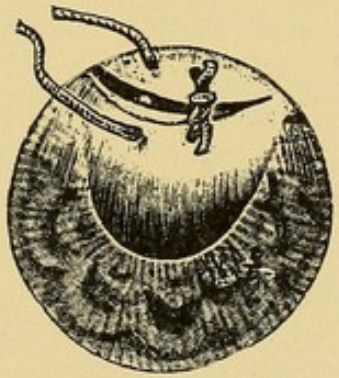

Fig. 214.
Corneal suture.

and probably most important point is to clean not only the wound, but also the entire conjunctival membrane, along with the lids and adjacent tissues. Strong antiseptic solutions are not advisable for the conjunctival surface, as they usually increase the pain, redness and swelling. I prefer a thorough irrigation of these parts with a liberal amount of sterile water, or a solution of boric acid, using soap externally if necessary to cleanse the skin.

Fifty per cent. argyrol solutions, even injected into the anterior chamber, have saved many of my cases, although apparently already infected, and I almost invariably use this as a dressing after injuries and operations. 1:3,000 sublimate ointment is applied to the lids and then an occlusive bandage, which must not be tight enough to press on and interfere with coaptation of the lips of the wound.

The use of local or general anesthesia not only gives us an opportunity for thorough cleansing, but also for any surgical procedure that may be necessary, such as the removal of any accessible foreign body, replacing or excising prolapsed iris, removal of shreds of tissue, and trimming the edges of the corneal wound when very rough and irregular. In small fresh wounds attempts may be made to replace the iris by a fine probe or Daviel's spoon, and the use of atropin for a central perforation (as a rule in all cases, for while eserin in marginal corneal wounds may be theoretically indicated, practically it has not fulfilled expectations). Very small point-like prolapses of the iris may be cauterized. After completing the toilet of the conjunctiva, iris and cornea, any wound of the lids should be sutured or otherwise treated as indicated.

Corneal suture.

The needle and suture with proper care are placed only through the external layers of the cornea, about 0.5 mm. from the edge and about half way through, passing through the lamellæ of the cornea. After pulling the edges of the wound together a square knot retains them in place for five to seven days, when the suture is snipped by the scissors and removed with forceps. As a rule corneal sutures are well borne and have been used by me many times with good results. Czermak[22] and Eversbusch[23] recommend them highly. However, such corneal sutures may not be well tolerated, as shown by Adamuck.[24]

Closing the corneal wound with sutures is usually a questionable proceduce, as eyes needing corneal sutures are usually so badly damaged that they had better be enucleated. One to two sutures may be taken by very fine and sharp needles, care being used not to tie the threads too tightly so as to cause the lips of the wound to over-ride.

A different view is taken of conjunctival sliding flaps as recommended by Schoeler in 1876 and revised by Kuhnt in 1884, the latter's book[25] having been published in 1898. I know I have saved many eyes by this procedure. A full description is given under Operations with the Conjunctiva.

Two sides of a triangle of conjunctiva may be excised at one side of the wound and a flap drawn over the surface of this side by one of the sutures. An oblong piece may be pulled over the wound and fastened

by sutures to the limbus, or the flap may be left adherent at either end. The single or double pedunculated flap of Kuhnt may be used.

Dissection of the entire margin of the conjunctiva, which is drawn up in a purse-string suture over the entire cornea, may be made in extreme wounds. The suture either pulls through or is cut in about 5 days, when the cornea will be found to have coapted under it. The cut edge of the conjunctiva soon reattaches at the limbus and after some weeks cannot be recognized to have been detached.

A child was injured by a pocket knife stab-wound clear across the cornea. I saw the case the same day of the injury, the eye looking clear. I replaced the protruding iris; cut the conjunctiva entirely around the limbus; instilled 25 per cent. argyrol into the anterior chamber; and drew the conjunctiva in a purse-string over the cornea. Removed the suture in four days, when wound of cornea was coapted. Result, healing with anterior leucoma. V = 6/xii.

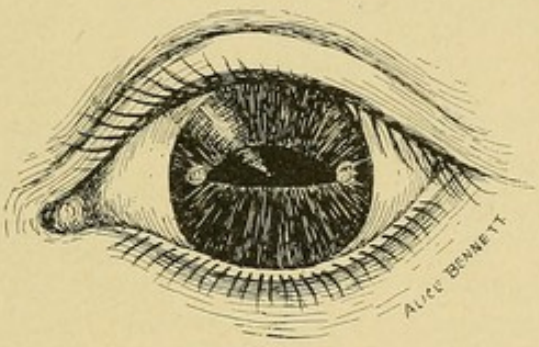

Fig. 215.
Transfixion of cornea by hatpin. (Bennett.)

A child was injured by scissors, making a triangular flap at lower part of cornea. Here I made a Kuhnt bi-pedunculated flap, after iridectomy, and saved the eye with V = 6/xxx.

A man was injured by a piece of kindling wood at edge of cornea, with loss of substance and iris prolapse. Iridectomy and a single Kuhnt flap saved the eye, with V = 6/xvi.

In a case of perforating wound by hatpin, seen three days after injury, infection had occurred and the pin had evidently penetrated the lens and vitreous, as a purulent cyclitis developed. An exenteration was made. The reaction in this case was great, but a prothesis was later fitted.

A double perforation of the cornea by a hat pin is reported by Bennett,[26] in which the cornea was transfixed laterally from the nasal side, with no injury to the lens, prolapse of iris, which was freed by atropin, with resultant healing and good vision.

Suker[27] among others says a class of cases formerly entailing either a partial or total loss of corneal substance, because of injury or disease which heretofore necessitated enucleation, or one of its substitutes, need not any longer be thus sacrificed. The same is true of extensive wounds of the sclera. By the use of these flaps we get support, promote union and prevent infection.

Kuhnt[28] in treatment of recent complicated penetrating injuries of the cornea, advocates the performance of iridectomy as the first step in cases of recent extensive penetrating injuries of the cornea and lens, in which the lenticular substance shows a tendency to swelling, i. e., in larger injuries of the cornea, iris, lens, vitreous, especially if centrally located and if a primary reunion is not probable, and in large perforated central ulcers. Iridectomy acts here, so to speak, as a safety valve, for the following reasons: Extraction of a traumatic cataract later on generally requires iridectomy. Lens matter is better absorbed if it is not re-

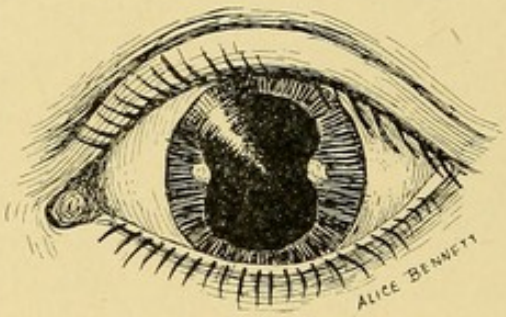

Fig. 216.
Transfixion of cornea by hatpin. (Bennett.)

tained in the posterior chamber but can freely enter the anterior chamber. After iridectomy the pressure of lens matter on the iris will be less and thus the causes for synechiæ will be removed. The eye becomes quiet sooner. The wound of the cornea is more readily and better agglutinated if tension is diminished through iridectomy. It gives a better access to the lens, in case a speedy operation should be required.

LITERATURE.

1. Würdemann, *Journ. A. M. A.*, Aug. 27, 1892.
2. Kilkowe, *Wien. Med. Woch.*, Apr. 21, 1906.
3. Strader, *Ophth. Record*, Nov., 1906
4. Köllner, *Wien. Klin. Rundschau*, Jan. 3, 1909.
5. Landesberg, *Klin. Mon .f. Aug.*, 1880, p. 467.
6. Baudry, *Étude médico-légale*, etc. Lille, 1896.
7. Fuchs, *Lehrbuch*, p. 217.
8. Szili, *Arch. f. Aug.*, XIII, 1, p. 39.
9. Hirsch, *Woch. f. Ther. u. Hyg. d. Aug.*, 1898, Nos. 21-22.
10. Nettleship, *Ophth. Rev.*, July, 1889.
11. Nieden, *Centralbl. f. Aug.*, 1891, p. 129.
12. Higgins, S. C., *Ophth. Record*, July, 1909.

13. Tooke, Fred, *Ophth. Record,* Aug., 1908.
14. Pollock, ref. Praun, l. c., p. 176.
15. Ramiero-Guedes, *Arch. Ophthalmotherap.,* Lisbon, IV. 1885.
16. Rust, *Journ. Ophth. & Oto-Laryngol,* 1892.
17. Becker, *Arch. f. Psychol.* XII, p. 250.
18. Ziino, ref. Praun, l. c., p. 176.
19. Praun, l. c., p. 178.
20. Würdemann, *Ann. Ophth. & Otol.,* III, 4, Oct., 1894.
21. Dolganoff, *Arch. f. Aug.* XXIX, 1.
22. Czermak, *Augenärtzlichen Operationen,* 2 ed., Vol. II, p. 665.
23. Eversbusch, *Münch. Med. Woch.,* 1891, p. 487, 511, 521.
24. Adamuck, *Wjestnik, Oph.,* 1, p. 16, 1892.
25. Kuhnt, *Die Verwerthbarkeit der Bindehaut,* etc.
26. Bennett, *Ophthalmology,* Jan., 1910.
27. Suker, *Ophthalmology,* July, 1905.
28. Kuhnt, *Zeitschr. f. Aug.,* 1906, XV, p. 912.

B. FOREIGN BODIES.

Definition. The larger percentage of foreign bodies on and in the cornea come under the heading of motes in the eye. They may be denominated as (1) Lying on the cornea, not firmly attached; (2) Burned into the cornea, as cinders, sparks, emery; (3) Metal chips, stone, etc.

Etiology. Foreign bodies on or in the cornea are most common accidents. Some, as particles of chaff, wheat husks, rhizomes of plants, etc., simply adhere to its surface. Others cause solution of continuity of the epithelium, as in the case of cinders and ordinary motes in the eye; others penetrate the true corneal tissue and remain impacted, as particles of emery, stone, metal chips, etc.; and others pass entirely through and usually wound the iris, lens or deeper structures, as shot grains, iron and copper chips, etc. The latter is discussed under the heading of Foreign Bodies within the Eyeball.

Besides the ordinary run of foreign bodies, thorns, fingernail clippings, insect stings, caterpillar hairs, etc., enter and cause ulceration or perforation of the cornea.

Cilia and other foreign bodies may be carried into a wound, rarely remaining inert, usually setting up inflammatory reaction, shown by development of giant cells. (Schwartz[1]).

The air-gun gives rise to many of these avoidable injuries, and its use should certainly be prohibited.

Symptoms. The subjective symptoms are usually those of great smarting, or piercing pain, and copious flow of tears immediately following the accident, which is usually reported by the patient to the minute or hour. In sensitive individuals the pain may be great and there may be blepharospasm. Cramp of the face often occurs. Praun[2] reports nystagmus horizontalis, v. Michel[3] epileptoid attack. The face is congested and the patient holds his hand or handkerchief to the eye to keep

the lid from rubbing. But his attempts at removal as a rule only succeed in further impact of the foreign body, which often, in the case of cinders, has at first only lodged beneath the lids. Attempts at removal are frequently made, particularly in the shops by "mote removers" as hereinbefore described. These persons as a rule succeed in removing such motes, and in some instances quite skilfully. In others the patient may appear to the physician with the cornea pretty well scratched and gouged from a successful or unsuccessful attempt at such removal.

The severity of irritative symptoms depends upon the part of the cornea in which a foreign body lodges, as well as the amount of damage done. As a rule immediate stoppage of work is necessary and the patient is incapacitated until the foreign body is removed and the solution of continuity healed. If where the lids rub continually in the act of winking the irritation is severe, but in some cases where the particle is small and lodged between the lid aperture the patient may not even

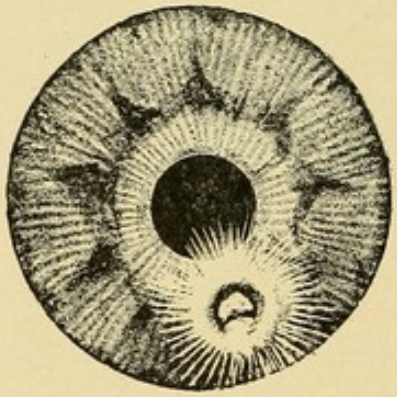

Fig. 217.
Ulcer of cornea with retained iron chip.

know that there is a foreign body present, having perhaps forgotten the trivial accident of a few days, or even weeks, before. This often happens in the case of emery.

Sometimes a small foreign body may be driven against the cornea so forcibly that it lodges under the epithelium and at first gives rise to but little inconvenience, as, being covered, it offers no sharp surface to grate against the lid; after a while it projects slightly and the epithelium gives way, then occasioning all the painful symptoms of a foreign body. It frequently happens that patients carry such foreign bodies for many days, and sometimes attribute their sufferings to other causes, and many instances have been seen of improperly diagnosed cases treated for days, weeks, or even months by physicians whose prescription pads are more facile than their eyes and fingers.

The result on vision depends upon the position of the foreign body. If in the optical zone sight may be greatly diminished and the

patient see a spot before the eye. Old grinders and workers at the emery wheel may have their corneæ full of many old, impacted, and healed-in pieces of emery, etc., and many small scars of previous accidents. The sight is, as a rule, found to be diminished.

A woman whose eyes were being measured for glasses was seen by me a few days ago in whose right cornea the point of a needle was seen and extracted by the spud. She had been recently sewing but had not noticed any accident to the eye.

Among countless cases of unrecognized foreign bodies on the cornea was a man who had been under treatment by an oculist and he, too, of good standing in the community, for a full week for "conjunctivitis." Inspection by focal illumination and staining for fluorescein revealed a minute cinder in the cornea against the bright green background of the stained erosion. Many cases of corneal ulcer are due to a retained foreign body.

A man with a chip of metal lodged in the cornea, without producing irritation until after a week, came to me on account of a foreign body within the eye with all the usual symptoms, stating that he had been struck while working at the forge one week before and since that time the eye had hurt him a little but he had gone on with his work. I removed the substance with immediate relief and healing.

A farrier came stating that a piece of horse-hoof paring had gotten into his eye a week before, giving rise to no special inconvenience until two days ago, when an ulcer began to develop; this was readily seen and in it a small foreign body, which proved to be a piece of a horse's hoof. Healing followed antiseptic measures.

Such cases as the following are of not uncommon occurrence. In a farmer the corneal epithelium was macerated and stained readily to fluorescein solution. A small brown object was found closely applied to the cornea, which was brushed away and the patient received immediate relief.

A man while on a visit to New York was passing along the subway when an explosion occurred throwing up a great quantity of stones and much dust, some of which got in both his eyes. He washed out his eyes himself and came home (Milwaukee) within 48 hours; was treated there by an old physician, whose eyesight is not particularly good, for a conjunctivitis for over ten days, finally coming to me, when I found six or seven particles of stone dust imbedded in the cornea. These were removed and healing took place within a few days.

Dowling[4] had a case of a piece of steel retained in the cornea for one year, then removed by gouge and magnet.

Objective Symptoms. Examination under direct and focal illumination, especially by the aid of the loupe, will usually reveal the

presence of a foreign body. Staining of the injured area by fluorescein makes a green background in which the object appears more distinctly, especially if the mote has been in some days, when the edges of the wound are macerated and the fluorescein stains more deeply. All ulcers should be subjected to close examination for the presence of a foreign body, which may lie deeply and have been the original exciting cause.

Adherent husks of seeds, sawdust, fly wings, etc., are usually found at the limbus; other particles may be anywhere on the corneal surface. Penetrating objects are usually emery, sand, stone, particles of iron or other metal, glass, thorns, caterpillar hairs, etc. The majority of objects look dark brown against the iris and light against the background of the pupil under direct and focal illumination. By the ophthalmoscope even glass chips appear black against the background of the fundus. Under diaphanoscopy the objects likewise appear black.

If the object is retained long on the surface of the cornea it is usually surrounded by mucous secretion; if in the tissue it may heal thereon or the edges infiltrate and ulceration occur.

Particles of iron rust cause siderosis of a small or large portion of the cornea if they remain long, only recent cases appear glistening gray, older ones are brown from the rusting.

Particles of copper appear reddish-brown and may get greenish from the verdigris forming.

Course and Complications. On removal of the mote and the use of an antiseptic dressing, healing usually sets in with formation of a more or less minute scar. If infection results it may run the gamut of the various forms of ulceration and even cause traumatic interstitial keratitis in syphilitic subjects. Even the most trivial injuries may prove very serious, as has been often noted.

An old man with exophthalmic goitre and inability to completely close his eyes from lagophthalmus was riding in the street-cars when a quantity of dust passed into his eyes; this was wiped out with his pocket-handkerchief and four days later I was called to see him, finding an ulcerative keratitis having already set in in both eyes. His general nutrition being poor, the cornea sloughed away and after a lingering illness of more than six weeks he fortunately died.

Conkey[5] is impressed with the ability of the cornea to withstand infection. He has never met with a case of serious corneal infection in 360 minor corneal injuries. Many of these had first been operated upon by fellow workmen. Most of the cases were working in dirty surroundings. On the other hand he has seen two cases of severe corneal infection following the removal of a foreign body by physicians who had not sterilized their instruments. He concludes that it is more likely that infection germs are to be found upon the instruments of physicians than

upon the pocket-knives of working men. Such is likewise brought out by the observations of Snell.

Iritis is often observed, usually accompanied by corneal infection and hypopion keratitis or onyx.

The Diagnosis is made by the history and results of careful examination under direct and oblique illumination, usually by the aid of the magnifier, and the area of the wound stained, if necessary, in the case of very small motes, by fluorescein.

Acute inflammations of the eye always call for examination as to the possibility of a foreign body being lodged therein.

The Prognosis, in nearly all trivial cases, is good. It depends largely upon infection rather than the size or site of the foreign body and amount of immediate damage to the tissues. Long remaining foreign bodies may cause ulceration. Resultant central scars always reduce the visual acuity. Praun[2] gives statistics of the position of 702 iron splinters in the cornea as follows:

	R.	L.
In upper-inner quadrant	72	76
In upper-outer quadrant	53	40
In under-inner quadrant	78	123
In under-outer quadrant	71	26
	274	303

Therapy. The treatment consists of speedy removal of the foreign body, sterilization of the wound, antiseptics if necessary, and a bandage.

Motes, such as insect wings, husks of seeds, pieces of leaf, sawdust, and some other foreign bodies that simply adhere to the surface of the cornea by atmospheric pressure may be wiped away by a cotton- tipped pledget.

For others where instrumental means are necessary local anesthesia should be obtained by solutions of cocain 5 per cent., holocain 1 per cent., eucain 2 per cent., alypin 2 per cent., which may be freshly prepared from tablets or the stock solutions sterilized by heating from time to time.

When cocain is used the eyes should be kept closed on account of it producing dryness of the cornea and a tendency to erosion of the epithelium. Holocain is more irritating and causes conjunctival congestion, which may be prevented by instillation of 1:10,000 adrin, adrenalin, suprarenalin or other of the suprarenin products.

The removal of foreign bodies under such local anesthesia is entirely painless, and no ill effects should be observed if the drugs are not

used too freely. It should, however, be remembered that idiosyncrasy to their use has been observed, and that minute amounts of cocain and holocain have produced general toxic disturbances. Such, however, should not be confused with hysteric fainting, which is often observed in physician's offices from the mental effect of any procedure that approaches the nature of an operation.

For the removal of foreign bodies on and in the cornea, the patient is seated in a good light facing the source of illumination, or having it reflected upon the eye by a head mirror, or focused by oblique illumination through a lens held by an assistant, or by the patient himself, as recommended by Thorcy,[6] or by the ocular illuminator of the author, or even, par excellence, by the electric-lighted spud of A. C. Snell[7]. The binocular loupe of Berger or Jackson aids in the recognition of the object, which is brought into view by a 2 per cent. sodium bicarbonate fluorescein solution, which stains the abraded surface a brilliant green, forming a bright green background against which the object appears in relief.

The surgeon may stand in front of or behind the patient, as he prefers. The latter should be seated with his head in a rest, or, in an emergency, backed against the wall, as is the custom of the "mote removers" of Sheffield and other manufacturing towns. In quiet patients superficially lying foreign bodies may be brushed away by a cotton-tipped stick or toothpick without a local anesthetic. In most cases, however, numbing the tissues by cocain 5 per cent., alypin 2 per cent., or holocain 1 per cent., is advisable. Even dropping sterile, cold water into the eye will afford a slight anesthesia sufficient to allow of a foreign body being brushed away.

In shops of the iron and steel trades where many trivial accidents happen to the eyes daily, as Simeon Snell[8] says, "in the proportion of one accident to one workman a year," the workmen should be instructed to use a wisp of cotton rolled on a toothpick, and to dispense with the pin, knife blade, horse-shoe nail, etc., or instruments of any kind, contenting themselves with simple efforts to remove the foreign body with the cotton twisted on a stick, which can do little or no damage, and to let the oculist attend to those cases in which the foreign body is not thus immediately removed. Even the general practitioner would be wise to do little more when the services of an oculist are available, for the usual history of cases reaching the oculist is that some of the mechanics at the shops have first tried to remove the foreign body, with not infrequent infection from unsterilized instruments, and further abrasion of the corneal epithelium with infection and ulcer; and the worst cases we have to do with are those that have been unskillfully handled by the patient's mates at the shop, on the road, or by some physician whose eyesight and

manual dexterity were not sufficient to remove the foreign body without causing more damage to the eye than if it had been left alone.

Some of these cases do not come for skilled assistance until several days have passed and a slough has formed in which the foreign body is not visible, and here special instruments are necessary to remove the foreign material, including the sloughing, ulcerating area, as described in the next paragraph.

In undertaking the removal of objects impacted or burned into the cornea, in but few cases is the foreign body so loosely held by the tissues as to be removed by brushing. The patient's eye is then prepared, and he placed in the same position as in the foregoing, the lids held apart by the operator's fingers or those of an assistant. If the foreign body be deeply buried in the corneal tissue, it is sometimes advisable to attempt to pick it out, as attempts to reach it from the surface may end by pushing it into the anterior chamber; therefore, after anesthetizing the cornea, a broad needle may be passed into but not through the cornea, inserting it by the side of the foreign body, traversing the corneal lamellæ until the broad part of the blade is behind the foreign body, when another needle may be used to pick from the surface until it reaches the object, when it can be lifted away.

Should the foreign body have so deeply penetrated that it is feared any attempt to reach it from the surface may end in pushing it into the anterior chamber, a keratome, or broad needle, may be passed into the anterior chamber, pressed against the inner surface of the cornea immediately behind the foreign body and the surgeon can then cut through the cornea layer after layer until he reaches the foreign body, removing it by the spud or by forceps if large enough. The latter cases come under the heading of more serious injuries and are usually best treated in a hospital with subsequent rest in bed. When the foreign body has remained in the cornea for a number of days it is apt to cause a halo of inflammation around, which may extend over the whole of the cornea, its epithelium becoming whitish and swollen, the foreign body ulcerating out, if not too deep, and it is then washed away, leaving the cornea in a condition of ulceration, and when cured leaving behind it opacities which impair the vision. Such cases require subsequent treatment by antiseptics and continuous bandaging, until cicatrization of the wound occurs.

Most small substances may be lifted out by the point of the needle being inserted under them, some have to be cut around, some, and especially iron rust and emery, must be gouged out. The use of the electromagnet for iron particles does not here offer any particular help, although after loosening the object the magnet may be employed to withdraw it, although this is a needless procedure, or to demonstrate that the object is iron.

The conjunctival sac is then douched out with boric solution, the site of the injury wiped out with a pledget of cotton dipped in boric solution, 25 per cent. or 50 per cent. argyrol instilled, or the part dusted with iodoform powder, and a light bandage applied, which may be a wad of cotton behind the patient's spectacles or held in place by adhesive plaster, a special eye bandage or a few turns of a roller bandage.

Powder and dynamite explosions may lead to the impaction of particles of lead, small shot, sand, stone, or other small foreign bodies in the cornea, which may be picked out as in the foregoing.

In a large majority of these minor injuries the patient does not return to be seen by the surgeon. After removing the foreign body and cleansing the eye regeneration usually takes place within 24 hours. The patient should be instructed to keep the bandage on for that time and to return if the eye be at all irritable.

A few unique cases are the following:

A woman had her teeth filled by a dentist about two weeks before she consulted me, and since that time her eye had been somewhat irritable. Examination showed a fine piece of gold impacted just below the pupil. Removal cured the irritation.

Another woman came with a bristle from a hair brush sticking straight out from the cornea.

Another being examined for refraction had a chip of stone, or large grain of sand, imbedded so that the epithelium had grown over it, giving rise to no inconvenience. A large number of grinders, stone-masons, miners, oyster shuckers, etc., have been seen by me with such overgrown and non-irritating foreign bodies.

An unique case is reported by De Beck.[10] A farmer lad in passing through some dense underbrush had been switched in the right eye by a thorny branch. The thorn had broken off flush with the surface of the cornea, being driven almost exactly through the center, and vertically. Its tip reached just to the anterior surface of the lens, and it was already beginning to scratch the anterior capsule. De Beck saw him the day following the injury and found the fragment broken off exactly even with the surface of the cornea. As there was danger of pushing it on into the anterior chamber, or into the anterior capsule of the lens, two fine discission needles were passed through from each side, and then the opposing points carefully inserted into the opposite sides of the thorn. With a slight outward leverage the thorn was brought out a bit, and was then easily removed with a pair of fine forceps. Recovery was uneventful.

It was remarkable that no traumatic cataract developed. The scratches were perfectly distinct, but evidently did not open the capsule.

Only recently there came into my consulting room an Italian gar-

dener who two months before was hoeing in his garden when something flew off and struck his eye, which had been a little sore since. A blackish and glistening object was seen in the depths of an ulcer of the cornea. Application of the giant magnet immediately withdrew an iron chip weighing 10 grains.

LITERATURE.

1. Schwarz, *Arch. f. Ophth.,* XLVIII, 1898.
2. Praun, l. c., p. 180.
3. v. Michel, ref. l. c., p. 180.
4. Dowling, *Journ. Ophth., Ot. and Laryn.*
5. Conkey, *Ophth. Record,* Feb., 1906.
6. Thorcy, *Klin. Mon. f. Aug.,* XLVII, Sept., 1909.
7. A. C. Snell, *Ophthalmology,* July, 1908.
8. Simeon Snell on *"The Prevention of Eye Accidents Occurring in Trades,"* London, 1899.
9. Todd, *Railway Surgical Journal,* Aug., 1906.
10. DeBeck, *Lancet-Clinic,* Apr. 28, 1900.

C. INJURIES FROM BLUNT OBJECTS—CONTUSIONS AND RUPTURE.

a. Contusions.

Etiology. Round, blunt, foreign bodies, usually of some size, as handles of mechanics' tools, stones, balls, etc., as well as shot and bullets coming with slight force (spent balls) may fly against the cornea directly, or the force is communicated through the lids, usually causing bruising, may be with erosion of the anterior epithelium. There often results an extensive opacity of the central portions, lattice or panel-like keratitis, which under the magnifier is seen to be composed of delicate gray striæ interlacing in different directions. This in Descemet's or the membrana elastica posterior. Fuchs[1] says it is dependent upon reduction of the intraocular pressure. If the force has been more severe, causing a dimpling in of the cornea, it may be more diffuse and dense and is here due to a loosening of the true corneal tissue. In still greater injuries the cornea may be infracted or dented in and remain so, as happens occasionally after small stone or shot, non-penetrating injuries.

In contusion opacities of the cornea Wagenmann[2] says the cloudy, deep, contusion opacity is chiefly due to an edema and must be considered a swelling phenomenon of which lesions of the endothelium are perhaps the chief cause.

Symptoms. The tension of the globe is lowered, the ciliary vessels injected. There is tenderness but not much pain, the absence of the latter due to bruising and consequent destruction of the sensitive nerve endings. The sight is always reduced and if accompanied by hemorrhage blindness occurs.

Course. The cornea either clears, or if it does not do so a grayish

opacity remains. Such perhaps is the etiology of child-birth injuries from forceps delivery. If the blow be very severe, contusio bulbi, with chronic irido-cyclitis and degeneration and blindness, may result.

The diagnosis is obtained by the history and subjective and objective symptoms, particularly loss of vision and hypotension.



Fig. 218.
Lattice-like keratitis from contusion.

The prognosis is not good, and extensive secondary changes, even to atrophy of the globe, may occur.

The therapy is rest, atropin and symptomatic treatment.

A case showing these fine radiating opacities was seen by me after a

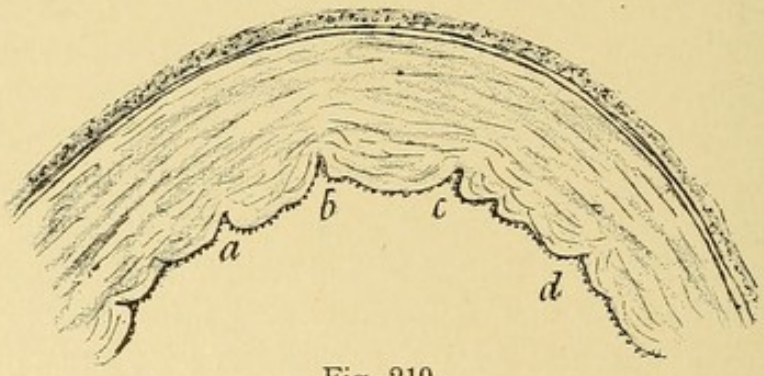

Fig. 219.
Section of cornea showing foldings of membrane of Descemet in panel-like opacity of the cornea, following contusion.

blow from a fist during a fight. This cleared up after several weeks with full return to health and function of the eye.

A girl at a brewery bottling works was injured by a cork flying against her eye and developed this lattice-like keratitis. Degeneration from irido-cyclitis ultimately set in and the sight was lost.

A case where a handle of a plow struck an eye was seen some years

after when degeneration of the globe had ensued with total opacity of the cornea.

Blaauw[3] reports the following case in which he observed this condition: A middle-aged man while automobiling in the country received a charge of peas in the face which prevented use of the right eye for half an hour. The next day parenchymatous opacities were found in the lower half of cornea, with irregularity of epithelium. Thirty hours later the pupil had not dilated under atropin and instillation of fluorescein solution showed the back part of the cornea stained green and a little later the whole cornea stained deeply. Six days later even the endothelium lesion could be demonstrated. Full recovery ensued.

Majewski[4] reports a case of infraction of the cornea. The accident resulted from the slipping of the blades of a pair of bandage scissors. The blade between the bandage and the skin rotated and the

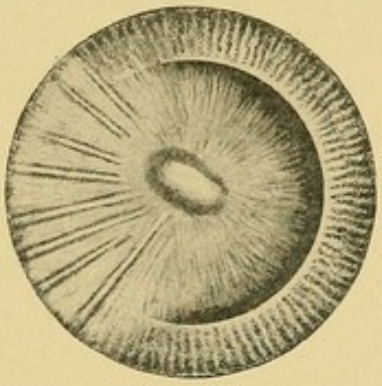

Fig. 220.

Wrinkling or rupture of Descemet's membrane and blood pigment in cornea, resulting from rupture of the canal of Schlemm. Redrawn from sketch by Swan Burnett.

rounded flat end was pressed firmly against the eyeball. The tear extended from the nasal margin horizontally across the cornea, gradually becoming less deep and terminating about 1½ mm. from the temporal margin. The eye recovered with a permanent linear cicatrix, demonstrating how deeply the fracture had extended. The author explains the mechanism of the injury by supposing that the end of the scissor's blade rotated eccentrically and came to bear upon the cornea. The dimpling thus produced was followed by immediate restoration of its curvature through its own elasticity and the intraocular tension.

b. Rupture.

Rupture of the cornea is seldom observed, only a few instances having been reported in the literature.

Etiology. The same causes that produce scleral ruptures, which are more common, prevail here. Blows from fists, large blunt objects,

cow-horns, meat-hooks, wagon-shafts, are the most common, according to Müller, who reported 17 cases from Fuchs' clinic in Vienna. The cornea is more tender under twenty years of age than later in life, only four of his patients being adults.

Mechanism. Müller[5] explains the mechanism of direct corneal rupture, the same as direct scleral rupture, as due to the action of the impinging body being in such a direction and pushing with such force that there is no place for the globe to go. Hence that portion of the capsule which is impinged on by the foreign body is pushed in quickly into the globe, and bursts in, just as the skin of the head breaks under a blow from a cane against the skull.

The cornea or sclera is between the foreign body and the ocular contents, which are then under great pressure, and the tunic has to give way at this place and burst inwards.

Indirect corneal rupture is due, according to Müller, as follows: "The cushion of fat of the orbit protects the globe as far as it is encompassed by it and thus the whole of the posterior portion of the eye is protected so that under the pressure that portion of the sclera not so covered, or the cornea has to give way," and it is usually the cornea, for the resiliency of the sclera is much greater, and the cornea being stiffer is more apt to burst under extraneous force.

Examination. Cases where there has been a cicatrix from previous ulceration are perhaps more liable to such rupture from a blow directly, or from a jar indirectly, and here the rupture may extend from this point. The limbus is perhaps most generally detached, but otherwise there is no typical form in which they occur. In most cases the wounds are straight, but they are sometimes ragged or flap-shaped.

Diagnosis. The differential diagnosis between lacerated wounds and direct rupture is difficult except upon determination of the object producing the injury. Balls, large handles of instruments, etc., are most apt to cause rupture, while sharp instruments, teeth and claws of animals, beaks of birds, cause jagged wounds.

Prognosis. The prognosis is better than in scleral rupture. The outcome, according to Müller, was eight cases good and seven bad. Infection is the main danger.

A young man was brought to me immediately after a fist fight in which his opponent knocked him senseless. The right eye socket was deep and the lids sunken in. The cornea was found to be almost completely detached at the limbus, the iris prolapsed, lens already extruded and vitreous escaping. Immediate enucleation was done.

A case seen with Swan Burnett had an upward rupture of about ¼ mm. on the cornea, and dislocation of the lens under the conjunctiva.

Windle[6] presented a case of traumatic expression of cataract in

the capsule through a corneal rupture from striking the eye against a projecting bar of iron while cleaning a plow. V. with + 9.00 = + 2.00, 165° = 20/100.

Fuchs[7] says rupture of the outer coats of the eyeball are considered solutions in continuity produced by blunt injuries to the eyeball. Ruptures on the corneal border are usually of very small dimensions and are often not considered as such. Typical scleral ruptures are usually 8 to 12 mm. long, while ruptures on the corneal border are usually only 2 to 4 mm. long. These ruptures are usually situated either very near to or in the limbus itself or partly in the cornea; their direction is either directly upward, or upward and inward; the iris is, as a rule, prolapsed, the pupil irregular, the zonula of Zinn, and even the lens capsule, may be torn. Scleral ruptures occur usually in older people, whereas ruptures on the margin of the cornea occur more often in the young.

The prognosis is, as a rule, favorable. It very rarely happens that a rupture is followed by infection of the interior of the eye.

The therapy consists of an excision of the prolapsed iris and the mattress or Nuel suture. If the iris is not excised, vision becomes impaired by the irregular curvature of the cornea and the development of a higher degree of irregular astigmatism; the scar later becomes ectatic and produce an increased tension which may lead to blindness.

De Beck[8] reports a case of traumatic evisceration from gouging of the eye. The right thumb had evidently been thrust in across the front of the eyeball, and then forcibly pushed into the inner angle with the palmar surface against the side of the nose. His idea is that a long, ragged thumb-nail had first cut across or into the eyeball, and then under the pressure it had ruptured along the line of this scratch or cut. There had been a rupture resembling closely the Graefe incision for cataract extraction, only extended about equally inwards and outwards, and with a downward curve. It would have formed a very good upper incision for complete abscission of the cornea, and, in fact, he practically used it for such. The eyeball was turned almost inside out; there were no signs of lens or vitreous, and most of the uveal tract and retina seemed to have also disappeared.

The socket was cleansed with antiseptics; the upper edge was trimmed even; the lower edge was cut off by a corresponding incision, and the cavity was cleared of all remnants and clots and thoroughly swabbed out. A medium-sized glass ball was inserted and the incision closed with seven vertical sutures. The reaction was tremendous, but there were no signs of extrusion. Eventually it quieted down into an excellent stump, and an artificial eye was inserted with most satisfactory deceptive effect.

Coats[9] gives his personal observations on the pathology of rupture

of Descemet's membrane, based on the study of 13 cases of buphthalmos, 8 of glioma with increased tension, and 4 of myopia of high degree. Ruptures were found in all cases of buphthalmos but one. In 8 cases of glioma they were present twice, while he failed to find any in uncomplicated myopia, but found them in one case of myopia associated with glaucoma. The author attributes their absence in high myopia to the fact that in myopia it is the posterior hemisphere of the globe that stretches and not the anterior. Coats states that in microscopic preparations the fissures are more numerous and extensive in the periphery of the cornea where the stretching and thinning is greatest in buphthalmos. In the author's case the endothelium was always intact over the gap, and he believes that the preservation of the transparency of the cornea is due to that fact. He mentions a rare form of rupture in which overlapping of the edges occurs instead of spreading apart, due to a relaxation of the heightened intraocular tension after the occurrence of the rupture. The subsequent changes consist of processes of repair by the deposition of new membranes, or masses of similar substance, from the endothelium, and this occurs in an imperfect manner.

This author gives the essential cause of rupture of Descemet's membrane as stretching of the cornea, and states that the term "elastic" as applied to it is a misnomer and that it is inferior in elasticity to the corneal lamellæ, as evidenced by the fact that when divided it assumes curly and spiral forms instead of retaining its original form.

It must not be forgotten that these clefts are generally seen with ease, both by direct and indirect illumination. Casey A. Wood[10] has published an illustrated account of a case in point.

LITERATURE.

1. Fuchs, *Text book,* Amer. Ed., a. p. 219, b. p. 259.
2. Wagenmann, *Graefe-Saemisch,* 2 Ed. IX, 5, p. 412.
3. Blaauw, *Ophth. Rec.,* and personal communication, 1910.
4. Majewski, *Ophth. Klinik,* March 5, 1907.
5. Müller, *Ueber Rupture der Cornea-scleralkapsel durch stumpfe Verletzung,* Vienna, 1895.
6. Windle, *Ophth. Record,* July, 1910.
7. Fuchs, *Med. Blatter,* Oct. 26, 1905.
8. DeBeck, *Lancet Clinic,* Apr. 28, 1900.
9. Coats, *Trans. Oph. Soc. U. K.,* Vol. 27.
10. Casey A. Wood, *Ophth. Record,* July, 1907.

D. BURNS AND CAUTERIZATIONS.

As a rule not only the cornea but the conjunctiva and frequently the lids and skin of the face are injured by burns and cauterizations. Such are described under the general heading of Thermal Injuries.

Pathology. Symptoms and Course. In simple cor-

neal burns, there is always photophobia, great pain from the injury and exposure of the ends of the sensitive nerves, lacrimation, considerable conjunctival secretion and usually swelling of the lids and chemosis of the conjunctiva, especially about the limbus. As a rule superficial burns are similar in appearance to erosions, though more painful. Depending upon the form of the injury they cause striped, spotted, large or small grayish opaque solutions of continuity of the epithelium and interlayers of the cornea. If superficial the epithelium is eroded, cast off and replaced within one to two days and full healing results. In deeper burns the cornea becomes more opaque and looks like ground glass, the sensibility remains but is diminished. In the very severe injuries the cornea looks like porcelain, and its nerves being destroyed the feeling is totally lost. In the deeper burns a line of demarcation forms, and the neurotic area is cast off, leaving a corneal ulcer. The blood vessels congest and healing ultimately with scar tissue and formation of macula, which may later result in ectasia and corneal staphyloma. All burns of the cornea, except the most superficial, are serious on account of the hindrance to vision. If the circumcorneal zone be injured the nutrient blood vessels are cut off and the whole cornea may come away in a mass.

In the course of healing of superficial and moderate burns vesicles may form which rupture from time to time, with recurrence of pain and other described symptoms.

Sulphuric acid burns of moderate severity are characterized, according to Praun,[1] by formation of phlyctenulæ, especially about the limbus. He found crystals of zinc salt in the pustules as well, as zinc is frequently used in connection with sulphuric acid in the arts. Lye, ammonia, and chemical burns have been sufficiently described under the general heading. Lime burns have been fully described in our general chapter.

V. Guhmann[2] distinguished three grades of lime injuries to the cornea. 1. A hard, nebulous opacity. 2. A thicker ground-glass opacity. 3. A porcelain-like opacity.

The effect of glowing metals depends upon the degree of heat and whether or not the substance remains in contact with the tissues. Melted lead is perhaps less dangerous to the integrity of the tissues than molten iron, and especially molten glass or slag, the latter two forms of which stick to the underlying tissues and cause deeper damage.

Guillery[3] says a peculiarity of the cauterization of the cornea by acids is, that the cornea, soon after the primary opacities, clears up and may remain transparent. After days and weeks the true nature of this suspicious clearness becomes apparent: The cornea has been fixed by the acid, similar to the action of acids on organic tissues as utilized for histiological purposes. Such a cornea is necrotic and without reaction.

Lime, on the other hand, produces a permanent opacity, owing to a chemical combination with the organic substance of the cornea.

Guillery found that this peculiarity of the course of the primary opacity caused by acids is due to their action on the mucoid substance of the cornea. Mucoid is at first coagulated by the acids, and then dissolved. The acids destroy the endothelium of Descemet's membrane, followed by edema of the cornea, which produces the secondary opacities and may lead to ectasia of the cornea and keratoglobus.

Baths of ½ per cent. solutions of hydrate of potash remove the mucoid sediments, and Guillery proved by a number of experiments that the further course is greatly influenced by the neutralization of the acids by hydrate of potash. He thus found in hydrate of potash a very effectual remedy for cauterization of the cornea by acids.

Further experiments with lime showed that this also coagulates mucoid, though less than acids. The resulting opacities can be cleared in a few minutes by a 10 per cent. solution of chloride of ammonium with 0.1 per cent. tartaric acid.

Results and complications. From intense burning, with ulcer formation, secondary iritis with synechiæ results. After the necrosed tissue is thrown off perforation with iris prolapse, formation of cataract, irido-cyclitis, ectasia, or phthisis bulbi, or, in the case of infection, panophthalmitis may result.

When chemotic conjunctiva at the limbus comes in contact with a small ulceration of the cornea it may grow fast and be the starting point for a pterygium. Symblepharon occurs in all forms, primarily from the adherence of raw surfaces on the globe and lids, and secondarily from cicatricial contractions. Ankyloblepharon ensues when the lids grow together. In perforation leucoma adhesions result, staphyloma corneæ with or without complication with the iris, occurs when the structure is so weakened that the intraocular pressure forces the tissue forwards. More or less blindness occurs, depending upon the amount of tissue destruction and the resultant leucoma.

Diagnosis. The diagnosis is to be made from the history of the injury, the finding of particles of lime, molten metal, etc. Heated fluids as a rule affect the conjunctival surfaces more, and particularly the lower part of the globe and the conjunctival surface of the lower eyelid. Fluorescein will determine the extent of the damaged surface.

Prognosis. The prognosis depends upon the grade of the injury and the resultant scar tissue formation. As noted, burning of the limbus is particularly unfavorable, as damage to the nutrient vessels results in necrosis of the cornea. This was particularly noticeable in a lime burn case of mine (cited below).

Epithelial burns are trivial and heal in a few hours. The burn from

molten lead is as a rule lighter than that from other molten metals. I have several times picked out a cast of lead of the eye from between the lids with no permanent damage resulting from the burn. Burns from molten glass or slag are particularly dangerous, as well as those from melted candy, syrup or preserves.

The determination of the sensitiveness of the cornea to touch is a particularly fine point in diagnosis. In trivial injuries the cornea remains hyper-sensitive, in moderate burns it is diminished, and in very dangerous ones that are apt to be followed by necrosis of all the tissue the nerves are destroyed and the cornea is insensitive to touch.

Therapy. The treatment has been fully described under the general chapter on Burns. Especially is the physician to be warned against the use of cocain and the suprarenin products, for these diminish the vitality of the tissues and prevent nutrition. Removal of the foreign bodies, use of holocain for anesthesia, dionin for analgesia, atropin, ointments, and mild antiseptics, cold application at first and then heat, are the indications.

The formation of symblepharon is specially to be guarded against by use of ointments, passing of probes between the globe and lids, Thiersch grafts, egg membranes, lead, gold, aluminum plates, etc.

The treatment of the resultant leucoma, by massage with ung. hydrarg. obid. flav., the Bellarimow massuer, dionin in solution or powder, thiosinamine locally and internally. Vibratory and suction massage and direct sparking from the high frequency current will, with the effect of time and nature, materially diminish the opacities.

For the treatment of the symblepharon and formation of new pupil behind a clear space of the cornea, and other such operations, see elsewhere. Staphylomata may have to be abscised, and lastly the eye may look so badly that for cosmetic and business reasons enucleation and proper prothesis may be preferable.

I have seen numbers of simple burns from heated instruments, as curling-irons, of which the following is a good example.

A lady in a hotel heating her curling iron over a lamp in its manipulation brought the end of it into one eye, intense smarting pain, lacrimation, photophobia resulted in a hurry call to me. Immediate relief by 1 per cent. holocain, 5 per cent. dionin, and healing in 24 hours under 5 per cent iodoform ointment and bandage.

A plumber came immediately after flying melted solder got into his eye, caused by ice getting into the melting pot and producing an explosion. I picked out an almost perfect cast of the aperture of the lids in which the roundish eminence of the cornea could be seen as a concavity. The cast adhered mainly to the eyelashes, which had to be cut away. Healing with no leucoma resulted in 48 hours.

An iron moulder brought to me a chunk of iron which was a cast of the internal canthus, which had been molten and spilled into his eye a few hours before. The skin was only reddened, the caruncle swollen, the conjunctiva of the globe slightly chemotic, the epithelium of the cornea over about a quadrant exfoliated. A few solid drops of metal were picked off the eyelashes and brows. Healing resulted under 5 per cent. iodoform ointment within two days.

Several cases of lime injury were given in a preceding chapter. An additional most severe one is here appended on account of its severity, and in that the prognosis was foretold by the character of injury to the nutrient vessels and by the insensitiveness of the cornea.

A boy was white-washing a fence when some of the fluid got into the eye. On examination three days later, although he had been attended by his home physician, quite a lot of lime was removed by me from the upper lid. The iris and pupil were visible and responded to stimulus; the cornea was absolutely insensitive and at first this was ascribed to a cocain solution which he was using under the advice of the aforesaid physician. The bulbar conjunctiva, and particularly the limbus, was white and dead looking. The eye was not much injected and the symptoms were so slight that the parents at first protested against the case being taken to the hospital. Within a few days, despite hot applications, beef extract locally, good feeding and regimen, the corneal layers gradually peeled off, the cornea became porcelain-like and then the iris again became visible, the lens came out and I did evisceration in order to get a large stump and save as much conjunctiva as possible. Despite these precautions the socket ultimately shrank so much from cicatricial contraction that a prothesis could not be worn until I made a plastic restoration of the orbit after the method of Weeks.[4]

LITERATURE.

1. Praun, l. c., p. 193.
2. Guhmann, *Inaug. Dissert*, Breslau, 1884.
3. Guillery, *Arch. f. Aug.*, LXV, p. 139.
4. Weeks, *Trans. Internat. Cong.*, Lucerne, 1904.

E. GUN SHOT INJURIES.

Gun shot injuries are but seldom limited to the cornea.

Contusions may occur from air rifles, spent shot, particles of lead from bullets which have struck targets or surrounding objects. Pieces of stone, wood, earth, etc., may be carried by the impact of the projectile, especially from cannon shot and bursting shells, and cause such contusions, as well as the other forms of injury noted below.

Perforating wounds of this nature are more common and are always complicated by injuries to other structures.

Ruptures of the cornea and sclera have been reported by Isenschmidt,[1] and also by the German War Office from shell injury.

Arens[2] reported a case of an air gun injury, the ball coming from 3-4 m. distance, which ruptured the cornea. Infection and subsequent enucleation followed.

Foreign bodies, as powder grains and burns, are often seen from gunpowder explosions, flarebacks of small arms and artillery pieces. Particles of lead from the spattering of bullets on a target have been picked out of the eyes by me. In the case of larger-sized, high-powdered rifles, on impact with the iron target, the heat evolved is so great that most of the lead bullet melts, only a "button" usually being picked up.

A marker at a military rifle range came to me with particles of melted lead on his face and in his eyes from this cause. Removal of the foreign bodies was all that was indicated.

Shot wounds of the cornea during war are all complicated and are dealt with under a special chapter.

LITERATURE.

1. Isenschmidt, ref. Praun, l. c., p. 200.
2. Arens, ref. Praun, l. c., p. 200.

F. CHANGES IN THE CORNEA FOLLOWING INJURIES.

Injuries which involve only the epithelium are rapidly filled in, first by pressure of the neighboring cells, later by karyokinesis, healing without leaving opacity. Injuries involving Bowman's membrane are likewise replaced by epithelium. This tissue is never reformed and the thickening is prolonged for long periods. When the loss of substance is greater, involving the superficial lamellæ, the wound is likewise filled in by epithelium which invades every crevice, forming downward, oblique, and lateral processes into clefts and into the interlamellar lymph spaces.

Proliferation of corneal corpuscles occurs as granulation tissue, increasing more rapidly than the epithelium, which is pushed more toward the surface. The downward growths, however, often persist indefinitely. The granulation tissue is partly derived from the walls of the larger vessels, which possess connective tissue adventitia. It is seldom profuse and finally consolidates into scar tissue, dwindling with the development of the fibrous tissue. The bundles of fibers are whiter than the normal lamellæ, so a permanent nebula or leucoma results. Most of the vessels disappear, their walls falling together and forming part of the scar. Some of the larger vessels often persist and carry blood. The epithelium is usually thicker, but may be thinner than normal over the scar. The epithelium may become epidermoid by cornification of the surface cells, especially in anterior staphylomata.

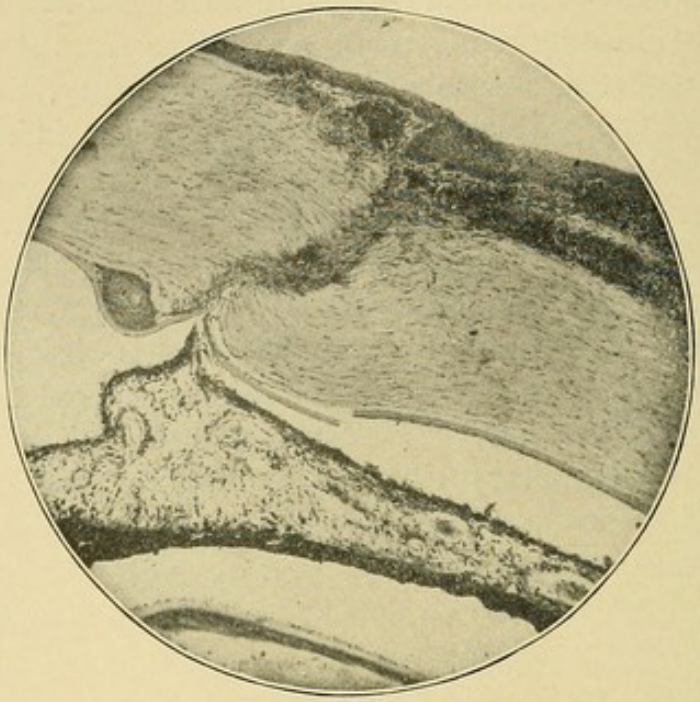

Fig. 221.

Section of cataractous eye removed post mortem two weeks after operation. Healing of corneal incision by primary intention. (Tooke. From a case operated upon by the regular capsulotomy operation.)

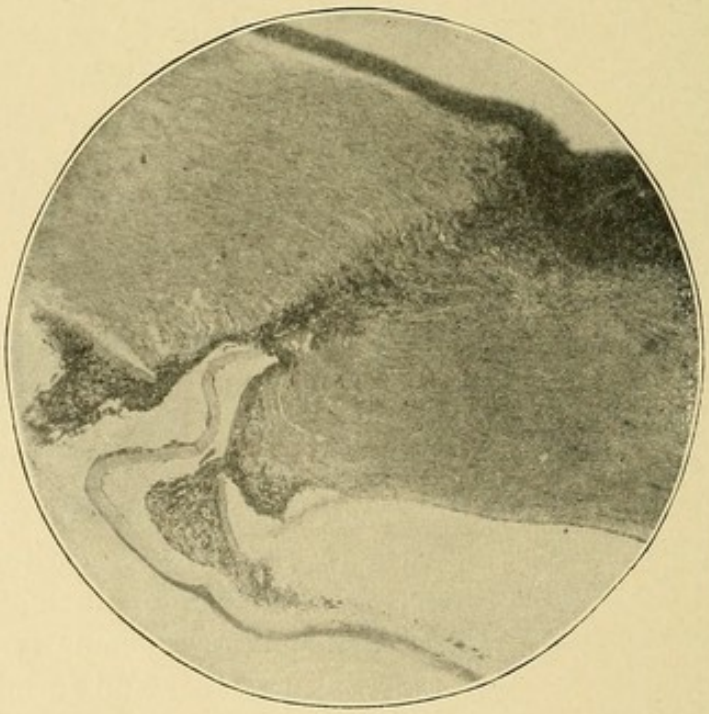

Fig. 222.

Section of cataractous eye removed post mortem. A distinctly weakened globe shown to be due to inclusion of anterior lens capsule. Infiltration of leucocytes in anterior chamber, as well as about the base of incision due to the same cause. (Tooke. From a case operated upon by the regular capsulotomy operation.)

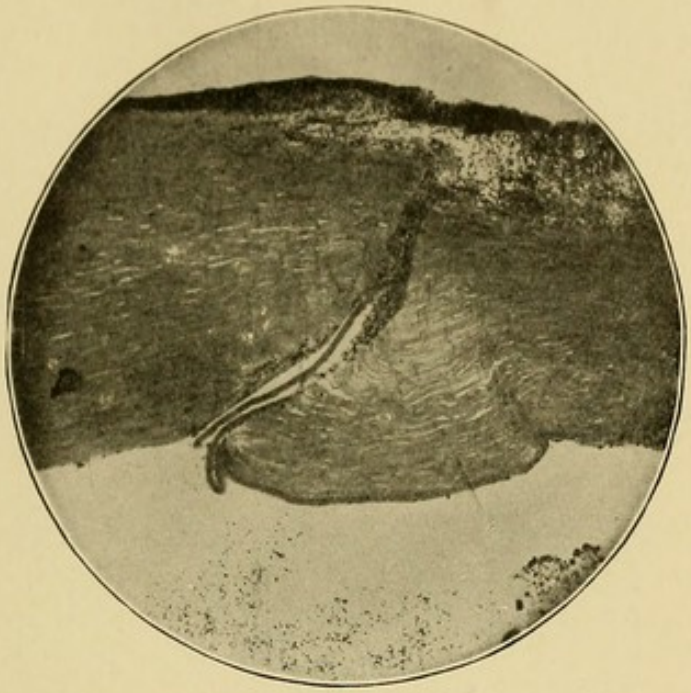

Fig. 223.

Section of cataractous eye removed post mortem thirteen days after operation. Retarded healing due to included membrane between the lips of the corneal incision (Tooke, from a case operated upon by the regular capsulotomy operation.)

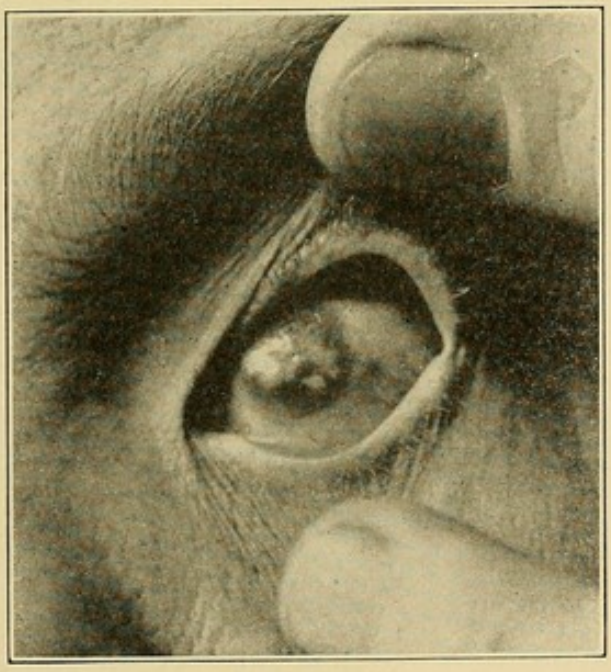

Fig. 224.

Nodular opacity of cornea (nontraumatic). Before operation. (Jobson.)

The process is much the same in penetrating wounds and injuries to the deeper tissues of the cornea. In perforating wounds, Bowman's membrane becomes folded, and the scar between the lips of the wound, which often over-ride, is filled in by epithelium which for a long time

prevents union. It later fills in with fibrous tissue. In such cases there may be likewise impaction of a portion of the iris in the wound, forming the so-called cystoid cicatrix.

Uncomplicated wounds. Uncomplicated incised wounds usually heal by adhesion of the edges in the middle and posterior layers

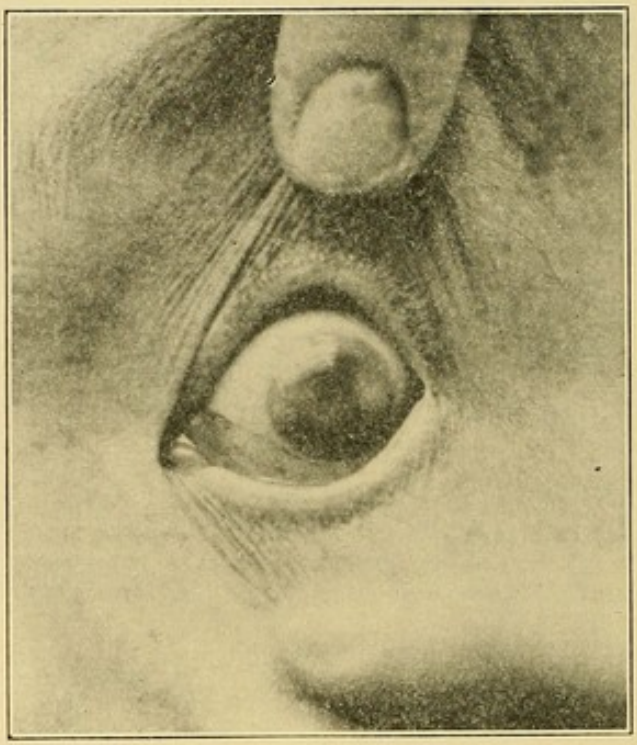

Fig. 225.
Nodular opacity of cornea (nontraumatic), one year after operation. (Jobson.)

Fig. 226.
Nodular opacity of cornea.

of the substantia propria, brought about by inbibition of the corneal lamellæ, whereby they swell so that the cut edges come into contact. The new-formed aqueous contains a larger amount of proteid which forms a fibrinous coagulum. The cohesion begins within two minutes, and is complete within half an hour in favorable cases. It may be delayed to

two or three hours, or even to days or weeks. The anterior cut is quickly filled in with epithelium (24 hours), and karyokinesis occurs at first. The epithelium grows inwards, often half to two-thirds of the way through the cornea. The posterior triangle fills in with endothelium and is covered in three to six days. The cut ends of Descemet's membrane do



Fig. 227.
Calcareous leucoma.

not unite, but a new cuticular membrane, which is usually thinner, is formed by the activity of the endothelial cells. The cut ends may not unite in a scar for even six or seven years. (O. Becker[1]).

Complicated wounds. The most frequent complication is some foreign body between the lips of the wound, usually the iris, lens, fibrous capsule, or vitreous, rarely the cilia or detached retina, or some

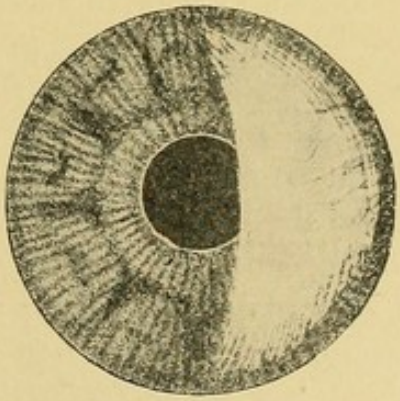

Fig. 228.
Calcareous leucoma.

extraneous foreign body. Cystoid cicatrices are formed by the scar tissue not being strong enough to reunite under the intraocular pressure. Its walls consist of epithelium and the layers of scar tissue, and the retinal pigment layer of the iris.

Wounds of the cornea are often accompanied by striate opacities, less commonly by filamentary keratitis, and in the case of infec-

tion by changes due to ulceration of the edges of the wound and proliferation of the cells. Scar tissue is always formed which shows later as an opacity of the cornea.

Edema of the cornea, or desquamation of the epithelium, is characterized by uniform haze with marked dullness of the surface, which, when magnified, shows uneven epithelium, in advanced cases minute vesicles are formed. (Vesicular keratitis).

These may increase in size and form bullous keratitis. As the layers of the cornea become affected, the epithelial cells are desquamated, the nerve cells become vacuolated, fluid gets between them, exudation occurs between Bowman's membrane and the surface lamellæ, and there is separation of the lamellæ by fluid. Descemet's membrane remains unchanged, but the endothelium is often affected. The liquid effused in and between the cells diminishes their coherence, in that the surface cells fall off. After the elimination of the surface cells, the surface is usually uneven, and shows stippled, in blood appearance, seen clinically. Instillation of cocain, especially if the lids be not closed, causes the epithelium to become black and dull and thrown off. The surface layers swell, become loosened and detailed, and the basal cells change into a light mass with shrunken nuclei scattered here and there, in consequence of which the whole epithelium becomes detached from Bowman's membrane and exfoliates.

Opacities of the cornea.

Linear wounds are almost always followed by linear scars which are usually white and may interfere with the visual acuity, depending upon the position of the wound and production of astigmia. If the scar be in the visual zone the amount of diminution of acuity of vision will depend upon its extent and thickness. If in the periphery of the cornea, upon its extent and the amount of contraction of scar tissue, by which astigmia may be produced. This is commonly noted after cataract extraction, the astigmia usually being 6 or 8 D., at an axis of 180°, and changing soon after the operation to one or two, or less, after complete healing has taken place. The production of this form of astigmia depends largely upon healing of the wound, and especially upon exact coaptation of its edges.

Injuries of the corneal tissue, especially those produced by jagged wounds or ulcerations following injuries, produce nebulæ which vary from translucent, almost transparent, patches of scar tissue to leucomata which are thicker, translucent, but never transparent, and are usually large opacities. These opacities often take the most bizarre forms and may, as before noted, undergo amyloid and calcareous degenerations.

If such scars yield to intra-ocular pressure the various forms of keratectasia may be produced.

The clearing of corneal cicatrices.

After months or years cicatrices may more or less clear up and small ones become altogether invisible, the extent of this clearing de-

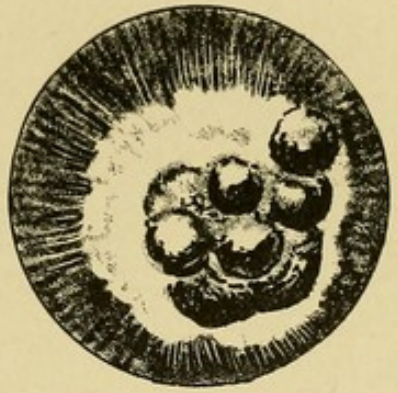

Fig. 229.
Keratocele following extensive corneal ulceration.

pending upon the thickness of the cicatrization tissue and the age of the individual. The deeper the cicatrix penetrates into the cornea the less is to be expected.

Cicatrices of the cornea, be they ever so small, usually remain opaque.

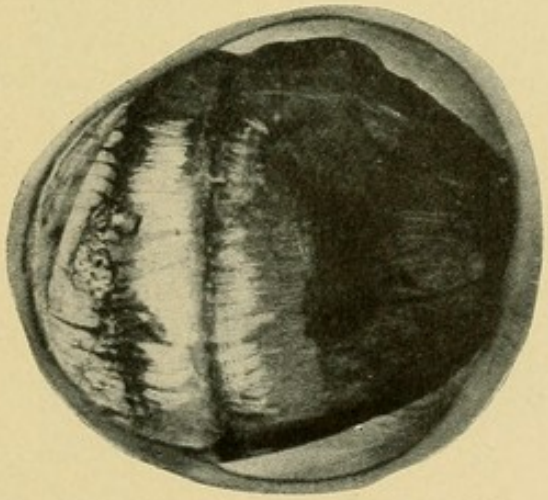

Fig. 230.
Buphthalmos following corneal ulceration.

Discission wounds remain visible as gray points in the cornea during life. The age of the individual influences the process of clearing, so that the younger a patient is the more clearing of a leucoma may be expected, as is often seen in leucoma left after ulceration from ophthalmia neonatorum.

Anterior synechia or protuberant cicatrix, arising from a prolapse of the iris, while usually due to perforation of an ulcer, may follow a perforating wound. The primary impaction occurs at the moment of the prolapse of the iris, cicatrization following, and in the case of a small prolapse, may lead to a flattening of the scar, the soft cicatrix

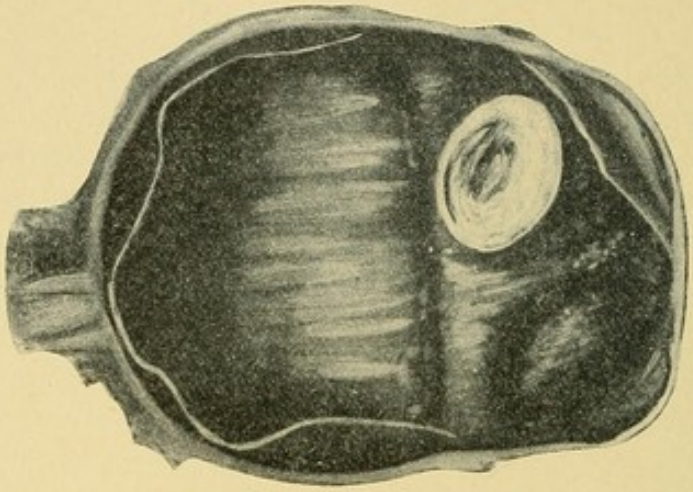

Fig. 231.
Great sclero-corneal staphyloma following ulceration.

yielding to the normal tension; however, the latter is generally raised, owing to the prolapse of the iris blocking the opening of the anterior chamber, while the internal tension rises, the cicatrix protruding still more, leading to staphyloma.

Partial staphyloma is usually conical and may extend to the margin of one side. Total staphyloma is usually hemispher-

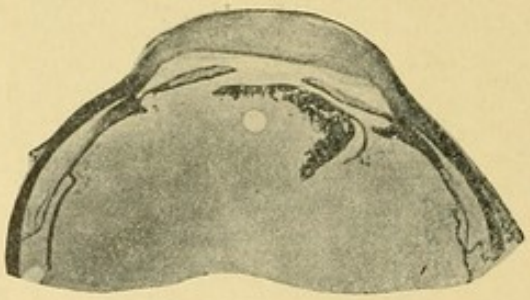

Fig. 232.
Thickened corneal leucoma following a non-perforating ulceration.

ical, with a rim of cornea around the staphyloma. The thickness of a staphyloma varies greatly. In some cases the cornea becoming quite thick, in others thinning greatly. Bands of cicatricial tissue may develop and a grape-like staphyloma be produced. The epithelium is usually very thick, showing downward growths, or full of papillæ, or it may become carnified. Various degenerative changes occur in the epithelium, espe-

cially over calcareous deposits, and ulcers may occur. The scar tissue consists of a very dense, fibrous tissue with spaces, calcareous deposits, and pigment. Sometimes hyaline degeneration occurs. The anterior chamber is often obliterated while the posterior chamber is enormously enlarged. The ciliary body and iris are atrophic and the lens is often ab-

Fig. 233.
Staphylomatous and thickened pseudo-cornea.

sent, having been expelled when the perforation occurred, or absorbed through the formation of traumatic cataract. It may be cataractous and shrunken, sub-luxated, or have other changes. The other parts of the eye show changes depending chiefly upon the secondary glaucoma.

Keratectasia is a protrusion of the cornea, following inflammatory processes without perforation. It consists of corneal tissue with

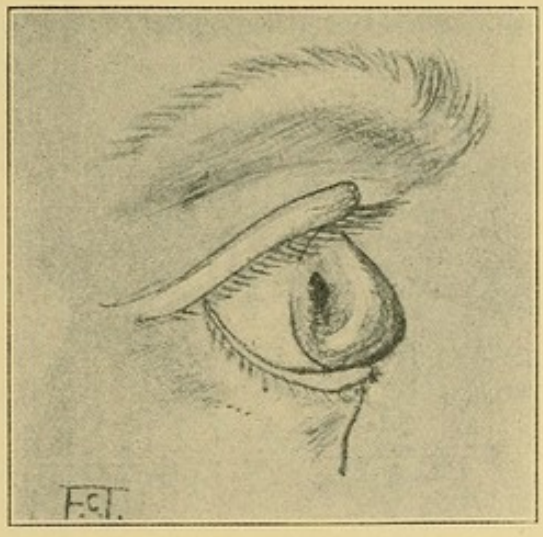

Fig. 234.
Keratectasia, with transparent cornea. (Todd.)

no protrusion of iris. If only Descemet's membrane persists and keratocele is produced, it may cicatrize in the form of keratectasia. It then forms a transparent vesicle above the surface and may form a ring of opaque cicatrous tissue. The cicatrix is usually thicker than the cornea.

Such a case was seen[2] in which there was a clear miniature cornea

engrafted upon a clear cornea. A few weeks after observation her child injured the ectasia, rupturing it by the finger nail. Recovery ensued with better vision than at first.

Keratoconus, or conical cornea, is a form of keratectasia, in which there is a gradual thinning at the apex. The path-

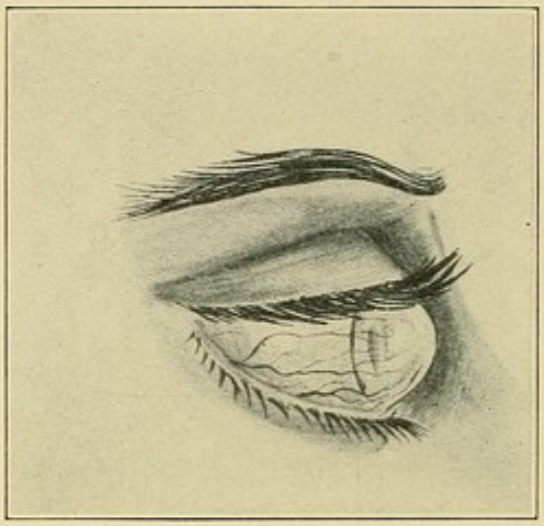

Fig. 235.
Conical cornea from keratitis-traumatica.

ology is purely theoretical, the main theories being increased intraocular pressure, mal-nutrition, diminution of resistance of cornea, inherent weakness, defective embryological development, chronic disease of Descemet's membrane and endothelium, greater extra-ocular than intra-ocular pressure, etc. (Parsons.[3])

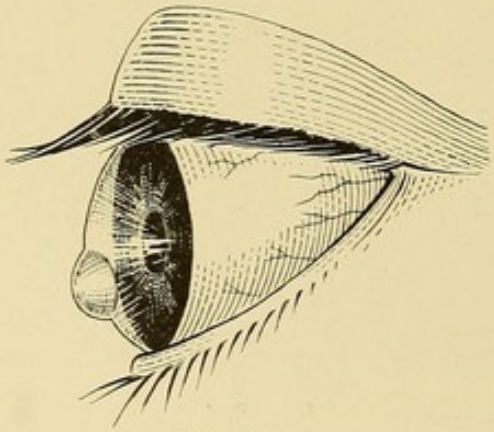

Fig. 236.
Semi-keratoconus.

Todd[4] reports a unique case of transparent ectasiæ which was practically a keratoconus in a man aged 60 who was injured in battle in 1860, after which both his eyes became inflamed. The patient presented a ghastly appearance. The corneæ dropped out of the lids like two

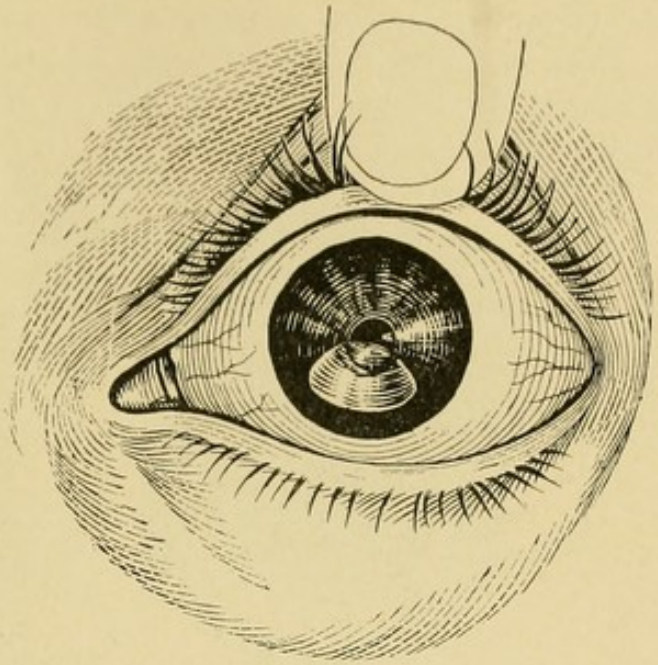

Fig. 237.
Clear corneal ectasia.

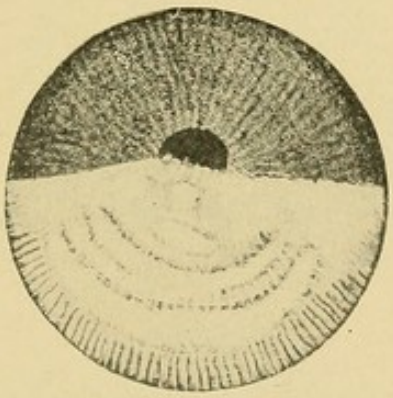

Fig. 238.
Traumatic keratitis from burn by hot cinders.

pouches distended with water fastened to the scleræ and supported beneath by the lower lids.

LITERATURE.

1. Becker, ref. Parsons, Vol. I, Part 1, p. 154.
2. Würdemann, *Ann. Ophth. and Otol.*, 1894.
3. Parsons, *Pathology of the Eye*, Vol. I, Part 1, p. 155.
4. Todd, *Ophth. Record*, Jan., 1898.

G. SPECIAL TYPES OF CORNEAL DISEASE FOLLOWING INJURIES.

a. Striate opacity or keratitis.

As a rule this is traumatic and presents a series of fine gray lines running nearly parallel through the edge of the wound towards the center of the cornea. It is one of the common sequelæ of cataract extraction.

Etiology. Operative and other wounds of the cornea which do not immediately coapt, and particularly those in which the patient has been under the influence of cocain or strong solutions of antiseptics, are apt to develop this phenomena.

Patholgy. Microscopically there has been found by Becker[1] marked widening in the tissue spaces in the cornea, especially in the

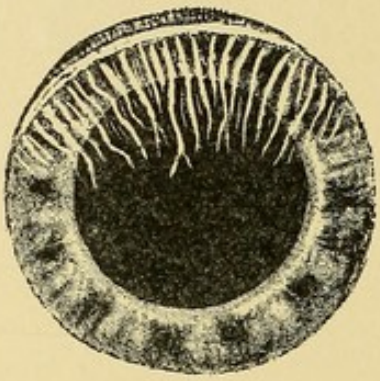

Fig. 239.
Striped keratitis after cataract extraction.

deeper layers. Schirmer[2] and Hess[3] have found the folding due to increase in tension of Descemet's membrane.

Holmes-Spicer[4] regards some cases as due to edema of the posterior layers of the cornea. Varieties of stiriate opacity occur in which the stripes are not parallel but cross each other in all directions like crumpled paper. This is due to folding of the deeper layers, and is found

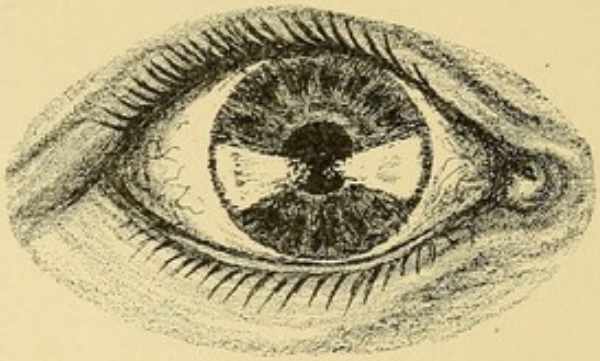

Fig. 240.
Keratitis bandeletta.

especially in cases of detached retina that have been treated by firm bandaging.

Hulen[5] reports a case of striped keratitis going on to general opacification, which could not have been due to any of the usual causes, as use of bichloride of mercury, traumatism during operation, or bad general condition of the patient. The other eye had been operated by

combined extraction years before and showed a similar condition, the line of section being completely white and opaque, and the cornea rather thickly, but entirely, opaque with patches of greater density. The con-

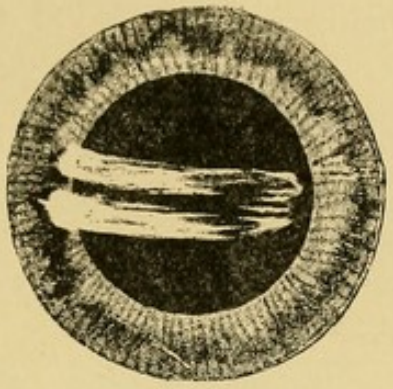

Fig. 241.
Band-like keratitis.

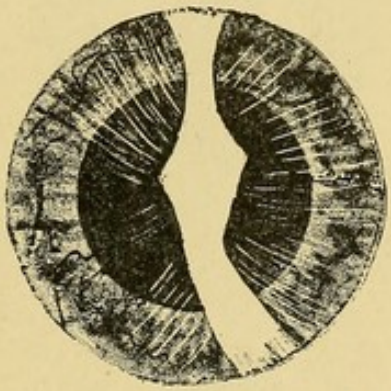

Fig. 242.
Band-like ulcer.

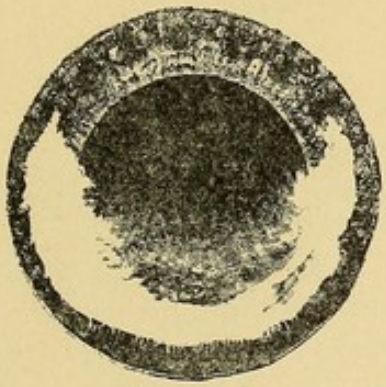

Fig. 243.
Zonular keratitis.

dition is extremely rare. Treatment is of no avail, and the causes are unknown. Where the condition has followed extraction in one eye it might be well to consider the danger of a similar operation on its fellow and have recourse to some other method, such as couching. In the dis-

cussion, attention was called to the fact that this condition may develop from striate keratitis, to the importance of traumatism due to a small section and consequent pressure in delivery, and as an etiological factor, the rôle of strong antiseptics, such as bichloride and carbolic acid, even in ointment form, and to the therapeutic value of dionin in the early stage of corneal opacification.

Still other forms are found after operation and injury, due to imbibition, thread-like, filiform, panel-like, band-like, etc., which occur in an edematous cornea where there are opacities, divided into separate areas by striate dark or white lines.

In hypopion ulcer and other ulceration there are other striæ which

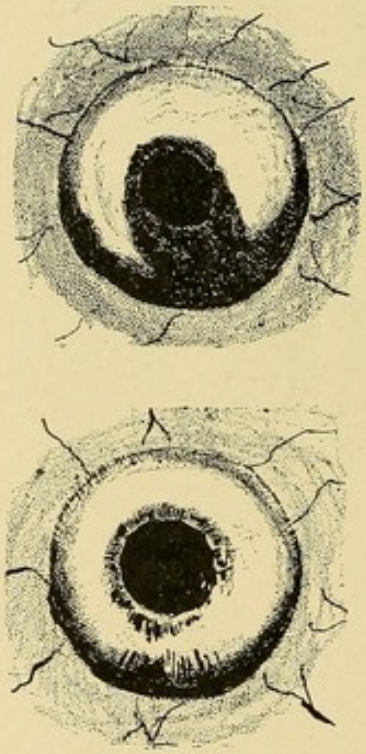

Figs. 244-245.
Annular sclerosing keratitis.

do not branch and are usually due to the crinkling of Descemet's membrane.

H e a t h[6] discusses the condition variously described as calcareous film, band opacity (Graefe), or ribbon-shaped keratitis. It may be primary or occur in eyes blind from glaucoma or irido-cyclitis. The opacities are punctiform and crowded together, forming a gray stripe across the cornea, occupying the exposed portion of the lid fissure. The disease progresses slowly. Sooner or later both eyes are involved. In some cases there are attacks of severe pain, but ulceration is never observed. Most cases were in men over 25. The pathologic basis of the condition is a hyaline degeneration of corneal cells that later become calcareous.

Gout, renal disorders, loss of vital energy in the cornea through vascular changes, repeated irritation of the surface of the eye, as by foreign bodies, are etiologic factors. Graefe noted a resemblance to glaucoma and bad effects of atropin. Sight has been improved by scraping the cornea and by iridectomy. Carbonate of soda, nitric acid, hydrochloric acid, 5 per cent. have been recommended. In Heath's case, scraping and weak applications of carbonate of soda solutions were of no avail. Iridectomy resulted in vision of 15/lx, where the patient had been unable to get about alone.

Striate opacity in which Bowman's membrane is folded has been observed by Schirmer and Parsons.

b. Filamentary keratitis.

This sometimes occurs after operations and wounds. Fine filaments appear upon the cornea, two to four mm. long, firmly attached at one end,

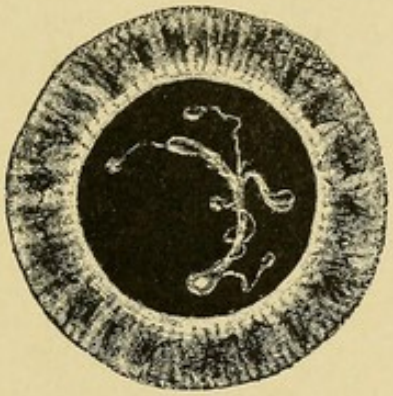

Fig. 246.
Filaform keratitis.

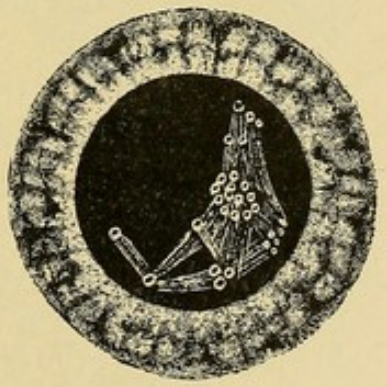

Fig. 247.
A typical filamentary keratitis.

the free end having a knob. These are due to coagulation productions from the conjunctival sac or fibrinous coagula directed from the fluids of the inflamed cornea. The free end becomes twisted from the move-

ment of the lids. Hess[9] describes a form of filament which occurs only at the site of discission wounds not attached to the epithelium, but passing deeply into the wound, and is attributed to vitreous which engages in the puncture.

As noted in the paragraph on edema of the cornea, vesicular and bullous keratitis may arise from the formation of vesicles and blebs in the epithelium.

c. Hemorrhage.

Bleeding into the cornea is rare and is due to the transudation of blood between the corneal layers. A few such cases have been seen by

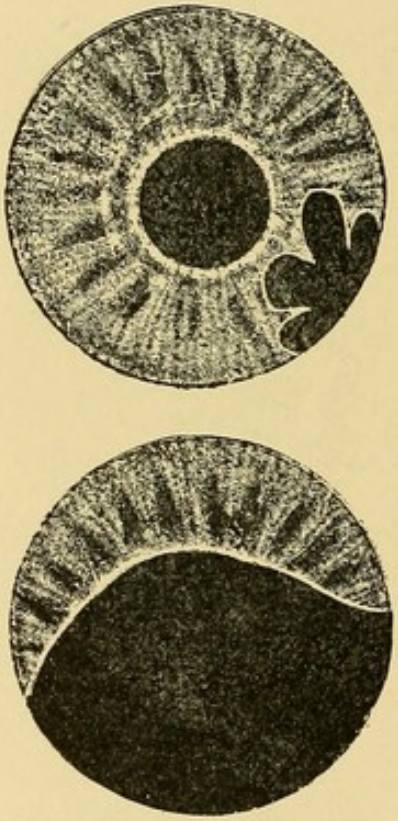

Figs. 248-249.
Hemorrhage into cornea. (DeBeck.)

me after accidental injuries, as after the impaction of a pencil point at the limbus, which was edematous and suffused with blood. The appearances at first were of a bright red clot. Later as the blood became absorbed the spot grew brownish, and later greenish-brown, which may remain for a long time as in a case reported by Casey A. Wood.

The following case has been reported in detail by De Beck.[10]

Hemorrhage into the anterior chamber is observed frequently enough, and a splash of it may often appear to careless observation to be in the cornea itself; but a hemorrhage that is actually between

the layers of the cornea itself must be extremely rare. Such a case we have recently had the good fortune to have under continued observation during the development of the successive stages of the condition.

Patient was a railroad man, and the day before had been struck in the left eye by a flying cinder from the engine. The eye had been painful, and vision was beginning to be badly blurred. The outer zone was intensely congested, and at the lower-outer margin there was one distinct enlarged vessel that passed up sharply to the corneal margin. There was a peculiar four-leaf-clover-shaped hemorrhage into the cornea. The next day this had enlarged in all directions, but was still rather regularly tri-lobed. The upper lobe had reached the edge of the pupil. The next day the area had increased to an almost rectangular patch, involving near-

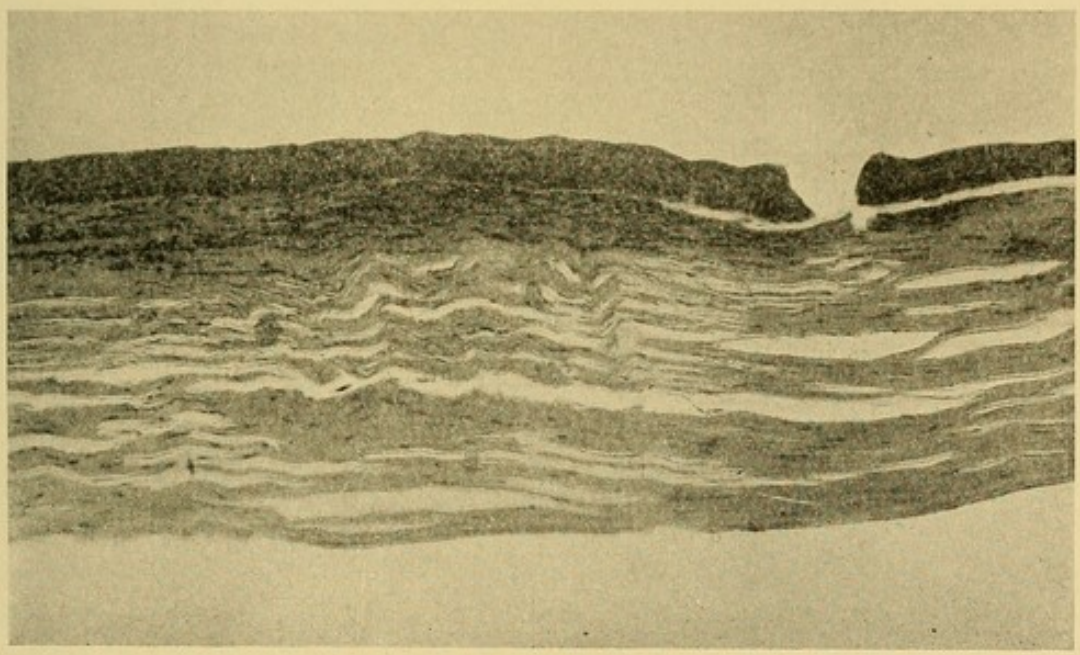

Fig. 250.
Blood staining of cornea. (Wells.)

ly the lower half of the cornea. The tint had changed from a bright-red to a dark-red, with a bright-red streak still showing.

This hemorrhage was unquestionably in the cornea, and evidently was a dissection between the cornea proper and the membrane of Descemet. Oblique illumination and inspection well from the side showed clearly the anterior chamber empty and the entire iris clearly visible. By similar inspection, far to the side, the smooth, shining posterior surface of the red patch could be readily made out. Between the red patch and the observer the cornea lay like a thin zone of delicate fog. Even in the later stages, with the head thrown forward so that rays could enter the pupil over the upper edge of the patch, vision was very good; only clouded, due to the delicate infiltration of the cornea in general.

The final outcome was some pigment stippling into the cornea.

Blood staining of the cornea. Three cases of staining of the cornea with blood pigment out of fourteen reported in the literature have been examined microscopically.

In all cases there seems to have been extensive hemorrhages into the anterior chamber at first, some of these following wounds which have not involved the cornea. The whole cornea appears to be involved at first, but after a few days the periphery clears and complete absorption takes place in some months, or after a year or two. The coloring is of



Fig. 251.
Blood staining of cornea. (Wells.)

soluble hemoglobin which deposits in the tissues, and hematoidin granules. In a few cases the iron reaction shows that the deposit is hemosiderin.

Bomgartner[11] in 1883 reported the first case, followed by Lawford,[12] Vossius,[13] Weeks,[14] Treacher Collins,[15] Wadsworth,[16] and David Wells,[17] completing the list of observers.

The latter's case was in a woman, age 43, with double syphilitic iritis, energetic mercurial treatment being given. Gummata developed with plus tension, for which, some six months after first seeing the case,

a sclerotomy was performed, four punctures being made. Three days later the anterior chamber was full of blood. A month later anterior clearing on the upper side; the rest filled with brownish mass. This changed in color until one year later the deposit was slatey white. Three years after first receiving the case enucleation had to be done on account of pain and irritation. Histologic examination showed slit in the epithelial layer of the cornea, which may have been made by the operation. Pigmentation of anterior fifth of substantia propria, with fine round oval bodies somewhat larger than bacteria, stained a bright-red when observed, limited anteriorally by Bowman's membrane.

Richter[18] reported blood-staining of the cornea in an infant, which had been caused by ophthalmia neonatorum. The child had universal cyanosis. The cornea appeared blank and reflecting, but completely opaque and of a bronze color.

Kerry[19] reports a man 20 years old struck several weeks previously on right eye by base ball. Taken to hospital, but left as it was proposed to remove his eye, then consulted Kerry. Cornea uniform rusty-red color and opaque except at the limbus where there was a semi-transparent seam too narrow to admit of examination of anterior chamber or interior of the eye. Light perception good. Palliative treatment. The clear seam gradually grew larger, fifteen months later the opacification and staining only showing in the center, absorption having taken place from periphery. Irido-dialysis.

d. Metallic oxides in the cornea—iron, copper, lead—siderosis corneæ.

Brownish rust deterioration of the cornea following injury was first reported by Bunge,[20] who made microscopic and chemical examinations of excised pieces. I have seen a number of these cases, in all of which the discoloration followed many minor injuries in the cases of grinders, and in which the discoloration took the form of a ring about each little seat of retained particle of rust. No treatment was instituted and none is recommended in the literature.

Siderosis of the bulb, especially the iris, lens, retina and vitreous has been frequently observed.

Oxide of copper in the cornea. The possibility of being struck in the eye with oxid of copper while walking or driving in the public highways did not exist until that period of the present age when the overhead trolley wire system was introduced into use as a means of conducting and applying the electric current as motive power. As the wheel of the trolley pole runs over the plates of which the hangers and switches are made, there is always some combustion. Ordinarily this is invisible and insensible, but under any influence which makes poor or interrupted contact, the copper is detached, immediately oxidized, and

thrown off in brilliant sparks. The substance of the sparks thus emitted is always oxid of copper, when there is some mechanical abrasion on the wire or on the hanger, in which instance the spark substance consists of either pure copper from the wire, or a poor grade of bronze from the trolley wheel. The substance of these sparks occasionally strikes the cornea, and always becomes deeply imbedded.

Oxid of copper is a body which does not scratch, as it is smooth, and often is almost buried beneath the epithelial cells. The ciliary injection, pain, and photophobia are intense, until every vestige of the copper is removed.

E. G. Rust[21] reports a case of a lady suffering acutely from "having just been struck in the eye by a spark from a trolley wire as she was running her automobile by a street-car under a number of intersecting wires."

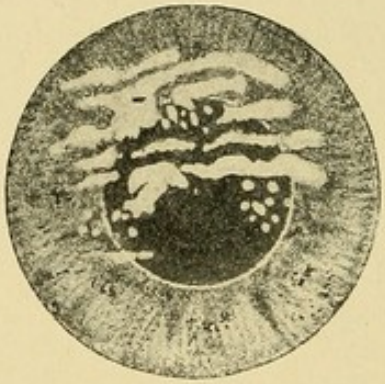

Fig. 252.
Lead opacities in cornea.

On examination he found a brownish-black circular body about 1 mm. in diameter, smooth on its outer surface but with its under side raggedly spreading into and beneath the corneal epithelium. "To the contact of my instrument the foreign substance seemed like half-rotten rubber. It was very clinging and difficult to remove, and found to be oxid of copper."

Twenty-six other persons had come to him with oxid of copper in the cornea. Twenty-five came with the statement of having "been struck in the eye by a spark from a trolley wire." One, that "he had in his eye a spark which flew from the wire of a traveling electric crane." In four cases the copper had been imbedded in the cornea for more than a week. In one only was there any tendency to ulceration.

Lead incrustations. The application of lead preparations, although but seldom used by the ophthalmologist, is still very common with the laity and the general practitioners; the direct result of the fre-

quency with which it was formerly prescribed for any and all ocular injections. The evil results of this indiscriminate use has caused the modern ophthalmologist to pronounce the lead preparations as more harmful than beneficial. As is well known the danger lies in the use of lead acetate in the presence of an abrasion of the corneal epithelium, due to a slight ulceration, a burn, or any superficial trauma.

Fernandez[22] extols the benefit of the proper use of the acetate of lead in conjunctival injections, but warns against its indiscriminate instillation and advises a careful inspection of the corneal epithelium in all cases.

In deep ulcers the author has never noted any bad results. The corneal lesion is due to the formation of the albuminate of lead, a bluish-white opacity not always easily distinguished from the ordinary leucoma seen every day. In some cases the true etiology is suggested by the presence of photophobia, although there is no corneal or conjunctival injection, and in others photophobia may be wanting and the patient complains of epiphora and consequent troubled vision.

Kursle,[23] who attributes the corneal opacity to an albuminous combination of the metal, holds that it can be dissolved by applying a solution of iodid of potassium, and so forming a soluble iodate of lead; he reports good results in fresh cases, and in old opacities he advises a preliminary removal of the epithelium. Fernandez used the above method of treatment in two cases, but without result and finally had to resort to a surgical interference, i. e., the removal of the entire opacity.

The corneal lesion was determined to be due to the instillations of some collyrium containing lead, prescribed by a physician or the laity after some trauma with abrasion of the corneal epithelium; relief of the annoying symptoms was obtained by complete excision.

Schiele[24] has succeeded in removing fresh lead deposits from the cornea by applying to the ulcer, by means of cotton pledgets, a 3 to 5 per cent. solution of iodid potash, followed by the immediate application of a 3 to 5 per cent. solution of iodic acid. By this method nascent iodin is liberated, which penetrates the affected tissue, exciting a local leucocytosis. In this manner the lead albuminate and other salts are loosened, and removed, partly by chemical and partly by mechanical means. Old cases would probably require primary curretting.

A marked example in my practice was in the case of an irregular practitioner who was then about 60 years of age. He said that at birth he had ophthalmia, which was treated by lead and opium wash. He had never seen well. The deposit was even now well marked and he allowed me to scrape some of it away. The epithelium speedily regenerated and his visual acuity was somewhat improved.

e. Cysts of the cornea.

Small perforating wounds of the cornea, as a rule accompanied by the retention of a foreign body, have been reported by several authors to have caused implantation cysts, which are yellowish and occupy the outer layers of the cornea.

In one case which I observed there was not only a cyst of the cornea at the proximal end of the cilium, but at the distal end a large cyst of the iris had likewise arisen. A case has also been reported by Leviste.[25]

Therapy of complications following injuries. As a rule the conditions just described disappear in the course of a few hours or days. Striate keratitis needs no treatment except time. In filamentary keratitis the filaments may be lifted away by the forceps and simple cleansing treatment instituted.

A cyst may be removed from the cornea, and all foreign bodies should be taken away as soon as seen. The treatment of maculæ and leucomata of the cornea is, as a rule, disappointing, except in young persons where Nature may grow new normal tissues and cause absorption, in part at least, of cicatricial tissue. Massage of corneal maculæ has been practised since the beginning of the art, more especially with irritating or alterative ointments. The instillation of calomel powder and massage with yellow oxide of mercury ointment is a common procedure. The application of dionin, either in solution or in powder, causes a rapid edema, notably of the conjunctiva, but also of the epithelium and outer layers of the cornea, and the rapid exosmosis of fluids thus results in some absorption of scar tissue. The irritating effects of thiosinamin in solution or ointment are likewise beneficial. Thiosinamin is given internally in doses of .01 gram to .05 gram a day, and causes the absorption of cicatricial tissue. Local mechanical massage, either directly by stroking the cornea with a glass rod, or by the Bellaramow massuer, by suction massage, as with the Pynchon pump, and by the fingers or vibratory massage through the lids, is practised. The use of galvanism has in some instances been efficacious, assisting materially in removing obstructions to vision.

Of special importance must be noted the application of sparks from the high frequency or vacuum electrode, which produces a certain amount of local irritation and perhaps some electrolysis of the tissues, thereby causing a disappearance or a mitigation of the opacity.

The treatment of the forms of keratectasiæ is surgical and is described elsewhere herein.

Corneal grafting.

Zirm[26] has given the opinion that corneal grafting is the substitution, for optical purposes, of transparent corneal tissue for opaque

corneal tissue. Risinger,[27] in 1884, was the first one to express the opinion that a human cornea could be substituted by a cornea from some other animal; this he called "keratoplasty."

After reviewing this history of keratoplasty, the author reports his own case, which showed good results, and arrives at the following conclusions:

1. A cornea of a young individual only should be used as a substitute.

2. The exclusive use of von Hippel's trepan for the operation; if there is an anterior chamber, eserin instillation should be resorted to.

3. Deep narcosis and no antisepsis.

4. The flap is to be held between two pieces of gauze, which have been moistened with physiological salt solution above a warm vapor; no instruments are to be used.

5. The transplanted flap is fastened by two sutures in the form of a cross, pierced through the conjunctiva bulbi.

6. Only centrally located scars of the cornea are proper cases for the performance of keratoplasty.

He reports a case of successful total keratoplasty. The patient was a man who had total bilateral leucomata as the result of a lime burn. In the R. E. V. = inability to count fingers; L. E. hand movements. The grafts were obtained from the cornea of an eye removed from a boy 11 years of age after an unsuccessful attempt at extraction of a piece of steel from the vitreous. The foreign body had entered the eye six months previously. There was a small marginal adherent cicatrix. A 5 mm. graft was removed from the periphery of the cornea and transplanted into the more opaque cornea (R. E.). A similar disc removed from the center was implanted into the cornea of the L. E. The grafts were held in place by two conjunctival sutures crossing the disc at right angles. Because of the occurrence of glaucomatous symptoms a few days later the cornea (R. E.) had to be abscised. In the L. E. the graft remained clear, and eight months later the following condition was noted: Superficial vesesls in the cornea extending from the limbus to the margins of the graft; cornea gray-white; fine gray band separating the graft from the cloudy cornea, within this the disc was clear and transparent; a crescent of blue iris tissue shows through the upper part and is apparently attached thereto; through the disc the details of the healthy fundus could be made out; V. = + 5 D. 3/xx, + 7 D. Jr. 13. The author believes that success was in a measure due to the favorable conditions existing in the eye from which the graft was obtained and the one to which it was transferred. He further believes that the vessels leading from the margin of the cornea up to the edge of the graft was a factor. He believes by bringing about such a condition previous to implantation a

higher probability of success would be attained. He would accomplish this by the following method: 1. A few weeks previously mark out a circle in the center of the leucoma at the site of the subsequent trephining with a 5 mm. v. Hippel trephine. 2. Dissect off the superficial layers of the cornea between this point and the conjunctiva. 3. Circumcise and dissect up the bulbar conjunctiva. 4. With sutures bring the conjunctiva over the denuded corneal ring.

The following points contribute to success: 1. Proper conditions for grafting. Exact coaptation of the margins of the disc with the surrounding corneal tissue, to obtain which the operation must be completed with the v. Hippel trephine, without the use of scissors. 2. Keeping the graft in normal physiologic salt solution; its transplantation without the use of instruments; its fixation against a vis a tergo.

LITERATURE.

1. O. Becker, *Atlas d. path. Topog. d. Aug.*, 1878.
2. Schirmer, *Arch. F. Ophth.*, xlii, 3, 1896.
3. Hess, *Arch. F. Ophth.*, xxxviii, 4, 1892.
4. Holmes-Spicer, *Roy. London Ophth. Hosp. Rep.*, xiv., 1896.
5. Hulen, *Journ. Amer. Med. Assoc.*, July 25, 1908.
6. Heath, *Journ. Amer. Med. Assoc.*, July 18, 1908.
7. Schirmer, l. c. (2).
8. Parsons, *Path. of Eye*, Vol. 1, p. 182.
9. Hess, *Arch. F. O.*, xxxviii, 4, 1892.
10. DeBeck, *Can. Lancet Clinic*, Apr. 28, 1900.
11. Bomgartner, *Arch. f. Ophth.*, XXV, p. 2, 1883.
12. Lawford, *Trans. Ophth. Soc. U. K.*, XV, p. 860.
13. Vossius, *Arch. f. Ophth.*, XXXV, p. 2.
14. Weeks, *N. Y. Eye and Ear Infirm. Reports*, p. 1.
15. Treacher Collins, *Trans. Ophth. Soc. U. K.*, XV.
16. Wadsworth, *Ophth. Record*, Aug., 1905.
17. David Wells, *Homeopath. Eye, Ear and Throat Journ.*, Oct., 1909.
18. Richter, *Die Ophth. Klinik*, No. 16, 1904.
19. Kerry, *Ophthalmology*, July, 1910.
20. Bunge, *Trans. X. Internat. Med. Cong.*, 1890, p. 151.
21. E. G. Rust, *Arch. Ophth.*, XXXVII, 2, 1908.
22. Fernandez, *Arch. d. Optal.*, Oct., 1906.
23. Kursle, ref. Fernandez.
24. Schiele, *Woch. f. Therap. in Hyd. d. Aug.*, No. 34, 1904.
25. Leviste, *Ann. d. Oculist*, cxii, p. 298.
26. Zirm, *Arch. f. Ophth.*, Oct., 1906, und *Wein. Klin. Woch.*, Jan. 18, 1907.
27. Risinger, ref Zirm.

H. a. THE DEVELOPMENT OF INTERSTITIAL KERATITIS FOLLOWING CORNEAL TRAUMATISM.

Csapodi[1] in 1896 was perhaps the first to bring up the question as to whether a traumatism of the cornea could develop parenchymatous keratitis in a congenital syphilitic subject, and described the case of a six-year-old girl.

He has been followed by a number of other writers. Vollaro[2] reports three cases of traumatic keratitis, in one of which the disease assumed the character of the "disc-shaped keratitis," described by Fuchs.

In all cases there was a deep infiltration, apparently formed of closely agglomerated points situated on various planes, with bands of opacity in Descemet's membrane. The traumatic origin of the affection was well-established and the final result was a dense leucoma. The slowness of

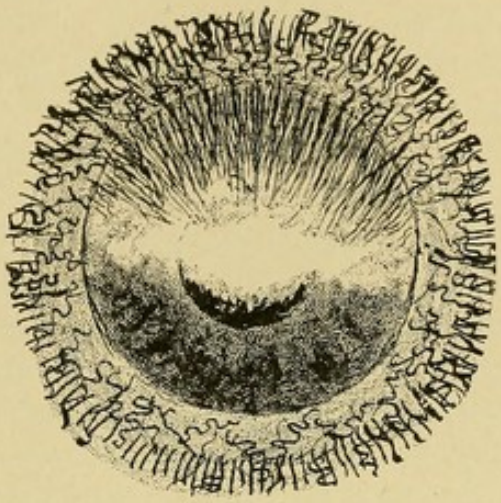

Fig. 253.
Interstitial keratitis ex trauma.

the process and the slight reaction suggest that the infective agent could not have been very virulent. The presence of a denser halo, separating the keratitis focus from the rest of the (transparent) cornea is a point of analogy between this form and the keratitis from experimental inoculation. The author thinks it is sometimes difficult to distinguish this

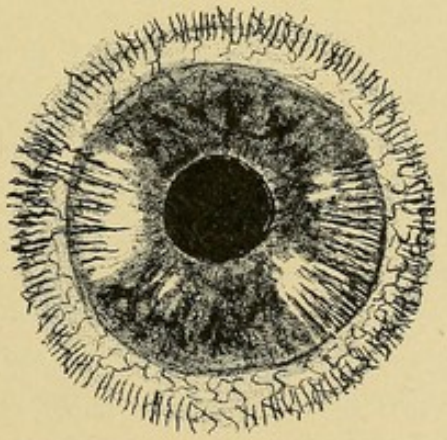

Fig. 254.
Parenchymatous keratitis occurring after injury.

from the interstitial keratitis produced by general causes, when the signs and history of a trauma are lacking and a constitutional malady can not be definitely excluded.

Enslin,[3] as a proof that traumatism may elicit parenchymatous keratitis, reports the following case: A piece of old calcimine flew into

the right eye of a man, aged 18, while tearing off wall-paper. He washed his eye with water, but the eye became more inflamed. Five days later the patient was admitted to the hospital. There was no sign of a caustic action, which, on account of the old material, would have been very unlikely, but a typical parenchymatous keratitis developed. V. sunk to motioning of hand at 1 m. After three and a half months the eye was without irritation and V = 5/x. It was peculiar that during the whole time of observation no blood vessels could be seen in the cornea, although it was frequently examined with Zeiss' corneal microscope.

That the avascular form is not materially different from vascular parenchymatous keratitis, Enslin proves by another case, in which in one eye the parenchymatous keratitis took an avascular course, while after a few months the other eye exhibited the same affection, however with abundant vascularization. Although corneal affections had occurred in the family of the first patient, he presented no signs of constitutional disease and never had had any symptom of scrofulosis or congenital syphilis in his childhood. But even if (the methods of examination being not sufficient to prove it) any such dyscrasia may have existed, Enslin is certain that the traumatism was the immediate cause of the parenchymatous keratitis.

O h m,[4] anent the discussion, records the following case: A woman, 23 years of age, with hereditary syphilis, had been struck in the right eye by a card one week previously, but no trauma could be made out. The eye, however, had been watery and painful. A typical parenchymatous inflammation followed. Two months later the fellow-eye developed a similar affection.

In a second case the author removed a foreign body from the cornea of a man 32 years of age. The patient expressed the fear that a prolonged inflammation might follow as a similar result followed the removal of a foreign body from the fellow eye two years previously (a typical parenchymatous inflammation requiring six months' treatment). The fears of the patient were realized, as three days later an interstitial inflammation, which finally involved the whole cornea down to Descemet's membrane, set in. No evidence of inherited syphilis. There was some consolidation of the right lung. A third case, without syphilitic history, resembling the first, is given.

H o e b e r[5] discusses the question of how far the traumatism may be the cause for developing a parenchymatous keratitis in an individual affected with a constitutional anomaly, viz., heredity or acquired syphilis, scrofulosis or tuberculosis. He reports 28 cases from the literature of the last ten years and, in detail, 4 from the eye clinic of Prof. Haab and one from the practice of Dr. Sidler-Huguenin. Among these were cases in which the traumatism occurred in individuals with undoubted

constitutional diseases, others in whom their existence had to be proven by especial diagnostic means, and others, in whom a dycrasia could not be ascertained nor excluded. The author reaches the conclusion that the occurrence of traumatic parenchymatous keratitis in constitutional anomalies cannot be doubted.

Asmus[6] reports a case of bilateral parenchymatous keratitis in hereditary syphilis after injury of the eye. The left cornea of a boy, aged 16, was struck by a piece of emery which caused a very small infiltration. It was treated with hot applications. After a week he returned with extensive opacity around the original infiltration, which now appeared depressed. A conversation with the father elicited that he had severe syphilis and that a younger son had a saddle-nose, Hutchinson's teeth and had suffered from typical parenchymatous keratitis.

A few days later the whole left cornea of the patient was opaque, dotted, and showed central nebulæ near Descemet's membrane. Under iodide of potash and mercurial inunctions the affection healed, leaving faint opacities. The place of the injury was visible, after months, as a small pit, such as Asmus had never observed after innumerable injuries by foreign bodies of almost daily occurrence.

About two months after the injury the patient returned with an opacity of the lower third of the right cornea. A month later vascularization of the left cornea began. After disappearance of irritation the cornea was massaged with yellow ointment and vision R = 6/ix, V. L. = 6/vi, in spite of remaining opacities.

b. Keratitis disciformis.

Meller[7] gave the first histiologic description of keratitis disciformis and compares it with the clinical picture of this affection as originally demonstrated by Fuchs (1901). The characteristic features are: A circumscribed focus of inflammatory infiltration in the cornea in the form of a disc, undoubtedly due to infection. The tendency toward spreading soon disappears, as total necrosis occurs. The bacteriologic investigations of Meller were negative. The result is a lasting opacity of the corneal parenchyma, and the prognosis, on account of the central location, is bad with regard to sight. Very good drawings illustrate the histologic condition.

Peters[8] referring to Meller's article "On Histologic Examinations of Keratitis Disciformis" in which the necrosis is considered as the consequence of an inflammatory infiltration, emphasizes that the necrosis is the primary and the essential point of the process. Keratitis disciformis is a variation of herpes, or of certain forms of traumatic keratitis. Peters sees in the necrosis of the deeper parts of the cornea an analogue to gangrenous herpes zoster. As set forth in his former papers, there is

an intimate relation between the large class of traumatic corneal affections and herpes, given by irritation of the nerves.

In Posey's article[9] is described two cases of this affection. He says the classification of keratitis disciformis among the parenchymatous affections of the cornea has now been placed beyond doubt. Schirmer,[11] whose observations were carried out on human eyes accidentally infected with vaccine virus, and supplemented by inoculation of animals' eyes with the same virus, not only established the connection of keratitis

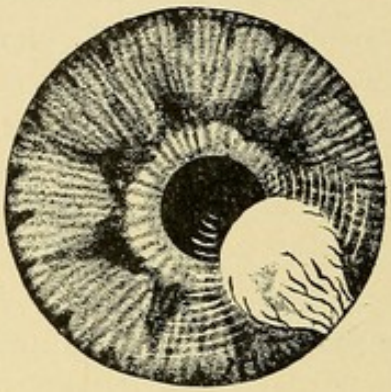

Fig. 255.
Disc-like keratitis.

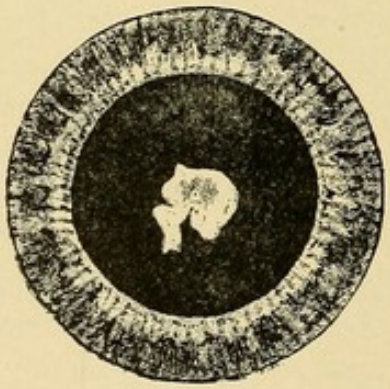

Fig. 256.
Keratitis disciformis. (Posey.)

disciformis with the corneal involvement in vaccine cases, but also traced the changes in the cornea from the time of first infection. Thus, it was observed that shortly after the virus was injected, the cornea became superficially hazy in a small disc-like area, with sharply-defined edges; the centre of the opacity, which marked the site of entrance of the virus into the eye, being denser than elsewhere. After a time, however, radiating lines and circles concentric to the disc appeared in the deeper layers of the cornea, and the superficial changes became less prominent, the epithelium restoring itself. Considerable opacity of the cornea always

persisted. As in Fuchs'[10] description of the disease, Schirmer found that uveal complications may occur, though rarely.

LITERATURE.

1. Csapodi, Ungar. *Med. Press,* No. 5, 1896.
2. Vollaro, *Arch. di ottal,* XII, 11, 12, 1905.
3. Enslin, *Zeitschr. f. Aug.,* XV, 1906, p. 227.
4. Ohm, *Woch. f. Ther. u. Hyd. d. Aug.,* No. 5, 1905.
5. Hoeber, *Beitr. z. Aug.,* 73, p. 1.
6. Asmus, *Zeitschr. f. Aug.,* 1909, XXII, p. 335.
7. Meller, *Klin. Mon. f. Aug.,* 1905, II, p. 335.
8. Peters, *Klin. Mon. f. Aug.,* 1905, II, p. 535.
9. Posey, *Ophthalmology,* Apr., 1906.
10. Fuchs, ref. Meller and Posey.
11. Schirmer, ref. Posey.

I. SUPPURATIVE KERATITIS—ULCER OF THE CORNEA.

Etiology. The intact epithelium offers an insurmountable obstacle to the invasion of the cornea by almost every organism except the gonococcus and diphtheria bacillus, which may attack the normal epi-

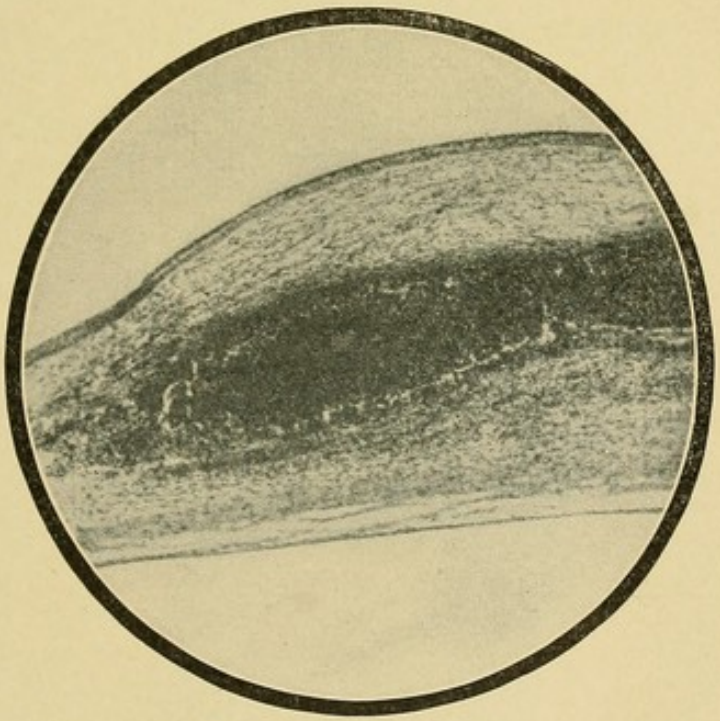

Fig. 257.

Section through cornea of rabbit inoculated with aspergillus niger; infective keratitis. Condition going on to abscess formation; necrotic center with numerous polymorphonuclear cells and well-marked reparative changes about periphery of area of infiltration. Localized abscess; kerato-mycosis. (Tooke.)

thelium, disintegrate it and invade the substantia propria if remaining undisturbed in contact for a considerable length of time.

If, however, there be a wound in the armor (the epithelium), as an abrasion or cut, or if desquamation of epithelial cells occur, as from the

effect of cocain, or from drying, it causes a weakening of the first line of defense and the germs get into the tissues, propagate and give rise to disease; which in the case of suppurative infections, characterized by

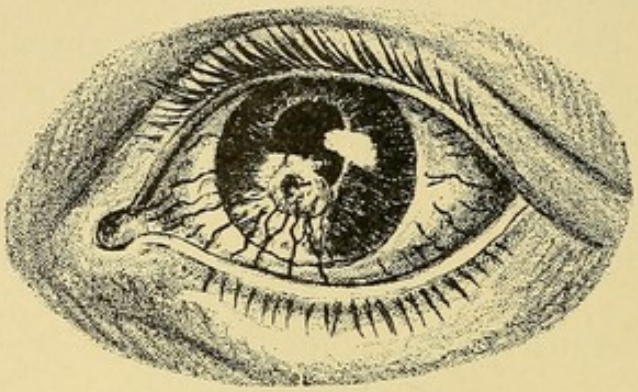

Fig. 258.
Perforating ulcer of cornea.

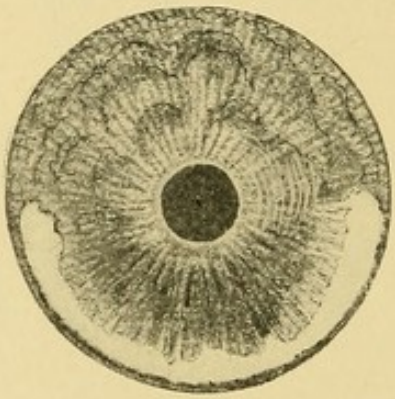

Fig. 259.
Serpiginous ring ulcer.

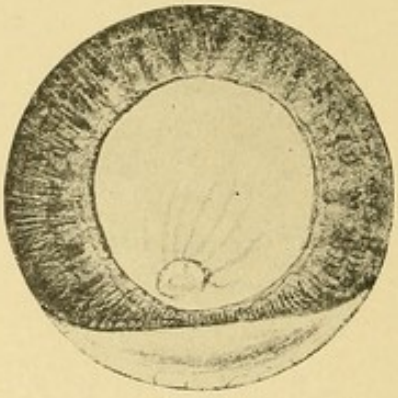

Fig. 260.
Hypopion keratitis, ulcer, striate keratitis.

loss of tissue or ulceration, may result in destruction of other structures, in the case of the cornea, the iris, ciliary body, and even the whole globe (panophthalmitis). When healing occurs, the site of the ulcer always

is healed by a white scar tissue and shrinking. Cicatricial tissue does not resist intra-ocular pressure or extraneous forces, and may break down or cause recurrent ulceration or staphyloma.

The origin may be endogenous or ectogenous. The infection may arise from germs in the conjunctival cul-de-sac and in the

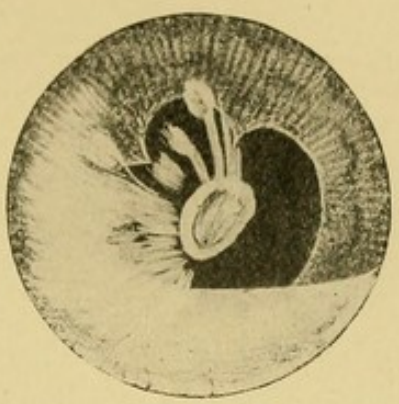

Fig. 261.
Ulcus serpens with secondary foci. Hypopion iritis and keratitis.

lacrimal passages. The edge of the lids usually harbors the staphylococcus.

The existence of a chronic conjunctivitis or trachoma will favor pus-producing germs in the eye sufficient to form the same as an infected

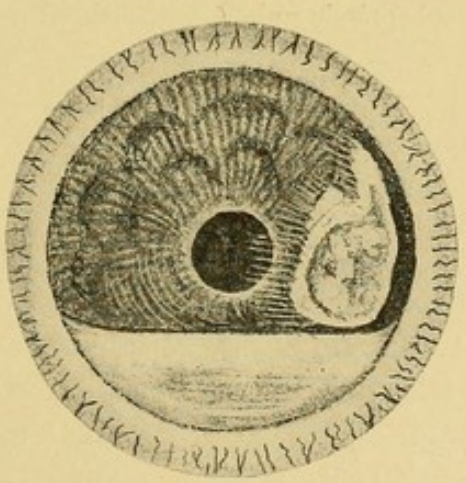

Fig. 262.
Serpiginous ulcer, hypopion keratitis, circumcorneal congestion.

wound. There may be a chronic suppuration of the lacrimal sac, a coryza, an ozena or atrophic rhinitis from which infection will be carried. The object producing the injury may be infected. The patient's fingers, handkerchief, or the bandages applied, medicaments, and lastly instruments used upon the eye may not be sufficient sterile. Again, the moot ques-

tion of auto-infection from the patient's own tissues may cause infection in an otherwise sterile wound. (Hansell.[1])

Fig. 263.
Necrosis of cornea in exophthalmic goiter, with orbital cellulitis and great chemosis of conjunctiva.

a. Hypopion ulcer.

Pathology. The typical hypopion ulcer, ulcus serpens, or hypopion keratitis, is due in the majority of instances to the diplococcus of Fraenkel-Weichselbaum (see Bacteriology).

It is yellowish or white, usually disc-shaped, occupying the region of the wound in gross traumatic cases, in others usually the center of the cornea. The opacity is greater at the edges from edema and it generally spreads in one direction. Gray striæ extend from the margins into the surrounding, yet transparent, cornea. There is accompanying iritis, usually with formation of synechia and hypopion.

Fuchs[2] has carefully studied the development of hypopion keratitis, showing that in the earliest stages there is dense infiltration of the lamellæ which swell up and infiltrate so that a flat, open ulcer is formed, the floor of which consists of fibers that are swollen into an almost homogeneous mass, with a few pus cells. At the margins the infiltrate penetrates like a wedge into the sound cornea. This corresponds with the yellow advancing border, which looks like a yellow crescent. At other

portions the wedge-shaped infiltrate is absent and the epithelium may extend into the ulcer, but is often necrotic. Bowman's membrane is destroyed over the ulcer and is often split beyond. The middle layers are least infiltrated and the deeper layers more, so that a definite posterior abscess or onyx is formed, usually corresponding in situation with the site of the ulcer.

Descemet's membrane offers great resistance and often remains unbroken when all other layers of the cornea are destroyed, but it splits into layers, is perforated, according to Wintersteiner[3]; from before backwards, according to Elschnig[4], supported by Fuchs.[2] Early perforation is a conspicuous feature of ulcus serpens and is due to attack from behind, or internal ulcer.

The opaque striæ here described and considered by Kipp[5] as an evidence of the arrest of progress were first described by Saemisch[6] and later by v. Michel.[7] Neither of these authors consider the striæ a sign that the ulcer has begun to retrogress. Neither Fuchs,[2b] Vossius[8] nor Schirmer[9] appear to have observed the intermediary lines encircling the margin of the ulcer. The diverging opaque lines may be due to cell infiltration (Schmidt-Rimpler[10]), or to folds in Descemet's membrane (Schirmer), similar to those seen radiating from the corneal wound after cataract extraction, except that in the latter there are no intermediary opacities connecting the ends of the lines.

The hypopion was at first thought to be derived from the cornea but is now known to come from the vessels of the iris and ciliary body. (Leber,[11] Uhthoff and Axenfeld,[12] L. Bach,[13] Wagemann,[14] Nuel,[15] et al.)

Parsons[16] gives the cause as chemotaxis, due to the diffusion of toxins. The hypopion being sterile as long as Descemet's membrane is intact. There is aggregation of leucocytes upon the back of the cornea near to the site of infection. The iris is covered by a fibrinous network containing relatively few cells.

The form and site of the ulcer varies with its inception and duration. It is at first flat, the advancing edge often being raised. It becomes deeper on long duration, but the progress on the surface is greater than in depth. The epithelial defect is in many cases more extensive than the ulcer. Mitoses are commoner near the limbus than at the edge of the wound. Active proliferation of epithelium occurs in long-standing cases. Hertel[17] has also found it in acute cases.

The size also varies with the virulence of the bacteria; according to Hertel in glaucomatous eyes the ulcer is larger, the duration being the same. Early perforation of Descemet's membrane is a characteristic, according to Elschnig[4b] and Hertel, glaucoma being a weighty factor in its determination.

A man of 80 was injured by a stick of wood flying into his eye while splitting kindling. This was evidently followed by a superficial wound. When I saw him there was well-developed hypopion keratitis which yielded to electro-cautery, and antiseptics, with resultant moderate leucoma and V = 6/1x.

A child was injured by a slate pencil wound of the cornea, and developed hypopion keratitis of such a severe type that Saemisch section, cauterization and an iodoform rod was placed in the anterior chamber. The eye healed with adherent leucoma. The iodoform rod was at least three months in absorbing.

A girl at a brewery bottling works received a penetrating cut of the eye from a breaking glass bottle. Infection and hypopion keratitis set in; cauterization and subconjunctival injections of the cyanide of mercury

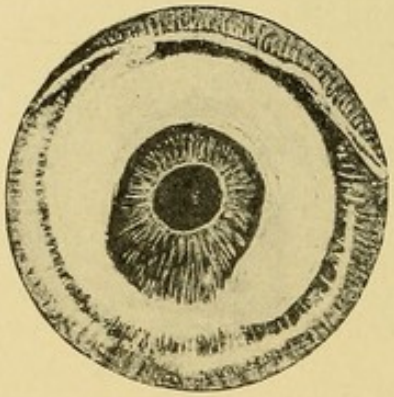

Fig. 264.
Ring ulcer from cataract wound.

saved the globe with some vision. Tattooing of the cornea was later done for cosmetic purposes.

b. Peripheral annular infiltration.

Ring abscess is met with occasionally in perforating wounds, usually caused by chips of metal and septic operations. Parsons[15] says it was especially common in cataract operations in the pre-antiseptic days.

The ring is at first gray, then yellow, 1.5 mm. broad with the peripheral edge 1 to 1.5 mm. from the limbus, although it may reach the limbus. The inner edge is usually less well-defined. The edges of the wound are little or not at all infiltrated. The infiltration is peripheral, aggregations of bacteria are always found between the lamellæ, and the infiltration consists of an anterior ring amongst the middle and superficial lamellæ.

Two rings of infiltration develop, the one in the corneal tissue proper and another immediately in front of Descemet's membrane. The

anterior ring is most marked and always present; the posterior ring is less constant. There is generally a wide, clear zone between the infiltration and the limbus, but sometimes a localized infiltration at the extreme periphery of the cornea. The epithelium and endothelium are for the most part destroyed. Bowman's and Descemet's membrane remain intact. The anterior chamber contains pus or fibrinous coaglum, elsewhere there is commencing panophthalmitis.

Fuchs[20] explains peripheral annular infiltration by bacteria entering the eye from a perforating wound, multiplying within it and setting up a purulent irido-cyclitis and keratitis which attacks the cornea from behind. Ring infiltration follows by emigration of leucocytes from the peripheral vessels and is directed towards removal of the necrosed parts or sequestrum. Rarely this is successful, and the eye is usually lost.

In 1892[19] I had the misfortune to have ring abscess develop after one of my cataract operations, when the present asepsis and antisepsis was not so generally practised after operations. The cornea sloughed and the patient left the hospital without my knowledge, returning six weeks later with the eye shrunken to a painful stump and the other eye sympathetically affected. Total blindness resulted in both.

c. Rodent ulcer.

Mooren's ulcer is very rare. I can recollect but three cases. It is a chronic serpiginous ulcer developing at the margin of the cornea,

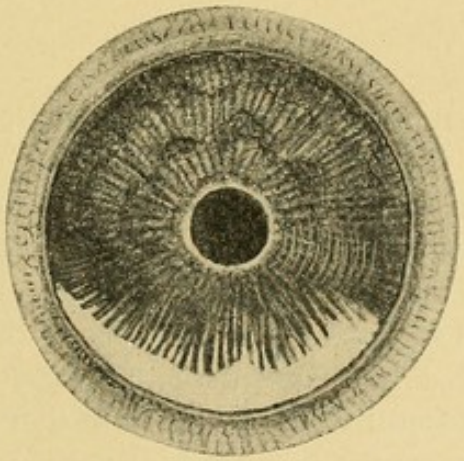

Fig. 265.
Mooren excavating ulcer; edema and congestion of circumcorneal zone.

with characteristic undermined edges slowly invading other parts of the cornea and finally destroying the entire membrane. Perforation does not occur, as it destroys about ⅓ of the thickness of the cornea, granulating up from the bottom. Andrade[20] has described a specific bacillus.

d. Mycotic keratitis.

Keratomycosis aspergillina is due to entrance into the tissues of the aspergillus fumigatus.

This usually occurs at the center, which shows an infiltration undergoing superficial disintegration, and is distinguished by a dry surface of ulceration. A gray or yellow line forms about the area, gradually deepening into a gutter leading to exfoliation of the necrosed portion. Hypopion is usually present. The irritation is usually slight.

This mold causes a superficial necrosis with formation of a sequestrum which is penetrated by the fibrils of the mycelium. In some cases a simple infiltration resembling fascicular keratitis without hypopion formation occurs.

I have recognized but few instances of severe types of mycotic keratitis, or those accompanied by hypopion. In one such a crater-like for-

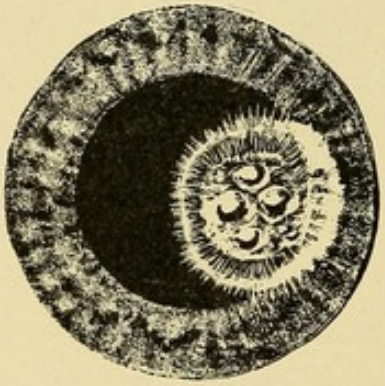

Fig. 266.
Mycotic keratitis.

mation occurred. Cauterization, chinosol applications and irrigations cured the complaint, with resultant leucoma.

In a number of instances the mycosis has been in the form of fascicular or dendritic keratitis and has yielded after many weeks of antiseptic treatment by chinosol and sulphate of copper applications.

Rollet and Aurand[18] say that, notwithstanding the rarity of the affections produced in man by the moulds, the mycoses are well enough known in a general way. They state that in the respiratory passages of animals, especially birds, Mayer, then Miller (1842) found moulds in them for the first time. A few months later Bennett described the first case of human pseudo-tuberculosis. Soon numbers of observations were published; those of human pneumo-mycosis of Virchow (1856) and of Slieda (1866). Since then Wreden, Bezold and Politzer (1870) have published reports on otomycosis. The same year Grohe and Block inaugurated experimental studies in human aspergillus and obtained positive inoculations. Koch and Gaffky

(1881) proved, in short, that the aspergillus fumigatus is pathogenic. Lister, Dieulafoy, Chantemesse and Widal discovered the pseudo-tuberculosis aspergillus in the throat of pigeons (1887). The authors state that, if the aspergillus is well-known as causing pulmonary involvement, it is much less so as to its ocular manifestations. The published cases of ocular aspergillus or kerato-mycoses are very few; and with all of the authors' efforts they were able to find only sixteen undoubted cases. The first observation was published by Leber (1879). The others are Fuchs (1894), Uhthoff and Axenfeld (1896), Schirmer (1896), Uhthoff and Axenfeld, two cases (1897), Wicherkiewicz (1900), Colloumb (1900), Markoff (1900), Basso (1900), Gentilini, three cases (1900), Jas. Moores Ball (1900), Buchanan (1903), Martin (1904). All these cases originated from wounds in agriculture, from blades of wheat, from blows with earthy material, farina, portions of fruits, from points of chestnut capsules.

The affection begins with a cup-shaped ulceration, its center a whitish-yellow; soon a grayish-yellow projection appears, resembling a small button and somewhat like a phlyctenule, but differing from the latter by its dry aspect; it is hard, dry and friable; a sub-epithelial abscess follows. There is always conjunctivitis, iritis and secondary hypopion, with more or less acute pain. The evolution is always slow—two or three months. In about a month there is formed about the aspergillus zone a line of demarkation with a white annular infiltration, the appearance of which ring is eliminated and readily detached. These keratites may often perforate the cornea, and in many instances the eye is lost. Colloumb has remarked that in all the cases described before his the site of the lesion was at the corneal center, where the defensive vascular reaction is less and the receptivity greater. In nearly all the cases there is found the aspergillus fumigatus. Markoff has also said that the rarity of the affection is due in part to the fact that only the aspergillus fumigatus is pathogenic, and he further states that the attention of authors has not been attracted by typical cases, while those cases in which the lesion is but little accentuated are recorded under other names. From the experimental point of view, Leber, who published the first case of keratomycosis, and who was also the first author to study the subject by inoculation with aspergillus fumigatus, was able to provoke keratitis, hypopion and panophthalmitis. He also inoculated with aspergillus niger in the rabbit's cornea. Deutschmann, also, after inoculating the spores into the vitreous of the rabbit, brought about a panophthalmitis and also provoked sympathetic ophthalmia of the other eye. In nearly all the cases which have been carefully studied the a. fumigatus has been found. Halbertsma, however, has described a case of keratitis with hy-

popion which was caused by a. flavescens. Rollet and Aurand state that there are pathogenic varieties of aspergillus with which the authors experimented: a. fumigatus, a. flavus, a. niger, a. ficuum, a. glaucus, a. ostianus, a. minimus, a. oryzæ, a. clavatus, a. varians, a. caudatus, a. wetii, a. novus. The authors' conclusions are that the a. fumigatus is very pathogenic for the rabbit's cornea; the a. flavus is equally pathogenic in the cornea of the rabbit; the a. oryzæ is clearly pathogenic; a. niger is moderately so, as is the a. wetii; a. candidus is only slightly pathogenic; a. glaucus, a. ostainus, a. maximus, a. clavatus, a. varians, a. novus are not pathogenic in the rabbit's cornea.

Symptoms and Course of Ulceration of the Cornea. The course of ulceration in the cornea varies with its nature.

Serpiginous ulceration begins clinically one to three days after a wound or abrasion, the patient shows redness of the eye, lacrimation and swelling of the lids, which may be so edematous as to prevent their opening and the patient applies for relief on that account more than from pain.

As a rule there is central epithelial loss with beginning ulceration, the edges undermined and showing whitish or yellowish in contrast to the grayish bottom of the ulcer. One part spreads more rapidly than the other and here a crescent is usually formed. Severe types are met with in which several other foci of infection exist, connected with the original central one by fine lines. When the swelling of the conjunctiva at the limbus is not too great gray stripes may be seen radiating sector-like towards the ulcer.

Kipp[5] has observed "that in the cases in which the straight, diverging, grayish lines radiate from all parts of the margin of the ulcer, if this was situated in the central part of the cornea, or from the margin nearest the center of the cornea, if the ulcer was situated near the periphery of the cornea, did as well under the simple treatment of warm fomentation of boric acid solution and instillations of a solution of atropin, as the ulcers in which the straight, diverging, linear opacities were connected by the grayish intermediate striæ." In cases in which the grayish, linear opacities were seen only on a part of the margin of the ulcer at the time the case came under observation, he has often seen the striæ develop from the parts of the margin which were free from them when seen first, and further progress was arrested. In other cases of the same class the ulcer continued to progress, and the margin of the ulcer from which no grayish striæ radiated became somewhat raised and of a yellowish color and progressed.

The whole cornea becomes dull, especially in the neighborhood of the ulcer, and may hide the hypopion which always forms. The hypopion arises practically with the beginning of the clinical manifestations, and

being due to iritis and cyclitis, posterior synechiæ, and occlusion of the pupil from exudate, occurs. The ulcer spreads slowly, the disease lasting a week, or weeks, before perforation occurs, when iris prolapse results, in favorable cases with evacuation of part of the hypopion, absorption of the balance, cicatrization with formation of leucoma adherens, which, when in the center of the cornea, is a hindrance to sight. In other cases the exudate within the pupil becomes organized, seclusion and occlusion with subsequent secondary glaucoma results.

Ring ulceration appears very quickly after the injury, in from one to eleven days, usually about the third day. The ring appears gray, then yellow, the infiltration proceeds, the cornea melts away and panophthalmitis develops and atrophia bulbi follows. Sympathetic ophthalmitis is apt to develop.

Rodent ulcer is a very chronic process, going or for months or years. It does not cause hypopion and seldom leads to loss of sight or eye. The edges of the ulcer heal and relapses frequently occur. The patient may have but little irritation and keep on with the daily duties.

In the two forms of mycotic keratitis described there are but slight inflammatory symptoms and the patients generally consult the oculist on account of the opacity which interferes with vision. Severe types, with formation of hypopion, take much the same course as the hypopion keratitis caused by the streptococcus and the staphylococcus.

Diagnosis. The diagnosis of traumatic ulcer of the cornea is obtained by the history, appearance and bacteriologic diagnosis. All these germs are readily stained from a smear. Preparations and determination of the character of the infection should be made on first examination in every case in order to formulate proper treatment and to state the prognosis.

Chaillous[21] concludes that, in cases of traumatic infections of the eyes in which bacteriologic examinations have been made, and from the negative result of the cultures, the conclusion had been reached that the infectious germs were absent, it is possible that anaërobic microbes may have been present. He says that, to be complete, the bacteriologic study of every case of infection of the eye should include the search for anaërobic microbes.

Prognosis. The prognosis for all forms of corneal ulceration is serious, and particularly those due to microscopic lesions. Infection by the pneumococcus is most serious, next by the staphylococcus and streptococcus. Mixed infections are particularly potent to cause extensive and rapid ulceration, severe suppuration of the cornea, and extension to other parts of the globe, with resultant panophthalmitis and perhaps sympathetic ophthalmitis.

The occurrence of serpent ulcer does not, however, necessarily por-

tend destruction of vision and loss of the eye. In a few cases natural processes cure the complaint. Radical and speedy treatment will in most cases cut short the process and save some vision.

Ring ulcer invariably leads to loss of the eye from panophthalmitis. It is rare in these aseptic days, but was formerly common from operations involving corneal incisions.

Mooren's rodent ulcer is a chronic process, hard to heal, but is compatible with economic vision.

Mycotic ulceration, while a chronic process, is one of the least unfavorable forms of the corneal ulceration, and progresses to a cure under proper treatment.

e. Keratitis lagophthalmo, et keratitis neuroparalytica.

Ulcerative keratitis following exposure and drying of the cornea from inability to close the eyelids is due to irritation, followed later by bacterial ingress.

Etiology. More recent investigators indorse the conclusion that the disease is due to exposure and subsequent iritation of the substantia propria.

Keratitis e lagophthalmo and keratitis neuroparalytica present, as a rule, two definite and clinical pictures, although some authorities have been led to regard them as the same disease. It is possible to find a condition where symptons of both forms of the disease are manifested, where a differential diagnosis is impossible.

Pathology. Although due to distinct etiological disturbances, they would seem to present a common pathology, the first evidence of which is dessication of the superficial corneal epithelium.

Keratitis e lagophthalmo is a low grade of inflammation of the cornea, due to exposure of the corneal cells, with subsequent irritation. This is substantiated by the swelling of the corneal corpuscles and a marked condition of amitosis or budding, particularly beneath that portion of the cornea which has been uncovered by its protecting epithelium and by Bowman's membrane.

The comparatively few leucocytes, particularly those of the polymorphonuclear variety, and the absence of bacteria in the tissues, substantiates the diagnosis of an irritative keratitis rather than one the result of bacterial ingress. (Tooke.[22])

Course. Both these affections lead to ulcerative keratitis and loss of sight if the cornea be not protected.

Therapy. Bandaging of affected eye, mild antiseptic ointments, as 1:10,000 sublimate, and tarsorrhaphy to close the lid aperatures, are indicated.

I have noted a most severe case of keratitis e lagophthalmo in an old man, the subject of exophthalmic goiter, who developed a keratitis following a suburban ride on a trolley car, in which, despite careful attention, both corneæ sloughed, the patient fortunately dying several weeks later.

In another case of atypical exophthalmic goiter[19b] I reported total necrosis of corneæ, as well as later death from sepsis.

In several instances of facial paralysis there has likewise developed a neuroparalytic keratitis with ulceration, which, however, healed under antiseptics and occlusion.



Fig. 267.

Section through middle of pupillary area; large area of cornea exposed to desiccation of superficial epithelium. Rupture of Bowman's membrane and marked infiltration of substantia propria. Smaller point of desiccation showing degenerate character of neighboring epithelium. (Tooke.)

Chance[23] reports a case of oculomotor paralysis accompanied by facial palsy, neuroparalytic keratitis and hemiplegia. On August 24, 1905, a negro woman, aged thirty, complained of a sudden closure of the left eye two weeks before. It had been inflamed for six weeks. The eye was completely covered by the upper lid. There was facial palsy on the left side and the mouth was drawn towards the right. When the lid was raised the globe was seen to be rotated outward. It was deeply injected, and the epithelium of the cornea was macerated and steamy over nearly the entire surface. The summit was edematous and infiltrated; it stained deeply when fluorescein solution was instilled. No view

of the fundus could be obtained, nor could the iris be seen. Atropin suspended in oil was prescribed, and the patient was instructed to take a saturated solution of potassium iodide, beginning with fifteen drops and rapidly increasing the dose. Some improvement followed, but, by September 21st, the ball remained divergent and fixed at the outer extremity. Facial paralysis was complete on the left side, and in the distribution over the superior and inferior maxillary branches of the fifth nerve there was anesthesia. The cornea continued hazy and anesthetic. About this time the patient's left arm and leg became numb and powerless. On October 12 the diagnosis of cerebral syphilis was made. On

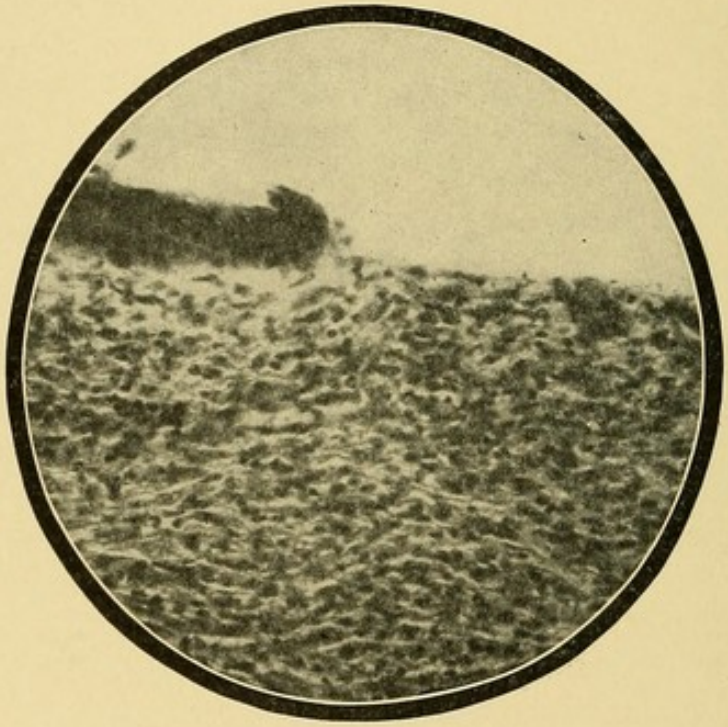

Fig. 268.

Section same as preceding figure, high power. Contortion of corneal cells, infiltration consists of lymphocytes, polymorphs being practically absent. Swelling of corneal corpuscles showing process of budding, stimulating polymorphonuclear leucocytes. No actual necrosis. Irritative keratitis. (Tooke.)

October 24 the solution of atropin was discontinued and antisyphilitic treatment continued until November 28, when signs of ptyalism appeared. Marked improvement began by the end of December. After another denudation of the cornea had occurred, the return of power was marked. The ptosis almost disappeared and the woman could walk with greater comfort. She was not seen from February 1906 to January 1909, during which time she was able to keep house and work as a laundress. She has had a constant dull ache over her left brow, and when over-tired she has attacks of headache, and the arm and leg feel like "pins and needles." She is very much annoyed by diplopia when she attempts to

look up or down, yet even in the primary position there are two images, the left being the false one and the higher. There is now partial ptosis when at rest. There is paralysis of the superior and inferior recti, the inferior oblique, and the superior oblique muscles; the ocular excursions are limited to the extent of free adduction and abduction, while supraduction is abolished and infraduction is only faintly perceptible. The diplopia is upward. There is no accommodation power. The cornea is perfectly smooth; it is, however, anesthetic, and so is the conjunctiva. The facial movements have been regained and the face is anesthetic to pin pricks. It is probable that the hemiplegia was caused by vascular disturbance in the right side of the brain, while the oculomotor palsy arose through a disturbance at the base on the left side, in advance of the nerve fibers supplying the extremities.

Prophylaxis. The prophylaxis of corneal ulceration is largely that of prevention of injuries to the eye, together with aseptic handling of such eyes and the use of local antiseptics which have been found by laboratory and clinical use to be efficacious in the prevention of the growth of micro-organisms which are normally present in the eye, are causative of the ordinary forms of conjunctival or lacrimal disease, or may incidentally be introduced by improper handling, or have been carried in by the object producing the injury.

Ulcus corneæ serpens occurs most commonly in the case of workers in stone, plasterers, and other industrial workers or in farmers. Due care in the regulation of machinery and work and the use of protective glasses largely diminishes these forms of accidents and consequent ocular infection.

Proper care of children in preventing them from playing with sharp instruments, and in games whereby they might be injured, diminishes these accidents and infections. Training of the public as regards infection from unclean instruments, medicaments, and other applications, will diminish these sources.

One of the most common sources of the infection in serpent ulcer is suppurative disease of the lacrimal passages, the existence of which should always be determined and its removal effected by operation and antiseptic treatment in all cases of corneal ulcer.

This prophylactic treatment may be by free slitting and antiseptic washes through the canaliculus, or by complete extirpation of the lacrimal sac. In all cases alkaline washes and treatment of the nasal passages should be used.

The prophylaxis of ring abscess, rodent ulcer, and mycotic keratitis is the same as that of serpiginous ulcer.

The mechanism of cicatrization of a corneal ulcer with prolapse of iris is thus: The prolapsed iris becomes solidly agglutin-

ated to the walls of the cuts by the rupture, and whenever it is exposed it is converted by inflammation into granulation tissue, so the prolapse loses the color of the iris, becoming grayish red. Subsequently there develops from the proliferating tissue cicatrices which first become visible as isolated gray bands. These contract and constrictions are formed upon the surface of the prolapse, which, as the cicatrix proceeds, becomes bloody, fused together and renders the prolapse constantly flatter. Hence, in favorable cases, the process terminates in the formation of a flat cicatrix, situated at the level of the cornea at the site formerly occupied by the bulging prolapse. This cicatrix is mainly composed of the changed iris, the remainder of the iris being united to it. This addition to the iris of the corneal cicatrix is called anterior synechia, or adherent leucoma.

The pupil loses its round shape in peripherally situated ulcers, being drawn strongly towards the site of the permeation, having the shape of a pear, the tapering end being directed towards the cicatrices. If the permeation be near the center of the cornea the pupillary margin becomes engaged in it in healing, and the distortion of the pupil may be slight. If the permeation be so large that the pupillary margin becomes involved the pupil becomes permanently closed, producing occlusion and seclusion. The shrinking of the cicatrization tissue is often so great that the corneal cicatrix appears flattened when compared with the normal curvature of the cornea. This may extend over the whole cornea (applationale corneæ).

If the cornea becomes totally destroyed, with total prolapse of the iris, which becomes reduced to a small and flat cicatrix, it is called phthisis corneæ. The healing of a prolapse of the iris with the formation of a flat cicatrix is a comparatively favorable outcome, but when ectasiæ form it is unfavorable. Here the prolapsed iris becomes covered with cicatrization tissue, but this is not strong enough to affect the flattening of the prolapse, hence it protrudes, becoming converted into an ectatic cicatrix, with inclusion of the iris (staphyloma corneæ). It may even take a mushroom shape, and acquire great bulging. If the perforation is in the region of the pupil it cannot be covered by the iris, and the anterior chamber may remain empty for a long time, sometimes the perforation not closing completely so that a permanent aperture remains (fistula of the cornea). Unless this closes up atrophy and detachment of the retina occurs. Fistula may close from time to time and reopen until finally severe inflammation or intraocular hemorrhage occurs.

T h e r a p y. The treatment is prophylactic, disinfectant and operative.

The prophylactic treatment is as just described, especially as to cleansing of the conjunctiva and the region of the eye, the care of the tear passages and nose. Among the antiseptics advised and in most

common use are the douching of the conjunctival sac with 3 per cent. boric acid; 1:3000 sublimate solution; 1:3000 iodide of mercury; the instillation of 1:1000 sublimate in petrolatum, or 2 per cent. yellow oxide of mercury; or 5 per cent. iodoform in ointment. Among the powders iodoform or xeroform are the most commonly applied. The application of atropin is always indicated where no elevation of intra-ocular tension occurs. Hot applications, which may be made of boric acid or 1:5000 sublimate solution applied on pieces of lint, changed every five minutes, for half an hour, for every three hours, are indicated. I do not agree with a number of authors that tepid applications are advisable, for these act as a poultice and do not favor the nutrition as is found to be the case from intermittent application of compresses as hot as can be comfortably borne. Hot applications may likewise be made by the use of a syphon apparatus, passing through a lead plate or small hot water bag, or dry heat may be applied by a modification of the Japanese charcoal-burning hand-warmer. But the weight of these forms of apparatus is discomforting to the patient, and we are usually obliged to employ the constant services of a nurse to change the compresses every few minutes.

If the tissues become macerated the compresses may be stopped and beef juice or Bovinine instilled every few hours to help the local nutrition.

The cauterization of corneal ulcers is essentially a conservative operation, by which many wounds and ulcers dooming the eye to perdition are thereby cleaned out and caused to rapidly heal. Chemical cauterization is done by phenol 95 per cent. solution on a small, cotton-tipped stick; fused rod of silver nitrate, or fused bead of trichloracetic acid, after local anesthesia by cocain, alypin, or holocain.

More satisfactory cauterization and cleansing of the ulceration is, however, afforded by the actual cautery, which was first described by Martinache[24] in 1873 for this purpose, but probably used from ancient times.

The following rules may be observed in cauterization:

1. In beginning ulcerations.
2. In progressive ulcerations.
3. For the cauterization of the edges of large ulcers, after which the base of the ulcer may be opened by the von Graefe knife and the hypopion removed.

After-effects of the operation by cauterization are observed in that while the hypopion may not be removed it is absorbed. The patient is usually relieved by the operation, much corneal tissue is usually burned out, yet the scar resulting therefrom is no greater than when healing occurs without cauterization, or after the Saemisch incision. Staphy-

loma formation may occur, as well as perforation, but this happens under other circumstances.

As a rule, however, cauterization offers the following advantages over the Saemisch section: The after-treatment is usually not so prolonged; it is safer, and may be repeated two or three times; the results are usually better, as it generally saves the eye; it can be done without perforating the eye and causing prolapse of the iris, which always occurs after the Saemisch section; it is an easier and more precise operation.

Cauterization. Under general or usually local anesthesia the extent of the ulcer is to be defined by staining with a 2 per cent. fluorescein solution. The conjunctival cul-de-sac is disinfected, the lids held open by a stop speculum, the bulb fixed by forceps and the deeper portion of the ulcer, its whole base, and especially the edges, down to clear corneal tissue, cauterized by a dull-red heat. A dry, brownish eschar is immediately produced which is thrown off in a few days and healthy granulation tissue sets in. The after-treatment is by washing out of the conjunctival sac three times a day, dropping in of atropin and dionin, applications of iodoform powder, the 1:3,000 bichloride salve, a light bandage or the Fuchs wire mask.

Otherwise, as previously described, the area of ulceration may be covered over by conjunctival flaps.

Platinum-pointed cautery instruments which may be heated in the alcohol flame, and are very convenient, have been devised by Simeon Snell, Frank Todd and others, and the galvano-cautery with miniature tips as devised by Knapp give a variety of tools for selection.

Cutting operations are made by paracentesis of the base of the ulcer and are not, as a rule, indicated, except where the tension becomes high, and this offers an opportunity for further infection to the deeper structures by the entrance of micro-organisms direct into the eye from the cornea, which are otherwise shut out by Descemet's membrane. Rather is a cutting operation by complete section through the cornea, according to the method of Saemisch, indicated.

Keratomy or Saemisch section is made after local anesthesia and fixation of the eye, by cutting with a small Graefe or Beer's knife into clear corneal tissue at one edge of the ulcer, the counter-puncture being made at the other side, and then bringing out the knife 1 mm. from the lower edge of the ulceration in clear tissue. After this the hypopion may be removed by forceps or antiseptic syringing, a Haab iodoform rod or disc put in, or 50 per cent. argyrol introduced by a curved pipette into the anterior chamber, and the lids closed. The after-treatment is daily cleansing of the wound, removal of protruding hy-

popion by forceps, and the application of a bandage. As a rule it is inadvisable to excise any portion of the iris during this procedure, as this opens up the lymph spaces in the iris to further channels of infection. The iris always prolapses and a leucoma adherens is thus produced. Since the advent of cauterization Saemisch section is rarely performed.

General constitutional treatment is usually prescribed. A calomel purge, 0.15 to 0.50 grams, followed in a few hours by a saline draught, is necessary in most instances. The patient must be well-fed, and if old and weak a small amount of alcohol with meals, malt liquors if they do not disturb digestion, are the most valuable. Of the drugs, those of most value are quinin in full doses, usually 0.30 three

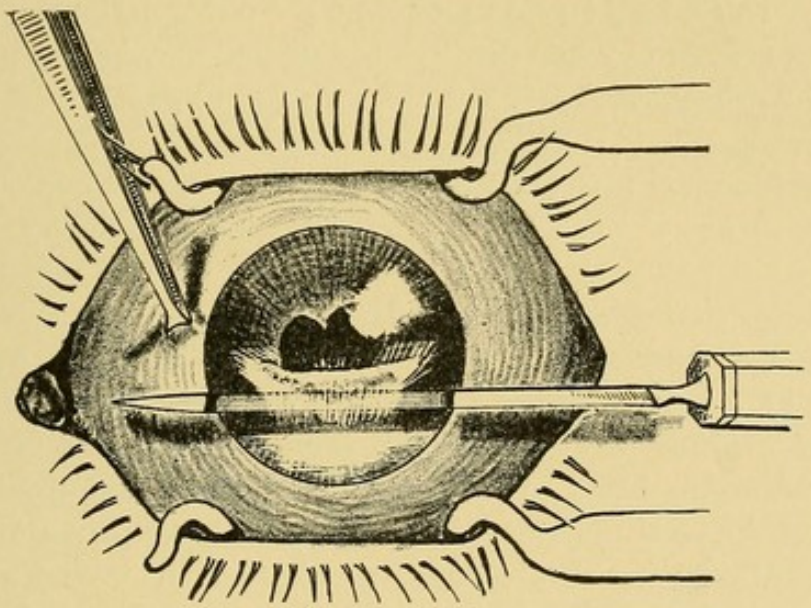

Fig. 269.
Saemisch section in hypopion keratitis.

times a day; opium administered by the mouth, or morphin by hypodermic injection.

Otto Frank reports 60 per cent. of recoveries with the treatment of infected injuries of the eye by large doses of mercury, and by mercurial inunctions and intergluteal injections of mercury iodide, besides local applications and cauterization, paracentesis, atropin, bandage, and rest in bed.

I have saved many eyes by the injection of the salts of silver, especially argyrol in 25 per cent. to 50 per cent. solutions, into the anterior chamber, and use it in the treatment of perforating wounds of the eyeball, and after the Saemisch section. As a routine application 25 per cent. to 50 per cent. argyrol, or 10 per cent. protargol, instilled into the conjunctival sac with each

dressing, has been preferable to the application of more irritating substances, such as sublimate and the various antiseptic powders.

In 1909 Haab[26] advised the introduction of iodoform discs into the anterior chamber and reported good results. I have followed this method in several cases with success, but prefer the argyrol injections, and most other observers are skeptical of the effect of iodoform. The iodoform rod may be seen to remain in the anterior chamber for a number of weeks, and it ultimately apparently causes an irritation with exudation, with which it becomes covered.

Flushing of the anterior chamber by normal salt solution 9/10 of 1 per cent. or 3 per cent. boric acid, may be used, after an incision through the ulceration or by the wound of entrance of the foreign body. The Lippincott or McKeown irrigator, or a curved pipette, or a stream directed through the undine may be used. The Todd or Elwood wash bottles carry the stream of fluid gently into the anterior chamber).

Subconjunctival injections of mercury and normal salt solutions was brought forth by Darier[27] and recommended for years by him and others as of the utmost benefit in cases that do not respond to other treatment. A stop speculum and fixation forceps are commonly used, although not necessary with a quiet patient. The eye is first rendered insensitive by a local anesthetic, half a hypodermic syringeful of 1:5000 cyanid, bichlorid, or iodid of mercury solution is injected under the conjunctiva, the needle being inserted well under the tissue back of the limbus between the recti muscles. This raises the conjunctiva in a bleb over the globe. Massage with the finger tips is then made and a light bandage applied for 12 to 24 hours.

Perforating ulcers of the cornea are almost invariably complicated by prolapse of the iris, which has been ascribed by Tooke[22] as an effort of Nature at repair, for the iris fills the opening, stops the wound, becomes adherent, and forms a sort of misdirected healing which may become infected, or at any rate causes irregular healing and the development of a high degree of irregular astigmatism. The scar later becomes cystoid, ectatic, and produces increased intraocular tension which may lead to blindness and hence excision of the prolapsed iris is to be made.

LITERATURE.

1. Hansell, *Ann. Ophth.*, Apr., 1905.
2. Fuchs, a, T. o. s. XXII, ref. Parsons, Vol. 1, p. 203, v. b., Text book, c. *Arch. f. Ophth.* LVI, 1, 1903.
3. Wintersteiner, *Arch. f. Ophth.* LIII, 3, 1901.
4. Elschnig, (a) *Klin. Mon. f. Aug.*, XXXIX, 1901. (b) *Arch. f. Ophth.* XLV, 1898.
5. Kipp, *Amer. Journ. Ophth.*, Nov., 1902.
6. Saemisch, *Das Ulcus Serpens, Bonn*, 1870.

7. v. Michel, ref. Kipp.
8. Vossius, ref. Kipp.
9. Schirmer, ref. Kipp.
10. Schmidt-Rimpler, ref. Kipp.
11. Leber, *Die Entstehung d. Entzündung,* etc., Leipzig, 1891.
12. Uhthoff and Axenfeld, (a) *Arch. f. Ophth.* XLII, 1, 1896. (b) *ibid,* XLIV, 1, 1897.
13. L. Bach, and Neumann, *Arch. f. Aug.,* XXXIV, 1897.
14. Wagenmann, *Arch. f. Ophth.,* XXXVIII, 3, 1892.
15. Parsons, *Path. of Eye,* Vol. 1, (a) p. 203 et seq. (b) p. 217.
16. Nuel, *Arch. d'ophth.,* XV, 1895.
17. Hertel, *Arch. f. Ophth.,* LIII, 2, 1901.
18. Rollet and Aurand, *Rev. Gen. d'ophtal.,* Dec. 31, 1905; also ref. Virchow, Slieda, Wreden, Bezold, Politzer, Grohe, Block, Koch, Gaffky, Lister, Dieulafoy, Chantemasse, Widal, Leber, Fuchs, Uhthoff and Axenfeld, Schirmer, Wicherkiewicz, Colloumb, Markoff, Basso, Gentilina, Jas. Moores Ball, Buchanan, Martin, Deutschmann, Halbertson.
19. Würdemann, (a) *Ophth. Record,* Nov., 1905. (b) *Ophthalmology,* Apr., 1906.
20. Andrade, *Ann. de ottal.,* XXIX, 1900.
21. Chaillous, *Ann. d'oculist.,* Aug., 1905.
22. Tooke, *Ophth. Record,* Aug., 1908.
23. Chance, *Amer. Journ. Med. Scien.,* Aug., 1909.
24. Martinache, *Pacific Med. and Surg. Journ.,* Nov., 1873, p. 294.
25. Otto Frank, *Beitr. z. Aug.,* No. 60, p. 1.
26. Haab, *Atlas operative ophthalmology,* 1905, p. 72.
27. Darier, *Thérapeutique oculaire,* p. 32.

CHAPTER XX.

INJURIES OF THE SCLERA AND CORNEO-SCLERAL MARGIN.

A. Wounds. (a) Non-perforating wounds—Etiology, Symptoms and course—Diagnosis—Prognosis—Therapy. (b) Perforating wounds—Etiology—Symptoms and course—Healing—Complications—Therapy—Conservative Treatment — Ectasia — Diagnosis — Prognosis — Therapy — Scleral suture —Mattress—Nuels'—Cystoid cicatrix—Literature. B. Foreign bodies—Etiology—Symptoms and course—Diagnosis—Prognosis—Therapy—Literature. C. Injuries through blunt objects—Direct—Indirect rupture—Etiology—Mechanism—Direct—Indirect—Symptoms—Course and complications—Diagnosis—Prognosis—Therapy—Pigment deposition—Posterior rupture—Partial rupture—Rupture canal of Schlemm—Symptoms and course—Diagnosis—Prognosis—Therapy—Literature. D. Thermal injuries—Etiology—Symptoms—Course and complications—Therapy—Literature.. E. Injuries from firearms—Etiology—Wounds—Foreign bodies—Contusions and rupture—Direct rupture—Therapy.

A. WOUNDS.

a. Non-perforating wounds.

Etiology. Wounds occur in the form of scratches and abrasions, the conjunctiva usually receiving the brunt of the injury. All those I have seen have been from pencil and hat-pin points, and scratches from claws of dogs and cats, beaks of birds and even bites of aniamls.

Symptoms and course. The irritation and pain is much less than in such injuries to the cornea. As a rule there is some lacrimation and feeling as of a foreign body. Examination shows solution of continuity of the conjunctiva and outer layers of the sclera, with congestion of the episcleral blood vessels and tumefaction of the conjunctiva. If the edges of the wound in the latter are closed perhaps some foreign body may be found lying under the membrane. If the sclera be nearly divided the bluish color of the uvea may show through.

Diagnosis. From inspection and from the fact that the intraocular pressure is normal will differentiate non-perforating from perforating wounds.

Prognosis. Superficial, non-perforating wounds of the sclera are of little moment and heal kindly if the conjunctival wound be closed over them, so a simple stitch or two bringing the edges of the conjunctiva together, insures good healing.

Therapy. Asepsis and antisepsis of the conjunctival cul-de-sac and application of a bandage, usually results in closure of the small wound and restitution ad integram within a few days.

A child was playing with a cat when she received a scratch of the conjunctiva, sclera and outer canthus. This healed under 1:3000 sublimate salve and bandage within three days.

A stenographer poked a pencil point into her eye, cutting the conjunctiva and sclera. Same treatment and result.

A lady cut the inner canthus and the sclera by a scratch with a hatpin. This, too, rapidly healed.

Korschenowsky[1] reported a woman who had stooped under a table to pull out a dog. The animal bit her in the eye, causing a 3 mm. long conjunctival and scleral wound, followed by scar formation.

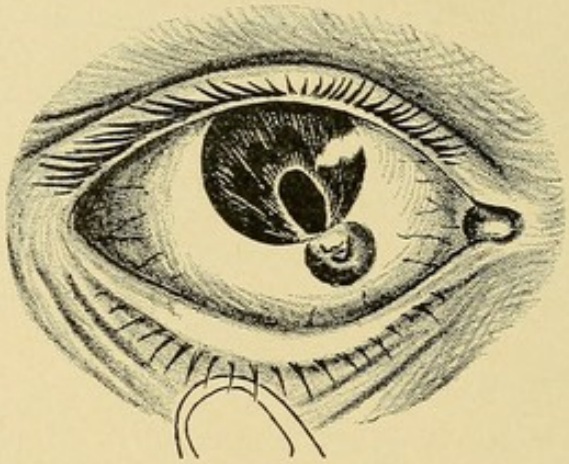

Fig. 270.
Perforating wound, corneal limbus. Prolapse of iris.

b. Perforating wounds.

Only at the corneo-scleral margin can perforating wounds occur without involving either the conjunctiva, uvea and retina, as well as the vitreous, or the cornea, iris and lens. As a rule such scleral wounds are complicated by injuries to these structures with loss of aqueous or vitreous and prolapse of the interior tunics.

Etiology. The causes are the same as those which produce perforating corneal wounds, especially blows, bodies flying with force, and knife or scissor wounds.

Symptoms and course. The irritation and pain are less than in purely scleral injuries when complicated by injury to the ciliary body and cornea. In the latter cases we find swelling of the lids, chemosis of the conjunctiva, bleeding under the conjunctiva and perhaps a hyphema, ciliary injection, and congestion of the conjunctival vessels in the neighborhood of the wound. The wounds may be linear, curved or

angular, but are seldom in the form of a flap. They are usually in a direction perpendicular or at an angle to the limbus and are seldom parallel. Small perforating wounds are difficult to see and are marked by small extravasations of blood.

Most penetrating and perforating wounds of the sclera likewise involve the ciliary body and open both the vitreous and the anterior chamber, the iris prolapsing and becoming impacted into the wound. Where the opening in the sclera is great, prolapse of the vitreous occurs and the ciliary body and chorioid may be seen in the wound. If the hyaloid membrane is not broken or cut the vitreous may protrude as a clear bead from the wound. In large wounds the lips separate and between them is seen the injured iris and lens matter. Where the ciliary body and chorioid protrude the edges of the wound are stained a brownish color. The vitreous extrudes more and more with each movement of the globe and from pressure of the lids. In very large wounds almost the entire contents of the globe may extrude. If the lids be injured at the same time the wound may be seen directly.

If the wound be posterior to the zonula the anterior chamber will be intact; if anterior or combined with perforating injury to the cornea the anterior chamber may be abolished until closed by prolapse of the iris in the minor cases, when it is again restored.

The intra-ocular tension is always diminished, even to a flabbiness of the globe.

In favorable cases healing occurs with the formation of a flat scar. The chorioid and the retina in the neighborhood of the wound becoming atrophic, ophthalmoscopic examination showing the white sclera at the spot of the injury. Atrophy of the optic nerve fibers corresponding to the portion of the retina injured, with lowered visual acuity and angular defect in the visual field, follows. The conjunctiva is usually attached by cicatricial bands, in a radial form, to the scar and a black or brown pigment deposit forms and persists indefinitely.

In cases where the wound is small, as in piercing injuries, the scar may become thin so that the color of the uvea is observed through it. This may be due to a small prolapse and impaction of the chorioid into the wound.

In large healed wounds cicatricial contraction may occur so that the globe becomes indented.

The h e a l i n g of scleral wounds is more rapid the sooner the edges are brought together, but not by direct adhesion, rather by new deposit of connective tissue (S c h u n k i t z - M y a s h i t a[2]) which, according to L u b l i n s k y[3] is produced from the conjunctiva and chorioid, and from which also the vitreal bands are produced. Through the contrac-

tion of the scar tissue the chorioid and retina become pulled away and detachment occurs.

Complications. Iris and ciliary body prolapse are most frequent; injury to the zonula causes entire or partial dislocation of the lens; to the lens capsule and body causes traumatic capsular and lenticular cataract. The lens may escape through the wound, in the case of large wounds, together with some or all of the vitreous.

Eversbusch[4] shows that after resorption of the lens the contraction of the lens capsule and thickening of the zonular fasiculæ may drag on the ciliary body and cause sympathetic irritation.

So much of the vitreous may be lost that the eye goes on to phthisis bulbi. How much may be lost with retention of function has not been established, but it is safe to say that if over one-fifth be extruded no vision may be expected. It is doubtful whether the vitreous ever regenerates. Experiments now in progress may settle the contention.

Bleeding into the vitreous usually occurs and may be seen for a long time by the ophthalmoscope, either as blood, blood pigment or membranous opacities.

Loss of a portion of the uvea and retina, as well as impaction thereof and injury to the lens, is an unfavorable sign, as the cicatricial contraction ultimately leads to disturbances of contiguity and the formation of a thin scar leads to staphyloma from inability of the weak, new-formed membrane to resist the intraocular pressure.

Small perforating wounds of the cornea-scleral margin may heal with the formation of a cystoid cicatrix, caused by lining of the wound canal by the iris or by the lens capsule. The conjunctiva grows over the projection, but the wound canal persists and the aqueous fills it, forming a projecting bead. This condition occurs more seldom after injuries than from cataract extraction and iridectomy, when the iris or lenticular capsule has not been fully replaced; or in secondary iris prolapse after such operations. Secondary glaucoma or infection is apt to occur.

Scleral staphyloma comes more commonly in case of rupture than in perforating wounds. Ectasia of all kinds predisposes to secondary glaucoma and blindness. Cysts of the iris have been often seen after corneo-scleral wounds.

The future of the eye depends upon the changes in the vitreous, and especially the amount of contraction of the exudation, which we cannot see distinctly in such eyes, but which we recognize by steadily diminishing sight, due to implication of the retina, and gradually increasing softness of the globe.

We should repeatedly test the acuity of vision and the light perception, and when we find perception of light has been lost it is well to

enucleate if at the same time the eye has become soft. The observable changes in the anterior portion of the eye are a plastic irido-cyclitis, but are not so much to be depended upon as enucleation indications (aside from the infective signs), as those relating to the gradual loss of sight and tonicity of the globe.

Therapy. Conservative treatment. This is described under the general chapter, with asepsis, antisepsis and surgical procedures. Of special importance here is the removal of prolapses of the interior; the iris, by iridectomy, the chorioid and vitreous, by cautery, and careful suturing of the scleral wound, followed by conjunctival covering.

I am sure that I have saved many eyes from infection by the instillation of 50 per cent. argyrol solution into the conjunctival cul-de-sac, as a routine dressing for injuries and operative wounds, and especially by the injection of a 50 per cent. argyrol solution into the an-

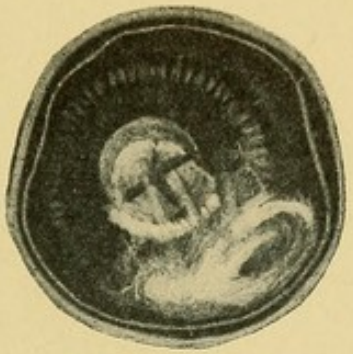

Fig. 271.
Recent wound of lens and ciliary body, showing fresh exudate in the vitreous.

terior chamber through the accidental wound, even when evidences of infection, as iritis and hypopion were already evident. The 1:3000 bichloride ointment as a dressing for the edges of the eyelids prevents entrance of micro-organisms and kills off the streptococcus endemic to the tarsus.

Old cystoid cicatrices may be dealt with by the galvano-cautery, the outgrowth being seared evenly with the surface of the globe; antisepsis, atropin and a bandage applied. I have cut off and seared by the cautery a number of such protrusions without causing special irritation.

The treatment of sequelæ frequently sums itself up in enucleation or one of its substitutes. Cystoid cicatrices may be ablated by the cautery, or various operations done for ectasiæ.

Landesberg[5] ablates a scleral ectasia by repeated corneal incisions, even to 17 sittings. As this method is very wearisome to the patient he recommends the excision of a sectoral section 1 to 2 mm. in

width, the end results being the formation of a thickened cicatrix which conserves the normal form of the globe.

Eversbusch[4] recommends many small punctures by the galvano-cautery.

Diagnosis. The loss of tension bespeaks an opening of the eyeball. If the wound be posterior to the corneo-scleral margin it will probably remain open, vitreous extrude and the tension be greatly diminished. If anterior and followed by prolapse of iris, the latter may clog the wound and the tension be re-established. Careful examination with the loupe by direct and oblique illumination, and by the ophthalmoscope and diaphanoscope, should reveal the condition.

Prognosis. The prognosis as regards retention of the globe, barring the possibiilty of sympathetic disease, is now-a-days very good. In former times most such eyes came to immediate enucleation. (See chapter on Sympathetic Inflammation). But even the smallest prick of

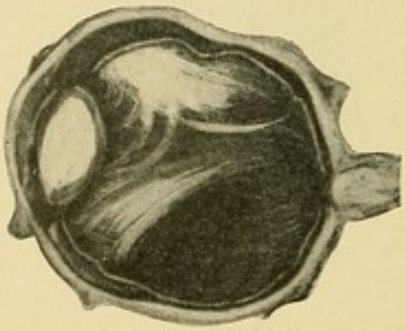

Fig. 272.

Organized exudate in vitreous from wound of ciliary region, and vitreous with membrane formation.

a needle, if septic, may cause loss of the eye through infection, and as we never know until several days have elapsed as to this probability, the prognosis should be withheld. As regards sight, the prognosis is never good, for the subsequent cicatrical contraction changes the relation of the parts and may give rise to a chronic iridio-cyclitis, and ultimate atrophy of the globe.

Therapy. We have here to choose between the radical removal of a badly injured eye, which as a rule prevents the patient from working for a long period of time, or conservative efforts to preserve the globe with more or less sight.

Immediate enucleation, or one of its substitutes, should be done in all badly-lacerated injuries of the ciliary region, particularly if infected or if over 20 per cent. of the vitreous has been lost. Immediate enucleation should be done in badly injured globes where little or no sight can be expected, in the case of working men who cannot afford the loss of time or expense ensuant upon conservative handling. If in spite of con-

servative treatment inflammation occurs and progresses, we should enucleate as soon as we see that the sight cannot be saved.

The future of the eye depends upon the changes in the vitreous and especially the amount of contraction of the exudation, which we cannot see distinctly in such eyes, but which we recognize by steadily diminishing sight, due to implication of the retina, and gradually increasing softness of the globe.

We repeatedly test the acuity of vision, the light perception, and when we find perception of light has been lost it is well to enucleate if at the same time the eye has become soft. The changes in the anterior portion of the eye observable belong to a plastic irido-cyclitis, but these are not so much to be depended upon, aside from the infective signs, for enucleation indications as those relating to the gradual loss of sight and tonicity of the globe.

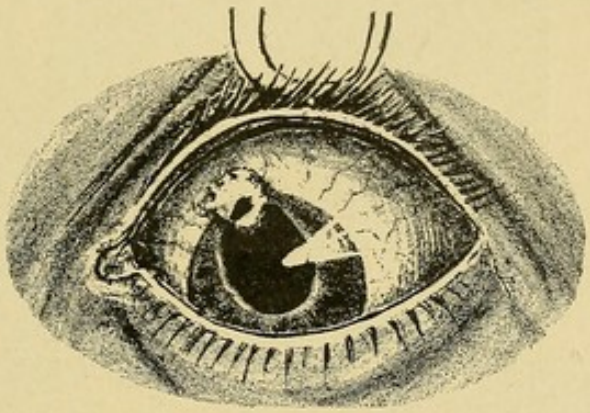

Fig. 273.

Cystoid cicatrix of iris at limbus cornea from penetrating wound.

The next indication is the iridectomy for prolapsed iris. It is generally useless to attempt to replace a prolapse, it only recurs, because impacted and results in a cystoid cicatrix with its resultant dangers. Eserin likewise is a failure in the attempt to produce union, and retraction of the iris from the wound. Indeed, neither atropin nor eserin exercise any effect upon the position of the pupil if the anterior chamber be open. It is good, then, to seize the prolapse with delicate forceps and by gentle traction draw it out a little, immediately snip it off, and complete the toilet of the wound.

Protruding portions of the ciliary body and chorioid should not be excised on account of possibility of loss of vitreous and infection of the interior of the globe. Prolapses of the vitreous should be excised. If the lens be injured it is best, as a rule, to wait a number of days before sewing up the wound, or weeks before attempting removal of the traumautic cataract by discission or linear extraction.

Penetrating wounds of the posterior part of the eyeball pass through the conjunctiva and sclera, and involve prolapse of the intraocular contents. These wounds are most successfully treated by the conjunctival flap method, with or without scleral stitches.

The Scleral Suture. All scleral wounds over 3 mm. in length are apt to gape and allow extrusion of the intra-ocular contents. One, two, or more finest catgut, kangaroo or rat-tail tendon, interrupted sutures, threaded on very sharp, moderately-curved needles, may be passed through the lips of the scleral wound and it coapted thereby, care being taken not to lose more vitreous; the lips of the wound may be

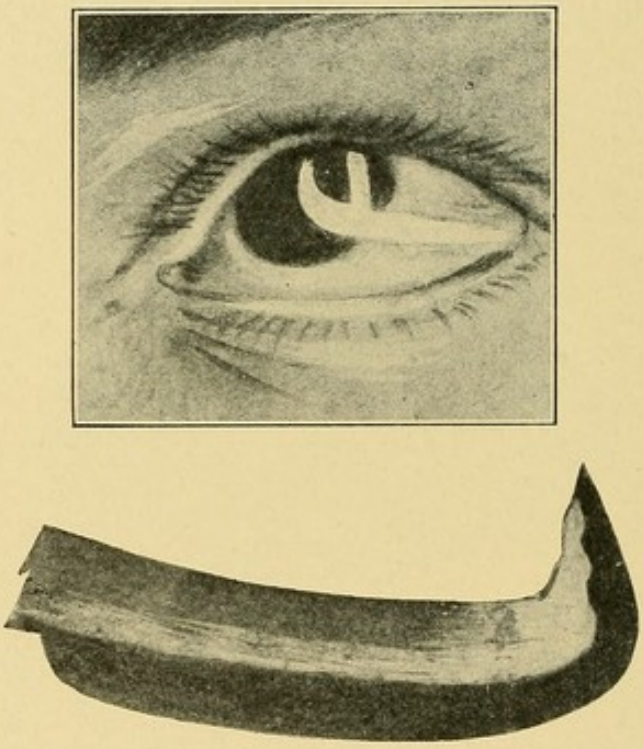

Figs. 274-275.

Extensive laceration of eyeball from piece of hot horseshoe. Recovery with V=20/xl. (Eaton.)

seized by toothed forceps and, with needle sufficiently sharp, the central suture is taken first and loosely tied. The stitches are snipped close to the knots and a flap of the conjunctiva dissected up and sutured in place by interrupted, iron-dyed silk sutures, the line of the conjunctival stitches passing outside of the sclera, the stitches in the latter being buried and allowed to absorb, those in the conjunctiva being removed about the fifth day.

Baretti,[6] in 1833, first described suturing of the sclera in a 1 cm. long wound caused by penetration of the eye by a splinter of glass. Bowman,[7] Critchett,[8] Windsor,[9] and Lawson,[10] and others in past decades, used this procedure with good results. In all wounds

of the sclera it is necessary to replace or remove tags of tissue therefrom in order to secure good healing. In the olden days these cases were usually treated only by the bandage and rest, but many such were followed by ectasiæ and infection, and hence the suturing of such wounds was taken up.

When the wound is sectoral and does not gape its closure by conjunctival suture is advised by Simeon Snell[11] as the operative procedure needed aside from the toilet of the wound. In the gaping, tangental, or meridianal wounds actual sutures of catgut through the sclera, either through the outer layers where the sclera is thick, as anciently used by Lawson,[10] or, where thin, through the whole thickness, as advised by Czermak,[12] should be placed.

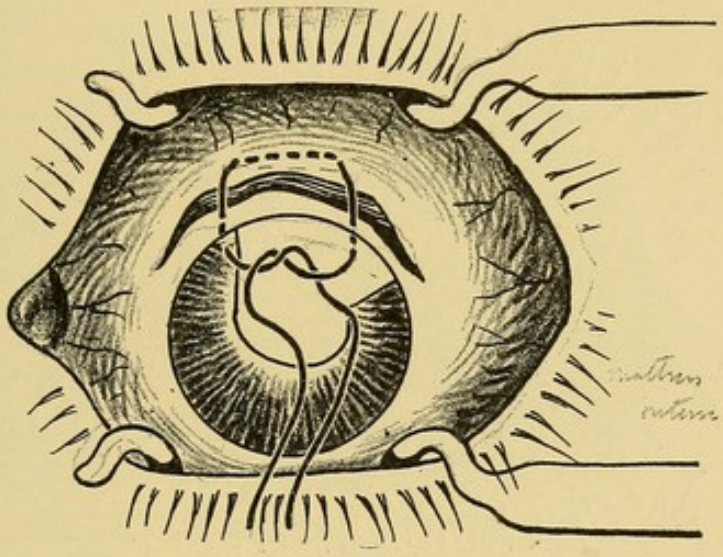

Fig. 276.
Author's mattress suture.

Fage[13] sums up the advantages of the scleral suture: 1. It protects the interior of the eye from infection. 2. It hinders the further loss of vitreous. 3. It prevents the formation of fistula, cystoid cicatrix and staphyloma. 4. It causes the formation of a much more regular and flat cicatrix, and the probability of secondary retinal detachment is less. 5. It shortens the healing period.

Eversbusch[4] recommends the suture even in central contused and lacerated wounds when not infected. Czermak[12] gives the following contra-indications for the scleral suture: 1. In severe, and especially deeply penetrating wounds with extensive loss of vitreous, threatening entire loss of the intra-ocular contents, extensive bleeding into the vitreous cavity, and when the eye is so severely damaged that its removal is immediately indicated. 2. When a foreign body remains which cannot be removed from the globe. 3. When appearances or course point

to inflammation of the globe. 4. Fage[13] also gives the following as a contra-indication for the suture: When in the case of a scleral rupture the conjunctiva has not been torn open.

Czermak[12] does not agree with the latter contra-indication, as under modern asepsis wounds should heal well without infection, and a gaping conjunctival rupture would allow of prolapse of intra-ocular contents and, therefore, especially when the lens has been dislocated from the conjunctiva it is necessary to remove the lens and sew up the wound.

The needle and suture operation is made as in the case of corneal suture under local or general narcosis, the edges of the wound being held by fine forceps, or, as Kerzendorfer[14] advises, by a fine hook, but I prefer the forceps. If the conjunctiva be torn or wounded at the same

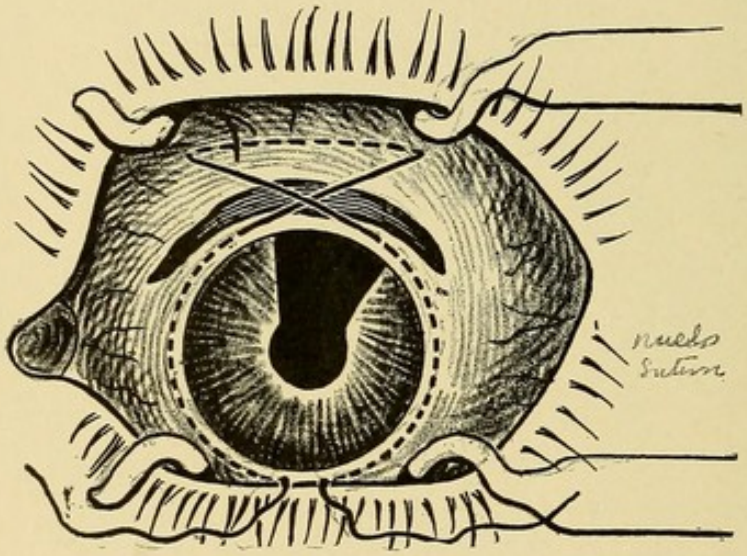

Fig. 277.
Nuel's suture.

place the needles and threads may pass through the conjunctiva or episclera, when silk sutures may be used. If the conjunctival wound is at another place the sutures should be of catgut or tendon and the conjunctival suture of silk.

Lawson,[10] in 1871, and other authors up to Czermak,[12] in 1907, recommended double-armed sutures, i. e., with a needle on each end passed through the lips of the wound edge out and then tied.

In some cases I have used the mattress suture, made by passing the first needle of the double armed suture from without towards the lower lip of the wound, through the corneal or episcleral substance, then across the wound, again into the episclera of the lip of the wound, crossing over, entering the scleral tissue again behind the lower lip of the wound. The wound then being approximated by forceps the knot is tied on the surface of the cornea.

Another kind of retaining or tension suture has been made by Nuel[15] for corneo-scleral rupture and after sclerectomy for cystoid cicatrix. A double-armed suture about 2 cm long is passed under the conjunctiva behind the wound about the equator of the globe, then crossed over the wound to the inner side, being tied below. These sutures may be removed about the fifth day, when the wound will be found to have sufficiently coapted.

Wounds over one cm. in length are apt to gape and one or more scleral sutures of finest chromicized cat-gut should be put in, and the lips drawn together. Over this the Kuhnt[16] double-pedicled, conjunctival flaps should be drawn, or if the wound be posteriorly a flap may be made in the conjunctiva and bridged over the sewn-up scleral wound.

Immediately after coaptation of the edges of the wound by sutures, and covering by a conjunctival flap, atropin and eserin again affect the pupil, and of these atropin is preferably used in order to open the pupil and to quiet ciliary contraction. A 5 to 10 per cent. solution of dionin will give relief to the pain.

In some cases where the conjunctiva is chemosed it will be necessary to subdue the swelling by iced compresses or by leeches to the temple, before the toilet of the wound and suturing may be made.

Where the patient is exceedingly nervous, and in the case of young children, a general anesthetic is necessary for these procedures, but usually in adults cocainization gives ample anesthesia.

Cystoid cicatrix should be dealt with by the galvano-cautery, the outgrowth being seared evenly with the surface of the globe; then antiseptics, atropin, and a bandage applied. I have cut off and seared by the cautery a considerable number of such protrusions without causing any special irritation.

A hunter, trying to capture a wounded crane, was struck in the face by the bill of the bird. Luckily the blow expended itself mainly on the malar bone and only the point of the bill entered the eye through the sclera. I saw him several days afterwards when the eye, though congested, had nearly healed, and uneventful recovery took place.

A girl was playing with a vicious dog who snapped at her face, tearing away the lower lid at the outer canthus, and the brow above, the incisor teeth evidently catching the globe between them and biting out a piece of the sclera and cornea. When I saw her the contents of the globe had run out, and aside from the reposition of the lids nothing could be done except an enucleation, which was immediately made under general anesthesia. The lids healed kindly and prothesis was ultimately made.

Schmidt-Rimpler[17] saw a dog-bite through the sclera which,

although iritis with a gelatinous exudate ensued, recovered with vision and only a small scar.

Rodewald[18] reports a perforating scleral wound from the beak of an owl.

Pitchfork and whiplash injuries, from the nature of the agent are usually infected and result in panophthalmitis. Of such I have seen several, fortunately early enough to remove the eye by enucleation and thus remove the focus of infection.

I have seen many stab wounds of the sclera from knives and scissors, the majority of which came to enucleation; in some the scleral and conjunctival suture has saved the eye.

An irregular, of Chicago, one of whose specialties was the "curing" of diabetes by operation on the extrinsic ocular muscles, had done this job on a man with such crudeness that he had contrived to snip through the sclera during his attempted tenotomy, producing the effect, in after years, if a quadrantic atrophy of the chorioid, retina and optic nerve, with reduction of visual acuity to 6/lx and a quadrantic defect in the visual field.

A young man was set upon at night by highwaymen and slashed across the face with a knife which cut through the upper lid, cornea, ciliary region and sclera. As this was a slicing wound and evidently not deep, not involving the lens, I put in four scleral stitches of fine catgut, and pulled a large flap of conjunctiva down over the wound, after the manner of Kuhnt, and had the satisfaction of securing immediate healing with resultant vision of 6/xxxv after two years, although the visual field became contracted and the cicatrix was depressed.

In a child who had cut the sclero-corneal margin with a sharp knife I made a double-pedicled conjunctival flap and saved the eye, with vision.

LITERATURE.

1. Korschenowsky, ref. Praun, p. 204.
2. Schunkitz-Myashita, *Inaug. Dissert.* Wurzberg, 1886.
3. Lublinsky, *Arch. f. Ophth.*, XIII, p. 378.
4. Eversbusch, *Münch. Med. Woch.*, p. 487, 527, 1891.
5. Landesberg, *Arch. f. Aug.*, XVII, 2, p. 202.
6. Baretti, *Gaz. Ital. d. Etats Sardes,* 1833.
7. Bowman, ref. Czermak, p. 688.
8. Critchett, ref. Czermak, p. 688.
9. Windsor, *Roy. Lond. Hosp. Reports,* p. 397, 1871.
10. Lawson, *Roy. Lond. Hosp. Rep.*, p. 14, 1871.
11. Simeon Snell, *Ophth. Rev.*, p. 88, 1887.
12. Czermak, *Augenärtzlichen Operationen.* Vol. II, 1907, pp. 689-690.
13. Fage, *Ann. d'oculist.*, cxii, p. 262.
14. Kerzendorfer, *Arch. f. Aug.*, p. 44, 1878.
15. Nuel, *Ann. d'oculist.*, p. 270, 1888.
16. Kuhnt, *Die Verwerthbirkeit der Bindehaut,* etc.
17. Schmidt-Rimpler, *Klin. Monatsbl. f. Aug.*, XIII, p. 315.
18. Rodewald, *Inaug. Dissert.*, Kiel, 1896.

B. FOREIGN BODIES.

Etiology. Praun[1] says that foreign bodies in the sclera occur about 200 times less frequently than in the cornea, the cause being the more efficient protection by the brows and lids; its resiliency from being of a greater radius than the cornea, and foreign bodies rebounding therefrom or boring through into the interior of the eye rather than remaining in the scleral tissues. In very few cases does the foreign body remain in the sclera or sclero-conjunctiva. Of these powder grains, sand, etc., the result of explosions, are most common. Surgical accidents, like the breaking off of needle points in advancement operations, or the point of cataract knife in corneal incisions, doubtless happen to all operators, as they have in my own experience.

I can recall no case of iron particles in the sclera, but I have seen several glass, stone and powder splinters, and shot grains. Other authors have reported lead, brass, and wood splinters.

Symptoms and course. A hemorrhagic spot is usually seen at the wound of entrance and the conjunctiva may be moved over the foreign body, the latter membrane may have been more or less torn by its entrance and stained by particles of the same substance. Small, glowing foreign bodies may burn deeply into the sclera and remain there, as hot sand, particles of metal, etc. After powder and dynamite explosions many grains of powder, sand, etc., may be found in the skin of the lids, in the corneo-scleral conjunctiva and sclera occupying in the eye the opening of the lids. As a rule the further course is attended by swelling and injection of the conjunctiva. There is not much pain and small aseptic foreign bodies, as powder grains, sand, etc., may heal into the tissues without causing irritation. Large foreign bodies may remain in the sclera or penetrate into the capsule, ultimately causing loss of the globe by infection.

Diagnosis. Small foreign bodies lodged in the sclera may not be visible on first inspection on account of the conjunctiva being stretched over them, their imbedment and blood clots disguising their nature. So days and even weeks may pass without their presence being known. However, most of them may be seen in the eye, or felt by means of a probe passed over the surface of the wound.

Prognosis. The prognosis is generally good, as small foreign bodies may heal in the tissue of the sclera without much irritation and at any rate when diagnosed they may be readily removed, except when perforating.

Therapy. Medium-sized foreign bodies sticking into the sclera, may, after cocainization of the eye, be seized by the forceps and pulled out. Others have to be cut around by the scissors points, gouged or cut

out by the gouge and knife, care being taken not to push the foreign body through into the interior of the eye. In the case of iron the magnet may be first tried. If the foreign body cannot be removed, in a first attempt, without too much discission, it is better to wait a few days and then to try again. Powder grains and stains, and particles of stone or sand, may be cut and scraped away after incising the conjunctiva.

Many cases of powder grains and stains and impaction of sand in the sclera have been attended by me, of which the 4th of July cases already noted are a type.

Industrial accidents in mines frequently result as follows:

A miner was tamping a fuse when it, with its charge, exploded, killing him immediately and knocking unconscious his helper, who was then a few feet away, facing him. The latter's face was burned, the right eye literally blown out, i. e., a large rupture of the sclera with immediate loss of all the ocular contents resulting; in the other eye, and in the face, there was impaction of many particles of stone and sand, some of them in the lids, cornea, conjunctiva, and sclera, and in addition there was a detachment of the retina. The case was attended to by the mine doctor; little could be done when I first saw him.

A girl labeling full beer bottles had a bottle break and explode from knocking it against another. Pieces of glass flew into her face and a particle into her eye, from which it extruded, between the lids, when I saw her. On seizing it with the forceps the splinter, which was about ½ inch long and 1/6 inch thick, was removed. Full healing without loss of function occurred.

In several cases I have broken off the points of defective needles in the sclera while operating, usually succeeding in immediately finding them, but in one instance not getting the point out for several weks, when the localized congestion pointed to the place of its impaction.

I once saw a German operator break off the point of a von Graefe knife in the sclero-cornea, call for another and proceed with the operation. The outcome of the case is unknown to me.

LITERATURE.

1. Praun, l. c. p. 211.

C. INJURIES BY BLUNT OBJECTS; RUPTURES OF THE SCLERA.

Bursting of the sclera may be either direct or indirect. It usually involves all the layers but in rare instances may be partial. It generally occurs within 3 mm. of the corneo-scleral margin, that being the weakest portion, but may in exceptional cases be posterior.

Direct rupture results from a blow with a blunt object, striking the eye directly, and is of less frequent occurrence than indirect rupture of either the sclera or cornea.

Müller[1] reported such a case in a 20-year-old cooper, who fell against the round end of a barrel rack, in which the eye was driven outwards and forwards, the blow evidently coming from behind and sideways, the rupture being on the same side. The eye went on to phthisis bulbi.

Indirect rupture results from the globe being driven against the walls of the orbit and suddenly put in a condition of increased tension, and thus burst betwen the nether and the impinging body. As a rule such a blunt body as a cow's horn enters between the eyeball and one wall of the orbit, although sudden, even compression, as from the blow of a fist, may do the same injury.

Etiology. The etiology of both direct and indirect ruptures is the same.

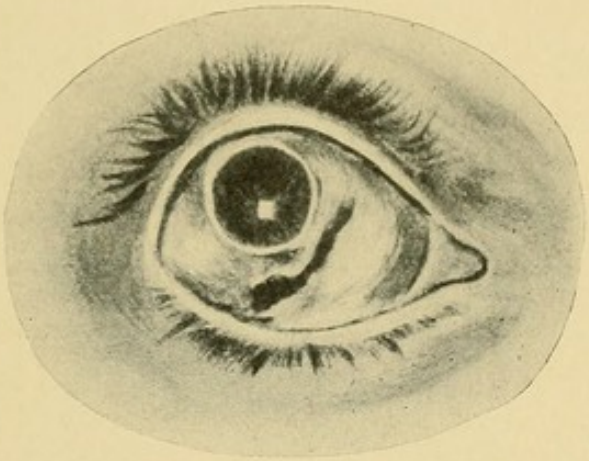

Fig. 278.
Rupture of the eyeball.

Sachs,[2] in 97 cases gives the causes as follows: 23 from cow's horns; 19 by falls against ordinary household furniture, as tables, bureaus, beds; 14 from ends of wood or iron objects as sticks, wagon-shafts, gas-jets, gun-barrels, etc.; 8 from fisticuffs; 6 from finger ends; 1 from the outstretched hand; 9 from flying pieces of wood; 3 from thrown pieces of stone or chunks of earth; 4 from hoofs; 3 from whip-lashes; 2 from falling against a door; one each from a blow by a hammer, quoit, rapier or rod. In Müller's[1] cases 14 were due to cow's horns, 22 to other blunt, and 5 to sharp ended objects.

Of other causes Landesburg[2] gives four cases due to blow from a beer glass. Ansiaux[4] one to blow from the curve of a cow horn, not its end. Rane[5] one to highwaymen gouging the eye. Other objects are thrown pieces of wood, snowballs, potatoes, ends of rope, corks springing out of charged water and champagne bottles. Praun[6] says that it is remarkable that indirect rupture has not been reported

from gunshot injuries. Older eyes are more subject to scleral; younger to corneal rupture.

Not only normal eyes may be injured but diseased organs with staphyloma, both anterior and posterior, high grades of myopia and buphthalmos, are physically predisposed to such a break in their walls. Eyes blind from glaucoma have already heightened intra-ocular tension and are predisposed to bursting. Blind or poor-sighted eyes from other causes are more liable to acquire injury from not seeing objects and being able to dodge their approach.

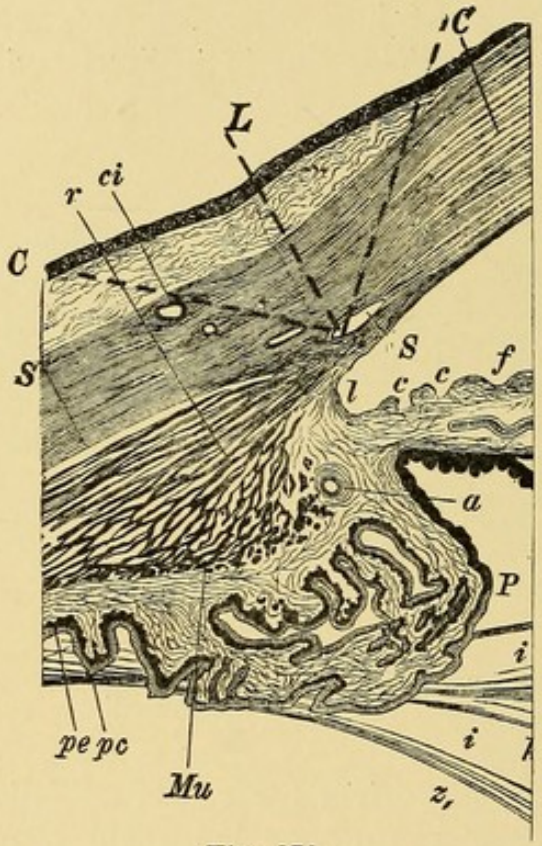

Fig. 279.

Course of a scleral rupture. Magnified. (Modified from Fuchs.) s-c, canal of Schlemm to limbus; s'-c', canal of Schlemm to cornea. s, sclera. c, conjunctiva. r, radial fibers of ciliary muscle. ci, anterior ciliary vein. l, limbus. c', cornea. s', canal of Schlemm.

Mechanism. The mechanism of direct scleral rupture is the same as that of direct corneal rupture. The portion of the eye impinged upon by the force has to give way and the eye bursts at that point.

Indirect scleral rupture is due to the globe giving away where it has no cushion of fat to afford it resiliency and to absorb the shock in the weakest place. The strongest place in the sclera is just behind the insertion of the extra-ocular muscle tendons, but this is protected by the orbital fat and the globe never bursts here, but in the zone

between the insertion of the muscles and the limbus, the rupture taking place from within outwards, in the region of Schlemm's canal, which is the weakest place, for here the tough inner layers of the sclera are transformed into the delicate lamellæ of the ligamentum pectinatum and its resistance diminishes at this point. Müller[1] says that in the otherwise strong scleral wall here a frail place exists.

Most scleral ruptures start from a point situated upwards and inwards, where the trochlea forms a bony prominence, at the upper and inner angle of the orbit, and when the eye is forced against it by a blow coming, as most do, from below and outwards, the trochlear prominence presses into the sclera and causes the rupture to begin in this meridian. The rupture is in the so-called meridian of expansion about 2.5 mm. behind and concentric to the limbus, a fact shown by both clinical observation and by the experimental research of Müller[1] and others.

The rupture varies from 3 to 12 mm., being commonly ⅓ to ½ the corneal circumference, and sometimes much larger than the ordinary cataract extraction wound. At either end the rupture does not usually go through all of the lamellæ. The wound usually gapes and the vitreous extrudes, however in some cases in not a sufficient quantity to ruin the eye.

Müller[1] worked out the direction of the force in 29 cases, of which 22 were out and above, in and outwards and above, 3 in and down, 2 down, and 2 out and down.

In 17 cases of the 29 the distance of the middle of the rupture from the point of impact was 90°; in 3 cases less and 5 greater. In one case the point of the cow horn had bored between the bulb and the orbital wall. In other authors' statistics quoted by Praun[6] of 20 cases, 11 times the foreign body had passed between the globe and the orbital walls.

Symptoms. Ruptures of the sclera are such serious injuries because a force sufficient to burst the eye causes injuries in more than one place. The eye is immediately blinded, the fluids run out, lacrimation and pain with occasionally great nervous shock are the immediate symptoms.

The iris is almost always torn away from its insertion at a point corresponding to the extent of the scleral rupture, causing irido-dialysis, and either protrudes or is incarcerated under the conjunctiva, the eye presenting a coloboma. The portion of the iris remaining in the eye retracts or infolds in itself (inversion), or shrinks so that but little of the structure can be seen (irideremia), or the whole iris may be extruded (aniridia). However, the iris can remain intact and the pupil remain round, especially in cases where the lens is luxated under the conjunctiva, for here the aqueous does not flow out and force the iris into the wound.

The ciliary body in many cases is injured and severe bleeding into the anterior chamber and vitreous results, so that at first the internal conditions are not visible. Where the iris is inverted the ciliary processes can not be seen, but when a dialysis or aniridia is produced they are ultimately visible.

In but few cases does the lens remain in position, being usually extruded from the wound as the pit from a cherry, or it may lodge under the conjunctiva, provided the latter be not ruptured. The lens usually comes away in its capsule, the latter seldom remaining in the eye. It may also be dislocated into the vitreous.

The vitreous extrudes and is lost to a greater or less extent, even to total loss. Bleeding is usually extensive into the vitreous.

The tension is always diminished; the anterior chamber is deepened; hyphemia usually occurs.

The retina and chorioid may remain intact but are frequently torn or detached by sub-chorioidal hemorrhage. Where the visual acuity is restored they cannot have been injured.

Course and complications. In very favorable cases where the iris, ciliary body or lens are not affected, the eye heals in 4 to 6 weeks. The hemorrhage is resorbed; the wound is filled in by scar tissue. Even where the lens has been extruded, vision may remain, as in a case seen incidentally by me, and one reported by Fuchs.[7]

Since to the severity of such lesions as above described there is added the danger of subsequent infection of the wound, traumatic irido-cyclitis, formation of membranes in the vitreous, scleral staphyloma, phthisis bulbi and sympathetic ophthalmitis, it is little to be wondered that most such eyes go on to destruction, or are early enucleated to avoid these disastrous sequelæ. De Wecker[8] speaks of secondary glaucoma following suturing of the wound, but other authors, especially Kuhnt,[9] Schirmer,[10] Vossius,[11] Eversbusch,[12] are in favor of it.

A few of the rarest complications are concomitant dislocation of the bulb, fracture of the orbital walls and traumatic tetanus.

Diagnosis. The character of the injury, its position, the usual loss of the lens and scleral impaction of the iris, loss of vitreous and diminished tension, tell the tale of a ruptured sclera.

It is difficult to distinguish a direct rupture from an indirect, but in the former the area around the rupture shows evidence of bruising, laceration and loss of epithelium.

The bleeding into the anterior chamber, in the wound, and under the conjunctiva prevents all the injury from being immediately seen, but this clears up in a few days when the injured parts can be thoroughly examined.

The diagnosis is helped by transillumination which shows up the

interior blood clots, the iris, ciliary body and lens, if the latter remain. If the Purkinje-Samson reflexes, antero-posterior surfaces of the lens, be absent, diagnosis of aphakia may be substantiated, or if present and misplaced, of dislocation of the lens. A tremulous iris bespeaks aphakia or total dislocation; an iris that is pushed forwards in one part, the opposite being tremulous and the anterior chamber deeper, tells of a partial dislocation. Sooner or later such lenses become cataractous and are then readily seen.

Prognosis. The prognosis is usually unfavorable, except where the iris, ciliary body, or lens is not affected, or the eye remains free from infection. As a rule traumatic irido-cyclitis sets in and the eye goes on to atrophy. Müller had 12 favorable outcomes in 35 cases.

Therapy. The first duty is to cleanse the injured eye; bandage both to keep them still and prevent further loss of vitreous, and in about 48 hours to remove the iris prolapse, put in scleral sutures and sew over the wound a bipedunculated conjunctival flap. Next to control the hemorrhage by the application of cold, and to use antiseptics in the conjunctival cul-de-sac. Both eyes should be kept lightly bandaged and the patient in bed. The after-treatment is that of perforating wounds of the sclera and sclero-corneal margin.

The lens should be removed if under the conjunctiva, and cataract may be later dealt with by the usual method if there is enough vision left to warrant the operation.

Cystoid cicatrices may be ablated by the cautery, or various operations done upon the staphyloma, but the treatment of sequelæ frequently sums itself up in enucleation, or one of its substitutes.

Landesberg[3] ablates a scleral ectasia by repeated parallel incisions (even to 17 sittings), or as this method is very wearisome to the patient, recommends excision of the sectoral section ½ mm. in width. The end results are the formation of a thickened reuniting cicatrix, which conserves the normal form of the globe.

Eversbusch[12] recommends many small punctures by the galvano-cautery.

I must admit that I have taken out nearly all eyes that have come to me with rupture of the sclera, so great is my dread of sympathetic disease. However, I have seen several in which a scleral rupture had undoubtedly occurred where the remarkable efforts of Nature had conserved the eye with vision.

A man of 60 years with only one eye, the other having been lost by ophthalmia neonatorum, came to me for glasses, stating that he had almost lost his remaining eye from a blow on a table corner some years before. In this eye there was an almost total irideremia, a little tag existing below, the lens was almost clear and the ciliary processes could be

beautifully seen. There was a scar about 3 mm. back of the corneo-scleral margin. The vision, with a high compound lens, was about 6/1x. He was able with this to get about town and sell goods as a peddlar.

An old man with partial cataract in one eye and aphakia in the other was incidentally seen, who stated that the aphakic eye which he was depending upon, had been blind, when a cow hooked him and he felt the water of the eye come out. He had some pain, put on a home-made bandage and did not consult a doctor. His sight gradually returned in this eye and he got a glass from a jeweler-optician with which his vision was better than in the other eye, which was now getting blind from cataract. I have had more or less authentic reports of other such cases, the occurrence of which is substantiated by the following:

Fuchs[7] says: A farmer once presented himself at his clinic who had been gored first in one eye and then, some years afterward, in the other also, by a cow's horn. In both eyes there was a healed rupture of the sclera on the inner side, with what looked like a well-made coloboma of the iris. Both lenses were absent, but the fundus was healthy and with cataract glasses the sight was very good. This man, therefore, may be said to have had a double extraction performed by the cow, and that too, with more success than many operators are accustomed to have with their operations. Undoubtedly here the cow did the modern operation of expression of cataract in the capsule, hence the good result!

Leonhardt[13] says the comparative rarity of pigment deposition accompanying contused wounds with rupture of the sclera and traumatic coloboma of the iris (particularly aniridia) is the reason given by the author for the report of such a case. He summarizes the findings as follows: An extensive subconjunctival scleral rupture with an underlying dark pigmented area which may have been either a continuation of the first or an independent rupture, or there may have been no rupture of the sclera at all at this point. The determined rupture was in the usual position, up and in, and concentric with the corneal limbus, and removed several millimeters therefrom. The explanation of this predilection is the resistance offered by the trochlea and the weakening of the sclera at this position by the grooving occasioned by Schlemm's canal. It is worthy of remark that traumatic coloboma of the iris, when directed towards the staphyloma, points to an indirect rupture. In some cases there occurs total aniridia, with or without dislocation of the lens. In this case the lens was absent. In a number of cases the lens was luxated beneath the conjunctiva or was expelled entirely from the eye through bursting of the conjunctiva. In only a few cases was vision as good as in this case, $+ 10 = 5/x$.

The source of the pigmentation of the lower half of the conjunctiva which makes this case remarkable is problematic. That it was not

of hemic origin is shown by the fact that one hour after the accident the conjunctiva was blue-black in the lower half and over the rupture, and this was even more marked eight days later, after the ecchymosis had disappeared. It is very likely that primarily incarceration and infolding of the iris into the scleral wound took place and pigment was detached and washed by the blood beneath the conjunctiva. It is also possible that the ciliary body, with its rich pigment, was drawn towards the rupture and pigment particles were detached and commingled with blood, and finally that in the same manner some of the pigment may have been derived from the chorioid.

Shumway[14] says single rupture of the sclera is common, but a double rupture must be rare, as no mention of it can be found in literature. His patient was a man of 51 years who was struck a blow with a fist in O. D., which caused a rupture of the sclera in the horizontal meridian on each side of the cornea about 3 mm. posterior to the limbus. One rupture was about 6 mm. long and the other (temporal) was 3 mm. long. Each wound was filled with vitreous and pigmented tissue. This was trimmed off. The eye made a slow recovery, with distorted pupil, hazy cornea and no fundus reflex. Enucleation was advised, but was refused.

Posterior rupture. Rebounding missiles of small size, such as spent balls from fire-arms, have caused posterior, indirect ruptures of the sclera, which are usually concentric to the papilla. Such have been reported by Mules[15] and Chisholm.[16] Posterior direct ruptures from the double penetrating wounds by missiles are discussed herein under Fire-arm Injuries.

Partial rupture. When the conjunctiva is not torn the episcleral tissue also escapes, and such partial rupture has been reported by v. Arlt[17] and by Müller.[1] The latter's case showed, 2 mm. behind the upper corneal limbus in front of the rectus superior, two short bluish-black lines near each other, between which was a scleral bridge. Later staphyloma developed and a bluish-black line was seen extending to the horizontal meridian concentric to the limbus.

Rupture of the canal of Schlemm.

The rupture may be slight and not proceed beyond the canal of Schlemm, where it has been noted all anterior indirect ruptures begin.

Etiology. Contusions at the limbus, more particularly from small, semi-rounded objects as pencil ends, flying foreign bodies of small size and some weight, as spent shot, pieces of metal, small projectiles from play things, as beans, peas, etc., may strike the eye at the corneo-scleral margin directly, or force be communicated through the lid and

break the sinus venosus scleræ, causing a direct rupture with bleeding into the anterior chamber.

The indirect bursting of the canal of Schlemm alone is due to an incomplete rupture of the sclera at this point where only the inner wall bursts.

Symptoms and course. Czermak,[18] who is the principal writer on this subject, describes the bleeding as rapidly occurring and seen as a bright-red hyphema. Later diffuse dullness and fine dark or reddish lines, extending inwards from the limbus, appear in the cornea. The lines appear against the opacity, in examination by focal illumination, as a glass rod does in water. They lie in the posterior layers of the cornea and are probably due to folds in Descemet's membrane, or perhaps to tears in the same with imbibition of the aqueous and blood. The pupil is temporarily dilated but returns to normal after a few days.

The subjective symptoms are slight pain and temporary loss of vision from the hyphemia, which resorbs in a few days. The vision remains affected until the corneal dullness disappears and if there has been no rupture of the iris, ciliary body or zonule restitutio ad integram occurs.

The diagnosis is from the hyphema unaccompanied by damage to the iris, and by the mydriasis disappearing.

The prognosis is good, recovery ensuing in a few days.

The therapy is atropin and occlusion of the eye.

Czermak's[18] case may be quoted as typical. A 20-year-old iron worker had a piece of iron fly against the right eye and he saw dimly for several days thereafter. There was an excavation of the upper lid, conjunctival and ciliary vessels somewhat injected. Cornea diffusely dull; from the lower part of the limbus fine, light-gray lines converged to the center, which appeared under illumination by the reflecting mirror like glass rods in water. On the posterior corneal surface in the middle of the lower half there was an oval blood spot 4x2 mm. The anterior chamber was free from blood, the pupil round and reaction normal.

In William's[19] case there was an injury by a pellet of shot and the hyphema appeared.

I have not recognized such a case, but I found among the sketches of the late Swan M. Brunnett one which accurately fits Czermak's description.

LITERATURE.

1. Müller, *Über Rupture der korneo-skleral Kapsel durch stumpfe Verletzungen*, Leipzig, 1898.
2. Sachs, *Arch. f. Aug.*, XX, 4.
3. Landesberg, *Arch. f. Aug.*, XVII, 2, p. 202.
4. Ansiaux, ref. Müller.
5. Rane, ref. Müller.
6. Praun, l. c., p. 215.

7. Fuchs, *Text book of Ophthalmology,* Amer. Duane. Ed., 1909, p. 262.
8. DeWecker, *Traite des Mal., des Yeux.*
9. Kuhnt, *Die Verwerthbarkeit d. Bindehaut,* etc.
10. Schirmer, *Inaug. Dissert.* Griefswald, 1896.
11. Vossius, *Beitr. z. Aug.* XXII, p. 120.
12. Eversbusch, *Münch. Med. Woch.,* 1891, p. 487.
13. Leonhardt, *Arch. f. Ophth.,* LXVIII, July 14, 1908.
14. Shumway, *Ophth. Record,* Nov., 1906.
15. Mules, *Trans. Oph. Soc. U. K.,* p. 296, 1887.
16. Chisholm, *Arch. Ophth.,* XI, March, 1882.
17. v. Arlt, ref. Müller.
18. Czermak, *Klin. Mon. f. Aug.,* Apr., 1889.
19. Williams, ref. *Klin. Monatsbl. f. Aug.,* XXVII, p. 151.

D. THERMAL INJURIES.

Burns of the sclera proper are always complicated injuries; not alone the sclero-conjunctiva and scleral tissue may be burned, but in severe cases the true sclera even to its entire thickness, from which a defect occurs with prolapse of vitreous and uvea.

Etiology. Such deep burns occur from glowing or fluid metals or slag, the more superficial ones from chemicals, as acids and alkalies, especially lime, the latter of which may remain for a long time in contact with the tissues.

Symptoms, course, and complications. These are such as belong to severe burns. In addition there is the opening of the sclera and the danger of infection, which usually leads to panophthalmitis. More particular is the danger to the nutrient vessels of the cornea in burns involving the sclero-cornea, by which its nutrition is cut off and necrosis ensues. De Vincentiis[1] has seen a large cyst develop from a burn of the sclera.

The therapy is that of thermal injuries to the conjunctiva, cornea, and burns in general.

A man was struck by the glowing end of a heated iron rod on the sclera near the outer canthus, which caused a searing of the conjunctiva and a depressed burn of the sclera. Healing occurred after several weeks, but an opacity of the vitreous was found on ophthalmoscopic examination, which probably veiled over an atrophy of the retina and chorioid under the impaired area. V. = 6/xviii with angular defect in the visual field.

I have never seen perforation of the sclera from a burn. Praun[2] reports a foreman who received a glowing piece of slag in his right eye; great pain followed; cold compresses used. The eye looked, upon examination, as if panophthalmitic, lids swollen, pus oozing, conjunctiva chemotic, cornea intact. A small, round, black body was found impacted in the sclera, and under the upper lid, which was removed by

forceps. Healing in 14 days with end result of a thick white scar and adherent conjunctiva.

In a severe cauterization by lime I saw the cornea slough off from the destruction of its nutrient vessels in the sclero-cornea.

LITERATURE.

1. De Vincentiis, *Centrabl. f. prak., Aug.,* 1887, p. 340.
2. Praun, l. c., p. 225.

E. INJURIES FROM FIRE-ARMS.

Etiology. In civil life most cases are due to fire-works, gunpowder and dynamite explosions and the air-rifle in the hands of boys. Others occur from hunting accidents. A few bullet wounds occur as the result of attempted suicide or murder; in war the small shot is eliminated and the wounds are from bullets or particles of shells or their surroundings.

Wounds. Tangental and glancing wounds of the sclera occur in conjunction with those of the conjunctiva and cornea. They either cut through only the overlying areas or the entire thickness. Shot pellets may be retained between the conjunctiva and sclera without opening the globe. It is often difficult to find the opening in the sclera of penetrating shot wounds, and still harder to see the wound of exit in double-penetrating cases.

Bullet wounds make a larger opening and usually pass entirely through, the ball lodging in the orbit or cranial cavity.

Small shot wounds are usually round, seldom irregular or flap-like, the latter occurring when the shot does not strike perpendicular to the surface of the globe, nor in a tangental direction. In the neighborhood of the wound the conjunctiva is suffused with blood, the ciliary body, retina and chorioid may be seen impacted in the opening. In the case of perforating wounds at the limbus the iris prolapses and the anterior chamber is deeper than normal. The anterior chamber and vitreous fills with blood. The lens may likewise be broken up by the passage of a pellet.

Foreign bodies. Shot pellets and even portions of bullets may remain in the conjunctiva, under it and in the sclera. A grain may pass into the eye and be impacted in the sclera in the posterior wall, and in this case, if not much damage be done by the trauma after the bleeding is resorbed, it may be seen by the ophthalmoscope.

Contusions and rupture. A spent shot may strike the sclero-conjunctiva and produce thereby only a bruise, or the blow may be sufficiently severe as to injure the chorioid and retina, producing sub-retinal or sub-chorioidal hemorrhage, or later retinal detachment.

Direct ruptures of the sclera are common in injuries to the eye from bullet wounds, and such are reported in statistics relating to war.

Therapy. Excepting the most trivial wounds from shot grains, usually cases come to enucleation on account of the great damage done by the trauma.

Cases of injury to the sclera will be found reported in the general chapter.

CHAPTER XXI.

INJURIES OF THE UVEA, THE IRIS, CILIARY BODY AND CHORIOID.

A. Wounds. (a) Wounds of the Iris—Etiology—Symptoms—Course—Diagnosis—Prognosis—Treatment. (b) Wounds of the ciliary body. (c) Wounds of the chorioid—Etiology—Literature. B. Prolapse of the uvea. (a) Prolapse and incarceration of the iris—Etiology—Mechanism—Symptoms—Diagnosis—Prognosis—Therapy. (b) Prolapse of the ciliary body and chorioid—Therapy. (c) Operations for prolapse of the iris—Literature. C. Foreign bodies in the uvea. (a) Foreign bodies in the iris, the anterior and posterior chambers—Etiology—Symptoms and course—Long retained foreign bodies—Siderosis—Silver wire—Shot—Myiasis—Cilia in anterior chamber—Diagnosis—Prognosis—Therapy. (b) Changes in the iris due to the entrance of foreign bodies. 1. Tramautic iritis. 2. Iritis nodosa. 3. Cysts—Etiology—Symptoms and course—Diagnosis—Prognosis—Therapy. 4. Granulation tissues of the iris. 5. Sarcoma. 6. Tuberculosis. (c) Foreign bodies in the ciliary body—Etiology—Symptoms and course—Diagnosis—Prognosis—Therapy. (d) Foreign bodies in the chorioid—Etiology—Diagnosis—Prognosis—Therapy—Literature. D. (a) Injuries to the uvea from blows. 1. The iris—Hyphema—Etiology—Symptoms—Course—Diagnosis—Prognosis—Therapy. 2. Iridodialysis—Etiology—Mechanism—Direct and indirect dialysis—Objective symptoms—Subjective symptoms — Course — Complications—Diagnosis—Prognosis—Therapy. 3. Traumatic aniridia or irideremia—Etiology—Mechanism—Sypmtoms—Diagnosis—Prognosis—Therapy. 4. Inversion—Etiology—Mechanism—Symptoms—Diagnosis—Prognosis—Therapy. 5. Laceration of the sphincter — Etiology — Mechanism — Symptoms — Complications—Course—Diagnosis—Prognosis—Therapy. 6. Rhexis iridis. 7. Dehiscences between pupillary edge and ciliary processes. 8. Pigment dehiscences. 9. Anterior synechia after contusion. 10. Mydriasis and myosis traumatica — Iridoplegia — Etiology — Mechanism — Symptoms — Complications —Diagnosis—Prognosis—Therapy. 11. Atrophy after contusion—Literature. (b) Injuries to the ciliary body from blows. 1. Cyclitis traumatica. 2. Accommodation cramp and paralysis. 3. Rupture—Literature. (c) Injuries to the chorioid from blows. 1. Hemorrhage—Etiology—Symptoms—Diagnosis—Course and prognosis—Therapy. 2. Rupture of the ciliary arteries. 3. Hemorrhagic dislocation—Etiology—Mechanism—Symptoms—Course—Diagnosis—Prognosis—Therapy. 4. Indirect rupture—History—Etiology — Pathology — Types — Ophthalmoscopic examination—Atypical conditions—Single—Double—Multiple ruptures — Fork-shaped — Horizontal—Large ruptures—Functional disturbances—Course—Complications—Diagnosis—Prognosis—Therapy. 5. Direct rupture. E. Tumor formation. F. Injuries from firearms. 1. Iris and anterior chamber—Wounds—

Prolapse—Foreign bodies—Contusion and concussion. 2. Ciliary body—Wounds—Foreign bodies—Contusions. 3. Chorioid—Wounds—Contusions—Rupture—Literature.

A. WOUNDS.

a. Wounds of the iris are complicated by perforating wounds of the eyeball, of the cornea or sclero-corneal limbus, and usually by injuries to the lens.

Etiology. Such injuries generally occur through wounds of the cornea, then of the sclero-corneal limbus or sclera. The causes are those of penetrating wounds of the eyeball generally, especially sharp and pointed objects and foreign bodies, as knives, glass splinters and iron particles.

Symptoms. The patient complains of piercing pain of slight degree as is usual after an iridectomy. If inflammation occurs the pain

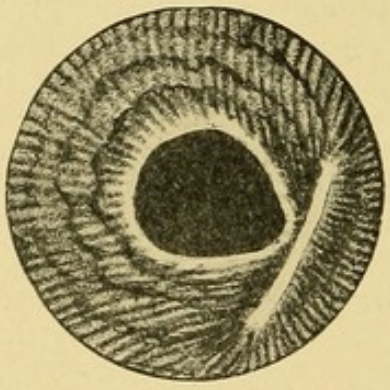

Fig. 280.
Incarceration of the iris after simple linear extraction without iridectomy.

may be severe, especially over the brow, and a piercing pain in the eye, headache, worse in the early hours of the morning or after lying down for several hours; photophobia, loss of vision and lacrimation are the common symptoms of an iritis.

Course. Wounds of the iris do not close; the lips stay open and a coloboma remains. The edges of the wound may heal onto the cornea causing anterior synechia and adherent leucoma, or to the capsule of the lens—posterior synechia.

Diagnosis. If the wound be not immediately obscured by a hyphema it may be seen in the iris as an opening in this membrane, in the depths of which a small blood clot is observed. The anterior chamber generally has a small hyphema and a little blood may be seen in the wound of the iris, which opens widely.

Prognosis is good, as injuries to the iris without implication of the lens do not materially affect the vision unless iritis occurs.

Treatment. By splinting the iris with atropin, and the use of asepsis, healing usually occurs with posterior synechia, but with a good eye if the other structures be not too seriously wounded. Iced applications are recommended by Praun[1] as well as eserin, the latter in peripheral wounds. I have never seen any good effect from the latter, as wounds of the iris never coapt and atropin is the one drug indicated to keep the eye quiet, to prevent anterior and posterior synechia, with secondary resultant dangers of glaucoma. Asepsis, argyrol and a light bandage are indicated for the accompanying corneal wound.

b. Wounds of the ciliary body, have already been quite fully discussed in treating of wounds of the sclero-cornea.

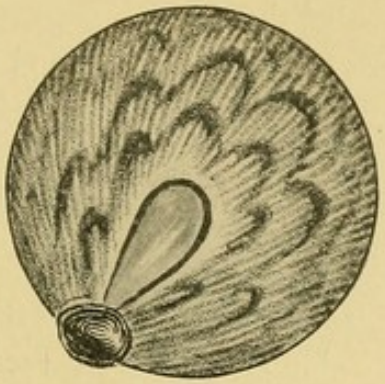

Fig. 281.
Small peripheral prolapse of iris.

c. Wounds of the chorioid.

These occur from all the causes of perforating wounds of the eyeball, especially from without, as those which pass through the sclera, such as cuts and foreign bodies. Penetrating wounds of the posterior portion of the eyeball involve the chorioid; they are likewise accompanied by injuries to the retina and vitreous. If clean they heal by cicatricial tissue, if septic, inflammatory changes result, producing iridochorioiditis and panophthalmitis.

Small foreign bodies may also pass through the vitreous and injure the fundus, passing through the retina to the chorioid and lodging against the sclera. Double penetration may likewise occur, particularly in case of shot wounds and occasionally chips of metal may be projected with such great force as to pass entirely through the globe. Sewing-needle, hatpin, and other piercing wounds of the sclera may pass into the interior of the globe by way of the chorioid and retina, causing circumscribed hemorrhage into the vitreous at the point of passage. In larger wounds the hemorrhage into the vitreous is severe and leads to formation of membranous opacities with great loss of vision. Larger wounds

of the chorioid are so intimately connected with those of the sclera that they have been discussed with these on another page.

If the hemorrhage occurs under the chorioid detachment of this membrane results. If the cut in the sclera heals without inflammation an atrophic spot remains in the chorioid.

In other cases retinal detachment ultimately results from cicatricial contraction, or the eye may go on to irido-cyclitis plastica and atrophy, or, if infected, to chorio-retinitis suppurativa, formation of abscess in the vitreous and panophthalmitis.

A man of 40 came complaining of loss of vision of one eye after an operation done by a quack oculist of Chicago who claimed to cure, by tenotomy and prisms, all sorts of local and general affections. Examination showed vision 6/xxx, visual field sectorally and concentrically contracted, a whitish area of the fundus corresponding to the place covered by the external rectus showed a localized detachment of the retina which later replaced, and chorioidal atrophy and optic nerve atrophy, with loss of vision, followed. The history showed plainly that the quack had cut through all the envelopes of the eye and the resulting localized inflammation had caused the atrophy.

A boy of 19 was slashed across the face, cutting through the eyelid, nose and chin, the cut extending through the lid, conjunctiva, sclera and chorioid between the inferior and superior recti insertions. The cut in the eye was oblique and though ½ inch long was not deep. At first severe reaction set in, but under rigid antisepsis (1:1000 sublimate compress and ointment, and atropin) the eye has been retained with good shape but with loss of vision from chorioidal and retinal detachments following the subchorioidal hemorrhages.

A foreign body may pass clear through the eyeball into the orbit, as in the following: An iron-worker was injured by another, who was fettling or chipping off the rough edges of castings, several feet away. The foreign body passed through the sclerocornea, ciliary body and vitreous, not injuring the lens, and made its exit from the eye about a disc diameter over the macula, passing through the sclera into the orbit. Recovery with useful vision.

Marple[2] reported two cases of double perforation of the eye from bird shot in which the eyes were saved with some sight. He quotes the case of Milbradt[3] in which there was double perforation.

Sweet[4] has reported a number of cases of double perforation.

Curt Cohen[5] reports a case in which the left eye of a man, aged 20, was injured by the explosion of a gun-cartridge, and was enucleated on the eleventh day after the symptoms of panophthalmitis had developed. The histological condition, which is described in detail, showed that the foreign body was lodged on the disc, causing an in-

flammation of the retina, with subsequent inflammatory exudation and infiltration of the chorioid, with formation of an abscess in the chorioid at the region of the macula. Violent exudation from this abscess through the basal membrane followed, with bursting of the pigment epithelium, subretinal accumulation of the inflammatory products under the macula, detachment of the macula under increasing accumulation of leucocytes and inflammatory edema. Finally, after two days, the retina was perforated in the fovea, and through this hole pus oozed into the vitreous. A blood vessel was ruptured and the blood filled the hole. The inflammation was propagated to the anterior segment, producing irido-cyclitis and hypopion.

The recent character of the hemorrhage proved that it was secondary, and that the macula was not ruptured directly or indirectly by the

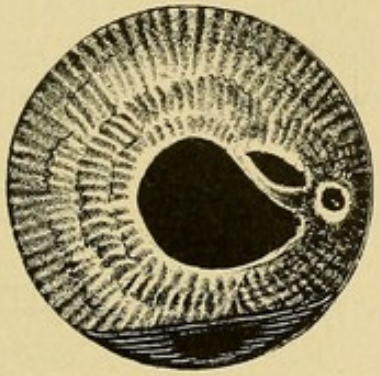

Fig. 282.
Wound of iris; anterior synechia; hyphema.

injury. The other possibility that the hole in the macula was caused by a process from the vitreous towards the chorioid could also be excluded by the absence of connection of the infiltrations of the vitreous, which were confined to the anterior portions, with the pus through the opening in the macula, and by the character of the pathological products. For the predilection of the formation of ruptures in the macula. Cohen emphasizes the peculiar vascular supply of the chorioid in the macular region, and the greater vulnerability of the macula on account of its architecture. The case showed that the chorioid may play an important part in the etiology of the formation of perforations at the macula. The literature, from the first description of Haab, is reviewed, and the histologic conditions illustrated on a colored plate.

LITERATURE.

1. Praun, Die Verletzungen des Auges, p. 227.
2. Marple, *Trans. Sec. Ophth. A. M. A.*, 1906.
3. Milbradt, *Inaug. Dissert.* Grünwald, 1890.
4. Sweet, *Ophth. Record*, July, 1907.
5. Cohen, Curt., *Klin. Mon. f. Aug.*, XLVI, 1, 1908, p. 620.

B. PROLAPSES OF THE UVEA.

a. Prolapse and incarceration of the iris.

Etiology, mechanism and symptoms. If the anterior chamber be opened the escape of the aqueous humor drives the iris forwards as far as the cornea, and if the wound is sufficiently open a portion of this membrane blocks the opening of the wound causing incarceration. In this way the anterior chamber may be restored in a very short time.

In case the perforation is larger the iris is driven into it by the escaping aqueous, engaging between the lips of the wound, and it may be extruding from the eye forming a prolapse or hernia of the iris. This, while recent, is a hemispherical prominence having the color of the iris and being wholly composed of its structure. Soon, however, a grayish exudation occurs which covers the iris like a cap and may be removed by the forceps. When the prolapsed portion is much stretched the retinal pigment of the posterior surface shows through and the color is black. This is particularly the case in large prolapses. The extent of the prolapse is proportioned to the size of the opening, and where the corneal tissue has been lost through suppurative necrosis may occupy the whole extent of the cornea, comprising total prolapse of the iris. If the patient strains hard during the prolapse the protrusion may take place with great force and be large, or if he is restless afterwards a relatively larger portion of the iris will extrude. The relation of the healing of an iris prolapse into the corneal wound is discussed under Cornea.

The pupil loses its round shape and is drawn to the wound, the portion of the iris impacted depending upon the position of the wound. If in the ciliary portion the ciliary zone of the iris becomes impacted and the pupil has the shape of a pear, if near the center of the cornea the pupillary edge engages and the pupil is not so distorted—it may be nearly round.

As in wounds of the eye the prolapse is synchronous with the injury; the symptoms are those of a wound. When, however, a wound secondarily opens, or an ulcer bursts, the patient feels the gush of the aqueous and a sharp pain, which may disappear in a few minutes or persist as a dull ache until reposition or operation for its removal.

Diagnosis. Prolapse of the iris is manifested differently according to the extent of protrusion. If the iris has pushed through to the outside it is visible as a dark swelling, or nodule, in the wound, in the middle of the section or at the sides. When the iris does not protrude but is merely jammed between the inner lips of the wound the pupil is displaced. If an iridectomy has been made the corresponding pillar of the iris is shortened and the angle of the sphincter drawn up even so that it may not be visible.

Prognosis. Inclusion of the iris in a wound interferes with the healing of the wound, which thus is protracted. The cicatrix is less solid, is irregular and even when formed may ultimately give rise to increased intra-ocular tension, inflammation and sympathetic disease. (See Healing of Corneal Ulcers).

Tooke,[1] writing on the protective influence exerted by the iris in perforated wounds of the cornea, says the wound of the cornea is frequently of an infective nature, be it a perforated ulcer or a perforation due to the entrance of a foreign body. By walling off the infected sides of the incision, an effort is made to ward off the entrance of bacteria into the anterior chamber and to avoid subsequent panophthalmitis. Beyond this purely mechanical action the blood vessels of the iris assist in carrying off the localized infection to the general circulation, thus preventing subsequent necrosis of the cornea. A second feature, noted by the presentation of the iris, is that the process of actual healing, or of granulation tissue formation, is materially assisted; that after draining away the infective agencies the number of leucocytes supplied by the blood vessels of the iris readily assist in the formation of new connective tissue elements. This tends to permanently close the perforation, and allows the reformation of the protective epithelial strata of the cornea. Besides completely filling the gap in the cornea and preventing any escape of the aqueous humor, the anterior chamber is restored and the intra-ocular circulation re-established.

It cannot be denied that many lamentable results are avoidable by performing an iridectomy or by releasing the anterior synechia. The author does not advocate Nature's method as being superior to surgical interference, but presents it as the means Nature adopts for closing an infected perforation in the cornea in a most effectual manner.

Therapy. Prolapse of the iris is common in operations involving opening of the anterior chamber as well as in perforating injuries. Therefore every attempt should be made to avert these results, and the wound carefuly freed from all bits of iris tissue, usually by abscission. In but few cases will the iris retract under eserin myosis, which usually proves disappointing. The spatula or a blunt hook may be used either through the wound opening or through a cut in the cornea made some distance away, the second opening equalizing the outflow of aqueous and permitting the pupil to resume its circular form, but iridectomy is the only safe procedure, as a prolapse is with difficulty retained within the anterior chamber. Heckel[2] uses eserin sulphate before ablating a prolapse, frees the wound by a spatula and in 24 hours uses atropin.

The following case ran the gamut of advice and treatment. A child of three years was playing with an opened pocket knife which had been used for ripping new cloth. He cut upwards, making a small wound

through the cornea, at the limbus, with an iris prolapse. A neighborhood doctor was called in who gave an eyewash of a cocain solution and said the injury was not serious. This not being believed two other physicians were called in, both of whom referred the case to me. They tried the effect of eserin, but on arrival at the hospital the prolapse still existed. Under general anesthesia I replaced the iris with the spatula and instilled eserin, but on dressing the eye the next day found it again prolapsed, so chloroform was again administered and a small iridectomy made and atropin instilled. This time the anterior chamber reformed without incarceration of the iris and the eye recovered in one week with perfect vision, the lens not having been injured and no infection resulting.

Every care should be taken to avert prolapse and inclusion of the iris in a wound.

With regard to fresh traumatic prolapses that cannot be replaced we can all agree that there is no treatment like a clean excision, but an attempt at reposition of iris prolapse may be made by replacing it with the spatula, either through the wound opening or through a cut in the cornea made some distance away from the wound (Dunn's and Jameson's method). In the latter case the second opening equalizes the outflow of aqueous and permits the pupil to resume its circular form, but as a rule iridectomy is the only safe procedure, as a prolapse is with difficulty replaced, and even harder to retain within the anterior chamber. Therefore the prolapsed iris should be seized by delicate forceps, slight traction being made, and the projecting portion abscised, after which the pillars are replaced by the spatula and the toilet of the wound completed.

Dunn[3] advocates indirect reposition through a new corneal incision through which a blunt iris hook is passed, making traction on the incarcerated iris, drawing it back into the anterior chamber instead of trying to push the prolapse back through the original wound.

Prolapse of the iris is a common complication of perforating and penetrating wounds of the anterior portion of the eyeball, with or without the entrance and retention of foreign bodies. All operations opening the anterior chamber involve risk of this event, in consequence of which iridectomy is in many cases made a part of such operation, as in the combined cataract extraction, removal of foreign bodies, etc.

The treatment of iridic prolapse was formerly either entirely expectant, the eye being bandaged and left to natural resources or it was subjected to the simple operation of cutting off the extruding portion of the iris and the stump seared by the thermal or galvano-cautery. As a portion of the iris remained in the wound, healing therein, an ectasia of greater or less degree followed this method.

There were many bad reports, not alone of increased tension but of infection of such a cicatrix, even years later, leading to suppurative irido-chorioiditis and panophthalmitis, as by Zehender,[4] Swanzy,[5] Leber,[6] and von Arlt,[7] so that now the healing of the iris into a corneal wound or perforation is looked upon with fear. Gifford[8] reports a case of sympathetic ophthalmitis from galvano-cauterization of iris prolapse and gives the literature with comments upon 7 such reported cases.

Leber[6] has explained his operation for loosening and removal of old iris prolapse. In many cases, especially in children and when the eye is inflamed and painful, general anesthesia is necessary. Even under general anesthesia the eye is fully cocainized. A lid speculum is commonly used, put in from the temporal side. Other operators, including the author, for all operations for opening the globe, prefer lifting the upper lid by the Wm. Fisher lid-holder or large strabismus hook as used by Major Smith and D. W. Greene, for expression of cataract in the capsule. The globe is held by fixation forceps near the prolapse at the corneo-scleral margin.

A conical Anel sound or a Wilder tapered dilator, is taken in one hand of the operator and in the other he holds a fine, straight, mouse-tooth iris forceps. The point of the sound is then pushed into the exudate at the edge of the prolapse and this undermined through the iris tissue proper, which is easily done in fresh cases, when the forceps seizes the exudated membrane and removes it. In older cases the separation of the membrane from the iris tissue is more difficult, but it can always be peeled away by care.

The next step is to loosen the iris from the wound canal. This is also done by the conical sound, which is placed between the prolapse and the sides of the wound canal. If any membrane remains here it is removed by forceps. The prolapse having been freed the conical sound may be bent a little and by its aid the iris pushed back into the anterior chamber, into which the sound may enter 1 to 2 mm., placing it between the prolapse and the anterior surface of the cornea, thereby freeing it and all of the iris falling into the anterior chamber; or a fine spatula may be used for the same purpose, taking special care not to brush against the anterior surface of the lens, thereby bruising it and later causing traumatic cataract.

Now the neck of the prolapse may be seized by the forceps, slightly withdrawn, and cut away by de Wecker's scissors placed flat against the globe.

The stretched iris then generally recedes by itself into the anterior chamber, the edges free from the wound canal. If not a fine, curved probe or spatula may be inserted and the iris stroked gently away from

the dangerous proximity of the opening, care being taken to see that the sphincter angles are equidistant from the limbus. If the wound canal be very narrow this procedure may have to be made by the conical sound and a very fine probe. If any of the iris tissue is left in the canal it is to be removed by fine forceps and scissors.

Heckel[2] uses a solution of eserin sulphate, 1 grain to the ounce, before removing a prolapsed iris. After cutting the iris tissue close to the cornea, he places a small horn spatula into the corneal wound, permitting the iris, aided by the myotic action of the eserin, to withdraw into the anterior chamber. After 24 to 48 hours he uses atropin. He adopted this procedure after his observations that mydriatics will not dilate a pupil when there is an open or leaking anterior chamber, while myotics act with an open corneal wound. The wound is then bestrewed with powdered iodoform or xerform, covered with a 50 per cent. argyrol solution, 1:3000 sublimate salve and bandaged if the wound coapts well. Otherwise it is necessary to cover the deficit over by a bridge of conjunctiva after the manner of Kuhnt.

The result of the operation is the removal of the iridic and exudative plug from the corneal wound which comes together and heals firmly, leaving no weak spot for the entrance of germs. A coloboma is made which should appear as if made at the time of the operation or wound. The removal of an iris prolapse by such an operation is only indicated in fresh cases when the connection between the iris and corneal tissue is by a beginning fibrinous exudation and has not yet produced true cicatrization. Cicatricial tissue would prevent such a loosening of the neck of the prolapse and clearing out of the wound canal.

This operation is contra-indicated in suppurative cases, where the entrance of an instrument into the anterior chamber would be apt to carry infection into the globe, causing loss of the eye. One should wait in such cases until the suppurative process has been subdued.

The iris prolapse is not firmly connected with the walls of the wound by exudate until after the eighth day.

The operation is mainly indicated in peripheral prolapse. Large central prolapses are not amenable to such work, as only a small part of the cornea remains and the iris must be entirely removed in order to prevent recurrence. These are to be left entirely alone and later to be subjected to staphyloma operation.

Da Gama Pinto[9] showed that bottle and bubble-like prolapses always heal with synechiæ and the operation is here contra-indicated. In a few cases, especially in children, when the loss of corneal substance is large, yet the perforation of Descemet's membrane is small, atropin and eserin and a bandage may cause the prolapse to disappear. The

size and position of the wound, the extent of the prolapse and its duration, should be considered in treatment.

If the prolapse be fresh and not too great, and the wound be radial, its replacement should be tried, eserin dropped in and the eye closed. If the wound be crossways, the iris prolapse older, and the wound gape it is best to excise the prolapse.

When bleeding is great, as noted by Franke,[10] the view is greatly hindered and the operator may not determine if all of the iris is removed from the wound. When the wound is straight and radial it tends to close, and if the iris be freed from it tends to withdraw into the anterior chamber.

Peripheral wounds of the cornea whose edges are close and parallel are apt to pinch the iris in their posterior lips.

Nicati[11] indents the globe a little, causing the iris to protrude, then seizes the small protrusion by forceps, snipping it with scissors, making a fenestration in the iris.

In old iris prolapse the operation is that of excision of staphyloma. Old, small, bead-like prolapses are best seared away by the cautery.

P. Chalmers Jameson[12] gives the following for removal of iris prolapse: "This operative procedure is attended with best results in, and is more adapted to, small circumscribed wounds of the cornea. The peripheral incision in the cornea should be made from the opposite side to that portion of the iris which is incarcerated, traction being made toward the pupillary border of incarceration. In attempting it from the same side the iris is much more likely to be torn if by agglutination or strangulation the incarceration is resistant. Traction on the ciliary body can be avoided by delicate manipulation. Gentle pressure on the posterior surface of the cornea circumscribing would assist in breaking up adhesions. Slight traction should be made first on the broadest portion of incarceration and the two angles at the junction of iris border and wound, before final effort is exerted upon it as a whole. For this purpose I have used a slender, blunt pointed hook, the shank made of malleable material, the bend like a button hook or shepherd's crook. The advantage in a hook of this construction being that the free end, bend and neck, can all be utilized. The use of forceps will rarely be necessary." He claims the following advantages:

1. The method enables one to substitute moderate traction from within the anterior chamber, for what must sometimes be damaging pressure to the iris on the outside.

"II. It preserves to the greatest degree the edges of the corneal wound from instrumental injury in replacement.

"III. It calls into use two efficacious physical forces in replacement,

instead of one, namely, slight manipulation from without, and traction from within the anterior chamber.

"IV. The peripheral incision of the cornea diverts the flow of aqueous from the direction of the corneal wound, thus lessening the danger of secondary prolapse; and the equalization of aqueous pressure on the cornea by peripheral incision permits the lips of the wound to approximate and coapt more thoroughly, inviting quicker closure, thus furthering the healing process.

"V. It permits of more complete and thorough irrigation of the anterior chamber after replacement."

Gifford's[8] conclusions on this subject may be summed up as follows:

"1. Fresh non-infected prolapses should be replaced, if possible; preferably by Dunn's method.

"2. Prolapses which cannot be cleanly excised should, if possible, be cauterized and the area scraped and protected at once by a conjunctival flap.

"3. On account of the danger of sympathetic ophthalmia no prolapse should be treated by a hot metal cautery, unless a protecting conjunctival flap can be made to adhere to the area cauterized; it is probably safer to let the prolapse alone.

"4. In some cases of large corneal prolapses to which conjunctival flaps can be made to adhere with difficulty or not at all, the use of trichloracetic acid (and probably of various other chemicals) produces a firm non-irritable scar. Whether this method is entirely devoid of danger remains to be seen."

Prolapse of the chorioid and ciliary body should be replaced within the scleral capsule and retained by scleral and conjunctival sutures if these structures be not penetrated, otherwise the protrusion should be snipped away by the scissors placed flat to the globe and the wound toilet be completed before suturing.

LITERATURE.

1. Tooke, *Ophth. Record*, Aug., 1908.
2. Heckel, *Penn. Med. Journ.*, Aug., 1907.
3. Dunn, *Arch. Ophth.*, Sept., 1907.
4. Zehender xiv, *Ophth. Gesell.*, Heidelberg, 1882, p. 120.
5. Swanzy, discussion on Zehender's paper.
6. Leber, discussion on Zehender's paper.
7. Von Arlt, discussion on Zehender's paper.
8. Gifford, *Journ. A. M. A.*, July 20, 1910.
9. DaGama, Pinto, *Klin. Mon. f., Aug.*, 1887, xxv, p. 1.
10. Franke, *Munch. Med. Woch.*, 1891, p. 803.
11. Nicati, *Arch. d'ophtal.*, 1883, iii, p. 400.
12. Jameson, *Arch. Oplth.*, xxxviii, 1, 1909.
13. P. Chalmers Jameson, *Arch. Ophth.*, XXXVIII, 1, 1909.

C. FOREIGN BODIES IN THE UVEA.

a. Foreign bodies in the iris, the anterior and posterior chambers.

Etiology. Injuries occurring in trades from flying particles of iron, stone, copper or brass, more seldom wood and glass, shot and powder grains and occasionally other metals, cause the larger proportion of such cases. In addition to these comes that class of cases where cilia get into the anterior chamber, either through perforating wounds or by operations. An iritis nodosa is produced by the entrance of caterpillar hairs into the eye.

These foreign bodies usually enter by way of corneal wounds, less often by the sclero-cornea. In the case of gun-shot injuries the shot or particles of other foreign substances, cilia or other hairs may be carried in first through the lids and then into the eye by the corneal route. In a few cases the foreign body may have entered the eye through the sclera, lodging in the lens or zonula and then migrating into the anterior

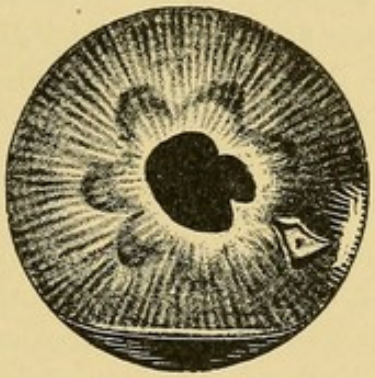

Fig. 283.
Steel chip in iris; wound of cornea; small hyphema; posterior synechia.

chamber, or in the case of absorption of a traumatic cataract the foreign body causing same may drop into the posterior or anterior chamber or become impacted in the iris.

Severe rubbing of the cornea in which a sharp foreign body is impacted, or ill-considered operative attempts at removal, are responsible for quite a number of cases of foreign bodies in the anterior chamber or iris.

The iris is more usually the recipient of a foreign body than the anterior chamber, and the object is very rarely found in the posterior chamber. Those particles which penetrate the iris and go into the lens are not here considered.

Symptoms and course. The subjective symptoms are usually more or less irritation, but occasionally cases appear where the accident has been forgotten until the occurrence of an iritis. The iris is very tolerant of foreign bodies, but their presence near the lens is a

source of danger and such patients should be under skilled observation.

Foreign bodies in the anterior chamber are usually in the lower part and difficult to see; larger objects may be anywhere, those in the iris may be in the anterior layers or penetrate the membrane. Long, sharp objects may remain, transfixing the cornea, iris and lens. In most cases of foreign bodies in the iris the capsule of the lens is likewise injured.

In fresh cases the anterior chamber is yet open and shallow and the tension is diminished; the iris may have prolapsed, but as the foreign body is usually small the wound of the cornea or sclero-cornea is usually too small to allow of prolapse and in these cases the lips of the wound come together very soon and the anterior chamber is speedily restored. If the iris is wounded a small hyphema may be seen, or a flake of blood in the iris about the foreign body. Where the foreign body is large the iris may be so severely wounded as to cause much bleeding and the anterior chamber may thus be full of blood.

The further course of the case depends upon whether or not infection takes place, and the chemical reaction of the foreign body. Indifferent objects, such as gold, silver, splinters of glass, porcelain, stone and wood, powder, lead and shot pellets and cilia may remain for a long time without causing reaction.

Kümmel[1] had a piece of copper from a gun cap lodge in the posterior part of a man's eye for 3½ years, with useful vision. After two light intermittent attacks a severe inflammation developed with hypopion and bulging of the iris, on which the foreign body became visible and was removed by iridectomy—resultant vision = fingers at 3 m. Apparently it had been loosened by the suppuration. He thinks the experiments of Leber (l. c.) and observations of Kostenitsch justify the advice not to enucleate at once an eye injured by copper, but to attempt the immediate extraction of the foreign body.

Bettremieux[2] noted xanthopsia, or seeing yellow, as a premonitory symptom of siderosis.

Vossius[3] reports two cases to show the diagnostic and practical value of siderotic discoloration of the iris and yellowish dots on the anterior surface of the lens.

If siderosis of the iris is lacking in a cataract with yellow dots on the anterior surface of the lens we are justified in inferring a piece of iron in the lens, whereas, siderosis of the iris and cataract with yellow dots on the surface of the lens point to the seat of iron in the vitreous or retina. If the foreign body remains in the eye, the siderosis of the iris may disappear after a few years, but the iris may still give iron reaction, as observed by von Hippel.[4]

Muetze[5] reports injury to the eye by a piece of iron rule which the X-ray failed to locate, the eye remaining quiet for a year with good

vision, then became inflamed. A cataractous lens was removed and the eye recovered. The iris and lens showed siderosis.

Iron particles usually cause siderosis after some weeks, copper and brass cause a destructive chemical reaction within a few days and destroy the eye.

Silver wire has been removed from the iris by Kipp[6]; glass and porcelain, stone, iron, copper and other commoner substances by most ophthalmic surgeons. (For the tolerance of these substances in the interior of the eye see the general chapter).

Powder grains and shot pellets may be retained within the anterior chamber and iris for months without causing reaction. These occur from powder and dynamite explosion, and from fire arms. In several of my cases the cornea has been perforated and powder grains have lodged in the iris without causing an appreciable permanent damage.

Kipp[6] had a case in which a pellet of shot remained eight years in the lower part of the anterior chamber without causing inflammation.

Kümmel[1] reports where a shot pellet migrated after 1¼ years from the interior to the sinus of the anterior chamber, from which it was extracted, with almost normal vision.

Gotti[7] saw a peasant with a shot grain injury with hyphemia, and diagnosed the case first as a contusion. One year later he found a shot pellet in the anterior chamber of the same eye and removed it by incision.

Ewetzky and von Kennel[8] say myiasis of the eye is most frequently observed in children and persons who sleep out of doors. The flies deposit their eggs or larvæ on the lids or into the palpebral fissure at the inner canthus, and the larvæ penetrate from the conjunctival sac into the orbit, eating through lymphatics and veins, causing sometimes a severe general infection.

A boy, about five and a half years of age, suffered from an inflammation of his left eye for five months. The eye showed pericorneal injection, especially downwards. The lower portion of the cornea was opaque to a zone of 1.5 mm., and contained a few superficial blood vessels under the smooth epithelium. The iris was also opaque and spongy and there was a broad, posterior synechia on the temporal side. In the lower sinus of the anterior chamber a worm-shaped parasite was seen, 6 to 7 mm. long, 1.5 mm. wide, of cylindrical form. It did not show any movements of its own, it only changed its position passively, and was nowhere attached. Since the inflammation increased the parasite was extracted with a pair of forceps introduced through a section at the temporal limbus with a lance-shaped knife.

The zoological examination proved it to be a larva of a fly. Although no scar could be seen on the cornea, which, however, might have

been hidden by the opacity of the lower portion, the larva may have entered at the limbus by means of its mandibulæ. A similar case was observed by Krautner and another by Stählberg. The condition of the eye and the larva are illustrated.

Cilia in the anterior chamber following accident or operation are rare, but I have seen two cases, in both of which cysts of the iris formed.

Cilia which entered the eye by traumatism are generally tolerated for years without causing the least symptoms. They may, however, give rise to infection, or, more or less early, to irritation, ciliary injection, photophobia, lacrimation, pain, or to the development of epidermoidal tumors of the iris, cysts, with subsequent glaucoma, blindness or loss of the eye. Therefore their early removal is indicated, although even then tumors may develop from simultaneously introduced epidermoidal particles. Each case must be individualized.

Müller[9] found five cases in two years' observation of Fuchs' clinic in Vienna in 30,000 patients.

Paderstein[10] reports the following case: A piece of iron flew against the left eye of a laborer, perforating the cornea, with incarceration of the iris, perforation of the anterior capsule and circumscribed opacity of the lens. The sideroscope showed that there was no iron in the interior, but there was a cilium with its root lying on the portion of iris which extended to the anterior synechia. An attempt to remove it, after five weeks, with a pair of forceps through a section at the inner margin failed on account of prolapsing iris tissue, but succeeded with the blunt iris hook, followed by speedy recovery.

Four weeks later another cilium was seen near the pupillary margin. An attempt to extract it was frustrated by the hemorrhage from the iris. The hemorrhage was absorbed within a few days, but now the whole lens was opaque and lens matter projected into the anterior chamber. After three weeks the cilium, probably having wandered about, appeared again at its former site. With regard to the further course Paderstein concluded to wait for a special indication, and if the removal should be desirable, to perhaps perform an iridectomy.

Barr[12] reports a case of cilium in the anterior chamber occurring in a man who had been injured in the eye twelve years previously, by a splinter of wood. Two weeks before the case came under the observation of the author the patient received a blow on the head, and this was immediately followed by a mild irido-cyclitis. Examination showed that there had been an absorption of the lens from the original injury, with a partial posterior synechia. There was a small leucoma in the center of the cornea, from the posterior surface of which a cilium extended backwards to the lens capsule. A corneal incision was made and the cilium removed.

Vieweger[13] collected 29 cases from the literature, in several of which a number of hairs (in one case 14 cilia) were found. In these cases the hair enters through a perforating wound of the cornea, usually at the limbus, and is either seen floating freely in the aqueous or with one end impacted in the wound or its resultant cicatrix. These hairs may be retained for a long time without causing irritation. Müller[9] reports one in the anterior chamber for 24 years. Of course to be thus retained, even for a few hours, cilia must be sterile.

Two cases of sympathetic inflammation have been reported from cilia impacted in the anterior chamber, one by Cuvier,[14] and the other by v. Graefe.[15] Samelsohn[16] describes a case in which a cilium was apparently absorbed. Müller[9] and Schwarz[17] from histologic examination show that a cilium may remain as long as 34 years in this location without being affected by the aqueous.

As noted, however, cilia are apt, from irritation, to give rise to cysts of the iris and should be removed by corneal incision and extraction by the forceps.

Emil Bock[11] reports two cases in which, several years ago, a piece of coal in the first, and a piece of wood in the second, had entered the eyes and were lodged in the iris, where they were tolerated without damage to the eyes. A circumscribed iritis followed without spreading to other parts of the eye, so that the foreign body must have been free from pathogenic germs and chemically indifferent. In case 1 the greater narrowness, the lack of delineation on the surface of the affected portion of the iris and its separation from the posterior fibrous layer, which had remained on the anterior capsule, showed that the inflammation was followed by shrinkage of the tissue of the iris. In case 2 the new-formed inflammatory connective tissue surrounded the foreign body with the fine fibers.

Diagnosis of foreign bodies in the anterior chamber and iris:

In those cases in which the foreign body is lengthy and one end remains in the cornea or sticks out through the iris the diagnosis is easy. Recent cases may likewise be readily seen if there has been no, or but little, hemorrhage into the anterior chamber, or if there has been no prolapse of the iris or lens mass hiding the object. However, even very small bodies in such cases may be seen by transillumination, and if impermeable to the X-rays are shown by the skiascopic plate. The probe may be carefully used to sound within the corneal wound only, but its use is to be deprecated for deeper investigation. When the anterior chamber is free from hyphemia the ophthalmoscope and direct examination by the magnifier will often reveal the intruder. But in older cases where the foreign body has caused irritation and become covered by inflammatory exudate it may not be directly visible. Here the diaphano-

scope and the Röentgen ray give us our best means for objective examination. Diagnosis by magnetic attraction may be carefully used.

Free-lying, foreign bodies in the anterior chamber may come into view when the patient stoops forward or lies on one side. I have thus seen a floating cilium. Those in the posterior chamber can only be seen after full dilation of the pupil, and are usually incidentally discovered in ophthalmoscopic examination.

W. Plitt[18] says: The presence of foreign bodies (not iron) in the sinus of the anterior chamber is sometimes very difficult to ascertain especially when associated with hypopion or granulation tissue in the iris. Then the Röentgen photograph is of inestimable value.

Plitt reports: A girl, aged 16, who worked in a wire factory, came with the history that five or six days ago two pieces flying off from the wires she was rolling had entered her right eye. Below the center of the cornea a linear wound, 1 mm. long, and at the bottom of the sinus a yellow exudation of the size of the head of a pin, were visible; iris hyperemic, pupil contracted, reacted well. The patient did not return until two weeks later. Then the eye was almost without irritation, excepting slight ciliary injection at the lower limbus. At the site of the former exudation a reddish-brown granuloma, with a yellow point at its surface, projected. No iritis. When this place was slightly touched with the lower lid, it became painful and the pericorneal injection increased. This left no doubt of the presence of a foreign body, which was verified by the Röentgen photograph. As the attempts to extract it with anatomical forceps, through a section to the side of the seat of the foreign body, were not successful, Plitt enlarged the wound with scissors toward the foreign body and excised the iris, which contained a piece of rolled copper wire, 1.04 mm. long, 0.26 mm. wide, 0.1 mm. thick. The skiagram revealed the other piece in a small pustule of the skin of the supraciliary region, from which it was expressed.

The prognosis is usually only favorable when the foreign body is early removed from the eye, for despite the curious and rare instances of such intruders being tolerated without damage for months or years, they almost invariably lead to loss of sight and of the eye, and may cause sympathetic disease and blindness in the other. Plastic iritis is usually the first step, then comes closure of the pupil, cataracta accreta, irido-cyclitis, and then the other eye begins to inflame.

Therapy. Extraction of the foreign body is the main procedure, aside from the regular care of the wound and atropinization. The only exceptions to this rule are those cases where, upon examination, a foreign body is found which has been in the eye for a long time, months or years, without causing inflammation. In such cases it is generally

safer not to disturb the status quo. In these it is wise to warn the patient of the necessity for operation upon the slightest sign of irritation.

Foreign bodies on the iris demand prompt removal, for usually, if allowed to remain, they will speedily set up a severe iritis. An exception, however, sometimes is found, as in which a particle of steel had been resting on the iris for five years before I saw the patient. If the magnet will not remove it, forceps must. If it cannot be readily disentangled from the tissue, we may succeed in so doing by drawing the portion of the iris containing it through the wound, so that we can more readily have access to it, and then after its removal replace the iris. Should these measures fail, it might be necessary to perform an iridectomy, removing the portion of the iris containing the foreign body.

The extraction of a foreign body from upon or within the iris should be done as early as possible after the accident, where its location is not disguised by pus or blood in the anterior chamber. If allowed to remain it may speedily set up a severe iritis. Local anesthesia by cocain is applicable for adults, general narcosis for children. The field of operation should be highly illuminated, preferably by the head lamp, of which the Stucky or Kierstein models are preferred. The former has the advantage of using the 110 volt current with a 6 to 16 c. p. lamp. The latter has miniature lamps, the current being reduced to 6 volts resistance. To the latter an ophthalmoscopic mirror may be attached, useful in magnet and other operations for removal of foreign bodies from the posterior portion of the globe, and, with a combination of the Berger binocular loupe, for operations on the anterior portion of the globe.

A hand electric lamp held by an assistant is used by many surgeons, particularly abroad, where assistants are plentiful. The instillation of atropin is not always advisable, for the foreign body may be drawn thereby under the pupil, closer in apposition to the lens capsule and cause damage, or it may draw the foreign body out of view behind the limbus or iris. Eserin, however, prevents the foreign body from going against the lens capsule or falling into the posterior chamber.

An iris prolapse may thus be reduced and in the extraction of the intruder from the anterior chamber by the interposition of the iris between it and the lens, the capsule is in a measure protected from further injury.

When a foreign body is loose in the anterior chamber, or is not fixed in the iris, the operator should endeavor to let it come out with the flow of aqueous upon the completion of the corneal incision, although this is seldom accomplished.

By depressing the keratome a little on one edge, and bringing its point up to the posterior surface of the cornea, the aqueous comes out more freely, but the point of the keratome is apt to wound the anterior

capsule of the lens and thus produce an operative traumatic cataract, as occasionally occurs in operations for the removal of foreign bodies from the anterior chamber and iridectomy for glaucoma. On account of this danger of the keratome many operators habitually use the Graefe knife, whose point, after the counter puncture, is kept away from the globe.

The foreign body may at times be extracted through the wound of entrance, but in most cases this has to be enlarged by the blunt-ended knife or scissors, or if the anterior chamber has been restored a linear incision into the cornea near, and peripherally to, the wound area may be made so that room is obtained for proper manipulation of the instruments and for egress of the foreign body.

Extraction of a foreign body without iridectomy can usually only be made in free-lying objects or those but slightly impacted into the iris. The Hirschberg magnet, or the extended flexible arm of the Victor magnet with its small tips, here finds its greatest use for removal of small magnetizable pieces of metal after the corneal incision. A magnetized keratome, forceps or steel spud is sometimes here useful. I generally prefer the giant magnet used after the manner of Haab.

Iridectomy as a rule has to be made either on account of irreducible prolapse of the iris, danger of anterior synechia, or because the foreign body is so entangled with the iris that it cannot be withdrawn without the iris coming with it. At times it may be possible to only excise a portion of the peripheral border of the iris, thus leaving the pupil round and movable without the deformity of a coloboma, as is produced by the usual iridectomy.

Small particles of iron and steel impacted into the angle of the anterior chamber, or between the sclera and ciliary body, can only be removed by entering the eye with the tip of the magnet, as the power of the giant magnet cannot be applied in such a direction without danger of drawing the chip of metal against, and thus injuring, the lens.

The iris forceps, blunt hook or curette is of use in dislodging such impacted foreign bodies so that the subsequent steps of the operation may be completed by the aid of the magnet. Round foreign bodies may be assisted in delivery by the Daviel or Pagenstecher spoons.

If the foreign body lie in the posterior chamber and be magnetic the giant magnet may be used to draw it into the anterior chamber, and then be extracted as above described. If non-magnetic, as stone, copper, glass, wood, etc., extraction may be attempted by the forceps, blunt hook or curette.

Adolf Alt[19] says sometimes a foreign body, after having struck the iris, will fall into the angle between the iris and cornea, and its removal from such a position is very troublesome, especially if it is not iron or steel and very small. In such a case it is well to first move the

foreign body with a needle, into a position on the iris nearer to the pupillary edge and then to remove it, with a portion of the iris, by iridectomy.

Bruner[20] reports a case of steel in the iris ten years. Removed. Recovery with normal vision. Patient's age 40 years; history that the left eye had been red and painful for a week. The inflammation came on without any apparent cause. There was moderate bulbar congestion, the iris responded readily to light and showed no discoloration or thickening. Resting on the iris, downwards and outwards, near the pupillary edge, was what looked like a piece of steel, rusty in spots, three to four mm. long and one-half to one mm. thick. On the upper portion of it was a grayish spot looking like lymph extending to the iris. The foreign body seemed merely to rest upon the iris and not to be imbedded in it, and there was no thickening of the iris about it. In the lower outer portion of the pupillary area of the cornea was a very fine horizontal scar. Johnson's magnet brought near the eye caused a very slight movement of the foreign body, but no attempt was then made to dislodge it. Further inquiry elicited the fact that he had not for many years engaged in any kind of work where he was liable to such injury, but that ten years before, while chipping, he had been struck in that eye with a piece of steel which pierced the eyeball, but had, he thought, been removed. The steel was removed by corneal incision and magnet.

Pieces of stone in the iris are not always followed by identical reactions. Some may rest there quietly from 19 to 32 years, others may cause such violent pain that an immediate operation is required. This may be due to the chemical or physical nature of the foreign body, to pathogenic germs or a special predisposition of the injured organ.

In order to elucidate these conditions, Cirincione[21] made three series of experiments on rabbits: 1, with pieces removed from his two patients; 2, with pieces of limestone, marble, sandstone, brick, turf, which were not made aseptic for better imitation of the injuries occurring in man; 3, with particles of the same material, previously immersed in bouillon, containing cultures of staphylococci. In Series 1 and 2 no marked disturbances were noted. In Series 3 the infection caused purulent keratitis, in comparison to which the reaction of the iris was irrelevant.

From this Cirincione concludes that the grave symptoms, created by pieces of stone impacted in the iris, cannot be ascribed to their chemical nature nor their physical condition, nor to the presence of micro-organisms. The cause of the peculiar reaction of the iris must be rather independent of the foreign bodies. Cirincione sees this, analogously to purulent affections, e. g., in fractures, etc., in a lowered organic resistance of the ocular tunics in general diatheses, as syphilis, tuberculosis, gout, dia-

betes, etc. In these cases the foreign body is nothing but the eliciting cause for the local manifestation of a preëxisting diathesis.

The extraction of the foreign body must leave the iris intact as much as possible.

Cirincione[21] gives a review of the incidents and literature and reports three cases of his own.

In the first case the man had injured his eye in hewing stones on the road. A piece of limestone was detected in the iris and removed by iridectomy. Recovery with V.=2/3.

Case 2. A piece of stone, impacted in the iris, was extracted with forceps. After five days the eye was normal.

In case 3 a piece of stone was seen on the iris near the margin; slight hyphemia. After this was absorbed the foreign body had fallen into the lower sinus and was left alone, as pericorneal injection, hyperemia of the iris and photophobia subsided, so that the patient could pursue his occupation. Half a year later it was still visible; it was movable and not surrounded by new-formed tissue.

b. Changes in the iris due to the entrance of foreign bodies.

Traumatic Iritis, while due to traumatisms of all kinds, especially if perforation of the eyeball has taken place, is especially apt to occur if a foreign body be left in the eye. The exciting causes are either due to the mechanical injury from contusion, traction, or pressure, as from the injury, or swollen cataractous lens masses; chemical irritation from decomposition of the foreign body, as from copper particles; or infection, the last cause being most frequent.

Operations on the eye are traumatisms, and of these the most apt to produce iritis and irido-cyclitis are cataract operations.

The iritis, and irido-cyclitis, from trauma is more acute and severe than that from general diseases, and atrophy of the eyeball is very apt to occur.

The hairs of caterpillars, spines of grasshopper legs, and portions of other insects, bee stings, etc., not only produce an ophthalmia nodosa of the conjunctiva, but also some weeks or months after their entrance violent inflammation may appear in the iris with development of nodules therein, causing iritis and even loss of the eye. The nodular portion of the iris should be excised by iridectomy. This subject is discussed in full elsewhere in this book.

Hilbert[22] reports iritis from a bee sting. The patient was seen the day following the injury. There was edema and discoloration of the lids and cheek of the affected side, and the sting was still imbedded in the skin. There was conjunctival and ciliary congestion, slight hypopion and deposits on the membrane of Descemet. The patient, although a

strong healthy woman of 60 years of age, was constitutionally affected, the pulse being 52 and thready, breathing superficial and rapid, and the skin cool and moist. The ocular conditions lasted four weeks, and the constitutional depression three days.

TUMORS OF THE IRIS.

1. Cysts of the iris.

As there are no glands nor epithelium in the iris no retention cysts occur. Those that develop are epithelial in type.

Serous cysts occur in the iris, after penetrating wounds, as a very rare affection.

Pearl cysts are distinguished from serous cysts by their contents, which are pultaceous or tallowy and composed of epithelial cells constantly thrown off from the inner surface, which undergo fatty degeneration.

Etiology. Wounds of the cornea heal by the epithelium growing rapidly down into the deeper parts; sometimes it extends beyond the inner aspect of the wound, growing into the center of the anterior chamber along its walls, covering the posterior surface of the cornea and the anterior surface of the iris, forming an anterior chamber cyst. If the iris be in contact with the wound the epithelium pushes into it, pushing the layers of the iris apart, thus forming an iris cyst, its walls being composed of rarefied iris tissue. The site is usually in the iris itself, seldom in the ciliary body. The epithelium is usually transparent and can only be demonstrated after removal by staining and the microscope. It is very destructive to the eye, as it leads to increase of tension because the epithelial lining hinders filtration through the sinus of the anterior chamber.

Pseudo-cysts occur from portions of the iris and cornea, or lens, dilating from accumulation of fluid between these structures.

Symptoms and Course. As a rule no irritative symptoms are apparent until the cyst fills the half of the anterior chamber, when glaucoma sets in. Serous cysts appear as grayish, transparent vesicles whose anterior wall shows some pigment and remains of rarefied iris tissue. When they reach the posterior surface of the cornea they flatten and the cornea becomes cloudy from proliferation of the endothelium. It then pushes into the pupil, which becomes kidney-shaped or even reduced to a slit. Dislocation and opacity of the lens occur from its growth backward. Disturbances of vision, elevation of tension and glaucoma cause blindness.

The Diagnosis is made by inspection. The cyst is translucent

and the red glow of the fundus may be seen through it by the ophthalmoscope.

The Prognosis is good upon early and complete removal, otherwise the sight may be lost from glaucoma.

The Therapy is operative, being early removal of the cyst by marginal incision of the cornea at the point corresponding to the cyst, entering the forceps, withdrawing it together with the iris and excising it completely, without rupture or damage to the walls of the anterior chamber, as, if any epithelium be left in the eye, another implantation cyst will grow. Often complete removal is not possible at one operation, hence a recurrence is to be expected, when another operation may cure the case.

Schweigger[13] had a case where six cilia had been carried into the anterior chamber through a corneal wound. Three months later

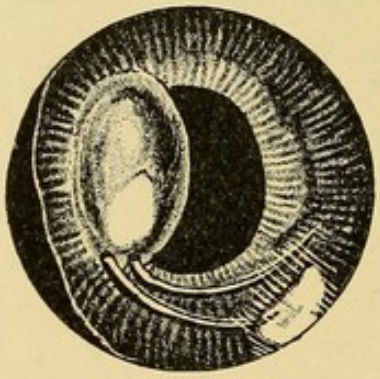

Fig. 284.

Cilia in anterior chamber carried through wound of cornea; showing scar, irido-dialysis and cyst of iris.

two white points appeared on the iris. The cilia were removed at this time and six months later the cysts were so well developed that they were removed by iridectomy. The larger was 1½ mm. in diameter, the smaller ½-¾ mm.

2. Granulation tumors of the iris.

Rarely mentioned in literature, wounds of the iris may granulate so freely as to form a new growth which must be differentiated from syphiloma, sarcoma, and tuberculosis. These have occurred from ablations of staphylomata of the cornea in which all the iris has not been removed and some of its tissue becomes entangled in the wound and resultant cicatrix.

H. Knapp[24] saw "proud flesh" or granulation-tissue appear after such an operation. In one of my staphyloma operations, performed according to the method of Critchett, I also found granulation-tissue, which, upon excision, did not recur.

Früchte[25] on February 19, 1909, saw a case in which the cornea and anterior capsule of the lens of a man, aged 32, was perforated by a piece of wood. In a few days the whole lens was cataractous, and opaque lens matter oozed from the ruptures of the capsule and partly fell into the lower sinus. On July 12th they were completely absorbed; V. with + 12 = 6/viii. Two small, greyish-white, flat, nodular, avascular tumors, 2.5 by 2 mm., had developed in the lower sinus. There were no inflammatory signs in the eye, and the iris showed no changes. The tumors grew smaller and disappeared after a month.

Most likely the nature of the tumors was somewhat on the order of granulomas, produced by the irritation of the iris through opaque lens matter repeatedly falling into the anterior chamber.

3. Sarcoma of the iris after trauma.

Nearly all the cases of intraocular tumor I have seen have given a history of some kind of more or less trivial accident to the eyes, usually a blow from a minor object, as a lead pencil. I cannot ascribe any of my cases directly to such a cause, although the theory of Cohnheim may apply to such cases.

4. Tuberculosis of the iris.

This is secondary to tuberculous disease in some other part of the body. Experimental tuberculosis of the iris is used as a diagnostic test in animals, being produced by inoculation into the anterior chamber of portions of the suspected tissue, and, as such, is primary. I can find only one authentic case of primary iris tuberculosis in the human being, that reported by Treitel.[26]

A 12-year-old boy four months before had a straw injure his right eye, causing keratitis. The aqueous was turbid, and in the middle of the temporal half a bean-sized tumor arose, which touched the cornea anteriorly. The surface of the tumor was uneven and composed of ciliary, grayish nodes. This was removed by iridectomy, but a few days later three new tubercles appeared. Treitel thought that the affection was not metastatic but due to infection of the wound by the hands.

Risley[27] reports traumatic irido-cyclitis, with a nodular conjunctival disease. With a broad face and flat nose, an opaque skin; pale, flabby and indented tongue; a large head well sunk between broad muscular shoulders; clubbed finger ends and a few enlarged cervical glands, a Russian, by birth, presented himself for treatment at the Wills Eye Hospital on July 5, 1905. He had just left a general hospital where he had been under treatment for injuries involving the hands, face and eyes, caused by a premature blast in the anthracite coal mines.

c. Foreign bodies in the ciliary body.

"Reizlose Verweilen eines Fremdkörpers längere Zeit hindurch ist ein unerhörtes Vorkomnis." (Praun[28]).

Etiology. Foreign bodies remaining in the ciliary body usually occur from explosions, as of gun-caps. Less often do we find chips of iron, glass, stone, wood or shot pellets, although these latter give a large proportion of foreign bodies which penetrate and pass through the ciliary body into the interior of the eye. These may get into the ciliary body either directly through the sclera, or after penetrating the sclera or cornea at another point may traverse the ocular contents until the ciliary body is reached, wherein they may lodge. Frequently foreign bodies entering the eye and lodging first in the vitreous or retina may wander, later on, to the ciliary body and become impacted therein, to be found upon enucleation and section.

Gradle[29] found spirillæ in the ciliary body in five cases of perforating injuries; whereas six cases, examined with the same methods, were negative. He is far from asserting that the spirillæ have any significance for irido-cyclitis, or even sympathetic ophthalmia, as long as experiments on animals have not yielded positive results, but wishes to call attention to these interesting findings.

Symptoms and Course. The most intense irritation, pain, tearing and dread of light is produced by a foreign body in the ciliary body, through its extreme sensitiveness from the ciliary nerves and the constant contraction of the muscles.

A sector of the limbus corresponding to the site of the intruder may be injected and specially tender to the touch. Unless removed, and often even then, cyclitis begins and extends to the iris, the disease going on to irido-cyclitis and atrophia bulbi. After the acute symptoms subside the foreign body becomes encapsulated, and from time to time new attacks with subsidence of inflammation occur.

In a few cases, most often those where copper chips have been retained, the chemical reaction is intense, and spontaneous extrusion of the intruder follows, either through the port of entry, or another opening, generally downwards, to the corneal limbus. A foreign body does not stay long in this location without giving trouble.

Diagnosis. The diagnosis of a foreign body in the ciliary body may only be positively made when it can be seen or felt by the probe. It may yet extend out of the scleral wound or be seen upon atropinization, through the enlarged pupil, as a grayish object. Certainly diaphanascopy or the X-ray help if the object be large enough to cast a shadow; but exact localization cannot be made by either, and the foreign body may be in the vitreous clear of the ciliary body when the X-ray plates seem to show it there. The ciliary region may be tender and in

some cases abscesses have been caused and have pointed at this location.

Prognosis. This is generally most unfavorable, even when speedy extraction of the foreign body is made, especially if the eye does not soon become quiet. In previous years most such eyes were immediately enucleated by the conscientious surgeon. Now perhaps we are getting ultra-conservative and are saving many eyes to the consequences of sympathetic disease.

Therapy. When the foreign body can be seen the wound may be opened and the unwelcome visitor removed by forceps, in magnetizable cases aided by the magnet. If the foreign body cannot be removed the eye should be immediately enucleated, as dilatory and deficient methods lend a false security and may lead the patient to blindness of both eyes.

d. Foreign bodies in the chorioid.

Etiology. It is possible for very small copper or iron particles to become imbedded between the retina and sclera in the chorioid. There it must have first penetrated the eye, passing through the vitreous and becoming imbedded in the posterior coats. The vitreous is readily penetrated, the chorioid also, but the sclera offers great resistance and stops the flight of the particle, and it thus remains on the sclera imbedded in the chorioid and is seen through the retina, as it does not become encapsulated in this location for a considerable period of time.

But foreign bodies within the posterior part of the globe, in the vitreous and retina, usually cause acute inflammation which leads to plastic shrinking of the bulb. A foreign body near the sensitive ciliary body is very dangerous.

The Diagnosis is made when the foreign body is seen under and through the retina.

The Prognosis is that of retained foreign bodies, generally poor unless speedily removed.

The Treatment is that of foreign bodies; removal or enucleation.

de Schweinitz[30] reports a case of foreign body in the chorioid quiescent for 18 years, then irido-cyclitis, localization by X-rays, then enucleation. Accident while chipping with cold chisel; eye blinded but remained without irritation for the 18 years.

LITERATURE.

1. Kümmel, *Zeitschr, f. Aug.,* Jan., 1908.
2. Bettremieux, *L'ophtal. Provin.,* Feb., 1905.
3. Vossius, *Deut. Med. Woch.,* No. 1, 1909.
4. v. Hippel, ref. Vossius.
5. Muetze, *Ophth. Record,* Sept., 1908.
6. Kipp, *Amer. Journ. Ophth.,* 1892.

7. Gotti, *Recueil d'opht.*, 1892.
8. Ewetzky and v. Kennel, *Zeitschr. f. Aug.*, XII, p. 337.
9. Müller, *Wien. Med. Woch.*, No. 13, 1894.
10. Paderstein *Centralbl. f. Aug.*, Jan., 1910.
11. Bock, *Centralbl. f. prak., Aug.*, March, 1907.
12. Barr, *Journ. Ophth. and Oto-Laryn.*, Sept., 1909.
13. Viewiger, *Inaug. Dissert.*, Bonn, 1883.
14. Cuvier, ref. Viewiger.
15. v. Graefe, *Arch. f. Ophth.*, x, 1, p. 213.
16. Samelsohn, *Klin. Mon. f. Aug.*, 1885, p. 363.
17. Schwarz, *Beitr. z. Aug.*, 1906, p. 51.
18. Plitt, *Klin. Mon. f. Aug.*, 1906, xliv, p. 537.
19. Alt, *A Treatise on Ophthalmology*, 2d Ed., p. 214.
20. Bruner, *Ophthalmology*, Oct., 1906, p. 97.
21. Cirincione, *Zeitschr. f. Aug.*, 1907, xvii, p. 143.
22. Hilbert, *Woch. f. Therap. Hyg. d. Aug.*, No. 26, 1904.
23. Schweigger, *Bericht. Ophth. Cong.*, Heidelberg, 1883.
24. H. Knapp, *Die Intraocularen Geschü lste*, 1868.
25. Früchte, *Klin. Mon. f. Aug.*, Feb., 1910, p. 185.
26. Treitel, *Berl. Klin. Woch.*, p. 445, 1885.
27. Risley, *Ophthalmology*, Apr., 1906.
28. Praun, l. c., p. 253.
29. Gradle, H. S., *Klin. Mon. f. Aug.*, March, 1910.
30. deSchweinitz, *Ophth. Record*, Aug., 1900.

D. INJURIES TO THE UVEA FROM BLOWS. a. IRIS.

1. Bleeding of the iris and into the anterior chamber. Hyphema.

Etiology. Blows of all characters, especially from rebounding foreign bodies of metal, wood and stone, blows from fisticuffs and blunt objects, as well as actual wounds and the passage of foreign bodies through the parts, causes hyphema, or bleeding, into the anterior chamber from injuries to the iris structure, as in traumatic iris dialysis, aniridia, irideremia, sphincter rupture, radial and circular tears and very seldom isolated ruptures of the bloodvessels. Bleeding from rupture of the canal of Schlemm has already been described. Bleeding from the canal of Petit is pictured by Jäeger,[1] but must be a very seldom event; concentric red streaks near the periphery of the lens is here seen. If the zonula be torn the anterior chamber may fill with blood from injuries to the chorioid and ciliary processes.

Symptoms, course, and diagnosis. In small injuries the blood flows out of the ruptured vessel and spreads over the iris as a diffuse red-brown flake, which gradually grows smaller and in a few days is entirely absorbed.

In more severe tears the blood may partially or completely fill the anterior chamber. In a few days it sinks to the bottom of the anterior chamber, becoming fully absorbed in the course of three to seven days. Small quantities may disappear in the course of 24 hours. When it occurs in a diseased eye the absorption may be very slow, even taking two to three weeks, and then leaving a residue.

Fuchs[2] says blood clots in both the anterior chamber and the

vitreous, after an injury, may suddenly have the coloring matter dissolved in the ocular fluids and diffuse all through the eye, the aqueous humor, too, becoming colored red so that the iris looks as if seen through ruby glass.

When there is much blood in the anterior chamber, especially if the eye be otherwise diseased, it may remain a long time, even months, becoming darker in color; and thus where repeated hemorrhages have occurred a hyphemia may be composed of several different colored strata, the lowest and darkest being the primary hemorrhage. Very old and incompletely absorbed hyphema may become brown or dirty-green in color, the cornea or the iris may become tinged, the latter also from the hemorrhage into the vitreous.

If the blood remains for a long time in the anterior chamber and the eye is also inflamed the colored exudate may become organized and

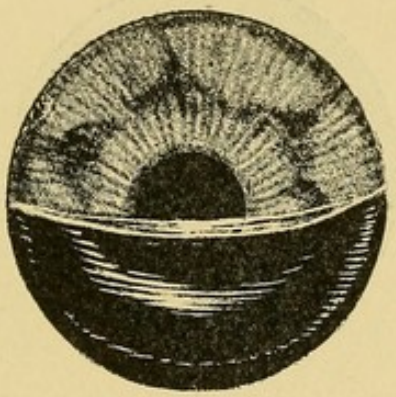

Fig. 285.
Hyphema.

form a permanent membrane, occluding the pupil and negativing the result of operations for clearing the pupil.

Eyes that have an excessive intra-ocular tension, as in glaucomatous states, or where vessel walls are weak from arterio-sclerosis, are predisposed to intra-ocular hemorrhage from injury or otherwise. Changes in the character of the blood, as after inhalations of nitrous oxide or carbonic acid gas, or in anemia or scurvy, likewise predispose to such accidents.

The subjective symptoms are those of sudden loss of sight, from the pupil being obscured by blood, and a feeling of fullness in the eye.

The p r o g n o s i s is generally good, the blood speedily resorbing, except in otherwise diseased eyes where organization of the clot may take place. Iritis seldom occurs unless the globe has been penetrated.

T h e r a p y. The therapy of hyphema is usually that of the wound or contusion; atropin, asepsis and rest. However, iced compresses may prevent further hemorrhage; ergot by hypodermic or by the mouth may

contract the vessels. Calcium chloride is indicated internally. Hot compresses and dionin locally aid in the resorption of the blood clots, and atropin keeps the pupil free so that the contracting sphincter may not force the possible irido-dialysis wider open. If radial tears are seen then atropin is contraindicated and eserin should be used to contract the pupil and draw the tears closer together.

2. Irido-dialysis.

The tearing away of the iris from its connection with the ciliary body at the angle of the anterior chamber is an interesting clinical event of not uncommon occurrence.

Etiology. Blows striking the sclera near the root of the iris, especially rebounding objects, as particles of coal, stone, wood or metal,

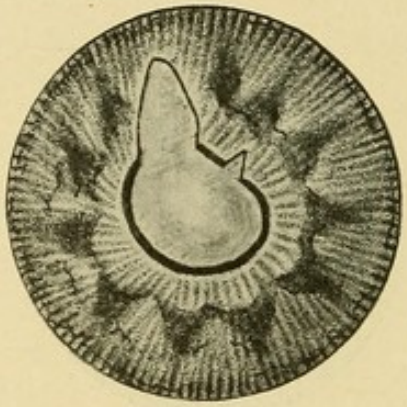

Fig. 286.
Sphincter rhexis. Marginal tears of the iris.

corks from charged beverages, ends of canes and spent shot pellets and whip lashes, are the objects usually producing such an injury.

Direct irido-dialysis is sometimes unintentionally produced in the course of operations on the iris if the eye makes a sudden movement at the moment when the operator grasps the iris with the forceps. The iris may be thus separated from its insertion to a varying extent, or even torn out of the eye. In iridectomy for occlusion of the pupil, when the pupillary edge is not first set free from the occluding membrane, the latter pulls with the traction on the opposite side, tearing away the iris at its insertion. Hence the iris should always be released from the occluding membrane by lateral movements of the forceps, before drawing it out of the wound. Irido-dialysis may also be produced spontaneously when atrophy has occurred in spots, and by the forward growth of neoplasms of the ciliary body, pushing the iris away from its insertion.

Indirect irido-dialysis is produced by (1) flattening of the cornea during trauma, from which its circumference and the circle of insertion

of the iris become larger. If this enlargement takes place suddenly the iris can not adapt itself and tears away from its insertion in one or more places (v. Arlt[3]).

(2) The aqueous is pushed back through the pupil by the flattening of the cornea, deepening and increasing the pressure on the poste-

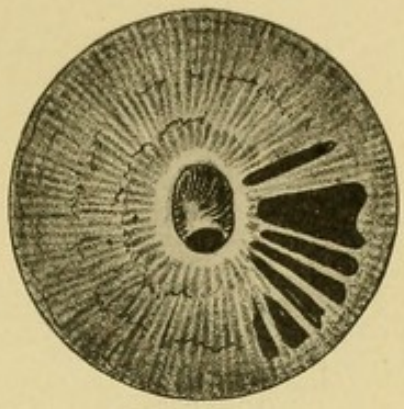

Fig. 287.
Radial atrophy and holes in the iris.

rior chamber, the force being exerted mostly at its deepest portion at the base of the iris. This is ballooned forward and gives way at the insertion if a radial tear does not first result.

(3) Blows on the edge of the sclera dent in the globe, pushing the vitreous against the ciliary body and root of the iris, which gives way at this point.

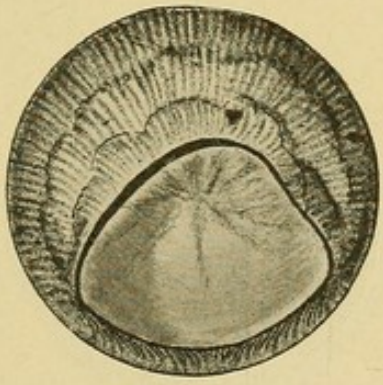

Fig. 288.
Partial inversion of iris.

(4) Müller[4] thinks that the dialysis in dislocation of the lens and scleral rupture is due to the sphincter and dilator of the iris, at the moment of the trauma, suddenly and forcible contracting.

(5) Wintersteiner[5] shows that when the canal of Schlemm and ligamentum pectinatum is ruptured the arteriosis iridis, or the ciliary body vessels with the anterior ciliary vessels, are broken and the blood forces the root of the iris away from its insertion.

Objective symptoms. If the immediate hyphemia is not too great we will find on one side, at the ciliary margin of the iris, a black crescent which is formed by the separation of the iris from its insertion, and then, or after absorption of the blood, we can look through into the interior of the eye. When the separation is considerable we will

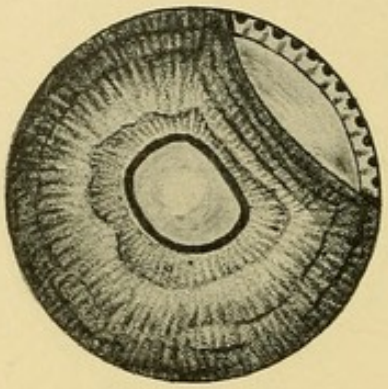

Fig. 289.
Irido-dialysis.

see the edge of the lens, the ciliary processes and the fibers of the zonula in the gap if oblique or focal illumination is used. The pupil is flattened to the side of the dialysis, being stretched into a straight line by the contraction of the sphincter, occupying a chord of the arc of the rounded pupillary margin. The pupillary margin is drawn inwards, the ciliary insertion drawn away so that it can never heal again to its root.

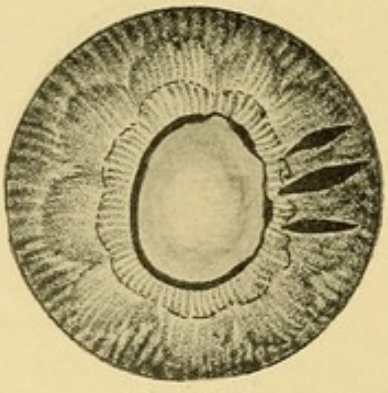

Fig. 290.
Radial tears of iris; small marginal tear of pupil.

The extent of rupture may be small, or very great so that an iridere-mia is produced, in the latter case the iris contracting, rolling up into a little ball, atrophying and sinking down to the bottom of the anterior chamber. Fuchs has remarked in his lectures (quoted by Praun) that he has never seen multiple dialysis produced by blunt force—yet Praun,[6] Müller,[4] Wintersteiner,[5] and myself[7] have seen and reported upon such cases.

Subjective symptoms. From the hyphema the eye is temporarily blinded, but vision returns upon resorption. The sight is but little affected by irido-dialysis; the only thing being that if the eye is not accurately focused, through the formation of another image upon the retina through the peripheral opening, monocular diplopia and confusion occur.

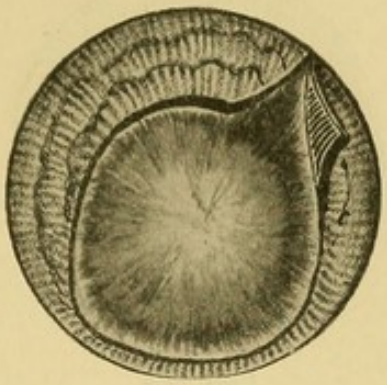

Fig. 291.
Rhexo-iridis with inversion of exversion.

Course. After resorption of the blood in the anterior chamber the sight returns and the extent of the damage is seen. It may be that some reattachment of the edges of the dialysis occurs if atropin be instilled, but it is doubtful, as we know that the cut or wounded iris does not heal but the wound remains open with no effort of Nature at repair. (Fuchs[2]).

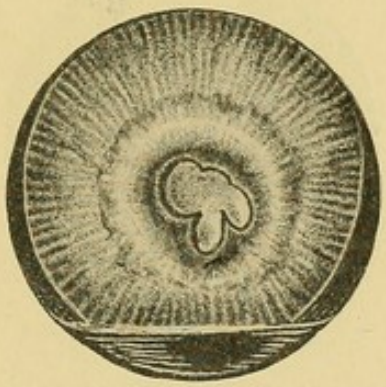

Fig. 292.
Irido-dialysis, nearly complete, in iris bombe, hyphema.

The pupil remains irregular and there is another permanent opening at the periphery of the iris.

Complications. Hyphema always exists, radiating tears of the iris structure or margin may co-exist. Rupture of the ciliary body and chorioid, with or without detachment of the retina, may occur.

Diagnosis. After the hyphema resorbs, or if it is not great,

the additional opening may be seen on inspection. If the dialysis be small it will be best seen by the ophthalmoscope. The contour of the pupil gives a hint as to another opening at one side.

Prognosis. This is not unfavorable as to vision if there be no other damage. In mild cases the acuity and accommodation may remain

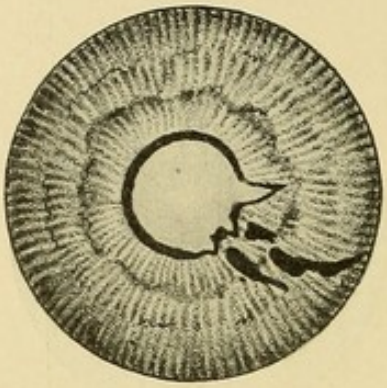

Fig. 293.
Marginal and radial tears of iris.

normal, in others this function is lowered on account of complications.

The therapy is atropin, iced compresses for two days, then hot compresses and dionin to secure resorption of the blood. Iridotomy and iridectomy may be made to relieve the monocular diplopia. Operative procedures have been made for cosmetic results. The older authors, as

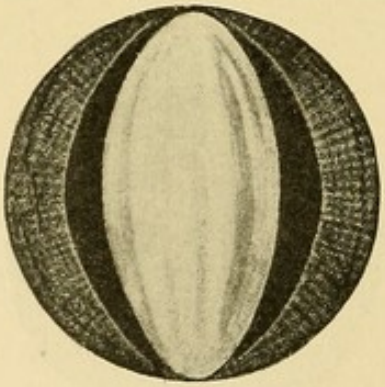

Fig. 294.
Veasey's case of traumatic anterior total luxation and version of lens (Redrawn by author).

Amedie,[8] made a corneal section and brought the periphery of the iris into it; a rather risky procedure and not to be advocated.

P. Chalmers Jameson[9] has recently presented a new method for operating on irido-dialysis, the objects of the operation being as follows: 1. Re-attachment of torn iris as near to its anatomical position as possible. 2. Re-attachment to a fresh surface within the anterior chamber without incarceration. 3. Simple, accurate, and practical technique.

The first is accomplished by making the necessary incision into the sinus of the anterior chamber well back from the limbus. The second, by bringing the torn iris against a linear incision within the anterior chamber, not between its lips. The third, by the introduction of sutures before incision is made into the anterior chamber, and by impinging the

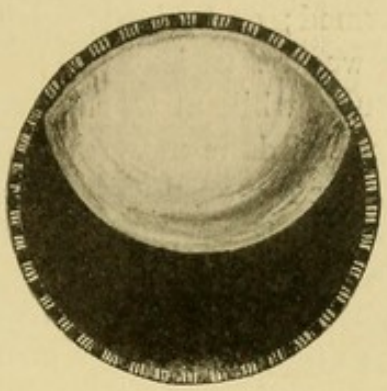

Fig. 295.
Traumatic irideremia with dislocation of lens upwards.

iris against the resistant posterior surface of the cornea, the iris is neither torn in the effort to perforate it nor lacerated by forceps.

In one pronounced case of irido-dialysis where the torn bridge covered the center of the lens and interfered greatly with vision. I excised the torn portion and increased the acuity of sight.

A little boy was stealing a ride on the back end of a wagon with

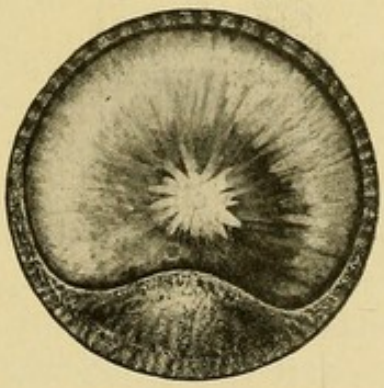

Fig. 296.
Nearly complete inversion of the iris; traumatic cataract.

other children and the teamster cracked his whip back to frighten them, unfortunately striking the boy over the eyelid and causing him to fall off and cry with pain. This happened close to my office and the child was brought immediately afterwards. I found the anterior chamber already filled with blood and was unable to offer prognosis until after its resorption, which occurred, under hot compresses and atropin, within

three days, when a small irido-dialysis was found, which never gave rise to diplopia or further trouble.

A young man was opening a bottle of beer when the cork flew up, striking him upon the closed lids, producing immediate blindness. I saw him several months after the accident and found that he complained of double vision, the secondary pupil being large enough to allow of a secondary image being formed; operation of iridectomy would have removed the defect but it was refused.

A man had been struck, while at work in a foundry, with a piece of hot iron which, however, had done more damage by its weight than the slight burn which it produced upon the face and lids. The irido-dialysis which it caused was about half of the iris, thus allowing the stretched band of the iris to get in the visual axis, causing considerable damage to central vision, and diplopia. In this case an iridectomy removed the diplopia and restored central vision.

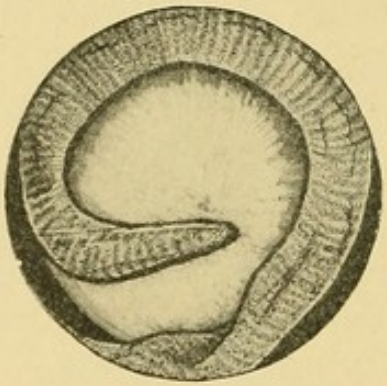

Fig. 297.
Rupture of iris; irido-dialysis; partial inversion; traumatic cataract.

A boy was playing with an air-gun, using bb shot, one of which was accidentally projected against the ciliary region of the eye, causing immediate irido-dialysis with some abrasion of the cornea. The shot, remaining between the closed lids, was picked out and the eye did well for a few years; ultimate detachment of the retina was, however, later made out, which was some years afterwards followed by a low grade of irido-cyclitis and resulted in blindness from lenticular and vitreous opacities. I saw the case at the time of the accident and likewise 11 years later.

Sisson,[10] after discussing the various lesions of the iris from trauma, cites a case of a man aged 23 years, who was struck in the left eye by a piece of signboard. The external canthus was lacerated, but the sclera was not punctured. The iris was torn from its superior temporal attachment to the extent of 4 mm. The pupil was egg-shaped. Two days later there was a hemorrhage into the anterior chamber with + 1 tension. After the blood was absorbed the irido-dialysis had completely

disappeared. The author does not say whether the pupil was restored to its normal shape and position.

3. Traumatic aniridia or irideremia.

If the irido-dialysis be of such extent that the iris becomes fully torn from its ciliary attachment, it may fall down in the bottom of the anterior chamber and later shrink into an inconspicuous gray mass. If rupture of the sclera in the ciliary region be produced at the same time the iris may extrude or be expelled from the eye.

Etiolgy. All very heavy blows upon the globe, especially those which produce scleral rupture, may cause irideremia. It seldom occurs without opening of the globe. The iris has been known to have been entirely torn out of the eye during an operation for iridectomy.

The occurrence of irideremia from contusion without a bursting of the sclera is of different character than when the globe is opened. In the first instance the mechanism is the same, only greater in degree, as that of irido-dialysis, the lens remains, although it may be dislocated at the same time, in the second the iris extrudes from the wound, usually with the lens. Wintersteiner[5] thinks that the force of the blow must have first caused the complete loosening of the iris at its attachments to the ciliary body and the outflow of aqueous through the wound forces it out of the eye.

Symptoms. After resorption of the hyphema, which is usually great, the whole corneal space is black and by the ophthalmoscope is seen to be all pupil. The remains of the iris, where there has been no opening of the globe, are to be found in the depths of the anterior chamber as a little black ball which may vary in its location with the movement of the globe. The retina may be detached, the lens usually is dislocated from rupture of the zonula.

In cases where aphakia coexists there is a flattening of the limbus so that the globe becomes somewhat conical. Praun thus explains it: In this condition the whole interior of the eyeball becomes one chamber and the pressure of the extrinsic muscles lengthens the globe to an ovoid.

Hemorrhages occur in the vitreous, showing a dark-red reflex. If the media be clear, streaks of blood in the vitreous, the glare of the fundus and the ciliary processes may be seen on direct examination. In a few cases a portion of the iris may remain attached to its insertion and the remainder of the iris hang from it on a pedicle. In several instances the iris has been completely detached, expelled from the anterior chamber through the scleral opening, with or without the lens, and remained impacted under the conjunctiva. If any vision remains the symptoms are of asthenopia due to glare, the protecting iris being removed, and total loss

of accommodation. If the lens be extruded 1 or more D. of hyperopia is produced.

Diagnosis. The differential diagnosis is to be made between aniridia and total inversion of the iris. The latter is very rare and in the former the ciliary processes are to be seen, while in the latter they are covered by the iris.

Prognosis. These eyes are usually blinded, but in some cases sufficient vision remains to allow the patient to get about.

Therapy. The immediate treatment is that of contusion with hyphema, or of scleral rupture. Increased tension is to be combatted with eserin or paracentesis of the cornea. Sphero-cylindric lenses help the vision when the retina yet functionates. The theoretically advised stenopaic glasses, as recommended by L. Webster Fox[11] and others, do not seem to be of much use and are worn by the patients for but a short time when they are laid aside.

A man of 50 years of age, with one eye blind from ophthalmia, received a blow from an ax handle of sufficient severity to immediately blind the fellow eye. He was taken to a hospital and treated by a specialist. I saw him several years after the accident and could find no trace whatever of the iris, except a little mass at the bottom of the anterior chamber. The ciliary processes were easily seen, the lens was yet in situ, partial cataracts, but the patient had sufficient vision to allow him to get about the city by himself.

Fejer[12] reports a case in which a blow on the anterior segment of the eyeball caused a dislocation of the entire iris and lens into the vitreous. There was no injury to the sclera, the anterior chamber was deep, iris and lens absent from the anterior portion of the eye, and ciliary processes invisible. Deep in the eye could be seen a solid body, probably a portion of the iris and lens, which later became atrophied and partially absorbed.

Faith[13] reported three cases, two of which had corneal ruptures with iris excision shortly after the injury. The other case did not have corneal rupture. The lens was dislocated into the vitreous. In all the cases the anterior chamber was filled with blood for several days. The prominent symptoms in all the cases was increased tension, which was combatted by the use of eserin.

4. Inversion or retroflexion of the iris.

Inversion of the iris consists in its being pushed back so as to lie upon the surface of the ciliary body and looking as if it were absent. Partial dislocation is frequently observed and here the iris seems to be wanting, a coloboma appearing to exist. Total inversion is very rare.

Etiology. This form of injury results from contusions of mod-

erate severity, especially spent shot and whip lash blows. While other authors (Praun[6]) have observed it when the sclera has been opened, yet Müller[4] had not seen it in his extensive observation of ruptures of the sclera.

The other factor causing traumatic change comes from the cornea being flattened, which pushes the aqueous backward against the posterior wall of the anterior chamber, in which the area of the pupil is formed by the lens and in the rest of its extent by the iris. The latter when pushed backward finds its support in the lens, except in the marginal portion of the iris where the posterior chamber is deepest and, therefore, the periphery forms the most yielding spot and is the first to give way before pressure; this forces the iris back as far as the zonula or even into the vitreous causing inversion of the iris.

Symptoms. In but few cases is the iris entirely inverted, usually only a fourth or half gets into this position. If all be inverted a maximal mydriasis is accomplished, usually without luxation of the lens into the anterior chamber, which, however, may accompany the disassociation of relation. If a portion of the iris suffer this posterior prolapse a more or less large coloboma will be apparent, the base of the iris, however, not being involved and frequently only the pupillary edge being folded over. In contra-distinction to irideremia, the ciliary processes are covered over by the enfolding iris and are not to be seen in the coloboma. Atropin has no effect in retroverting the iris, as the pupillary edge becomes attached to the ciliary body by adhesions. There are no special subjective symptoms except from the contusion. Dazzling from the wide-open pupil may be noticed.

Diagnosis. Maximal mydriasis and a coloboma with the base of the iris remaining, and the folding over of the edges of the iris, should be observed. If the lens be partially dislocated the coloboma pillars will not be in the same plane as the rest of the iris.

In uncomplicated cases there is nothing to be said about prognosis or therapy. The iris remains in the new location without causing any particular disturbance.

A boy of 17 had put some powder in a can and dropped in a lighted match, the explosion took place while his head was over the can, which struck him on the eyebrow, cutting the brow and lid, producing blindness after a couple of days, as the force of the blow had ruptured the capsule of the lens causing traumatic cataract, and had likewise inverted a small portion of the iris to the upper and outer part. He was attended by another oculist but came to me a month later for removal of the cataract, which was done by discission with the effect of also removing the iris inversion.

Decided inversion, anteversion and radial tear of the iris with

traumatic cataract, from gunpowder explosion, occurred in a similar instance to the one above mentioned, and was attended by cutting of the eyebrow and lid, but there was more severe inversion of the iris with rupture and over-folding of the pupillary margin. Treatment by discission of the traumatic cataract has not restored the round contour of the pupil, the iris remaining torn and the pupil dilated.

5. Laceration of the sphincter. Sphincter rhexis; marginal tears of the iris.

Lacerations of the iris usually start from the pupil and may extend to the ciliary margin so that the pupil appears to be pear-shaped; or the laceration may be in the form of a pointed Gothic arch, or the pupillary margin may be torn but little and the gaping can only be discovered by careful examination.

Etiology. Such lacerations are the most frequent cause of dilatation of the pupil occurring after contusions (mydriasis traumatica), as they cause weakening or paralysis of the sphincter, due to laceration of its fibers; they frequently accompany simple cataract extraction (without iridectomy) and are caused by tearing of the iris in the efforts to remove the cataractous lens through an unyielding pupil. The ciliary muscle may also be paralyzed by contusion so that accommodation is affected.

Mechanism. There may be one or more tears at the same time. Foerster[14] states that the edge of the pupil remains passive over the convex surface of the lens during the trauma and has to give way by a rupture. Franke[15] thinks that at the moment of trauma a spastic contraction of the sphincter exists, while the corneo-scleral ring is enlarged, and if this does not give way, producing a dialysis, the pupillary tear occurs. Schirmer[16] thinks that the indentation of the cornea by the object producing the injury presses the iris on the lens and holds it fast so that the aqueous goes on either side and exerts a force sideways, thus tearing the iris apart.

Symptoms. The sphincter tear may go entirely through the membrane or only the muscle may be torn. In the former case the objective damage is apparent on direct examination, in the latter only by diaphanoscopy. Small tears are more common, extending 1-2 mm. from the pupillary edge. The edges of the tear separate so that a triangular enlargement of the pupil is seen. As a rule the bleeding is slight, only causing a hyphemia of a couple of mm. in height. The pupil is moderately enlarged, seldom fully dilated and less often normal. The subjective symptoms are those of contusion and dazzling except in complicated cases.

Complications. Other injuries, as lacerations of the ciliary body, dislocation of the lens, bleeding and formation of membranes in the

vitreous and rupture of the chorioid, frequently accompany this lesion.

Course. No inflammation follows, but the iris never heals, as the endothelium grows over the torn edges. Thus objectively the defect may be seen many years after, and histologic examination shows the want of union.

Diagnosis. If not obscured by bleeding, or upon resorption of same, the solution of continuity may be objectively seen by the naked eye or by the magnifier. In some cases dialysis is combined, and as a rule there are other injuries, before described, which are apparent to diaphanoscopy and the ophthalmoscope.

Prognosis. This depends upon the complications, especially of the vitreous, retina and chorioid. Single sphincter tears have no special significance as to vision.

Therapy. We would theoretically imagine that miotics would bring the torn pupillary margins together and cause healing, but such never happens. Atropin, however, is contraindicated, as its action would only tend to deepen the tear.

Sweet[17] reports three cases of rupture of the iris. In one of these there were five tears of the pupillary margin, with two radial ruptures at the lower portion, from a blow upon the eye from a bed post.

6. Rhexis iridis, tears through the entire width and extent of the iris.

A continuation of the marginal tear through the entire thickness and extent of the iris forms a traumatic coloboma which may be so regular that it seems as if surgically accomplished. This may happen in the case of scleral rupture when a piece of the iris is nipped off. Without an opening of the globe, the condition must be both a sphincter tear and dialysis accompanied by a doubling over, or inversion, of the torn lips of the iris.

Ginsburg[18] saw double tearing of the iris from a blow in a 44-year-old man. The retina also showed dialysis and complete rhexis.

Ayres[19] reports double radial rupture of the iris, stating that it is the only one on record since 1821. His case was in a boy aged 10, struck by a bb shot, penetrating, but not perforating, the lower lid, producing coloboma of the iris down and out with free-lying mass of iris tissue, which was separated from the iris both at the sides and at the ciliary attachment. After three months this was shriveled up and disappeared. The coloboma contracted, making a slit-like pupil. V. = fingers at three feet.

7. Dehiscences between the pupillary edge and the ciliary processes.

These dialyses anterior to the root of the iris, and between it and the pupil, are rare and are usually the result of a spent shot or other

substance striking the globe betwen the ciliary region and the pupil, denting it in and rupturing the iris in a circular manner. Usually several such tears exist and are parallel to each other and to the root of the iris.

I have seen but one case, here pictured, in a man who was struck by the end of a file. The dehiscences remained the same during the several months I knew him .

8. Pigment dehiscences.

Praun[6b] says that traumatic pigment coloboma is seldom seen, but it is, however, very common after cataract operations, as may be readily shown by transillumination. In but few cases does the lens escape from the globe without rubbing some of its retinal layer off. I have likewise noticed this condition is many cases of contusion which involved the iris. The trauma is not apparent by direct examination; if much of the posterior coat has been rubbed away the red reflex of the fundus may show through by the ophthalmoscope, but diaphanoscopy renders the diagnos easy, showing the dehiscences which appear reddish through the thinned membrane, almost as red as the pupil.

9. Anterior synechia after contusion.

Purtscher[20] described a case in which, following an accident, a cross-like adhesion of the iris to the posterior layer of the cornea had formed. He thought that the blow had caused such a lowering of the intra-ocular pressure that the cornea had remained sunken in, and adhesion of the iris had taken place. The condition may have been congenital, as Praun puts it, or there may have been a perforating wound which would put the case under the category of ordinary anterior synechia.

10. Mydriasis and myosis traumatica. Iridoplegia.

Etiology. Traumatic paralysis of the pupil is very common after severe contusions, especially blows upon the eye, spent shot, and injury from lightning.

Mechanism. Injury to the sphincter is the usual cause and can, in the majority of cases, be elicited by transillumination. In other cases the nerve endings of the oculomotor may be directly bruised, or bleeding into the iris tissue may prevent contraction.

Symptoms. As a rule irregular and moderate dilatation of the pupil is found with tears of the iris. More seldom is the pupil round. The reaction is absent or diminished. Hypotony usually exists.

The pupil is usually oval or moderately and irregularly dilated, as in the cadaveric position. Maximal mydriasis or myosis rarely exists. Fuller dilatation may be effected by atropin but the pupil dilates more

slowly than normally. If the pupil fully dilates to atropin there has been no lesion of the dilator muscle; if contracting fully to eserin, none of the constrictor.

Enlargement and diminution of the pupil, in themselves, do not cause any special interference with vision, if not combined with paralysis of accommodation. Slight dazzling may exist.

Complications. As a rule the chief significance of changes in the pupil following injury is that there is generally a deep-seated trauma, combined with paralysis of accommodation; fine opacities of the cornea; bleeding into the anterior and vitreous chambers, followed by retinal, chorioidal, and optic nerve hemorrhages and atrophy; disassociation of contiguity of the lens, chorioid and retina, in some cases with Berlin's opacity of the retina and destruction of the macula. In a few cases, according to Praun[60] myopic astigmia follows from spasm ot accommodation, or, as reported by Berlin[21] a myopic lens astigmia arises.

Diagnosis. The pupil is moderately enlarged, maybe irregularly, and does not react to light or accommodation. Accommodative paralysis or spasm exists, frequently with myopia. If no bleeding obscures the view injury to the sphincter may be seen on transillumination. The patient should be questioned as to previous use of mydriatics and it should be remembered that paralytic mydriasis is seldom maximal. Diseased conditions must be excluded.

Prognosis. Slight degrees may get well in the course of a few weeks, but many cases persist for the patient's life time.

Therapy. Protective smoked, euphos, amethyst or amber glasses give relief to the slight dazzling. Strychnin internally, eserin locally, the high tension and high frequency electrical currents may all assist Nature in the return to normal.

Cosmettatos[22] says usually the light and accommodative reflexes coexist, and the abolition of one is accompanied by that of the other, but it occasionally happens that one is abolished while the other remains. The cause of this partial abolition is referred to a lesion of the oculomotor, either at its nucleus or during its course, but traumatic lesions of the iris may also cause it, as shown in the case reported. A priest, 60 years of age, had received a blow on the right eye, in consequence of which his vision was disturbed. The pupil was partially dilated but sound, and there was no rupture of its margin. The light reflex was completely abolished, while the accommodation reflex was normal. The consensual reflex was also abolished and myotics had no effect. The iris oscillated and the lens was found to be dislocated downward and inward.

The abolition of the light reflex, of nuclear origin, without abolition

of the accommodative reflex, occurs in certain affections of the nervous system, particularly in tabes. To explain it a subdivision of the nucleus for iris reflex is supposed. A partial lesion may abolish one of these reflexes without disturbing the other; but this hypothesis has not been positively confirmed by pathologic and anatomic observations.

Lesions occuring in the extra-cerebral course of the oculomotor show that this nerve must contain two separate fasciculæ, one belonging to the light reflex and the other to the accommodative.

To explain the case reported above we must suppose that two kinds of nerve fibrils exist in the iris—one distinct to the accommodation and the other to the light, reflex.

This separation of the nuclei and of the nerve fibers, even if it has not been demonstrated anatomically, must be admitted to explain the clinical facts.

11. Atrophy of the iris after contusion.

This may occur, as reported by Goldberg.[23]

An employe of a locomotive works was slapped in the face by the breaking of a large leather belt. His face was bruised and cut. He was rendered unconscious for a few moments, and upon recovery was found totally blind. Vision was gradually returning when an attack of facial erysipelas set it back to where it was. It gradually returned, however, in both eyes, but never improved beyond, O. D. 5/xxx; O. S. 2/lx. The immediate effects of the injury to the eyes was manifested by O. D. anterior chamber deep, pupil eccentric, oval and dilated, tension slightly plus, several localized granular lenticular opacities and just below the macula a curvi linear lesion, yellowish in color, with pigmented borders. O. S. anterior chamber shallow, pupil oval, a few posterior synechiæ, on temporal side of disc a small pigmented area from hemorrhage. Later the pupil of the left eye became dilated ad maximum, immobile and markedly degenerated in appearance. In this eye there was also a well-pronounced neuro-retinitis and a localized retinal detachment. A posterior sclerotomy was performed and subretinal fluid allowed to escape. The final status of the case presented changes in the iris as follows: Left eye, two large areas of absorption in the iris plane of 160°; here the stroma had undergone an atrophic change, exposing the underlying retinal pigment. Right eye; a number of pigmented points which appeared as though laid on the surface, instead of being a part of the retinal pigment exposed by atrophy. They might be described as proliferations from the retinal pigment cells, which were reaching up through the fibers of the stroma to bud upon the surface; the atrophic changes were a later change, a true degeneration, in which the proliferated cells also suffered. The two eyes represented different steps in this process; the

left being more advanced and showing both changes taking place at the same time.

LITERATURE.

1. Jaeger, *Atlas,* 1869. Plate III, Fig. 20.
2. Fuchs, *Text-book,* Duane Ed., 1908, a. p. 259, 219. b. p. 258.
3. Arlt, ref. Fuchs, *Text-book,* p. 358.
4. Müller, *Ueber die Ruptur der Korneo-Scleral Kapsal durch stumpfe Verletzung,* Leipzig, 1895.
5. Wintersteiner, *Arch. f. Ophth.,* xl, 2.
6. Praun, a. l. c., p. 270. b. p. 283. c. p. 284.
7. Würdemann, *N. W. Med.,* March, 1909.
8. Amedie, *Gaz. d. Hop.,* Paris, 1866.
9. Jameson, *Arch. Ophth.,* July, 1909, p. 391.
10. Sisson, *Ann. Ophth.,* Oct., 1904.
11. Fox, L. Webster, *Text-book,* 1910.
12. Fejer, *Arch. Ophth.,* Sept., 1908, p. 568.
13. Faith, *Ann. Ophth.,* Oct., 1907.
14. Foerster, *Bereicht über die Heidelberger Versamml.,* 1887.
15. Franke, *Arch. f. Ophth.,* xxxii, 3, and xxxiii, 1.
16. Schirmer, *Klin. Mon. f. Aug.,* May, 1890.
17. Sweet, *Ophth. Record,* July, 1901.
18. Ginzburg, *Wjestnik. oftal.,* July, Oct., 1893.
19. Ayres, *Trans. Sec. Ophth. A. M. A.,* 1904.
20. Purtscher, *Centralbl. f. Prak.,* Aug., 1891, p. 324.
21. Berlin, *Klin. Mon. f. Aug.,* 1873, p. 42.
22. Cosmettatos, *Arch. d'ophtal.,* Nov., 1905.
23. Goldberg, *Ann. Ophth.,* July, 1910.

B. INJURIES TO THE CILIARY BODY FROM BLOWS.

1. Cyclitis traumatica.

Isolated inflammation of the ciliary body seldom occurs as it is part of the uvea and with it the iris and chorioid are usually affected. Praun[1] describes it as accompanied by severe pain, lacrimation and photophobia, pericorneal injection, hyperemia of the iris without synechia, stationary contracted pupil, spasm of accommodation, exudate in the vitreous and sometimes into the aqueous. So long as the inflammation remains confined to the ciliary body, not proceeding anterior to the iris or back into the chorioid, it may get well in a few weeks but in others goes on to irido-cyclitis with resultant atrophia bulbi. Kriener[2] says that rupture of the zonula or swelling of the ciliary body closes up the filtration angle and causes glaucoma.

2. Accommodation cramp and paralysis.

Mydriasis occurs with paralysis of accommodation; myosis with spasm. Perhaps cases of brief duration may be accompanied by commotio retinæ, and those of longer duration by bleeding into the ciliary muscle or rupture of the focus. Of special interest is the accompanying accommodative myopia.

3. Rupture of the ciliary body.

In severe cases of scleral rupture the ciliary body is usually implicated. There may be even pronounced laceration of the ciliary body from its attachment, or entire separation from the sclera. Fuchs[3] remarks that this sort of injury is found quite often in anatomical specimens, while clinically it cannot be diagnosticated, because we cannot see the ciliary body in the living eye. By laceration of this sort the anterior chamber is placed in direct communication with the space between the sclera on one hand, and the ciliary body and chorioid on the other (peri-chorioidal space). It thus becomes possible for the aqueous to enter this space and detach the chorioid from the sclera.

LITERATURE.

1. Praun, l. c. p. 285.
2. Krienes, *Festschr. z. 100 Jahr. Stiftungsfeir d. Fr. Wm. Inst.*, Berlin, 1895.
3. Fuchs, *Lehrbuch*, p. 359.

C. INJURIES TO THE CHORIOID FROM BLOWS.

1. Hemorrhage.

Etiology. Bleeding may occur from the ruptured chorioidal vessels following contusions of the eyeball.

Symptoms. In slight cases the hemorrhage may be circumscribed and appear in spots under the retina. In severe forms the blood does not remain in the parenchyma of the chorioid but spreads between it and the sclera, causing detachment of the chorioid, or between that membrane and the retina, causing retinal detachment. If the latter be also perforated the blood oozes into the vitreous. Zandler and Geissler[1] state that the blood may pass by way of a ruptured zonule into the anterior chamber.

Diagnosis. By the ophthalmoscope irregular blotches of blood are seen under the retina. At times these may be rounded and bluish-red; their centers dark-red; their edges blurred. The retinal vessels pass undisturbed over these hemorrhages. When the retina is torn its edges appear apart and rolled up as whitish-gray membrane.

Course and prognosis. If the hemorrhages be not accompanied by other damage they may resorb after a month or more, leaving a whitish plaque which later becomes replaced by pigment, the function being little altered. If, however, the hemorrhage causes dislocation of the chorioid or retina, or the retina be involved in the trauma, through cicatricial shrinking the function of vision is lost.

Therapy. Rest. Ergot and calcium chloride internally, followed by iodides; local treatment by galvanism and high frequency electric currents induce resorption.

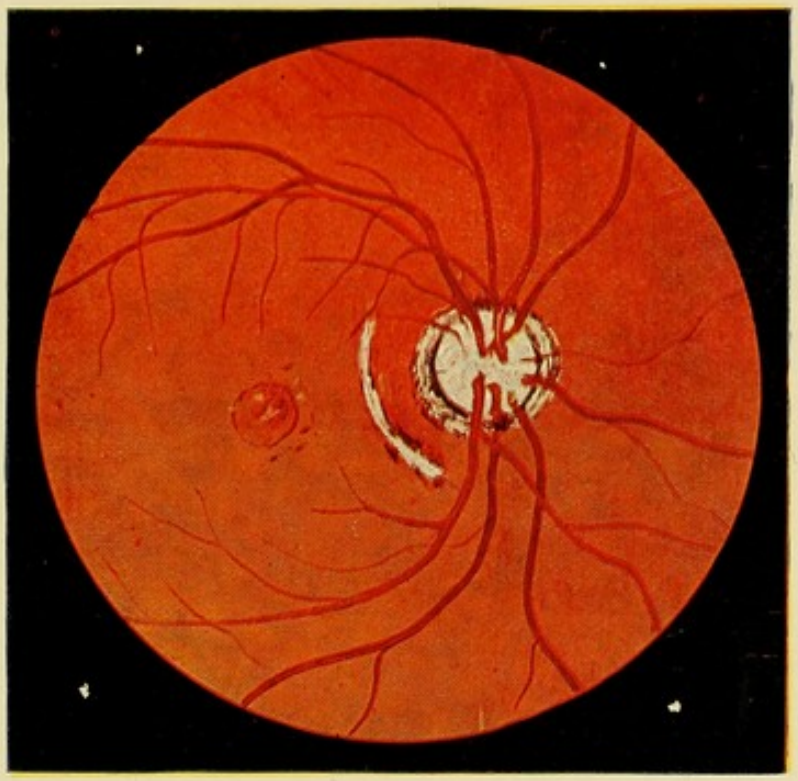

PLATE VI

Rupture of the chorioid two months after injury from whiplash. Jan. 29, 1908.

2. Rupture of the arteries.

Siegrist[3] has the only writing I can find on this subject, except Praun's[3] allusion to the article. Siegrist described four cases of contusion of the globe where yellowish discolorations of the fundus, of more or less spherical shape but with sharply defined edges and with later wandering pigment into the retina, followed. In one case there was an apoplexy of the macula, in two white stripes in the retina. He describes the discoloration as proceeding from the papilla forwards. There were central and para-central scotomata.

Wagenmann[4] produced these same appearances experimentally by cutting the ciliary vessels, and ascribes them as primary to nutritive disturbances in the chorioid and secondary to partial degeneration of the retina.

3. Hemorrhagic dislocation.

Etiology. Dislocation of the chorioid from hemorrhage under it is rare in eyes that have not been opened. It is often seen in scleral rupture, has occurred after cataract, iridectomy, and staphyloma operations, and is often found in anatomic examination of atrophic eyes.

Mechanism. This is due to rupture of a large vessel of the chorioid near the posterior pole, most likely at the venæ vorticosæ. After operations it is due to the sudden relief of intra-ocular tension.

Symptoms and course. Immediate loss of vision follows bleeding under the chorioid. If acute glaucoma, with diffuse opacity or bleeding into the media, does not prevent examination by the ophthalmoscope, then may be seen a reddish-brown or yellowish prominence in the vitreous behind the retina. The blood vessels of the chorioid may be seen over the surface of the swelling. Retinal opacity and hemorrhage often obscure the view. This is direct from the retina, and from migration of blood from the chorioid.

Diagnosis. If the blood vessels of the chorioid be seen by ophthalmoscopic examination over the reddish tumor a diagnosis may be made. Even here there is a distinction to be made between a hematoma and sarcoma. The history should help, as the loss of sight is sudden from bleeding, and slow from a true tumor. The hemorrhagic swelling may change in position, as the head is carried to one side, while a true tumor remains in the same place.

Prognosis. The prognosis is bad as regards sight, and even as to retention of the globe, for acute glaucoma sets in and in most cases these eyes have to be enucleated. In cases where the globe has been opened, as after cataract, the bleeding may be extremely severe.

Therapy. Iced compresses, ergot, calcium chloride, and, when acute glaucoma with great pain sets in, enucleation.

In an old woman who had chronic corneal ulcer spontaneous perforation took place which caused severe intra-ocular hemorrhage, which poured forth from the eye, saturating clothes and forcing out the ocular contents. Enucleation was practised, with ultimate cure.

In an old man on whom I had successfully made iridectomy of the other eye for glaucoma, which restored much of the lost vision, an iridectomy on the totally blind eye was followed by immediate good results, but 24 hours later the bandage was stained with blood which came in great clots from the eye, and enucleation had to follow.

Posey[5] reports two cases, one of extensive hemorrhage into the vitreous during cataract extraction which forced the vitreous out of the eye. After a long process of pain and inflammation, the globe passed into phthisis bulbi. The other case was one in which a vitreous hemorrhage

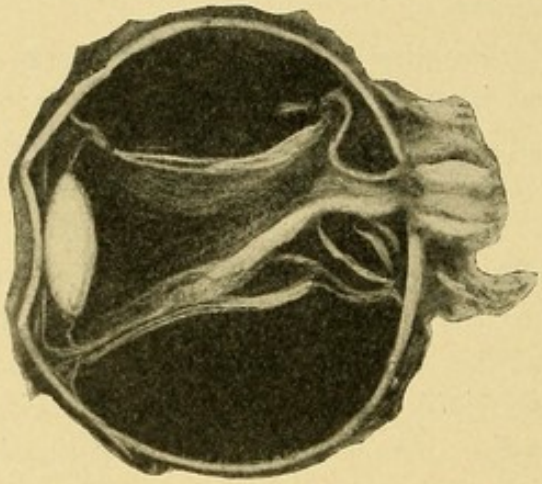

Fig. 298.
Detachment of chorioid and retina from subchorioidal hemorrhage.

occurred during the performance of a sclerectomy to relieve secondary glaucoma in an eye which had been operated upon for cataract six months previously. The eye passed into low-grade uveitis, with subnormal tension, with faint light perception remaining.

4. Indirect rupture.

History. While ruptures of the chorioid are looked at even now with some curiosity by ophthalmologists, yet since they were first pointed out by von Graefe,[6] in 1854, there have been many publications concerning same. The early authors, Mauthner,[11] in 1868, in his text book, Caillet,[7] in 1869, H. Knapp,[8] and de Wecker,[9] in 1870, and Achard,[10] in 1877, gave very complete descriptions. Many cases were seen during the war between France and Germany. Ammon[12] was the first who made a microscopic examination of these ruptures.

Etiology. Causing rupture of the chorioid are all contusions which agitate the bulb in its surroundings, the most common of which are corks flying out of bottles, the impact of shot or thrown pieces of wood and iron, whiplash and pencil injuries, and industrial accidents. In a few cases the chorioidal rupture may come, as noted, from an injury distant from the eye, such as Ammon[12] describes from a shot in the mouth, from a water pistol, which caused a fracture of the inner orbital wall. Adamück[13] described the case of an officer who received a blow at the battle of Plevna and fell upon the ground, causing a great jar and chorioidal rupture. Mannhardt[14] saw a rupture in a workman following an extensive convulsion of the whole body. Benson[15] described one from a fall from a horse. Schmidt-Rimpler[16] saw one in the case of a new-born child from a forceps delivery.

One chorioidal rupture is found in about one thousand patients. Ohm[17] states that of 289 cases 70 per cent. were single ruptures, some 16 per cent. double; while a radial rupture is found in some 10 per cent. Those combined with arc-like rupture happened only in 7 per cent. of the cases, that is, once in 15,000 eye patients.

Pathology. Parsons[18] says: "The early stages of rupture of the chorioid have not been examined microscopically. In indirect wounds caused experimentally or by foreign bodies, other structures are invariably injured in addition. In experimental wounds in rabbits Tepljaschin found the changes to be essentially inflammatory and reparative. The tissues were separated by serous exudate and infiltrated by wandering cells, whilst karyokinetic figures formed a distinct feature in vertical sections. They were principally 'internal to the chorio-capillaris,' in the layer described as the musculus choriodæ in rabbits by Hällsten and Tigerstedt. Karyokinetic figures were also seen in the cells of the muscular layer of the walls of the large chorioidal vessels. He found similar results in experimental injuries on monkeys, and it is to be noted that the chorioid affords the chief means of repair in these cases, as might be expected from its highly vasular nature."

Types. There are interesting variations of this condition.

Ophthalmoscopic examination: The consensus of literature shows, according to Hughes[19] that temporal ruptures occur in 82 per cent. nasal ruptures in 14 per cent., horizontal ruptures in 4 per cent. The tear is usually found in the posterior pole of the eye, concentric with the optic nerve, between the optic disc and the macula, forming a half circle about the papilla. In a recent case the eye is often so swollen and photophobic, and the injury is so obscured by obstructions in the anterior chamber, vitreous, bleeding into the retina, that it is difficult to see; but it may be observed as a yellowish streak with its edges covered by blood, mixed with pigment. Upon resorption of the blood and clear-

ing of the media, as a rule the injury appears to be about ⅓ to ½ the width of the disc, and two or three times its length, sharp at its ends, with its concavity directed toward the optic nerve, forming a concentric defect of a yellowish-red color, later becoming white, which is caused by the sclera showing through its edges, and still later becoming pigmented. In the neighborhood of the tear the retina shows streaks of blood and the swelling of its blood vessels are seen over the defect when the tear does not also extend through the retina; but as a rule the pigmented epithelium of the latter membrane is likewise torn. The bleeding is confined to the tear and its neighborhood, and in some cases is very slight, so that in but few the vitreous and the anterior chamber show any effusion of blood. The tension of the eyeball remains about the same unless the bleeding is severe, except in the case where there is a perforating wound of the eyeball with loss of vitreous, when the tension is lowered and much blood may be observed in the interior of the eye.

De Wecker[20] stated that the defect is white when the lamina fascia remains unbroken and in connection with the sclera, and not bluish, which is the case when the sclera itself is uncovered in the line of the rupture.

Atypical Conditions: These are mainly confined to the form of the tear, which may be even three or four times the width of the optic nerve and very much longer. An enormous rupture which occupied the entire posterior portion of the fundus is described by Mannhardt.[14] In another case the end of the crescent was in the form of a fork and directed towards one side. Aub[21] found in a 14-year-old patient, who had a stick of wood fly against the eye, that the region of the macula was occupied by the chorioidal defect which had two processes from above and two downwards.

The position of the tear in perhaps one-tenth of the cases occurs inward from the papilla, while a number have been described which occurred radially from the papilla to the periphery, in a few the tear being horizontal and more seldom vertical.

The following is a typical case of single injury. A boy received a blow from a whiplash on his face and eyes two months before I saw him, in January, 1908, after which his sight gradually failed until upon examination it was reduced to fingers at 1.00. Pupil slightly dilated and slow. Optic nerve atrophic. Crescentic linear rupture two disc diameters long, one disc diameter distant and between disc and macula. The macula showed degeneration similar to that of the senile type with pigment migration. Some pigment about edges of rupture and about the scleral ring, which was very pronounced.

Double recent ruptures of the chorioid. A teamster was seen by me in consultation in March, 1906, who, while skylarking in the barn

with a fellow-workman, had been struck on his temple by a heavy rope end. Externally the left temple was found discolored by a bruise. Vision 6/lx. Opthalmoscopic examination showed two small ruptures of the chorioid; one linear, two disc diameters long, vertically between the disc and macula, which was partially obscured by a small hemorrhage, apparently in the vitreous; and the other at the temporal side, likewise vertical, the ends of which were obscured by blood and beginning pigment migration, the latter hemorrhage being under and in the retina, and apparently the source of the smaller blood stains in the vitreous. Patient seen about one month later when the blood had resorbed, and the region of the chorioidal ruptures was with difficulty observed as simple pigment discolorations. Vision had increased to 6/xxiv.

Still more atypical cases of fork-shaped and triple ruptures are met with, as in the following:

A farmer was seen by me in consultation in January, 1908, one month after a kick from a horse on his eyebrow. No external injury manifest. Three ruptures of clear, white aspect, downwards and slightly outwards from the disc, the nearest being linear and only as long as the width of the disc, the middle one wider and double the length of the first and forked at the lower extremity, the lowest one likewise forked and about three times the length of the upper. Some pigment deposit was observed, especially at the upper portion of the middle rupture and about the chorioidal ring. Vision 6/lx, V. F. showed re-entrant and contraction at upper part. Optic nerve pale but not otherwise showing atrophy.

Examples of horizontal tears have also been described by Mauthner[11] and Teillais,[22] the latter of whom found, after a luxation of the lens, a disturbance of the vitreous, and four horizontal tears of the chorioid which were parallel to each other. Hirschler[23] observed a rupture in the form of a triangle whose angle was against the optic nerve. Hughes[19] described a case of a horizontal rupture of both the chorioid and retina. Hutchinson[24] described a very long, horizontal scar of the chorioid after a blow upon the eye, which later caused pigmentation of the retina and blindness. An example of a vertical tear was given by Mannhardt,[14] in whose case the rupture occupied this position. De Wecker[20] described, as a very rare case, a tear between the papilla and macula in a five year old boy who had had a piece of sod fly against the eye.

The tear may also go around the whole or three-fourths of the optic disc, when optic nerve atrophy begins rapidly from disturbance of nutrition.

Two such were seen by me,[24] one of which was as follows: A farmer consulted me in August, 1904, three months after being hooked in the

eye by a cow. The horn of the animal had torn the upper lid away from the brow, but it had been rather clumsily replaced and sutured by a local physician. Plastic operations restored the external appearances. Pupil slightly dilated. V. = objects. Large crescentic cicatrizing rupture of the chorioid occupying about half a circle, about the middle of which an island of red showed, it passing into a fork-shaped prolongation. The rupture converged into one continuation and finished the horns of the crescent as it began. One disc diameter above this, and parallel to it, extending from the inferior vein upwards and outwards to the macula was another curvi linear cicatrix. Both of these sites of ruptures had pigment deposits about their edges in places, but not so much as might have been expected from the condition of other portions of the fundus, which showed roundish areas of chorioidal atrophy through which the sclera appeared yellowish, and about the edges of which pigment deposits were beginning to form, as was likewise the case at the chorioidal ring where the pigmentation was diffuse and profuse. The chorioid was likewise torn away from the optic disc nearly half way around at the superior and temporal quadrants, at the upper end of which it had three prolongations. This is the most striking picture of the condition I have ever observed. The optic nerve was atrophic. V. = movement of objects. Visual field reduced.

H. Knapp[8] told of a chorioidal tear which went around three-fourths of the optic nerve, following a blow upon the eye, without any other injury, in which chorioiditis with atrophic spots followed. A case of double rupture of the chorioid in which a tear was observed inwards from the optic nerve, and another outward and forward, was described by Ginzburg.[26] When both the tears have the same radius it is possible that a cross-shaped tear may be seen, which occupies the deeper layers of the chorioid in the deeper sectors. De Wecker[9] said that in many cases he had seen small tears extending out from the larger one, especially in the neighborhood of the macula.

These ruptures may go directly from the macula and have been described by Adamück[13] and Vossius.[27] Saemisch[40] saw a case in which one extended peripherally from the ciliary body. In another one a central rupture above the papilla, and a more peripheral one above the ora serrata, were found accompanying a case of rupture of the posterior capsule of the lens, by Aub.[21]

Hoor[28] found and described many ruptures of the chorioid in one case of a boy of 12 years.

The number of tears which may exist at one time may be two, three, four or more, of which the central one is usually the largest, that peripherally the smallest, and sometimes these cross over one another.

The peripheral tears are usually more of a yellowish color, and situated in the posterior layer of the chorioid.

Polano[29] has described the characteristics of multiple tears. These usually occur from gunshot injuries. Double chorioidal ruptures are described by Genth[30] and Talco[31] in which case the vision was normal, as were likewise those of Hersing[32] and Vossius.[27]

Banister[33] described a double rupture of the chorioid under the papilla from impact of a pebble, in which there were three concentric ruptures. Benson[15] described another case in which there were three ruptures, one in the neighborhood of the macula, one in the papilla, and a greater one in the periphery, in the case of a 19 year old girl, from an exploding vessel.

Fage[34] saw three half-moon-like ruptures in the right eye of a 40-year-old man, one medial, two lateral, from the posterior pole. Besides this there was bleeding into the retina and peripheral flap detachment. Teillais found four horizontal ruptures in another case.

Kröner[36] reports rupture of the chorioid and retina in the shape of a coloboma in a girl who fell down stairs, her face striking on a cup, producing external injury of the lids, nose, etc., which soon healed. The pole was eccentric, vision 8/x. Nasal, downward, two or three papillary diameters distant from the papilla, a large clear white spot is visible, the end toward the periphery and not to be seen. Adamück,[13] Hirschler and Pincus[38] also described cases of spot-like chorioidal rupture.

Kröner[37] had pigmentation of the retina with rupture of the chorioid in the case of a 42-year-old man in whom a piece of rail had flown against his left eye that morning. Case observed for several months, at first a large light spot with many small bluish black pigment spots in same. This changed gradually into two spots, or resolved into irregular pigment spots. Vision became fully normal.

H. Knapp[8] saw a case of Lawson's[35] in which an isolated rupture of the retina at the posterior pole of the eye was at first diagnosed as a rupture of the chorioid. This occurred from a block striking the eye. Two months afterwards there was a central scotoma. With the ophthalmoscope there was a tear found at the macula, and there was a dark spot, either of pigment or the remains of blood.

Accompanying the rupture of the chorioid may be other injuries, such as traumatic mydriasis, paralysis of accommodation, rupture of the iris and sphincter, seldom dialysis, aniridia, etc., tearing of the zonula, the capsule of the lens and luxuation of the lens. In many cases bleeding into the macula occurs. Such have been reported by Vossius[27] and Knapp.[8] Mannhardt[14] reported an interesting complication in which the chorioidal tear lay outwards and above the papilla end of the

usual curved shape. At the same time he found at the outer quadrant of the papilla a round, gray spot of about one-third its diameter, in which there was a cup-shaped portion which pulsated synchronously with the radial pulse, caused by a spurious aneurism from the central artery of the retina in the optic nerve. In a few cases retinal pulsation also occurs.

The secondary degenerative changes are due to cicatrization of the chorioid, atrophy, and degeneration of the retina, especially at the macula, leading to atrophy of the optic nerve. Streatfield described a deep glaucomic excavation.

Functional Disturbances. Immediately after the occurrence of an accident there is traumatic mydriasis, loss of accommodation, etc., the loss of vision depending upon the opacity of the media. Commonly the pigment layer of the retina is affected in the rupture, and a loss of function is shown, and goes hand in hand with the loss of the visual field. By streakiness, opacity, and bleeding in the neighborhood of the retina the sight is interfered with. In many cases peripheral defects of the visual field are shown, which are ascribed by Pohlenz[39] to tearing of the nerve fibers in the optic nerve itself. The loss of vision is later due to interference with the nutrition of the retina, and particularly of the macula from connective tissue forming in the chorioid. These occur without the sight being complained of. The retina, however, especially the macula, is affected in the formation of scar tissue. If the retinal tissue is not affected the beginning metamorphopsia of the sight may pass away and the vision return entirely, as was the case with the patients of Hersing,[32] Knapp,[8] Saemisch,[40] Adamück,[13] and Vossius.[27]

Meneghelli[41] had an iron-worker who received a blow in the right parietal region and fell unconscious, striking the left temple on a pile of coal. The left eye also struck the coal, the lids were ecchymosed and in the region of the external angle the skin was lacerated. He partially recovered consciousness in a few hours, but remained stupid for two or three days. The sight of the left eye was somewhat diminished. Without treatment vision improved, but there remained before the eye numerous movable bodies, one of which was very noticeable with every movement of the eye. Internally there was seen on the sclera, a mm. below the horizontal meridian and parallel to the same, a blue line which extended from the external angle to within 7 mm. of the corneal limbus, measuring lengthwise about 14 mm. The line appeared slightly depressed. V. = 5/xv and in the good eyes = 5/vii. V. F. showed an annular scotoma, absolute, for white and for colors. The ophthalmoscope revealed moving bodies in the vitreous, some black, others of the aspect of a semi-transparent membrane. The papilla, slightly red in color, was

oval with long diameter vertical. About 4 papilla diameters from the macula, externally, there was a rupture of the chorioid which one could follow with the ophthalmoscope along the horizontal meridian to the anterior limit of exploration. Radiating from this point were two horns, one above and one below.

Cuperus[43] showed a patient who, two years before, was wounded by an iron particle, which perforated cornea and lens and produced a slight cloudiness of the vitreous. After two years' rest the eye became suddenly blind and showed a large white streaky focus with pigmentation in the temporal part of the fundus. From this focus different striæ retinales pass out; above the disc the symptoms of retinitis proliferans. He could not find out if iron still was present within the eye.

Course. The blood in the neighborhood of the injury is resorbed and the opacities of the media go away; the hemorrhage of the rupture is resorbed, and pigment is deposited at the edges. The region of the rupture is now made clear, and blood stripes are found in the retina here and there, especially at the macula. The tear in the chorioid commences to cicatrize and may be observed from time to time to grow smaller (Hersing,[32] Knapp,[8] Adamück,[13] Vossius[27]). Large tears very seldom come together, smaller ones more commonly, with or without the healing up of pigment, and then will be found chorioidal changes and pigment deposits and atrophic spots.

If increase of vision occurs and the chorioidal tears come entirely together, and the retina is not affected, which is only occasionally observed, sight may fully return, but as a rule the retina becomes atrophic from changes and the sight declines. Detachment of the retina and atrophy of the optic nerve may likewise follow.

Complications. The most common complication is contemporaneous tearing of the retina, which renders the prognosis of the injury very unfavorable. Rupture of the retina may likewise occur primarily from the contusion of the eye, and secondarily from blood effusion from the torn blood vessels of the chorioid. The pigment layer of the retina is commonly affected with the chorioidal injury, but not so often does the injury extend through the entire membrane.

A restitutio ad integrum is of course impossible in such unpromising cases. The retina degenerates and the sight diminishes.

I have observed simple detachment with effusion in several cases, one of which was as follows:

Two days after a blow during a fist fight a mulatto boy was seen by me at the Washington Infirmary, in 1888, coming on account of hemorrhage of the conjunctiva. I was doing a great deal of illustrative work then and made the drawing of the fundus which is shown herewith, and which at the time puzzled some well-known ophthalmologists, and a def-

inite diagnosis of the condition was not then made. In the light of the following score of years, however, the diagnosis is now quite easy. Near the optic disc, which is seen to have an extreme physiologic cup, there are two crescentic lines in a greenish area, about the size of the disc, over which the retinal vessels pass, but are wavy and altered in their course. This is an effusion of serum from the chorioid under the retina, causing slight and probably temporary detachment due to the chorioidal rupture. No hemorrhages seem to have occurred. Some pigment spots in the retina, probably of ancient origin, are likewise seen, but had no connection with the injury.

Rupture of the retina and pigment migration from hemorrhage into the vitreous, complicating rupture of chorioid, has been seen by me in one case.

Recent multiple ruptures of the chorioid, with retinal rupture and detachment (author's case), were seen in a boy who received a blow from a whip-lash, by which he was immediately blinded, two weeks before I saw him in consultation in January, 1906. Three linear diagonally-placed ruptures between the optic disc and macula, each about double the length of the disc, were seen. Over these in the vitreous was a hemorrhage. Beginning pigmentation was observed between and around the disc, which was decidedly hyperemic. At the lower part of the fundus a flat detachment of the retina with a peculiar, spotted-black, pigment migration into the vitreous and a horizontally placed hemorrhage over a ruptured retina, completed a striking and, at first, a puzzling picture.

For combined retinal and chorioidal rupture see Cowell,[44] Hirschberg,[45] Genth,[30] and Baüerlein.[46]

Magnus[47] saw a tear of the retina and chorioid on the inner side of the papilla without any other injury. The sight, which was at first good, failed rapidly.

Diagnosis. One can see that rupture of the chorioid happens more commonly than is shown by clinical research. At first it is obscured by bleeding and opacity. Later it is often overlooked, or the patients do not return for further treatment. One should observe these patients for a long time and examine them from week to week, but many indolent patients allow their eyes to become blind without the cause of it being ascertained. The ophthalmoscopic picture of a rupture of the chorioid is so typical that it cannot well be mistaken for any other condition.

Prognosis. In a very few cases complete healing occurs with resultant good sight, but as a rule the vision deteriorates from secondary changes in the retina and optic nerve. In extraordinary cases the vision remains good, as in a case of Talco's, where a double rupture of the chorioid had occurred twenty years before and vision remained.

Therapy. At first atropin should be ordered so that the ciliary muscle remains quiet, and then strychnin injection resorted to, with then high frequency and high tension electric applications. The patient should be quiet for a long time. Leeching, sweating, and the dark-cure are without any particular benefit. Atropinization does no harm and keeps the eye quiet during the course of changes following the injury to the chorioid.

Hirschberg[45] reports three cases of rupture of the chorioid caused by tennis balls. Sight was restored in all. He recommends to high myopes and people who wear glasses great care in playing tennis, as injuries are quite frequent.

5. Direct rupture.

The tear of a direct rupture of the chorioid is situated, in contradistinction to the indirect, at the periphery of the fundus at the ciliary region. An irregular, wide tear in the chorioid is here seen, through which the sclera shows bluish white. The retina may be burst open, opaque, or detached. The sclera may be indented or opened. It is usually combined with laceration of the ciliary body and generally connected with contused wounds or rupture of the sclera. Müller[48] found chorioidal tears parallel to the scleral opening in several cases of his series of ruptures of the sclera.

LITERATURE.

1. Zandler and Geissler., ref. Praun, p. 288.
2. Seigrist, *Mitteil. aus d. Klin. u. Med. Inat. d. Schweiz.*, Basel, 1895, p. 554
3. Praun, (a) l. c., p. 289 (b) p. 293.
4. Wagenmann, *Arch. f. Ophth.*, xxxvi, 4.
5. Posey, *Ann. Ophth.*, July, 1909.
6. von Graefe, *Arch. f. Ophth.*, i, 1, 1854.
7. Caillet, *Thése de Strasbourg*, 1869.
8. H. Knapp, *Arch. f. Aug.*, i, 1, 1870.
9. de Wecker, *Traite des mal. l. oeil*, 1870.
10. Achard, *Thése de Paris*, 1877.
11. Mauthner, *Lehrbuch der Ophthalmoskopie*, 1868.
12. Ammon, *Arch. f. Ophth.*, i, 2, p. 124.
13. Adamück, *Centralbl. f. prakt. Aug.*, Nov., 1878.
14. Mannhardt, *Klin. Monatsbl. f. Aug.*, p. 132, 1875.
15. Benson, *Brit. Med. Journ.*, 1883, p. 256.
16. Schmidt-Rimpler, *Die Erkrankungen des Auges im Zusammenhang*, etc., 1898, p. 526.
17. ref. Pohlenz.
18. Parsons, *Pathology of the Eye*, 1905, ii, p. 445.
19. Hughes, *Arch. f. Ophth.*, xxxiii, 3.
20. de Wecker, *Graefe-Saemisch*, Vol. iv, p. 668.
21. Aub, *Arch. f. Aug.*, ii, p. 256.
22. Tellais, *Annal. d'oculist*, 1877, p. 26.
23. Hirschler, ref. N. M., 1887, p. 365.
24. Hutchinson, *London Ophth. Rep.*, July, 1888.
25. Würdemann, *N. W. Med.*, March, 1909.
26. Ginzburg, *Westnik. Ophth.*, x, p. 361.
27. Vossius, *Klin. Monatsbl. f. Aug.*, p. 276, 1883.
28. Hoor, *Wein. Med. Woch.*, 1886, No. 32.

29. Polano, *Inaug. Dissert.*, Kiel, 1897.
30. Genth, *Klin. Monatsbl. f. Aug.*, p. 143, 1871.
31. Talco, *Klin. Monatsbl. f. Aug.*, p. 143, 1871.
32. Hersing, *Klin. Monatsbl. f. Aug.*, p. 11, 1872.
33. Banister, ref. *Centralbl. f. Aug.* Suppl., p. 524, 1894.
34. Fage, ref. N. M. 1894, p. 391.
35. Lawson, *Injuries to the Eye*, 1868.
36. Kröner, *Tydschr. V. Geneesk*, March 10, 1896.
37. Kröner, *Tydschr. v. Veneesk*, April 14, 1906.
38. Pincus, ref. Kröner.
39. Pohlenz, *Inaug. Diss.* Halle, 1891.
40. Saemisch, *Klin. Monatsbl. f. Aug.*, p. 33, 1867.
41. Meneghelli, *Ann. di ottal.*, Nos. 5-6, 1906.
42. Hirschberg, *Centralbl. f. Aug.*, p. 263, 1906.
43. Cuperus, *Tydschr. v. Gencesk*, March 7, 1908.
44. Cowell, *Ophth. Hosp. Rep.*, vi, p. 251.
45. Hirschberg, *Berlin Klin. Woch.*, 1870, p. 532.
46. Bäuerlein, *Blätter f. Heilw.*, ii, p. 9, 1871.
47. Magnus, *Klin. Monatsbl. f. Aug.*, 1887, p. 478.
48. Müller, *Über Ruptur d. Korneo-Skleral Kapsel*, etc.

E. TUMOR FORMATION IN THE UVEA AFTER INJURY.

Fuchs[1] found that in 11 per cent of the cases of chorioidal sarcoma in the literature, and in his own practice, accidents are ascribed as the etiologic factor. In the 19 cases of chorioidal sarcoma observed by him practically all of them gave a history of some accident to the eye, such as impact of pencil, finger, or large foreign body.

If we accept trauma as the exciting cause of new growth we must then consider the theory of Cohnheim as developed by Leber and Krahnstöver[2] that the nucleus of the sarcoma is existent in the eye before the injury and is thereby excited to development. Phthisical eyes are prone to such degeneration, as was first reported by von Graefe.[3] Leber and Krahnstöver found that the majority of their 34 cases of sarcoma of the chorioid had a history of previous injury.

LITERATURE.

1. Fuchs, *Das Sarkom des Uveal traktus*, Wien, 1882.
2. Leber and Krahnstöver, *Arch. f. Ophth.*, xlv, 1.
3. von Graefe, *Arch. f. Ophth.*, xiv, 2.

F. INJURIES FROM FIREARMS.

a. Injuries of the iris and foreign bodies in the anterior chamber. Wounds and prolapse.

The iris is often wounded at the same time as the cornea, and the injury is complicated by the prolapse of the iris into the perforation.

Foreign bodies. Of isolated foreign bodies in the iris and the anterior chamber, powder grains are most common. Pellets of shot, as well as pieces of metal and splinters from bullets have been found in the iris and anterior chamber, being well borne as a rule, as they are usually aseptic.

Contusion and Concussion. Effusion of blood into the anterior chamber is found from direct, as well as by indirect, shot lesions of the eye. From spent shot there occurs most commonly mydriasis and myosis, irido-cyclitis and the severe forms of tearing of this membrane. The dialysis usually occurs from direct injury from spent shot, the location being at the point of impact. I have seen this a number of times. Rupture of the iris does not occur often in the case of indirect shot wounds where only the orbit, and not the eyeball, has been hit by the projectile.

Cohn[1] has reported such a case of dialysis and other ruptures of the iris, other severe injuries accompanying this lesion, such as bleeding into the interior of the eye, opacities of the vitreous, discolorations of the lens, rupture of the chorioid, dislocation of the retina, etc.

Irideremia has not been reported.

Schmidt and Ammon[2] reported indirect inversion of the iris in two cases of attempted suicide by shot through the mouth. Elsewhere I have noted two cases of inversion of the iris from gunpowder explosions, as well as radial tear of the sphincter. In the case of rupture of the sclera the whole iris may be torn out. Traumatic enlargement and contraction of the pupil and rupture of the chorioid have been described on preceding pages.

b. Injuries of the ciliary body.

Wounds. Injury of the ciliary body by perforating corneal and scleral wounds from shot pellets or bullets is common, being previously described.

Foreign Bodies. Occasionally a shot or portion of a bullet will remain in the ciliary region, especially from artillery shots. Cohn describes one in which the bulb was enucleated three months after the injury, on account of sympathetic ophthalmitis, in which a small particle of granite stone was found in the ciliary body.

Contusions. Contusions of the ciliary body cause hemorrhage into the iris structure, dislocation of the sclera, and laceration. These all occur in perforating wounds of the ciliary body.

c. Injury of the chorioid.

Contusion from shot causes, as a rule, chorioidal rupture, which may be either direct or indirect. This is the most common lesion from spent shot wounds which cause changes in the deeper portions of the eye, coming from blows upon the orbital walls, by which severe concussion takes place on the eyeball directly injured by the projectile.

Von Oettingen[3] states that indirect chorioidal rupture from

fire arms is characteristic, in that the chorioid is torn upon the side of the injury to the bony walls, and is not usually concentric to the optic nerve entrance. Direct chorioidal rupture is caused by the shot or bullet causing lesion of the capsule of the globe, and is usually accompanied by contused wounds and loss of the eye on account of the force of the explosion as well as the impact of the projectile and splinters of bone.

Direct chorioidal rupture from firearm injuries are usually of great extent, irregularly-shaped, and their edges not well defined, and are followed by irregular pigmentation in the neighborhood of the lesion.

Hirschberg[4] reports several cases in which the entire neighborhood of the optic nerve entrance showed as a white area without any blood vessels being visible therein.

The course of a chorioidal rupture is unfavorable on account of the degenerative changes in the chorioid and the retina, which are followed by chorio-retinitis and optic nerve atrophy, although the form of the globe is usually preserved. The diagnosis at first cannot be well made on account of the swelling of the lids and bleeding into the media. After this clears up the conditions can be seen by the aid of the ophthalmoscope. The treatment is rest and palliation.

LITERATURE.

1. Cohn, *Schutzverletzungen des Auges,* etc.
2. Schmidt and Ammon, ref. Praun, l. c., p. 298.
3. Von Oettingen, *Die Indirect Schutzverletzungen,* etc.
4. Hirschberg, *Der Revolver und das Auge.*

CHAPTER XXII.

INJURIES OF THE LENS AND ZONULA.

I. Injuries of the lens. A. Direct wounds and traumatic cataract—Etiology and mechanism—Symptoms—Course—Resorption—Complications— Diagnosis—Iritis—Prognosis—Medicinal therapy—Atropin—Dionin—Bandage — Iced and hot applications—Leeches—Operation— Discission—Linear extraction —Extraction and expression—Sympathetic ophthalmitis—Literature. B. Foreign bodies—Etiology—Long retention—Iron—Copper—Glass—Symptoms and course—Complications—Diagnosis—Prognosis—Therapy—Literature. C. Injuries from contusion—Indirect traumatic cataract—Etiology—Glass blowers—Electric cataract—Literature. D. Thermal and light injuries and from electricity—Etiology—Glass blowers—Electric cataract—Literature. E. Injuries to the lens from firearms—Wounds—Foreign bodies—Contusions—Literature. II. Injuries of the zonula and dislocations. A .Wounds. B. Laceration—(a) Relaxation—(b) Partial laceration without displacement of the lens—(c) Partial laceration with subluxation of the lens—Definition, symptoms and course—Diagnosis—(d) Total laceration with dislocation—Etiology—Mechanism—Symptoms and course. 1. Complete luxation—Anterior luxation—Prognosis—Therapy. 2. Incomplete anterior luxation. 3. Posterior luxation. 4. Wandering lens—Complications of lens luxation—Diagnosis—Prognosis—Therapy—Operation. 5. Laceration of the zonule and luxation of the lens in rupture of the sclera and cornea—Dislocation under conjunctiva and extrusion from globe—Mechanism —Literature.

I. INJURIES OF THE LENS.

The effect of external force upon the lens is manifested either by solutions of continuity or contiguity, and by opacification of the lenticular capsule, cortex and body; commonly both participate in the injury and its results.

A. Direct wounds and traumatic cataract.

Etiology and Mechanism. Direct wounding of the lens occurs from pointed or cutting objects and flying foreign bodies, which as a rule pass through the thin capsule into the cortex or nucleus, or even through the structure into the vitreous. Aside from these more common causes Rodenwald[1] saw a case of a farmer boy who had tried to catch a wounded heron which had struck him in the eye with its beak, producing a corneal and lenticular wound with traumatic cataract, which was removed by discission.

Talco[2] cites the case of a Russian recruit who stuck a needle in his eye, producing cataract, in order to escape conscription.

All injuries which make an opening in the lens capsule result in opacity, which is usually complete, as the edges gape, the lens fibers absorbing the aqueous, swelling, becoming opaque and finally separating from each other in layers through a process of cleavage. When the traumatism affects the posterior capsule, the vitreous acts in the same way. The operation of discission affects the lens in a like manner. In many cases of contusion it is likely that rupture of the capsule, probably in the equator, is likewise caused, but lenticular opacity may also be caused by simple concussion.

Of the traumatic opacities of the lens there appear some that are stellate and situated in the posterior cortical area. These are interesting, first, because in perforative traumatisms the foreign body need not reach the posterior zone in order to produce the cataract; second, because such a cataract may appear from injuries with blunt objects without tearing the capsule or causing a visible lesion of the zonule; and third because the opacity may remain stationary or clear up and disappear.

Fuchs[3] is credited with having done the greatest amount of original work in the study of this form of cataract. One should distinguish sharply between posterior polar cataract and posterior cortical cataract. The former is a dot at the posterior pole, and the latter a star-shaped opacity just anterior to the posterior pole. It has been rarely found following traumatism, but the author thinks it frequently is present, but is obscured by the injury of the anterior layers of the lens or by the corneal wound. It may progress until total opacity of the lens takes place, or it may clear up to a certain extent, but it never clears up entirely. It would seem, therefore, that the opacity is due to a deposit between the layers rather than to a destruction of the lens fibers themselves.

zur Nedden[4] believes that, on account of the trauma, the union between the capsule and lens is not disturbed, and the lens is pushed into the capsule. His experience with two cases of operation for myopia, in which a cataract occurred after superficial discission of the anterior capsule, strengthens his belief. He ascribes the pushing of the lens into the capsule to the "lever" movement of the needle and the diminution of the tension in the capsule by opening it with the needle. The question, "Why the union between the lens and the posterior capsule should be disturbed rather than with the anterior one?" is answered by the fact that the union of lens and posterior capsule is stronger on account of the presence of an epithelial layer anteriorly, and the absence of such a layer posteriorly.

The occurrence of a cortical cataract by the entrance of a foreign body into the lens is explained as follows: Fuchs[3] insisted long

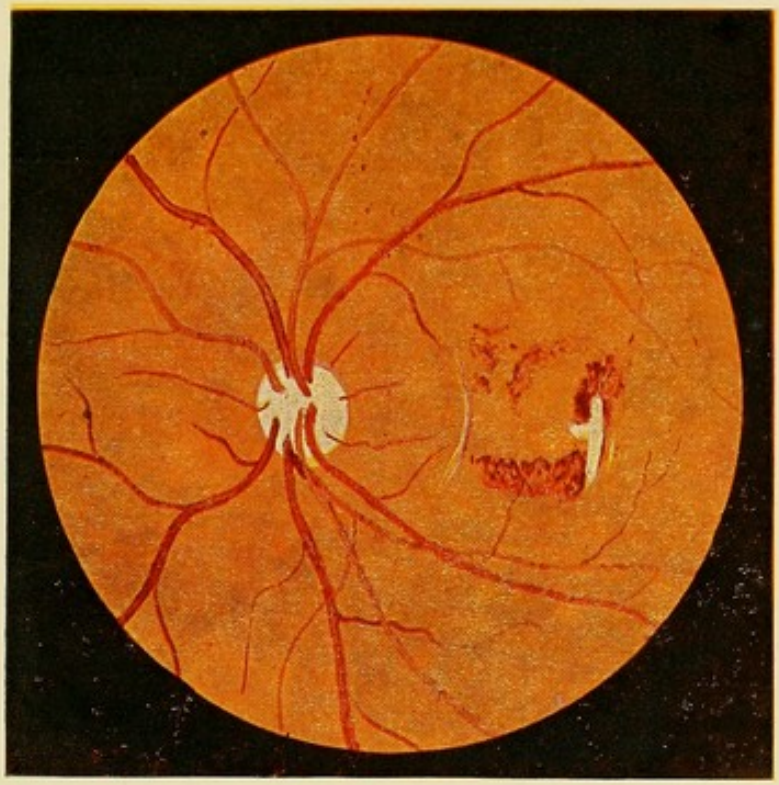

PLATE VII

Recent ruptures of the chorioid. One week after injury from end of a rope.

ago the entrance of a foreign body into the periphery of the lens produced a cataract, but here the author believes that on account of the "lever" influence on the lens, a pushing of the lens into the capsule occurs with greater ease than when a foreign body enters the center of the lens.

zur Nedden[4] reports three cases of this form of cataract after perforation of the cornea and capsule.

Koller[5] reports the case of a man 26 years of age, who sustained a penetrating wound of the cornea, with very slight injury to the anterior capsule. In six days a star-shaped opacity could be seen situated in the posterior portion of the lens. Later there was found a dot-like opacity in the anterior layer of the lens, and adjoining it a frost-like opacity of bean shape. The posterior opacity was smaller but better defined. The case was observed for five years, during which time very little change in the opacities took place.

Schmidt[6] noticed, eight days after a slight accidental cauterization of the left eye with hydrochloric acid, which had caused a transient erosion of the upper inner quadrant of the cornea, small greyish-white opacities all over the cortex of the lens. They were visible only on oblique illumination. With the ophthalmoscope the fundus appeared slightly veiled, but no distinct opacities of the lens could be discerned. V. = .07, at a later examination 0.50, when the opacities appeared larger.

I have seen several cases of piercing wounds of the lens capsule, and presumably of the lens substance, which only developed partial cataract. Quite a number of penetrating foreign bodies have likewise been observed which caused but slight and stationary opacity.

Symptoms. Fresh cases show the corneal or corneo-scleral wound, older ones the cicatrix. If the injury be in the pupillary area the wound in the capsule may be seen: if through the iris the wound may be so small in the latter that the first evidence thereof is the opacity of the lens, following hours, days, weeks, or months later. If the wound of the bulbus capsule be extensive there will likely be prolapse of the iris, and the lens may be even partially or completely extruded from the eye. If the lens capsule be greatly torn and the lenticular substance broken up chunks of the lens may be seen in the anterior chamber.

If the wound in the capsule be very small, as from a needle, none of the lens substance comes out and on first observation we note but a grayish spot on the capsule, with perhaps the line of penetration showing on oblique illumination as a grayish canal in the body of the lens and, proceeding from the latter more or less radiating lines of opacity.

Linear wounds are caused by such instruments and objects as knives and glass splinters; contused and lacerated wounds by more blunt objects, as thorns, forks and perforating foreign bodies, etc.

In fresh cases the wound canal of perforating foreign bodies may be made out, and in many instances the resistance of the lens substance is sufficient to stop their passage so that they may be retained anterior to the posterior capsule of the lens.

Course. The pupil does not respond readily to atropin, as the iris is often hyperemic, and the wounded iris adheres to the capsule of the lens. The tension is lowered so long as the wound of the ocular envelope is open, then as the lens swells it becomes increased, the tumefaction of the lens perhaps becoming so great as to occlude the angle of the anterior chamber, and the aqueous so heavy from lenticular debris that glaucoma arises.

In small wounds the process of tumefaction and opacification may be watched from hour to hour, until in a few hours to days the whole lens becomes opaque.

As early as a few hours after injury the lens substance is found cloudy in the region of the capsular wound. Some swollen lens fibers protrude through, projecting in the form of gray floccules into the anterior chamber until in some cases the entire chamber is found filled with lenticular debris. As a rule these prolapsed masses dissolve in the aqueous, are absorbed and new floccules keep protruding through the wound. At the same time the opacity proceeds into the lens substance so that in the few days the whole lens is opaque. In favorable cases the lens goes on to absorption, but in most instances the absorption comes to a stop from healing and closure of the capsular wound. Then opaque portions of the lens remain in the capsule and discission is required to obtain a clear pupil and vision.

The course of lenticular absorption varies in children from six weeks or so, to but partial absorption of the cortex in adults of over forty years; the nucleus in adults not absorbing but remaining as an obstacle to vision as a shriveled cataract.

The anterior capsule does not absorb. There is great tendency to closure and healing by proliferation of the epithelium if the wound edges are close together. When not, the cut edges of the capsule retract and curl over, as they do after cataract extraction.

The posterior capsule and the hyaloid membrane likewise have a strong tendency to regeneration, so that wounds of these membranes tend to close and heal quickly. Thus it is that the vitreous is held in place and even forced back after free posterior discission. When either or both anterior and posterior capsules remain, unless proliferation occurs, they are sufficiently transparent to offer but little obstacle to vision after the lens body is absorbed.

The opacity may be mainly capsular and partial and exist in any

part of this membrane. If the cortex be involved the opacity may first radiate from the nucleus in a star-shaped form.

After most of the lens nucleus and cortex has been absorbed or removed, as after cataract extraction, the edges of the capsule curl over, imprisoning some lenticular substance which may not become entirely absorbed, but as it is locked up behind the iris out of the pupil, offers no obstacle to a clear pupil and vision.

Complications. The irritation of the injury, and to the lens masses and iris, causes hyperemia and may lead to iritis. The course of traumatic cataract is unfavorable if inflammation or tension occurs The inflammation is probably always due to some form of infection, although Fuchs[7] and others regard it in some cases as a direct result of the mechanical injury, especially of the uveal tract. Slight inflammation of the iris may occur as the result of pressure or traction from the swelling of the traumatic cataract. This leads to proliferation of the capsule (cataracta accreta), or posterior synechia, seclusion and occlusion of the pupil, which render the relief of sight by operation more difficult. Other cases go on to loss of vision from irido-cyclitis, or of the globe from panophthalmitis.

Diagnosis. As in the case of other wounds, the character of the injury to the lens should be ascertained; its length, width and depth; whether punctured, linear, bow or sickle-shaped, lacerated, etc.; the direction from which it came and character of the foreign body or object producing the injury; whether or not a foreign body may be retained in the globe; the wound of entrance to the eye, etc., all of which have a bearing upon the character of the injury, its prognosis and treatment,

After some time has elapsed the wound of entrance through the cornea, and that in the lens capsule, may have so healed that they cannot be recognized, or are seen only on the closest examination. Such may not be recognized when in the sclera. If the wound be in the lens capsule behind the iris, the diagnosis is only made after opacification has proceeded so that it is seen in the pupil, the enlargement of which by atropin helps the diagnosis.

Iritis is determined from discoloration, slow dilatation and the presence of synechia, cyclitis, minus tension, as a rule, and precipitation on Descemet's membrane; irido-cyclitis, from plastic exudates in the pupil and vitreous. Secondary glaucoma manifests itself by increased tension, extreme pericorneal congestion, loss of vision, typical one-sided head pains, etc.

The Prognosis of traumatic cataract as a general thing is unfavorable, as most cases are complicated by inflammation of the uvea. One must, however, strongly differentiate between simple, clean, uncomplicated traumatic cataract, as produced by small wounds, being prac-

tically a traumatic discission; and complicated cases in which at least one-half the eyes lose their vision and a comparatively large percentage are lost through infection.

The prognosis is good in simple cases, particularly in children, where the lens substance may go on to absorption without operation, and a convex glass may later give good vision. It is likewise good where one or more discissions may remove the obstruction to vision. In old people, however, the lens does not absorb and even simple wounds of the lens are apt to result in irido-cyclitis and glaucoma, especially if the lens is well broken up and portions fall into the anterior chamber.

If inflammation develops the prognosis is bad, for the lens substance is a fine food for germs and the eye soon goes on to panophthalmitis.

Therapy. The treatment of traumatic cataract is both medicinal and surgical. In recent cases the first indication after antisepsis of the conjunctival cul-de-sac is atropin to dilate the pupil and to paralyze the ciliary muscle. One per cent. atropin solution should be dropped into the eye 3 to 5 times a day, or even a 5 per cent. solution may be used at first to insure dilatation of the pupil, care being taken not to poison the patient, for this strong solution saturates the system, causing atropin poisoning.

In the case of non-penetrating wounds of the eyeball a bandage should not be applied until full action is obtained; but in open wounds of the anterior chamber the mydriatic action of atropin is not secured until the wound has closed. Atropin causes increase of intra-ocular tension and thus the eye should be carefully watched and the tension estimated daily during its use.

Wandless[8] has for several years used atropin and eserin, alternately, or homatropin and pilocarpin, to hasten the absorption of traumatic and secondary cataracts, and believes that the process of absorption is very greatly facilitated and the final results much better than by keeping the pupil constantly dilated with atropin.

Dionin in 5 to 10 per cent. solutions, or the pure powder, is the most effective local analgesic, and from its lymphagogue action leads to absorption of the cataractous masses from within the lens capsule and anterior chamber, and in some authoritative instances is known to have caused clearing of a lenticular opacity.[13] It gives an analgesia of from three to 24 hours with each application. For the first few instillations it produces great chemosis of the conjunctiva, and with this much speedy absorption of intraocular exudates, but this reaction is soon lost, so after a few applications but little lymphagogue action is observed.

A protective bandage should always be put over the wounded eye, and in large wounds over both, to protect from external infection, from

light and to keep it quiet. The 1:3000 sublimate salve and the argyrol treatment are effective antiseptics.

Iced applications immediately after the injury for the first 24 hours, applied over compresses wet with 1:5000 sublimate solution, reduce the immediate swelling of the tissues and the tendency to infection. The artificial leech may be applied on the temple for the same purpose. If iritis or irido-cyclitis arises we endeavor to combat this by hot compresses and mercurial subconjunctival injections. If tension increases operative treatment must not be delayed beyond 24 hours.

Paracentesis of the anterior chamber may then be made, preferably by a fine von Graefe knife—if there be no lens masses in the anterior



Fig. 299.

a. Clear substantia propria corneæ. b. Clear anterior chamber. c. Lymph formation over anterior layers of iris. d. Infiltration of iris tissue. e. Lens capsule. f.Cataractous lens.

chamber. If, however, the anterior chamber becomes filled and tension rises then linear extraction is indicated up to the age of 35 to 40 years, when nucleus formation begins, and then regular flap extraction may be preferable.

Operative Discission. As the danger of prolapse of vitreous must ever be borne in mind on account of accompanying rupture of the suspensory ligament, which complication is not always easy to recognize, but which is particularly to be remembered, especially in cataract from contusion, as the vitreous infallibly forces itself into the corneal incision, a cataract of this nature should, if possible, be dealt with

by the operation of discission with two needles without making any corneal cut. The discission wound in the capsule should be small so as to prevent escape of a large quantity of lens substance into the anterior chamber causing the development of glaucoma. The operation may have to be repeated in two weeks to two months, and perhaps several operations may be necessary. Although this method is slow it is safe and sound.

For children general anesthesia is necessary, for adults cocain anesthesia is sufficient. The preparations are the same as for cataract extraction. Although the operative wound of the cornea is a mere perforation and seems trivial, yet the complications and infections from discission are quite as frequent, and of as great importance, as those from the major operations.

Dilatation of the pupil by atropin is first secured in order to avoid wounding of the iris. The spring speculum, lid-holder or assistant's fingers open the lids, the operator seizes the ocular conjunctiva near the limbus at the nasal side by fixation forceps, pierces the cornea perpendicularly with a Bowman or Hays stop needle, preferably at a point a little below the horizontal meridian and 3 mm. from the temporal limbus or just at the limbus, carrying the point of the needle into the anterior chamber, then depressing the handle of the instrument, passing it farther into the eye until it pierces the lens capsule, passing a millimeter into the body of the lens. By slight rotary movement the lens fibers are cut and then the needle is withdrawn quickly so as to prevent escape of aqueous humor, which would flow alongside of the shank of the needle if withdrawn slowly.

On a second operation the needle may be rotated and moved about in the cataract, the cornea acting as a fulcrum. On a third operation, or where a thickened capsule is to be divided, the needle may have even freer movement, and here the knife-needle of Knapp is to be preferred. Personally I prefer the operation with two knife-needles, fixing the cornea with one, dispensing with the fixation forceps, and piercing the lens with the other at the first operation. At subsequent operations both knife-needles enter the lens and with the cornea acting as a fulcrum the needle ends are carried away from each other, thus dividing the lens substance and the capsule. The lens being held on both needles, any pull on the zonule and ciliary body is thus obviated.

For division of the capsule I have often entered a very fine von Graefe knife into the anterior chamber, in the opaque corneo-scleral margin, depressed the handle, passed the blade of the knife almost parallel to the surface of the iris into the pupillary membrane above, and with an elevation of the handle depressed the blade and with a slight sawing

motion out perpendicularly, or in the arc of a circle, downwards through the membrane without any traction upon the ciliary body.

The after-treatment is a light occlusive bandage, atropin and argyrol. In the case of young children the arms must be bound to the sides to prevent handling of the dressings and possible infection.

The eye must be dressed once a day and carefully examined for increase of tension, which portends glaucoma, and, if the lens substance is not well broken up, necessitates paracentesis with a Graefe knife alone, as above described for discission, without however, again touching the lens.

If the tension rises and masses of lenticular debris are seen in the anterior chamber, either after the primary trauma or after a discission, then so-called linear extraction is performed, the eye being anesthetized and fixed as in the foregoing.

A keratome is introduced into the anterior chamber, preferably in the temporal portion of the cornea, between the margin and the center about the edge of the dilated pupil so as to make a vertical incision 4 to 6 mm. in length, the extremities being at equal distance from the center of the cornea. The keratome passes through the cornea perpendicularly to its surface, then the handle is depressed and the point passed in so it pierces the lens capsule, entering well into the body of the cataract. After the keratome is withdrawn the spatula depresses the periphery of the wound and may enter the eye for light currettement of the lens matter, which flows with the aqueous out of the corneal wound. Where large and hard masses do not come out forceps may be introduced and these seized and withdrawn. The Teale suction apparatus is helpful. The Lippincott and other irrigators, the Elwood or Todd wash bottle, undine or small medicine dropper assist in removal of cortical masses. I have found the latter a most useful instrument at this stage, for it may not only be used for irrigation but for suction as well. Slight pressure with a curette, forceps, or the fingers on the limbus near the corneal wound causes it to gape and let out the lenticular débris.

The anterior chamber may also be opened at the lower, temporal or upper border of the cornea, preferably by the wide von Graefe knife instead of the keratome as above described, thus making a flat or moderately-curved incision.

If the iris prolapse, as it usually does during the evacuation of the lenticular débris, it should be replaced by gentle use of the flat spatula. If a tendency to prolapse again be observed a small iridectomy is allowable. The after-treatment is the same as after ordinary cataract extraction.

In persons beyond 45 years of age who acquire a traumatic cataract, the regular three-fifths corneal circumference flap extraction with a con-

junctival flap is indicated, and where there is evidence of rupture of the zonula the Kalt bipedunculated flap should be made after an incision of three-fifths of the clear cornea at the upper limbus; for at this age, and after, the nucleus is hard and large, it will come freely out of the capsule so the operation is practically the ordinary form of extraction.

As a rule iridectomy should not be made in traumatic cataract unless the iris insists on prolapsing, as there has already been sufficient damage to the tissues from the trauma.

These methods require great care not to rupture the zonula or posterior capsule, thus causing escape of vitreous into the wound.

Colin Campbell[9] gives the following as a procedure that saves prolonged irido-cyclitis or thickened secondary membranes after cataract extraction with iridectomy when we are so unfortunate as to have the capsule in the wound. The wound is opened a few days later to introduce Lang's knife from the opposite periphery of the cornea and sweep around so as to divide the adhesion. A Saunder's needle with blunted point (after using a sharp Saunder's to make the puncture) does not possess the objectionable shoulder and conical shaft of Lang's model, and may be used in preference.

In the cataract of sympathetic ophthalmitis no operation should be attempted on the sympathizing eye until all acute symptoms have subsided for several months, for any attempt to perform an iridectomy, to open the pupil, to extract or divide a cataract, or even to do a paracentesis of the cornea or a sclerotomy, even if successful at the time of operation, will be followed by accentuation of the symptoms and increased inflammatory exudation with reclosure of the pupil.

After a sufficient time, a year or eighteen months, has elapsed, and if, during that interval, there has been no recurrence of inflammation, the intra-ocular tension has not diminished, and the patient's perception of light be satisfactory, operative interference may be considered. Cases in which the sympathizing eye has become quiet, with almost complete posterior synechia, pupil occluded, vision = perception of light, projection good, tension normal or slightly below normal, the exciting eye is not a factor where cataract has formed in the sympathizing eye. The tension is plus and increasing (secondary glaucoma); projection still good; the inflammatory process in a subacute stage, the exciting eye is now a factor.

Should operation be resolved upon the iris should, as far as possible, be let alone. The lens must be got rid of, either by needling in the manner suggested by Critchett, or, in more favorable cases, by drawing it off with a curette after the toughened capsule has been divided with a knife. Once the cataract has been removed, an iridectomy may open up the pupil sufficiently to allow light to enter the eye, and enable the patient to

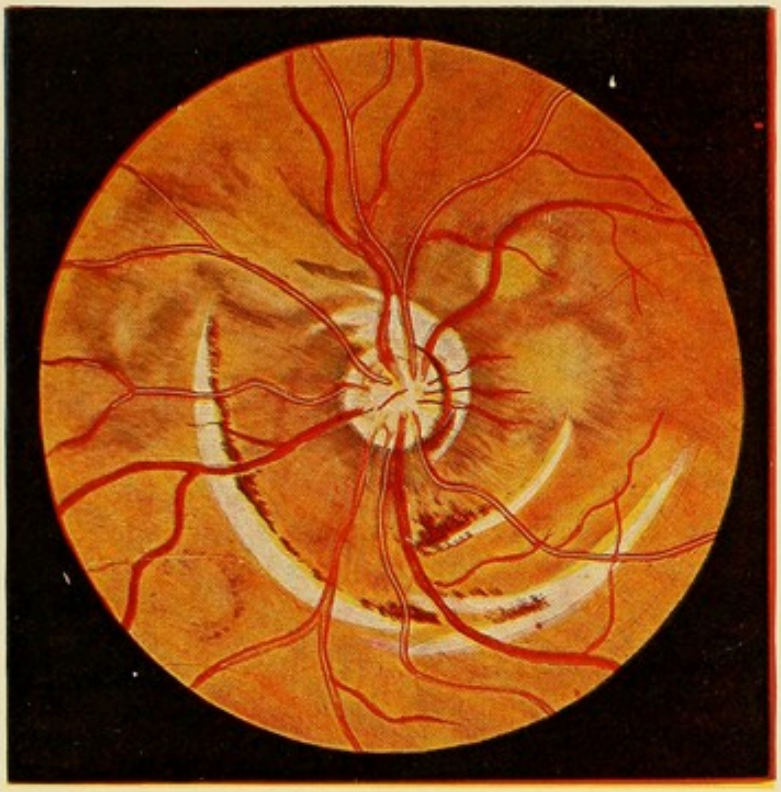

PLATE VIII

Ancient multiple ruptures of the chorioid, atrophy of optic nerve, atrophy and pigment degeneration of the retina, three months after injury from cow horn.

see as well as the damaged state of the retina will permit. In operating on such eyes, it must always be remembered that the vitreous is quite fluid and escapes readily, therefore it is important that all incisions be as small as possible and made wholly in the cornea. After operation the eye must be carefully bandaged and the patient kept quiet in bed in a dark room, while the local application of ice and the administration of sedatives will do much to prevent the occurrence of inflammatory reaction.

In sympathetic soft cataract Hirschberg[10] makes an operation consisting of section of the lower limbus, and, carefully avoiding the iris, removes the capsule with the four-toothed forceps. The pupil at once enlarges and lens matter oozes, which is removed partly by irrigation, partly by outward pressure.

In another case Hirschberg cut the capsule with Knapp's knife, which had to be repeated, as the lens matter was not sufficiently removed by the first operation. If in such cases the pupil should again close, Hirschberg advocates opening with Knapp's knife through the iris. He considers this preferable to the method of Wenzel, in which the cataract knife penetrates cornea, iris and lens.

Borghetti[11] makes a sclero-corneal incision with a Graefe knife on each side, leaving a bridge of cornea above and below. The iris is cut all along this incision close to its base, leaving a bit of it at the top and bottom. The lens is now needled or its elements disintegrated by pressure. The next day the capsule is removed and the lens is removed by suction.

LITERATURE.

1. Rodenwald, *Inaug. Dissert.*, Kiel, 1896.
2. Talco, *Klin. Mon. f. Aug.*, 1892, p. 403.
3. Fuchs, ref. z. Nedden.
4. zur Nedden, *Wien, Med. Woch.*, Oct. 15, 1904.
5. Koller, *Ann. Ophth.*, Jan., 1905.
6. Schmidt, *Zeitschr. f. Aug.*, xxiii, March, 1910, p. 241.
7. Fuchs, *Textbook*, Duane Ed. p. 345.
8. Wandless, *Arch. Ophth.*, May, 1910, p. 247.
9. Colin Campbell, personal communication, 1910.
10. Hirschberg, *Centralbl. f. prak. Aug.*, 1905, p. 97.
11. Borghetti, *Ann. Ophth.*, Apr., 1908.
13. MacWhinnie, *Ophth. Record*, May, 1910.

B. FOREIGN BODIES.

Etiology. Flying foreign bodies projected with sufficient force to pass the cornea may also pass through the pupil or iris into the lens and be stopped therein by the anterior capsule, body of the lens or its posterior capsule. These are usually iron, steel or copper splinters and are frequently observed; more seldom wood, coal, glass and other particles; powder grains may lodge therein, but shot pellets are rare.

Milliken[1] and others have described shot pellets in the lens. Post[2] described glass in the iris and lens. Spierer[3] described a case of a splinter of bone in the lens.

According to the freeness of the body from infection, and its chemical qualities, foreign bodies may remain in the lens for a long time

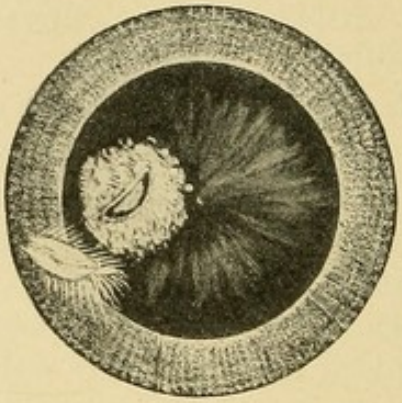

Fig. 300.
Steel chip in lens capsule; partial capsular cataract; scar in cornea.

without causing reaction, and in a few instances produce but little opacity, but as a rule complete cataract ultimately occurs.

I have seen several instances where a foreign body has remained in the lens for a long time without causing full opacity. In these the wound of the lens capsule must have immediately coapted and healed, not

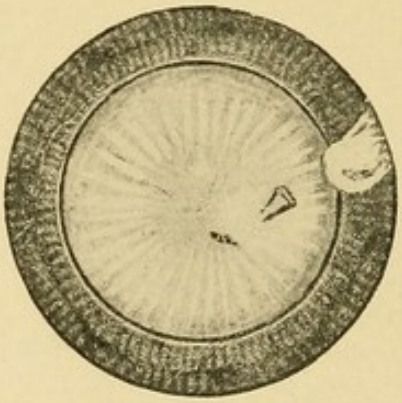

Fig. 301.
Steel chip in lens; total lenticular opacity; scar in cornea.

allowing the aqueous to enter and cause swelling and disassociation of the lens fibers.

A man was chipping and a small piece of the hammer flew off and entered the eye, one year before he came to me for correction of his refraction. A glistening piece of steel in the body of the lens was observed. This was allowed to remain. V. = full 6/vi with correction.

One of my powder explosion cases carried as a memento for many

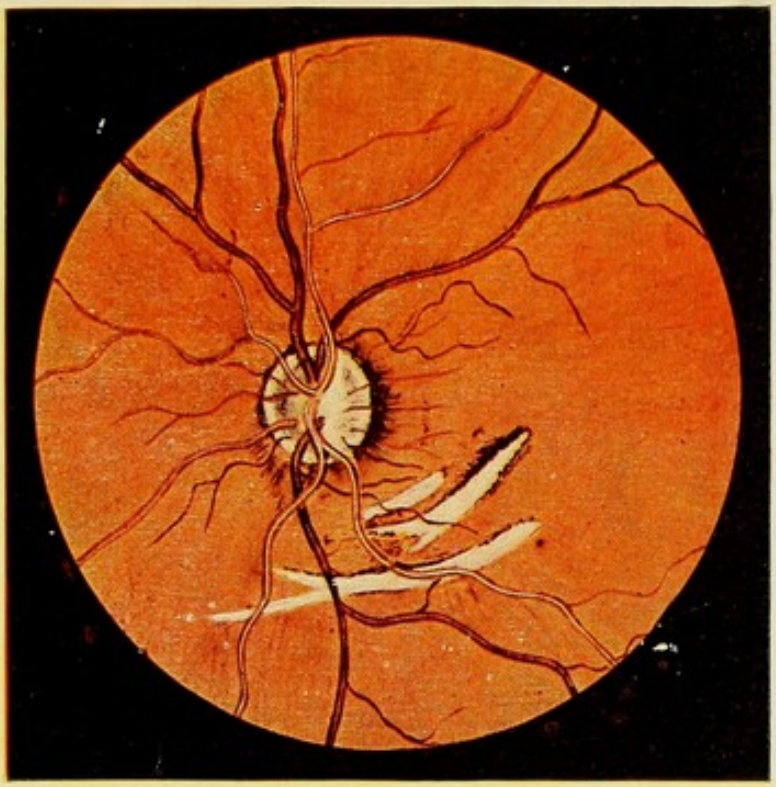

PLATE IX

Recent multiple ruptures of the chorioid. One month after kick from horse on eyebrow.

years not only a tattooed countenance, but also carbon marks in the cornea, lens capsule and one in the body of the lens, without reduction of vision.

Marx[4] says in most cases of injury of the lens by a piece of iron, without traumatic cataract, a more careful examination reveals a more

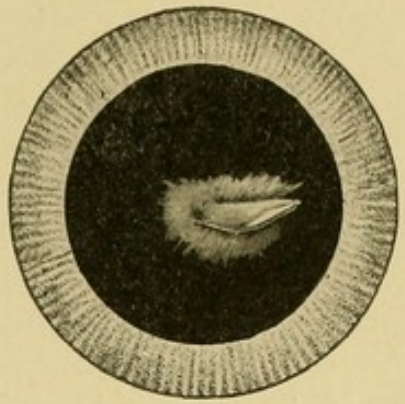

Fig. 302.
Steel chip in lens.

or less partial opacity of the lens, with perhaps two exceptions, the cases of Desmarres fils and Laquer. Marx claims exactness for his case, as it was examined with all possible diagnostic methods; two days after the injury a piece of iron in the lens was diagnosed with sideroscope and focal illumination. The eye was very much inflamed. At the wound of

Fig. 303.
Iridic prolapse and prolapse of swollen lens tissue into anterior chamber.

the lens there was a posterior synechia and an accumulation of pus. The piece of iron was extracted with Volkmann's giant magnet by the same way it had entered. The next day a slight gray opacity was visible at its former seat, which could not be recognized after 24 hours. Three months later the lens was clear but showed irregular refraction at the place of injury.

He assumes that after the injury the capsular wound was closed and by the coagulation and the adherent iris a firm wall was established against the entrance of aqueous. After the magnet extraction an immediate closure by fibrin from the aqueous must have followed.

While such a favorable result of injury of the human lens is extraordinarily rare we find that in animals, especially the rabbit, frog, fish, birds and goat, the lens as a rule reacts to injuries with the formation of slight or partial cataract.

Nottage[5] reports a case of a foreign body remaining in the lens for 32 years. V. = 6/xviii. The man was struck in the eye by a piece of steel in 1866. In 1899 the foreign body appeared against the posterior capsule, showing clearly on front or side illumination as about 1/6 the diameter of the lens in length, with only a light cloud of opacity in the shape of a crescent and parallel to the circumference of the lens.

Bruner[6] reports foreign body in the lens. Removal. Recovery without increase in the opacity. Man, aged 39 years, consulted him April 6th, 1903, with the history that 12 days before, while he was working with a steel hammer, a small chip of steel hit him in the left eye. He did not think it penetrated the eye, there was not much pain but the sight at once became blurred, and ever since the eye has been slightly reddened. Examination showed very slight ciliary injection, a small linear scar in the cornea below the pupillary area, some lens material in the anterior chamber, the iris normal, lens partially cataractous. Vision equalled fingers at two feet. When the pupil was dilated with a mydriatic, a small piece of steel could readily be seen with metallic reflex in the posterior portion of the lens below the center. Operation was advised, though this did not appear particularly urgent on account of the location of the foreign body. Under atropin the pain entirely disappeared and the redness became less, while the lens material in the anterior chamber began to absorb. Operation, however, was advised, and four days later, under hospital care the Haab magnet applied to the cornea drew the steel into the anterior chamber. A small incision with a Graefe knife was then made at the limbus and the tip of a Hirschberg magnet, introduced just within this opening, readily removed the steel. Recovery was prompt and uninterrupted. A month later vision in that eye was 3/xxxxv; and three months later the condition of the eye was the same without any increase in the lens opacities.

Bruner also reports a case of foreign body in the lens without the patient knowing he had been injured.

Laquer[7] reports two cases with fragments of glass in the lens. In the first instance the foreign body remained inactive for three and one-fourth years. Then cataract slowly developed, taking three years to become ripe, and then only after preliminary iridectomy and discission.

A successful linear extraction was performed. In the second instance the splinter of glass had entered through the sclera and ciliary body into the posterior part of the lens. Nearly a year later V. was normal and no change had occurred in the lens. The patient had had monocular diplopia for several months. The accommodative power of the eye was 2 D. less than its fellow. The author believes the late changes in the lens in the first case to have been due to chemical processes. He points out that glass is more soluble than it is commonly thought to be, and he believes that the sodium silicate was gradually dissolved and freed and in the course of years caused a general opacification of the lens.

Symptoms and Course. Most foreign bodies entering the lens do so through the pupil; those passing through the iris are noted elsewhere. The corneal wound will be noted in fresh cases, otherwise the cicatrix. After months or years the latter may with difficulty be observed. The aqueous has escaped and the anterior chamber is empty in recent cases, but if the corneal wound be small it soon closes and the chamber is restored. In these cases irritation is slight and iritis may not develop. The particle may usually be seen by the ophthalmoscope and diaphanosocope. Particles piercing the lens through the iris damage that structure and cause hyphemia and iritis.

Large foreign bodies break the lens up, cause immediate swelling of its fibers and falling of cortical masses into the anterior chamber. Where such occurs the foreign body may not be visible, except by the X-ray. If the entrance be by way of the ciliary body the damage to the eye is great and inflammation is apt to quickly occur with resultant danger of sympathetic ophthalmitis. The foreign body itself causes little irritation if enclosed in the lens and may be, as before noted, encapsulated and even cause but little opacity. Of course vision is immediately affected by the foreign body in the lens, becoming reduced to perception of light as the opacity progresses.

Complications. The main danger to the eye is iritis and irido-cyclitis, aside from infection and chemical reaction of the intruding substance. From these sympathetic inflammation may occur.

Praun[8] states that isolated infection of the capsular wound through pus cocci, carried in by the foreign body, may occur without the wound of entrance being infected.

Diagnosis. The diagnosis of foreign bodies in the lens is made by the history; the wound of entrance through the cornea, or corneosclera; the lens opacity and resultant loss of vision; by seeing the object itself under direct or focal illumination assisted by magnification; by the ophthalmoscope and diaphanoscope.

The parallactic displacement in ophthalmoscopy, the X-ray and the sideroscope, give an idea of its localization, change in position of the

foreign body in movement of the head and its movement under careful use of the magnet for diagnosis, and the sideroscope will explain its character if it is magnetizable.

Iron particles usually cause a change in the color of the lens, producing siderosis from rusting of the metal. Ocular inspection of the broken tool or material with which the patient was working may give some idea of the nature and size of the object.

When the lens masses have been extracted and no foreign body found, the Berlin blue reaction on the extracted material may show the presence of iron in solution, and then the foreign body has probably been left in the eye. Particles of iron in the interior of the eye may cause a central scotoma.

Prognosis. The prognosis is good if the foreign body be peripheral and become encapsulated without causing central opacity, which blinds the eye. This seldom occurs except in the case of particles of copper which, strange to say, are well tolerated by the lens, yet cases of steel and iron have been observed, as heretofore cited, which did not cause siderosis or progressive cataract. Siderosis from iron, however, usually occurs, and the opacity progresses.

If complicated by injury to the iris and ciliary body, the prognosis is not good for reasons explained under complications.

Weidmann[9] lost the eye in 30 per cent. of his series of cases of foreign bodies in the lens. Praun[8] says the percentage of cures is not a large one and thinks that at least one-third of these cases are lost from infection or irido-cyclitis.

Therapy. If a copper, stone, or other non-magnetizable body becomes imbedded in the lens and is well tolerated it may be allowed to remain until the lens has become opaque and then should be removed together with the cataract. But if the foreign body is of iron or steel it is better to extract it as soon as possible by the magnet, and then extract the cataract later.

If the steel splinter be loosely impacted in the lens capsule a peripheral corneal incision and the entrance of the tip of a Hirschberg or extended Victor magnet may be made into the anterior chamber upon withdrawal of which the chip will adhere and be removed thereby, or the Haab magnet may be used. If the wound of entrance be large it may be further enlarged, although where nature has already repaired the entrance wound by closure it is preferable to make a new clean incision, as this may usually be made nearer the foreign body than the wound of entrance. The magnetized lance may also be used with "safety, exactitude, and elegance." If the foreign body be more deeply impacted the large Haab, or the Victor, magnet may be used and the foreign body withdrawn with less danger of further rupture of the lenticular capsule.

If the lens be greatly swollen it may be removed, as previously described, at the same time; but as a rule the cataract is to be dealt with later. For fuller description of the magnet operation for non-magnetizable bodies see other sections herein. Iridectomy usually has to be made in these cases but should be avoided if the iris is not damaged and does not tend to prolapse.

A man came with the history of having a chip of steel fly in his eye from the end of a wire, several days before, and a small chip of steel was made out in the lens, its end protruding into the aqueous, the wound of entrance in the cornea being scarcely visible. Corneal incision, entrance of tip of Hirschberg magnet attracted and removed object. Good healing and V., one month later, 6/xii with but slight capsular opacity.

A man was injured in the right eye by a chip from a hammer while driving a nail. A small sclero-corneal cicatrix, treated for three weeks thereafter, and as the oculist had no large magnet, nor access to X-ray outfit, the patient was sent to me. Pupil dilated and no foreign body visible to inspection, focal illumination or ophthalmoscopy, but the trans-illuminator showed a shadow proceding from behind the iris, which was corroborated by the Röentgen ray as a foreign body, and also by the magnet at time of operation, for the iris visibly moved when the eye was brought within the magnetic field of attraction. The substance was extracted by corneal incision and the large Victor magnet, not entering the eye. V., one month later, 6/xviii, the lens only partially opaque.

In the case of a farrier who had a spicule from a hot horseshoe enter the eye, the lens was already cataractous and was removed by a large corneal incision after a chip of iron had been taken out by the magnet. V. with + 10.00 = 6/xii.

In a man injured by a chip of steel from a hammer I first extracted the iron successfully from the iris with V. 6/vi, and he said his sight remained good for several years; but some five years thereafter he came to me with the lens cataractous and no vision, from a resulting irido-cyclitis.

Bruner[6] gives a case which illustrates how prompt removal of a foreign body will at times save an eye when serious infection has taken place and the eye appears doomed to loss. A man, age 37, was brought to him with the history that two and one-half days previously, while he was pounding with a hammer, a chip of steel struck him in the right eye. After twenty-four hours acute inflammation developed with severe pain. Vision, when he saw him, equaled movements of the hand. There was marked bulbar congestion, cornea was very hazy, the iris cloudy, considerable pus in the bottom of the anterior chamber, in fact he had the clinical symptoms of a beginning panophthalmitis. The small wound of the cornea had entirely healed. Atropin was instilled and he

was at once taken to the hospital. By the time he had arrived there the pupil was dilated in all directions, except up and out. Upon application of the large magnet to the eye, the iris was noticed at once to move, the pupil dilated widely and there was some movement of the pus in the bottom of the anterior chamber. The foreign body, which had been stuck in the lens, pinning the iris down to it, had been withdrawn and had fallen into the hypopion. A small incision was then made in the limbus, the Hirschberg magnet introduced and the piece of steel withdrawn. At the same time, of course, the pus was also let out. Recovery was prompt and uninterrupted, and in five days he left the hospital. Five weeks later vision of that eye was 6/xxii, there was a dense opacity in the upper outer portion of the lens and very slight cloudiness of the central portion; the vitreous was clear and there was nothing pathologic in the fundus.

LITERATURE.

1. Milliken, *Ophth. Rev.*, 1892, p. 295.
2. Post, *Arch. f. Aug.*, xxxiv, 4, p. 252.
3. Spierer, *Klin. Mon. f. Aug.*, 1891, p. 224.
4. Marx, *Klin. Mon. f. Aug.*, Aug., 1909, p. 178.
5. Nottage, *Ophth. Record*, Feb., 1899.
6. Bruner, *Ophthalmology*, July, 1907.
7. Laquer, *Arch. f. Aug.*, liii, 2.
8. Praun, l. c., p. 317.
9. Wiedmann, *Inaug. Dissert. Zürich*, 1888.

C. INJURIES TO THE LENS FROM CONTUSION.

Indirect traumatic cataract.

Besides cataract from wounds of the capsule, opacity of the lens may arise from actual contusion of its structure, both in the anterior and posterior lens capsule and in the lens structure itself. We also differentiate a cataract from tearing of the lenticular capsule.

Etiology. Blows from thrown objects, direct blows, falls and other injuries from blunt objects, more seldom spent shot or whip lash injuries, may cause either rupture of the capsule, or failing in this, sufficient bruising of the lens structure as to disintegrate its cellular arrangement and thus produce opacity. These injuries are in some cases associated with penetration of the eyeball and in some have a brownish pigmentary deposit on the anterior surface of the lens.

Mechanism. In some cases the opacity may be attributed to direct crushing of the lens structure, where the lens comes in contact with the contusing object through a wound of the cornea or sclera, in others indentation of the ocular envelopes as a sort of forcible massage, and in others through disturbances of circulation, as shown by Schirmer[1] in his experiments upon rabbits.

Schirmer likewise explains the tearing of the zonula and poste-

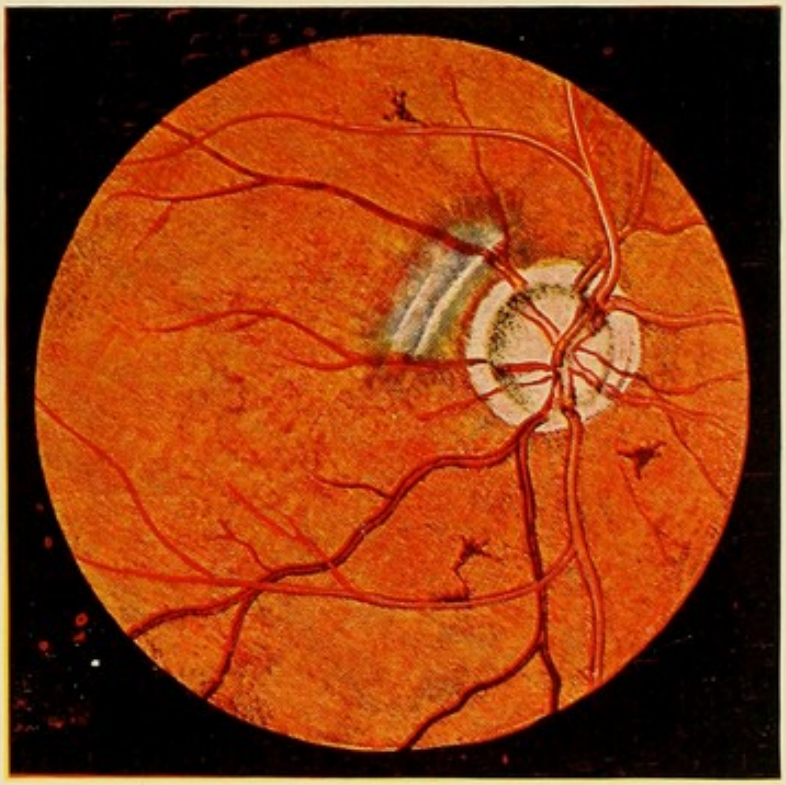

PLATE X

Recent ruptures of the chorioid, small detachment of retina. Two days after blow from fist in fight.

rior capsule by a case in which there was a strong and quick pressure on the cornea which, diminished the antero-posterior diameter of the eye the ring of the zonula tending to enlarge, and as the zonula did not break the posterior capsule stretched and broke under the pressure causing posterior capsular rupture and cataract.

In ring-shaped opacities on the anterior surface of the lens the consensus of opinion seems to be that these represent an impression of the pupillary margin on the lens. Some see the cause of them in the introversion of the cornea and the lens, others think that the iris is pressed against the lens by the suddenly increased pressure of the aqueous.

In 1903 Vossius[3] first described two cases of brownish pigmented opacity on the anterior surface of the lens which disappeared after a few weeks. He attributed this annular opacity to the impression of the pupillary margin on the anterior capsule. Most authors have accepted the explanation of Vossius.

Höeg[2] maintains from the completeness, regular form and size of the ring of opacity, and shape of injuring bodies, that the mechanism of the injury is due, not, as Vossius[3] thinks, to the inversion of the cornea, and subsequent incarceration of iris between cornea and lens, but to the pressure of the iris against the anterior surface of the lens caused by the sudden increase of pressure of the aqueous. He adopts the explanation of Vossius that the affection is due to an impression of the pupillary margin on the anterior capsule of the lens. Vossius attributes the brownish opacities to pigment, squeezed from the pigment cells of the posterior layer of the iris by the pressure of the inverted cornea against the iris and lens, and fixated by fibrin. The gray opacities are ascribed to degenerative changes of the capsular epithelia and the uppermost fibers of the lens, in accordance with the experimental findings of O. Schirmer in rabbits, after pressing the button of a probe, introduced into the anterior chamber, against the anterior capsule.

Imai[4] collected from literature 14 cases of annular opacity of the anterior surface of the lens, which are given in abstract, and reports in detail three new cases from the clinic of Prof. Vossius.

The injuries consisted in 15 cases of contusions, in two of perforations of the eyeball. Hyphema was the most common complication, viz., in 14 cases, subconjunctival hemorrhage or conjunctivitis in 10, wound of the cornea or opacity in 7, in one case in the form of stripes, in one the whole cornea was hazy, mydriasis in 5, in one irregular, rupture of the sphincter in 4, iridodonesis in 1, extravasations on the iris in 1, posterior synechiæ in 2, posterior and anterior synechia in 1, opacity of the retina in 1, hemorrhages at the macula in 1, rupture of the chorioid in 3, papillitis in 1. Dislocation of the lens was never observed.

The shape and condition of the opacity of the lens varied. It was either a complete or incomplete annular opacity, or a very fine circle, dotted or composed of fine lines, or a circular opaque band of different width at different places. Caspar observed in a case at first a disciform opacity which gradually became annular. This multiform opacity always lies in the center of the anterior surface of the lens and has the diameter of the normal pupil. In 6 cases it had a brownish color, similar to the rings left from posterior synechiæ after dilation of the pupil, but it finally disappeared. The unpigmented ring is caused, according to Vossius, by the pressure of the iris against the capsule, which produces transient degenerative changes of the capsular epithelium similar to those experimentally created by Schirmer[1] in contusion cataracts which were regenerated and became invisible ophthalmoscopically.

The annular opacity disappeared in 11 cases within from 1 to 4 weeks without traces, in one after six weeks. V. in uncomplicated cases was finally normal. Baeck and Loehlen, in their experiments on the effects of contusion on the lens, could not obtain an opaque ring on the anterior surface.

Caspar[5] reports a case in which the eye of a woman, age 29, was struck by a nail, causing a perforating wound of the cornea from its lowest point to the temporal end of the horizontal meridian, with a large prolapse of iris, and hyphemia. After the blood was absorbed, a few days later, he saw, by oblique illumination, the characteristic faintly-dotted opacity of the anterior surface of the lens, of the size of the normal pupil. but not in the form of a circle, but oval, corresponding to the defect of the iris. The case clearly showed the origin of the opacity of contusion from the impression of the pupillary margin on the lens, at the moment in which the pupil after the prolapse of the iris, had assumed the oval shape.

zur Nedden[6] observes that among traumatic opacities of the lens those involving the posterior cortex in star-shaped form must be especially distinguished with regard to their origin and course. The peculiarity consists in the fact that a foreign body having entered the lens need not reach the posterior cortex to cause them, nor is, in blunt injuries, a lesion of the capsule or zonula necessary. Frequently they remain stationary a long time, clear up without destruction of the lens substance, or disappear entirely.

He reports three cases of posterior cortical cataract after contusions and three after perforation of the cornea and capsule. They could not be due to mechanical destruction of the lens substance, since they were not in continuity with the wound of the capsule. By the recent investigations of Leber on the metabolism of the lens and the opinion of Fuchs, so far universally accepted, has become untenable, viz., that the star-

shaped opacity is due to the injection of a preformed lacunar system in the deeper layers of the lens. According to Leber no anatomically preformed canals exist in the capsule or between the lens fibers, which are cemented by a minimal quantity of interfibrillar substances, and the nutrition of the lens rests entirely on endosmosis. He thinks that the seat of the opacity immediately before the posterior capsule suggests a disturbance of the connection of the lens with the capsule by the traumatism, viz., by a slight dislocation of the lens within the capsule. The consequence will be a lesion of the mosaic epithelial covering at the posterior capsule which allows liquid to enter from the vitreous into the posterior cortical layer. Naturally the parts of the lens favored in normal diffusion, viz., the interfibrillar substance, will be mostly affected, which explains the stellar shape. Probably traumatic posterior cortical cataract occurs more frequently than thus far supposed, according to the small number of cases published. It apparently escapes observation in most cases, since it becomes invisible by simultaneous cataractous changes of the anterior cortex.

Zur Nedden has observed that this form of cataract follows discissions in operating for myopia. The author has also observed it in triturating for immature senile cataract. In both these conditions the layers of the lens were more disturbed, and yet the greatest opacity followed in the posterior layers.

Höeg[2] adds to the 12 cases, tabulated from literature, another one in a man, aged 19, who was struck by a football in the region of the left eye. After 5 days there was annular dotted opacity at the anterior surface of the lens, of 3 mm. diameter, slight opacity in the area of the ring, not visible on oblique illumination. It was complicated by sugillations of the eyelids, mydriasis, hyphemia, opacities of vitreous, whitish opacities, later extensive atrophy and pigmentations, in the upper half of the fundus. After 13 days it decreased in intensity and gradually subsided. The opacity at the anterior surface of the lens equaled exactly the former cases with this apparently typical clinical picture. It has been observed at the earliest a few hours after the injury, remained unaltered for from 6 to 18 days and disappeared in from 8 to 60 days, and has no essential influence on the sight.

Caspar[7] reports two cases which show in all details perfect similarity to the type described by Vossius. In the first case a piece of iron flew against the left eye of a man, aged 19, causing abrasion of the epithelium of the cornea, hyphemia, irregular mydriasis. The next day a gray annular opacity of 4 mm. diameter was seen at the center of the anterior surface of the lens. With the ophthalmoscope and strong convex glasses it appeared to be composed of very fine dark dots in or closely behind the capsule. The peripheral outlines were more marked than those toward

the center. The retina showed Berlin's opacity. Everything had disappeared after a week.

In the second case the opacity had the form of a disc and was caused by a contusion through a piece of wood. There was also edema of the retina. Restitution took place within a week.

Loehlein[8] reports a ring-shaped opacity of the anterior surface of the lens and papillitis after contusion in the case of a man who was struck in the left eye by a piece of iron 2 cm. long and 1 cm. wide. At the examination three days later the cornea was hazy and the anterior surface of the lens showed a ring-shaped opacity of the diameter of the pupil. Under the corneal microscope the opaque ring consisted of dots and lines in radial arrangement, and the center was also slightly opaque from yellowish-brown deposits. On account of opacities of the vitreous the fundus appeared indistinct. V.=0.2. After two weeks the ring-shaped opacity had completely subsided. There was also a papillitis, which undoubtedly was of chemical or toxic origin, as there was no perforation nor signs of infection in the anterior segment of the globe. About six weeks after the accident the borders of the disc were not yet entirely distinct, but V. was normal and the visual field almost normal.

Steiner[9] examined the eye of a young man, who, 12 days previously, had shot with a revolver into his right temple. There was no lesion of the brain, the right eye protruded, could only be moved slightly upwards, two small ecchymoses in the ocular conjunctiva, no hyperemia, pupil maximally dilated, media clear, disc diffusely red, vessels very fine, at its temporal side a chorioidal rupture, profuse retinal hemorrhages around the disc, tension normal, no perception of light. At the center of the anterior surface of the lens an opacity of the diameter of a contracted pupil could be clearly seen in transmitted light, on focal illumination only a few fine dots. Gradually the hemorrhages disappeared, but floating opacities of the vitreous developed, which were absorbed in a few weeks. At the center of the fundus a large white disc and some pigment spots were visible, in which the optic disc and chorioidal rupture could not be discerned. The annular opacity of the lens was still unaltered after three months. The bullet destroyed the optic nerve near the globe and contused the eyeball, with considerable increase of the intraocular pressure of short duration, and most likely remained in the orbit.

Symptoms and Course. In cases of opacity of the lens without tearing of the capsule the opacity may start in thirty-six hours (Magnus[10]), or not, as in Schirmer's[1] experiments, for hours, days or weeks thereafter.

In direct bruising the opacity may commence in the posterior layers

of the lens, the bruise starting with a tear in the equatorial region of the capsule; the neighboring zonule is also torn and this complication makes itself manifest by the appearance of a small portion of the vitreous in the pupil, which is often distorted and may be recognized under focal lateral illumination. The partial cataract forms a figure like a wreath at the posterior pole. The tear in the capsule usually enlarges and the lens masses come forward into the anterior chamber, as described under Wounds of the Lens.

In other cases the capsular tear closes and the opacity may remain stationary. Progressive loss of vision without pain or other symptoms, except that if the lens swells greatly or in complicated cases, is the only subjective symptom from contusions.

Diagnosis. Rupture of the capsule is diagnosed from the solution of the continuity of the capsule, followed by opacity and swelling of the lens in an eyeball without external wound, seen by focal illumination, diaphanoscopy and ophthalmoscopy. Contusion cataract developing slowly after injury is apt to be a true contusion of the fibers. Complicated cases are attended by changes in the position of the lens, color of the iris and mobility of the pupil, and by lessened intraocular pressure.

Polar figures, either in the anterior or posterior cortex, are pathogonomonic. Folds of the capsule may be seen. Equatorial capsule tears are apt to be connected with rupture of the zonule.

Prognosis. The prognosis as to vision is apt to be better than in direct wound cataract, the opacity may progress to a certain extent and then remain stationary, as the broken capsule may close. Infection is excluded and if the lens does not swell greatly glaucoma is not apt to arise. Only complicated cases where the iris, ciliary body, chorioid and retina are likewise affected by the injury, are apt to lose vision so completely that an operation cannot restore it in part.

Therapy. Atropin to open the pupil and rest the accommodation is to be ordered in all cases. Dionin may be used for its lymphagogue absorbent action. If complicated, iced compresses at first, followed by hot compresses, may be used. Cataract discission, linear and flap extraction, after full opacity of the lens, are the operative procedures.

LITERATURE.

1. Schirmer, *Klin. Mon. f. Aug.*, 1890, p. 161.
2. Hoeg, *Klin. Mon. f. Aug.*, June, 1907, p. 593.
3. Vossius, ref. Hoeg and Imai.
4. Imai, *Zeitschr. f. Aug.*, xl, p. 389.
5. Caspar, *Klin. Mon. f. Aug.*, xlvii, June, 1909.
6. zur Nedden, *Zeitschr. f. Aug.*, xl, p. 389.
7. Caspar, *Klin. Mon. f. Aug., xlv.*, Nov., 1907, p. 425.
8. Loehlein, *Zeitschr. f. Aug.*, xx, 1908, p. 364.
9. Steiner, *Klin. Mon. f. Aug., xlvii*, Jan., 1910, p. 60.
10. Magnus, *Deut. Med. Woch.* No. 3, 1888.

D. THERMAL AND LIGHT INJURIES, AND THOSE FROM ELECTRICITY.

Under the general chapter on Thermal Injuries the effects of light and electrical force upon the eye were fully discussed, noting also the lens. A few additional notes are here appended.

Etiology. The influence of the sun, and intense heat and light, is injurious to sight and causes cataract. Hirschberg[1] said that there is an etiologic connection between cataract formation and occupations entailing exposure to intense heat, as well as residence in hot climates. Of 30 men employed as glass-blowers, but 5 had reached the age of 40, and all of them had developed glass-blowers' cataract. Cataract occurs in India at an average age of 40 years, while in Western countries the average age is 66 years.

Cramer[2] says the frequency of cataract in glass-blowers has been ascribed by Meyhoefer[3] and Hirschberg[1] to the influence of extreme heat; by v. Arlt to the bright light; by Leber to concentration of the aqueous by the constant evaporation on the surface of the cornea and the intense sweating; by Peters to changes of the aqueous in consequence of congestion in the vortex veins, produced by the act of blowing. The latter view is not sustained by the fact that the glass-blower's cataract is always unilateral and that nothing similar has been observed in trombone players. There is no doubt that constant exposure to intense heat predisposes to premature cataract, as Cramer observed many cases in blacksmiths and founders at the end of the forties. They showed, however, not the least variation from the course of senile cataract, as the cataract of glass-blowers does.

There is a difference between the main features of manufacture of plate glass and hollow glass, as cataract occurs much more frequently and earlier in the latter. The red-brown discoloration of the skin of the face, also the cataract, almost always begins (except in left-handed persons) on the left side, which is nearer to the oven. The cataract starts with the formation of round opacities, more or less in a ring, around the posterior pole of the lens. By their confluence a very dark opacity of the hindmost strata in the area of the pupil develops, in which condition the lens may remain for years, while other cases may take a more rapid course. Then irregular white opacities develop in the anterior cortex, which spread peripherally until they reach the equator.

This cataract cannot be caused by the heat, as the lens is sufficiently protected by the aqueous. According to Finsen, blood and coloring matter are the greatest obstacles against the entrance of chemical rays into the skin. Both obstacles are abundantly furnished by the iris, so that, if the cause of the cataract is ascribed to the chemical rays, its first occurrence in the pupillary area of the lens, which is not protected by the iris,

is easily explained. The posterior portions of the lens are first affected, being mostly exposed by the concentration of the rays in them through the refraction of the optical system. The red-brown patches on the skin are not the result of combustion, but of pigment formation in the upper strata, which, according to Unna and Widmark, are produced by the chemical, chiefly the ultra-violet, rays, never through heat. The coarse constituents of common bottle glass are sand, carbonate of sodium and emery. The latter is a mixture of carbonate of lime and clay. Finsen showed that lime-light is very rich in ultra-violet rays, and the author concludes that the constant exposure to these, supported by the influence of heat, is the direct cause of the cataract.

The impairment of vision is usually very great (1/10), on account of the opacities forming in the pupillary area, so that the desire for operation in these people is very strong. Cramer advises flap extraction of the lens, and warns against artificial ripening of the cataract, according to Foerster, or with iridectomy, on account of the diminished elasticity and greater frailty of the capsule found in glass-blowers.

Cramer did not see dacryocystoblennorrhea and ozena in glass-blowers, which is like a racial peculiarity of that portion of our population. He attributes this to the germicidal influence of light, proved by Finsen.

A volume of water 7 mm. thick lets through only 8 per cent. of the rays of heat. Cramer, therefore, suggests, for protection, boxes of strong glass, filled with water and tunnelled by the tube with the glass material. The water must be stained with fuchsin for better recognition of the glass mass around the end of the tube.

Simeon Snell[4] refers to articles which have been published at different times, chiefly in Germany, asserting the frequency of cataract among glass workers and connecting this with the powerful heat and sweating to which their work exposes them. He had previously doubted the connection, since, if the extreme heat and consequent loss of moisture were regarded as sufficient cause for the production of cataract, then it should be found especially among iron and steel workers, and his experience has not shown this to be the case. Reference also is made to a paper which appeared in the *British Medical Journal* in 1903, asserting a remarkable frequency of cataract among one particular group of men employed in glass works—namely, bottle-finishers.

The writer availed himself of an opportunity for making an investigation with the object of discovering whether or not his doubt as to the real frequency of cataract among the employes in glass-blowers' works was well founded or not. He had not only investigated the matter personally in two bottle making manufactories near Sheffield, but he also

addressed letters asking for information to fifteen different factories, receiving replies from nine firms.

As a result of all these investigations, the writer considers himself justified in the conclusion which practice in a large bottle-making district had previously inclined him—that, though, as in other trades, there are men engaged in the bottle trade who undoubtedly do suffer from cataract, and who come under treatment for it, there is not sufficient evidence to show that they are liable to the affection to such an extent as has been asserted.

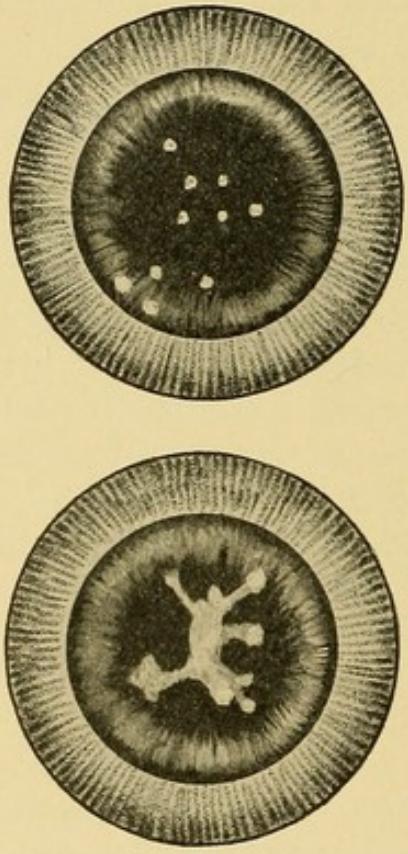

Figs. 304-305.
Electric cataract.

In cataract produced by lightning stroke, and by the commercial current, a review of the incident literature shows that in some cases the opacities were absorbed. The opacities occurred after a few days or several months. So far the action of the electric current has not been explained. It may be traumatic, producing a concussion of the lens, or electrolytic, causing trophic disturbances with subsequent opacities. Like through lightning, which today is considered as an alternating current of many thousand volt tension and of as large a number of periods, technical strong currents may produce opacities in the lens. In most cases the cataract has been partial and non-progressive. I have seen only one in which it was complete.

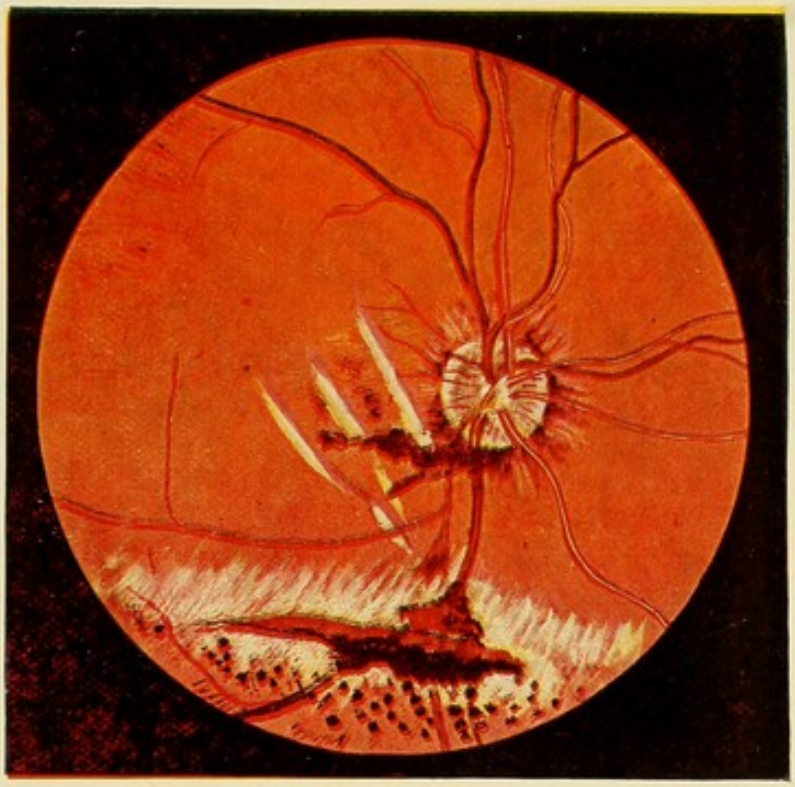

PLATE XI

Recent multiple ruptures of the chorioid, recent vitreal hemorrhages, peculiar partial rupture and detachment below with pigment migration. Two weeks after blow from whip lash.

Bistis[5] reports a cataract from electric stroke in a man, aged 55, who fell with the right superciliary arch on the negative rail, with his body on the positive rail of the electric railroad charged with a current of 500 volts. He was unconscious for three hours, but noticed no visual disturbances until a month later. These were due to changes of the lens; numerous dust-like opacities in the anterior and posterior strata. The milky cataract had become total after four months, when extraction was performed. V. with + 12 = 6/xii.

Freysz[6] reports five cases from literature with three of his own observation. From these it appears most probable that in order to produce electric cataract, the current must pass through the individual, especially the eyeball, and the opacities of the lens are due to electrolytic alterations of the lens. In the cases of passage of the current through the patient, the place of contact always was the head; in case of unilateral cataract mostly on the affected side. A certain density of the current seems necessary to produce cataract. The first opacities occurred in from one to four months after the accident (in animals much earlier), and were at first dotted and subcapsular. In all but one total cataract developed in from four to seven months, in one case in one and one-half years. The prognosis for operation is good and V.=6/xii, 3/vi, 1, after extraction. In three cases hyperemia of iris and ciliary hyperemia were observed.

In Stillson's[7] case, also seen by me, the cataractous opacities were incomplete after four years. They are peculiar in being mostly capsular, arranged in dots, being a sub-epithelial albuminous coagulation followed by degeneration of the neighboring films of the cortex and penetrating the aqueous through the capsule of the lens.

LITERATURE.

1. Hirschberg, *Berl. Klin. Woch.*, Feb. 7, 1898.
2. Cramer, *Klin. Mon. f. Aug.*, Jan., 1907, p. 47.
3. Meyhoefer, ref. Cramer.
4. Simeon Snell, *Brit. Med. Journ.*, Jan. 5, 1907.
5. Bistis, *Zeitschr. f. Aug.*, xvi, 1906, p. 525.
6. Freysz, *Beitr. z. Aug.* No. 74, 1909, p. 179.
7. Stillson, *N. W. Med.*, Feb., 1907.

E: INJURIES TO THE LENS FROM FIREARMS.

Wounds. The lens is injured by perforating shots through the cornea or sclera. Only very small shot, No. 10, No. 12, or dust shot, can pass entirely through the lens leaving a wound so small that the capsule closes up immediately, and but a partial cataract is thereby produced. Unfortunate cases, as one by Fernandez,[1] have been reported where both eyes have been injured by shot at the same time. In his case the right had to be enucleated and the left had a cataract from the perforating shot.

Foreign Bodies. Shot pellets, portions of bullets and powder grains are rarely found in the lens. A few have been reported. Upon absorption of the lens the shot pellet may be found in the anterior chamber.

Contusions. Severe contusions and bursting of the lens is common after spent shot, or those propelled by moderate force, as from air-guns, bean-shooters, etc. There may be opacity of the lens without discernible lesion of the capsule. Tearing of the capsule and zonula is more often found in cases of penetrating shot grain wounds.

The German war office noted lenticular capsular injury following contusions of the eye only once in their statistics. Praun[2] states this as a curious circumstance, as indirect lesions of the eye from balls and shells are common. In this instance a piece of granite broken off by a shell struck a horse and a piece of its flesh was projected against the soldier's eye.

LITERATURE.

1. Fernandez, *Arch. f. Aug.*, x, 3, p. 307.
2. Praun, l. c., p. 326.

INJURIES TO THE ZONULE OF ZINN, AND DISLOCATIONS OF THE LENS.

(A) Wounds of the zonule.

Wounds of the zonule are direct or indirect. Direct injuries are caused by the passing of a foreign body or the direct effect of the piercing or cutting instrument at the time of the accident. The foreign body may pass through the eye or remain therein. Direct wounds of the zonule are complicated by wounds of the cornea, sclero-cornea and ciliary body through which the trauma is first applied. Through the tear in the suspensory ligament vitreous escapes into the anterior chamber and perhaps also through the external wound. There is an immediate effect upon the lens, for the tension of the zonule at this place of injury is lost and the lens at the meridian regains its elasticity, contracts, and causes a lenticular astigmatism in the meridian. Correction by cylindric glasses cannot be made, for the refraction is only changed in a portion of the meridian, corresponding to the tear in the capsule, the other parts of the lens remaining normal. As a rule opacities of the vitreous or lens and other intraocular changes appear, having an unfavorable effect upon vision. Foreign bodies may remain in this location, but usually pass through; small ones without injury to the lens itself. The tear in the zonule heals but the tension of the ligament is never so good, so some defect in vision remains. Such is seen after the Haab method of pulling a foreign body around the edge of the lens from the vitreous by magnetic attraction.

In a few cases the opening in the zonule may be visible.

Becker[1] reports the case of a 12-year-old boy who got a piece of gun cap in his eye, with a 3 mm. wound in the cornea 2 mm. from the sclero-corneal margin, and iris prolapse. Extruding iris cut off clear to the periphery and through the coloboma could be seen a sinking in of the lenticular margin (coloboma lentis artificiale) with resulting astigmia. Although the piece of cap remained within the eye five years later the function was good.

LITERATURE.

1. Becker, *Graefe-Saemisch.*

(B) LACERATION OF THE ZONULE FROM CONTUSIONS AND DISLOCATIONS OF THE LENS.

a. Relaxation of the zonule.

Myopia has been reported after contusion of the globe without other apparent injury. This has been referred to by many authors as due to a slackening of the zonular fibers.

Fuchs[1] states that such a relaxation can take place from simple elongation and loosening, or from rupture or complete destruction, and that changes of this sort may affect either single portions or the entire circumference of the zonule.

Praun[2] dismisses this assumption with the declaration that this is very improbable, as the zonule is a system of supporting fibers for making a tension on the lens capsule, from differences in the tone of the ciliary muscles, and that this is due to rupture of the muscle.

b. Partial laceration of the zonule without displacement of the lens.

If the zonule be completely torn, the tension of the ciliary muscle is taken off and the lens becomes thicker antero-posteriorly and its circumference lessened, thus increasing the refraction, bringing in the far point to meet the near point, so only one focus is possible and myopia is produced. If only partially lacerated the tension is removed at the injured meridian and less astigmatism results.

The diagnosis may be made by tremor of the iris and of the lens on movement of the head, and by the subjective testing of the accommodation and refraction. The diagnosis is certain when the lens changes in position or when from an iridectomy the defect is actually visible. The lens may remain in position for a long time until some movement of the body, such as occurs from shivering, sneezing or a fall or blow, puts it out of position, causing dislocation or lens luxation.

c. Partial laceration of the zonule with subluxation of the lens.

Subluxation may consist in the lens being tilted a little so that one edge is somewhat forward, the opposite edge backward (dis-

location ad axem); or it may be moved partially out of the fossa patellaris to the side where the ligament still holds (dislocatio ad latus).

Symptoms and Course. This is recognized from the unequal depth of the anterior chamber, it being deeper in one side and shallower in the opposite half. If the pupil be dilated, or if the displacement be marked even with the normal pupil, the edge of the lens will be seen by direct and focal illumination.

The portion of the pupil situated beyond the edge of the lens is a deep black color, the lenticular portion shows dark-gray, the lens itself reflecting some light while the vitreous reflects so little that it appears black. By ophthalmoscopy or diaphanoscopy the edge of the lens appears dark, while the red of the fundus shows through its body and through the extra-lenticular point of the pupil. The part of the pupil not filled in by the lens is highly hyperopic (about 10 D. in emmetropia) while the lenticular part shows an astigmatic variance from the normal refraction. There is usually paralysis of accommodation and if the edge of the lens divides the pupil monocular double vision occurs. The lens may remain clear, but as a rule gets opaque when the visual acuity is markedly lowered.

Subluxation generally goes into complete luxation. If the iris and vitreous remain normal the lens is apt to keep its position. Congenital disease and weakness, as myopia, fluid vitreous, etc., predisposes to weakness of the zonula and dislocation of the lens. Glaucoma from pressure, interference in the iridic angle and irido-cyclitis from injury to the ciliary body are the complications mostly to be found.

Diagnosis. While tremulous iris and lens is not a positive sign yet this condition points strongly to laceration of the zonlue. The movement of the lens is only to be directly seen when there is lenticular opacity; the pupil is usually enlarged from the trauma and hence these signs sometimes fail. If full mydriasis be produced, or when an iridectomy has been made, in some cases the torn zonular fibers can be seen.

d. Total laceration of the zonule with dislocation of the lens from the fossa patellaris. Luxation of the lens without external opening of the globe.

If the zonule be completely torn the lens will come out of the patellar fossa and pass into the anterior chamber or the vitreous. In partial luxations it remains attached to the suspensory ligament by a few strands of tissue.

Etiology. This injury is usually caused directly by blows from stone-throwing, lumps of coal and large pieces of iron, falls and blows from blunt objects. The shrinking of a hypermature cataract may cause stretching of the zonule with atrophy and thus give rise to spontaneous

dislocation, or a slight traumatism or even sneezing, bending over, etc., might dislocate the cataract and restore the vision. Indirectly the lesion happens from severe shaking of the body, as from a fall upon the buttocks or a more severe blow upon the head. Double-sided dislocation has been observed.

Mechanism. Foerster[3] showed that a blow on the front of the eye pushed the aqueous humor with it, inverting the iris so that the zonule was pressed upon and burst. Another reason must be shown for lateral blows and in severe concussion of the body. When the limbus is impinged upon the lens springs back and tears away from its support. In concussion of the head or body the lens may tend to tear away from the inertia of the blow, suspended as it is by the delicate and easily torn ligament of Zinn.

The ligament is more fragile and the lens has less support in anomalous and diseased eyes, such as in high grades of myopia, staphyloma of the cornea, fluid vitreous and congenital anomalies, as ectopia of the lens.

Vogt[4] reports 15 cases of hereditary spontaneous dislocation of the lens, occurring at the ages of 20 to 65 years in different generations of the same family for almost a century. The dislocation was spontaneous, as in none of the numerous family members had any symptoms of congenital ectopia or previous inflammatory or degenerative effects been noticed. In some cataract developed, which, however, was secondary. Myopia, according to literature, prevalent in most cases of spontaneous dislocation, was not always present. Hence, it seems that the affection may be independent of anomalies of refraction. Out of 30 male descendants 15 showed the affection; of the female, 26, only 3. The clinical histories show that the uncomplicated dislocation is a disease of itself, differing from the displacement secondary to congenital ectopia.

Williams[5] saw a woman with an old left-sided lens luxation, who also, from a blow unnoticed at the time, acquired a slight right-sided luxation. Her brother had double-sided lenticular luxation with eccentrically placed pupils.

Symptoms and Course. The lens luxates in its capsule, leaving the patellar fossa and passes either into the anterior chamber or vitreous.

1. Complete anterior luxation.

The lens shows as a round, convex, usually transparent body nearly filling the anterior chamber in front of the iris. If it be clear the pupil may be seen through and behind. The rim of the lens appears like a curved line of golden luster so that it looks like a great drop of oil in the anterior chamber. The iris is pressed backwards by the posterior

surface of the lens which is more convex than when it is in the natural position, as it is no longer kept flat by the tension of the zonule. The anterior chamber is deeper, especially below. The effect of gravity keeps the center of the lens a little below the center of the pupil and the iris shows above its upper rim, but not below. If the patient lie on one side

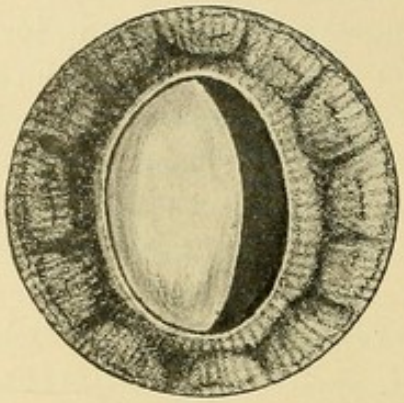

Fig. 306.
Partial luxation of lens laterally into vitreous.

the lens may gravitate to that side, but upon regaining the erect posture again seeks the former position.

Every dislocation of the lens entails considerable disturbance of vision. If completely forwards the eye will become myopic from the increased refraction; if somewhat to one side there will also be astigmia, and if a portion of the pupil be unfilled by the lens diplopia will result.

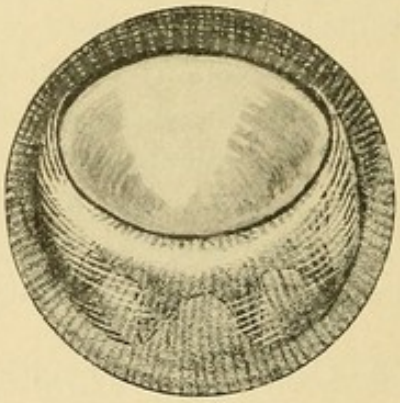

Fig. 307.
Partial luxation of lens forward and upward into anterior chamber.

On examining with the ophthalmoscope when the visual line of the observer passes through the rim of the lens, thus looking through the stronger refracting lens and the unfilled area of pupil the fundus details will be seen doubled.

Irritation caused by the prolapsed lens on the iris produces spasm of the sphincter, the pupil contracts and the return of the lens to the pos-

terior chamber is prevented. It may even happen that on account of this spasm the lens is held tight at the moment of passing through the pupil, as in Veasey's[6] case. It is then jammed in the pupil and irritation is at once set up. There are also cases where the lens may slip back and forth through the pupil (wandering lens).

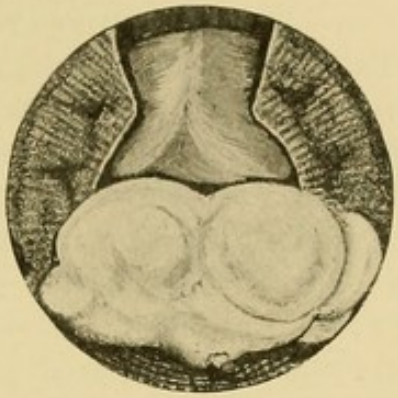

Fig. 308.
Complete luxation of discided lens substance into anterior chamber. Iridectomy.

The rule is that a lens luxated into the anterior chamber generally stays there, on account of the inflammation which it excites, becoming attached to the cornea and iris by exudates. As a rule such eyes become blind from glaucoma with formation of staphyloma of the sclera, or from irido-cyclitis. Sympathetic inflammation in the other eye has been reported.

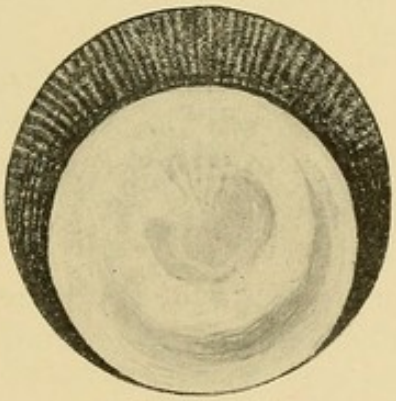

Fig. 309.
Complete luxation of clear lens in capsule into anterior chamber.

Dermett[7] reported a case occurring after 35 years with irido-cyclitis in the exciting eye. von Graefe[8] showed that partial luxation of the lens caused more quickly appearing irritation from dragging on the ciliary body than complete luxation. In a few cases of complete luxation into the anterior chamber the lens has been well borne therein.

Rampoldi[9] saw a 54-year-old man who had a fist blow upon the eye, with subluxation of a clear lens which lay against the posterior surface of the cornea. There was normal vision with —4.00, —5.00 D. but with loss of accommodation.

Elliott[10] has collected 125 cases in which the lens has been couched into the vitreous by native Indian operators. Some of the conditions in which the operation was performed misled the operators into the wrong diagnosis of cataract. For example, glaucoma, optic atrophy and retinal detachment. Thirty-two per cent. had vision ranging from 1/iv to 1/1, and are classed as successes; 8 per cent counted fingers at two feet or less, and are classed as partial successes; 68 per cent. had hand movements only, or vision nil, and were classed as failures. Seventeen of the failures are attributed to glaucoma. Imperfect dislocation accounts for 13 failures, but the greatest cause of failure was from iritis and irido-cyclitis, which numbered 52 cases. The remaining 4 cases were from detachment of the retina, vitreous opacities and optic atrophy. Thirty of these 86 cases stated that they had experienced some improvement in vision immediately after operation, but the vision was lost in from a few days to two years, with the exception of one case who retained useful vision for nine years. The author places himself on record as being unalterably opposed to this operation.

In some instances the edge of the lens shows a curved grayish line to focal illumination, or as a dark curved line to ophthalmoscopy and diaphanoscopy.

Prognosis. The prognosis is only favorable in these cases when the optical correction may be made by lenses. Tears of the zonule, like the iris, do not heal. The lens may become opaque and the laceration more complete when the lens dislocates. There is danger of glaucoma and irido-cyclitis, especially of the latter. Praun states that inflammation of the second eye may occur, but this is hardly possible except in ciliary wound cases.

Therapy. In mild cases cylindric lenses may give better vision. Iridectomy should be done where the tension raises; discission or extraction of the cataract where the lens becomes opaque. Knapp[11] recommended fixation of the lens through the cornea and iridectomy. Weak eserin or pilocarpin solutions reduce the tension, make the pupil small and give the lens the support of the iris so that it may not prolapse forward.

Schöler[12] reported myopia and paralysis of accommodation in several cases of lens luxation.

Pflüger[13] had a case where a man was struck on the left eye with a rapier, with mydriasis, tremulous iris, bleeding into the anterior chamber and vitreous. The lens was forced upwards so that the lower

edge was visible after eight weeks. The resultant astigmia was corrected by lenses.

K i p p[14] reports a case struck in the right eye by a piece of wood the day before. The left eye had been enucleated for similar injury fifteen years before. O. D. vision = 5/xxxvi, conjunctiva injected and edematous. There was a small lacerated wound at the lower inner margin of the cornea; anterior chamber shallow and well filled with blood; tension somewhat reduced; treated with cold applications. Inflammation subsided in one month, so that the discolored iris could be seen, pupil of medium size, not influenced by atropin instillations and dionin, although no adhesions. The lens was seen to be tremulous, and torn below from its suspensory ligament in and out, but still transparent; fundus not seen, due to vitreous opacities; vision improved by January 10, 1909, sufficient for house work. Lens became opaque eight months later and an extraction of the lens in the capsule was performed, resulting in 20/lxx vision with correction.

2. Incomplete anterior luxation.

If a cramp of the sphincter retains the lens part way in the passage a more or less transparent rounded object remains in the pupil, the edge

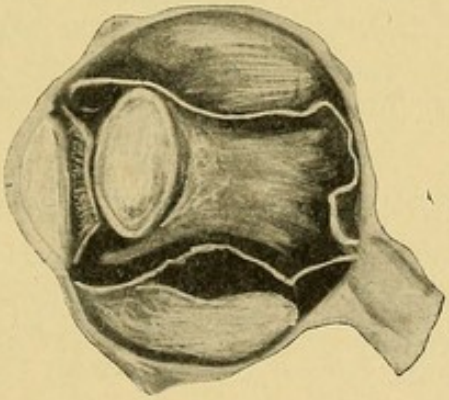

Fig. 310.
Chronic irido-cyclitis following dislocation of lens into vitreous from blow on eye by fist 20 years before.

of the lens partly in the anterior chamber, partly in the posterior or indenting the vitreous. If increase of tension and inflammation arise there is opacity of the cornea and exudation into the anterior chamber. In a few cases the condition may be tolerated for a long time, but as a rule inflammation occurs.

The lens may turn a somersault so that its posterior surface looks forwards, or, as in the peculiar case of V e a s e y,[6] the edge is forward.

A case of the former was described by R e i d e l.[15] In this the

iris lay before the lens, but the extraction showed that the posterior surface had been anterior.

Veasey[6] reports a case of traumatic dislocation of the lens from a blow with a fist in which the lens rotated exactly one-half way on its axis and appeared in the anterior chamber in this position, practically dividing the anterior chamber into halves; secondary glaucoma occurred a week later; extraction of the lens without loss of vitreous.

I can remember but one case of partial traumatic anterior dislocation of the lens which was not followed by opacification and which could be subjected to optical treatment. In this a large grain of powder had passed through the cornea and had become encapsulated in the anterior layers of the lens, the shock producing partial anterior dislocation with resultant astigmia of about 2 D., for which lens was prescribed.

In the numerous other cases of partial dislocation, cataract has followed, which has ordinarily been dealt with by discission, as most of these are juvenile. Total traumatic dislocation of the lens in my own practice has been rare. In a number of instances I have seen entire expulsion of the lens from an injured eye.

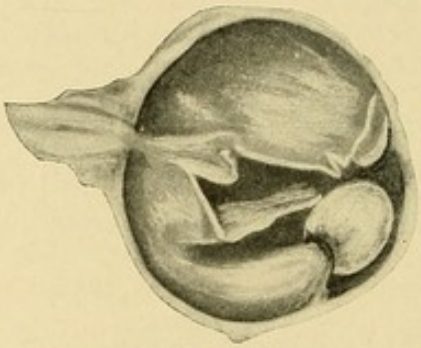

Fig. 311.
Detachment of the retina, inversion of the iris, dislocation of the lens into the anterior chamber.

3. Posterior luxation of the lens into the vitreous.

This is the commonest form of lens luxation. The anterior chamber is deep because of the recession of the iris, which is tremulous. The pupil is a pure black and the lenticular reflections of the anterior and posterior capsule are not elicited. If the lens be opaque it may sometimes be seen upon direct or focal illumination, but as a rule the ophthalmoscope is required to see it. It is usually in the lower part of the fundus, attached to some spot by masses of exudation, or it floats freely about in the vitreous (cataracta natans) and is seen to move as the head is moved. The lens becomes speedily opaque, and, in a few cases of young persons where the capsule has been torn, absorbs.

Simeon Snell[16] saw a case in which a flying piece of steel had driven the lens into the vitreous. The lens became cataractous and resorbed in one and one-half years without causing inflammation. V.=20/xxx. In a few cases the clear lens remains in the vitreous for many years.

I saw a man whose lens had been dislocated by a cow's horn injury into the vitreous five years before, in which the lens remained clear and did not cause any inflammation. V. with +11.00=6/viii.

Guepin[17] and Jaeger[18] reported such cases of 25 and 30 years' duration respectively.

Glaucoma and cyclitis, with the termination in atrophia bulbi, may here occur even after months or years of quiet, as was seen in many instances of the old method of cataract operation by depression of the lens into the vitreous.

Luxation of the lens into the vitreous is better tolerated than the forward form of dislocation.

Koster[19] treated in his clinic a 55 year old man for serious iridocyclitis of the left eye. Through the diffuse opaque cornea a lens-shaped body could just be distinguished in the anterior chamber. The right eye was aphakic and from the patient's report it was probable that also extraction lentis was tried in the left eye; the lens-shaped body was therefore most probably the lens nucleus, which became luxated in the vitreous body during the operation and now appeared in the anterior chamber. Tension was not higher. A few days later the nucleus was removed through a linear incision in the lower cornea. The eye became quiet directly; a few days later only some irritation reappeared, which soon ceased. The cornea cleared a little, but remained diffusely opaque. The patient left on May 3, 1908, with vision of the left eye, without correction, 3/ccc; the right eye had vision 2/x with + 5.

Patient had consulted some colleague in 1898 for myopia gravior and cataracta zonularis of both eyes; extractio lentis of the right eye was then done with success. In 1899 discission was done of the left lens, later linear extraction followed, but the lens slipped into the vitreous body, inflammation set in, but after some time the eye became quiet. Vision of the left eye was then with + 5. ⊂ cyl. + 1. axis 60° nas. = 5/lx, right eye with + 5. ⊂ cyl. + 1. axis horiz. = 6/xii. Most probably the eye remained quiet as long as the nucleus remained in the vitreous body; inflammation set in with the displacement into the anterior chamber. Mechanical irritation of the iris and ciliary body was the chief cause, as secondary glaucoma was absent.

The vision in the right in seven years diminished considerably from 5/x to 2/x; sympathetic inflammation was not the cause. As we have here myopic eyes, the chorio-retinitis, which accompanies progressive

myopia, will act as a cause, while the hyperemia, which with the strong inflammation in the left eye also must have been present in the right one, will also have been detrimental.

One year later, in July, 1907, vision was the same as before, in May, 1906. The left cornea had cleared considerably, light perception was good so that discission of the present secondary cataract may ameliorate the vision.

The case shows that a lens without its capsule had been well tolerated in the vitreous body during seven years, which is of importance for trying reclination, if it should be indicated; and it shows that the prognosis is not absolutely hopeless when the lens becomes luxated in the vitreous body during extraction. But a lens-nucleus in the vitreous body will always be a dangerous foreign body, so that everything should be tried to remove it, when accidentally during the operation the lens becomes luxated.

In a case in which I performed a couching operation the man only had one eye, the other having been enucleated following an accident, and the remaining one being cataractous with tremulous iris showing relaxation of the zonule and fluid vitreous. I luxated the cataract into the vitreous by posterior reclination. The man had useful vision for about two years, when detachment of the retina blotted out the light forever.

P r a u n[20] reports an unfortunate result of a blow with a stick against the eye of an eight year old boy causing luxation of the lens posteriorly. Increase of tension, scleral ectasia at the spot where the lens lay, followed. Extraction tried through the scleral ectasia, but the Weber's loop failed to find the lens. Some loss of vitreous, suture. Primary healing eight days after, increase of tension and enlargement of the globe; enucleation.

In a specimen prepared by E. C. T h o m p s o n[21] from the laboratory of the Manhattan Eye and Ear Hospital, there is a lens luxated upon the ciliary body, which had caused sympathetic irritation of the other eye. Several such have been seen in my experience.

4. Movable or wandering lens.

In some cases a lens may pass back and forth through the pupil, even voluntarily, without causing irritation. The patient can bring the lens forward into the anterior chamber by bending his head and shaking it, while to carry it behind the iris he lies on his back. In such cases the lens is always small and thus passes through the pupil without difficulty. In some instances these movable lenses are still attached to the zonule, which is then greatly elongated.

F u c h s[22] advises us, in the extraction of such lenses, to first bring them in position by an appropriate manœuvre, then to imprison them

behind the iris before making the corneal incision.

Cases where the lens shows capacity for making such extraordinary excursions are rare. Once the lens is luxated it tends to remain in the new location.

Noyes[23] reported such a case in which the refraction varied from myopia 1/9 to myopia 1/24.

Dub[24] reported a Morganian cataract which came back and forth through the pupil.

Complications of Lens Luxation. At the same time as the lens dislocation, mydriasis traumatica, dialysis, tears and inversion of the iris, rupture of the chorioid, vitreous and retinal bleeding and dislocation, but seldom lens capsule laceration, may occur.

Berger[25] saw retinal detachment with dislocation of the lens in a 35-year-old needle-woman who 19 years before had been hit in the eye with a fork. A cataractous lens was seen in the fundus, and also a retinal detachment.

Diagnosis. The diagnosis or lens luxation is made by the deep anterior chamber, tremulous iris, viewing of the whole or the edge of the lens, which, in the anterior chamber, looks like a large drop of oil if clear, or a cataract if opaque. It is readily seen in the vitreous if the latter is clear and the lens is opaque. The absence of the intraocular reflections from the anterior and posterior capsule of the lens, and the hyperopia of about 10 D., will show the aphakia. In other cases opacities of the media and the blindness will obscure the diagnosis. Contact of the lens with the cornea causes corneal opacity and perhaps ulceration.

Prognosis. The prognosis is doubtful, but practically all cases of anterior dislocation lead to inflammation and blindness if the lens be not extracted. The lens in the vitreous tends to get smaller or be encapsulated; the sight may be restored by the dislocation of the cataractous lens, but as a rule after a few years the eye is lost by chronic iridocyclitis.

Penet[26] in 12 cases of anterior dislocation saw two with visual acuity of 2/x; two with 1/1; one with 1/x, and three only quantitative vision; in four complete blindness. By luxation in the vitreous one was blind, one had light perception and in others there was V. = 1/x and 2/x.

Henke[27] in eight anterior luxations had six cases with useful vision, while two cases of posterior dislocation were unfavorable.

Therapy. All injuries causing rupture of the zonula of Zinn, producing partial or complete displacement of the lens from the fossa patellaris, are attended with commotio bulbi. They are seldom uncomplicated, particularly with rupture of the iris, ciliary body, vitreous and hy-

phemia; in fact, they are seldom recognized until the case has been under observation sufficiently long to permit of the exudated blood being resorbed, therefore, the treatment is usually that of a non-penetrating injury to the eye; rest in bed, atropin to dilate the pupil and get the edge of the iris out of harm's way before the setting up of an iritis; cold compresses to hinder bleeding and, after 48 hours, hot compresses to secure resorption of the blood clot and to relieve pain; eserin and dionin. If hypertension occurs, the atropin must be discontinued and paracentesis of the cornea may be made to let out the blood clot. If the lens be partially luxated and remain clear, optical treatment to neutralize the resultant astigmia is needed. If it becomes cataractous, this may be

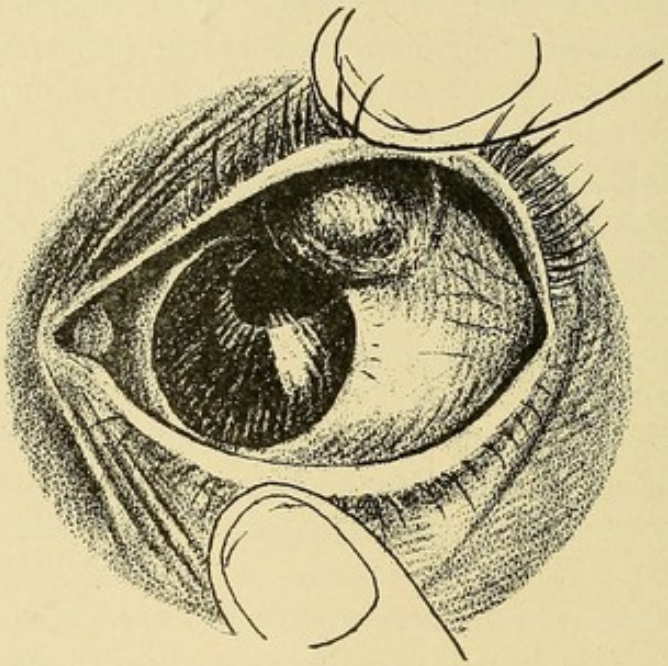

Fig. 312.
Dislocation of lens under conjunctiva through wound of corneo-scleral margin, with prolapse of iris.

dealt with by discission or extraction, depending upon the age of the patient. If at the same time there is rupture of the capsule, complete or partial absorption may spontaneously occur; if the lens swells the pupils should be kept widely dilated by atropin and the lens extracted when its swelling causes reaction. If the lens be dislocated into the anterior chamber, it should, as a rule, be extracted, although when seen early an effort may be made to reduce it by gentle pressure of rubbing over the cornea, either with or without scleral incision behind the ciliary body to diminish the tension. Extraction of the lens dislocated into the anterior chamber is attended at times with much difficulty, as on opening the cornea, it may slip back into the posterior chamber, hence, it should be transfixed by a knife needle before the incision and sup-

ported thereby, or the bident of Agnew may be used to transfix it after the incision. I have usually operated with a downward section, the patient being in a sitting position, or have allowed the head of the patient to hang over the edge of the table for the upward incision in order to facilitate the dropping out of the displaced lens.

The dressings and after-treatment are similar to ordinary cataract extraction.

Where the lens is dislocated under the conjunctiva, it may be left to disintegrate and absorb, but as a rule it is preferable to remove the foreign body by incision and extraction.

If the lens be in the vitreous chamber, it should not be disturbed unless it gives rise to irritation, when an attempt should be made to extract it through a scleral incision, but this may prove futile, especially with a freely movable or a floating lens even without very great loss of the vitreous and collapse of the eye. If inflammation takes place, it is advisable to enucleate the eyeball on account of sympathetic inflammation of the other eye.

It is a difficult operation to extract a dislocated lens, for the zonule is ruptured and allows the vitreous to present and some is always lost. Even such complicated cases as the following may, however, be dealt with successfully in skilled hands:

C. Zimmermann[28] had a man of 53 who received a blow on the left eye from the stock of a whip, wound of lids but none of globe, nasal third of iris dialyzed, cornea showed striated opacity, lens dislocated into anterior chamber, showing iris magnified. Extraction of lens by upper corneal section, slight vitreous prolapse. V. with + 10.0 = 15/cc.

5. Laceration of the zonule and luxation of the lens in rupture of the sclera and cornea. Dislocation under the conjunctiva. Extrusion of the lens from the globe.

In ruptures of the sclera several forms of dislocation of the lens may take place, the more common being extrusion of the lens from the wound, traumatic aphakia. This subject has been touched upon in dealing with Scleral Rupture and a number of instances described.

Mechanism. Müller[29] showed from anatomical preparations that the lens is torn away from the ciliary body and passes behind the iris, tearing the latter away at its root, thus making a passage for it through the posterior chamber. The lens never passes through the pupil and into the anterior chamber.

The lens capsule goes with the lens and is seldom torn. The rupture of the zonule occurs at the same time as the scleral rupture. In one case v. Graefe[8] had only a portion of the lens escape under the conjunctiva in a scleral rupture, the balance remaining in the capsule,

causing a coloboma of the lens, which allowed of a clear pupil and useful vision. Müller[29] described the same result as occurring from a cataract operation where the zonule had been torn.

In scleral rupture the lens also may be subluxated, remaining partly in the patellar fossa, or it may lie between the lips of the wound, remain buried under the conjunctiva or be entirely extruded; the latter being an accidental cataract operation which in some cases has been as successful as that made by a skilled operator. In but few cases has the lens passed backwards into the vitreous. As a rule a sector of the iris is torn off and passes out with the lens; there is in other cases a pronounced prolapse of the iris.

Luxation of the lens into the anterior chamber with scleral rupture has never been observed. Weber, Jr.[30] reported an instance where such a diagnosis had been made by three oculists, in the case of a woman with scleral rupture, and when an attempt at extraction of the supposed lens was made a bead of vitreous was found to have successfully simulated the condition. The woman recovered with useful vision.

Mercanti[31] reported a scleral tear from a fall on a bundle of wood, with incomplete luxation of the lens into the wound, the lens being two-thirds under the conjunctiva. I have seen several cases of complete luxation under the conjunctiva, one accompanying a blow from the end of an umbrella in which the sclera was torn, but the conjunctiva remained, the lens passing through the wound and being retained under the conjunctiva until removed by incision. The eye healed well with useful vision with correcting lens. Many such cases have been reported.

In several cases where the scleral rupture has been posterior the lens has passed out of the eye and been retained in the cavity of Tenon's capsule. Such have been reported by Müller,[29] Schlodtmann,[32] and others, being found in anatomico-pathologic specimens.

In most cases the conjunctiva tears, allowing the lens to pop out of the eye, so that the specimen is seldom seen by the surgeon. Praun[33] reports a case where the patient brought a mashed-up lens in his handkerchief.

Of the cases where the lens has escaped by a scleral passage, from an accident, with resultant good vision we may refer to White-Cooper,[34] Mules,[35] Szili,[36] Fuchs.[37]

Of interest are those cases of so-called spontaneous luxation of the lens under the conjunctiva where the patient has no recollection of any accident, as described by Andre[38] and Zehender.[39] In these, however, the condition of the iris showed that there must have been an accident at some time.

If the lens be not extruded, the capsule is generally being opened, it becomes cataractous and may be resorbed.

The course, diagnosis, and prognosis, as well as therapy, are those of scleral rupture.

LITERATURE.

1. Fuchs, *Textbook,* Amer. (Duane) Ed., p. 460.
2. Praun, l. c., p. 322.
3. Foerster, *Bericht. u. d. XIX Versamml. d. Ophth. Gsell.,* Heidelberg, 1887.
4. Vogt, *Zeitschr. f. Aug.,* 1905, xiv, p. 153.
5. Williams, *Trans. Amer. Ophth. Soc.,* 1875, p. 291.
6. Veasey, *Ophth. Record,* Jan., 1901.
7. Dermett, ref. Praun, p. 333, and Baudry, p. 102.
8. von Graefe, ref. Praun, p. 333.
9. Rampoldi, ref. Praun, p. 333.
10. R. H. Elliot, *Ophthalmoscope,* Apr., 1907.
11. H. Knapp, *Arch. f. Aug.,* xii, l, p. 85.
12. Schoeler, *Klin. Jahresbericht,* 1875, p. 22.
13. Pflueger, *Klin. Mon. f. Aug.,* xiii, p. 109.
14. Kipp, *Journ. Med. Soc., N. J.,* March, 1909.
15. Reidel, *Inaug. Dissert. Griefswald,* 1894.
16. Simeon Snell, *Ophth. Rev.,* 1882, p. 400.
17. Guepin, *Ann. d'oculist,* xvi.
18. Jaeger, ref. *Schmidt's Jahrb.* v., p. 380.
19. Koster, *Tydschr. v. Geneesk.,* Aug. 3, 1907.
20. Praun, l. c., p. 335.
21. E. C. Thompson, see Posey and Spiller, *Dis. of Eye and Nervous System,* p. 479
22. Fuchs. *Textbook,* p. 465.
23. Noyes, *Arch. f. Aug.* i, l, p. 134.
24. Dub, *Wien. Med. Woch.,* 1888, No. 14.
25. Berger, *Arch. f. Aug.,* xv, 3-4, p. 286.
26. Penet, *Inaug. Dissert,* Lyons, 1884.
27. Henke, *Inaug. Dissert,* Strassburg, 1893.
28. C. Zimmermann, *Arch. Ophth.,* xxii, 3, 1893.
29. Müller, *Ueber Ruptur d. Korneo-scleral Kapsel, durch stumpfe Verletzung,* Leipzig u. Wien, 1895.
30. Weber, Jr., ref. Praun, l. c., p. 338.
31. Mercanti, *Ann. di. ottal.* xx, 4, p. 365.
32. Schlodtmann, *Arch. f. Ophth.,* xliv, l, p. 212.
33. Praun, l. c., p. 339.
34. White-Cooper, ref. Praun, p. 339.
35. Mules, *Trans. Ophth. Soc. U. K.,* vii. 1887, p. 296.
36. Szili, *Arch. f. Aug.,* xxii, l.
37. Fuchs, *Textbook,* Amer. (Duane) Ed., p. 262.
38. Andre, ref. Praun, p. 339.
39. Zehender, *Klin. Mon. f. Aug.,* xiii, p. 84.

CHAPTER XXIII.

INJURIES OF THE VITREOUS.

A. Wounds and prolapse—Mechanism and symptoms—Diagnosis—Course and complications—Literature. B. Foreign bodies—Etiology—Mechanism—Symptoms—Course—Iron in the vitreous—Copper—Lead and glass—Stone—Wood—Coal and other particles—Diagnosis—History—Prognosis—Prophylaxis—Therapy—Literature. C. Injuries from contusions—Hemorrhage into the vitreous—Etiology—Symptoms and course—Diagnosis—Prognosis—Therapy. D. Gun shot injuries—Foreign bodies—Therapy—Literature. E. Infections. F. Degeneration following injuries—Opacities—Shrinking—Detachment—Blood staining—Literature.

A. WOUNDS AND PROLAPSE.

The vitreous humor is not a fluid like the aqueous, but a body composed of connective tissue cells filling in the posterior and five-sixths of the eyeball. The cells are nearly transparent, admitting and carrying the light rays to the retina.

Mechanism and Symptoms. In all deeper incisions of the capsule of the globe the vitreous is wounded, as a rule without any more serious results than localized opacity. Vitreous incisions may not be followed by bleeding, but this generally occurs, though slight and soon resorbed. Opacities are more dense and numerous after contusions. If the wound of the ocular envelope gapes, the vitreous extrudes as a clear bead. If the wound be in the cornea and vitreous prolapse succeed, the zonule must have been injured, the vitreous escaping through the pupil into the anterior chamber. As a rule the lens is likewise injured in such cases. Foreign bodies wound the vitreous in their flight to the depths of the eye.

The Diagnosis of prolapse is readily made from the appearance of a transparent bead projecting into and out of the wound. When the wound edges gape the area is dark.

Course and Complications. Wounds are followed by more or less dense opacities which interfere with vision, according to their location in respect to the visual axis, with shrinking of the vitreous, if with considerable resultant detachment of the retina and atrophia bulbi.

This condition occurs from the contraction of exudates which come from inflammation of the ciliary body, the chorioid and retina. Contraction of the vitreous body and resultant retinal detachment may also occur after wounds of the vitreous without formation of exudates.

Infection of the vitreous by pus germs leads to loss of the eye by panophthalmitis. Infection by wounds has been reported by Nobbe.[1]

The Prognosis of wounds of the vitreous depends upon the possibility of infection and the contraction of exudates. As a rule wounds of the anterior portion of the vitreous, as in discission of secondary membranes in the pupil, heal without leaving perceptible traces. Loss of over 20 per cent. of the vitreous leads to retinal detachment and atrophia bulbi.

Greeff[2] considers, with Cirincione, that true regeneration of the vitreous does not occur. He has never seen karyokinetic figures either in anatomic studies of clinical cases, or experimentally in rabbits.

The following steps follow the withdrawal of part of the vitreous: First, a provisional transudation, followed after a time by the appearance of a rich network of fibers plainly visible on the surface of the retina where they rest on a broad base, or they come from the depths of the retinal layers and also from the midst of the Müller supporting fibers. The second act is the formation of vitreous cells. They are found at the equator or at the ciliary region in more or less dense collections. They are rare in the posterior part of the eye. At times they project from the surface of the retina and are independent of the vessels. For this see also Parsons.[3]

Operations upon the vitreous are mostly confined to abscissions of vitreous prolapse by cutting with scissors, the blades being placed flat on the surface of the globe, after which the wound is closed by scleral and conjunctival suture. Injections of salt solution and of calve's vitreous for replacement of same are dealt with under Detachment of the Retina.

LITERATURE.

1. Nobbe, *Arch. f. Ophth.*, xlv, 3.
2. Greeff, *Arch. f. Aug.*, liii, 2.
3. Parsons, *Pathology of the Eye*, Vol. II, p. 429.

B. FOREIGN BODIES.

In the following the discussion is confined as much as possible to foreign bodies remaining in the vitreous itself, those impacted in the other portions of the eye being considered under the appropriate chapters.

Etiology. Particles of iron, steel, copper, stone, glass, and wood are most common, especially the metals. Shot, powder, and sand are less often seen. The great expansion of the iron and steel industries has given rise to this form of accident which, previous to our era, was much of a curiosity. With the exception of such countries as Switzerland and

France, where women work with hoes on stony land, the occurrence of foreign bodies within the eye is practically limited to men, and mostly to those in the iron and steel trades, copper and brass workers, stone-cutters, etc. Powder grains occur from explosions of fireworks, gunpowder, and from blasting, in the latter sand grains usually accompany the injury.

I have seen a number of such results after fireworks and blasting explosions, in which the powder grains or sand first passed through the cornea, lens and iris, becoming encysted in the vitreous and discernible after extraction of the resultant cataract.

In Hirschberg's[1] case nine grains had penetrated through the cornea, iris and lens, through the vitreous to the retina and rebounded from the posterior wall into the vitreous. The eye was removed on account of irido-cyclitis.

Rare objects such as portions of whip lashes, bone, wax, cilia, etc., have been reported.

The luxated lens must be considered a foreign body, as well as the occurrence of cysticercus in the vitreous.

Mechanism. Foreign bodies enter the vitreous (1) either through the cornea and pupil, through the central portion of the lens; (2) through the cornea, iris and lens, in which cases traumatic cataract is also produced; (3) through the cornea, iris and zonule, in which the body of the lens is not impaired; (4) through the sclera, with or without injury to the ciliary body.

As a rule a foreign body entering the eye with sufficient force to penetrate to the vitreous reaches the opposite inner wall and rebounds to again pass into the vitreous and remain generally gradually sinking to the bottom of the eye. De Wecker,[8] however, reports shot pellets encapsulated in the upper third of the vitreous. If coming with a little more force the foreign body may rebound sufficiently to again pass into the retina, ciliary body or lens and if with enough force it may pass entirely through the posterior walls of the globe into the orbit, as is common in wounds from bird shot.

Berlin[3] showed that splinters of metal usually richochet. In 19 enucleated eyeballs he found that the foreign body had reached the opposite wall in all cases, in 14 had rebounded, in 4 stuck in the posterior wall, and in 1 had passed through into the orbit.

Foreign bodies remain in the position left after the accident until moved by some mechanical force such as movement of the head and body, which gradually causes them to fall to the lower part of the vitreous, as the vitreous usually becomes fluid. Detachment of the retina and shrinking of the vitreous likewise dislodges them. The chemical irritation set up by foreign bodies aids in their wandering and sometimes in their complete extrusion.

Symptoms. If the foreign body pass through the central part of the cornea, the wounds or their cicatrices, will be seen if the media be sufficiently clear; one each in the cornea, anterior and posterior capsule of the lens, in a line with one another and with the wound canal or opacity in the lens showing between the lenticular capsule wounds of entrance and exit. If the splinter turn in its course it may deviate from this straight line after entering the eye, especially after leaving the lens for the vitreous, and take a parabolic course, or turn at an angle. If passing completely through the eye, the posterior perforation shows if not covered by a blood clot; upon resorption of the blood the tear in the retina and sclera will be seen by the ophthalmoscope. If the foreign body pass through the iris the opening will be seen therein, as iris wounds never close. If through the sclera the site will be marked by a blood clot, which at first fills in the wound. It may be that the shot or splinter first passed through the lid, most commonly the lower, in such cases the wound canal in which may be followed by probing.

In many cases it is impossible to determine the location of the foreign body by inspection, focal or transillumination, or by the ophthalmoscope, on account of opacities of the media, but in those where such examination is possible the foreign body may be seen by the ophthalmoscope, if not too near the ciliary region, and its location estimated by its behavior on parallactic examination. In a few cases the portion of the posterior wall from which it rebounded may be seen as a bloody spot on the retina, and its course through the vitreous be visible as a diffuse linear opacity. In some cases air bubbles are to be seen in the vitreous along the course of the foreign body. These show as little, sharply defined round spots with light centers and dark rims, and in most cases a line of blood pigment or blood will show the direction of its passage.

Subjective Symptoms. As there are no sensory nerves in the vitreous the pain and irritation, if any, is referred to the external wound or to secondary inflammation of the iris and ciliary body. The sight is affected from the injury to the lens, or if this remains clear, by the bleeding or opacities in the vitreous. If the media remain clear the foreign body may be entoptically seen by the patient.

Course. As a rule eyes entertaining such a guest as a foreign body in the vitreous go on to plastic irido-cyclitis, with loss of vision in the injured eye and possible sympathetic ophthalmitis in the fellow. In but few cases does a foreign body become encapsulated. Some, however, have been reported remaining in the vitreous for many years. Intruders carrying virulent pus germs cause acute suppuration and panophthalmitis; other less active germs cause irido-cyclitis and sympathetic inflammation. Those that cause irritation either through the gravity of the trauma, their

location or their chemical nature, produce shrinking of the eyeball, iridocyclitis, and sympathetic irritation.

Iron in the vitreous.

Infected iron particles do not as a rule cause infection of the wound of entrance, but such occurs from the conjunctiva, lids or from extraneous infection, but they begin to form abscess in the vitreous in 12 to 48 hours, which spreads, infiltrating the posterior portion of the eye and then the uvea. If the infection be of a mild type the abscess does not form but the tissues so strongly react that the foreign body becomes encapsulated. Leber[4] and von Hippel[5] both declare from anatomical examinations and the literature that a perfectly clean splinter of iron or steel never causes encapsulation. While encapsulated foreign bodies may remain in the vitreous for a very long time they sooner or later cause chemical irritation and inflammation of the retina and vitreous so that the eye is ruined thereby.

The vitreous becomes opaque, thickened, and then shrinks; the retina then detaches; in some cases a disease of the pigment epithelium of the macula with irregular spotting and pigmentation, follows on account of disturbances of circulation, described by Haab.[6] von Hippel[5] showed that degeneration of the whole retina occurs.

Hirschberg,[7] out of the large number of cases seen by him, only found two in which the particles remained in the vitreous without irritation, while there were 15 innocuous ones in the retina. Most cases of reactionless particles of iron in the posterior portion of the eye, with retention of good vision, were encapsulated in the retina.

Elschnig,[8] among others, reported such a case, where he could watch the healing process from the beginning. A piece of steel passed through the ciliary region, through the vitreous, striking the posterior wall above and outwards from the macula, rebounding therefrom and then sinking into the vitreous. It was observed to become encapsulated and caused changes in the retina similar to retinitis pigmentosa. The spot struck on the retina was referred to in the visual field as a scotoma. The visual acuity was 6/xii and Jaeger No. 2 with + 3 O. D. Such eyes, however, ultimately usually become blind through retinal disease. A marked exception, however, was a case of mine of a piece 1 m. retained in the eye.

Larger pieces of iron, with of course loss of vision, may heal in the eye and remain for years.

Castelman[9] extracted a piece of iron 30 mm. long by 5 mm. wide and 65 cg. in weight, from the eye of a man. It had entered three and one-half years before.

As a rule, however, such large pieces immediately cause severe

symptoms of inflammation so that they must be removed at once, together with the eye.

Several such cases have fallen to my lot. In a man who was welding rails a piece of the hammer flew off, causing an extensive wound of the sclera and imbedding itself in the globe. He was brought to me three days later with the conjunctiva chemotic and pus streaming from the wound. I enucleated and found a piece of steel 1.8x6 mm., weighing 75 mmg. within the globe.

Spratt[10] reports the case of a machinist who was struck in the eye by a particle from a cold chisel. Eight days later he consulted an ophthalmologist, who made an unsuccessful attempt to remove the foreign body with a giant magnet. Two days later the author was consulted who, after locating the foreign body by Hulen's method, successfully extracted it through an incision in the sclera 14 mm. behind the temporal corneal margin. At the time of the operation there was pus in the anterior chamber and cloudy vitreous. Three months later the eye had vision of 6/v. The ophthalmoscope showed a yellowish, spindle-shaped scar posterior to the macula and a little below a crescent-shaped area in the retina caused by steel. The author recommends, in all cases, that the situation of the foreign body be accurately determined, and that an incision be made at the nearest point in the sclera, through which the foreign body is to be removed with the tip of a powerful hand magnet.

I have seen several cases where after extraction of such a large piece of the eye regained more or less of a natural form and was retained.

Praun[11] reports that he extracted a 7x5x3 mm. piece of steel of a quadrangular shape from an eye 12 hours after the accident without losing vitreous. Though the eye was blinded—consent to enucleation could not be obtained. The eye healed without irritation in three weeks.

A splinter which has been tolerated for a long time in the retina, or even in the lens, from contraction of membranes may be carried into the vitreous or ciliary body and cause heavy inflammation.

Such a case was reported by H. Knapp[12] where a piece of metal had been encapsulated in the retina for six years and then fell on the ciliary body, causing irido-cyclitis, for which the eye was enucleated.

Many cases of sympathetic inflammation are reported in the literature produced by the retention of a foreign body.

Iron splinters may be spontaneously extruded from the vitreous, though more seldom than in the case of copper.

Mandelstamm[13] reports such in the case of a phthisical eye. Bull[14] one in which 30 days after the accident a piece of steel appeared in the yet opened wound and was extracted by forceps. Landmann[15] one in which 34 days after the accident a piece of iron appeared in the

opposite side to the wound of entrance and was extracted through an incision.

Dickey[16] reports a case in which the patient had been injured in the eye by a piece of steel 17 years previous to the time when the writer was consulted. The eyeball showed signs of degeneration and was painful and inflamed. Enucleation was done and the eyeball found firmly attached to the orbital tissue, in the region of the optic nerve, by dense bands of adhesions. A piece of steel, the size of a buckshot, was found lying on the floor of the eyeball in the lower anterior quadrant.

Copper in the vitreous.

Particles of copper, even if aseptic, in the vitreous, nearly always cause severe inflammation from chemical irritation, producing an aseptic purulent exudate and later thickening and shrinking of the vitreous with total detachment of the retina and irido-cyclitis, closing the chapter with atrophy of the globe after months of painful inflammation. If septic panophthalmitis, perforation, and phthisis bulbi occur.

Leber's experiments are referred to elsewhere. Kostenitsch[17] fully corroborated Leber's experiments in the main facts. The encapsulation of copper in the vitreous with retention of good vision is not often observed. Such a case is quoted on another page.

Decker[18] reported one of a small copper splinter in the vitreous for six years which had not caused any other irritation than spasm of accommodation. There was full vision and no vitreous opacities.

Cases have been reported quite often where, while the sight had been lost from plastic inflammation the eye remained quiet. Hirschberg[19] saw a chip of copper encapsulated for 10 years in such an eye.

Ruhberg[20] reported a case observed for more than 20 years where the bulb looked normal, the pupil wide and the lens clear, the foreign body being encapsulated in the vitreous.

It is impossible to estimate how long such encapsulated foreign bodies may remain innocuous without producing renewed inflammation and sympathetic ophthalmitis in the other eye.

A number of cases of spontaneous extrusion of a piece of copper from the vitreous have been reported, this occurring from copper far more often than in the case of iron and other foreign bodies.

Spechtenhauser[21] says that this occurrence is due to late development of infection, the copper salts forming from contact with the fluids of the eye, setting up an inflamamtion and letting loose the germs which had been locked up by encapsulation; the copper salt acting in the uveal and scleral tissues and softening them so that the foreign body extrudes at this point.

Leber's[4] experiments show that copper need not carry sepsis in

order to produce pus, and that extrusion of the aseptic foreign body from the eye is not commonly a septic process as in other parts of the body.

Praun[22] cites the case of a piece of percussion cap in the vitreous of a 12 year old boy, in which at the first dressing he could not find a foreign body. Irido-cyclitis followed. Nine months later the boy complained of a foreign body sticking in the eye and a dark object was seen protruding through the sclera, which, on removal, was found to be the original foreign body.

Raulin[23] had a case where the copper splinter remained in the eye for 20 years.

Lead and glass in the vitreous.

While glass splinters are, as a rule, aseptic and become encapsulated without causing much irritation, and may remain for many years in the eye, yet chemical changes arise from contact with the vitreous causing shrinking of the vitreous and degeneration and detachment of the retina.

Zirm[24] had a case where a large splinter remained in the eye for 4½ months without causing inflammation. In a very few encapsulation ensues as in Grünthal's[25] patient, which had been in 10 years with retention of good vision.

As a rule traumatic irido-cyclitis follows with retinal detachment, atrophy of the globe or infection of the wound by pus germs, and panophthalmitis. The wound of entrance by glass is, as in the case of stone and wood, larger, more contused and lacerated than from small grains of iron and copper.

It is different with shot and powder grains, for these may remain in the eye for a long time, becoming encapsulated and not giving rise to inflammation.

I well remember a sportsman friend who was shot in the face at a range of about 75 yards by No. 10 snipe shot. One pellet entered the sclera back of the ciliary body and passed into the vitreous, rebounding from the posterior wall and again into the vitreous, becoming encapsulated therein in the lower portion. V. three years later full 6/vi; small sector defect in the visual field above.

I have noted several instances of powder grains impacted in the vitreous, one of which was in a boy who was injured by the premature explosion of a toy cannon. Irido-dialysis, inversion of the iris and a partial cataract followed with several grains of powder in the lens and vitreous; vision, however, nearly a year later, was 6/lx.

Stone, wood, coal and other particles become encapsulated but, like glass, lead later to inflammation and irido-cyclitis. Occasionally such may remain for a long time.

I recall a man who lost an eye by rupture of the sclera and loss of

its contents in a blasting injury; in the other eye cataract was produced from several sand grains passing through the cornea, in which there had been so many impacted that I scraped them away at the time of enucleation of the other. After the cataract was removed by linear incision, several months later, the pupil was quite clear and V. = 6/lx with + 10.00. Three encysted foreign bodies could be seen, one apparently in the retina and two in the vitreous.

The spontaneous extrusion of stone, wood, coal and glass is uncommon; they may remain for a score of years or more, though the eye be ruined by the resulting irido-cyclitis. Only ancient cases are to be found in the literature.

Diagnosis. There are four things to do: First, determine the immediate loss of vision; second, the character of the wound and its direction; third, the kind of foreign body; fourth, its location. The chapter on General Diagnosis should be studied for the various methods. It often happens that a patient supposes he has a foreign body in the eye when none exists, or that the object is iron or steel when it may be wood or stone, and thus non-magnetizable.

The History is not fully to be relied upon, as the excitement of the accident, or, in some cases, malingering, will lead to misleading statements of the patient or those who may accompany him. It is well to question the patient as to the circumstances of the accident, the character of the tool and object on which he may have been working and to place him in the position in which he was at the time of the accident. In some cases it is advisable to examine the tool which he was using, as a portion from this generally forms the foreign body.

The visual acuity immediately following the accident does not bear much relation to the prognosis on account of the obscuration of the media by hemorrhage or exudates which may ultimately clear up.

The character and location of the wound is of great importance as to the trauma done by the foreign body; accompanying injuries of the lens and ciliary body are respectively dangerous.

Small wounds are generally due to iron, steel, or copper particles, larger ones to stone, glass, etc.

The direction of the wound canal may be determined by direct and focal illumination and ophthalmoscopy, giving us some idea of the first course of the projectile. The study of the small air bubbles in the course of the wound in fresh cases will show its direction.

Careful probing of the wound with a fine, disinfected sound may give evidence of a foreign body near the surface when the media are obscured, or when the ophthalmoscope does not show the intruder, as when the foreign body lies near the ciliary body. The probe must not be entered into the vitreous except as a part, and at

the time, of a magnet operation for a supposed iron or steel chip, as advised by Hirschberg in his numerous writings anent this.

Examination of the visual field, as advised by Berlin,[26] with two lights at a meter distance will show defects in the field as sectors or large scotomas, which may give an idea as to the localization and contraction of the field in a general diagnosis for retained foreign bodies. This contraction is usually above, as the foreign body sinks below.

When the media remain clear enough the perimeter examination may show the scotoma corresponding to the foreign body. Intelligent persons will often entoptically see, and be able to describe, the position of the foreign body.

A symptom of more or less diagnostic and localizing importance is circumscribed redness and pain on touching a spot over or near the foreign body, as shown by von Graefe,[27] but it must be remembered that the same symptoms are to be elicited over a cyclitic area.

The course bears no relation to the presence or absence of a foreign body as other injuries may give much the same evidence, but as a rule eyes retaining a foreign body in the vitreous go to ruin from irido-cyclitis and are apt to set up sympathetic ophthalmitis in the fellow.

During the last score of years there have come into use several subtile methods for the detection of foreign bodies within the vitreous chamber, by means of which a diagnosis may be established which would otherwise in most cases be utterly impossible.

I refer to diagnosis by the Röentgen-rays, described heretofore, the sideroscope, and diagnosis with the electro-magnet by the movement of the foreign body and the pain reaction.

Prognosis. In no other part of the eye is the prognosis so unfavorable as when the foreign body remains in the vitreous. In but few cases is the object encapsulated, and in fewer still is vision retained. Nearly all cases result in irido-cyclitis, with a large proportion of sympathetic ophthalmitis cases unless the foreign body be speedily removed. In the statistics of Weidmann[28] he showed that 100 per cent. of cases were lost previous to the aseptic era, and that from 1883 to 1886 when the magnet was not used 83 per cent. were lost. Haab[29] and Hirschberg[30] now show a much less percentage of loss.

Iron splinters give the best prognosis, for they may in many cases be early diagnosed and removed by the magnet operation. In the case of splinters of copper the extraction is very difficult and is seldom accomplished, and in the case of other objects removal practically never happens.

Prophylaxis. The chapter on General Prophylaxis gives this subject more in detail. Metal workers should wear protective glasses and masks and their machinery should be encompassed by screens. Due care

in the use of tools and explosive compounds would prevent the larger part of these accidents. Good tools and proper appliances prevent breakage.

The removal of foreign bodies from the posterior chamber of the eye gives the principal indication for operation within the vitreous.

A large proportion of the cases brought to the ophthalmologist are of traumatic nature, and in manufacturing communities injuries attended by entrance of foreign bodies are extremely common. Simeon Snell[31] says that very few persons working at the iron and steel trades escape injury in the course of two years, and there are many more accidents to the eye in the course of this time than the number of men employed.

Therapy. The treatment consists in the care of the wound and the extraction of the foreign body in order to get healing and insure the function of the organ if not too much damaged. Even if the foreign body be removed and no sight be left, the form of the eye should be remembered, as a sightless, good-looking, and non-painful or dangerous, orb is better than a prothesis. If the foreign body cannot be removed and the eye be blinded it should be enucleated. If the wound be lacerated and contused and in a dangerous location, as the ciliary region, particularly in working men and in patients who cannot remain under skilled observation, it may be advisable to remove the globe rather than to run the risk of a long course of healing, with the expense and ultimate risk of sympathetic ophthalmitis from neglect or inability to recognize its approach and dangers.

The extraction of iron and steel fragments from the vitreous, if they can be magnetized, is to be effected at as early a moment as possible after their diagnosis. This is described in previous pages.

The extraction of copper and other non-magnetic foreign bodies from the vitreous may at times be successfully accomplished. For this procedure see hereinbefore.

E. E. Maddox[32] writes the author the following: "Paralenticular Route to Vitreous. A small boy was struck in the eye by a fragment of copper percussion cap. At the time when I first saw him, about three months after, no aperture of entrance was visible. The eyeball was inflamed; the iris was discolored brown; the pupil dimmed with iritis exudation. Enucleation had been advised by an eminent colleague. After subduing the inflammation by powerful antiphlogistic measures, with mercury, electric heat, atropin, dionin, etc., the pupil dilated and the iritis almost disappeared in a week or ten days. A white mass could now be seen through the pupil lying on the ora serrata. The encapsulation of the copper explained why the iritis could be dispelled. Under

chloroform I made an iridectomy downwards, the corneal incision being made with a narrow linear knife, coming out perpendicular to the surface, slightly within the limbus. A fine pair of forceps with spoon-shaped ends and bent shanks, which enabled me to watch their progress, was then pushed gently through the suspensory ligament of the lens and the foreign body grasped and removed. The eye healed perfectly, no cataract ensued, and it became a strong and useful eye."

The absence of any hemorrhage that might obscure the proceeding, and the visibility of all that is done, are great points in favor of this route.

LITERATURE.

1. Hirschberg, *Centralbl. f. prakt. Aug.*, 1890, p. 110.
2. DeWecker, ref. Praun, p. 342.
3. Berlin, *Arch. f. Ophth.*, xiii, 2, and xiv, 2.
4. Leber, *Die Entstehung der Entzündung und die Wirkung die enzüntdungs erregenden Schädlichkeiten, Leipzig*, 1891.
5. Von Hippel, *Arch. f. Ophth.*, xlii, 4.
6. Haab, *Atlas Ophthalmology*, Fig. 41.
7. Hirschberg, *Arch. f. Ophth.*, xxxvi, 3.
8. Elschnig, *Arch. f. Aug.*, xxii, 1.
9. Castelman, ref. Praun, p. 345.
10. Spratt, C. N., *Ophth. Record*, Sept., 1908.
11. Praun, l. c., p. 346.
12. Knapp, H., *Inaug. Dissert.*, Bonn, 1875.
13. Mandelstamm, *Klin. Mon. f. Aug.*, 1881, p. 284.
14. Bull, *Arch. f. Aug.*, x, 2.
15. Landmann, *Arch. f. Ophth.*, xxviii, 2.
16. Dickey, *Ophth. Record*, Sept., 1908.
17. Kostenitsch, ref. Praun, p. 347.
18. Decker, *Klin. Mon. f. Aug.*, 1890, p. 500.
19. Hirschberg, *Deut. Med. Woch.*, No. 14, 1894.
20. Ruhberg, *Inaug. Dissert.*, Kiel, 1889.
21. Spechtenhauser, *Wien. Klin. Woch.*, No. 43, 1894.
22. Praun, l. c., p. 348.
23. Ranlin, *Arch. f. Aug.*, xxxvi, 1 and 2.
24. Zirm, *Klin. Mon. f. Aug.*, 1890, p. 311.
25. Grünthal, *Berl. Klin. Woch.*, No. 4, 1895.
26. Berlin, *Arch. f. Ophth.*, iii, 2.
27. Von Graefe, *Arch. f. Ophth.*, ix, 2, p. 80.
28. Weidmann, *Inaug. Dissert.*, Zürich, 1888.
29. Haab, *Trans. Sec. Ophth. A. M. A.*, 1902.
30. Hirschberg, *Berl. Klin. Woch.*, No. 25, 1896.
31. Simeon Snell, *The Prevention of Eye Accidents in Trades*, London, 1899.
32. Maddox, Personal communication, 1910.

C. INJURIES FROM CONTUSIONS.

Hemorrhage into the vitreous.

Etiology. Bleeding into the vitreous occurs from all forms of injury to the globe from blunt objects; not only when it is opened, as in rupture of the sclera, but in contusions without tearing or wounding of its envelopes.

The blood comes from torn and ruptured blood vessels of the ciliary body, chorioid or retina, in old age and myopia, arterio-sclerosis, anemia,

leukemia and a phthisic predisposition to this condition which may happen in such eyes from very slight trauma and it may permeate the vitreous so thoroughly that even quantitative perception of light is abrogated.

Symptoms and Course. When bleeding into the anterior chamber and lenticular opacity does not prevent, the blood may be seen in the vitreous either as a dark, cherry-red reflex of the whole fundus when the vitreous is fully permeated, or as well-defined dark clouds with red edges when localized. Fresh blood masses are lighter red than older ones. In a few cases the origin may be found in a broken and leaking retinal blood vessel, but mostly the hemorrhage leads down from the ciliary body behind the posterior capsule of the lens.

The vision is affected according to the amount of hemorrhage; in full permeation of the vitreous being reduced to perception of light. In other cases the patient may see red or have scotomata with reduced visual acuity. There is a feeling of tension within the eye which may be perceptible to palpation. Absorption of the blood in ancient cases takes place, often taking a year or more for completion, or it may clear, in some cases, in six to eight weeks. In full permeation the older the eye the longer is the duration of the recovery, as the eyes become softer and membranes form in the vitreous from organization of the blood clots. In unfavorable cases the blood pigment may wander into the other structures of the eye, especially causing a brownish or greenish discoloration of the iris (Fuchs[1]), so that the iris seems as if made of a ruby-red glass.

Diagnosis. Where the ophthalmoscope can be used the diagnosis should be clear from the appearances. When there is also bleeding into the anterior chamber (hyphema), the diagnosis may be made from the light sense and the visual field.

Prognosis. The prognosis depends upon the amount of bleeding, the general condition and age of the patient, the implication of the retina, which may be affected at the same time as the vitreous and be later subject to atrophy. When the hemorrhage is large, organization of the blood clots with resultant new-formed membranes in the vitreous occur which blot out the sight.

Therapy. Iced and compress bandages, calcium chloride, or ergot may hinder further hemorrhage. Hot compresses and dionin, later with pilocarpin sweats, will assist in their resorption. The effect of the positive pole of the galvanic current at 10-15 milliamperes, or of the high frequency current, is worthy of trial.

LITERATURE.

1. Fuchs, *Textbook*, Amer. (Duane) Ed., p. 470.

D. GUNSHOT INJURIES.

In bullet wounds of the globe, more or less complete loss of vitreous follows. In those from bird shot little or no loss may occur.

Foreign Bodies. Shot grains and portions of other projectiles may remain quiet in the vitreous even without causing sufficient irritation as to become encapsulated, but as a rule they cause inflammation in the uvea and end in atrophia bulbi. Powder grains and pieces of stone carried thence by explosives are noted. I have seen several cases of complete perforation of the vitreous by pellets of shot, or retention of same in the vitreous.

Praun[1] says that in but few cases has the wound of exit in double perforation been seen by the ophthalmoscope, and cites two.

I remember, however, of seeing two such in my own practice, both somewhat similar in that the Nos. 5 and 7 shot, respectively, passed through the sclero-cornea and upper margin of iris and lens, or lens ligament, without producing lenticular opacity, and into the orbit through the posterior wall, in both instances just above the macula. Both cases recovered with useful vision.

Valois[8] and Weeks[3] give full descriptions of shot in the vitreous, in some of which, upon resorption of a traumatic cataract, the shot pellet was found in the anterior chamber.

As a rule there is only one shot pellet, in other cases more. Johannes Berlin[4] in one of his cases had 11 shot in the orbit and eye, several being in the vitreous. V = fingers at 1.00, eccentric outwards.

Concussion and contusion of the vitreous is common and complicated by entrance of blood. Opacities and resultant new membranes occur both by direct and indirect injuries from the organization of blood clots resulting from hemorrhages from ruptured retinal, choroidal, or ciliary blood vessels, as described in the section on Hemorrhage into the Vitreous. As a rule other damage is done to the eye to be discerned as soon as the media clear, as rupture of the choroid and retina, detachments, etc.

Therapy. The treatment is that of perforating wounds of the posterior part of the eye. It is practically asepsis, and either palliative or radical. The shot may seldom be extracted unless it is found in or near the wound of entrance. In severe injuries enucleation should be practised, and is the principal eye operation for the field surgeon in time of war.

Neeper[5] described a healthy girl of 17 who was first seen by him September 20, 1909, after having received a gunshot wound of the left eye during the previous evening. The foreign body, supposed to have

been fine bird shot, passed through the lower lid and entered the conjunctiva about 5 mm. below the lower fornix and about 1½ mm. to the left of the median line. The lid wound was probed and seemed to be about 2½ mm. in diameter. The pupil was dilated in an oval form, the axis lying in the horizonal meridian. The interior of the eye appeared normal except the vitreous, which was slightly turbulent, and there seemed an unusual whitish spot at the macula. The lids were greatly swollen and there was much conjunctival ecchymosis. L. V. = 20/lxxx and had remained practically unchanged. X-ray, front view, showed the foreign body to be 4x6 mm., side view, 4x4 mm., and showed the center of such body to be 13½ mm. below the horizontal plane and ½ mm. to the temporal side of the vertical plane. Since the swelling had subsided the foreign body could be felt as located by the X-ray.

LITERATURE.

1. Praun, l. c., p. 373.
2. Valois, *These de Paris*, 1896.
3. Weeks, *Trans. Sec. Ophth. A. M. A.*, 1903, p. 217.
4. Berlin, Johannes, *Inaug. Dissert.*, Giessen, 1908.
5. Neeper, *Journ. Ophth. and Oto-laryngol.*, Dec., 1909.

E. INFECTIONS OF THE VITREOUS.

Wounds of the vitreous carrying infection act primarily on the surface of the membranes covering the vitreous body—the retina and ciliary body. Exudates extend from the ciliary body and processes into the fossa patellaris, forming a tough exudation membrane in which a localized vitreous abscess may develop. From the retina the exudate covers its inner surface and it soon becomes detached and wrinkled, beginning near the outer margin of the optic nerve. The infiltration of the retina and papilla and detachment of the retina is likewise speedily effected by the toxins of the infection, which combination accounts for the rapid extinction of the light perception.

Hence the amount of light perception is the distinguishing mark for enucleation in these cases; the eye should be removed as soon as the perception is lost. Fuchs[1] notes that it is true that when such enucleated eyes are opened the retina and optic nerve do not display the grave changes that we expect to find, and that even under the microscope they prove to be almost normal. This agrees with the clinical fact that in many cases in which enucleation is not performed the light perception, which has been almost lost, is restored. In others, however, the grave purulent infiltrations above described exist. In the lighter cases the organization of exudate in the vitreous occurs, which ultimately shrinks, causing atrophy of the eyeball. A marked example of this is the effect of copper particles in the vitreous. In these severe cases the

exudate consists wholly of pus and is incapable of organization, causing different degrees of inflammation, according as the suppuration is circumscribed, when it is possible to make a diagnosis of abscess of the vitreous. Here where the anterior part of the eye remains transparent we may see a yellow reflex behind the lens, the pus in situ. This is later transformed into a membrane which shrinks and causes detachment of the retina with atrophia bulbi.

If the process be very virulent the case goes on to panophthalmitis, perforation of the eyeball, and phthisis bulbi.

Vogelsang[2] describes the disease "hyalitis suppurativa traumatica." His first case was a woman with cataract in both eyes, and ozena. After irrigation of the lacrimal sac and nose, after the symptoms had diminished from the side of the nose, Prof. Straub performed extraction with iridectomy. A typical hyalitis developed, which remained progressive, although the wound was opened twice and atropin instilled, so that the eye had to be enucleated. The chief clinical symptoms were strong secretion from the conjunctiva, chemosis, pus in the anterior chamber, opaque cornea, higher tension, strongly infiltrated wound margins.

2. A girl, 10 years old, had wounded the right eye four days before coming to the clinic. The symptoms of infection were found: viz., an opaque infected cornea; a thick iris not reacting to atropin; opaque corpus vitreous; fever. The lens was touched and a traumatic cataract developed. In the beginning the eye progressed favorably, so that Prof. Straub made a broad incision at the corneo-scleral margin and after iridectomy removed the swollen lens mass, when at the same time a fibrinous membrane was removed from the anterior surface of the lens. The healing, however, did not continue. When the chemosis increased, the grayish reflex from the interior became more intense and the iris remained hyperemic; the eye was enucleated two weeks after the injury.

3. A 10 years old girl injured her right eye with a steel fork. Examination showed swelling of the eye lids; vulnus corneæ and of the bulbar conjunctiva; slight infiltration of the wound canal and surroundings, iris hyperemic and blood in the anterior chamber and the pupillary plane. Tension about normal. Patient was treated with salicylate of soda and atropin. The pupil changed from narrow to medium wide, and showed a posterior synechia and fibrin in the pupillary plane. The inflammatory symptons increased (a small hypopion and pain on pressure developed). Then the hyperemia of the iris diminished, the pupil dilated and the exudate in the anterior chamber resorbed. But in the inferior nasal part an irido-dialysis and rupture of the iris was seen and a grayish-white reflex from the fundus became visible. This hyalitis remained progressive. Fourteen days after the injury vessels in the iris could no more

be seen, still some posterior synechia remained. As the fundus reflex increased and the tension became lower (-1 to -2), the eye was enucleated seventeen days after the injury.

Aseptic suppuration may occur from chemical irritation, especially in the case of copper particles, and cause a localized abscess of the vitreous, most instances of which end in atrophia bulbi, but a few in recovery.

Cramer[3] reports the case of a man injured by a particle of gun cap in the sclera, the foreign body passing into the vitreous. A globular, yellow prominence at the nasal wall and opacities of the vitreous, were seen by the ophthalmoscope. Attempts at extraction by incision of 4 mm. deep, then pus oozed out, but repeated attempts at extraction of the foreign body by forceps failed. Uneventful recovery and about a month later the foreign body could be seen in perfectly clear surroundings. Two months later V. normal but foreign body more movable.

LITERATURE.

1. Fuchs, *Text-book, Amer.* Ed., p. 335.
2. Vogelsang, *Doctorate Thesis*, 1908.
3. Cramer, *Centrlbl. f. prak., Aug.*, June, 1907, p. 167.

F. DEGENERATION OF THE VITREOUS FOLLOWING INJURIES.

The occurrence of vitreal opacities has been a number of times noted in these pages. These result from hemorrhages and exudates, the more minute opacities consisting of masses of cells or pigment granules or filaments, the large become organized into membranes, cords or large masses of connective tissue. A new formation of blood vessels supplying these membranes may take place, running from the retinal vessels into the vitreous, and to be seen by the ophthalmoscope, the so-called retinitis proliferans discussed more fully on another page.

Cirincione[1] says the importance of the region of the ciliary body as the matrix of the vitreous humor is confirmed by the disastrous results to the integrity of the eyeball following lesions of this region.

Greeff[2] states the normally greater fluidity of the center of the vitreous increases with age. These changes may also occur in youth. Liquefaction of the vitreous is a sequel of various conditions, but is constant after chronic cyclitis and union of the ciliary processes; not only this, but the albuminous element is increased. Greeff believes this to be due to alterations in the epithelium of the orbicularis ciliaris, permitting the albumin of the blood to penetrate. Various conditions follow this, particularly that known as fibrillary degeneration. He says, in relation to this, that as rarely as we have a regeneration of the vitreous fibrillæ, so rarely do we have, either as a result of the inflammation or

other degeneration, an hypertrophy, a thickening or an increase of the same. There is no such thing as fibrillary degeneration of the vitreous. The only change the fibrillæ of the vitreous undergo is their solution. He confirms the existence of both posterior and anterior separation of the vitreous, but considers it an artifact.

Elschnig[3] says detachment of the vitreous is of especial interest as being the preliminary stage or predisposing cause of detachment of the retina. Since this was claimed also for the detachment of vitreous in myopic eyes by Ivanoff[4] he has studied these conditions and reports in tabular form his ophthalmoscopic and anatomic investigations on 17 globes with myopia from 2.00 to 30.00, and of all kinds of shapes, from normally formed, only enlarged, to typic and atypic posterior staphylomata. Only in four detachment of the vitreous appeared to exist, but the microscopic examination revealed the hyaloidea, with remnants of vitreous, attached to the retina. In all others the microscopic and macroscopic topography of the vitreous was normal. This corresponds exactly with v. Arlt's[5] description of the liquefaction of vitreous, often found in high degrees of myopia, viz., that the remaining portions of vitreous terminate behind in fringes and flakes, fluctuating in serous fluid. Thus the assumption of the frequent occurrence of detachment of the vitreous in staphyloma posticum is refuted by the observations of Elschnig. In myopic eyes with separation of the retina, detachment of the vitreous is by no means the rule, as he found in quite a number of myopic globes. If these observations are compared with the frequent cases of funnel-shaped or total detachment of vitreous after traumatism or irido-cyclitis, without solution of the retina, the connection of detachments of vitreous and retina are very improbable. Funnel-shaped separations of the vitreous may be diagnosed with the ophthalmoscope, but may be mistaken for persistent hyaloid artery, as Elschnig found in a case which he describes.

Kerry[7] reports a case of blood staining of the vitreous in a man of 30, struck in the right eye with a relatively large piece of metal. Small healing wound at the limbus. Anterior part of eye and lens normal. No fundus reflex. Hemorrhage from one of the long ciliary arteries, extending between lens and vitreous, was diagnosed. The absorption took nearly a year before the fundus reflex was again visible. The sight became nearly normal.

LITERATURE.

1. Cirincione, ref. Greeff.
2. Greeff, *Arch f. Aug.*, liii, 2.
3. Elschnig, *Klin. Mon. f. Aug.*, 1904, p. 529.
4. Ivanoff, ref. Elschnig.
5. v. Arlt., ref. Elschnig.
6. Kerry, *Ophthalmology*, July, 1910.

CHAPTER XXIV.

INJURIES OF THE RETINA.

A. Wounds and prolapse. 1. Wounds—Etiology—Symptoms—Diagnosis—Prognosis—Therapy. 2. Prolapse—Literature. B. Foreign bodies—Etiology—Symptoms and course—Iron and copper chips—Dangers—Diagnosis—Prognosis—Therapy—Literature. C. Injuries from blunt objects. (a) Contusions—Commotio retinæ—Berlin's traumatic edema—Etiology—Mechanism—Symptoms—Complications—Course—Diagnosis—Prognosis—Therapy. (b) Traumatic excavation of the macula—Holes in the macula—Etiology—Spontaneous hole at the fovea. (c) Haab's traumatic macular disease—Etiology—Symptoms—Diagnosis—Prognosis—Therapy—Electric macula disease. (d) Hemorrhage into the retina and of the retinal vessels—Etiology—Symptoms—Course—Therapy—Embolism of vessels—Air embolism. (e) Retinal vessel aneurysm—Literature. D. Rupture—Dialysis and detachment of the retina. 1. (a) Isolated rupture. (b) Rupture accompanying rupture of chorioid. (c) Accompanying rupture of globe. II. Traumatic retinal detachment—Etiology—Statistics in myopia—Symptoms—Complications—Diagnosis—Prognosis—Therapy. III. Striæ retinalis—Etiology—Retinitis striata and striæ retinalis—Literature. E. Blinding or dazzling. F. Injuries from firearms—Literature.

A. WOUNDS AND PROLAPSE.

Etiology and Symptoms. 1. Wounds of the retina, like those of the chorioid, can only occur after the ocular envelopes have been opened. The wound may be through the anterior portion of the eye, in which case the cornea and lens, or cornea, iris and lens, zonule or sclera and ciliary body must first be penetrated; or through the conjunctiva, sclera and chorioid; or rarely through the orbit, Tenon's capsule, sclera and chorioid. Then, too, objects may penetrate through one wall of the eye, pass through the vitreous and wound the retina, either piercing it and the sclera, thus making a double perforation to the orbit, or, as is the case with some foreign bodies, rebounding into the vitreous, even traversing this structure again and lodging in some other part of the retina.

Wounds passing first through the sclera and chorioid to the retina cause a more or less pronounced local hemorrhage, which spreads later into the parenchyma of the retina and into the vitreous. About this we find a circumscribed edema which tends to acquire a yellowish tinge from the formation of small blood infiltrates into the retinal tissue. If

the retina be torn its edges will roll up and float in the vitreous, and if the chorioid be torn at the same time the white sclera will be visible. This occurs in double perforations of the eyeball by foreign bodies.

In one such case I found, in addition to the wound of entrance through the sclera, another at the nasal side of the disc about two disc diameters away. The edges of the rent showed plainly, the retina being triangular, the hole in the chorioid more irregular and the scleral opening closed but not well defined. X-ray showed a chip of metal in the orbit. V = full 6/vi after one month.

Fridenberg[1] described a tear of the retina over the macular area, in a clerk, with no history of accident. The frayed edges of the retina were very distinct to ophthalmoscopic examination. V = movements of hand at two feet. (See also Haab's Atlas, Fig. 48.) He thinks that this may have been due to a small, local accumulation of fluid in the superficial layers of the slightly detached and edematous retina, which finally made its way through the few thin layers separating it from the vitreous and bursting them, escaped therein.

The nerve fibers, according to Berlin[2] show varicose hypertrophy in the neighborhood of the retinal wound. A partial retinal detachment has been observed which heals by formation of an exudate in the wound which later becomes a whitish cicatrix, always causing a more or less scotomatous defect in the visual field.

The Diagnosis is not possible unless we know by the depth of the scleral wound that the retina is directly cut through, or we see it later by ophthalmoscopy after the accompanying intra-ocular hemorrhage has cleared up.

The Prognosis in small wounds is good. As noted above, healing occurs with scotoma of the visual field. Of course where the macular region is injured the loss of sight is great and leads to atrophy of the nerve with central scotoma.

The Therapy is that of penetrating wounds of the eyeball.

Prolapse of the retina occurs in very large wounds and ruptures of the sclera and is attended with considerable loss of vitreous. A portion or all of the retina appears in the wound and extrudes from the eyeball. The sight is destroyed, but in favorable cases the form of the eyeball may be preserved by scleral stitches. Atrophy of the globe or infection with acute panophthalmitis follows.

The retina may be dislocated in cases of luxation of the lens, with ruptures of the zonula, and appear in the anterior chamber, as reported by Berger,[3] in which the lens was dislocated into the vitreous and the retina appeared in the anterior chamber upon dilatation of the pupil.

LITERATURE.

1. P. H. Fridenberg, *Ophthalmology*, July, 1908.
2. Berlin, *Arch. f. Ophth.*, xiv, 2, p. 275.
3. Berger, *Arch f. Aug.*, xv, 3-4, p. 286.

B. FOREIGN BODIES.

Etiology. Foreign bodies in the retina have to first pierce the outer envelopes, either passing through the cornea, sclero-cornea or sclera, injuring thereby in their passage the lens, iris, ciliary body, chorioid and vitreous, and being directly impacted in the retina of the opposite side. The larger proportion of foreign bodies are splinters of steel or iron, then come copper chips and shot pellets.

Symptoms and Course. If the media be sufficiently clear a small, dark, metallic, glistening object will be seen in the retina, surrounded in recent cases or imbedded in a hemorrhagic clot which extends into the vitreous, or in older ones with a whitish or yellowish region of swollen retina. Later on the foreign body is imbedded in a yellowish-white organized exudate with whitish degenerated chorioidal spots in the neighborhood, with or without pigment proliferation. Fine changes occur in the region of the macula in the shape of irregular lines or spots of pigmentary degeneration (Haab[1]). Further degenerative changes have been described by Von Hippel.[2] In some cases localized detachment of the retina and shrinking of the vitreous is observed.

In a case where I observed a splinter of iron in the vitreous six days after the injury the macular region was strongly pigmented and edematous. (See Plate).

A man had been struck by a splinter of steel, it penetrating the sclera; six weeks afterward the macula was occupied by a grayish spot over which there was much fine black pigmentation. (Plate). This was before the days of the Roentgen-ray and shortly after the magnet had come into use. Attempted extraction was futile and the eye was then enucleated, the steel being found in the vitreous and impacted into the retina.

Splinters of iron are rapidly encapsulated in the retina and useful vision may exist for a long time before further degeneration or irritation sets in, or it may remain good for the life time of the patient.

Hirschberg[3] states that particles not over ½ mm. long may remain in the eye for 16 or more years, and perhaps to the end of the patient's days without causing irritation, if they only be aseptic. The acuity remains good although not fully normal, and there remains a defect in the visual field corresponding to the location of the foreign body.

The foreign body may remain for a long while encapsulated and then work out into the vitreous and cause fresh inflammation. Hirsch-

Berg[3b] cites large splinters of 4 mm. in length, 30 mg. in weight, that remained two years in the retina and finally caused complete blindness. Particles of iron may so rust that they become non-magnetic. If they are septic an acute abscess of the vitreous and loss of the eye from panophthalmitis speedily occurs.

Copper chips cause immediate suppuration when in the retina, just as they do in the vitreous. In only a few instances have they become encapsulated and some vision been retained, and as a consequence of this action and their non-magnetic qualities, most eyes retaining copper in their depths come to speedy enucleation. Other foreign bodies, if aseptic and having no special chemical reaction, act much like iron and are sometimes encapsulated.

The tolerance of the retina to iron and copper splinters is much greater than that of the vitreous, though less than the lens. The encapsulation occurs through proliferation of connective tissue cells of the retina and may completely cover the particle from observation. If very great it extends into the vitreous causing opacity and shrinking with subsequent detachment of the retina, especially when the splinter is quite large.

Kümmel[4] says that lead in the vitreous or retina is well tolerated but is frequently followed by detachment of the retina or formation of folds.

A few very favorable cases have been reported. Priestly Smith[5] saw a piece of bell bronze remain 15 months in the retina with completely clear media. Kipp[6] saw a copper chip which remained without causing irritation for 24 years, with V = 1/4. Goldzieher[7] described a case where copper had remained for 10 years in the retina with good vision. Metallic reflecting plaques occurred in the retina which he designated as chalkers retinæ, due to impregnation with a cupric salt.

Four dangers threaten the eye containing iron or copper particles in the retina. 1. Retinal detachment. 2. Recurring severe attacks of inflammation. 3. A new form of inflammation which leads to retinal degeneration and blindness, as described by von Hippel,[8] in which the disease looks like retinitis pigmentosa with hemeralopia, but the pigmentation is not so prolific. 4. Changes at the macula as described by Haab[9] who states that most cases of iron in the eye eventuate in a macular affection which rapidly diminishes the vision causing central scotoma. The fovea becomes yellowish-brown and the surrounding retina dark-red.

Drucker[10] reported a case of disease of the macula after extraction of a splinter of iron from off the retina. The chip had entered through the sclera and could be seen down and out from the macula, surrounded by a narrow rim of blood. A meridianal incision was made and

the foreign body, which measured 2¼x1¼ mm., at once extracted by the Hirschberg magnet, only a bead of vitreous presenting in the wound. In spite of rapid healing and, in general, normal appearances, V = 6/xxxvi due to macular changes. Two years later there were vitreous opacities, and in the position corresponding to the foreign body there was a triangular black spot measuring 1.5 D. diameter. At the fovea there was a horizontally oval central negative scotoma. The author states that changes at the macula in eyes containing foreign bodies are common, but he could find no analogous case to the above where the foreign body had remained in the eye only two and one-half hours.

Hirschberg[11] shows that the cicatrices may be seen by the ophthalmoscope, one a simple cicatrix and the other characterized by a bluish-white pyramid in the vitreous spreading towards the point of entrance.

In a third type the changes are those due to obstruction of retinal arteries with hemeralopia due to pigment degeneration, not to toxic action in the ganglion cells.

Fridenberg[12] found an unusual condition in two cases in which the retina had been injured by the penetration of a foreign body, and in one instance degenerative and cicatricial processes following hemorrhage. The changes appear to be in the most superficial nerve fiber layers, and consist of very fine, white, hair-like striations, of equal caliber throughout, following the usual radiating course of the nerve fibers. Their point of origin is invariably the site of lodgment of a foreign body, or the cicatrix surrounding an encapsulated chip of metal, or the atrophic patch following a blood clot. The change is one which results in fibrillary edema with an increased refraction index, and later in sclerosis and opacification of the nerve fibers. The fine, white, radiating hairs resemble strikingly the opaque nerve fibers ("whiskers") seen at the lateral margins of the optic discs in rabbits. They are sometimes seen with difficulty, and are quite unlike the already described retinal striæ.

Diagnosis. Only when the splinter itself can be seen by the aid of the ophthalmoscope may we be sure that it is in the retina, although the X-ray is a fairly accurate method of localization. The chip of metal appears black or has a metallic lustre, after it becomes encapsulated it is covered by whitish, well-defined, connective tissue membranes.

When the injury is new it is accompanied by streaks of blood in the parenchyma of the retina and in the vitreous, later pigment accumulates in the neighborhood of the foreign body. If no inflammatory symptoms occur, when a foreign body is known to be in the posterior portion of the globe, it is probable that it is in the retina and has become encapsulated therein.

Prognosis. This is better than in the case of the vitreous, for small splinters may become encapsulated and leave clear vision. This

occurred in Hirschberg's series of cases, 15 times for the retina, and for the vitreous only twice. If not removed or the eye be not enucleated the patient must be warned that not only loss of sight may occur from subsequent inflammation but even loss of the eye, with danger of sympathetic ophthalmitis.

Iron particles are more difficult to remove by the magnet when in the retina than when in the vitreous, because they are often strongly impacted, even into the subjacent sclera. Copper and other foreign bodies offer a poor prognosis, as they are difficult and generally impossible to get out and nearly always cause inflammation and ruin of the eye, and do not generally become encapsulated, hence rendering enucleation necessary.

Therapy. If the particle be iron, freshly entered the eye, the wound be open and the foreign body be localized by the ophthalmoscope, the sideroscope or the X-rays, it may be immediately extracted by the magnet through the wound, after either the method of Haab or Hirschberg. If the wound be closed it is well to instil atropin and after definite localization make a new incision posteriorly and extract the chip by the aid of the magnet.

If the injury be old and the chip encapsulated the eye should be left alone until symptoms of irritation occur, when an attempt at removal may be made, followed, if unsuccessful, by enucleation. Copper, glass, and other foreign bodies in the retina cannot be well removed or even found by instruments without too much damage to the globe. These cases should either be subjected to immediate enucleation, or watched and at the beginning of inflammation the eye must be removed.

LITERATURE.

1. Haab, *Atlas of Ophthalmology,* Amer. Ed., Figs. 41, 53.
2. von Hippel, *Arch. f. Ophth.,* xlii, 4.
3. Hirschberg (a) *Arch. f. Ophth.,* xxxvi, 3 (b) 25, *Jahresbericht über die Augenanstalt,* Berlin, 1895.
4. Kümmel, *Zeitschr. f. Aug.,* Jan., 1908.
5. Priestly Smith, ref. *Arch. f. Aug.,* xxvii, 1 and 2.
6. Kipp, *Trans. Ophth. Cong.,* Edinburgh, 1895.
7. Goldzieher, *Centralbl. f. prak. Aug.,* 1, 1895.
8. von Hippel, *Arch. f. Ophth.,* xxxvi, 3.
9. Haab, *Korrespondenzbl. f. Schweiz. Aerzte,* xx, 19, and *Atlas der Ophthalmoskopie,* Figs. 41 and 45.
10. Drucker, *Die Ophth. Klinik,* No. 9, 1904.
11. Hirschberg, *Centralbl. f. Prak. Aug.,* Apr., 1907.
12. Fridenberg, *N. Y. Eye and Ear Infirmary Rep.,* 1904.

C. INJURIES FROM BLUNT OBJECTS.

a. Contusions. Commotio retinae or Berlin's traumatic edema of the retina.

This form of opacity of the retina, which is often observed after external violence to the eye by blunt objects, was first described by Berlin,[1] and is undoubtedly one of the conditions to which, before that

time, had been given the name commotio retinæ as an analogue to commotio cerebri. Other conditions in which a molecular degeneration of the retina, after blows was supposed to have taken place, are probably those of hemorrhage into the sheaths and ischemia following injury to the nerve behind the globe, to which the term of commotio retinæ was likewise applied until in more recent years their cause has been explained.

Etiology. This form of retinal edema is caused by a compression of the globe, from blows, thrown or flying foreign bodies, or from gunshot injuries.

Mechanism. The mechanism is the same as that of rupture of the chorioid, but the force is not so great, or perhaps the globe is not so indented in direct cases. Berlin described the contusion as due to a bloody exudate between the chorioid and sclera, from which the serum came to infiltrate the retina, but this does not seem to explain the rather quick disappearance and the slight loss of normal acuity therefrom. It is well to think, with Hirschberg,[2] that the condition is one of anemia due to reflex contraction of the blood vessels at the contused area. A transient form may be the same as exists in many persons who have been temporarily blinded by a blow upon the eye. The real nature, however, of this condition, is not yet known.

Symptoms. There is a milk-white evanescent opacity at the spot impinged upon by the blow, and a curved, semi-lunar or almost circular opacity at the macula around the fovea, which sometimes shows as an isolated, more or less pale, spot, distinctly separated from the remainder of the macular opacity. Haab[3] says that this is probably not caused by opacity, as the membrane is exceedingly thin at this point; it is probable that its substratum is situated behind the floor of the central fovea, perhaps in the pigmentary epithelium, perhaps between the latter and the layer or rods and cones. The opacity at the place of impact is more extensive, marked and persistent than that at the macula. The retinal vessels pass over the area undisturbed and the retina is not elevated. At the same time with Berlin's opacity there are often other symptoms of contusion of the globe, as spastic miosis or mydriasis, cramp of accommodation, myopia and myopic lens astigmia, bleeding into the ciliary muscle and permanent changes in the macula.

Berlin[1] showed that the light sense was greatly reduced but soon returned, in fact, the visual power is usually intact, although in some cases central vision may be temporarily lowered without a proportional decrease in the periphery of the field. Contraction of the field is also stated to take place by Fuchs.[4]

The Complications are iridio-dialysis and other forms of iris rupture, when the blow comes from the front; rupture of the chorioid,

retinal hemorrhages, as well as rupture and dislocation. In Schmidt-Rimpler's[5] and in Hoch's[6] cases there was bleeding under the retina. In severe degrees of force hemorrhage into the nerve sheath and fracture of the canalis opticus, with optic nerve atrophy, has followed.

Aneke[7] described a case of one-sided coloration of the optic nerve after commotio retinæ with full normal function.

Course. The opacity commences immediately after the trauma, in some cases taking one or two days to fully develop, reaching its height in 24 to 36 hours after extending over the greater part of the fundus, and passing away in three or four, or at the latest, eight days without leaving any traces. When the vision is found reduced other injuries to the macula, retina or nerve must have occurred.

Diagnosis. The condition, no doubt, has often been mistaken for a separation of the retina, but should be readily distinguished, for it is milk-white, the course of the vessels is not affected, there is no parallactic displacement, marked degree of hyperopia, but frequently myopia, and no folds. In dislocation of the retina the retina is translucent and more of a grayish-green from subjacent fluid, and the course of the vessels is uninterrupted. There is marked hyperopia, folds and usually tremulousness of the detachment.

In embolism the edema exists but is not as white and the vessels are not as contracted as the arteries carry little blood, while the veins may be tortuous and full. In retro-bulbar hemorrhage with contracted blood vessels and a gray fundus, the appearances are quite like those of Berlin's opacity, but they occupy the entire fundus and there is usually exophthalmus from the pressure of the intraorbital hematoma. In Berlin's opacity the vision is but seldom even temporarily affected and the visual field remains normal.

Prognosis. Traumatic edema at the macula always progresses to full recovery within a few days unless complications occur, especially at the macula.

Haab,[8] out of 167 cases of contusion of the eye where it was possible to examine the fundus, found 82.6 per cent. without any changes, 4.7 per cent. Berlin's opacity only at the macula and 12.5 per cent. opacity at both the macula and periphery of the retina. In 16 the vision remained practically normal, in one 6/xxiv and in one 6/lx in amount of opacities of the media. Five had a pigmentary degeneration follow at the macula, discovered from the first to the ninteenth day, and in these the outcome was not so good. In one there was atrophy of the opticus and in one chorioidal changes.

Therapy. The treatment is protection of the eyes from light by coquilles, medium dark room, atropin and bandage, if ciliary spasm occurs.

Rosenhauch[9] reports a case of Berlin's opacity with preservation of normal vision. The left eye of a boy, aged 11, was struck by a stone, which caused a wound below the temporal orbital margin; hyperemia of conjunctiva with a few small ecchymoses. The pupil was of normal size and reacted normally. Ophthalmoscopically there was a triangular-shaped milky opacity on the temporal side of the disc, a similar opacity at the macula lutea and a dark spot on the fovea. V. was normal, no scotomas, and the opacities disappeared in a few days. Rosenhauch assumes extra- and intra-retinal exudations in such a case. Although they generally end with complete recovery and disappearance of the ophthalmoscopic changes, he thinks that these may be so slight that they can be detected only microscopically.

b. Traumatic excavation of the macula.

Etiology. "Holes" in the macula are observed in cases of injury to the globe as the result of retained foreign bodies or as a sequel of commotio retinæ. The hole appears punched out with perfectly round, sharp edges, and, what is very striking, reveals in the depths an area of chorioiditis with atrophy and pigment proliferation corresponding to the retinal lesion.

Butler[10] reported four cases, some of which were retinal holes, and some depressions from atrophy. None of them was caused by traumatism.

In some cases microscopic examination of the specimen shows that an actual hole did not exist, the hole corresponding to an area of retinal atrophy enclosing a cystic space filled with fluid.

Coats[11] says "Macular holes are produced by an edema of the retina at the posterior pole. The edema may not be confined to the region of the fovea, but the appearance of a hole will only be produced if there is a defect at least of the inner layers of the retina. A total defect of all the layers of the retina, without membranes or shreds, is necessary for the completely typical picture; and that such a complete defect may arise from retinal edema is proved by his case. The edema may result from a contusion, in which case it is the same as the edema that produces Berlin's opacity; or it may arise from toxins in the vitreous, the result of irido-cyclitis; or from retinal vascular disease.

"Rupture of the retina at the time of injury is not the cause of macular holes. This is proved (1) by those instances which occur without an injury, as in irido-cyclitis, chorio-retinitis, retinal vascular disease, albuminuric retinitis, etc.; (2) by those cases in which diffuse opacity of the retina without a hole has been observed after a contusion, and in which a hole has subsequently developed; (3) by case 4, reported above, in which such a rupture had occurred, but in which the measurements and

appearances could not be brought into line with the clinical picture of macular hole."

Von Hippel[12] gives a note upon spontaneous hole at the fovea centralis. Of the foveal border the internal nuclear and ganglion cell layers were of normal thickness. In the internal nuclear layer and in the layer of cone fibers the retinal elements were separated from one another by cavernous spaces. The internal nuclear layer was thus divided into two layers. In the fovea itself there was a large space filled with fluid separated from the vitreous by the bulging internal limiting membrane, and bounded posteriorly by a thin layer of retinal tissue. The latter is composed exclusively of hypertrophied supporting substance with isolated pigment cells, while the external nuclear layer and cones are entirely absent in this position. In the region of the fovea the pigment epithelium shows irregular heaping and small defects and is everywhere separated from the artificially detached retina by narrow clefts. In the region of the entire posterior pole the retina, in its individual layers, is thickened and there is the appearance of massive nuclei in the cells of the intermediary granular layers. The nuclei are oval with their long axes at right angles to the retina. They stain comparatively faintly with hematoxylin and must be due to proliferation of the glia. The m. l. int. was separated from the retina over large areas, including the foveal region. The lacerated ends of the retina are seen jutting into these cavernous spaces. The author considers these artifacts. In the foveal region, as well as in many other places, but not demonstrably continuous, there is a delicate endothelial membrane incarcerated in the l. m., The vessels, especially the arteries, showed thickening of the walls, narrowing of the caliber and here and there hyalin degeneration. There was edema of the retina confined to the foveal region thinning outwardly from the margin of the fovea. In the latter there was a cavity filled with fluid. It could not be determined whether there was at this point a complete perforation of the retina. Certainly after the absorption of the edema a condition could result which would give, ophthalmoscopically, the picture of a hole at the macula. Unfortunately, the media were too opaque for such an examination. The edema was very likely due to disease of the retinal vessels. The identity of the findings of the author with those of Fuchs[13] speaks decidedly for the view expressed by Reis[14] that in the traumatic, as well as spontaneous, hole formations at the macular region a pronounced edema is at first present.

A boy came to me having been struck by a snowball and immediately blinded. I saw him several weeks after when the vision was only fingers at 3 m., and the macular zone looked as if it had been punched out. (See Plate).

Curt Cohen[15] describes the case of a man injured, by explosion

of a gun, in the left eye, which was enucleated on the eleventh day after symptoms of panophthalmitis had set in. The foreign body was lodged in the disc, with inflammatory exudation and infiltration of chorioid and vitreous, with formation of an abscess in the chorioid at the macula, with subretinal accumulations, bursting and edema, the pus oozing into the vitreous. The inflammation was propagated to the anterior segment and irido-cyclitis with hypopion appeared, hence the enucleation.

Cohen shows that the chorioid may thus play an important part in the formation of holes at the macula.

Zentmayer[16] reports two cases which presented the typical picture of the macula being at a lower level than the surrounding retina, with well defined margins. The floors were a little darker than the surrounding parts, with a somewhat granular appearance. One case followed a blow on the eye from a piece of wood, causing hyphemia and increased tension. The other gave no history of injury, but there was a scar on the forehead, said to have been received in childhood.

Wisselink[17] reports the case of a policeman who was thrown forward from his falling horse into the sand. Immediately afterward he saw everything misty. On the sixth day he came to the clinic, where central scotoma in both eyes, and a very small hemorrhage between right optic nerve and fovea, was ascertained. The immediate surrounding of the left fovea was slightly gray. Later on very fine lines, composed of small dots, in form of radial striations, were noticeable. The different shapes of the scotomata in right and left eyes showed that the ruptures in the macula, caused by the contusion of the posterior pole of the eye through direct pressure from the front, were in the right eye radial, in the left circular. Wisselink attributes the radial ruptures to an intense stretching at the tunics of the posterior pole; the circular ruptures to the change of power of resistance of the retina within the foveal ring. He assumes that in the intermediate strata of the retina a separation took place in accordance with the lacunar formations described by Fuchs.

Twietmeyer[18] reports two cases, caused by contusions of the eyeball through blunt objects. The macular region was at first opaque, the veins engorged and tortuous. In from about ten days to three weeks a round hole, half the size of the optic disc, had formed at the macula, the bottom of which was a markedly lower level than the surrounding retina. It was red and was covered with white dots and surrounded by a diffuse grayish opacity, gradually passing into normal retina. In the second case this opacity showed a great number of shining yellow crystals. Subjectively a central scotoma corresponding to the seat of the affection.

c. Haab's traumatic macular disease.

Haab in 1888[19a] described a form of traumatic macular disease after severe contusions of the eye.

Etiology. Severe external violence from a blunt body, as a blow from a fist, hammer, stone, arrow, whip, wadding from a cartridge, etc., of greater intensity than that which produces Berlin's opacity, causes permanent degenerative changes at the macula which have been called Haab's disease of the retina and macula lutea.

The cases may begin with Berlin's opacity, in which the visual acuity is more affected than would be expected and does not return to normal after 10 to 12 days, or the disease may not manifest itself clearly until several weeks have elapsed.

In 1897 Haab[19c] described a case with similar appearances and results to the vision from an electric current. Oliver[20] also described such a case.

Haab[19b] showed by a series of cases that those in which the Berlin opacity occurred the subsequent changes in the macula did not appear as frequently as in certain cases when the patients returned after the contusion. Out of 29,437 eye cases in five years he saw 80, or 0.43 per cent. with traumatic macular disease.

In 192 cases of contusion injury to the eye in which ophthalmoscopic examinations were made 23.96 per cent. showed macular disease. Praun[21] remarks that the percentage must be much greater, for in many injuries to the eye the fundus is never examined.

Haab has certainly showed us that some of the cases previously put down for malingerers have a real affection of the organ of vision demonstrable by the ophthalmoscope.

Symptoms. At first the macula is reddish and the fovea may be occupied by a still redder spot, with very fine stippling or a minute hemorrhage. The reflexes of the fovea are not found.

Later the macular area may become more mottled and the pigmentation a little stronger about the macular region, or the mottling and pigmentation may be very insignificant, especially in the beginning, and be replaced by distinct pale patches, as is shown in cut No. 4, Fig. 48 of Haab's Atlas (de Schweinitz American Edition, 1909). As a rule the disease does not manifest itself clearly until several weeks have passed, but the appearances are to be seen for years afterwards. The central vision is markedly and slowly diminished, forming at first a relative, then a total, central scotoma, while the peripheric field is little or not at all affected.

Diagnosis. The examination of the macula after contusions is often difficult, as there may be great photophobia and the lids may be much swollen. Likewise there may be wounding of the conjunctiva,

cornea and sclera, erosions and opacification of the cornea and lens, bleeding into the anterior chamber and vitreous, rendering the media turbid or opaque. However, all eyes that have been subjected to contusion should be carefully examined by the ophthalmoscope at the earliest possible moment, and at intervals for several weeks thereafter, especially if the patient complain of lowered vision after the accident; and no one should be declared a malingerer until we are sure there has been no resultant macular disease.

The Prognosis is bad. The central vision deteriorates for months, but the process may come to a halt before a large central scotoma forms.

The Therapy is that of ocular contusion, atropin, rest, and protective glasses.

A woman struck her head and brow on the edge of an opened door at night, causing a black eye, and thereafter she could not see well. I examined the fundus the same day, finding a slight degree of Berlin's opacity at the macula, in the center of which was a hemorrhagic-like spot. After two weeks the edema still persisted and there was also a fine pigmentation in parts of the edematous area. (See Plate) V = 6/xii, absolute small central scotoma.

A man was struck on the face by a rope-end and three weeks afterward came saying he could not see well, when at the macula a ring-shaped circle of pigmentation was found at the edge of the fovea, with small pigmentation outside and whitish areas within the ring. (See Plate) V = 6/lx.

A boy was struck by a companion's fist, seeing "stars," and several days thereafter came to me with the remains of a black eye, saying he could not see well. The macular area was reddish, with fine white stippling. The area about it was quite dark. V = 6/xii, recovery to 6/vi after several weeks, but the macula retained the same appearance (see Plate), while that of the other eye was normal.

In Oliver's case of electric macular disease[20] the patient was shocked by a blinding flash of lightning, falling to the earth and feeling as if all his joints had been pulled out. (A horse was knocked down on the other side of the street by the same shock.) He was totally blinded, but the sight came back, there remaining a spot before each eye. Central scotomas were found in the visual fields. Eleven days later light points in grayish backgrounds of spots were found. These changed their appearances at the next examination.

In Haab's case[19e] of electric macular disease a machinist had a strong electric current from a dynamo pass through his body from the hands and out of his right eye, reducing V to 3/xviii, later 3/iv. A red, foveal spot on an edematous background occupied the macular region.

d. Hemorrhage into the retina, and of the retinal vessels.

Etiology. We consider here only hemorrhages from the retinal vessels into the vitreous and retinal structure. In perforating wounds the vessels of the retina may be cut, and with those of the chorioid cause hemorrhage into the vitreous. Direct contusions from foreign bodies may occur.

Wendell Reber[22] says obstetric injuries account for many cases of interrupted binocular vision from retinal hemorrhages.

The force of contusions of all sorts on the eye or head may be communicated indirectly to fragile vessels, particularly to those of arteriosclerotics and in the hemorrhagic diathesis, and cause them to rupture. A blow upon the eye indenting it may rupture the retinal vessels without breaking open the globe.

Symptoms. Unless in the case of severe contusions or wounds the patient seldom complains of loss of vision if the bleeding into the vitreous be not in the visual axis, although he may see a dark spot before the eye. The ophthalmoscope generally shows a single hemorrhage proceeding from an artery in the case of sclerotics, or it may be in the vein after direct contusions, as reported by C. A. Oliver.[23] If the bleeding be great only an extra-vitreal hemorrhage may be diagnosed. The fresh blood-clot looks cherry-red; older ones blackish. The blood stain may diffuse throughout the vitreous, but as a rule it is circumscribed, showing as a streak or projection. Commonly when within the retina, or pre-retinal, between the retina and the vitreous lamella, the upper margin of the clot is horizontal.

Course. A hemorrhage may be fully resorbed in one or two months or longer in old subjects, or it may become organized and persist indefinitely as membranes in the vitreous or in the retina as a yellowish, pigmented area in which the retina elements will atrophy. A scotoma of the field naturally follows and when the bleeding has been great, permanent loss of sight results from the secondary changes. Macular bleeding cuts off central vision.

In C. Zimmerman's[24] case of rupture of the central vessels the intra-ocular hemorrhage resulted in a marked degree of retinitis proliferans, in which dense masses of connective tissue extended out from the retina into the vitreous and a portion of the fundus, even the papilla itself. Into these masses run new blood vessels from the retina. These are probably generally preceded by hemorrhages which later have become organized.

A tall, strong man of thirty-seven years attempted to board the front platform of an electric car, which was moving fast. He fell, however, and dropped with the right side of his face on the ground with such violence that the strong leather visor of his cap was detached and struck his

nose and right eye. Laceration of the retinal vessels behind the eye with picture of thrombosis of the artery and vein were thereby produced.

The further course of the morbid changes, as reported from the examination of Nov. 7, 1896, was degeneration of the retina with development of connective tissue covering the disc and a great portion of the retina. The blood vessels were partly hidden over it, partly branched over it. The extensive tracts of white and gray fibrous tissue, which at some places projected +6.00 C., reminded one very much of the affection described by Mans[25] as retinitis proliferans. Mans examined his case anatomically and found a chronic retinitis with new formation of tissue on the inner surface of the retina, and therefore called the disease retinitis proliferans, since he regarded the inflammation of the retina as the primary change.

Banholzer[26] examined another case microscopically, which was similar, inasmuch as in both the new-formed tissue in the retina consisted of proliferated Mueller's fibers, connective tissue and vessels. According to Manz, intraocular hemorrhage stands doubtless in intimate causal relation with the proliferation, as observed in most of the cases published. S. Schultze[27] considers "the name retinitis proliferans unsuitable for this affection, since an inflammation of the retina has never been observed as the primary disease, while retinal and vitreous hemorrhages were always found." He thinks that "the new masses are not inflammatory or exudative, but rather deposits of unresorbed blood fibrin. The deposits are in intimate connection with the retina, cause atrophy of the nervous elements of the retina, hypertrophy of the connective-tissue elements, and finally become themselves transformed into fibrous cicatricial tissue." In Schultze's paper will be found a review of the literature on this subject: Manz, Leber, Alexander, Schleich, Proebsting, Martinet, to which we may add the observations of H. Knapp,[28] Chodin,[29] and the experiments of Colucci[30].

Re-establishment of circulation. In most of Wagenman's[31] animals an imperfect circulation was established through the capillary anastomoses at the periphery of the disc; even the artery on the disc was refilled. Later on he found several fine, new-formed blood-vessels at the disc coming from outside, to which he is inclined to attribute the restitution of circulation. Vertical and frontal serial sections of the entrance of the optic nerve indicated that the restitution of circulation is chiefly owing to new-formed vessels which enter the disc partly from the chorioidal opening, partly from the optic sheath and the episcleral tissue; i. e., from the fibrous degeneration of the underlying retina with hypertrophy of the connective tissue elements of the retina. Later on detachment of the retina and phthisis of the eyeball may be expected.

Hillemanns and Pfalz[32] report a case in which a large piece of

wood fiber flew against the right eye of a man, aged 42, without causing an external injury or hindering him from continuing his work. Ten days later he could only count fingers at 3 to 4 m. distant, and the eye presented the ophthalmoscopic picture of intense congestion of the central retinal vein, haziness of the disc, ischemia of the central artery; i. e., the aspect of thrombosis of the central vein, lasting four months. A vascular affection was diagnosed from the heart, dullness extending to the left and the tortuosity of the temporal arteries.

Ten months later almost complete recovery had taken place, with V=5/xii and normal visual field. Therefore, a gradually increasing hemorrhage into the sheath of the optic nerve from a fissure of the optic canal seemed more likely to have been the cause of the intense disturbance of circulation in the retina. The result shows that the prognosis must be guarded in such cases and must not be pronounced unfavorable even after the affection has lasted for several months.

C. A. Oliver[23] describes a case of a 14 year old apprentice who was struck by a triangular wedge of steel about 2 inches long and ½ inch wide, and half an inch thick at the base, thrown by a fellow workman about 25 meters away. Seen fifty hours after the accident the lids were found swollen. V=5/xxv. Dense irregular subhyaloid hemorrhage in lower part of field proceeding from the inferior temporal vein. Nine months later full vision; no scotoma; striated retinitis and thicker vessel wall.

The Therapy consists of pressure bandage, rest, administration of calcium chloride, ergot, pilocarpin sweats, and mild cathodal galvanism.

Embolism of the vessels can hardly be classed as traumatic except in injury to the vessels behind the globe.

Air embolism from caisson disease may, however, be here considered, as it is vocational and of medico-legal importance.

This has been well described by Schapringer[33]. In cases of sudden blindness after coughing spells, air embolism must be thought of first. In support of this view Schapringer quotes Ewald and Kobert's remarks, viz.: "Whenever the pressure in the lungs reaches a certain height, small quantities of air enter the pleural space and the circulation, but no damage results from it to the organism, on account of the small quantities escaping in a short time." Schapringer suggests the same treatment as in caisson disease; i. e., to bring the patient into a pneumatic chamber and let him breathe compressed air for a considerable time. If there is no pneumatic cabinet at disposal, an attempt with inhalation of oxygen might be made.

Schapringer explains also the instantaneous blindness in whooping cough by embolism of the central retinal artery, or of the corre-

sponding parts of the brain in cases of hemianopia. Sudden blindness after hemorrhages from the stomach is likewise ascribed to air embolism. Pneumatic therapeutics ought to be applied in these cases as soon as possible after the attack before the critical moment has elapsed.

B e s t[34] observed, in a woman, aged 43, after extirpation of a goiter, of which a remnant was left, around the somewhat veiled disc of the left eye several large hemorrhages and white foci encroaching upon the disc. Under thyreoidin 0.1 a day the hemorrhages were almost absorbed within two months. After further six months there was only a small streaky

Fig. 313.
Rupture of the nerve. (Zimmerman.)

ecchymosis at the nasal side of the disc. An intercurrent administration of iodide of potassium was not well borne, as the swelling of the face increased. This was in accordance with the observations of Kocher, who found that iodide of potassium exerts a deleterious effect on the healthy remnants of the thyroid gland.

From the experimental arterio-sclerosis produced by extirpation of the thyroid gland in dogs, sheep and goats, Best infers the dependence of the intraocular hemorrhages in his case upon this operation. As injection of thyroid juice accelerates the pulse and lowers the blood pressure, and perhaps acts favorably on arterio-sclerotic changes of the blood ves-

sels, the author recommends thyroid tablets in the treatment of retinal hemorrhages, especially in glaucoma, in which favorable results from this substance have been recorded by Angelucci. Best warns, however, from too large doses, which may cause optic neuritis and atrophy of the optic nerve.

E. RETINAL VESSEL ANEURISM.

Rarely a new formation of blood vessels may occur in the retina after injury, as first described by Galezowsky[35] in a near-sighted and

Fig. 314.
Proliferating retinitis. (Zimmerman.)

weak woman who had been struck upon the eye by a key and 14 days later was nearly blinded. In the periphery of the inner half of the retina there was a tear and serous infiltration with tortuous vessels. Later on there developed in this place an aneurism, from the arterial twig, of the size of a pin head.

M a g n u s[36] described an arterio-venous retinal aneurism developing in the eye of a hospital attendant who two years before had been struck on the eye with a hard hand-cuff by an insane person. Arteries and veins could not be differentiated and a pulsating anastomosis of them existed 2½ disc diameters from the papilla.

LITERATURE.

1. Berlin, *Klin. Mon. f. Aug.*, 1873, p. 42, and *Graefe-Saemisch*, vol. vi, 2.
2. Hirschberg, *Centralbl. f. Prak. Aug.*, 1887, p. 37.
3. Haab, *Atlas Ophthalmology*, 1909.
4. Fuchs, *Text Book*, p. 500.
5. Schmidt-Rimpler, *Arch. f. Aug.*, xii, 2.
6. Hoch, *Wien. Med. Presse*, No. 1, 1880.
7. Aneke, *Centralbl. f. Prak. Aug., Apr.*, 1885, p. 313.
8. Haab, *Beitrag. z. Aug.*, xxii, p. 8.
9. Rosenhauch, *Arch. f. Aug.*, lxiv, 3, 1909, p. 289.
10. Butler, *Ophthalmoscope*, Jan., 1909.
11. Coats, *Royal London Hosp. Rep.*, vol. xvii, part 1.
12. Von Hippel, *Arch. f. Ophth.*, lxvi, 1, June, 1906.
13. Fuchs, ref. v. Hippel.
14. Reis, ref. v. Hippel.
15. Curt Cohen, *Klin. Mon. f. Aug.*, xlvi, 1, 1908, p. 620.
16. Zentmayer, *Ann. Ophth.*, July, 1909.
17. Wisselink, *Klin. Mon. f. Aug.*, 1905, ii, p. 385.
18. Twietmeyer, *Zeitschr. f. Aug.*, 1907, p. 447.
19. Haab, a. *Beitrag. f. Aug.*, xxii, p. 8, 1888.
    b. *Arch. f. Ophth.*, xxxiv, 1.
    c. *Atlas of Ophth.*, Amer. Ed., 1909, Fig. 48.
    d. *Atlas of Ophth.*, Fig. 47a.
    e. *Klin. Mon. f. Aug.*, July, 1897.
20. C. A. Oliver, *Trans. Amer. Ophth. Soc.*, 1896.
21. Praun, l. c., p. 383.
22. Reber, *Trans. Sec. Oph. A. M. A.*, 1910.
23. C. A. Oliver, *Ann. Ophth.*
24. C. Zimmermann, *Arch. Ophth.*, xxvi, 1, 1897.
25. Mans, *Arch. f. Ophth.*, xxii, 111, p. 229, and xxvi, 11, p. 55.
26. Banholzer, *Arch. Ophth.*, xxii, p. 212.
27. Schultze, *Arch. Ophth.*, xxii, p. 224.
28. H. Knapp, ref. Zimmermann.
29. Chodin, *Jahresbericht f. Ophth.*, xxv, p. 370.
30. Colucci, *Jahresbericht*, xxv, p. 238.
31. Wagenmann, ref. Zimmermann.
32. Hillemans and Pfalz, *Klin. Mon. f. Aug.*, 1905, ii, p. 373.
33. Schrapringer, *Centralbl. f. Prak. Aug.*, Dec., 1906, p. 358.
34. Best, *Zeitschr. f. Aug.*, xx, 1908, p. 548.
35. Galezowsky, *Rec. d'ophth.*, 1874, p. 368.
36. Magnus, *Arch. f. Path. Anat.*, lx, p. 38.

D. RUPTURE DIALYSIS AND DETACHMENT OF THE RETINA.

I. Isolated r u p t u r e s of the retina are seldom seen except when the eye itself is torn open, as in scleral rupture. In other cases they may occur together with that of the chorioid. (See plate.)

a. Isolated retinal rupture.

The vessels are broken and torn and the wound edges of the retinal laceration are rolled inwards, as shown in Haab's Atlas, Figs. 61 and 62,[3] where he states that it is not uncommon to find in retinal detachment a tear or hole of varying size and shape, often surrounded by a shred of membrane of a corresponding outline, which appears to have been torn out and floats in the vitreous. Moderate blood streaking is often observed in the vitreous. The chorioidal vessels show more plainly through

the opening than through the attached retina; often a tongue of retina is seen in the opening. Small tears are of no immediate moment, although the retina usually further detaches, as it always does where the laceration is of any extent. When the rupture is at the ora serrata it is practically a dialysis and leads to further detachment.

I saw such a case in a woman who struck her face against a door-jamb in the dark, in which almost the lower half of the retina was broken away from its attachment at the ora serrata.

Scheffels[2] reported two interesting traumatic cases, in one of which there was a circumscribed rupture at the ora serrata with but little detachment, and in the other a more considerable detachment in the same situation.

Fuchs[3] reported a case of laceration of the retina without dialysis at the ora serrata after discission and reclination of a cataracta aridoliquidata in which a coloboma of the retina was produced by the manœuvre.

b. Rupture of the retina accompanying rupture of the chorioid.

At the same time as the rupture of the chorioid the retina may also break, usually in a line with that of the chorioid, either through the direct force of the contusion or secondarily from the pressure of sub-retinal hemorrhage in the blood seeking a passage into the vitreous. In such combined ruptures the function is lost immediately except in minor defects, where in the most favorable cases a visual field defect follows, but as a rule from shrinking of the vitreous a decided detachment of the retina results.

In a boy struck by a whip lash two weeks before, quadruple ruptures of the chorioid were produced, between the disc and the macula, and below there was found a long tear in the retina with hemorrhage into the vitreous and pigment immigration. As the case was only seen in consultation the outcome is unknown to me.

c. When the bulb capsule is opened by rupture.

The chorioid and retina participate in the damage as well as the sclera. Müller,[4] however, in his large series of typical scleral ruptures only found one case in which the retina was torn. Praun[5] says that in gun-shot injuries affecting the optic nerve in the orbital region, pulling it out of the bulb, the retina is often torn away from the papilla by a ring-shaped opening.

II. A TRAUMATIC RETINAL DETACHMENT.

Dislocatio, ablatio sive amotio retinæ.

Dislocation of the retina is a solution of its contiguity with the chorioid, having a tendency to enlarge and become total, probably always

happening through some form of trauma. Myopic eyes in which the vitreous does not completely fill the globe are especially predisposed to the affection.

Etiology. For those cases where the detachment may be actually traced to a trauma it may have been from a poke in the eye, a blow, a

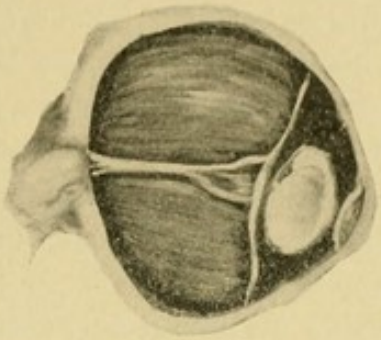

Fig. 315.
Total detachment of retina; calcareous lens.

thrown object, or an opening of the ocular envelopes by a wound with resultant cicatricial changes in the vitreous.

In traumatic detachment five causes are to be differentiated: 1. Inflammatory retraction of the vitreous with adhesion to the retina. 2. Retinal tears. 3. Post-retinal hemorrhages. 4. Cicatricial contraction of a scleral wound. 5. Sudden collapse of the eyeball, with addition of

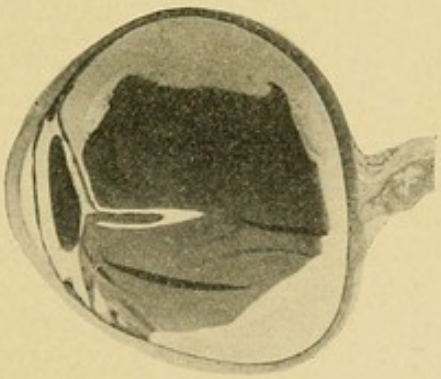

Fig. 316.
Detachment of retina.

trauma. Only in the first group does the vitreous play an active rôle. When adhesions were absent there was detachment of the vitreous.

The retina simply lies upon the chorioid without being connected with it anywhere except at the papilla and the ora serrata, being kept pressed against the chorioid by the vitreous. A detachment is possible only when either the pressure exerted by the vitreous ceases to act, or when the retina is pushed away from its bed by a force greater than this pressure.

In the case of injuries or operations when a large quantity of vitreous is lost with shrinking of vitreous in consequence of exudative organization and contraction, especially after irido-cyclitis and irido-chorioiditis, favors the condition.

The detachment of the retina, in an unopened eye, through direct trauma, is of rare occurrence except as a secondary result of contraction of exudation from the chorioid, which I have found to be serum tinged with blood pigment or a hemorrhage from the chorioidal vessels.

Detachment of the retina is most common in men between the ages of 44 and 60. The chief exciting causes are those agencies that increase intraocular strain, such as lifting heavy weights, stooping, vomiting, constipation, childbirth, sneezing, severe injuries to the globe or its neighborhood, etc.

A table, representing an investigation of 300 cases of separation of the retina, examined in Horner's klinik, furnishes a satisfactory clinical

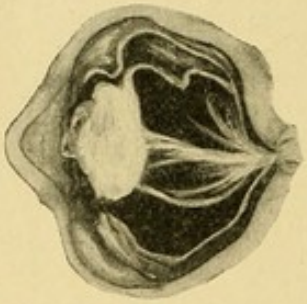

Fig. 317.
Detachment of retina and chorioid. Atrophia bulbi.

index of its pathogenesis, especially of the predisposing causes, is given by Casey A. Wood[6]:

Myopia	144 cases,	48 per cent.
Injury	49 cases,	16.3 per cent.
Iritis, uveitis	11 cases,	3.6 per cent.
Chorioiditis	10 cases,	3.3 per cent.
Hemorrhagic diathesis	23 cases,	7.6 per cent.
Congenital anomalies	2 cases,	0.6 per cent.
Congestive causes	11 cases,	3.6 per cent.
Opacities of the vitreous alone	22 cases,	7.2 per cent.
Idiopathic detachments	28 cases,	9.3 per cent.
	300 cases,	100 per cent.

Myopic and senile detachments are likewise serous, due to loss of pressure of a fluid or partly degenerated vitreous and imbibition of fluid therefrom. It is probable that in all such cases, however, a slight trauma, as a blow or jar of the head or body, may be the exciting cause of the actual detachment. A third cause is tumor of the chorioid, or cysticercus forming beneath the retina.

Von Hippel[7], out of 100,000 patients, found that 529 had myopia greater than 14 D.; i. e., 0.53 per cent; and in 842 myopic eyes, spontaneous detachment of the retina was observed in 53; i. e., in 6.3 per cent. Detachment in his patients was possibly due to the operation of extraction of the lens for high myopia (13 times; i. e., 4.9 per cent). In 7 of these von Hippel attributes the detachment to frequent operation, yielding to the solicitations of his patients. In the remaining 6 the cause of the solution seemed doubtful, since neither the operation nor the course of healing gave a direct provocation. He says further: "A condensation of fibrillar character may be presented in the microscopic picture of the elements of the vitreous structure by a marked degree of constriction. This is possible: (a) in consequence of hardening (an artifact); (b) the result of compression (e. g., in chorioidal and extraocular tumors); (c) as a vital shrinking of the vitreous body."

He sought to determine experimentally whether a vitreous of the

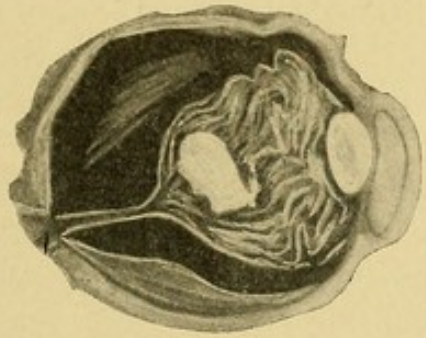

Fig. 318.
Total detachment of the retina.

consistence of albumin, which, in life, completely filled the bulbar cavity, could by hardening in Müller's fluid, by expression of the albuminous fluid be drawn together into the anterior portion of the cavity. It was found that the uniformly coagulated vitreous filled the space between the lens and retina, and in neither case was the retina dragged forward, and an albuminous coagulated fluid layer found between the vitreous and retina.

Leber[8] found with great constancy, in his anatomical specimens, changes which must be ascribed to retraction of new-formed cellular-fibrous tissue at the interior surface of the retina and in the vitreous.

Best[9] concludes that if the consistency of the vitreous, the firmness of the retina and its cohesion with the pigment epithelium are changed, as in senile and myopic eyes, by gradual summulations, this constant traction may become the cause of idiopathic detachment of the retina.

Symptoms. In traumatic cases the ophthalmoscopic view may be at first obscured by opacities of the media, such as hemorrhages into

the anterior chamber and vitreous. Externally the eye looks normal, only the anterior chamber is often strikingly deep and the tension is diminished. The ophthalmoscope shows, in a pronounced case, a delicate grayish membrane back of the pupil projecting into the vitreous, rising above the level of the fundus and, being focused with a convex lens, varying according to the projection, upwards to ten, or more, diopters. Over this the retinal vessels are seen to course, interrupted as they dip into the folds of the membrane, and are thus lost to view. If the sub-retinal fluid be serous, a slightly greenish color is seen, if the fluid be blood or tinged by blood the color is dark gray or reddish.

The detachment may develop at any spot, but usually changes to the lower part of the fundus on account of the effect of gravity on the subjacent retinal fluid. In traumatic cases there is a greater tendency to be reapplied to the chorioidal surface than in myopia, and hence cure of such cases may be expected by proper treatment.

The subjective symptoms consist in the disturbance of vision, especially a limitation of the field, usually upwards from the detachment being below. In the beginning of a detachment there is often dazzling and metamorphopsia. This is often perceived by the patient as a dark cloud corresponding to the portion detached. The patient complains of a dark curtain which veils him from the upper part of objects, as, for instance, he may see the body but not the head of a man standing in front of him. Hence the examination of the visual field is of great importance for the diagnosis. In total detachment the blindness is absolute.

M ü g l i c h[10] collected 136 cases of detached retina from the literature in which the retina became reattached without surgical intervention. Healing occurred 42 times in myopic eyes, 11 after albuminuric retinitis, 12 after trauma, 10 after chorioiditis syphilitica, 5 after ordinary chorioiditis, 3 after operation, and 50 without diagnosis of the cause of detachment.

A d a m ü c k[11] reported three cases of reattachment after traumatism.

A woman, aged 57, had an extensive detachment of the upper portion of the retina, commencing above the upper temporal vessels, with a rupture at the upper lateral periphery. It was gray, very prominent, but not floating. The vitreous body contained large opacities. V=5/x, with defect of the lower half of the visual field. After the patient had been treated with lying in bed, diaphoresis, iodide of potash, for two and one-half weeks, the retina seemed reattached, but, immediately after her leaving the bed, became again detached. Within three months the detachment had as usual settled downward.

At the next examination, one and one-half years later, the retina was reattached all over and the former rupture could not be detected. There

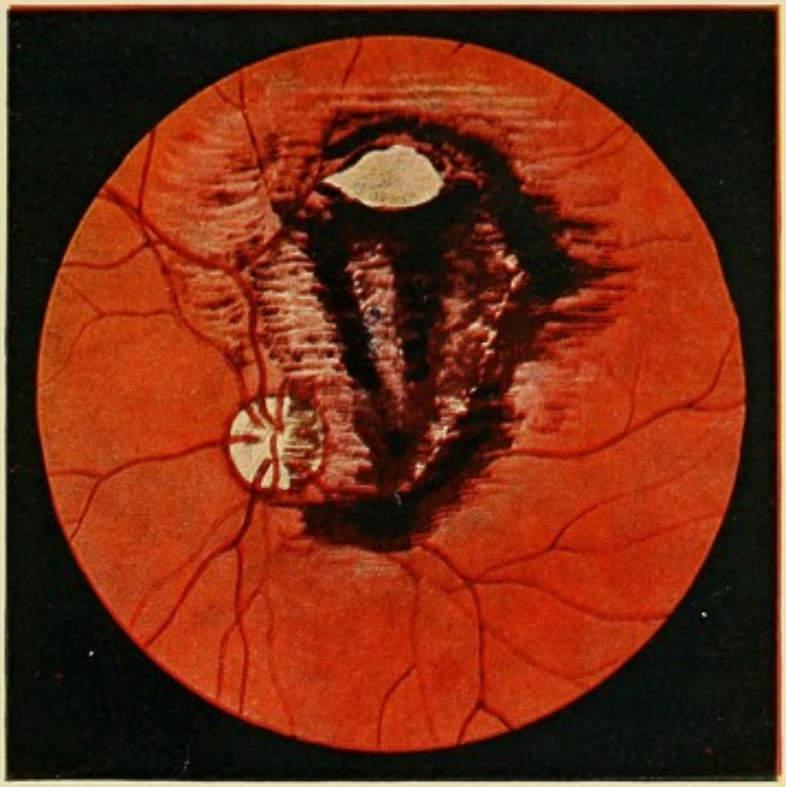

PLATE XII

Point of impact of a foreign body in the fundus and blood clot in vitreous.

was one large immovable opacity of the vitreous and a few very small floating ones. The patient related that she had run against a tree with the right side of her forehead and sustained such a severe contusion that she fell down, bleeding from forehead and occiput. The sight of the right eye then steadily improved, with full recovery within three months. Probably the contusion caused a rupture of the detached retina and admitted the subretinal effusion into the vitreous. This pressed the retina against the chorioid, to which it became agglutinated by hemorrhages into the subretinal space.

Hirschberg[12] reported the case of a woman, aged 50, who, from her sixteenth year, remembered to have been myopic, but never wore glasses. Accidentally injured by a shoe hurled against her right eye, she noticed a fine-dotted, movable veil before this eye, and three weeks later a fixed dark wall, when she applied to Hirschberg. V = perception of the light of a candle at 2 cm.; projection uncertain, was lacking below. T. very much diminished. Detachment of upper portion of retina, which showed a rupture near the lower border. Treatment had to be limited to rest, slight diaphoresis, idodid of potash; a bandage was not tolerated. After three days the soft, painful form of detachment, described by Hirschberg, was fully established. T. —3, very deep anterior chamber, great sensitiveness to pressure, a synechia downward, vitreous very hazy. A month later an improvement was noticeable; anterior chamber was not as deep; tension almost normal; V = fingers at 2 m.; but the retina was detached all over, with two ruptures in its upper prominence. After two months further the retina was reattached, opacities of vitreous and blood were seen at the lower portion, and four weeks later recovery was complete. No trace of the ruptures could be seen, only slight opacities of the vitreous and pigment changes remained. Hirschberg cannot recall having seen a similar case.

Complications. The usual complications are degeneration of the vitreous with minus tension and subsequent cataract, but Hoor[13] and Gonin[14] reported a case of glaucoma, following a traumatic retinal detachment in a workman whose eye had been struck by a piece of iron, which had to be relieved by iridectomy.

In a woman on whom I had about a month before incised the sclera, relieving the subretinal fluid and seeming reattachment of the retina, thereby an acute attack of glaucoma occurred with loss of vision from the regained 6/xii to movement of objects. Withdrawal of atropin, instillation of eserin and free purgation by salines relieved the attack after three days. The vision at present writing is 6/xii and the retina firmly anchored in the lower part where formerly detached, although not completely reapplied to the chorioid.

Diagnosis. The grayish, floating membrane in the vitreous, projecting anteriorly and in focusing which the retinal vessels are seen to course, is pathognomonic. The visual field is contracted, corresponding to the portion of the retina detached. The tension is diminished and the anterior chamber usually deeper than normal. Differential diagnosis must be made between Berlin's opacity, in which the level of the retina is normal and the vessels uninterrupted, and especially as regards chorioidal sarcoma. In many cases of the latter the diagnosis has not been made until too late to prevent metastasis by enucleation, the cases being labeled as retinal detachment. Such an error of observation is nowadays inexcusable.

In the traumatic and myopic forms the portion detached, when viewed with the ophthalmoscope, generally appears as a grayish mobile surface, composed of folds, creases and undulations. Over all run the sinuous retinal vessels, arteries and veins, both showing darker than normal, and no sign of the underlying chorioid is visible. In detachment secondary to a tumor—which is nearly always a sarcoma—the retina over it is smoother: i. e., not thrown into folds; the limits of the retinal separation are more sharply defined; the whole is but slightly movable, or not at all; the retinal vessels, save at the borders of the detachment, are much less tortuous. In short, its aspect is more that of a sort of dome—more or less rigid. Unfortunately, these characteristics are by no means constant, but merge into each other in the two forms. The surface of the detachment must be studied minutely, with dilated pupil and very strong illumination, preferably by the direct method. By using a concave mirror held very close to the eye, and turning on various convex lenses, one can examine not only the surface, but can, in a measure, look into the detachment, as it were. In this way one may often see pathognomonic evidence of the presence of a neoplasm. When a detachment is situated between the equator of the globe and the ciliary body, and the signs just mentioned are not positive, the transilluminator may render great service. Another sign of great value, when present, is a bloody infiltration of the detached retina, evincing a tumor. Minor signs are those, for instance, as to location. A tumor is to be suspected when a circumscribed detachment appears at the vault of the vitreous chamber, or in the macular region. Detachment with hypertension, be it ever so slight, is suggestive of a tumor. So is slowly progressive failure of vision, instead of sudden or rapid; as also the persistence of good or fair vision with a rather extended detachment. Close study of the field of vision may furnish a clue. The limits of the scotoma in simple detachment are less precise than are those of the secondary variety. The examiner should remember that, in rare instances, the tumor is found diametri-

cally opposite to the point where the detachment is located. Hence the importance of close scrutiny of the entire fundus.

Pfalz[15] ventilates the question, How long after a traumatism by a blunt force may a detachment of the retina, which with the greatest probability was caused by the former, remain undiscovered by our methods of examination? Pfalz saw a case four days after the accident. Vision was somewhat impaired, but the eye looked normal, aside from some scratches on the lids at the point of impact. Four weeks later vision was almost normal, but the pupil was enlarged and acted sluggishly. After three days detachment of the retina could be ascertained. Pfalz surmises there was at first slight detachment near the ora serrata caused by the contusion of the eye. The attachment of the retina at this point being tighter, the detachment remained at first circumscribed and gradually became more extensive. The period between injury and the possibility of diagnosing the detachment must, however, be limited, and very likely is shortened by physical exertions or concussions.

Onken[16] reported a man, aged 19, who complained that he had been unable to see with his right eye for two days. There was a large floating detachment of the retina upward, later on downward. The patient, being questioned with regard to an injury, stated that five weeks before he received a blow from the handle of a harrow. Probably this was directly followed by edema or a slight detachment of the anterior portions of the retina, without arousing the attention of the patient, who had always had very poor vision, being myopic from early childhood (—15 in left eye). Onken recommends, after injuries by blunt objects, very careful ophthalmoscopic and perimetric examinations for changes, especially in eyes predisposed to detachment, the diagnosis of which may be of great prognostic and therapeutic importance.

Asmus[17] on Oct. 26, 1905, had an iron worker, age 24, come to him on account of failure of sight of the left eye, which, he said, had set in the day before. T. — 1; pupil does not react directly to light; retina detached upward and outward in large gray folds; fluctuating. No other intraocular changes; no myopia. V = motion of hand outward and upward. The anamnesis, however, revealed that in April, 1904, while chiseling, a piece of iron flew with quite a force against his left eye, so that he saw poorly for two days, but did not discontinue his work. An oculist had found a hemorrhage in the white of the eye close to the corneal margin.

If the possibility of late detachment of the retina after traumatism is accepted at all, the author claims it for this case. Very likely a peripheral flat detachment was produced by the foreign body, but was not noticed by the patient until it became more central and caused a perceptible defect of the visual field.

Strict proof can never be furnished, as detachment of the retina may occur in normal eyes without previous injury. Asmus[17] quotes such a case in a painter, aged 19, with a large detachment of the retina downward, who could not remember ever having met with an accident. Treatment with bandage, diaphoretics and iodid of potash for several weeks was unsuccessful.

Schwarz[18] reported a blacksmith, age 24, who sustained a perforating injury of the sclera by a piece of iron which had broken off a piston. In the gaping vertical wound, 2.5 mm. distant from the temporal margin of the cornea, the ciliary body could be seen. Recovery after suture, with V = 5/viii. No changes of the fundus remained, but paresis of accommodation. Eight years afterwards detachment of the retina downwards, inwards, and outwards; opacities of the vitreous, and in or under the anterior capsule of the lens fine gray stripes, converging towards the scar of the sclera, were noticed. V. L. = 1/xxxvi.

Apparently there was a retracting scar of the ciliary body, adherent to the sclera, which exerted traction on the surrounding parts and was the cause of the detachment. The fine stripes on the lens most likely were traction folds of the zonula and capsule of the lens, caused by the cicatrix. The paresis of accommodation which remained after the injury had been healed indicated damage of the ciliary body.

Schwarz recommends a careful search for these symptoms in cases of late detachment. A positive result would suggest the existence of cicatricial changes in chorioid and ciliary body.

V. Ammon[19] reports two cases in which detachment of the retina occurred, four and three weeks, after contusion of the eyes, and found a third one in the papers of an accident insurance company. The author emphasizes the great practical importance of these observations for adjusting claims for accident.

E. Cramer[20] reported a man, aged 52, who received a blow from a thrashing flail on the inner angle of the left eye, between the root of the nose and the orbital margin. He lost consciousness and fell down. The eye was red, but there was no subconjunctival hemorrhage, and vision was not disturbed. Five weeks later the patient complained of fluttering before his eye, which, in a few days, turned into practical blindness. Cramer found an extensive, even, non-vascular detachment of the temporal half of the retina. In the lowest and most peripheral portions the detached retina showed an irregular rupture, with its ends curling up, through which the normal chorioid could be seen distinctly. This rupture lay opposite the point of impact. Apparently the end of the thrashing swingle had produced a violent, isolated contusion of the inner upper segment of the eyeball, which led to a fine rupture on the opposite side, without symptoms, on account of its peripheral seat and slight dimen-

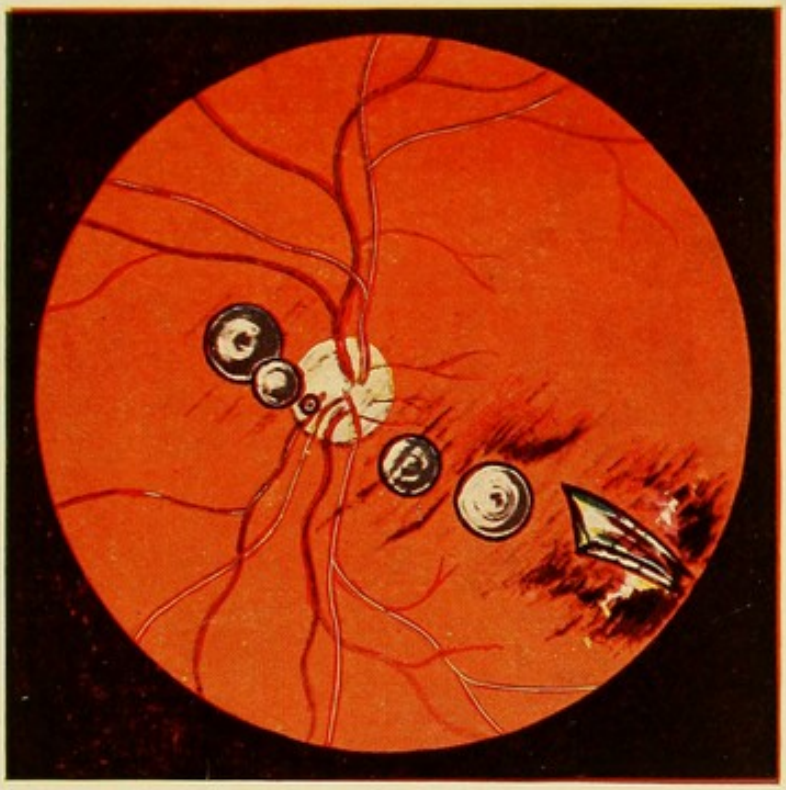

PLATE XIII

Glass chip in vitreous with air bubbles in course of wound through vitreous.

sions. Gradually serous fluid from the vitreous collected between the wound edges, widening the gap and thus making room for post-retinal effusion with its consequences. Since the other eye was amblyopic and showed posterior cortical cataract, prognosis of regaining vision after operation being very uncertain, the knowledge of the occurrence of secondary detachment was of utmost importance to the patient.

Weill[21] reports two cases of contusion of the eyeball of healthy emmetropes by weights of several pounds falling from considerable height, in which the symptoms of detachment of the retina set in respectively two and four weeks later. Although spontaneous detachment of the retina may occur in emmetropes and hypermetropes (W. had at the same time two such cases under treatment), the solution was undoubtedly the direct consequence of the accident. He leaves it undecided whether the separation of the retina in these cases starts from a peripheral rupture of the retina, which cannot be detected with the ophthalmoscope, or whether, according to Pfalz, a peripheral detachment takes place immediately after the injury. He advises, however, to treat patients with severe contusions of the eyes with rest in bed, even if the first examination does not reveal changes in the fundus, on account of their dubious prognosis and threatening detachment of the retina.

Prognosis. Traumatic detachment of the retina is more apt to be cured either spontaneously, medicinally or by operation than in the case of idiopathic types. It is less apt to spread and we always hope for healing.

Sattler[22] says the smaller the detachment and the more recent the case the more encouraging the prospect.

Schoeler[23] says that the most successfully treated cases are recent, present a clear vitreous and a bagging of the detached retina.

Fuchs[24], however, says: "It is generally possible in recent and not too excessive cases of separation of the retina to obtain an improvement of the sight by partial reattachment of the retina, and, in especially favorable cases, even to cause the detachment to disappear completely. Unfortunately, it is only in the rarest cases that these good results are lasting," etc. Such, however, has not been my experience nor that of many recent writers (see Therapy). Where a laceration of the retina also occurs a permanent visual field defect obtains and when the retina is completely loosened, cataract, optic nerve atrophy and atrophia bulbi completes the clinical picture.

Therapy. Praun[25] dismisses the subject with the words "Ruhelage und Druckverband, pilocarpin injektionen." However, many advances have been made in therapeutics during the last decade and in the treatment of retinal detachment we have taken a great step forward. Even if we may not secure a complete reattachment, yet in many cases we may

anchor the retina down to the ocular envelopes in several places and give what seems to the patient a satisfactory cure, for this has been my experience.

The hopes of both patient and surgeon are often doomed to disappointment because of secondary detachment of the replaced retina. It quite frequently happens that, after a complete reposition of the separated membrane (with demonstrable increase in both central and peripheral vision lasting for a considerable time), the retina is once more torn away from the chorioid. This accident, due to various causes, has, in many instances, taken place while the patient was quietly lying in bed, under atropia and wearing a bandage.

Casey A. Wood[6] says a ray of comfort and hope is thrown upon this discouraging fact in the surgical conduct of separated retina in that quite a number of brilliant and permanent cures have followed persistent treatment and the repetition of operations, in spite of these relapses. In my opinion, it is desirable in the preliminary discussion with the patient of the "pros and cons" of proposed operative measures that this irregular course of the disease be frankly stated. No surgical intervention should be undertaken unless all parties to it are willing to have the patient submit to repeated operations as long as there is a chance of recovery. Deutschmann, for example, has finally succeeded in several cases of relapse, after operating a dozen times or more.

In 1892, a gentleman from Kansas, who had one highly myopic eye, was induced by an osteopath, who was massaging him, to allow him to massage this eye to "work some sight back into it"; two days later the eye became more blind from loss of a portion of the visual field. He was sent to me by his physician for operation and I found localized retinal detachment. Rest in bed with pilocarpin sweats, which offer the best hope in other than traumatic cases, were used without result, but three incisions over the site of the retinal detachments permitted the subjacent retinal fluid to exude and restored the retina to place, patient leaving the hospital two weeks after the operation. Two days after his return home the retinal detachment recurred, probably from going up and down stairs. This shows the futility of operative procedures for detached retina in high myopia.

In a moderate myope (6 D.) who suffered an injury to the head, which was followed by a partial loss of one eye, the retina was restored to its place, and the subjacent liquid absorbed, by ten days' rest in bed with pilocarpin sweats. After five years the detachment had not recurred.

In a plumber who seven months before had a blow upon the eye from a piece of piping there was retinal detachment downwards. V=5/1. V. F. contracted upwards. The iris of this side was of a brown color, while

the other eye was blue. By scleral incision a brownish serum was let out and the retina returned to place. One month later V=6/xviii and no detachment could be observed, the incision part showing striæ retinales at right angles to the incision. Vision remained good for several years, but ten years later he returned with a blind eye from secondary cataract and presumable recurrent retinal detachment, as the anterior chamber was deep, the tension subnormal and the pupil reacted only consensually to light. The contrast in the color of the eyes was more marked than at first.

b. Striæ retinalis following traumatic retinal detachment.

Etiology. Fuchs[26] reiterates his claim that a real spontaneous case of retinal detachment with reattachment of the retina does not occur. If a functional cure be made, yet a portion of the retina seems so greatly damaged as to have but little functional power, and can readily be made out by the ophthalmoscope; the fundus in the region concussed is spotted, and frequently traversed by rectilinear striæ, either pure white or lined with pigment, and which lie in front of, back of, and along the retinal vessels, being formed by strands of connective tissue from organization of the sero-fibrinous sub-retinal exudate, retinitis striata. The whole affected area is separated from the remaining normal fundus by a sharp, usually curved line, yellowish or gray and surrounded by pigment.

Praun[27] makes a distinction between retinitis striata and striæ retinales, the former being a pigment degeneration process from a chorio-retinitis, and the latter due to bands of white fibrin, and should be rightly denominated striæ sub-retinales. The striæ are not always parallel, but may converge toward one another, the direction depending upon the stretching of the retina, if from the papilla the striæ converge. There are cases without pigmentation as well as with. Prevascular striæ come from hemorrhages in and in front of the retina and are of the same character as those of retinitis proliferans. Manz[28] ascribed them to proliferation of the sublenticular fibres of Müller in the retina. The stripes lie both in front of and behind the retinal vessels.

Perivascular striæ occur along the vessels from perivascularitis, and have no particular relation to trauma. Such, however, may follow an incised wound of the sclero-chorioid and retina, as shown in a case where an oculistic quack, who "cured" everything from diabetes to diarrhea, by operating upon the ocular muscles, in doing a "graduated" tenotomy, cut through the sclera, chorioid and retina with his scissors, producing a most picturesque condition of the fundus, as I saw it about a year later. A large, spear-shaped, white cicatrix existed, temporally from the fovea, deeply pigmented at its edges with convergent striæ

retinalis and pigment changes from a striate retinitis, with perivascular striæ, macular disease similar to that of Haab and optic nerve atrophy. The condition well represented all three forms of retinal striation and is depicted on accompanying plate.

Retrovascular striæ are due to organization of the sub-retinal exudate, as described above. Many such cases have been reported. In a case of "healed" retinal detachment I found a marked retinal striation with whitish bands arranged nearly parallel on either side of an intensely pigmented stripe along the center of which could be observed a thin, strongly glistening line. (See plate.)

de Schweinitz[29] remarks upon retinitis striata following cured retinal detachment in a woman with 5 D., the detachment being raised to + 1 D. Treatment by rest in bed, pilocarpin injections, sodium salicylate. Thirteen days after she got up with reattachment which remained at end of five weeks. There was a dark line bordered by white stripes, bifurcated at its commencement near the macula and slightly frayed out at the other end with a white channel in its center.

He agrees with Caspar[30] in thinking that some cases of retinal striation, if not all, are end stages, or the remains of cured retinal detachments.

LITERATURE.

1. Haab, *Atlas Ophthalmoscopy*, Amer. Ed., 1908, Figs. 61, 62.
2. Scheffels, *Arch. f. Aug.*, xxii, 2, 3.
3. E. Fuchs, *Klin. Mon. f. Aug.*, Dec., 1877.
4. Müller, *Ueber Ruptur der Corneo-Skleralkapsel*, etc., 1895.
5. Praun, l. c., p. 387.
6. Casey A. Wood, *System of Ophthalmic Operations*, 1911.
7. von Hippel, a. *Deut. Med. Woch*, No. 26, 1905. b. *Arch. f. Ophth.*, Apr., 3, 1908.
8. Leber, 35 *Cong. Ophth. Soc.*, Heidelberg, 1908.
9. Best, *Klin. Mon. f. Aug.*, 1904, 11, p. 538.
10. Müglich, *Inaug. Dissert.*, Marbourg., 1891.
11. Adamück, *Ophth. Bote. Kiew.*, July, Oct., 1890.
12. Hirschberg, *Centralbl. f. Brak. Aug.*, March, 1907, p. 72.
13. Hoor, *Wien. Klin. Woch.* No. 10, 1888.
14. Govin, Dil. *Ophth. Klinik*, Nos. 17, 18, 1904.
15. Pfalz, *Zeitschr. f. Aug.*, xii, p. 36, 1905.
16. Onken, *Zeitschr, f. Aug.*, xiv, p. 165, 1905.
17. Asmus, *Zeitschr, f. Aug.*, 1906, xv, p. 444.
18. Schwarz, O., *Zeitschr. f. Aug.*, Jan. 1907, xvii, p. 54.
19. Ammon, *Zeitschr. f. Aug.*, 1901, xi, p. 406.
20. E. Cramer, *Zeitschr. f. Aug.*, 1905, xiii, p. 31.
21. Weill, *Zeitschr. f. Aug.*, 1906, xv, p. 140.
22. Sattler, *Deut. Med. Woch.*, 1 and 2, 1905.
23. Schoeler, *Zur operative Behandlung der Netzhaut Ablösung*, Berlin, 1889.
24. Fuchs, E., *Text book*, p. 495.
25. Praun, l. c., p. 389.
26. Fuchs, *Text book*, p. 496.
27. Praun, *Beitr. Aug.*, xii, p. 104.
28. Manz, *Arch. f. Ophth*, xxii, 3, p. 229, and xxvi, 2, p. 55.
29. de Schweinitz, *Ophth. Record*, Aug., 1900.
30. Caspar, *Arch. f. Ophth.*, 1897, p. 80.

BLINDING OR DAZZLING OF THE RETINA.

Dazzling or glare of the retina has been quite fully treated under Injuries from the Sun's Rays. It is a combination of photo-chemic and heat injury, mostly due to the effect of the ultra-violet rays.

Haab and Siegfried[1] say that "In all cases of direct gazing at the sun there is danger of a scotoma being permanently made, more or less as large as the size of the sun picture in the retina, the point of fixation"; the permanent damage being little less than at first. Macula lutea has the most delicate anatomical structure of any tissue of the eye and is specially vulnerable. It is likewise affected by the commercial electric light. We must not confound this condition with that of so called snow-blindness, which is due to irritation of the conjunctiva and cornea.

LITERATURE.

1. Haab and Siegfried.

F. INJURIES TO THE RETINA FROM FIREARMS.

Besides the wounds produced by shot pellets or portions of bullets or grains of powder, etc., passing through the coats of the eyeball and thus injuring the retina, described elsewhere, this delicate membrane may likewise be greatly injured by contusion and concussion, either from the results of the projectile or from the concussion of the air due to the explosion. The latter was markedly manifest at the explosion of the Roburet factory. (Stoewer.[1].)

The most common condition of the retina produced by firearms, aside from those first mentioned, are edema, hemorrhage, rupture, and detachment.

Commotio retinæ or Berlin's opacity occurs from direct shots, spent or glancing balls and in indirect lesions where the ball enters the orbit or its neighborhood, producing a violent concussion. Von Oettingen[2] reported five cases of retinal edema from firearms.

Hemorrhage into and under the retina often comes from contused shot injuries of the globe, presenting a similar picture to that of retinal hemorrhages caused by other contusions. If it affect the macula there will be a central scotoma.

Cohn[3] saw a soldier injured when a grenade exploded and a piece flew against the eyebrow. Patient was knocked senseless and was at first blind, later seeing peripheral hand movements. Vision gradually returned with metamorphopsia. A prominent, dark-brown, pigmented spot occupied the macula.

Bleeding under the retina also occurs, as shown by the sanitary report of the Franco-Prussian War, from an examination of an enucleated eye.

Rupture of the retina is found in connection with that of the sclera and chorioid. In only a few cases has it been seen alone, and in these from bullet wounds of the nerve when the latter has been torn out of the eyeball.

Detachment of the retina is common after shot injuries. It is usually due to sub-retinal bleeding, or in the case of perforation may follow the loss of vitreous. Secondary detachment of the retina follows all forms of degenerative processes in the vitreous.

LITERATURE.

1. Stoewer, *Klin. Mon. f. Aug.,* March-Apr., 1907.
2. von Oettingen, *Der Indirekten Schossverletzungen des Auges,* Stuttgart, 1897.
3. H. Cohn, *Schussverletzungen des Auges,* Erlangen, 1872.

CHAPTER XXV.

INJURIES OF THE VISUAL NERVOUS SYSTEM. THE VISUAL SPHERE AND OPTIC NERVE.

Medico-legal significance—Amblyopia—Amaurosis. A. Injuries to the cerebro-visual sphere—Anatomy and physiology—Physical—Cortical—Psychical—Verbal blindness—Gun shot injuries of the visual centers—Aphasia—Ideographic blindness—Anatomy — Hemianopsia — Statistics — Literature. B. Injuries to the optic nerves—Anatomy—Pathology—Blindness without direct injury—Symptoms—Tearing of nerve from chiasm—Pressure blindness—Diagnosis—Hemianopsia—Prognosis—Therapy—Literature. C. Injuries to the optic nerve within the optic canal—Anatomy. (a) Wounds and Foreign Bodies. (b) Hemorrhage. (c) Direct laceration and contusion in fracture of optic foramen—Etiology—Sequence of symptoms—Optic nerve atrophy—Nature of traumatism—Statistics. D. Injuries to the optic nerve in the orbit between the foramen opticum and the bulb. (a) Wounds—Anatomy—Etiology—Symptoms and course—Ophthalmoscopic signs—Gunshot injuries—Complications—Diagnosis—Prognosis—Therapy. (b) Foreign bodies. (c) Injuries from blunt objects—Cubic contents of orbit—Evulsio nervi optici—Symptoms and course. (d) Gunshot injuries—Literature. E. The ophthalmoscopic signs of injury to the optic nerve — Experiments — Mechanism — Symptoms — Complications—Diagnosis—Prognosis—Literature. F. Injuries to the optic papilla—Wounds—Foreign bodies—Pathology—Symptoms and course—Therapy—Optic neuritis after blow on head—Literature.

Medico-legal reports of accidents occurring to persons working in various industries should of necessity be exact as to the determination of the etiology and prognosis of certain visual troubles, such as amblyopia and amaurosis following traumatism of the head.

Many cases of amaurosis follow, as is well known, a blow on the head, of which the pathogeny is indirect fracture through the optic canal, or an effusion of blood in the nerve sheath. But more frequently is it the case where, following a trauma of the cranium, the injured person, in good faith or not, claims the visual loss to be due to the injury, while the lessened vision may have existed prior to the accident.

There is differentiation to be made between central injuries, those due to damage to the visual sphere, those to the conducting apparatus, the optic nerve and to the peripheral end of the optic apparatus, the retina and other parts of the eyeball.

In this chapter it has been deemed best to briefly refer to certain

points in the anatomy and physiology in order to properly elucidate the relations of head injuries to loss of vision.

A. INJURIES TO THE CEREBRAL VISUAL SPHERE.

Anatomy and Physiology. Clinical evidence and physiology agree that the visual sphere of the cortex is located on the internal surface of the occipital globe in an area chiefly comprehending the calcarine fissure (Henschen[1]). Its limits are undecided. The same may be said in regard to the limits of other functions, as none is rigorously localized in the cortex, whose function is not only to collect the impulses, but to put them in conflict with each other, thus extracting the elements of knowledge from them, and to send them forth in the form of motor ac-

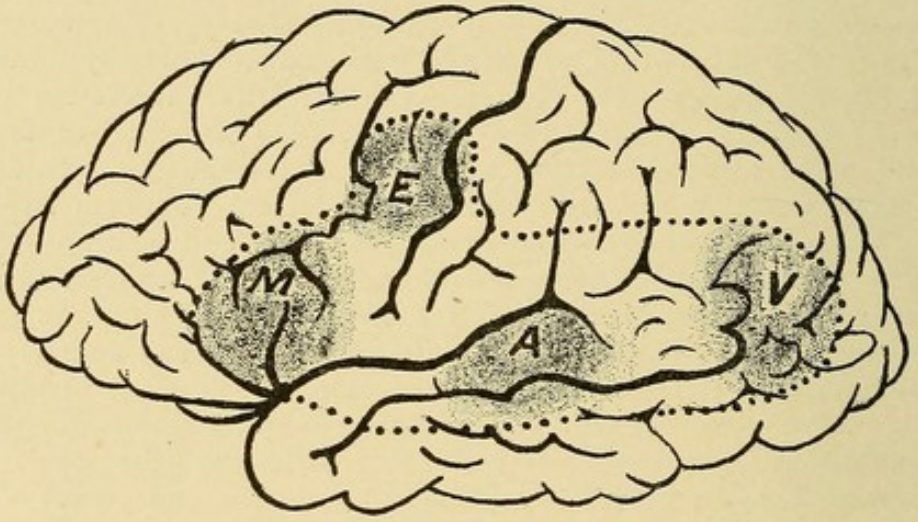

Fig. 319.

Area of language and its four centers of images: A. Center of the auditory images of words (center of Wernicke); M, center of the motor images of articulation (center of Broca); V, center of the visual images of words; E, ideographic center. A dotted line indicates the limits of the area of language as a whole.

tivities. Previous observations have regarded the gyrus angularis as being the cortical center. Morat[2] explains this by the anatomic fact that the optic radiations, in their journey from the basal ganglia to the occipital lobe, pass slightly below the cortex of the angle gyrus, and are easily cut or compressed by changes affecting the latter. The cortical sphere has to do with both luminous sensation and natural vision. Conceptions of form, space, locality, and of orientation are herewith determined, perhaps with the aid of other centers which are not yet estimated.

Blindness may be limited to colors, or to both white light and colors, and may be partial or complete for either.

There is a difference between the physical and psychical image. The image may be properly formed on the retina and carried to the visual

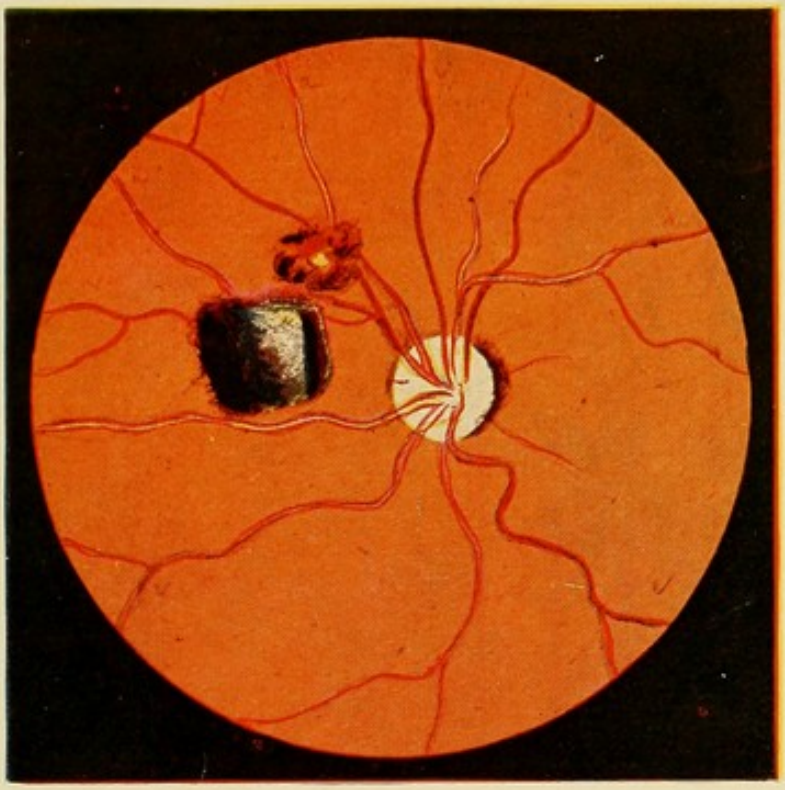

PLATE XIV

Steel chip in vitreous

sphere without the latter perceiving it through suppression of the receptive apparatus. There may also be loss of correlation of the several centers connecting with the visual sphere, especially that of language, causing verbal blindness.

Therefore, in discussing the pathologic anatomy and physiology of vision, we should distinguish with M o r a t,[1] physical blindness, the physical interruption of the recipient and carrying portions of the ocular apparatus; i. e., the eyeball and nerve tracts. (2) Cortical blindness, equivalent to the loss of luminous sensation. (3) Psychical, equivalent to the loss of commemorative images of objects. (4) Verbal blindness, implying the loss of power of reading words or signs. This last variety is a form of aphasia.

H i r s c h b e r g[3] reports the clinical histories of two cases of this rare, but important, affection. A man, aged 32, was knocked down, 6

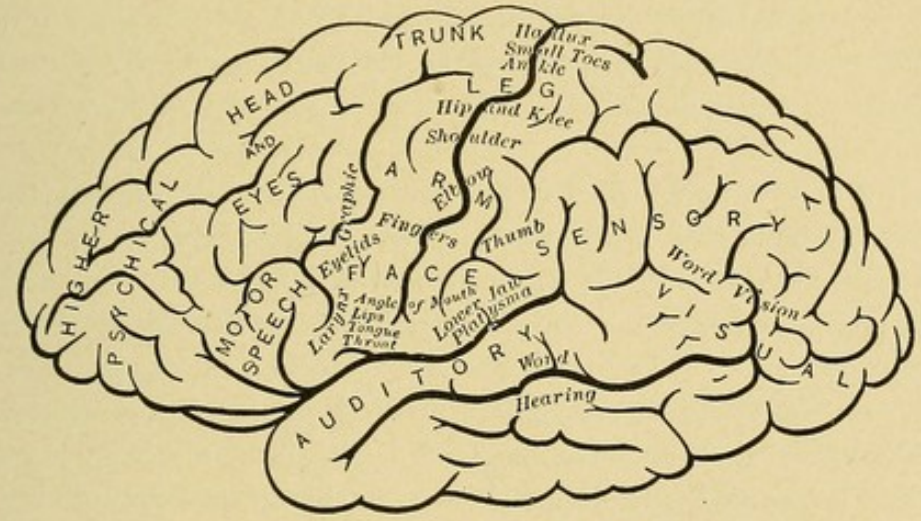

Fig. 320.

Lateral aspect of the left hemicerebrum, showing the cortical centers. (Nagel.)

years before, by a piece of iron, weighing 300 pounds, which struck his head from behind. He was unconscious for eight weeks. Then right homonymous hemianopia and total color blindness of both eyes were ascertained. The latter disappeared after removal of fragments from the left side of the occipital bone one and one-half years later. V.=1, but hemianopia, due to lesion of the left occipital lobe, paralysis of left facial nerve with lacrimation and left-sided deafness remained. There seemed to be hemianopic reaction of the pupils. The temporal halves of both optic discs were pale and somewhat atrophic.

A man, aged 21, received, on November 3, 1905, at Odessa, a blow on his left parietal bone by the butt of a rifle. He at once fell down, lost much blood and his vision became lost after 10 minutes, and remained so for three weeks. Gradually some sight returned upon the right side. He

came to Hirschberg February 24, 1906. His memory was impaired and he frequently had slight convulsions of his limbs. At the left parietal region a scarcely movable scar, 18 cm. long, covered a defect in the bone. Pupils and ocular movements normal. The patient could see objects only on the left side and upwards. Vision R. = fingers at ¾, L. at 1.5 m. The visual fields showed right hemianopia and peripheral contraction of left halves. Right optic nerve pale, left slightly pale. The left pupil responded to light only from the left side. Reaction of right pupil was very slight. In this case both visual spheres were damaged, but the left more than the right.

Chaillous[4] reports case of a patient who, after having fallen on his head, remained unconscious for nine days. Later he regained consciousness, but complained of headache and poor vision. Fourteen days later neuritis optica of the right eye, and retinitis hemorrhagica of the left, were observed; a lumbar puncture was performed and 15 c. c. of clear cerebrospinal fluid was obtained, and after a few days all the symptoms had disappeared. The author recommends lumbar puncture in all cases of injury with symptoms of intracranial compression where neuritis optica is found.

Tatsuji Inouye[5] found in gunshot injuries that the small bullets generally penetrate the brain in a straight line. By the location of the bone wound the localization of the injury of the brain is usually given. By geometrical construction the course of the canal taken by the bullet can be exactly pursued.

He gives detailed reports of 28 cases of penetrating injuries of the head with visual disturbances, selected from about 80,000 wounded, viz., 4 pure and 2 impure right or left hemianopsia; 4 pure and 1 impure inferior hemianopsia; 3 pure and 1 impure inferior hemianopsia quadrata; 1 pure and 1 impure superior hemianopsia quadrata; 1 pure small and 2 probable pericentral scotomas; 1 large inferior pericentral, and 1 pericentral scotoma; 2 cases with no homonymous defect and marked atrophy of the optic nerve; 2 large and 3 medium sized pure concentric contractions of the visual field and a case of multiple annular scotoma. In the 4 cases of inferior hemianopsia both visual spheres were injured from behind and above and thus probably both visual spheres above the fissure calcarina. In one case of pure inferior hemianopsia the visual radiation most likely was injured from above, and in the 4 cases of inferior hemianopsia quadrata the mathematic calculation suggested an injury of the corresponding visual sphere, or visual radiation of one side from above, and in a case of superior hemianopsia quadrata the foremost portion of the visual graduation from below.

He gives graphic demonstration of the visual field and the true surface of the visual sphere. He assumes two functional parts of the

whole visual sphere, viz., a main and a supplementary visual sphere. The main part corresponds to the visual sphere proper, with a sharp projection of the retina on the cortex; the supplementary part comprises the remaining visual sphere with a projection of the retina, but not a distinct one. The function remaining in bilateral hemianopsia, and limited to the point of fixation, is the function of the supplementary visual sphere, which but by the several functional disturbance of the main visual sphere, has become objectively noticeable.

The following case of extreme gunshot injury of brain is introduced not only to show its ocular features, but to show the adaptation of the intracranial contents and its toleration of an aseptic body that has not injured vital structures. (Girard.[6])

Private, wounded at long range, by a Mauser bullet entering cavity of cranium, three-fourths of an inch above the supra-orbital ridge and one-fourth of an inch to the left of the medial line. There was total loss of consciousness during first few hours following receipt of the traumatism, with the exception of a few short intervals of semiconsciousness, at which time excruciating pain in the head was experienced. The patient was taken to the First Reserve Hospital at Manila, where he laid in bed for about four weeks. While in bed he suffered extremely from pain in the head, most severe the first three days, moderating slightly at the end of the fifth week, becoming intermittent, greatly exaggerated, on exertion, by heat, and especially direct rays of the sun, exposure to which caused him to reel, stagger and almost lose consciousness. At the time of the report (August, 1899) is still quite susceptible to direct rays of the sun. First few days of illness were marked by extreme nausea and persistent vomiting; the slightest thing taken in the stomach would be rejected. The pain in the head increased the severity of these attacks. During early weeks of illness any exertion of the brain, as reading, caused pain in back of eyes and vertex of the head.

Returned to San Francisco with his regiment in August, 1899. Radiograph taken August 20 showed Mauser bullet imbedded in left occipital lobe.

Condition, October 1, 1899, six months after receipt of injury: Occasionally has pain in the lumbar region and describes it as being a "catch," lasting about five minutes at a time. Pain in the head, when present, is located a little anterior to parietal eminence on left side. There is no history of loss of power on either side, but a weakness is appreciated in the right arm and leg, and a slowness in response to mental impulse. This last is demonstrated in the act of writing; though the thought is perfectly clear, there is a slowness in the forming of words.

Voice: Patient did not, to his knowledge, exercise this function for first two days of illness, but on beginning to do so, noticed a slight con-

fusion of ideas, it being necessary to first clearly fix a thought before giving expression. There was also temporary loss of power to recall past events and names of companions. This returned with full clearness at other times. A slight confusion still remains.

Eye: Pain back of left eye more or less severe, and increased by use, and relieved by closing the lid. During confinement to bed following injury, patient tested vision of left eye by closing right. The vision was clear, but slight weakness and photophobia were noticed. Ptosis of left eye was marked during early weeks of illness. Aperture is now smaller than that of right eye. A slight diplopia was also present, a line of print appearing double. Pupils are regular, but left slightly larger. Reaction to light and power of accommodation are noticeably decreased, especially in left eye. Visual field normal. No nystagmus.

Hearing is normal. Sense of smell more acute on right side. Sense of taste more acute on right side, the anterior two-thirds of left showing marked dullness. Tactile sense seemingly dull on right side. General sensation of right side not as acute as on opposite side.

Reflexes: Knee reflex very marked on right side, responding to touch above, as well as below, the joint; the contact from finger causing a disagreeable tingling throughout the thigh. On left side, reflex is exaggerated, but not to such a marked extent. Wrist reflex marked on right side, causing a chronic spasmodic contraction of the fingers, and the hands tingling. Reflex absent on left side. Ankle clonus and patellar reflex absent. Cremasteric marked on both sides. Sphincters uninvolved at any period of illness; coördination good, though a slight uncertainty is felt on attempting to walk with the eyes closed. No epileptiform seizures. No disturbance of nutrition or bodily functions. The patient afterward entered the mail service and returned to Manila on duty.

Injuries to the brain may cause various kinds of aphasia, of which a unique form is that of ideographic blindness, a case of which has been reported by me,[7] by which a center for this faculty has been demonstrated.

Anatomy. The area of language is located in the lateral cortex, reaching from the first and second frontal convolutions, where the center of the motor images or the articulation or center of Broca exists, backwards along the upper part of the temporal lobe where, immediately below the Sylvian fissure in the ascending parietal convolutions is located the center of the auditory images of words, or center of Wernicke. Farther back, at the end of the parieto-occipital fissure is located the center of the visual images of words.

Broca's center is in contact with the general motor area, the center for auditory images is almost identical with that of general audition. The center for visual images is connected with the center of general

PLATE XV

Cysticercus in vitreous emerging from superior temporal retinal vein.

vision by its deep surface, and comes in contact with the optic radiations, which proceed from the internal surface of the posterior portion of the occipital lobe, especially including the cuneus and a portion of the lingual lobe, the two convolutions forming the boundary of the calcarine fissure. The ideographic or writing center is now located by this case and by deductions from the observations of other authors, in the upper part of

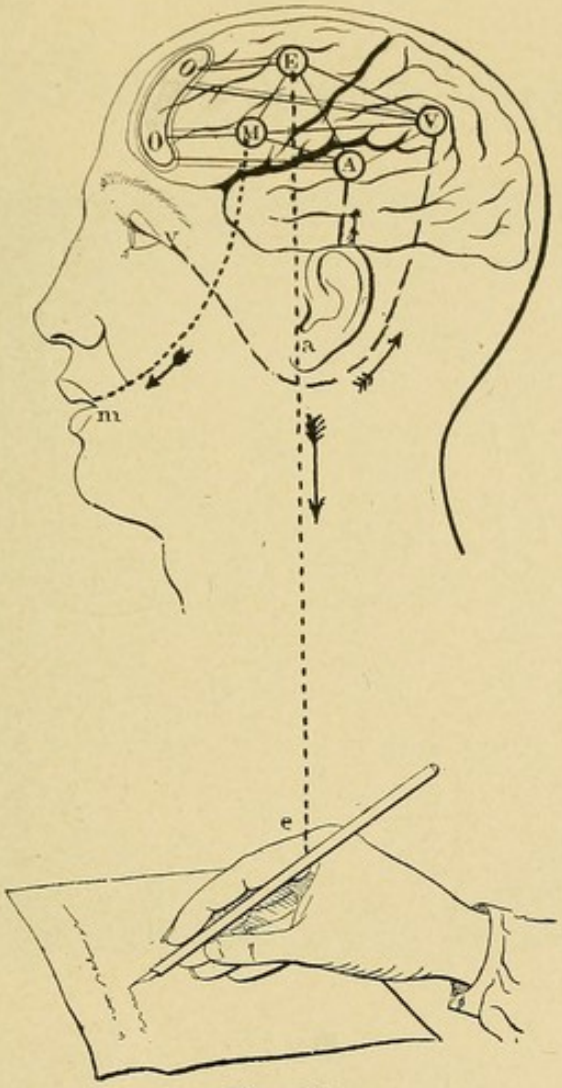

Fig. 321.

Centres or systems of language and their principal associations: A, auditory center; V, visual center; M, motor center of speech; E, motor center of writing; OO, intellectual center. Sensory nerves in broken lines: aA, Auditory nerve, vV, optic nerve. Motor nerves in dotted lines; mM, nerves of phonation; eE, nerves of writing (Morat and Grasset).

the third frontal convolution. Disturbances of any of the so-called centers of the visual sphere, or the radiations proceeding between them, cause distinct clinical manifestations which cannot be entered into here.

A girl now aged 16, in February, 1893, then being three years of age, fell ten feet from a shed, striking upon the vertex. Was uncon-

scious for 24 hours, and the following May developed epileptiform attacks, during which month she had three, remaining one hour and fifteen minutes in the last one. Has had none for the last ten years. Has had more or less constant headache at the vertex. Since that time has developed well physically, but has the mind of a child of three or four years of age. Has no inclination to play and cannot be brought to put her mind on anything. Never has learned to read or write. Has learned more

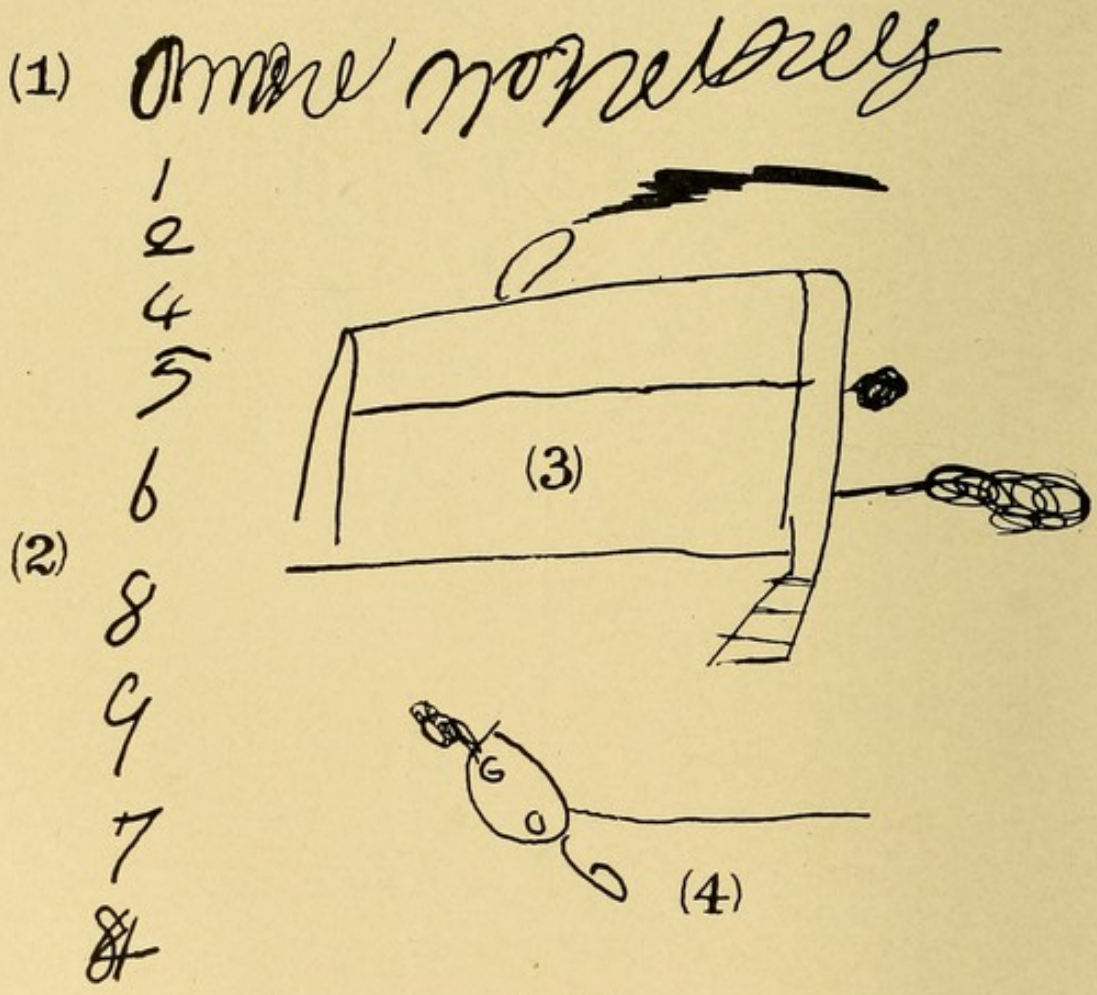

Fig. 322.

Writing, numbering and drawing from memory: (1) Signature of the patient from memory; (2) column of figures, supposed in rotation from one to ten, from memory (the round black figure on right is said by patient to be knob of door; she lives in a house with a number of steps leading up from the street); (4) drawing of dog from memory (she did not remember the body or limbs).

or less rapidly by hearing. Is musical and can play simple pieces on the piano and sings correctly. Cannot sew or crochet. Can do second work, but cannot cook. She has been unable to count beyond two.

Has been to various schools, one of them a convent, during which time she learned to make letters and figures, but was unable to remember them. Cannot tell the day of the week or time of day, or do any action

PLATE XVI

Double perforation of globe by chip of steel
Perforation to nasal side.

which involves much reason or computation. Has some echolalia and repeats names.

Examination. Visual acuity measured by the illiterate chart was full 6/vi. Matches colors correctly. Visual fields full. There is a coarse lateral nystagmus on fixation. There is orthophoria and normal degrees of version. Colored audition, i. e., when certain chords on the piano

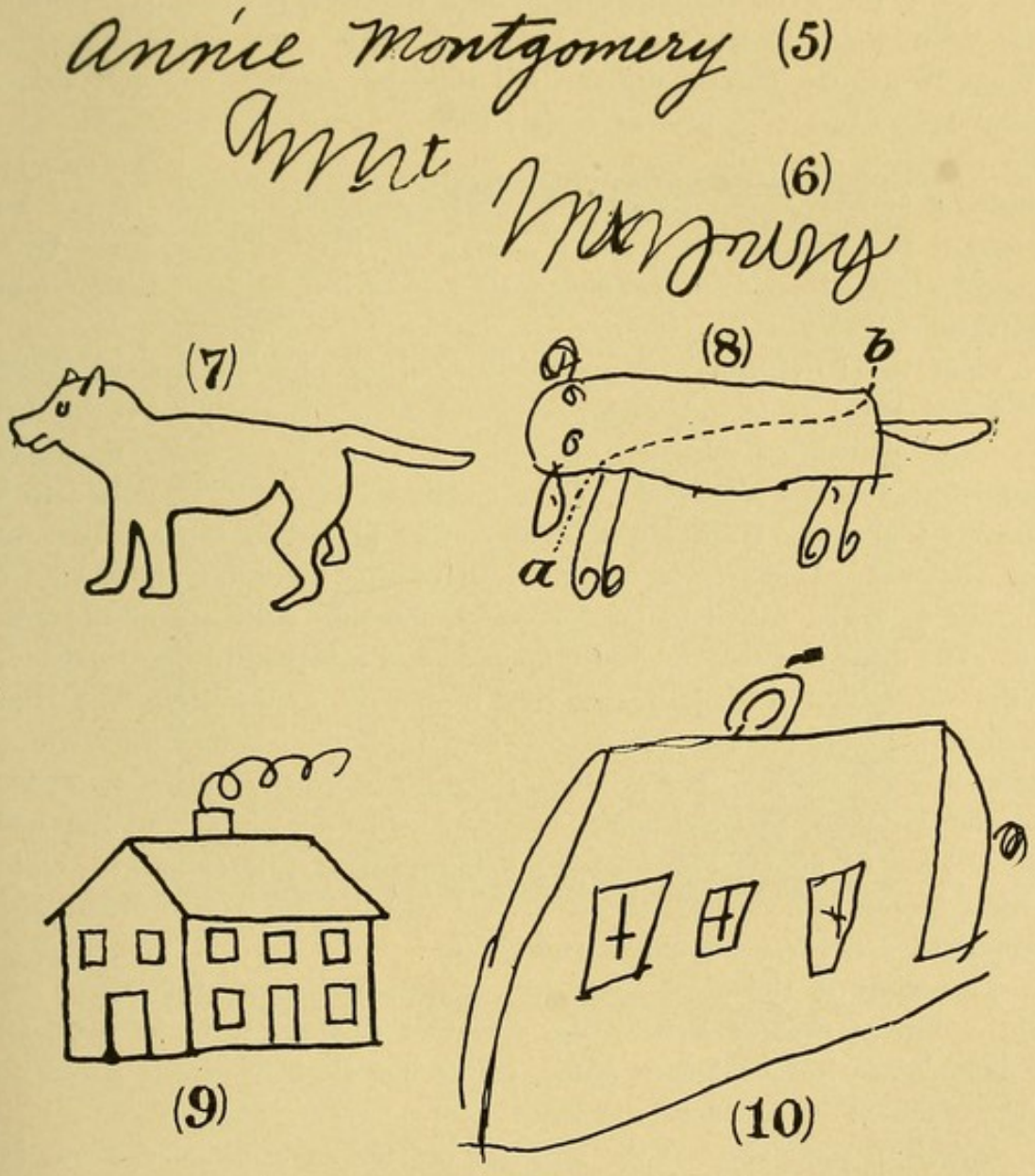

Fig. 323.

Writing and drawing from copy: (5) her name written by author for copy; (6) her copy of above (note the similarity to No. 1); (7) outline drawing of dog by author for copy; (8) copy by patient of (7) above dotted line a-b (when she was asked whether the dog did not have a body and tail and legs, and these pointed out on the figure, the part below a-b was added); (9) outline drawing of house by author for copy; (10) copy of diagram (the windows were added after she was asked whether the house had windows or not, and these pointed out on diagram 9. Note the similarity of No. 10 and No. 3.)

are struck, or hearing certain noises she remembers seeing certain colors and has spoken of them at home. Conversely, certain colors, notably bright red, seem to sound to her.

General physical examination: well-developed, but with slight kyphosis and scoliosis. Blood pressure 150. On the left side of the head there is a scar in the scalp, over the Sylvian fissure, about three inches long. Oral memory very good. Poor as to time. Repeats names and days of the week after they have been told her, but cannot remember them very long. Keeps time to music, recognizes her name in writing but not in print. Thinks she can tell time by months, but says that it "snowed in August." She says that things happened "long time ago" even if only a few minutes before. She has some fixed ideas and undoubtedly is irresponsible as to ideas of meum and tuum. There was repetition and misplacement and elision. She has but little appreciation of symbolism. Results of graphic tests are shown in the accompanying illustrations.

Operation: February 18, 1909, under ether anesthesia, skull shaved and a flap of the scalp was made, retaining a large bone flap, but the bone was found eburnated over the attempted incision, there being no diplöe, the thickness of the skull being ⅜". Section was 2x2½". It had to be removed separately from the skull flap, was placed in salt solution and later replaced. Inner table of the skull at this place on under side of the bone-flap was found to be depressed, showing evidence of old fracture. The dura was scarred and thickened and attached to the periosteum of the skull, and the pia mater had numerous adhesions. The brain convolutions were flat but apparently normal. Believing that there was no reason to do more than the decompressive operation the dura mater was replaced, stitched, and the bone plate replaced in position and the scalp flap sutured in place; the dressing being normal salt solution. Union by first intention occurred, the stitches being removed on the fifth day. Temperature never went above 100.4°.

The site of the decompressive operation bulged for about two months, but at present writing the elevation is scarcely to be seen, and the bone plate has healed in place, being but slightly raised above the level on the other parts of the skull.

March 9, 1909, she left the hospital, the family thinking she was improved mentally. April 22, 1909, after a number of lessons given by me as to number and direction, a teacher was secured who carried on these lessons for some months when the financial affairs of the family precluded further expense as to teaching. The girl has markedly developed mentally, although she is yet a child. She has learned to recognize all the letters and reads some words and counts correctly from one to a hundred. Can add and subtract minor sums. Recognizes various

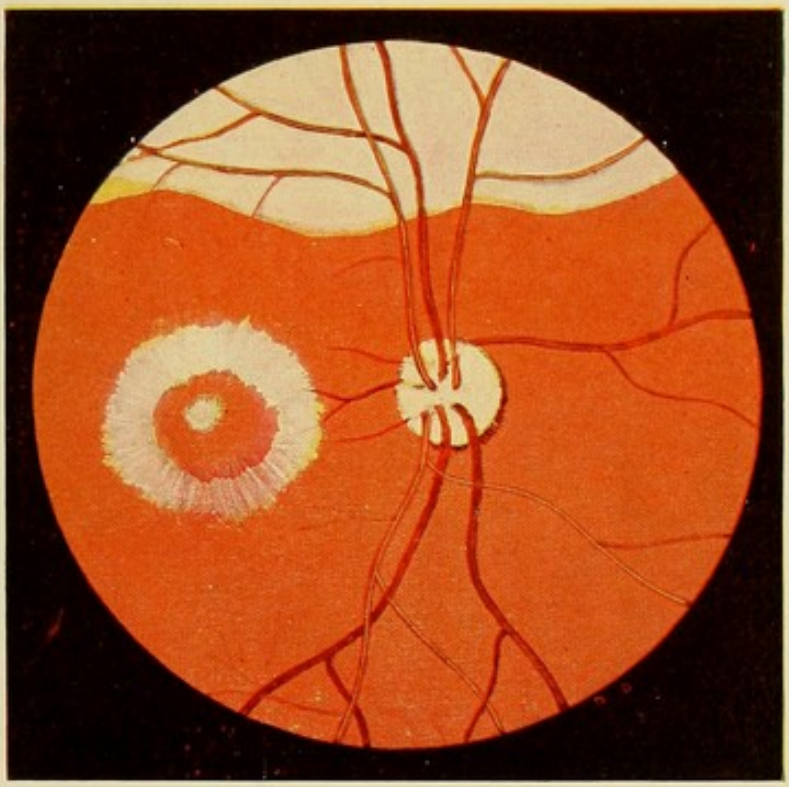

PLATE XVII

Opacity of retina due to blow on eye. Berlin's opacity. Taken a few hours after being hit in the eye by a wedge.

pieces of money and objects, remembers names, days of the week, can tell the time; but has made absolutely no progress, so far as I can see, in ideographic representation, the results of an interview two years later showing deterioration in writing and drawing.

Behr[8] examined cases of hemianopsia to the number of 20 with

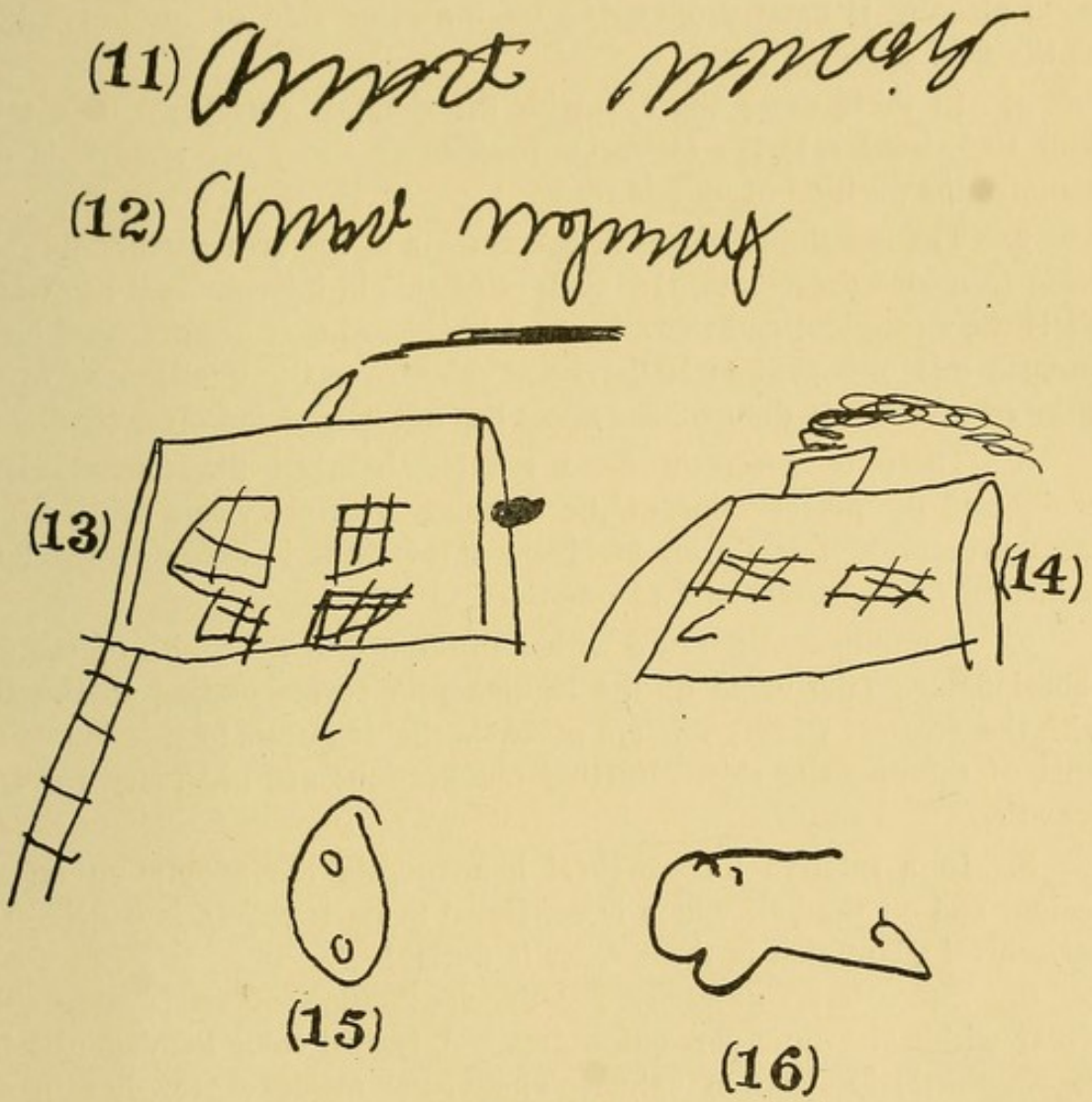

Fig. 324.

Writing and drawing from memory and copy (Jan. 17, 1910); (11) her signature from memory; (12) copy of (5); (13) drawing of house from memory (this time it is noted that she put the windows in the house; the door knob is still in evidence); (14) copy of (9); (15) drawing of dog from memory (it will be noted that she forgot entirely about the body, legs, and ears of the dog); (16) copy of (7).

especial reference to Wernicke's sign and that of Wilbrand's prism reflex conjugate deviation. His conclusions are as follows:

1. The hemianopic papillary inaction is with proper investigation demonstrable in every case of tract hemianopsia accompanied by large absolute field defects.

2. The absence of reflex eye movements in Wilbrand's prism test is also proof of a tract hemianopsia.

3. A degeneration of the optic tracts descending from an intracerbral focus leads to a secondary degeneration of the basal tracts through the primary optic centers and with it to a bilateral atrophic papillary pallor only when the hemianopsia is developed in early childhood. The optic atrophy is most pronounced on the same side of the nerve head as the field defect.

4. In these cases the eye with the greatest peripheral field takes over the visual act; the other becomes more and more amblyopic and assumes the position of muscle rest.

5. The remaining visual field contracts to the area surrounding fixation (macular preservation). Failure of this in intracerebral hemianopsia is the exception, and there is great likelihood that in pure tract hemianopsia this preservation is the rule. Moreover the question as to the place of division of the macular fibres has not been definitely settled.

6. There is a certain fixed relation between the central visual acuity and the preservation of the maculæ. Normal vision always indicates preservation while an involvement of them is accompanied by a reduction of from one-half to one-third.

7. A pupillary difference with a difference in the width of the palpebral fissure (the name of the hemianopsia corresponding to the side with the greatest width) renders probable the diagnosis of a lesion of the tract of the opposite side. Further observations are necessary for confirmation.

8. In a relative intracerebral hemianopsia the adaptation on the seeing, and on the half which is restricted in its function, is equal. The pericentral adaptation in these cases is normal.

9. There is no necessity for the assumption of an isolated color center within the optic perception area. A typical color hemianopsia has no diagnostic localization value. The visual memory area lies in one hemisphere in the occipital or temporal lobe. In the vast majority of cases in literature of disturbance of orientation associated with hemianopsia the lesion with the greatest likelihood has been located in the left hemisphere. It is a center in the narrowest sense of the term.

10. The quality of a visual field defect (expressed through the smallest observable perimetric object) permits of a fairly accurate conclusion as to the degree of the disturbance of the visual fibres.

11. The nasal retinal half has a greater pupillomotor excitation than the temporal. The periphery of the retina also has pupillomotor properties.

12. Through a positive result with the prism test of Wildbrand in

cerebral hemianopsia proof is afforded of the existence of a subcerebral reflex arc for automatic eye movements.

Wilbrand's Prism Test:—The patient is requested to fix a white point on a large gray surface, 30 cm. distant. Then, suddenly, both eyes are covered with equal prisms, apex towards side of the hemianopic defect. The refracting angle must be twice the angle of the remaining active portion round the point of fixation, or more, so that the image is thrown upon the hemianopic portion. The test presupposes the existence of a subcortical link between retinæ, and eye movements near the corpus geniculatum externum remains uninjured. In any interruption of this connection, the involuntary associated eye movement will be wanting.

Possek[9] had a man who received a severe blow on the occipital region which caused a depressed fracture. This was operated upon, and, following the operation, blindness set in, which gradually recovered until in each eye V = 6/xii, but the fields showed a hemianopsia, temporal on the left and nasal on the right, macular vision being retained in both eyes.

Lange[10] reports a man, age 20. Occupation, roofer. Fell 36 feet from the roof of a building to the pavement, causing a fracture at the base of the skull. Recovery, with complete hemianopsia of temporal fields. Light, when reflected into the eyes, upon the temporal halves of the retinæ, caused pupillary contraction. But when reflected upon the nasal halves of the retinæ only caused very slight contraction of the pupil, and it was inferred that this contraction was due solely to secondary reflection from the nasal to the temporal halves of the retinæ. Diagnosis, complete division of the optic chiasm, with destruction of the decussating fibers which pass to the nasal sides of the retinæ, with corresponding loss of pupillary reaction through stimulation of the nasal halves of the retinæ. Apparently the fracture extended from the right frontal bone over the right orbital roof, injuring the right olfactory nerve, to the sphenoidal plane, on which the chiasm lies, in a saggital direction.

Blindness and ocular palsies following violent injuries of the face and head, not only are due to both direct and indirect injuries to the optic and oculomotor nerves, but also the cerebral centers. A number of cases are on record of immediate and permanent blindness after the injury, followed in some weeks by signs of atrophy, due to central injury. Rarely there may be a recovery of some vision, even with a white disc and contracted fields.

Berlin[11] reported the statistics of von Hölder, comprising 124 cases of fracture of the cranium in which post-mortems had been made, and in which the fracture, in 79, passed through the orbital vault; and of these 63 involved the walls of the optic canal. He believes that such fractures and direct injuries to the nerves are essential factors

in producing the blindness and paralysis often found after head injuries.

Hubbell[12] cites ten cases in which the injury was not direct, and attributes the lesion to reflex phenomena. He summarizes his ten cases as follows: "Of these ten cases, six are paralysis of the extraocular muscles, without any evidence of the muscles themselves or their nerve supply being directly injured, either by a contusion, compression or hemorrhage, and 4 are cases of unilateral blindness which vary somewhat in the nature of the injury. In cases 7 and 10 it seems impossible to account for the blindness, on the assumption that the optic nerve was injured directly, or by compression through fracture of the optic foramen. In the one it does not seem to me that the knife could have penetrated to the apex of the orbit, and cut or bruised the optic nerve, without seriously injuring, also, other important orbital structures, or that the sphenoid bone could have been fractured at the optic foramen through impact on the vault of the orbit. In the other case we have the positive statement of the patient that the wire did not penetrate deeply into the orbit, and the symptoms following the injury, so far as the orbital structures are concerned, are opposed to such a supposition. In the other two cases the injuries were more violent and, while I do not see how they could cause a fracture at the optic foramen, yet I am not prepared to say that such an occurrence was not possible. My present opinion, however, is that none of these 10 cases is clearly explainable on the fracture or direct injury theory. Are they not all reflex?"

Axenfeld[13] reports several cases, with the following résumé: After contusions of the head not only cases of paralysis of the sphincter iridis, due to partial paralysis of the third nerve, are observed, in which the reaction on convergence returns earlier and more intensely than that to light (showing traces of paresis of the sphincter on closer examination), but also of the typical picture of Robertson's pupil: lacking direct and consensual reactions, with prompt contraction upon convergence, of otherwise normal or miotic pupils.

In other cases of injuries of the optic nerve the pupillary fibers are chiefly or exclusively damaged so that the direct reaction of light is disturbed, while vision, consensual reaction and reaction on convergence, are preserved. This may also occur after contusions of the globe without injuries of the head. Finally, very peculiar cases of permanent reflex immobility to light, even without traumatic mydriasis, may be encountered after contusions of the eyeball, very likely caused by changes of the iris itself, perhaps of certain nerve endings.

Elze[14] reports a case in which there had been concussion of the brain six months before the examination, with symptoms indicating labyrinthine disease and involvement of the semicircular canal in the left side. The subjective symptoms were diplopia and tinnitus. There was homony-

mous diplopia in all directions, with no change in the relative distance of the two images. The fundus were normal except for a slight pallor of the left optic nerve (not atrophied). Color perception was somewhat subnormal.

In the second case the history and symptoms were similar. No spontaneous diplopia, but with Maddox red and double images, close together, widening on lateral deviation to the right or left.

That the ocular disturbance is due to changes in the semicircular canal and not to labyrinthine disease is shown in a case reported by the author, in which the auditory nerve was greatly damaged in its peripheral distribution and was not accompanied by any ocular symptoms.

Gaupillat and Regnault[15] report a case of a young soldier at St. Cyr, who was struck in the inner angle of the eye by a bayonet while fencing, making a very slight tear of the conjunctiva. Patient was much depressed, fearing loss of sight; eye immovable; pupil dilated; accommodation absent; ophthalmoscopic examination negative; light perception only. All unfavorable symptoms passed away and the question arose as to whether hysteria was the factor to the symptoms.

Casey A. Wood[16] says "Within the past six months I have had two cases of diplopia following head injuries without evident traumatism in or about the orbital region. In one instance the patient fell from a second story window to the pavement below. He was unconscious for three days and on awakening noticed that he could not see as well as before. Central vision was affected about equally in each eye, being two-thirds of normal, with ability to read Jaeger 8 only. Before the accident he had been able to read fine print. No glass helped his vision, but in the course of a month his sight improved both for distance and near. The double vision persisted and examinations disclosed a paresis of the external rectus.

"In the second case the patient had an almost complete unilateral third nerve paralysis following a blow upon the back of the head. In this instance, also, vision deteriorated after the injury, but slowly improved, but the double vision has persisted, although after six months it has slightly improved."

H. Fisher[17] points out that some cases of congenital word-blindness, or inability to learn to read, are due to obstetric injuries from limited meningeal hemorrhage over the left angular gyrus, resulting in failure of development.

Lieut. Shorter[18] reports retrobulbar neuritis in a native soldier from some traumatism or sudden shock. Unconsciousness, followed by recovery, but dimness of sight, hazy and woolly discs, fields contracted, anemic discs for a long time and could not see well in a bright light. The

injury probably affected the meninges and cerebral cortex, the retrobulbar neuritis being due to continuation of the inflammation.

Camill Hirsch[19] relates the case of a boy, aged 12, who was run over by an automobile, picked up unconscious, causing commotio cerebri, with transient cortical amaurosis, no light perception, pupil reaction sluggish, slight dilatation, after three hours recognition of large objects, four hours later fingers counted, right-sided homonymous hemianopsia and amnesic aphasia. Next day visual field extended over median line; third day vision and field normal. Amnesia lasted a few days, but full recovery ensued.

LITERATURE.

1. Henschen, *Congress. Internat.*, Rome, 1894.
2. Morat, *Physiology of the Nervous System*, 1906.
3. Hirschberg, J., *Centralbl. f. Aug.*, p. 200, 1906.
4. Chaillous, *Wien. Med. Woch.*, Sept. 15, 1906.
5. Tatsuji Inouye, *Die Sehstörungen bei Schussverletzungen die corticalen Sehsphaere, nach Berbachtungen an Verwundeten der letzen Japanischen Kriege*, Leipzig, 1909.
6. Girard, A. C., *The Use of the Roentgen Ray by the Med. Dept., U. S. A., in the War with Spain*, 1898.
7. Würdemann, *International Clinics*, Sept., 1910.
8. Behr, *Arch. f. Aug.*, April, 1909.
9. Possek, *Zeitschr. f. Aug.*, Ergänzungsheft, 1905.
10. Lange, O., *Klin. Mon. f. Aug.*, xlii, 1, p. 419, 1904.
11. Berlin, *Trans. Heidelberg Cong.*, 1899.
12. Hubbell, A., *Journ. A. M. A.*, Jan. 7, 1905.
13. Axenfeld, H., *Deut. Med. Woch.*, p. 663, No. 17, 1906.
14. Elze, *Woch. f. Ther. u. Hyg. d. Aug.*, Oct., 1908.
15. Gaupillat and Regnault, *La Clin. Opht.*, Feb. 25, 1908.
16. Wood, Casey A., *Practical Med. Series*, Vol. III, 1909.
17. H. Fisher, *Med. Press*, May 18, 1910.
18. Lt. Shorter, *Ind. Med. Gaz.*, June, 1910.
19. Camill Hirsch, *Deut. Med. Woch.*, No. 31, 1910, p. 1436.

B. INJURIES OF THE OPTIC NERVE.

Injuries of the optic nerve may take place at the intra-cranial, intra-canal, orbital, or papillary portions. The clinical conditions are so different that they are described under separate headings.

Anatomy. The basal or intra-cranial portion of the optic nerve consists of the short portion of the nerve extending back from the optic canal in the sphenoid bone to the chiasm, and the optic tract. Injuries involving the optic centers are considered on another page. The optic tracts are not entirely separate from the gray substance of the brain with which they merge at their posterior ends. Beginning there the tract of either side condenses, becomes contracted and converges towards the chiasm in which the inner fibers cross over, communicating directly with the centers of the opposite side. The middle and inner fibers decussate entirely with the optic nerve of the opposite side, while the external fibers

do not cross over, but form the outer bundle of fibers in the optic nerve in the 10 mm. portion from the chiasm to the canal.

The surface of the optic disc contains only decussating fibers. The direct and consensual reactions of the pupil necessarily demand a central connection of the nuclei of both sphincters, as found experimentally by Bernheimer. If this did not exist, only a direct, never a consensual, reaction could have taken place on illuminating the seeing temporal retinal halves, since only the non-crossed fibers were preserved, and, as is universally held, the centrifugal pupillary fibers course to the homolateral eye. In the human eye the nasal half of the retina, from the macula on, is provided only by the decussating optic fibers, the temporal halves by the non-decussating fibers.

The optic nerve is not a nerve in the same sense as the other peripheral nerves, but forms a part of the brain, so that it is more appropriate to speak of the optic tract, even in its most peripheral portions.

Pathology. Parsons[1] says "Injuries of the optic nerve in man have seldom been investigated microscopically. v. Michel[2] has recorded two cases in which the nerve has been torn in the neighborhood of the lamina cribrosa. In the first the nerve was completely divided at the anterior level of the lamina, the space being filled with blood clot, which had undergone hyaline change in the center. The anterior part of the nerve was drawn forwards into the eye and the posterior part showed interstitial proliferation. In the second case there were two tears on opposite sides, and both were filled with blood.

The behavior of the nerve fibers when the nerve is cut across may be gathered from experiments on animals, and from rare cases in which the nerve has been completely constricted by blood-vessels or tumors. In the former the ends soon become covered with connective tissue, which links them together and invades the spaces between the sheaths. The anterior end of the proximal segment may show epithelioid and giant cells (Wagenmann[3]). More experiments are required on this subject, especially some directed toward explaining the peripheral atrophy that takes place.

The second group of cases involve a gradual, and often only partial, obliteration of the nerve. Sachs[4] records a tumor of the pituitary body, which pressed the nerve against the internal carotid and the artery of the corpus callosum, causing complete obliteration on one side. The "pressure atrophy" differed from secondary atrophy in the more rapid breaking up of the medullary sheaths, the earlier appearance of wavy fibers—probably naked axis cylinders—and the extensive destruction of neuroglia cells. There was no great proliferation of connective tissue, such as is found in the traumatic cases. Bernheimer[5] records

cases in which sclerosed vessels have almost completely divided the nerve in the intra-cranial portion.

In all cases of section of the optic nerve the nerve-fibers eventually degenerate, not only centrally, as might be expected from their origin in the ganglion cells of the retina, but also peripherally. Birch-Hirschfeld[6] has shown that the retinal ganglion cells rapidly degenerate after section of the nerve. It may be that the cells and axons are particularly sensitive, so that injury of the axon far from the cell causes shock which leads to atrophy of the cell and the part still attached to it. There is evidence in favor of this view in the analogy of motor nerves. Thus, if the hypoglossal is cut across the peripheral end shows the ordinary Wallerian degeneration by Marchi's method; if, however, it is forcibly torn out there is also Marchi degeneration in the proximal part. Similarly by the Nissl method, in the first case there is moderate breaking up of the Nissl granules—a degree which is probably capable of repair; in the second case, however, the Nissl granules break up entirely, and it is probable that the cells die (vide infra).

Another factor leading to centrifugal degeneration is the efferent fibers which are, undoubtedly, present in the nerve. It is probable that these are more numerous than has hitherto been suspected. (Parsons[1]).

Probably the most important factor in many cases is interference with the blood supply, as in cases of optic atrophy following fractures of the base of the skull involving the optic foramen. Here there is not only the local injury and rupture of vessels, but bleeding takes place into the sheaths of the nerve, so that the resulting blood clot contributes to the atrophy by causing extensive pressure atrophy.

The optic nerve, being part of the central nervous system, does not regenerate. It is true that Stroebe[7] has described the formation of young nerve fibers in the spinal cord of the rabbit after section, but it is accompanied by rapid proliferation of the interstitial tissue, which prevents functional reunion. Evidence that regeneration occurs in man is lacking.

Casey Wood[8] says in a case of attempted suicide under his care the bullet passed through the orbit into the nose without direct injury to the optic nerve, yet the patient became totally blind, thus confirming the suspicion of many observers that molecular changes within the nerve tissues may take place without actual contact with the missle.

Symptoms. The clinical picture differs according to the portion of the part affected by the injury. Injury to the right tract causes left-sided hemianopsia; to the left side, right-sided hemianopsia; destruction of the chiasm, complete blindness on both sides, while incomplete destruction or laceration partial amaurosis sets in. Cutting of the chiasm

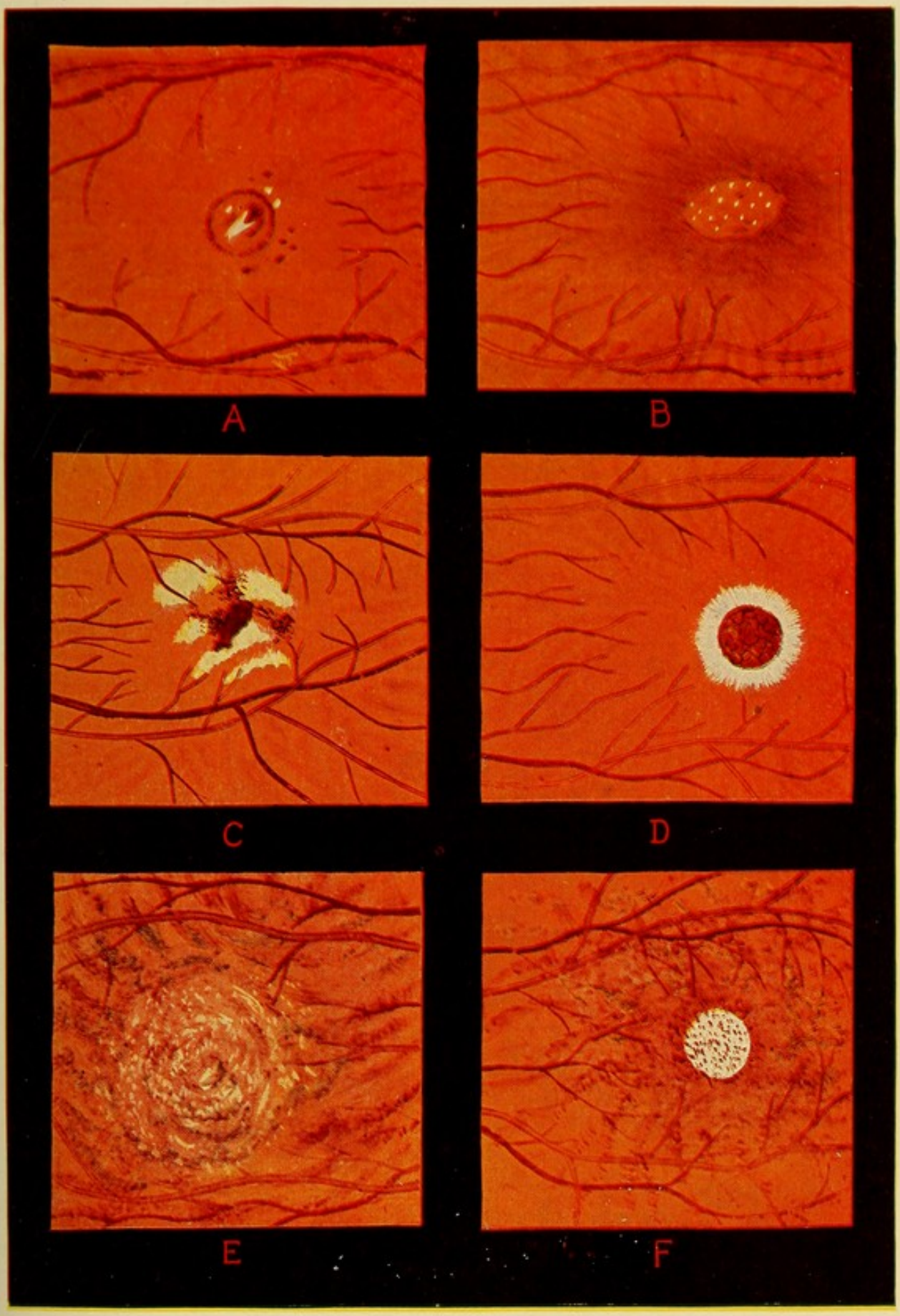

PLATE XVIII

A. Macular injury, contusion of globe from rope end. B. Blow from fist. C, Blow from door. D. Hole at macula from snowball. E. Iron in vitreous, 6 days, changes at macula. F. Iron in vitreous, 6 days, changes and disease of macula from contusions of globe and retained foreign body in vitreous.

at the middle line causes bitemporal hemianopsia. The existence of binasal hemianopsia from injury has not been reported, though several cases from disease of the chiasm are noted in the literature. Section of the short intra-cranial portion of the nerve between the chiasm and the canal causes blindness of one eye, while an incomplete section causes amaurosis. Compression of the various portions through fragments of bone or hemorrhage at the base of the skull further complicates the picture.

As a rule most intra-cranial injuries to the optic tract and chiasm are lethal on account of the severe trauma to other parts of the brain, so that even the character of the loss of visual acuity and field of vision can not be ascertained.

The injury may be direct, as from bullet and shell wounds in war, attempted murder and suicide, from saber, bayonet, knife wounds, stone, crowbar, and other blasting injuries; or indirect, from falls or blows on the skull which at the time produce a fracture at the base of the skull with accompanying compression, contusion, laceration, or complete severance of the parts from bone fragments, or compression from hemorrhage. Very commonly the intra-canal portion of the opticus is injured at the same time.

A considerable number of cases have been reported where one or both of the clinoid processes of the sphenoid bone have been fractured, either directly or by indirect force through fracture at the base, and these broken off pieces of bone have infringed against, compressed or lacerated the nerve.

Brodie[9] described such a case in which immediate total blindness was caused from a fracture at the base of the skull, in which the fragments of the sphenoid compressed both optic nerves behind the orbital cavity.

The nerve is seldom torn from the chiasm. Post[10] reports the case of a negro boy who was violently struck on the lower orbital rim so that the bone was broken, the lid torn and the bulb dislocated. The nerve was found completely torn away in the neighborhood of the chiasm.

Nieden[11] and Weiss[12] have reported two cases, with contusion of the brain substance and solution of its continuity, and laceration of the neighboring arteries, especially the internal carotid, the artery of the corpus callosum and the posterior communicating artery, with loss of vision, as obtains in injuries of the base of the skull near the tract and chiasm.

Besides these direct lesions, basal bleeding causes compression of the intracranial portion of the optic nerve and it is difficult to say whether the lesion be to the nerve or within its sheaths.

Berlin[13] says that a much better prognosis obtains from pressure

blindness from bleeding within the skull than when the hemorrhage is in the nerve sheaths, which is probably so, as sub-dural hemorrhage is quite common without any affection of vision resulting.

Secondary results may occur without primary symptoms, as atrophy of the optic nerve. Inflammatory changes in the brain structure and chiasm may cause a retro-bulbar neuritis. The nerve may later become imbedded in cicatricial tissue so that pressure atrophy occurs.

Diagnosis. Localization of this form of injury may be very difficult. In general it may be said that double-sided loss of sight following an intracranial injury is due to lesion of the tract or the chiasm, while one-sided blindness usually comes from injury to the nerve after it leaves the chiasm.

The hemianopsia is on the opposite side to the injury. In many cases it is impossible to state whether the optic nerve is injured within the cerebral cavity or within the canalus opticus, especially if in the latter case both nerves be implicated. Several such cases have been observed and only diagnosed at the autopsy. Similar appearances and symptoms are observed in the intra-orbital lesions when the blood vessels have not been implicated.

Prognosis. When the optic nerve is lacerated the prognosis is unfavorable, as blindness results; bleeding at the cranial base may be resorbed sufficiently early to allow of relief of pressure before atrophy sets in, with restoration of vision.

Therapy. The treatment is mostly surgical. (See next chapter.)

LITERATURE.

1. Parsons (a), *The Pathology of the Eye*, Vol. II, pp. 672- 673; (b) *Brain*, xxv, 1902.
2. v. Michel, *Zeitschr. f. Aug.*, vi, 1901.
3. Wagenmann, *Arch. f. Ophth.*, xxxvi, 4, 1890.
4. Sachs, *Arch. f. Aug.*, xxv, 1893.
5. Bernheimer, *Arch. f. Ophth.*, xxxvii, 2, 1891.
6. Birch-Hirschfeld, *Arch. f. Ophth.*, i, 1900.
7. Stroebe, *Arch. f. allg. Path. u. Path. Anat.*, vi, 1895.
8. Casey A. Wood, *Pract. Med. Series*, III, 1909.
9. Brodie, ref. Praun, p. 402.
10. Post, *Amer. Journ. Ophth.*, June, 1887.
11. Nieden, *Arch. f. Aug.*, xii, 1, p. 30.
12. Weiss, *Arch. f. Aug.*, xxxi, 4, p. 407.
13. Berlin, *Graefe-Saemisch*, vi.

C. INJURIES OF THE OPTIC NERVE WITHIN THE OPTIC CANAL.

Injuries to the optic nerve within the canal occur from wounds and foreign bodies, but mostly from fracture of walls of the optic foramen by which the optic nerve is either primarily lacerated or secondarily compressed through bleeding.

Anatomy. The optic nerve from its entrance into the optic canal is covered by a connective tissue sheath, a prolongation of the

dura mater, lined by the arachnoid and pia mater. These are intimately connected, but lymph spaces separate them slightly. The dural sheath is connected externally to the upper wall of the periosteum of the canal, while laterally and downwards it is more loosely attached by bundles of connective tissue fibers. Movement of the nerve and its sheaths in the canal from above is thus negatived by this close connection.

The optic nerve and its sheaths are richly supplied with blood vessels, especially in its pial sheath. The periosteum of the canal is likewise unusually well supplied with vessels. The ophthalmic artery passes below the nerve. These three points, the fast connections of the sheath, the slight motion, and the vascular richness, are of importance in recognizing the mechanism of lesions of this locality.

(a) Wounds and foreign bodies.

Direct injuries of the optic nerve in the canal usually occur through bullet wounds, inflicted through one side of the head, usually the temporal region, the favorite spot for pointing the pistol of the would-be suicide.

Bayonette, sabre, knife, bullet and shell wounds occur in war. As a rule the injury of the canal is in the side of the head that is wounded, the right optic nerve being wounded on the right side, and conversely, but cases have been reported when the nerve has been injured from trauma to the opposite side. Even so may both optic nerves be injured at the same time, but as a rule the injury is to one side only.

Bullets may remain in this locality, points of knives or sabre ends have been broken off therein. Such severe injuries may occur and yet the patient live.

F i s c h e r[1] had a soldier, where a ramrod had been discharged from a carbine, penetrating the body in the back at the fourth rib, passing upwards through the neck and head, projecting 30 cm. upwards from the left side of the head. After an incision in the neck the ramrod was hammered down through the skull and extracted from the neck. The right eye became blind, yet 14 days after the accident he could see hand movements at two feet, better in the median line than sideways. The right pupil was slightly dilated and moved slowly to the light. The right disc was white and the vessels contracted. Fischer traced the course of the ramrod through the right sphenoidal cavity, the lower root of the orbital wing, the right optic canal, the nerve and the cerebral cavity.

(b) Hemorrhage.

In 42 cases of the 54 fractures of the canal described and examined postmortem by v o n H ō l d e r[2] there was bleeding into the sheath of the optic nerve, never, however, without fracture of the bony canal. When

this was not found he thinks that death was so swift that there was not time for the blood to get into the nerve sheaths. In no case did he find a fracture of the canal without hemorrhage into the nerve. The greater the laceration and extent of the fracture the more is the hemorrhage.

Berlin[2] shows that the blood gets into the intervaginal spaces in three ways: 1. From the cranial cavity; 2. From torn blood vessels of the sheath itself; 3. From rupture of the central vessels before their entrance into the optic nerve. Additional to these causes are those in which the sheaths of the optic nerve in the orbit are opened so that the sub-vaginal space is liable to be filled with blood from hematoma of the orbit.

In most cases the blood enters the nerve from the cranial cavity, as the hemorrhage is great and soaks into the intervaginal sheaths. The nerve being torn the circulation of the central vessels and those of the sheath is immediately cut off. The lighter cases of damage to the nerve and vision from hemorrhage are those in which the laceration of the sheath and the damage is slight and may recover with useful vision. In a few cases, according to von Hölder[3] and Berlin[2] the bleeding has been from a torn ophthalmic artery. The artery is, however, very small and tortuous, so it not only gives way under pressure, but also acts somewhat as a protection to the nerve for the lower part of the sheath.

Kuhnt[4] shows that hemorrhage may occur from the small veins communicating with the central ophthalmic vein in the canalus opticus. Certainly a severe hemorrhage with laceration of the dural sheath of the nerve in the canal, leads to immediate and permanent blindness.

The visual field in partial cases shows a contraction in the upper half as the blood clot and pressure therefrom is confined to the lower part of the canal, owing to the anatomic relations as already described.

Oishi[5] describes clinically and anatomically a case of each kind. In both the blood from the cranial cavity entered the intervaginal spaces along the osseous optic canals. In the diabetic case the largest amount of blood filled the posterior quarter of the pia-arachnoidal, and the anterior three-quarters of the dura-arachnoidal spaces; in the case of fracture of the skull the blood was found chiefly between dural and arachnoidal sheaths. In both cases there was an ampullar expansion of the optic nerve. In the first case there was no papillitis, but a cellular infiltration of the supporting tissue, most likely a sequel to the long-standing diabetes. The choked disc in the second case undoubtedly was due to mechanical influences, as there were very slight inflammatory symptoms. Both cases presented the phenomena subsequent to hematoma of the dura mater.

(c) Direct laceration and contusion of the optic nerve in fracture (of the walls) of the optic foramen.

This injury is of eminent importance in practice, especially as to forensic procedures. Many cases of optic nerve atrophy have their origin in injury to the nerve at this point. Examination of the fundus, visual field and acuity of vision should always be made, as soon as possible after the accident, in patients having injuries to the head; and this examination should be repeated at intervals of several weeks, or at any time loss of vision is noted, in order that not only a proper scientific study of the case be made, but also data be obtained for the possible appearance of the examiner in court. While it is not possible to definitely fix the lesion in life, so many cases of autopsy have shown the injury to be in the canalus opticus that the probabilities point strongly to this location as the site of the lesion in most cases of obscure atrophy of the nerve after blows upon the skull.

Etiology. The cause of fracture of the canalus opticus and lesion of the optic nerve therein were in two-thirds of Von Hölder's[3] statistics due to gun shot injuries, and one-third to falls or blows upon the head.

Leber[6] found nine-tenths of his cases due to falls upon the head from a height. Blows upon the head, especially kicks from horses, in farmers and cavalrymen, have been noted. Perhaps a considerable proportion of the so-called congenital cases of optic nerve atrophy occur from fracture of the skull in difficult births and forceps delivery.

The blow may be from any direction, but as a rule the force is exerted upon the frontal bone, especially the superior orbital margin; then upon the root of the nose; the temple; and not a few of occipital injuries. In v. Hölder's cases of attempted suicide the pistol was discharged in the mouth in most of them, though in some the region of the external wound was the forehead or temple.

The intensity of the blow is so great as a rule that it is to be wondered at that the injury is chiefly limited to the optic canal, and some cases have but a slight trauma.

In a case of Vossius[7] the patient fell from a rocking chair and had no cerebral symptoms.

Praun[8] cites a blow from a potato, and a fall upon the nose, as some of these slight accidents.

Evans[9] notes that cases of loss of vision in one or both eyes, following blows or falls on the head, are of interest in that they seem to show that a special type of incomplete unilateral blindness is apt to result from blows in the region of the external angular process of the frontal bone. The sequence of events in these cases was as follows:

1. A more or less severe blow in the region of the external angular process of the frontal bone.

2. Sudden impairment of vision on the side of injury.

3. Loss of the greater part of the temporal field of vision on the same side.

4. Absence of ophthalmic changes for the first few weeks, followed by atrophy of the nerve head on the injured side.

5. Central vision may be almost completely restored, but the limitation in the field of vision remains practically and permanently the same.

While the nature of the lesion in these cases is very problematical, it is probably limited contusion of the nasal fibers of the optic nerve by contrecoup. The nerve on the side of the injury is driven against the inner boundary of the optic foramen, whilst the nerve on the opposite side is driven against the outer wall of its foramen. That the nerve on the opposite side does not get bruised is in the main due to the protection given to it by the ophthalmic artery, which winds around its outer side from below.

Assuming such an immediate cause for the symptoms mentioned, the course and prognosis of the cases can easily be deduced. A certain number of fibers are permanently destroyed (functionally) at the time of the accident. The more centrally-placed fibers are not so extensively damaged and partly recover their function, as shown by the improvement in central vision. The atrophy of the nerve is apparently not progressive, and no increase in the limitation of the field need be feared.

Generally speaking, we may expect a considerable improvement of central vision in those cases in which there is a fair central vision immediately after the accident, but little or no change for the better or for worse in the field of vision.

D e c h e r d[10] reviews the subject of nerve atrophy following blows or falls upon the orbital margin (with or without demonstrable fracture) or upon other parts of the skull (contrecoup), penetrating or punctured wounds involving the orbit, but not the eyeball itself, and, occasionally, falls upon the feet or buttocks.

The underlying factor is a fracture or fissure of the walls of the orbit, involving the optic foramen or sphenoidal fissure, inducing either direct trauma of the optic nerve, or else hemorrhage into its sheath, with subsequent pressure from blood or inflammatory exudate. In the last, i. e., exudate, the onset and progress of blindness would likely be gradual. Laceration of cranial vessels, vessels of the sheath, or of the central retinal vessels might be responsible for the hemorrhage. Should the fracture involve the middle fossa, a direct injury of the chiasm or optic tract, or an extravasation nearby, could easily produce visual impairment

of both eyes. A localized meningitis might effect a similar result. Furthermore, it is easy to see how a penetrating foreign body might be directed to the apex along the orbital walls, although these are fairly thin. According to Morton,[11] the inner wall is least protected, and unless the force is perpendicular to its plane, it is directed to its apex. Lacrimal sac and ethmoid involvements are apt to supervene upon trauma of the inner wall. Penetrating fractures of the roof are quite common, and often fatal.

That so few of these are correctly diagnosed is surprising, after a perusal of Callan's[12] and von Hölder's[3] statistics. The former cites 25 occurring in his own practice, with autopsies. Callan thus explains the nature of the traumatism. "The frontal bone unites with the nasal, maxilla, lacrimal and ethmoid bones by a continuous line of sutures, until the lesser wing of the sphenoid is reached; and at this point the suture line bifurcates, forming an obtuse angle. Quite near the apex of the angle is the foramen opticum. The jar made by the blow would find its weak point along this line of sutures; and the first resistance would be at the bifurcation adjacent to the foramen opticum. The movement or jar could not follow both lines with equal force at and beyond the bifurcation; consequently the unequal strain would result in fracture of the bone into the foramen opticum, causing compression of the optic nerve and sudden loss of vision to the eye."

Berlin,[2] quoting von Hölder's 1244 cases of skull fracture, found 86 of the base; 79 of these were through the orbital vault, 63 involving the optic foramen. The fracture was always through the upper wall, and sometimes also through the inner wall of the foramen. In 42 there was hemorrhage into the nerve sheath, but never without fracture of the bony canal. Hence, it can be inferred that in many skull-base fractures, involvement of the orbit escapes notice entirely, either because the patient dies and the autopsy (if any) is not thorough; or, also, because other symptoms mask those of the eye. Later on, when atrophy is discovered it is usually ascribed to some other cause than fracture (reflex, direct injury to nerve, etc.). In addition to the cases already noted, Hewitt[13] notes 68 fractures of the base, 23 extending into the orbit. Indeed, fracture of the walls of the orbit, usually involving the optic foramen, have, on close clinical study and postmortem investigation, so often been found to be the basis of sudden blindness following orbital injuries that it may practically be regarded as a sine qua non.

Pollak[14] says that in frequently examining the visual field with the ophthalmoscope, in connection with the pupillary reaction, the sensitiveness of the region of the injured eye and its power of mobility, we can determine not only whether the optic nerve is injured, but also the seat of lesion.

Fissures are mostly found in the upper and inner orbital wall and extend into the optic canal; fissures in the outer and lower orbital wall which extend to the superior or inferior orbital fissure are very rare.

The lesions in the nerve are produced either by the bone fragments themselves or by hemorrhages into the sheath of the nerve or into the substance of it; very frequently hemorrhages take place into the orbital tissue, which may lead to swelling of the lids or protrusion of the eyeball.

If the nerve is totally severed a lasting amaurosis will follow. Loss or diminished pupillary reaction on direct illumination or preserved consensual reaction on the same side prove that the motor fibers of the oculomotorius nerve are intact, and the centripetal part of the reflex arch is injured, thus proving a lesion in the tract of the optic nerve.

The ophthalmoscope shows whether the lesion of the optic nerve is in front of or posterior to the entrance of the arteria centralis retinæ. Injuries of the nerve in the optic canal lead, after two or three months, to a descending atrophy of the optic nerve.

The main point to be ascertained in these cases is whether the lesion of the optic nerve is situated outside of the canal or whether anteriorly or posteriorly.

Pridham[15] reports the case of a man, aged 41, who fell from a building April 21, 1907. He was conscious immediately after, but bled freely from the nose. There was a bruise over the right supraorbital margin. Examination at the hospital disclosed fracture of three ribs, but no fracture or depression of the right frontal bone could be found. The eyelids of both eyes became extensively ecchymosed, and both ocular and palpebral conjunctivæ filled with blood—more on the right side. The right pupil, the day following, did not react to light and was larger than the left. The nervous system was otherwise normal. The patient at no time lost consciousness. On the 22nd loss of vision in the right eye was complained of, and there was no perception of light. The red reflex was present, but the light reflex absent. There was paralysis of the ocular muscles, or ptosis. Ten days after the accident (May 1) the disc was fluffy at the edges, veins very large, and whitish exudation in the center of the disc. No hemorrhages were seen. On May 8th the outer half of the disc was whiter than the inner. On May 20th the light reflex was absent, perception of light still lost, but the consensual reflex present. Both pupils contracted on accommodation. The whole disc was now white, the arteries much smaller, and the edges better defined than in the other disc. There were shooting pains in the sound eye, but no signs of inflammation.

The lesion seemed to have involved solely the right optic nerve, and

was probably, therefore, about the optic foramen. The ophthalmic artery would seem to have escaped.

A very similar case is described in the *Lancet*, Jan. 21, 1905, and the subject is also discussed in the annotations of the same number From the literature it seems uncertain whether the lesion was a hemorrhage into the optic nerve sheath or division of the nerve by a splinter of bone from the anterior clinoid process.

A man had fallen on his head 12 feet from a scaffolding six days before and had sustained a fracture of the zygoma, base of skull and frontal bone. Bleeding from the nose followed. Fracture at supra-orbital foramen and junction of parietal. Sight of same side gradually failed from date of accident until the fourth day that eye was totally blind. I found that the supra-rectus muscle was paralyzed but no other evidence of paresis. I operated to relieve supposed depressed bone in orbit, and made incision two inches long under eyebrow but found that whole fragment was depressed, the fracture extending all the way back to the optic foramen. Since operation the paralysis of the supra-rectus has been relieved, but sight has not returned, and will probably not come back, as ophthalmoscopic examination showed beginning atrophy of the optic disc, and there has evidently been a localized retrobulbar neuritis between the eye and optic foramen.

An engineer was struck by a bursting lubricator glass tube, a large fragment striking the closed lid of the right eye, not cutting it but producing a severe ecchymosis and contusion of the globe. He fell to the floor of the cab, striking his brow. Later on he sued the railway company for damages. As is noteworthy in such cases the reports of four oculists differed. All of them found lessened visual acuity and slight corneal nebula, but the patient so exaggerated his complaint of poor vision that his answers were not to be relied on. However, the optic disc of the injured eye was pale, with the vessels normal. The visual acuity = 6/lx, and the field concentrically contracted. A diagnosis of a fracture at the canalis opticus was sustained by further deterioration of vision, even after the patient had received compensatory damages.

In a man who committed suicide by jumping out of a window of the hospital just before an expected operation, striking on the occiput, the effect of the transmission of the force along the base of the skull was plainly shown at the postmortem by the shattering of the base and complete fracture of the clinoid processes of the sphenoid, the fracture extending laterally through both optic foramen.

A man was injured in getting off a trolley car, striking against the central supporting pillars holding the trolley wire in position. Four weeks after recovery from the immediate effects of the accident the optic disc of one eye showed blanching, with apparently normal vessels.

The vision was then 6/lx and slowly went on to complete blindness from descending atrophy.

Many such cases may be found in the literature, some of which reach the courts. It behooves the examiner not to be led into error by the apparently normal fundus which exists immediately after, and for several weeks following the accident; and to reserve his opinion until six or more weeks have elapsed, when the time for the appearance of atrophy at the disc should have appeared.

Prescott Hewitt[13] cites 23 cases out of 68 fractures of the base of the skull. von Hölder's[3] statistics gave 79 fractures of the orbital region out of 124 fractures of the skull, of which 86 were of the base; these were observed in postmortems, 54 or 60 per cent. of which had fracture of the wall of the optic canal.

v. Bergmann[17] pointed out the fact that the irradiation of fractures of the forehead tends to go through the optic canal, and that fissures of the skull of the middle fossa tend to go forwards to the clinoid processes. The fracture is usually on the injured side and, as a rule, is on one side.

LITERATURE.

1. Fischer, *Deut. Zeitschr. f. Chir.*, xviii, p. 393.
2. Berlin, *Graefe-Saemisch*, l, vi, 604.
3. Von. Hölder, ref. Berlin.
4. Kuhnt, *Arch. f. Ophth.*, xxv, 4, p. 30.
5. Oishi, *Arch. f. Aug.*, lxi, p. 17, 1908.
6. Leber, *Graefe-Saemisch*, l, vi.
7. Vossius, *Klin. Monatsbl. f. Aug.*, p. 284, 1883.
8. Praun, l. c., p. 402.
9. Evans, J. Jameson, *Brit. Med. Jour.*, p. 329, 1895
10. Decherd, *Med. News*, July 8, 1905.
11. Morton, *N. Y. Med. Jour.*, p. 329, 1895.
12. P. Callan, *Trans. Amer. Ophth. Soc.*, p. 174, 1891.
13. Hewitt, *System of Surgery*, ref. Decherd.
14. Pollak, J., *Wien. Med. Woch.*, Jan. 13, 1906.
15. Pridham, *Austral. Med. Gaz.*, June, 1907.
16. Prescott Hewitt, *Graefe-Saemisch*, l, vi.
17. v. Bergmann, *Lehre von den Kopfverletzungen*, Stuttgart, 1880.

D. INJURIES TO THE OPTIC NERVE IN THE ORBIT, BETWEEN THE FORAMEN OPTICUM AND THE BULB.

(a) Wounds.

We should differentiate between direct wounds and cuts, stabs, and gunshots, which lacerate or cut the nerve directly; and those which are caused indirectly by the force driving broken splinters of bone into the nerve.

A large blunt object may tear the globe away from the nerve, or tear the eye out of the orbit with a portion of the nerve, together with the ocular muscles, as in avulsio bulbi. We differentiate clinically those cases in which the nerve is cut or torn behind the globe at the entry of the retin-

al vessels into the stem of the nerve, and those in which the injury is closer to the globe. In the former the fundus looks normal at first, just as in wounds and lacerations of the nerve in the canal, while in the latter the fundus gives the picture of embolism of the central vessels. In a few cases the nerve has been torn at its insertion in the globe, and here the vessels are entirely empty and the eye shows a hole in the fundus in the place of the optic disc.

Anatomy. The foramen opticum is a funnel-shaped or pyramidal passage with its point inwards. The optic nerve is, according to Merkel[1] 28-29 mm. long; the length of the orbit from the face to the foramen is 43 mm. in man, and 40.5 in woman; other authors give slightly different measurements, doubtless depending upon the type of skull examined. The vasa centralia enter the nerve in its under and inner quadrant, 15-20 mm. from the bulb, and course in the axis of the nerve to the disc when they then spread out in the retina to form the retinal vessels. The optic nerve, therefore, in the orbit, consists of a central portion free from the vessels and a distal part carrying them. Injuries occur in the part without vessels three or four times to once in the portion carrying them, as stands to reason from the movability of the ocular portion, the relative features of the central portion and the fact that knives, sabers, bayonets, etc., are apt to slide along the walls of the orbit to its apex and it is in the latter part where splinters of bone cut or lacerate the nerve.

Etiology. Aschmann's[2] statistics of 18 direct cases not due to firearms show the cause of injury as follows: fencing foils, 5; shoemaker's awl, 2; sharp pieces of iron, 2; sword point, 1; sabre, 1; knife, 1; rapier, 1; bayonet, 1; pencil, 1; sharp end of a bean pole, 1; umbrella end, 1; and one unknown. Numerous observations have been made of bullet wounds of the orbit where the wounding is quite as liable to be in vascular as in the avascular portion of the nerve.

The course of the wound may be from the front between the lids through the conjunctiva and Tenon's capsule or through the closed lids, or from the side, gliding along the orbital walls until the nerve is reached and wholly or partially cut through. Aschmann[2] found that these wounds entered six times as often at the nasal canthus as at the external, cutting the semilunar fold and the lacrimal passages.

Zandler and Geissler[3] also found that foreign bodies enter the orbit most often at this place. Praun[4] wonders that injuries of this character to the optic nerve are not common from pointed objects, as the orbit has no protection anteriorly.

Symptoms and Course. Externally there is to be found a wound of entrance through the conjunctiva, lids or temple; rarely the latter save in bullet wounds. The wound may be of any shape and size. This is one of the instances where the probe plays a principal part in the

diagnosis and should be thoroughly but carefully used in order to establish a proper diagnosis. Very small external wounds rapidly close, and as a rule the damage within the orbit is greater than may be apparent from the external appearances, especially in punctures from pointed or sharp objects. Where the wound gapes, orbital fat protrudes. Ecchymosis of the conjunctiva and lids exists in the region of the wound and may suffuse the whole bulbar conjunctiva and fill the subdermal tissue of the lids, causing suggulation, edema and chemosis of such extent that the wound of entrance may be found with difficulty.

The orbital bleeding and swelling of tissue commonly causes exophthalmos with lessening of the bulbar rotations, which may likewise be due to laceration or cutting through of the muscles and nerves. In many cases there is ptosis and paralysis of the abducens.

The eyeball itself is usually unaffected, except that there is mydriasis, the pupil reacting only consensually, the media clear.

In total solution of continuity of the nerves there is complete blindness, while in partial cases there is amblyopia with contraction of the visual field.

If the patient retain consciousness he will doubtless remember that at the moment of the accident there was a blinding flash of light, but this symptom also occurs in severe contusions.

Examination with the ophthalmoscope shows no changes in the fundus at first, where the injury has occurred to the nerve behind the entrance to the retinal vessels into the optic nerve stem, except in rare instances where the edges of the disc may be a little hazy and the veins somewhat tortuous, but in a week to six weeks the picture changes to that of optic nerve atrophy, the blanching of the disc beginning in the temporal half and extending over the entire surface. The edges of the disc become sharply defined, but the vessels retain their normal caliber. If the nerve be not fully discided then a sector atrophies and but a part of the disc corresponding to the sector of contact, or of the visual field, becomes white.

In gunshot injuries the picture is usually different for in most cases the blood vessel carrying part of the nerve is injured. Here the ophthalmoscope shows the picture of embolism and at first a grave edema so that it looks like Berlin's opacity. The edges of the papilla are blurred, passing into the retina without definition. The edema is greatest at the macula, and the periphery may be normal or show chorioidal changes. The retinal vessels, where they are visible, are entirely empty of blood, or are interrupted in their course. Later on the vessels may partially fill again, either from the collateral circulation from the vessels of Zinn, or from canalization of the thrombus, but incompletely, so that arteries and veins look alike. The retinal edema gradually disappears and pigmenta-

tion occurs. After some weeks optic nerve atrophy, with sharply defined disc edges and contracted vessels, is found.

Complications. These are of coincident injury to the lids, lacrimal apparatus, and orbital structures; without infection of the wound canal, the hematoma of the orbit, as well as injuries to the canal and to the brain, are of great importance. Sepsis of the orbit naturally leads to not only local abscess, but likewise to septicemia. Many cases of foreign bodies retained in the orbit without the knowledge of the patient or attendant have been reported; especially to be noted are those of punctures where the end of the object has broken off in the depths of the orbit.

Diagnosis. The patient's history is that of a blow or penetrating wound of the orbit with resultant blindness, commonly attended by a subjective flash of light at the moment of injury or in the case of firearms, through accident, attempted suicide, or murder.

Where possible the surgeon should examine the object producing the injury to see its nature and if any portion of object has been broken off and thus remain in the wound.

The character of the lid and conjunctival wound is observed and whether or not infected. The probe will be used to open the wound and let out serum or pus. The amaurosis with enlargement of the pupil and remaining consensual reaction, the normal fundus in apex cases, and the embolic appearance where the nerve is injured near the globe, gives the diagnosis. If the sight returns there must have been hemorrhage; if atrophy occurs in a week there has been a cutting through of the nerve. The character of the injury shows whether or not the nerve has been injured in the orbit or in the canalis opticus.

Prognosis. Retention or return of function after complete section has not been observed, either in the lower animals or in man. In a few cases where the laceration or section has been incomplete there may be amblyopia with contracted visual fields for a while, but usually the case proceeds to complete atrophy and blindness. Laceration of the nerve may lead to sympathetic ophthalmitis.

Therapy. The therapy is surgical, being that of wounds of the orbit. It is questionable whether in partial atrophy following incomplete section of the nerve or not, strychnin, mercurial inunctions, or massage and electricity have any influence. In laceration of the nerve enucleation may be necessary.

Treitel[6] saw a soldier whose orbit was punctured by a comrade's bayonet, with pain and immediate blindness. Bulb not injured and intact movements, pupil enlarged reacting synergetically, papilla normal, wound of lower lid. Retina somewhat grayish; vessels normal. Fifteen days

later undoubted atrophy of the temporal papillary fibers; four weeks later the retinal vessels smaller.

Pagenstecher[7] saw a girl who was injured by the iron-shod end of a pole. Unconsciousness, great bleeding, vomiting and headache. Four days later amaurosis. Wound outwards in the orbit; no fractures. Bulb forwards, not injured. The enlarged pupil did not react to either direct light or consensually. Red reflex from the pupil and the papilla could not be seen; blood vessels interrupted by blood clots and the veins could not be differentiated from arteries; the entrance of the nerve was localized as a whitish zone about four times the width of the normal disc. The next day the edema had almost passed away and later the reddish nerve head was seen, its edges became defined and the vessels partially filled. Pigment appeared in the periphery of the fundus and proceeded to the papilla, in which pigmentation with contraction of the vessels later occurred.

(b) Foreign bodies.

These are practically limited to small iron, wood, glass, and stone particles, with the exception of shot grains. It is likewise possible for particles of bone to enter the nerve. Lengthy objects, as wood splinters, may not only pass into the orbit through the nerve, but also into the cranial cavity, remaining in all these locations at the same time. This subject is discussed more fully under Injuries of the Orbit.

von Graefe[8] reported shot pellets in the orbital portion of the nerve; Ravà[9] a piece of gun cap; Hillemans[10] a piece of stone, which was found on cutting through the nerve on enucleation.

(c) Injuries from blunt objects, contusion, laceration and dislocation.

Contused and lacterated wounds of the optic nerve from the impact of blunt objects such as sticks, umbrellas, and splinters of wood, as well as in gunshot injuries in which the impact of the bullet may cause contusion, as well as laceration or complete tearing of the nerve from the globe, have been observed.

The cubic contents of the orbit, according to Vierordt,[11] are 27-33 ccm. When a foreign body of any size intrudes into the orbit the eye is forced outwards and the nerve may be torn out of its insertion at the scleral opening or the nerve torn across, the bulb thereby remaining intact.

Salzmann[12] understands by evulsio nervi optici the forcible backward dislocation of the optic nerve from the scleral canal without any break in the continuity of the coats of the eyeball in the immediate vicinity. The injury is so rare that the author was only able to find in the literature seven cases to compare with the one observed by him-

self, and in five only of these cases were ophthalmoscopic conditions known. The other cases had been reported as purely anatomical findings.

Symptoms and Course. The ophthalmoscopic picture of evulsion of the optic nerve is characterized first of all by the absence of the papilla and its vessels. In place of the optic disc a deep hole or excavation is seen, due to the tearing backward of the optic nerve from its canal, which in turn is filled to a considerable depth by the vitreous pressing backward. In Salzmann's case the depth of the hole was about four millimeters; in Aschman's and Birch-Hirschfeld's, the only others in which measurements were taken, something like 2.5 and 2.0 mm. respectively.

The question why in these cases the extravasation of blood into the empty optic nerve canal was so inconsiderable is easily answered. It is only in a few isolated cases that the fundus is clear enough to permit of a diagnosis of this condition by means of the ophthalmoscope; numerous other examples of evulsio nervi optici, in which the affected territory is obscured by hemorrhage and the like, must necessarily pass unrecognized.

The floor of the hole is formed by tissue, the exact nature of which cannot be made out ophthalmoscopically. It appears for the most part of a gray shade; only in Salzmann's case was it at the commencement dark-red in color, changing later toward the end of the period of observation into a gray. Generally, however, the color of the floor is strikingly dark, and this fact excludes any possibility of confusion with an ordinary excavation. Differences in the level of the floor in Salzmann's case were made out with certainty by the direct method and also with refractive differences and parallactic movements in high degrees.

Such a backward displacement of the optic nerve without a break in the continuity of the lamina cribrosa is hardly to be thought of, and Salzmann believes that this structure in great part is torn out of the canal along with the optic nerve. Still greater, however, is the uncertainty as to how the dural sheath of the nerve behaves in these cases. Ophthalmoscopic examination reveals nothing and anatomical findings only show that separation may or may not be present. As regards the retina, in pronounced cases, such as Salzmann's, Aschman's, and possibly also Kariafiath's, this structure was torn through about the whole circumference of the papilla; in Birch-Hirschfeld's patient, however, a refilling of the retinal vessels in their full extent seemed to show that no break in continuity had taken place. It goes without saying that in an end artery like the arteria centralis retinæ, such a circular rupture of the retina must lead to an anemia in the strictest sense of the word in the parts left in situ. The fact that in Salzmann's case the arteries and veins reacquired their normal color and calibre in ten

and fourteen days respectively must be explained by means of fresh anastomoses with the chorioidal vessels at the point of separation.

As regards the subjective symptoms, there is little to say; like the other injuries of the optic nerve evulsio nervi optici causes immediate and permanent blindness. Unfortunately, our knowledge concerning the outcome of these injuries is very faulty. In Nicolai's case there formed after a month an excavation of a greenish color, but the vessels did not reappear. In Birch-Hirschfeld's case masses of whitish scar tissue formed in front of the papilla and macular area hiding these parts. In Salzmann's case there was a tendency for the hole to fill up from the bottom; the depression disappeared and the foramen opticum scleræ became smaller, an occurrence attributable to contraction of scar tissue which had formed in the floor and sides of the excavation.

From an etiological standpoint, the eight cases of evulso nervi optici fall into two groups of four cases each. In the one set there is a history of trauma resulting from the entrance in the orbit from before backward of a blunt body, umbrella (His), cow's horn (Pagenstecher), bean-pole (Aschman), hay-fork prong (Birch-Hirschfeld). In the other group (Kariafiath, Issekutz, Nicolai and Salzmann), the injury was due to a revolver shot at close range.[13]

Hesse[14] tells of a case in which a playmate stuck the point of a cane into the left eye of a patient, aged 12, at the inner angle. A profuse hemorrhage ensued with intense pain and instantaneous blindness. Cornea was dull, anterior chamber very deep, almost completely filled with fresh blood, partly liquid, partly coagulated. The eye was very sensitive to pressure. As the amaurosis remained, the pain increased and the tension diminished, the eyeball was enucleated after three months. Iris, ciliary body and anterior portions of the chorioid showed inflammatory changes, the retina was totally detached, very much folded and torn off from the ora serrata. The disc presented the aspect of partial evulsion of the optic nerve; the retina torn from the temporal margin of the optic nerve and displaced to the side, the lamina cribrosa partly severed from the insertion at the sclera to the extent of the temporal third of the margin at the margin of the disc. Through this hole vitreous and blood had entered the intervaginal space. A large accumulation of blood had forced the loose tissue of the pia apart. The dural sheath of the optic nerve was not damaged, the nerve only being dislocated backwards. Apparently the cane had forced the eyeball into extreme adduction, thus stretching the optic nerve, so that it finally tore off at the point of greatest tension, viz., at its temporal portion. A similar case of Dimmer is briefly reported.

The same sort of injury may happen from gunshot. Nurnberger[15] had two cases, in one of which the place of the papilla was occupied by a

large white striped area; in the other the retina was pulled backwards into the hole, forming folds.

Gehl[16] had one in which the nerve, together with the retina, was torn out of the eye.

C. Zimmermann[17] reported an unique case of laceration of the optic nerve near the bulb, which was followed by retinitis proliferans. A man fell from an electric car on the right side of his face, the visor of his cap striking nose and eye. He did not lose consciousness and immediately went to a physician, showing horizontal wound of the upper lid and vertical at median angle of palpebral fissure; nasal bones fractured; considerable bleeding; sutures were placed. Three days later no exophthalmus; chemosis of conjunctiva; ptosis; impeded ocular motion, out, down and up. Pupil irregular; not reacting to light directly and but slightly consensually. Media clear; optic disc not clearly defined; most blood vessels lacking, some linked; edema as in embolism; retinal hemorrhages. V = o. Tn. normal. Case observed for about a year afterwards when tension diminished. Eye blind, vitreous membranes with newformed blood vessels—a picture of retinitis proliferans.

Pischler[18] reports imperfect evulsion of the optic nerve from the kick of a horse, on the cheek below the eye. Immediate blindness, amaurotic immobile pupil, exophthalmus from fractured lower and medial orbital walls. Displacement of disc backward, connective tissue formation in the vitreous with cavernous network of fibers over disc and a grey band projecting into vitreous, ending in a fine tuft.

(d) Gunshot injuries.

These injuries have been noted in the foregoing pages. The rule is that the nerve is injured by a shot from a lateral direction going through the orbit, generally in cases of attempted suicide, seldom from accident or in war. The ball goes in most often from the temporal side, usually the right, the pistol being placed more or less perpendicular to the temple, when the direction of the shot is not toward the brain, but in front of the apex of the orbit. Thus the ball goes upwards and forwards, missing its purpose so far that in some cases the opposite optic nerve is injured.

In but few cases in which the optic nerve is injured without destroying the globe, has the direction been from the front. Leber[19] describes a case in which the wound of entrance was at the inner canthus. Hirschberg[20], in his article on the eye and the revolver, says that half of the attempted suicides die and about a third lose the sight of the right eye from attempted suicide by the revolver.

LITERATURE.

1. Merkel, *Graefe-Saemisch,* I.
2. Aschmann, *Inaug. Dissert.,* Zurich, 1884.
3. Zandler and Geissler, ref. Praun l. c. p. 412.
4. Praun, l. c., p. 413.
5. Praun, l. c., p. 415.
6. Treitel, *Arch. f. Aug.,* x, 4.
7. Pagenstecher, *Arch. f. Ophth.* xv, 1, p. 223.
8. von Graefe, ref. *Graefe-Saemisch,* v, p. 916.
9. Rava, *Ann. di. Ottal,* 1881, p. 298.
10. Hillemanns, *Arch. f. Aug.,* xxii, 3, p. 198.
11. Vierordt, *Daten u. Tab. f. Med.,* p. 74.
12. Salzmann, *Zeitschr. f. Aug.,* May, 1903, ref. also Birch-Hirschfeld, Aschmann, Kariafiath, Nicolai, His, Pagenstecher, Issekutz.
13. Rev. in *Ophth. Record.,* Vol. xii, p. 399.
14. Hesse, *Zeitschr. f. Aug.,* Jan., 1907, p. 45.
15. Nurnberger, *Inaug. Dissert.,* Kiel, 1888.
16. Gehl, *Inaug. Dissert.,* Kiel, 1894.
17. C. Zimmermann, *Arch. Ophth.,* xxvi, No. 1, 1897.
18. Pischler, *Klin. Mon. f. Aug.,* 48, II, p. 246.
19. Leber, *Graefe-Saemisch,* v, p. 915.
20. Hirschberg, *Berl. Klin. Woch.,* 38, 1891.

E. THE OPHTHALMOSCOPIC SIGNS OF INJURY TO THE OPTIC NERVE.

Wagenmann[1] experimented on rabbits, and showed that in some the retinal vessels had not been divided, as supposed by the authors, and that some of the subsequent ophthalmoscopic changes were due to a division of the ciliary, not the retinal, vessels. In order to verify whether the ciliary or the retinal vessels, or both, were divided, he made injections from the common carotid artery, a method which alone can yield reliable results.

Wagenmann examined his rabbits with the ophthalmoscope, a few minutes after division of the optic nerve and the central retinal vessels, and saw the disc become pale and white, the vessels narrowing by the blood current being cut off, the papillary portion emptying its blood outside, and following interruption of the blood current in several portions. When he divided the central vessels by the galvano or thermocautery, the vessels on the disc contained decidedly more blood, and the current did not spread as readily into several portions, because the eschar obviated an effusion of blood into the orbit.

Von Hölder[2] found in his cases of divers firearms injuries that the nerve itself was commonly torn through, although in some only partly lacerated, and that bleeding into the nerve sheath recovered in 77 per cent. Demme[3] noted bleeding into the nerve substance which Berlin[4] ascribes to a stretching and rupture of its smaller blood vessels.

Mechanism. A force which breaks the bone of the canal carries along with it in its sheath at the upper part where it is closely attached and rips open the connective tissue and with it the nerve itself. The anterior and posterior clinoid processes or other parts of the broken

bone impinge on or compress the nerve. Compression and contusion may thus occur without tearing of the nerve itself, and from direct compression or from the secondary effect of the callus formation thus giving rise to pressure atrophy.

Wagenmann[1] says the nerve tissue is usually immediately affected, as shown by Berlin's 27 cases of amaurosis or amblyopia, in which 24 became permanently blind.

The visual field, as shown by Leber and Deutschmann[5] of mildly injured cases, indicates that the nerve is torn below, as the defect is in the upper half.

Symptoms. The clinical picture is many sided, depending upon the extent of the injury, whether or not the nerve tissue itself is injured,

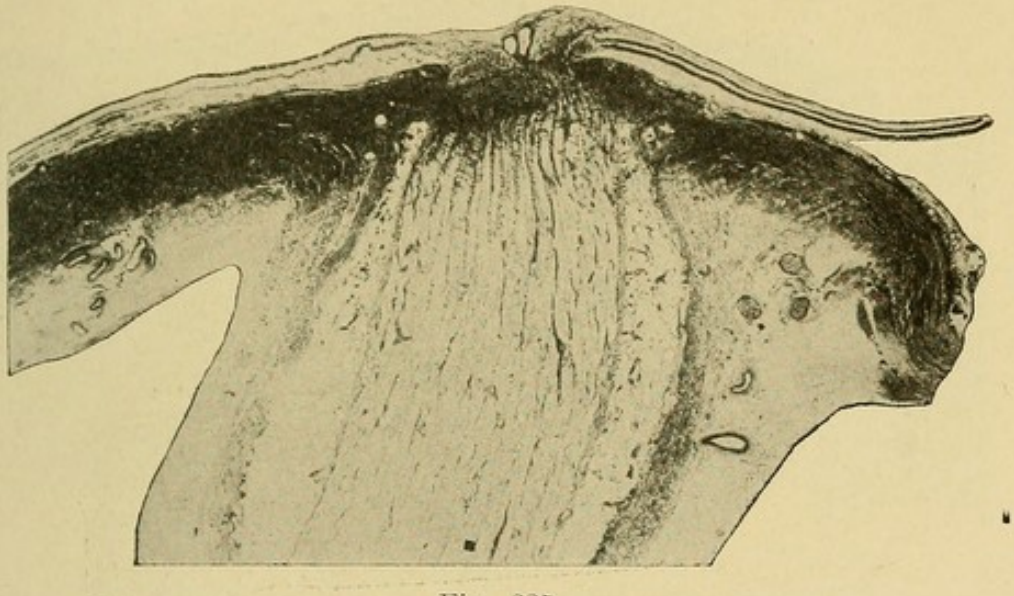

Fig. 325.
Section of optic disc in mild optic neuritis. (Gunn).

how much laceration or compression exists, and the extent of the hemorrhage.

If the nerve be fully torn through as a rule the immediate ophthalmoscopic picture is normal, but there is blindness. After a short time the disc becomes white. If it be partially lacerated amblyopia exists. Bleeding into the sheath causes compression of the nerve and interferes with its blood circulation so that here there is a high grade of amblyopia with contraction of the visual field, especially in the upper part. Immediate closure of the blood vessels causes arterial ischemia and venous hyperemia, which may be so great as to produce appearances like choked disc, owing to edema of the nerve. When the blood is resorbed cases of partial laceration or pressure may regain some vision.

All severe cases, with fracture of the base of the skull are accompanied by symptoms of brain concussion, contusion or compression; as loss

of consciousness, vomiting, bleeding from the mouth, nose and ears and into the orbit, with slight or great exophthalmus. It is to be noted that the subconjunctival hemorrhage from fracture of the skull first appears at the outer canthus and proceeds to chemosis and suffusion of the lids. In many we find loss of speech, hearing, taste and smell, hemiplegia and paralysis of the ocular muscles. These symptoms may be entirely absent in light injury where the fracture is only a fissure or it is isolated, and where the cranial periosteum is not torn through.

The pathogonomonic symptoms of direct injury to the optic nerve in fractures of the base are immediate, complete, and irrecoverable, one-sided loss of sight. In a few cases this has been on both sides, where the fracture must have gone through the base of the skull sideways, in-

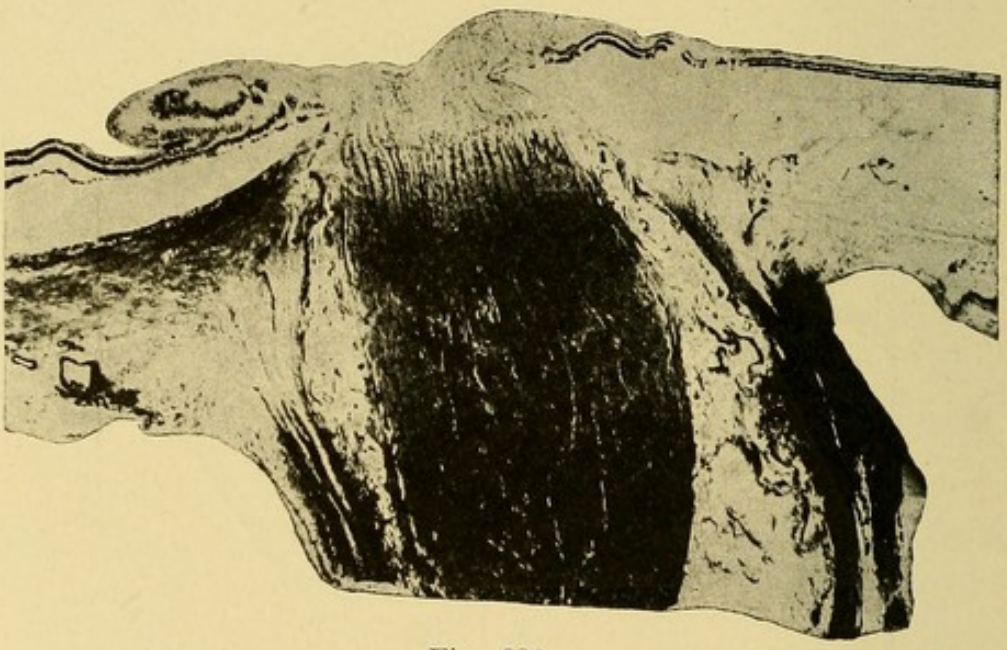

Fig. 326.
Section of optic disc in severe optic neuritis. (Gunn.)

juring either both foramen; or from behind forwards, as in the case of a person falling backwards and striking the occiput, with resultant fracture of the base.

If there be amblyopia with contraction of the field, caused by incomplete rupture or compression of the nerve, a feeble, direct reaction of the pupil remains. If complete loss of sensation there is an immovable pupil. No restoration of function occurs when the injury is complete.

At first the optic nerve head and retina may appear normal where immediate compression from a hematoma of the sheath does not occur after two to six weeks; as a rule in three weeks descending white atrophy with sharply defined edges of the papilla occurs, with normal sized blood vessels. In but few cases do the arteries and veins become smaller.

Leber[6] refers those cases where there is congestion, edema and neuritis, with resultant thickening of the vessel walls and reduction in their size, to extravasation of blood in the sheath and nerve tissue, or partial thrombosis.

Descending atrophy caused by interruption of the continuity between the central organ and the eye takes about three weeks before it shows as a blanching, and then a whiteness, of the papilla. Praun[7] reports a case in which the blanching was seen in 14 days.

The clinical picture is far different where there is no interruption of the continuity, but either compression from a bony fragment or from hemorrhage that has occurred. Acute ischemia of the fundus occurs with the retinal arteries and veins much contracted, streaks of blood in the

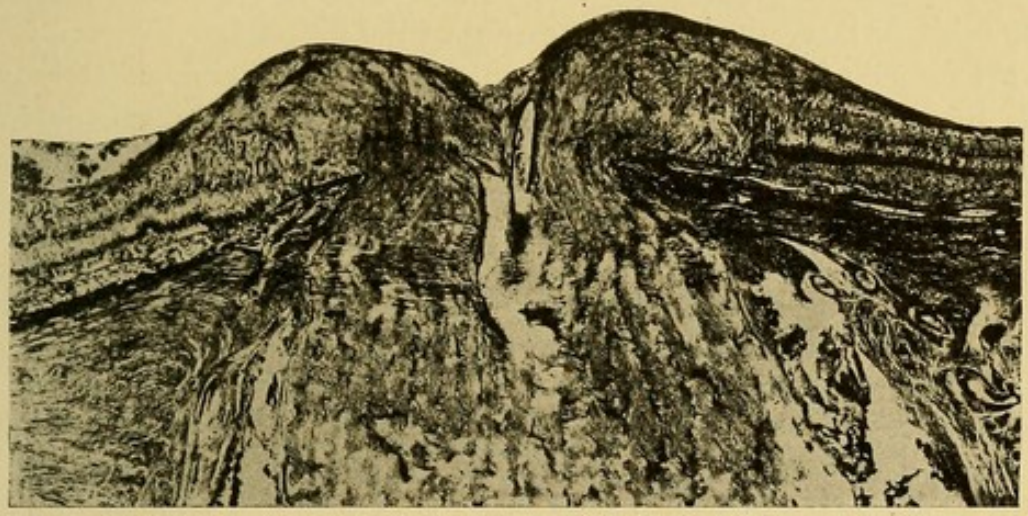

Fig. 327.
Section of optic disc in moderate optic neuritis. (Gunn.)

nerve head, retina and vitreous. The nerve sheaths are opaque and the retina whitish. This should not be mistaken for atrophy, as it is seen immediately after the accident.

If the hemorrhage ceases before the nerve is fully compressed the ischemia passes into venous stasis with edema and hemorrhage of the papilla, the veins greatly enlarged, and later neuritis or neuro-retinitis follows.

The loss of sight is not complete and the patient may ultimately recover useful vision, but with some degree of amblyopia remaining. In some cases there may be pigment migration into the papilla, as reported by H. Knapp[8].

The course and results of hemorrhage are much more favorable than in the direct injuries to the nerve. The peripheral nerve fibers being most compressed in hemorrhage, there consequently follows peripheric contraction of the field, and as the macular fibers in the canalis opticus

pass through the center of the nerve there is not so much pressure thereon. The atrophy is mostly confined to the peripheric fibers and thus the field of vision remains contracted with more or less amblyopia.

Complications. As we have shown, basal fractures are apt to be complicated with severe injuries to the brain; even so is the fracture at the optic canal of special interest in connection with high grades of exophthalmus from bleeding into the orbit, pulsating exophthalmus and diabetes insipidus as reported by Weiss[9] and Nieden.[10]

Berlin[4], Leber[6], and others have shown cases complicated by various cranial paralyses, especially of the oculo-motor and the abducens, more seldom of the trochlearis, acousticus, facialis, and ophthalmic division of the trigeminus. In such cases there has been laceration, crushing or compressing of the nerves in these passages through the foramen or in the orbit, or laceration or compression of the muscles.

Diagnosis. One-sided blindness happening immediately after blows upon the skull points to an injury behind the chiasm, or in the orbit or canalis opticus behind the entrance of the central retinal vessels, if on ophthalmoscopic examination the retinal vessels be found normal. If the injury be at the chiasm the blindness will be on both sides. The localization is often difficult and impossible except by autopsy, whether or not the injury be in the canalis opticus or within the cranial cavity.

As a rule the injury is in both these situations. The one-sided, sudden, and irrecoverable blindness with resultant atrophy speaks for both.

The differential diagnosis between full or partial solution of continuity or compression from hemorrhage is determined from the ophthalmoscopic examination. In the first instance, either complete or partial blindness occurs with little or no change in the fundus, followed some weeks later by optic nerve atrophy with contraction of the field. In hemorrhage the amaurosis or amblyopia with blanching or edema of the papilla and even neuritis, is not instant to the accident, but follows some hours or days later and tends to partial recovery.

Simulation and aggravation of symptoms are often seen in examining this class of cases for the results of such an injury. Thus various tests for these forms of malingering should not be neglected in the examination.

The Prognosis in complete laceration or severe contusion of the optic stem is altogether bad, as atrophy always results. In incomplete tearing or contusions partial sight may remain. Compression cases from hemorrhage have a better future, as resorption of the blood ensues with more or less return of vision. A definite prognosis should be reserved until the optic disc commences to show signs of atrophy or until after two months have passed.

The Therapy is that of fracture of the base of the skull. In

direct injuries, as from gunshot wounds, drainage, antisepsis and removal of fragments of tissue or loose bone. Probing is, as a rule, not to be indulged in. If the injury is from a bullet it may become encapsulated and the wound heal. When the nerve has been torn through in whole or in part there is no hope for regeneration, but where the loss of sight has been due to compression by hemorrhage, mercury by inunction, by intragluteal injection, and the hypodermic injection of strychnin are advocated. Suction, vibratory massage of the eye, the high tension and high frequency electrical applications, are recommended above all.[11]

LITERATURE.

1. Wagenmann, *Arch. f. Ophth.*, xxxvi, iv, p. 1.
2. von Hölder, ref. Berlin.
3. Demme, ref. Berlin.
4. Berlin, *Graefe-Saemisch*, vi.
5. Leber and Deutschmann, *Arch. f. Ophth.*, xxvi, 1.
6. Leber, *Graefe-Saemisch*, v, p. 219.
7. Praun, *Die Verletzungen des Auges*, p. 406.
8. Knapp, H., *Arch. f. Ophth.*, xiv, 1, p. 254.
9. Weiss, *Arch. f. Aug.*, xxxi, 4, p. 407.
10. Nieden, *Arch. f. Aug.*, xii, 1.
11. Würdemann, *Ophthalmology*, Jan., 1907, and *Ophthalmology*, Jan., 1908.

F. INJURIES TO THE OPTIC PAPILLA.

Wounds. Isolated wounds of the papilla are possible from foreign bodies entering the eye and passing into the vitreous, rebounding against the papilla. Hyperemia of the spot of contact, and blood streaks in the vitreous will be found. Wounds of the disc must occur in some cases of deeply penetrating stab wounds, but also involve the other coats of the eye.

Mauthner[1] describes a boy injured by an arrow bolt which penetrated the sclera and stuck in the eye until removed by the boy himself. Two years afterward inflammation had subsided, the vision was 2/vii and a tear of the papilla was seen.

Foreign Bodies. In a few cases small splinters of iron, copper, sand, glass and stone have been found in the papilla. Oeller[2] shows one such in his atlas. Webster[3] found upon enucleation a piece of a copper gun cap in the papilla.

Papillitis Accompanying Injuries of the Anterior Part of the Eye.

The serous swelling in this form of papillitis surpasses the infiltration in the histological picture and resembles much the choked disc as seen with affections in the brain cavity. Elschnig[4] demonstrated the chief difference between the induced papillitis of cerebral and that of ocular origin. In the first form the lamina cribrosa is arched anteriorly, in the second the lamina scleralis has a normal vaulting. In the ocular

form the physiologic excavation shows the infiltration, first described by Kampherstein and Van der Berg,[5] as well in the experimental as in the pathologico-anatomical examination. The papillitis does not originate by progression of the infection in the optic nerve, but only by chemical action, in the same way as, for instance, collateral edema in the neighborhood of other inflammatory foci.

Pathology. Rümsczwicz[6] examined microscopically four eyeballs enucleated following wounds of the anterior part. He found in all the cases changes in the optic papilla which are characteristic of papillitis. The only difference was that the lamina cribrosa is pressed, not forward, but backward. The changes in the disc following injury to the cornea, iris, or lens have been described by many authors. Hirschberg, Elschnig, Stack, Kampherstein, Uhthoff, Yudin, Knapp, Van der Berg, Hoppe, not only clinically but anatomically studied and published their findings. Rümszwicz observed further in a case of tubercular kerato-iritis, a well-defined papillitis which showed itself on microscopical study to be of inflammatory and not tubercular origin. The author believes that the cause of this papillitis is the toxins which in this case very easily reach the optic nerve. The outflow of the intra-ocular lymph, on account of the adhesion of the space of Fontana and canal of Schlemm, surely takes the way through the spaces surrounding the optic nerve, and in greater quantities than in normal conditions. It seems most probable that the origin of papillitis in injury to the anterior part of the eyeball is through these same channels.

According to the idea of the author the inflammation of the papilla, both in cases of poisonous toxins and following traumatic inflammation is due to disturbance of the intraocular lymph.

Van der Berg[5] describes a number of cases, among them a 10 year old boy who had a perforating wound in the nasal side of the cornea. Blood upon the iris and in the pupillary opening prevented judging the deeper parts. T — 1. Slight edema. Next day the surroundings of the wound were more opaque; deep grayish discoloration. The eye became more painful. T. seemed higher, swelling of the lower lid increased, chemosis and small hypopion. At the fifth day a grayish-white reflex from the fundus. T = N. Hypopion disappeared. On the seventeenth day enucleation on account of increased painfulness, peri-corneal injection and opacity of the vitreous with diminished tension. The wound in the cornea had healed, epithelium grown in the cicatrix. Separate leucocytes in the anterior chamber, in masses against the posterior surface of the cornea and on a fibrine-layer, which had shrunk through the hardening. The defect in sclera and chorioid was filled with new-formed connective tissue with numerous vessels, in direct contact with the shrunken vitreous. At the posterior surface of the lens a well-limited infiltration

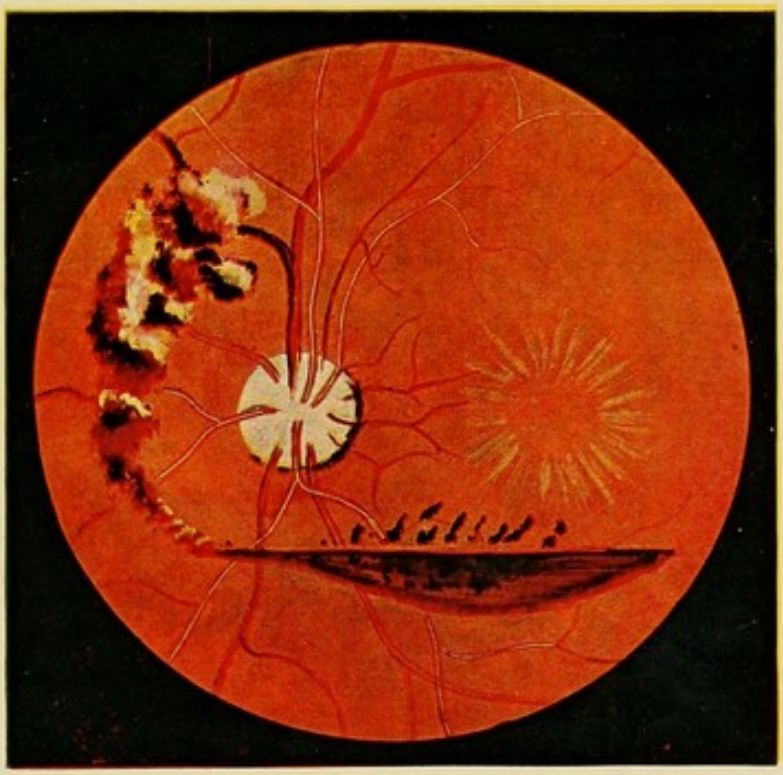

PLATE XIX

Rupture of superior nasal vein. Pre-retinal hemorrhage.

with leucocytes. In the posterior part of the vitreous separate leucocytes, also here and there in small masses on the retina and some on vitreous membranes. The retina bordering the disc was swollen through serum, on it lay some masses of leucocytes. The chorioid swollen through filling of the large veins; in the most forward part above the ora serrata the capillary layer was strongly infiltrated. The intraocular part of the optic nerve was thickened, most in the middle, a little above 0.5 mm. The funnel around the vessels corresponding to a physiologic excavation was thickly infiltrated, also the most superficial layer of tissue. A number of brown pigment particles lay upon the optic nerve; the scleral part of the lamina cribrosa convex to the back.

Haab,[7] in plate 17 of his *Atlas,* pictures optic neuritis from intense inflammation of the optic nerve after meningitis caused by a blow upon the head. The inflammation existed in both eyes, leading to marked infiltration of the tissues of the nerve, manifesting itself in grayish-white patches and striæ on the papilla and surrounding portions of the retina, and in the hemorrhages on the lower border of the described areas. The diameter of the nerve is enlarged and the nerve itself moderately swollen and prominent, the veins distended and tortuous.

Etiology. Fracture of the bones of the orbit, and especially hemorrhage into the nerve sheaths of cellular tissue of the orbit and secondary cellulitis of the orbit or meningitis following head injuries, is frequently found clinically in traumatisms of the anterior part of the eye combined with infection and with tuberculosis of the anterior part and with true inflammation of the vitreous body, where it only can be observed after resorption of the exudate.

Symptoms and Course. These are similar to those of papillitis from other causes and will not be entered into here, except to mention that the atrophy following is grayish, the edges of the nerves not being well-defined and both veins and arteries become contracted, where a papillitis develops during a traumatic or inflammatory affection of the anterior part of the eye. When the anterior part of the eye recovers then also the inflammation of the optic nerve passes away.

Therapy is that of the cause, and has been considered in several of the preceding chapters.

LITERATURE.

1. Mauthner, *Vortr. a. d. gesamt. geb. der. Augenklinik,* Wiesbaden, 1878, p. 9
2. Oeller, *Ophth. Atlas* 4, plate xiv.
3. Webster, *Arch. f. Aug.* xxi, 2.
4. Elschnig, ref. Rümszwicz.
5. Van der Berg, *Tydschr. v. Gen.*, Feb. 29, 1908.
6. Rümszwicz, *Postep. Okulyst.* 4, 1909, ref. also Hirschberg, Elschnig, Stack, Kampherstein, Uhthoff, Yudin, Knapp, Van der Berg, Hoppe.
7. Haab, *Atlas Ophthalmoscopy,* deSchweinitz Amer. Ed., Plate 17, 1909.

CHAPTER XXVI.

INJURIES OF THE LIDS.

A. Wounds. (a) Incised wounds—Etiology—Symptoms and course—Therapy. (b) Punctured wounds—Etiology and course—Complications. (c) Stabs. (d) Lacerations and contused wounds—Etiology—Symptoms and course—Infections — Erysipelas — Gangrene—Syphilis. Therapy—Plastic operations—Literature. B. Foreign bodies—Etiology—Symptoms—Diagnosis—Therapy—Prognosis—Literature. C. Injuries from blunt objects. (a) Extravasation or Suggulation—Etiology, Symptoms and course—Therapy. (b) Emphysema. (c) Contusions. (d) Burns and cauterizations—Etiology—Prognosis—Therapy—Literature. D. Injuries from fire arms—Literature. E. Tumor formation after injury—Literature.

Injuries of the lids are very common, not only from industrial accidents but even in family practice, and are to be noted for forensic purposes as they may be an important factor in evidence, especially as they are the external signs of many deeper injuries to the eye and cranium.

A. WOUNDS.

a. Incised wounds.

Etiology. All kinds of sharp objects used in work or play, accident or assault, cause these lid wounds, many of which are but the external signs of deeper injuries, and complicated by those of the frontal, nasal, or temporal regions and the face, as well as those of the eye and orbit.

Nance[1] refers to the extreme infrequency of injuries to the eyeball caused by broken lenses. He refers to seven cases of injuries to the ocular appendages that have come under his observation, in which the wound was caused by broken lenses. He believes that injuries to the eyeball by broken lenses are extremely rare; that injuries to the ocular appendages are more common; that they occur more frequently among wearers of spectacles than nose glasses; that the injury is usually due to breaking of rimless glasses, and that such injuries are extremely rare in patients under the age of 14 years. Samuel Higgins[2] also reports such injury.

A marked case of such injury in my experience was that of an iron worker who was accidentally struck by a wrench in the hands of another workman. The young man had acquired his first pair of eye glasses

only two days before. The lens was broken, one piece passing through the upper lid, making a large ciliary region injury with prolapse of iris and vitreous down and out. Another direct penetrating wound of the globe above and in. Iridectomy and double Kuhnt flaps secured healing of globe with V = objects. The lid wound was stitched and healed by first intention.

Another case was that of a young man with gonorrheal iritis who was under atropin and wearing dark glasses. Was struck by street car at a crossing and the lower lid torn through by the rim of the glasses. The parts were brought together and healed with scarcely perceptible scar.

Symptoms and Course. The wound may be superficial, cutting only the skin or through the muscle, tarsus and conjunctiva, in some cases only penetrating, in others dividing the lid, in which it may be followed by a permanent coloboma and great deformity. From the cicatrization, ectropia, entropia, lagophthalmus and other deformities result. In many cases the patient appears with the lid-wound gaping and full of dust, but the blood supply is so rich that infection rarely results.

Horizontal wounds, parallel with the fibers of the orbicularis muscle, come together and often heal without suturing, leaving but little cicatrix except where the entire lid has been cut through, a lengthy wound resulting. If the wound be vertical the edges gape widely and do not tend to heal together unless rendered aseptic and properly stitched.

Ptosis occurs from cicatrization of the upper lid and interference with the drainage of the tears through the lacrimo-nasal duct from injury to the lower, whereby a chronic irritation and eczema of the lid and cheek is produced. From incomplete closure of the lids chronic conjunctivitis and ulceration of the cornea results. If the septum orbitale or fascia tarso-orbitalis be divided the lid is not well supported, so ectropion or entropion results.

The common complications are injuries to the orbital margin and soft parts, cutting into the lacrimal canal or gland, symblepharon and cicatricial changes producing ectropion, entropion, trichiasis, stoppage of the lacrimal passages, and lagophthalmus from shortening and defects of the lids.

Therapy. Longitudinal wounds that do not gape tend to heal kindly unless they are deep or of some extent, otherwise stitches may not be needed, but if the deeper structures be injured, especially in the case of the levator tendon of the lid so that ptosis is produced, the divided ends should be sought and joined together with several interrupted catgut sutures and the skin wound sewed with silk. Where the lid is divided vertically so that a coloboma is produced the edges

PLATE XX

Dialysis of retina

should be brought together not only by interrupted fine silk sutures, but as the skin is so delicate and thus easily torn, and swelling is apt to ensue, deep tension stitches should also be placed outside of the wound sutures. In old cases the edges of the coloboma are to be freshened and then sutured together. Where sloughing has caused loss of tissue, flap and whole-skin grafts may be made.

b. Punctured wounds.

Etiology and Course. Small punctures from clean instruments are not at all dangerous, but those which perforate the lid through to the conjunctival surface, or to the lacrimal sac or gland, may leave a permanent fistulous opening through which the tears flow. Praun[3] notes a fistula produced by a leech bite. Symplepharon may likewise occur.

The fascia tarso-orbicularis is easily torn by such wounds, the healing resulting in dislocation of the lid from the eye because of cicatricial contraction. The direction of these wounds is generally backwards.

Praun[3] reports the case of a wire drawer who had a piece of wire 5 cm. long going in 2 cm. into the upper lid between the skin and the cartilage. This healed in 8 days.

At times cilia may be torn away or carried into the wound if it be at the ciliary margin of the lids.

The Complications of penetrating wounds of the lids are of coincidental injury to the globe and the orbit, usually through foreign bodies of some size. But often smaller foreign bodies, as shot pellets, chips of metal, glass, sand and stone from explosives may pass through the lid. Recognition of the port of entry should be made by stretching the lids and by close examination. The probe may be sparingly and carefully used.

c. Stabs.

Stabs come from sabres and knives and were more common in the older days than in this age, but are occasionally seen now, as in the following: A young man was cut by a large-bladed pocket knife during a drunken fight, the stab extending from the brow to and through the upper lid, but not to the margin thereof, and incised the globe. Full healing with no symplepharon, but isolated detachment of the retina and contracted visual field.

d. Lacerations and contused wounds.

Etiology. Tears and bruised wounds are perhaps more common than cuts and punctures, as they obtain, in most cases, from foreign bodies entering the orbit, particularly in the case of broken timbers,

handles of tools, bullet injuries, explosives of powder and dynamite, cow horns, tears from claws and lacerations from bites, and contused wounds from hoofs of animals. The butcher's meat hook has caused several such injuries in my practice.

R o d e n w a l d[4] described a number of such injuries from animals, one of which happened from the bite of an owl.

Bites from human beings and animals are usually complicated, involving other parts of the face, or at times, the eyeball.

In a girl who was bitten by a ferocious dog the eyelid was completely bitten through, together with the eyebrow, forming a large flap which hung over the face. The eye was likewise destroyed and had to be

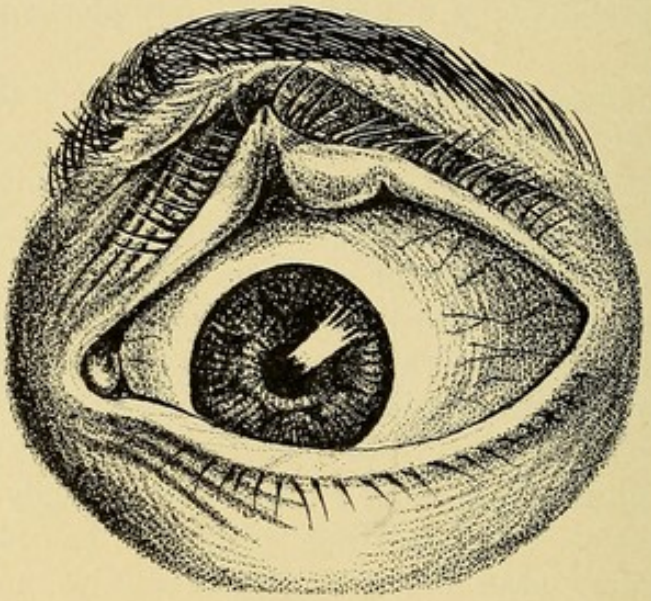

Fig. 328.
Ectropion and deformity of upper lid from dog bite.

immediately enucleated. Reposition of the lid and careful suturing resulted in a very good esthetic result.

A patient who has been under my care within a few days was standing in front of a bear den feeding the animals with peanuts, when one of the bears thrust his paw towards the man, clawing downwards, tearing the lower lid from the face, leaving it hanging by a pedicle. Reposition by some ten sutures, and antiseptic precautions used a few hours later, resulted in union by first intention, and no deformity, within five days.

A man came to me stating that his sweet-heart had bitten him in the eye. The upper lid was bitten through, plainly showing marks of the incisor teeth. Immediate suturing resulted in prompt healing with but little scar.

I have seen several cases of cow-horn injury in America and this

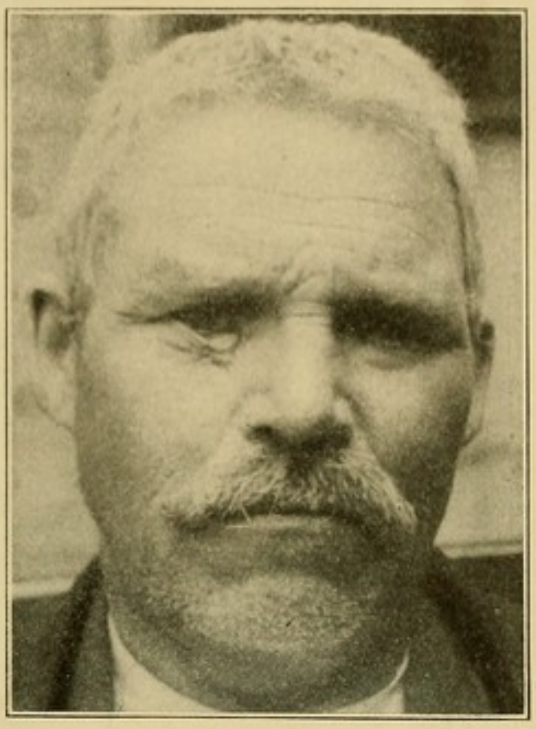

Fig. 329.
Cicatrical ectropion from cowhorn injury. Operation; cured.

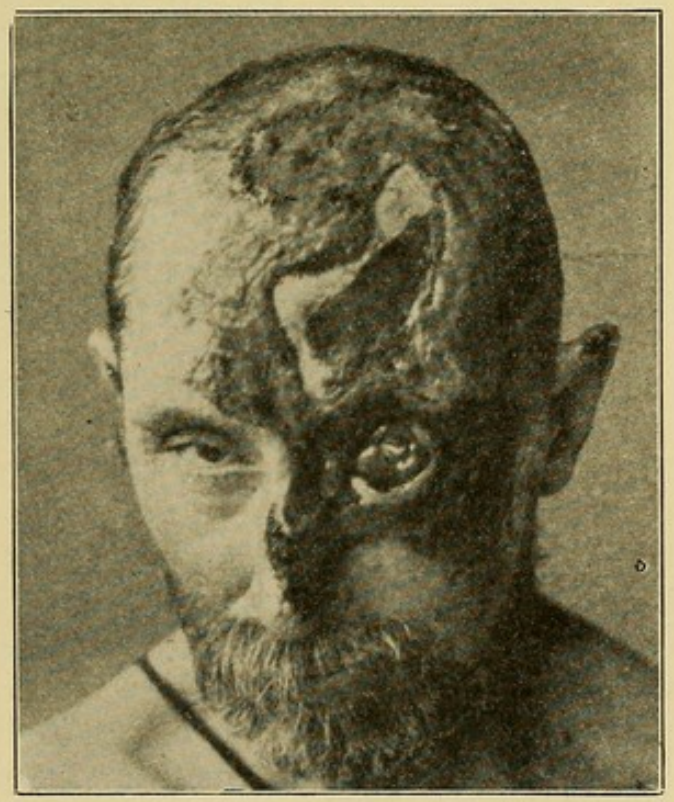

Fig. 330.
Severe burn of face, scalp, with loss of left eye (enucleated). Recovery after Thiersch skin grafting. (Author's case.)

has generally involved the upper lid. These accidents are probably more common amongst the peasantry of Europe than in America, where milch cows are usually dehorned. One such case is illustrated herein. A number of cases of fracture of the bones of the face and orbit have been seen by me, resulting from kicks of animals, in one of which the lower lid was badly torn.

Szili[5] reports a tear of the lid from a clothes hook which, under exact suturing, made good healing.

Symptoms and Course. Lacerations and contused wounds vary in appearance according to their character and that of the object producing the injury. The edges of the wounds are turned in or out, lacerated, bruised, ragged and usually impregnated with dust. Where there is entrance to the orbit wounds of the globe and contents occur,

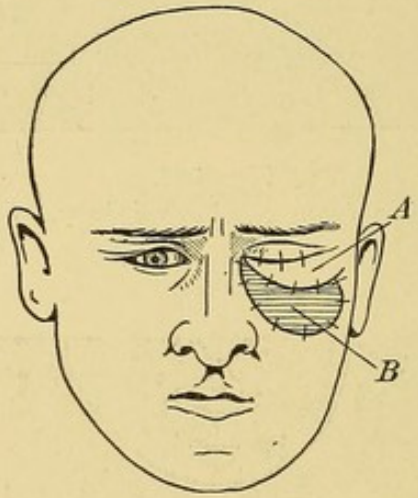

Fig. 331.

Operation for restoration of orbit and lids. Author's case. Large Wolff graft transplanted from arm (b), and sliding flaps from cheek (a) and Thiersch grafts to line orbit.

and in deeper, direct injuries fracture of the walls or base of the brain. Care should be taken to determine the presence of foreign bodies. The course depends upon the amount of tissue lost and the question of infection and complications. Where a portion of the tissues are removed by the injury or by ulceration the function of the lid is affected and cicatricial contraction causes ugly deformities.

Infection leads to erysipelas and gangrene of the lid.

Wicherkiewicz[6] could only find three observations of infection in literature. He observed the following cases in June, 1903: The right lower lid of a boy, age 15, was injured by the point of a stick. Three days later a contused wound of the skin, 2 cm. long, with purulent discharge, was seen at the lower orbital margin. Lower lid and cheek were swollen. The wound was carefully washed with a solution of boric

PLATE XXI

Total detachment of the retina.

acid, painted with 10 per cent. ichthyol salve, and covered with paper dressing. The next day trismus set in, and the patient was transferred to the department of infectious diseases, where a subcutaneous injection of 20 c.c. tetanus serum was made. The attacks of trismus, however, grew more violent and almost constant, in spite of injections of morphin

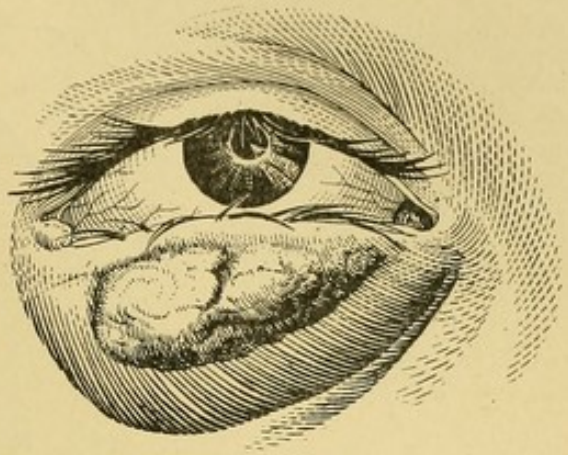

Fig. 332.
Primary chancre of lid.

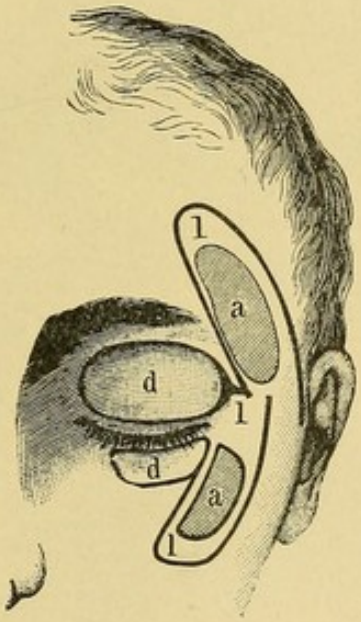

Fig. 333.
Fricke's lid plastic operation.

and chloral hydrate. Two further subcutaneous and intravenous injections did not save the patient from death.

A number of instances of infection by syphilis of a scratch wound have been observed, of which Alexander[7] reported several and I have seen two.

Marlow[8-9] reported a case of syphilis insontium in which a grand-

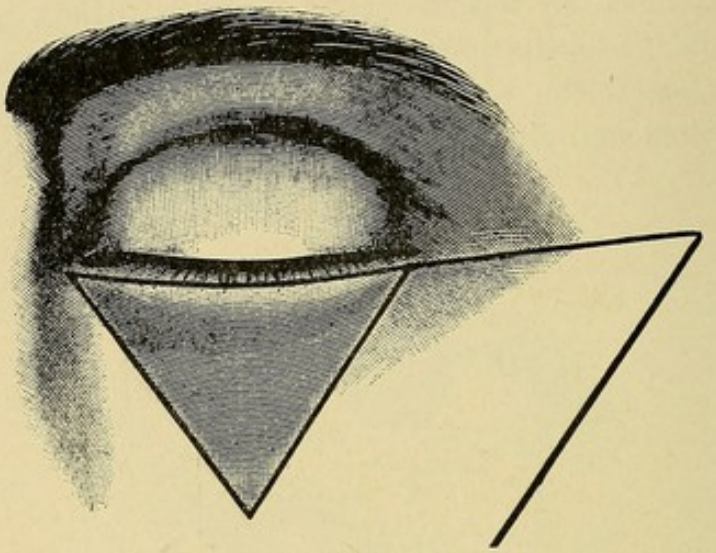

Fig. 334.
Dieffenbach's lid plastic operation.

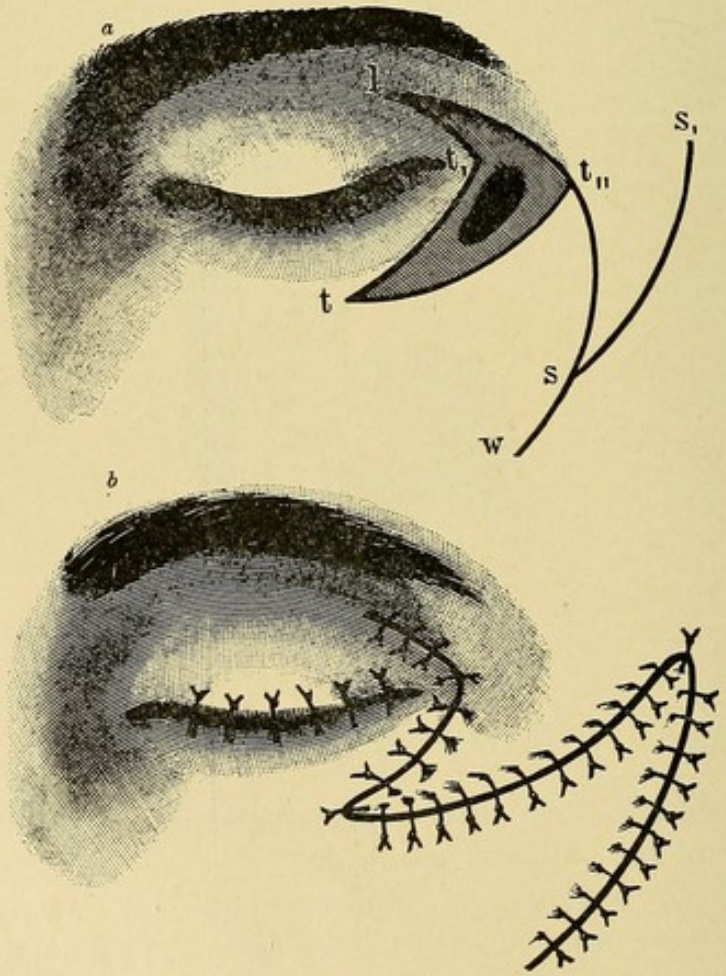

Fig. 335.
Richet's lid plastic operation.

mother became infected from the syphilitic child of her daughter scratching the lid, a chancre being thereby developed.

In 1891 Mr. J. B. Lawford of the Royal London Ophthalmic Hospital sent me a personal communication[9-10] relative to a chancre developing on the lower lid of a wet nurse.

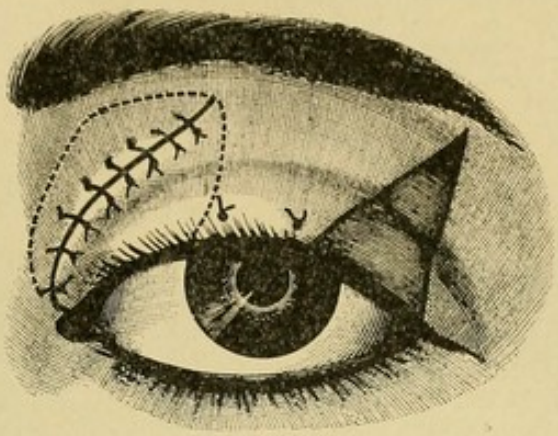

Fig. 336.
Landolt's procedure.

The Therapy of wounds of the eyelids is asepsis and coaptation of the wound. Ragged and bruised edges must be cut away and in old cases the cicatricial tissue removed and the wound edges freshened and coapted by sutures, with or without undermining the adjacent skin to make sliding flaps. Wounds over 5 mm. in length should be sutured

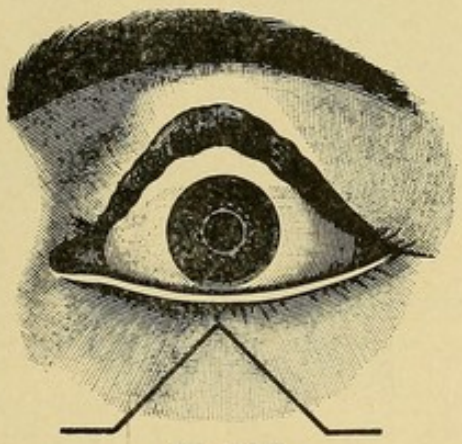

Fig. 337.
Wicherkiewicz procedure.

with fine silk and thin needles, always taking care to secure proper coaptation by entering the edges of the skin wounds by forceps after tying the stitches. As the swelling is usually great several tension stitches should be put in to insure the fine skin sutures remaining. When the lid has been completely torn through deep stitches of fine catgut may be laid in

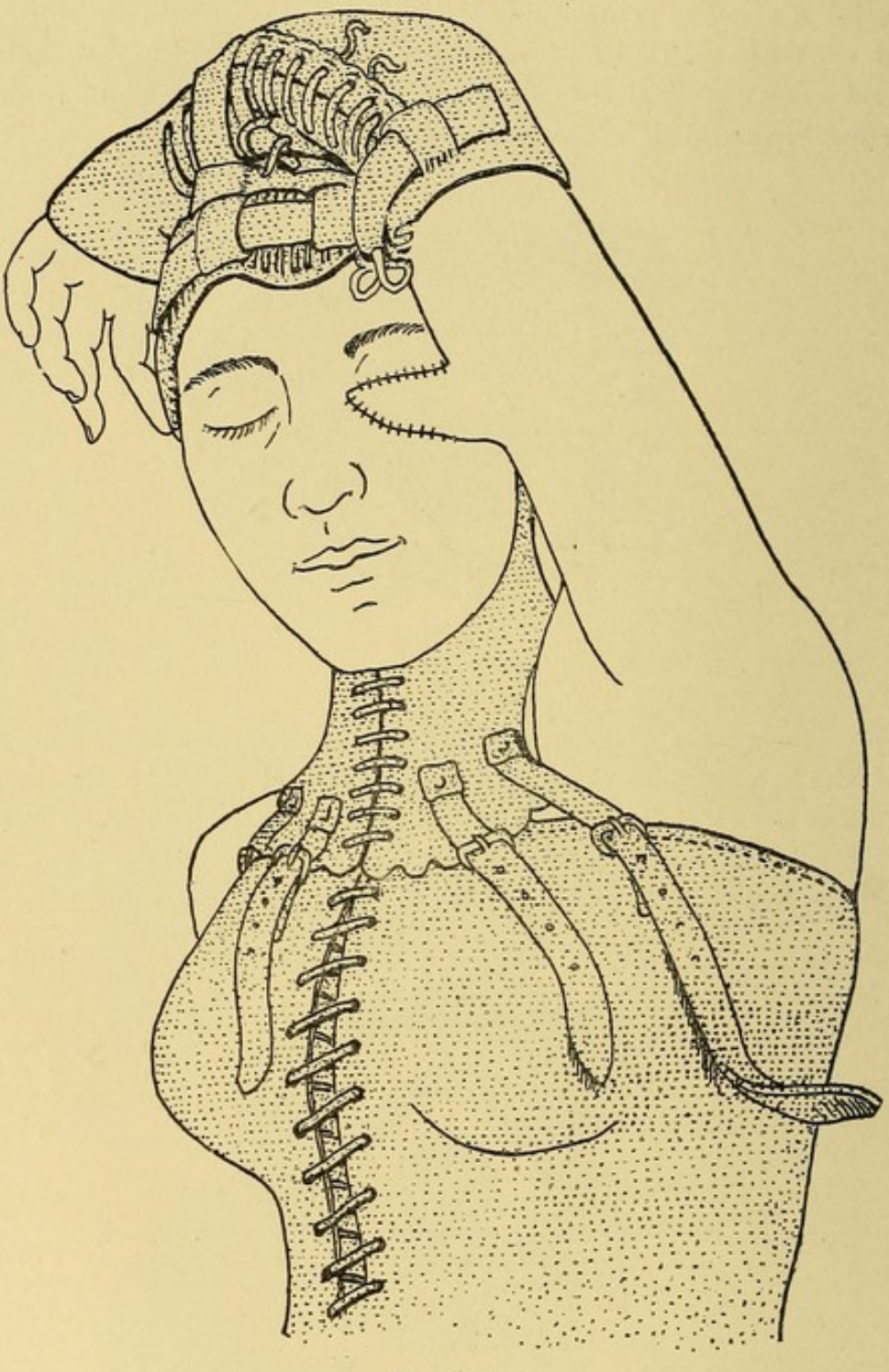

Fig. 338.
Autoplasty according to the Italian method. (Terrien. Paul Berger's procedure).

the depths of the wound and remain buried therein upon closure by superficial sutures.

When sloughing or trauma has caused loss of tissue, and when cicatricial contraction has ensued, various surgical procedures, for ptosis, entropion, ectropion, lagophthalmus, symplepharon and anklyoblepharon,

PLATE XXII

Healed detachment of retina. Striated retinitis.

as well as to replace large defects, must be used. These operations will not be described in detail here.

As regards lid plastics a great variety of operations have been proposed and used in former days but are not now in such vogue, their places being better supplied by the Thiersch and Wolff grafts. In order to cover

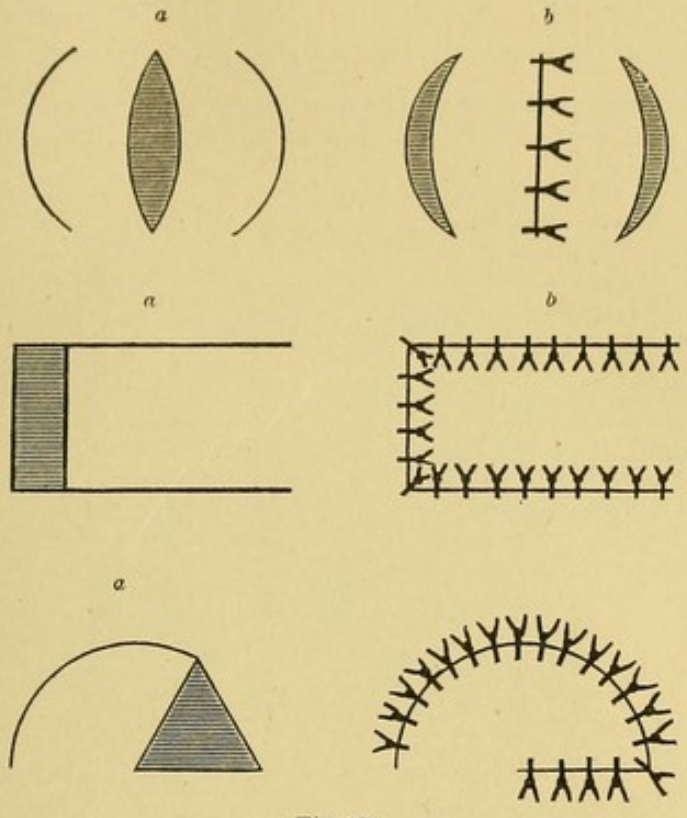

Fig. 134.



Figs. 339-342.

a. Sliding flaps with tension reducing incisions. b. Sliding flaps for quadrangular defect. c. Sliding flap for triangular defect. d. Sliding flaps according to Burrows' method. (Czermak.)

a defect of the skin caused by removal of tissue, either by accident or design, these flaps may be taken from the neighborhood, as the temple or cheek, according to the principles used in general surgery shown in accompanying figures. Modifications of these principles have been made

by many surgeons for lid plastics, such as those of Fricke,[11] Dieffenbach,[12] Richet,[13] Landolt,[14] Wicherkiewicz,[15] Knapp,[16] and others.

In addition to these comes the so-called Italian method where the flap is taken from the arm, it being bound to the head until union has taken place, when the base is cut away and the limb allowed to resume its position. Terrien.[17]

LITERATURE.

1. Nance, *Journ. Ophth. and Oto-Laryngol.*, Aug., 1907.
2. Samuel Higgins, *Ophth. Record*, July, 1909.
3. Praun, l. c., p. 493.
4. Rodenwald, *Inaug. Dissert.*, Kiel 1896.
5. Szili, *Arch. f. Aug.*, xiii, 1, p. 150.
6. Wicherkiewicz, *Postep. Okulist.*, No. 2, 1907.
7. Alexander, *Syphilis und Aug.*
8. Marlow (a) *Amer. Journ. Ophth.*, May, 1890. (b) ref. Würdemann.
9. Würdemann, Some Syphilitic Lesions of the Eye, *Trans. Wis. State Med. Soc.*, 1891.
10. Lawford, ref Würdemann (9).
11. Fricke, *Bildung neuer Augenlider Blepharoplastik*, etc., Hamburg, 1829.
12. Dieffenbach, *Casper's Wochenschrift*, 1835, p. 7.
13. Richet, *Traite prat.*, Paris, 1873.
14. Landolt, *Arch. d'ophtal*, 1881 p. 9, and 1885, p. 492.
15. Wicherkiewicz, *Klin. Mon. f. Aug.*, 1891, p. 20.
16. Knapp, *Arch. f. Aug.*, Bd. v. 1, p. 195.
17. Terrien, *Chirurg d'l'oeil*, p. 417.

B. FOREIGN BODIES.

Etiology. With the exception of powder and sand grains impacted into the lids from explosions, other foreign bodies are rarely seen, as the lids are thin and objects projected with much force usually pass through into the eye and orbit.

Glass splinters, chips of metal and sharp pieces of wood are occasionally seen in the skin of the lids.

Symptoms. Most foreign bodies cause a certain amount of inflammation and suppuration and are extruded thereby through the wound of entrance. Sterile stone, pellets of shot and powder grains, however, become impacted, and from the latter extensive tattooing and resultant deformity takes place, these cases being quite common in practice from careless handling of gunpowder and fireworks. In some instances the powder or other particles pass entirely through the lids into the globe, causing ulceration and granuloma of the conjunctiva, and various injuries to the eyeball, previously described in these pages.

Abscess of the lid is uncommon from retained foreign bodies but does occur at times.

The Diagnosis is not difficult, but it should be remembered that in explosions many foreign bodies may be impacted in all parts of the

face and eyes. The finger tip is useful for feeling the foreign body, and it may be brought to view by small incisions.

Heustis[1] gives a satisfactory method of removing powder stains in fresh cases. The patient must first be thoroughly anesthetized. Then with a stiff nail-brush, and using soap and water rendered antiseptic by carbolic acid, bichlorid solution, or any other antiseptic solution that may please the operator, scrub the part thoroughly. Do not hesitate to draw blood, and do not cease until the grains of powder have been entirely removed and face, hands, and other surfaces are clean. Should it become necessary to remove the entire cuticle do not hesitate to do so, as it

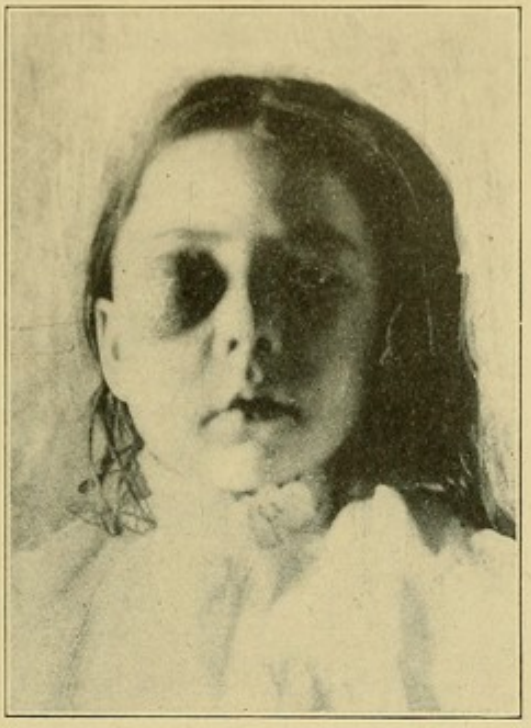

Fig. 343.
Abscess of eyelid.

will reform in a few days. It is sometimes impossible to eradicate a spot entirely, and then a smooth, elliptical incision is to be made, the stain removed, and a light suture inserted. Following the operation of scrubbing, it is only necessary to cut a covering the shape of the surface denuded, soak it in carbolized oil and apply. The next day the patient is liable to complain of a stiffness of the skin of the affected parts, which passes away in a short time. After the skin has resumed its normal condition it may be necessary, where blue spots remain, to remove by the elliptical incision previously mentioned.

In but few cases are large sized bodies found encapsulated. In one case reported by Lenoir[2] a mistaken diagnosis of new growth was made.

Kreuzberg[3] reports the case of a locksmith, aged 17, who complained of pain and slight swelling of his left upper lid, with the statement that, two days previously, while working, he was told by a fellow laborer that his left upper lid bled a little, but he had not paid any attention to it. After removal of a scab, 1 to 2 mm. wide, at the upper portion of the lid, a small opening suggested the entrance of a foreign body. Upon application of Hirschberg's magnet the tissue bulged forward. The wound was enlarged, and a piece of iron, 14 mm. long, 1 to 2 mm. thick,

Fig. 344.
Abscess and edema of eyelid. (H. M. Becker.)

weighing 200 mgr., was extracted with the magnet. Recovery within three days.

The Prognosis has to do more with the facial expression than the health or function. The proper removal of powder grains should leave little or no deformity. This has been fully described and several instances given.

LITERATURE.

1. Heustis, *Ophth. Record*, Oct., 1898.
2. Lenoir, *Arch. d'ophth.* 11, p.261.
3. Kreuzberg, *Centralbl. f. Aug.*, 1906, p. 172.

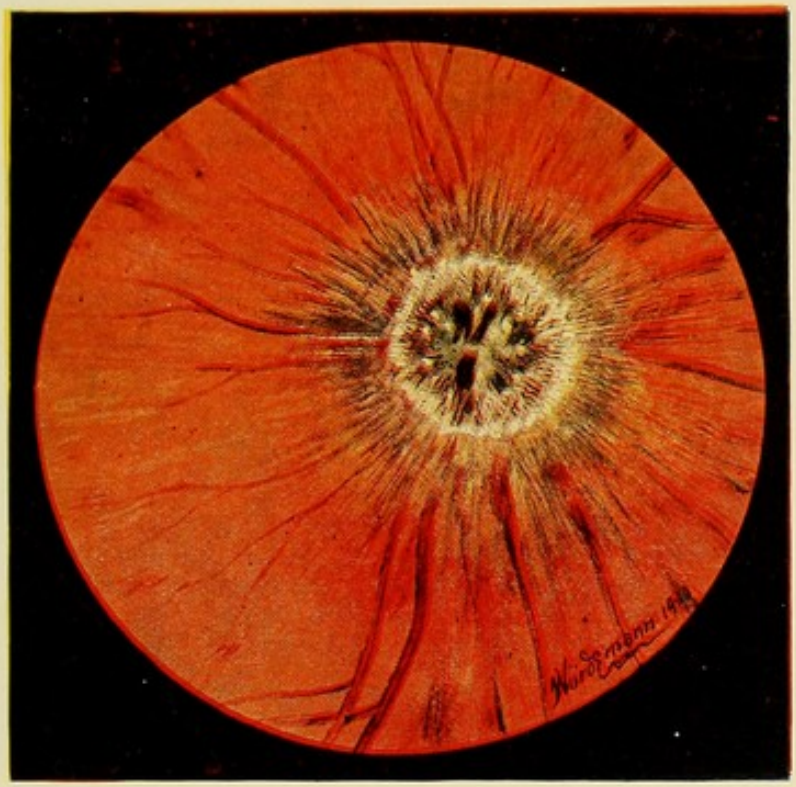

PLATE XXIII

Severe papillitis.

C. INJURIES FROM BLUNT OBJECTS.

a. Extravasation or suggulation of the eyelids.

Etiology. Where hemorrhage into the lids results from a blow upon the ocular region and no other complications ensue the case is one of ordinary "black eye" so common from fisticuffs and striking the face against a door in the dark, and such a patient generally ascribes the event to some such cause as the latter. But we should ever be on our guard in examining such cases to search thoroughly for a deeper and more important lesion, as the discoloration of the lids by extravasation of blood under the skin is in some cases but one of the symptons of a grave injury to the cranium, as previously described. The main causes



Fig. 345.
Edema of eyelids from fracture base of skull, anterior cerebral fossa.

of the "black eye" are falls, blows and contact with moving or fixed objects and flying foreign bodies of size.

Many operations, such as those through the conjunctiva and Tenon's capsule, as in the squint operation and enucleation, lead to extravasation under the conjunctiva and lids, not only of the operated but also of the fellow eye, the bloody suffusion passing through the subdermal cellular tissue of the nasal bridge.

Symptoms and Course. If bruising of the tissues of the lid has not occurred, then the blood, as where the extravasation comes from some injury to the conjunctiva or capsule, i. e., as from a strabismus operation, where there is little swelling but decided discoloration of the lids, especially the lower, is at first reddish, afterwards passing

through gradual shades of greenish brown to yellowish and usually completely disappearing in a couple of weeks, although in a few cases some permanent deposit of blood pigment occurs in isolated spots under the skin.

Where there has been bruising and rupture of the subdermal cellu-

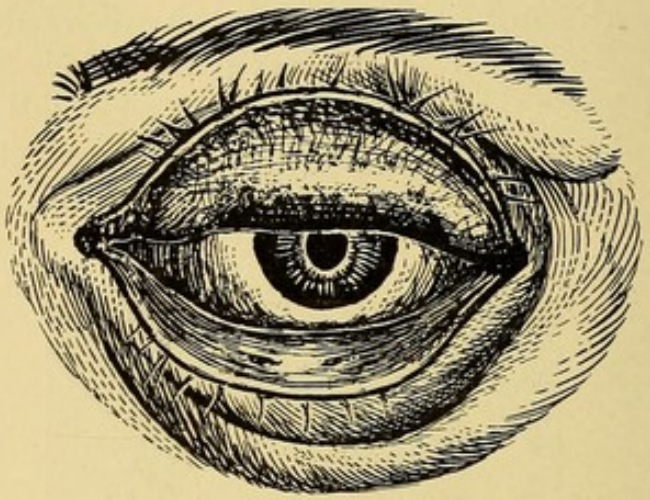

Fig. 346.
Great ectropion of both lids from cicatricial contraction following burn.

Fig. 347.
Gangrene of lids following freezing from iced applications in ophthalmia.

lar tissue and vessels the extravasation is more pronounced and may lead to suggulation with pronounced hematoma of the lids, which in a few cases may be so great that it causes much pain from the intense pressure.

Of particular importance in diagnosis are those suggulations coming

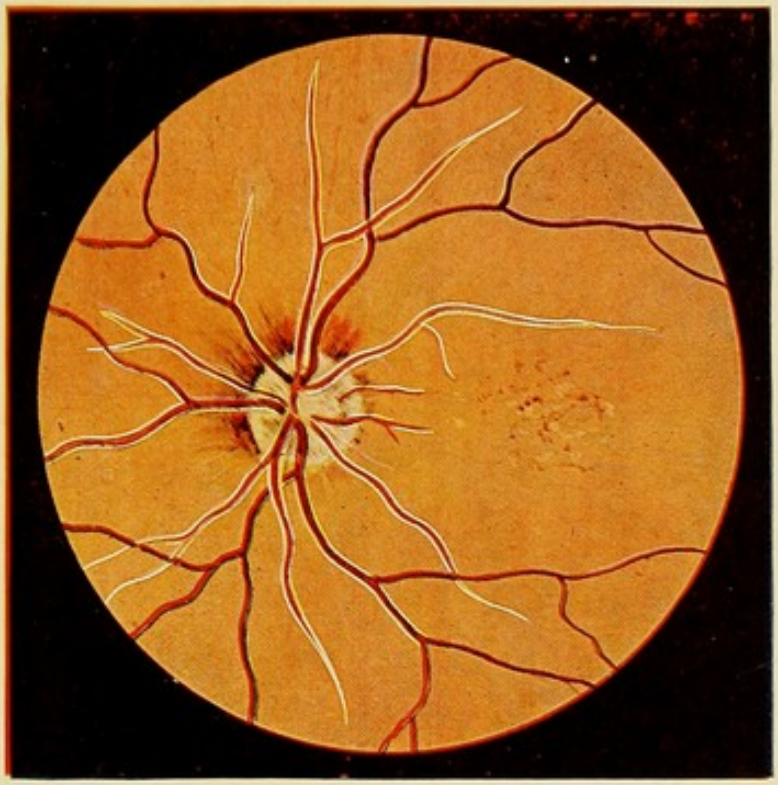

PLATE XXIV

Atrophy of the optic nerve and retina following optic neuritis.

from direct and radiating fractures of the bones of the face, orbit, and skull. The bleeding occurs immediately in the two former and in orbital injuries is accompanied by a speedy-forming and extensive hematoma. The bleeding from fracture of the base of the skull appears 12 to 24 hours after the accident, at first in the lower lid near the orbital margin and then extravasates slowly through the cellular tissue under the nose to the other eye.

This form of extravasation coming on after an injury to the head with or without unconsciousness is pathogonomonic of basal fracture and not favorable as regards vision, so the acuity and field should be carefully noted from time to time.

The Therapy of an ordinary black eye is at first iced compresses and after 24 hours hot compresses and finger-tip massage. In the case of prominent personages who have to go about their business bearing this stigma, grease, paint or water colors may disguise the discoloration and should be kept on hand by the oculist. In severe suggulation it may be necessary to let out the blood serum and reduce the swelling by incision through the skin.

b. Emphysema of the lids.

Etiology. Emphysema is a symptom of fracture of the floor or inner wall of the orbit and laceration of the mucous membrane, peri-

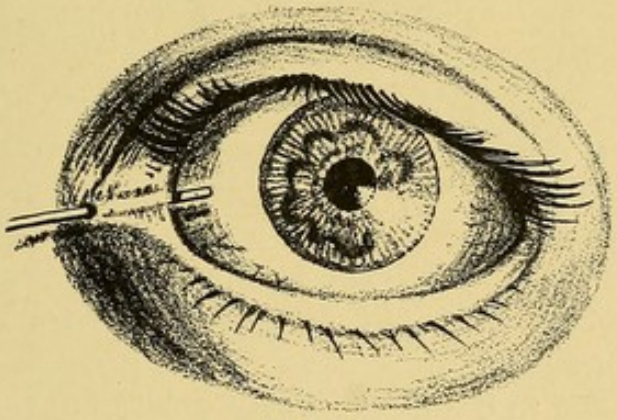

Fig. 348.
Atresia of inner canthus due to burn from carbolic acid.

osteum, and orbital tissues, with communication with the nasal accessory sinuses. Dentists sometimes cause emphysema of the face and lids after drilling a tooth through and blowing out the cavity by compressed air. Such a case has been recently seen by me. I have likewise seen emphysema of the face and lids following inflation of the middle ears after the use of an eustachian bougie and catheter.

The chief symptoms of emphysema of the orbit and lids are

proptosis, limited movement, diplopia, swelling, gaseous crepitation supervening after blowing the nose, violent sneezing, or forced expiration. Usually emphysema of the orbit and lids is confined to these structures by the strong anterior lamina of fascia between the lids and orbital margins. The usual causes are traumatism, disease or necrosis of the bones, surgical operations, or because of the presence of erosion of the buccal mucous membrane. A break in the continuity of the mucous membrane lining the accessory cavities and a fracture of the bony walls of the orbit, with a rupture of the periosteum, are common causes. Fuchs[1] explains the mechanism of many fractures by the giving way of the

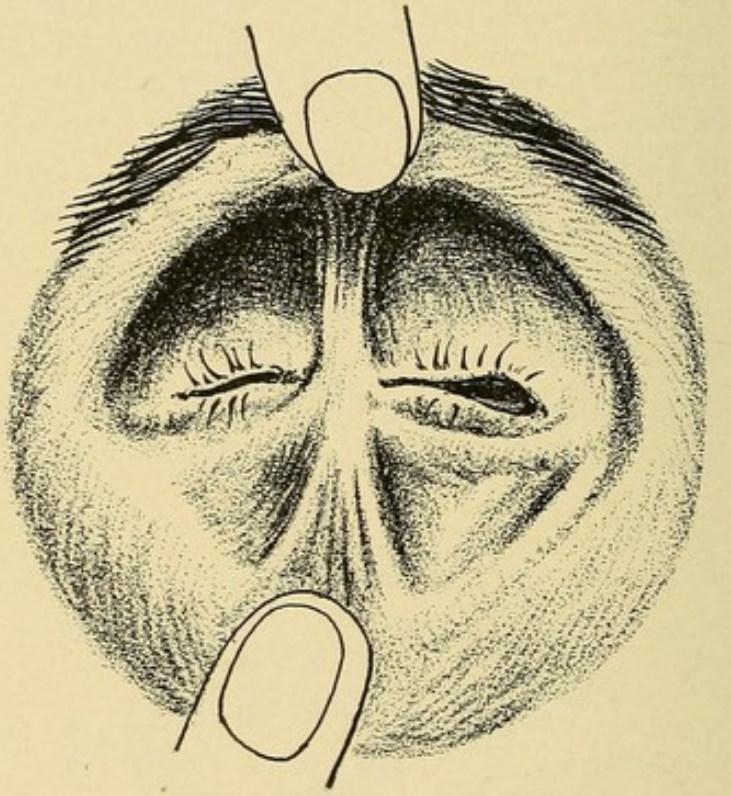

Fig. 349.
Cicatricial contraction of lids and orbit after burn by lime.

lamina papyracea due to the increase of pressure in the orbit by the ball being forced backward. This theory throws no light on those cases in which the injury involves the back of the skull. Extensive hemorrhage is not likely to occur because of the tortuosity of the larger vessels, and their protection by the soft tissues. Complete recovery in a few days, or, if the eye, being pushed back into the orbit, may be forced out by blowing the nose, militates against the diagnosis of orbital hemorrhage. Manipulation and pressure is the uniform treatment.

LITERATURE.

1. Fuchs, *Text Book*, Amer. Ed., p. 712.

c. Contusions.

Severe contusions, and prolonged pressure, as from hematoma and emphysema, are usually combined with wounds which are readily infected and in a few cases become gangrenous.

d. Burns and cauterizations, gangrene.

Etiology. Burns of the skin of the lids show the several degrees of burns, the symptoms of redness, vesicularization and gangrene. These injuries are part of burns of the face and eyes, the cornea and conjunctiva being involved, the lids swollen and very painful.

Continuous iced compressing in weak individuals has given rise to gangrene of the lids. I saw such a case in a scrofulous child who had been under continuous ice-bag applications ordered by a physician for a conjunctivitis. The upper lid sloughed severely, especially at the inner canthus, leaving cicatricial disfigurement on recovery.

A most severe case is here depicted of cicatricial contraction of orbit after burn from quicklime; another of great ectropion of both lids from burn in a boy who got burning jelly in his face while investigating the process over his mother's cook-stove; and another of atresia of inner canthus where a mistake had been made by the patient, in the dark, of putting pure (95 per cent.) carbolic acid in the eye instead of eye-drops; all of which were relieved by plastic surgical procedures.

Severe cases are more frequent than trivial ones; an example of the latter was in an Italian, seen recently, who one month ago had "fire" fly into his eye while working with hot iron. The left upper lid was burned at the ciliary margin resulting in slight entropion and trichiasis of four hairs, which by their rubbing had produced superficial corneal erosions. Epilation and antisepsis resulted in cure of the corneal ulceration in a few days.

The Prognosis depends upon the extent and character of the burn. The complications are not only those of the eye, but also from contraction of the lids, lagophthalmus, entropion, ectropion, trichiasis, narrowing of the lid aperature, cauterization and closure of the lacrimal puncta and canals are to be found.

The Therapy of burns of the lids is placed upon general surgical principles. Burns of the face of this character are usually of the first degree, i. e., superficial, involving only the epidermis; when its vitality has been destroyed and the true skin or corium cooked by the heat, the burn is then that of the second degree. Application of carron oil, which is a mixture of linseed oil and lime water; picric acid 3 per cent. or boric acid ointment 5 per cent. is the treatment. Very few cases should be left with their faces disfigured by the tattoo marks of powder explosions.

The eyes, themselves, are also to be treated on general surgical principles, the foreign bodies removed by the spud after the use of holocain, not cocain, as cocain diminishes the vitality of the parts; the application of antiseptic ointments; the use of boric acid washes; and, if ulceration ensues, hot applications, which are preferably given one-third hour every three hours; dionin, atropin and bandages are the proper procedure. Even if the eyeball has been penetrated, if it be only the cornea or the sclera, sight may be saved; but if detachment of the retina has occurred from the force of the explosion, or suppuration ensues, or if the ciliary region has been injured, blindness, or even loss of the eyeball, may follow. Enucleation and plastic procedures on the lids may have to be done.

LITERATURE.

1. Fuchs *Textbook*. Amer. (Duane) ed., p. 712.

E. INJURIES FROM FIREARMS.

Injuries from firearms occur from burns and impaction of powder grains, etc., into the lids from gunpowder and dynamite explosions, and the lids may bear the first brunt of the injury from projectiles. Isolated wounds of the lids from shot, bullets and flying objects impelled by their impact are not so common as the cases that penetrate and pass into the eye or orbit.

The reports of the Sanitation Department of the German War Office,[1] however, show many such isolated lid injuries, followed later by cicatricial deformities. Projectiles coming with minor degrees of force are stopped by the lids, others penetrate and are lodged therein, the most of these perforating and passing through into the eye and orbit. Thus there may be impacted shot pellets, portions of bullets, powder grains, particles of metal and stone.

Shot Injuries. If the projectiles come from the temple side the shot may glance and pass lengthwise through the lids. Those from the nasal side are well protected. Hence those from one side or downwards may form long wound canals in the lids; those from forwards or the nasal side, or above, usually have short canals. The shot may remain in the lids or pass through the cornea or sclera and rebound from that, or pass into the globe or orbit. The fine wounds made by bird shot close rapidly and are difficult to find.

Bullet Wounds. Rather long wounds in the lids may likewise be made from bullets or particles of shell coming through one side, most of them, however, pass in more directly, tearing the lids and the bulb and passing into the orbit.

LITERATURE.

1. Praun, l. c., p. 499.

F. TUMOR FORMATION IN THE LIDS AFTER INJURY.

Van Duyse and Cruyl[1] reported myxosarcoma after a blow upon the upper lid.

In the olden days Larger[2] and other authors reported benign growths, as dermoid cysts, protruding from the upper orbital rim and to which he gave a traumatic origin, but such in the light of modern research may be deemed to be congenital.

LITERATURE.

1. Van Duyse and Cruyl, *Ann. d'oculist*, xcviii, p. 112.
2. Larger, *Deut. Med. Zeit.*, 1817, p. 89.

CHAPTER XXVII.

INJURIES OF THE ORBIT, CONTENTS AND WALLS.

A. Wounds. 1. Superficial wounds of soft parts and rim—Etiology—Course—Diagnosis—Prognosis—Therapy. 2. Deep wounds—Etiology—Symptoms Course—Complications— Diagnosis—Prognosis—Therapy— Literature. B. Foreign bodies—Etiology—Symptoms—Course—Complications — Diagnosis—Prognosis—Therapy. C. Injuries from blunt objects. 1. Exophthalmus from orbital hemorrhage—Etiology—Symptoms—Course—Complications—Diagnosis—Prognosis—Therapy. 2. Contusions of the soft parts. 3. Contused and lacerated wounds of the soft parts of the orbital rim—Etiology—Symptoms and course—Complications—Inoculation by syphilis —Tetanus. Enophthalmus— Diagnosis— Prognosis —Therapy. Supra-orbital neuralgia—Supra-orbital amaurosis and amblyopia. 4. Contusion and isolated fracture of the orbital margins—Etiology—Therapy—Diagnosis—Prognosis. 5. Fracture of the orbital walls and the facial bones—Etiology—Symptoms— Complications— Diagnosis— Prognosis— Therapy. (a) Fracture of the roof—Etiology—Symptoms and course—Diagnosis—Prognosis —Therapy. (b) Fracture of the outer wall—Etiology—Diagnosis—Prognosis—Therapy. (c) Fracture of the inner wall—Etiology—Prognosis —Therapy. Orbital emphysema—Etiology—Symptoms and course—Therapy. (d) Fracture of the floor—Etiology—Therapy. (e) Fracture of the malar bone—Etiology—Diagnosis—Prognosis—Therapy. (f) Fracture of the superior maxilla—Literature. D. Injuries from fire arms. 1. Injuries to the orbital margins—Surgical treatment of fracture complicating foreign bodies — Simple — Complicated — Inner — Outer — Upper walls —Floor—Zygoma—Old healed fractures—Direct of rim and walls—Literature. 2. Injuries to the walls and contents. (a) Roof. (b) Floor. (c) Temporal wall. (d) Inner wall. (e) Injuries from behind. (f) Injuries of contents without injury of the walls. E. Tumor formation in the orbit after traumatism.

A. WOUNDS.

The orbital symptoms of injury to the skull are of special importance to the general surgeon, who is commonly the first consulted in such cases. Bergmann[1] showed the semeiotic importance of conjunctival, palpebral and orbital extravasations from the surgical standpoint.

Berlin[2] calculated that traumatic diseases of the orbit occur in 5 per cent. of all diseases thereof, which is true, but as they represent 0.19 per cent. of all ophthalmic diseases, the average ophthalmologist sees little of these rare injuries.

1. Superficial wounds of the soft parts and the rim of the orbit.

Etiology and Course. Incised wounds of the soft parts of the orbital rim and of the face are very common, and especially so are lacerated and contused wounds occasioned by blows from blunt objects or from falls. In wounds of the superior and temporal parts the lacrimal gland may be involved. Extensive injuries to the orbit cannot be sustained without affecting the eyeball, as will be shown in a number of instances following.

Stab wounds are commonly seen extending from the forehead to the upper rim of the orbit, their direction being in the axis of the blow, from above downwards and outwards or inwards, as a rule producing wounds of the superficial tissues but in some cases penetrating the bone to the brain. They may be perpendicular to the plane of the surface or tangental, in the latter causing flap formation, whereby a piece of bone may be cut and hang to the flap, especially in the case of incised wounds, as those from sabres. Blunter instruments cause fracture of the outer part of the bone which, too, may hang to the flap.

The Diagnosis depends upon the depth of the wound and whether or not it enters the cranium. Inspection, palpation by sterilized fingers, and probing differentiates these from the deeper forms.

The Prognosis as regards healing is usually good. If the wound be clean primary union may be effected; if infected healing ensues with more or less scar tissue formation, phlegmonous inflammation or erysipelas may follow. Frequently part of the wound heals kindly, but in other parts small localized abscesses develop. The supra-orbital artery bleeds freely but is readily compressed, so that upon suturing the wound the hemorrhage ceases. Anesthesia of the side of the face occurs when the supra-orbital nerve is divided. In contusions or lacerated wounds the nerve twigs may be encompassed in the scar and give rise to neuralgia and even functional amaurosis.

Praun[3] observed the case of a servant girl who had a wound from a sharp hook over the supra-orbital groove of the right eye. Six weeks later complete anesthesia of the skin supplied by the same nerve, while the area at the exit of the chief nerve was painful. Excision of the scar cured the pain.

The Therapy is antiseptic surgery. In large wounds a drain may be laid within, besides suturing, and the drain removed in 24 hours, when the wound usually heals by first intention. If a piece has been completely excised from the lids, Thiersch grafts may be applied. The wound should always be carefully probed to determine its extent and the possibility of a foreign body lying therein, and the X-ray diagnosis should be made where possible.

If the supra-orbital fascia be opened catgut drains may be put in, otherwise the wound should be fully sutured.

2. Deep wounds of the orbit.

Etiology. Incised wounds of the orbital margin may be continued into the depths of the orbit, but these, as well as stab wounds, are uncommon except in war or personal assault cases. Punctured wounds from accidental injuries occur more often, the most common objects inflicting them being knives, hooks, pen holders, lead and slate pencils, ends of umbrellas, walking sticks, pointed pieces of wood, thorns, hoofs, pipe stems, files, cow horns, glass splinters, iron nails, ends of cold and glowing wire, sabres, bayonets, foils, lances, etc., may all enter the orbit and cause more or less incised, lacerated or contused wounds.

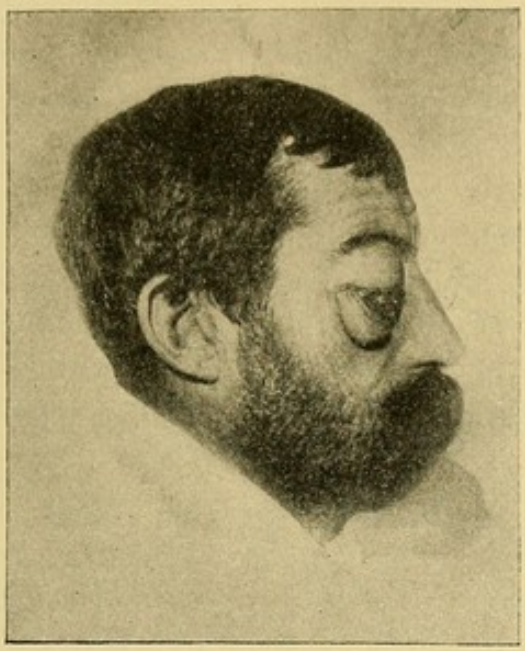

Fig. 350.
Abscess and cellulitis of orbit from blow by boot heel during fracas.

Symptoms. As a rule the object enters the orbit at the region of the inner canthus, from before, and passing into the depths of the orbit in many cases injures the optic nerve, as described previously. Fortunately for vision the eyeball is usually pushed to one side and the wound often lies entirely in the soft tissues between the globe and the orbital walls, and if the object does not injure the globe or nerve the injury may be altogether confined to a wound of the soft parts. Bleeding from a stab wound of this locality is slight, as the globe and the swelling of the tissues holds it in check from pressure.

The Course of simple, clean, uncomplicated wounds is primary and speedy union. The exophthalmus rapidly disappears. In infection

orbital phlegmon, erysipelas, meningitis and tetanus occur. If the periosteum be injured periostitis, caries and necrosis, emphysema of the orbit and lids, occurs.

The Complications are many and severe. Fractures of the orbital walls with opening of the cranial or sinus cavities, by which the vessels of the brain may be injured and subsequent intracranial hemorrhage occur, or the nerves may be cut, with resultant paralysis. Injury to the globe, especially common being rupture of the sclera; more seldom luxation and avulsion; injuries of the optic nerve; the extra-ocular muscles; the lacrimal gland; tear sac and canaliculi. In quite a number of cases prolapse of the tear gland has been observed. Atrophy of the globe follows severe injury to the eyeball, especially in rupture of the globe and injury to the optic nerve. Ptosis, symblepharon, sinking in of the caruncle and dislocation of the tear passages are among the lightest of the complications.

Retro-bulbar inflammation from stab with penholder and retention of piece 6 mm. long, 5 mm. wide, in orbit wound being at upper inner angle of orbit, causing exophthalmos and cellulitis with retro-bulbar venous congestion and formation of scars, is reported by Fejer.[4] V = 5/xv. The conditions were favorably influenced by fibrolysin.

Abscess and cellulitis of the orbit may arise from infected deep wounds.

I noted such a case in which these conditions developed after injury to the eye and orbit from a man being kicked by a hostler's boot during a fracas. Extensive local swelling and general symptoms of pyemia developed, with temperature of 105° F. The eye was enucleated and the orbit drained with subsequent recovery.

Diagnosis. The anamnesis and the examination showing a perforating lid wound, with swelling and bleeding into the tissues, especially if accompanied by a protrusion of the orbital fat, are pathognomonic. Geissler[5] says that the swelling and bleeding of the lid wound is less where a foreign body is retained than in an open wound, as the passage is tamponed thereby. The change in position and loss of the motility of the globe speaks for injury either to the muscles or the nerve, and is characteristic of a deeply-penetrating wound. This may be passive from swelling, hemorrhage, inflammation, or retention of a foreign body. If the eye be blinded and no direct injury of the globe appear the opticus must have been injured, thus showing that the foreign body has penetrated deeply. The sterilized finger and the probe should be carefully used, likewise the X-ray; the former to determine the extent of the wound and to detect the presence of a retained foreign body, and the latter to localize it. In using the finger and the probe the globe should

be pushed in various directions or pulled about by forceps in order that the examination may be thorough.

Prognosis. In favorable cases healing takes place in two to three weeks if complications, especially infective and inflammatory processes, have not occurred.

The Therapy is antisepsis and coaptation of the parts.

Arnold Knapp[6] reports a case of blindness from penetrating wound of orbit with cellulitis. The patient was injured in the right orbit by a lead pencil, which entered in the outer half of the lower lid. Orbital abscess followed, and was opened and pus evacuated. Two weeks later there was exophthalmos; lids hard and swollen, chemosis; disc white and arteries small; V = o.

The author believes that the ophthalmoscopic picture seems to prove an involvement of the arteries, which could be explained by an inflammation of the central retinal artery, which shut off the blood supply and subsequently led to a proliferation of the empty arteries.

LITERATURE.

1. v. Bergmann, ref. Berlin.
2. Berlin, *Graefe-Saemisch,* vi.
3. Praun, l. c., p. 447.
4. Fejer. *Centralbl. f. Prak., Aug.,* Aug., 1910.
5. Geissler, ref. Praun, l. c., p. 448.
6. Arnold Knapp, *Arch. Ophth.,* Nov., 1906.

B. FOREIGN BODIES.

Etiology. The ends of objects entering the orbit may be broken off and retained, as described under etiology in the foregoing chapter on Deep Wounds of the Orbit. These injuries more often occur from accidents than from malicious assaults. In the trades, flying chips of metal or stone may go with sufficient force to penetrate the lids and pass into the orbit, or to pass completely through the eye into the depths of the eye socket. I have noted several such.[1]

Berlin,[2] a score of years ago, stated that 6 per cent. of all ocular injuries occur in trades, but the proportion is now much higher, owing to the increase in the iron and steel industries; 45 per cent. now being due to outside accidents and 49 per cent. through injury by another person.

Perhaps dynamite and powder explosions give rise to the larger part of such cases, carrying chips of stone into the orbit; next come shot pellets and pistol balls.

Symptoms. Foreign bodies may pass through the conjunctiva into the depths of the orbit, commonly injuring the caruncle, or through the lids. Seventy-five per cent. pass by way of the inner canthus and glide

easily along the nasal side of the orbital walls to the depths of the orbit, on account of most flying objects coming from downwards and outwards. Seldom does a foreign body remain superficial, and they seldom enter from the outer side.

The mode of entrance of foreign bodies into the orbit is usually through the anterior aspect, because of the protection afforded by the bones to the side walls. The inner angle is more often injured than the outer; more rarely the space between the globe and the roof, and very rarely the space between the ball and the floor, as the two latter are very narrow. Occasionally it reaches the orbit through the globe.

The patient is frequently unconscious at first from the force of the injury causing concussion of the brain, or great shock without producing an actual lesion of the brain. Afterwards he complains of pain, pressure, and headaches, generally of double vision if the muscles or the nerves be injured, and if the opticus be hurt there will be immediate loss of vision. The lid or conjunctival wound will be seen and the eye is usually to one side and more or less prominent from the orbital hemorrhage and effusion. Foreign bodies that lodge in the orbit usually cause no ocular symptoms, providing, however, the eyeball itself be not injured.

Sweet[3] notes a case where a bird shot was lodged back of the eyeball. Two months later the eyeball was the seat of almost continuous pain, and upon enucleation a thick cord was found to have passed through the posterior surface of the sclera back of the orbit. The shrinkage of the band of tissue and the pull exerted upon the orbital nerves with each rotation of the globe evidently kept up irritation and pain.

The loss of vision may be due directly to the injury by the foreign body when it damages the globe or nerve, or to compression of the bulb by the object itself. In other cases it is due to extravasation of blood into the tissues or to subsequent inflammatory reaction.

The optic nerve is edematous; the circulation obstructed; the veins tortuous and the arteries constricted, even to carrying no blood, and even when the nerve itself is not injured; and then, in many cases, after removal of the foreign body from the orbit the sight returns as the pressure upon the globe and the nerve is released.

If the foreign body be very large or enters with great force it is liable to bore through the orbital walls, producing fracture and passing through the bone to the brain or nasal cavity; in one instance of mine a splinter of wood passed even into the naso-pharynx. If into the brain, cerebral symptoms shortly occur. There have been cases in which even after such a severe injury the foreign body has been encapsulated and remained for months without causing severe inflammation.

Sharp-pointed objects of small caliber may pass through the optic

canal or superior orbital fissure into the brain without breaking the walls, injuring thereby the optic and other nerves as well as the brain tissue. Even so can slender objects pass through the inferior orbital fissure to the temporal region, lacerating the inferior maxillary vessels or causing swelling and abscess of the aural region.

Course. Aseptic foreign bodies may enter the orbit, cause but little reaction, becoming encapsulated and remain for years; especially, to be noted is the occurrence in this location of shot pellets and pistol balls. Septic bodies cause intense reaction and may be found in the sinus leading to the abscess of the orbit caused thereby. This is particularly the case in injuries by twigs or splinters of wood, portions of which may come out from time to time in the discharge from the wound.

Praun[4] reports a case in which a knife blade passed into the orbit and caused a chronic abscess of the brain without marked symptoms; and also a case where the end of a file remained 30 years in the orbit, when heavy sneezing caused it to pass into the nasal cavity and be expelled from the mouth.

As a rule a suppurative process ensues, causing orbital phlegmon, from which the foreign body may be spontaneously extruded by way of the suppurating sinus. A fistula develops which may remain for years, and from which a sanguineous purulent discharge comes out. Inflammation of the periosteum and of the optic nerve is seen in the form of periostitis, caries, necrosis and optic neuritis.

Complications are such as belong to surgical wounds with retention of a foreign body. Of special note is the occurrence of tetanus, with which I have never had any experience, this form of infection being extremely rare in the localities wherein I have practised. However, quite a few cases have been noted in the literature.

Hulke[5] reports a drunken woman who was struck in the eye by a washing board, followed by a high grade of exophthalmus, swelling of the soft parts and lids, freshly cicatrized wound of the upper lid and ulcer of the cornea. The right temple and masseter were swollen and the lower jaw firmly closed. After 8 days, stiffness of the neck and body, spasms, opisthotonos and death occurred. Necropsy showed several pieces of wood in the orbit.

Fromaget[6] collected the cases of tetanus from eye injuries up to 1886, showing that paralysis of the facialis and trigeminus occurred similar to the paralysis following diphtheria.

Tetanus of the head is not invariably fatal, as Güterbeck and Bernhardt[7] found four recoveries.

The Therapy of cephalic tetanus is the injection of antitetanic serum, by means of which light cases may be led to recovery.

The Diagnosis is plain if the foreign body be seen in the

wound, which may be enlarged for the purpose of examination, touched by a probe or seen in a Roentgen ray plate, which procedures should always be made when the first methods do not give the diagnosis.

The extent of the exophthalmus does not give any idea of the size of the intruder, for the protrusion is due to hemorrhage or effusion rather than to the foreign body. Long and thin objects, as knife ends and slate pencils, pipe stems, umbrella ends, etc., may be difficult to find in the orbit if applied closely to the walls.

The diagnosis may be difficult if the object be aseptic, as a foreign body of considerable size may gain entrance to the orbit, causing loss of vision and motion, leaving but little evidence of the wound of entrance.

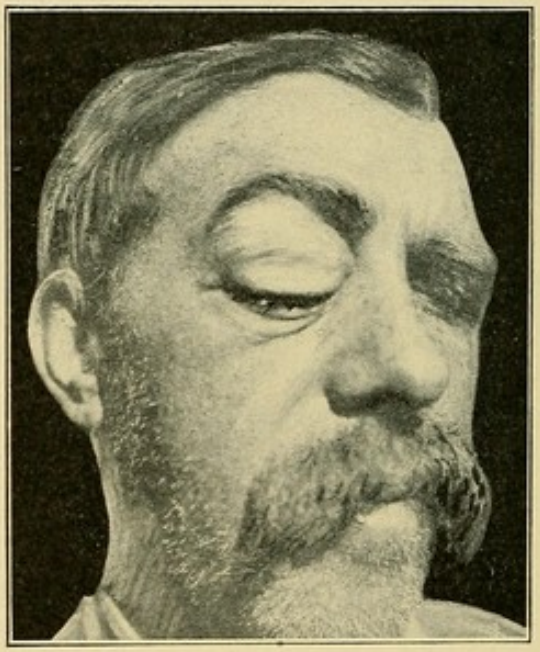

Fig. 351.

Edw. Jackson's case of dislocation of lacrimal gland, and foreign bodies in orbit. Condition on examination.

In a few cases the patient has not been aware of the intruder, there having been but little discomfort after the first effect of the blow.

I have particularly noted several cases in quarry men, woodsmen and farmers who came some time after the accident, with blind but not particularly inflamed eyes, after injury from fiying pieces of stone, twigs and splinters of wood, and there may be many pieces, as in Edw. Jackson's[8] case, where nine pieces of sage brush wood were taken from the orbit.

Cases are on record of large foreign bodies being lodged in the orbit for some time without the patient's being aware of it.

If a foreign body be aseptic and causes no inconvenience for some

weeks, there is no reason why it should not remain for an indefinite period.

One of the first reported was the famous hat-peg injury of Brundenel Carter[11] which had remained in the orbit 10 to 20 days without the patient being aware of it. That of Noyes[12] in which a breech-pin had not only gone into the orbit and cranial cavity but had healed

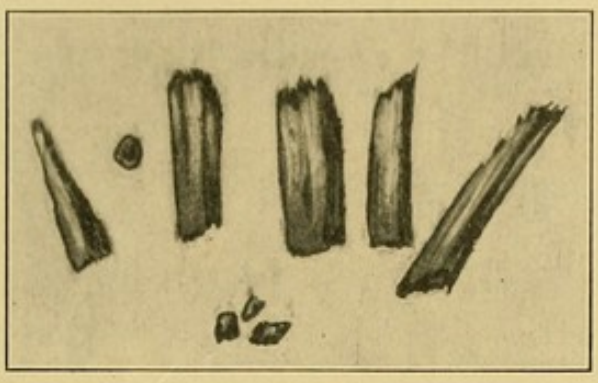

Fig. 352.
The nine pieces of sage brush wood removed from the orbit. Exact size.

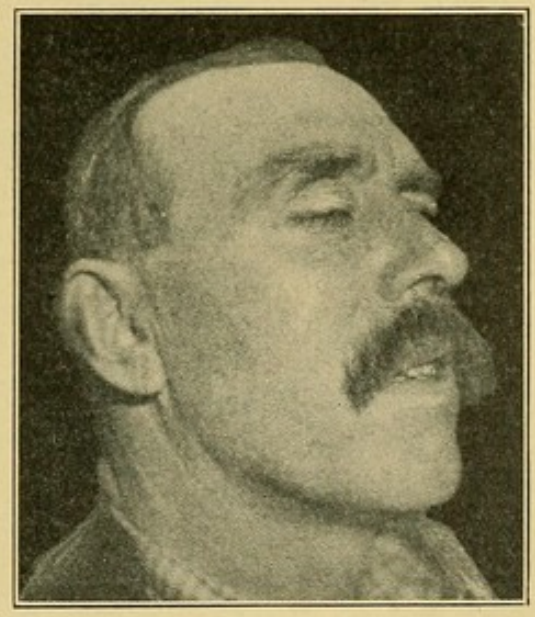

Fig. 353.
Condition on recovery.

therein and was not removed for five months, is most interesting; also that of Wright[13] in which not only the breech-block, but a long screw, remained for seven years before removal.

Keiper[9] reports the case of a negro who had the tine of a steel fork pushed through the upper eyelid, the ball and antrum of Highmore, remaining therein for fourteen years, when it was removed.

Packley[10] reports the following interesting case: In May, 1902, while at play, a small boy was knocked against a rail fence and fell with another boy on top of him. Immediately afterwards he pulled a splinter

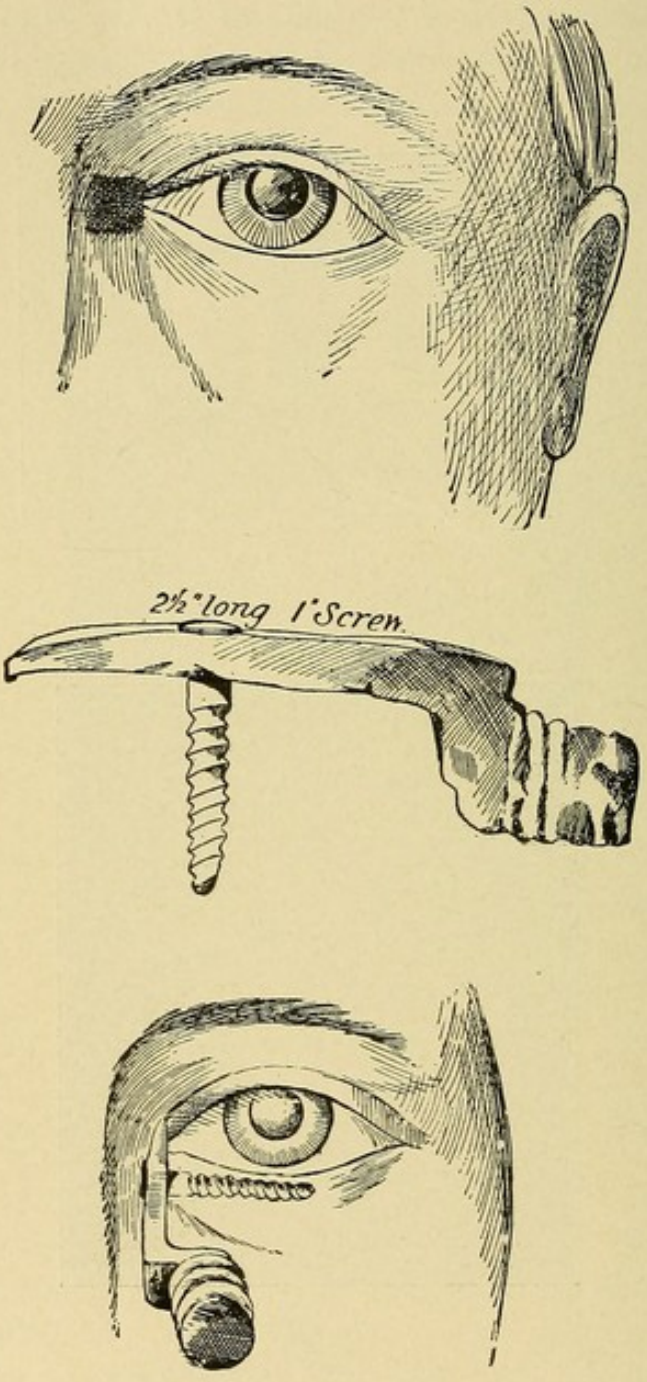

Figs. 354-356.
Sketch from patient before operation. (Wright.)
Breech block after removal (reduced to one-third).
Sketch showing way breech block entered.

of hard-wood "out of his right eye." Only trifling bleeding. For two days afterward had headache and occasional retching. On recovery from the momentary concussion he discovered he had no perception of light

in the right eye, and that the ball was protruded somewhat. When first seen, eight days after the accident, the right eye was proptosed, a small cicatrix on cheek below and slightly to nasal side of the eye. Tenderness on pressure, in orbit below the eye. Ophthalmoscope showed great swelling and tortuosity of the veins near the disc.

A conjunctival incision was made midway between the inferior oblique and inferior rectus, and in exploring through this incision, a hardwood splinter, ¾ inch long and 3/16 inch thick, was drawn out with forceps. Careful probing revealed no other foreign body. There was little pus around the foreign body, but the wound was cleaned and left open with gauze drain for a few days.

A week later the eye had gone back nearly to normal position. No pain or tenderness on pressing back into the orbit. Optic neuritis much more marked. No light perception. Disc eventually passed into a con-



Fig. 357.
Breech pin removed from orbit (Gifford).

dition of white atrophy, and when last seen a few weeks after accident, his eye was quite normal in position and movement, and no pain or tenderness.

Four years later patient's mother brought in specimen No. 2, a piece of wood 1¼ inches long and ⅛ inch thick, which the boy had found "sticking out of the corner of his eye" on waking, a few days before. There had been no pain or swelling previously, and nothing had been noticed when he went to bed the night before. The dentations on the end of the second piece exactly fitted those on the end of the first piece. In this case the foreign body was septic, and caused suppuration, yet after removal of the first piece the remaining portion lay quiet for years.

Edw. Jackson[8] reports a patient, male, age 44, who was thrown from a wagon, receiving a wound in the upper lid parallel to the orbital margin; the wound had been closed with sutures and healed by first intention, but the swelling continued. The eyeball was displaced forward,

downward, and inward and slightly movable in all directions; in the outer two-thirds of the upper lid was an almond shaped mass, the dislocated lacrimal gland. Twenty-four hours later suppuration occurred in the region of the gland, an incision was made, the gland removed and the cavity drained. Two weeks later the wound continued to discharge and a foreign body was felt at the bottom of the sinus; this was removed and proved to be a splinter of wood; later several more pieces of wood were removed and the wound healed, nine pieces being removed in all.

Result: Vision in right eye 4/iv, no deficiency of lacrimal secretion, cornea 6 mm. in advance of fellow eye, movements of upper lid imperfect, movements of eyeball normal in all directions, except upward, where it is limited to 30 degrees.

J u n i u s[14] reported a case in which a man, aged 27, received a stab in the left eye six years before. The wound healed, but often broke open and discharged pus. The eye gradually became protruded and was frequently inflamed. The ophthalmoscope showed a few old pigment foci in the lower temporal quadrant of the chorioid. For the last six weeks the inflammation was especially obstinate. The outer two-thirds of the lower lid was everted and bound down by a fistulous scar at the lower orbital margin, from which pus could be pressed out. After laying this bare, a piece of a knife, 6.1 cm. by 1.4 cm., the upper two-thirds of which projected into the orbit, was found firmly impacted in the orbital wall, from which it was extracted after chiselling a wedge out of the bone. The wound healed permanently with normal vision. An examination with Roentgen rays would of course, have cleared the condition at once.

The A n a m n e s i s is apt to be misleading, as many of these cases are rendered unconscious and some of them are drunk at the time of the accident.

Examination, if possible, of the object producing the injury will give some hint of its nature and perhaps of its size, if due to breaking off of the tip, as in the case of umbrellas, sticks, etc. The breech-block injuries from bursting firearms are of much interest in this connection. In many of them the retention of such a large foreign body was at first unsuspected.

G i f f o r d[15] has an extensive article reporting a series of breech-pin cases from the literature, and one of his own in which the breech-pin remained in the orbit and was not found by the attending surgeon two years before, despite the fact that enucleation of the injured eye was done at the time of the accident. The breech-pin was readily seen at the bottom of the socket and was clearly shown by the X-ray.

Gifford remarks that in a case of injury to the eye or face through gun explosions one should think of the possibility of missiles having been

blown in out of sight, not only the breech-pin, but also the stock-bolt or screw stock. That, whether or not the presence of a foreign body can be detected by probing, it is well worth while to have one or more skiagraphs taken.

In a number of cases of shot gun injuries whereby the globe had to be enucleated I have found one or more shot in the orbit, in one instance of

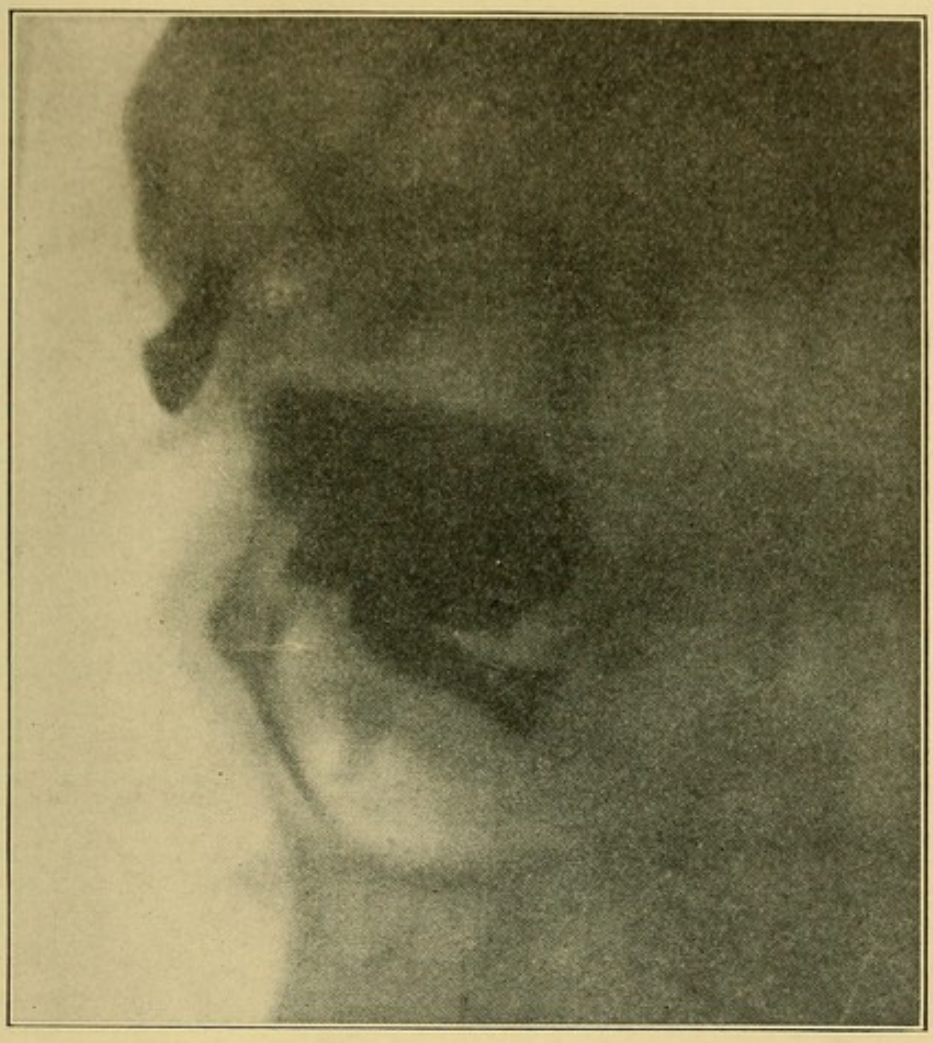

Fig. 358.
Skiagram of breech-pin in orbit. (Gifford.)

a Flaubert 22 calibre rifle injury, finding the bullet impacted in the optic canal at the very apex of the orbit.

In Morrow's[16] case the bent stock-bolt was picked out of the orbit by a member of the family. This weighed 32.2 grams, was 43 mm. long, 26 mm. wide, and 14 mm. thick. Reposition of the parts was made and globe enucleated. Although orbital cellulitis ensued a prothesis was made later, giving good results.

Ledbetter[17] reports case of a breech-pin of a gun stock destroying the eye and remaining in the orbit for three years.

Baker[18] reports case in which a part of the extractor spring of a Winchester rifle was driven through the eyeball into the orbit from the explosion of the rifle. The eye became shrunken and was enucleated a month after the injury because of the evidences of sympathetic trouble in the fellow eye. The presence of a foreign body in the orbit was not suspected and came as a surprise during the enucleation. It was found to have penetrated the roof of the orbit and was firmly fixed, great force being required to extract it. It was one and a quarter inches long and one-eighth inch square.

Then, too, the possibility of a small foreign body having passed entirely through the eyeball into the orbit should be carefully considered in penetrating wounds of the eyeball from shot pellets, and particularly in trade injuries. Several such have been noted in previous pages.

I well remember the case of a double perforation in which a chip of iron passed through the globe, making its exit just over the macula into the orbit; and several in which shot pellets passed cleanly through the eyeball.

Allport[19] reports a case of a piece of hammer passing through the eye, entering the sclera over the external rectus, emerging about 5 disc diameters in superior temporal quadrant, passing into the fatty tissue of the orbit and remaining without causing trouble. Resultant vision with +1.25=20/xxx. V. F. contracted.

Sweet[3] reports 13 cases in which metal chips passed completely through the eyeball into the orbit, the globe being lost in five instances, two because of panophthalmitis, one through irido-cyclitis, one through collapse of the ball following an attempt to extract the metal and one in which extraction failed.

Prognosis. The prognosis can only be good when the foreign body has not caused great direct damage on entering; may be easily removed without too great disturbance of the structures; and when the resultant wound will not be followed by inflammatory and cicatricial changes.

As noted, some exceptional cases have been reported where a foreign body has remained for years without giving rise to severe symptoms and has been removed or was spontaneously extruded. To account for such instances it must be supposed that the orbital tissue is particularly immune to infection, or else the foreign bodies that have gained entrance into the orbit have been aseptic.

The future usually depends upon the extent of the injury and its resultant complications. If the optic nerve be not directly injured the vision may become better, even normal, upon removal of the foreign body. Even here we must be careful in our prognostications, for secondary inflammation may occur in the orbit, resulting in atrophy of the

nerve or even of the globe. If both nerves be injured the patient usually dies from concomitant brain injury, but, as in the following, some live to pass their days in blindness. Johannes Berlin[20] reports attempted suicide with a pocket revolver. Injury behind right eye; protrusion of eye; sealing of lids; blood in the vitreous. Tension +. Blindness. Enophthalmus; anterior chamber full of blood; rupture of sclera; blindness. Small bullet discovered in the left orbit by the Roentgen ray. Removed under the lower lid with cocain. Blindness both sides. Phthisis bulbi.

Therapy. Small metallic objects, as shot pellets, bullets, chips of iron, copper, stone, etc., may be left alone to become encapsulated. However, bullets have been successfully removed from the orbit with conservation of the globe, as reported by Posey[21]. The length of time that objects of other characters remain in the orbit not only brings the danger of orbital phlegmon, but also of inflammation of the optic nerve and resultant blindness; so that operation for their removal should be instituted before severe inflammation with great swelling renders it more difficult and dangerous. In fresh cases, after localization by the X-ray, the opening should be carefully probed and enlarged in the direction of entrance; in older cases the sinus followed up or the cicatrix cut open, the foreign body seized by forceps, cut away from the tough connective tissue by scissors, carefully dissected out and withdrawn in the direction of least resistance, or where the procedure will do the least damage.

Johannes Berlin[20] reported injury received in the left temple from a Flaubert rifle ball, at the hands of a comrade, by a boy while playing Indian. No pain, but swelling and ecchymosis; ectropion under lid. Blindness. Treatment with hydrarg. oxycyan., 1 to 1,000. Sajodin internally. The next day right eye irritable. Roentgen ray showed bullet in the inner orbital wall; left eye. Double perforation of the bulb. Atropin and dionin used. Ball not removed. Two months after right eye normal. Left eye atrophic.

In another case of bird shot injury there were many wounds; nose, right eye. Lid and conjunctiva chemosed. At the limbus a small perforation. Vision = light perception. Therapy, atropin, aspirin. Roentgen ray showed 11 shot in the region of the eye. Not removed. Vision = fingers one meter. Eccentric outwards.

In a case of shot in forehead by a revolver at about 2½ meters away there was no sight either eye. Nose-bleeding. Wound over eye, but both lids swollen. The ball small. Exenteration of the eyeball. Pus found later. Ball discovered by Roentgen ray in the under part of the sella turcica in the sphenoidal bone in the medial line. Result, healing of wound, total blindness.

In cases where there is absence of definite evidence indicating the presence of a foreign body, Jackson[8] makes the following rule: "Bear in mind the possibility of the embedding of a foreign body in connection with every open wound of this region; but in the absence of definite evidence of its presence and location do not endanger important structures in the search for it."

W. Zimmermann[22] had a lad, aged 16, who had been shot in the left orbit; presented intense exophthalmus, swelling of the upper lid, which could spontaneously be scarcely raised; motility of the globe upwards very limited, outwards totally abolished. The pupil reacted sluggishly, was larger than normal, V=5/xxxv. T. and V. F. normal; no changes of fundus except small hemorrhages of the retina outwards and downwards. The wound of entrance of the 9 mm. projectile was situated at the border of outer and middle thirds of the lower orbital margin. Of general symptoms, vomiting and bradycardia were observed and pulse of 48. The Roentgen photograph revealed the projectile in the posterior portion of the orbit inwards of the posterior portion of the optic nerve, while the clinical symptoms pointed to its seat outwards of the optic nerve.

After four days, Kroenlein's operation was performed, but not until a longitudinal incision of the external rectus was made was the ball found near the optic foramen, close to the optic nerve, and extracted. The wound healed promptly. Exophthalmus disappeared; motility of the eyeball outward was slightly impeded without causing diplopia; pupillary reaction was normal. V = 5/x (astigmia).

Trendelenburg[23] operated on a case of monocular total ophthalmoplegia, ptosis and amaurosis with blanched optic papilla. He operated after the manner of Kraus and removed numerous osseous splinters. The author stated his belief that the function of the optic nerve might be restored by uniting the torn portions.

One should be sure that all of the foreign body is removed, particularly in the case of wood, as urged by Edw. Jackson[8]. A drain should be laid into the depths of the wound and gradually withdrawn as healing progresses.

In withdrawal of a foreign body and caring for the wound, caution should be used not to injure, any more than is necessary, the levator of the lids, the orbicularis, the tear passages and the ocular muscles, as well as the globe. When parts have been divided by the injury, or by the operation, they should be carefully sutured in order to regain and preserve the function. If the foreign body be imbedded in the bone lateral or twisting movements should not be made on account of the danger of fracture, but it should be seized by forceps so that direct traction may pull out the object. If the body has passed through into the spheno-

palatine fossa, resection of the outer wall of the orbit (Kroenlein's operation) should be selected, as reported by W. Zimmermann.[22] If the body enter the facial sinus appropriate operations upon them may be selected. In many cases it is necessary to enucleate the eyeball, as it is usually ruined, and the retention of a large and usually unclean foreign body in the orbit is dangerous to life.

Some unusual cases of foreign bodies in the orbit are herewith appended:

Hirschberg[24] observed a man, aged 19, who, while hammering iron, had a piece of the hammer fly through the lower lid into the nasal part of the orbit. The next day Hirschberg found ptosis; the eyeball protruded, almost immovable; pupil dilated to 8 mm.; V.=1/xv (fingers at 4 meters): visual field contracted outward, upward and inward. The sideroscope indicated maximal deviation downward and toward the nose, none toward the temple. By the long, cone-shaped tip of the large hand magnet a piece of steel, 12x9x3, weighing 780 mg., was extracted, with recovery. V.=5/vii.

A slight contraction of the visual field upward and outward was due to half a dozen small ruptures of the chorioid. Another insular defect above the fixation point was attributed to a partial injury of the macular fibers of the optic nerve. Corresponding to it, pallor of the macular half of the optic disc was ascertained at a later examination. The paralysis of the internal rectus muscle was probably caused by a direct lesion of the branch of the oculomotor nerve supplying it.

Out of Hirschberg's 340 magnet operations this is the only case in which a piece of iron was lodged in the orbit, and no similar case has been published. Hirschberg remarks that it is readily conceivable that a very great force is required to drive a piece of iron through the lid far into the orbit.

Chacon[25] reports a case of some clinical interest. The patient, laborer, had the evening before been struck by a box of bottles, making a slight wound above the brow one centimeter in length at the junction of the outer two-thirds of the orbit roof. Pus soon formed, and although the swelling was repeatedly incised, the wound did not heal. Finally the probe discovered a foreign body of wood 9 mm. broad and 53 mm. long, cone-shaped, which had penetrated the orbit horizontally. Vision was lost, the disc was pale, atrophic. In all probability the splinter had penetrated to the optic foramen.

Hirschberg[26] had a man, aged 34, who complained of occasional excruciating pain in his eye from a foreign body which had entered the eye more than two years before. All attempts with giant magnet, soon after the injury, had been in vain. This was peculiar, since the eyeball was without irritation and showed no siderosis. There was a scar of a

penetrating injury and detachment of the retina, vision being reduced to perception of motion of hand. The Roentgen photograph cleared the condition by revealing a large foreign body at the temporal border of the orbit. After an incision the foreign body followed neither hand magnet nor giant magnet, but had to be cut out with forceps and scissors from enclosing tough connective tissue. The pain subsided at once.

LITERATURE.

1. Würdemann, *Northwest Medicine,* March, 1909.
2. Berlin, *Graefe-Saemisch,* Bd. vi.
3. Sweet, *Ophth. Record,* July, 1907.
4. Praun, l. c., p. 451.
5. Hulke, *Brit. Med. Journ.,* No. 28, 1887.
6. Fromaget, (a) *Arch. f. Ophth.* xiv, p. 657. (b) Brundenel. Carter, *Ophth. Rev.,* No. 4, p. 337.
7. Güterbeck and Bernhardt.
8. Edw. Jackson, *Ophth. Record,* Aug., 1904.
9. Keiper, *Ophth. Record,* Sept., 1905.
10. Packley, *Australian Med. Gaz.,* June, 1906.
11. Brundenel. Carter. *Ophth. Rev.* No. 4, p. 337.
12. Noyes, *Dis. of Eye.,* 1890, p. 689.
13. John W. Wright, *Text book of Ophthalmology,* 1909, p. 55.
14. Junius. *Zeitschr. f. Aug.,* 1909, p. 138.
15. Gifford, *Ophth. Record,* March, 1905.
16. Morrow, *Ophth. Record,* Oct., 1904.
17. Ledbetter, *Ophth. Record,* March, 1905.
18. C. H. Baker, *Ophth. Record,* June, 1900.
19. Allport, *Ophth. Record,* June, 1900.
20. Johannes Berlin, *Inaug. Dissert,* Giessen, 1908.
21. Posey, *Ophth. Record,* March, 1905.
22. W. Zimmerman, *Klin. Mon. f. Aug.,* Sept., Aug., 1907, p. 195.
23. Trendelenburg, *Ophth. Klinik,* No. 15, 1904.
24. Hirschberg, *Centralbl. f. prak., Aug.,* 1906, p. 106.
25. Chacon, *Anales de oftal.,* Feb., 1904.
26. Hirschberg, *Centralbl. f. prak. Aug.,* 1906, p. 259.

C. INJURIES FROM BLUNT OBJECTS.

a. Exophthalmus from orbital hemorrhage.

Etiology. As a rule the bleeding occurs from direct or indirect injury to the walls of the orbit, the former by shot and stab wounds where the vessels are directly opened; the latter in fractures of the walls where the blood comes from the periosteal lining of the orbit, the facial sinuses, the base of the brain and the vessels of the latter. We here consider both forms of injury, although the direct forms have been touched upon in treatment of Injuries of the Optic Nerve, and will be referred to again in Fractures of the Orbital Walls.

When the injury is a contusion the bleeding fills up the orbital cellular tissue, causing moderate exophthalmus, but when the tissues are badly torn, as from fracture of the walls and laceration of the contents, the proptosis may be very great. Therefore it is reasonably safe to sup-

pose a fracture when the exophthalmus is severe. In many cases only the autopsy determines the actual amount and cause of the lesion.

In von Hölder's series of autopsies Berlin[1] found 6 in which the orbital hemorrhage was not accompanied by fracture of the walls of the orbit.

Morian[2] reports a patient who fell from the third story of a building and died one and one-half hours afterwards, in whom the autopsy showed bleeding into the orbit without fracture.

Symptoms. A small amount of hemorrhage does not give rise to any symptoms unless the blood extravasates under the conjunctiva and lids, when it appears as an ecchymosis. However, such a suggulation may appear as a blood tumor or hematoma of the conjunctiva (as shown in figure), and in the case of much bleeding behind the eye to cause a hematoma of the orbit with resultant exophthalmus, hindrance of the ocular rotations, double vision from strabismus and loss of sight from pressure on the optic nerve. The eye does not protrude directly forwards, but usually outwards and down or upwards, depending upon the pressure exerted by the blood clot. The greater the protrusion the less the amount of ocular movement, as the muscles are stretched, pressed upon and have no room for contraction. The recti nerves are also subject to pressure, and this may lead to degenerative atrophy.

Bleeding under the conjunctiva and into the lids may not be apparent at first, but generally shows after several days. When it happens immediately it is a sign of contusion of these structures. On pressure the eye does not recede into the orbit and it also seems firmly fixed above, below, and to the sides. The patient complains of a feeling of pressure and fullness and has considerable pain, but not as in the case of orbital phlegmon. The sight fails from pressure on the nerve, bleeding into the sheaths and from direct injury. The prominence of the globe straightens out and stretches the optic nerve, but does not cause the loss of sight. The fundus examination is negative unless the nerve be compressed, when the fundus is edematous and the arteries carry little blood, the veins being tortuous. When the nerve is injured directly the circulation is thereby cut off.

Pagenstecher[3] and others have considered an otherwise unexplainable mydriasis after contusion of the orbit to be due to pressure from a hematoma.

Ulrich[4] saw a case in which a retro-bulbar hemorrhage dented in the eye at the lower part and caused retinal detachment. A myopia of 6 D. was produced by the lateral compression.

Causé[5] reports a case of retro-bulbar hemorrhage into the orbit, with great protrusion of the eyeball of 8 to 10 mm., in a boy who was struck by a two pound stone thrown by another boy, causing a lacerated

wound of the superciliary arch with bleeding therefrom, but not from the nose, ear or mouth. An aspirating needle was entered through the outer part of the upper fornix and 15 ccm. of brown, partly clotted blood removed, when the eye "came back." After three days the patient was discharged cured, and eight months later was well.

Course. The resorption occurs in three to four weeks. The vision and motility usually return if the nerve be not directly injured by laceration or bleeding into the sheath.

I had the sad experience[6] of having an extensive hematoma of the orbit follow a lipoma operation, which first produced exophthalmus from an extensive hematoma of the orbit, followed later by enophthalmus, atrophy of the optic nerve and abducens nerve.

In old and weak individuals the resorption is much slower. The hematoma may develop into an orbital abscess if infected by a foreign body, via a wound of the skin or from a nearby sinus, especially the nasal, frontal or ethmoidal or sphenoidal, and bacteria thereby find lodgment.

Complications of injury to the globe, nerve and infection. The protrusion of the globe leads to lagophthalmus and corneal ulcertion.

The Diagnosis is secure upon finding increased pressure of the orbital contents, protrusion of the globe, and suffusion of the lids after a trauma.

If abscess supervenes fever develops and the pain is very great, the local temperature rises and palpation shows fluid. Concurrent fracture of the walls is difficult and often impossible to diagnose.

The Prognosis of orbital hematoma without fracture of the walls is good, as most cases result in full recovery after about one month.

The Therapy is pressure bandage and the ice bag. As a rule it is not advisable to make incisions to withdraw blood unless the high grade of protrusion gives reason to fear for the safety of the cornea.

b. Contusions of the soft parts of the orbit.

Bleeding into the tissues of the orbit with contusion is very common from blows and falls, forming a part of the picture of the ordinary black eye discussed more fully heretofore. The bleeding may occur in the form of a tumor under the skin, the fascia or the periosteum, and it spreads very rapidly through the tissues, appearing in both lids and proceeding under the skin of the root of the nose to the other eye. In many cases the edema is so great that the lids cannot be separated at will.

The course is favorable, as the resorption is usually complete in a couple of weeks. In scrofulous children and syphilitics blows and falls upon the orbital rim may first cause contusions, but later lead to periosti-

tis and caries. In severe cases the question of fracture should be determined.

The treatment is compress bandage, iced compresses, and massage. After several days hot compresses aid in resorption of the blood and blood stain.

We may add to this paragraph one form of the so-called injury by contre-coup.

Cheney[7] reports one of his cases, a boy, who was struck over the eye by a stalk of rhubarb. Eight days after exophthalmus set in with limitation of ocular movements. Eleven days from the injury optic neuritis developed and diagnosis of pus in the orbit was substantiated by operation. He thinks that the counter stroke was of sufficient severity to result in breaking down of tissue and formation of an abscess, the point of injury being in the posterior third of the orbit within the muscular cone.

c. Contused and lacerated wounds of the soft parts of the orbital rim.

Etiology. Blows (and falls) from objects which compress the tissues between them and the orbital walls.

Symptoms and Course. As a rule contusions of the orbital rim are accompanied by more or less solution of continuity of the skin and overlying tissues. Of particular interest in medico-legal practice is the sharply defined wound of the upper and outer part of the brow, produced by falls or blows, as the medical witness will surely be asked if it is not possible that this was produced by a knife or other sharp instrument. This goes to the bone, but not into it, and the injury is greater next to the bone and it does not gape as would be the case of a cut by a knife. As a rule severe edema of the wound and eyelids follows, so that the eye cannot be opened.

Complications. Infection is quite probable, for the edges of the wound are contused. Periostitis, caries and necrosis are common sequelæ. Local and phlegmonous inflammation and gangrene of the soft parts may follow, as in the case of Valude[8], where gangrenous phlegmon of the lids and eyeball, with death from septicemia, resulted from such an injury.

By greater force fractures accompany the injury and may be attended by emphysema from the air coming from the nasal cavity.

Such injuries may be attended by contusion and laceration of the deeper parts of the orbit, and in fact, when found, this contiguity should never be overlooked.

Priestley Smith[9] reported a young man hit by a brass pipe, cut on the left eyebrow and the eye drawn forwards. The vision was

reduced to qualitative light perception. Bleeding into the orbit was diagnosed and found to recur, as the man was a hemophilic.

Inoculation by syphilis happened to the patient of Moret-Lavallée,[10] who was bitten in the left eyebrow by a robber.

Tetanus has been reported by many observers, the literature being collected by Fromaget[11] and Wahl.[12]

Enophthalmus follows such injuries, especially if accompanied by fracture.

Supra-orbital amaurosis is an interesting complication.

Diagnosis. There is a contused wound, generally of the upper and outer orbital margin, lying lengthwise with the orbital rim, and the injury is greater nearer the bone than at the skin, while knife wounds gape open and are smaller in the deeper parts than at the skin edges.

The Prognosis is generally good, although a scar remains which may sometimes be depressed and attached to the periosteum.

The Therapy consists in freshening the edges of the wound and suturing. If infected, drainage and surgical dressings.

J. Ivimy Dowling[13] reports two cases of supra-orbital neuralgia due to calcus and fracture about the supra-orbital foramen, with operations and cure:

In one a woman of 54 had been struck in the center of the eye by the lid of an ice box several weeks before. Immediate pain, subsequently becoming intolerable, and the general health affected by the nervous strain. Incision one inch in length parallel and below the eyebrow showed stenosis of the foramen. This was converted into a notch by chiseling; the wound sutured; union by first intention. The nerve was injured so that one-half inch was resected. Numbness and crawling sensation followed. No pain or recurrence after two years.

Supra-orbital amaurosis and amblyopia.

Praun[14] states that the literature of supra orbital amaurosis reaches back to Hippocrates and gives many references.

The blinding or diminution of vision from a blow upon the forehead is either due to injury of the brain, the optic nerve or to the bulb, which we have previously described, and the so-called reflex amaurosis must be referred to these causes, even if in the living case we may be unable to definitely fix the lesion to any one locality.

Certainly most cases are due to fractures at the optic foramen, but there is described by certain authorities a form of reflex amaurosis after injury to the supra-orbital nerve, a sensory twig of the trigeminus, which is an analog to reflex amblyopia with contraction of the field of vision caused by disease of the teeth, the nerves in the intestinal tract, and to the sympathetic irritation of irido-cyclitis.

Leber[15] reports a boy who four weeks before had been hit by a comrade with his knuckles in the neighborhood of the right eye. Cramp of the facial muscles followed; on the upper lid under the foramen a yellowish suggulation discoloration was seen and the spot was tender. Papilla vessels red and congested; V. R.=15/200; L.=fingers at four feet. Double vision with red glass. Case cured by small hypodermics of morphia and galvanism. Experiments upon animals have never produced such results.

Bettremieux[16] saw a case of pseudo-paralytic ptosis following an accident, the damages pertaining to the injury having been settled, a month after, by a pension corresponding with a reduction of 8 per cent in professional capacity.

The patient, a carpenter, 22 years old, was injured March 10, 1906, by the falling of a heavy piece of wood, which produced a right fronto-parietal contusion with cerebral concussion. The injury did not seem to produce any serious consequence, and at the end of March the man returned to work. He complained in April that the vision of the right eye had diminished and the question was raised as to whether there was an optic nerve lesion. Bettremieux saw the case May 3, and found a complete closure of the right eye, with lowering of the corresponding eyebrow, which eliminated the diagnosis of a veritable ptosis. There was no appreciable lesion discovered by ophthalmoscopic examination. The pupillary reflex was normal; patient complained of a pronounced amblyopia of right eye. From several proofs of simulation, Bettremieux believed that the amblyopia was feigned, and two confrêres confirmed that opinion, which was based on the fact of the association in the same subject of hystero-traumatic blepharospasm and simulated amblyopia. Such a combination would be an exception to the rule of Parinaud that amblyopia or amaurosis does not occur with blepharospasm. There was anesthesia of the pharynx and nearly complete right hemianesthesia, with a few zones of intermittent sensibility; the knee-tendon reflex was normal; the right plantar reflex was suppressed.

The visual acuity of the left eye was normal; the limits of the field for this eye were approximately the same for all directions, 30° for white, 20° for red and green and 10° for blue. Medical treatment and electrization gave no result. Operation for ptosis was refused. Bettremieux believes it would be more just, in disability resulting from injury to insist on the elapse of a longer period before deciding as to the amount of indemnity.

d. Contusion and isolated fracture of the orbital margins.

Etiology. Contusions of the bony margins of the orbit, especially in children, through falls or blows, are very common. The soft

parts are bruised and periostitis or caries may come, especially in scrofulous subjects, with formation of pus and a fistulous opening. Emphysema of the lids and brows occurs from breaking of the frontal or ethmoidal sinus walls.

Mitteldorpf[17] reported six cases of inflammatory edema or emphysema following fracture of the anterior wall of the frontal sinus.

Detachment of portions of the bone may occur from bullet wounds, as reported by von Oettingen.[18]

Isolated fractures of the external or internal tables of the frontal, malar or upper jaw bones sometimes occur, but are rare.

The Diagnosis is from the abnormal passive movement and coaptation and from X-ray examination. One should be sure that other bones of the face and orbital wall are not implicated.

The Prognosis is generally good, but unsightly depressed cicatrices may follow and the soft parts may become adherent, producing ectropion.

The Therapy is removal of fully detached portions of bone, or in their reposition by wiring, nailing and bandaging, together with surgical care of the wound of operation.

Brandenburg[19] described a splintering of the outer margin of the orbit, with impaction of the splinter under the roof of the orbit. The splinter was removed by the chisel and fitted exactly into the defect of the outer wall.

e. Fracture of the orbital walls and the facial bones.

The conditions of displacement, the symptoms, as well as the complications of orbital and facial fractures differ according to the location and are better taken up separately.

Generally we differentiate: 1. Direct isolated fractures, with or without displacement of the fragments. 2. Fractures from radiation or extension of those of the skull or facial bones. 3. Isolated indirect fractures, or those from contrecoup in which there is an unbroken part between the place of impact of the force and that fractured.

Etiology. Direct fractures are caused by shots and punctures, likewise fractures from extension, but, in addition, through blunt force, as falls, blows and thrusts; the isolated and indirect fractures from contre-coup.

Symptoms. Hemorrhage under the conjunctiva and into the lids and orbit, with exophthalmus and dislocation of the globe, are apparent from the hematoma. In a few cases the globe may be moved from place by dislocation of the boney fragments.

Complications. Opening of the cranial cavity and facial sinuses; injury to the orbital contents, especially the eyeball and the

optic nerve, the blood vessels, muscles, nerves and lacrimal apparatus; and exophthalmus, are common complications.

The course may be complicated by inflammation of the opticus, causing a descending neuritis with resultant atrophy, adhesions in the orbit and loss of motion of the globe, and cicatricial contraction of the orbit so that a prothesis is impossible without plastic operation, and not then satisfactory. There is danger of infection of the wound either externally or from the sinuses, with orbital phlegmon, sinus thrombosis, meningitis and encephalitis.

Diagnosis. In a few cases the break may be seen or felt by the finger or probe. The abnormal movability of the fragments shows the fracture. We may seldom observe crepitation which is so apparent at the rim of the orbit or in other bones. Bleeding under the conjunctiva, into the lids, and the hematoma of the orbit, with full and rapid protrusion of the eye, and great pain on pressure near the broken region, is pathognomonic.

The fragments may be felt in the orbit upon light pressure by using the fingers. When the hematoma resorbs enophthalmus may result. Localization may be made by the concomitant symptoms. Where the cranial cavity is opened, brain symptoms occur; where the accessory sinuses are opened, emphysema; and in fracture of the apex, one-sided amaurosis may be seen if the optic nerve be injured.

Prognosis. Fractures of the orbit are always dangerous and their effects often impossible to prognosticate. When the cranial cavity is opened and there is infection, the prognosis as to life is bad. When the eye or optic nerve is injured, or is involved later by inflammation, the outlook as to sight is likewise very bad.

Therapy. This is aseptic surgery; foreign bodies and loose splinters of bone must be removed. If the accessory sinuses are involved the nose should be gently cleansed, but not douched, and packed with iodoform gauze strips, removed within 48 hours.

1. Fracture of the roof of the orbit.

Of all fractures of the orbit, that of the roof is the most important and dangerous to life, as here the cranial cavity is impinged upon or entered, the meninges and brain tissue injured, with danger of resulting meningitis and abscess, followed by an exitus lethalis.

Etiology. The direct isolated fractures are usually from penetrating and fire-arm injuries, which come from the front or sides and upwards through the orbit, more seldom from the side or from the mouth or nose.

The radiation fractures may come from shot, usually those through the mouth, or from severe blunt force as blows or falls, and proceed from

the vertex of the skull, usually the frontal bone, down to the roof of the orbit. The force may be exerted only on one side, but it may be upon both (as in compression of the skull in a boy whom I saw whose head was crushed by an elevator), or from the compression by the forceps in childbirth.

In suicidal shots into the mouth the bullet passes through the hard palate and the base of the skull, injuring the sphenoid and passing into the middle fossa of the skull from which the fracture extends to the orbit. Shots from an oblique direction seldom give rise to this form of fracture.

Isolated indirect fractures of the roof occur in connection with bullet fractures of the vertex.

Symptoms and Course. The external appearances in direct fractures are those of a penetrating wound of the orbit. The inner angle is the usual point entered, then the upper lid, more seldom between the eyelids at the point of transmission.

About one-fourth of the cases of brain injury in this connection prove immediately fatal, according to Berlin.[1] In others there is unconsciousness, delirium, headache, vertigo and weakness. The symptoms of concussion of the brain, as slow pulse and vomiting, are not constant. Convulsions, hemiplegia, etc., depend upon the part of the brain injured. The further course is inflammation and fever with meningitis. Most of the cases pass out from the direct injury to the brain, hemorrhage, meningitis or encephalitis. In a large proportion of the cases that live through the injury, secondary affections, as hemiplegia, headache and vertigo, epilepsy, insanity and imbecility, follow the injury.

In fractures by irradiation, or contrecoup, of the roof of the orbit, there are symptoms of fracture of the base of the skull and concussion of the brain, especially bleeding from the ears, nose and mouth, as well as orbital hematoma, with quickly developing proptosis, conjunctival suffusion and suggulation of the eyelids; and, by injury to the optic canal, one-sided blindness, besides loss of consciousness, vomiting, superficial respiration, small pulse, disturbances of motion and speech and loss of function of the nerves passing along the base of the brain. But few cases of brain concussion occur without these symptoms, which are here proportionately greater than those of direct laceration of the brain tissue, occurring in direct fracture of the roof of the orbit and which cause pronounced localization symptoms.

If the effect of the force be exerted on the forehead, orbital margin, or in its neighborhood, a defect in the bone and displacement of the fragment may be observed. In mouth, temple and other skull shot wounds the connection may not be seen but be inferred from the resulting symptoms. While shot wound fractures of the orbital roof

connected with injuries to the brain usually prove lethal, uncomplicated cases generally recover. At least a fatal ending is less common than when complicated or than in direct fracture.

Opening of the fissures of the orbital roof between the frontal, ethmoid and sphenoidal bones may be caused by a moderate degree of contusion, such as blows upon the rim of the orbit, blows or falls on the head, or on the feet or buttocks, without causing brain symptoms or exophthalmus, and the main symptom be a slight degree of subconjunctival hemorrhage.

Complications. In direct breaking of the orbital roof there is always opening into the anterior fossa of the skull, the bone being very thin in this location, and commonly, there is laceration of the meninges and the substance of the brain and the entrance of the object producing the injury. The retention of a foreign body or the impaction of broken bits of bone into the brain is very unfavorable to life. A few authors, Anders,[20] Norton,[21] Bock[22] and Zinsmeister,[23] have reported caries and necrosis following an irradiating fracture of the roof of the orbit. In my case there developed permanent paralytic ptosis.

Diagnosis. The anamnesis is of aid in determining the existence of a direct injury and where the brain is injured the symptoms of laceration will appear.

The rapidly occurring suggulation of the lids and conjunctiva, and hematoma of the orbit with exophthalmus, the prolapse of orbital fat and occasionally of brain tissue, show the character of the lesion. Where the brain symptoms fail the diagnosis is difficult, although they often ultimately occur as meningitis, encephalitis, with unconsciousness and other symptoms from intracranial hemorrhage. Therefore it behooves us to keep these patients quiet in bed for several weeks after such an injury.

The direct examination of this form of fracture is often impossible, as it is often in the depths of the orbit and the bulb covers the wound canal, as during the infliction of the injury the eyeball may have been pushed to one side and afterward returned to its place. The sterile finger here makes the best and safest sound and is not so apt to push broken fragments of bone further into the brain. Unless there be evidences of a retained foreign body probing is superfluous and dangerous.

In radiating and isolated fractures by contre-coup the symptoms of basal fracture and brain concussion, with the rapidly occurring bleeding into the lids, under the conjunctiva and into the orbit, with proptosis and the generally occurring blindness, are prominent symptoms. Bleeding from the ear means fracture of the petrous bone. Bleeding from the nose may only be due to injury of the soft parts. Flow of cerebro-spinal fluid from the ear and nose, the latter from the cribriform plate of the

ethmoid, means a basal fracture. Where the margin of the orbit is fractured the fissure may be seen as a notch, or felt by the fingers.

Prognosis. Direct fracture of the roof of the orbit is unfavorable to life and the few who live usually have severe secondary affections.

Berlin[1] states that only 21 per cent live. Of three living patients one was hemiplegic, one had headaches on bending over, and one became weak-minded.

In contradistinction the prognosis of basal fracture with radiation to the roof of the orbit is comparatively good, although commonly blindness results, as the fracture may extend to the optic foramen.

Therapy. In direct fractures we should, under rigid aseptic precautions, freely open the wound of entrance and remove foreign bodies, bone splinters and wound secretion. Probing and irrigation are not to be done, as pathologic products may thereby be carried deeper into the tissues and cause infection. This is to be remembered likewise in dealing with orbital abscesses. Gauze drainage from the opening will remove the secretions with less danger.

The operation may be best conducted through an incision through the brow, the skin well retracted, and if necessary resection of the margin of the orbit be made in order to safely reach the foreign body for its removal and that of the broken bone splinters. The finger here makes the best probe, and by it the broken bone may be diagnosed and the splinters seized with forceps and removed.

When the posterior part of the roof is fractured and a foreign body known to be therein, as the eyeball has usually been destroyed, enucleation or partial exenteration of the orbit may be done, and thus direct access to the fracture be obtained, the foreign body and bone splinters brought into view and soon easily removed, and the wound secretion better drained. All splinters should be taken away, as even very small ones may later cause inflammation, meningitis, brain abscess and loss of life. If a localized brain abscess, which is common in bullet hole fractures, is found, it should be opened and drained.

In the milder cases, as where brain symptoms do not occur, the eyeball may be retained and simple drainage of the wound secured, but where the bulb is injured there should be no compunction about an enucleation, as we thereby secure a better diagnosis and drainage.

The treatment of irradiating and contre-coup fractures is that of fracture of the basis cranii. If foreign bodies occur and bone splinters are found they should be removed under stringent asepsis.

There have been many cases of direct fractures of the roof of the orbit observed from ancient days. The eye has ever been the mark for the arrow, for the bullet and for the fist.

Morrow[24] reported the following case of direct injury with pene-

tration of the middle fossa of the skull by a breech-pin. Male, aged 56. Injury from explosion of an old shotgun, with shattering of the breech and stock. The brow of right eye was torn from its bony attachment, and the lid was also partially torn from the brow. Fracture of the nasal bone and the upper rim of orbit. The breech of the gun, 43 mm. long, was found imbedded in the orbit and was removed. The orbital plate of ethmoid was found fractured into small bits, and was removed. Roof of orbit fractured and fragments removed, exposing pulsating dura. It was backward through the sphenoidal fissure that the cranial cavity was entered, and it was estimated that the foreign body had extended 14 mm. into the middle fossa. The globe was not penetrated, but was so extensively damaged that it was enucleated. Severe orbital cellulitis followed, with temperature of 104° F., but under irrigation and free drainage recovery was uneventful. A photograph of patient with prothesis in position shows an excellent cosmetic result.

I have seen a number of cases of undoubted irradiating fractures of the base of the skull implicating the roof of the orbit. Unfortunately most of them were only seen once in consultation, and the subsequent histories are unknown. Most of these were railway and trolley car accidents. In one case a man fell down a cellar stairs and the next day walked to my office on account of two very severe black eyes, as he called them. He then had slow speech, rapid pulse and superficial respiration; the right eye was bulged forward, lids of both suggulated with blood and he had bled freely from the nose. Diagnosis of irradiation fracture of the roof was made and the patient sent to the hospital, recovering fully after several weeks.

Messerer[25] reports an indirect contrecoup shot fracture in an attempted suicide, who held the revolver against the right temple. The wound canal passed through the soft parts, bone and brain, to the left side of the inner wall of the cranium, richochetted in an angle of 45° backwards and inwards. The post mortem showed also a localized oblique fracture of the roof of the right orbit.

I also noted a localized fracture of the orbit in a patient who suicided by jumping out of a third floor window, falling flat on his outstretched body. The post-mortem showed among many injuries a fracture of the base of the skull, not, however, connected with that of the orbit.

2. Fracture of the outer wall.

Etiology. Fractures of the outer wall may be direct and these most often due to bullet wounds, more seldom to punctures and irradiating fractures proceeding from those of the orbital margin or the zygoma. In war time, and more in the olden days, injuries from bayonets, sabers,

and knives were more common. The wall is usually injured from the temporal side rather than from the orbit. The foreign body passes, with or without injury to the globe, to the floor of the orbit and may also break this or pass through the lower fissure. The lacrimal gland is seldom involved, as it is well protected by the projection of the brow.

In firearm injuries the force generally comes from outwards and the orbital contents, as well as the globe, are generally greatly damaged. Of these the globe, the nerve, the orbital vessels, muscles and nerves are most affected, and the intra-orbital bleeding produces hematoma with marked exophthalmus. Wagenmann[26] explains the occurrence of corneal necrosis from injury to the ciliary ganglion and nerves, as well as to the posterior long ciliary arteries, and has proven this upon rabbits.

The Diagnosis is from appearances and sounding by the finger and probe. Crepitation may commonly be elicited.

The Prognosis depends upon the amount of injury and damage to the eyeball.

The Therapy is surgical.

3. Fracture of the inner wall of the orbit.

Etiology. Direct fractures come from punctures and shot wounds. In bullet fractures the inner walls of both orbits are usually broken on account of their contiguity and thinness. Nearly all these fractures come from bullet wounds; two from other forms of injury are, however, noted below.

The irradiating fracture occurs with fracture of the base of the skull, usually connected with that of the roof of the orbit, then the frontal, malar, the upper jaw bones, connecting with the thin lamina papyracea of the ethmoids and the lacrimal bones. These fractures come from blows, falls and shot wounds.

The break is generally due to direct force and is evident to the examining finger. Two characteristic symptoms occur, bleeding from the nose and emphysema of the orbit and lids, as was well marked in Reber's case.[27]

In a case seen by me of fracture of the nasal bones, nasal process of frontal, ethmoids, and presumably the roof of the orbit, in a man who was struck by a scantling across the brow, there not only developed the deformity of a saddle-nose but pronounced paralytic ptosis.

The prognosis is good, barring complications of infection and orbital abscess, which arise from external wounds or from those of the sinuses.

The Therapy is surgical and especially prevention of infection by tamponade of the nose by iodoform gauze. Injections are not to be made on account of carrying infection to deeper structures.

Stoewer[28] describes a case injured at the Roburit factory explosion in which there was a wound over the eyebrow, lid suffused by blood, eyeball not injured. Paralysis of abducens, lack of pupillary reaction,

Fig. 359.

Reber's case of emphysema of lids following fracture of the inner wall of the orbit.



Fig. 360.

Fracture of nasal bones, nasal process of frontal, ethmoids and roof of orbit, with paralytic ptosis and saddle-nose.

fundus normal, V.=o. Frontal sinus open, inner wall fractured with exposure of brain, posterior ethmoid cells and orbit fractured and optic nerve found injured by lesion of bone at post-mortem two weeks later.

In a lady who got off a street car and passed behind it just in time to have her eye almost completely gouged out by the end of the shaft of a light wagon, the nasal bones were fractured and also the inner wall of the orbit, the ethmoids being comminuted. I had to immediately enucleate the eye, remove the bone fragments, and from the orbit could observe the middle fossa of the nose. Full healing resulted and a more or less satisfactory prothesis was later fitted. This patient sued for $10,000 damages, but the case was thrown out of court on account of some technicality.

4: Orbital emphysema.

Etiology. This symptom is due to air being carried into the orbital tissues through communication of the nasal cavity with the orbit by fracture of the ethmoidal and sphenoidal plates of the inner wall, thus opening the ethmoidal and sphenoidal sinuses; by break of the superior inner wall, the frontal sinus, and by that of the floor, the superior maxillary sinus. Also in rupture of the lacrimal sac air may gain communication to the orbit. In all of these injuries there must also be a laceration of the periosteum, the bone, and the mucous membrane of both the sinuses and that of the orbit.

Symptoms and Course. Emphysema of the orbit is usually combined with that of the lids and conjunctiva. There is moderate exophthalmus, which is lessened by closing the mouth and by full expiration. There may be lessened motility of the globe and rotation to one side, as in hematoma, but the globe may be readily pushed back in place, with a feeling of crepitation and a sound as of crunching snow. The diagnosis is safe if the globe goes back on pressure and prolonged expiration; and on blowing or sneezing fills out again. In abnormal communication, as from caries, emphysema may recur for years.

Orbital emphysema in itself is harmless. Marcus[29] injected air into rabbits' orbits with force and in a few cases caused death by the force, tearing open the ophthalmic veins. This has not occurred in human beings.

The therapy is to avoid forcible expiration and sneezing and the use of a pressure bandage.

This condition also occurs occasionally after intranasal operations, particularly for ablation of the middle turbinal body and opening the ethmoid cells, from fracture of the inner wall or perforation by the currette. I have noted three such cases in my own, and others practice, in none of which were there any evil effects, the emphysema disappearing in a few hours and no infection taking place, except in one instance where a localized abscess of the lower lid developed, which was opened and drained externally with good results.

5. Fracture of the floor of the orbit.

Etiology. Direct fractures obtain from all forms of foreign bodies and implicate the maxillary antrum, nose and naso-pharynx, or may first pass through these cavities to the orbit. These may either be from punctured or shot wounds. Bullet wounds from the temporal side may shatter the floors of both orbits; those from the mouth may range upwards and pierce the floor of the orbit, injuring the globe and passing up into the brain.

When inflicted by great force radiating fractures extend from the maxilla, malar and base of the skull. The causes of these are usually blows or falls upon the face. Such a fracture may be primarily in the orbital wall and extend to the malar, as reported by Bergman,[30] or conversely from the zygoma to the base of the skull, as shown by König.[31] The break is often observable by a depression or can be felt by the finger. Bleeding from the nose and emphysema from opening of



Fig. 361.

Actual size of piece of wood penetrating orbit, causing fracture of floor of orbit, etc. (Whitledge.)

the maxillary antrum are common. Infraction of the lower margin of the orbit and dislocation of the globe are seen.

The healing and course are favorable if uncomplicated. Commonly the injury to the infra-orbital nerve leaves loss of sensation of the cheek.

The Therapy is symptomatic. The fragments may be raised and held in position by wiring or nailing.

I have seen several instances of fracture of the floor of the orbit, mostly in connection with the malar bone. In the case of penetration of the orbit to the nose and naso-pharynx by a splinter of scantling in a sawyer, the inferior wall of the orbit, as well as the temporal wall, was fractured.[32]

Whitledge[33] reports penetration of the orbit through the lower lid, fracture of lower wall into the antrum, fracture of the internal wall and ethmoid and wound communicating freely with naso-pharynx, from large piece of wood. Vision not at the time affected. Parts brought together, healing. The fourth day the patient complained at dressing of black spot in front of eye. Partial detachment of retina, oblong in shape and twice

the size of disc, above and temporally to disc, seen. One year and nine months afterward V. was normal and narrow line of retinal atrophy marks original course and position of detachment.

A radiating fracture of the malar bone extending through the floor of the orbit and base of the skull was seen by me in a man who fell from a two-story scaffold ten days before. There was failing sight, the nerve had blanched, some hemorrhages in retina, V.=fingers at one meter. Moderate hematoma, paralysis of inferior rectus, moderate protrusion of globe, but it was not immovable. Death from meningitis about a week later; post-mortem showed fracture of malar, floor and apex of orbit extending part way to body of sphenoid.

6. Fracture of the malar bone.

Etiology. As a rule malar bone fractures are combined with those of the upper jaw or zygomatic process of the temporal bone. They are generally direct injuries, though, as noted under fractures of the floor of the orbit, may be due to irradiation from the base of the skull or orbital rim.

The malar bone may be torn away from its sutures with the maxilla and luxation be thereby constituted. As a rule these injuries are due to crushing of the head or to heavy blows, as from a horse's hoof. The cheek is depressed, the dislocation of the broken fragment being backwards and downwards. If the break go through the floor of the orbit the infra-orbital nerve is injured, with loss of feeling of the cheek. The usual symptoms are crepitation, exophthalmus, bleeding into the orbit, conjunctiva and lids, from the nose and mouth, difficulty and pain on chewing on account of partial laceration of the masseter, or movement of the fragments of bone against the coronoid process.

The Diagnosis is based upon the general symptoms of fracture, the flattening of the face, pain on chewing and direct examination by the finger.

The Prognosis is good, most cases making recovery.

The Therapy is symptomatic. The bone should be replaced by manipulation and held in position by bandaging.

I have never seen a fresh fracture of the malar bone except the one noted under fracture of the floor of the orbit, though I well remember several old cases where the flattening of the face was due to kicks from horses' hoofs, and two of bullet wounds in the Civil war.

Praun[34] quotes an instance of a man who came 14 days after being kicked in the face by a horse. The eye was proptosed, lids and conjunctiva suffused with blood, nose bleeding on the right side. The right side of the face was bruised and excoriated, especially over the nose and malar bone. The continuity of the lower rim of the orbit was broken

and the outer part of the malar bone found pushed downwards and backwards. There was loss of sensation on the cheek, pain on chewing, mouth-breathing and nasal speech, as the nasal passages were stopped up. The nose was washed out by sublimate solution and tamponned with iodoform gauze; full healing resulted.

7. Fracture of the superior maxilla.

Fractures of the upper jaw occur from the same causes as those of the malar bone. In but few cases is this bone injured separately. Generally it is combined with fracture of the malar, ethmoid, nasal, lacrimal, nasal processes of the frontal, walls of the orbit, base of the skull and lower jaw from severe compression of the head, kicks from horses or heavy blows from blunt objects. Railway wrecks, elevator and runaway accidents are usual causes. Fracture likewise occurs from bullet wounds. Dislocation of fragments may occur into the orbit and cause injury to the globe or nerve, orbital hematoma, exophthalmus and emphysema. Bleeding from rupture of the superior maxilla is dangerous.

The diagnosis is from the loosening of the jaw and symptoms generally of fracture. The prognosis is good when there is no fracture of the base of the skull. The treatment belongs to the general surgeon, who replaces the fragments and wires them into position.

A man was knocked over by a runaway and besides fracture of the femur he sustained a fracture of both the lower and upper jaws and zygoma, the latter from a blow from the horse's hoof, a triangular fragment from the inferior rim of the orbit entering the orbital cavity and being readily replaced by the fingers and held in position by a compress bandage. Full recovery ensued.

Therapy. The surgical treatment of fracture of the orbital walls consists in reposition, removal of loose fragments, and rest.

In splintering and comminution of the bones, with external wounds in complicated fractures, the loose fragments should be removed by forceps, attended by dissection of retaining bands of tissue by blunt-pointed scissors. However, loose fragments that yet remain attached by a good sized band of periosteum which can be replaced and held in position may be reposited and will heal in place. Fragments that have pierced the soft tissues may be elevated, cleared from the tissues, and properly replaced, being held by periosteal catgut sutures, metal clamps, or even by sutures placed in the soft tissues and supported by a retention bandage.

Simple fractures, without solution of continuity of the external skin or mucous lining of the walls of the sinuses or the dura mater of the cerebral cavity, are generally amenable. The complicated fractures which open up the sinuses need no direct form of surgical interference. They are generally upwards and inwards, or inwards and

downwards, and lead to infective processes from tearing of the mucous membrane lining the pneumatic sinus. Fractures of the inner-upper walls cannot be replaced except by external incision, which may be made below the eyebrow and the bone reposited by periosteal probes and forceps.

Those of the inner wall and those of the nasal processes may be replaced by manipulation through the nasal passages by the flat nasal probe, and held in place by nasal tampons. The treatment is usually combined with that of fracture of the nasal bones and heals with an external splint made out of dental rubber or composition to mould the external nose into shape. If the accessory sinus be involved the nose should be gently cleansed, but not douched, and packed with iodoform gauze strips, which should be removed within 48 hours.

Fracture of the zygoma may extend into, and a piece penetrate, the maxillary antrum. This may be replaced by the forefinger of one hand of the operator entering the mouth well behind the zygoma and the piece raised by the finger into place, the head being steadied by the operator's other hand. If this is not possible a strong resection hook is passed around the zygoma at the nasal process and it is pushed into place. If the fracture be complicated by an open wound then the splintered bone may be reached through the opening and raised by forceps or penetrated by a screw and thereby purchase given to relieve the impaction and replace the fragment.

In old healed fractures of the orbital rim, as well as in uncomplicated fractures, an external incision may be made with resection of the bone—i. e., an osteotomy—in order to reach the injured part, free the impaction and replace it.

Direct fractures of the orbital rim are the rule. Indirect fractures without replacement of the fragments require no operative interference. They are accompanied by indirect fracture of the orbital wall and usually with fracture of the base of the skull.

Direct fractures of the orbital walls are, as a rule, due to penetrating injuries of the orbit, are isolated, and are more amenable to surgical intervention than the indirect.

Under rigid antiseptic precautions one should freely open the wound of entrance, remove foreign bodies, bone splinters and secretion. Probing and irrigation are not to be done, as pathologic products may thereby be carried deeper into the tissues and cause infection. This is to be remembered likewise in dealing with orbital abscesses. Drainage by the opening with gauze will remove the secretions with less danger. The operation for fracture of the roof of the orbit may best be conducted by an incision through the brow, the skin well retracted, and, if necessary, resection of the margin of the orbit be made in order to safely reach the

foreign body for its removal and that of the broken bone splinters. The finger here makes the best probe, and by it the broken bone may be best diagnosed, the splinters seized and removed by forceps.

When the roof of the orbit is known to be fractured and the foreign body be therein, as the eyeball has usually been destroyed, enucleation of the globe or a partial exenteration of the orbit may be made and thus direct access to the fracture be obtained, the foreign body and bone splinters brought into view and more easily removed, and the wound secretion better drained.

All splinters should be taken away, as even very small ones may cause inflammation, meningitis, brain abscess, and loss of life. If a localized brain abscess (which is common in bullet hole fractures) is found it should be opened and drained.

In the lighter cases, as where brain symptoms do not occur, the eyeball may be retained and simple drainage of the wound secured, but when the bulb is injured there should be no compunction about an enucleation, as we thereby secure entire diagnosis and drainage.

In complicated or old healed fractures of this character, as the deformity is the only defect, it may be well to leave the matter alone, as no evil results have been reported from such conditions.

The treatment of irradiating and contre-coup fractures is that of fractura basis cranii.[35]

LITERATURE.

1. Berlin, *Graefe-Saemisch*, vi, p. 567.
2. Morian, *Zeitschr. f. Chirurg.*, xviii, 4, p. 803.
3. Pagenstecher, *Arch. f. Aug.*, xii, 2, 3, p. 143.
4. Ulrich, *Klin. Mon. f. Aug.*, 1882, p. 242.
5. Causé, Fritz, *Arch. Ophth. Record*, May, 1900.
6. Würdemann, *Ophth. Record*, May, 1900.
7. Cheney, *Boston Med. and Surg. Journ.*, Aug., 1898.
8. Valude, *Ann. d'oculist*, ciii, p. 204.
9. Priestley Smith, *Ophth. Hos. Rep.*, xii, 2, 1888, p. 70.
10. Moret-Lavalleé, Ann. de dermat. et physiol., 2, 1886.
11. Fromaget, *Arch. d'ophtal.*, xiv, p. 657.
12. Wahl, *St. Petersburg Med. Woch.*, No. 39, 1882.
13. Dowling, *Ophthalmology*, July, 1910.
14. Praun, *Die Verletzungen Des Auges*, p. 458.
15. Leber, *Graefe-Saemisch*, v, p. 973, and Arch. f. Ophth, xxvi, 2, p. 249.
16. Bettremieux, *la Clin. Ophtal.*, May 10, 1907.
17. Mitteldroff, *Breslauer, Arzlich. Zeitschr.*, No. 22, 1886.
18. Von Oettingen. *Die Indirekten Läsionen des Auges.* Stuttgart, 1879.
19. Brandenburg, *Arch. f. Aug.*, xxxi, 3, p. 272.
20. Landers, *Deut. Zeit. f. Chirurg.* 1876, p. 200.
21. Norton, *Arch. Ophth.*, xiii, 1884, p. 30.
22. Bock, *Allgemein. Wien. Med. Zeit.*, 1889.
23. Zinsmeister, *Wien. Klin. Woch.*, No. 24, 1888.
24. Morrow, *Ophth. Record*, Oct., 1904.
25. Messerer, *Centralbl. f. Chirurg*, No. 80, 1880.
26. Wagenmann, ref. Praun, l. c. p. 468.
27. Reber, *Ophth. Record*, Nov., 1889.
28. Stoewer, *Klin. Mon. f. Aug.*, March-Apr., 1907.
29. Marcus, *Deut. Zeitschr. f. Chirurg*, xxiii, p. 169.

30. Bergmann, *Centralbl. f. Chirurg,* No. 80, 1880.
31. König, *Lehrbuch d. Spec. Chirurg.,* Bd. 1, p. 178.
32. Würdemann, *Ophth. Record,* June, 1900.
33. Whitledge, *Ophth. Record,* Dec., 1901.
34. Praun, l. c., p. 470.
35. Würdemann, *The Surgical Treatment of Injuries to the Eyes,* etc. Vol. I, p. 755 Wood's *Ophthalmic Operations.*

D. INJURIES TO THE ORBIT FROM FIRE-ARMS.

a. Injuries to the orbital margins.

Glancing or superficial wounds of the orbital margins may occur when the shot does not come from in front, but from the outer, upper or downward direction. It may carry away a piece of the soft tissues or bone and produce contusion of the globe. Seldom does the shot remain in the orbital margin.

b. Injuries to the walls of the orbit and contents.

1. Injuries to the roof.

If the bullet comes from above and in front it splinters the upper margin and roof, ranging downwards, destroying the eyeball, passing through the anterior portion of the orbit, through the floor and outer wall, the face, and out of the head, usually by the aural region or through the naso-pharynx and neck. Bullet hole and radiation fractures have already been discussed.

Shots ranging from below upwards through the roof to the brain have more interest for the coroner than the ophthalmic surgeon, as they are invariably, and generally immediately, fatal.

2. Injuries to the floor.

As noted above, shots ranging from above pass downwards to the neck through the floor of the orbit. Grazing shots affecting superficially or passing through and fracturing the jaws and malar bone likewise shatter the walls of the orbit, particularly the floor. Those ranging from below pass upwards through the neck, face, floor and roof of the orbit into the brain, or the bullet may be stopped where resistance is sufficient and thus lodge in the root of the nose, orbital rim, base or sphenoid or its cavity, and likewise that of the frontal bone.

3. Temporal wall injuries.

The temple being the favorite situation for the would-be suicide to press his revolver muzzle, and at least 50 per cent of them pointing the barrel too far forward and thus failing in their immediate attempt, a large number of injuries to the eyes and orbit have been reported from this cause. Likewise in modern long range war, the shot injuries to the head have increased in proportion to those of the body.

The bullet passes from the temporal region through the outer wall of the orbit, destroying the eyeball if striking it; if passing behind, cutting through the optic nerve or avulsing the globe. The bulb and nerve may escape injury, but this, as well as the bullet remaining in the orbit or nasal cavity, is rare. Such injuries in war are usually fatal. The various injuries to the eye and surroundings produced by such shots have been amply illustrated under Injuries to the Nerve and Fractures of the Orbital Walls.

W e ek s[1] reported the case of an attempted suicide by shooting in the temple. The ball passed through both orbits without in any way interfering with vision.

4. Inner wall injuries.

The bullet may pass through the base of the nose or from the nose into the orbit; glancing and tangental shots passing through the superficial part of the face may range upwards and inwards to the inner wall, those passing through the inner wall of the side of the orbit anteriorly may range backwards and across the medial line and perforate the inner wall of the opposite orbit and destroy the optic nerve or globe.

N e w o l i n a[2] reports an interesting case in a man, aged 44. There was instantaneous blindness without ophthalmoscopic changes, which gradually developed into atrophy of the optic nerve and narrowing of the blood vessels. From the symptoms and Roentgen photographs, the shot apparently entered the orbit between its inner wall and the eyeball to the superior orbital fissure, along the osseous septum between this and the optic foramen, the cavernous sinus, above the Gasserian ganglion to the upper face of the temporal pyramid, where it became lodged. It injured the optic nerve, most likely the upper portion, in its avascular part, the ophthalmic branch of the fifth nerve, grazed its ciliary twigs, and contused the oculo-motor and trochlear nerves.

5. Bullet injuries from behind.

The bullet may range from the occiput forwards, reaching the eye and orbit. Also the bullet may enter the skull near the ear and pass forwards to the orbit, commonly destroying or tearing out the eye in its passage. Such injuries are only of medico-legal and mortuary interest, as none live thereafter.

6. Shot injuries of the orbital contents without injury to the walls.

The amount of damage done to the eyeball and orbital contents depends upon the size and velocity of the projectile, as well as the parts upon which the injury is inflicted.

In such bullet wounds of the orbital contents the eyeball is usually burst open; in shot wounds penetration or perforation of the globe is common, but at the same time shot pellets may be impacted in the tissues with or without injury to the globe. Cases have been known of penetration of the orbit by a bullet in which no physiologic damage has resulted. Instances have been given under Foreign Bodies in the Orbit.

LITERATURE.

1. Weeks, *Trans. Sec. Ophth. A. M. A.*, 1903, p. 217.
2. Newolina, *Beitr. z. Aug.*, 1908, p. 584.
3. Edgar R. Williams, *Ophth. Record*, June, 1908.
4. A. C. Girard, *The Use of the Roentgen Ray by the Med. Dept., U. S. A., in the war with Spain*, 1898.

E. TUMOR FORMATION IN THE ORBIT AFTER TRAUMATISM.

The cause of orbital tumors is usually ascribed to an injury, yet in few cases may the direct connection be established. Blows and contusion

Fig. 365.

Exophthalmus and proptosis of the eye due to non-malignant inflammatory hypertrophy and hyperplasia of orbital tissue complicated by periostitis of temporal bone. Exenteration of orbit. Recurrence of growth. Disappearance under radio-therapy.

of the orbital margins are so common, and so seldom followed by tumor formation, that unless we accept the Cohnheim theory we may be allowed to express doubt as to the connection.

LITERATURE.

Würdemann, *Wis. Med. Journ.*, Nov., 1904.

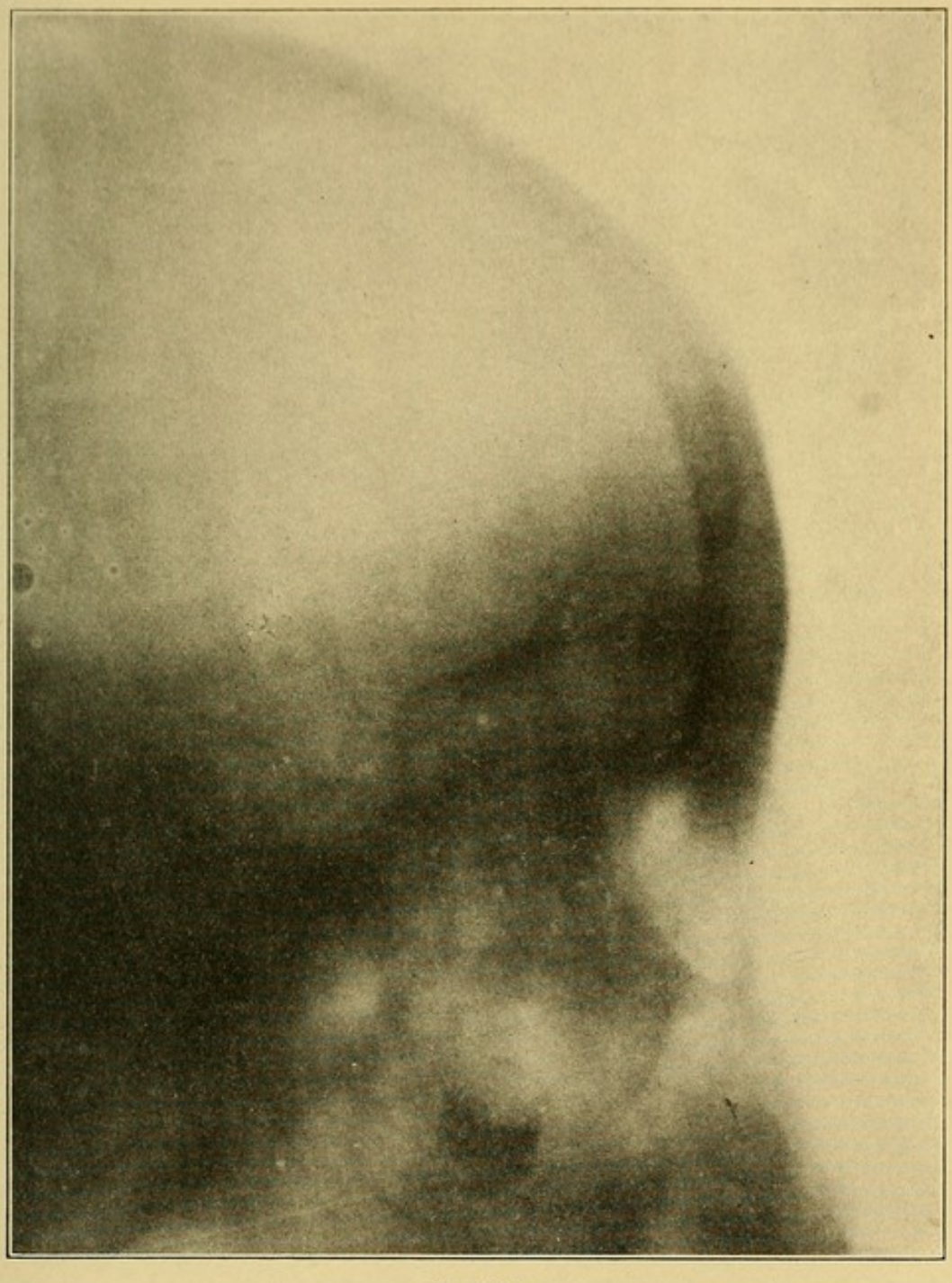

Fig. 362.

Bullet wound of orbit. Skiagram shows bullet impacted in upper jaw, below floor of orbit. (Edgar R. Williams.[3])

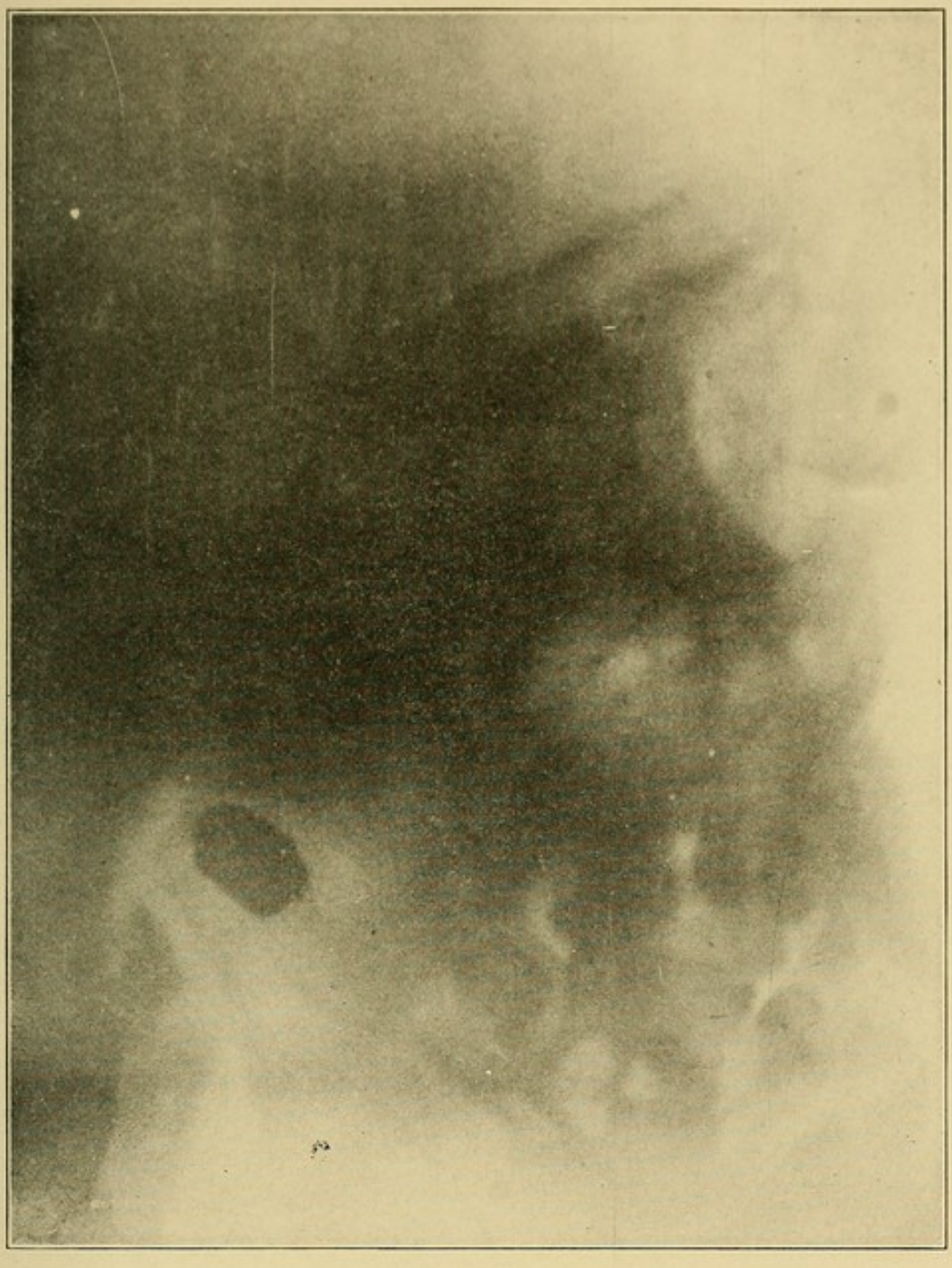

Fig. 363.

Bullet wound of orbit. Skiagram shows bullet impacted at angle of jaw. (Edgar R. Williams.[8])

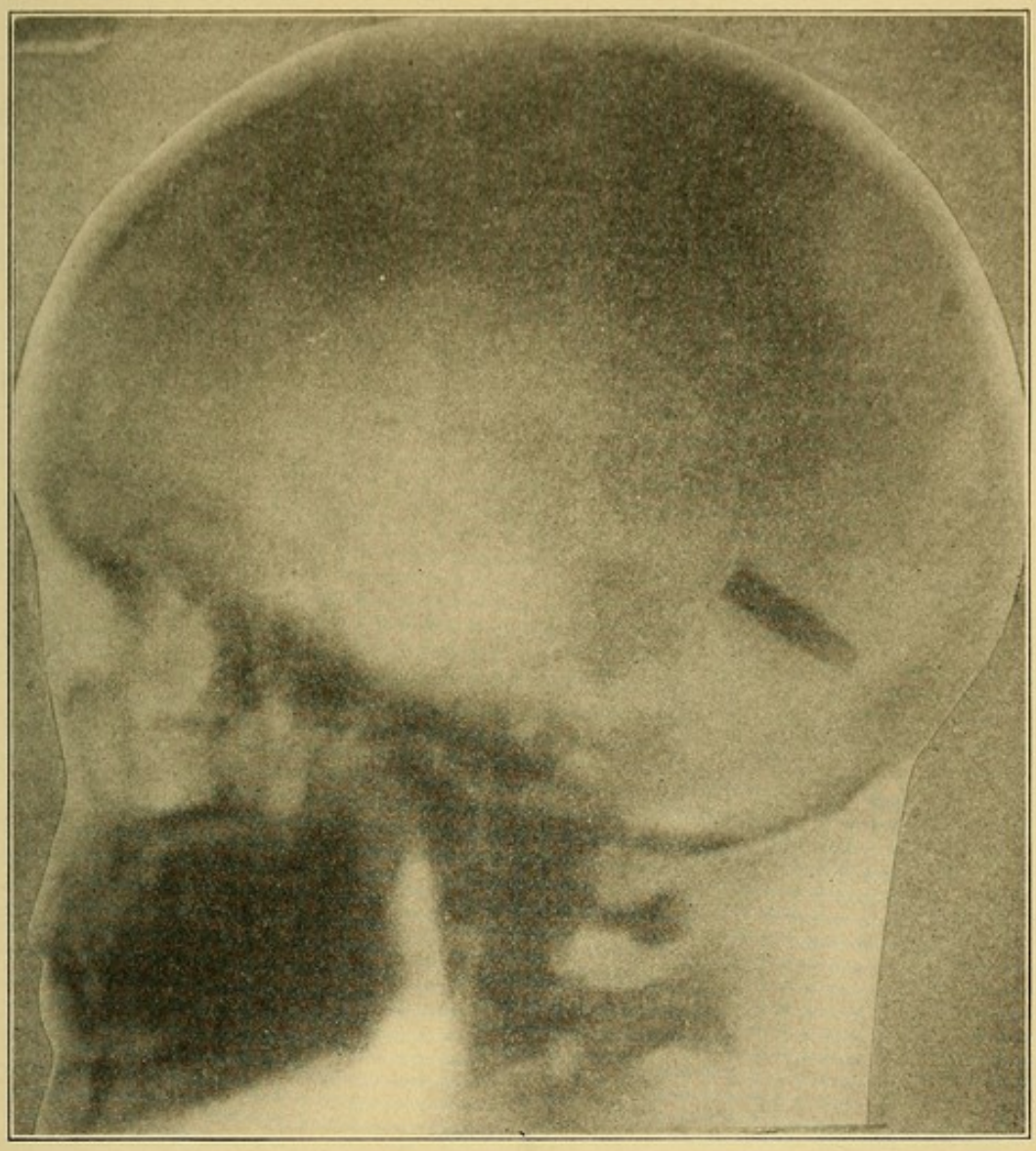

Fig. 364.

Bullet wound of orbit. Skiagram shows Mauser bullet impacted in posterior chamber of cranium. (Girard.[4])

The occurrence of osteoma and osteosarcoma after trauma to the bone is possible.

Noyes[1] reported the case of a seven year old girl who two weeks before was injured in the eye by a foot-ball. High grade of exophthalmus resulted. He enucleated the globe, but further operation was refused. The tumor rapidly grew and the child died. Post-mortem revealed myxosarcoma.

Elliot[2] reported a woman who five months before received a blow on the right eye. Blindness, exophthalmus, chemosis and swelling of the supraorbital and temporal veins. Exenteration of the orbit was done when examination of the tissue showed a fibrosarcoma originating in the cellular tissue of the orbit.

LITERATURE.

1. Noyes, *Trans. Amer. Ophth. Soc.*, 1879, p. 594.
2. Elliot, *Lancet*, Nov. 23, 1893.

CHAPTER XXVIII.

INJURIES INVOLVING THE ENTIRE EYEBALL.

A. Contusion without rupture—Literature. B. Traumatic exophthalmus—History—Etiology—Pathology—Mechanism—Objective symptoms—Subjective symptoms—Complications—Course—Diagnosis—Prognosis—Therapy—Ligation operation—Literature. C. Traumatic enophthalmus—Types—Tropho-neurotic — Cicatricial — Mechanical — Etiology — Mechanism — Symptoms — Differential diagnosis — Prognosis — Therapy — Literature. D. Luxation and evulsion—Definition—Etiology and Mechanism—Symptoms and Course—Pathology—Prognosis—Therapy—Injuries from firearms—Literature.

We treat here of injuries of the entire eyeball, comprising those from contusions and displacements.

A. CONTUSION WITHOUT RUPTURE.

The lesions caused by severe contusion of the eye are characteristic, viz., suffusions of blood under the skin of the lids and conjunctiva; perhaps also anterior displacement of the globe from hemorrhage into the orbital tissues; pericorneal injection; opacification of the cornea; wide and immobile pupil; blood in the anterior chamber and vitreous.

The patient complains of poor sight, pain, photophobia and lacrimation. The vision deteriorates and as a rule loss of accommodation with loss of intra-ocular tension occurs. Fuchs[1] gives the lesions that may occur from contusions without rupture, as follows: Parenchymatous opacity of the cornea; hyphema; dialysis of iris; aniridia; partial or total inversion; radial tears; pigmented dehiscences; mydriasis or myosis; cramp or paralysis of accommodation; bleeding; hemorrhagic detachment of chorioid or rupture; complete or partial rupture of the zonule, with changes in position of lens, then rupture of the capsule with cataract following; point-like pigment deposits in the capsule; vitreous bleeding and membrane formation; increase and decrease in the intra-ocular tension from the resultant glaucoma or degenerative changes; bleeding; detachment and rupture of retina; Berlin's edema; changes at the macula; bleeding into the nerve sheaths; opticus laceration with rupture and tearing out of the retina. All of these lesions will be found specifically described under appropriate titles in these pages.

Kunst[2] reports the case of a soldier who struck his right eye on

the stump of a reed. Small superficial wound of lower retro-tarsal fold. No perforation, exophthalmus or disturbance of motility. Three days later the light-blue iris commenced to turn green from hemorrhage into the ciliary body. Nineteen days after the accident the optic disc appeared pallid. Four months later central retinal vessels commenced to be atrophic and genuine white atrophy occurred, believed to be from contusion of the eyeball.

LITERATURE.

1. Fuchs, *Textbook*, Amer. (Duane) Ed., 1908, p. 712.
2. Kunst, *Centralbl. f. prak., Aug.*, June, 1910.

B. TRAUMATIC EXOPHTHALMUS.

Traumatic exophthalmus occurs from several forms of injury to the eyeball or its adnexa. Protrusion of the eye occurs from bleeding into the orbit and from movement forward of bone fragments, both of which are common in injury to the orbit and are dealt with under that chapter. Here we deal with pulsating exophthalmus, which in 71 per cent. of the cases is due to traumatism (Murray[1]).

History. The first technical description of this lesion was given by Travers[2] in 1809; the first anatomic examination was made by Barron[3] in 1835. Since then many cases have been reported by other authors.

Etiology. Traumatic pulsating exophthalmus is found most often (75 per cent.) in men between thirty and fifty years of age, i. e., in the most active working period of life when most commonly exposed to severe exertion and accidents. The so-called spontaneous form is more common in women. Peck[4] reports a case of unilateral exophthalmus in a new-born infant, spontaneous here by establishment of collateral circulation.

Pathology and Mechanism. This affection may be due to an arterio-venous aneurysm of the internal carotid and the sinus cavernosus, aneurysm of the ophthalmic artery, anginous, and other kinds of tumors, especially sarcoma and encephalocele, in all of which the exciting cause of the protrusion may be a traumatism, but in most cases it is due to a rupture of the internal carotid artery in the sinus cavernosus, by which the arterial stream passes directly into the veins, which fill with blood and push the eye outwards. The blood from the ophthalmic veins is not then carried back into the circulation properly on account of the pressure of the carotid in the sinus being more than in the veins, so the vein becomes practically an artery and forms a pulsating tumor above and to the inner side. From this condition of pressure all the clinical symptoms arise. In cases not due to rupture, such as aneurysm

of the carotid or ophthalmic arteries, the conditions are somewhat different and due to direct pressure. The lesion, in most cases, is situated in the cranium and not in the orbit. The superior thyroid artery plays an important part in the compensatory circulation after tying of the common carotid, when it is found dilated and strongly pulsating.

A. Maitland Ramsay[5] in his book on *Eye Injuries and their Treatment* dismisses the subjects of luxation and avulsion, exophthalmus and enophthalmus with a short anatomical description of the check ligaments: "Should these ligaments be ruptured the globe may be dislocated completely forwards (exophthalmus) or driven back into the socket (enophthalmus)."

MacCallum and Cornell[6] made an effort to determine experimentally the mechanism of exophthalmus by arranging an apparatus that would mark upon the smoked drum any movement of the eye, and then proceeding to alter the normal vascular and muscular conditions. It was shown that obstruction to the outflow of blood from the veins of the orbit produces exophthalmus at once, which is relieved by the establishment of collateral circulation. This process is completed, however, so slowly that in the meantime the orbital tissue, as well as the tissue of the face, becomes very edematous, thus adding to the exophthalmus. Furthermore entirely independent of any circulatory changes, there is an exophthalmus produced directly by the stimulation of the cervical sympathetic nerve. This protrusion is due to the peristaltic contraction of the orbital muscle tissue. From these experiments no conclusions could be drawn as to the mechanism of exophthalmus in Graves' disease, but the possibilities are more closely defined.

Objective Symptoms. Soon after, but usually not immediately upon, receipt of the traumatism, usually a few hours or days, sometimes weeks or months afterwards, the patient has a violent pain in the eye, the lids become reddened and swollen, the veins full, the upper lid especially swollen and immovable and cannot be raised, sometimes on account of its weight and sometimes on account of paralysis. The under lid becomes swollen, the conjunctiva chemotic, the eyeball protrudes strongly, usually outwards and downwards, and is generally immovable so that double images occur. An even pressure upon the globe may force it back into position, but it soon returns. Bending over increases the symptoms. Pulsation of the eyeball, synchronous with the radial pulse, is then apparent, and is heard, upon ausculation over the eyeball in the region of the orbit and even the neck, as an aneurysmal murmur which, as a rule, the patient himself hears.

In true rupture of the carotid in the sinus the bruit is increased in systole. On pressure on the common carotid in the neck the symptoms disappear. As a rule the condition appears only upon one side and then

later on the other. The conjunctiva of the eyeball becomes chemosed, its blood vessels enlarged, and the tension increases.

The lid aperture becomes enlarged, no longer fully protecting the cornea, and when the lids cannot be closed the cornea becomes dry and ulcerated. Foreign bodies may become impacted without notice, as in most cases the sensitiveness is lost. The anterior chamber becomes deeper, the iris discolored, the pupil moderately enlarged and immovable. The vitreous becomes turbid and papillitis develops. The veins enlarge, the arteries diminish in size. Capillary hyperemia follows later. Atrophy of the optic nerve occurs when the canalis opticus is injured. The sight depends upon the condition of the media and the implication of the optic nerve. It may be normal or greatly diminished, even where there is high degree of papillitis, as in choked disc, the sight may remain good. From the pressure behind, the eye becomes shorter and hyperopia develops. The accommodation is usually diminished. In old cases the sight is lost through disease of the uvea and increased ocular pressure proceeding to degenerative changes, or through ulceration of the cornea.

The Subjective symptoms at first are pains in the head and orbit, vertigo, feeling of pressure, blowing, ringing, and knocking sounds in the head. Patient is very uncomfortable generally, although in but few cases does the pressure extend sufficiently to the brain to cause changes therein.

Mechanism. The clinical picture fully explains the conditions of communication of the carotid with the sinus. The symptoms, as a rule, do not occur immediately upon receipt of the injury, but somewhat later. As but little blood at first passes from the carotid, the ophthalmic veins become more filled through the collateral circulation. Later inflammatory changes set in and then the arteries become atrophic. The blood now flows from the carotid through the cavernous sinus into the veins of the eye and lids, which accounts for the synchronous pulsation, and the picture of venous stasis of the retina. Through the impact of the arterial pressure on the veins come the noises which are apparent at the time of systole, produced by irregular pressure on the carotid artery in the sinus. Immovability of the eye outwards occurs from paralysis of the abducens nerve, which passes by the cavernous sinus. From this cause likewise, occurs paralysis of the oculomotor, trochlear, and the first twig of the trigeminus.

Complications. From the immovability of the eye and the wideness of the lid aperture the cornea may get dry and become the seat of infection and ulceration. The paralysis is caused from the first twig of the trigeminus. In many cases there are anomalies of hearing.

Course. In a few cases all symptoms cease or ultimately disappear after a year or two. Pincus[7] reports such a case. In one case

bleeding occurred with severe hemorrhages from the nose and orbit Death may likewise be due to the breaking of the bones of the skull, and involvement of the brain from bleeding or infection. Inflammation of the mediastinum may occur from thrombosis in the sinus. When such complications do not occur the pulsating exophthalmus may become less and sight better, but as a rule the subjective symptoms remain.

The Diagnosis is made from the cardinal symptoms, the proptosis, pulsation, objective and subjective noises, and vertigo. It should be differentiated from proptosis due to Graves' disease and tumors, cellulitis and orbital phlegmon, ethmoidal mucocele (Cirincione[8]), rachitic deformity of the skull (Cohen[9]), osteoporosis (Schwenck[10]). The differential diagnosis from rupture of the carotid or aneurysm of the ophthalmic arteries may be made, as in rupture of the carotid there is paralysis of the nerves, especially of the abducens, and in aneurysm of the ophthalmic artery the vision is much affected on account of the lesion being in the orbit.

Prognosis. The prognosis is not so bad. In 80 cases only 9 died; 11 per cent. The carotid walls seem to heal in about half the cases, either through natural means, through pressure, or the result of operation. Where pulsating ophthalmus depends upon fracture of the skull the prognosis is not good.

In Sattler's[13] series of 113 cases of ligature operations only 10 died, 3 from infection (all before 1880), 2 from hemorrhage, 1 from changes in the blood vessels, 1 from anemia and 1 from general debility.

In Keller's cases 1 died from hemorrhage and one from old age.

The Therapy is either by pressure upon the carotid, by the fingers or instruments, or by operative procedures. Only a few cases are relieved by compression, in most of which it has been of short duration. necessitating frequent repetition during the day. Rascalon[11] reviews the observations of Lefort.[12] Of seven cases not treated, two became better, two grew worse, and three died, one of the deaths occurring from hemorrhage after operation for a supposedly malignant tumor. Of thirty-seven cases treated by compression there was a complete cure in three cases, an incomplete cure in six, and sudden death in one case, while there was not any result in the remainder.

When compression does not lead to a cure the radical operation of tying the common carotid in the neck has cured a large number of cases, the general mortality being not over 10 per cent. Sattler and Sloman[13] show that the percentage of cures by this operation as about fifty, the mortality, according to their tables, being about 4 per cent. There are six cases in all recorded (Murray[1]) of tying of both common

carotids for this affection, all accomplished without mortality and in five with cures.

Hansell,[14] however, reports a case in which death resulted, one carotid being tied four weeks after the first. Jack and Verhoeff[15] report a death from tying one carotid. Murray[1] advises that the internal carotid be first tied, the external below the origin of the superior thyroid, to delay establishment of collateral circulation. This failing, then the ligature and resection of the branches of the superior ophthalmic vein at the inner angle of the orbit; and if this fails ligature of the opposite carotid should be instituted.

Golowin[16] says that in every case the operative treatment of pul-

Fig. 366.
Traumatic exophthalmus.

sating exophthalmus must be individualized according to the clinical form of the affection. In those cases where marked brain symptoms are present, as, for instance, vertigo, distressing subjective noises, etc., one must by all means ligate the common carotid. In those cases where the clinical symptoms are confined to either the orbit alone or to the orbit and face together, it is better to perform an orbital operation. It is probable that in some cases one would get a good result by ligating the ophthalmic vein, making the incision under the eyebrows. The ligation of the ophthalmic vein with a previous resection of the orbital wall (Kroenlein) will be found generally useful in those cases where relapses have occurred or where ligation of the carotid has failed. In such cases, indeed, this operation should be given the preference to ligating the

common carotid of the opposite side since this latter is apt to excite too great disturbance of the cerebral circulation. Resection of the orbital wall must be performed whenever the clinical picture of the pulsating exophthalmus suggests the possibility of an intraorbital growth.

I reported[17a] the case of a woman who, while rasing a window, two years before examination, heard something snap in the head; shortly afterwards the right eye protruded, the conjunctiva became congested, rushing sounds and headache followed; many physicians were consulted, one of whom proposed enucleation! V = 6/xxiv with + 1.50, 90° = 6/viii. V. F. large, small paracentral scotoma, 10° exotropia, 10° R. hypertropia at 6.00 M. Conjunctival and cilary veins and lids congested. Bruit to touch and stethoscope later than ventricular movement; vertigo,

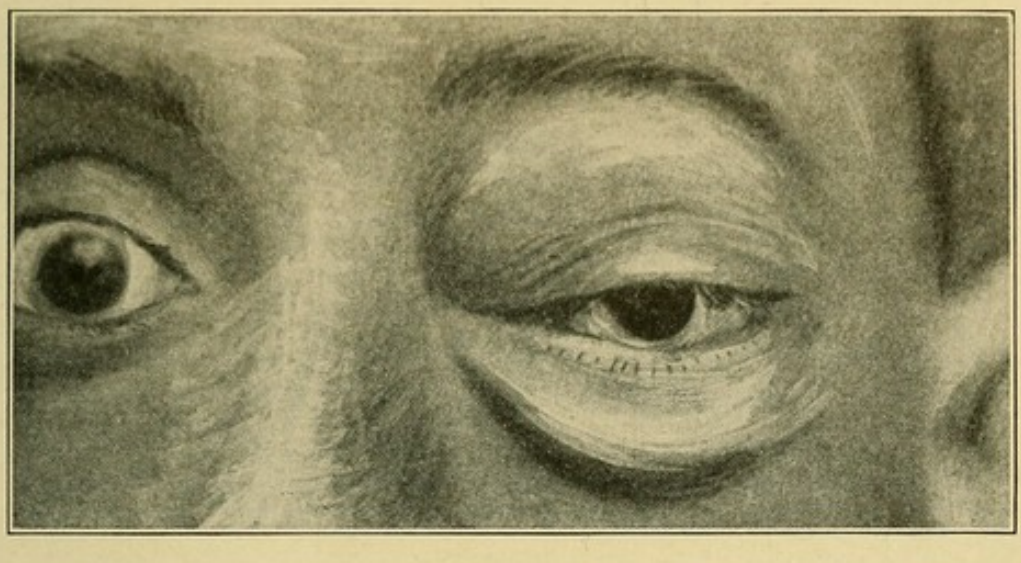

Fig. 367.
Traumatic pulsating exophthalmus. (F. Park Lewis.)

headache, and tinnitus symptoms increased on stooping and lying, diminished by pressure on closed lids and carotid, returned on removal of pressure. Ophthalmoscopic examination showed dilated vessels and congested disc. Tied common carotid in neck. From time of operation eye retracted, bruit stilled, noises and headache relieved, uninterrupted recovery. Cure six months later.

I cannot let pass the opportunity to remark that enucleation of such an eye would have been a grave mistake, as the varix behind the ball would have protruded in a mass, causing dangerous bleeding, as did occur in another case of which I have hearsay evidence, in which tying of the carotid was finally resorted to.

I have also reported[17b] a boy who while on a railway platform was struck by a mail bag thrown from a moving train; was knocked unconscious; bleeding from the nose and mouth followed. Six weeks later

he gradually developed protrusion of the right eye, vertigo, pain on stooping over, headache and bruit, subjective noises. Compression of external carotid reduced the symptoms, and bending over or lying down increased them. Operation of tying common carotid advised but refused. In this case, too, a popular oculist had advised enucleation!

Rollet[18] cured a case by malar orbitotomy, Kroenleins' operation, with tying of veins.

Bettremieux[19] reports a case with a souffle that disappeared on compression of the angular vein and quotes de Wecker and Jocqs, the former of whom explained the action that the pressure on the vein stopped the vibration from the neighboring arteries, and the latter that the souffle caused by compression of the ophthalmic artery by the vein ceased when the vein was partially emptied. B. explains the effect of this pressure simply by reduction of the orbital circulation.

F. Park Lewis[20] cured a case of aneurysm of the ophthalmic artery, causing pulsating exophthalmus, by ligation of the ophthalmic artery.

Sattler[21] reported a case in which ten years before a 17 year old girl received a blow over the upper orbital margin, where a pulsating, compressible tumor developed, and another non-pulsating tumor developed on the inner orbital margin. There was probably a small perforation of the internal carotid inside of the cavernous sinus; the aneurysmal dilatation involved the frontal and angular veins. The treatment consisted in the application of a loose ligature over the common carotid, the laying bare of the sac and ligating it twice; the aneurysmal tumor was then resected and the superior ophthalmic vein ligated. The result was very satisfactory.

Schwabach[22] with reference to Sattler's method of operating for pulsating exophthalmus, reports the following case: A boy, aged 12, was injured by a knitting needle, which pierced the medial portion of the left upper lid in a direction toward the nose. Half a year later the upper lid commenced to swell from exophthalmus, and the finger felt a variation in the depth of the orbit, so that the diagnosis, aneurysma arterio-venosum of the left internal carotid and the cavernous sinus, was made. After ligating the left common carotid the vibration subsided, but not the blowing murmur. Therefore, Schwabach entered the orbit by an incision at the supraorbital margin, extending from the medial to the lateral angle and through Tenon's capsule. Resection of 4 cm. of a very tortuous vein of varying lumen, after double ligation, stopped the blowing noise at once. The eyeball resumed its normal position and the wound healed per primam.

From this and Sattler's observations Schwabach recommends for the treatment of pulsating exophthalmus at first to resect the aneurys-

matic varix, and, if not sufficient, to ligate the carotid artery. Since the ectatic vessels almost always lie near the medial wall, they can be easier and less dangerously approached through the upper lid than by Kroenlein's resection of the lateral orbital wall.

Usher[23] reports three cases operated on by ligation on the same side as the lesion, of the common carotid, or else of the internal and external carotid simultaneously. "The suggestion of ligaturing the internal and external carotids instead of the common carotid was made to us by Prof. Reid. The advantages of this procedure are (1) prevention of collateral circulation by the branches of the opposite external carotid on the affected side, thence down to the bifurcation into the internal carotid; (2) diminution of the rush of blood between the branches of the ophthalmic artery and those with which they communicate outside the orbital cavity, e. g., the facial, infra-orbital, temporal, etc., on the side of the lesion."

Rollet[18] reports the case of a 42 year old man who, with a negative history, developed an increasing cephalalgia three years before his having been seen by the author. One month before the study of his case, right orbital pain with exophthalmus on the corresponding side developed. Examination showed that there was marked right exophthalmus with limitation of ocular motion, complete ptosis, optic neuritis, and vision reduced to one-third of normal. The findings of transillumination were negative. The left eye was healthy.

The cause of the exophthalmus, the author says, is obscure, but possibly it was, he thinks, the result of plastic inflammatory changes from toxines. The operation performed was preferred to that of Krönlein.

Hansell[14] read a paper giving the history of a case with left-sided pulsating exophthalmus three weeks after injury to the opposite side of the face; venous congestion of the lids and ball; partial immobility of the globe; diplopia and deep-seated pain. In spite of prolonged rest in bed and medicinal treatment, the symptoms slowly increased in severity. Ligation of the left common carotid was followed by amelioration of all symptoms and recession of the globe. Relapse in four weeks, attended with retinal hemorrhages. Ligation of the right common carotid, with edema of face and brain, convulsions, and death five days later.

F. Park Lewis[20] reports pulsating exophthalmus being due to a blow on the back of the head of a man who had been celebrating with a party of convivials. He was taken home in an unconscious condition and did not recover for several weeks, when the left eye was found to be bulging with sensation of being extruded from the head, continuing for a year and gradually increasing. Aneurysm of the ophthalmic artery was diagnosed and dissection made down to the tumor, the artery found to

have curved upon itself, having the diameter of a man's little finger. Several ligatures were applied and cure effected.

Sattler[13] reported 106 cases of exophthalmus, in most of which ligatures of the common carotid were performed.

LITERATURE.

1. Murray, *Ann. Surgery,* March, 1904.
2. Travers, ref Praun, l. c., p. 436.
3. Barron, ref. Praun, l. c., p. 436.
4. Peck, *Ann. Ophth.,* July, 1907.
5. A. Maitland Ramsay, *Eye Injuries and Their Treatment,* Glasgow, 1907, p. 6.
6. MacCallum and Cornell, *Boston Med. and Surg. Journ.,* June 2, 1904.
7. Pincus, *Zeitschr. f. Aug.,* July, 1907.
8. Cirincione, *La Clin. Oculistica,* Jan., 1907.
9. Cohen, *Klin. Monatsbl. f. Aug.* xliv, ii, 1906.
10. Schwenck, *Ann. Ophth.,* Apr., 1901.
11. Rascalon, *Recenil d'Ophtal.,* Oct., 1901.
12. Lefort, ref. Rascalon.
13. Sattler, *Graefe-Saemisch,* Vol. 6, p. 745.
14. Hansell, *Trans. Sec. on Ophth. A. M. A.,* 1904.
15. Jack and Verhoef, *Ophth. Record,* Oct., 1907.
16. Golowin, *Zeitschr. f. Aug.,* Sept., 1900.
17. Würdemann, (a) *Annals Ophth.,* Apr., 1903. (b) *Northwest Med.,* March 1909.
18. Rollet, *Ann. d'oculist,* Nov., 1901.
19. Bettremieux, *Ann. d'oculist,* Jan., 1909.
20. Lewis, F. Park, *Ophth. Record,* Feb., 1907.
21. Sattler, *Wien. Med. Woch.,* March 3, 1906.
22. Schwabach, *Klin. Mon. f. Aug.,* 1905, ii, p. 475.
23. Usher, *Ophth. Rev.,* Nov., 1904.

C. TRAUMATIC ENOPHTHALMUS.

The globe may be forced backwards as well as forwards. This condition is less often observed than protrusion. It is caused by a trauma followed by either absorption of the orbital fat, from cicatricial inflammatory processes of the orbital contents, from enlargements and defects of the orbital walls following mechanical or traumatic causes. Under enophthalmos Praun[1] distinguishes the tropho-neurotic, cicatricial, and mechanical forms.

Types. The tropho-neurotic type occurs after blows from large objects upon the margins of the orbit or the skull, which cause a sinking of the bulb into the orbit; also from tropho-neurotic absorption of the retro-bulbar orbital fat following lesions of the nerve trunks or the centers. Cicatricial enophthalmos is caused by periostitis of the orbit, causing contraction of the connective tissues and of the orbital fat. Through inflammatory processes in the orbit with cicatricial contraction, Tenon's capsule and the globe become more or less atrophic.

Mechanical enophthalmus is due to a fracture of the orbital

walls causing depression down and back. In tropho-neurotic enophthalmus the bulb loses its motility and the sight is lost.

Etiology. Most of these cases are caused by blows from large objects upon the orbital walls, usually above, sometimes on one side, which produce fracture of the bones. The cause of the condition is a rupture of Tenon's capsule, or the thickened bands of this, known as the check ligaments, and as this contains smooth muscular fibers which are innervated by the sympathetic, a peripheral or central lesion of this would cause relaxation of the smooth muscular fibers of the check ligaments and also atrophy and absorption of the orbital cellular tissue which permits the eye to sink backward according to the theory of Beer.

Mechanism. Nieden[2] observed, in a case where a large amount of earth had fallen on a man and compressed his head on the side, the enophthalmus was due to atrophy of the bolster of fat of the orbit following the long and heavy pressure.

Lederer[3] believes that the symptoms are due to direct injury of the orbital structures and hemorrhage, followed by cicatricial contraction, which is responsible for the depression of the eyeball. He is concurred in by LeBoux and Maklakoff[4] from a study of 52 cases in the literature.

Kilbourn[5] believes that the condition is a rupture of Tenon's capsule or the check ligament.

Luniewski[6] considers two possibilities: (1) the trauma may cause the enophthalmus in a mechanical manner, and that, either by occasioning an increase in the intraorbital space through fracture, or a decrease in same by retraction and contraction of the scar tissue; (2) the trauma may give rise to enophthalmus reflexly in an indirect manner. In such cases one may suppose it to be caused by minute hemorrhages into the nerve sheaths (particularly the sympathetic nerve) and slight compression of the nerve fibers. Maklakoff believes in the possibility of a rupture of the ophthalmic artery; this seems improbable to the author, or, at the most, may only be applicable to exceptional cases. Section of the cervical branch of the sympathetic nerve is known to lead to enophthalmus and slight ptosis. This last named symptom was observed in both cases and indicated an injury to the sympathetic nerve.

de Schweinitz[7] explains his case, by which there was an infraction of the orbital walls, by the lesion of the sympathetic.

Chas. Zimmermann[8] believes the explanation of traumatic enophthalmus without fracture of the orbital walls based on the assumption of paralysis of the sympathetic nerve to be very uncertain, as he experimented with cocain in his cases, finding reaction persistent. Gessner[9] explains these cases on the ground of periostitis of the orbit, and atrophy of the retro-bulbar fat. Lang[10] claims that in most

cases there is a fracture or depression of the orbital walls. Schrapinger,[11] in his three cases, which were accompanied by ptosis, enophthalmus, and hypotony, declared that there was a sympathetic paralysis. Beer[12] thinks that traumatic enophthalmus from the effects of blunt force is in some cases due to atrophy of the retro-bulbar fat and orbital tissues from lesions of the nerve centers and the sympathetic, which causes relaxation of the muscular fibers of the check ligaments and trophic changes.

The occurrence of either enophthalmus or exophthalmus in lesions of the sympathetic nerve, is due to relaxation of Müeller's muscles of the



Fig. 368.
Traumatic enophthalmus. (Geo. F. Keiper.)

orbit and the implication of the blood vessels of the orbital tissues, either being contracted or dilated.

Dunn[13] thinks enophthalmus is mainly due to loss of tonus in the check ligaments of Tenon's capsule, and the site of the sympathetic lesion is in the lenticular ganglion, and an expression of direct injury by contusion or compression. This might also explain the frequency of abducens paralysis with traumatic enophthalmus, as the sixth nerve obtains some of its supply from the sympathetic. The vascular changes in the skin of the face are absent in direct injury of the lenticular ganglion, and show a lesion of the cervical sympathetic.

Hesse,[14] in experiments upon rabbits by cutting of the sympathetic, produced enophthalmus. Denig[15] thought his case was due to irritation of the trigeminus. v. Michel[16] says that the occurrence of enophthal-

mus after blows is due to a lesion of the vaso-motor centers. Fick[17] declares the cause of enophthalmus to be due to a tearing or pressing upon the orbital connective tissues which go from Tenon's capsule to various points in the orbit, i. e., check ligaments.

Luniewski[6] reports two cases: In one the injury was inflicted by a thrust with the point of an umbrella. Enophthalmus developed immediately after the trauma, and recession of the bulb into the orbital cavity occurred some weeks later. He ascribes it to a retro-bulbar hemorrhage, with subsequent contraction of the scar tissue. In the second case, due to a horse shoe, owing to the presence of mydriasis and slight paralysis of accommodation, associated with the enophthalmus, the most probable conclusion seems the presumption of a compression, tearing or rupturing of the sympathetic and other nerves, particularly the oculomotor.

Lukens[18] states in an exhaustive article and study of 78 cases from the literature, with one of his own, when there is no gross depressed fracture, the most rational explanation is that of absorption of orbital fat, due to pressure, incident to the violent cellulitis, confined, as it is, within an inelastic bony cavity. Immediately upon subsidence of the intraorbital swelling, the loss of fatty cushion becomes manifest and the eye recedes.

"The relationship of the cellulitis to the traumatism varies. There is usually a wound of the lids or a fracture of the orbit, either direct or indirect. I am inclined to think a hematoma, as suggested by Lederer, frequently plays an important rôle—and I think this was true in my case. See also Würdemann's case, where the hematoma followed an operation for lipoma of the orbit and was followed later by enophthalmus."

Beer's tropho-neurosis theory is doubtless true in a few cases, but the maximum enophthalmus is usually manifest too soon to be accounted for by a trophic lesion.

Enophthalmus may occur indirectly as the result of a traumatism, through a nerve lesion. Mueller's orbital muscle and the unstriped muscle fibers in the check ligaments (a part of Tenon's capsule) are both controlled by the sympathetic. Schapringer[11] and Shoemaker[19] assume a palsy of the former.

Symptoms. The patient comes with the explanation that some time before, as a rule several weeks, the eye had become smaller than the other, following a contusion in the region of the eye. Ordinarily a scar may be observed, usually upon the eyebrow, and it is sometimes painful to pressure. The upper lid droops and is not so convex. The retro-tarsal depression is deeper and the lid opening is not so large as on the other side. Upon examination the eyeball is usually found to be of normal size, the space between the orbit and the bulb is enlarged. Praun[1]

says the appearance of the patient is as if he were wearing an artificial eye. As a rule the globe has full movement and vision. Binocular vision as a rule remains, except in cases where there is paralysis or fracture of the skull. The movement of the eyeball, especially upwards and downwards, seems to be greater. Tension of the eye and the fundus is usually normal. The subjective symptoms in a few cases were those of a foreign body in the eye, more often of anesthesia of the injured side of the nose, cheeks and lips, caused by rupture of the infra-orbital nerve and infraction of the floor of the orbit. In Denig's[15] case there was



Fig. 369.
Traumatic enophthalmus. (Swan Burnett.)

parasthesia in the region of the trigeminus and on the injured side of the face.

The differential diagnosis is to be made from neurotic atrophy of half of the face, which gives a picture similar to that of traumatic enophthalmus, phthisis bulbi or microphthalmus, for the eye is normal in size but has an abnormally deeper location.

The Prognosis is that further sinking of the eyeball will occur, in many cases with loss of sight. In others the visual acuity remains.

Therapy. There is no treatment except that galvanism or high frequency currents may be employed to stimulate nutrition.

Only a few cases have been seen in my[20] experience, one due to crushing of the head by a slamming door, one following a hematoma of

the orbit after an operation for removal of an orbital lipoma located temporally from the globe. First there occurred decided exophthalmus which resulted several months later in enophthalmus with loss of motility of the eye, ptosis and optic nerve atrophy with total loss of vision in that eye.

Burnett's[21] case was injured by a cow, probably by the horn, as there was a long, deep wound over the right eyebrow, the left eye flattened and the tear duct practically torn out, great swelling of the eyelids after the accident, followed by cicatricial contraction with excessive degree of enophthalmus. He believed the condition was due to plastic inflammation of the orbital contents, absorption of fat, fracture of floor of orbit and cicatricial contraction.

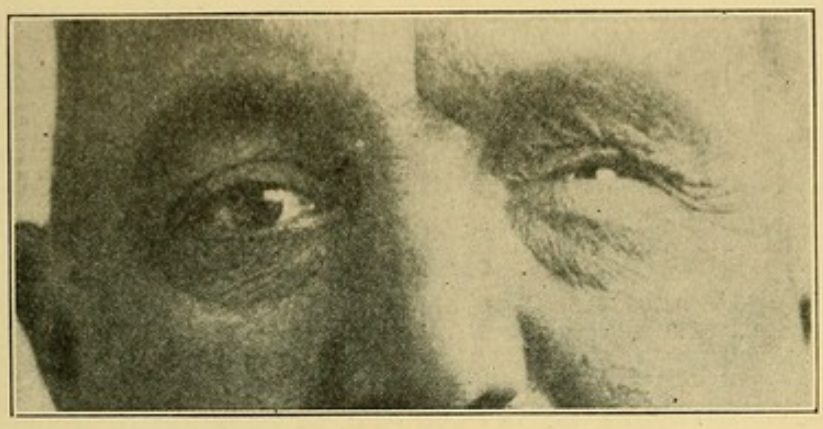

Fig. 370.
Traumatic enophthalmus. (Lukens.)

In Lukens' case[18] a man of 54 was in a drunken fight and his assailant stabbed him three times in the face with the small blade of a pocket knife, after which he was thrown down stairs. Marked exophthalmus, rupture of artery, fracture of orbit communicating with accessory sinus. Three months later enophthalmus followed.

Chas. Zimmerman[8] reported two cases, one which presented marked enophthalmus. The enophthalmus was caused by a fall on the right eye, by which the visor of the patient's cap was detached and injured the lids and the eyeball, and caused paralysis of the superior rectus muscle. The second came under his care July 19, 1892. The right eye of a carpenter, while looking up on a new building, in which he worked. was struck by mortar falling down about 90 feet. Examined soon afterwards and a cast of mortar found filling the conjunctival sac. The whole cornea was opaque and the conjunctiva discolored. Sloughing of the cornea and symplepharon necessitated enucleation in four weeks. In this case the enophthalmus was caused by the violent contusion of the eyeball and the contents of the orbit.

Kilbourn[5] reports the case of a man, age 53, being thrown from a sleigh, striking on left side of face, breaking glasses and lacerating upper lid, cuts not extending through lid. Ten days after accident enophthalmus and ptosis on left side were noticed. V = 6/iv in either eye with correction, orthophoria vertically, esophoria 2°.

LeBoux[4] describes the case of a 15 year old boy who was kicked in the face by a horse. The nose was broken and wounded at its base, with another wound of the left upper eyelid. The eye was not injured. For two weeks' time the eye was prominent and the lids were so swollen and discolored that they could not be opened. A few weeks later there was marked enophthalmus. The ocular motions, intraocular tension, and the eye-grounds were all normal. The pupil was moderately dilated and the iris was inactive to light stimuli and accommodation. Vision was reduced to one-eighth of normal, and there was a central scotoma for green.

Basetti[22] reports a patient who had transitory exophthalmus, which was produced especially when the head was lowered. Four years before the boy was struck by the fist of a companion. The blow produced a slight ecchymosis which soon disappeared. There was no diminution of vision afterward. Two years later the eye was more shrunken. A short time afterward, while bending toward the ground, the boy had the sensation as if the eye had passed out of the orbit. Each time he repeated the experiment he noticed the same phenomenon. When he ceased the movements, the eye took its natural position.

Bergmeister[23] describes a case of congenital enophthalmus, with asymmetry of the face. V = fingers at ¾ m., V. F. normal. Coloboma of chorioid and disc. Electric irritability of facial muscles normal. Ptosis from the retraction of the globe. Motility of eyeball very much impaired. Tenotomy of the four recti muscles did not change the enophthalmus, apparently owing to the same condition of the obliques as was observed during the operation on the recti. No muscular insertion could be felt with the squint hook, only hard, tendonous non-elastic bands. He assumes that congenital enophthalmus is caused by embryonic changes independent of the congenital anomalies. Two other cases are briefly reported.

LITERATURE.

1. Praun, *Die Verletzungen des Auges*, 1899.
2. Nieden, *Klin. Monatsbl. f. Aug.*, xix, p. 72.
3. Lederer, *Archiv. f. Ophth.*, liii, 2.
4. LeBoux, *Arch, d'opthal*, March, 1904.
5. Kilbourn, *Archiv. Ophth.*, July, 1902.
6. Luniewski, *Postep. okulist*, No. 2, 1903.
7. DeSchweinitz, *Trans. Am. Ophth. Soc.*, 1891.
8. Chas. Zimmerman, *Arch. Ophth.*, xxvi, No. 1, 1897.
9. Gessner, *Arch. f. Aug.*, Bd. xvii, p. 297.
10. Lang, *Trans. op. Soc.*, Vol. ix, p. 541.

11. Schrapringer, *New York Med. Journ.*, July, 1890.
12. Beer, *Arch. f. Aug.*, Bd. xxv, p. 315.
13. Dunn,
14. Heese, *Arch. f. des Physiol.*, lii, p. 535.
15. Denig, *Arch. f. Aug.*, xxvii, p. 276.
16. v. Michel, ref. Denig.
17. Fick and Denig,
18. Lukens, *Ophthalmology*, Oct., 1906.
19. Shoemaker, ref. Lukens.
20. Würdemann, *Ann. Ophth.*, Apr., 1903.
21. Burnett, Swan M., *Am. Journ. Ophth.*, July, 1899.
22. Basetti, *Ann. di ottal., Nos.* 5-6, 1906.
23. Bergmeister, *Arch. Ophth.*, Vol. 48.

D. LUXATION AND AVULSION OF THE EYEBALL.

Definition. Luxation of the globe is caused by a force acting from all sides, or behind, sufficient to cause it to protrude from the orbit between the lids. The optic nerve and muscles are thereby greatly stretched and, in severe cases, may be partly or completely torn across. The connections between the orbital cavity, however, remain sufficient to allow of the ball being retained within the orbit. If such cannot be done the case becomes one of avulsion, which varies from this degree of trauma to those in which the globe is completely torn out, in which the conjunctiva, Tenon's capsule, muscles, nerves, optic nerve, are completely severed, and usually some of the orbital fat protrudes. In avulsion the eyeball cannot be returned to place nor retained to heal therein.

Etiology and Mechanism. This injury occurs from large blunt objects, explosions, as close shots from fire-arms, and large bullet or shell wounds which come from one side and push the bulb forwards and outwards. In the case of projectiles which come behind the equator, the globe is pushed forwards, the lids open widely and the globe passes out between them. If the foreign body be so large that there is not room for it to pass between the globe and the apex of the orbit it usually causes the more common injury of rupture of the globe. In general the objects causing such injuries, besides those from firearms, are the ends of umbrellas, parasols and canes, shafts of vehicles, blunt hooks and keys and kicks from hob-nailed boots, horns and hoofs and bites of cattle, horses and large dogs. Then comes the digital removal of their own eyes by the insane; the horrible practice of gouging by robbers, as was largely practiced in previous centuries and of which occurrences are even now reported.

In some portions of the world quarrels among the lower classes may be accompanied by this occurrence. On account of its mechanism this merits space. The assault is completed by thrusting the thumb into the socket at the outer canthus and pressing outwards, the fulcrum being furnished by the fingers grasping the nose. I am surprised to find that

Leber,[1] Praun[2] and Fick[3] state that this form of assault was formerly common in America, especially in Virginia, as from my experience I had seen it confined to the Welsh, and my reading ascribes it mostly to the French. Praun[2] writes that it is known in Salzburg and the upper Bayern provinces of Germany and a few years ago was a favorite form of assault amongst the street ruffians of London. Fick[3] states that in Uganda slaves are subjected to this barbarity, one-eyedness being a livery of servitude.

The eyeball has been washed out of the orbit by a stream of water as from a fire engine like a foreign body from the ear. Stoewer[4] states that at the explosion of the Roburit powder factory, the suction drew the eyeballs out of the sockets of many persons. A further group is caused by injuries to the head from forceps delivery and from crushing of the head between large objects, as. in transportation and elevator accidents.

In exophthalmic goiter, pulsating exophthalmus, and retro-bulbar tumors the eyeball may be forced so far forwards that the lids slip over its convexity beyond the equator and luxatio bulbi results. A further group is afforded by childbirth, especially forceps injuries.

Objective and Subjective Symptoms and Course. In luxation the globe protrudes and cannot be replaced by muscular effort, the lids clasping the eye around the optic nerve and muscular cone well back of its middle diameter. During the luxation the sight is lost from the squeezing, which cuts off the circulation. At the time of the protrusion there is a sharp pain which may be so great as to cause unconsciousness. Upon reposition the pain diminishes and some or all of the sight returns. The bleeding is usually slight as the tearing may be confined to one or two muscles. If infection occurs orbital cellulitis and meningitis may result. If the eyeball be not replaced it becomes atrophic and later is found in the socket as a large, round stump. In the case of a complete avulsion there is no stump, the socket appearing later as if a bungling enucleation had taken place.

Pathology. Reis[5] histologically examined a case of evulsio nervi optici with luxation of the bulb. According to Salzman,[6] evulsio nervi optici consists of a tearing away of the optic nerve from the lamina cribrosa, without rupture or evulsion of the globe. A rupture of the optic nerve seldom occurs following orbital injuries. The author describes a case of a 37 year old man in whom the left eye, following a blow from a hoof, had been forced out of the orbit and hung by only its blood vessels and attachments (luxatio bulbi completa vel avulsio bulbi). The globe being cut off, was histologically examined. Hemorrhage into the vitreous, retinal detachment and laceration of the nerve in the region of the lamina cribrosa was found. The sheaths of the nerve

were not torn away from the sclera and formed a pouch 28 min. long containing vitreous and blood clots.

The Prognosis in both luxation and avulsion as regards life is good if there be no infection leading to orbital phlegmon and meningitis, which depends usually upon concomitant fractures of the bones of the orbit and cranium. In case of luxation, if the eye be immediately replaced the sight may return, but there will be no interference with its movement on account of tearing of the muscles. If the optic nerve or its sheaths be torn blindness results. Reposition or the completely avulsed globe has not resulted in its retention.

Therapy. Immediate reposition of the luxated globe by manual manipulations and by pulling the lids outwards, pressing the globe between them back into the orbit. If possible, immediately suturing of the divided muscles and torn tissues and pressure bandage. If the swelling is too great, ice and pressure bandaging until subsidence, then reparation of the torn tissues, portions of the orbital fat protruding through the wound are to be trimmed off by the scissors. In the case of complete avulsion general surgical measures are indicated.

In a Welsh colony in Wisconsin during an altercation one of the opponents varied the usual performance of pommelling his antagonist by inserting his thumb into the other man's socket and in the most approved manner gouging out the eyeball. There being no tearing of the lids the case healed under antiseptics after suturing, as in a badly performed enucleation such as I saw in one which had been done by a knife and scissors. Practically no movement of the stump and prothesis resulted, as most of the muscles had come away with the globe, being torn out by the roots.

In a Russian colony in Milwaukee during a fight one fellow had kicked the other in the face with his heavy, hob-nailed boot, the toe of which fractured the malar bone and squeezed the eyeball out, causing immediate luxation. Seen one week later there was extensive cellulitis of the orbit, temperature 105.5. Incision let out pus, eyeball immediately enucleated. Recovery and prothesis.

A boy had his head crushed in an elevator accident, both eyeballs protruded, one luxated. Death in a few hours.

A butcher while hanging up a side of beef slipped and the hook caught him in the orbit, tearing off the upper lid and practically enucleating the eyeball, the operation being completed by me some hours later.

Several cases of exophthalmic goiter, one of pulsating exophthalmus and one of orbital tumor have been seen by me in which luxatio bulbi occurred in each instance, on several occasions, the patients being able to return their own eyes to their sockets.

Such a case is also reported by Levin[7] where exophthalmus was

not due to trauma or above causes in which luxation occurred during sleep or on bending over, with blindness, paleness of disc, congestion of conjunctiva. V. at other times 6/vi and 6/viii, assumed to be stagnation in the veins of the orbit with looseness of the orbital fascia (check ligaments).

A woman in getting off a street car, passed behind it, not observing a light buggy propelled by a single horse. One of the shafts struck her, entering the orbit at the temporal side, not only rupturing the eye but causing almost complete avulsion. The accident happening close to my office I saw her within a few minutes, and on removal to a hospital completed the removal of the globe, having later to appear in the courts as a medical witness.

In a child bitten by a large dog the marks of its upper jaw were on the forehead while the teeth of the lower jaw had torn away the lower lid and, catching in the eyeball, had almost completely torn it away from its connections with the orbit. Enucleation and reposition of the torn lids and prothesis secured fair cosmetic results.

Williams[8] says scant reference is given to the condition of avulsio bulbi in literature. Little distinction is made between luxation and avulsion. The former may be non-traumatic, while the latter is always traumatic. The case of a man aged sixty years is reported who was driving home at dusk and, while passing a wagon with some gas pipe projecting out from it at an angle, an end of one of the pieces of pipe struck his eye, lacerating the lids and gouging the eyeball out on the cheek. The only attachment left between it and the orbit was the external rectus muscle.

Fage[9] describes luxation of the eyeball in a new-born infant. The delivery had been natural without the aid of instruments or force, and the dislocation was attributed to a contusion in the lower abdominal region, by the end of a shaft, that the mother had received the day before the birth of the child.

von Hippel[10] writes of a total dislocation of the eyeball from the kick of a horse. The patient did not lose consciousness, but walked directly after the accident, for three-quarters of an hour, to a clinic. One and one-half cm. from the lateral commissure of the lids of left eye a gaping vertical wound, 4 cm. long, showed the bone. The upper orbital margin was torn off and eleven sequestra were found in the orbit. It was ascertained by palpation that the optic nerve was not torn. The ecchymosed lids were retracted behind the immovable, stretched eyeball, the internal rectus was torn off from the sclera, the epithelium of the cornea below the center scraped off, anterior chamber normal, pupil enlarged without reaction, eye totally blind. The lids were drawn back and the eyeball replaced, the internal rectus sewed on.

Optic disc pale, its borders indistinct, surrounding retina whitish grey, opaque, veins almost normally filled, arteries very thin, blood current partially interrupted, circulation in retina totally abolished. Healing took place with opacity of the cornea.

The ophthalmoscopic changes were of great interest, as they explained the cause of the complete permanent blindness of the left eye. Within the first two weeks the retinal circulation seemed to be restored to a certain degree, but after the third week the veins grew thinner, then all vessels on the disc had disappeared except two twigs; at the periphery were a few filiform vessels. The optic disc was white, a little opaque, the intense gray discoloration of the retina had somewhat cleared up. This showed that blindness was due not to stretching of the optic nerve produced by the dislocation of the eyeball, but by a rupture of the central retinal artery, which gives the same ophthalmoscopic picture as embolism.

A weak, transient circulation takes place by capillary anastomoses between branches of the posterior ciliary arteries and the central artery at the entrance of the optic nerve into the sclera. The scanty blood supply not being sufficient for the nutrition of the retina, a rapid necrosis of the inner strata follows, shown by the early occurrence of the diffuse opacity. This disappears after a few weeks with the resorption of the destroyed retinal elements and the development of atrophy, and the normal red color of the fundus reappears, on which the thickened walls of the more or less completely empty retinal vessels are clearly visible as white lines.

Exactly the same condition prevailed in this case. A simultaneous laceration of the ciliary arteries could be excluded, on account of the absence of pigment in the retina. According to clinical experiences and the experiments of Wagenmann,[11] the separation of the ciliary arteries is followed by pathological changes of the chorioidal vessels, secondary affection of the pigment epithelium and immigration of pigment into the retina.

As to the mechanism of the injury von Hippel assumes that one point of the horse-shoe must, after breaking the upper orbital margin, have entered the orbit between roof and eyeball. By the pressure upon the contents of the orbit from the temporal side, the globe was suddenly crowded forward and turned toward the temple with such force that the tendon of the internal rectus was torn. It was remarkable that the eyeball itself was not hit, as may safely be inferred from the lack of rupture of the chorioid or hemorrhages into the vitreous.

Dzuatowski[12] describes a farmer who sustained an injury of the right eye through a blow from a cow's horn, causing marked protrusion of the bulb with inability to close the lids. The sclera, above

the cornea, was completely exposed. The superior and external recti and the superior oblique muscles were ruptured. The fundus of the eye could not be examined owing to the traumatic opacity of the cornea. The following operations were performed by Wicherkiewicz:[13] reposition of the bulb into the orbital cavity, suture of the superior oblique and temporary blepharorrhaphy. A corneal ulcer and hypopion developed subsequently. The ulcer healed rapidly and the hypopion was emptied. The patient was discharged with preservation and normal position of the eyeball, though marked limitation of the movements of the eye and anesthesia of the cornea and bulbar conjunctiva remained.

Lundsgaard[14] reports a case of avulsion of the eyeball by an insane person. Although no witness was present, all circumstances pointed to the assumption that one insane woman had, within two minutes, as they were not longer together, torn out the eyes of another insane woman. One eyeball was lying on the floor, the other was hanging by the internal rectus. The optic nerves were severed at about 4 and 5 mm. from the eyeballs.

De Beck[15] reports traumatic enucleation from a fire hose, the force of which is tremendous, requiring three or four men to hold the nozzle. It occasionally gets away from the operators and on this occasion struck a fireman full in the face at a distance of about three feet, knocking him unconscious twenty feet away. No trace of eyeball was found, the current being driven into the corner of the eye had neatly torn it out. Speedy and complete recovery followed.

Guy L. Noyes[16] reports a case of self-enucleation of one eye and severe contusion of the other, resulting in total blindness, in an insane woman who said she did it in accordance with scripture: "If thine eye offend thee, pluck it out,"—recovery with blindness.

MacKinlay[17] described an insane butcher who said to his attendant "Watch me gouge out my eye," and quick as thought, with his thumb, he did so, throwing his eye against the wall opposite. Had he not been forcibly prevented he would have proceeded in the same manner with the other eye. Full recovery.

McHardy's[18] case gouged out one eye and died of suppurative meningitis in four days.

Fulton[19] had a drunkard who almost completed double self-enucleation, the eyeball being held in only by the conjunctiva.

In Young's[20] case the patient grew religiously maniacal five weeks after injury and recovery from successful operation following removal of steel from eye with giant magnet and, as in Noyes' case, according to the scripture injunction, was about to pluck out his eye but was forcibly prevented. He died from acute mania in six days.

Injuries from firearms during war, attempted suicide or murder

and hunting accidents causing avulsion of the eyeball, occur from close range and are usually fatal. I have seen several such corpses in which the eye, with the side of the face, was completely blown away by the force of the explosion. Praun[2] says that in a few cases a projectile may come from such a direction and strike the side of the head in such a way as, on its exit or from tissue or bone being carried along, the eyeball may likewise be carried along and out of the orbit.

LITERATURE.

1. Leber, ref. Fick.
2. Praun, l. c., p. 444.
3. Fick, *Dis. of Eye and Ophthalmoscopy*, Eng. Ed., 1896, p. 459.
4. Stoewer, *Klin. Mon. f. Aug.*, March-April, 1907.
5. Reis, *Postep. okulist.*, No. 1, 1908.
6. Salzman, ref. Reis.
7. Levin, *Berl. Klin. Woch.*, No. 35, 1905.
8. Carl Williams, *Ann. Ophth.*, July, 1909.
9. Fage, *Arch. d'ophth.*, Aug., 1907.
10. von Hippel, *Deut. Med. Woch.*, No. 40, 1907.
11. Wagenmann, ref. von Hippel.
12. Dzuatowski, *Postep. okulist.*, 1902, No. 9.
13. Wickerkiewicz.
14. Lundsgaard, *Klin. Mon. f. Aug.*, xlvii, 1, 1909.
15. DeBeck, *Cincinnati Lancet-Clinic*, Apr. 28, 1900.
16. Guy L. Noyes, *Ophth. Record*, March, 1907.
17. MacKinlay, *Trans. Oph. Soc. U. K.*, Vol. vii.
18. McHardy, *Trans. Oph. Soc. U. K.*, Vol. vi.
19. Fulton, *Am. Journ. Ophth.*, Vol. iv, 1887.
20. H. B. Young, *Ophth. Record*, Sept., 1906.
21. Praun, l. c., p. 446.

CHAPTER XXIX.

TRAUMATIC DISTURBANCES OF THE MOTILITY OF THE EYE.

Primary injuries—Secondary disease. I. Muscles. (a) Wounds—Etiology—Symptoms—Diagnosis—Prognosis—Therapy. (b) Injuries from blunt objects—Etiology. (c) Secondary disease—Literature. II. Injuries and paralysis of the motor nerves. (a) Paralysis due to lesion in orbit. (b) Base of brain. (c) Cerebral centers—Etiology—Symptoms and course—Diagnosis—Differential diagnosis—Prognosis—Therapy. Cases illustrating injury and paralysis of ocular nerves. 1. Abducens. (a) Orbital. (b) Basal. (c) Cerebral. 2. Oculomotor. (a) Orbital. (b) Basal. (c) Central. 3. Trigeminus. 4. Facialis.

The traumatic disturbances of the motility of the eye are due to injury to the muscles, nerves or motor centers, and to amblyopia from ocular changes.

The muscles may be primarily injured by stabs and shots, or torn, through the effect of blunt force, which may likewise cause contusion of the muscle elements, bleeding into the muscles, bleeding into the orbit, or rupture and laceration from bone fragments in fractures of the orbital walls.

The ocular muscles may become secondarily diseased through inflammatory or degenerative changes in the orbit.

Injuries to the nerves may occur in the orbit from the same character of causes as those affecting the muscles, so that commonly they are involved together in the bony canals at the apex of the orbit, as from fractures where they are usually involved with the optic nerve, at the base of the brain along their course to the nerve centers where the lesion may be nuclear, fascicular or cortical; or combined in several localities together with injury to the brain substance and the meninges, as in fractures of the skull.

Wendell Reber[1] says that obstetric injuries account for many cases of interrupted binocular vision from retinal hemorrhages.

Gaylord C. Hall[2] reports four cases that came with a history of strabismus immediately following injury, in which the relationship appeared intimate, in all of which the strabismus seemed to have been caused by the resultant amblyopia.

A boy of 19 years, who at the age of six was hit on the head by some lumber. Since then left eye has been turned in. Vision fingers at one

meter. Eye deviates so far inward that only a portion of the cornea is visible. Action of external rectus not sufficient to straighten the eye with other closed, though attempts were made.

Right eye vision 6/vi, no trouble. Operation tenotomy of left internal rectus, after which external could turn eye outward without difficulty, though when at rest left eye still deviated inward. External rectus was advanced and eye slightly over-corrected. Cosmetic result good.

I. INJURIES TO THE OCULAR MUSCLES.

A. Wounds.

Etiology. The entrance of pointed objects, shot and foreign bodies into the orbit, as noted before, is somewhat common. In many cases it is impossible to determine whether the paralysis is due to direct injury to the muscle or to its supplying nerve, or whether it be from hemorrhage or laceration from bone fragments. The levator of the lid is most often cut through, causing ptosis. Commonly several muscles are injured at the same time, especially where a luxation of the globe has been produced where the tendons are dragged out of the body of the muscle.

Symptoms. The wound of entrance in the conjunctiva or lids, and characteristics of a penetrating wound of the orbit, are to be observed. The subconjunctival ecchymosis, chemosis and swelling of the lids being usually prominent. In isolated ruptures or wounds there is loss of motion towards the injured side and the eye is pulled the other way on account of the action of the antagonist.

Double vision is complained of or readily elicited. If several muscles be injured the eye protrudes from loss of their tension and from the hematoma in Tenon's capsule and the orbit, and the ocular movements in all directions are diminished thereby. The motility of the globe is permanently damaged from solution of continuity of the muscles or nerves, but may return if the loss of motion be due to hemorrhage. As a rule the globe remains intact, but it may likewise have been opened by the injury.

The Diagnosis depends upon the anamnesis and the kind of injury. Wounds over the insertion or belly of the muscles are characteristic. If over the tendon, shreds of tendon tissue may protrude or the lacerated tendon be seen in the depths of the wound. Partial laceration is difficult to diagnose on account of the bleeding and the contused nature of the wound.

The Prognosis of isolated injury to muscle or tendon is good if an operation be done to correct the accidental tenotomy. Where much

scar tissue forms, especially after the retention of foreign bodies, the prognosis is unfavorable as to recovery of function.

The Therapy is surgical. The ends of the divided muscle or tendon should be brought together by two or three interrupted sutures, or if the tendon has been divided, the Worth or other advancement operation may be made, especially where the injury has happened some time before. It is worthy of remark that a partial division of the tendon or



Fig. 371.

Penetrating wound Tenon's capsule, with laceration left internal rectus (meat hook). Patient looking forward; L. external strabismus.

muscle may not produce permanent disturbance or motility, for it heals rapidly. In some cases it may be necessary to perform a graduated tenotomy on the antagonist in order to secure muscle equilibrium.

In a young man who slipped while hanging up a side of beef and was injured by a butcher's meat-hook, the point of hook penetrating the orbit at the inner canthus and lacerating the belly of the internal rectus, paralytic external strabismus was produced. This I corrected by finding the divided ends and suturing them together.

Weeks[2] reported paralysis of external rectus lasting six weeks, from a fencing foil striking just below the margin of the lid.

In another case a meat-hook caught a man in the orbit in falling, tearing the internal rectus across without injuring the eyeball, but lacerating the lid somewhat. There was marked divergence with diplopia, but by catching up the tissue of Tenon's capsule, together with the torn muscle, and suturing it to the eyeball the diplopia was corrected. This was very similar to my own case.



Fig. 372.

Penetrating wound Tenon's capsule, with laceration left internal rectus (meat hook). (b) Head turned to left; parallelism.

Berger[4] reports two cases of traumatic paralysis of the internal rectus, one of the inferior rectus, one of the superior oblique, and two of the external rectus, all caused by more or less pointed, wedge-shaped objects, entering between eyeball and orbital wall, with contusion of the former.

As to the prognosis, Berger says that complete separations of the muscles entail lasting paralysis with secondary contracture of the

antagonists. Partial lacerations may, like partial resections, heal after some time with perfect restoration of function. Berger recommends to postpone the suture until the ecchymosis is absorbed and a complete division of the muscle is ascertained. The absorption in his case was materially accelerated by internal use of iodid of potassium.

Fig. 373.
Traumatic enophthalmus. Paralysis external rectus.

LITERATURE.

1. Wendell Reber, *Trans. Sec. Ophth. A. M. A.*, 1910.
2. Gaylord C. Hall, *Ophthalmology*, Oct., 1910.
3. Weeks, *Trans. Sec. Ophth. A. M. A.*, 1903, p. 218.
4. Berger, *Klin. Mon. f. Aug.*, 1905, 11, p. 480.

B. Injuries to the ocular muscles from blunt objects.

Etiology. The ocular muscles may be directly contused and rendered functionless by blows on the eye from blunt objects, especially the levator of the lid, whose exposed tendon is most often bruised. Such isolated injuries to the levator come from blows from thrown stones, shots and other blows upon the eyebrow without specially showing swelling or the production of scar tissue.

The muscles may be indirectly affected by the pressure of a hematoma, or fragments of bone in the orbit following a blow from a blunt object, or torn out of their insertions, or in two, by luxation and avulsion of the globe. Fire-arm injuries may both directly and indirectly contuse or rupture the muscles.

Hirschberg[1] saw a case of isolated paralysis of the inferior oblique following a shot wound of the temple.

The Sanitary Commission of the German army[2] reported three cases of isolated paralysis of the levator from bruising or laceration of the muscle.

Greven[3] reported left-sided trochlearis paralysis where the homulus of the trochlearis was torn away.

Gaylord C. Hall[4] gives the case of a boy of four years, who was

hit in the left eye with a stick when two years of age. Doesn't see so well out of left eye. Has convergent strabismus, left eye turning in about 20°. No scars on cornea. Ordered atropin ½ per cent in both eyes for two weeks. Returned, convergence improved, eyes nearly straight. Retinoscope showed +4.00 in both eyes; neutralizes shadow. Ordered +2.50 constant. Atropin in good eye and shield over good eye one hour each morning and evening. January 15, '10, wearing glasses without trouble. Axis straight when glasses are worn, but squint returns on removing them.

Chas. Zimmerman[5] reported a case of traumatic paresis of left inferior rectus combined with traumatic insufficiency of left external rectus in a healthy sailor, aged 36, who never had any eye disease; received a blow on his left eye from a fist coming from his left. His lids swelled so that he could not open his eye, but he ascertained that when he pulled them open with his fingers he could see. He complained of diplopia when looking straight and in the lower portion of the field of fixation. Especially in walking on the street he was greatly annoyed by seeing objects double. If he wished to avoid double vision in a straightforward direction he bent his head forward, turned it to the left and looked to the right and a little upwards.

C. Secondary disease of the ocular muscles following injury.

Following hemorrhage and laceration of the eye muscles and the capsule of Tenon these structures, as well as the orbital cellular tissue, fat and periosteum, may become inflamed and end in abnormal adhesions and cicatricial contraction of tissue whereby the movements of the eyeball may be impeded. Such conditions are apt to follow orbital phlegmon, periostitis and other inflammatory conditions, especially in the case of retarded foreign bodies in the orbit. Cicatricial enophthalmus with atrophy of the globe results.

LITERATURE.

1. Hirschberg, *Berl. Klin. Woch.*, 38. 1891.
2. Sanitary Commission German Army, ref. Praun, p. 480.
3. Greven, *Inaug. Dissert. Bonn.*, 1875.
4. Gaylord, C. Hall, *Ophthalmology*, Oct., 1910.
5. Chas. Zimmerman, *Ann. Ophth. and Otol.*, Apr., 1894.

II. INJURIES AND PARALYSIS OF THE MOTOR NERVES OF THE OCULAR MUSCLES.

A. Paralysis due to lesion in the orbit.

Isolated laceration of the nerves of the ocular muscles from penetrating injuries must necessarily be of rare occurrence. As a rule such injury is combined with damage to other nerves and the ocular muscles, as well as other structures of the orbit, and combined with blood extra-

vasation or fractured bones, and so the actual lesion is difficult to differentiate. This is especially the case in injuries from foreign bodies, where the nerves, as well as the muscles and broken orbital walls, lead to compression of the nerves of the orbit, affecting even the ciliary ganglion.

The ocular nerves are often injured altogether, as they lie so close together at their entrance into the orbit.

Wounds affecting the opticus frequently affect those nerves coming out of the superior orbital fissure; i. e., the oculomotor, abducens and trochlearis, as well as the first twig of the trigeminus. Even so may a hematoma of the apex of the orbit cause paralysis of these nerves without appreciable exophthalmus.

B. Injury and paralysis due to injuries at the base of the brain.

These nerves are seldom directly injured through shots and stabs, although according to Leber[1] they are often injured at the moment of the fracture of the skull at the supra-orbital fissure, either through laceration by fragments of bone, pressure from hemorrhage or subsequent inflammation. Actual laceration, according to Bergmann,[2] seldom occurs, while stretching and compressing from bone fragments, and bleeding, is the usual effect of such an injury. If the compression or contusion is slight the resultant paralysis soon spontaneously disappears; if the nerve be divided the injury is permanent. If the paralysis appears several days after the accident the cause is probably pressure from hemorrhage, or due to secondary inflammatory changes. The abducens is most often affected, next the oculo-motor, then the trochlearis, facialis and trigminus. In many cases of fracture of the base the acusticus, abducens and oculomotor are implicated. This combination of paralysis is pathognomonic in fracture of the base of the skull.

The localization is often difficult and can be explained only by the combination of lesions and symptoms.

The Prognosis is good as regards recovery of function, as most cases are due to compression from hemorrhage. When the nerve is known to have been divided the prognosis is unfavorable, as the paralysis is permanent.

The Therapy is symptomatic, depending upon the main and graver injury.

C. Injuries and paralysis of the cerebral centers.

Etiology. These lesions may occur either through direct wounds, through pressure from bleeding, through laceration of the brain, as in stabs and fire-arm injuries, or secondarily through hemorrhage or inflammation, and the atrophic processes following the cerebral injury. As a rule they are accompaniments of severe injuries to the skull.

Simon[3] reported the causes in seven cases as a fall or blow on the occiput, twice a blow from a horse, once from hoof injury, once from a bombshell, causing contusion of the face and temple, and a blow from a heavy post.

The abducens and oculomotor nerve nuclei are most often injured, next the trochlearis, and very seldom isolated parts of the oculomotor. In most cases the facial and acousticus are affected from central causes, most of which are due to hemorrhage or softening at the base. Association changes in the other nuclei occur so that the ocular movements may be lessened in all directions. Nystagmus is often observed, either primarily from brain pressure or secondarily following changes in the brain from inflammation and softening. Lesions along the course of the nerve may be surmised from the character of the injury, due directly to the wounding instrument, bone fragments or blood clot, or to secondary changes.

Symptoms and Course. There is paralysis of a muscle or muscle group, according to the nerve center implicated. Incomplete paralysis usually disappears after some months, as it is generally due to pressure from hemorrhage. In destruction of the centers or resulting degenerative processes the paralysis persists and ultimately involves other centers.

The Differential Diagnosis is very difficult and often impossible. The site of the lesion, whether at the base of the brain or in the centers may in some instances be determined by the character of the injury and the course. Orbital lesions are to be excluded as a rule when exophthalmus occurs, and here we may find a wound or fracture of the orbital walls. When these signs fail a cerebral site must be considered.

In basal paralysis from injury the symptoms of fracture of the base of the skull obtain, as a rule several of the nerve trunks being injured while in nuclear paralysis special nerves are affected. In basal cases the paralysis exists on the same side as the injury, while in nuclear paralysis it may be crossed. It is not definitely ascertained that the trochlearis or the abducens cross over, but the nerve fibers of the oculomotor do. Secondary effects, as ophthalmoplegia externa or interna, bespeak a nuclear lesion, as well as does the complication of a diabetes following the accident, as this points to the implication of the fourth ventricle. When the paralysis affects the same muscles on each side, or when the paralysis affects nerves having the same or a neighboring nucleus, a hemorrhage or softening at the nuclei of the nerves may be diagnosed.

The Prognosis is favorable, as about half the cases recover function.

The Therapy is symptomatic.

Cases illustrating injury and paralysis of the ocular nerves.

1. The abducens.

(a) Orbital. Berlin[4] reports from the literature a case of injury from shot pellet. Schiess[5] one in connection with the oculomotor nerve.

(b) Basal. The abducens paralysis is most common. In 168 basal fractures Battle[6] found 5 cases; Purtscher[7] found 46 intracranial cases in the literature, of which 30 were on one side, 13 bilateral and 3 doubtful. In 36 cases the paralysis was direct from the trauma, in 8 secondary. In 17 these were basal, 25 cerebral and 4 times not defined. The nerve itself is seldom discided. Eulenberg[8] had a case of stab wound of the posterior, lower part of the right temple, which produced complete paralysis of the right abducens.

Fractures of the base of the skull may not show all the common symptoms, but may be followed by isolated paralysis of the abducens. Such is common in delayed and forceps deliveries and is the cause of some of the so-called congenital cases.

Friedenwald[7] collected the literature of cases from fracture of the skull to date and reported one of injury from the cow catcher of a locomotive which produced paralysis of both abducens, the sensory portion of the trigeminus and rupture of the membrana tympani. Transverse fissure of the base was diagnosed. The left side recovered in five weeks and the right a little later.

Hansell[8] reported a case of double external rectus paralysis, traumatic in origin. A laborer of 31 years was struck on the head by a 50-pound block of ice. Unconscious for 14 hours. Pain for next three weeks at site of injury (occipito-parietal). He then began complaining of diplopia. Unable to travel alone. Each internal rectus was almost completely paralyzed. No other muscles paralyzed. The lesion was located at the base of the brain at the superficial origin, or in the course of both sixth nerves.

Gontermann[9] on the eighth day after lumbar injection of 0.0625 tropococain (without adrenalin) between the first and second lumbar vertebræ, noticed the left abducens become paretic; also the right one slightly. Recovery occurred after six weeks. The late occurrence of the paralysis spoke for a toxic affection of the nuclei, not through direct local action, but by way of absorption, similar to nephritis after lumbar anesthesia, and other palsies.

(c) Cerebral. Purtscher reported 12 cases with nuclear seat and 9 cases in which it was doubtful whether basal or nuclear, one case being fascicular and 3 cortical.

Mauthner[12] describes a man who was hit by the back of a carriage and fell upon the occiput, but got up without immediate further

injury. Soon afterwards double vision occurred. Paralysis of both abducens was found. He diagnosed bleeding at the middle floor of the fourth ventricle, as the height of the abducens nuclei.

2. Injury and paralysis of the oculomotor.

(a) Orbital. These injuries are either from orbital wounds or hemorrhage into the orbit.

Silex[13] reported the case of a woman who penetrated the orbit in the region of the right lacrimal bone by the blunt end of an iron while stooping over. Great pain and slight bleeding in the wound; the eyelids could not be opened and the sight was lost; several days later some suggulation in lower lid; the eye immovable, the pupil dilated, no light sensation. The ophthalmoscope revealed nothing abnormal. The ocular motion returned during the next week, but the papilla became greenish-gray. Silex thinks there was a fracture of the optic canal with laceration of the opticus, bleeding in the posterior part of the orbit with compression of the ocular muscle nerves.

Rhein and Risley[14] report a woman, age 50, who was struck on the left side of the face, left arm and chest by a hawser snapping under great strain. Diagnosis was made of fracture of the nasal bones. Four weeks after when Risley first saw her there was slight ptosis of the left eye-lid, restriction of the outward movement of the eyeball, partial loss of power of muscles on the left side of the face except the orbicularis oris and forehead muscles. The external rectus was paralyzed, the other extrinsic muscles unimpaired. When a thin superficial opacity of the cornea of the left eye cleared, vision improved to 5/vi; in the right it was 5/v. Tear duct was closed with an apparently bony obstruction. No change in fields as to form and color. Six months later her condition was much aggravated, though ptosis improved. There were areas of numbness and hyperesthesia present, reflexes normal. Risley now found paralysis of the external rectus, superior rectus, and superior oblique, complete left hemianopsia, the macula included in the scotoma, central fixation lost in the left eye, left nerve head paler than the right, Wernicke's hemiopic pupillary reaction absent, the last symptom being the only one that could not be accounted for by the injury to the walls of the orbit and periorbital region, and pointed strongly to a lesion far back. A fracture of the floor of the orbit involving the lesser and greater wings of the sphenoid on a plane with the sphenoidal fissure and the foramen rotunda and ovale, would explain the injury to the third and fourth nerves—shown by the paralysis of the inferior and superior oblique and superior rectus—and the frontal division of the fifth; the sixth nerve—shown by paralysis of the external rectus—and an injury to the second and third divisions of the fifth. The disturbance of the fifth

was shown by the numbness and hyperesthesia. If degeneration is indicated by the paleness of the optic nerve, the second nerve was diseased. Drooping of the mouth showed implication of the facial nerve.

(b) Basal. Basal oculomotorius paralysis is rare, occurring mainly from forceps delivery, pulsating exophthalmus or fracture of the base, the case of Leber[1] being the latter.

A boy fell from a platform onto his head; bleeding from both ears, nose, and mouth, and was unconscious. The next day both upper lids sunken and could not be opened; on the next the left could be partially opened, and after a few days the ptosis disappeared on the left side, but remained on the right. The patient complained of pain and tenderness in the occiput. Five weeks later full ptosis right side. Strabismus divergens from total paralysis of oculomotor, pupil immovable and medium dilated.

(c) Cerebral. A number of cases of nuclear paralysis with ophthalmoplegia externa of various grades have been reported.

Mauthner's[12] case is typical. A 65 year old man slipped on the street and fell, striking the occiput. No headache, but vertigo and double vision. Right eye slight ptosis and all the third nerve muscles paretic, the internus especially. Pupils reacted to light and accommodation. Diagnosis: nuclear paralysis following traumatic hemorrhage in region of the oculomotor center.

3. Injury and paralysis of the trochlearis.

(a) Orbital. No orbital injuries have been reported.

(b) Basal. These cases are very rare.

Bergmann's[2] case was in a domestic who fell from the third floor of a house to the pavement below. Left upper and forearm and left thigh-bone broken; a triangular flap wound of the left eyebrow, reaching to the nose. Unconscious; all symptoms of concussion of brain and severe bleeding from nose. Fourteen days later recovered consciousness. Fifteen weeks after the injury double vision in looking downwards, the images being above one another and that of the left eye in an oblique position. She carried her head forwards and turned toward the sound side.

(c) Cerebral. Simon reports a man who fell from a horse; severe nose bleed; double vision from paralysis of one superior oblique; healing in 14 days.

4. Basal paralysis of the trigeminus.

Isolated basal paralysis of the trigeminus has not been anatomically found, but there are several cases reported in which this lesion was probable.

Hirschberg[15] reported one in 1868 from hoof injury.

Combined paralysis of the trigeminus is, according to Bergmann,[2] more common.

Hauptman[16] reports progressive paralysis of the third to the seventh cranial nerves, following a blow from a hoof on the left side of the face. Immediately following there was left-sided paralysis of the trigeminus, three weeks later total oculomotor and trochlearis paralysis, and in four weeks more left-sided facial paralysis. The cause was fracture of the base of the skull and the progression due to callus formation. The affection proved permanent.

5. Basal paralysis of the facialis.

Facial paralysis is common in fracture of the base and in fire-arm injuries, as the nerve is encased in the petrous portion of the temporal bone and is often injured. In laceration the paralysis is permanent; in contusion or compression recovery often ensues.

A remarkable case of recovery from a fracture of the base of the skull, showing complication of the facialis and oculomotor, is at present under my care.

The lady was thrown from a train moving at the rate of 55 miles an hour, through an open door, while passing through the vestibule to the dining car (with her child of 6 years), November 18, 1909, striking the ground 58 feet away from the track, the child, being but slightly injured, following with and landing on her body. Among other general injuries, clavicle broken, scapula dislocated, great contusion of body, nasal, aural and mouth hemorrhage; unconscious three weeks; in hospital two months. Deafness, blindness left eye, double facial paralysis, loss of smell and taste followed. Occiput and base of skull said to have been fractured. Now depressed scar over right parietal, deep posterior walls of auditory canals with cicatricial drumheads and scars in skin of canals show that there has been a basal fracture passing through petrous portion of both temporal bones. Right side, partial facial paralysis. Left side, complete with lagophthalmus. All rotations, especially downwards, incomplete, due to partial paralysis of left inferior rectus. Loss of sense of taste on left side of tongue. V. R.=6/1x, with correction 6/xxv. I.=6/xii, with correction —1=6/vi. Right optic nerve slightly atrophic and visual field contracted. Partial deafness both ears due to cicatricial changes in tympanum.

LITERATURE.

1. Leber, *Arch. f. Ophth.*, xxvi, 1, p. 291.
2. Bergmann, *Die Lehre von den Kopfverletzungen, Stuttgart*, 1887.
3. Simon, *Inaug. Diss.*, Griefswald, 1896.
4. Berlin, *Graefe-Saemisch*, vi, p. 644.
5. Schiess, *Klin. Mon. f. Aug.*, viii, p. 218.

6. Battle, *London Lancet,* July, 1890.
7. Purtscher, *Arch. f. Aug.,* xviii, 4, p. 307.
8. Eulenberg, *Neurol. Centralbl.,* 1894, p. 578.
9. Friedenwald, *Arch. Ophth.,* xxiii, p. 403.
10. Hansell, *Annals. Ophth.,* Oct., 1906.
11. Gontermann, *Berl. Klin. Woch.,* 1908, p. 1522.
12. Mauthner, *Lehre von der Augenmuskellähmung.*
13. Silex, *Klin. Mon. f. Aug.,* 1888, p. 429.
14. Rhein and Risley, *Amer. Med., Oct.,* 1906.
15. Hirschberg, *Berl. Klin. Woch.,* 1868, p. 486.
16. Hauptmann, *Inaug. Dissert.,* Griefswald, 1897.

CHAPTER XXX.

INJURIES OF THE LACRIMAL APPARATUS.

A. Wounds and dislocations—Etiology and Mechanism—Symptoms and Course—Diagnosis—Prognosis—Therapy. B. Foreign bodies—Etiology and Mechanism—Abscess of gland—Therapy. C. Blows from blunt objects—Etiology and Mechanism—Symptoms—Rupture—Adenitis of gland. D. Thermal injuries. E. Tumor formations.

A. WOUNDS AND DISLOCATIONS.

Etiology and Mechanism. In a few cases of wounds of the lids and soft parts of the orbit, especially from broken bottles, sharp stones, or pieces of wood, the orbit may be entered and the lacrimal gland be cut, evulsed or prolapsed through the wound, especially in the case of children.

In 13 cases of dislocation of the gland collected by Jackson,[1] ten occurred in children of 11 to 14 years of age. The slight development of the upper margin of the orbit in childhood leaves the gland unprotected, and in adults this accident occurs in those having undeveloped orbital margins.

In children the accident usually results from falling and cutting the lid; in adults from penetrating wounds under the brow. Noyes[2] had a spontaneous case of dislocation of the gland and removed it. In Jackson's[1] case the impalement of the gland by the stick drew it partly out.

Roy,[3] among causes of dislocation of the gland, gives swelling of adjoining parts and cicatricial contraction.

Injury to the canaliculi, sac and canal occurs from lid and nasal wounds from shot and pointed sticks. Horizontal wounds are less common than vertical.

The Symptoms and Course are those of wounds of the orbit; of dislocations of the gland are the presence of the tumor, diplopia, eyeball forced forwards, down and inwards, and movements limited.

The Diagnosis of wounds and dislocations is not difficult as to the cut and the gland, for where combined the gland may be seen protruding from the wound, and in other cases may be felt as a tumor the size of an almond in its shell.

The abuse of probes in treatment of lacrimal obstructions may cause false symptoms and infections.

The Prognosis depends upon infection and retention of foreign bodies in the orbit. No case has lost the eye nor resulted in permanent fistula, or disturbance of the lacrimal function, where the lacrimal passages are cut, the patulency of the canal is prevented in the healing and epiphora occurs. Fistula or caries and necrosis with suppuration from dacryocystitis may follow.

Therapy. In most cases antisepsis and restoration of parts to normal position by suturing will be followed by complete restoration with external cicatrix. It may be necessary to excise all or a portion of the protruding gland. Secondary operations for relief of lacrimal stricture may be necessary in wounds of the lacrimal passages.

In a cow-horn injury, besides tearing of the lid there was a fracture of the ethmoids and nasal bones and the process of repair by cicatrization produced closure of the lacrimal passages.

The same occurred in the case of a dog bite of the lid, brow and globe.

Edw. Jackson[1] reports a man who had been thrown from a wagon 15 days before, receiving a wound of the upper lid, parallel to the orbital margin, one inch long. Eye was almost immovable and displaced down 4 mm., forward 12 mm., inward 3 mm. Great swelling over globe and dislocated lacrimal gland felt. Operation under ethyl chloride spray, gland dissected out and pus cavity opened. Two weeks later splinter of sage brush, 3x2x18 mm., found, and at other dressings during following week six more splinters removed. Healing with V.=4/iv, eye 6 m. in advance of fellow. The author gives abstracts from the literature of 13 cases of dislocation of the lacrimal gland.

Durr[4] reported two cases of traumatic defect of the lacrimal bones in which the fragments had cut the lacrimal sac and resulted in closure with epiphora.

Szili[5] reported lacrimal fistula from injury by a pointed object.

Shot wounds of the sac and canal destroy it and the cicatricial healing produces closure of the passage.

LITERATURE.

1. Edw. Jackson, *Ophth. Record*, Aug., 1904.
2. Noyes, *Trans. Amer. Ophth. Soc.*, 1887.
3. Dunbar Roy, *Amer. Journ. Med. Scien.*, Jan., 1904.
4. Durr, *Klin. Mon. f. Aug.*, 1879, p. 367.
5. Szili, *Arch. f. Aug.*, xiii, 1, p. 50.

B. FOREIGN BODIES.

Etiology and Mechanism. The lacrimal gland is seldom the seat of a foreign body, still the case of Jackson[1] reminds us that the possibility of imbedding a foreign body in connection with every open

wound of the lids and orbit should be borne in mind; but in the absence of definite evidence of its presence and location, do not endanger important structures in the search for it.

All kinds of foreign bodies may be found sticking in the lacrimal canaliculi, especially cilia, portions of insects, grains of chaff, wood, finger-nail clippings, more seldom iron, stone or sand particles. These have first laid in the conjunctival sac and been carried by the tears and movements of the lids into the canaliculus. They may cause considerable irritation and are often overlooked.

One of the most grateful patients I ever had was a gentleman who had had an irritation of the caruncle for over three months and who during that time had consulted eminent specialists in Toronto, New York and Chicago. Fortunately I examined the lacrimal passages in the course of the routine objective examination and found a cilium impacted not only into the passage but into the lining of the canaliculus. It came away by use of the forceps, the irritation subsided within 24 hours and never returned.

Naturally as the sac has such a small entrance through the canaliculi foreign bodies seldom gain entrance save where the canaliculus has been divided. Concretions may form in dacryocystitis.

I took a hard body the size of a No. 2 shot out of such a case: whether it was a stone or a concretion I do not know.

Simi[2] took a grain out of a case of lacrimal fistula.

Foreign bodies may wander from the nose or be blown up there.

Berry[3] reported the case of a girl who bit off the thread in sewing and in whom there was a lacrimal fistula containing 62 little balls composed of ends of thread.

Praun[4] says cherry-stones have been found in this location. Styles have been retained for many years in the lacrimal canal.

A man in whose lacrimal canal I had inserted a lead style in 1891 and who was shortly afterwards lost to observation returned in 1905 with it still in position.

The evident Therapy is removal of the foreign body.

Abscess of the lacrimal gland was seen by me in the case of a sawyer who had a splinter of wood penetrate the orbit just under the brow, and break off therein. Proptosis, temperature 103°, great pain in orbit and swelling of testicle. Incision, removal of splinter 1½ cm. long, drainage and recovery in two weeks.

LITERATURE.

1. Edw. Jackson, *Ophth. Record,* Aug., 1904.
2. Simi, ref. Praun, p. 490.
3. Berry, *Ann. d'oculist.,* x, p. 125.
4. Praun, *Die Verletzungen des Auges,* p. 490.

C. BLOWS FROM BLUNT OBJECTS.

Etiology and Mechanism. Inflammation of the lacrimal gland may occur from blows on the brow or gland. It is seldom of moment and not often recognized. I have seen a number of cases in connection with ordinary black eye. Several cases of dislocation of the gland without wounding and of spontaneous prolapse have been reported.

Coughing, epilepsy, and moral emotions, noted in some cases, have been suggested as etiologic factors; sudden hyperemia of the gland consecutive to vaso-dilatation causes its displacement and subsequent pro-

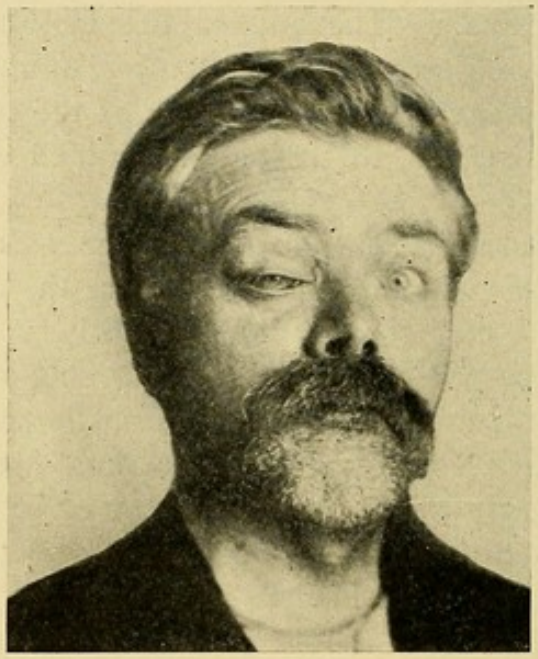

Fig. 374.
Pseudo-ptosis and suppuration of lacrimal gland, due to penetrating splinter of wood. Operation; recovery.

lapse. Congenital dislocation of the lacrimal gland is known to occur in connection with defects in the conformation of the orbit.

To explain the mechanism of the luxation we must admit the intervention of two factors—increase in the volume of weight of the gland and, second, relaxation of its system of suspensory ligaments. The first factor is realized when the organ is the seat of chronic infective inflammation, in consequence of which and of the increase in volume the ligaments are stretched, distended and altered in their histologic structure.

Spontaneous reduction of the dislocated lacrimal gland has been observed; extirpation has been practised; attempt has been made to keep it in place by an apparatus; and Golovine has undertaken to fit it by means of sutures.

Symptoms. There is a rather hard tumor of oval form at the outer angle of the orbit, contained in a fold of skin in which it rests as in a sac or hammock, and may hang down over the commissure of the lids. It is freely movable between the skin and the tarsus in the horizontal and upward directions, but not downward, and unless too large can be replaced in its proper position in the orbit, but falls out at once spontaneously by its weight or as the result of lowering the head or straining.

Rupture of the gland has been reported.

Santucci,[1] in connection with a case of his own, gives a review of the literature on this subject, which shows some discrepancy among

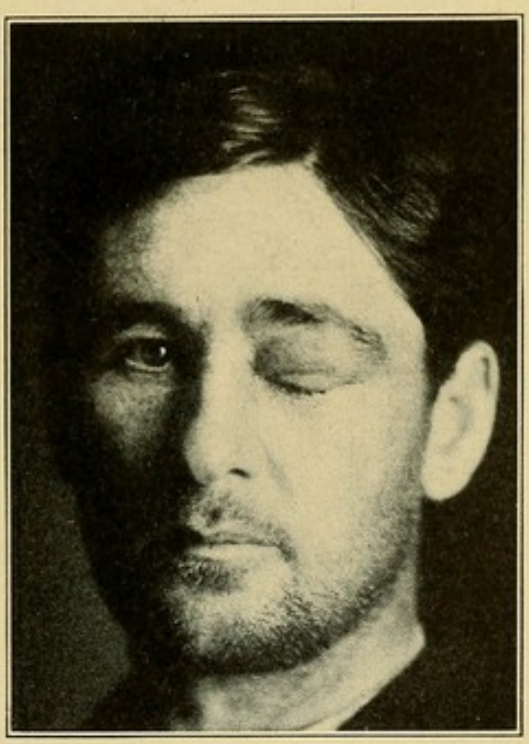

Fig. 375.
Adenitis of lacrimal gland.

authors as to the expediency of extirpation of the dislocated lacrimal gland after traumatism. Santucci advocates the removal of the gland, since the replacement of the gland into its fossa is rather difficult, and if not successful, causes a disfigurement of the patient. The lubrication of the eyeball after extirpation of the lacrimal gland does not suffer, since the former is due to secretion of the conjunctival glands (the tubulous gland of Henle, the tubulo-acinous glands of Krause, and the acinous glands of the tarsus of Ciaccio). Finally, it must not be forgotten that the integrity of a displaced gland suffers from lack of nutrition, and undergoes histologic changes, terminating very easily in atrophy.

Crowder[2] reports a girl of 13, while playing basket-ball, collided

with another player and sustained a dislocation of the lacrimal gland. It could be replaced by pressure. A compress was applied and discontinued the fourth day, when the dislocated gland again presented. The pressure was again resumed and continued for two weeks, when the gland then remained in its normal position.

Rupture of the lacrimal sac or canal sometimes occurs in fractures of the nasal and lacrimal bones. It is hardly recognizable except when emphysema of the orbit or obliteration of the passage after wounds occurs. I have seen such following a forceps delivery.

Adenitis of the lacrimal gland was seen by me in a man who had fallen down while intoxicated, striking his brow. He also had urethral gonorrhea and gonorrheal rheumatism. The blow here probably was the exciting cause of the lacrimal gland inflammation.

LITERATURE.

1. Santucci, *Centralbl. f. prak. Aug.*, 1904, p. 137.
2. Crowder, *Ophth. Record*, Sept., 1906.

D. THERMAL INJURIES.

In connection with burning of the lids and conjunctiva, particularly by glowing metals, acids, alkalies and lime, the lacrimal passages may be involved. They usually close up and may in favorable cases be again opened by surgical methods.

I have seen this in lime burns, molten lead, and carbolic acid instillation, in the last instance from mistake in putting in this escharotic.

E. TUMOR FORMATION.

Pfingst[1] has reported a sarcoma of the canaliculus following trauma.

LITERATURE.

1. Pfingst, *Klin. Mon. f. Aug.*, 1895, p. 259.

PART III

FORENSIC MEDICINE

CHAPTER XXXI.

MEDICO-LEGAL.

A. The physical examination of injury cases. B. The relation between accidental injuries and previcusly existing inter-current and post-traumatic changes in the eye. C. The prognosis in medico-legal cases—The responsibility of the physician—Literature. D. Malingering—Self-inflicted damage—Simulation and aggravation—Hysteria—Previously existing lesions—Cases—Literature. E. The physician in court. 1. His rights—Contracts. 2. Malpractice. 3. Legal compensation for damage in the United States of America. 4. Measure of damages—Nominal—Substantial or compensatory—Exemplary—Punitive or vindictive damages. 5. Recent judgments in appellate and supreme courts—Literature.

A. THE PHYSICAL EXAMINATION OF PERSONAL INJURY CASES.

The examination of an injured person from a medico-legal standpoint should be conducted in a sympathetic manner in order to obtain the patient's confidence, and while the examiner should ever be on the watch for malingering, yet he should not take an antagonistic stand. Such an examination is often grudgingly submitted to, the patient looking upon the examiner in the light of an opponent who has been hired by the defense to find some excuse for prevention of the collection of damages.

The opposite frame of mind is shown by those injured persons who themselves secure an examination as a basis for mal-practice or personal injury suit. Yet they too invariably distort and magnify the importance of the economic damage.

It behooves us, therefore, in examination of injury cases, to leave no impression upon the patient as to the advisability of his seeking recourse at law, but to conduct the examination in an impartial and sympathetic manner, at the same time leaving a favorable opinion upon his mind.

A comparatively small proportion of accidental injuries have, in American law, a basis for collection of damages; the larger number have been worked up by irresponsible legal parasites for pecuniary rather than eleemosynary purposes. Be this as it may, one should not lose sight of the fact that cases occur in which there are really grounds for damages and which should obtain pecuniary relief thereby.

Shastid[1] says "it is everywhere admitted that, with certain restrictions, the plaintiff in a personal injury suit may, if he so choose, exhibit his injuries either, in proper cases, direct to the jury, or, in

other instances, indirectly to physicians who are afterwards to go upon the stand. But what about cases where the plaintiff does not so choose? What if, when the defendant or the court itself suggests that the plaintiff undergo a physical personal inspection, he objects? May the plaintiff then, when he does so object, be compelled, against his will, to undergo the examination? Further, in jurisdictions where such power of compulsion is conceded, under what circumstances may the power appropriately be exercised? On these two questions the decisions are irreconcilably at variance. The authority to order personal inspection may be required or depends upon the judge's discretion. It seems to be definitely settled that the authority is one, the exercise of which depends upon the sound discretion of the trial court; in other words, that it is an optional power in the judge, rather than a personal right in the defendant.

To sum up the various conclusions arrived at since the beginning of these investigations:

1—In a suit for personal injuries, the plaintiff may, by the weight of authority, be compelled to submit to a physical examination. This is a settled law in Ohio, Indiana, Michigan, Kentucky, Alabama, Georgia, Kansas, Arkansas, Iowa, Missouri, Wisconsin and Minnesota. The courts of the United States, of Illinois, and possibly of Massachusetts and Texas, hold otherwise.

2—There is no absolute right in the defendant to have the examination, but the power to order it rests in the sound discretion of the trial court.

3—This discretion is subject to review on appeal.

4—It is declared in one case that the court has no power to compel the examination after the defendant has withdrawn his request for such examination.

5—By the great weight of authority, it is not an abuse of the discretion to refuse to order a physical examination after the beginning of the trial.

6—Nor is it an abuse to refuse the order when the examination might endanger the patient's life or health.

7—Nor when the use of an anesthetic would be requisite in order that the examination might be made.

8—Nor where the nature and extent of the injuries are obvious to all.

9—Though opinions are scanty on the point, it would seem that no abuse of the discretion lodged in the trial court is committed when the examination is refused on the ground of delicacy, and when the facts in the case bear out the trial court in its opinion that a delicate case exists.

10—It has been suggested, further, in one case, that the court might properly refuse to grant the order 'when the testimony would be

merely cumulative, or where, on the judgment of the trial court, it would not materially aid the jury.' "

LITERATURE.

Shastid, *Mich. Law Rev.*, Dec., 1902, and Jan., 1903.

B. THE RELATION BETWEEN ACCIDENTAL INJURIES AND PREVIOUSLY EXISTING, INTERCURRENT AND POST-TRAUMATIC CHANGES IN THE EYE.

Conditions due to an accidental injury must be differentiated from those existing before, those concurrent with, or those occurring after the injury from other causes.

In uncomplicated, fresh cases blemishes due to previous-existing disease, or the results of former accidents, are readily determined, but especially those which come to the examiner a long time after the alleged injury, such may not be so evident, and afford weighty problems.

It is especially necessary in these cases to make a general examination of the body and to carefully note the conditions in the non-injured eye. In the injured organ note whether typical scars or inflammatory changes or their effects are to be seen.

Determine whether conjunctival inflammation is due to foreign bodies, dust or chemicals, or to inflammation from infections by microscopic examination of smears. Exclude the presence of trachoma by the typical appearances of the granulations and cicatrices.

Exclude scrofulous and syphilitic disease of the cornea; ulcers caused by infections, which is one of the most trying differential diagnoses. It may be that a foreign body may be found in the ulcer.

Iritis, cyclitis, and chorioiditis may be rendered worse by a blow or may be caused by injury. The systemic causes, syphilis, rheumatism, etc., should be excluded.

Hemorrhages within the globe, the anterior chamber or vitreous, and under the conjunctiva, may be caused by the hemorrhagic diathesis or by constitutional diseases, as diabetes, arterio-sclerosis, and renal affections.

Cataract in one eye in otherwise sound and young individuals is usually due to trauma; luxation of the lens usually happens in a weak eye. Cataract from dyscrasiæ and senility is generally double-sided.

The retina is often affected in short-sighted eyes in connection with changes in the vitreous. Detachment of the retina occurs in 5 per cent of high grades of myopia.

Hemorrhages occur in renal and cardiac affections and diabetes, and the possibility of sudden blindness from thrombosis should be excluded. The optic nerve becomes atrophic following a number of constitutional

diseases and brain affections. Such is usually double-sided, while traumatic atrophy of the optic nerve following a blow upon the head, or fracture of the skull, or bones of the walls of the orbit, and from tearing of the optic nerve, is usually one-sided.

In these cases the relation between the alleged accident and the atrophy of the nerve may be very difficult to determine. The same may be said of the relation of injuries to the skull and optic nerve.

Injury to the visual sphere, with hemianopsia, from blows on the head, may occur and should be differentiated from apoplexy, tumors of the brain, etc.

As intercurrent diseases we may cite chronic conjunctivitis, trauma, corneal and uveal infections, and changes in the retina and optic nerve. The intercurrence of general diseases should likewise be noted, especially those conditions which have local lesions in the eye, as syphilis and tuberculosis.

C. THE PROGNOSIS IN MEDICO-LEGAL CASES.

The future prospects for eyes that have been injured opens a wide and doubtful field for prognosis, but as the physician is frequently asked in court concerning prognosis, and as this is a matter of constant inquiry from patients, he must have certain knowledge of the subject and be prepared with proper answers. While upon questions of prognosis it is not well to make definite statements; on account of the psychic element, with dangers of loss of the patient or his suicide from unfavorable prognosis, such as a rule should not be communicated directly to the patient, but the family physician or the family should invariably be made fully conversant with the prognosis. There are certain lesions of the eye which almost invariably result in loss of function and even in loss of the eyeball itself; for instance, ulcerations of the cornea are as a rule followed by opacities, varying from nebulæ to leucomata, which materially diminish the visual acuity, especially if these be in the visual axis. Likewise, lesions complicated with iritis may, if not properly treated, result in occlusion of the pupil. Injuries of the lens almost invariably result in total opacity, although there have been a number of cases observed and reported in which foreign bodies have remained in situ for a number of years without causing further opacity; and development of partial cataract is observed in many cases. To this we refer to cataract from electricity and distinguish a true contusion of the lens.

Contusions and wounds of the ciliary region frequently result in chronic irido-cyclitis and atrophy of the bulb. Retained foreign bodies in the eye result in blindness from such causes, as well as from sympa-

thetic ophthalmitis, the latter of which is usually caused by septic injuries to the ciliary region.

Injuries to the optic nerve result in loss of sight from resultant atrophy, and, as is noted herein, the diagnosis may be especially difficult. Injuries of the head affecting the visual sphere may result in optic atrophy, or those of the muscles result in paralysis. A small group of cases should be noted in which the appearances of an accident are seen, but in which no history may be obtained of its occurrence. To this group the occurrence of cataract, the detachment of the retina and rupture of the chorioid, together with optic nerve atrophy, are most common. The patient may, upon questioning, tell of a number of accidents to the head or eyes too trivial in character, to none of which the patient can with definiteness attribute the present affection.

Jocqs[1] gives medico-legal reports of accidents to persons working in the various industries. They should of necessity be exact as to the determination of the etiology and prognosis of certain visual troubles, such as amblyopia and amaurosis following traumatism of the head.

Many cases of amaurosis follow, as is well known, a blow on the head, of which the pathogeny is an indirect fracture through the optic canal, or an effusion of blood in the nerve sheath. But more frequently is it the case that, following a trauma of the cranium, the injured person, in good faith or not, claims the visual loss to be due to the injury, while the lessened vision may have existed prior to the accident. Of course, when the case is seen just after the trauma and amaurosis exists, it is impossible, before some days have elapsed, to discover any optic nerve change. Optic nerve atrophy will follow in a short time. The optic papilla will guide in these cases. When the case is seen long after the accident, while the etiology is determined with less certainty, nevertheless to the trauma of the cranium may be attributed the cause if the contour of the atrophied papilla is clear. The arteries may have preserved their calibre, it rarely happening that they become less in size from pressure on the nerve at the level of the optic foramen.

The refraction and visual field should be estimated, bearing in mind that hyperopia and astigmatism occur in dislocation of the clear lens into the vitreous, myopia and astigmatism from anterior luxation and from traumatic spasm of the ciliary muscle.

While true instances occur where the injury seemed to bring out or emphasize a latent error of refraction, there are cases of amblyopia of many years' standing in which attempts are made to blame a trivial injury for the condition of the eyes.

Two such are reported by Gaylord C. Hall,[2] of which the following is a good example:

Removed a piece of emery imbedded on cornea of left eye. Claims

that one year ago similar accident occurred when the foreign body was removed by my office associate, since which time the eye has been blind. No scars are visible. Has perception of large objects only. No previous disease of eyes, no blows or falls, eyes never crossed.

Vision O. D. 6/vi, O. S., movements of hand 3m. Ophthalmoscope shows no appreciable change in either fundus. Patient's habits are bad; both drinks and smokes a great deal. Ordered solution atropin 1 per cent in left eye. Reported after three days. Ophthalmometer showed axis 80°, 170° retinoscope, vertical +7.00, horizontal +10.00 reverses. Accepts O. S. +5.50, S⌒ +2.50 C ax. 80°. Vision is clearer, but no letters are read. The situation was explained to the patient and his complaint ceased.

Gaylord C. Hall[2] gives a case which illustrates an extremely dangerous phase of cases from a medico-legal point, and one where a positive opinion concerning the previous condition of the eye could not be given.

A man was injured November 5. While grinding a brass fitting something flew into his eye. The next day at the foundry he claimed that a foreign body was removed. The eye felt better afterwards, but suddenly got worse the night of the 9th. Examination showed eye very red, watery and tender. Cornea hazy, iris discolored, tension normal, anterior chamber unaffected, pupil contracted. Vision, hand movements. Has a foreign body imbedded near center of cornea surrounded by a ring of necrotic tissue. Cocain, eye cleansed, removed foreign body with spud, atropin instilled. All attempts to dilate pupil failed. Has a complete posterior synechia occlusi pupilla due to old iritis. Denies syphilis. No previous eye trouble. Drinks heavily. Gave brisk mercurial purge, followed by salts, and used atropin in substance. The redness and pain were relieved after several days, but pupil was still occluded. After pain and redness disappeared patient seemed satisfied and voluntarily ceased his visits.

The denseness of the adhesions and completeness of the synechia in this case pointed to an old iritis even in the absence of any previous history. There was enough, however, in the six days that elapsed before treatment, to have caused an iritis, to say the least.

Cases of this kind with previous injury to the eye could, if so disposed, following an injury however slight, make fraudulent claims for damages and very likely obtain a verdict, since it is an undeniable fact that the eye is injured.

Bell[3] says traumatic corneal ulcer is common in railway surgery. No one hesitates to attempt to remove a foreign body from the eye. Every member of a train crew, from the conductor to the porter, has in hand for this emergency a cotton dip, soiled handkerchief, match or dis-

carded toothpick. The consequences of these friendly but unskilled efforts are often provocative of trouble, physically for the patient and financially for the road. The patient, in losing an eye, may gain a competency. A small corneal scar has served more than once to lift a fireman from the cab of his engine to a position of easy affluence.

No attempt should be made to remove a foreign body from the cornea while the train is in motion or at any time or place by a person not qualified for the responsibility thus assumed. A protective bandage over the closed lids will suffice until the nearest physician is reached. Aside from the dangers of infection, unskilled efforts usually result in an opaque scar (more often an infected ulcer). As long as this indiscriminate practice is permitted by the executives of the road the company is legally and financially bound by the results. Moreover the medical staff is forced to act as consultant authority to the layman and has immediately to bear the burden of his mistakes. No traumatic involvement of the cornea is a trivial matter in railway surgery. The ophthalmic surgeon should have full authority to commit a patient to the hospital in the exercise of his judgment.

These precautions and attention to apparently trivial details of treatment would curtail in a marked degree the number and success of personal-injury suits against railroads.

The responsibility of the physician.

"Legally, the physician may be said to have no responsibility as regards prognosis, as that is a matter of personal opinion rather than of fact; but ethically his position is one which is twofold. From his own standpoint and that of the patient's good it is necessary that the patient retain a favorable opinion of the physician and, in many cases, continue to take treatment. Thus, by an unfavorable prognosis which may not prove to be true—for wonderful are the ways of Nature in curing disease and healing injury—the physician may be discredited by a partial or complete restoration to health of the patient. Pecuniarily he may suffer as a result of the patient leaving him to go to some other physician who gives a more favorable prognosis. Secondarily the effect upon the patient's mind is one that should be considered, and hope should always be afforded to what is esteemed the hopeless cases. While the whole truth should be told the family physician and to the family of the patient, yet the whole, and what may be most unpalatable, truth need not be told the patient himself. This has to be learned by experience in the most unpleasant manner by the average physician by the result of an unfavorable prognosis being communicated either directly or indirectly to the patient, and the suicide of the latter being accomplished a short time thereafter. (See Psychoses.)

"Bearing this in mind it is a problem whether or not, when an unfavorable prognosis is given by the physician, particularly by one of note, he may not be deemed by the public, and perhaps, too, at law—if such a case should ever come up in the courts—a party to the cause of such a crime, and held liable for damages therefrom."[3]

LITERATURE.

1. Jocqs, *La Clin. Ophthal.*, May 25, 1908.
2. Gaylord C. Hall.
3. Bell, James H., *Texas State Medical Journ.*, Apr., 1906.

D. MALINGERING, SELF-INFLICTED DAMAGE, SIMULATION AND AGGRAVATION.

Accidental injuries to the eyes may be imitated by the patient putting in medicinal or irritative substances or wounding or otherwise causing actual injuries to his own eyes (self-inflicted damage), or, what is more commonly the case, alleging loss of sight or other function or inability to use the eyes, or painful affections (simulation), or overstate the degree of damage to the function of sight (aggravation), all of which are classes under the generic term of Malingering.

The production of a conjunctivitis is common, especially among conscripts, by the rubbing of the eye with the finger shortly before the expected examination by the physician, the laying in the eye of foreign bodies, etc. Of these Praun[1] gives sand, chalk, plaster from walls, stones, earth, tobacco ashes, tobacco, soap, salt, pepper, cantharides, and matches, to which may be added broken glass and cinders or small pieces of wood or coal. More infrequently coloring material, paint and dye, irritating and caustic solutions of sulphuric acid, ammonia, zinc, copper sulphate, sublimate, alcohol and urine are used to imitate irritation from injury. The appearances are usually most apparent on the conjunctival surface of the under lid, and in the case of foreign bodies, while there is hyperemia, there is no such secretion of mucus as would be apparent in a foreign body which had flown in by accident and where as a rule the mote is found under the upper lid, which in these cases is not affected. It is typical of such instances that they appear before the examiner with their eye already bandaged. Educated dissemblers may irritate the other eye from the one that may have been actually injured, in order to imitate sympathetic disease of the sound organ.

The cornea may be injured by scratching with the finger nail, the eye cut or punctured by broken glass, or knife or needle, the latter having been used to pierce the eye and cause traumatic cataract. Cauterization of the cornea by caustics to produce apparent ulcer, instillation of atropin solution or belladonna salve or plaster to produce mydriasis, has

been reported by Himly[2] and Hasner[3] in recruits. The diagnosis of the former injuries is apparent and atropin mydriasis is characterized by extreme dilatation. If only instilled in one eye, the consensual reaction of the other remains.

More commonly anomalies of the function, and especially amaurosis or amblyopia, may be simulated. This is usually alleged in one eye, if in both only diminution of vision or use is complained of. Very many cases are reported and are common in practice. It is characteristic of such people to complain of the light and especially of the light reflected by the ophthalmoscopic mirror during examination. They generally wear very dark, smoked glasses, or a shade, and are led to the examiner with eyes bandaged, and invariably appear so adorned before a jury in suits for damages. They complain of pain in the necessary manipulation of the eyelids by the examiner and wince when his hand approaches the face; but such eyes wink normally when the examiner suddenly directs his finger or an instrument near the eye. The pupillary reaction is normal, there is no divergence on covering the organ, and nothing abnormal is found by inspection, and especially on ophthalmoscopic examination. Confusion tests by plus and minus lenses and prisms, the colored red and green glasses and letters, the stereoscope with unlike pictures, Gratama's tubes and the general unwillingness or over aptitude of the patient will greatly aid the examiner.

These cases offer quite a contrast to applicants for admission to the army and navy, to the railway and steamship services and the industrial occupations, where good eyesight is required, who always ameliorate rather than depreciate their qualifications.

A class of patients must here be mentioned in which, before the accident, the patient originally had a defect and either did or did not know it. Here belong those cases of high refractive errors, in one or both eyes; people who have claimed that they could see as well as any one; those with anomalies of development and those whose eyes were diseased.

More difficult to determine are those cases where the existence of an actual accidental lesion is apparent in which the injured party claims greater functional damage than actually exists to the individual. A number of observations should here be made in order to determine the proper relations. Of special value is notation of the visual acuity with different sized types or test objects at different distances and under different degrees of illumination at separate examinations. Well-informed malingerers may show changes in the visual fields, more especially contraction. This is to be detected by charting the visual fields at different distances from the patient. Nieden[4] declared that such malingerers usually gave their visual field limits in the form of a circle at about

32° from the fixation point. In these cases, too, the normal relations of the color field are not shown.

The results obtained by the several examinations of the acuity and field should practically agree where no dissembling is practised.

Other functional anomalies, such as paralysis of the muscles, are not simulated. Blepharospasm and convergent squint may be temporarily imitated. Nieden[4] says that nystagmus cannot be produced by will but that a rhythmic rolling of the eyeballs has been seen in such cases from which it should be differentiated. Nystagmus may be due to injury of the skull or to ear disease through implication of Deitor's nucleus.

A diagnosis of hysterical blindness may, according to Howard Hansell,[5] be made when accompanied by certain hysterical stigmata, such as ciliary spasm or paresis; amblyopia due to anesthesia of the retina, corresponding in kind to the anesthesia of the skin; contraction of the visual field; relatively greater for white than for colors, and reversal of the fields for blue and red; the tubular field, blepharospasm, monocular diplopia, anesthesia of the conjunctiva and ring scotoma. Simulated blindness is usually not difficult and is to be detected by testing the pupillary reaction, the stereoscopic tests, the use of red and green letters, etc. These patients always have some very good reason for malingering.

Self-inflicted damage, under circumstances simulating accident, is extremely rare and, as shown in the following case, requires great nerve, quick orientation and a peculiar frame of mind.

A man who had a staphylomatous cornea from previous gonorrheal ophthalmia was standing in a crowded electric car when a sudden movement forced his shoulder through a glass window, breaking same; he thereupon seized a splinter of glass and jabbed it into his own imperfect eye, which was the next day enucleated by me on account of the great injury to the ciliary body and for cosmetic reasons. A few weeks later he sued the transportation company for $25,000.00 damages, but it was shown that his radical action had been observed, and the fact that only the week before he had taken out a large amount of accident insurance, together with certain other factors, was so against him that the suit was compromised for a few hundred dollars.

In hysteria, as reported by Heath,[6] in which accidental trauma was simulated by placing pieces of glass into the conjunctival sac, in a girl, aged 16, an inmate of the Chicago Refuge for Girls. She complained of having gotten some pieces of glass into her left eye on the day before through the breaking of one of her lenses. Five pieces of glass were removed by one of the attendants. Considerable attention was given the girl and she was taken down town to see the oculist, and in order to continue in that role she repeatedly put small pieces of glass in the

conjunctival sac, which were removed by the attendants, as well as the oculist. Examination of her visual fields showed them to be contracted for white with reversal for colors. General examination revealed her to be a subject of characteristic hysterical attacks. She had areas of hypalgesia and hyperalgesia over the body and extremities.

Many evidences of simulation could be given by physicians who have been called into court as expert witnesses in personal injury cases, and especially in insurance cases. Abroad such are often met with in conscript examination practice.

Hasner[3] reported the case of a cavalry cadet who put atropin in his eye in order that he might be sent to a hospital and thereby get to a large city.

Most cases of malingering in America are met with in examining accident insurance cases or in personal injury suits. Practically all of these have a basis of poor sight which existed either before, or has occurred from the effects of, the accident, upon which to base their claim for damages at law. There have been many such in my experience.

I saw a case of hysterical blindness and deafness[7a-b] from an uncharged electric wire dropping on the head of a woman who imagined it to be charged and that she was shocked thereby. She sued for damages but none were allowed as it was shown by the Electric Co. that all the wires in that vicinity were out of circuit. Recovery ensued immediately after the case was dismissed by the court.

I have seen several other cases of psychic blindness and deafness[7c] in some of which the restoration of function was incidental to the recovery of pecuniary damages.[7d]

LITERATURE.

1. Praun, *Die Verletzungen des Auges*, p. 155.
2. Himly, *Text-Book of Ophth.*, 1843.
3. Hasner, Mascha's *Handbuch der gerichtl Med.*
4. Nieden, *Ges Beitr. aus d. Gebiet. der Chir. u. Med.*, Bergman, 1893.
5. Hansell, *Annals of Ophth.*, Oct., 1907.
6. Heath, *Ophth. Record*, April, 1907.
7. Würdemann, (a) *Ophth. Record*, Oct., 1901; (b) *Med. News*, Feb., 1891, and (c) *Journ. A. M. A.*, Oct. 3, 1896; (d) *Ophthalmology*, Apr., 1911.

E. THE PHYSICIAN IN COURT.

1. His rights.

The position of the physician as to the medico-legal aspects of eye accidents and damage to sight is of course similar to that in regard to injuries or disease of other localities. But the fact that a large percentage of suits for damages and suits for malpractice is composed of eye cases, most of these as the result of damage from injury, and as the oculist is an expert in eye diseases and injuries and always testifies in court as such,

it may be well to give a brief resumè[1a to i] of his position as to legal standing, as to recovery of compensation, his protection from damage and malpractice suits, and as to expert evidence in general.

The right to practise medicine and surgery is not restricted except by statute, and in the United States of America the candidate must either have a diploma from a medical college in good standing and pass satisfactory examination, or either of these. Exemption of "medicine men" of their own race applies to the Cherokee and Choctaw Indian nations in Oklahoma, but there is no law in the Creek nation, and there is no medical law in Alaska. There are separate medical practice acts for Hawaii, Porto Rico, the Canal Zone and the Philippines. Privilege of attending cases outside of his own state is awarded in a number of states and in others only the privilege of consultation.

Canada and Mexico have their own laws of practice, as do most other countries.

As regards the contract of the patient with the physician, this is implied on the part of the patient from the relations of the parties and it is very seldom the subject of an expressed agreement, yet the physician in law is quite secure on this point. The patient is bound not only to pay the attending physician but also the one who is called in consultation. The custom is well established that the patient himself will pay the consultation fee. Failure to benefit the patient is no bar of recovery of compensation, the first step of which is demand upon the patient for the amount due, usually done in the form of a bill. If this and other amicable efforts fail to produce the desired result, attempt may be made to enforce the payment by legal measures; for this, the physician should be legally qualified to practice, in most states, not only having a license, but it must have been filed with the proper County Officer. In most states there is statutory limitation of the age of claims.

In court the physician first shows proof of authority to practise by swearing to his diploma and registry, establishes the fact that his services have been rendered, and, in contested cases, he may be required to show books of account, or even have to particularize the items. As there is no presumption of law concerning the value of a physician's or surgeon's services, where the value is debated, conflicting evidence may be brought on this point, another physician or physicians may testify as to their value.

In a portion of the following, and that of the chapter on Malpractice, and regard to the laws of England, France and Italy, I quote liberally from the most excellent article by Thomas Hall Shastid,[2] being Part II, the Forensic Laws of Ophthalmic Surgery, Vol. I, *System of Ophthalmic Operations*, by Casey A. Wood.

"A subordinate, yet not wholly unimportant matter is that of the

expert's fees. In criminal cases no fee of any sort need ever be paid to render valid the services of the subpoena, while in civil cases the mileage and per diem, which is usually an insignificant sum, must always be paid or tendered to the witness, whether expert or ordinary, to render the services effective. In many states the physician is required to give not only ordinary fact testimony but scientific opinions involving the possession of learning and skill, in many cases turning himself wrong side out for the benefit of people whom he has never seen, who care nothing for him or his interests and who are striving on one side to get money, on the other side to keep it. The per diem is never enough to pay even his ordinary expenses. He should receive extra compensation and this fee should be fixed and in most cases received in advance before he should give testimony. Paid in advance, I say, for the lawyer knows that the law allows no extra compensation to the doctor, and after the patient receives a judgment for thousands of dollars, dividing the amount with his lawyer, he may get the answer for you 'nothing,' even after the doctor has made the most arduous preparation for the case.

"In the states of Iowa, Louisiana, North Carolina, Rhode Island, and Wyoming, the statutes provide for payment of special fees to experts. In the others it is a matter of personal agreement with the client of the lawyer by whom the expert is retained.

"In England the law relative to expert witnesses is much the same as in America. The testimony of physicians, however, is not wholly privileged, compelling the medical witness to reveal in open court the most confidential communications and to disregard the most solemn promises, as is the case in the various states of America where the matter has not been changed by statute.

"The medical expert system of France is most admirable and has worked out so satisfactorily to the ends of justice that it is hoped that a similar medico-legal arrangement may be made for America. Medical experts are appointed at the commencement of each year by the Court of Appeal sitting in council conferring the title of expert before the courts, who appear in every class of cases and in every court. In civil cases the expert may be appointed by the courts or chosen by the parties, being not obliged to accept the appointment, but once accepted the duties are obligatory. Medical experts in criminal matters are not invariably at liberty to reject an appointment; they may do so only in certain cases.

"Expert reports are composed of four essential parts:

"1. Preamble (reciting the names of the experts, the order of the court by virtue of which the investigation was made, etc.).

"2. Statement of the facts.

"3. Discussion.

"4. Conclusions.

"In Germany there exists a corps of official expert witnesses which, however, do not so uniformly appear before the courts as in France to the almost total exclusion of non-official experts. The various members of this corps take on the duties of expert witnesses only when called upon by the police or State's Attorney. In Germany professional secrecy is very rigidly enforced, being legally divulgeable up to a certain extent, the law being very specific.

"In Italy there is no corps of experts before the courts, any physician practicing being called as an expert, as in America."

2. Malpractice. Iatoi.

"Malpractice, or injury to the person, in American law and in English, upon which it is founded, is punishable in the criminal courts by imprisonment, depending upon the criminality of the offense. The intent to produce, rather than the amount of damage done, seems to be the basis for punishment. Indeed, Anglo-Saxon nations are getting away from the old Mosaic maxims, 'An eye for an eye.' While malpractice suits are not now frequent and very few judgments have been obtained against reputable physicians, still, the danger of some unscrupulous competitor initiating, or some lawyer fostering, a suit, is ever present, and thus careful physicians protect themselves by liability insurance.

"In counterclaims or suits for malpractice the ordinary physician and surgeon is only required (1) To show that he has properly continued his attendance in the case. (2) That he possesses a reasonable degree of learning and skill, which is based upon the learning and skill of physicians in the community in which he practices, i. e., the physician and surgeon of a larger city is required to show that he knows more than those practicing in small towns and in the country. (3) He is required to use this learning and skill, and (4) To use his best judgment in doubtful cases; and if he has done this he is not liable in damages for an injury resulting from an error of judgment. The practice of the particular school from which he graduated obtains as to treatment.

"There is, however, a certain responsibility in Great Britain and America, upon anyone who professes to be a specialist. He may be required to show the attainments of the leaders of our profession. Even the degree of which required by a specialist is by no means such as would enable him to effect a cure in every case that comes before him. A warranty to cure can arise only from an expressed contract, which, with its possible disastrous legal consequences, is a very unwise statement for any physician to make.

"In malpractice the failure, either to produce or to use the proper skill, which varies as to locality, specialties, etc., must be shown, i. e., not only the injury and its effects upon the patient's body and its functions,

as well as in loss of time, effect upon his earning ability, and pain and suffering, must be shown in order to constitute malpractice.

"It often happens that a counter claim for damages is set up by a patient who has not paid his bill, where legal institution is made by the physician for recovery of his fee."

In common with others I have not escaped such unpleasant attacks.

In one case I attended a boy blown up by playing with a dynamite cartridge, by which he lost one hand, and the fingers of the other. Both ear drums were ruptured, there was a severe burn of the face, impaction of wire and sand in the face, lids, and eyes, one eye was destroyed and subsequently enucleated, in the other there was partial detachment of the retina. Many consultants and varying advice was received. I dropped the case on account of the parent's interference and negligence, sued for fee, obtained judgment in the justice, circuit court, court of appeals and in the supreme court of the State of Wisconsin, an abstract of whose opinion was as follows:

The Supreme Court of Wisconsin, in discussing the evidence to support a counterclaim which had been set up as against a physician's claim for fees speaks as follows: "The evidence wholly fails to support the counterclaim. It is claimed that the defendant's son grew worse under the plaintiff's treatment, and that he grew better after the plaintiff had been discharged, but this does not show that the paintiff was guilty of negligence or unskillfulness in treating him. Other physicians were in attendance on the patient, but their evidence was not produced. No surgical or medical witness was called by the defendant to say that the treatment was negligent or improper in the least degree whatever. Uneducated persons or non-experts might conjecture upon the subject. The plaintiff could not be convicted of malpractice upon such evidence."

An oculist removed by mistake a perfectly sound eye, when he intended to remove the other, which was blind and staphylomatous; patient being under general anesthesia and the operator under the influence of alcohol. The boy was left totally blind. No suit resulted, but certainly both civil and criminal suits could here have been sustained. The oculist's reputation, however, was ruined, and he had to leave the country for foreign parts.

"In England the law of medical and surgical malpractice is very much the same as in America. The jury assisting if they saw or thought they saw occasion to impose punitive as well as compensatory damages. In France the question of malpractice in civil cases is mainly submitted to a jury because civil proceedings in France are omitted before the judges. In France, moreover, the physician is responsible only for a clumsy

mistake, gross imprudence, or ignorance of those things which all men of the profession ought thoroughly to understand.

"In Germany a physician is responsible if he does not exercise a high degree of skill, i. e., the skill of a thoroughly educated physician."

According to paragraphs 223, 223a, and 224 of the German laws[3] hard and fast punishments are decreed, and injuries relating to the various parts of the body are enumerated. For instance, where one person mishandles or causes wilful injury to another, he gets from two months to three years imprisonment, or 1,000 marks fine. However, if he blinds one or both eyes (and certain other injuries are mentioned) he is punished by not less than one year or more than five years in gaol. In Austria paragraph 156 of the criminal code gives between five and ten years. Such stringent laws are calculated to be deterrent to malpractice and of crime, but history shows that they have ever failed of their purpose.

"In Italy any act of a person productive of damage to another imposes upon such person the obligation to indemnify for such damage, he being responsible not only for the damage caused by his own act, but also that by his negligence or imprudence. No civil responsibility in Italy ensues until prosecution has been brought successfully."

In closing this chapter we go back to the Code of Hammurabi, King of Babylon, quoted by Shastid,[2] translated by Robert Francis Harper,[4] which would seem to possess special interest for oculists, because without doubt they constitute the oldest extant legislation concerning ophthalmology.

"196—If a man destroy the eye of another man, they shall destroy his eye.

"198—If one destroy the eye of a freeman, or break the bone of a freeman, he shall pay one mana of silver.

"If one destroy the eye of a man's slave, or break the bone of a man's slave, he shall pay one-half his price.

"215—If a physician * * * open an abscess (in the eye) of a man with a bronze lancet and save that man's eye, he shall receive ten shekels of silver (as his fee).

"216—If he be a freeman, he shall receive five shekels.

"218—If a physician * * * open an abscess (in the eye) of a man with a bronze lancet and destroy his eye, they shall cut off his fingers.

"220—If he open an abscess (in his eye) with a bronze lancet, and destroy his eye, he shall pay silver to the extent of one-half his price."

3. Legal compensation for damages in the United States of America.

In fixing the value, cost or price, as it may be termed, of any injury, the rule of compensation must be applied to each individual case,

and this for many forms of accident or injury is a most difficult matter. Our common law holds that "compensation is the basic principle of the law of damages, the measure thereof being limited and controlled, and the elements of recovery primarily determined by this fundamental consideration." We are also told by the books that "There are frequently elements involved so wholly unsusceptible of money valuation that the measure of recovery must be left largely, if not entirely, to the discretion of the jury. This is noticeably the case in actions for damages for personal injuries where physical suffering has resulted, and, likewise, where mental distress has been a consequence of the defendant's act."

4. Measure of damages.

Damages is defined as "the injury or loss for which compensation is sought," and the measure of damages refers to the amount of such injury or loss. Three distinct conditions are recognized and awarded to suit the merits of the case.

Nominal damages. Some trifling sum which is awarded when a breach of duty or infraction of the plaintiff's right is shown, but no serious loss is proven to have been sustained. Such are awarded for violation of a plaintiff's right, but where no damages are shown by the evidence.

Substantial or compensatory damages. These are are such as are designed and awarded to compensate for the actual loss or injury sustained. The jury weighs the evidence and fixes the amount which in their opinion properly compensates the injured party for the loss suffered.

Exemplary, also termed vindictive or punitive damages. This class exceeds the loss actually sustained, and is given as a kind of punishment to the defendant.

Thus, in America, the price to be paid as compensation for an injury is left to a jury trial, which stands unless the verdict be so excessive or grossly inadequate as to indicate passion, prejudice or corruption on the part of the jury.

It will be remembered that it is the province of the courts not only to set aside verdicts which are considered excessive and oppressive, but it is also their duty to set aside such verdicts as, in their judgment, may be inadequate, and it will be of interest to the profession to know that, so far as my investigation has gone in the leading legal authorities on this subject, the highest verdict which is reported to have been set aside was that in favor of a physician.

I refer to the case of Phillips *vs.* London R. R. Company, etc., where a verdict of £7,000 for "injuries sustained by plaintiff through the neg-

ligence of the defendant," was set aside as inadequate on the ground that "the jury must have omitted to take into consideration some of the elements of damage." The plaintiff, who was a physician in the prime of life, having a practice worth perhaps £7,000 ($35,000.00) per annum, was reduced by the injury to a condition of helplessness, with every enjoyment of life destroyed, and with a prospect of a speedy death.

5. Recent judgments in the United States of America by the Appellate and Supreme Courts of the States fixing damages for eye injuries.

I have collected a number of recent cases in which damages were given by the lower courts and sustained as reasonable verdicts by the higher, for injury to vision. One striking thing about this class of cases, so far as the American cases are concerned, is their comparative rarity—at least the number that have found their way into the appellate courts is small.

I can only find two in which a woman was the complaining party. In only one did the appellate court exercise its power in decreasing the amount of damages assessed by the jury. In most of them I think much larger verdicts would have been sustained. On the whole, the verdicts do not seem to be at all liberal in amounts. On the other hand, the plaintiffs in many cases were laborers without great earning capacity.

$5,000 held not excessive. Section boss, 35 years old, lost one eye and had sight of other affected every time he took cold; working capacity was reduced one-half. (No showing in report of any other element of damage.) Johnston *vs.* Mo. Pac. Ry. Co.

$3,000 held not excessive. Porter, age not given, one eye totally lost, use of other more or less impaired, although no finding that impairment was permanent. Expense incurred, $100.00; no proof of loss of earning power. Jones *vs.* St. Louis & S. W. Ry. Co.

$5,000 held not excessive. Farmer, one eye lost; no proof of any damage other than this; court assuming that his earning capacity was impaired. Texas & C. Ry. Co. *vs.* Bowlin.

$5,000 held not excessive. Traveling salesman, 43 years old, earning $190.00 a month and expenses, eyesight of both eyes so seriously impaired as to incapacitate him from business, also severely cut in various parts of body (train wreck). Missouri, K. & T. Ry. *vs.* Huff.

$5,000 held not excessive. Man suffered, apparently, loss of one eye; age not given nor occupation nor any fact in regard to expense or extent of suffering. Palmer *vs.* Delaware & Hudson Ry. Co.

$7,000 held not excessive. Woman, age not given, occupation not given; married or single not stated, suffered loss of sight of one eye and had it permanently disfigured. Injury very painful. Caused by flying glass. Shaw *vs.* Chicago & Grand Trunk Ry. Co.

$9,000 held not excessive. Man, age not given, total loss of sight, earning capacity nor other facts appearing. Stearns *vs.* Reidy.

$3,000 held not excessive. Locomotive engineer, age not given and no data except fact of loss of one eye and consequently disability to perform usual work. E. St. Louis *vs.* Dougherty.

$2,000 held not excessive. Roustabout in mill, 22 years old, one eye, no other data. 70 No. App. 209.

$15,000 recovered, reduced on appeal to $10,000. Laborer, 23 years old, burned in eyes by molten slag, sight of one eye completely gone and the other seriously injured. His own physician testified to there being 30 per cent. normal vision in remaining eye. No data about suffering, expense, etc. Ribich *vs.* Lake Sup. Smelting Co.

$100 was sustained by the Supreme Court of New York for an injury described as a "black eye."

$15,000 was sustained in the case of Wallace *vs.* Vacuum Oil Company, decided by the Supreme Court of New York, in which the injury is described as "the loss of eye and other serious injuries."

$7,000 awarded Coolidge *vs.* Halliner, La Crosse, Wis., Nov. 2, 1906, claimed $15,000 damages for loss of eye inflicted while working on a machine which was allowed to remain out of repair in a pearl button factory.

$12,000 was awarded a young and pretty woman stenographer in the Superior Court of Milwaukee (Dec. 3rd, 1904) for loss of an eye. She had suffered greatly for a long time from inflammation, and the eye was finally enucleated. Suit was brought for $25,000 damages. Olwell *vs.* Skobis.

This verdict is eclipsed by a judgment in Boston of $18,500, given June 10, 1904, to a stenographer for loss of an eye from alleged negligence of a railway corporation. This shows what a sympathetic jury will do for a young and pretty woman.

$13,000 was awarded May 1st, 1909, in case of Magnuson *vs.* Johnson in Seattle for total loss of sight in one eye and partial in the other, due to a blast of dynamite.

$16,333 awarded in case of Finch Haggard *vs.* City of Seattle for partial loss of vision due to cataract produced by defective insulation and jumping of a current in the city electric lighting plant.

$10,861 awarded Emil Corme *vs.* Boston Bridge Works for loss of his left eye by piece of steel from riveter.

LITERATURE.

1. Wurdemann and Magnus, (a) *Annals. Ophth.*, Apr., 1901.
Würdemann, (b) *Trans. Sec. Ophth. A. M. A.*, 1901.
(c) *Journ. A. M. A.*, Feb. 8, 1902.
(d) *Amer. Journ. Ophth.*, Aug., 1902.
(e) *Trans. Internat. Cong. Ophth.*, Lucerne, Sept., 1904.

(f) *Ophthalmology*, Jan., 1905.
(g) *Northwest Medicine*, July, 1908.
(h) *Northwest Medicine*, March, 1909.
(i) Magnus and Würdemann, *Visual Economics*, Mil., 1902.
2. Shastid, Part II, Vol. I, *System of Ophthalmic Operations*, Wood, 1911.
3. Praun, *Die Verletzungen des Auges*, p. 151.
4. Harper, ref. Shastid.

CHAPTER XXXII.

PROTECTIVE LEGISLATION, PENSIONS AND ACCIDENT INSURANCE.

A. Protective legislation. 1. Legal liability of employers—Duties of employers—Place and instrumentalities—New devices—Intended use—Customary methods—Inspection—Ownership of appliances—Hiring co-servants—Rules—Instructions and warnings—Restrictions and employes' rights to recover—Defenses of employees—Assumption of risks—Ordinary risks——Extraordinary risks—Forgetfulness caused by pressure of duties—Contributory negligence—Cause of injury—What negligence bars recovery—Remaining in place of danger—Knowledge of danger—Negligence not imputable—Emergencies—Fellow-servants rule—Common employment—Factors modifying liability—Promise to repair—Contributory negligence. 2. Protective legislation in England. 3. Canadian industrial disputes investigation act of 1907. 4. Summary of compensation acts. B. Pensions. 1. U. S. government. 2. German accident insurance law. C. Accident insurance—Tables.

A. PROTECTIVE LEGISLATION.

Our own workmen are protected by various laws for the regulation of machinery, of different natures in the several states, and in the case of public carriers, as the railway and steamship companies, by the Interstate Commerce Commission and by their own stringent rules, which, however, have more to do with conservation of the public safety and their own goods and machinery than with the individual workman.

Study of the appalling list of accidents occurring annually in American industries has led employers to install many modern devices for making factory work safer and more healthful. The policy of doing this is profitable as well as humane, for it makes workmen brisker and more contented.

Devices have been put into use, moreover, to prevent accidents, and provision has been made to attend to the men injured when accidents occur. Ten years ago an accident would drive a factory engineer away from his throttle at the critical moment. Nowadays a factory girl can shut down the most ponderous engine by pressing a button. Accidents do happen, however, many of them. In the best regulated factories the victim goes to the factory hospital.

In case of negligence being shown on the part of the employer by reason of defective tools, surroundings, or placing the men at extra-

dangerous work for which they have not specially contracted and from which circumstances accidents arise, the workmen are entitled by law to recover some compensation. In all such suits, however, the compensation asked is more, and ofttimes many times the amount, than should be allowed. We claim that all compensation, not alone that to be given as the result of claims at law, but also claims for insurance, should be regulated by the amount of the economic damage.

1. The legal liability of employers for injuries to their employees in the United States of America.

Although the English common law lies at the foundation of our doctrine of employers' liability, this doctrine is continually undergoing change, both by the rulings of State and National courts and by the enactment of numerous statutes passed with a view to a more exact definition of the rights of the employee or to some amelioration of his condition in other respects.

The great volume of litigation on the subject has not effected results of a conclusive character, mainly, perhaps, because of the fact that it is largely an effort to determine the boundaries between the risks assumed under the law by an injured employee and the unlawful negligence of the employer in causing or permitting dangerous conditions to exist. The gradual growth of the doctrine of the duty of the employee's protection by the employer has given rise to a variety of decisions and statutory enactments, with the result that we now have in the United States a body of law and practice that is in effect largely of the nature of a compromise.[1]

The duties of employers.

The briefest statement of the rule governing the employer is that he is required to use due care for the safety of his employees while they are engaged in the performance of their work. This is taken to include all reasonable means and precautions, the facts in each particular case being taken into consideration.

"The workmen's lives, limbs and senses have been sacrificed in a social service. In truth they have been working for every one of us. Have we no responsibility for conditions in the mines and factories? Are the widows and orphans alone to carry the great loss by the death of husbands, fathers, and sons—breadwinners, every one of them? We cannot bind up the broken hearts, or fill the vacant chairs in the home circle. We can, though, be just——and in doing justice we can reduce the number of such horrors. This is not an appeal for alms or charity; only for justice—that and nothing more.

"Some measure of justice can be obtained by making operators liable

for those killed or injured in their service. For every person killed in dangerous trades certain sums fixed by law should be paid to those dependent upon his labor. For every man injured compensation should be paid proportioned to his injury. These payments should not depend upon the fault of any one, except the person killed or injured.

"The present system of liability depends upon negligence. If you cannot prove that the owners were negligent, they are not liable. If one worker was careless, all the rest, no matter how careful they have been, are equally responsible. The whole negligence theory is wrong. It imposes upon those least able to bear it the whole burden in the great majority of cases. Society—you and I—is unjust.

"By making compensation in case of accident an expense of the business, just as much as wages paid, not only owners but the public help to bear the burden. Thus it is distributed and the present injustice is mitigated.

"But the more important consequences are that accidents would become less frequent. That is the experience of countries that have tried the system. The careless and inefficient owner is put out of business. Freedom from accident means ability to produce at a lower cost. Ingenuity and business ability are directed to preventing accidents. The sensitive nerve of the pocketbook is touched.

"Is it not time that America was aroused? In no other country in the world is the disregard of human life so great. The annual sacrifice of lives is appalling. Our system is wrong. The responsibility of every man and woman must be made clear. Public opinion must be awakened. Then the system will be changed. Legislation will compel a greater measure of justice, and these horrors will become less frequent."[2]

Place and instrumentalities—Tools and appliances.

In accordance with the rule as to due care, the obligation rests on the master to supply tools and appliances that are reasonably safe for the intended use, and reasonably well adapted to perform the work in contemplation. These must be provided at the place of use or a place of such ease of access as to be reasonably procurable.

New devices.

The employer cannot be made an insurer, nor is he bound to introduce the newest and safest appliances. The doctrine that the employer is bound to safeguard his employees from exposure to needless and unreasonable risks is subject to the general qualification that one has a right to carry on a business which is dangerous, either in itself or because of the manner in which it is conducted, provided it does not interfere with

the rights of others, without incurring liability to a servant who is capable of contracting and who knows the dangers attendant on employment in the circumstances. The continued employment of tools that are so worn as to increase the danger of their use will in general entail liability on the employer.

Intended use.

Liability attaches only where the injury is the result of the use of an appliance for the work in the manner for which it was furnished. Thus the common practice of allowing workmen on elevators intended only for freight is at the risk of the workmen; so, also, of the use of one ladder for splicing to another when it was intended solely for use alone.

Customary methods.

In close connection with the above is the rule that the employer is not liable to the employee for an injury incurred by a departure from the customary method of performing work, or by leaving the place of his employment to work in some other department, unless on instructions from a properly authorized representative.

Inspection.

The duty of making repairs necessarily involves the duty of discovering the need for them as may arise, which entails the duty of inspection.

Ownership of appliances.

The duty of inspection above considered assumes the ownership of both appliances and premises to be in the employer. Where ownership is divided various distinctions exist, based on the relations of the employer and the owner of the premises or instrumentality.

Besides the duty to use care in regard to inanimate or irresponsible instrumentalities, the employer must also be reasonably and properly careful and diligent to see that each employee hired by him has such qualifications as will enable him to perform his duties without greater risk to himself and his co-employees than the business necessarily involves.

Hiring co-servants.

The disqualifications of persons of suitable age may be mental, moral, or physical, the most common being those that arise from the intemperate use of intoxicants, though habitual carelessness or recklessness, such as

may reasonably come to the knowledge of the employer, likewise charge him with liability.

Rules.

Another branch of the employer's duty is that of providing appropriate rules and securing the carrying out of a suitable system for the conduct of his work. Such rules and practices as are prescribed must be brought to the knowledge of the employe before he is considered to be bound by them, but it may be inferred from circumstances that this has been done. Enforcement of rules is no less a duty than the promulgation of rules in so far as a reasonably careful supervision will accomplish it.

Instructions and warnings.

Besides the general rules by which the conduct of business is determined, instructions may be necessary either in case of abnormal conditions or of the employment of inexperienced persons. The principle lying at the foundation of this duty is the same as in the case of providing appliances, viz., liability does not attach on account of the dangers of the situation, but for placing the employe in a situation of the hazards of which he is excusably ignorant.

Restrictions and employees' right to recover.

Efforts on the part of the employer to make his workmen insurers of their own safety by the adoption of rules or the requirement of contracts releasing the employer from liability will in general be discountenanced by the courts. It has been held that an employer could not relieve himself by contract of a liability imposed by statute, although the statute itself made no reference to such contracts. Where the feature of relief benefits exists a new factor is introduced, and the rulings are quite uniform in favor of the contract. The terms of the contract, in general, are that the acceptance of benefits by the injured employer, and that if action is brought and is compromised or carried to judgment no claim shall lie against the fund.

The defenses of employees.

The principle of the maxim, "Volenti non fit injuria," is of general application, the meaning of the phrase as freely rendered being "That to which a person assents is not esteemed in law an injury." A clearer statement is that by an English judge: "One who has invited or assented to an act being done toward him cannot, when he suffers from it, complain of it as a wrong." In a Massachusetts case the doctrine was thus expressed: "One who knows of a danger from the negligence of another, and understands and appreciates the risk therefrom and volun-

tarily exposes himself to it, is precluded from recovering for an injury which results from the exposure." In brief, the injured person has assumed the risk, and, apart from the contractual relation of employer and employee, there is a considerable class of cases in which the defense to an action for damages may be interposed.

Assumption of risks.

When a contract of employment is entered upon, the law imports into the agreement an assumption by the employee of the ordinary risks incident to the employment, and of such risks as may be known to and appreciated by him.

Ordinary risks.

The determination of what are ordinary risks evidently becomes important in view of the fact that with regard to them the employer is relieved of all responsibility, even if the employee did use ordinary care, unless by reason of inexperience or minority he was not chargeable with having assumed such risks.

Extraordinary risks.

Risks which may be obviated by the exercise of reasonable care on the part of the employer are classed as extraordinary, and these the employee is held not to have assumed without a knowledge and comprehension of the dangers arising from the employer's negligence.

Forgetfulness caused by pressure of duties.

Temporary inadvertence or forgetfulness of dangerous conditions, even if occasioned by the urgency of the situation, is generally held not to relieve the employee from the burden of the assumed risk, though as to this element the courts are not agreed.

Contributory negligence.

When a risk involves such a degree of danger that a prudent man would not assume it, the defense to an action by an injured employee is not that the plaintiff by his contract assumed the risk, but that he was, by his conduct, guilty of contributory negligence. The line is not clearly drawn between the two defenses, nor is it always easy to do so, inasmuch as the facts in a given case may support either defense.

Cause of injury.

The negligence of an employee will not be a bar to his action unless it is the actual and proximate cause of his injury. Conduct merely fur-

nishing the occasion or condition of the injury does not amount to negligence.

What negligence bars recovery.

What does and what does not constitute such negligence as to be a bar to an employee's claim for damages have not been consistently ruled upon by the courts.

Remaining in place of danger.

The general rule that the employee loses his right to a recovery by remaining at work after the discovery of unsafe conditions predicates a duty to leave the service in due time to escape the threatened dangers.

Knowledge of danger.

It is not negligence for one to expose himself to dangers of which he is excusably ignorant; so that even if defects are known to exist the employee may still recover if it appears that the dangers involved were not appreciated.

Negligence not imputable—When?

Attempts to save life, etc. Exposing oneself to danger in the attempt to save life, unless so hopeless that the act would amount to rashness, is not negligence as a matter of law.

Emergencies. In general the fact of an emergency will be held to have a qualifying effect, both of the unusual promptitude of action required and because the mind is likely to become more or less confused under such circumstances.

Necessity, etc. Apparent necessity may justify an otherwise negligent action, unless obviously rash.

The "fellow-servant" rule.

The remaining defense to an employer's action for damages is what is known as the "fellow-servant rule," or the doctrine of common employment.

Common employment.

The first question, then, to be considered is what constitutes common employment. It was said in a leading case that "prima facie, all who enter into the employ of a single master are engaged in a common service, and are fellow servants," but this broad statement will not answer as a conclusive test.

Factors modifying the liability and defenses of employers.

Certain modifying factors may be found to exist in the circumstances of an accident which may affect the rights of an employee and the liability of the employer, but which impinge on so many points that they do not properly fall under any one of the heads above discussed. The most important of these factors will now be briefly presented.

Promise to repair.

In cases where repairs are needed, and the fact is known to the servant, the risk involved in continuing in the service under the conditions of disrepair may be shifted to the employer by his giving a promise to remedy the defective conditions. The effect of the promise is the same whether it is made in response to a complaint by the servant or voluntarily.

Contributory negligence.

It follows from the giving of the promise that the question of negligence, which, apart from the promise, would have been decided adversely to the plaintiff as a matter of law, will be submitted to the jury, and that some reason than mere continuance of work in the position where the injury was received must be presented in order to impute contributory negligence.

2. Prctective legislation in England.

More than a century ago the necessity for legislation destined to protect workers in textile factories was realized. In 1802 an act was passed for the "preservation of health and morals of apprentices" and others employed in cotton mills. The statutes of 1833 and 1845 brought under inspection the manufacture of several materials other than cotton and wool. Subsequent acts regulated employment in print works, bleaching and dye works, and the manufacture of lace; but the acts passed in 1864 and 1867, afterward embodied in the act of 1878 (the principal act), practically included almost every occupation in the country.

In the old days the common law afforded but a poor protection for the working classes; while it held the master liable for his own personal negligence, he was not liable for his servants and workmen, a fact which led to such an amount of agitation for a statutory change that a liability law was enacted in 1880, taking effect January 1, 1881; then followed the workmen's compensation acts of 1897, 1900 and 1906, under the protection of which some 13,000,000 people in the United Kingdom pursue their callings.

The Factory Act of 1891 provided in Sections 9, 10 and 11 what was

universally accepted as a legal remedy based upon principles of humanity, moderation and common sense. Power was given to the Secretary of State to frame special rules and requirements as to dangerous and unhealthy incidents of employment. Penalties were provided for the contravention of special rules duly established. Schedule 1 of the act of 1891 described in minute detail the methods of procedure when arbitration had to be resorted to.

The list of trades scheduled as "Dangerous Trades,"[5] together with the series of special rules legally instituted, is of interest, seeing that the rules were framed after most exhaustive and careful inquiry by experts and scientists, whose opinions commanded respect. Year by year the practical good done by this legislation is more fully realized, as the results of the subsequent acts of 1880, 1897, 1900 and 1906.

The designs of the framers of these acts to keep disputes away from the lawyers has not, however, been a brilliant success; only 13 cases were settled by regular arbitration, 9 by special arbitration, while 1,209 issues came to the county court judges.[5]

3. Canadian industrial disputes investigation act of 1907.

The Canadian Industrial Disputes Investigation Act, to provide machinery for the settlement of labor disputes and to prevent strikes and lock-outs in mines and public-utility industries, was enacted in March, 1907. Although the act has been in effect but a short time, it has already been employed successfully in the adjustment of a considerable number of disputes affecting large numbers of workmen employed in mining and transportation.

5. Summary of foreign workmen's compensation acts.

By the term "workmen's compensation laws" are meant enactments which embody the principle that the workman is entitled to compensation for injuries received in the course of his employment. Such laws have been enacted in twenty-two foreign states and governments.

Usually the injuries must cause disablement for a specified number of days or weeks before compensation becomes due. The employer may usually be relieved from the payment of compensation if he can prove that the injury was caused intentionally or by willful misconduct, or, in some countries, by the gross negligence of the injured person or during the performance of an illegal act.

The industries usually covered by the acts are manufacturing, mining and quarrying, transportation, building and engineering work, and other employments involving more or less hazard. In Belgium, France, and Great Britain the laws apply to practically all employments. In Austria, Belgium, Denmark, Finland, Germany, Italy, Luxemberg, Netherlands,

Norway, Russia, Spain, and Sweden only workmen engaged in actual manual work, and in some cases those exposed to the same risks, such as overseers and technical experts, come within the operations of the law. On the other hand, in France, Great Britain, the British colonies, and Hungary the laws apply to salaried employees and workmen equally. Overseers and technical experts earning more than a prescribed amount are excluded in Belgium, Denmark, Germany, Great Britain, Italy, Luxemberg, and Russia. Employees of the state, provincial, and local administrations usually come within the provisions of the act.

The entire burden rests upon the employer in all but four countries—Austria, Germany, Hungary, and Luxemberg—where the employees bear part of the expense. The laws in every case fix the compensation to be paid. Except in Sweden the compensation is based upon the wages of the injured person. It consists of medical and surgical treatment and periodical allowances for temporary disability, and annual pensions or lump sum payments for permanent disability or death.

LITERATURE.

1. Lindley D. Clark, *Bull. U. S. Bur. Labor,* No. 74, Jan., 1908.
2. Editorial, *Seattle Star,* Nov. 12, 1909.
3. Würdemann, writings.
4. Barnett, *Accidental Injuries to Workmen,* London, 1909.
5. F. Oliver, *Dangerous Trades.*

B. PENSIONS.

1. Pensions by the United States Government for disability due to the eyes are at the following rates:[1]

Total blindness of both eyes, $100.00 per month; loss of sight of one eye, with loss of eyeball or destruction of same, $17.00 per month; loss of sight of only one eye, $12.00 per month. Partial disability from accident or disease of the eyes, $2.00 to $72.00 per month, depending upon the estimated degree of disability in respect to manual labor, estimated empirically.

4. The German accident insurance law.[2]

Several years ago the appearance of German medico-legal essays upon accident insurance called my attention to the paternal system in vogue in the German Empire, and especially to the law of July 6, 1884. "Consider the advance in the general spirit of kindness which is indicated by such a fact as the founding and successful operation of the system of Workingmen's Insurance in Germany. A certain sum of money is set aside for each workman every week (the employer and the employee each contributing half), and the government adds a supplement of $12.00 on each pension. Ten million workmen are thus insured against sick-

ness; seventeen million against accident; ten million against disability from old age. Six hundred and seventy thousand persons receive the benefit of this fund in yearly pensions. Incidentally there has been an immense benefit in the increase of care and precautions to prevent accidents and to reduce dangerous occupations. The employer who is not yet willing to protect his workmen for kindness' sake will do it to escape heavier taxes. And the community which silently compels him to do this, the community which says to the laboring man, 'If you will perform your duty, you shall not starve when you are sick or old,' is certainly growing more kind as well as more just."

Paragraph 5 of this law defines its intentions as follows: Compensation for the loss resulting from bodily injury or death is to be adjusted according to the following provisions:

1. The cost of necessary treatment commencing at the beginning of the fourteenth week after the accident. It will be noted that this insurance law deals only with the results of accidental injuries after the fourteen weeks have elapsed from the date of the accident; the reason for this may lie in the fact that most German manufacturers pay their city hospitals certain sums (which have been retained from the workmen's wages) for the care of their sick employees, and indemnification for accidents is considered due only after the lapse of fourteen weeks.

2. A regular income to be paid to the injured person from the beginning of the fourteenth week during the time of his inability to work. The wording of the law shows that neither the injury itself nor any temporary results, such as the detention from work or the expense of treatment up to the fourteenth week thereafter, is considered grounds for indemnification, but it relates solely to effects when they have a more permanent detrimental influence upon the earning powers.

Section 2, Paragraph 5, shows that the law-makers had no other intention and the law should not be interpreted in any other sense. The law does not mean that under all circumstances injured persons should receive indemnification.

LITERATURE.

1. Lyman F. Ware, U. S. Commiss. Pensions. Personal communication, Apr. 19, 1904.
2. Deutschen Strafgesetzbuch, 1884, et seq.

C. ACCIDENT INSURANCE.

Accident insurance in America.

Accident insurance in American and British companies is a purely mutual and financial arrangement made between the applicant for insurance and the company that underwrites the policy, whereby the applicant agrees to pay a certain amount annually, usually in one payment, but which in some companies may be by monthly or quarterly payments, and

in others by assessments called at times by the officers when the exchequer of the company needs replenishing. This contract is either a valued policy fixing a definite sum in the event of loss of vision in one or both eyes; the loss of an arm, or a leg, or other bodily organ; or a definite weekly indemnity for total or partial loss resulting from injuries. The principal amount is paid when the injury totally disables the insured from performing all his duties; and when it disables him from performing one or more, partial indemnity is paid. This rule naturally holds in other than ocular cases.

The estimation of pecuniary indemnity in cases of partial or complete loss of vision from accident depends upon the form of policy which the insured has purchased. Some of the companies grade their patrons into various classes, according to their occupation. If, for instance, this is such as to entitle the insuree to the select or preferred classes, the indemnity payable for loss of sight of both eyes is equal to the full amount of the insurance, being placed upon the same basis as a fatal accident.

To those who are conversant with the scientific estimation of the resultant economic damage from injuries to the eyes, it is remarkable that the exact mathematic demonstration shown by the methods of Magnus so nearly coincides with the empiric amounts allowed in the law courts and by accident insurance companies, especially for the loss of one or both eyes. All the companies give the full life indemnity for total blindness of both eyes, thereby recognizing the fact the visual earning ability is synonymous with the total earning ability.

The loss of the entire sight of one eye is compensated for by payment of one-eighth to one-half of the amount that would be paid for death or loss of both eyes. If the loss of sight be temporary and results in the insured being unable to perform the duties of his occupation, he is indemnified for loss of time only, just as though he were injured in any other organ.

A number of companies issue policies for loss of an eye or other organs, or loss of time from disease, which are called "health policies," the indemnity as a rule not exceeding 100 weeks of total disability.

Payments by insurance companies for loss of sight were originally arbitrarily fixed by a few companies, and others have followed in their lead, all of them being materially governed by the same rules.

There are fifty-five casualty insurance companies doing business in the United States, of which twenty-four are stock accident insurance companies and thirty-one assessment accident associations. I have corresponded with all of them, receiving specific replies to the following questions. The answers, together with their names and the amount of personal accident premiums they received during the year 1907, are herewith abstracted and tabulated:

STATISTICS O[illegible] ASSESSMENT AND ACCIDENT INSURANCE COMPANIES

[illegible]

REMARKS

[illegible]

CHAPTER XXXIII.

VISUAL ECONOMICS.

DETERMINATION OF THE RELATION TO AND AMOUNT OF ECONOMIC DAMAGE RESULTING FROM INJURIES TO THE EYES AND VISION.

A. Status of the physician in relation to estimation of economic damage and indemnity. (1) The proper position of the physician—(2) Present status in Europe—(3) Empiricism and precedent of present judge and jury methods in America and British countries. B. (1) Methods for scientific estimation of economic damage—(2) Recent comments upon ocular accidents and indemnity. C. The Magnus and Würdemann method for mathematical estimation of economic damage. (1) Relationship of vision to the earning ability—(2) Economic value equivalent to wages—(3) Factors in economic vision—(4) Estimation of damages to economic vision—(5) The formula of Magnus—(6) Examples—(7) Estimation of the pecuniary loss to the individual by reason of visual imperfections—(8) Examples—(9) Resumé.

A. STATUS OF THE PHYSICIAN IN RELATION TO ESTIMATION OF ECONOMIC DAMAGE AND INDEMNITY.

(1) The proper position of the physician.

The question by whom this estimate should be made may perhaps be taken up here. The average physician is an educated man who is not only competent to judge of the nature of an injury, but of its relations to the earning capacity. The physician acquires a certain knowledge of the peculiarities of the different trades in his daily work, as there are but few vocations with which he does not come in contact. Of what use is it to tell a jury that a certain person has suffered from paralysis of the musculus rectus externus sinistra? Technical physiological knowledge is certainly needed to judge of the relations between the laming of an ocular muscle and its effect upon the person's work, and verily we cannot expect the tradesman or the average citizen to have a scientific mind. It is the province of the physician to estimate the proportional loss of earning ability resulting from disease or traumatism. The question of monetary compensation may be left to the business corporations and the courts of law after the opinion of the physician has been expressed.

If we can establish the foregoing, what would be the legal standing of the subject, and what should be the relation of the probable economic

damage to pecuniary compensation for the results of accidents to the eyes?

Such expression would not be established as a fact, but would be a matter of expert opinion and be considered as such in law.

Physicians are not only called into court to give evidence as to questions of fact, but also for opinions upon probabilities. For instance, we may testify that a certain client has become totally blind, or that his visual acuity or visual field has been reduced to a certain amount; such a statement is accepted as a fact; but when we enter into the actual effect or probable result of the diminished vision upon the working or earning ability, there is always the question of personal opinion. If, however, by the acceptance of rules such as we give, a certain general opinion may be established, it will be accepted in the courts as the highest and best opinion obtainable, and will be almost as strong a statement as an actual fact, and due weight will be given to it in instructions to the jury.

(2) The physician's status as to this estimation in Europe.

We are not living under a paternal government such as obtains in Germany, Austria and France, and even in England, where every working man that may be injured is supposed to receive a certain compensation, depending upon the amount of damage to his earning powers; more especially Germany, whose advanced paternal laws and system of pensions to working men require of the physician, especially the ophthalmologist, a most thorough knowledge of these matters. The degree of damage resulting from alleged injuries is required in connection with pensions for the army and navy, in countries where troops are conscripted, and occasionally in private practice it is an essential requirement of the educated and up-to-date physician.

(3) Empiricism and precedent of present judge and jury methods in America.

In America and in other countries the estimation of the damage done by accidents in legal cases is left to the empirical dictum of the judge, who is guided by precedent, and to the sympathies or prejudices of the jury, which may be aroused by the attorney presenting the case, pain of body and anguish of mind being apparently very important factors.

Therefore, even though we may scientifically establish the percentage of economic damage and express it in pecuniary terms, the other factors will be considered by the courts. We hold, however, that the economic damage should be the basis upon which claims should be allowed, modified by the importance of the other factors. By reckoning these factors, we think that we can estimate, in a manner fair and just

to all parties, the amount of damage to the earning ability which may have occurred as a result of accidental injuries to the eyes, and that this should be considered the principal factor in the settlement of legal claims.

B. METHODS FOR SCIENTIFIC ESTIMATION OF ECONOMIC DAMAGE.

(1) Attempts at solving the amount of injury to the earning ability by mathematical means have been made by a number of authorities, among them Zehender, Groenouw, Heddaeus, Berry, Percival, Sulzer, Axenfeld, Schleich, Hummelschein, Magnus et al. I have collaborated with the latter, whose formula seems to give the most satisfactory estimate, and one which agrees very closely with the results of examination into the character of the accident and inquiry into the subsequent earning power of workmen, and with the empiric pecuniary damages awarded by courts, and with pensions and policies given by accident insurance companies.

Within the present limits we cannot take up all the arguments for and against the various mathematical theories, but refer the reader to the work of Magnus and Würdemann[1] on *Visual Economics,* and to the *Transactions of the Tenth International Ophthalmological Congress,* held in Lucerne in September, 1904,[2] when this subject was chosen for discussion, the essays being by Sulzer,[2a] Axenfeld,[2b] and Würdemann;[2c] to the author's published writings; and to the rather extensive essays which are mostly in German literature.

These mathematical theories have been variously assailed, the objection to all of them being the empirical assumption of data which, depending as it does upon personal observation and upon disease or injury to living structures, cannot be absolutely exact.

The main trouble with all these formulæ is, as Prof. Huxley remarks, "The result you get out of the mathematical mill depends entirely upon what you put into it." Be this as it may, the results obtained by mathematical calculation, according to the methods of Magnus and Würdemann, agree very closely to those of experience, and may be taken as the basis for economic damage upon which claims may be allowed.

(2) Recent comments upon ocular accidents and indemnity.

Bettremiux[3] says commentators on the law of accidents generally submit that it is not possible to determine the condition of the subject prior to an accident when one has to fix the indemnity due to the injury. The author goes over the ground thoroughly and shows that many conditions existing previous to the injury might increase the defect and yet without the injury these conditions would not (might not) be a factor to a decreased earning capacity of the individual.

Hummelsheim[4a] holds that no formula will cover all cases. Much depends upon the occupation and station in life. Callings with high visual requirements are to be most highly estimated. Visual acuity of 1/100 or less is occupational blindness. In the young it is especially necessary to strongly individualize. The question of the necessity for stereoscopic vision is to be considered, and, it is to be remembered, the impairment of earning capacity induced by the loss of this faculty is transient. Schemes to estimate the loss sustained by visual field defects and disturbances of ocular movements do not, as a rule, correspond with the facts. Right hemianopsia in the right-handed is more serious than loss of the left field. Disturbances of convergence and infraduction cause great injury, while in mountaineers paresis of the elevators is especially damaging.

Fischer[4b] said that the original estimate of ½ and later ⅓ was based upon philanthropic and philosophic grounds, yet the loss of an eye must never be estimated at zero, even though history records that Hannibal and Philip of Macedon each had but one eye. The loss of an eye halves the reserve fund, and the remaining eye may later be lost outside of business or through disease, for which no claim can be made. At the present time there is again a tendency to place a high value on the loss of an eye. For a long time a differentiation has been made between unskilled and skilled labor, the first obtaining 25 per cent., the latter, among them miners, 33⅓ per cent. Annoying diplopia calls for not more than 20 per cent. In detachment of the retina from traumatism the predisposition of myopic eyes is to be taken into consideration. This writer goes fully into the difference between accidents and occupational disease. Lead poisoning and nystagmus are not accidents.

Nieden[4c] stated that 33⅓ per cent. was originally merely a sentimental estimate. A differentiation based on statistics he considered difficult, but of value. Mayweg[4d] expects but little from statistics. Stood[4e] feared that a statistical basis would place the normal compensation too low. Baker[4f] favored a statistical basis. Hoedrath[4g] suggests grouping together cases of similar injuries received in different manner, and, where possible, by workers in the same branch.

Schleich[5] expresses his opposition to the general opinion that the exclusive use of one eye for work can have an injurious effect upon that eye. He suggests the following scale of compensation for diminished vision, caused by an injury to the eye: 1. The capacity for earning is diminished when, as the result of injury, the power of vision decreases to 4/x. 2. In injuries of both eyes when their combined power of vision is below ⅓. 3. The damages for the loss of one eye must be higher when the vision of the other eye is not normal. 4. In cases of aphakia with a power of vision of ½, the damages should amount to 10 to 15

per cent. of the patient's previous income. 5. In aphakia of both eyes, about 50 per cent. 6. The loss of both eyes, 100 per cent. 7. The loss of one eye, 25 to 35 per cent. 8. The loss of binocular vision, 10 to 15 per cent.

Deschamps[6] calls the attention of oculist experts to this matter where there is a form of incapacity for work which has so far not been recognized and of which the law (French) says nothing. Deschamps refers to a partial temporary incapacity, lasting more or less long. The rule is that after an injury the workman ceases all work until the wound is consolidated, which term is that used before the tribunal, and during the lapse of that time the workman is considered as totally disabled and is paid an indemnity equaling his salary. That after consolidation is reached, no further indemnity is received, as very often the workman is just as able to work as before the accident. There may exist a permanent partial incapacity, in which case the indemnity should equal the difference between the former salary and the present worth. It is to establish the question of this permanent partial incapacity that tribunals ordinarily have recourse to experts.

He states that when he has been charged by a tribunal to act as an expert, he has been struck by the fact that the wound had been consolidated, but that there had been a corneal infection; that the man was unable to return to work; that there might exist a lowered V.—in other words, a partial though permanent incapacity which will justify a varying indemnity; that there may be photophobia and ocular fatigue.

Deschamps saw one case of injury in which there was infectious keratitis that had been treated with subconjunctival injections resulting in curing the ulcerations, but which provoked the appearance of hyperopia in the injured eye. The V. in each eye was good when used separately, but together, vision was had with discomfort. This latter was removed by the aid of a weak convex glass. Here, then, was a case of six months' standing in which there was partial temporary incapacity that disappeared at once. The judge had concluded that the workman was not able to return to work until the end of six months, and allowed a half salary indemnity during that time. But Deschamps thinks this was unjust to the employer or the insurance company.

LITERATURE.

1. Magnus and Würdemann, *Visual Economics* (and the author's essays)
2. a. Sulzer, *Trans. 10th Internat. Ophth. Cong.*, Lucerne, 1904.
   b. Axenfeld,
   c. Würdemann,
3. Bettremeiux, *La Clin. Ophthal.*, Aug. 10-25, 1908.
4. a. Hummersheim, *Trans. Rhein-Wesphal. Ophth. Gesell*, 1904, *Woch. f. Ther. u. Hyg. d. Aug.*, No. 22, 1904.
   b. Fischer,
   c. Nieden,
   d. Mayweg,

e. Stood,
f. Baker.
g. Hoedrath,
5. Schleich, *Wien. Med. Woch.*, July 28, 1906.
6. Deschamps, *La Clin. Ophth.*, July 10, 1904.

C. THE MAGNUS AND WURDEMANN METHODS FOR SCIENTIFIC ESTIMATION OF ECONOMIC DAMAGE.

Upon the use of the organ of vision depends the earning powers for the large majority of trades and professions; thus earning ability is economically synonymous with visual earning ability.

(1) Relationship of vision to the earning ability.

It is self-evident that a totally blind person is absolutely incompetent in any trade or profession requiring eyesight. An economically blind person—i. e., one whose visual acuity is less than 5 per cent. of the normal—is in the same position; for, although he may be able to get about, the vision is not sufficient to allow of even the lowest grade of remunerative work. The vast majority of blind people are not only incapable of earning anything, but are a charge upon their families and upon the community. It is true that there are certain exceptions to the above proposition. There are, and have been, blind persons who have become poets, machinists, chair-makers, broom-makers, etc., but cases that have become economic factors are so unusual as to be commented upon in the public press and held up as especially talented and well-placed persons, who, by great labor of their teachers, and by their own exceptional diligence, have been so highly educated as to be able to meet, in a measure, with the competition of normal individuals. In the case of an adult suddenly becoming blind, his previous economic education goes for naught, and he at once steps out of the ranks of workers.

Nearly all trades and professions require good eyesight; even the coarsest sort of labor being affected if the vision falls below 50 per cent., and being impossible if it is below .05 per cent. of the normal visual acuity. For finer kinds of work, the visual range is between 75 per cent. and 15 per cent. A working man who either suddenly or gradually becomes blind loses his job, and with it his earning ability. Aside from the loss of time and wages ensuant upon the injury and convalescence therefrom, poor sight certainly affects the amount and character of work, the quality and output diminishing in a direct ratio to the loss of sight, until a degree is reached where the person cannot work any more. The remuneration for work necessarily depends upon its amount and its quality. Thus injury to vision generally necessitates loss of earning powers.

(2) The economic value of vision is equivalent to the wages of the individual.

The pecuniary value of a man's life may, for our purposes, be expressed by the amount of money that he may earn in the course of his life. We stated above that the visual earning ability was economically synonymous with the full earning ability and we may thus value vision with the pecuniary valuation of life.

We may say that "sight is priceless" and "vision is not a commodity that may be purchased or disposed of in the market;" for there are few persons who would voluntarily allow of the infliction of any unnecessary bodily injury for any compensation whatever; but such matters of ethics do not fall within the pale of our persent discussion. We are dealing with the established economic fact that injury to vision of more than a certain extent necessitates limitation of the amount and character of work. Following upon this, it is easily deduced that the amount of wages received would be less.

The question now arises, how are we to reckon the loss of wages? This we may do from experience in examining large numbers of individuals. It has been found that the loss of vision of a certain amount results in a certain effect upon the earning ability of the individual. We may also deal with futurities, and figure the probable loss in any given case by finding the percentage of damage to the normal function, and apply our reasonings to the calculation of the probable pecuniary loss. In order to do this, we have accepted the visual earning power as equivalent to the total earning power.

(3) Factors in economic vision.

We must next see if the visual act may be divided into factors; estimate the relation of these factors; and build up a working mathematical formula for the purpose.

First, and most important, of the visual factors is the central visual acuity; next in importance is the visual field; and next the ocular motions. There are secondary factors concerned in the act of seeing that are physically of importance, which are the cerebral vision, the sense of light and color, and that of adaptation. Accidental injury limited exclusively to any one of these factors is certainly not recognizable; for where such takes place, other portions of the visual act, especially the visual acuity, and the field, are implicated. Therefore we include the secondary functions when we treat of injuries to the three primary factors of vision.

These are not of equal value, the visual acuity being the most important, the visual field next, and the ocular musculature being of less importance. We have established a formula for the normal act of seeing in which these factors have been given their relative valuations. In

relating this to the earning ability, we have to add another factor of great importance, which is the ability to use the vision for gainful purposes—i. e., the ability to compete in the labor market. We consider this portion of our formula to be made up of several factors of sight expressed in their mathematical relations, and have added this to our formula in such a way that an individual expression may be given to each case. This is a variable quantity, as it not only depends upon the ability to use the eyes in working, but upon the opinion of the employer as to the effect of the injury upon the amount of work he may expect to get out of the laborer.

It is well known that we can exactly estimate the visual acuity by the Snellen standard of test letters; that we can measure the visual field by the perimeter; and that we can value the amount of muscle defect.

The act of vision and its relation to earning is of a complicated nature. We cannot make exceedingly simple formulæ without doing damage to nature and to truth. The reasons for our opinions as to the relations between visual factors and the ability to compete are too many and too long to enter into here. Suffice it to say, that we believe we have established a mathematical formula for the ocular earning ability which agrees very closely with results that have been obtained from examination of a large number of cases, especially those having ocular defects occurring from accidents. This mathematical expression is as simple as the complex act of seeing and of competing in the labor market will allow; and, when helped out by our mathematically exact tables and diagrams, is reduced to a simple example in multiplication that any educated person can readily and quickly calculate.

(4) Estimation of damage to economic vision.

Normal physiologic vision consists of a series of different factors: the central acuity, the visual field, light and color sense, the adaptive faculty, the muscular movements and cerebral processes, all acting together in creating the sense of sight. We may, therefore, regard the act of seeing as a sum whose numerals are formed by the different functions; if one numeral be taken from the sum which represents the complete act of seeing, then a balance will be left and vision will be damaged to the extent of the loss of one function, but in a limited way it is yet in existence. In the development of a formula for physiologic vision we have to consider that in losing simultaneously the two most important factors, central and peripheric vision, the act of seeing would be nil; but in the estimation of economic vision we have to use a different method, for the different secondary functions forming sight have different valuations. In calculating injury to the visual earning ability, we have to exclude cerebral vision because accidental injuries to the cerebral cen-

ters alone are so very rare. The sense for light and color and that for adaptation are not of themselves to be considered in estimating accidental damage to the ocular seeing ability. Injuries limited exclusively to these functions are not known; theoretically they are possible, but practically they are not recognized, and if they occur they would be connected with disturbances of other parts of the visual act, especially the visual acuity and the visual field; therefore, we include the functions of the light and color sense, and of the adaptive power, when we take the central visual acuity, the visual field and the muscular movements. These are to be regarded as factors of a product, and multiplied; none of them could be left out, for without them the earning ability would disappear. If a person loses his central acuity, we certainly have complete earning disability, for a large central scotoma certainly causes economic blindness; total paralysis of the ocular muscles would keep the eyes immovable and prevent work. Great contraction of the visual field, so that only central vision is left, certainly prevents the person earning anything by the aid of his eyes.

(5) The formula of Magnus.

Magnus therefore evolved a formula, which we have accepted as the simplest and most appropriate, which considers the visual earning ability as composed of the several factors entering into vision, together with the ability to compete, expressed as an arithmetic equation;—Thus:

$E = F \sqrt[x]{K}.$

E = Earning ability = Ocular earning ability.

F = Visual act.

$\sqrt[x]{K}$ = Ability to compete.

$F = C_{(maximum)} \sqrt{P} \sqrt[x]{M}$ = Physiologic act of vision, in which

$C_{(maximum)}$ = Maximum acuity of the better eye;

$\sqrt{P}$ = Binocular visual Field;

$\sqrt[x]{M} = \sqrt[4]{M}$ = Normal value of ocular muscles;

This is modified by the ability to compete:

$$\sqrt[x]{K} = \sqrt[x]{\frac{C_1 + C_2}{2} \sqrt{P} \sqrt[4]{M}.}$$

in which $\frac{C_1 + C_2}{2}$ = the added acuities of both eyes; $\sqrt{P}$ the visual field, and $\sqrt[4]{M}$ the muscular action. The complete formula for the ocular earning ability being

$$E = C_{(maximum)} \sqrt{P} \sqrt[4]{M} \sqrt[x]{\frac{C_1 + C_2}{2} \sqrt{P} \sqrt[4]{M}.}$$

which is the mathematical expression of the earning ability and which may be readily calculated by anyone who can do a simple algebraic equation, as it is reduced to a simple multiplication example by using tables which have been compiled for the purpose, as the algebraic signs are replaced by figures which are readily found therein. The roots are readily calculated or may be found in our tables.

(6) Examples.

From this formula we figure, for example, that a one-eyed person has lost 30 per cent. of his earning ability for the first year after the accident, and 20 per cent. afterwards for the higher class of trades, and for the lower class the proportion would be 27 per cent. for the first year and 18 per cent. thereafter, and the effect of all other injuries to the eyes and vision upon the earning ability of the individual.

In the case of the loss of one eye our valuations admit, after one year, of a reduction, because those muscular functions which were formerly executed by both eyes are partly or entirely restored. The figures of 21.97 per cent., or 18.39 per cent., should be regarded as a maximal limit to which the damage may be reduced. Sudden total loss of one eye is of more economic damage to the individual than where the sight gradually goes. We have figured that the impairment of the earning ability from the gradual loss of sight in one eye following an accident in trades requiring higher visual demands is 21.97 per cent.; in professions with lower visual demands 18.39 per cent. Our figures are much lower than those given by previous impractical methods, for there was a time when 50 per cent. was regarded as a valuation of the lass of one eye, and even now the German Insurance Office gives a rating of 33⅓ per cent.

If such a formula may be made, how may we express the amount of damage to the working powers of the individual so that it may be understood by the ordinary jury and used as a basis upon which to adjust claims for damages to vision resulting from accidents to the eyes?

This may be done both by expressing the percentage of loss to the earning ability and by calculating its pecuniary effect upon the prospective wages of the workingman.

(7) Estimation of the pecuniary loss to the individual by reason of visual imperfections.

It stands to reason that we may express the loss to the earning ability both in percentage and in dollars and cents by calculating the prospective loss of wages to the working man. Money being the world's medium of exchange and of valuing a man's work or time, we must reduce the economic damage in each individual case to its value in dol-

lars and cents, or the monetary medium of the country in which the compensation for damage may be sought. It goes without saying that the value of men's time and wages differs greatly, not only in different trades and professions, but even the various members of the same trades receive varying wages.

If we wish to exactly estimate the damage to the individual case, we must, therefore, figure with the compensation that the individual himself has been getting and his probable future earnings. It must be allowed that this may be done and that this estimate may be legitimately used as a basis with which to calculate the pecuniary loss he may sustain by reason of lessened working and earning ability. In the case of artisans and the working classes generally, it might be considered strict justice to the defendant to take the average earnings of the class to which the plaintiff may belong as a basis upon which to figure the indemnity.

In dealing with money matters a number of other questions arise. May we figure upon the probable duration of working life and consequent remuneration therefor? Numerous industrial corporations have estimated such probabilities—as the life, and accident insurance corporations, which have been so successfully managed from both the philanthropic and pecuniary standpoints.

In the case of an accident involving damage to the earning ability, the prospective loss is greater to a young man than to an old one, and this loss is dependent upon the age of the individual as well as the amount of corporeal damage, as an old man will have but a few years more of working life, even though he lives to the Biblical limit. We have, therefore, established an average age at which working life is supposed to cease. Hence in our calculations as regards possible pecuniary damage, not only the percentage of loss to the earning ability is calculated, but this is also applied to the probable future earnings of the working man figured from the date of the accident to the probable termination of his working life.

We cannot figure upon the damage to ambition, to treasured hopes and plans, in calculating the economic damage—the probabilities of successful achievements are too small. The ambitions of our youths are so varied; thousands of young persons are doing, temporarily, more or less low grades of work, with the expectation of some day getting work of a higher class which may be more remunerative. By far the greater number remain in the same station of life in which they started. There are thousands of young men whose ambition lies between that of President of the United States and the turnkey of some provincial jail. In our profession, it is the ambition of one man to be one of the foremost surgeons, while others have to be satisfied with practising in some obscure

village. We can only consider the facts that have existed before the accident and the station of life in which the working man may have been at that time. To this may be added the probable working life and percentage of damage to the earning ability for the calculation of the economic damage. The law, however, does not deal with this alone; it also allows damages, depending somewhat upon precedent, for pain and mental anguish, and upon philanthropic and punitive reasons, as well as upon evidence as to physical damage that may have been sustained. Therefore, even though we may scientifically establish the percentage of economic damage and express it in pecuniary terms, the other factors will no doubt be considered by the courts. We hold, however, that the economic damage should be the principal basis upon which claims should be allowed, modified by the importance of the other factors. As regards insurance companies, the amount allowed depends upon a business contract between the parties, as before shown.

(8) Examples.

EXAMPLE 1. For our first example we take a case that often comes up in the courts of law. An artisan whose business has higher visual demands, who has previously had normal vision, receives an injury to one eye while working at his trade, by which the sight of the injured eye is wholly lost, the vision in the other remaining normal. The question then arises, what economic damage has this man sustained?

We have shown that in the higher class of trades, during the first year following the accident, a one-eyed person lost 30 per cent. of his earning ability and afterwards the loss may be reckoned as 20 per cent. As a matter of convenience we will suppose that this man is injured at the 30th year of age, and that he has been earning for the previous five years $1,000.00 a year, with the expectation of earning this sum annually until he is 50 years of age, when for the next 15 years his average earnings, on account of disability, due to age and the competition of younger workmen, will fall to $750.00 a year and his working life is to cease at 65 years. His total earnings for the balance of his life would then be reckoned as follows: 20 years at $1,000.00 a year; 15 years at $750.00 a year; total, $31,250.00. For the first year after the accident instead of earning $1,000.00 he may expect a loss of 30 per cent. ($300.00) and for the following 19 years instead of earning $19,000 he would lose 20 per cent. ($3,800) and the following 15 years instead of earning $11,250 he would lose 20 per cent. ($2,250), making a total loss for the thirty-five years of working life of $6,350.00, which is his personal economic damage, an amount which discounted at bank rates for cash, or used as the basis for an annuity he might reasonably demand as an indemnity for the loss of earning ability due to the accident, if liability

of the employer or defendant could be proven. This sum should be used as the scientific basis for settlement of contested cases; modified according to American law by a reduction being made in favor of the defendant in case of extenuating circumstances or contributory negligence and an addition made thereto for actual expenses incurred by the plaintiff during his illness and damages for the pain and anguish suffered by reason thereof. These amounts must always be empirically estimated by the courts.

EXAMPLE 2. If this man were injured at the age of 40 the same method of calculation would give him a prospective compensation of $21,250.00 for the balance of his earning life, instead of which, for the first year he would receive $700.00, for the nine years more, $7,200.00, and for the fifteen years following $9,000.00; making a total economic value of $16,900.00, a resulting economic damage of $4,350.00.

EXAMPLE 3. If this man were injured at the age of 50, instead of his prospective compensation being $750.00 per year for fifteen years, or $11,250.00, for the first year after the accident he would be earning 30 per cent. less, or $525.00, and for the following fourteen years 20 per cent less, or $8,400.00, making total economic value of $8,925.00 and total economic damage of $2,325.00.

By the use of different rates of compensation and different years other examples could be readily given. The same method of reasoning applied to the loss of one eye in case of an artist or other professional man would yield proportional results. The only difference in the calculations would be the fact that such professions usually become more remunerative as the person grows older. In the case of the common laborer, the only difference would be the lower rate of compensation and the figuring of his economic loss at 20 per cent. for the first year after the accident and 18 per cent. thereafter.

We will now go on to the calculations involved in more complex cases where the same principles are to be used as those which have been invoked for simple cases:

EXAMPLE 4. We will take the case of an architect or draughtsman, in his 46th year of life, earning $3,000.00 a year, whose visual acuity in one eye is reduced by an accident to 0.50, the other remaining normal. His profession demands good vision and he is in a measure handicapped for some of his work, especially that of fine draughting. We will proceed to work out this case from the beginning and will, therefore, recapitulate our formula:

$$E = C\sqrt{P}\,\sqrt[4]{M}\sqrt[x]{\frac{C_1 + C_2}{2}\sqrt{P}\,\sqrt[4]{M}}$$

In this case the maximum C remains unchanged because this is the higher visual acuity of the sound eye=1. $\sqrt{\ }\overline{P}$ the visual field, and $\sqrt[4]{\ }\overline{M}$ the muscular action remain unchanged; the three factors each representing the Value I. In this case the unknown quantity is the ability to compete,

$$\sqrt[x]{\frac{C_1 + C_2}{2}\sqrt{P}\ \sqrt[4]{M}}$$

$\frac{C_1+C_2}{2}$ being the arithmetical proportion of the central visual acuity of both eyes. C_1, the uninjured eye remains=1; C_2 the injured eye should be reduced to 0.50 of the scientific value 0.5, of the scientific standard. Looking now on plate, on the abscis for the scientific value 0.5, we trace this line upwards until we meet the economic curve II, which is for vocations having higher visual demands, and from the point where the line cuts the curve we go to the left and find there on the ordinate the economic value of the scientific estimation for the acuity of vision. This is 0.58; inserting this value into the arithmetical proportion of the acuity for both eyes, into $\frac{C_1 + C_2}{2}$ we have $\frac{1 + 0.58}{2} = 0.79$. This we insert into the factor $\sqrt[x]{\frac{C_1 + C_2}{2}\sqrt{P}\ \sqrt[4]{M}}$; we then have $\sqrt[x]{0.79\ \sqrt{P}\ \sqrt[4]{M}}$ in which $\sqrt{\ }\overline{P}$ and $\sqrt[4]{\ }\overline{M}$ are each = 1; the whole value is then

$$\sqrt{0.79 \times 1 \times 1}$$

As this is a slight injury, the ability to compete is only partly impaired, so we make the root exponent X = 10. This value $\sqrt[10]{0.79 \times 1 \times 1}$ we can find in plate II, curve V, where we look on the abscis for the value 0.79, trace the line from there upwards until we meet the curve V, going from there to the left on the ordinate we find the value 0.972. If we insert this value into the formula we would find $E=1\times1\times1\times0.972$, which multiplied by 100 gives the earning ability E=97.2 per cent. This man being injured at his 46th year, he would expect to earn $60,000 during the next twenty years. His earning ability being reduced to 97.2 per cent, he would probably earn $58,320.00, which subtracted from the reasonable expectations of his business, would leave the sum of $1,680.00, an amount which he might expect as the indemnity for the loss of earning ability due to the accident.

EXAMPLE 5. A traveling salesman, 45 years of age, who recently consulted me, had bi-nasal hemianopsia with a remaining central acuity of 0.20 in both eyes. He stated that he had this condition for a number of years and was enabled to do all his work satisfactorily until recently,

when the visual acuity had failed from what he thought was normal, to 0.20. He was now able to get about and sell some goods, but largely from memory, as he could not read his business catalogues and letters, and was about to give up his business entirely. His income depended upon sales made and was about $2,000.00 a year. Thus for the balance of his working life his expectations would be for 20 years at $2,000.00 a year, amounting to $40,000.00. According to his experience he was able to do all his work until the visual acuity failed. As nasal hemianopsia does not necessarily incur earning disability, we would figure his economic damage from the amount of the reduction of the visual acuity; the scientific standard, 0.20, would have an economic equivalent of 0.38. Reasoning from this economic loss of acuity and inserting same and working out the formula, we find that the value of his economic powers is about 30 per cent., which has a pecuniary valuation of $600.00 per annum, which agrees fairly well with his lessened expectations of earning if his vision should remain as it is, but if it further deteriorates he will be totally incapacitated.

EXAMPLE 6. In the case of an iron moulder 40 years of age receiving a blow upon his head which laid him up from work for a year and caused permanent homonymous hemianopsia. From the effects of the accident, he being laid up for a year, afterwards being obliged to take a lower position in the same line of work, which paid him about one-third less, we would figure his theoretic loss by means of table as 31.6 per cent., which agrees near enough with the actual conditions of his work, for he was previously earning $4.00 a day and afterwards was enabled to earn but $2.75 a day; the total economic damage can be readily figured in this case as in the foregoing.

Examples of such character might be multiplied and cases cited from the most simple form to that of the most complicated character. The foregoing are surely sufficient demonstration of the fact that the percentage of economic loss and its pecuniary equivalent in any given case of ocular injury may be readily ascertained.

(9) Resumé.

1. The present usages for the estimation of pensions, insurance, and damages at law, from injury to vision, are based wholly upon precedent and are purely empirical.

2. The relation of the visual act to the earning ability is susceptible of mathematic demonstration.

3. The probable loss of wages—i. e., the effect on the earning ability of the individual—may be determined by the particular injury to vision.

4. (a) Insurance contracts will probably be continued under the present business arrangements, but could be made equitable, subject to the amount of economic damage—a percentage of the sum for total disability being paid for partial losses. In the case of loss of vision of one eye the rates should be modified to between 18 and 30 per cent. of the total disability.

(b) For the settlement of pensions and annuities the full annual economic damage should be paid.

(c) For the settlement of claims at law the probable economic damage should be estimated and considered the principal element, subject to business discount, to additions for the actual expenses consequent on the accident, and empirical amounts for the pain and anguish thereto incurred; contributory negligence and other legal factors being also considered in the verdict.

5. The calculations and rules of Magnus and Würdemann afford a method of estimating the amount of the probable economic damage in a manner fair and just to all parties and agreeable to all legal demands.

AFTERWORD.

"Forsan et haec olim meminisse juvabit." (Horace.)

INDEX OF AUTHORS.

A

Abadie, 152, 160, 167.
Achard, 586, 595.
Adamück, 442, 445, 587, 590, 591, 592, 593, 595, 684, 692.
Ahlström, 129, 140, 159, 167.
Alberti, 205, 211.
Alexander, L., 204, 205, 211, 745, 750.
Allport, 325, 774, 788.
Alonzo, 54, 56.
Alphonse, 40, 41, 50.
Alt, Adolph, 558, 588.
Alvarado, 77, 83.
Amedie, 572, 583.
von Ammon, 126, 167, 586, 587, 595, 597, 598, 688, 692.
Andrade, 500, 511.
Andre, 640, 641.
Andreae, 56, 58, 62.
Andrews, J. A., 189.
Aneke, 668, 679.
Ansiaux, 527, 534.
Antonelli, 414, 424.
Arens, 463.
von Arlt, 6, 122, 125, 127, 167, 176, 180, 533, 535, 547, 550, 569, 583, 622, 660.
Aschmann, 723, 730.
Asmus, 243, 245, 246, 247, 248, 488, 491, 687, 692.
Aub, 588, 590.
Aubineau, 108, 109.
Aurand, 498, 511.
Axenfeld, 104, 106, 122, 125, 167, 495, 499, 511, 889.
Ayers, S. C., 43, 50, 89, 100, 579, 583.

B

Bach, L., 138, 140, 167, 302, 306, 312, 495, 511.
Bacchi, 140, 167.
Baeck and Loehlein, 618.
Baer, 84, 85.
Baker, 890, 891.
Baker, C. R., 157, 159, 167, 774, 788.
Ball, Jas. Moores, 214, 359, 499, 511.
Banholzer, 675, 679.
Banister, 591, 596.
Baretti, 520.
Barnett, 884.
Barr, 554, 566.
Barron, 810, 818.
Bartells, 173.
Bartisch, George, 126, 166.
Bartolinus, 126, 166.
Basetti, 823, 824, 825.
Basso, 499, 511.
Battle, 841, 845.
Baudry, 6, 430, 444.
Baüerlein, 594, 596.
Baum, 242, 248.
Bayer, 405.
Beal, 345, 348.
Becker, H. M., 408, 410.
Becker, O., 119, 197, 198, 199, 439, 445, 467, 473, 474, 486, 627.
Beer, 6, 820, 825.
Beers, 126, 167, 176, 180.
Bell, 860, 862.
Belt, 325.
Bennett, 443, 445, 498.
Benson, 587, 591, 595.
Berard, 210, 211.
van der Berg, 736, 737.
Berger, 395, 397, 450, 662, 663.
Berger, Emil, 230, 231, 237, 637, 641, 836, 837.
von Bergmann, 722, 761, 765, 793, 797, 839, 833, 844.
Bergmeister, 6, 824.
Berka, 200, 201.
Berlin, J., 77, 83, 214, 215, 581, 583, 645, 652, 654, 662, 663, 667, 679, 713, 714, 716, 719, 722, 730, 734, 735, 761, 765, 779, 786, 788, 797, 841, 844.
Berlin, Johannes, 83, 84, 656, 657, 775, 788.
Bernhardt, 767, 788.
Bernheimer, 711, 714.
Berry, 849.
Best, 48, 50, 677, 679, 683, 692.
Bettremieux, 552, 565, 783, 797, 816, 818, 889, 890.
Beweren, 404, 406.
Bezold, 498, 511.
Bietti, 104, 105.
Bildoo, 126, 166.
Birch-Hirschfeld, 41, 42, 45, 46, 50, 712, 714.
Bistis, 625.
Blaauw, 226, 230, 455, 458.
Black, Melville, 355, 359.
Black, N. M., 202, 211.
Bloch, 214.
Block, 498, 511.
Blok, 195, 199.
Blumenthal, 195.
Bocci, 179, 180.
Bock, Emil, 555, 566, 787, 797.
Boissoneau, 331, 348.

Bomgartner, 480, 486.
Bonner, 319.
Borghetti, 166, 168, 609.
Borsch, J. L., 333, 348.
Bortello and Garbasso, 255, 281.
Bourgeois, 185, 309, 310, 312, 414, 424.
Bourgg, 39, 50.
Le Boux, 819, 824.
Bowen, 265.
Bowman, 127, 167, 520, 524.
Brandenburg, 784, 797.
Brailey, 176, 180.
Braav, 197, 198, 199, 218, 223, 409, 410.
Brobst, 163, 168.
Brodie, 713, 714.
Bronner, 176, 180.
Brose, 157, 167.
Brown, E. V. L., 134, 135, 141, 167.
Brundenel, Carter, 769, 788.
Bruner, 364, 367, 559, 566, 612, 615, 616.
Bruns and Robin, 317, 330.
Buchanan, 170, 173, 216, 223, 499, 511.
Bull, C. S., 296, 312.
Buller, 341.
Bulson, A. E., 199, 200.
Bunge, 482, 496.
Burnett, Swan, 455, 456, 823, 825.
Butler, 669, 679.
Byers, 163, 167, 414, 424.

C

Caillet, 586, 595.
Callan, 719, 722.
Campbell, Colin, 608, 609.
Campbell, Don M., 163, 167.
Carman, 257, 263, 268, 281.
Carter, 230, 231.
Caspar, 250, 281, 385, 389, 618, 619, 621, 692.
Castelman, 647, 654.
Causé, 779, 797.
Chacon, 777, 778.
Chaillons, 501, 511.
Chance, 503.
Chantamesse, 499, 511.
Chapman, 109, 412, 413.
Cheney, 781, 797.
Chibret, 326, 330.
Chisholm, 533, 535.
Chodin, 194, 195, 675, 679.
Cirincione, 559, 560, 566, 644, 659, 660, 813, 818.
Claiborne, J. H., 190, 195.
Clarke, Lindly, 7, 876, 884.
Coats, 457, 458, 669, 679.
Cohen, Curt, 542, 543, 813, 818.
Cohn, Herman, 83, 84, 166, 168, 205, 211, 597, 598, 670, 679, 693, 694.
Collins, Treacher, 375, 480, 486.
Colucci, 675, 679.
Conkey, 90, 100, 448, 453.
Coppez, 160.
Cosmettatos, 581, 583.
Coulomb, 331, 332, 335, 336, 341, 342, 348, 359, 499.
Cowell, 594, 596.
Cramer, 622, 623, 625, 659, 688, 692.
Creste, 112, 119.
Critchett, 165, 328, 329, 330, 520, 524, 608.
Croskey, 403.
Crower, 851, 852.
Csapodi, 486, 491.
Cuperus, 593, 596.
Cuvier, 555, 566.
Czermak, 7, 440, 445, 521, 522, 524, 534, 535.
Czermak and Elschnig, 7.

D

Da Gama Pinto, 548.
Dalen, 133, 167.
Dangan, 214, 215.
Darier, 205, 211, 305, 312, 510, 511.
Davidson, MacKenzie, 255, 256, 257.
Daviel, 442.
Deane, J. Edgar, 424.
DeBeck, 452, 453, 457, 458, 478, 486, 830, 831.
Decherd, 718, 722.
Decker, 649, 654.
Demme, 730, 735.
Demours, 126, 167.
Denig, 55, 56, 820, 822, 825.
Dermitt, 631, 641.
Deshogues, 143, 167.
Desbrieres and Bourgg, 39, 50.
Deschamps, 183, 185, 891.
Desmarres, 6, 611.
Deutscher Strafgesetzbuch, 884, 885.
Deutschmann, 121, 125, 128, 138, 140, 152, 167, 499, 511, 731, 735.
Dianaux, 352, 358, 359.
Dickey, 364, 367, 649, 654.
Dieffenbach, 750.
Dieulafoy, 499, 511.
Dimmer, 47, 50, 205, 211, 239.
Dixon, 252, 280, 281, 375.
Dolganoff, 113, 119, 440, 445.
Dolganoff and Sokaloff, 113, 119.
Donders, 127, 167.
Donovan, 67, 69, 70, 92, 93, 94, 100.
Dowling, 447, 453, 782, 797.
Doyne, 354, 359, 365, 367.
Drake-Brockman, 192, 195.
Drucker, 664, 666.
Dub, 637, 641.
Dujardin, 412, 413.
Dunbar, 847, 848.
Dunn, 141, 166, 546, 550, 820, 825.
Dunn, John, 229, 231.
Durr, 848.
Van Duyse and Cruyl, 759.
Dzuatowski, 829, 831.

E

Eaton, 520.
Editorial, Journ. A. M. A., 64, 71.
Ellett, E. C., 39, 50, 175.
Elliott, R. H., 201, 202, 632, 641.
Elschnig, 7, 193, 195, 208, 300, 312, 365, 367, 495, 510, 647, 654, 660, 735, 737.
Elwood, 301, 607.
Emerson, 163, 168, 305, 307.
Enslin, 201, 202, 228, 229, 231, 487, 491.
Ertl, 386, 389.
Eschenauer, 88, 100.
Eulenberg, 841, 845.
Evans, 717, 722.
Eversbusch, 442, 445, 518, 521, 524, 530, 531, 535.
Ewetzky and von Kennel, 553, 566.
Ewing, 245, 246, 248.

F

Fabian, 182, 183.
Fabricus, 375.
Fage, 216, 217, 521, 522, 524, 591, 596, 828, 831.
Faith, 576, 583.
Fallopius, 6.
Fejer, 145, 167, 222, 224, 576, 583, 764, 765.
Fenton, R. A., 339.
Ferber, 172, 173.
Fermé, 43.
Fernandez, J. Santos, 80, 83, 199, 200, 483, 486, 626.
Ferrier, 34, 37.
Fick, 296, 826, 831.
Fick and Denig, 821, 825.
Finsen, 622.
Fischer, 715, 722, 890, 891.
Fisher, H., 223, 224.
Fisher, Wm., 380, 389, 547.
Fiske, 54, 70.
Foerster, 578, 583, 629, 641.
Fox, L. Webster, 6, 48, 50, 257, 281, 325, 330, 576, 583.
Frank, Mortimer, 368, 388.
Frank, Otto, 509.
Franke, 302, 312, 549, 550, 578, 583.
Freysz, 625.
Fricke, 750.
Fridenberg, Percy, 662, 665, 666.
Friedenwald, 841, 845.
Fröhlich, 202, 211.
Fromaget, 767, 782, 788, 797.
Frothingham, 307.
Früchee, 563, 566.
Fuchs, E., 7, 131, 134, 135, 136, 141, 167, 171, 173, 176, 180, 194, 195, 205, 211, 306, 307, 431, 444, 453, 457, 458, 489, 491, 494, 495, 497, 510, 528, 532, 535, 566, 570, 571, 584, 600, 603, 609, 627, 636, 640, 641, 655, 657, 659, 667, 670, 679, 680, 689, 691, 692, 756, 758, 809, 810.
Fulton, 830, 831.

G

Gaffky, 498, 511.
Gallemaerts, 336, 348.
Galezowsky, 6, 678, 679.
Garbasso, 255.
Garnier, 172, 173.
Gaupillat, 180.
Gaupillat and Regnault, 180.
Gayet, 296.
Gehl, 729, 730.
Geissler, 6, 584, 595, 764, 765.
Genth, 591, 594, 595.
Gentilini, 499.
Gersuny-Eckstein, 350, 359.
Gessner, 819, 824.
Gifford, H., 80, 83, 129, 137, 157, 164, 167, 205, 211, 347, 373, 379, 389, 547, 550, 772, 788.
Ginsburg, 579, 583, 590, 595.
Girard, 84, 85, 799, 808.
Goldberg, 582, 583.
Goldzieher, 386, 387, 664, 666.
Golowin, 814, 818.
Gonin, 685, 692.
Gosselin, 57, 62.
Gotti, 553, 566.
Goutermann, 841, 845.
v. Gouvea, 56, 62.
Gradle, H. S., 564, 566.
v. Graefe, A., 127, 167, 191, 299, 312, 555, 566, 586, 652, 726, 730.
Graefe-Saemisch, 7.
Grand-Clement, 6, 176, 180.
Greeff, 644, 659, 660.
Greene, D. W., 193, 195, 547.
Green, John, 218, 219, 222, 223.
Greven, 837, 838.
Griffin, 309.
Groenouw, 239.
Grohe, 498, 511.
v. Grohmann, 184, 185.
Gruening, 42, 50, 81, 83.
Grünthal, 650, 654.
Guepin, 635, 641.
v. Guhmann, 56, 62, 459.
Guillery, 59, 62, 108, 109, 459.
Gussenbauer, 30, 31.

H

Haab, O., 7, 38, 50, 150, 156, 167, 223, 224, 246, 248, 304, 319, 330, 369, 370, 375, 377, 378, 380, 384, 386, 389, 510, 511, 647, 652, 654, 663, 664, 666, 667, 668, 672, 673, 679, 680, 692, 693, 737.
De Haas, 40, 50.
Halbertson, 511.
Hall, Gaylord C., 286, 292, 395, 397, 833, 837, 838, 859, 860, 862.
Hallauer, 373, 388.
Hällsten, 587.
Haltenhoff, 355, 359.
Hanke, 90, 100, 404, 406.

Hansell, H., 250, 281, 494, 510, 814, 817, 818, 841, 845, 864, 887.
Harlan, George C., 79, 83, 358, 359.
Harper, 872, 873.
Hasner, 863, 865.
Hauptmann, 844, 845.
Heath, 476, 486, 864, 865.
Heckel, 545, 548, 550.
Heefordt, 136, 143, 167.
Henderson, 179, 180.
Henke, 637, 641.
Henschen, 696, 710.
Herm, 347, 348.
Hersing, 591, 592, 593, 596.
Hertel, 495, 511.
Hertzell, 241.
Hess, C., 38, 44, 50, 474, 488, 820, 825.
Hesse, 728, 730.
Heustis, 388, 389, 751, 752.
Hewitt, 719, 722.
Higgins, S. C., 434, 444, 733, 750.
Hilbert, 43, 50, 201, 202, 560, 566.
Hillemans, 290, 292, 726, 730.
Hillemanns and Pfalz, 675, 679.
Himley, 126, 167, 863, 865.
v. Hippel, 219, 220, 224, 552, 565, 647, 654, 663, 664, 666, 670, 679, 683, 692, 828, 831.
Hirota, 104, 106.
Hirsch, 432, 444.
Hirschberg, J., 29, 30, 78, 80, 83, 109, 118, 119, 127, 151, 166, 167, 168, 226, 230, 240, 247, 248, 369, 375, 376, 380, 383, 389, 409, 594, 595, 596, 598, 609, 622, 625, 645, 649, 652, 654, 663, 664, 665, 666, 667, 685, 692, 697, 710, 729, 730, 777, 778, 837, 838, 844, 845.
Hirschberg and Steinheim, 109.
Hirschler, 589, 591, 595.
Hoch, 668, 679.
Hock and Schirmer, 6.
Hoeber, 488, 491.
Hoedrath, 890, 891.
Höeg, 617, 619, 621.
von Hoelder, 206, 716, 719, 730, 735, 822.
v. Hofmann, C., 116, 119, 214, 215.
Holden, 177, 208.
Holmes-Spicer, 474, 486.
Holth, 356, 359.
Hoor, 172, 173, 590, 595, 685, 692.
Horace, 294, 312.
Hubbell, A. A., 143, 167.
Hughes, 587, 589, 595.
Hulen, Vard, 257, 270, 273, 277, 278, 281, 474 486.
Hulke, 767, 788.
Hummersheim, 890, 891.
Hurd, 208.
Hutchinson, 226, 230, 589, 595.

I

Illing, 356, 359.
Imai, 618, 621.
Inouye, Tatsuji, 84, 85.
Isenschmidt, 463.
Ivanoff, 660.

J

Jack and Verhoeff, 814, 818.
Jackson, Edward, 237, 450, 766, 771, 776, 747, 748, 749, 788.
Jaeger, 566, 583, 635, 641.
James, 319.
Jameson, P. Chalmers, 546, 549, 550, 572, 583.
Jamieson, R., 193, 195.
Jobson, 465, 466.
Jocqs, 210, 211, 859, 862.
Johnston, Wilson, 90, 100.
Joseph, 138, 167.
Jung, 244, 248.
Junius, 772, 788.
Jurnitschek, 372, 388.

K

Kalt, 205.
Kampherstein, 736, 737.
Kanzel, 245, 248, 383, 389.
Karibuchi, 40, 50.
Kauffmann, 409, 410.
Keiper, 769, 788.
Keller, 78, 83, 813, 818.
v. Kennel, 553, 566.
Kerry, 68, 71, 482, 486, 660.
Kerzendorfer, 522, 524.
Kierstein, 238, 557.
Kilbourn, 819, 824.
Kilkowe, 427, 444.
Kindermann, 203, 211.
Kipp, 28, 29, 30, 495, 499, 510, 553, 555, 632, 641, 664, 666.
Klein, S., 202, 211.
Klingelfuss, 372, 375.
Koch, 498, 511.
Koller, 70, 71, 601, 609.
Köllner, 428, 444.
Konig, 793, 797.
Korschenowsky, 514, 524.
Kostenitsch, 649, 654.
Koster, 246, 248, 635, 641.
Koyle, 422, 423, 424.
Knapp, Arnold, 206, 211, 765.
Knapp, H., 109, 189, 246 248, 363, 365, 508, 562, 566, 586, 590, 591, 592, 593, 595, 648, 654, 675, 679, 733, 735, 750.
Knapp and Stoell, 380, 389.
Knies, Max, 230, 231, 375.
Krahnstöver, 596.
Kramsztyk, 54, 56.
Krauss, 227, 231.
Kreibich, 47, 50.
Kreuzberg, 752.
Krienes, 170, 173, 583, 584.
Kröner, 591, 596.

Krueger, 404.
Kuffler, 103, 105.
Kuhnt, H., 156, 167, 304, 312, 325, 350, 359, 414, 415, 416, 417, 418, 419, 424, 442, 444, 445, 523, 524, 530, 535, 548, 716, 722.
Kümmel, 243, 248, 552, 553, 565, 664, 666.
Kunst, 809, 810.
Küstner, 217.
Kuttner, 206.

L

Laas, 205, 206, 211.
Lagleyze, 351, 359.
Lagrange, 326, 330.
Landers, 787, 797.
Landesberg, 429, 444, 517, 524, 527, 531, 534.
Landolt, 321, 356, 359, 750.
Lang, 325, 608, 819, 824.
Lange, 240, 248.
Lans, 286, 292.
De Lapersonne, 351, 352, 354, 359.
Laquer, 610, 612, 616.
Larger, 759.
Lauber, 350, 359.
Lawford, 480, 486, 747, 750.
Lawson, Arnold, 155, 167.
Lawson, George, 6, 520, 521, 522, 524, 591, 596.
Leber, 28, 30, 107, 108, 113, 119, 121, 125, 128, 138, 140, 167, 241, 250, 281, 495, 499, 511, 547, 550, 596, 622, 647, 649, 654, 683, 692, 717, 722, 729, 730, 731, 733, 734, 735, 781, 795, 826, 831, 839, 843, 844.
Leber and Krahnstöver, 596.
Ledbotter, 80, 83, 773, 788.
Lederer, 819, 824.
Lefort, 813, 818.
Leiter, 309, 310.
Lenoir, 751, 752.
Leonhardt, 532, 535.
Leplat, 183, 185.
Levin, 827, 835.
Leviste, 484, 486.
Lewis, F. Park, 204, 211, 227, 231, 365, 816, 817, 818.
Limbourg, 139, 167.
Lindahl, 157, 167.
Lippincott, 302, 358, 510, 607.
Lister, 499, 511.
Lochlein, 618, 620, 621.
Lodato, 82, 83.
Lopez, 349, 359.
Loring, 239.
Lublinsky, 515.
Lukens, 821, 823, 825.
Lundsgaard, 39, 50, 830, 831.
Luniewski, 819, 821, 824.

M

MacCallum and Cornell, 811, 818.
McHardy, 375, 830, 831.
McKee, J. H., 103, 105.
MacKenzie, 6, 126, 127, 138, 167.
McKeown, 375, 516.
MacKinlay, 830, 831.
McNabb, 197, 199.
MacWhinnie, 5, 308, 604, 609.
Maddox, 420, 422, 424, 653, 654.
Magnus, H., 283, 284, 620, 621, 678, 679, 889, 891.
Magnus and Würdemann, 7, 283, 284.
Majewski, 455, 458.
Manchester Royal Eye Hospital, 197.
Mandelstamm, 648, 654.
Mans, 675, 679.
Mannhardt, 587, 588, 589, 591, 595.
Manz, 681, 692.
Marcus, 792, 797.
Markoff, 499, 511.
Markwort, 176, 180.
Marlow, 175.
Marple, 77, 83, 542, 543.
Marshall, Devereaux, 202, 211.
Martin, 499, 511.
Martinache, 507, 511.
Marx, 350, 359, 610, 616.
Mathewson, 143, 167.
Mauthner, 586, 589, 595, 735, 737, 841, 843, 845.
Maxwell, 359.
May, Emil, 58, 62, 356, 359.
Mayer, 498.
Mayweg, 890, 891.
Meller, 488, 491.
Mellinger, 247, 372, 374, 375, 388.
Mellinger and Klingelfuss, 372, 375.
Mellinghoff, 229, 231.
Meneghelli, 592, 596.
Mercanti, 640, 641.
Merkel, 723, 730.
v. Merz, 84.
Messerer, 789, 797.
Meyer, E., 375, 414, 424.
Meyer, Otto, 318.
Meyerhoefer, 622, 625.
v. Michel, 7, 143, 167, 445, 453, 510, 711, 714, 820, 825.
Milbrandt, 542, 543.
Milhes, 375.
Miller, 478.
Milliken, 345, 348, 610, 616.
Mitchell, S., 49, 50.
Mitteldorf, 784, 797.
Mooren, 107, 108, 138, 167.
Mooren and Rumpf, 138, 167.
Monell, 40, 41, 42, 46, 50.
Monat-Lavellee, 782, 797.
Monosmith, 322.
Morax, 356, 359.
Moretti, 172, 173.
Morgagni, 375.

Morian, 779, 797.
Morrison, 228, 231, 386, 389.
Morrow, 773, 788, 797.
Morton, 341, 348, 719, 722.
Morton, H. McI., 407, 408, 410.
Muetze, 552, 555.
Muglich, 684, 692.
Mules, 325, 533, 535, 640, 641.
Müller, 347, 354, 456, 458, 527, 529, 531, 533, 534, 554, 555, 566, 567, 570, 577, 583, 638, 640, 641, 680, 692.
Müller, Heinrich, 126, 167.
Murphy, F. G., 303, 312.
Murray, W. R., 202, 211, 810, 813, 814, 818.

N

Nägeli, 182, 183.
Nagel, Michel, 7.
Nance, 739, 750.
Natanson, 229, 231.
Zur Nedden, 600, 601, 609, 618, 619, 621.
Neepee, 656, 657.
Nettleship, 176, 180, 255, 281, 432, 444.
Neumann, 511.
Newlowina, 79, 83, 799.
Nicati, 549, 550.
Nicolai, 326, 330.
Nieden, 432, 444, 713, 714, 734, 735, 819, 824, 864, 865, 890, 891.
Nobbe, 644.
Norman-Hansen, 414.
Norris and Oliver, 6.
Norton, 787, 797.
Nottage, 610, 616.
Noyes, 6, 79, 83, 637, 641, 769, 788, 830, 831, 847, 848.
Nuel, 457, 495, 511, 522, 523.
Nurnberger, 728, 730.

O

Oatman, 141, 167.
O'Connor, 194, 195.
Oeller, 7, 735, 737.
v. Oettingen, 84, 85, 597, 598, 693, 694, 784, 797.
Ohm, 488, 491, 587.
Oishi, 716, 722.
Oliver, C. A., 6, 36, 37, 141, 154, 165, 167, 672, 673, 674, 676, 679.
Oliver, F., 883, 884.
Oliver, Thos., 81, 83.
Onken, 687, 692.
Onodi, 205.
Ovio, 51, 56, 75, 83.

P

Packley, 770, 788.
Paderstein, 554, 566.
Pagenstecher, 167, 192, 726, 730, 797, 799.
Paré, Ambroise, 313, 330, 333, 334.
Parsons, J. H., 43, 46, 50, 103, 105, 122, 125, 167, 472, 473, 477, 486, 495, 496, 511, 587, 595, 644, 711, 712, 714.
Peck, 810, 818.
Penet, 637, 641.
Perlmann, 246, 248.
Peters, A., 171, 173, 200, 201, 217, 220, 223, 224.
Pfahl, 42, 50.
Pfalz, 687, 692.
Pfingst, 852.
Pflüger, 632, 641.
Pichler, 55, 56.
Pick, 74, 83, 216, 217.
Pincus, 591, 596, 812, 818.
Pischler, 729, 730.
Placido, 430.
Plitt, 556, 566.
Polano, 591, 595.
Politzer, 498, 511.
Pollock, 439, 445, 719, 722.
Pooley, 151, 167.
Posey, W. C., 79, 83, 490, 491, 586, 595, 775, 778.
Post, 355, 359, 610, 616, 713, 714.
Powell, 230, 231.
Praun, 7, 38, 50, 83, 84, 119, 121, 125, 149, 166, 167, 168, 170, 172, 173, 174, 175, 215, 217, 289, 291, 292, 296, 312, 375, 389, 395, 397, 412, 430, 440, 441, 445, 448, 453, 459, 525, 527, 534, 535, 536, 541, 543, 564, 566, 570, 575, 577, 580, 581, 583, 584, 613, 614, 616, 626, 627, 635, 640, 641, 648, 650, 654, 656, 657, 672, 679, 680, 689, 691, 692, 717, 722, 723, 730, 733, 735, 741, 750, 758, 762, 765, 767, 768, 782, 794, 797, 818, 824, 826, 831, 849, 862, 865, 874.
Pridham, 720, 722.
Puccini, 198, 200.
Purtscher, 580, 583, 841, 845.

Q

Quackenboss, 198, 199.
Queen, 252.

R

Ramiro-Guedes, 439, 445.
Rampoldi, 185, 632, 641.
Ramsay, A. Maitland, 6, 144, 160, 168, 174, 175, 183, 185, 325, 811, 818.
Rane, 527, 534.
Randolph, R. L., 63, 70, 398, 403.
Ranlin, 650, 654.
Rascalon, 813, 818.
Ray, J. M., 191, 195.
Reber, Wendell, 223, 224, 674, 679, 790, 797, 833, 837.
Regnault, 180.
Reich, 84, 85.
Reidel, 633, 641.
Reis, 670, 679, 826, 831.

Rheim, 842, 845.
Richet, 750.
Richter, 482, 486.
Ring, 305, 307.
Ring, W. F., 191, 192, 195.
Risinger, 485, 486.
Risley, 563, 566, 842, 845.
Robin, 317, 330.
Rockcliffe, 210, 211.
Rodewald, 524, 599, 609, 741, 750.
Rohmer, 206, 211, 326, 330, 352.
Rollet, 350, 359, 816, 817, 818.
Rollet and Aurand, 498, 499, 511.
Rollins, Wm., 40, 50.
Rosenhauch, 669, 679.
Roth, 239.
v. Rothmund, 139, 151, 167, 375.
v. Rothmund and Eversbusch, 139, 151, 167.
Rout, 38, 50.
Le Roux, 39, 50, 193, 195.
Roy, Dunbar, 8, 130, 131, 132, 159, 167.
Ruge, 135, 141, 167.
Ruhberg, 649, 654.
Rumpf, 138, 167.
Rumczwicz, 736, 737.
Rupprecht, 219, 220, 223.
Russell, 226, 230.
Rust, 439, 445, 482, 486.
Rymowicz, 296.

S

Sachs, 241, 527, 534, 711, 714.
Saemisch, 7, 495, 510, 590, 592, 596, 595.
Sager, 230, 231.
Salzmann, 726, 730, 826, 831.
Samelsohn, 359, 555, 566.
Sanitary Commission German Army, 837, 836.
Santucci, 851, 852.
Sattler, 81, 83, 365, 367, 379, 389, 689, 692, 813, 816, 818.
Saunders, 608.
Scarpa, 6.
Schanz and Stockhausen, 44, 48, 50.
Schapringer, 676, 679, 820, 821, 825.
Scheffels, 680, 692.
Schieck, 47, 50.
Schiele, 483, 486.
Schiess, 185, 841, 844.
Schirmer, 6, 121, 125, 129, 135, 140, 141, 167, 284, 474, 477, 486, 490, 491, 495, 511, 530, 535, 578, 583, 616, 618, 620, 621.
Schleich, 116, 119, 890, 891.
Schlodtmann, 640, 641.
Schlösser, 375.
Schmidt, 7, 597, 598, 601, 609.
Schmidt and Ammon, 597, 598.
Schmidt-Rimpler, 139, 167, 495, 511, 523, 524, 587, 595, 668, 679.
Schoeler, 115, 119, 414, 424, 442, 632, 641, 689, 692.
Schoen, 404, 406.
Schröder, 214, 215.
Schuleck, 119.
Schultze, 675, 679.
Schunkitz-Myashita, 515, 524.
Schwabach, 816, 818.
Schwartz, 445, 453, 555, 566.
Schwarz, 688, 692.
Schweigger, 327, 330, 562, 566.
de Schweinitz, 188, 195, 223, 224, 230, 231, 251, 313, 330, 565, 566, 692, 819, 824.
Schwenck, 813, 818.
Seattle Star, 875, 884.
Seigfried, 693.
Selenkowsky, 42, 50.
Servel, 216, 217.
Shastid, 855, 857, 866, 874.
Sherer, J. W., 15, 50.
Shoemaker, 821, 825.
Shumway, 533, 535.
Siegrist, 317, 330, 585, 595.
Sidler-Hugenin, 217.
Silex, 205, 842, 845.
Simi, 849.
Simon, 840, 844.
Sirieys, 193, 195.
Sisson, 43, 46, 47, 50, 574, 583.
Slieda, 498, 511.
Smith, Major Henry, 193, 195, 547.
Smith, Priestly, 226, 230, 664, 666, 781, 797.
Snell, A. C., 229, 231, 450, 453.
Snell, Simeon, 81, 83, 88, 89, 90, 91, 94, 96, 97, 99, 100, 102, 158, 167, 286, 288, 289, 290, 292, 361, 367, 375, 388, 450, 453, 508, 522, 524, 623, 625, 635, 641, 653, 654.
Snellen, H., 322, 323, 330, 333, 348, 358, 359, 414, 424.
Sokaloff, 113, 119.
Somer, 214, 215.
Sourdille, 157, 168.
Spechtenhauser, 649, 654.
Spengler, 227, 230.
Spierer, 610, 616.
Spratt, 256, 281, 368, 388, 648, 654.
Stall, 78.
Stradler, 49, 50.
Steiner, 620, 621.
Steinheim, 109.
Stellwag, 356, 359.
Stephenson, Sydney, 222, 224.
Stevenson, Mark, 393, 397.
Stieren, 54, 56, 230, 231.
Stilling, 250, 281.
Stillson, H., 39, 40, 50, 625.
Stock, 104, 106, 219, 220, 223.
Stockhausen, 44, 48, 50.
Stower, 62, 70, 74, 81, 83, 172, 173, 693, 694, 791, 797, 826, 831.
Stoll, 380, 389.
Stood, 890, 891.

Strader, 427, 444.
Stroebe, 712, 714.
Stroebel, 44, 50.
Stroschein, 57, 62.
Stucky, 236, 557.
Stuelp, 317, 330.
Stutzer, 62, 109, 395, 397.
Suker, 322, 414, 424, 444, 445.
Sulzer, 143, 167, 889, 891.
Swanzy, 547, 550.
Sweet, 251, 256, 257, 258, 259, 260, 261, 281, 368, 375, 381, 382, 383, 388, 389, 542, 543, 579, 583, 766, 774, 788.
Sweet-Bowen, 265.
Szili, 183, 185, 431, 444, 640, 641, 744, 750, 848.
Szumann, 182, 183.

T

Talco, 84, 85, 591, 594, 595, 600, 609.
Talmud, 333.
Tavignol, 126, 127, 167.
Taylor, 6, 356, 359.
Taylor, S. J., 297, 298, 312.
Teale, 607.
Teillais, 589, 595.
Tepljaschin, 587.
Terrien, 193, 195, 317, 318, 330, 750.
Terson, 226, 230.
Theobald, 127, 167, 190, 195.
Thiersch, 356, 359.
Thompson, Edgar, 157, 158, 168.
Thompson, E. C., 636, 641.
Thompson and Buchanan, 216, 217, 218, 219, 221, 223.
Thorcy, 450, 453.
Thomer, Max, 241.
Tigerstedt, 587.
Todd, 300, 322, 475, 472, 473, 508, 607.
Tooke, Fredk., 8, 435, 436, 437, 445, 464, 465, 502, 503, 504, 511, 445, 550.
Tornatolu, 75, 83.
Trantas, 239, 248.
Travers, 810. 818.
Treitel, 109, 563, 566, 725, 730.
Trendelenburg, 776, 778.
Trousseau, 137, 167, 168, 205, 211.
Truc, 219, 223.
Turnbull, 217.
Twietmeyer, 671, 679.

U

Uhthoff, 103, 104, 105, 122, 125, 167, 208, 412, 413, 495, 499, 511.
Uhthoff and Axenfeld, 104, 105, 122, 125, 167, 495, 499, 511.
Ulbrich, 105, 347, 348.
Ulrich, 779. 797.
Unna, 623.
Usher, 817, 818.

V

Vail, 52, 53, 54, 56.
Valois, 75, 77, 81, 83, 656, 657.
Valude, 160, 168, 226, 230, 413, 781, 797.
Veasey, C. A., 157, 167, 216, 217, 631, 633, 634, 641.
Vedas, 375.
Velez, 349.
Verderame, 204, 211.
Victor, 246, 371, 372.
Vierordt, 726, 730.
Vieweger, 555, 566.
Vigier, 388, 389.
Villard, 51, 56, 123, 125, 169, 173, 203, 211.
De Vincentiis, 535, 536.
Virchow, 498, 511.
Vogelsang, 658, 659.
Vogt, 228, 231, 629, 641.
Volkmann, 610.
Vollars, 104, 105, 486.
Voltemis, 375.
Vossius, 6, 209, 211, 312, 313, 480, 486, 495, 511, 530, 535, 552, 565, 590, 591, 592, 593, 595, 617, 621, 717, 722.

W

Wadsworth, 480, 486.
Wagenmann, 7, 113, 119, 453, 458, 495, 585, 595, 675, 679, 711, 714, 730, 731, 733, 790, 797, 829, 831.
Wahl, 782, 797.
Wandless, 604, 609.
Wappler, 254.
Ware, 884, 885.
Weber, Jr., 640, 641.
Webster, 735, 737.
de Wecker, 109, 144, 167, 328, 330, 414, 420, 424, 530, 535, 586, 587, 589, 590, 595, 645, 654.
Weeks, 257, 281, 356, 357, 359, 480, 656, 799, 836, 837.
Weidmann, 614, 616, 652, 654.
Weill, 689, 692.
Weiss, 246, 248, 318, 319, 330, 386, 389, 414, 424, 713, 714, 734, 735.
Wells, David, 479, 480, 486.
Westhoff, 307, 312.
Westphal, 180.
Wharton, 367, 379, 389.
White, Jos., 156, 303, 312, 431.
White-Cooper, 6, 126, 167, 176, 180, 375, 640, 641.
Whiteledge, 793, 797.
Wicherkiewicz, 326, 327, 329, 330, 355, 359, 499, 744, 750, 830, 831.
Widal, 499, 511.
Widmark, 157, 167, 623.
Wilder, 547.
Williams, 534, 535, 629, 641, 799, 801, 803, 828, 831.
Williams, C. H., 79, 83.

Windle, 456, 458.
Windsor, 520, 524.
Wintersteiner, 495, 510, 569, 570, 575, 583.
Wirtz, 103, 106, 203, 211.
Wisselick, 671, 679.
Witalinski, 82, 83.
Wolff, 355, 359.
Wolff, Bruno, 213, 215, 223, 224.
Wolffberg, 179, 180, 307.
Wood, Casey A., 6, 230, 231, 304, 458, 478, 682, 690, 692, 709, 710, 712, 714.
Wood and Woodruff, 235, 404.
Woodruff, T. A., 45, 50, 235, 356, 359.
Wreden, 498.
Wright, 769, 788.
Würdemann, 6, 39, 50, 64, 71, 107, 108, 129, 140, 147, 167, 175, 176, 193, 195, 196, 199, 238, 240, 242, 248, 283, 284, 292, 307, 202. 211, 341, 348, 405, 406, 426, 444, 472, 473, 498, 511, 521, 522, 570, 583, 589, 595, 700, 710, 735 747, 750, 788, 765, 793, 780, 797, 800, 815, 818, 822, 825, 865, 866, 873, 882, 884, 889, 891.

Y

Young, H. B., 182, 183, 830, 831.
Yvert, 6.
St. Yves, 6.

Z

Zahn, 208, 211.
Zandler and Giessler, 6, 584, 595, 723, 730.
Zehender, 547, 550, 640, 641.
De Zeng, 240, 242.
Zentmayer, Wm., 129, 167, 356, 359, 671, 679.
Ziegler, 306, 312.
Zimmermann, C., 630, 641 674, 679, 730, 819, 823, 824, 838.
Zimmermann, W., 776, 777, 778.
Zinmeister, 787, 797.
Zirm, 484, 486, 659, 654.
Züno, 439, 445.

62

INDEX OF SUBJECTS.

(In general chapters referring to more important captions; in anatomic chapters fuller details are noted.)

A

Ability, relationship of vision to earning, 892.
Abducens, atrophy, 780.
paralysis, 791-841.
Abscission, relative movement of eye after, 338.
Abscess, brain, 491-767.
lids, 214-750-751-752.
orbit, 764-767-774-780.
chorioid, 543-671.
cornea, 496-498-812.
lacrimal gland, 772-849-852.
Accidents, *vide*, anatomic headings.
domestic, 32.
industrial, 32.
gunpowder, firearms, dynamite and high explosives, 66-67.
explosions, 66.
hunting, 66.
relationship to earning ability, 892.
legal relations, 855.
Accident insurance, 885.
America, 876.
Germany, 870, 884.
Foreign, 883.
Accommodation, spasm, cramp, paresis and paralysis, 581-583-591-632-688.
Acetate of lead leucoma, 228.
Acts, American, 883.
Canadian, 883.
English, 882.
German, 884.
Summary of compensation, 883.
Aggravation, 734-862.
Air pressure, contusions, 74.
Alloys, magnetic properties, 367.
Aniridia, 530-575.
Amnesia, 710.
Amaurosis and amblyopia, 695-707-720-725-728-731-782.
Amaurosis, cortical, 710.
simulated, 783.
Ankyloblepharon, 460.
Anesthesia, general, ether, chloroform, 316.
local, cocain, 311-316.
infiltration, 319.
spinal, 209.
scopolamin-morphin, 316.
Aneurysm, arterio venous, 810.
ophthalmic artery, 816.
Aneurymal murmur, 811.
Antisepsis and asepsis, 293-294.
Anisometropia, 184.
Anterior chamber, paracentesis, 605.
hyphema and hemorrhage, 478-530-555-566.
foreign bodies, 551-556-557.
iron and steel, 28-558.
cilia, 554-562.
myiasis, 553.
shot, 596.
lens, 601.
Aphakia, 575-697.
Aphasia, 697.
Apparatus, protective, 99.
investigation of injury from protective, 286.
Appliances, ownership, 876.
safety, 285-875.
Applications, hot and cold compresses, 308.
strong, complaints of patients, 225.
idiosyncrasy, 225.
Arteria centralis retinæ, embolism, 207.
Arteria iridis, rupture, 569.
Artery, ophthalmic, aneurysm, 816.
cartoid, rupture, 811.
ciliary, rupture, 585.
Argyrosis, 227-409-434.
Artificial eyes, *vide* phothesis.
Astigmia, 183-200-218-219-432-440-859.
Asthenopia, 184.
Atrophia bulbi, 118-123-327-564-583-635.
Autoplasty, 356-748.
Avulsion *vide* evulsion.

B

Bacteriology, *vide* anatomic headings, 102.
Bandaging, 306.
Berlin blue, reaction to iron, 614.
Black eye, 406.
Blasting, 67-93.
Blepharospasm, 445.
Blindness, immediate, 437-725-729.
physical, 697.
psychical, 697.
cortical, 697.
verbal, 697.
ideographic, 700.
economic, 892.
hysteric, 176, 177.
word-congenital, 709.
pressure, 735.
one sided, 734.
binocular from childbirth, 215.
following injuries to face and head, 707.
from tearing of nerve, 731.

without ophthalmoscopic signs, 799.
from operation on frontal sinus, 206.
following injections of protargol, 227.
from electricity, commercial current, 38.
short circuiting, 38.
Röentgen ray, 40.
lightning, 42-580.
sunlight, 43.
acids, 50.
alkalies, 54.
lime, 56.
Bottling, 99.
Burns, *vide* anatomic headings.
domestic, 32-110.
industrial, 32-110.
electric, 32-110.
glowing metals, 34-110.
commercial current, 38.
Röentgen ray, 40.
photo-therapy, 42.
lightning, 43.
sunlight, 43-110.
electric light, 43.
violet light, 44.
tropical light, 45.
high intensity and heat rays, 46.
acids, 50-101.
alkalies, 50.
lime, 56.
gunpowder explosions, 63.
steam, hot water, oil, 101.
chemical, 56-228-230.

C

Caisson disease, air embolism, 676.
Calefaction, 34.
Canaliculi, tying off, 298.
Canthotomy, 319.
Cartoid artery, rupture, 811.
ligation, 814.
Cataract, cortical, 600.
traumatic, *vide* lens, 577-599.
from perforation of cornea, 601.
cauterization, 601.
sympathetic soft, 609.
posterior cortical, 618.
lightning, 624.
natans, 634.
Cataracta accreta, 556.
Cataract, operation accidents, 189.
loss of vitreous, 190-191.
infection, 190.
statistics, 197.
collapse of sclera, 193.
detachment of chorioid and retina, 194.
hemorrhage, 195-197-198.
glaucoma, 199.
disturbances of healing, 200.
keratitis bullosa, 200.
keratitis striata, 200.
kerato-iritis, 200.
delayed union, 200.
astigmia, 200.
kyanopia, 201.
lens in capsule, 189.
Caterpillar hairs, 404.
Cauterization, dangers of, 204.
of corneal ulcers, 507-508.
Cellulitis of orbit, 174.
Chemotaxis, 495.
Chemical effects, of lime, 57.
of glass and metal, 28.
Centers, of vision, 696.
cerebral, paralysis, 839.
of language, 700.
ideographic, 701.
Check ligaments, 811.
Childbirth, injury to lids, 215.
exophthalmus, 215.
evulsion, 215.
paralysis of muscles, 217.
injuries to globe, 218.
opacity of cornea, 219.
rupture of Descemet's membrane, 222.
retinal hemorrhage, 223.
fractures, 214.
Chipping, 95.
Choked disk, 716.
Chorioid, abscess, 543, 671.
wounds, 541.
prolapse, 550.
foreign bodies, 565.
copper, 565.
iron, 565.
hemorrhage, 584.
rupture of ciliary arteries, 585.
hemorrhagic dislocation, 585-586.
sub-chorioidal hemorrhage, 542.
ophthalmoscopic examination, 587.
indirect rupture, 586-597.
single rupture, 588-777.
double rupture, 588.
triple rupture, 588.
multiple rupture, 589-594.
horizontal rupture, 589.
fork-shaped rupture, 588.
large rupture, 589.
combined chorioidal and retinal rupture, 594.
direct rupture, 595.
whip-lash rupture, 588.
functional disturbances, 592.
tumor formation, 596.
injury from gunshot, 597.
dislocation, 584-585.
detachment, 584.
serous detachment, 194.
Chorioiditis, plastica, 148.
serosa, 150.
Chorio-retinitis, 598-635.

Cicatrix, dolorosa, 176-431-432-523.
cystoid, 417-517-523-531.
Ciliary body, wounds, 511.
prolapse, 550.
foreign bodies, 564.
cyclitis traumatica, 583.
accommodation cramp and paralysis, 583.
rupture, 584.
gunshot injuries, 597.
Ciliary neuralgia, 176.
Combined injuries *vide* anatomic headings.
Coloboma iridis, 532-548-576.
lentis, 627.
lids, 740.
Complications *vide* anatomic headings.
Commotio cerebri, 710.
Concussion, contusions and ruptures *vide* anatomic headings.
blunt force, 23-31-74.
Conjunctiva, abrasions, 393.
wounds, cuts, stabs, 393-413.
lacerations, 394.
infection and complications, 394.
bruising, 406.
tuberculosis, 395.
foreign bodies, 397.
ophthalmia nodosa, 403.
ecchymosis, 406-724.
hemorrhage, punctate, 408.
hematoma, 406.
edema and chemosis, 407-812.*
emphysema, 407.
tumefaction, 512.
pigmentation, 409.
argyrosis, 227-409-434.
siderosis, 409.
blood pigment, 409.
methyl violet, 409.
tattooing, 409.
burns and cauterizations, 410.
tumor formation, polypus, epithelioma, 412.
firearm injuries, 413.
powder grains, 388-413.
cicatricial formation, 412.
copper, 29.
tearing, 189.
indirect rupture, 394.
operations with, 413.
diphtheritic membrane, 415.
Conjunctivitis, traumatic, 395.
Constitutional eye disease, traumatism exciting, 108.
Copper, use of in ocular injuries, 418.
Cornea, frequency of injury, 425.
erosions, 176-426-428-431.
abrasions, 188-401-426-450.
optical and pupillary zones, 426.
infection, 98-438.
non-perforating wounds, 432.
perforating wounds, 207-434-462-586-593-736.
conical (kerato-conus), 440-472.
fistula, 418-440-504.
astigmia, 432-440.
foreign bodies, 445-450-463.
motes, 425.
metallic oxides, 481.
iron, 445-481.
copper, 445-448-481.
lead, 452-482-483.
stone, 447.
suture, 442.
siderosis, 448.
contusions, 453-462.
infraction, 193-455.
rupture, 456-463.
collapse, 193.
burns and cauterizations, 408-458.
sulphuric acid, 459.
necrosis, 215.
gunshot injuries, 462.
staphyloma, 418-434-439-470.
re-opening of cicatrix, 441.
changes following injury, 462.
opacities, 218-221-404-468-483.
striate opacity, 467-473-639.
leucoma, 228, 476.
calcareous film, 476.
blood staining, 480.
hemorrhage, 478.
edema, 468-474.
clearing of cicatrices, 469.
cystoid cicatrix, 417-517-523-531.
anterior synechia, 470.
keratocele, 418.
keratectasia, 471.
keratoconus, 440-472.
cysts, 484.
grafting, 484.
ulcer, 498-812.
hypopiom ulcer, 494.
ulcer rodens, 497.
annular infiltration, 496.
prophylaxis, 505.
cauterization, 507.
dangers of cauterization, 204.
Corneo-scleral margin, perforating wounds,, 514.
foreign bodies, 525.
Co-servants, hiring of, 878.
Cranium, fracture anterior wall, 407.
Crushing, 73.
Cyclopegics and myotics, *vide* anatomic headings.
Cyclitis traumatica, 583.

D

Damages, legal compensation, 870.
measure, 871.
nominal, 871.
compensatory, 871.

exemplary, 871.
punitive or vindicative, 871.
counter claims, 869
Danger, knowledge of, 881.
remaining in place of, 881.
Descement's membrane, rupture of, 219-220-458.
Descemetocele, 422.
Devices, new, 877.
Diagnosis, 232-249, *vide* anatomic headings.
Diaphanoscopy, 240-564-613-628-632.
Diplopia, following head injuries, 708-836.
homonymous, 708.
Discission of cataract, 605.
Dislocations, 30.
Disposition of diseased and abnormal eyes to injury, 100-107.
Dressings after operations and accidents, 306.
Duties of employers, 876.
Duties, forgetfulness caused by pressure of, 880.

E

Earning ability, relationship of vision, 892.
Economic damage, determination of and relative amount of resulting from injury to the eyes and vision, 885.
status of the physician in relation to estimation of indemnity, 889.
methods of scientific estimation, 889.
Magnus and Würdemann's method for mathematical estimation of, 892.
Economic vision, factors, 893.
estimation of damages, 894.
Economic blindness, 890.
Ectropion, 740-742.
Empiricism and precedent, 886.
Emphysema, orbital, 175-792.
lids, 754.
Employers, duties, 876.
instructions and warnings, 879.
Employment, 881.
Enophthalmus, 780-785-818-820.
congenital, 824.
cicatricial, 838.
Endophthalmitis, non-sympathetic, 130.
Entropion, 740.
Enucleation, simple, 319.
Vienna method, 320.
French method, 321.
American method, 322.
substitutes, 313.
indications, 314.
preliminary treatment, 314.
operation for, 319.
hemorrhage during, 322.
self, 830.
traumatic, 830.
Ethmoid fracture, 408, 848.
Errors of refraction produced by trauma, 183-583-668.
Etiology, *vide* anatomic headings.
of injuries to the eyes in domestic life, 87.
industrial injuries, 87.
trades in which injuries occur, 87.
industrial accidents, 90.
iron workers, 92.
mote removers, 96.
glass and bottle workers, 98.
Estimation, of damage, 894.
of pecuniary loss, 896.
Erysipelas after ocular injuries, 744.
Eviseration or exenteration, 324.
Eviseration traumatic, 457.
Eversion of lids, 236.
Exenteration and enucleation, 357.
Exophthalmic goiter, 827.
Evulsio nervi optici, 726.
Evulsion of eyeball, 825.
Examination of injury cases, 233.
Exhibition of injuries, 855.
Explosions, 62.
Exophthalmus, 174-183-216-724-729-763-768-776-778-784-794-807-809-811-816.
pulsating, 734-809-813.
from orbital hemorrhage, 778.
transitory, 824.
Eyeball, contusion without rupture, 809.
traumatic exophthalmus, 174-183-215-778-810.
traumatic enophthalmus, 810.
tropho neurosis, 818.
luxation and avulsion, 215-825.
injuries from firearms, 825.
copper in the, 250.
variation in size of, 250.
Eye stones, 402.

F

Fluorescein, 237-430-433.
Force, *vide* anatomic headings.
blunt, 30.
Focal illumination, 238.
Foramen opticum, anatomy, 723.
Foreign bodies, *vide* anatomic headings.
in the anterior segment, 362.
in the cornea, 362.
in the anterior chamber, 362.
in the lens, 363.
in the orbit, 765.
within the globe, 27-362.
dangers of retained, 365.
general description of, 368.
long retained in the ciliary body, 364.

in the posterior segment, 365.
in iris causing changes, 560.
removal of, from interior, 361.
oyster shell, 398.
Formalin, injury from, 229.
Formula of Magnus, 895.
Fovea, spontaneous hole, 670.
Fractures, of skull (see childbirth and orbit).
of skull involving eyes, 719.
clinoid processes, 713.
of base, 789.
of canalis opticus, 717.
of inner orbital wall, 587-790.
of orbital walls, 784.
orbital rim, 796.
orbital roof, 797.
middle fossa, 718.
frontal bone, 707.
sphenoid, 713.
facial, 784.
pertous, 787.
malar, 794.
ethmoid, 408-848.
zygoma, 757-796.
superior maxilla, 795.
Freezing, 37.

G

Glare, 46.
Glaucoma, traumatica, 169-171-541-583-631-632-635-685.
acute, 585.
secondary, 603.
Globe, collapse of the, during enucleation, 323.
failure to extrude, 323.
atrophy and phthisis, 118-123-327-516-564-583-586-635.
Goggles, obligatory in Germany, 290.
wearing of, by workmen, 286.
Graft, cutaneous, 746-749.
Thiersch and Wolff, 749.
corneal, 784.
Gunpowder explosions, burns and injuries, 63.
etiology and mechanism, 63.
Gunpowder and dynamite explosions, prognosis, 69.
prophylaxis, 69.
therapy, 69.
Gunshot wounds, *vide* anatomic headings.
direct and indirect rupture, 72.
penetration from small shot, 75.
penetration from bullets, 72-78.
penetration from particles of shell, 78.
of orbit, 78.
during war, 83.
infection in, 85.
to the visual centers, 597.

H

Heat rays, affects, 46.
Hemeralopia, 665.
Hemianopsia, 697-707-712-714.
Hemiplegia, 503.
Hemi-anesthesia, 783.
Hematoma, 757-780-785-790.
Hemorrhage, *vide* anatomic headings.
retrobulbar, 668-779.
subhyaloid, 676.
intra-cranial, 787.
History, 233.
Hyperopia, 183-668.
Hyalitis, 191.
Hydrophthalmus, 216.
Hypotony, 580.
Hypopion, *vide* ulcer, 494-500-543-552-560-671-736.
Hyphema, 478-530-534-540-552-566-570-575-603-613-617-655.
Hysteria, 177-709.

I

Idiosyncrasy, 225.
Implantation, of fat, 326-349.
Indemnity, comments upon, 889.
Infection, *vide* anatomic index.
after ocular injury, 85-111.
methods of, 112.
suppurative, of the uvea, 111.
from corneal cicatrices, 113-118.
sources of, 296.
Infiltration, peripheral annular, 496.
Inflammation, *vide* anatomic headings.
retrobulbar, 764.
Injections, subconjunctival, 203-204-510.
into anterior chamber, 509.
paraffin about eye and nose, 206.
paraffin, 350.
semi-solid paraffin, 352.
solid paraffin, 353.
Injuries, mechanism of special types, 109.
trades in which occur, 86.
Injury, cause of, 880.
Instructions and warnings, 879.
Instruments, portions of, left in wounds, 210.
Internal rectus, tear of, 829.
Iodoform, effect of, 226.
rod and disc, 510.
Inspection, 236.
Insurance, accident, 885.
Iridectomy, 444-517-519-552-557-572-608-623-632-740.
injury to the lens in, 202.
Irideremia, 531.
Iridotomy, 572.
Irido-chorioditis. 541.
Iridocyclitis traumatica, 119-436-454-519-543-556-560-563-564-597-603-604-608-613-631-632-646-648-650.

plastica, 148-542-556.
serosa, 149.
Iridodialysis, 529-568-573-575-658-667.
Iridoplegia, 580.
Iris, wounds of the 540.
coloboma, 532-548-576.
hernia, 544.
protective influence of iris, 545.
prolapse and incarceration, 190-417-510-536-544-546-557-596-607-740.
operation for prolapse, 550.
foreign bodies, 551.
silver wire, 553.
myiasis, 553.
steel, 557.
stone, 559.
lime stone, 560.
shot, 596.
cysts, serous, pearl, 561.
granulation tumor, 562.
sarcoma, 563.
tuberculosis, 563.
traumatic aniridia and irideremia, 530-575.
atrophy after contusion, 582.
siderosis, 552.
rupture, 591.
marginal tear, 578.
radial tear, 569.
rhexis iridis, 571-579.
dehiscences, 579.
anterior synechia after contusion, 543-580.
pigment dehiscences, 580.
dislocation, 576.
inversion, 569-576-597.
laceration of the sphincter, rhexis, 578.
hemorrhage, 597.
mydriasis and myosis traumatica, 580.
iridoplegia, 580.
granuloma, 109.
bombé, 122.
holes, 569.
changes in, following injury, 560.
tremor, 627.
tremulous, 632.
Iritis traumatica, 449-551-557-560-603-613.
nodosa, 551-560.

J

Judgments, recent, in appellate and supreme courts, 872.
Judge and jury methods, empiricism and precedent of in America and Great Britain, 888.

K

Keratalgia, 176.
Keratectomy or abscission, 328.
Keratocele, 471.
Keratomy or Saemisch's section, 508.
Keratoplasty, 414-485.
Keratectasia, 471.
Keratoconus, 440-472.
Keratitis, bullous, 468.
parenchymatous, 431-477-486-489.
punctata, 122.
panel, 121-123-454.
striata, 200-474.
filiform, 477.
lattice, 454.
band, 240.
ribbon, 476.
filamentary, 431-477.
traumatica interstitialis, 486.
disciformis, 489.
suppurative, 491.
mycotic, 498-501.
dendritic, 498.
neuroparalytic, 428-502.
e lagophthalmo, 502.
sclerosing, 476.
zonular, 475.
hypopion, 434-494.
peripheral annular infiltration, 496.
Kleptomania, 182.

L

Lacrimal apparatus injuries, 847.
wounds and dislocations, 847.
foreign bodies, 768-848.
blows from blunt objects, 850.
abscess and suppuration gland, 772-849-852.
rupture, gland, 851.
rupture, sac, 852.
adenitis, 852.
dislocation, 847-850.
thermal injuries, 852.
tumor formation, 852.
Language, area, 700.
Leeching, 308.
Legislation, protective, America, 875.
England, 882.
Canada, 883.
German, 884.
Foreign, 883.
Lens, astigmia, 184.
myopia, 184.
wounds, 599.
traumatic cataract, 599.
traumatic opacity, 600.
tumefaction, 602.
absorption, 602-604.
complications of wounds, 603.
therapy, 604.
atropin, 604.
dionin, 604.
bandaging, 604.
iced and hot applications, 604.
leeches, 604.

discission, 605.
linear extraction, 605-607.
extraction and expression, 607.
sympathetic ophthalmitis, 608.
foreign bodies, 609.
long retention of foreign bodies, 610.
iron, 611.
copper, 29-609-614.
glass, 610.
stone, 614.
steel, 614.
bullets, 626.
bone, 610.
contusions, 616-626.
indirect traumatic cataract, 616-626.
ring-shaped opacity, 617-620.
annular opacity, 617.
electric cataract, 622.
injuries to the, in glass blowers, 622.
thermal, light and electric injuries, 622.
bursting. 626.
luxation and dislocation, 183-569-576-581.
sub-luxation, 185-627-640.
spontaneous luxation, 640.
complete luxation, 628-629.
anterior luxation, 184-572-628.
incomplete anterior luxation of the, 633.
posterior luxation, 634-639.
wandering, 636.
complications of luxation of the, 637.
dislocation of the, under conjunctiva, 638.
dislocation in myopia, 629.
extrusion from the globe, 639.
couching of, 632-636.
lightning stroke, 624.
capsule, perforation, 202.
injury, 600.
rupture,, 621.
zonule, 626.
Lenses, protective, 47-49-288.
injury from broken, 739.
Leucoma, from acetate of lead, 228.
adherens, 501.
Liability, legal, of employers, 874.
factors modifying, 880.
Lid, sinking in of upper following enucleation, 340.
ectropion of lower, 354.
Lids, incised wounds, 739.
coloboma, 740.
edema, 781.
punctured wounds, 741.
stabs, 741.
lacerated wounds, 741.
contused wounds, 741.
infection, 173-744.
erysipelas, 174-744.
gangrene, 37-744-757.
syphilis, 175-745.
tetanus, 745.
plastic operations, 746-749.
extravasation or suggulation, 323-753.
injuries from blunt objects, 753.
foreign bodies, 750.
emphysema, 175-757.
hematoma, 757.
burns and cauterizations, 757.
injuries from firearms, 758.
powder stains removal, 751.
tumor formation, 759.
chancre, 747.
abscess, 214-750-751-752.
shots, 758.
bullets, 758.
Light, perception loss, 438.
Limbus, granuloma, 556.
Lime, *vide* burns.
Luxation, of eyeball, 216-825.
of optic nerve, 726.
of lens, 628.

M

Macula, traumatic excavation, 669.
apoplexy, 585.
holes-fovea, 669-670.
Haab's traumatic disease, 672.
electric disease, 673.
Berlin's opacity, 673.
Magnification, 238.
Magnet, use of small, 252.
character, 368.
Hirschberg's 369-558.
Haab's giant, 246-369-370-614.
Victor, 246-371.
interpolar or Mellinger, 247-372-373.
classification of, operations, 251.
rules for giant, 375.
rules for hand, 376.
diagnosis with, 247.
Magnet operations, 367-565-612-652.
complications, 378.
technic with large, 377-379.
technic with hand, 376-379.
technic with medium, 379.
technic with interpolar, 379.
reasons for failure, 378.
results, 380.
history of, 375.
complications, 378.
precautions, 378.
modifications, 379.
Malingering, 862.
Mania, post operation, 181.
following accidents, 181-830.
Mechanism of special types of eye injuries, 109.

Metals, glowing, 34.
Metamorphopsia, 693.
Methods of enucleation of eyeball, Arlt or Vienna, 320.
French, 321.
American, with pouch suture, 321.
Mule's or implantation, 325.
Methods of X-ray localization, Fox's, 257.
Sweet's, 259.
Carman's, 263.
Vard Hulen's, 273.
Dixon's, 280.
Methylviolet, 228-409.
Meningitis, 439-737-786.
Medico-legal, 855.
Metallophon, 246.
Methylene violet stain, 228.
Motes in eye, 397.
Mote, remover, 96.
instruments used by, 97.
Mules' operation, 325.
Muscles, injuries of, 834-837.
wounds, 834.
injuries from blunt objects, 837.
secondary disease, 838.
Myiasis, 553.
Mycosis, 176-498.
Myosis and mydriasis traumatica, 183-225-580-597-724-777.
Myopia, 183-583-632.
transitory, 770.
dangers of operation, 202.

N

Nasal bones, fracture, 791-796.
process of frontal, fracture, 791-796.
Naphthalin, 227.
Nebulae caused by emery, 82.
Negligence, contributory, 880-882.
what, bars recovery, 881.
not imputable, when, 881.
Nerves, injuries and paralysis, 838.
paralysis of the motor, due to lesion in orbit, 838.
paralysis, due to injury at base of brain, 839.
paralysis, due to injury of the cerebral centers, 839.
cases illustrating injury and paralysis, 841.
paralysis of the vaso-motor, 30.
Neuralgia, ciliary, 176.
Neurectomy, optico-ciliary, 327.
Neuritis optica, 698.
retrobulbar, 709-714.
Neuro-retinitis, 582.
sympathetica, 151.
Non-magnetigable bodies, 384.
Nose and sinuses, injuries to eyes from operations, 205.

O

Objects causing injuries, 100.
Operations, *vide* anatomic headings.
dangers of magnet, 378.
plastic, 353-413-746.
on nose and sinuses, 205.
radical, 313.
conservative, 362.
Ophthalmoscopy, 238.
Ophthalmia nodosa, 399-403.
Ophthalmo-diaphanoscopy, 241.
Ophthalmo-fundoscopy, 242.
Ophthalmoplegia, 776-840.
Ophthalmoscope, value of, 238.
Optic canal, hemorrhage within the, 715.
Optic foramen, direct laceration and contusion in fractures, 717.
sequence of symptoms in fracture, 717.
Optic tract, 711.
Optic neuritis, after meningitis, 737.
Optic nerve, anatomy, 710.
injuries, 710-722.
papillitis, 735.
wounds, 715.
atrophy, 598-711-718-720-724-733-734-780-812.
injury between the foramen opticum and bulb, 722.
hemorrhage, 581-715.
edema, 724-766.
ophthalmoscopic signs in injury, 730.
gunshot injury, 729.
blindness without direct injury to the, 712.
tearing from the chiasm, 713.
foreign bodies causing injury within the optic canal, 715.
foreign bodies, 726.
injury from blunt objects, 726.
evulsion, 726.
laceration, 726-729-842.
contusion, 726.
dislocation, 726.
gunshot, 729.
Optic papilla, injuries, 735.
wounds, 735.
foreign bodies, 735.
tear, 735.
Optico-ciliary-neurectomy, 327.
Orbit, abscess, 764-767-774-780.
cellulitis, 764.
cubic contents, 726.
tumor formation, 800.
foreign bodies, 765.
deep wounds, 763.
hematoma, 780-785-790-839.
fracture of the walls and facial bones, 784.
fracture of the floor, 793-798.
old healed fractures, 796.
fracture of superior maxillary, 795.

fracture of zygoma, 796.
fracture of nasal bones and processes, 791-796.
direct fractures of the rim and walls, 796.
injury to the roof, 785-797-798.
blows, 798.
injury to the temporal wall, 798.
injury to the inner wall, 587-790-799.
injury to the outer wall, 789.
injury from behind, 799.
surgical treatment of fracture, 763-798.
wounds, superficial, 761.
deep, 763.
abscess and cellulitis of, 764.
retrobulbar inflammation, 764.
blunt objects, 778.
exophthalmus from hemorrhage, 778.
contusions, 780.
emphysema, 792.
firearms, 798.
tumor formation, 800-807.
Orbital margin of rim, incised wounds, 762.
contused and lacerated wounds of the soft p.rts of the, 762-781-783.
fracture, 783-796.
symptoms of injury to the skull, 761.
phlegmon, 764.
inoculation by syphilis, 782.
erysipelas, 762.
tetanus, 767.
supra-orbital amaurosis from wounds, 782.
supra-orbital neuralgia from wounds, 782.
amblyopia from wounds of the, 782.
pseudo paralytic ptosis, 783.
Orbital walls, fissures of, 720.

P

Pathology, *vide* anatomic headings.
Papillitis, 735-812.
Paralysis, accommodation *vide* accommodation.
sphincter iridis, 708.
cerebral centers, 839.
oculomotor nerves, 503-812-842.
external rectus, 709-721.
inferior rectus, 794-838-842.
internal rectus, 836.
superior rectus, 842.
trochlearis, 812-843-837-843.
abducens, 209-791-841.
orbital injury, 841.
basal injury, 839, 840, 841.
cerebral injury, 839, 841.
central injury, 217-843.
trigeminus, 843.
facialis, 844.
motor nerves, 838.
sympathetic, 819.
Palsies, *vide* paralysis.
ocular, 707.
nuclear, 843.
Panophthalmitis, 111-128-388-492-541-603-615-644-646-650-658-671.
Paraffin, injuries from infections, 206.
method of, 350.
Patient, position of, in X-ray examination, 256.
Pecuniary loss, estimation of the, to the individual, 896.
by reason of visual imperfection, 896.
examples of estimation, 898.
Pensions, United States Government, 884.
German accident insurance law, 884.
accident insurance tables, 885.
Petrous bone fracture, 787.
Phenol, burns from, 230.
Physician, responsibility, 861-869-870.
position in estimation of economic damage, 887.
in court, 865.
rights, 865.
contracts, 866.
experts fees, 867.
testimony, 867.
mal-practice, 868.
Phthisis bulbi, 118-123-516-586.
Phthisis cornæ, 506.
Pia-arachnoidal space, blood in, 716.
Pituitary body tumor, 711.
Psychical blindness, 697.
Posterior chamber, foreign bodies, 551-558-596.
Post-operative mania, 181.
Potassium permanganate, 230.
Preparation for operation, 295.
powder stains, removal of, 388-413-751.
Prism test, Wilbrand's, 707.
Prognosis, *vide* anatomic headings, 283.
in perforating injuries, 284.
in medico-legal cases, 858.
Proliferative uveitis and endophthalmitis, 131.
Protargol, blindness from, 227.
Protection afforded by Nature, 107.
protection from infection, 300.
Protectors, kind of, for workmen, 287-289.
Prothesis, uses, 331.
kinds, 332.
interims, 333.
manufacture, 339.
care, 341.

method of insertion and removal, 342.
inconvenience, 345.
ordering, 347.
bursting of, 345.
death from use of provisional, 347.
Proptosis, 787.
Prophylaxis, 285.
Psychoses, 181.
Pterygium, 460.
Ptosis, 700-740-776.
pseudo-paralytic, 783.
Pupil, occlusion, 603.
seclusion, 603.
Argyll-Robertson's, 708.

R

Radiography, 249.
methods of taking, 257.
Fox's method, 257.
Sweet's, 259.
Carman's, 268.
Hulen's 273.
Dixon's, 280.
Radical treatment, 293-313.
Reform eye, 348.
Refraction, errors of, 183.
Repair, promise of employer to, 882.
Retina, aneurysm, 175-678.
wounds, 661.
prolapse, 662.
foreign bodies, 663.
iron, 663.
copper, 664.
lead, 664.
injuries from blunt objects, 666.
contusions, 666.
macular disease, 672.
traumatic edema, 666-669.
commotio or Berlin's opacity, 581-620-666-693.
hemorrhage, 223-674-693.
rupture, 593-669-678-694.
radial ruptures, 671.
dialysis, 679.
tear, 584.
exudation, 669.
dislocation, 584-608-668-680.
detachment, 30-183-542-582-584-593-637-642-657-660-675-682-688-758-779-793.
tremulous detachment, 668.
idiopathic detachment, 683.
myopic detachment, 685-690.
spontaneous reattachment, 691.
rupture of the chorioid accompanying ruptures, 680.
rupture of bulb accompanying rupture, 680.
blinding or dazzling, 693.
injury from firearms, 693.
excavation of macula, 669.
embolism, 668.
Retinal pulsation, 592.
striæ, perivascular, 691.
retovascular, 692.
Retinitis proliferous, 593-729.
hemorrhagica, 698.
striata, proliferating, 691-678.
Retrotarsal folds, foreign bodies, 402.
Risks, assumption of, 880.
ordinary, 880.
extraordinary, 880.
Röentgen ray, effects of, 40.
Rules, fellow servant, 879-881.
Ruptures, *vide* anatomic headings, 30.

S

Sac, lacrimal, in suppuration of tear passages, 299.
cleansing of conjunctival cul-de-sac, lids and surroundings, 300.
operations on, 350.
Schlemm, rupture of canal, 533-566.
Screens, use of, to avoid injury, 291.
Sclera, non-perforating wounds, 513.
perforating wounds, 514.
glancing wounds, 536.
conservative treatment of wounds, 517.
dislocation, 597.
staphyloma, 516-631.
ectasia, 517.
suture, 520.
Nuel's operation, 522.
cystoid cicatrix, 517-523.
foreign bodies, 525-536.
injuries from blunt objects, contusions, 526-536.
pigment deposition, 532.
posterior rupture, 533.
indirect rupture, 527-537.
partial rupture, 533.
bursting, 526-536-569-584.
rupture, 457-526-537.
thermal injuries, 535.
injuries from firearms, 536.
contusions and ruptures, 526.
collapse, 193.
cyst of, 535.
Scotoma, central, 585-591-652-671.
paracentral, 585.
negative, 665.
Self-inflicted damage, 862.
Sella turcica, ball in, 775.
Siderosis bulbi, of conjunctiva, 28-409-481.
of iris, 552.
lens, 614.
Sideroscopy, 243-613.
Simulation, 734-783-862.
Sinuses, operations on, 205.
Snow blindness, 48.
Socket, gonorrhea of the, 341.

plastic operation for restoration, 355.
Staphyloma, 434-439-470-516.
Sterilization, of conjunctival cul-da-sac, 301.
of lids, 303.
of lacrimal passages, 303.
Striæ, perivascular, 692.
retrovascular, 692.
retinal, 691.
Suicide, 181-712-721.
Superior maxilla, fracture, 795.
Sunlight, injuries from, 43.
Surgical diseases following orbital and lid injuries, 175.
Symblepharon, 412-460-741.
Sympathetic ophthalmitis, 125-597-608-646-653.
disease, occurring after substitutes for enucleation, 125-162.
post sympathetic treatment and operations, 165.
treatment of sympathizing and exciting eye, 165.
after shot wounds in war, 166.
history, 126.
rarity of sympathetic inflammation and pan-ophthalmitis, 128.
theories of transmission, 137.
exciting eye, 141.
sympathizing eye, 146.
clinical types, 147.
mixed forms, 152.
diagnosis, 154.
prognosis, 154.
prophylaxis, 154.
therapy, 156.
local treatment of exciting eye, 156.
general dietetics, 157.
hygiene and medical treatment, 158.
dangers, 160.
conservation of the eye, 160.
inflammation, 142-555-631-648.
duration and incubation, 142.
symptoms and course, 144-146.
irritation, 142-636.
Sympathetic nerve, paralysis, 819.
Synechia, anterior, 437-470-506-540-543-580.
posterior, 404-431-435-439-540-541-603-611.

T

Technique (Technic), surgical, 299.
Tenon's capsule, opening, 395.
Tetanus, 174-176-439-767.
Tear gland, prolapse, 764.
Thermal injuries, *vide* anatomic headings, 31.
Theory, of transmission of sympathetic ophthalmitis, 137.
ciliary nerve, 138.
migration, 138.
predisposition and malnutrition, 139.
intoxication, 139.
criticism, 140.
Therapy, *vide* anatomic headings.
general, 294.
Thrombosis, partial, 733.
Treatment, *vide* anatomic headings, surgical, 304.
of infected wounds, 305.
after treatment, 306.
radical, 293-313.
medicinal, 293.
necessity of immediate, 366.
Traumatism, as an exciting factor of constitutional eye disease, 108-486.
Trichiasis, 740.
Tools and appliances, 877.
Traumatic neurosis, 176.
Transplantation of animal's eyes, 326.
Tropical light, injuries from, 45.
Tubes, kinds of X-ray, 252.
position of, in taking radiographs, 253.
Tumor formation after injury, *vide* anatomic index, 175.

U

Ulcer, *vide* anatomic index.
of cornea, 491-812.
serpiginous ring, 492-501.
rodent, 497-501.
perforating, 492.
hypopion, 476-494.
healing of, by conjunctival flaps, 417.
Ulcus serpens, 493.
Use, intended, of instruments and apparatus, 878.
Uvea, injuries to, 539.
foreign bodies, 551.
prolapse, 535-544.
injuries from blows, 566.

V

Vein, ophthalmic, tumor of, 810.
ligation, 814.
Vessels, hemorrhage of the retinal, 674.
embolism of retinal, 676.
air embolism of retinal, 676.
Violet light, injuries from, 44.
Visual nervous system, 695.
Visual sphere, 696-690.
gunshot injuries, 699.
Vitreous, wounds and prolapse, 420-424-515-529-535-605-643-740.
injuries, 642.
loss, 190-191.
foreign bodies, 644.

luxated lens, 645.
bysticercus, 645.
iron in the, 647.
copper, 649.
lead, shot, 650-656-664.
glass, 387-650.
stone, 387-650.
wood, 650.
coal, 387-650.
air bubbles, 646.
extra vitreal hemorrhage, 674.
hemorrhage (blood) 515-536-541-567-586-589-654-674-680.
gunshot injuries, 656.
infection, 644-657.
degeneration 659.
opacities, 626-646-659-685.
shrinking, 659.
detachment, 659.
blood staining, 660.
lens in vitreous chamber, 628-645.
hyalitis, 658.
Visual economics, 887.

W

Wages, economic value equivalent, 893.
War, injuries during, 83.
Whiplash, 438-524-568-588-680.
Wound infection in injury of the lids and soft parts of the orbit, 173.
after ocular injury, 174.
non-penetrating, 62.
penetrating, 75.
Wounds, *vide* anatomic headings.
Wounds, gunshot, 71.
surgical treatment, 304.
infected, 305.
small shot, 75.
bullet, 78.
shell, 78.

X

Xanthopsia, 552.
X-ray tubes, and diagnosis, 252.
time of exposure of, 255-613.
kinds of, 252.
distance at which to be placed, 253.
X-ray coil, 253.
X-ray, table of permeability to the, 255.

Z

Zonula, injuries to the, 627.
lacerations, 627-639.
relaxation, 629.
partial laceration with subluxation of the lens, 627.
partial laceration without displacement of the lens, 627.
total laceration 628.
Zygoma, fracture, 796.