

**Spontaneous dislocation of the head of the femur into the ischiatic notch,
occurring in morbus coxarius / by James R. Wood.**

Contributors

Wood, James R. 1816-1882.
National Library of Medicine (U.S.)

Publication/Creation

[New York] : [publisher not identified], [1854?]

Persistent URL

<https://wellcomecollection.org/works/jk6vzvfn>

License and attribution

This material has been provided by This material has been provided by the National Library of Medicine (U.S.), through the Medical Heritage Library. The original may be consulted at the National Library of Medicine (U.S.) where the originals may be consulted.

This work has been identified as being free of known restrictions under copyright law, including all related and neighbouring rights and is being made available under the Creative Commons, Public Domain Mark.

You can copy, modify, distribute and perform the work, even for commercial purposes, without asking permission.



Wellcome Collection
183 Euston Road
London NW1 2BE UK
T +44 (0)20 7611 8722
E library@wellcomecollection.org
<https://wellcomecollection.org>

Wood (J. R.)

SPONTANEOUS DISLOCATION

OF THE

Head of the Femur into the Ischiatic Notch,

OCCURRING IN

MORBUS COXARIUS,

BY JAMES R. WOOD, M. D.,

SURGEON TO BELLEVUE HOSPITAL.

REPORTED BY DR. LOINES, LATE HOUSE SURGEON; WITH SOME REMARKS, BY DR. WOOD, UPON THE SUPPOSED FREQUENCY OF LUXATIONS IN THIS DISEASE.



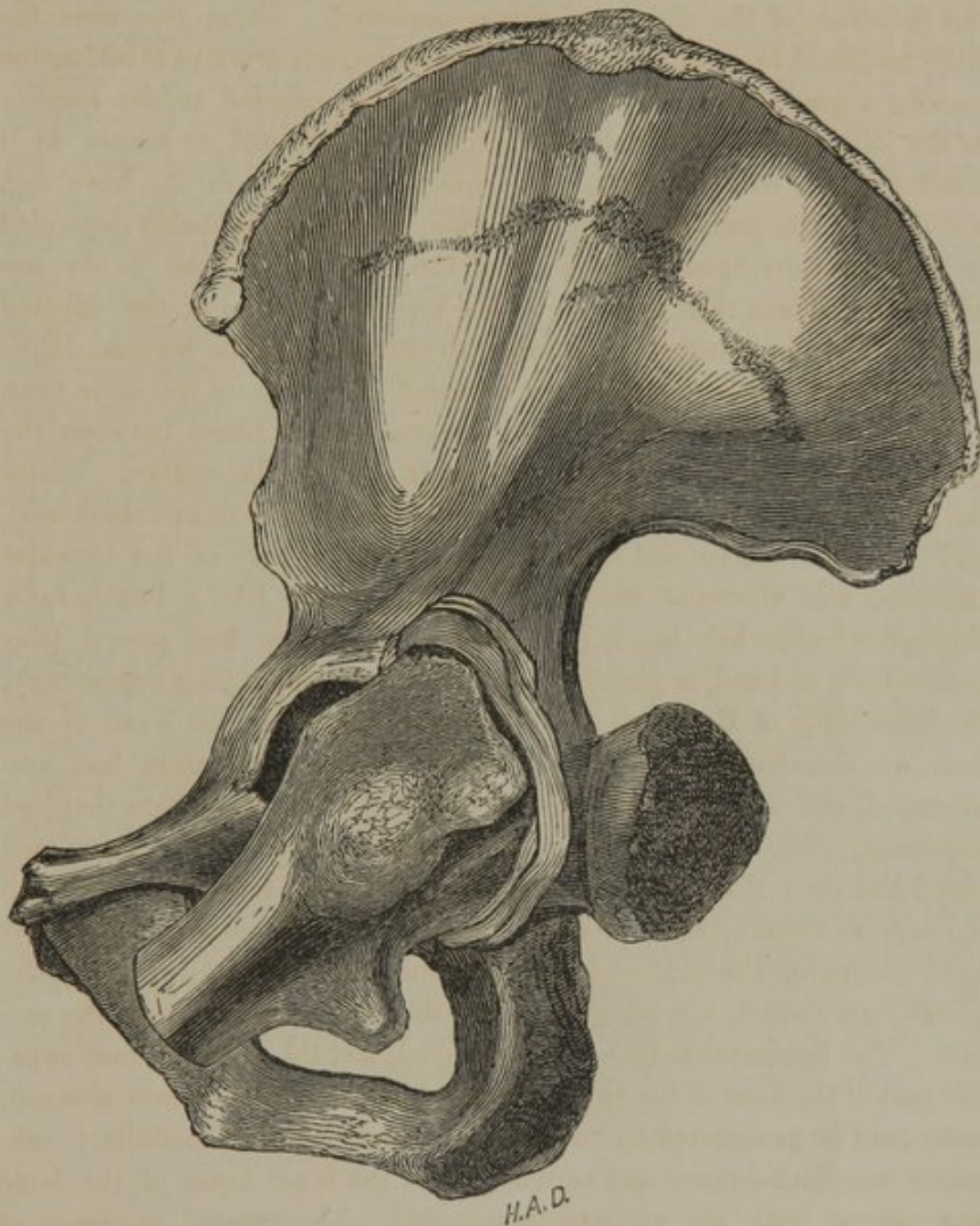
ELIZA Leonard, æt. 36, a native of Ireland, was admitted into Bellevue Hospital, Sept. 13th, 1847. Upon examination, she said that her living, for a long period, had been very poor; she had been much exposed to the wet, cold, and abuse from an intemperate husband, although her habits had been good in other respects; had great pain in the hip-joint and knee, from which she has suffered for the past six months. The state of the parts showed clear evidence of an advanced stage of disease of the hip-joint; and a deep abscess existed, having one opening into the rectum discharging through the anus, and another in the neighborhood of the great trochanter. When admitted, she could walk with assistance. *Treatment*—The best diet the house afforded, relief from pain procured by narcotics, counter-irritation, &c. Administered syrup of iodide of iron and sarsaparilla. The disease gradually progressed, however, with almost constant suffering from intense pain. About the middle of October, in one month after admission, *spontaneous luxation* of the head of the thigh-bone into the ischiatic notch occurred. In consequence of this, there were extreme adduction of the leg and foot, and turning-in of the affected thigh. From this extreme adduction, the pressure of the

thigh upon the tuberosity of the pubis was so great (notwithstanding the placing of small bolsters between the thighs) that it produced sloughing of the integuments at that part. The least attempt at abduction was productive of excruciating pain. Hectic fever soon commenced, and the disease as rapidly progressed. On the 17th of December, spontaneous *reduction* of the dislocated femur occurred. From this time the limb remained in a state of extreme abduction, any attempt at adduction causing a great aggravation of pain, which was referred to the locality of the joint solely. The pain at the hip still continued as severe as it was before the reduction, but it was much diminished in the knee, leg, and foot. (The pain that was felt before reduction probably depended in great measure upon the pressure of the head of the bone on the sciatic nerve; it was then as severe at the knee and foot as at the affected joint.) The sloughing still continued to extend; and she became delirious, one week before death, which occurred Dec. 20th, of the same year.

The *postmortem* section showed extravasation of blood between the transversalis muscle and the peritoneum, in the left iliac region. Under the seat of the slough, the periosteum was much inflamed and thickened, and beneath it matter had formed. The posterior part of the capsular ligament was ulcerated away, leaving an opening like a button-hole, through which, when luxated, the head of the femur had passed (this button-hole, or band, is plainly shown in the accompanying engraving); the immobility of the thigh was accounted for, while the head of the bone was thus fixed. The hinder margin of the acetabulum had also ulcerated, and was absorbed sufficiently to allow the dislocation that had happened. The cavity of the joint contained considerable coagulated blood and pus; there was also a large quantity of blood infiltrated into the cellular tissue of the adductor muscles. A large abscess was discovered, occupying the venter of the right ilium, communicating with the acetabulum (which was ulcerated quite through), and also with the rectum. The ligamentum teres was destroyed, and the posterior and superior part of the head of the femur ulcerated and flattened; it was also soft, and could be penetrated by the point of the knife; the medullary substance was dark-colored and softened; and the inner layer of the bone was carious, with the endosteum removed. The morbid specimen, of which the cut is a remarkably accurate representation, was exhibited at a meeting of the Academy of Medicine, and is now preserved in my pathological collection.

I have deemed it judicious to publish this, partly on account of the

unique character of the case, it being at least, the only one of dislocation into the ischiatic notch that I have ever seen or heard of in morbus coxarius; and also, because it has been recently proved that any spontaneous luxation (as the word is commonly defined), in the course of hip-



joint disease, is a very rare event; so rare, indeed, that every occurrence of it, shown indubitably by the postmortem, should be publicly recorded for the benefit of the profession. It may, here be stated, that there

is, in my museum, one other specimen of this kind of displacement, but upon the *dorsum ilii*; which *two* comprise all that I have ever seen either in the museums of New York, or the other large cities of this country. The proposition of the relative *infrequency* of this luxation may be somewhat startling; but the occasion seems to be seasonable to enforce the refutation of a *time-honored error*, as all the books and schools have hitherto taught that it was a common circumstance.

My friend, Professor March, of Albany, who has made this a subject of special research for eight years, both in this country and Europe, presented an able essay upon it to the American Medical Association last year, from which I take the liberty to quote the following brief summary of the subject in question. "Nearly every surgical author assumes that *spontaneous dislocation of the hip is of ten the result* of absorption, ulceration, or destruction of the ligaments of the joint, and of contraction of the muscles surrounding it;" but he believes that such *assumptions were only founded upon the appearances during life*, and he further says, that in addition to his own private cases, in visits, and examinations of more than *forty* of the largest pathological collections in the world, and the careful scrutiny of nearly *two hundred* specimens of true hip-disease, or ulcerative absorption of the head of the femur and the acetabulum, he found that about one-fourth of the whole showed that ankylosis had taken place, in one-fifth the ulcerative absorption had extended through the acetabulum; but it is a remarkable and instructive fact, that out of all there was but *one* case of *spontaneous luxation* from ulcerative absorption. Therefore, "the position may be taken that *spontaneous dislocation of the hip* (as purely the result of morbid action unaided by super-added violence) *seldom takes place*; and the *conclusion*, also, that all the usual *symptoms* of a *dislocation*, such as are commonly relied on, during life, as diagnostic of an *idiopathic dislocation*, can be accounted for satisfactorily by the strongly marked *organic changes* in the form and relations of the head of the femur, the cervix, the great trochanter, and the acetabulum, *without the existence of such an accident*."

2 IRVING PLACE, August 19, 1854.

