

The dissector, or, Practical and surgical anatomy / by Erasmus Wilson.

Contributors

Wilson, Erasmus, Sir, 1809-1884.
Goddard, Paul B. 1811-1866.
National Library of Medicine (U.S.)

Publication/Creation

Philadelphia : Blanchard and Lea, 1851.

Persistent URL

<https://wellcomecollection.org/works/z2bpyzp5>

License and attribution


This material has been provided by This material has been provided by the National Library of Medicine (U.S.), through the Medical Heritage Library. The original may be consulted at the National Library of Medicine (U.S.) where the originals may be consulted.


This work has been identified as being free of known restrictions under copyright law, including all related and neighbouring rights and is being made available under the Creative Commons, Public Domain Mark.

You can copy, modify, distribute and perform the work, even for commercial purposes, without asking permission.


**wellcome
collection**

Wellcome Collection
183 Euston Road
London NW1 2BE UK
T +44 (0)20 7611 8722
E library@wellcomecollection.org
<https://wellcomecollection.org>









THE DISSECTOR.

DISSERTATION

ON THE

THE DISSERTATION

ON THE

ON THE

THE
DISSECTOR;

OR,

PRACTICAL AND SURGICAL ANATOMY.

BY

ERASMUS WILSON,


AUTHOR OF A "SYSTEM OF HUMAN ANATOMY," ETC.

WITH ONE HUNDRED AND FIFTEEN ILLUSTRATIONS.

EDITED BY

PAUL B. GODDARD, M. D.

A NEW AND IMPROVED EDITION.



LIBRARY
SURGEON GENERAL'S OFFICE

DEC. 3--1902

181315.

PHILADELPHIA:
BLANCHARD AND LEA.

1851.

Annex

Q.S

W747p

1851

Entered, according to the Act of Congress, in the year 1843, by

LEA & BLANCHARD,

in the Clerk's Office of the District Court for the Eastern District of
Pennsylvania.

King & Baird, Printers.

TO
JONES QUAIN, M.D.,

THIS WORK

IS INSCRIBED

BY

HIS SINCERE AND GRATEFUL FRIEND,

THE AUTHOR.



PREPARED BY
SECOND AMERICAN EDITION
JOHN B. O'LEARY, M.D.

THE VALUE OF THIS WORK
has been established by the fact that it has been
repeatedly reprinted and has become a standard
work in the library of every student of medicine
and every practitioner of the profession. It is
the only book of the kind which has been
translated into French, Spanish, Italian, and
German. The author has revised the work
and brought it up to date with the latest
discoveries in the science of anatomy.
The work is the property of the author and
is not to be sold or otherwise disposed of
without his consent.

P R E F A C E

TO THE

SECOND AMERICAN EDITION.

THE work of Mr. Wilson, which is here presented in a new guise, was calculated for the English school, where the dissector generally commences with the extremities, and when they are finished studies the viscera, if any remains of them can be found. They have probably got into this habit in consequence of the trunks of their subjects being generally much decomposed before they procure them. In the United States, however, subjects are generally fresh, and the muscles and viscera of the abdomen claim the student's first attention; and it was thought that a new arrangement of this most excellent Dissector would prove a valuable aid to the student of practical anatomy. It has, therefore, been carefully modified in such a manner that the student, by following the order of parts as they are laid down, will obtain the utmost advantage which can be derived from a single subject.

The reputation which the work has acquired in the United States, has shown the Editor that he was not mistaken in his estimate of its value. In preparing this new edition, there-

fore, he has endeavored to supply any deficiencies that the advance of scientific investigation may have created in the work, and trusts that it may be found, as heretofore, a complete and reliable guide to the student of Practical Anatomy.

A number of new cuts have been added, illustrating the difficult and important anatomy of hernia and the perineum, which are accompanied with full descriptive explanations.

PHILADELPHIA, MARCH 1851.

CONTENTS.

INTRODUCTION.

CHAPTER I.

General composition of the body	13
Nature of dissection	ib.
Nature of surgical operation	ib.
Integument; cuticle—rete mucosum—cutis	14
Superficial fascia	ib.
Deep fascia	15
Muscles.	ib.
Vessels;—Arteries—Veins	16
Lymphatics—Nerves—Bones	ib.
Ligaments;—Joints	17

CHAPTER II.

ABDOMEN.

Muscles of the abdomen.	19
Linea alba—surgery of the	20
Linea semilunaris—surgery of the	ib.
External oblique muscle.	21
Poupart's ligament	ib.
Gimbernats ligament	ib.
External abdominal ring	22
Internal oblique muscle	24
Transverse muscle	ib.
Rectus muscle	28
Sheath of the rectus	ib.
Anatomy of Hernia	29
Umbilical Hernia	ib.
Ventral Hernia	30
Inguinal Hernia	ib.
Transversalis fascia	ib.

Internal abdominal ring	31
Spermatic canal	32
Oblique inguinal Hernia	ib.
Direct inguinal Hernia	33
Seat of Stricture	ib.
Congenital Hernia	35
Encysted Hernia	ib.
Vessels of the abdominal parietes	36
Nerves of the abdominal parietes	ib.
Cavity of the abdomen	ib.
Regions of the abdomen	ib.
Position of the viscera	37
Peritoneum	ib.
Lesser omentum	38
Foramen of Winslow	40
Great omentum	41
Transverse meso-colon	ib.
Mesentery	ib.
Meso-rectum	ib.
Appendices epiploicæ	ib.
Gastro-splenic omentum	42
VISCERA OF THE ABDOMEN	ib.
Stomach	ib.
Small intestine	43
Duodenum	ib.
Jejunum	44
Ileum	ib.
Large intestine	ib.
Cæcum	ib.
Colon	ib.
Rectum	ib.
Mucous membrane of the alimentary canal	45
Structure of the mucous membrane	46
Epithelium	ib.
Papillary layer	ib.
Villi	ib.
Sub-mucous fibrous layer	47
Follicles	ib.
Solitary Glands	ib.
Aggregate Glands, Peyer's	ib.
Duodenal glands, Brunner's	ib.
Gastric follicles.	48
Muscular coat of the alimentary canal	ib.
Serous coat of the alimentary canal	ib.
Vessels of the alimentary canal	49
Nerves of the alimentary canal	ib.
Superior mesenteric artery	50
Superior mesenteric vein	ib.
Lacteals—Mesenteric glands	ib.
Superior mesenteric plexus	51
Inferior mesenteric artery	ib.
Celiac axis	52
Gastric artery	ib.
Hepatic artery	53
Splenic artery	ib.

Ductus communis choledochus	54
Liver	ib.
Lobes	55
Fissures	ib.
Ligaments	ib.
Vessels	56
Vessels and nerves of the Liver	57
Gall-Bladder	ib.
Kiernan's Researches, upon the structure and minute anatomy of the Liver	58
Lobules	ib.
Acini of Malpighi	59
Glisson's capsule	ib.
Portal vein	ib.
Hepatic duct	61
Hepatic artery	62
Hepatic veins	63
Nerves and Lymphatics	64
Summary	ib.
Physiological deductions	65
Pathological deductions	ib.
Spleen	66
Pancreas	ib.
Semilunar ganglia	67
Solar plexus	ib.
Sympathetic	ib.
Abdominal Aorta	68
Relations	ib.
Branches	ib.
Phrenic arteries	ib.
Supra-renal arteries	ib.
Renal arteries	ib.
Spermatic arteries	ib.
Lumbar arteries	70
Sacra media	ib.
Inferior vena cava	ib.
Relations	ib.
Branches	ib.
Right Spermatic vein	ib.
Renal veins	71
Kidneys	ib.
Ureters	72
Diaphragm	73
Openings	74
Posterior abdominal muscles	ib.
Lumbar plexus of nerves	76
Branches	ib.

CHAPTER III.

HEAD AND NECK.

Muscles of the head—arrangement	78
Dura mater	80
Glandulæ Pacchioni	ib.
Falx cerebri	81
Tentorium cerebelli	ib.
Falx cerebelli	ib.
Sinuses of the dura mater	82
Superior longitudinal sinus	ib.
Inferior longitudinal sinus	ib.
Straight sinus	83
Occipital sinus	ib.
Lateral sinuses	ib.
Torcular Herophili	84
Cavernous sinuses	ib.
Inferior petrosal sinus	ib.
Circular sinus	85
Superior petrosal sinus	ib.
Transverse sinus	ib.
Arteries of the dura mater	ib.
Nerves of the dura mater	ib.
Arachnoid membrane	ib.
Sub-arachnoidean cellular tissue	86
Sub-arachnoidean fluid	ib.
Pia mater	ib.
Arteries of the brain	87
Circle of Willis	89
Development of the cerebro-spinal axis in animals	90
Development of the cerebro-spinal axis in man	91
CEREBRUM	92
Medullary and corticle substance	ib.
Centrum ovale majus	93
Corpus callosum	ib.
Lateral ventricles	95
Corpus striatum	ib.
Tenia semicircularis	95
Choroid plexus	96
Corpus fimbriatum	ib.
Middle cornu	97
Hippocampus major	ib.
Fascia dentata	98
Fornix	99
Velum interpositum	100
Thalami optici	101
Third ventricle	ib.
Corpora quadrigemina	102
Pineal gland	ib.
Fourth ventricle	ib.

Valve of Vieussens	103
Calamus scriptorius	ib.
Lining membrane of the ventricles	104
CEREBELLUM	ib.
Peduncles	105
BASE OF THE BRAIN	106
Tuber cinereum and infundibulum	107
Corpora albicantia	108
Crura cerebri	ib.
Pons Varolii	ib.
MEDULLA OBLONGATA	109
Corpora pyramidalia	ib.
Corpora olivaria	ib.
Corpora restiformia	ib.
Diverging fibres of the brain	110
Arciform fibres	ib.
Converging fibres	111
Commissures	ib.
CEREBRAL NERVES	112
Olfactory	113
Optic	ib.
Auditory	114
Motor tract	ib.
Motores oculorum	115
Abducentes	ib.
Lingual	116
Respiratory nerves of Bell	ib.
Pathetici	ib.
Fascial nerve	ib.
Glosso-pharyngeal nerve	ib.
Pneumogastric nerve	ib.
Spinal accessory nerve	117
Trifacial nerve	ib.
Muscles of the neck	124
Superficial fascia	ib.
Platysma myoides	ib.
Deep cervical fascia	125
Sterno-cleido-mastoid muscle	126
Muscles—groups	127
Parotid gland	131
Fascial nerve	133
Branches	ib.
Communications	134
External jugular vein	135
Superficialis colli nerve	136
Auricularis magnus nerve	ib.
Occipitalis minor nerve	ib.
Triangles of the neck	137
Great anterior triangle	ib.
Great posterior triangle	138
Submaxillary triangle	ib.
Superior carotid triangle	139
Inferior carotid triangle	ib.
Suboccipital triangle	ib.
Subclavian triangle	ib.

COMMON CAROTID ARTERY	140
Relations	ib.
EXTERNAL CAROTID ARTERY	141
Relations	ib.
Branches	142
Superior thyroid artery	ib.
Lingual artery	143
Facial artery	144
Mastoid artery	145
Posterior auricular artery	ib.
Occipital artery	146
Transversalis faciei artery	ib.
Temporal artery	147
Internal maxillary artery	149
Ascending pharyngeal artery	150
INTERNAL CAROTID ARTERY	151
Relations	ib.
Branches	ib.
Internal jugular vein	152
Anterior jugular vein	ib.
SUBCLAVIAN ARTERY	ib.
Branches	154
Vertebral artery	ib.
Basilar artery	155
Thyroid axis	ib.
Inferior thyroid artery	ib.
Supra-scapular artery	ib.
Posterior scapular artery	156
Superficialis cervicis artery	ib.
Profunda cervicis artery	ib.
Superior intercostal artery	156
Internal mammary artery	ib.
NERVES OF THE NECK	157
Glosso-pharyngeal nerve	158
Pneumogastric nerve	159
Pharyngeal nerve	160
Superior laryngeal nerve	ib.
Recurrent laryngeal nerve	161
Spinal accessory nerve	163
Lingual nerve	ib.
Sympathetic nerve	164
Superior cervical ganglion	ib.
Middle cervical ganglion	165
Inferior cervical ganglion	ib.
Cervical nerves	166
Anterior cervical plexus	167
Phrenic nerve	169
Posterior cervical plexus	ib.
LARYNX	ib.
Thyroid cartilage	168
Cricoid cartilage	ib.
Arytenoid cartilage	ib.
Epiglottis	169
Ligaments of the larynx	ib.
Chordæ vocales	170

Muscles of the larynx	170
Mucous membrane of the larynx	172
Glottis	ib.
Ventricle of the larynx	ib.
Sacculus laryngis	173
Glands of the larynx	ib.
Vessels and nerves of the larynx	174
TRACHEA	ib.
THYROID GLAND	175
ORBIT	ib.
Tabular arrangement of structures	177
Muscles of the orbit	ib.
Nerves—arrangement in cavernous sinus	179
Ophthalmic nerve	ib.
Fourth nerve	182
Third nerve	ib.
Sixth nerve	ib.
Ciliary ganglion	183
Ophthalmic artery	ib.
FIFTH PAIR OF NERVES	185
Superior maxillary nerve	ib.
Inferior maxillary nerve	187
Gustatory nerve	188
Inferior dental nerve	ib.
Auricular nerve	189
CRANIAL GANGLIA of the sympathetic	ib.
Otic ganglion	190
Spheno-palatine ganglion	ib.
Submaxillary ganglion	191
Naso-palatine ganglion	ib.
PHARYNX	ib.
Muscles of the pharynx	192
Openings into the pharynx	193
Soft palate	194
Fauces	ib.
Muscles of the soft palate	ib.
Prevertebral region	196
Muscles	ib.

CHAPTER IV.

ORGANS OF SENSE.

Nose	197
Nasal fossæ	199
Boundaries	ib.
Meatuses	200
Pituitary membrane	ib.
Vessels of the nose	ib.
Nerves of the nose	ib.
Practical observations	201
EYE	202

Sclerotic coat	203
Cornea	204
Choroid coat	204
Ciliary ligament	205
Iris	ib.
Ciliary processes	206
Retina	206
Zonula ciliaris	207
Aqueous humour	209
Chambers of the eye	ib.
Vitreous humour	ib.
Crystalline lens	ib.
Canal of Petit	ib.
Vessels of the eye-ball	210
Nerves of the eye-ball	ib.
Physiological observations	ib.
APPENDAGES OF THE EYE	211
Eyebrows	ib.
Eyelids.	ib.
Meibomian glands	212
Eyelashes	ib.
Conjunctiva	ib.
Caruncula lachrymalis	213
Plica semilunaris	214
LACHRYMAL APPARATUS	ib.
Lachrymal gland	ib.
Puncta lachrymalia	ib.
Lachrymal sac	ib.
Nasal duct	215
EAR	ib.
Pinna	ib.
Muscles of the pinna	216
Meatus auditorius	ib.
Vessels and nerves of the pinna	217
Tympanum	ib.
Membrana tympani	ib.
Ossicula auditus	ib.
Muscles of the tympanum	218
Openings in the tympanum	ib.
Eustachian tube	219
Vessels of the tympanum	221
Nerves of the tympanum	ib.
Labyrinth	ib.
Vestibule	ib.
Semicircular canals	222
Cochlea	223
Auditory nerve	224
Arteries of the labyrinth	ib.
TONGUE	ib.
Papillæ circumvallatæ	225
Papillæ conicæ and filiformes	ib.
Papillæ fungiformes	ib.
Vessels of the tongue	ib.
Nerves of the tongue	ib.

SKIN	226
Cutis	ib.
Corium	227
Papillary layer	ib.
Rete mucosum	ib.
Cuticle	228
Nails	229
Hairs	ib.
Sebaceous follicles	ib.
Perspiratory duct	ib.
Pores	ib.

CHAPTER V.

ANATOMY OF THE PERINEUM.

General idea	230
Dissection	232
Common superficial fascia	ib.
Superficial perineal fascia	233
Muscles of the perineum	ib.
Internal pudic artery	236
Branches	ib.
Dorsalis penis vein	238
Compressor venæ dorsalis muscle	240
Internal pudic nerve	ib.
Compressor urethræ muscle	ib.
Cowper's glands	241
<i>Perineum in the female</i>	244
Muscles of the female perineum	ib.
Arteries	245
Nerves	ib.

CHAPTER VI.

PELVIS AND ORGANS OF GENERATION.

Bladder	245
Ligaments of the bladder	246
Coats of the bladder	248
Trigone vesicale	249
Uvula vesicæ	ib.
Muscles of the ureters	250
Urethra	250
Prostatic portion	ib.
Membranous portion	251
Spongy portion	ib.
Cowper's glands	ib.
Prostate gland	252
Vesiculæ seminales	ib.
Vasa deferentia	ib.
Ejaculatory duct	253

Pelvic fascia	253
Levator ani muscle	ib.
Internal iliac artery	254
Sacral plexus of nerves	256
Penis	257
Corpora cavernosa	ib.
Corpus spongiosum	ib.
Scrotum	258
Testicle	259
Tunica vaginalis	ib.
Tunica albuginea	ib.
Tunica vasculosa	ib.
Epididymis	261
Vas deferens	ib.
Spermatic cord	262
Surgery of the testicle and cord	ib.
<i>Female pelvis and organs of generation</i>	263
Bladder	264
Female urethra	ib.
Mons Veneris	ib.
Labia majora	ib.
Labia minora, or Nymphæ	265
Clitoris	ib.
Hymen	ib.
Meatus urinarius	ib.
Vagina	266
Uterus	267
Fallopian tubes	268
Ovaries	ib.

CHAPTER VII.

REGION OF THE BACK.

Arrangement of the muscles	270
Posterior thoracic region—First layer	ib.
Second layer	272
Third layer	ib.
Fourth layer	274
Fifth layer	276
Sixth layer	277
Table of origins	278
Table of insertions	279
Actions of the muscles of the back	280
SPINAL CORD	281
Membranes of the spinal cord	ib.
Sub-arachnoidean fluid	ib.
Membrana dentata	283
Motor columns	284
Sensitive columns	ib.
Spinal nerves—Origins	285
Arrangement	ib.

Dorsi-spinal veins	286
Meningo-rachidian veins	ib.
Medulli-spinal veins	ib.

CHAPTER VIII.

THORAX.

Thorax—Boundaries	287
Muscles	ib.
Thoracic fascia	288
Lungs	289
Pleura	290
Anterior mediastinum	ib.
Middle mediastinum	291
Pericardium	292
Heart	ib.
Circulation	ib.
Right auricle	293
Right ventricle	296
Left auricle	298
Left ventricle	ib.
Structure of the heart	299
Coronary arteries	300
Aorta—ascending—arch	301
Pulmonary artery	303
Superior vena cava	ib.
Pulmonary veins	ib.
Trachea—Bronchi	ib.
Posterior mediastinum	304
Relations—Branches	ib.
Vena azygos major	305
Vena azygos minor	306
Superior intercostal vein	ib.
Thoracic duct	ib.
Œsophagus	ib.
Pneumogastric nerves	307
Sympathetic nerve	ib.
Splanchnic nerves	308
Cardiac ganglion and plexuses	ib.

CHAPTER IX.

UPPER EXTREMITY.

General principles in the disposition of the Bones	309
Muscles	310
Arteries	313
Veins—Lymphatics	314
Nerves	ib.
Anterior thoracic region	315
Muscles	ib.

Lateral thoracic region	318
Muscles	ib.
Subscapular region	ib.
Acromial region	ib.
Bend of the elbow	ib.
Nerves	319
Veins	320
Anterior brachial region	321
Muscles	322
Posterior scapular region	ib.
Muscles	323
Posterior brachial region	ib.
Triceps muscle	ib.
Axilla	325
Axillary artery	326
Branches	ib.
Brachial artery	327
Relations	328
Branches	ib.
Axillary plexus of nerves	329
Fore-arm—anterior region	331
Muscles—superficial group	333
Deep group	334
Radial artery	335
Branches	336
Ulnar artery	337
Relations	338
Branches	ib.
Median nerve	339
Ulnar nerve	340
Musculo-spiral nerve	341
Fore-arm—posterior region	342
Muscles—Superficial layer	343
Deep layer	345
Palmar region	347
Muscles—Radial group	ib.
Ulnar group	348
Palmar group	349

CHAPTER X.

LOWER EXTREMITY.

Surgical observations	351
Anterior femoral region	352
Superficial fascia	ib.
Superficial vessels and nerves	356
Saphenous opening	356
Deep fascia ;—fascia lata	357
Cribriform fascia	358
Muscles—Anterior group	359
Internal group	361
Femoral artery	363

Operation—Relations	365
Branches	ib.
Profunda artery	366
Relations—Branches	ib.
Obturator artery	367
Veins	368
Nerves	ib.
Crural nerve	ib.
Obturator nerve	369
Femoral hernia	370
Coverings—Operations	372
Gluteal region	375
Muscles	376
Arteries	379
Nerves	381
Posterior femoral region	382
Muscles	ib.
Arteries	383
Nerves	384
Popliteal region	ib.
Popliteal artery	385
Relations	ib.
Popliteal nerve	386
Anterior tibial region	ib.
Superficial anatomy	387
Muscles	388
Anterior tibial artery	390
Relations	ib.
Branches	391
Anterior tibial nerve	ib.
Dorsal region of the foot	ib.
Muscles	ib.
Dorsalis pedis artery	392
Branches	ib.
Nerves	393
Fibular region	393
Muscles	ib.
Nerves	394
Posterior tibial region	395
Superficial anatomy	ib.
Muscles—Superficial group	ib.
Deep group	397
Posterior tibial artery	398
Branches	399
Peroneal artery	ib.
Branches	ib.
Sole of the foot	400
Plantar fascia	ib.
Muscles	401
Arteries	403
Nerves	405
Plantar interossei muscles	ib.
Analysis of the arrangement and action of the muscles of the lower extremity	406

CHAPTER XI.

ON THE LIGAMENTS.

Synarthrosis	408
Harmonia	ib.
Schindylesis	ib.
Gomphosis	ib.
Sutura	ib.
Amphi-artrosis	ib.
Symphysis	409
Diarthrosis	ib.
Arthrodia	ib.
Ginglymus	ib.
Enarthrosis	ib.
LAGAMENTS OF THE TRUNK	410
Articulations of the vertebral column	ib.
of the atlas with the occipital bone	412
of the axis with the occipital bone	ib.
of the atlas with the axis	413
of the lower jaw	ib.
Dislocations	414
of the ribs with the vertebræ	ib.
of the ribs with the sternum	415
of the vertebral column with the pelvis	ib.
of the pelvis	ib.
LIGAMENTS OF THE UPPER EXTREMITY	419
Sterno-clavicular articulation	ib.
Scapulo-clavicular articulation	420
Proper ligaments of the scapula	ib.
Shoulder-joint	421
Elbow-joint	ib.
Radio-ulnar articulation	422
Wrist-joint	423
Articulation between the carpal bones	ib.
Carpo-metacarpal articulation	424
Metacarpo-phalangeal articulation	425
Articulation of the phalanges	ib.
LIGAMENTS OF THE LOWER EXTREMITY	426
Hip-joint	ib.
Knee-joint	427
Articulation between the tibia and fibula	430
Ankle-joint	ib.
Articulation of the tarsal bones	431
Articulation of the tarsus with the metatarsus	432
Metatarso-phalangeal articulation	433
Articulation of the phalanges	ib.

CHAPTER XII.

SYMPATHETIC NERVE.

General description	433
CRANIAL GANGLIA	434
Ganglion of Ribes	ib.
Ciliary ganglion	435
Naso-palatine ganglion	436
Spheno-palatine ganglion	ib.
Vidian nerve	437
Submaxillary ganglion	ib.
Otic ganglion	438
Carotid plexus	ib.
CERVICAL GANGLIA	ib.
Superior cervical ganglion	440
Middle cervical ganglion	ib.
Inferior cervical ganglion	ib.
Vertebral plexus	441
Cardiac nerves	ib.
Cardiac ganglion	ib.
Great cardiac plexus	442
Anterior cardiac plexus	ib.
Posterior cardiac plexus	ib.
Anterior coronary plexus	ib.
Posterior coronary plexus	ib.
THORACIC GANGLIA	443
Great splanchnic nerve	ib.
Lesser splanchnic nerve	ib.
Semilunar ganglion	444
Solar plexus	ib.
Abdominal plexuses	ib.
LUMBAR GANGLIA	ib.
Aortic plexus	ib.
Hypogastric plexus	445
SACRAL GANGLIA	445
Ganglion impar, or azygos	ib.

THE DISSECTOR.

CHAPTER I.

DISSECTION.

THE human body is composed of certain principal structures, which occupy the same relative position to each other, wheresoever they be examined. To obtain a good knowledge of these, is, therefore, the first duty of the dissector; the more particularly, that a just conception of their nature and position will greatly facilitate the future progress of his studies. These parts may be thus arranged, in the order of their superposition:—

Integument,	Arteries,
Superficial fascia,	Veins,
Deep fascia,	Lymphatics,
Muscles,	Nerves,
Vessels,	Bones and ligaments,

and cellular tissue, the common connecting medium of the body, by which they are all held together.

The business of dissection, therefore, consists in dividing and turning aside the integument, the superficial fascia, and the deep fascia; in freeing the muscles from their enveloping cellular tissue; in separating them, so as to display the vessels and nerves which lie between them; and in following the latter to their ultimate ramifications.

In the same manner the performance of an operation with the aid of the knife, as, for example, the tying of an artery, requires the division of the integument, superficial fascia, and deep fascia, the separation of the muscles, and the finding and securing of the vessel. So again in amputation, the same structures are to be divided, and in precisely the same order. Thus the student will perceive that one principal object of dissection, is the practice of his knife in the division

and separation of these parts, so as to enable him to accomplish his end with ease and dexterity. All the operations of dissection should be conducted with the same delicacy that is observed in the treatment of the living subject. The result of such practice must be obvious—the attainment of that confidence and precision in surgical manipulations, which is so necessary to the intelligent surgeon.

Now, let us inquire into the nature of the structures composing the preceding table.

The *integument* (integere, to cover in,) is the investing covering of the entire body; in common parlance, the skin: it consists, of

Cuticle,	{	Papillary layer,
Rete mucosum,		Corium.

The *cuticle* (epidermis, scarf-skin) is the thin horny layer that protects the surface of the integument. The *rete mucosum* is the soft layer interposed between the cuticle and cutis, in which the colouring particles of the skin are deposited. It is modelled upon the papillæ of the cutis, so as to resemble a beautiful network when examined beneath the microscope. Hence its designation *rete*; and *mucosum* from having been seen only when softened by decomposition, or by the irritation of a blister when the cuticle is raised. It may, however, with care, be separated from the cutis in layers of considerable size.

The *cutis* ($\sigma\chi\epsilon\rho\tau\omicron\varsigma$ the skin, dermis) is formed of two layers—a superficial, the *papillary*, which presents a surface bristled with papillary elevations variously arranged, in which resides the sensibility to touch; and a deep layer, the *corium* (leather,) which is firm, elastic, and resisting, and is made up of fibres and bands closely interwoven into each other, so as to give strength and support to the tegumentary covering.

The *superficial fascia* (fascia, a bandage,) placed immediately beneath the tegument over every part of the body, is the medium of connexion between that layer and the deeper parts. It consists of cellular tissue, in which is deposited an abundance of adipose matter. The fat, being a bad conductor of caloric, serves to retain the warmth of the body; while it forms at the same time a yielding tissue, through which the minute vessels and nerves may pass to the papillary layer of the skin, without incurring the risk of obstruction from injury or pressure upon the surface. By

dissection, the superficial fascia may be separated into *two layers*, between which are found the superficial or cutaneous vessels and nerves; as the superficial epigastric artery, the saphenous veins, the radial and ulnar veins, the superficial lymphatic vessels, or the cutaneous nerves, and in one instance a muscle, platysma myoides.

The *deep fascia* is a dense and resisting layer, found chiefly in the extremities and in the neck, where large vessels are carrying onwards the circulating fluids in opposition to the laws of gravity, and where muscles are often acting with prodigious force. In other situations, as over the trunk of the body or upon the head, this layer cannot be said to exist. The deep fascia in the limbs is a tendino-fibrous membrane, formed by a close interlacement of tendinous fibres, which cross each other in various directions. To the eye it presents a brilliant, nacreous lustre. It is strong and unyielding, enclosing the entire limb, and is prolonged into its substance so as to form distinct sheaths to all the muscles. Upon the inner side of the limb it is thin; on the outer and less protected side it is dense and thick. It is connected to the prominent points about the limb, as to the pelvis, knee, and ankle, in the lower extremity, and to the clavicle, scapula, elbow, and wrist, in the upper extremity. Its tension is regulated in some situations by muscular action, as by the tensor vaginæ femoris and gluteus maximus in the thigh, and by the biceps and palmaris longus in the arm.

The deep fascia of the neck is different in its structure from that in the limbs; it is a cellulo-fibrous membrane, and consists of cellular tissue very much condensed. It has no tendinous fibres, and none of their resplendency. In its office, it acts precisely the same part with the *tendino-fibrous fasciæ*.

The *muscles* (musculus, from movere, to move) are the moving organs of the body: they are made up of fibres disposed parallel to each other in a framework of cellular tissue. Towards the extremities of the muscles the fibres cease, and the cellular framework is condensed into a rounded cord, called *tendon* (tendo, a sinew,) by which it is attached to the bones. The more fixed extremity of a muscle is called the "*origin*;" its more moveable end the "*insertion*." The muscles which enclose cavities, as the abdominal, are broad and extensive; and their tendon is flattened out into a thin

expansion, which is called "*aponeurosis*" (*απο*, longé—*νευρον*, nervus—a nerve widely spread out.) This derivation demands some explanation. The ancients named all the white fibres of the body *νευρα*, or nerves.

The *vessels* are of three kinds—*arteries*, veins, and lymphatics. The former are cylindrical tubes, composed of three layers—an *external*, formed of condensed cellular tissue, the "*cellular coat*;" a *middle*, of fibres of elastic tissue, the "*fibrous coat*;" and a lining membrane, or "*serous coat*." After death they are usually found empty, but preserve their cylindrical form, by reason of the thickness of their coats; hence their name (*αρη τρησειν*, to contain air,) from a supposition of the ancients that they were intended to confine the vital spirits. Their office is to convey the vital fluid to every part of the system; and their ultimate terminations are denominated, from their extreme minuteness, *capillaries* (*capillus*, hair).

The *veins* are found in company with the arteries; with the exception of the superficial veins. They return the blood from the capillary vessels of the arteries to the right side of the heart, to be then circulated through the lungs. They are larger than the arteries, and after death are found filled with dark coloured blood. The coats are the same as those of the arteries, but much thinner; and the internal coat is reflected inwards at various points, so as to form valves. The position of these valves is evidently marked on the exterior of the tube, by the swellings on that part of the vessel which immediately precedes them.

The *lymphatics* (*lympa*, water,) are small, delicate vessels which accompany the veins, and present many points of resemblance with them. They return a limpid fluid to the venous circulation, and are provided with a number of valves placed at short distances, which, with the corresponding swellings, give them a knotted appearance. Their coats are the same as those of veins and arteries. Near the flexures of the joints they enter small red bodies, called *glands*, from which they emerge fewer in number, and larger in size. They are too minute to be seen in an ordinary dissection, unless the subject be anasarcaous.

The *nerves* (*νευρα*, nerves) are white, flattened cords, composed of filaments, which are connected by one extremity with the cerebro-spinal axis; and, by the other, are dis-

tributed to all the textures of the body, communicating to them sensibility and power of motion. The smallest nerve is made up of a number of filaments, enclosed in a peculiar transparent sheath, called *neurilema*; which, when freshly exposed, presents a contiguous zigzag line along its cylinder. The nerves are usually found accompanying the arteries, and, in the extremities, are placed nearer to the integument than those vessels, as if to be ready to apprize the neighbouring muscles of the first approach of injury, that they may withdraw the more immediately important organs, the arteries, from its consequences.

The *bones* are the organs of support to the animal frame. They give firmness and strength to the entire fabric, afford points of connexion to the numerous muscles, and bestow general form upon the body. In the limbs they are hollow cylinders, calculated by their form and structure to support weight, and resist violence. In the trunk and head they are flattened and arched, to protect cavities and provide extensive surfaces of attachment. In many situations they present projections of considerable length that serve as levers; and smooth surfaces that possess all the mechanical advantages of the pulley.

While strength and solidity are the principal objects sought for in the shaft of the bone, the extremities are expanded into broad surfaces, that they may transmit the weight of the body with perfect security to the bones below.

In the formation of a joint a new organ is introduced, "the *ligament*" (ligare, to bind). It consists of short strata of fibres passing from bone to bone, in order to connect them together. The different varieties of joint demand a different arrangement of these ligaments. Thus the *hinge joint*, as the elbow, wrist, knee, ankle, moving in one direction only, has necessarily a squareness of form, and is provided with a ligament to each of its four sides. These are named from their position, anterior, posterior, and lateral. A great proportion of the joints of the body are constructed upon this simple principle. When more extensive movements are demanded, the ball and socket joint is provided, and to accommodate its circular form, the four ligaments are, as it were, united into one; which completely surrounds the ends of the two bones. Hence in the capsular ligaments of the hip, the shoulder, and the thumb; and when repose and solidity are the great objects, as in the vertebral column, the pelvis, the

carpus, and tarsus ; small slips of ligament are seen passing from bone to bone in every direction in which these straight bands can be arranged, without inconvenience to the general plan.

These then are the structures of which, with the exception of the viscera, the whole animal frame is composed ; and it is incumbent upon the student of anatomy to possess a clear and distinct idea of all these parts, their uses, and natural dependencies, before he can hope to display and examine them in the body with advantage.

[The dissector should furnish himself with an apron with sleeves, which will protect his clothes from the contact with the subject or table, and a case of dissecting instruments. This case must contain from three to six scalpels of different sizes, a tenaculum, a double hook, a pair of forceps, a couple of needles, a pair of scissors, and a cartilage knife. Every other requisite is usually furnished by the rooms in which the student dissects. A dissector in the country must provide himself in addition with several large sponges, a couple of blocks of different sizes, a saw, and a mallet, and chisel.]

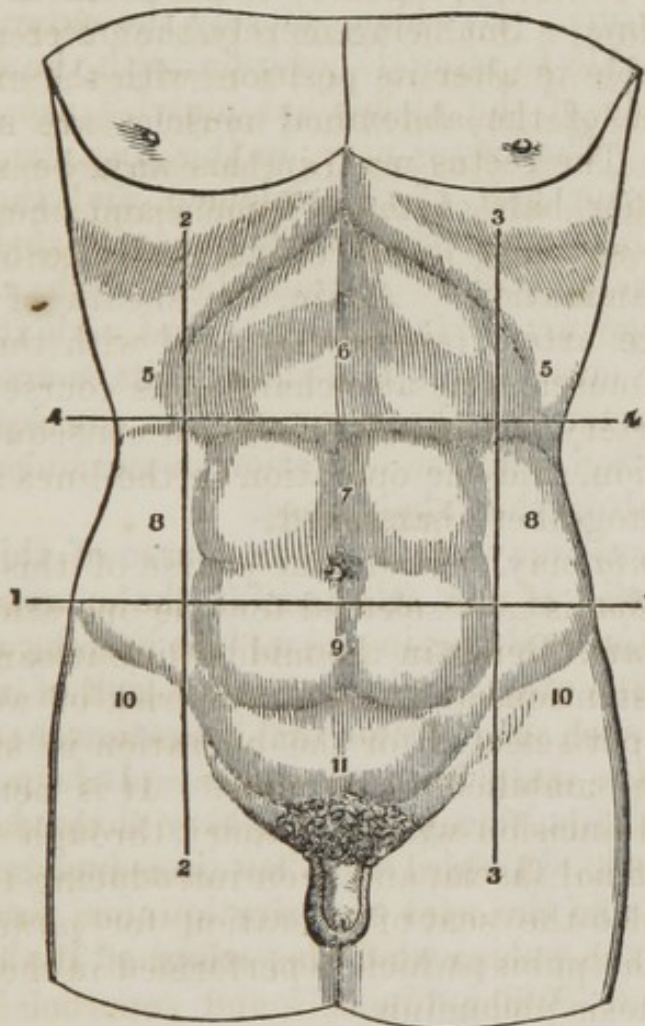
CHAPTER II.

ABDOMEN.

[The dissection of the abdomen is to be commenced by an incision from the lower part of the second piece of the sternum down the median line to the pubis, this incision must be carried on each side of the umbilicus so as to isolate it. A second incision starts from the upper end of the first, downwards and outwards, forming an angle with the first of about forty-five degrees. A third is to be commenced at the pubis and carried to the anterior superior spinous process of the ilium, and from thence around the crista of the ilium as far back as possible. When the skin and superficial fascia are raised from the central line outwards, commencing at the upper corner, the external oblique muscle will be fully uncovered. These latter incisions must be repeated on the opposite side of the subject.] The integument alone should be dissected at first, leaving the superficial fascia. Between

the two layers of the superficial fascia, at the lower part of the abdomen, is the *superficial epigastric artery and vein*; and, near the crest of the ilium, some branches of the *superficial circumflex artery and vein*. When these have been examined, the superficial fascia may be removed from the muscle. In turning back the flap, several superficial nerves will be cut across; these are cutaneous branches of the lower intercostal and lumbar nerves. If the flap be in the way, it may be removed altogether. One side of the abdomen should be dissected exclusively for the muscles, and on this side the skin and fascia may be taken up together; the other should be reserved for studying the relations of hernia.

Fig. 1.



Surface of the abdomen, with lines (1, 2, 3, 4) drawn upon it, marking off its artificial subdivisions into regions. 5, 5. Right and left hypochondriac. 6. Epigastric regions. 7. Umbilical. 8, 8. The two lumbar. 9. Hypogastric. 10, 10. The right and left iliac regions. 11. Regio pubis.

The *Muscles of the Abdomen* are the

External oblique,
Internal oblique,
Transversalis,

Rectus,
Pyramidalis.

If the external oblique muscle be dissected on both sides, a white tendinous line will be seen along the middle of the abdomen, extending from the ensiform cartilage to the pubis, this is the *linea alba*. A little external to it, on each side, two curved lines will be observed extending from the sides of the chest to the pubis, and bounding the recti muscles; these are the *lineæ semilunares*. Some transverse lines, *lineæ transversæ*, three or four in number, connect the *lineæ semilunares* with the *linea alba*.

The *Linea semilunaris* was the situation formerly chosen for the operation of tapping the abdomen in dropsy, *paracentesis abdominis*. But being merely the outer margin of a muscle, it is liable to alter its position with the expansion to which the whole of the abdominal muscles are subjected in that disease. The rectus may, in this way, be spread over the whole anterior half of the abdomen, and the *linea semilunaris* become so much displaced as hardly to be discerned by external examination. Again, the sheath of the rectus contains a large artery (*epigastric*); and with the increased breadth of the muscle, this also changes its course. In a few instances the artery has been wounded in consequence of this change of position, and the operation in the *linea semilunaris* is, therefore, altogether abandoned.

Ventral hernia may occur in the course of this line.

The *Linea alba* is now selected for the operation of *paracentesis abdominis*. Being in the middle line it cannot change its place by distention, and there is no risk of wounding an artery. The spot selected for the operation is usually midway between the umbilicus and pubis. It is performed by making a small incision with a bistoury through the integument and superficial fascia, and then introducing the trochar.

This line is also the seat of operation for *puncturing the bladder* above the pubis; which is performed in the same manner as *paracentesis abdominis*.

The *High operation for lithotomy*, a practice wholly disused in this country, has also its seat in the *linea alba*.

The *Cæsarian section* for opening the uterus and removing the foetus, an operation which is now becoming frequent, in consequence of success, is also practised in the *linea alba*.

Moreover, a weakening of the linea alba, from over-distention, or congenital deficiency, gives rise to the protrusion of intestine at the umbilicus, called *umbilical hernia*.

Deficiencies of development also occur in this line, in which some of the abdominal viscera are exposed; the most frequent instance of this arrest is in the case where the mucous membrane of the bladder is protruded through the integument. (Exstrophy of the bladder.)

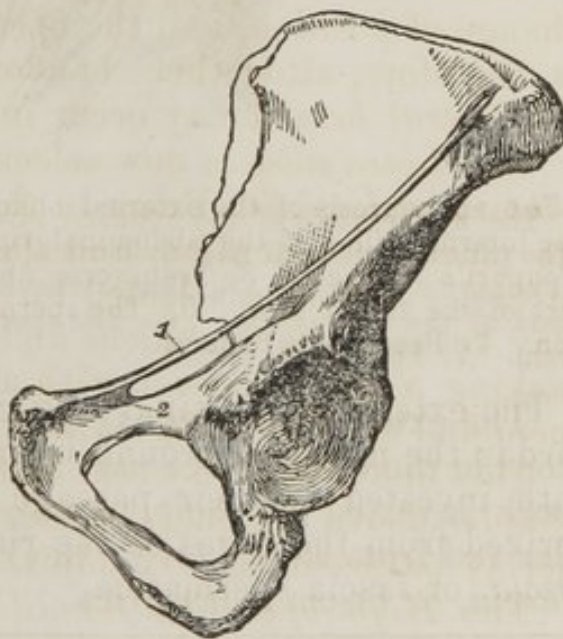The *External oblique muscle (obliquus externus abdominis)* is the external flat muscle of the abdomen. Its name is derived from the obliquity of its direction, and the descending course of its fibres. It *arises* by fleshy digitations from the external surface of the eight inferior ribs. The five upper digitations being received between corresponding processes of the serratus magnus, and the three lower of the latissimus dorsi, it spreads out into a broad aponeurosis, which is *inserted* into the outer lip of the crest of the ilium for one-half its length, the anterior superior spinous process of the ilium, spine of the pubis, pectineal line, front of the pubis, and linea alba.

The lower border of the aponeurosis, which is stretched between the anterior superior spinous process of the ilium (*fig. 3. 2.*) and the spine of the pubis, is folded inwards, forming *Poupart's ligament*, *fig. 2. 1.*

The insertion into the pectineal line is *Gimbernat's ligament*.*

Just above the crest of the pubis is the *External abdominal ring*, (*fig. 3. 1.*) a triangular opening formed by the separation of the fibres of the aponeurosis of the external oblique. It is oblique in its direction, and corresponds with the course of the fibres of the aponeurosis. It is bounded below by the crest of the pubis; on either side, by the borders of the aponeurosis, which are called *pillars*; and above, by

Fig. 2.

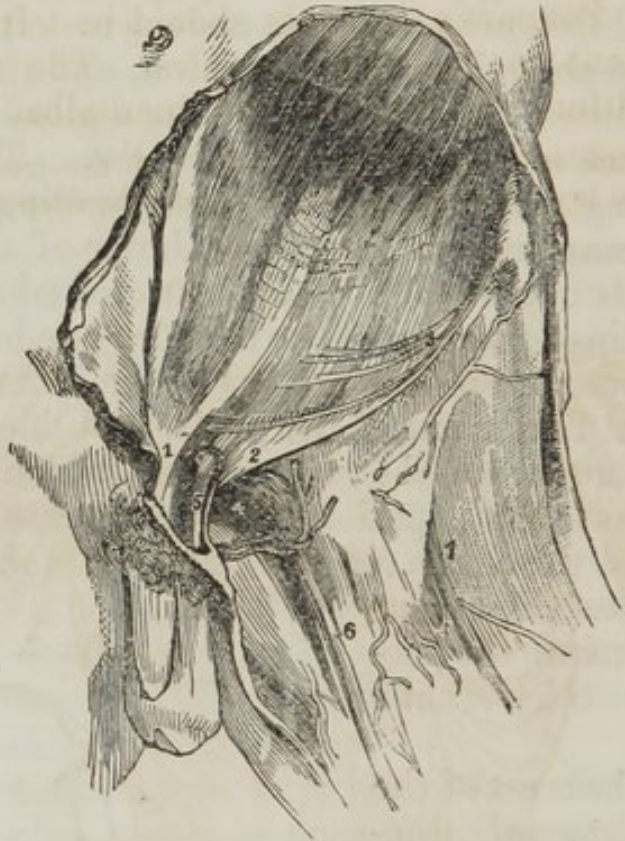

The innominate bone of the left side with, 1., Poupart's ligament; 2. Gimbernat's ligament.

* Antonio de Gimbernat, was surgeon to the King of Spain; he published

some curved fibres, which originate from Poupart's ligament, and cross the upper angle of the ring, so as to give it strength. The *external pillar*, fig. 3. 2. which is at the same time *inferior*, from the obliquity of the opening, as inserted into spine of the pubis; the *internal or superior pillar*, fig. 3. 1. forms an interlacement with its fellow of the opposite side, over the front of the symphysis pubis.

Fig. 3. The anatomy of inguinal hernia, the right inguinal region.



The aponeurosis of the external oblique muscle and the fascia lata.—1. The internal pillar of the abdominal ring. 2. The external pillar of same (Poupart's ligament). 3. Transverse fibres of the aponeurosis. 4. Pubic part of the fascia lata. 5. The spermatic cord. 6. The long saphenous vein. 7. Fascia lata femoris.

The external abdominal ring gives passage to the spermatic cord in the male, and round ligament in the female; they are both invested in their passage through it by a thin fascia derived from the edges of the ring, and called *inter-columnar fascia*, or *fascia spermatica*.

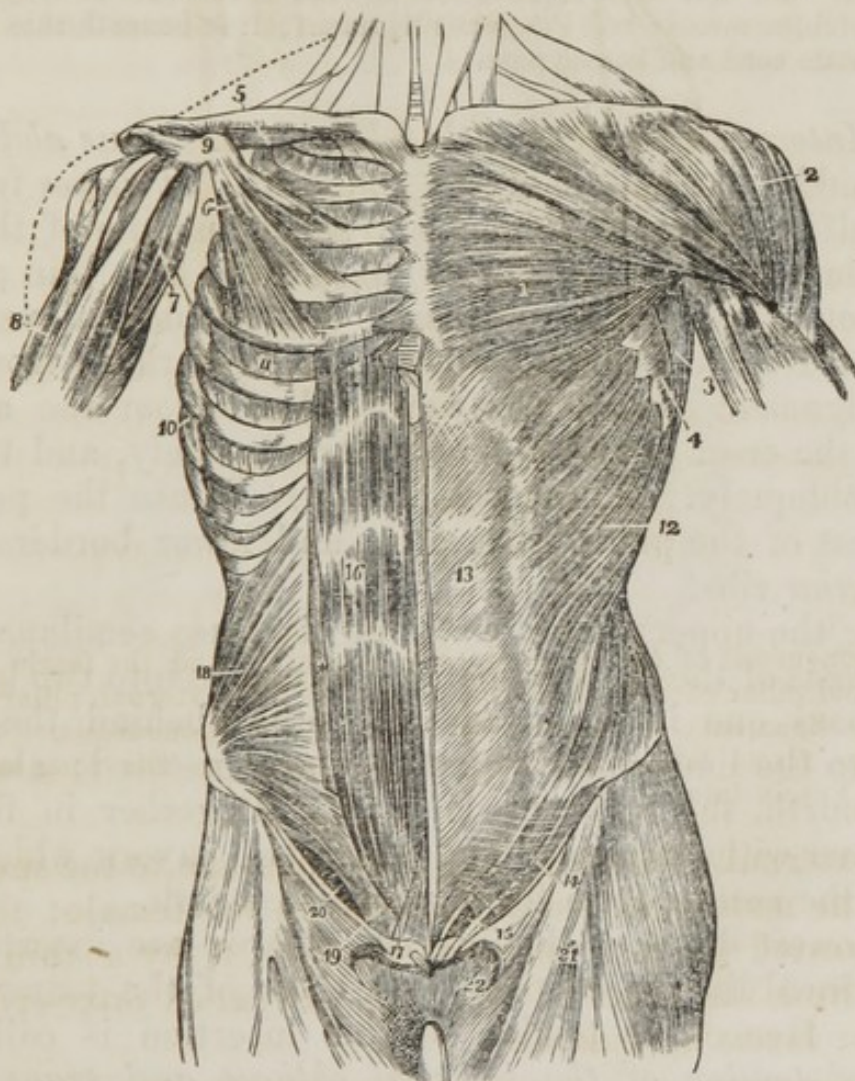
an excellent essay on femoral hernia in 1793, in which he pointed out the relations of this portion of the tendon of the external oblique to the neck of the sac. His work is entitled "Nuevo Metodo de Operar en la Hernia Crural."

The pouch of inguinal hernia, in passing through this opening, receives the *inter-columnar fascia*, as one of its coverings.

The posterior border of the external oblique is in close relation with the anterior border of the latissimus dorsi, which sometimes overlaps it.

The external oblique is now to be removed by making an incision across the ribs just below its origin to its posterior border, and another along Poupart's ligament and the crest of the ilium. Poupart's ligament should be left entire, as it gives attachment to the next muscles. The muscles may then be turned forwards towards the linea alba.

Fig. 4. The muscles of the anterior aspect of the trunk; on the left side the superficial layer is seen, and on the right the deeper layer.



1. The pectoralis major muscle. 2. The deltoid; the interval between these muscles lodges the cephalic vein. 3. The anterior border of the latissimus dorsi. 4. The serrations of the serratus magnus. 5. The sub-clavius muscle of the right side. 6. The pectoralis minor. 7. The coraco-

brachialis muscle. 8. The upper part of the biceps muscle, showing its two heads. 9. The coracoid process of the scapula. 10. The serratus magnus of the right side. 11. The external intercostal muscle of the fifth intercostal space. 12. The external oblique muscle. 13. Its aponeurosis; the median line to the right of this number is the *linea alba*; the flexuous line to its left is the *linea semilunaris*; and the transverse lines above and below the number, the *lineæ transversæ*, of which there were only three in this subject. 14. Poupart's ligament. 15. The external abdominal ring; the margin above the ring is the superior or internal pillar; the margin below the ring, the inferior or external pillar; the curved intercolumnar fibres are seen proceeding upwards from Poupart's ligament to strengthen the ring. The numbers 14 and 15 are situated upon the fascia lata of the thigh; the opening immediately on the right of 15 is the saphenous opening. 16. The rectus muscle of the right side brought into view by the removal of the anterior segment of its sheath; * the posterior segment of its sheath with the divided edge of the anterior segment. 17. The pyramidalis muscle. 18. The internal oblique muscle. 19. The conjoined tendon of the internal oblique and transversalis descending behind Poupart's ligament to the pectineal line. 20. The arch formed between the lower curved border of the internal oblique muscle and Poupart's ligament; it is beneath this arch that the spermatic cord and hernia pass.

The *Internal oblique muscle (obliquus internus abdominis)* is the middle flat muscle of the abdomen. It arises from the outer half of Poupart's ligament, from the middle of the crest of the ilium for two-thirds of its length, and by a thin aponeurosis from the spinous processes of the lumbar vertebræ. Its fibres diverge from their origin, so that those from Poupart's ligament curve downwards, those from the anterior part of the crest of the ilium pass transversely, and the rest ascend obliquely. The muscle is inserted into the pectineal line, crest of the pubis, *linea alba*, and lower borders of the five inferior ribs.

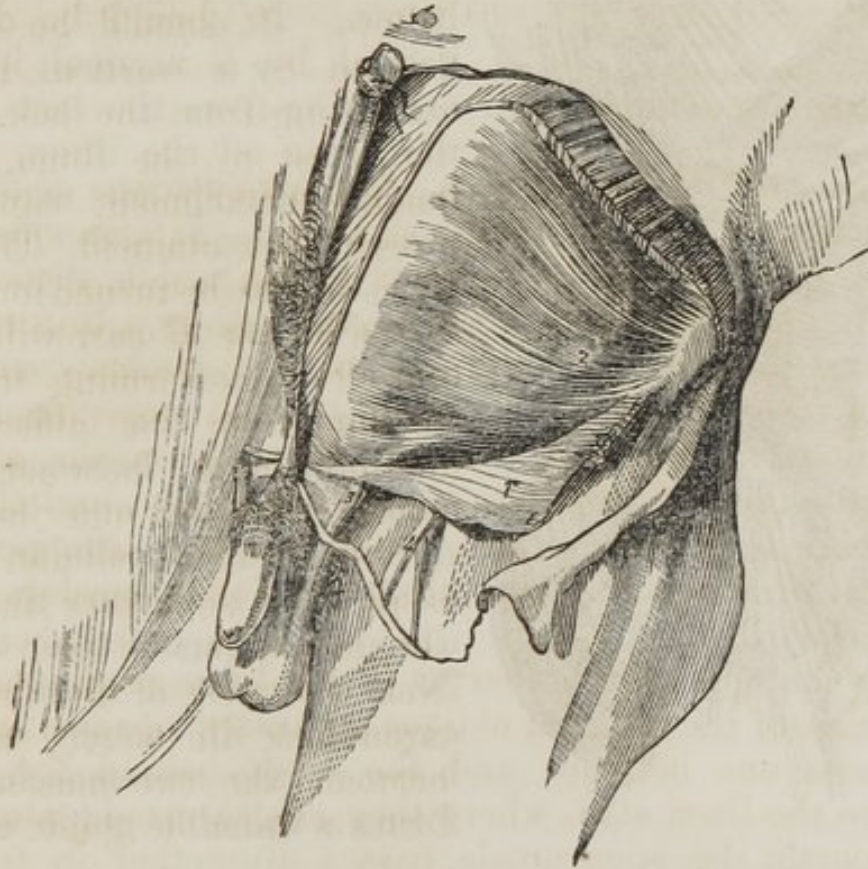Along the upper three-fourths of the *linea semilunaris*, the aponeurosis of the internal oblique separates into two lamellæ, which pass one in front and the other behind the rectus muscle to the *linea alba*, where they are inserted; along the lower fourth, the aponeurosis passes altogether in front of the rectus without separation. The two layers which thus enclose the rectus, form for it a partial sheath.

The lowest fibres of the internal oblique are inserted into the pectineal line, in common with those of the transversalis muscle. Hence the tendon of this insertion is called the *conjoined tendon of the internal oblique and transversalis (fig. 5. 6.)* This structure corresponds with the external abdominal ring, and forms a protection to what would otherwise be a weak point in the abdomen. Sometimes it is

insufficient to resist the pressure from within and becomes forced through the external ring: it then forms the distinctive covering of *direct inguinal hernia*.

The spermatic cord passes beneath the arched border of the internal oblique muscle, between it and Poupart's ligament. During its passage some fibres are given off from the lower border of the muscle, which accompany the cord downwards to the testicle, and form loops around it: this is the cremaster muscle. In the descent of oblique inguinal hernia, which travels the same course with the spermatic cord, the cremaster muscles form one of its coverings.

Fig. 5. The internal oblique and transversalis muscle in the inguinal region, with the boundaries of the inguinal canal.



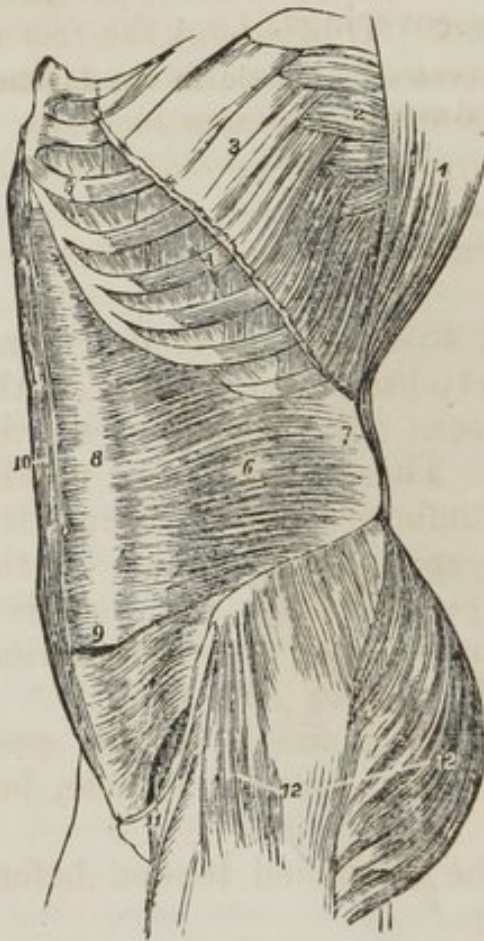
The aponeurosis of the external oblique muscle having been divided and turned down, the internal oblique is brought into view with the spermatic cord escaping beneath its lower edge.—1. Aponeurosis of the external oblique. 1'. Lower part of same turned down. 2. Internal oblique muscle. 3. Spermatic cord. 4. Saphenous vein.

The *Cremaster*, considered as a distinct muscle, *arises* from the middle of Poupart's ligament, and forms a series of loops upon the spermatic cord. A few of its fibres are inserted into the tunica vaginalis, the rest ascending along the inner

side of the cord, to be *inserted*, with the conjoined tendon, into the pectineal line of the pubis.

A large nerve is seen piercing the lower fibres of the internal oblique muscle, and passing through the external abdominal ring with the spermatic cord, to which it is distributed: this is the *scrotal branch of the ilio-scrotal nerve (superior musculo-cutaneous)*.

Fig. 6. A lateral view of the trunk of the body, showing its muscles, and particularly the transversalis abdominis.



The internal oblique muscle is to be removed by separating it from its attachment to the ribs above, and to the crest of the ilium and Poupart's ligament below. It should be divided behind by a vertical incision extending from the last rib to the crest of the ilium, as its lumbar attachment cannot at present be examined. The muscle is then to be turned forwards. Some degree of care will be required in performing this dissection from the difficulty of distinguishing between this muscle and the one beneath. A thin layer of cellular tissue is all that separates them for the greater part of their extent. Near the crest of the ilium the circumflex ilii artery ascends between the two muscles, and forms a valuable guide to their

1. The costal origin of the latissimus dorsi muscle.
2. The serratus magnus.
3. The upper part of the external oblique muscle divided in the direction best calculated to show the muscles beneath without interfering with its indigitations with the serratus magnus.
4. Two of the external intercostal muscles.
5. Two of the internal intercostals.
6. The transversalis muscle.
7. Its posterior aponeurosis.
8. Its anterior aponeurosis, forming the most posterior layer of the sheath of the rectus.
9. The lower part of the left rectus with the aponeurosis of the transversalis passing in front.
10. The right rectus muscle.
11. The arched opening left between the lower border of the transversalis muscle and Poupart's ligament, through which the spermatic cord and hernia pass.
12. The gluteus maximus, and medius, and tensor vaginæ femoris muscles invested by fasciâ lata.

separation. Near to Poupart's ligament they are so closely connected that it is impossible to divide them.

The *Transversalis* is the internal flat muscle of the abdomen; it is transverse in the direction of its fibres, as is implied in its name. It *arises* from the outer third of Poupart's ligament, from the internal lip of the crest of the ilium, its anterior two-thirds; from the lumbar vertebræ, and from the inner surfaces of the six inferior ribs, indigitating with the diaphragm. Its lower fibres curve downwards, to be *inserted*, with the lower fibres of the internal oblique, into the pectineal line, and form the conjoined tendon. Throughout the rest of its extent it is inserted into the crest of the pubis and linea alba. The *lower fourth* of its aponeurosis passes in front of the rectus to the linea alba; the *upper three-fourths*, with the posterior lamella of the internal oblique, behind it.

The *Posterior aponeurosis* of the transversalis divides into three lamellæ:—

1. *Anterior*, which is attached to the bases of the transverse processes of the lumbar vertebræ.
2. *Middle*, to the apices of the transverse processes.
3. *Posterior*, to the apices of the spinous processes.

The anterior and middle lamellæ enclose the quadratus lumborum muscle; and the middle and posterior, the erector spinæ. The union of the posterior lamella of the transversalis with the posterior aponeurosis of the internal oblique, serratus posticus inferior, and latissimus dorsi, constitutes the *lumbar fascia*.

The spermatic cord and oblique inguinal hernia pass beneath the lower border of the transversalis muscle, but have no direct relation with it.

Direct inguinal hernia forces the conjoined tendon before it, which forms one of its coverings.

The muscular branch of the circumflex ilii artery will be seen near to the crest of the ilium, ramifying upon the transversalis. Some muscular and cutaneous branches of the lumbar nerves will soon be seen perforating its fibres.

To dissect the *rectus muscle*, the sheath should be opened by a vertical incision extending from over the cartilages of the lower ribs to the front of the pubis. The sheath may then be dissected off and turned to either side: this is easily done excepting at the lineæ transversæ, where a close adhesion subsists between the muscle and the external boundary of the sheath. The sheath contains the rectus and pyramidalis muscles.

The *Rectus muscle* arises by a flattened tendon from the crest of the pubis, and is *inserted* into the cartilages of the fifth, sixth, and seventh ribs. It is traversed by several tendinous zig-zag lines, called *lineæ transversæ*. One of these is situated at the umbilicus, two above that point, and one below. They are vestiges of the abdominal ribs of reptiles, and very rarely extend completely through the muscle.

The *Pyramidalis muscle* arises from the crest of the pubis in front of the tendon of the rectus, and is *inserted* into the *linea alba* at about midway between the umbilicus and the pubis.

The rectus may now be divided across the middle, and the two ends drawn aside for the purpose of examining the mode of formation of its sheath.

The *Sheath of the rectus* is formed *in front* for the upper three-fourths of its extent, by the aponeurosis of the external oblique and the anterior lamella of the internal oblique, and *behind* by the posterior lamella of the internal oblique and the aponeurosis of the transversalis. At the commencement of the lower fourth, the posterior wall of the sheath terminates in a thin curved margin, the aponeurosis of the three muscles passing altogether in front of the rectus.

The quadratus lumborum must be left until the viscera of the abdomen have been examined.

ACTIONS.—The external oblique muscle, acting singly, would draw the thorax towards the pelvis, and twist the body to the opposite side. Both muscles, acting together, would flex the thorax directly on the pelvis. The internal oblique of one side draws the chest downwards and outwards: both together bend it directly forwards. Either transversalis muscle, acting singly, will diminish the size of the abdomen on its own side, and both together will constrict the entire cylinder of the cavity. The recti muscles, assisted by the pyramidales, flex the thorax upon the chest.

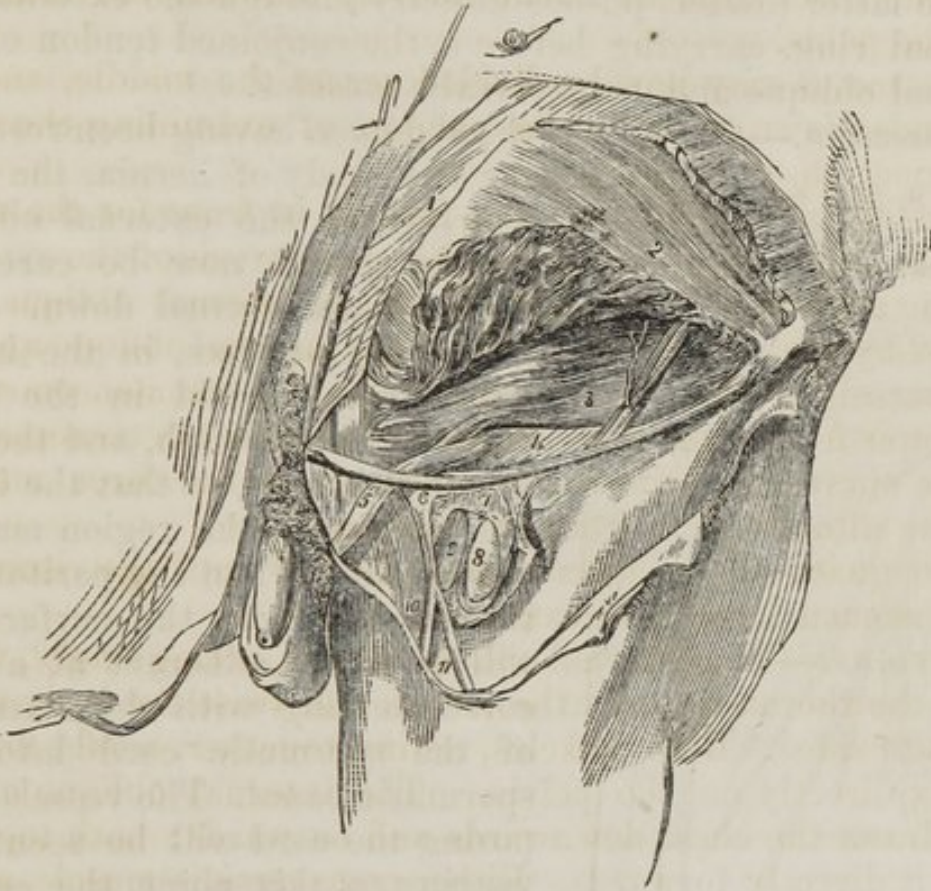
The abdominal muscles are the chief agents of expulsion; by their action the foetus is expelled from the uterus, the urine from the bladder, the fæces from the rectum, the bile from the gall-bladder, and the ingesta from the stomach and bowels in vomiting. To produce these efforts they all act together. Their violent and continued action produces hernia; and, acting spasmodically, they may occasion rupture of the viscera.

ANATOMY OF HERNIA.

The herniæ occurring in the parietes of the abdomen have been divided by Sir Astley Cooper into four species; namely, *umbilical*, *ventral*, *inguinal*, and *femoral*: to which may be added, as occasionally occurring, *phrenic*, *obturator*, *ischiatric*, *gluteal*, *perineal*, and, in the female, *vaginal*.

Umbilical hernia occurs at the umbilicus from weakening

Fig. 7.



After the removal of the lower part of the external oblique (with the exception of a small slip including Poupart's ligament), the lower portion of the internal oblique was raised, and thereby the transversalis muscle and fascia have been brought into view. The femoral artery and vein are seen to a small extent, the fascia lata having been turned aside and the sheath of the blood-vessels laid open.—1. External oblique muscle. 2. Internal oblique. 2'. Part of same turned up. 3. Transversalis muscle. Upon the last-named muscle is seen a branch of the circumflex iliac artery, with its companion veins; and some ascending tendinous fibres are seen over the conjoined tendon of the two last-named muscles. 4. Transversalis fascia. 5. Spermatic cord covered with the infundibuliform fascia from preceding. 6. Upper angle of the iliac part of fascia lata. 7. The sheath of the femoral vessels. 8. Femoral artery. 9. Femoral vein. 10. Saphenous vein. 11. A vein joining it.

of the linea alba, either by over-distention, as in utero-gestation, or from congenital deficiency. Its coverings are the

Integument,	Distended aponeurosis,
Superficial fascia,	Peritoneum.

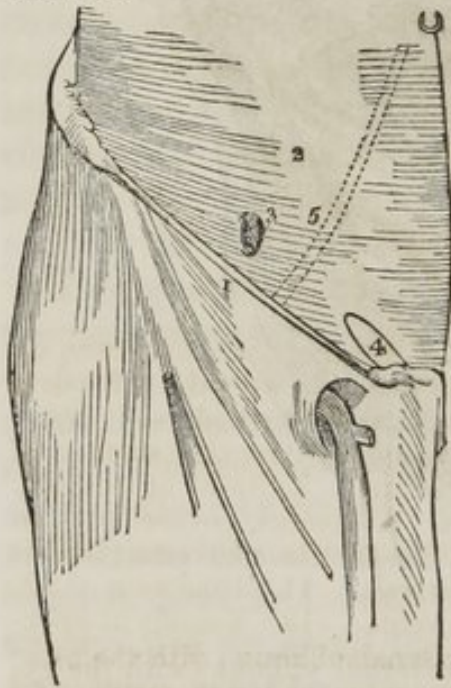Ventral hernia occurs chiefly in the linea semilunaris, and from the same causes: its coverings are the same; but it has usually three layers of aponeurosis.

Inguinal hernia is of two kinds, *oblique* and *direct*: the former takes the course of the spermatic canal, descending by the side of the spermatic cord.

The latter (*direct*) pushes directly through the external abdominal ring, carrying before it the conjoined tendon of the internal oblique and transversalis muscles.

Dissection.—One side of the abdomen having been reserved for the study of hernia, the aponeurosis of the external oblique muscle should now be carefully dissected and turned down. The abdominal parietes, in the inguinal region, should in the next place be cut through, and the flap drawn forwards, so that the internal surface of the region may be examined. When the peritoneum is removed from the surface, it will be found adherent at a part corresponding with the entrance of the spermatic cord into the spermatic canal. The vessels composing the cord will be seen converging to this point, the spermatic artery from over the psoas muscle, and the vas deferens from

Fig. 8. The transversalis fascia, the abdominal muscles being removed.



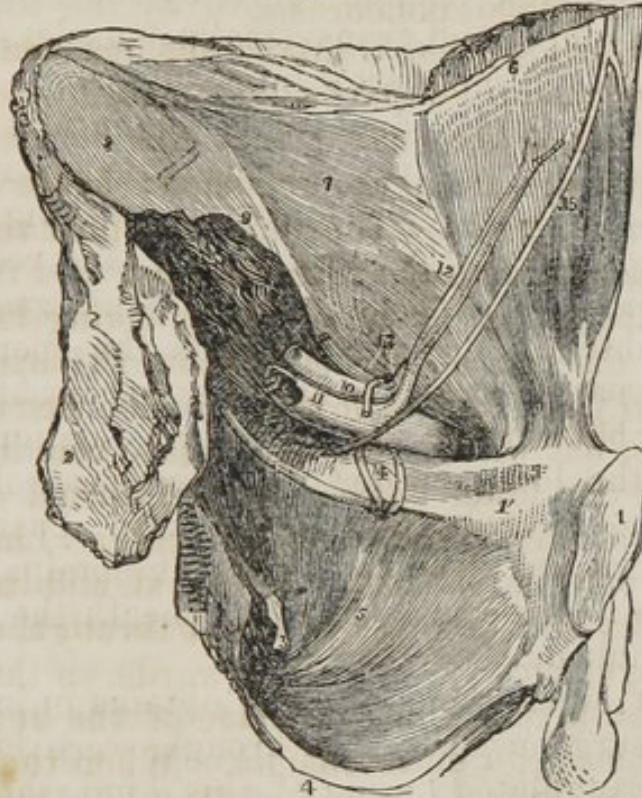1. Poupart's ligament. 2. The transversalis fascia. 3. The internal abdominal ring, an opening in the transversalis fascia. 4. The situation of the external abdominal ring. 5. A dotted line marking the course of the epigastric artery between the two rings.

the side of the bladder. The epigastric artery will also be seen ascending obliquely to the sheath of the rectus.

Beneath the peritoneum, and immediately investing the transversalis muscle, is the *transversalis fascia* (*fig. 8. 2.*) a dense layer of cellular fibrous membrane, continuous with Poupart's ligament, 1., below, and on the inner side with the edge of the sheath of the rectus: above and upon the outer

side it is gradually lost in the subserous cellular tissue. In this fascia, which is an important defence to the occurrence of hernia in the inguinal region, is situated the opening for the transmission of the spermatic cord, the *internal abdominal ring*, 3.

Fig. 9.



A portion of the wall of the abdomen and of the pelvis is here seen on the posterior aspect, the os innominatum of the left side with the soft parts connected with it having been removed from the rest of the body.—1. Symphysis of pubes. 1'. Horizontal branch of same. 2. Irregular surface of the ilium which has been separated from the sacrum. 3. Spine of ischium. 4. Tuberosity of same. 5. Obturator internus. 6. Rectus, covered with an elongation from 7. Fascia transversalis. 8. Fascia iliaca covering iliacus muscle. 9. Psoas magnus cut. 10. Iliac artery. 11. Iliac vein. 12. Epigastric artery and its two accompanying veins. 13. Vessels of spermatic cord, entering the abdominal wall at the internal ring. The ring was in this case of small size. 14. Two obturator veins. 15. The obliterated umbilical artery. This cord, it will be remembered, is not naturally in contact with the abdominal parietes in this situation.

The *internal abdominal ring* (fig. 8. 3.) is an oblique opening in the fascia transversalis, situated midway between the anterior superior spinous process of the ilium and the spine of the pubis, and about half an inch above Poupart's ligament. The border of the ring invests the spermatic cord with an *infundibuliform sheath* in its passage through it, and the hernial protrusion taking the same course obtains necessarily the same sheath or covering.

The *Spermatic canal* is the oblique space in the abdominal parietes, near to Poupart's ligament, which transmits the spermatic cord. It is about an inch and a-half in length, is terminated at one extremity by the internal ring, and at the other by the external ring. It is bounded in front by the aponeurosis of the external oblique, and behind by the fascia transversalis and conjoined tendon above by the lower margins of the internal oblique and transversalis muscles, and below by the folded edges of Poupart's ligament.

It is along this *oblique canal* that the hernial protrusion travels in its passage from the abdomen: hence it is named *Oblique inguinal hernia*. The intestine, pushing before it a *sac of peritoneum*, enters the internal ring, and receives from it the *infundibuliform process of the transversalis fascia*, which, in the absence of hernia, invests the spermatic cord alone. It then passes beneath the lower border of the transversalis muscle, but without any immediate relation. It next passes beneath the lower border of the internal oblique, and receives the *cremaster muscle* as a covering. Lastly, emerging from the external abdominal ring, it obtains the *inter-columnar fascia*, and becomes placed beneath the superficial fascia and integument.

The different layers which it thus obtains in its progress, and which the surgeon must cut through, were he called to operate on a strangulated hernia of this kind, the *coverings of the hernia*, as they are technically called, are, the

Integument,	Cremaster,
Superficial fascia,	Fascia transversalis,
Inter-columnar fascia,	Peritoneal sac.

If the hernia be small and become strangulated while situated within the spermatic canal, the external wall of that canal must be laid open. The layers to be divided would then be, the

Integument,	Cremaster,
Superficial fascia,	Fascia transversalis,
Aponeurosis of the external oblique,	Peritoneal sac.

Oblique inguinal hernia in its course through the spermatic canal lies above the spermatic cord. In rare cases the hernial protrusion may separate the components of the cord, so that some of them may lie in front of the tumour. Hence one of many reasons for extreme care and caution in operating for strangulated hernia.

Turning again to the inner wall of the abdomen, and observing the position of the internal ring, the epigastric artery will be seen ascending to its inner side. And on the inner side of the artery is a smooth and rather depressed triangular surface, which is the seat of the protrusion of intestine in *direct inguinal hernia*.

Direct inguinal hernia is named from passing *directly* through the external abdominal ring. It pushes before it a *sac of peritoneum*, the *transversalis fascia*, the *conjoined tendon*, and as it escapes at the external ring receives an investment from the *inter-columnar fascia*. Its coverings are therefore, the

Integument,	Conjoined tendon,
Superficial fascia,	Transversalis fascia,
Inter-columnar fascia,	Peritoneal sac.

In escaping at the external ring it often carries the spermatic cord before it, so that the vessels of which it is composed become spread over the front of the hernial sac, or slip to one side.

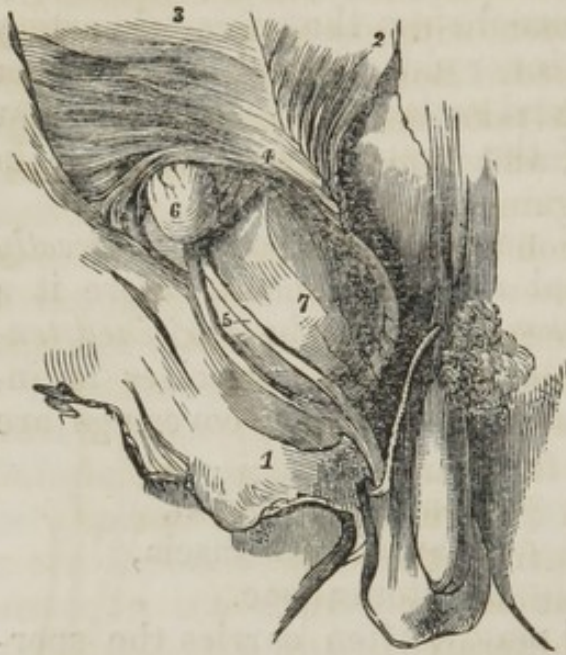The *Seat of stricture* in all the varieties of inguinal hernia is always the neck of the sac. In recent oblique hernia the neck of the sac is formed by the internal ring. In old and large hernia, the internal ring is dragged down so as to become placed exactly opposite the external, and the two together form its neck. In direct hernia, the fascia transversalis with the border of the conjoined tendon are the structures forming the neck of the sac.

Fig. 10.



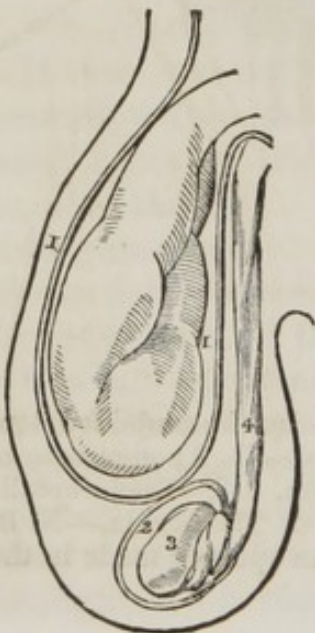
A direct inguinal hernia on the left side, covered by the conjoined tendon of the internal oblique and transverse muscles.—1. Aponeurosis of the external oblique. 2. Internal oblique turned up. 3. Transversalis muscle. 4. Fascia transversalis. 5. Spermatic cord. 6. The hernia.—N. B. A small part of the epigastric artery is seen through an opening made in the transversalis fascia.

Fig. 11.



A small oblique inguinal hernia, and a direct one, are seen on the right side. A little of the epigastric artery has been laid bare, by dividing the fascia transversalis immediately over it.—1. Tendon of the external oblique. 2. Internal oblique turned up. 3. Transversalis. 4. Its tendon (the epigastric artery is shown below this number). 5. The spermatic cord (its vessels separated). 6. A bubonocoele. 7. Direct hernia protruded beneath the conjoint tendon of the two deeper muscles, and covered by an elongation from the fascia transversalis.

Fig. 12. Common oblique inguinal hernia. The intestine in a distinct sack of peritoneum and separated from the testicle by the tunica vaginalis.



inwards in direct hernia, to avoid wounding this artery. But as the diagnosis of the exact nature of the hernia is always uncertain, and as the division of the epigastric artery would possibly be fatal, and as moreover obliquity in the direction of the incision is quite unnecessary for the safety of the operation, experience has established the rule, that the incision should be made *directly upwards* in every case of inguinal hernia; and if the history of femoral hernia be referred to, it will be seen that a general principle may be established, that in all cases of abdominal hernia, *inguinal, femoral, umbilical, or ventral*, the incision is invariably to be made *directly upwards*.

1. The sac of the hernia. 2. The tunica vaginalis enclosing the testicle. 3, 4. The spermatic cord.

If oblique and direct hernia existed together, it is obvious from the position of the epigastric artery, (*fig. 9. 12.*) that that vessel would be placed between the necks of both; and if either existed separately, the artery would be situated to the *inner side of oblique*, and to the *outer side of direct hernia*. In the division of the stricture, therefore, the surgeon would make his incision *upwards and outwards in oblique and upwards and*

There are two varieties of oblique inguinal hernia occasionally met with; these are *congenital* and *encysted*. Both result from protrusions, which take the course of the spermatic canal, and they differ from common oblique inguinal, and from each other, only in relation to the tunica vaginalis of the testicle.

In the descent of the testicle from the abdomen into the scrotum in the foetus, a sac of peritoneum is carried with it. The form of this sac may be familiarly illustrated by the simile of a Florence flask. The neck of the pouch from the internal ring to near the testicle, becomes gradually closed and obliterated, and that portion of it which remains and encloses the testicle is the *tunica vaginalis*.

Fig. 13. 1. The tunica vaginalis testis, continuous superiorly with the peritoneum, of which it is a part. 2. The testicle. 3. The spermatic cord.

Common oblique hernia, (*fig. 12.*), occurring in this condition of the tunica vaginalis, is placed altogether above it, and in a distinct sac or pouch of peritoneum.

Congenital hernia (*fig. 13.*) results from the nonclosure of the sac of the tunica vaginalis; the intestine, in its descent, passes along the open canal left by the transit of the testicle, and enters the tunica vaginalis, being in actual contact with the testicle. The sac of congenital hernia is, therefore, the tunica vaginalis itself. In other respects it exactly resembles common oblique hernia.

Fig. 14. 1. The hernial sac. 2. The cavity of the tunica vaginalis. 3. The testicle. 4. The spermatic cord. The arrow shows that three layers of serous membrane must be divided before the intestine can be reached.

Fig. 13. Congenital hernia, the intestine being in contact with the testicle; the tunica vaginalis of the testicle forming the sac of the hernia.

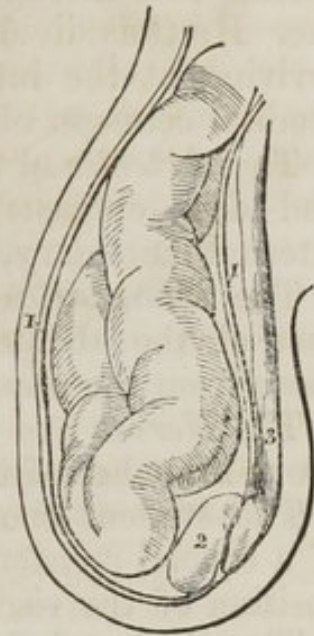
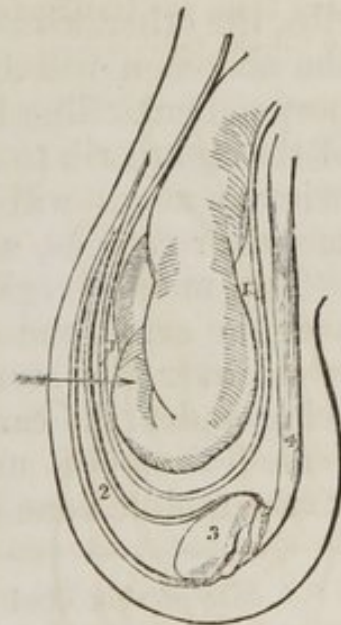


Fig. 14. Encysted hernia; the hernial sac containing the intestine being behind the tunica vaginalis.



In *encysted hernia** (*fig. 14.*) (*hernia infantilis* of Hey) the neck of the pouch of the tunica vaginalis is closed only at the upper part, and the hernia carrying with it a peritoneal sac descends behind the tunica vaginalis, so that, in operating, the surgeon opens first the tunica vaginalis, and, finding no hernia, cuts through its other side until he reaches the hernial sac. He thus divides *three layers of serous membrane*, before arriving at the intestine. In other respects the hernia resembles common oblique inguinal.

The *Arteries* of the Abdominal parietes are the superficial and deep epigastric, superficial and deep-circumflexed ilii, internal mammary, inferior intercostal, and lumbar.

The *Lymphatics* accompany the veins, those from the lower part of the abdomen passing into the inguinal glands, and those from the upper ascending to the mediastinal glands.

The *Nerves* are the inferior intercostal and musculo-cutaneous branches of the lumbar plexus.

The student should now lay open the abdomen by means of a crucial incision, and study its divisions into regions, the position of the viscera, and the peritoneum.

The *Cavity of the abdomen* is bounded in front and at the sides by the lower ribs and abdominal muscles; behind, by the vertebral column and abdominal muscles; above, by the diaphragm; and, below, by the pelvis.

REGIONS.—See Fig. 1. If two transverse lines be carried around the body, the one parallel with the convexities of the ribs, the other with the highest points of the crests of the ilia, the abdomen will be divided into three zones. Again, if a perpendicular line be drawn at each side from the cartilage of the eighth rib to the middle of Poupart's ligament, the three primary zones will each be subdivided into three compartments or regions, a middle and two lateral.

The middle region of the upper zone being immediately over the small end of the stomach, is called *Epigastric* (*ἐπι-γαστήρ*, over the stomach,) *fig. 1. 6.* The two lateral regions being under the cartilages of the ribs, are called *Hypochondriac* (*ὑπό-χονδροί*, under the cartilages,) 5. The middle region of the middle zone is the *Umbilical*, 7. The two lateral, the

* A case of this kind occurred to Mr. Liston in 1835. The student will find a full account of it in a Clinical Lecture in the 1st volume of the *Lancet* for 1834--5, page 883.

Lumbar, 8. The middle region of the inferior zone is the *Hypogastric* (ὕπὸ—γαστήρ, below the stomach;) 9. And the two lateral, the *Iliac*. 10

In addition to these divisions, we constantly use the term *Inguinal region*, meaning thereby the vicinity of Poupart's ligament.

POSITION OF THE VISCERA.—In the *upper zone* will be seen the liver extending across from the right to the left side; the stomach and spleen on the left, and the pancreas and duodenum behind. In the *middle zone* is the transverse portion of the colon, with the upper part of the ascending and descending colon, omentum, small intestine, mesentery; and, behind, the kidneys and their capsules. In the *inferior zone* is the lower part of the omentum and small intestines, the cœcum, ascending and descending colon, with the sigmoid flexure and ureters.

The smooth and polished surface, which the viscera and parietes of the abdomen present, is due to the peritoneum, which may now be studied.

PERITONEUM.

The *Peritoneum* is a serous membrane, and, therefore, a shut sac: a single exception alone exists in the human subject to this character, viz. in the female, where the peritoneum is perforated by the open extremities of the Fallopian tubes.

The simplest idea that can be given of a serous membrane, which applies equally to all, is, that it invests the viscus or viscera, and is then reflected upon the parietes of the containing cavity. If the cavity contain only a single viscus, the consideration of the serous membrane is extremely simple. But in the abdomen, where there are a number of viscera, the serous membrane passes from one to the other until it has invested the whole before it is reflected on the parietes. Hence its reflections are a little more confused.

In tracing the reflections of the peritoneum in the middle line, we commence with the diaphragm, which is lined by two layers, one from the parietes in front, *anterior*, and one from the parietes behind, *posterior*. These two layers of the same membrane meet at about the middle of the diaphragm, and descend to the upper surface of the liver, forming the *lateral ligaments* of the liver. They then *surround* the *liver*, and, meeting at its under surface, pass

to the stomach, forming the *lesser omentum*. They then *surround* the *stomach*, and meeting at its lower border, descend for some distance in front of the intestines, and return to the transverse colon, forming the *great omentum*; they then *surround* the *transverse colon*, and pass directly backwards to the vertebral column, forming the transverse *meso-colon*. Here the two layers separate; the *posterior* ascends in front of the pancreas and aorta, and returns to the posterior part of the diaphragm, where it forms the posterior layer with which we commenced. The *anterior* descends, *invests* all the *small intestines*, and returning to the vertebral column, forms the *mesentery*. It then descends into the pelvis in front of the rectum, which it holds in its place by means of a fold called *meso-rectum*, forms a pouch between it and the bladder, ascends upon the posterior surface of the bladder, forming its false ligaments, and returns upon the anterior parietes of the abdomen to the diaphragm, whence we first traced it.

In the female, after descending into the pelvis in front of the rectum, it is reflected upon the posterior surface of the vagina and uterus. It then descends on the anterior surface of the uterus, and forms at either side the broad ligaments. From the uterus it ascends upon the posterior surface of the bladder and anterior parietes of the abdomen, and is continued as in the male to the diaphragm.

In this way the continuity of the peritoneum, as a whole, is distinctly shown, and it matters not where the examination commence, or where it terminate, still the same continuity of surface will be discernible throughout. If we trace it from side to side of the abdomen, we may commence at the umbilicus; we then follow it outwards, lining the inner side of the parietes to the ascending colon; it surrounds that intestine; it then surrounds the small intestine, and returning on itself forms the mesentery. It then invests the descending colon, and reaches the parietes on the opposite side of the abdomen, whence it may be traced to the exact point from which we started.

The viscera, which are thus shown to be investèd by the peritoneum in its course from above downwards, are the

Liver,

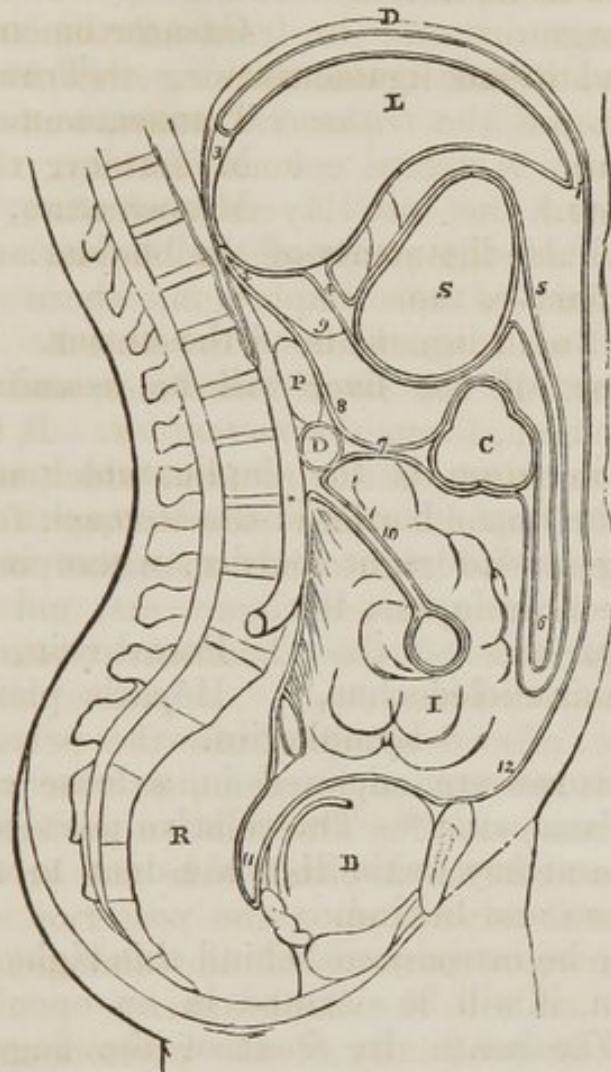
Transverse colon,

Stomach,

Small intestines,

Pelvic viscera.

Fig. 15.



The reflections of the peritoneum. D. The diaphragm. S. The stomach. C. The transverse colon. D. The transverse duodenum. P. The pancreas. I. The small intestines. R. The rectum. B. The urinary bladder. 1. The anterior layer of the peritoneum, lining the under surface of the diaphragm. 2. The posterior layer. 3. The two layers passing to the posterior border of the liver, and forming the coronary ligament. 4. The lesser omentum; the two layers passing from the under surface of the liver to the lesser curve of the stomach. 5. The two layers meeting at the greater curve, then passing downwards and returning upon themselves, forming (6) the greater omentum. 7. The transverse meso-colon. 8. The posterior layer traced upwards in front of D, the transverse duodenum, and P, the pancreas, to become continuous with the posterior layer (2). 9. The foramen of Winslow; the dotted line bounding this foramen inferiorly, marks the course of the hepatic artery forwards, to enter between the layers of the lesser omentum. 10. The mesentery encircling the small intestine. 11. The recto vesical fold, formed by the descending anterior layer. 12. The anterior layer traced upwards upon the internal surface of the abdominal parietes to the layer (1,) with which the examination commenced.

The folds, formed between these and between the diaphragm and the liver, are

Diaphragm.	Greater omentum.
Transverse and broad ligaments. (Liver.)	(Transverse colon.) Transverse meso-colon,
Lesser omentum. (Stomach.)	Mesentery, Meso-rectum,
	False ligaments of the bladder.

And in the female, the
Broad ligaments of the uterus.

The ligaments of the liver will be examined with that organ.

The *lesser omentum* is the duplicature passing between the liver and the upper border of the stomach: it is extremely thin, excepting at its right border, where it is free, and contains between its layers, the

Hepatic artery,	Portal vein,
Ductus communis choledochus,	Hepatic plexus of nerves,
	Lymphatics.

These structures are enclosed in a loose cellular tissue, called *Glisson's capsule*.* The relative position of the three vessels is,—the artery to the left, the duct to the right, and the vein between and behind.

If the finger be introduced behind this right border of the lesser omentum, it will be situated in an opening called the *foramen of Winslow*.† In *front* of the finger will lie the right border of the lesser omentum; *behind* it the diaphragm, covered by the ascending or posterior layer of the peritoneum; *below*, the hepatic artery, curving forwards from the cœliac axis; and, *above*, the lobulus Spigelii. These, therefore, are the *boundaries of the foramen of Winslow*, which is nothing more than a constriction of the general cavity of the peritoneum at this point, arising out of the necessity for the hepatic and gastric arteries passing forwards from the cœliac axis to reach their respective viscera.

If air be blown through the foramen of Winslow, it will descend behind the lesser omentum and stomach to the space between the descending and ascending pair of layers, forming

* Francis Glisson, Professor of Medicine in the University of Cambridge. His work, "De Anatomia Hepatis," was published in 1654.

† Jacob Benignus Winslow: his "Exposition Anatomique de la Structure du Corps Humain," was published in Paris in 1732.

the great omentum. This is sometimes called the lesser cavity of the peritoneum, and that external to the foramen the greater cavity; in which case the foramen is considered as the means of communication between the two. There is a great objection to this division, as it might lead the inexperienced to believe that there was really two cavities. There is but one only, the foramen of Winslow being merely a constriction of that one, to facilitate the communication between the nutrient arteries and the viscera of the upper part of the abdomen.

The *Great omentum* consists of *four layers of peritoneum*, the two which descend from the stomach, and the same two, returning upon themselves to the transverse colon. A quantity of adipose substance is deposited in its structure. It would appear to perform a double function in the economy—1st, protecting the intestines from cold; and, secondly, facilitating the movements of the intestines upon each other during their distention.

The *Transverse meso-colon* ($\mu\epsilon\sigma\sigma\omicron\varsigma$, middle,) being attached to the middle of the cylinder of the intestine, is the medium of connexion between the transverse colon and the posterior wall of the abdomen: it also affords to the nutrient arteries a passage to reach the intestines. It encloses between its layers at the posterior part, the transverse portion of the duodenum.

The *Mesentery* ($\mu\epsilon\sigma\sigma\omicron\nu\ \epsilon\nu\tau\epsilon\rho\omicron\nu$, being attached to the middle of the cylinder of the small intestine) is the medium of connexion between the small intestines and the posterior wall of the abdomen. It is oblique in its direction, being attached to the posterior wall, from the left side of the second lumbar vertebra to the right iliac fossa. It retains the small intestines in their places, and gives passage to the mesenteric arteries, veins, nerves, and lymphatics.

The *Meso-rectum*, in like manner, retains the rectum in connexion with the front of the sacrum. Besides this, there are some minor folds in the pelvis, as the *false ligaments of the bladder* and *broad ligaments of the uterus*.

The *Appendices epiploicæ* are small irregular pouches of peritoneum, filled with fat, and situated like fringes upon the large intestine.

Three other duplicatures of peritoneum are situated in the

sides of the abdomen: they are the gastro-splenic omentum, the ascending and descending meso-colon.

The *Gastro-splenic omentum* is the duplicature which connects the spleen to the stomach: and the *ascending* and *descending meso-cola* are the folds which retain the corresponding portions of the colon in their situations.

VISCERA OF THE ABDOMEN.

The *Viscera of the abdomen* are the *alimentary canal*, the organs subservient to digestion, viz. the *liver*, *pancreas*, and *spleen*, and the organs of excretion, the *kidneys*, and their *capsules*.

The *Alimentary canal* is a musculo-membranous tube, extending from the mouth to the anus. It is variously named in the different parts of its course: hence it is divided into the

Pharynx,	Œsophagus,	Stomach.
	{	
Small intestine	Duodenum,	
	Jejunum,	
	Ileum.	
	{	
Large intestine	Cœcum,	
	Colon,	
	Rectum.	

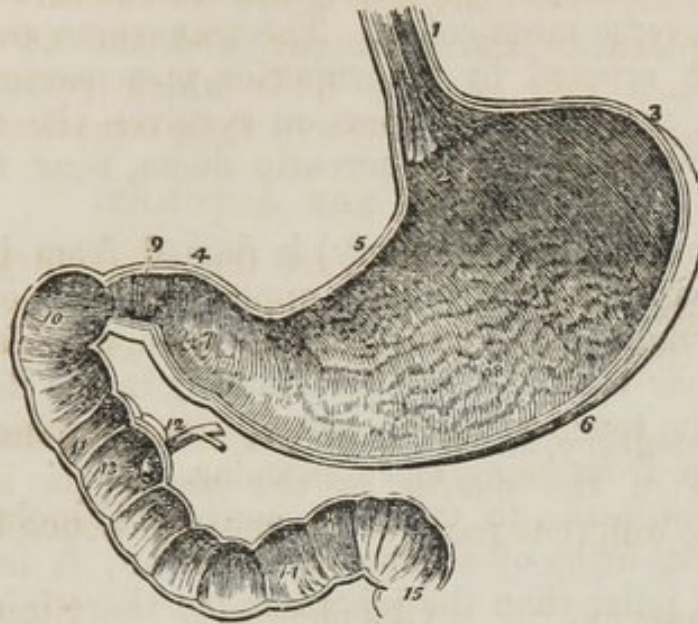
The *Pharynx* is situated behind the mouth, and extends from the base of the skull to the fifth cervical vertebra.

The *Œsophagus* commences opposite the fifth cervical vertebra, and descends the neck, behind and rather to the left of the trachea. It then passes beneath the arch of the aorta, and along the posterior mediastinum in front of the thoracic aorta to the œsophageal opening in the diaphragm, where it enters the abdomen, and terminates at the cardiac orifice of the stomach.

The *Stomach* is an expansion of the alimentary canal situated in the left hypochondriac region, and extending into the epigastric. On account of the peculiarity of its form, it is divided into a *greater* or *splenic*, and a *lesser*, or *pyloric end*, a *lesser curvature* above, and a *greater curvature* below, a *cardiac orifice* and a *pyloric orifice*.

The *Great end* is not only of large size, but expands beyond the point of entrance of the œsophagus. The *pylorus* is the small and contracted extremity of the organ.

Fig. 16. A vertical and longitudinal section of the stomach and duodenum, made in such a direction as to include the two orifices of the stomach.



1. The œsophagus; upon its internal surface the plicated arrangement of the cuticular epithelium is shown. 2. The cardiac orifice of the stomach, around which the fringed border of the cuticular epithelium is seen. 3. The great end of the stomach. 4. Its lesser or pyloric end. 5. The lesser curve. 6. The greater curve. 7. The dilatation at the lesser end of the stomach which received from Willis the name of, antrum of the pylorus. This may be regarded as the rudiment of a second stomach. 8. The rugæ of the stomach formed by the mucous membrane: their longitudinal direction is shown. 9. The pylorus. 10. The oblique portion of the duodenum. 11. The descending portion. 12. The pancreatic duct, and the ductus communis, choledochus close to their termination. 13. The papilla upon which the ducts open. 14. The transverse portion of the duodenum. 15. The commencement of the jejunum. In the interior of the duodenum and jejunum, the valvulæ conniventes are seen.

The two *Curvatures* give attachment to the peritoneum; the upper curve to the lesser omentum, and the lower to the greater omentum.

The *Small intestines* are divided into three portions *duodenum*, *jejunum*, and *ileum*.

The *Duodenum* (called δωδεκαδακτυλον by Herophilus) is named from being equal in length to the breadth of twelve fingers. Commencing at the pylorus it ascends *obliquely* to the under surface of the liver: it next descends *perpendicularly* in front of the right kidney, and then passes nearly *transversely* across the vena cava and aorta, opposite the third lumbar vertebra. It terminates in the jejunum on the left side of the second lumbar vertebra.

The *first* part of its course is completely enclosed by the peritoneum: the *second* is in apposition with the peritoneum only in front, and the *third* lies between the diverging layers of the transverse meso-colon. The transverse portion of the duodenum is crossed by the superior mesenteric artery and vein. The perpendicular portion receives the ductus communis choledochus, and pancreatic ducts, near to its lower angle.

The *Jejunum* (jejunus empty) is named from being found generally empty. It forms the upper two-fifths of the small intestine, commencing at the duodenum on the left side of the second lumbar vertebra, and terminating in the ileum. It is thicker to the touch than the rest of the intestine, and has a pinkish tinge from being more vascular.

The *Ileum*, (*ελειν*, to twist, to convolute) includes the remaining three-fifths of the small intestine; it is thinner in texture, and paler than the jejunum; but there is no mark by which to distinguish the termination of the one or the commencement of the other. It terminates in the right iliac fossa, by opening into the colon.

The *Large intestine* is divided into the *cæcum*, *colon*, and *rectum*.

The *Cæcum* (cæcus, blind) is the blind pouch or cul-de-sac at the commencement of the large intestine. It is situated in the right iliac fossa, and is retained in its place by the peritoneum, which passes over its anterior surface; its posterior surface is connected by loose cellular tissue with the iliac fascia. Attached to its extremity is the appendix vermiformis, a long worm-shaped tube, the rudiment of the lengthened cæcum, found in all mamiferous animals but man and the higher quadrumana.

The *Colon* is divided into *ascending*, *transverse*, and *descending*.

The *Ascending colon* passes upwards from the right iliac fossa, through the right lumbar region, to the under surface of the liver. It then bends inwards, and crosses the upper part of the umbilical region under the name of *transverse colon*, and on the left side descends (*descending colon*) through the left lumbar region to the left iliac fossa, where it makes a remarkable curve upon itself, which is called *sigmoid flexure*.

Rectum.—The large intestine then enters the pelvis, and descends in front of the sacrum, lying rather to its left side.

At the lower part of the pelvis it becomes considerably dilated, and makes a sudden bend backwards to terminate at the constricted opening of the anus.

Structure of the Intestinal Canal.

The pharynx and œsophagus have but two coats, the mucous and muscular; the stomach and intestines have three, *mucous* and *muscular*, and an external *serous* investment derived from the peritoneum.

MUCOUS COAT.—The mucous membrane of the pharynx is smooth, and is continuous with the mucous lining of the Eustachian tubes, the nares, the mouth, and the larynx. In the œsophagus it is disposed in *longitudinal plicæ*. In the stomach it is arranged in *rugæ* (wrinkles,) and at the pylorus forms a spiral fold, called the *pyloric valve*. In the lower half of the duodenum, the whole length of the jejunum, and upper part of the ileum, it forms valvular folds called *valvulæ conniventes*. These folds do not entirely surround the cylinder of the in-

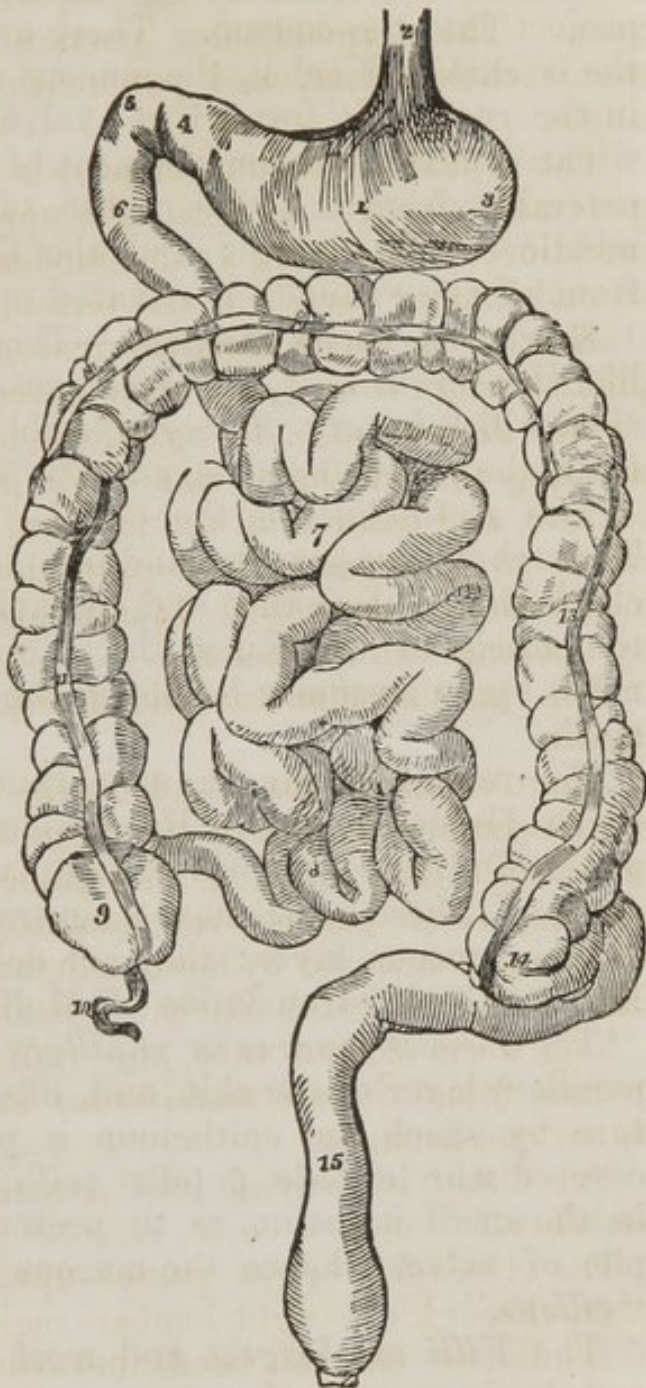


Fig. 17. Diagram of the stomach and intestines, to show their course.—1. Stomach. 2. Œsophagus. 3. Left, and 4. Right end of the stomach. 5. 6. Duodenum. 7. Convolutions of jejunum. 8. Those of ileum. 9. Cæcum. 10. Vermiform appendix. 11. Ascending. 12. Transverse; and 13. Descending colon. 14. Commencement of sigmoid flexure. 15. Rectum.

testine, but extend for about three-fourths of its circumference.

In the lower part of the ileum the mucous lining is without folds; hence the thinness of the coats of this intestine as compared with the jejunum and duodenum. At the termination of the ileum in the cœcum, the mucous membrane forms two folds, which are strengthened by the muscular coat, and project into the cœcum. These are the *iliocœcal valve*. In the cœcum and colon, the mucous membrane is smooth; but, in the rectum, it forms three valvular folds, one of which is situated near the commencement of the intestine; the second, extending from the side of the tube, is placed opposite the middle of the sacrum; and the third, proceeding from the front of the cylinder, is situated opposite the prostate gland.

Structure of Mucous Membrane.—This membrane is not simple, like the serous coat, but is composed of three layers like the skin, which it very closely resembles. These are the *epithelium*, the *proper mucous*, and the *fibrous layer*.

The *Epithelium* is the cuticle of the mucous membrane. Throughout the pharynx and œsophagus it resembles the cuticle, both in appearance and character. It is continuous with the cuticle of the skin at the margin of the lips, and terminates by an irregular border at the cardiac orifice of the stomach.

The rest of the mucous membrane has been recently shown by Dr. Henle* to be equally provided with an epithelium, composed of minute pyriform bodies placed perpendicularly to the surface. These bodies have a central nucleus, and are secreted by the mucous layer; they are delineated and described in Dr. Baly's able translation of Muller's Physiology.

The *Proper mucous* or *papillary layer*, is analogous to the papillary layer of the skin, and, like it, is the secreting structure by which the epithelium is produced. Its surface is covered with minute papillæ (*villi*), which are so numerous in the small intestine, as to present the appearance of the pile of velvet; hence the mucous surface has been named "*villous*."

The *Villi* are largest and most numerous in the stomach and duodenum, covering every part of the surface of the rugæ and valvulæ conniventes. They are not so abundant in the jejunum, but are still in sufficient number to give to that intestine its characteristic thickness and vascularity. In the

* Opus citatum.

ileum they are fewer and less developed, and in the large intestine have a particular arrangement.

The mucous layer is very loosely connected with the fibrous. It is continuous at the lips and at the anus with the papillary layer of the cutis.

The *Fibrous layer* (submucous, nervous) is the membrane of support to the mucous membrane, as is the corium to the papillary layer of the skin. It gives to the mucous membrane its strength and resistance. It is but loosely connected with the mucous layer, but is firmly adherent to the muscular coat. It is called, in the older works on anatomy, the "*nervous coat*."

In the loose cellular tissue connecting the mucous with the fibrous layer, are situated the four kinds of mucous glands belonging to the mucous membrane: these are

- Simple follicles (Lieberkuhn's),
- Glandulæ solitariae,
- Glandulæ aggregatae (Peyer's),
- Duodenal glands (Brunner's).

The *Simple follicles*, or follicles of Lieberkuhn, are small pouches of the mucous layer, situated in immense numbers in every part of the membrane.

The *Solitary glands* are very generally called Brunner's, but erroneously; for that anatomist confined his description to those situated in the duodenum: we have, therefore, attached his name only to the latter. The solitary glands are found in the stomach, small intestine, and large intestine; but are most numerous in the cœcum. They are small flattened granular bodies, without any apparent opening upon the surface of the membrane.

The *Aggregate*, or Peyer's* glands, are principally situated near to the lower end of the ileum, and occupy that portion of the intestine which is opposite the attachment of the mesentery. They present the appearance of oval patches, covered with small irregular fissures, which separate the secreting lobules.

The *Duodenal*, or *Brunner's*† glands, are small flattened granular bodies, compared collectively by Von Brunn to a

* John Conrad Peyer, an anatomist of Schaffhausen, in Switzerland. His essay, "*De Glandulis Intestinorum*," was published in 1677.

† John Conrad von Brunn: "*Glandulæ Duodeni seu Pancreas Secundarium*," 1715.

second pancreas. They resemble in structure the small salivary glands so abundant beneath the mucous membrane of the mouth and lips; and, like them, they open upon the surface by minute secretory ducts.

Besides the mucous follicles and glands, there are a considerable number of small lengthened follicles embedded in the mucous membrane of the stomach, which secrete the gastric juice—the *gastric follicles*.

MUSCULAR COAT.—The muscular coat of the pharynx consists of five pairs of muscles.

The muscular coat of the rest of the alimentary canal is composed of two planes of fibres, an *external, longitudinal*, and an *internal, circular*.

The *Œsophagus* is very muscular; its longitudinal fibres are continuous above with the pharynx, and are attached in front to the ridge on the cricoid cartilage. Below, both sets of fibres are continued upon the stomach.

On the *Stomach* there is a distortion of the longitudinal fibres in consequence of the expansion of its great end, which gives rise to a new order of muscular fibres, the *oblique*. The *longitudinal* are most apparent along the lesser curve, the *oblique* at the great end of the stomach, and the *circular* at the lesser end. At the pylorus the circular fibres produce a constriction, which, with a spiral fold of mucous membrane, forms the *pyloric valve*.

The *Small intestine* is provided with both layers, equally distributed over the whole surface. At the termination of the ileum the circular fibres are continued into the two folds of the ilio-cæcal valve, while the longitudinal fibres pass onwards to the large intestine.

In the *Cæcum* and *colon* these longitudinal fibres are collected into *three bands*, which, being shorter than the intestine, give it the puckered and sacculated appearance which is characteristic of the large intestine. The circular fibres are very thin.

In the *Rectum*, the three longitudinal bands spread out and form a thick and very muscular, longitudinal layer. There are no circular fibres: they appear to have slipped downwards to the lower end of the intestine, and to have formed there a thick muscular ring, the internal sphincter ani.

SEROUS COAT.—The pharynx and œsophagus have no other external covering than a layer of condensed cellular tissue.

The alimentary canal within the abdomen has a serous layer, derived from the peritoneum.

The *Stomach* is completely surrounded by the peritoneum. The *first* or *oblique portion of the duodenum* is also completely included by the serous membrane. The *descending portion* has merely a partial covering on its anterior surface. The *transverse portion* is also behind the peritoneum, being situated between the two layers of the transverse meso-colon, and has but a partial covering.

The rest of the *small intestines* are completely invested by it. The *cæcum* and *commencement of the colon* have the serous membrane only on their anterior surface: to the rest of the colon it forms a complete covering.

The upper third of the rectum is completely enclosed by the peritoneum; the middle third has only an anterior covering, and the inferior third none whatsoever.

The expression, complete covering, in the above description, must be received with limitation. No peritoneal investment can be perfectly complete, as a certain space must necessarily be left uncovered in every viscus for the entrance and exit of vessels. This spot corresponds with the point of reflection of the serous membrane.

VESSELS AND NERVES.—The *Arteries* of the alimentary canal, as they supply the tube from above downwards, are the ascending pharyngeal, superior thyroid, and inferior thyroid in the neck; œsophageal in the thorax; gastric, hepatic, splenic, superior and inferior mesenteric in the abdomen; and inferior mesenteric, iliac, and internal pudic in the pelvis.

The *Veins* from the abdominal alimentary canal unite to form the vena portæ.

The *Lymphatics* open into the receptaculum chyli.

The *Nerves* of the pharynx and œsophagus are derived from the glosso-pharyngeal, pneumogastric, and sympathetic.

The nerves of the stomach are the pneumogastric and sympathetic branches from the solar plexus; and those of the intestinal canal are the superior and inferior mesenteric and hypogastric plexuses. The extremity of the rectum is supplied by the coccygeal nerves from the spinal cord.

Dissection.—The student should now raise the transverse colon, and pin it upwards upon the chest. He should then draw the whole of the small intestines over to the left side.

Then let him dissect the peritoneal layer from the middle line, opposite the third lumbar vertebra, and he will expose the superior mesenteric artery, and by its side the superior mesenteric vein. The branches of the artery should be carefully cleared of fat and cellular tissue. In the progress of the dissection the nervous filaments, lacteals, and lymphatic glands will be exposed.

The SUPERIOR MESENTERIC ARTERY is the second single vessel given off by the abdominal aorta; it arises from that trunk behind the pancreas, passes forwards between it and the transverse duodenum, and descends within the layers of the mesentery to the right iliac fossa. It forms a slight curve in its course, the convexity being directed to the left, and the concavity to the right.

Branches.—From the convexity are given off from fifteen to twenty branches to the small intestine, which supply the canal, from the commencement of the jejunum to the termination of the ileum; and from the concavity are derived the ilio-colica, colica dextra, and colica media. They may be better studied in a tabular form:—thus,

Vasa intestini tenuis, 15 to 20.	Colica dextra,
Ilio-colica,	Colica media.

The branches of the mesenteric arteries have a peculiar distribution: they form in the first instance a succession of arches, by the communication of their larger branches. From these are developed secondary arches, and from the latter a third series of arches from which the branches arise, which are to be distributed to the coats of the intestine. By means of these arches a direct communication is established throughout the entire length of the alimentary canal, from the stomach to the rectum.

The branches to the small intestines communicate with the pancreatico-duodenalis, a branch of the hepatic, *above*, and with the ilio-colic *below*.

The *Ilio-colic* is given off from about the middle of the trunk of the superior mesenteric; it divides into branches, which are distributed to the lower end of the ileum and the commencement of the colon, and inosculates on the one hand with the termination of the superior mesenteric artery, and on the other with the colica dextra.

The *Colica dextra* arises from the superior mesenteric, a

little above its middle; it is distributed to the ascending colon, and inosculates with the ilio-colic and colica media.

The *Colica media* arises from the upper part of the superior mesenteric, and passes forwards between the layers of the transverse meso-colon, to be distributed to the transverse colon. It inosculates on the right with the colica dextra, and on the left with the colica sinistra, a branch of the inferior mesenteric.

Each branch of the superior mesenteric artery is accompanied by a vein, which is returning the blood from the intestines. The union of these veins forms a large trunk, the *superior mesenteric vein*, which is situated to the right of the artery, and passes behind the pancreas to unite with the inferior mesenteric, splenic, and gastric veins, and thus form the *vena portæ*.

The Lacteals are almost too minute to be seen in an ordinary dissection: but they may often be detected as a number of minute opaque lines, converging to the mesenteric glands. They terminate in the receptaculum chyli.

The Mesenteric glands are lymphatic glands in structure and function; they are most numerous near the attached border of the root of the mesentery.

The Superior mesenteric plexus accompanies the branches of the artery, and is distributed to the coats of the intestine; it is derived from the solar plexus.

Dissection.—The small intestines should now be removed by cutting through the mesentery near to its intestinal border, and placing a ligature around the jejunum at its commencement, and another around the ileum near its termination. They may then be set aside for the purpose of examining their interior, and the arrangement of the mucous membrane, at a convenient moment. It would be desirable also that the student should inflate a portion of the upper part of the jejunum, and of the lower part of the ileum, that he may observe their appearance when dry. The valvulæ conniventes will thus form a pretty and useful preparation. Then dissect carefully the anterior layer of the left meso-colon, and the inferior mesenteric artery, with its branches, will be brought into view.

The INFERIOR MESENTERIC ARTERY arises from the abdominal aorta, about two inches below the origin of the superior mesenteric. It descends between the layers of the

left meso-colon, to the left iliac fossa, where it divides into three branches:—

Colica sinistra, Sigmoideæ, Superior hæmorrhoidal.

The *Colica sinistra* is distributed to the descending colon, and ascends to inosculate with the colica media. This is the largest arterial inosculature in the body.

The *Sigmoideæ* are several branches which are distributed to the sigmoid flexure of the descending colon. They form arches, and inosculate above with the colica sinistra, and below with the superior hæmorrhoidal artery.

The *Superior hæmorrhoidal* artery descends along the meso-rectum, to the upper part of the rectum, to which it is distributed, anastomosing with the middle hæmorrhoidal branches of the internal pudic.

The *Inferior mesenteric vein* is formed by the convergence of branches returning the blood along the course of the artery, and terminates behind the pancreas in the portal vein.

The *Lymphatics* pass inwards to the numerous glands situated along the course of the aorta.

The *Inferior mesenteric plexus* accompanies, with its filaments, all the branches of the artery. It is derived from the solar and aortic plexuses.

Dissection.—The large intestines should now be removed altogether, and a ligature placed around the upper part of the rectum. The student should then pin up the liver and inflate the duodenum and stomach with a small quantity of air. The blowpipe may be inserted for this purpose into the upper part of the jejunum, which was left on the removal of the small intestines. Next remove the middle portion of the lesser omentum, and feel for the cœliac axis. The branches of the cœliac axis should then be dissected and followed to their distribution. It would be well to avoid disturbing the cœliac axis itself at present, as it is surrounded by the solar plexus, which must be afterwards examined.

The **CÆLIAC AXIS** is the first single trunk given off by the abdominal aorta; it is very short, and divides into three large arteries, the *gastric*, *hepatic*, and *splenic*.

The **GASTRIC ARTERY** (*coronaria ventriculi*) ascends between the two layers of lesser omentum to the cardiac orifice of the stomach, then runs along the lesser curvature to the pylorus, where it inosculates with the pyloric branch of the hepatic.

It is distributed to the lower end of the œsophagus, and the lesser curve of the stomach.

The HEPATIC ARTERY curves forwards and ascends along the right border of the lesser omentum to the liver, where it divides into two branches (right and left) which enter the transverse fissure, and are distributed to the right and left lobes.

The *branches* of the hepatic artery are the
Pyloric.

Gastro-duodenalis { Gastro-epiploica dextra,
Pancreatico-duodenalis.

Cystic.

The *Pyloric branch* is distributed to the pylorus and lesser curve of the stomach, and inosculates with the gastric.

The *Gastro-duodenalis* descends behind the pylorus, and divides into two branches, the *gastro-epiploica dextra* and *pancreatico-duodenalis*. The *gastro-epiploica dextra* runs along the great curve of the stomach, and inosculates at about its middle with the *gastro-epiploica sinistra*, a branch of the splenic artery. It supplies the great curve of the stomach, and the great omentum, hence the derivation of its name. The *pancreatico-duodenalis* curves along the fixed border of the duodenum, and is distributed to it and to the head of the pancreas: it anastomoses with the first jejunal branch of the superior mesenteric artery.

The *Cystic* is a small branch distributed between the coats of the gall bladder.

The SPLENIC ARTERY passes outwards along the upper border of the pancreas to the spleen, where it divides into five or six large branches, which are distributed to that organ, It usually makes several serpentine bends in its course, and sometimes a complete circular curve upon itself. Its *branches* are,—

Pancreaticæ parvæ, Vasa brevia,
Pancreatica magna, Gastro-epiploica sinistra.

The *Pancreaticæ parvæ* are small nutrient branches distributed to the pancreas, as the splenic artery runs along its upper border. One of these, larger than the rest, follows the course of the pancreatic duct, and is called *pancreatica magna*.

The *Vasa brevia* are several small branches distributed to the great end of the stomach.

The *Gastro-epiploica sinistra* runs forwards from left to right along the great curve of the stomach, and inosculates with the *gastro-epiploica dextra*. It is distributed to the greater curve of the stomach and great omentum.

The *Gastric* and *splenic veins* terminate in the portal vein, and the *hepatic veins* in the vena cava.

Each of the arteries is accompanied by a corresponding plexus of nerves derived from the solar plexus; they are the *gastric*, *hepatic*, and *splenic plexuses*.

The relations of the vessels situated in the right border of the lesser omentum should now be examined more particularly.

The hepatic artery will be found to the left, the ductus communis choledochus to the right, and the portal vein behind and between them. The student will also perceive very distinctly how the lower boundary of the foramen of Winslow is formed by the hepatic artery.

The DUCTUS COMMUNIS CHOLEDOCHUS is formed by the junction of the hepatic with the cystic duct. It descends along the right margin of the lesser omentum, and behind the descending duodenum to its inner border. It terminates with the pancreatic duct, near the interior angle of the duodenum, after running for some distance obliquely between the muscular and mucous coats of the intestine. Just before its termination it is considerably constricted. Its entrance upon the inner surface of the intestine is marked by a small elevated papilla.

The *Liver* may now be removed from the abdomen and examined separately. To effect this object it will be necessary to cut through the folds of peritoneum which are connected with its upper surface, and the hepatic artery, ductus communis choledochus, portal vein, and vena cava from below.

The LIVER is situated in the right hypochondriac region, and extends across the epigastrium into the left hypochondrium. It presents a narrow thin border *anteriorly*, which corresponds with the margin of the thorax, and a rounded border *posteriorly*, which rests against the diaphragm. *Superiorly* it is convex, and *inferiorly* concave. It is divided into *five lobes*, two principal, and three minor lobes; they are the

Right lobe,	Lobulus Spigelii,
Left lobe,	Lobulus caudatus.
Lobulus quadratus,	

The lobes are separated from each other by *fissures*, of which there are also *five*, viz., the

Longitudinal fissure,	Fissure for the gall bladder,
Fissure for the ductus venosus,	Fissure for the vena cava.
Transverse fissure,	

The *Right* and *Left lobes* are separated by the longitudinal fissure, and in front by the notch which lodges the round ligament. The right is much larger than the left, and presents the subdivisions which give rise to the minor lobes.

The *Lobulus quadratus* is bounded, *in front* by the free border of the liver, and, *behind*, by the transverse fissure; to the *right* by the gall bladder, and to the *left* by the longitudinal fissure.

The *Lobulus Spigelii** is a small triangular lobe, which is bounded *in front* by the transverse fissure, and *on the sides* by the fissures for the ductus venosus and vena cava.

The *Lobulus caudatus* is a small tail-like appendage to the lobulus Spigelii, from which it runs outwards like a crest into the right lobe. In some livers it is extremely well marked, in others it is small and ill defined.

The *Longitudinal fissure* runs from before backwards, commencing at a deep notch in the anterior border of the liver. At about half way between the anterior and posterior borders, it is joined by the *transverse fissure* which originates in the right lobe. The continuation of the longitudinal fissure backwards, from the extremity of the transverse fissure to the posterior border of the liver, is the *fissure for the ductus venosus*.

The *Fissure for the gall bladder* is simply the depression in which that organ is lodged, and the *fissure for the vena cava* a deep notch, sometimes a short tunnel in the posterior rounded border of the liver through which the vessel passes.

Upon the upper or convex surface of the liver are seen its *ligaments*: these are, the

Two lateral,	Coronary,
Longitudinal,	Round.

The two *Lateral ligaments* are formed by the two layers of peritoneum, which pass from the under surface of the diaphragm

* Adrian Spigel, a Belgian physician, professor at Padua after Casserius in 1616. He assigned considerable importance to this little lobe, but it was described by Sylvius full sixty years before him.

to the liver. They correspond with the two lobes; one being the *right*, the other the *left* lateral ligament.

The *Longitudinal ligament* (broad, ligamentum suspensorium hepatis) is an antero-posterior fold of peritoneum, extending from the notch on the anterior border of the liver to the junction of the lateral ligaments.

At the union of the longitudinal ligament with the two lateral, a triangular space is left which is uncovered by peritoneum, and where the diaphragm is in contact with the substance of the liver. The peritoneum around this space forms a kind of corona, hence it is called *coronary ligament*.

The *Round ligament* is a fibrous cord, situated between the two layers of peritoneum in the anterior border of the broad ligament. It may be traced from the umbilicus to the notch in the anterior border of the liver, and through the longitudinal fissure to the vena cava. It is the remains of the umbilical vein of the foetus.

The vessels entering into the structure of the liver are also *five* in number: they are the

Hepatic artery,	Hepatic ducts,
Portal vein,	Lymphatics.
Hepatic veins,	

The *Hepatic artery* and *Portal vein* enter the liver at the transverse fissure; from which point the branches of the portal vein spread out to every part of the liver, so that their direction is from below upwards.

The *Hepatic veins* commence at the circumference of the liver, and proceed from before backwards, to open into the vena cava upon its posterior border. Hence the branches of the two veins cross each other in their course.

The portal vein is accompanied to its ultimate divisions by a loose cellular tissue, the *capsule of Glisson*, which surrounds it in the right border of the lesser omentum. This capsule, by establishing only a loose connexion between the vessels and the substance of the liver, permits the veins to contract upon themselves, when emptied of their blood. The branches of the hepatic veins, on the contrary, are closely united by the circumference of their cylinders to the substance of the liver, hence they are unable to contract. The student will, therefore, easily distinguish between the openings of the two veins in a section of the organ: the branches of the *portal vein* will be found *collapsed*, and those of the *hepatic veins* widely *open*.

Again, in company with the portal vein, he will observe the hepatic artery and ducts, while the hepatic veins are solitary.

VESSELS AND NERVES.—The liver is supplied with the *hepatic artery* for nutrition; the *portal vein* for secretion; and the *hepatic veins* to convey to the inferior cava the residual blood. The smaller *hepatic ducts* unite to form a single duct for each of the two principal lobes, and these again form, by their union, the common hepatic duct.

The *Lymphatics* are variously distributed: those of the convex surface proceed upwards through the anterior mediastinum to the glands about the heart, and those from the concave surface pass backwards to the receptaculum chyli.

The *Nerves* of the liver are the filaments of the hepatic plexus, derived from the solar plexus.

The **GALL-BLADDER** is of a pyriform shape, and is lodged in a fissure on the under surface of the right lobe. The apex is directed upwards, and the fundus projects slightly beyond the narrow free border of the liver.

It has three coats, an internal *mucous*, middle *fibrous*, and external, a partial investment of *peritoneum*.

The *Internal*, or *mucous coat*, presents a beautifully reticulated structure in the interior of the bladder, and at its neck forms a spiral valve. It is continuous through the hepatic duct with the mucous membrane lining all the ducts of the liver, and through the ductus communis choledochus, with the mucous membrane of the alimentary canal.

The *Fibrous membrane* is a thin, but strong layer, formed by an interlacement of tendinous fibres. It is connected on the one side with the liver, and on the other with the peritoneum.

The *Peritoneal coat* is a partial covering, investing only that side of the bladder which is unattached. It serves to bind down the gall-bladder, and keep it in its place.

The excretory duct of the gall-bladder is the *cystic*, which unites with the hepatic to form the *ductus communis choledochus*. It is by the latter that the bile is conveyed into the duodenum.

Structure and Minute Anatomy of the Liver, according to Mr. Kiernan.

The *Liver* is composed of *lobules*, of a connecting medium called *Glisson's capsule*, of the ramifications of the *portal vein*, *hepatic ducts*, *hepatic artery*, *hepatic veins*, *lymphatics*, and *nerves*, and is enclosed and retained in its proper situation by the peritoneum. We shall describe each of these structures singly, following rigidly the discoveries of Mr. Kiernan.

1st. The **LOBULES** are small granular bodies of an irregular form, and presenting a number of rounded projecting processes upon their surface. When divided longitudinally (*fig. 19. 2.*) they have a foliated appearance, and transversely, (*fig. 18. 1.*) a polygonal outline with sharp or rounded angles, according to the smaller or greater quantity of Glisson's capsule contained in the liver. The *base*, (*fig. 19. 4.*) of each lobule is flattened and rests upon an hepatic vein, which is thence named sub-lobular. The rest of the surface of the lobule is called *capsular*, and is enclosed in a cellular sheath derived from Glisson's capsule. This cellular sheath separates each lobule from those surrounding it, and the interval in which it is contained is called the *interlobular fissure*, (*fig. 19. 6. fig. 18. 3.*) At the angle formed by the apposition of several lobules, the interlobular fissure dilates into a small space of a triangular or quadrangular form: this is the *interlobular space*, (*fig. 18. 13.*) In the centre of each lobule is situated a small vein, (*fig. 18. 19. fig. 1. 3.*) the intra-lobular, which runs in the longitudinal direction of the lobule, and passes through the centre of its base to terminate in the sub-lobular vein, and thus forms a principal bond of connexion between the lobule and the vein. The intra-lobular vein invariably corresponds with the form of the lobule: it is composed of a central vessel, and of from four to six or eight smaller vessels, which terminate in the central vessel. The central vessel represents the centre of the lobule, and the smaller vessels the number of processes which are developed upon its surface.

There is a slight variety of *form* between the lobules of the centre and those of the surface; the former are more angular, from being compressed by the surrounding substance; the latter have the outline more rounded, and appear larger from being placed obliquely on the hepatic veins which pass nearly parallel with the upper and lower surfaces of the liver to terminate at its posterior border. "The form of the lobules bears no relation to the arrangement of the ducts, the form of each lobule being always correspondent to the branches of the intra-lobular hepatic vein occupying the centre of the lobule."

"Each lobule is *composed* of a plexus of biliary ducts, of a venous plexus formed by branches of the portal vein, of a branch of an hepatic vein, and of minute arteries; nerves and absorbents, it is to be presumed, also enter into their formation, but cannot be traced into them."
"Examined with the microscope, a lobule is apparently composed of

numerous minute bodies of a yellowish colour, and of various forms, connected with each other by vessels. These minute bodies are the *acini* of Malpighi." "If an uninjected lobule be examined and contrasted with an injected lobule, it will be found that the acini of Malpighi in the former are identical with the injected lobular biliary plexus in the latter, and the blood-vessels in both will be easily distinguished from the ducts."

GLISSON'S CAPSULE is the cellular tissue which envelopes the hepatic vessels in the right border of the lesser omentum, and accompanies them through the transverse fissure to their ultimate ramifications. It forms a distinct capsule for each of the lobules, and is continuous with the fibrous layer which invests the entire liver, its *proper capsule*. But "Glisson's capsule," observes Mr. Kiernan, "is not mere cellular tissue; it is to the liver what the pia mater is to the brain; it is a cellulovascular membrane in which the vessels divide and subdivide to an extreme degree of minuteness; which lines the portal canals, forming sheaths for the larger vessels contained in them, and a web in which the smaller vessels ramify; which enters the interlobular fissures, and with the vessels forms the capsules of the lobules, and which finally enters the lobules, and with the blood-vessels expands itself over the secreting biliary ducts. Hence arises a natural division of the capsule into three portions, a *vaginal*, an *interlobular*, and a *lobular portion*."

The *Vaginal portion* encloses the portal vein, hepatic duct, and artery in the canals through which they ramify. In the larger canals it surrounds the vessels completely, but in the smaller it is situated only to that side on which the ducts and artery are placed; the opposite side of the portal vein being in close contact with the capsular surface of the lobules.

The *Interlobular portion* forming the sheath of each of the lobules, and occupying the interlobular fissures, gives support to the ramifications of the portal vein, hepatic ducts, and artery, previously to their entrance into the lobules.

The *Lobular portion* accompanies the vessels into the substance of the lobule.

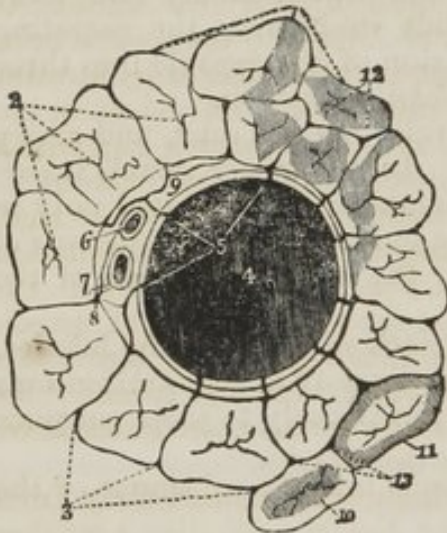
The PORTAL VEIN ramifies through the liver in canals which commence at the transverse fissure, and spread from below upwards throughout the entire organ. These portal canals are formed by the capsular surfaces of the lobules, and contain, besides the vein, a duct and an artery. The branches of the vein, according to the arrangement established by Mr. Kiernan, are divisible into those which are given off in the canals, *vaginal*; those which ramify into the interlobular fissures, *interlobular*; and the terminal branches which are distributed within the lobules, *lobular*.

The trunks of the portal vein, hepatic duct, and artery, are completely surrounded by Glisson's capsule in the larger canals; but in the smaller ones (*fig. 18.*) the capsule (9.) is situated only at that side on which the duct and artery are placed, the vein on the opposite side of its cylinder being in contact with capsular surfaces of the lobules. The portal vein being thus separated from the lobules, all around in the larger canals, and for one-third of its cylinder in the smaller, forms a plexus which ramifies in the capsule of Glisson, and has the effect of bringing the vein in relation with all the lobules forming the canal. The branches

of the vein forming this plexus which extends throughout the whole course of the canals, are the *vaginal*, and from the plexus are given off the interlobular veins opposite each interlobular space. From the side of the vein which is in contact with the lobules in the smaller canals, the interlobular veins are given off directly to the interlobular spaces, no vaginal branches or plexus being necessary. If the smaller portal veins be laid open, the outline of the lobules bounded by the interlobular fissures will be seen through their coats, and the opening of a venous branch will be observed to correspond with each *interlobular space*.

"The *Interlobular branches* (fig. 18. 5. 5.) of the portal vein cover, with their ramifications, the whole external surface of the lobules, with the exception of their bases, and of those extremities of the superficial lobules which appear on the surfaces of the liver. The freest commu-

Fig. 18. Transverse section of a small portal canal and its vessels from Mr. Kiernan's paper in the Philosophical Transactions for 1833.



1. Transverse sections of the lobules of the liver. 2. Intra-lobular hepatic veins in the centres of the lobules. 3. Interlobular fissures, in which ramify branches of the portal vein, hepatic artery, and hepatic ducts. 4. The portal vein, from which pass off on all sides interlobular veins (5. 5.) which ramify in the interlobular fissures. 6. The hepatic artery. 7. The hepatic duct. 8. A branch from each of the three vessels seen entering one of the interlobular fissures. 9. The cellular tissue, Glisson's capsule, by which they are all surrounded. It will be observed that the boundaries of the canal in which the portal vein is lodged, are formed by the sides of the lobules and interlobular fissures, and not by the bases of the lobules, as are those of the sub-lobular veins. 10. A lobule in the state of "passive congestion," or "hepatic venous congestion." 11. A lobule in the state of portal venous congestion. 12. The patches indicating the existence of "active congestion."

anastomoses exist between all the branches of the portal vein, and that the interlobular branches form the medium of communication.

"When the portal vein is imperfectly injected, and the venous circles,

nications take place between these vessels; when successfully injected, which can be done with size only, the interlobular fissures in which they are contained, whether examined on the surfaces of the liver or on the surface of a section, are coloured with the injection. Mercury thrown into a large branch of the portal vein returns by other large branches. This communication takes place through the medium of the interlobular branches; for though the vaginal branches in the same canal anastomose freely with each other, yet those of one canal communicate with those of another through the medium of the intervening interlobular branches alone. The interlobular veins also form communications between the lobular veins of a lobule and those of contiguous lobules. Hence it appears that the freest

formed by its interlobular branches around the lobules, are not brought into view, these branches are seen in the *spaces*, and three or four smaller branches are seen shooting into the fissures communicating with the spaces. These are the *stellated vessels* of anatomists. When the vessels are well injected, the stellæ are all continuous with each other, and the venous circles are formed; the stellated appearance, therefore, arises from the incomplete injection of the vessels."

The *Lobular veins* form a plexus within each lobule, and converge from the circumference to the centre to terminate in the hepatic vein. "This plexus interposed between the interlobular portal veins and the intra-lobular hepatic vein, constitutes the venous part of the lobule, and may be called the *lobular venous plexus*. The circular, ovoid, and oblong portions of the biliary plexus, seen," by means of a microscope of moderate power, "between the branches of the venous plexus, are the acini of Malpighi. The venous branches returning the blood from the coats of the ducts, and from the *vasa vasorum* of all the vessels in the liver, terminate in the portal vein."

The HEPATIC DUCT (*fig. 18. 7.*) enters the liver by the transverse fissure, and accompanies the portal vein and hepatic artery throughout all the ramifications of the portal canals, and through the interlobular fissures, to the substance of the lobules, wherein it terminates by forming the *lobular biliary plexus*. Hence the division which Mr. Kiernan has established for the portal vein, hepatic artery, and Glisson's capsule, is equally applicable to the duct, *viz. vaginal, interlobular, and lobular*.

The *Vaginal branches* arise from the principal ducts, nearly at right angles, and passing transversely across the capsule, divides into numerous branches, which form the *vaginal plexus*. The branches of the plexus run in the direction of the fissures, so as to form a net-work of vessels corresponding in form to the fissures upon which they lie. From this net-work of ducts both lobular and inter-lobular branches arise; "the former enter the lobules on the parietes of the canals; the latter leave the canals at the spaces, to ramify between the lobules."

"The transverse branches, and those which arise immediately from them, do not anastomose with each other, but the smaller branches sometimes appear to do so; I cannot, however, from dissection, affirm that they do, for those which appear to anastomose are exceedingly small vessels, and meet each other at the spaces, hence it is difficult to ascertain whether they really anastomose, or enter the spaces together without anastomosing."

The *Interlobular ducts* ramify with branches of the portal vein and hepatic artery, upon the capsules of the lobules in the inter-lobular fissures. They communicate very freely with each other, so that injection thrown into the hepatic duct of the left side will return by that of the right.

The *Lobular ducts* enter the substance of the lobules, and form a plexus, the *lobular biliary*, of which the lobule is principally composed. They terminate in caecal extremities, as do other glands, and form the true glandular portion of the globule.

"The coats of the ducts are highly vascular; the rugæ on their internal surface, and those on the internal surface of the gall-bladder are formed by the ramifications of the larger blood vessels, arteries as well

as veins, covered by the mucous membrane. This membrane is studded with vascular papillæ: and to the rupture of the delicate vessels forming these papillæ is to be attributed the facility with which Sœmmering and other anatomists injected the ducts from the arteries and veins, and not to any direct communication between the vessels and the ducts." The venous blood is returned from the ducts into the portal vein.

"From their extreme vascularity alone we might infer, that the ducts serve another purpose besides that of the conveyance of bile; and all anatomists are acquainted with the muciparous follicles of the lining membrane of their larger branches; in the smaller branches the existence of the follicles has been denied. In the former they are irregularly distributed over the surface; in the latter they are closely arranged in two longitudinal lines, occupying opposite sides of the ducts; and arranged in this manner they will be found in the smallest duct that can be examined."

The HEPATIC ARTERY enters the liver with the portal vein and hepatic duct, at the transverse fissure, and accompanies their ramifications to their ultimate terminations. Its branches, therefore, admit of the same division, with those of the portal vein and hepatic duct, into the *vaginal*, *interlobular*, and *lobular*.

In the portal canals, "the hepatic artery (*fig.* 18. 6.) and duct, (7.,) running together on one side of the canal, or winding spirally within it, are in opposition with but a very limited number of spaces; the two vessels are, however, brought into opposition with all the spaces by means of plexuses, from which the interlobular branches arise." "The branches forming these plexuses are the first which arise from the artery, duct, and vein; they form a vascular sheath around these vessels, and may be called *vaginal branches*."

The *Vaginal branches* anastomose very freely with each other, so much so, that "if the left artery be injected in the transverse fissure, the injection will return by the right artery; this communication takes place by means of vaginal branches, which the left artery gives off in the fissure, and which anastomose with similar branches of the right artery."

The *Interlobular arteries* are given off from the vaginal plexus, and enter the interlobular spaces and fissures, and are distributed upon the capsular surface of the lobules, but more particularly within the coats of the interlobular ducts, around which they form a very vascular network. "No anastomoses can be shown to exist between the interlobular arteries;"—"but, as the vaginal arteries communicate freely with each other, and as the interlobular ducts also communicate with each other, and as the arteries ramify in the coats of the ducts, we may conclude that the interlobular arteries anastomose."

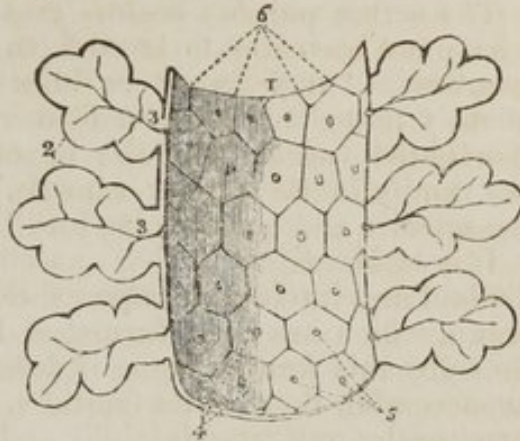
"From the superficial interlobular fissures, small arteries emerge and ramify in the *proper capsule*, on the convex and concave surface of the liver, and in the ligaments. These are the *capsular arteries*." Where the capsule is well developed, "these vessels cover the surfaces of the liver with a beautiful plexus," and "anastomose with branches of the phrenic, internal mammary, and supra-renal arteries," and with the epigastric.

"The *Lobular arteries* are exceedingly minute and few in number:

they are the nutrient vessels of the lobules, and, probably, terminate in the plexuses formed by the portal vein."

"The HEPATIC VEINS are contained in canals, which may be called the *hepatic venous canals*;" they commence in the interior of each lobule, by the intra-lobular vein. The intra-lobular vein, (*fig. 19. 3.*) pierces the base of each lobule, 5., to enter the sub-lobular vein, 1.; and the union of the sub-lobular veins forms the large trunks of the hepatic veins, which terminate in the inferior cava. The intra-lobular veins correspond therefore to the interlobular branches of the portal vein, duct, and artery; but as the former open directly into the sub-lobular veins, it follows that the hepatic veins have nothing analogous to the vaginal branches and plex-

Fig. 19. The distribution of the hepatic veins, according to Mr. Kiernan. From Mr. Kiernan's paper in the Philosophical Transactions for 1833.



1. A section of a sub-lobular vein. 2. Longitudinal sections of the lobules, presenting a foliated appearance. 3. 3. Intra-lobular veins. 4. "The bases of other lobules seen through the coats of the vein, and forming the canal in which the vein is contained." 5. The openings of intra-lobular veins, which issue from the centre of the base of each lobule. 6. The interlobular fissures separating the bases of the lobules.

uses of the vessels contained in the portal canals; "and as Glisson's capsule is composed of the vaginal vessels ramifying in cellular tissue, we consequently find nothing similar to this capsule around the hepatic veins." The hepatic veins are, therefore, closely adherent to the surface of the lobules.

The *Intra-lobular veins* (*fig. 19. 3. 3.*) are formed by the converging branches from the lobular-venous plexus; they occupy the centre of each lobule and pass through its base to terminate in the sub-lobular veins. They have no communication with the branches of the artery, and "their only office is to convey the blood from the lobular venous plexus."

The *Sub-lobular veins* (*fig. 19. 1.*) are the branches which unite to form the trunks of the hepatic veins; they are contained in canals formed solely by the bases of the lobules, 4., hence they are named *sub-lobular*. The bases of all the lobules in the liver are in contact with the cylinder of these veins, and have no intermediate lining of capsular membrane. The coats of the vein are "delicate in texture; they are transparent; the lobules and fissures are seen through them," and "their internal surface is studded with the orifices (5) of the intra-lobular veins," which are seen opening from the centre of the base of each lobule.

"The *trunks*" of the *hepatic veins* "are more dense in structure; their external coat is composed of longitudinal bands; their canals are lined by prolongations of the proper capsule, which render them opaque."

The lobules and fissures cannot be seen through them, and "they receive no intra-lobular branches."

"Dense in structure, they are not adapted to receive these minute and delicate veins; their canals, therefore, unlike those containing the sublobular veins, are, like those containing the portal veins, composed of the capsular surfaces of the lobules, the intra-lobular branches of which terminate in a neighbouring sublobular vein."

The *nerves* and *deep-seated lymphatics*, "ramify in the portal canals; I have not been able to trace them into the interlobular fissures. The *lymphatics* 'may always be injected from the duct, and the bile is frequently propelled into the former vessels by injecting the latter.' No lymphatics 'accompany the hepatic veins.' The '*superficial lymphatics* ramify in the proper capsule.' 'Injection sometimes passes from the arteries and portal veins into the lymphatics.'"

It is to Mr. Kiernan that anatomical science is indebted for the clear, distinct and intelligible idea of the structure of this most complicated organ, which has been furnished by the researches of that anatomist. To value this knowledge as it deserves, we have but to reflect upon the unsuccessful, though not fruitless, labours of those great discoverers in structural anatomy, Malpighi and Ruysch, upon the same subject. It is not, however, in an anatomical or even a physiological point of view merely, that we have to admire these discoveries, for in their practical application to the elucidation of pathological appearances, and the explanation of the phenomena of disease, they are still more interesting.

The liver has been shown to be composed of *lobules*;—the lobules (excepting their bases) are invested and connected together, the vessels supported, and the whole organ enclosed by *Glisson's capsule*:—and they are so arranged that the base of every lobule in the liver is in contact with an hepatic vein.

The *Portal vein* distributes its numberless branches through portal canals which are channelled through every part of the organ; it brings the returning blood from the chylo-poietic viscera; it collects also the venous blood from the ultimate ramifications of the hepatic artery in the liver itself. It gives off branches in the canals which are called *vaginal*, and form a venous *vaginal plexus*; these give off *interlobular branches*, and the latter enter the lobules and form *lobular venous plexuses*, from the blood circulating in which the bile is secreted.

The *Bile* in the lobule is received by a net-work of minute ducts, the *lobular biliary plexus*; it is conveyed from the lobule into the *interlobular ducts*; it is thence poured into the *biliary vaginal plexus* of the portal canals, and by the transverse branches into the excreting ducts, by which it is carried to the duodenum and gall-bladder, after being mingled in its course with the mucous secretion from the numberless muciparous follicles in the walls of the ducts.

The *Hepatic artery* distributes branches through every portal canal; gives off *vaginal branches* which form an arterial vaginal plexus, from which the *interlobular branches* arise, and these latter terminate in the lobular venous plexuses of the portal vein. It ramifies abundantly in the coats of the hepatic ducts, enabling them to provide their mucous secretion; and supplies the vasa vasorum of the portal and hepatic veins, and the nutrient vessels of the entire organ.

The *Hepatic veins* commence in the centre of each lobule by minute

radicles, which collect the impure blood from the lobular venous plexus and convey it into the *intra-lobular veins*; these open into the *sublobular veins*, and the sublobular veins unite to form the large hepatic trunks by which the blood is conveyed into the vena cava.

The physiological deduction arising out of this anatomical arrangement, is, that the *bile is secreted from mixed blood*. For the portal veins bringing the returning blood from the chylo-poietic viscera, receive also the venous blood which has resulted from the circulation of the arterial blood in the hepatic arteries, and the arterial blood itself of the terminations of the arteries in the lobular venous plexus. The bile is, therefore, separated from blood derived from *three* different sources.

The pathological deductions depend upon the following facts:—Each lobule is a perfect gland; of uniform structure; of uniform colour; and possessing the same degree of vascularity throughout. It is the seat of a double venous circulation, the vessels of the one (*hepatic*) being situated in the centre of the lobule, and those of the other (*portal*) in the circumference. Now the colour of the lobule, as of the entire liver, depends chiefly upon the proportion of blood contained within these two sets of vessels; and so long as the circulation is natural, the colour will be uniform. But the instant that any cause is developed which shall interfere with the free circulation of either, there will be an immediate diversity in the colour of the lobule.

Thus, if there be any impediment to the free circulation of the venous blood, through the heart or lungs, the circulation in the hepatic veins will be retarded, and the sublobular and the intra-lobular veins will become congested, giving rise to a more or less extensive redness in the centre of each of the lobules (*fig. 18. 10.*,) while the marginal or non-congested portion presents a distinct border of a yellowish white, yellow, or green colour, according to the quantity and quality of the bile it may contain. “This is ‘*passive congestion*’ of the liver, the usual and natural state of the organ after death;” and, as it commences with the hepatic vein, it may be called the first stage of *hepatic-venous* congestion.

But if the causes which produced this state of congestion continue, or be from the beginning of a more active kind, the congestion will extend through the lobular venous plexuses “into those branches of the portal vein situated in the *interlobular fissures*, but not to those in the *spaces*, which, being larger, and giving origin to those in the fissures, are the last to be congested.” In this second stage the liver has a mottled appearance (*fig. 18. 12.*,) the non-congested substance is arranged in isolated, circular, and ramose patches, in the centres of which the spaces and parts of the fissures are seen. This is an extended degree of *hepatic-venous* congestion; it is “*active congestion*” of the liver, and very commonly attends diseases of the heart, and acute diseases of the lungs and pleuræ.

There is another form of partial venous congestion which commences in the portal vein: this is, therefore, *portal venous* congestion. It is of very rare occurrence, and Mr. Kiernan has observed it in children only. “In this form the congested substance never assumes the deep-red colour which characterizes hepatic venous congestion; the interlobular fissures and spaces, and the marginal portions of the lobules are of a deeper colour than usual: the congested substance is continuous and cortical, the non-congested substance being medullary, and occupying the centres

of the lobules (*fig. 18. 11.*) The second stage of hepatic-venous congestion, in which the congested substance appears, but is not cortical, may be easily confounded with portal venous congestion.

These are instances of *partial congestion*, but there is sometimes *general congestion* of the organ. "In general congestion the whole liver is of a red colour, but the central portion of the lobules are usually of a deeper hue than the marginal portions."

If the stomach be raised and drawn over to the right side, the student will perceive the spleen attached to its greater end.

The spleen is a flattened organ of a dark bluish red colour, convex upon one surface, and concave on the other. Its edges usually present several notches. Its external or convex surface lies in relation with the diaphragm and ribs, the internal or concave, is applied against the great or splenic end of the stomach, and is marked by a fissure (*hilus lienis*,) through which the vessels enter and leave the substance of the organ. It is connected to the stomach by a duplicature of peritoneum, which is therefore called gastro-splenic omentum. It is between the two layers of the gastro-splenic omentum, that the vasa brevia reach the great end of the stomach.

Structure.—In addition to its peritoneal covering, the spleen is enclosed in a capsule of elastic tissue, which sends processes into the interior of the organ, and divides it into a number of cells; the fibrous membrane is also continued inwards, with the vessels forming sheaths for them to their ultimate ramifications.

Some small granular corpuscles are found disseminated through the substance of the spleen in animals, and in a few rare instances they have been observed in man.

The student should now remove the stomach after passing a ligature around the cardiac and pyloric orifices, by dividing the gastro-splenic omentum, and separating its connexions with vessels, and with the œsophagus and duodenum.

Having left the duodenum in its normal position, he should inflate it and observe its relations to surrounding parts, and then proceed to examine the pancreas.

The PANCREAS is a conglomerate gland, lying transversely across the posterior wall of the abdomen. It is divided into a greater and lesser end, the great end or head being situated to the right in contact with the descending portion of the duodenum, is enclosed in the triangular space formed by the curved course of that intestine. From the greater end it

tapers gradually to the lesser, and terminates in a point near to the concave surface of the spleen. It is covered *in front* by the ascending posterior layer of peritoneum and by the stomach. *Behind*, it rests upon the commencement of the vena portæ, the vena cava and the origin of the superior mesenteric artery from the aorta, opposite to the second lumbar vertebra. The transverse duodenum occupies its *lower* border, the superior mesenteric artery and vein being interposed, and the splenic artery and vein are situated along its *upper* margin.

In structure it resembles a salivary gland, consisting of lobules, from which small excretory ducts converge at right angles, to form a single *pancreatic duct*. Near the duodenum this duct is joined by a smaller one (*ductus pancreaticus minor*), which collects the secretion from the great end of the pancreas. The pancreatic duct terminates near to the inferior angle of the duodenum in a papilla upon the mucous membrane, which is common to it and the ductus communis choledochus. Sometimes the two ducts open separately; at other times they unite previously to piercing the coats of the intestine. Their course between the coats of the duodenum is always very oblique.

The pancreas and duodenum may now be removed, and the nerves and vessels dissected which lie on the lumbar vertebræ.

Near to the cœliac axis on either side, and piercing the crust of the diaphragm, is a large nerve, the *greater splanchnic* which enters an irregular ganglion of a semilunar form, situated by the side of the cœliac axis.

The SEMILUNAR GANGLIA send numerous branches of communication from one to the other, so as to form an intricate plexus around the cœliac axis, which is called the *solar plexus*. From the *solar plexus*, as from a centre, smaller plexuses are given off, which accompany all the branches of the abdominal aorta, and the aorta itself; hence we have the *gastric plexus*, *hepatic plexus*, *splenic plexus*, *superior mesenteric plexus*, *spermatic plexus*, *inferior mesenteric plexus*, *renal plexus*, *aortic plexus*, &c.

A little external to the greater splanchnic nerve, is the *lesser splanchnic*, which usually pierces the diaphragm over the ligamentum arcuatum internum, and joins the renal plexus.

The SYMPATHETIC nerve, within the abdomen, descends in front of the lumbar vertebræ at each side of the great vessels.

It presents four ganglia of a fusiform shape, from which branches are given off to communicate with the spinal nerves and other branches of large size, which pass inwards in front of the great vessels, and unite over the bifurcation of the aorta to form the *hypogastric plexus*. The branches of the hypogastric plexus are distributed to the viscera in the pelvis, and communicate very freely with those of the sacral plexus.

The *Abdominal aorta* enters the abdomen through the aortic opening of the diaphragm, and descends, lying rather to the left side of the vertebral column, to the fourth lumbar vertebra, where it divides into the two common iliac arteries.

Relations.—It is crossed, *in front*, by the left renal vein, pancreas, transverse duodenum, and mesentery; and, *behind*, is in relation with the thoracic duct and receptaculum chyli. On its *left side* is the left semilunar ganglion and sympathetic nerve; and, on the *right*, the vena cava, right semilunar ganglion, and commencement of the vena azygos.

Branches.—The *branches* of the abdominal aorta, in their order of origin, are the

Phrenic,	
Coeliac axis	{
	Gastric,
	Hepatic,
	Splenic.
Superior mesenteric,	Spermatic,
Supra-renal,	Inferior mesenteric,
Renal,	Lumbar,
	Sacra-media.

The *Phrenic* are two small arteries which are distributed upon the under surface of the diaphragm.

The *Coeliac axis* is destined to the supply of the stomach and duodenum, liver, spleen, pancreas, and omentum.

The *Superior mesenteric artery* is distributed to the jejunum, ileum, cœcum, ascending and transverse colon.

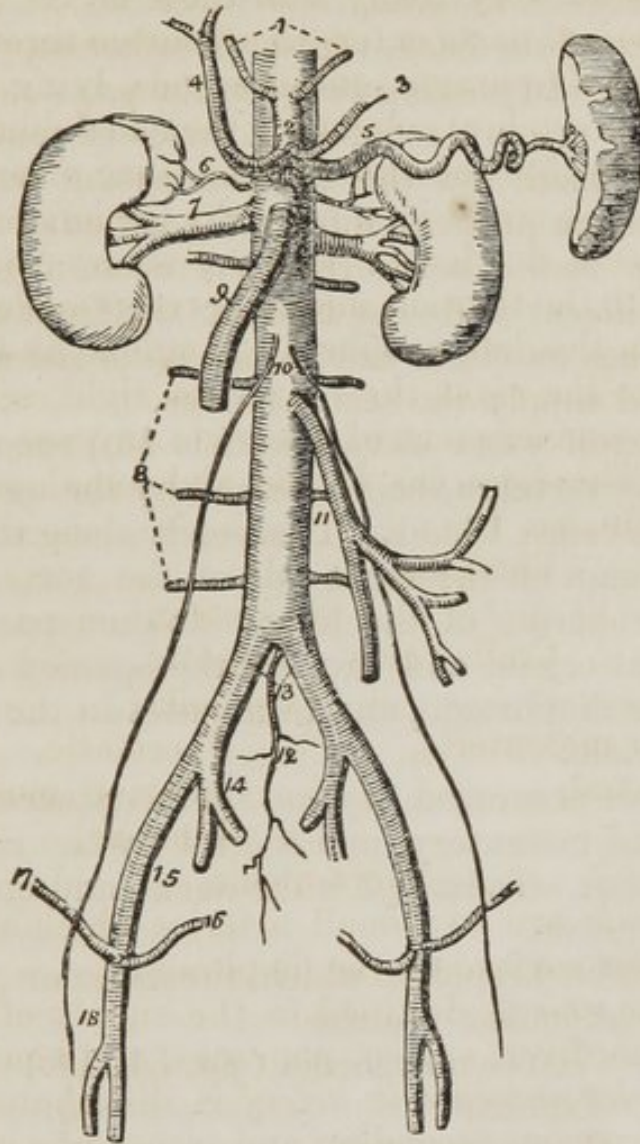
The *Supra-renal* are two small vessels, sometimes branches, of the phrenic or renal arteries, distributed to the renal capsules.

The *Renal arteries* are two large trunks given off on each side of the aorta to the kidneys; the *right* is *longer* than the left, from the position of the aorta, and crosses behind the vena cava to reach the kidney.

The *Spermatic arteries* are two small vessels given off from the front of the aorta; they pass outwards to the ureters, which they accompany for a short distance, then leave them,

and cross the iliacus muscle on each side to the internal abdominal ring, through which they descend along the spermatic canal to the testicle. They are each accompanied by two spermatic veins.

Fig. 20. The abdominal aorta with its branches.



1. The phrenic arteries. 2. The cœliac axis. 3. The gastric artery. 4. The hepatic artery, dividing into the right and left hepatic branches. 5. The splenic artery, passing outwards to the spleen. 6. The supra-renal artery of the right side. 7. The right renal artery, which is longer than the left, passing outwards to the right kidney. 8. The lumbar arteries. 9. The superior mesenteric artery. 10. The two spermatic arteries. 11. The inferior mesenteric artery. 12. The sacra media. 13. The common iliacs. 14. The internal iliac of the right side. 15. The external iliac artery. 16. The epigastric artery. 17. The circumflexa ilii artery. 18. The femoral artery.

These arteries, in the female, are distributed to the ovaries.

The *Inferior mesenteric artery* supplies the descending colon, sigmoid flexure, and upper part of the rectum.

The *Lumbar arteries* correspond with the intercostals in the chest; they are five in number on each side, and curve around the bodies of the lumbar vertebræ, beneath the psoas muscles, and divide into two branches; one of which passes backwards between the transverse processes, and is distributed to the muscles of the back, whilst the other supplies the abdominal muscles. In passing between the psoas muscles and the vertebræ, they are protected by a series of tendinous arches, which defend them and the communicating branches of the sympathetic from pressure during the action of the muscle.

The *Sacra media* arises from the aorta at its bifurcation into the two iliacs; it descends along the front of the sacrum, giving branches on either side, which enter the anterior sacral foramina, and supply the sacral nerves.

The INFERIOR VENA CAVA (*fig. 81. 10.*) commences at the fourth lumbar vertebra, being formed by the union of the two common iliac veins, 18. 11. It ascends along the front of the vertebral column on the right side of the aorta, and reaches the posterior border of the liver. It then passes through a groove in that organ, and through the opening in the central tendon of the diaphragm, and terminates in the under part of the right auricle.

Relations.—It is crossed *in front* by the pancreas, transverse duodenum and mesentery, and *behind* by the right renal and lumbar arteries. To its *left* is the aorta, and on the *right* the sympathetic nerve.

Branches.—The branches which the inferior vena cava receives in the abdomen, are the

Vena-sacra media	(<i>fig. 81. 14.</i>)
Lumbar	- - 15.
Right spermatic	- 16.
Renal	- - 17. 18.
Hepatic.	- - 19.

The *Vena sacra media* (*fig. 81. 14.*) terminates at the junction of the two common iliac veins.

The *Lumbar veins*, 22. 15., return the venous blood from the muscles of the posterior part of the abdomen, and from the spinal veins. The upper lumbar branches communicate with the azygos veins.

The *Right spermatic vein* (*fig. 81. 16.*) is formed by the

union of the veins of the right spermatic cord. It follows the course of the right spermatic artery, and terminates in the inferior cava.

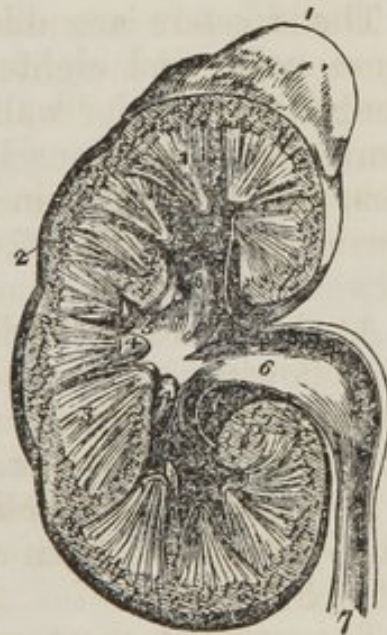The *Renal veins* (*fig.* 81. 17. 18.) return the venous blood from the kidneys; the left is longer than the right, on account of the position of the vena cava on the right side, and crosses the aorta to open into it. The spermatic vein of the left side terminates, at right angles, in the left renal vein: hence arises an impediment to the return of the blood, both on account of the greater length of the left than the right spermatic vein, and the direction of its entrance into the renal vein. As a consequence of this obstacle, *varicocele* occurs most frequently on the left side.

The *Hepatic veins* are of very large size, and open into the cava while that vessel is situated within the liver.

KIDNEYS.

The *Kidneys* are situated in the lumbar regions, on each side of the vertebral column, and behind the peritoneum. They are usually enclosed in a quantity of fat, and rest upon the anterior lamella of the aponeurosis of the transversalis muscle, which separates them from the quadratus lumborum, upon the lower border of the diaphragm. They are surmounted by the *renal capsules*, two yellowish triangular and flattened bodies, which project inwards towards the vertebral column, and are closely connected with the semilunar ganglia, from which they receive a number of filaments. The renal capsules belong to the economy of the fœtus, in which they are as large as the kidneys themselves. In the adult they consist of two lobes, and have an internal cavity, which contains a dark coloured fluid.

Fig. 21. A section of the kidney, surmounted by the supra-renal capsule; the swellings upon the surface mark the original constitution of the organ by distinct lobes.



1. The supra-renal capsule. 2. The vascular portion of the kidney, 3. 3. Its tubular portion, consisting of cones. 4, 4. Two of the papillæ projecting into thin corresponding calices. 5, 5, 5. The three infundibula; the middle 5 is situated in the mouth of a calyx. 6. The pelvis. 7. The ureter.

The right kidney is somewhat lower than the left, being pressed downward by the liver; it is in relation in front with the descending portion of the duodenum.

The concavity of the kidney is directed towards the vertebral column, and receives the vessels; the convexity looks outwards towards the parietes.

STRUCTURE.—Each kidney is invested by its proper *fibrous capsule*. When divided by a perpendicular section, it presents two structures, an external, *vascular* (cortical,) which is of a red colour, and consists chiefly of the ramifications of vessels, and an internal, *tubular* (medullary,) of a light colour and smooth texture, formed by the aggregation of the minute excretory, tubuli. The tubuli are arranged into conical processes, called *Cones*. Each *cone* terminates in a *Papilla*, which is pierced by a number of minute openings, which are the terminations of the tubuli. The points of the papillæ are invested with mucous membrane, which is continuous with the lining of the tubuli, and forms a small cup-like pouch, the *Calyx*, around the extremity of each papilla. There are from fifteen to twenty of these *calices*. Their union at each extremity, and in the middle of the kidney, forms three larger cavities, the *Infundibula*, and the union of the three *infundibula* constitutes the *Pelvis*, from which the ureter passes downwards to the urinary bladder.

The *Ureters* are dilatable tubes, of about the size of a goose quill, and eighteen inches in length. They descend along the posterior wall of the abdomen, and cross, in their course, the psoas muscle, common iliac artery, and vas deferens, and terminate in the posterior and lateral part of the base of the bladder, after passing for some distance obliquely between its coats.

At the concave border of the kidney, the vessels observe the following relation to each other from before backwards, the veins are situated most superficially next the branches of the artery, and then the pelvis and ureter.

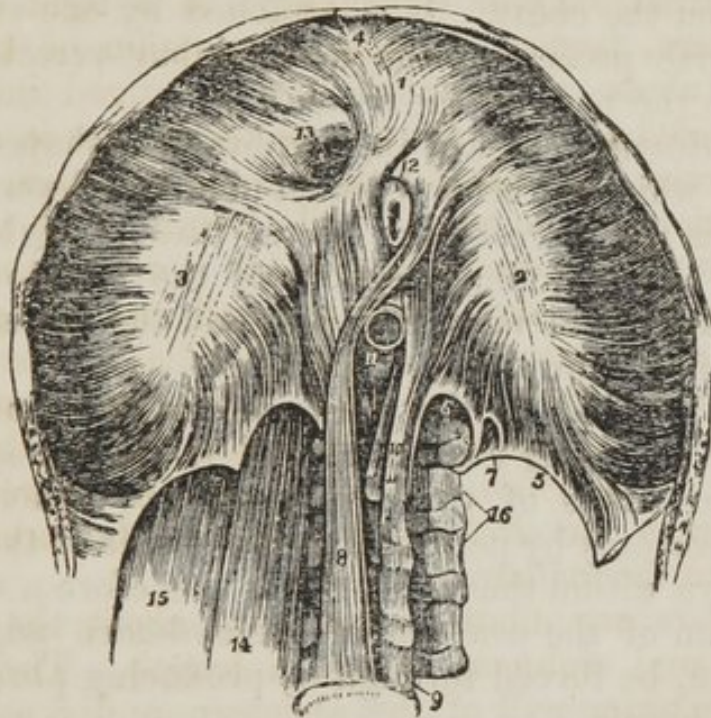
The kidney is supplied with *nerves* by the renal plexus, which is derived from the solar plexus and from the lesser splanchnic nerve.

The student must now examine the *Muscles*, which are situated on the posterior wall of the abdomen. These are the

Diaphragm,	Psoas parvus,
Psoas magnus,	Quadratus lumborum,
Iliacus internus.	

DIAPHRAGM.—To obtain a good view of this important inspiratory muscle, the peritoneum should be dissected from its under surface. It is the muscular septum between the thorax and abdomen, and is composed of two portions, a greater and a lesser muscle. The *greater muscle* arises from the ensiform cartilage, from the inner surfaces of the six inferior ribs, indigitating with the transversalis, and from the ligamentum arcuatum externum, and internum. From these

Fig. 22. The under or abdominal side of the diaphragm.



1, 2, 3. The greater muscle; the figure 1 rests upon the central leaflet of the tendinous centre; the number 2 on the left or smallest leaflet; and number 3 on the right leaflet, 4. The thin fasciculus which arises from the ensiform cartilage; a small triangular space is left on either side of this fasciculus, which is closed only by the serous membrane of the abdomen and chest. 5. The ligamentum arcuatum externum of the left side. 6. The ligamentum arcuatum internum. 7. A small arched opening occasionally found, through which the lesser splanchnic nerve passes. 8. The right or larger tendon of the lesser muscle; a muscular fasciculus from this tendon curves to the left side of the greater muscle between the œsophageal and aortic openings. 9. the fourth lumbar vertebra. 10. The left or shorter tendon of the lesser muscle. 11. The aortic opening occupied by the aorta, which is cut short off. 12. A portion of the œsophagus issuing through the œsophageal opening. 13. The opening for the inferior vena cava, in the tendinous centre of the diaphragm. 14. The psoas magnus muscle passing beneath the ligamentum arcuatum internum; it has been removed on the opposite side to show the arch more distinctly. 15. The quadratus lumborum passing beneath the ligamentum arcuatum externum; this muscle has also been removed on the left side.

points which form the internal circumference of the trunk, the fibres converge and are *inserted* into the central tendon.

The *Ligamentum arcuatum externum* is a fibrous band, extending from the last rib to the transverse process of the first lumbar vertebra, it arches across the origin of the quadratus lumborum muscle, and gives attachment to the posterior fibres of the greater muscle of the diaphragm above, and to the anterior lamella of the transversalis below.

The *Ligamentum arcuatum internum*, or proprius, is a tendinous arch thrown across the psoas magnus muscle as it emerges from the chest. It is attached by one extremity to the transverse process of the first lumbar vertebra, and by the other to the body of the second.

The *Tendinous centre* of the diaphragm is shaped like a trefoil leaf; of which the central leaflet points to the ensiform cartilage, and is the largest; the lateral leaflets, right and left, occupy the corresponding portions of the muscle; the right being the larger and more rounded, and the left smaller and lengthened in its form.

Between the sides of the ensiform cartilage and the cartilages of the adjoining ribs, is a small triangular space where the muscular fibres of the diaphragm are deficient. This space is closed only by peritoneum on the side of the abdomen, and by pleura within the chest. It is therefore a weak point, and a portion of the contents of the abdomen might by violent exertion, be forced through it, producing phrenic or diaphragmatic hernia.

The *Lesser muscle* of the diaphragm takes its origin from the bodies of the lumbar vertebræ by two tendons. The *right*, larger and longer than the left, arises from the anterior surface of the bodies of the second, third, and fourth vertebræ; and the *left* from the side of the second and third. The tendons form two large fleshy bellies (*crura*,) which ascend to be inserted into the central tendon. The inner fasciculi of the two crura cross each other in front of the aorta, and again diverge to surround the œsophagus, so as to present a figure-of-eight like appearance. The anterior fasciculus of the decussation is formed by the right crus.

The *Openings in the diaphragm* are three: one, quadrilateral in the tendinous centre, at the union of the right and middle leaflets, for the passage of the *inferior cava*; a muscular opening of an elliptic shape, formed by the two crura

for the transmission of the *æso-phagus* and *pneumo-gastric nerves*; and a third, the *aortic*, which is formed by a tendinous arch thrown from the tendon of one crus to that of the other across the vertebral column, beneath which pass the *aorta*, the *right vena azygos*, and the *thoracic duct*. One of the splanchnic nerves sometimes passes through the aortic opening, but more frequently they both pierce the crura. The lesser splanchnic nerves pass between the muscular fibres, which proceed from the *ligamentum arcuatum internum* at each side.

The *Psoas magnus* muscle lies at each side of the vertebral column in the lumbar region. It *arises* from the intervertebral substance of the last dorsal and four upper lumbar vertebræ, and from a tendinous arch thrown across the constricted portion of the bodies of the same bones. These arches are intended to protect the lumbar arteries, and communicating branches of the sympathetic nerve. It is *inserted* with the *iliacus* muscle by a common tendon into the lesser trochanter of the femur.

The *psoas* muscle is traversed by the branches of the lumbar plexus, and is pierced by the genito-crural nerve, which runs upon its anterior surface.

The *Psoas parvus* *arises* from the tendinous arches and intervertebral substance of the last dorsal and first lumbar vertebræ, and soon terminates in a long slender tendon which is *inserted* into the pectineal line of the pubis.

The *psoas* and *iliacus* muscles are covered in by the *iliac fascia*, which may now be examined. It will be found attached to the inner margin of the crest of the ilium, and to the folded border of *Poupart's* ligament; in both of which situations it is continuous with the *transversalis fascia*. It crosses the *psoas* muscle, and passes beneath the *iliac* vessels to be attached to the brim of the pelvis, where it is continuous with the pelvic fascia. *Below* it forms the posterior wall of the sheath of the femoral vessels: and *above* it is continued upon the *psoas* muscles to be attached to the sides of the lumbar vertebræ and *ligamentum arcuatum internum*.

The *Iliacus internus* muscle occupies the fossa on the inner surface of the ilium, from which it *arises*. It is crossed by the external cutaneous nerve and the crural nerve lies in the groove between it and the *psoas magnus*. It is *inserted* by a

tendon common to it and the psoas magnus, into the trochanter minor.

The psoas magnus should be removed, in order to bring into view the quadratus lumborum muscle.

The *Quadratus lumborum* muscle is concealed from view by the anterior lamella of the aponeurosis of the transversalis muscle, which is inserted into the bases of the transverse processes of the lumbar vertebræ, and ligamentum arcuatum externum. When this lamella is divided the muscle will be seen *arising* from the last rib, and from the transverse processes of the four upper lumbar vertebræ. It is *inserted* into the posterior fourth of the crest of the ilium. If the muscle be cut across or removed, the middle lamella of the transversalis will be seen attached to the apices of the transverse processes; the quadratus being enclosed between the two lamellæ as in a sheath.

ACTIONS.—The diaphragm is an inspiratory muscle, the contraction of its fibres increasing the cavity of the chest. It acts also as a muscle of expulsion, by pressing upon the abdominal viscera, as in the expulsion of the excretions of the foetus, &c. The spasmodic action of the muscle produces hiccup, sobbing, &c.

The psoas and iliacus muscles, flex the trunk upon the lower extremities or the legs upon the pelvis, at the same time everting the foot. The quadratus lumborum is an expiratory muscle, and assists in fixing the chest.

The psoas magnus, if not previously removed, must now be carefully dissected from its origin for the purpose of bringing into view the lumbar plexus of nerves, which is situated behind it.

The **LUMBAR PLEXUS** of nerves is formed by the anterior branches of the last dorsal and four upper lumbar nerves. The posterior branches passing backwards, to be distributed to the muscles and integument of the loins. The anterior branches increase in size from above downwards, and the posterior diminish in like proportion. The plexus is connected by communicating branches passing from one nerve to the other at their exit from the intervertebral foramina, besides which, each trunk receives one or two filaments from the lumbar ganglia of the sympathetic.

The *Branches of the lumbar plexus* are the

Musculo-cutaneous,
External cutaneous,
Genito-crural,

Crural,
Obturator.

The *Musculo-cutaneous nerves* (*fig. 98. 3.*) two in number, proceed from the first lumbar nerve. They cross the quadratus lumborum muscle, and, piercing the transversalis, divide into two branches; a *cutaneous branch*, which pierces the muscle, and is distributed to the integument over the hip and buttock; and a *muscular branch*, which winds along the crest of the ilium, and is distributed to the abdominal muscles, lying first between the transversalis and internal oblique, and then between the internal and the external oblique muscle. The *superior nerve*, after piercing the fibres of the internal oblique muscle, passes through the external ring with the spermatic cord, and is distributed to the scrotum; hence it is often called *ilio-scrotal*. The inferior nerve supplies the abdominal muscles.

The *External cutaneous nerve* (*fig. 98. 4.*) (inguino-cutaneous) proceeds from the second lumbar nerve. It pierces the posterior fibres of the psoas muscle, and crossing the iliacus obliquely to the anterior superior spinous process of the ilium, passes into the thigh beneath Poupart's ligament, and distributes cutaneous branches to the integument of the groin and of the outer side of the thigh.

The *Genito-crural* (*fig. 98. 5.*) proceeds also from the second lumbar nerve. It traverses the psoas magnus from behind forwards, and runs down on its anterior surface to near Poupart's ligament, where it divides into two branches; *genital*, which passes through the internal abdominal ring, and is distributed to the spermatic cord; and *crural*, which supplies the integument on the inner side of the thigh.

The *Crural nerve* (*fig. 98. 6.*) is formed by the union of branches from the second, third, and fourth lumbar nerves. It passes beneath the psoas magnus, and runs along its outer border to the thigh, where it is distributed.

The *Obturator nerve* (*fig. 98. 12.*) is formed by the union of two branches, one from the third and the other from the fourth lumbar nerve. It runs along the inner border of the pelvis, resting upon the pelvic fascia to the obturator foramen, through which it emerges to supply the muscles on the inner side of the thigh.

The last lumbar nerve, the *lumbo-sacral* (*fig. 107. 1.*) de-

scends into the pelvis to join the four upper sacral nerves, and assists in forming the sacral plexus.

CHAPTER III.

HEAD AND NECK.

The *Head* may be considered as an expansion of the superior part of the vertebral column, for the reception of the brain and the principal organs of sense.

The *Neck* is the medium of communication and connexion between the head and the rest of the body;—*communication*, by means of the trachea and œsophagus, with the internal organs: *connexion*, by means of the muscles and vertebral column, with the superficies and osseous fabric of the trunk.

The head may be divided into the *cranium* and *face*, the former being the osseous recipient of the brain, and the latter the apparatus for the development and protection of the principal organs of sense.

The exterior of the *cranium* presents but little for the study of the anatomist; the *face* is more varied, comprehending—1. The orbits for the organs of vision: 2. The nose or external organ of smell; 3. The mouth, containing the organ of taste; 4. The jaws or apparatus of mastication; and, immediately behind the jaws on the sides of the base of the skull, 5. The external organ of hearing.

We shall commence the dissection of the head and neck, by devoting one side to the learning of the muscles, reserving the other for the study of the vessels and nerves.

The *Occipito frontalis* is to be dissected by making a longitudinal incision along the vertex of the head from the tubercle on the occipital bone to the root of the nose, and a second incision along the forehead and around the side of the head to join the two extremities of the preceding. Dissect the integument and superficial fascia carefully outwards, beginning at the anterior angle of the flap, where the muscular fibres are thickest, and remove it altogether. This dissection requires care, for the muscle is very thin, and without atten-

tion would be raised with the integument. There is no deep fascia on the face and head, nor is it required, for here the muscles are closely applied against the bones upon which they depend for support, whilst in the extremities the support is derived from the dense layer of fascia by which they are invested, and which forms for each a distinct sheath.

The attachments of the *Occipito-frontalis* are expressed in its name. It *arises* from the rough surface immediately above the superior curved line of the occipital bone, being separated from its fellow by a considerable interval, and arches over the head to be *inserted* into the orbicularis palpebrarum and the nasal tuberosity of the frontal bone. A narrow slip from each muscle is continued downwards upon the nasal bones to form the pyramidalis nasi muscle.

The muscle is fleshy in front over the frontal bone, and behind over the occipital, the two portions being connected by a broad tendinous aponeurosis. The muscles of opposite sides cover the whole of the vertex of the skull, from the middle line to the temporal ridge.

After examining the occipito-frontalis muscle, the student should remove the brain, as being the portion of the head most susceptible of decomposition.

To examine the encephalon with its membranes, the upper part of the skull must be removed by sawing through the external table, and breaking the internal table with the chisel and hammer. After the calvarium has been loosened all round, it will require a considerable degree of force to tear the bone away from the dura mater. This adhesion is particularly firm at the sutures, where the dura mater is continuous with a membranous layer interposed between the edges of the bones: in other situations, the connexion results from numerous vessels which permeate the inner table of the skull. The adhesion subsisting between the dura mater and bone is greater in the young subject than in the adult.

Upon being torn away, the internal table will present the deeply grooved and ramified channels corresponding with the branches of the arteria meningeae media. Along the middle line will be seen a groove corresponding with the superior longitudinal sinus, and on either side may be frequently observed some depressed fossæ corresponding with the Pacchionian bodies.

The membranes of the encephalon and spinal cord are the *dura mater*, *arachnoid membrane*, and *pia mater*.

The DURA MATER* is the firm, bluish, fibrous membrane which is exposed on the removal of the calvarium. It lines the interior of the skull and spinal column, and sends processes inwards for the support and protection of the different parts of the brain. It also sends processes externally, which form sheaths for the nerves as they quit the skull and spinal column. Its external surface is rough and fibrous, and corresponds with the internal table of the skull. The internal surface is smooth, and lined by the thin varnish-like lamella of the arachnoid membrane. The latter is a serous membrane. Hence the dura mater becomes a *fibro-serous* membrane, being composed of its own proper fibrous structure, and the serous layer derived from the arachnoid. There are two other instances of fibro-serous membrane in the body, formed in the same way — the pericardium and tunica albuginea of the testicle.

On either side of the dura mater, the branches of the middle meningeal artery may be seen ramifying; and in the middle line is a depressed groove, formed by the subsidence of the upper wall of the superior longitudinal sinus. If the sinus be opened along its course, it will be found to be a triangular channel, crossed at its lower angle by numerous white bands, called chordæ Willisii; † granular bodies are also occasionally seen in its interior: these are glandulæ Pacchioni.

The *Glandulæ Pacchioni*‡ are small, round, whitish granulations, disposed in clusters. They are found in three situations: 1. On the dura mater, to either side of the superior longitudinal sinus, where they often produce considerable indentations in the inner wall of the skull; 2. In the superior longitudinal sinus; 3. On the under surface of the dura mater, by the side of the sinus, connecting that membrane to the arachnoid and pia mater.

* So named from a supposition that it was the source of all the fibrous membranes of the body.

† Willis lived in the seventeenth century: he was a great defender of the opinions of Harvey.

‡ These bodies have no analogy whatsoever with glands. Their nature and use are but imperfectly known. They are not found in infancy. They were described as conglobate glands by Pacchioni, in an epistolary dissertation, "De Glandulis Conglobatis Duræ Meningis indeque ortis Lymphaticis ad Piam Matrem productis," published in Rome, in 1705.

If the student cut through one side of the dura mater, and turn it upwards towards the middle line, he will observe the smooth internal surface of the dura mater. He will perceive also the large cerebral veins filled with dark blood, passing from behind forwards to open into the superior longitudinal sinus, and the firm connexions by means of these veins and the Pacchionian bodies between the dura mater and the pia mater. If he separate these with his scalpel, he will see a vertical layer of dura mater descending between the hemispheres, and if he draw one side of the brain a little outwards, he will distinctly perceive its extent: this is the *falx cerebri*.

The processes of dura mater which are sent inwards towards the interior of the skull, are the *falx cerebri*, *tentorium cerebelli*, and *falx cerebelli*.

The *Falx cerebri*, (*falx*, a sickle,) so named from its sickle-like appearance, narrow in front, broad behind, and forming a sharp curved edge below, is attached in front to the crista galli process of the ethmoid bone, and behind to the tentorium cerebelli.

The *Tentorium cerebelli* (*tentorium*, a tent,) is a roof of dura mater, thrown across the cerebellum and attached to the margin of the petrous portion of the temporal bone at each side, to the transverse ridge of the occipital bone, which lodges the lateral sinuses behind, and to the clinoid processes in front. It supports the posterior lobes of the cerebrum, and prevents their pressure* on the cerebellum leaving only a small opening anteriorly, for the transmission of the *crura cerebri*.

The *Falx cerebelli* is a small process attached to the vertical ridge of the occipital bone beneath the lateral sinus, and to the tentorium. It is received into the indentation between the two lobes of the cerebellum.

The student cannot see the two latter processes until the brain is removed; but he should consider the attachments of the tentorium upon the dried skull, for he will have to divide it in the removal of the brain. He should now proceed to that operation, for which purpose the dura mater is to be incised all round, on a level with the section through the skull, and the scissors are to be carried deeply between the hemispheres of the brain in front, to cut through the anterior part

* In leaping animals, as the feline and canine genera, the tentorium forms a bony tent.

of the falx; then draw the dura mater backwards, and leave it hanging by its attachment to the tentorium. Raise the anterior lobes of the brain carefully with the hand, and lift the olfactory bulbs from the cribriform fossæ with the handle of the scalpel. Then cut across the two optic nerves and internal carotid arteries. Next divide the infundibulum and third nerve, and carry the knife along the margin of the petrous bone at each side, so as to divide the tentorium near its attachment. Cut across the fourth, fifth, sixth, seventh, and eighth nerves in succession with a sharp knife, and pass the scalpel as far down as possible into the vertebral canal, to sever the spinal cord, cutting first to one side and then to the other, in order to divide the vertebral arteries and first cervical nerves. Then let him press the cerebellum gently forwards with the fingers of the right hand, the hemispheres being supported with the left, and the brain will roll into his hand.

We shall now complete the description of the dura mater to avoid perplexing the student by recurring to it in another place; but we would counsel him to commence the examination and study of the brain, while it is firm and fresh.

The layers of the dura mater separate in several situations, so as to form irregular channels which receive the venous blood. These are the *sinuses* of the dura mater: they are lined in their interior by a continuation of the lining membrane of the veins.

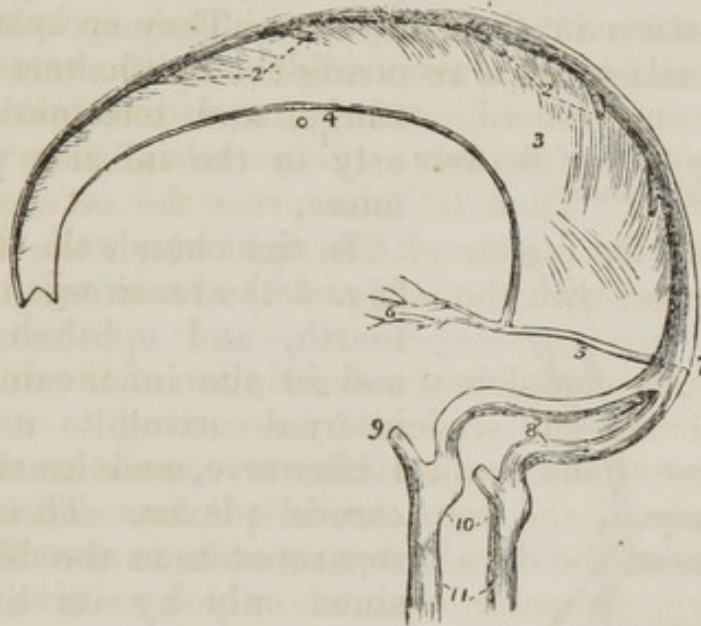
The *Superior longitudinal sinus* is formed by the splitting of the layers of the dura mater along the line of attachment of the falx cerebri. It is triangular in form, is narrow anteriorly, and increases in breadth as it proceeds backwards. It terminates at the middle of the occipital bone, by dividing into the two lateral sinuses. This sinus sometimes communicates in front with the nasal veins through the foramen cœcum. In its interior are found the chordæ Willisii above described, and some Pacchionian bodies. The cerebral veins opening into the superior longitudinal sinus present a very peculiar disposition: they enter from behind forwards directly opposite to the venous current in the sinus, and so obliquely that the inner wall of the vein is enabled to perform the office of a valve, and prevent the reflux of the blood into the veins in an over-distended condition of the sinus.

The *Inferior longitudinal sinus* is much smaller than the

superior. It is circular in its form, and contained within the free margin of the falx cerebri. It terminates posteriorly in the straight sinus at the anterior border of the tentorium.

The *Straight sinus*, (fourth,) is the sinus of the tentorium. It receives the venæ Galeni* from the velum interpositum, and runs backwards along the arch of the tentorium to the termination of the superior longitudinal sinus.

Fig. 23. The sinuses of the upper and back part of the skull.



1. The superior longitudinal sinus 2, 2. The cerebral veins opening into the sinus from behind forwards. 3. The falx cerebri. 4. The inferior longitudinal sinus. 5. The straight or fourth sinus. 6. The venæ Galeni. 7. The torcular Herophili. 8. The two lateral sinuses, with the occipital sinuses between them. 9. The termination of the inferior petrosal sinus of one side. 10. The dilatations corresponding with the jugular fossæ. 11. The internal jugular veins.

The *Occipital sinus* is a small venous channel, which collects its blood from around the foramen magnum, and ascends along the fixed border of the falx cerebelli, to terminate in the torcular Herophili.

The *Lateral sinuses*, starting from the termination of the superior longitudinal, curve around the occipital bone in the fixed border of the tentorium, and descend on each side behind the base of the petrous bone to the foramen lacerum posterius, where they pour their current into the internal jugular vein. These sinuses rest successively on the occipital

* Claudian Galen, chief of the Greek physicians after Hippocrates, was born about the year 130.

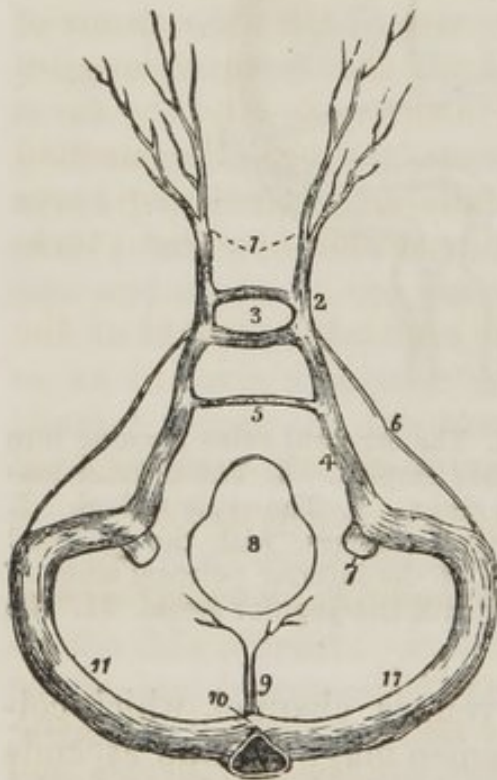
bone, posterior inferior angles of the parietal, temporal, and occipital bones.

The point of termination of the superior longitudinal sinus is therefore the centre of convergence of the straight and occipital sinuses, and the starting point of the lateral sinuses. Hence it is named the conflux of the sinuses or *torcular Herophili*.*

The sinuses of the base of the skull are as follows:—

The *Cavernous sinuses* are so named from presenting a cellular structure in their interior. They are placed on the side of the sella turcica, receiving the ophthalmic veins anteriorly, and terminating posteriorly only in the inferior petrosal sinuses.

Fig. 24. The sinuses of the base of the skull.



1. The ophthalmic veins. 2. The cavernous sinus of one side. 3. The circular sinus; the figure occupies the position of the pituitary gland in the sella turcica. 4. The inferior petrosal sinus. 5. The transverse or anterior occipital sinus. 6. The superior petrosal sinus. 7. The internal jugular vein. 8. The foramen magnum. 9. The occipital sinuses. 10. The torcular Herophili. 11, 11. The lateral sinuses.

* Torcular, (a press,) from a supposition entertained by the older anatomists that the columns of blood, coming in different directions, compressed each other at this point.

Herophilus was a great anatomist, and was well informed on many parts of the human structure; he lived about 500 years before Christ.

In the outer wall of this sinus (*fig. 48.*) are situated the third, fourth, and ophthalmic nerves, and in the inner wall with the internal carotid artery, the sixth nerve, and branches of the carotid plexus. These parts are separated from the blood of the sinus only by its lining membrane.

The *Inferior petrosal sinuses* are the continuations of the cavernous sinuses backwards along the lower border of the petrous bone to the foramen lacerum posterius, where they open with the lateral sinuses into the internal jugular veins.

The remaining sinuses are communicating channels passing between the preceding; thus,

The *Circular sinus* is situated in the sella turcica, surrounding the pituitary gland, and communicates on either side with the cavernous sinus.

The *Superior petrosal sinus* runs along the attached border of the tentorium, on the upper margin of the petrous bone, and establishes a communication between the cavernous and the lateral sinus at each side.

The *Transverse sinus* (basilar, anterior occipital) passes transversely across the basilar process of the occipital bone, forming a communication between the two inferior petrosal sinuses.

The sinuses of the dura mater communicate with the exterior of the skull by several large veins. On the summit of the skull a considerable vein opens into the superior longitudinal sinus, through the parietal foramen. Behind the ear a large vein opens into the lateral sinus, through the mastoid foramen; and at the base of the skull, another communicates with the lateral sinus, through the posterior condyloid foramen.

They communicate also very freely with the sinuses of the diploë.

The *Arteries* of the dura mater are the

Anterior meningeal from the internal carotid.

Middle meningeal }
Meningea parva } from the internal maxillary.

Inferior meningeal from the ascending pharyngeal and occipital arteries.

Posterior meningeal from the vertebral.

The *Nerves* are derived from the nervi molles of the sympathetic, the Casserian ganglion, the ophthalmic nerve, and sometimes from the fourth; they are given off while these nerves are situated by the side of the sella turcica. The branches of the ophthalmic and fourth nerves are recurrent, and are distributed between the layers of the tentorium as far as the lateral sinus.

Arachnoid Membrane.

The *Arachnoid* (*αραχνη*—*ειδος*, like a spider's web,) so named from its extreme tenuity, is the serous membrane of the cerebro-spinal centre, and, like other serous membranes, a shut

sac. It envelopes the brain and spinal cord, and is reflected upon the inner surface of the dura mater, giving to that membrane its serous investment.

The arachnoid is thin and transparent on the upper surface of the brain, and may be demonstrated by inserting a blow-pipe and injecting beneath it a stream of air. In other situations, as at the base of the brain and between the cerebellum and medulla oblongata, it is semitransparent and dense in its structure, and is rendered very evident by passing across from one convexity to another. In inflammation of the meninges, this membrane is often thickened and opaque.

The arachnoid is attached to the surface of the pia mater by a loose cellular tissue; the sub-arachnoidean. This tissue is filamentous at the base of the brain, between the hemispheres, and around the spinal cord, where the arachnoid is disposed very loosely.

The *Sub-arachnoidean cellular tissue* is the seat of an abundant serous secretion, the *sub-arachnoidean fluid*, which fills all the vacuities existing between the arachnoid and pia mater, and distends the arachnoid of the spinal cord so completely, as to enable it to occupy the whole of the space included in the sheath of the dura mater.

The arachnoid also secretes a serous fluid from its inner surface, which is small in quantity compared with the sub-arachnoidean liquid.

It does not enter into the ventricles of the brain, as imagined by Bichât, but is reflected inwards upon the venæ Galeni for a short distance only, and returns upon those vessels to the dura mater of the tentorium. It surrounds the nerves as they originate from the brain, and forms a sheath around them to their point of exit from the skull. It is then reflected back upon the inner surface of the dura mater. The cerebral nerves are retained in connection with the brain principally by this membrane, so that, in separating it from the brain, the nerves are also torn away.

There are no vessels apparent in the arachnoid, and no nerves have been traced into it.

Pia Mater.

The *Pia Mater* is a vascular membrane composed of innumerable vessels held together by a thin cellular layer. It invests the whole surface of the brain, dipping into its convo-

lutions, and forming a fold in its interior called *velum interpositum*. It forms folds (choroid plexuses,) also, in other situations, as in the fourth ventricle, and in the longitudinal grooves of the spinal cord.

This membrane differs very strikingly in its structure in different parts of the cerebro-spinal axis. Thus, on the surface of the cerebrum, in contact with the soft gray matter of the brain, it is excessively vascular, forming remarkable loops of anastomoses between the convolutions, and distributing multitudes of minute straight vessels to the gray substance. In the *substantia perforata*, again, and *locus perforatus*, it gives off tufts of small arteries, which pierce the white matter to reach the gray substance in the interior. But upon the *crura cerebri*, *pons Varolii*, and spinal cord, its vascular character seems almost lost. It has become a *dense fibrous membrane*, difficult to tear off, and forming the proper sheath of the spinal cord.

The *pia mater* is the nutrient membrane of the brain, and derives its blood from the internal carotid and vertebral arteries.

Its *Nerves* are the minute filaments of the sympathetic, which accompany the branches of the arteries.

The *Arteries of the brain* maintain a remarkable communication at its base, which is called the *Circle of Willis*. If the arachnoid membrane be removed, and the connexions of the *pia mater* slightly separated, these vessels may be distinctly seen and examined.

At the fissure of Sylvius the internal carotid artery will be seen to divide into three branches: Anterior cerebral, Middle cerebral, Posterior communicating.

The *Anterior cerebral artery* passes forwards in the great longitudinal fissure between the two hemispheres of the brain; then curves backwards along the *corpus callosum*, and inosculates with the posterior cerebral artery. It gives branches to the inner surface of the hemispheres. The two anterior cerebral arteries are connected soon after their origin by a short anastomosing trunk, the *anterior communicating*.

The *Middle cerebral artery* passes outwards along the fissure of Sylvius, and divides into several large branches, which supply the anterior and middle lobes. Near its origin it gives off the numerous small branches which enter the *substantia perforata*.

The *Posterior communicating artery*, very variable in size, sometimes double, and sometimes altogether absent, passes backwards and inosculates with the posterior cerebral, a branch of the basilar.

Commencing at the posterior extremity of the base of the brain, the two *Vertebral arteries* will be seen converging to the inferior border of the pons Varolii, where they form the *Basilar*. The vertebrals are often unequal in size, one being much larger than the other. Their branches within the skull are, Anterior spinal, Posterior spinal, Posterior meningeal, Inferior cerebellar.

The *Anterior spinal* is a small artery which unites with its fellow of the opposite side, and forming a common trunk, descends on the anterior aspect of the spinal cord to the cauda equina, where it is distributed.

The *Posterior spinal* winds around the medulla oblongata to the posterior aspect of the cord, and descends on either side nearly as far as the cauda equina, communicating very freely with the spinal branches of the intercostal arteries.

The *Posterior meningeal*, often a branch of the inferior cerebellar, is distributed to the dura mater.

The *Inferior cerebellar* arteries wind around the upper part of the medulla oblongata to the under surface of the cerebellum, to which they are distributed. This artery gives off a small branch which accompanies the seventh pair of nerves into the meatus auditorius internus.

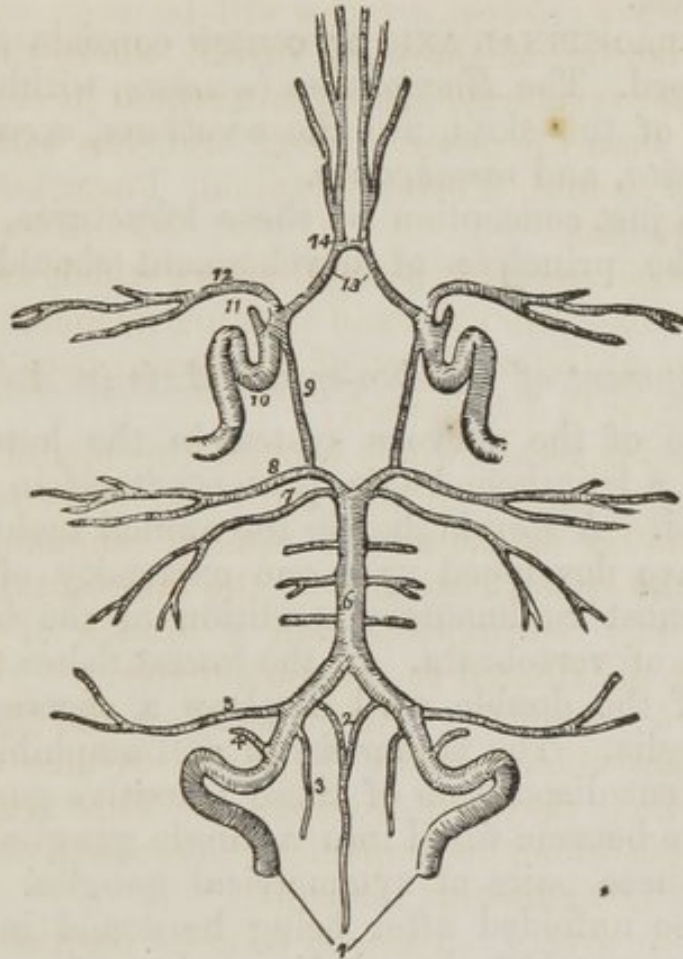
The *Basilar artery*, so named from its position at the base of the skull, runs forwards to the upper border of the pons Varolii, where it divides into four ultimate branches, two to either side. While resting against the pons, it gives off several transverse branches to the crura cerebelli. Its branches are, Transverse, Superior cerebellar, Posterior cerebral.

The *Superior cerebellar* supplies the upper surface of the cerebellum, and inosculates with the inferior cerebellar.

The *Posterior cerebral* passes off on either side to the posterior lobes of the cerebrum, and communicates on the corpus callosum with the anterior cerebral arteries. It is separated from the superior cerebellar artery, by the third nerve, and is in close relation with the fourth, in its course around the crus cerebri. Anteriorly near its origin, it gives off a tuft of small vessels, which enter the locus perforatus, and it re-

ceives the posterior communicating arteries from the internal carotid.

Fig. 25. The circle of Willis. The branches of the arteries have references only on one side, on account of their symmetrical distribution.



1. The vertebral arteries. 2. The two anterior spinal branches uniting to form a single vessel. 3. One of the posterior spinal arteries. 4. The posterior meningeal. 5. The inferior cerebellar. 6. The basilar artery giving off its transverse branches to either side. 7. The superior cerebellar artery. 8. The posterior cerebral. 9. The posterior communicating branch of the internal carotid. 10. The internal carotid artery, showing the curvatures it makes within the skull. 11. The ophthalmic artery divided across. 12. The middle cerebral artery. 13. The anterior cerebral arteries connected by, 14. The anterior communicating artery.

The communications established between the anterior cerebral arteries in front, and the internal carotids and posterior cerebral arteries behind, by the communicating arteries, constitute the Circle of Willis. Were we called upon to answer how this circle was formed, we should say by the anterior communicating, anterior cerebral arteries, and internal caro-

tids; posterior communicating, posterior cerebrals, and basilar artery.

The *Circle of Willis* includes within its area, several parts of the base of the brain, which should also be attended to. They may probably be more advantageously explained by the following plate.

The CEREBRO-SPINAL AXIS or centre consists of the brain and spinal cord. The *Encephalon* (*εν κεφαλή*, within the head,) or contents of the skull, are the *cerebrum*, *cerebellum*, *medulla oblongata*, and *membranes*.

To form a just conception of these structures, it is necessary that the principle of development should be briefly explained.

Development of Cerebro-spinal Axis in Animals.

The centre of the nervous system in the lowest animals possessed of a lengthened axis, presents itself in the form of a double cord. A step higher in the animal scale, and knots or *ganglia* are developed upon one extremity of this cord; such is the most rudimentary condition of the brain in the lowest forms of vertebrata. In the lowest fishes the anterior extremity of the double cord displays a succession of five pairs of ganglia. The higher fishes and amphibia appear to have a different disposition of these primitive ganglia. The first two have become fused into a single ganglion, and then follow only three pairs of symmetrical ganglia. But if the larger pair be unfolded after being hardened in alcohol, it will then be seen that the whole number of ganglia exists, but that four have become concealed by a thin covering that has spread across them. This condition of the brain carries us upwards in the animal scale even to mammalia; *e. g.*, in the dog or cat we find, first a single ganglion, the cerebellum, then three pairs following each other in succession; and if we unfold the middle pair, we shall be at once convinced that it is indeed composed of two pairs of primitive ganglia concealed by an additional development. Again it will be observed, that the primitive ganglia of opposite sides, at first separate and disjointed, become connected by means of transverse fibres of communication (*commissures*, *commissura*, *a joining*). The office of these commissures is the association in function of the two symmetrical portions. Hence we arrive at the general and important conclusion, that the brain among

the lower animals consists of *primitive cords*, *primitive ganglia* upon those cords, and *commissures* which connect the substances of the adjoining ganglia, and associate their actions. Let us now turn to the

Development of the Cerebro-spinal Axis in Man.

The earliest indication of the spinal cord in man exhibits a pair of minute longitudinal filaments placed side by side. Upon these, towards the anterior extremity, five pairs of minute swellings are observed, not disposed in a straight line as in fishes, but curved upon each other so as to correspond with the direction of the future cranium. The posterior pair soon becomes cemented upon the middle line, forming a single ganglion; the second pair also unite with each other; the third and fourth pairs, at first distinct, are speedily veiled by a lateral development, which arches backwards and conceals them; the anterior pairs, at first very small, decrease in size and become almost lost in the increased development of the preceding pairs.

We see here a chain of resemblances corresponding with the progressive development observed in the lower animals; the human brain is passing through the phases of improving development, which distinguishes the lowest from the lower creatures: and we are naturally led to the same conclusions with regard to the architecture of the human brain, that we were led to establish as the principle of development in the inferior creatures—that it is composed of *primitive cords*, *primitive ganglia* upon those cords, *commissures* to connect those ganglia, and *developments* from those ganglia,

In the adult, the *primitive longitudinal cords* have become cemented together, to form the *spinal cord*. But, at the upper extremity, they separate from each other under the name of *crura cerebri*. The *first pair of ganglia* developed from the primitive cords, have grown into the *cerebellum*; the *second pair* (the optic lobes of animals) have become the *corpora quadrigemina* of man. The *third pair*, the *optic thalami*, and the *fourth*, the *corpora striata*, are the *basis of the hemispheres*, which, the merest lamina in the fish, has become the largest portion of the brain in man. And the *fifth pair* (olfactory lobes,) so large in the lowest forms, has dwindled into the *olfactory bulbs* of man.

CEREBRUM.

The *Cerebrum* is divided into two hemispheres by the great longitudinal fissure, which lodges the falx cerebri, and marks the original development of the brain by two symmetrical halves.

Each hemisphere, upon its under surface, admits of a division into three lobes, anterior, middle, and posterior. The *anterior lobe* rests upon the roof of the orbit, and is separated from the middle by the fissure of Sylvius.* The *middle lobe* is received into the middle fossa, in the base of the skull, and is separated from the posterior by a slight impression produced by the ridge of the petrous bone. The *posterior lobe* is supported by the tentorium.

If the upper part of one hemisphere be removed with a scalpel, a centre of white substance will be observed, surrounded by a narrow border of gray, which follows the depressions of the convolutions, and presents a zig-zag outline. This appearance is called *centrum ovale minus*.

The brain is composed of these two substances, the white and gray. The *white*, or *medullary substance*, forms the great bulk of the cerebro-spinal axis. It is distinctly fibrous in structure, and, when hardened in alcohol, may be easily split in the course of its fibres. When cut across in the fresh brain, as in the section showing the centrum ovale minus, it will be found studded with small vascular points (*puncta*), which are the divided cylinders of minute arteries and veins.

The *gray*, or *cortical substance* (cineritious,) forms a thin layer of equal thickness over the whole surface of the cerebrum and of the cerebellum; hence its denomination, cortical (*cortex, bark*). It is softer than the medullary substance, and homogeneous in structure. It is also more vascular, receiving a prodigious number of minute straight arteries from the pia mater. Hence it is denominated the *formative substance* by Gall and Spurzheim, as being the nidus of support to the vessels, which are the source of nutrition to itself as well as to the medullary substance. The gray substance is found also in other situations than the surface, viz. in the interior of

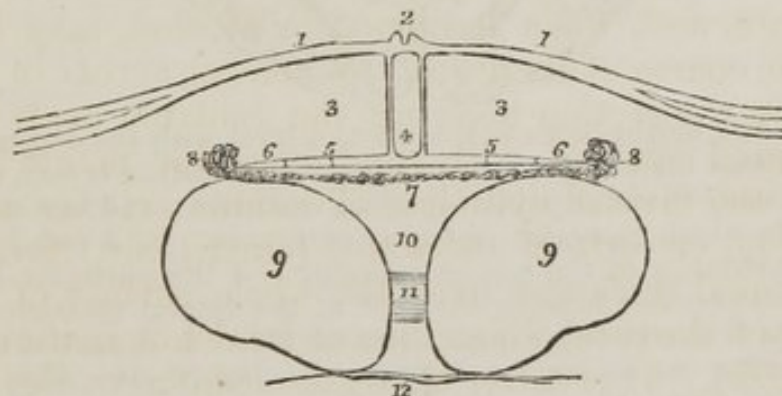
* James Dubois, a celebrated professor of anatomy in Paris, where he succeeded Vidius in 1550, although known much earlier by his works and discoveries, but particularly by his violence in the defence of Galen. His name was Latinized to Sylvius.

primitive ganglia, of the cerebrum, the corpora striata, and thalami optici, in the tuber cinereum at the base of the brain, in the commissura mollis of the third ventricle, in the floor of the fourth ventricle, in the centre of each lobe of the cerebellum, each corpus olivare, &c. It also exists in the interior of the spinal cord and crura cerebri, but of a much darker color than elsewhere. Indeed, the dark appearance in the centre of the section of the crus cerebri, is termed "*locus niger.*"

Now separate carefully the two hemispheres of the cerebrum, and a broad band of white substance will be seen to connect them. Remove the upper part of each hemisphere with a knife to a level with this white layer. The appearance resulting from this section is the centrum ovale majus.

The *Centrum ovale majus* is the large centre of white substance presented to the view on the removal of the upper part of each hemisphere; it is surrounded by the thin stratum of gray substance, which follows in a zig-zag line all the convolutions and the fissures between them. In the middle of the centrum ovale majus is the broad band which connects the two hemispheres to each other, the corpus callosum.

Fig. 26. A diagram, representing a transverse section of the brain.

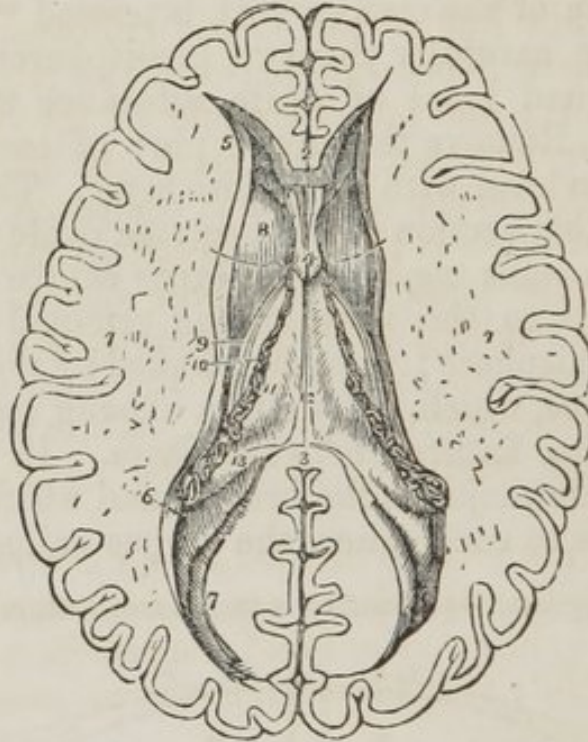


1. 1. The corpus callosum, or great commissure of the hemispheres, extending transversely into each hemisphere. 2. The raphé, a linear depression between two slightly elevated ridges. 3. 3. The lateral ventricles. 4. The space between the two layers of the septum lucidum, called the fifth ventricle. 5. 5. The fornix. 6. 6. The thin edges of the fornix, called corpora fimbriata. 7. The vellum interpositum. 8. 8. The plexiform borders of the velum interpositum, called choroid plexuses. 9. 9. The thalami optici. 10. The space between the two thalami, called third ventricle. 11. The gray commissure of the thalami optici, called middle commissure, or commissura mollis of the third ventricle. 12. The line of the base of the brain.

The *Corpus callosum* (fig. 26. 1. 1. fig. 28. 1.) (*callosus, hard*) is a dense layer of transverse fibres, connecting the

two hemispheres, and approaching nearer to the anterior than to the posterior extremity of the brain. Anteriorly it forms a rounded border (*fig. 28. 2.*) and may be traced downwards to the base of the brain, in front of the commissure of the optic nerves. Posteriorly it forms a thick rounded fold (*fig. 28. 3.*) which is continuous with the fornix.

Fig. 27. The lateral ventricles of the cerebrum.



1. 1. The two hemispheres cut down to a level with the corpus callosum so as to constitute the centrum ovale majus. The surface is seen to be studded with the small vascular points—*puncta vasculosa*; and surrounded by a narrow margin which represents the gray substance. 2. A small portion of the anterior extremity of the corpus callosum. 3. Its posterior boundary; the intermediate portion forming the roof of the lateral ventricles has been removed, so as to completely expose those cavities. 4. A part of the septum lucidum, showing an interspace between its layers—the fifth ventricle. 5. The anterior cornu of one side. 6. The commencement of the middle cornu. 7. The posterior cornu. 8. The corpus striatum of one ventricle. 9. The tertia semicircularis covered by the vena corporis striati and tertia Tarini. 10. A small part of the Thalamus opticus. 11. The dark fringed-like body to the left of the figure is the choroid plexus. This plexus communicates with that of the opposite ventricle through the foramen of Munro; a bristle is passed through this opening, and its extremities are seen resting on the corpus striatum at each side. The figure 11 rests upon the edge of the fornix, upon that part of it which is called the corpus fimbriatum. 12. The fornix. 13. The commencement of the hippocampus major descending into the middle cornu. The rounded oblong body in the posterior cornu of the lateral ventricle, directly behind the figure 13, is the hippocampus minor.

Beneath the posterior rounded border of the corpus callo-

sum, is the *transverse fissure* of the brain, which extends beneath the hemispheres from the fissures of Sylvius on one side, to that on the opposite side of the brain. It is through this fissure that the pia mater communicates with the velum interpositum. (*fig* 28. 8.) And it was here that Bichât conceived that the arachnoid entered into the ventricles; hence it is also named the *fissure* of *Bichat*.

Along the middle line of the corpus callosum, is the *raphé* (*fig*. 26. 2.) a linear depression between two slightly elevated longitudinal bands; and on either side of the *raphé*, may be seen the *lineæ transversæ*, which mark the direction of the fibres of which the corpus callosum is composed.

The corpus callosum is the commissure of the hemispheres.

If an incision be made through the corpus callosum on either side of the *raphé*, two irregular cavities will be opened, which extend from one extremity of the hemispheres to the other; these are the *lateral ventricles*. To expose them completely, the upper boundary should be removed with the scissors.

Each *Lateral ventricle* is divided into a *central cavity*, and three smaller cavities called *cornua*. The *anterior cornu* projects forward into the anterior lobe; the *middle cornu* descends into the middle lobe; and the *posterior cornu* passes backwards into the posterior lobe.

The central cavity (*fig*. 26. 3. 3.) is triangular in its form, being bounded above (*roof*) by the corpus callosum. It is separated from the opposite ventricle by the septum lucidum, and its *floor* is formed by the following parts, taken in their order of position from before backwards:—Corpus striatum, Tenia semicircularis, Thalamus opticus, Choroid plexus, Corpus fimbriatum, Fornix.

The *Corpus striatum* is so named from the striated lines of white and gray matter which are seen upon cutting into its substance. It is gray on the exterior, and of a pyriform shape. The broad end, directed forwards, rests against the corpus striatum of the opposite side; the small end, backwards, is separated from its fellow by the interposition of the thalami optici.

The corpus striatum is the superior ganglion of the cerebrum.

The *Tenia semicircularis* (*tenia*, a *fillet*) is a narrow band of medullary substance, extending along the posterior border

of the corpus striatum, and serving as a bond of connexion between that body and the thalamus opticus.

It is partly concealed by a large vein (*vena corporis striata*), formed by small vessels from the corpus striatum and thalamus opticus. This vein terminates in the venæ Galeni.

The vein is also overlaid by a yellowish band, a thickening of the lining membrane of the ventricle. This was first noticed and described by Tarinus, under the name of the *horny band*. We may, therefore, term it *tenia Tarini*.*

The *Thalamus opticus* (*thalamus, a bed*) is an oblong body, having a thin coating of white substance on its surface; it has received its name from being the origin of the optic nerve. It is the inferior ganglion of the cerebrum. The border only of the thalamus is seen in the floor of the lateral ventricle. We shall, therefore, defer its farther description until we can examine it in its entire extent.

The *Choroid plexus* (*χοριον-ειδος, resembling the chorion*) is a vascular fringe extending obliquely across the floor of the lateral ventricle, and sinking into the middle cornu. Anteriorly it is small and tapering, and communicates with the choroid plexus of the opposite ventricle, through a large oval opening, the *foramen of Munro*.

This foramen (*fig 28. 9.*) may be distinctly seen by pulling slightly on the plexus, and pressing aside the septum lucidum with the handle of the knife. It is situated between the under surface of the fornix, and the anterior extremities of the thalami optici, and forms a transverse communication between the lateral ventricles, and below with the third ventricle.

The choroid plexus is variable in its appearance, and sometimes presents groups and clusters of small serous cysts, which have been mistaken for hydatids.

The *Corpus fimbriatum* (*fig. 26. 6.*) is a narrow white band, which is situated immediately behind the choroid plexus, and extends with it into the descending cornu of the lateral ventricle. It is the lateral thin edge of the fornix.

The *Fornix* is a white layer of medullary substance, of which a portion only is seen in this view of the ventricle.

The *Anterior cornu* is triangular in its form, sweeping out-

* Peter Tarin, a French anatomist: his work, entitled "Adversaria Anatomica," was published in 1750.

wards, and terminating in a point in the anterior lobe of the brain, at a short distance only from its surface.

The *Posterior cornu* or *digital cavity* curves inwards, as it extends into the posterior lobe of the brain, and likewise terminates near to the surface. An elevation corresponding with a deep sulcus between two convolutions projects into the floor of this cornu, and is called *hippocampus minor*.

The *middle* or *descending cornu*, in descending into the middle lobe of the brain, forms a very considerable curve, and alters its direction several times as it proceeds. Hence it is described as passing backwards and outwards and downwards, and then turning forwards and inwards. This complex expression of a very simple curve has given birth to a symbol formed of the primary letters of these various words, and by means of this the student recollects with ease the course of the cornu, BODFI. It is the largest of the three cornua.

The middle cornu should now be laid open by inserting the little finger into its cavity, and making it serve as a director for the scalpel in cutting away the side of the hemisphere, so as to expose it completely.

Its *Superior boundary* is formed by the under surface of the thalamus opticus, upon which are the two projections called corpus geniculatum internum and externum, and the *inferior wall* by the various parts which are often spoken of as the contents of the middle cornu: these are the Hippocampus major, Pes hippocampi, Pes accessorius, Corpus fimbriatum, Choroid plexus, Fascia dentata, Transverse fissure.

The *Hippocampus major* or *cornu Ammonis*, so called from its resemblance to a ram's horn, the famous crest of Jupiter Ammon, is a considerable projection from the inferior wall, and extends the whole length of the middle cornu. Its extremity is likened to the club-foot of some animal, from its presenting a number of knuckle-like elevations upon the surface: hence it is named *pes hippocampi*.

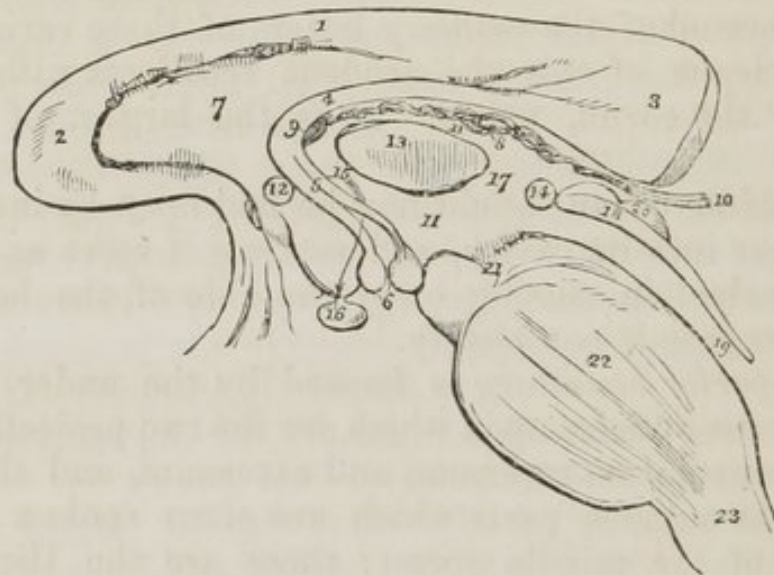
The hippocampus major is the termination of the lateral edge of the hemisphere, which in this situation is very much attenuated and rolled upon itself. If it be cut across, it will be seen to resemble the extremity of a convoluted scroll, consisting of alternate layers of white and gray substance. The hippocampus major is continuous superiorly with the fornix and corpus callosum.

The *Pes accessorius* is a swelling somewhat resembling the hippocampus major, but smaller in size: it is situated on the outer wall of the cornu, and is frequently absent.

The *Corpus fimbriatum* is the narrow white band which is prolonged from the central cavity of the ventricle, and is attached along the inner border of the hippocampus major to its termination.

Fascia dentata.—If the corpus fimbriatum be carefully raised, a narrow serrated band of gray substance will be seen beneath it: this is the fascia dentata.

Fig. 28. A diagram representing the longitudinal section of the brain between the two hemispheres.



1. The corpus callosum. 2. Its anterior extremity turning downwards to terminate at the base of the brain. 3. Its posterior extremity, much larger than the anterior, forms a rounded border, which is continuous with 4. The fornix. 5. The two crura of the fornix, terminating in 6. The two corpora albicantia. 7. The septum lucidum. 8. The velum interpositum. 9. The foramen of Munro. 10. The venæ Galeni, escaping through the fissure of Bichât to enter the straight sinus. 11. The third ventricle. 12. Section of the anterior commissure. 13. Section of the middle commissure, commissura mollis. 14. Section of the posterior commissure. 15. The foramen commune anterius, or space between the anterior and middle commissure, leading downwards in the direction of the arrow, between the crura of the fornix to the infundibulum: hence it is also named iter ad infundibulum. 16. The pituitary gland. 17. The foramen commune posterius. 18. The cut edge of the corpora quadrigemina, which forms the superior boundary of the iter à tertio ad quartum ventriculum, leading from the third (11.) into the fourth ventricle 19. 20. The corpora quadrigemina. 21. The crus cerebri of the right side. 22. Section of the pons Varolii. 23. Section of the medulla oblongata.

Beneath the corpus fimbriatum will be likewise seen the

transverse fissure of the brain, which has been before described as stretching from the fissure of Sylvius on one side, across to the same fissure on the opposite side of the brain. It is through this fissure that the pia mater communicates with the *choroid plexus*, and the latter obtains its supply of blood. The fissure is bounded on one side by the corpus fimbriatum, and on the other by the under surface of the thalamus opticus.

The internal boundary of the lateral ventricle is the *septum lucidum* (*fig. 28. 7*). This septum is thin and semi-transparent, and consists of two laminae of cerebral substance attached above to the under surface of the corpus callosum at its anterior part, and below to the fornix. Between the two layers is a narrow space, the *fifth ventricle*, (*fig. 26. 4.*) which is lined by a proper membrane.

The *Fifth ventricle* may be shown, by snipping through the septum lucidum transversely with the scissors.

The corpus callosum should now be cut across towards its anterior extremity, and the two ends carefully dissected away. The anterior portion will be retained only by the septum lucidum, but the posterior will be found incorporated with the white layer beneath, which is the fornix.

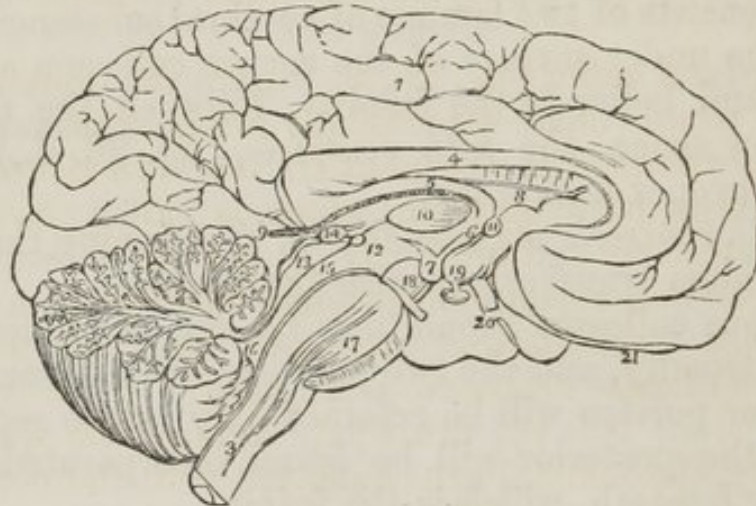
The *Fornix* (*fig. 26. 5. 5. fig. 28. 4.*) (arch,) is a triangular lamina of white substance, broad behind, and extending into each lateral ventricle, and narrow in front, where it terminates in two crura, (*fig. 28. 5.*) which arch downwards to the base of the brain. The two crura descend through the foramen commune anterius of the third ventricle, and terminate in the *corpora albicantia*, 6. Opening transversely beneath these two crura, just as they are about to arch downwards, is the *foramen of Munro*, 9. through which the two lateral ventricles communicate, and the choroid plexuses are connected anteriorly.

The lateral thin edges of the fornix are continuous posteriorly with the concave border of the hippocampus major at each side, and form the narrow white band called *corpus fimbriatum*. In the middle line the fornix is continuous with the corpus callosum, and at each side with the hippocampus major and minor.

Upon the under surface of the fornix towards its posterior part, some transverse lines are seen passing between the diverging lateral fasciculi; this appearance is termed the *lyra*, from a fancied resemblance to the strings of a harp.

The fornix may now be removed by dividing it across anteriorly, and turning it backwards, at the same time separating its lateral connexions with the hippocampi. If the student examine its under surface he will perceive the lyra above described.

Fig. 29. The mesial surface of a longitudinal section of the brain. The incision has been carried along the middle line; between the two hemispheres of the cerebrum, and through the middle of the cerebellum and medulla oblongata.



1. The inner surface of the left hemisphere. 2. The divided surface of the cerebellum, showing the arbor vitæ. 3. The medulla oblongata. 4. The corpus callosum, rounded before to terminate in the base of the brain; and behind, to become continuous with 5, the fornix. 6. One of the crura of the fornix descending to 7, one of the corpora albicantia. 8. The septum lucidum. 9. The velum interpositum, communicating with the pia mater of the convolutions through the fissure of Bichât. 10. Section of the middle commissure situated in the third ventricle. 11. Section of the anterior commissure. 12. Section of the posterior commissure; the commissure is somewhat above and to the left of the number. The interspace between 10 and 11 is the foramen commune anterius, in which the crus of the fornix (6) is situated. The interspace between 10 and 12 is the foramen commune posterius. 13. The corpora quadrigemina, upon which is seen resting the pineal gland, 14. 15. The iter à tertio ad quartum ventriculum. 16. The fourth ventricle. 17. The pons Varolii, through which are seen passing the diverging fibres of the corpora pyramidalia. 18. The crus cerebri of the left side, with the third nerve arising from it. 19. The tuber cinereum, from which projects the infundibulum, having the pituitary gland appended to its extremity. 20. One of the optic nerves. 21. The left olfactory nerve terminating anteriorly in a rounded bulb.

Beneath the fornix is the *Velum interpositum*, (*fig. 26. 7. fig. 28. 8.*), a reflection of pia mater introduced into the interior of the brain, through the transverse fissure.

This velum is connected at either side with the choroid plexus, and contains within its two layers two large veins, the

Venæ Galeni, (*fig. 28. 10.*), which receive the blood from the ventricles, and terminate posteriorly in the straight sinus.

Upon the under surface of the velum interpositum, are two fringe-like bodies which project into the third ventricle. These are the *choroid plexuses* of the *third ventricle*.

If the velum interpositum be raised and turned back, an operation which must be conducted with care, particularly at its posterior part, where it invests the pineal gland, the thalami optici and the cavity of the third ventricle will be exposed.

The *Thalami optici* (*fig. 26. 9. 9.*) are two rounded oblong bodies of a white colour superficially inserted between the two diverging portions of the corpora striata. In the middle line a fissure exists between them, which is called the *third ventricle*. Posteriorly and inferiorly, they form the superior wall of the descending cornu, and present two rounded elevations called *corpus geniculatum externum* and *internum*. The *corpus geniculatum externum* is the larger of the two, and of a grayish color; it is the principal origin of the optic nerve.

Inferiorly, the thalami are connected with the corpora albicantia by means of two white bands, which appear to originate in the white substance uniting the thalami to the corpora striata.

In their interior the thalami are composed of white fibres mixed with gray substance. They are essentially the *inferior ganglia of the hemispheres*.

The *Third ventricle* (*fig. 26. 10. fig. 28. 11. 11.*) is the fissure between the thalami optici and corpora striata. It is bounded above by the under surface of the velum interpositum, from which are suspended the choroid plexuses of the third ventricle.

Its *Floor* is formed by the anterior termination of the corpus callosum, the tuber cinereum, corpora albicantia, and locus perforatus.

Its *sides* are formed by the thalami optici and part of the corpora striata.

Anteriorly, it is bounded by the anterior commissure and crura of the fornix, and *posteriorly* by the posterior commissure and aqueduct of Sylvius.

The third ventricle is crossed by three commissures, the anterior, middle, and posterior; and between these are two

spaces, called *foramen commune anterius* and *foramen commune posterius*.

The *Anterior commissure* (*fig. 28. 12.*) is a rounded white cord, communicating with the *corpora striata*.

The *Middle, or soft commissure* (*fig. 28. 13. fig. 26. 18.,*) consists of gray matter, and is very easily broken down; it connects the adjacent sides of the *thalami optici*.

The *Posterior commissure* (*fig. 28. 14.*) is a rounded white cord, connecting the two *thalami optici* posteriorly.

Between the anterior and middle commissure, is the space called *foramen commune anterius* (*fig. 28. 15.,*) which from leading downwards into the *infundibulum*, is also designated *iter ad infundibulum*. The *crura* of the *fornix* descend through this space, surrounded by gray matter, to the *corpora albicantia*.

Between the middle and posterior commissure, is the *foramen commune posterius* (*fig. 28. 17.*) from which a canal leads backwards to the fourth ventricle, the *iter à tertio ad quartum ventriculum*.

Behind the third ventricle is placed the quadrifid ganglion, called optic lobes in the inferior animals, and *corpora quadrigemina* (*fig. 28. 27. fig. 32. 1.*) in man.

The two anterior of these bodies are the larger, and are named *nates*; the two posterior, *testes*. Resting upon them, and surrounded by a sheath of *pia mater*, obtained from the *velum interpositum*, with which it is liable to be torn off, unless very great care be used, is the *pineal gland*.

The *Pineal gland* consists of soft gray substance, and is of a conical form; hence one of its synonyms, *conarium*. It contains in its interior several brownish granules, which are composed of phosphate and carbonate of lime.

It is connected to the *thalami optici* by two small rounded cords, called *peduncles*. It is very improperly called a gland.

Behind the *corpora quadrigemina* is the *cerebellum*, and beneath the *cerebellum* the fourth ventricle. The student must therefore divide the *cerebellum* down to the fourth ventricle, and turn its lobes aside to examine that cavity.

The *Fourth ventricle* (*fig. 28. 19. fig. 32. 4.*) is the ventricle of the *medulla oblongata*, upon the posterior surface of which it is placed. It is an oblong quadrilateral cavity bounded on either side by a thick cord passing between the

cerebellum and corpora quadrigemina, called the *processus è cerebello ad testes* (fig. 32. 2. 2.,) and by the *corpus restiforme*, 3. 3. It is covered in *behind* by the arch of the cerebellum, which forms three remarkable projections into its cavity, named, from their resemblance, *uvula* and *tonsils*; and by a thin lamella of white substance, stretched between the two *processus è cerebello ad testes*, termed the *valve of Vieussens*.* This layer is easily broken down, and requires that care be used in its demonstration.

In *Front* the fourth ventricle is bounded by the posterior surface of the medulla oblongata; *above* by the corpora quadrigemina, and the termination of the iter à tertio ad quartum ventriculum; and *below* by a layer of pia mater and one of arachnoid, passing between the under surface of the cerebellum and the medulla oblongata, called the *valve of the arachnoid*.

We observe within the fourth ventricle the *choroid plexuses*, the *calamus scriptorius*, and *linex transversæ*.

The *Choroid plexus* resembles in miniature that of the lateral ventricles: it is formed by the pia mater, and lies against that part of the cerebellum called *uvula* and *tonsils*.

The anterior wall, or floor, of the fourth ventricle is formed of gray substance, which is continuous with that contained within the spinal cord. This gray substance is separated into two bands by a median fissure, which is continuous with the *calamus scriptorius*. The two bands are considered by Mr. Solly as the true *posterior pyramids*; and he has observed in their structure such an arrangement of fibres as induces him to name them the "*posterior ganglia of the medulla oblongata*," in opposition to the corpora olivaria, which he describes as the "*anterior ganglia of the medulla*."

The *Calamus scriptorius* (fig. 32. 6.) is a groove upon the anterior wall, or floor, of the fourth ventricle. Its pen-like appearance is produced by the divergence of the posterior median columns, 7., the feather by the *linex transversæ*. At the point of the pen is a small cavity lined with gray substance, and called *Ventricle of Arantius*.

The *Linex transversæ* (fig. 32. 8.) are irregular transverse

* Raymond Vieussens, a great discoverer in the anatomy of the brain and nervous system. His "*Neurographia Universalis*" was published in Lyons, in 1685.

lines upon the anterior wall of the ventricle, which in some degree resemble the plume of the pen. They are the filaments of origin of the auditory nerve.

There is no communication between the fourth ventricle and the subarachnoidean cellular tissue, as imagined by Magendie.

Lining Membrane of the Ventricles.

The lining membrane of the ventricles is a serous layer, quite distinct from the arachnoid, and having no communication with it. This membrane lines the whole of the interior of the lateral ventricles, and is connected above and below to the attached border of the choroid plexus, so as to exclude completely all communication between the ventricles and the exterior of the brain. It is reflected through the foramen of Munro on each side into the third ventricle, which it invests throughout. From the third it is conducted into the fourth ventricle, through the *iter à tertio ad quartum ventriculum*, and lines its interior, together with the layer of pia mater which forms its inferior boundary; in this manner a perfect communication is established between all the ventricles, with the exception of the fifth, which has its own proper membrane. It is this membrane which gives them their polished surface, and transudes the secretion which moistens their interior. When this fluid accumulates to an unnatural degree, it may then break down the layer of pia mater at the bottom of the fourth ventricle, and thus pour its fluid into the subarachnoidean cellular tissue; but in the normal condition no communication whatever can exist between the interior of the ventricles and the serous covering of the exterior of the brain.

CEREBELLUM.

The *Cerebellum*, according to Cruveilhier, is seven times smaller than the cerebrum. Like it, it is composed of white and gray substance, whereof the gray is in larger proportion than the white. Its surface is formed by parallel *lamellæ*, separated by fissures; and at intervals deeper fissures exist, which divide it into larger segments, termed *lobules*. The cerebellum is divided into two lateral hemispheres, or lobes, two minor lobes called superior and inferior vermiform processes, and some small lobules.

The *Lateral lobes* are separated from each other posteriorly

by a depression which lodges the falx cerebelli, and above and below by the projection of the vermiform processes.

The *Superior vermiform process* is all that exists of the cerebellum in birds, and forms the largest proportion of the organ in many mammalia. It is situated along the middle line, and serves to connect the lateral lobes superiorly.

The *Inferior vermiform process* forms a projection inferiorly, and is the means of connexion between the lateral lobes below.

The principal lobules are the pneumogastric, the tonsils, uvula, and linguetta laminosa.

The *Pneumogastric lobule* (flocculus) is situated on the anterior border of the cerebellum, near to the origin of the eighth pair of nerves, and is hence called pneumogastric. It is not unlike a convoluted shell in its form.

The *Tonsils* and *Uvula* resemble those organs in a swollen state very strikingly; they project from the under surface of the cerebellum into the fourth ventricle.

The *Linguetta laminosa* is a thin tonguelet of gray substance, marked by transverse furrows extending forwards upon the valve of Vieussens from the gray substance of the cerebellum.

When cut into vertically, the cerebellum presents the appearance termed *arbor vitæ*. If the incision be made through the outer third of the organ, a gray body, surrounded by a yellow zig-zag line of horny structure, will be seen in the centre of the white substance: this is the *corpus rhomboideum*, or ganglion of the cerebellum.

The cerebellum is associated with the spinal cord and cerebrum by three pair of peduncles, the Corpora restiformia, Processus è cerebello ad testes, Crura cerebelli.

The *Corpora restiformia*, or *inferior peduncles*, diverge at the upper extremity of the medulla oblongata, and enter the cerebellum, forming, by their divergence, part of the lateral boundaries of the fourth ventricle. Their fibres surround the corpus rhomboideum, and are expanded into the lamellæ of the cerebellum.

The *Processus è cerebello ad testes* are the *superior peduncles*: they ascend from the corpus rhomboideum on each side to the testis, and also form part of the lateral boundaries of the fourth ventricle. The valve of Vieussens, by connecting the two processus è cerebello ad testes from side to side,

and the cerebellum and testes from behind forwards, also contributes to the antero-posterior communication.

The *Crura cerebelli* are the terminations of the transverse fibres of the pons Varolii, or great commissure of the cerebellum, which serves to establish a transverse communication between the lateral lobes.

Base of the Brain.

The student should now prepare to study the base of the brain; for this purpose it should be turned upon its incised surface, and if the dissection have hitherto been conducted with care, he will find the base perfectly uninjured. The arachnoid membrane, some parts of the pia mater, and the circle of Willis, must be carefully cleaned away in order to expose all the structures. These he will find arranged in the following order from before backwards:—Longitudinal fissure, Olfactory nerves, Fissure of Sylvius, Substantia perforata, Commencement of the transverse fissure, Optic commissure, Tuber cinereum, Infundibulum, Corpora albicantia, Locus perforatus, Crura cerebri, Pons Varolii, Crura cerebelli, Medulla oblongata.

The *Longitudinal* fissure is the space separating the two hemispheres: it is continued downwards to the base of the brain, and divides the two anterior lobes. In this fissure the anterior cerebral arteries ascend towards the corpus callosum; and, if the two lobes be slightly drawn away from each other, the anterior extremity of the corpus callosum will be seen descending to the base.

On either side of the longitudinal fissure, upon the under surface of each anterior lobe, is the *Olfactory nerve*, with its bulb.

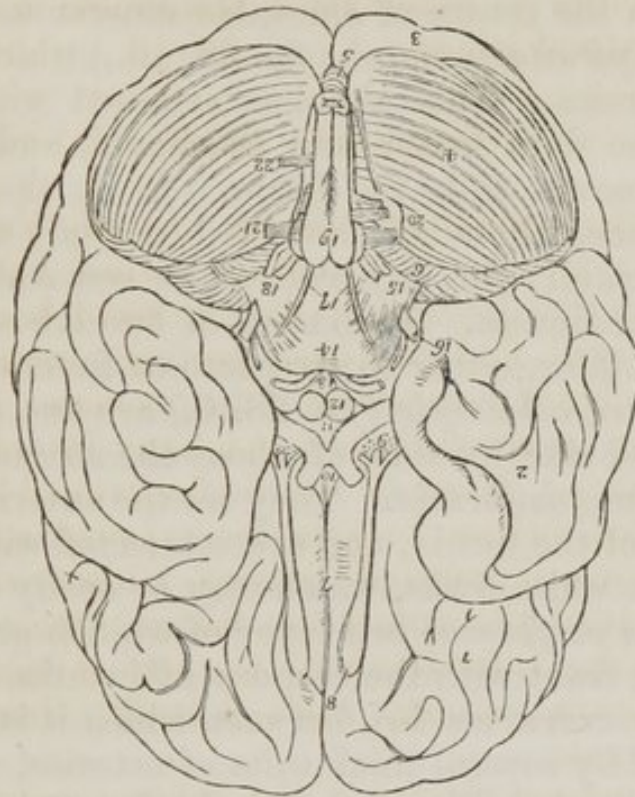
The *Fissure of Sylvius* bounds the anterior lobe posteriorly, and separates it from the middle lobe: it lodges the middle cerebral artery.

The *Substantia perforata*, is a triangular plane of white substance situated at the inner extremity of the fissure of Sylvius. It is named perforata from being pierced by a number of openings for small arteries, which enter the brain in this situation to reach the corpus striatum.

Passing backwards on each side beneath the edge of the middle lobe, is the commencement of the *great transverse fis-*

sure, which extends beneath the hemispheres to the same point on the opposite side.

Fig. 30. The under surface or base of the brain.



1. The anterior lobe of one hemisphere of the cerebrum. 2. The middle lobe. 3. The posterior lobe almost concealed by (4) the lateral lobe of the cerebellum. 5. The inferior vermiform process of the cerebellum. 6. The pneumogastric lobule. 7. The longitudinal fissure. 8. The olfactory nerves, with their bulbous expansions. 9. The substantia perforata at the inner termination of the fissure of Sylvius; the three roots of the olfactory nerve are seen upon the substantia perforata. The commencement of the transverse fissure on each side is concealed by the inner border of the middle lobe. 10. The commissure of the optic nerves. 11. The tuber cinereum, from which the infundibulum is seen projecting. 12. The corpora albicantia. 13. The locus perforatus bounded on each side by the crura cerebri, and by the third nerve. 14. The pons Varolii. 15. The crus cerebelli of one side. 16. The fifth nerve emerging from the anterior border of the crus cerebelli; the small nerve by its side is the fourth. 17. The sixth pair of nerves. 18. The seventh pair of nerves, consisting of the auditory and facial. 19. The corpora pyramidalia of the medulla oblongata; the corpus olivare and part of the corpus restiforme are seen at each side. Just below the number is the decussation of the fibres of the corpora pyramidalia. 20. The eighth pair of nerves. 21. The ninth or hypoglossal nerve. 22. The anterior root of the first cervical spinal nerve.

The *Optic commissure* is situated on the middle line: it is the point of communication between the two optic nerves.

The *Tuber cinereum*, is an eminence of gray substance

immediately behind the optic commissure, and connected with its posterior border. It forms part of the floor of the third ventricle.

The *Infundibulum* is a tubular process of gray substance, opening from the centre of the tuber cinereum, and attached below to the *pituitary gland*, (*fig. 28. 16.*) which is lodged in the sella turcica. This gland is retained within the sella turcica by the dura mater and arachnoid, and is with great difficulty removed with the brain. It is, therefore, better left in its place, where it is intended to study afterwards the base of the skull; for any attempt at removal would injure the cavernous sinuses. It consists of two lobes, but presents nothing glandular, either in structure or function.

The *Corpora albicantia* (*fig. 28. 6.*) are two rounded white bodies, placed side by side, of about the size of peas; hence their synonym, *pisiformia*. They are the anterior extremities of the crura of the fornix, and are connected with the thalami optici by two white cords, which may be easily traced.

The *Locus perforatus* is a layer of whitish gray substance, connected in front with the corpora albicantia, and on either side with the crura cerebri, between which it is situated. It is perforated by several thick tufts of arteries, which are distributed to the thalami optici and third ventricle, of which it assists in forming the floor. It is sometimes called *pons Tarini*.

The *Crura cerebri* are two thick white cords which issue from beneath the pons Varolii, and diverge to either side to enter the thalami optici. The third nerve will be seen to arise from the inner side of each, and the fourth nerve winds around them from above. If the crus cerebri be cut across, it will be seen to present, in the centre of the section, a dark spot, the *locus niger*.

The *Pons Varolii** (*protuberantia annularis*) is the broad transverse band of white fibres which arches like a bridge across the upper part of the medulla oblongata, and contracting on either side into a thick rounded cord, enters the substance of the cerebellum under the name of *crus cerebelli*.

* Constant Varolius, Professor of Anatomy in Bologna: he died in 1578. He dissected the brain in the course of its fibres, beginning from the medulla oblongata: a plan which has since been perfected by Vieussens, and by Gall and Spurzheim. The work, containing his mode of dissection, "*De Resolutione Corporis Humani*," was published after his death, in 1591.

There is a groove along its middle which lodges the basilar artery. The pons Varolii is the commissure of the cerebellum, and associates the two lateral lobes in their common function. Resting upon the pons, near its posterior border, is the sixth pair of nerves. On the anterior border of the crus cerebelli, at each side, is the thick bundle of filaments belonging to the fifth nerve, and, lying on its posterior border, the seventh pair of nerves.

The *Medulla oblongata* (fig. 44. 1.) is the upper enlarged portion of the spinal cord. Upon its anterior surface are seen two narrow projecting columns, the *corpora pyramidalia* (fig. 44. 21.) These bodies are broad above and narrow below, and at the point where they enter the pons Varolii they become considerably constricted. They are connected to each other in the middle fissure, at about an inch below the pons, by a *decussation* of their fibres, which form small interlacing bands crossing from side to side.

Externally to the corpora pyramidalia are two oblong and rounded bodies, supposed to resemble olives in their form, and hence called *Corpora olivaria* (fig. 44. 3.) If these bodies be divided by a longitudinal section, a gray zig-zag outline, resembling the corpus rhomboideum of the cerebellum, will be seen in the interior of each. This is the ganglion of the corpus olivare.

Behind the corpus olivare is a narrow white band, which descends along the side of the medulla oblongata at the bottom of the lateral sulcus. This is the *Respiratory tract* of Sir Charles Bell.

The *Corpora restiformia* (fig. 44. 4.) (restis, a rope) are the remaining columns of the medulla oblongata, and form its posterior segment. They diverge superiorly to enter the cerebellum. Between the two corpora restiformia posteriorly, are two other white bands, which diverge at the point of the calamus scriptorius, and join the corpora restiformia: these are the *posterior median fasciculi* of the medulla oblongata.

If a thin layer of the pons Varolii be carefully raised, or if a longitudinal incision be made across it, it may easily be seen that the corpus pyramidale passes through the pons into the crus cerebri. If the crus cerebri be traced forwards, it will be found to enter the thalamus opticus, and leaving it by its opposite border to plunge into the corpus striatum, and

pass from thence onwards to the convolutions of the hemispheres.

From pursuing this remarkable course, and spreading out as they advance, these fibres have been called by Gall the *diverging fibres*. While situated within the pons it is found that the fibres of the *corpus pyramidale* separate and spread out, and have gray substance interposed between them; and that they quit the pons much increased in number and bulk, so as to form the *crus cerebri*. The fibres of the *crus cerebri* again are separated in the thalamus opticus, and are intermingled with gray matter, and they also quit that body greatly increased in number and bulk. Precisely the same change takes place in the corpus striatum, and the fibres are now so extraordinarily multiplied as to be capable of forming a large proportion of the hemispheres, viz. the whole of the lower part of the anterior and middle lobes.

From observing this remarkable increase in the white fibres apparently from the admixture of gray substance, Gall and Spurzheim considered the latter as the material of increase or formative substance to the white fibres, and they are borne out in this conclusion by several collateral facts, among the most prominent of which is the great vascularity of the gray substance; and the larger proportion of the nutrient fluid circulating through it is fully capable of effecting the increased growth and nutrition of the structures by which it is surrounded. For a like reason the bodies in which this gray substance occurs, are called by the same physiologists "*ganglia of increase*," and by other authors simply ganglia. Thus the thalami optici and corpora striata are the ganglia of the cerebrum, or in other words, the *formative ganglia* of the hemispheres.

Mr. Solly, in a recent work upon "the human brain," has designated the diverging fibres of the corpus pyramidale that pursue the course above described, "*the cerebral fibres*;" to distinguish them from another set of fibres discovered by that gentleman, which also proceed from the corpus pyramidale, and pass outwards beneath the corpus olivare to the cerebellum. These he names the "*arciform fibres*," and divides them into two layers, the *superficial cerebellar*, and *deep cerebellar fibres*. They join the corpus restiforme, forming one-fourth of its whole diameter, and spread out in the structure of the cerebellum.

The *Corpora olivaria* owe their convex olive-shaped form to a "ganglion of increase" (the anterior ganglia of the medulla oblongata of Solly) placed in their interior. The white fibres which surround this ganglion form a fasciculus that is continued into the pons Varolii along with the corpora pyramidalia. Here its fibres are mixed with gray matter, and pass into the crus cerebri, forming its superior and inner segment. From the crus cerebri they traverse successively the thalamus opticus and corpus striatum, and become developed into the convolutions of the upper part of the hemispheres and posterior lobe.

The *Corpora restiformia* diverge as they approach the cerebellum, and leave between them the cavity of the fourth ventricle. They then enter the substance of the cerebellum under the form of two rounded cords. These cords envelope the corpora rhomboidea, or ganglia of increase, and then expand on all sides so as to constitute the cerebellum.

In addition to the diverging fibres which are thus shown to constitute both the cerebrum and cerebellum, by their increase and development, another set of fibres are found to exist, which have for their office the association of the symmetrical halves. These are called from their direction *converging fibres*, and from their office *commissures*. The commissures of the cerebrum and cerebellum are, the Corpus callosum, Fornix, Septum lucidum, Anterior commissure, Middle commissure, Posterior commissure, Peduncles of the pineal gland, Procèssus è cerebello ad testes, Valve of Vieussens, Pons Varolii.

The *Corpus callosum* is the commissure of the hemispheres. It is therefore of moderate thickness in the middle, where its fibres pass directly from one hemisphere to the other—thicker in front, where the anterior lobes are connected, and thickest behind where the fibres from the posterior lobes are assembled.

The *Fornix* is an antero-posterior commissure, and serves to connect a number of parts. Below it is associated with the thalami optici; on each side by means of the corpora fimbriata with the middle lobes of the brain, and above, with the corpus callosum, and consequently with the hemispheres.

The *Septum lucidum* is a perpendicular commissure between the fornix and corpus callosum.

The *Anterior commissure* connects together the anterior

portions of the posterior lobes of the brain, and the corpora striata.

The *Middle commissure* is a layer of gray substance, uniting the thalami optici.

The *Posterior commissure* is a white rounded cord, connecting the thalami optici.

The *Peduncles of the pineal gland* must also be regarded as commissures, assisted in their function by the gray substance of the gland.

The *Processus è cerebello ad testes* is the means of communication between the white substance of the cerebellum and cerebrum; and the linguetta laminosa and valve of Vieussens perform the same office to the gray substance.

The *Pons Varolii* is the commissure to the two lobes of the cerebellum. It consists of transverse fibres, which are split into two layers by the passage of the fasciculi of the corpora pyramidalia and olivaria. These two layers, the superior and inferior, are collected together on each side, in the formation of the crura cerebelli.

CEREBRAL NERVES.

There are *nine pairs* of cerebral nerves. Taken in their order from before, backwards, they are

1st. Olfactory.

2d. Optic.

3d. Motores oculorum.

4th. Pathetici (trochleares).

5th. Trifacial (trigemini).

6th. Abducentes.

7th. { Facial (portio dura),
Auditory (portio mollis).

8th. { Glosso-pharyngeal,
Pneumogastric (vagus, par vagum),
Spinal accessory.

9th. Lingual (hypoglossal).

Functionally or physiologically they are divided into four groups, and in this order we shall examine them.

Nerves of

1. <i>Special sense</i>	-	{	1st. Olfactory,
			2d. Optic,
			7th. Auditory.
2. <i>Motion</i>	-	{	3d. Motores oculorum,
			6th. Abducentes,
			9th. Lingual.
3. <i>Respiration, (Bell.)</i>		{	4th. Patheticus,
			7th. Facial,
			8th. Glosso-pharyngeal.
			Pneumogastric.
			Spinal accessory.
4. <i>Spinal</i>	-	-	5th. Trifacial.

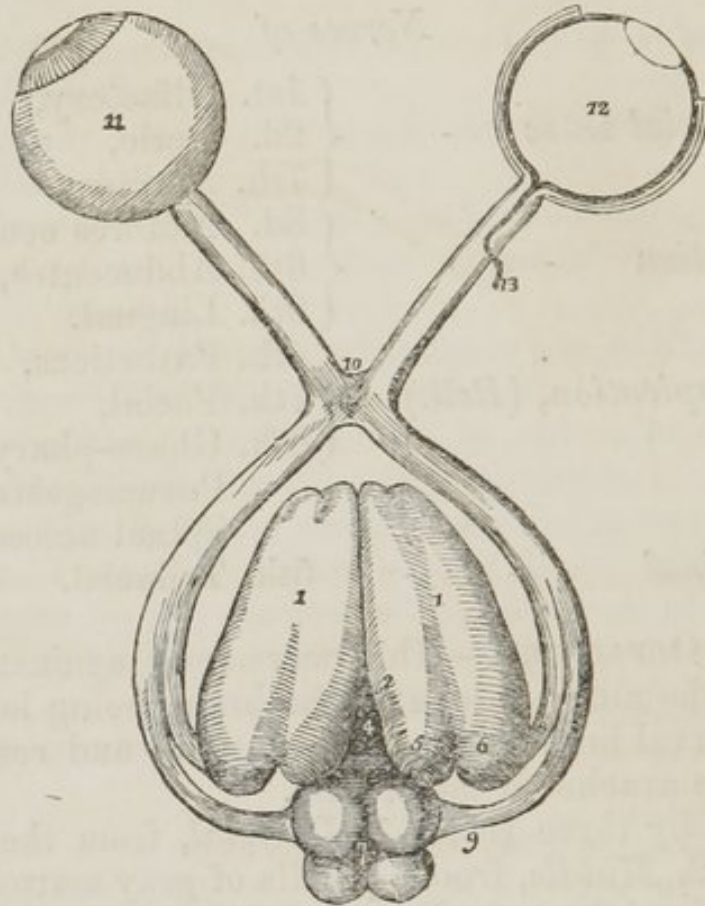
1st pair, OLFACTORY.—This nerve rests against the under surface of the anterior lobe of the brain, being lodged in the narrow interval between two convolutions, and retained in its place by the arachnoid membrane.

It arises by three roots, 1. *Internal*, from the substantia perforata. 2. *Middle*, from a papilla of gray matter embedded in the anterior lobe. 3. *External*, from a long root which is traced for a considerable distance along the fissure of Sylvius, into the middle lobe. The union of these roots forms a nerve, triangular in form, and soft in structure, which expands into a *bulb (bulbus olfactorius)*, and rests upon the cribriform plate.

Its branches are transmitted through the numerous foramina in the cribriform plate, to be distributed to the mucous membrane of the nose.

2d. pair, OPTIC.—The optic nerve (*fig. 31.*) arises by two roots,—*one*, 8., from the *corpus geniculatum externum*, 6.; the *other*, 9., from the *nates*. It winds around the crus cerebri as a flattened band, and unites with its fellow of the opposite side to form the *commissure*, 10. The two nerves then diverge from each other to enter the orbit through the optic foramen, pierce the sclerotic and choroid coats of the eyeball, and expand in the retina, 11. The commissure rests upon the processus olivaris of the sphenoid bone, and its posterior border is closely connected with the tuber cinereum. On entering the orbit, the nerve obtains a firm sheath from the dura mater, which is continuous with the sclerotic coat of the eyeball.

Fig. 31. The origin and distribution of the optic nerves.

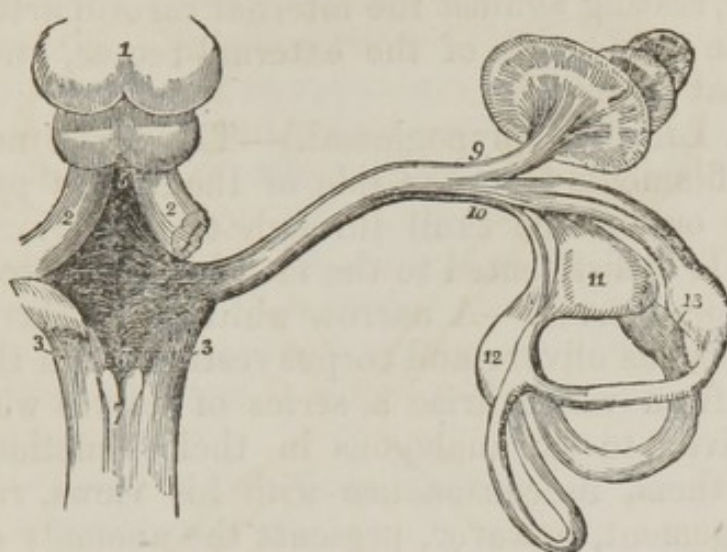


1. 1. The thalami optici, their upper surface. 2. The middle commissure of the third ventricle, connecting the two thalami. 3. The posterior commissure of the third ventricle. 4. The foramen commune posterius. 5. The corpus geniculatum internum. 6. The corpus geniculatum externum. 7. The corpora quadrigemina: the anterior pair are the nates, the posterior the testes. 8. One root of the optic nerve, arising from the corpus geniculatum externum. 9. The other root, arising from the nates. 10. The commissure. 11. The expansion of the optic nerve into the retina. 12. A section of the retina, showing its three layers: the external is Jacob's membrane, the next the nervous, and the internal the vascular, formed by the ramifications of the arteria centralis retinae, which is seen at 13, piercing the optic nerve, and running forwards in the centre of that nerve.

7th pair, AUDITORY (*portio mollis*.)—This nerve (*fig. 32*) arises from the anterior wall or floor, 4., of the fourth ventricle, by means of the white fibres, *lineae transversae*, 8., of the calamus scriptorius. It winds around the corpus restiforme, and enters the meatus auditorius internus, together with the facial nerve, which lies in a depression on its surface. At the bottom of the meatus it divides into two branches, which are distributed to the internal ear.

It is extremely soft in its structure: hence its synonyme, *portio mollis*.

Fig. 32. The origin and distribution of the auditory nerve.



1. The corpora quadrigemina. 2. 2. The processus à cerebello ad testes, at each side. 3. 3. The corpora restiformia. 4. The space included between these four bodies, the fourth ventricle. 5. The opening of the canal of communication which leads from the third ventricle, the iter à tertio ad quartum ventriculum. 6. The calamus scriptorius. 7. The posterior median columns of the spinal cord, which form by their divergence the point of the calamus, which is also called the ventricle of Arantius. 8. The lineæ transversæ of the fourth ventricle, which are the lines of origin of the auditory nerve. 9. The anterior branch of the auditory nerve, distributed to the cochlea. 10. The posterior, or vestibular branch. 11. The utriculus communis, which conceals the sacculus proprius from view. 12. The ampulla of the oblique semicircular canal. 13. The ampullæ of the perpendicular and horizontal semicircular canals.

The corpora pyramidalia are the continuations of the *anterior columns* of the spinal cord: hence their function is *motion*. The prolongation of these fasciculi through the pons Varolii into the crura cerebri is the *motor tract, tractus motorius*. Now the three motor nerves arise from the motor tract at different points of its course.

3d pair, MOTORES OCULORUM.—This nerve (*fig. 49. 3.*) arises from the inner side of the *crus cerebri*. It pierces the dura mater immediately in front of the posterior clinoid process, descends obliquely along the external wall of the cavernous sinus, and enters the orbit between the two heads of the external rectus, to be distributed to all the muscles of the orbit excepting the superior oblique and external rectus.

6th pair, ABDUCENTES.—The abducens nerve (*fig. 49. 6.*) arises from the upper part of the *corpus pyramidale*. It pierces the dura mater upon the basilar process of the sphenoid bone, and ascends to the cavernous sinus. It then runs

forwards along the inner wall of the sinus, below all the other nerves, and, resting against the internal carotid artery, passes between the two heads of the external rectus, and is distributed to that muscle.

9th pair. LINGUAL (hypoglossal).—The ninth nerve arises by several filaments from the side of the *corpus pyramidale*, and passes out of the skull through the anterior condyloid foramen. It is distributed to the muscles of the tongue.

Respiratory nerves.—A narrow white fasciculus exists between the corpus olivare and corpus restiforme in the medulla oblongata, from which arise a series of nerves which Sir C. Bell conceived to be analagous in their function. Hence he named them, in consonance with his views, *respiratory*. This arrangement, however, presents the anomaly of a respiratory nerve being distributed to one of the muscles of the orbit.

4th pair, PATHETICI (*fig. 49. 4.*) (trochlearis).—This is the smallest cerebral nerve; it arises from the *testis* and *valve of Vieussens*, pierces the dura mater at the anterior attachment of the tentorium, close to the oval opening which transmits the fifth nerve, and passes along the outer wall of the cavernous sinus to enter the orbit above the origin of the levator palpebræ muscle. In the sinus it is the second nerve from above, but soon rises above the third, and becomes the highest. It is distributed upon the orbicular surface of the superior oblique, or trochlearis muscle: hence its synonyme *trochlearis*.

7th pair, FACIAL (*portio dura.*)—The *facial nerve* (*fig. 44. 23.*) arises from the upper part of the respiratory tract, where it joins the pons Varolii. It enters the internal auditory foramen along with the portio mollis, and then passes along the aqueductus Fallopii to its exit from the skull at the stylo-mastoid foramen. It is distributed to the muscles of the face and head, and is the true motor nerve of the face.

8th pair.—This pair consists of three nerves, the *glossopharyngeal*, *pneumogastric*, and *spinal accessory*.

The GLOSSO-PHARYNGEAL NERVE arises (*fig. 44. 5.*) by several filaments from the respiratory tract, between the corpus olivare and restiforme, and quits the skull at the foramen lacerum posterius, to be distributed principally to the mucous membrane and secreting apparatus of the tongue and pharynx.

The PNEUMOGASTRIC-NERVE (*vagus*) arises (*fig. 44. 8.*) by

a great number of filaments immediately below the glosso-pharyngeal, and passes through the foramen lacerum posterius, with the preceding nerve. It is distributed to the respiratory and digestive apparatus and heart; its course is, therefore, long and wandering: hence its synonyme, *vagus*.

The SPINAL ACCESSORY NERVE arises (*fig. 44. 20.*) by several filaments from the respiratory tract, opposite the fourth cervical vertebra. It ascends to the foramen magnum, between the anterior and posterior roots of spinal nerves, and behind the ligamentum denticulatum, and joins the other two nerves at the foramen lacerum posterius, through which it accompanies them.

It is distributed to the sterno-mastoid, trapezius, and levator anguli scapulæ muscles.

Spinal nerve, 5th pair, TRIFACIAL (trigeminus.)—This nerve is analogous to the spinal nerves in its origin by two roots from the anterior and posterior columns of the spinal cord, and in the existence of a ganglion on the posterior root. Hence it ranges with the spinal nerves, and is considered as the spinal cranial nerve.

It arises by two roots, an *anterior root* (*fig. 49. 11.*) of small size, from the *corpus pyramidale*, and a *posterior root*, 10, larger than the anterior, from the *corpus restiforme*. The two roots pass forwards through the pons Varolii to the anterior border of the crus cerebelli, where the nerve makes its appearance on the brain. In this situation it consists of from seventy to eighty filaments, held together by arachnoid membrane. The nerve then passes through an oval opening in the border of the tentorium, near to the extremity of the petrous bone, and spreads out into a large semilunar ganglion, the *Casserian*, which divides into three large branches, *ophthalmic*, *superior maxillary*, and *inferior maxillary*. If the ganglion be carefully turned up, the anterior root will be seen as a flattened cord lying against the ganglion, and crossing it to join the inferior maxillary nerve.

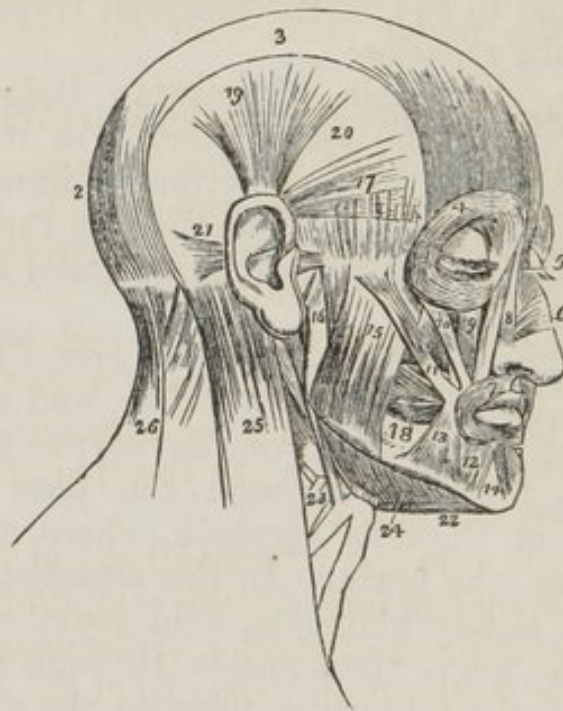The Casserian ganglion rests upon the anterior root of the fifth nerve, the cranial branch of the Vidian, the nervous petrosus superficialis minor, or the communicating branch from Jacobson's nerve, to the otic ganglion, the sixth nerve, and the internal carotid artery.

The *dissection of the face* is now to be commenced, for which purpose the longitudinal incision of the vertex is to be

continued onwards to the tip of the nose, and thence downwards to the margin of the upper lip; then carry an incision along the margin of the lip to the angle of the mouth, and transversely across the face to the meatus auditorius. Lastly, divide the integument in front of the external ear upwards to the transverse incision which was made for exposing the occipito-frontalis.

Dissect the integument and superficial fascia carefully from the whole of the region included by these incisions, and the next groups of muscles will be brought into view.

Fig. 33. The muscles of the head and face.



1. The frontal portion of the occipito-frontalis.
2. Its occipital portion.
3. Its aponeurosis.
4. The orbicularis palpebrarum, which conceals the corrugator supercilii and tensor tarsi.
5. The pyramidalis nasi.
6. The compressor nasi.
7. The orbicularis oris.
8. The levator labii superioris alæque nasi. The figure is placed on the nasal portion.
9. The levator labii superioris proprius; the lower part of the levator anguli oris is seen between the muscles 10 and 11.
10. The zygomaticus minor.
11. The zygomaticus major.
12. The depressor labii inferioris.
13. The depressor anguli oris.
14. The levator labii inferioris.
15. The superficial portion of the masseter.
16. Its deep portion.
17. The attrahens aurem.
18. The buccinator.
19. The attolens aurem.
20. The temporal fascia which covers in the temporal muscle.
21. The retrahens aurem.
22. The anterior belly of the digastricus muscle; the tendon is seen passing through the aponeurotic pulley.
23. The stylo-hyoid muscle pierced by the posterior belly of the digastricus.
24. The mylo-hyoideus muscle.
25. The upper part of the sterno mastoid.
26. The upper part of the trapezius. The muscle between 25 and 26 is the splenius.

The *Orbicularis palpebrarum* is a sphincter muscle surrounding the orbit and eyelids. It *arises* from the nasal process of the superior maxillary bone, and from a short tendon (*tendo oculi*) extending between that process and the inner angle of the eyelids. Its fibres encircle the orbit and eyelids, forming a broad and thin muscular plane, which is *inserted* into the under surface of the tendon and process of bone from which it arose. Upon the eyelids its fibres are thin and very pale.

The *Corrugator supercili* is seen by raising the upper segment of the orbicularis palpebrarum from the frontal bone: it *arises* from the inner extremity of the superciliary ridge, and is *inserted* into the under surface of the orbicularis palpebrarum.

The *Tensor tarsi* (Horner's* muscle) is a thin plane of muscular fibres, about three lines in breadth and six in length. It is best dissected by separating the eyelids from the eye, and turning them over the nose without disturbing the *tendo oculi*; then dissect away the small fold of mucous membrane called *plica semilunaris*, and some loose cellular tissue under which the muscle is concealed. It *arises* from the orbital surface of the lachrymal bone, and passing across the lachrymal sac divides into two slips, which are *inserted* into the lachrymal ducts as far as the puncta.

The *Pyramidalis nasi* is a pyramidal slip of muscular fibres sent downwards upon the nose by the occipito-frontalis. It is *inserted* into the tendinous expansion of the *compressores nasi*.

The *Compressor nasi* muscle *arises* from the canine fossa on the superior maxillary bone, and spreads upon the side of the nose into a thin tendinous expansion, which is continuous across its ridge with that from the opposite side.

To obtain a complete view of the *Orbicularis oris* muscle, the integument should be raised from the whole circumference of the mouth. It is, however, sufficient for our present purpose to see only a part of the muscle. It is the sphincter of the mouth, and encircles it entirely, forming a thick muscular plane. Its fibres are continuous all the way round, hence it has neither origin nor insertion.

* W. E. Horner, M. D., Professor of Anatomy in the University of Pennsylvania. The notice of this discovery is contained in a work published in Philadelphia in 1827, entitled "Lessons in Practical Anatomy."

The *Levator labii superioris alæque nasi* arises from the nasal process of the superior maxillary bone, and, becoming broader as it descends, is *inserted* into the ala of the nose and upper lip.

The *Levator labii superioris proprius* arises from the lower border of the orbit, and is *inserted* into the side of the upper lip.

The *Levator anguli oris* arises from the canine fossa on the superior maxillary bone, and is *inserted* into the angle of the mouth.

The *Zygomatic* muscles both *arise* from the malar bone, and are *inserted* into the angle of the mouth. The zygomaticus minor is sometimes wanting.

The *Depressor labii superioris alæque nasi* is seen by drawing upwards the upper lip, and raising the mucous membrane. It is an extremely small slip of muscle, situated on each side of the frænum. It *arises* from the incisive fossa, and passes upwards to be *inserted* into the upper lip and ala of the nose.

To dissect the inferior labial region continue the vertical section from the margin of the lower lip to the point of the chin. Then carry an incision along the margin of the lower jaw to its angle, and thence up the border of the ramus to the external ear. Dissect off the integument and superficial fascia from the whole of this surface, and the muscles of the inferior labial region will be exposed.

The *Depressor labii inferioris* arises from the surface of the lower jaw-bone, near to the symphysis, and is *inserted* into the lower lip.

The *Depressor anguli oris* is a triangular plane of muscle *arising* by its base from the side of the body of the inferior maxilla, and *inserted* into the angle of the mouth.

The *Levator labii inferioris* (levator menti) *arises* from the incisive fossa on the inferior maxillary bone, and is *inserted* into the integument of the chin.

Before proceeding to examine the maxillary group, it would be desirable to dissect the three small muscles belonging to the external ear. For this purpose a square of integument should be removed from around it, and the muscles will then be exposed.

The *Attolens aurem* (superior auris), the largest of the three, is a thin triangular plane of muscular fibres *arising*

from the temporal fascia, and *inserted* into the upper part of the concha of the ear.

The *Attrahens aurem* (anterior auris) *arises* from the temporal fascia immediately above the zygoma, and is *inserted* into the anterior part of the concha.

The *Retrahens aurem* (posterior auris) *arises* by three or four muscular slips from the mastoid process. They are *inserted* into the posterior surface of the concha.

The remaining group consists of the masticatory muscles. The first of these is the masseter: it has been already exposed by the dissection which has been directed for the other muscles.

The *Masseter* (*μασσαομαι*, to chew,) muscle is composed of two planes of fibres, superficial and deep. The *superficial* layer *arises* from the tuberosity of the superior maxillary bone, and the lower border of the malar bone and zygoma, and passes backwards to be *inserted* into the ramus and angle of the inferior maxilla. The *deep* layer *arises* from the posterior part of the zygoma, and passes forwards to be *inserted* into the upper half of the ramus. This muscle is tendinous and muscular in its structure. It is crossed by the duct of the parotid gland, by the transverse facial artery, and by several branches of the facial nerve.

The *Temporal* muscle is next to be examined. It is covered in by a very dense fascia (temporal fascia) which is attached along the temporal ridge on the side of the skull, extending from the external angular process of the frontal bone to the mastoid portion of the temporal: inferiorly, it is connected to the upper border of the zygoma.

Make an incision along the upper border of the zygoma, for the purpose of separating this fascia from its attachment. Then saw through the zygomatic process of the malar bone, and through the root of the zygoma, near to the meatus auditorius. Draw down the zygoma, and with it the origin of the masseter, and dissect the latter muscle away from the ramus and angle of the inferior maxilla. Now remove the temporal fascia from the rest of its attachment, and the whole of the temporal muscle will be exposed.

It *arises* from the whole length of the temporal ridge, and from the entire surface of the temporal fossa. Its fibres converge to a strong narrow tendon, which is *inserted* into the apex of the coronoid process, and for some way down upon its inner surface.

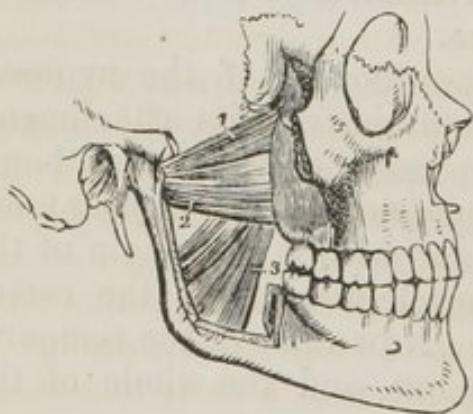By sawing through the coronoid process, near to its base, and pulling it upwards, together with the temporal muscle, which may be dissected from the fossa, we obtain a view of the entire extent of the buccinator muscle.

The *Buccinator* (buccina, a trumpet,) the trumpeter's muscle, *arises* from the alveolar process of the superior and inferior maxillary bones, and from a ligament stretched between the hamular process of the internal pterygoid plate and the extremity of the molar ridge of the lower jaw, the *pterygo-maxillary* ligament. The buccinator, by means of this ligament, is continuous with the superior constrictor of the pharynx. Its fibres converge to be *inserted* into the angle of the mouth, interlacing with the fibres of the orbicularis oris muscle. This muscle is pierced by the duct of the parotid gland opposite the second molar tooth of the upper jaw.

The *External pterygoid* muscle is also seen in this dissection. It *arises* by two heads, *one* from the crest on the greater ala of the sphenoid bone; the *other* from the external pterygoid plate. The fibres pass backwards to be *inserted* into the neck of the lower jaw and inter-articular cartilage.

The internal maxillary artery, as it curves inwards to enter the pterygo-maxillary fossa, is situated between these two heads.

Fig. 34. The two pterygoid muscles. The zygomatic arch and the greater part of the ramus of the lower jaw have been removed in order to bring these muscles into view.



This muscle must now be removed, the ramus of the lower jaw sawn through its lower third, and the head of the bone dislocated from its socket, and withdrawn for the purpose of seeing the pterygoideus internus muscle.

The *Internal pterygoid* muscle *arises* from the pterygoid fossa, and descends obliquely backwards to be *inserted* into the ramus and angle of the

1. The sphenoid origin of the external pterygoid muscle. 2. Its pterygoid origin. 3. The internal pterygoid muscle.

lower jaw: it resembles the masseter very remarkably in its appearance and direction.

ACTIONS.—The occipito-frontalis muscle raises the eyebrows, producing the transverse wrinkles of the forehead. Some persons have the power of moving the entire scalp by means of this muscle. The orbicularis palpebrarum acts as a sphincter in closing the eyelids; the corrugatores supercilio-rem approximate the inner extremities of the eyebrows, and throw the integument at the root of the nose into vertical wrinkles, as in frowning. The tensor tarsi, or lachrymal muscle draws the extremities of the lachrymal ducts inwards, so as to place the puncta in the best position for receiving the tears. It serves also to keep the lids in relation with the surface of the eye, and compresses the lachrymal sac. Dr. Horner is acquainted with two persons who have the voluntary power of drawing the lids inwards by these muscles, so as to bury the puncta in the angle of the eye. The pyramidalis nasi is merely a point of attachment of the occipito-frontalis. It also fixes the expansion of the compressor nasi.

The action of the muscles of the upper lip is expressed in their names. The orbicularis oris is the sphincter of the mouth. The levator labii superioris alæque nasi raises the upper lip, together with the ala of the nose. The depressor labii superioris alæque nasi is the antagonist to this muscle, and draws the upper lip and ala of the nose downwards. The levator labii superioris proprius is the proper elevator of the upper lip, and the levator anguli oris lifts the angle of the mouth. The zygomatic muscles draw the angles of the mouth upwards and outwards, as in laughter.

The muscles of the lower lip are also designated according to their actions: the depressor labii inferioris draws the lower lip downwards, whilst it is carried upwards by the levator labii inferioris, or levator menti. The depressor anguli oris expresses moroseness and grief, by drawing the angle of the mouth downwards.

The muscles of the auricular region possess but little action in man. They are the analogues of important muscles in brutes. Their use is sufficiently explained in their names.

The maxillary muscles are the active agents in mastication, and form an apparatus beautifully fitted for that office. The buccinator muscle circumscribes the cavity of the mouth, and with the aid of the tongue keeps the food under the immediate pressure of the teeth. By means of its connexion with the superior constrictor, it shortens the cavity of the pharynx,

from before backwards, and becomes an important auxiliary is deglutition. The temporal, the masseter, and the internal pterygoid are the bruising muscles, drawing the lower jaw against the upper with very great force. The two latter, by the obliquity of their direction, assist the external pterygoid in grinding the food by carrying the lower jaw forward upon the upper; the jaw being brought back again by the deep portion of the masseter and posterior fibres of the temporal. The whole of these muscles, acting in succession, produce a rotatory movement of the teeth upon each other, which, with the direct action of the lower jaw against the upper, effects the proper mastication of the food.

MUSCLES OF THE NECK.

The *Neck*, as we have before stated, is the medium of *communication* and *connexion* between the head and the trunk of the body.

Connexion is established by means of the integument and sterno-mastoid muscle, the muscles of the prevertebral region, and posterior cervical muscles.

Communication is effected by means of apparatus, connected with respiration and deglutition. Associated with *respiration* is the larynx, and with *deglutition* the os hyoides, the tongue, the soft palate, and the pharynx. These may be considered as the elements of the neck.

The student should commence the dissection of one side of the neck with a view to see the connexions and relations of the muscles. With this object an incision should be made along the middle line of the neck from the chin to the sternum, and bounded superiorly and inferiorly by two transverse incisions; the superior one carried along the margin of the lower jaw, and across the mastoid process to the tubercle on the occipital bone, the inferior one along the clavicle to the acromion process. The square flap of integument thus included should be turned back from the entire side of the neck, which brings into view the superficial fascia.

The *Superficial fascia* consists of two layers, between which is placed the *platysma myoides* muscle. The external layer must, therefore, be reflected from off its fibres, to the same extent with the flap of integument, observing to dissect always in the course of the fibres.

The *Platysma myoides* (πλατυς, μυς, ειδος, broad muscle-like

lamella,) is a thin plane of muscular fibres, *arising* between the two layers of superficial fascia, over the pectoralis major muscle, and passing obliquely upwards and inwards, along the side of the neck, to be *inserted* into the body of the lower jaw, the angle of the mouth, and side of the chin. The anterior fibres are continuous below the chin with the muscle of the opposite side. That portion of the muscle which is continued upwards to the angle of the mouth, was formerly called risorius Santorini* (the laughing muscle of Santorinus). The entire muscle is analogous to the cutaneous muscle of brutes, panniculus carnosus.

Upon removing the platysma, and with it the deep layer of superficial fascia, we bring into view the external jugular vein, and ascending branches of the cervical plexus of nerves. The jugular vein is lying obliquely along the neck, parallel with the fibres of the platysma myoides, while it crosses the direction of the sterno-mastoid muscle.

The sterno-mastoid is as yet concealed from view by a layer of fascia, which covers in the whole of the side of the neck. This is the deep cervical fascia, the reflections of which we have next to examine.

The *Deep cervical fascia* differs in structure from the deep fascia of the limbs, in having no tendinous fibres, and being composed entirely of condensed cellular tissue. It is attached posteriorly along the middle line of the neck to the ligamentum nuchæ, being overlapped by the trapezius muscle. It then passes forwards around the side of the neck to the posterior border of the sterno-mastoid, where it divides into two layers which embrace that muscle, and unite again at its anterior border. It is then directed onwards to the middle line, where it becomes continuous with the deep fascia of the opposite side of the neck. The *anterior layer*, that which is superficial to the sterno-mastoid, is prolonged upwards on the side of the jaw and parotid gland, and downwards over the clavicle and pectoralis major muscle. The *posterior layer*, which can only be examined by removing or drawing aside the sterno-mastoid muscle, is attached superiorly to the styloid process of the temporal bone, and is thence reflected to the angle of the jaw,

* John Dominico Santorinus, Professor of Anatomy in Venice. His notice of this muscle is contained in his "Observations Anatomicæ," published in 1724.

forming the *stylo-maxillary ligament*. Inferiorly it forms a loop, which acts as a pulley to the omo-hyoid muscle, and is then continued downwards behind the clavicle, so as to enclose the subclavius muscle. The extremities of the latter portion are attached firmly to the cartilage of the first rib and to the coracoid process: hence it is named *costo-coracoid membrane* or *ligament*. In the middle line the deep fascia is continuous with the thoracic fascia.

This fascia is of great importance in a surgical point of view. In its normal condition, it binds down firmly all the structures of the neck, and preserves their natural position. When, however, tumours form beneath it, as bronchocele, enlargements of the lymphatic glands, aneurism, &c., the pressure which is then exerted by this membrane may be fatal to the patient, from the compression of the trachea, larynx, and nerves, unless the tension be relieved by an incision.

The *Sterno-cleido mastoid* muscle is to be exposed by opening the sheath formed around it by the deep fascia. It *arises*, as its name implies, from the sternum and clavicle, (*κλειδιον*), and passes obliquely upwards and backwards to be *inserted* into the mastoid process and superior curved line of the occipital bone. The sternal portion arises by a rounded tendon, increases in breadth as it ascends, and spreads out to a considerable extent at its insertion. The clavicular portion is broad and fleshy, and separate from the sternal portion below, but becomes gradually blended with its posterior surface as it ascends.

ACTIONS.—The platysma produces a muscular traction on the integument of the neck, which prevents it from falling so flaccid in old persons as it would if the extension of the skin were the mere result of elasticity. It draws also upon the angle of the mouth. The sterno-mastoid muscles are the great anterior muscles of connexion between the thorax and the head. Both muscles acting together will bow the head directly forwards. The clavicular portions, acting more forcibly than the sternal, give stability and steadiness to the head in supporting great weights. Either muscle acting singly would draw the head towards the shoulder of the same side, and carry the face towards the opposite side.

The anterior border of the sterno-mastoid muscle is the guide for the incisions in ligature of the carotid artery.

The sterno-mastoid may now be removed, by dividing it

through the middle, and turning aside its ends. The upper end will be seen to be pierced by a large nerve, the spinal accessory of the eighth pair. The deep layer of fascia is then to be dissected from off the side of the larynx and trachea, towards the middle line, in order to bring into view the second group of muscles of the neck.

The *Sterno-hyoideus* is a narrow ribband-like muscle, *arising* from the posterior surface of the first bone of the sternum and sterno-clavicular articulation, and from the cartilage of the first rib. It is *inserted* into the body of the os hyoides. The sterno hyoidei are separated by a considerable interval at the root of the neck, but approach each other as they ascend.

The *Sterno-thyroideus*, broader than the preceding, *arises* from the posterior surface of the upper bone of the sternum, and is *inserted* into the oblique line on the ala of the thyroid cartilage.

The *Thyro-hyoideus* is the continuation upwards of the sterno-thyroid muscle. It *arises* from the oblique line on the thyroid cartilage, and is *inserted* into the body and great cornu of the os hyoides.

The *Omo-hyoideus* ($\omega\mu\omicron\varsigma$, shoulder,) passes obliquely across the neck from the scapula to the os hyoides. It *arises* from the upper border of the scapula, and from the transverse ligament of the supra-scapular notch, and is *inserted* into the body of the os hyoides. It is a double-bellied muscle, its extremities being muscular, and the middle a rounded tendon. The tendon glides through a loop formed by the posterior layer of the deep fascia, which serves it as a pulley.

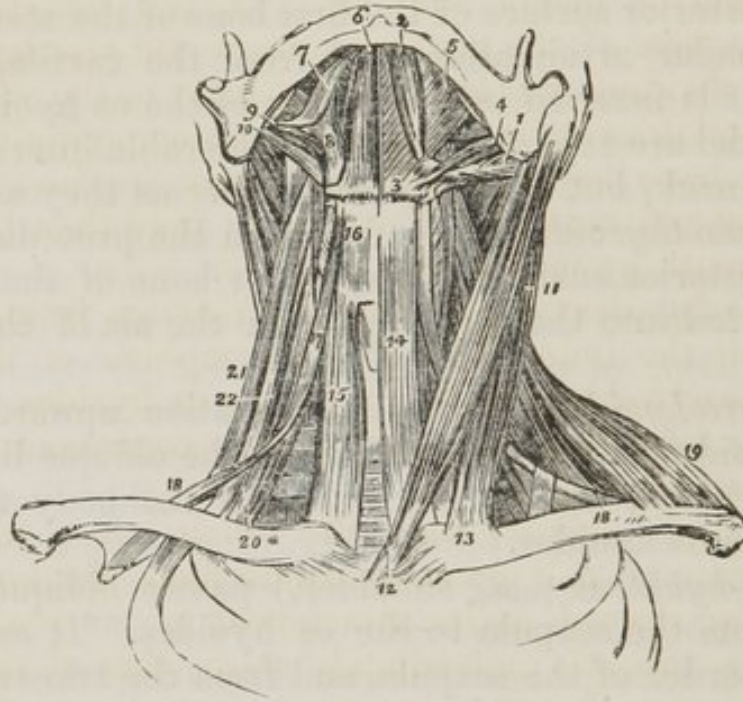
ACTIONS.—The four muscles of this group are the depressors of the os hyoides and larynx. The three former drawing these parts downwards in the middle line, and the two omo-hyoidei regulating their traction to the one or other side of the neck, according to the position of the head.

The following are best dissected by placing a high block beneath the neck, and throwing the head backwards, the integument has been already dissected away, and the removal of the cellular tissue and fat brings them clearly into view.

The *Digastricus* ($\delta\iota\varsigma$, twice, $\gamma\alpha\sigma\tau\eta\rho$, belly) is fleshy at each extremity, and tendinous in the middle. It *arises* from the digastric fossa, immediately behind the mastoid process of the temporal bone, and is *inserted* into a depression on the inner

side of the lower jaw, close to the symphysis. The middle tendon is held in connexion with the body of the os hyoides by an aponeurotic loop, through which it plays as through a pulley.

Fig. 35. The muscles of the anterior aspect of the neck; on the left side the superficial muscles are seen, and on the right the deep.



1. The posterior belly of the digastric muscle. 2. Its anterior belly. The aponeurotic pulley, through which its tendon is seen passing, is attached to the body of the os hyoides, 3. 4. The stylo-hyoideus muscle, transfixed by the posterior belly of the digastric. 5. The mylo-hyoideus. 6. The genio-hyoideus. 7. The tongue. 8. The hyo-glossus. 9. The stylo-glossus. 10. The stylo-pharyngeus. 11. The sterno-mastoid muscle. 12. Its sternal origin. 13. Its clavicular origin. 14. The sterno-hyoid. 15. The sterno-thyroid of the right side. 16. The thyro-hyoid. 17. The hyoid portion of the omo-hyoid. 18. 18. Its scapular portion; on the left side, the tendon of the muscle is seen to be bound down by a portion of the deep cervical fascia. 19. The clavicular portion of the trapezius. 20. The scalenus anticus, of the right side. 21. The scalenus posticus.

The *Stylo-hyoideus* is situated in immediate relation with the posterior belly of the digastric muscle, by which it is pierced. It arises from the middle of the styloid process, and is inserted into the body of the os hyoides.

The digastric and stylo-hyoideus must be removed from their connexion with the lower jaw and os hyoides, and turned aside to see the next muscle.

The *Mylo-hyoideus* ($\mu\upsilon\lambda\eta$, mola, *i. e.* attached to the molar

ridge of the lower jaw) is a broad triangular plane of muscular fibres, forming, with its fellow of the opposite side, the inferior wall or floor of the mouth. It *arises* from the molar ridge on the lower jaw, and proceeds obliquely inwards to be *inserted* into the *raphè* of the two muscles and body of the os hyoides.

After the mylo-hyoideus has been examined, it should be cut away from its origin and insertion, and completely removed. The view of the next muscles would also be greatly improved by dividing the lower jaw a little to the side of the symphysis, and drawing it outwards or removing it altogether, if the ramus have been already cut across in dissecting the internal pterygoid muscle. The tongue may then be drawn out of the mouth by means of a hook.

The *Genio-hyoideus* (*γενειοϋ*, the chin) *arises* from a small tubercle upon the inner side of the symphysis of the lower jaw, and is *inserted* into the body of the os hyoides. It is a short prettily formed muscle, very closely connected with the border of the following.

The *Genio-hyo-glossus* (*γενγλωσσα*, the tongue) is a triangular muscle, narrow and pointed at its origin from the lower jaw, broad and fan-shaped at its attachment to the tongue. It *arises* from a tubercle immediately above that of the genio-hyoideus, and spreads out to be *inserted* into the whole length of the tongue, from its base to the apex, and into the body of the os hyoides.

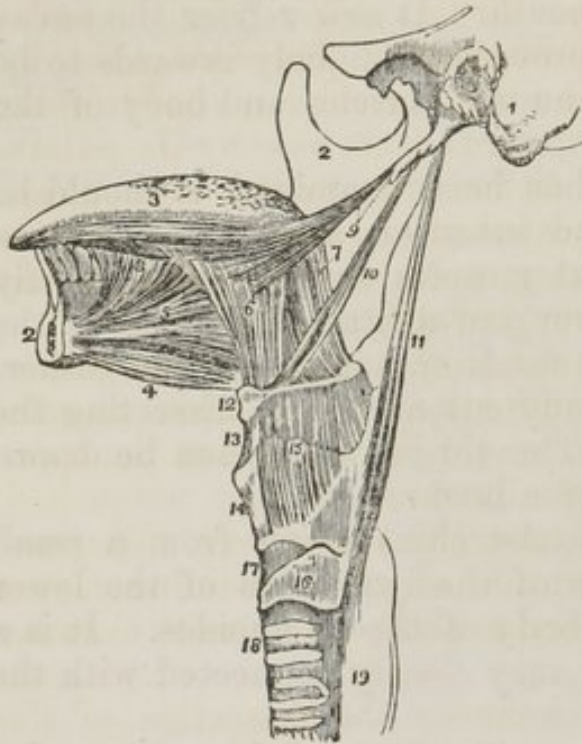
ACTIONS.—The whole of this group of muscles acts upon the os hyoides, when the lower jaw is closed, and upon the lower jaw when the os hyoides is drawn downwards, and fixed by the depressors of the os hyoides and larynx. The genio-hyo-glossus is, moreover, a muscle of the tongue.

The *Hyo-glossus* is a square-shaped plane of muscle, *arising* from the whole length of the great cornu of the os hyoides, and *inserted* into the side of the tongue. This muscle is remarkable from being crossed by two large nerves, the gustatory and lingual, and by the duct (Wharton's) of the submaxillary gland. See *fig.* 40.

The lingual artery and glosso-pharyngeal nerve pass behind it.

The *Lingualis*.—The fibres of this muscle may be seen towards the apex of the tongue, issuing from the space between

Fig. 36. The styloid muscles and the muscles of the tongue.



1. A portion of the temporal bone of the left side of the skull including the styloid and mastoid processes, and the meatus auditorius externus. 2. The right side of the lower jaw, divided at its symphysis; the left side having been removed. 3. The tongue. 4. The genio-hyoideus muscle. 5. The genio-hyo-glossus. 6. The hyo-glossus muscle; its basio-glossus portion. 7. Its cerato-glossus portion. 8. The anterior fibres of the lingualis issuing from between the hyo-glossus and genio-hyo-glossus. 9. The stylo-glossus muscle, with a small portion of the stylo-maxillary ligament. 10. The stylo-hyoid. 11. The stylo-pharyngeus muscle. 12. The os hyoides. 13. The thyro-hyoidean membrane. 14. The thyroid cartilage. 15. The thyro-hyoideus muscle arising from the oblique line on the thyroid cartilage. 16. The cricoid cartilage. 17. The crico-thyroidean membrane, through which the operation of laryngotomy is performed. 18. The trachea. 19. The commencement of the œsophagus.

The *Palato glossus* passes between the soft palate, and the side of the base of the tongue, forming a projection of the mucous membrane, which is called the anterior pillar of the soft palate.

ACTIONS.—The genio-hyo-glossus muscle effects several movements of the tongue, as might be expected from its extent. When the tongue is steadied and pointed by the other muscles, the posterior fibres of the genio-hyo-glossus would dart it from the mouth, while its anterior fibres would restore it to its original position. The whole length of the muscle acting upon the tongue, would render it concave along the

the hyo-glossus and genio-hyo-glossus. It is better examined, however, by removing the preceding muscle. It consists of a small fasciculus of fibres, running from the base longitudinally, where it is attached to the os hyoides, to the apex of the tongue.

The *Stylo glossus* arises from the apex of the styloid process, and from the stylo-maxillary ligament, and is inserted into the side of the tongue, nearly as far as the tip, intermingling its fibres with those of the hyo-glossus.

middle line, and form a channel for the current of fluid towards the pharynx, as in sucking. The apex of the tongue is directed to the roof of the mouth, and rendered convex from before backwards by the *linguales*. The *hyo-glossi*, by drawing down the sides of the tongue, render it convex along the middle line. It is drawn upwards at its base by the *palato-glossi*, and backwards or to either side by the *stylo-glossi*. Thus the whole of the complicated movements of the tongue may be explained, by reasoning upon the direction of the fibres of the muscles, and their probable actions.

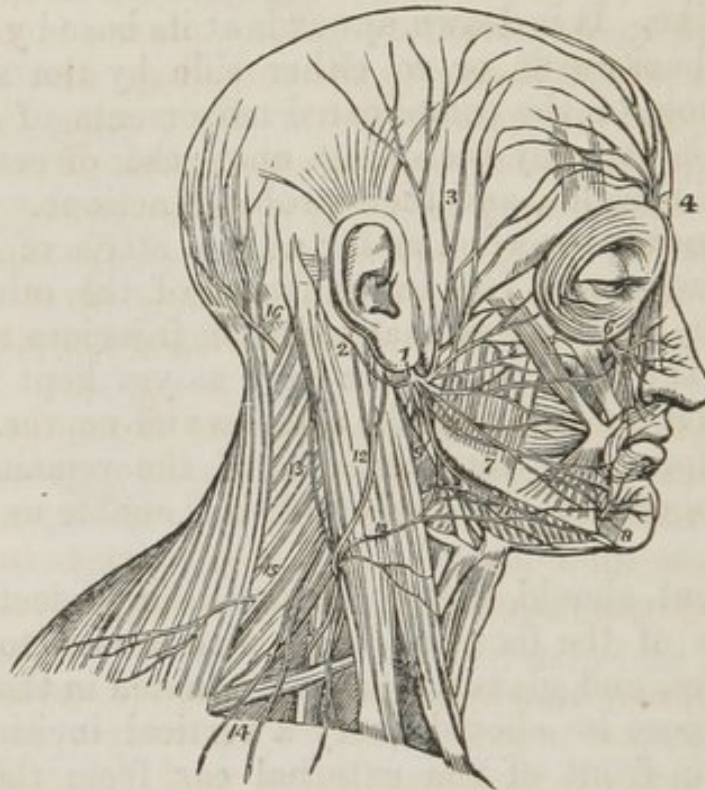
We have now proceeded as far as this stage of the dissection will permit us. The examination of the other muscles will require a preparation that would be injurious to the opposite side of the neck, which we have as yet kept untouched, for the purpose of studying the arteries and nerves. We postpone, therefore, the consideration of the remaining layers until the progress of the dissection shall enable us to examine them.

The student should now commence the dissection of the opposite side of the face and neck, with a view to study the vessels, nerves, and glands which are situated in those regions. For this purpose he should carry a vertical incision directly downwards in front of the external ear from the posterior part of the temple to the angle of the lower jaw; from this draw four transverse incisions, the uppermost along the middle of the forehead to the middle line, another to the angle of the eyelid, a third to the angle of the mouth, and a fourth along the border of the lower jaw to the chin. Then dissect each of these strips of integument carefully away, so as to expose the superficial fascia over the whole of the side of the face.

Immediately in front of the external ear, between it and the ramus of the lower jaw, is the large salivary gland, the *Parotid* (*παρα*, near; *ους, ωτος*, the ear). This gland extends for some little distance over the side of the face, overlapping the masseter muscle. It reaches inferiorly to below the level of the angle of the lower jaw, and posteriorly to the mastoid process, slightly overlapping the insertion of the sterno-mastoid muscle. At its upper extremity near the root of the zygoma, the temporal artery is seen issuing from beneath it; and in front, along its anterior border, the *transversalis faciei*

artery, the excretory duct, and several branches of the facial nerve will be observed.

Fig. 37. The distribution of the facial nerve and the branches of the cervical plexus.



1. The facial nerve, escaping from the stylo-mastoid foramen, and crossing the ramus of the lower jaw; the parotid gland has been removed in order to see the nerve more distinctly. 2. The posterior auricular branch; the digastric and stylo-mastoid filaments are seen near the origin of this branch. 3. Temporal branches, communicating with (4) the branches of the frontal nerve. 5. Facial branches, communicating with (6) the infra orbital nerve. 7. Facial branches, communicating with (8) the mental nerve. 9. Cervico-facial branches, communicating with (10) the superficialis colli nerve, and forming a plexus (11) over the submaxillary gland. The distribution of the branches of the facial in a radiated direction over the side of the face constitutes the pes anserinus. 12. The auricularis magnus nerve, one of the ascending branches of the cervical plexus. 13. The occipitalis minor, ascending along the posterior border of the sterno-mastoid muscle. 14. The superficial and deep descending branches of the cervical plexus. 15. The spinal accessory nerve, giving off a branch to the external surface of the trapezius muscle. 16. The occipitalis major nerve, the posterior branch of the second cervical nerve.

The *duct* of the parotid gland (Stenon's duct) proceeds from the upper part of the gland, and crosses the masseter muscle transversely to its anterior border, where it pierces the buccinator muscle, and opens upon the mucous membrane of

the mouth, opposite the second molar tooth of the upper jaw. A second portion of gland is often developed from the duct, while on the masseter muscle, and is called *socia parotidis*.

If the border of the parotid gland be raised, a plexus of large nerves, branches of the facial (portio dura,) will be seen beneath, and in its structure. This plexus is named from bearing some resemblance to the spreading foot of a palmipede, *pes anserinus* (goose's foot). By tracing the branches back through the gland, we reach the trunk of the nerve, and with a little care it may be exposed as far as the point where it issues from the stylo-mastoid foramen. We must then follow its branches forwards, in the opposite direction. These will be seen to radiate over the side of the temples, face, and upper part of the neck.

The *Facial nerve* (*portio dura*) arises from the upper part of the respiratory tract in the medulla oblongata. It enters the meatus auditorius internus with the auditory nerve (*portio mollis*), and at the bottom of that cavity passes into the canal which is expressly intended for it, the aqueductus Fallopii. In this canal it directs its course at first forwards towards the hiatus Fallopii, where it forms a gangliform swelling, and receives the petrosal branch of the Vidian nerve. It then curves backwards towards the tympanum, and descends along its inner wall to the stylo-mastoid foramen. Emerging at the stylo-mastoid foramen, it passes forwards within the parotid gland, and crossing the external carotid artery to the ramus of the jaw. While situated within the gland, it is joined by a branch from the auricular nerve, and divides into two trunks, which, by their subdivision and communications, form the *pes anserinus*. The *pes anserinus* divides into the numerous branches which supply the muscles over the whole side of the face.

The *Branches* of the *Facial Nerve* are,

<i>Within the aqueductus Fallopii.</i>	{	Tympanic, (Chorda tympani.*)
<i>After emerging at the stylo - mastoid foramen.</i>	{	Communicating, Posterior auricular, Digastric, Stylo-hyoid.

* The chorda tympani is not a branch of the facial, but being in close connexion with it, and being given off from it like a branch, we have inserted it here lest it should be overlooked.

On the face. { Temporal-facial,
 { Cervico-facial.

The *Tympanic* branches are two small filaments, which are distributed to the stapedius and tensor tympani muscles.

The *Chorda tympani* quits the facial nerve just before it emerges from the stylo-mastoid foramen. Entering the tympanum at its posterior and superior angle, it crosses its cavity between the handle of the malleus and long process of the incus, to its anterior inferior angle. It then escapes through the fissura Glaseri, and joins the gustatory nerve at an acute angle between the two pterygoid muscles. Enclosed in the neurilema* of the gustatory nerve, it descends to the submaxillary gland, where it unites with the submaxillary ganglion. It is a branch of the fifth pair.

The *Communicating branches* are filaments which it receives from the glosso-pharyngeal and pneumogastric nerves.

The *Posterior auricular* nerve ascends behind the ear, and crosses the mastoid process to the occipito-frontalis muscle; it gives branches also to the attolens and retrahens muscles of the pinna.

The *Digastric* branch supplies the posterior belly of the digastric muscle.

The *Stylo-hyoid* branch is distributed to the stylo-hyoid muscle. The facial nerve then enters the parotid gland, and divides into its two ultimate trunks—temporo-facial and cervico-facial.

The *Temporo facial* gives off a number of branches which are distributed over the temple and upper half of the face, supplying the muscles of this region, and communicating with the branches of the supra-orbital nerve. The inferior branches, which accompany Stenon's duct, form a plexus with the terminal branches of the infra-orbital nerve.

The *Cervico-facial* divides into a number of branches that are distributed to muscles on the lower half of the face, and upper part of the neck. The cervical branches form a plexus (*fig. 38. 11.*) with the superficialis colli nerve over the submaxillary gland.

The *Facial nerve* has been named *sympatheticus minor*, on account of the number of communications which it maintains

* No proof of this independent relation of the chorda tympani to the gustatory nerve has yet been afforded by anatomy; and recent physiological discoveries throw much doubt over the question.

with other nerves. These will be best seen in a tabular arrangement:—

<i>In the petrous bone it communicates with</i>	{	Auditory nerve, Petrosal branch of Vidian, Otic Ganglion.
<i>At its exit from the stylo-mastoid foramen, with</i>	{	Glosso-pharyngeal, Pneumogastric.
<i>In the parotid gland with</i>	{	Auricular of the inferior maxillary, Auricularis magnus, Occipitalis minor.
<i>On the face and neck with</i>	{	Supra-orbital, Infra-orbital, Temporo-malar of the superior maxillary, Buccal, Mental, Superficialis colli.

From the supra-orbital, infra-orbital, and mental foramina, will be found issuing the terminal branches of the fifth nerve distributed to the face. They form plexuses of communication with branches of the facial nerve.

Ascending obliquely across the face from the anterior inferior angle of the masseter muscle to the angle of the eye, is the *facial artery*: and descending along the anterior border of the masseter to join the artery, as it crosses the border of the jaw, is the *facial vein*.

The *Integument*, which has already been partly removed from the neck, may now be dissected back altogether, bounding it by an incision made along the line of the clavicle. The *superficial fascia* is next to be removed, and with it the *platysma myoides*, noting the direction in which its fibres run. The *deep fascia* is thus brought into view, extending from the border of the trapezius to the middle line on the front of the neck. In relation with this fascia on the side of the neck, are certain parts which demand the student's especial attention: they are,—the external jugular vein, the ascending branches of the cervical plexus, viz:—Superficialis colli, Auricularis magnus, Occipitalis minor, Sterno-mastoid muscles.

The external jugular vein lies upon the deep fascia.

The nerves lie partly between the two layers of the deep fascia, and partly superficial to them.

The muscle is between the two layers, being the cause of their separation.

The *External jugular vein* (fig. 38. 8.) is the superficial venous trunk of the neck; it receives the returning blood from the exterior of the side of the head, being formed by the Temporal vein, Internal maxillary, Posterior auricular, and near to the clavicle is joined by cutaneous veins from the back of the neck. Immediately beneath the parotid gland it communicates with the internal jugular vein.

COURSE.—Emerging from the parotid gland in which it lies imbedded, it descends somewhat obliquely along the side of the neck, and behind the clavicle to the subclavian vein.

RELATIONS.—It lies upon the sheath of the sterno-mastoid muscle for nearly its whole course, being placed for a short space to its anterior border above, and upon its posterior border below. It is accompanied by the auricularis magnus nerve, and is covered by the platysma muscle, enclosed between the two layers of superficial fascia.

The next step in the dissection is to open the sheath of the sterno-mastoid muscle, and carefully trace the three ascending branches of the cervical plexus to their destination.

The *Superficialis colli* (fig. 38. 11.) pierces the fascia at the anterior border of the muscle, and ascends obliquely towards the lower jaw, beneath which it forms a plexus with the cervico-facial branches of the facial nerve. It is distributed to the integument on the front of the neck.

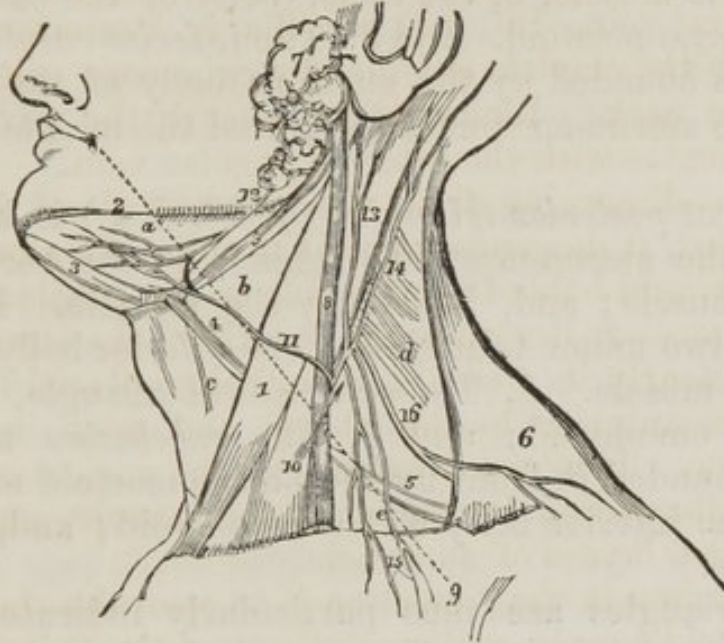The *Auricularis magnus* (fig. 38. 13.,) the largest of the three, pierces the fascia, and accompanies the external jugular vein. It is distributed to the integument over the parotid gland, and to the external ear, and communicates with the facial nerve.

The *Occipitalis minor* (fig. 38. 14.) ascends along the posterior border of the sterno-mastoid muscle, and is distributed to the integument of the occiput.

Having learned the jugular vein and ascending nerves of the cervical plexus, attention must now be directed to the sterno-mastoid muscle, from which the fascia should be removed so as to expose its entire length. The fascia should also be dissected from the whole of the rest of the neck, both

before and behind the sterno-mastoid, so as to enable us to examine the deep parts as an entire layer. Behind the sterno-mastoid some difficulty will arise in the dissection, from the number of branches given off by the cervical plexus.

Fig. 38. The triangles of the neck, with the external jugular vein and ascending branches of the cervical plexus.



1. The sterno-mastoid muscle, which divides the side of the neck into two great triangles, the anterior and posterior. *a.* The submaxillary triangle. *b.* The superior carotid triangle. *c.* The inferior carotid triangle. *d.* The sub-occipital triangle. *e.* The subclavian triangle. 2. The border of the lower jaw. 3. 3. The digastric muscle. 4. The superior belly of the omohyoid muscle. 5. Its inferior belly. 6. The trapezius muscle. 7. The parotid gland. 8. The external jugular vein. 9. A dotted line, marking the direction of the fibres of the platysma myoides muscle. 10. A small arrow, showing the direction of the incision for opening the jugular vein. 11. The superficialis colli nerve, which forms a plexus with (12.) a branch from the facial nerve, over the submaxillary triangle. 13. The auricularis magnus nerve. 14. The occipitalis minor. 15. The descending superficial branches of the plexus. 16. The spinal accessory nerve.

When this preparation has been entirely completed, the side of the neck will present a pretty regular square;—bounded above by the margin of the lower jaw and occiput, below by the clavicle, in front by the middle line of the neck, and behind by the vertebral column. The sterno-mastoid muscle (*fig. 38. 1.*) extends diagonally across this space, from the anterior inferior to the posterior superior angle, and divides it into two triangles of nearly equal size, the great anterior and the great posterior triangle.

The *Great anterior triangle* (*fig. 38, a, b, c.*) is bounded

above by the body of the lower jaw; in front, by the middle line of the neck; and, behind, by the sterno-mastoid muscle. It is subdivided into three minor triangles:—1. The *submaxillary* triangle, *a*, formed by the two bellies of the digastric muscle, 3, 3, and the border of the lower jaw, 2. 2. The *superior carotid* triangle, *b*, formed by the posterior belly of the digastric muscle, 3, the upper belly of the omo-hyoid, 4, and the sterno-mastoid. And 3. The *inferior carotid* triangle, *c.*, which is bounded by the superior belly of the omo-hyoid muscle, the sterno-mastoid muscle, and the middle line of the neck.

The *Great posterior triangle* (*fig. 38. d, e.*) is bounded, in front, by the sterno-mastoid; behind, by the border of the trapezius muscle; and, below, by the clavicle. It is subdivided into two minor triangles by the inferior belly, 5. of the omo-hyoid muscle. 1. The *suboccipital* triangle, *d*, situated above the omo-hyoid; and 2. The *subclavian* triangle, *e*, which is bounded in front by the sterno-mastoid muscle; behind, by the inferior belly of the omo-hyoid; and, below, by the clavicle.

These triangles are thus particularly indicated, because they contain certain important parts; for instance, the *Submaxillary* triangle, *a.*, contains in the posterior half of its area the submaxillary gland in which the facial artery lies embedded, while it conceals from view the commencement of Wharton's duct, the gustatory nerve, and the submaxillary ganglion. The anterior angle is occupied by the mylo-hyoideus muscle, the submental branch of the facial artery, and the mylo-hyoidean nerve. And in the inferior angle may be observed a small portion of the lingual nerve.

The *Submaxillary gland* is situated in the posterior angle of the submaxillary triangle of the neck. It rests upon the hyo-glossus and mylo-hoideus muscles, and is covered in by the body of the lower jaw and by the deep cervical fascia. It is separated from the parotid gland by the stylo-maxillary ligament, and from the sublingual by the mylo-hyoideus muscle.

Embedded amongst its lobules is the facial artery and the submaxillary ganglion.

The *Excretory duct* (Wharton's) of the submaxillary gland, passes obliquely forwards behind the mylo-hyoideus muscle, and resting upon the hyo-glossus to the papilla, situated at

each side of the frænum linguæ. It is in contact throughout its course with the mucous membrane of the floor of the mouth.

The *Sublingual gland* is situated beneath the mucous membrane of the floor of the mouth, on each side of the frænum linguæ.

It is in relation, *above*, with the mucous membrane; *in front*, with the depression on each side of the symphysis of the lower jaw; *externally*, with the mylo-hyoideus muscles, and *internally*, with the lingual nerve and genio-hyo-glossus muscle.

It pours its secretion into the mouth by seven or eight small ducts, which open upon the mucous membrane on each side of the frænum linguæ.

2. The *Superior carotid triangle*, *b.*, contains the upper portion of the common carotid artery, and its bifurcation into the external and internal carotids; the superior thyroid and the commencement of the lingual and facial arteries; the internal jugular vein and a chain of lymphatic glands; the descendens noni nerve in front of the sheath of the carotid, the pneumogastric within, and the superior laryngeal and sympathetic behind. Crossing the upper angle is the lingual nerve.

3. In the *Inferior carotid triangle*, *c.*, are found the lower part of the common carotid artery and jugular vein, descendens noni, pneumogastric and sympathetic nerves, and recurrent laryngeal nerve.

4. The *Suboccipital triangle*, *d.*, contains the suboccipital nerve at its upper angle, and the spinal accessory nerve and branches of the cervical plexus below.

5. The *Subclavian triangle*, *e.*, contains the termination of the external jugular vein, the third part of the course of the subclavian artery, and the brachial plexus of nerves, and is crossed by the posterior scapular artery.

We would not counsel the student to learn up the contents of these triangles by rote; the notice of their contents is meant chiefly for the dissector, who, in reading each structure, should seek for it in its appropriate place. The names of the regions carry with them the best idea of their principal features, and these the least attentive learner cannot fail of recollecting. The use of a good knowledge of the triangular

space is its application to the operations for ligature of the arteries of the neck.

VESSELS OF THE NECK.

Divide the sterno-mastoid muscle through its middle, and turn aside the ends; the upper extremity will be seen to be pierced by the spinal accessory nerve. Then dissect off the posterior layer of the deep fascia, and the sheath of the carotid vessels will be exposed throughout its entire extent. Lying upon the sheath, and forming a loop at about its middle, is a long slender nerve, the descendens noni. Open the sheath, and it will be found to contain the carotid artery, jugular vein, and pneumogastric nerve. Behind it is the recurrent laryngeal, and sympathetic nerve. Dissect the cellular tissue and lymphatic glands, which are numerous in the course of the jugular vein, from around the vessels, for the purpose of examining them and their relations more satisfactorily.

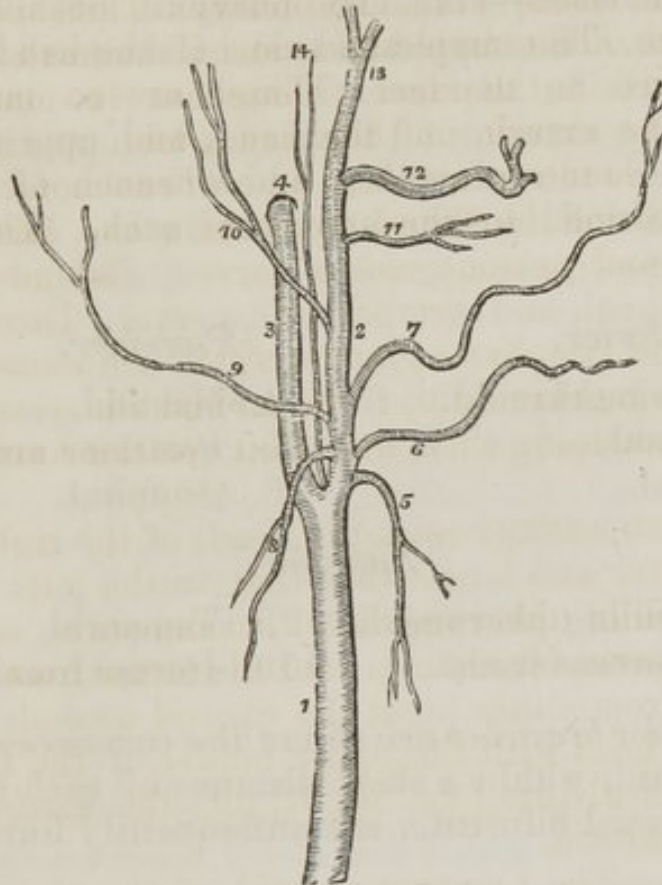
The CAROTID ARTERY (*καρὰ*, the head) of the right side (*fig. 42. 8.*) is shorter and larger than that on the left: the former being a branch of the innominata, commences opposite the right sterno-clavicular articulation, the latter from the arch of the aorta. From either point the carotid ascends the side of the neck to a level with the upper border of the thyroid cartilage, where it divides (*fig. 40. 7.*) into the external carotid and internal carotid.

RELATIONS.—The *Common carotid* of the *right* side rests, first, upon the longus colli muscle, then upon the rectus anticus major, the sympathetic nerve being interposed. The inferior thyroid artery and recurrent laryngeal nerve pass behind it at its lower part. To its *inner side* is the trachea, recurrent laryngeal nerve, and larynx: to its *outer side* the jugular vein and pneumogastric nerve; and *in front* the sterno-thyroid, sterno-mastoid, omo-hyoid and platysma muscles, and the descendens noni nerve.

The *Left carotid* (*fig. 42. 9.*) is smaller than the right, and more deeply seated. In addition to the relations just enumerated, which are common to both, it is crossed near its commencement by the left vena innominata; lies upon the trachea: then gets to its side, and is in relation with the œsophagus and thoracic duct.

The **EXTERNAL CAROTID ARTERY** (*fig. 40.*) ascends perpendicularly from opposite the upper border of the thyroid cartilage, to the space between the neck of the lower jaw and the meatus auditorius.

Fig. 39. The carotid arteries with the branches of the external carotid.



1. The common carotid. 2. The external carotid. 3. The internal carotid. 4. The carotid foramen in the petrous portion of the temporal bone. 5. The superior thyroid artery. 6. The lingual artery. 7. The facial artery. 8. The mastoid artery. 9. The occipital. 10. The posterior auricular. 11. The transverse facial artery. 12. The internal maxillary. 13. The temporal. 14. The ascending pharyngeal artery.

RELATIONS.—*In front* it is crossed by the posterior belly of the digastricus and stylo-hyoideus and platysma myoides muscles; by the lingual nerve (*fig. 40. 21.*) near its origin; and higher up, where it is situated in the substance of the parotid gland, by the facial nerve. *Behind*, it is separated from the internal carotid by the stylo-pharyngeus and stylo-glossus muscles, glosso-pharyngeal nerve, 20., and part of the parotid gland.

The *External carotid* artery is intended for the supply of

the organs in the neck and the external part of the head. If we reflect upon what these organs and parts should be, we shall find, that taking them in succession, from below upwards, they are, *in front*—1st. The thyroid gland and larynx. 2d. The tongue. 3d. The surface of the face. *Behind*—4th. The mastoid muscle. 5th. The external ear. 6th. The occiput. And *above*—7th. The pharynx. 8th. The side of the face. 9th. The temple and side of the head; and 10th. The deep parts in the face. These are so many arterial regions on the exterior of the head, and upper part of the neck: They are ten in number, and a branch of the external carotid is destined to the supply of each. The branches, therefore, are—

<i>Anterior.</i>	<i>Posterior.</i>
1. Superior thyroid.	4. Mastoid.
2. Lingual.	5. Posterior auricular.
3. Facial.	6. Occipital.
<i>Superior.</i>	
7. Ascending pharyngeal.	9. Temporal.
8. Transverse facial.	10. Internal maxillary.

The *Anterior branches* arise from the commencement of the external carotid, within a short distance of each other. The lingual and facial bifurcate, not unfrequently form a common trunk.

I. The *Superior thyroid artery* (*fig. 40. 8.*) descends to the thyroid gland to which it is distributed, anastomosing with its fellow of the opposite side, and with the inferior thyroid arteries. Its branches are—

- (1.) SUPERIOR THYROID.—*Branches.*
- | | |
|------------|-----------|
| Hyoid, | Muscular. |
| Laryngeal, | |

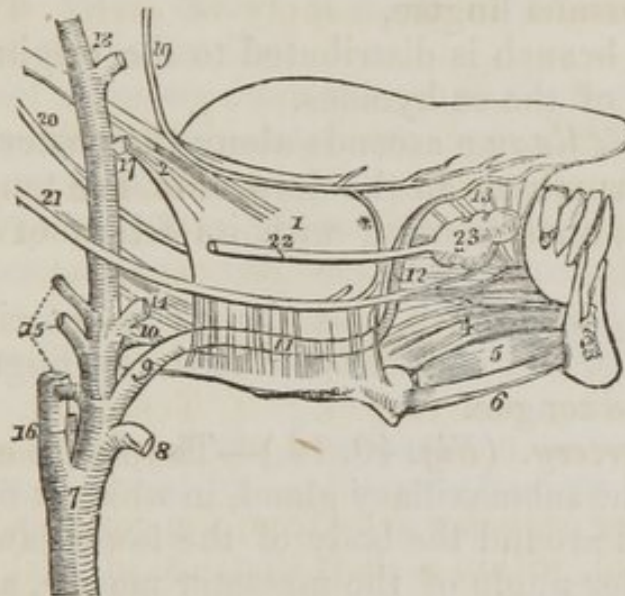The *Hyoid* branch is distributed to the insertion of the depressor muscles into the os hyoides.

The *Laryngeal* pierces the thyro-hyoidean membrane, in company with the superior laryngeal nerve, and supplies the mucous membrane and muscles of the larynx.

The *Muscular* branch is distributed to the depressor muscles of the os hyoides and larynx.

2. *Lingual artery*:—1st. Crosses obliquely (*fig. 40. 9.*) the great cornu of the os hyoides. 2d. It passes forwards parallel, 11., with the upper border of the os hyoides. 3d. Ascends, 12., to the under surface of the tongue; and 4th. Runs forward in a serpentine direction to its tip, under the name of *ranine* artery. 13. Its course is thus divided into four parts, and the relations of each are to be studied separately, with a view to operations on the artery in any part of its course.

Fig. 40. The anatomy of the side of the tongue, with the relations of the vessels and nerves.



1. The *hyo-glossus* muscle, arising from the side of the os hyoides below, and inserted into the side of the tongue, where it mingles its fibres with those of the *stylo-glossus* muscle. 2. 3. A section of the lower jaw at the symphysis. 4. The *genio-hyo-glossus* muscle. 5. The *genio-hyoideus* muscle. 6. The cut edge of the *mylo-hyoideus*. 7. The common carotid artery, dividing into the external and internal carotid. 8. The trunk of the superior thyroid artery. 9. The *lingual artery*; the first or oblique portion of its course, resting upon the great cornu of the os hyoides, and upon (10) the middle constrictor muscle. 11. The second, or horizontal portion of the *lingual artery*; its course beneath the *hyo-glossus* muscle it marked by dotted lines. 12. The third, or perpendicular portion of the *lingual artery*. 13. Its termination, the *ranine* artery. 14. The trunk of the *facial artery*. 15. The three posterior branches of the external carotid artery; they are from below, upwards, the *mastoid*, *occipital*, and *posterior auricular*. 16. The trunk of the *ascending pharyngeal artery*. 17. The trunk of the *transverse facial artery*. 18. The two terminal branches of the external carotid, the *internal maxillary* and *temporal*. 19. The *gustatory branch* of the fifth nerve. * Its communication with the *lingual nerve*. 20. The *glossopharyngeal nerve*. 21. The *lingual, or hypoglossal nerve*. 22. *Wharton's duct*. 23. The *sublingual gland*.

RELATIONS.—The *first* part of its course, 9., rests upon the

great cornu of the os hyoides, and the origin of the middle constrictor muscle, 10., of the pharynx; the *second*, 11., is situated between the middle constrictor and hyo-glossus muscles, the latter separating it from the lingual nerve, 21. In the *third* part of its course, 12., it lies between the hyo-glossus and genio-hyo-glossus, 4., and in the *fourth*, 13. (ranine,) rests upon the lingualis to the tip of the tongue. Its branches are,—

(2.) LINGUAL ARTERY.—*Branches.*

Hyoid,	Sublingual.
Dorsalis linguæ,	

The *Hyoid* branch is distributed to the origins of the elevator muscles of the os hyoides.

The *Dorsalis linguæ* ascends along the posterior border of the hyo-glossus muscle to the dorsum of the tongue, where it is distributed, anastomosing with its fellow of the opposite side.

The *Sublingual* branch runs along the anterior border of the hyo-glossus, and is distributed to the sublingual gland and muscles of the tongue.

3. *Facial artery.* (*Fig.* 40. 14.)—The *facial artery* ascends obliquely to the submaxillary gland, in which it lies embedded. It then curves around the body of the lower jaw, close to the anterior inferior angle of the masseter muscle, ascends to the angle of the mouth, and thence to the angle of the eye, where it is named the *angular artery*.

RELATIONS.—Below the jaw it passes beneath the digastricus and stylo-hyoid muscles, and at the angle of the mouth beneath the zygomatic muscles.

Its *branches* are divided into those which are given off below the jaw and those on the face: they may be thus arranged,—

(3.) FACIAL ARTERY.—*Branches.*

Below the jaw.

Inferior palatine,	Sub-mental.
Submaxillary,	

On the face.

Masseteric,	Superior coronary,
Inferior labial,	Lateralis nasi.
Inferior coronary,	

The *inferior palatine* branch ascends between the styloglossus and stylo-pharyngeus muscles, to be distributed to the tonsil and soft palate.

The *Submaxillary* are the numerous small branches supplying the submaxillary gland.

The *Sub-mental* branch runs forwards upon the mylo-hyoid muscle, under cover of the body of the lower jaw, and anastomoses with branches of the sublingual and inferior dental arteries.

The *Masseteric* branch is distributed to the masseter and buccinator muscles.

The *Inferior labial* branch is distributed to the muscles and integument of the lower lip.

The *Inferior coronary* runs along the edge of the lower lip, close to the mucous membrane, and inosculates with the corresponding artery of the opposite side.

The *Superior coronary* follows the same course along the upper lip, inosculating with the opposite superior coronary artery.

The *Lateralis nasi* is distributed to the ala and septum of the nose.

The *Inosculations* of the facial artery are very numerous: thus it anastomoses with the sublingual branch of the lingual, with the inferior dental as it escapes from the mental foramen, infra-orbital at the infra-orbital foramen, transverse facial on the side of the face, and at the angle of the eye with the nasal branch of the ophthalmic artery.

The *Posterior branches* of the external carotid (*fig. 40, 15.*) viz., the mastoid, posterior auricular, and occipital, are next to be dissected and studied.

4. The *Mastoid artery* turns downwards to be distributed to the sterno-mastoid muscle; sometimes it is replaced by two small branches.

5. The *Posterior auricular artery* ascends beneath the lower border of the parotid gland, and behind the concha, to be distributed to the external ear and side of the head, anastomosing with the occipital and temporal arteries: some of its branches pass through the fissures in the fibro-cartilage, to be distributed to the anterior surface of the pinna. The anterior auricular arteries are branches of the temporal.

BRANCHES.—The posterior auricular gives off but one named

branch, the *stylo-mastoid*, which enters the stylo-mastoid foramen to be distributed to the aqueductus Fallopii and tympanum.

6. The *Occipital artery* passes backwards beneath the posterior belly of the digastricus, the trachelo-mastoid, and sterno-mastoid muscles, to the occipital groove in the mastoid portion of the temporal bone. It then ascends between the splenius and complexus muscles, and is distributed upon the occiput, anastomosing with the posterior auricular and temporal arteries.

BRANCHES.—It gives off only two branches, inferior meningeal and princeps cervicis.

The *Inferior meningeal* ascends by the side of the internal jugular vein, and passes through the foramen lacerum posterius to be distributed to the dura mater.

The *Arteria princeps cervicis* is a large but irregular branch. It descends the neck between the complexus and semi-spinalis colli, and inosculates with the profunda cervicis of the subclavian. This branch is the means of establishing a very important collateral circulation between the branches of the carotid and subclavian, in ligature of the common carotid artery.

The *Superior branches* have now to be examined and traced throughout their course; we must commence with the two superficial arteries, the deeper ones requiring an especial dissection.

7. The *Transversalis faciei* (*fig. 40. 17.*) arises from the external carotid whilst that trunk is lodged within the parotid gland; it crosses the masseter muscle in company with Stenon's duct, and is distributed to the muscles and integument on the side of the face.

8. The *Temporal artery* (*fig. 40. 18.*) is one of the two terminal branches of the external carotid. It ascends over the root of the zygoma, and divides into three branches:—1st. *Anterior temporal*, which is distributed on the front of the temple and arch of the skull, anastomosing with the supra-orbital branch of the ophthalmic artery. 2. *Posterior temporal*, which passes towards the back of the head, anastomosing with the posterior auricular and occipital arteries. And 3. *Middle temporal*, which pierces the fascia, and supplies the temporal muscle.

BRANCHES.—While resting upon the zygoma, the temporal artery gives off several branches to the external ear, the *anterior auricular arteries*.

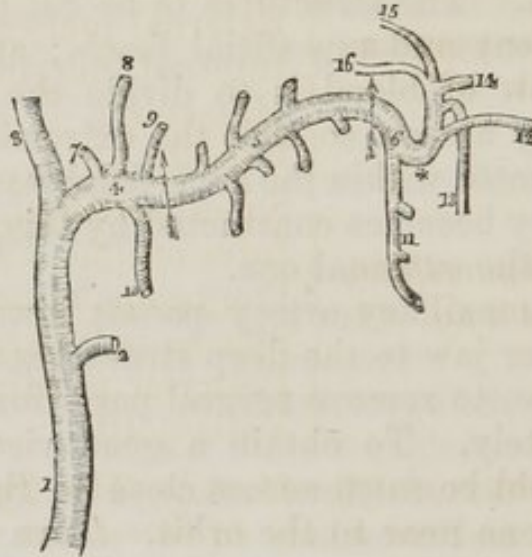
It is sometimes necessary to open the temporal artery for the purpose of producing a powerful effect upon the system; in this case, the more prominent of the two superficial vessels should be chosen. The structures to be cut through are simply the integument and superficial fascia; and the mode of arresting the flow of blood is to divide the cylinder of the artery completely across, so that the extremities of the vessels may be retracted within the superficial fascia. The middle coat of the artery becomes contracted by this proceeding, and is drawn within the external one.

The internal maxillary artery passes inwards behind the neck of the lower jaw to the deep structures in the face; we require, therefore, to remove several parts for the purpose of seeing it completely. To obtain a good view of the vessel, the zygoma should be sawn across close to the external ear, and the malar bone near to the orbit. Turn down the zygomatic arch with the masseter muscle. In doing this, a small artery and nerve will be seen crossing the sigmoid arch of the lower jaw, and entering the masseter muscle (the *masseteric*.) Cut away the tendon of the temporal muscle from its insertion into the coronoid process, and turn it upwards towards its origin: some vessels will be seen entering its under surface; these are the *deep temporal*. Then saw the ramus of the jaw across its middle, and dislocate it from its articulation with the temporal bone. Be careful in doing this to carry the blade of the knife close to the bone, lest any branches of nerves should be injured. Next remove this portion of bone, and with it the external pterygoid muscle. The artery, together with the deep branches of the inferior maxillary nerve, will be seen lying upon the internal pterygoid. These are to be carefully freed of fat and cellular tissue, and then examined.

10. The *Internal maxillary artery* (*fig. 40. 18. fig. 41. 4.*) is one of the two terminal branches of the external carotid. Commencing in the substance of the parotid gland, opposite the meatus auditorius externus, it *first* passes horizontally behind the neck of the lower jaw, *next* obliquely upwards between the two pterygoid muscles; it *then* bends suddenly into the pterygo-maxillary fossa. Its course is thus resolved into three

portions—1. That situated behind the neck of the jaw, the *maxillary portion*, 4.; 2. That between the pterygoid muscles, *muscular portion*, 5.; and 3. Its bend into the pterygo-maxillary fossa, *pterygo-maxillary portion*, 6.

Fig. 41. The internal maxillary artery, with its branches.



1. The external carotid artery. 2. The trunk of the transverse facial artery. 3. 4. The two terminal branches of the external carotid. 3. The temporal artery; and 4. The internal maxillary, the first or *maxillary portion* of its course: the limit of this portion is marked by an arrow. 5. The second, or *muscular portion*, of the artery; the limits are bounded by the arrows. 6. The third, or *pterygo-maxillary portion*. The branches of the maxillary portion are, 7. A tympanic branch. 8. The arteria meningea media. 9. The arteria meningea parva. 10. The inferior dental artery. The branches of the second portion are wholly muscular, the ascending ones being distributed to the temporal, and the descending to the four other muscles of the inter-maxillary region, viz. the two pterygoids, the masseter and buccinator. The branches of the pterygo-maxillary portion of the artery are, 11. The superior dental artery. 12. The infra-orbital artery. 13. The posterior palatine. 14. The sphenopalatine, or nasal. 15. The pterygo-palatine. 16. The Vidian. * The remarkable bend which the third portion of the artery makes as it turns inwards to enter the pterygo-maxillary fossa.

RELATIONS.—The *maxillary* portion is situated between the ramus of the jaw and internal lateral ligament, lying parallel to the auricular nerve: the *pterygoid* portion between the two pterygoid muscles, crossing the gustatory and dental nerves. It then makes a remarkable bend (*fig. 41.**) which projects between the two heads of the external pterygoid muscle, and passes directly inwards to the pterygo-maxillary fossa, where it divides into its terminal branches.

INTERNAL MAXILLARY ARTERY.—*Branches.*

<i>Maxillary portion</i> (fig. 41. 4.)	{ Tympanic, 7., Inferior dental, 10., Arteria meningea media, 8., Arteria meningea parva, 9.
<i>Muscular portion</i> (fig. 41. 5.)	{ Deep temporal branches, External pterygoid, Internal pterygoid, Masseteric, Buccal.
<i>Pterygo-maxillary portion</i> (fig. 41. 6.)	{ Superior dental, 11., Infra-orbital, 12., Pterygo-palatine, 15., Spheno-palatine, 14., Posterior palatine, 13., Vidian, 16.

MAXILLARY PORTION (fig. 41. 4.)—The *Tympanic* branch, 7. is very small, and not likely to be seen in an ordinary dissection; it passes into the tympanum through the fissura Glaseri.

The *Inferior dental*, 10, descends to the dental foramen, and enters the canal of the lower jaw in company with the dental nerve. At the chin it escapes with the nerve from the mental foramen, and anastomoses with the inferior labial and submental branches of the facial. It supplies the teeth of the lower jaw, sending small branches along the canals in their roots.

The *Arteria meningea media*, 8., is the great artery of the dura mater. It passes between the roots of the dental nerve, and through the foramen spinosum in the spinous process of the sphenoid, to the deep groove at the anterior inferior angle of the parietal bone. It divides into several branches, which ramify upon the external surface of the dura mater, and anastomose with corresponding branches from the opposite side.

The *Meningea parva*, 9, is a small branch which ascends to the foramen ovale, and passes into the skull to be distributed to the dura mater.

MUSCULAR PORTION (fig. 44. 5.)—The distribution of the muscular branches is implied in their names, supplying the five muscles of the temporo-maxillary region.

PTERYGO-MAXILLARY PORTION (*fig. 41. 6.*)—The branches of this portion of the artery cannot be seen at the present stage of the preparation; they must be left until the dissection has proceeded more deeply.

The *Superior dental* branch, 11, is given off from the artery, just as it makes its remarkable bend* inwards. It passes down upon the posterior surface of the superior maxillary bone, and sends its branches through several small foramina to supply the posterior teeth of the upper jaw.

The *Infra-orbital*, 12, would appear, from its size, to be the proper continuation of the artery. It is, however, more convenient to consider it simply as a branch. It runs along the infra-orbital canal with the superior maxillary nerve, sending branches downwards through canals in the bone, to supply the mucous lining of the antrum and teeth of the upper jaw, and escapes from the infra-orbital foramen, inosculating with the facial and transverse facial arteries.

The *Pterygo-palatine*, 15., is a small branch which passes through the pterygo-palatine canal, and supplies the upper part of the pharynx.

The *Spheno-palatine*, 14., or nasal, enters the spheno-palatine foramen with the nasal branches of Meckel's ganglion, and is distributed to the mucous membrane of the nares.

The *Posterior palatine* branch, 13., descends along the posterior palatine canal, in company with the posterior palatine branches of Meckel's ganglion. It is distributed to the palate.

The *Vidian branch*, 16., passes backwards along the pterygoid canal, and is distributed to the sheath of the Vidian nerve.

The external carotid artery should now be divided near its origin, and drawn upwards, or removed altogether. The ramus of the jaw should also be sawn across, and dissected away from the insertion of the internal pterygoid muscle and pterygo-maxillary ligament, in order to bring into view the side of the pharynx. The rest of the parotid gland may then be removed from its situation, and its deep relations attentively observed. We shall thus be enabled to trace the course of the remaining branch of the external carotid artery, and see the relations of the internal carotid.

The *Ascending pharyngeal artery* (*fig. 40. 16.*) arises from the external carotid, near to its bifurcation, and as-

cends by the side of the pharynx to the base of the skull, where it divides into branches which enter the foramina in that region, to be distributed to the dura mater. It supplies the pharynx.

The INTERNAL CAROTID ARTERY ascends perpendicularly from its bifurcation, opposite the upper border of the thyroid cartilage, to the carotid foramen in the petrous bone. It then curves inwards along the carotid canal, passes forwards by the side of the sella turcica, and at the anterior clinoid process pierces the dura mater and divides into three branches. Its course is naturally divided into four portions:—1. *Cervical*, situated in the neck; 2. *Petrous*, occupying the carotid canal; 3. *Cavernous*, lying by the side of the sella turcica; 4. *Cerebral*, after it has pierced the dura mater.

RELATIONS.—The *cervical portion* rests upon the rectus anticus major, and superior cervical ganglion of the sympathetic, and partly on the internal jugular vein, lingual and pneumogastric nerves. It is crossed behind by the pharyngeal and superior laryngeal nerves. To its *inner* side it has the pharynx, tonsil, and ascending pharyngeal artery; to its *outer* side the jugular vein, commencement of the eighth pair, and lingual nerve. And it is crossed *in front* by the styloglossus and stylo-pharyngeus muscles. and glosso-pharyngeal nerve, being covered in by the parotid gland.

The *Petrous portion* is in relation with the carotid plexus, and is covered by the Casserian ganglion.

The *Cavernous portion* is placed to the inner side of the cavernous sinus, and is crossed by the nerves passing to the orbit, viz., third, fourth, ophthalmic branch of the fifth and sixth, and branches of the sympathetic.

The *Cerebral portion* is lodged in the fissure of Sylvius.

BRANCHES.—There are no branches given off by the cervical portion of the internal carotid: from the other portions are derived the following:—

INTERNAL CAROTID.—*Branches.*

<i>Petrous portion</i>	Tympanic.
<i>Cavernous portion</i>	{ Anterior meningeal, Ophthalmic.
<i>Cerebral portion</i>	{ Anterior cerebral, Middle cerebral, Posterior communicating.

The *Tympanic* is a small branch which enters the tympanum through a minute foramen in the carotid canal.

The *Anterior meningeal* is distributed to the dura mater and Casserian ganglion.

The *Ophthalmic artery* enters the orbit through the foramen opticum, to be distributed to the globe of the eye and surrounding structures. Its course and branches are described with the dissection of the orbit.

The three remaining arteries are described with the membranes of the brain, Chapter VI.

The *Veins* of the head and neck are the *external* and *internal jugular*. The former receives its blood from the temporal, internal maxillary, and auricular veins, and from the superficial parts of the neck, and descends obliquely backwards between the platysma myoides and sterno-mastoid muscle, to terminate in the subclavian vein behind the clavicle.

The *Internal jugular* vein commences at the jugular fossa, in the foramen lacerum posterius, where it receives the blood from the sinuses in the interior of the cranium. It descends the neck at first behind, and then to the outer side of the internal carotid artery, and continues its course within the sheath of the common carotid, and, lying to its outer side, to the inner border of the first rib, where it unites with the subclavian vein, and forms the vena innominata. On the left side the vein, at its termination, advances rather in front of the artery: on the right it diverges from the artery, leaving a triangular space between them. The internal jugular receives the veins from the deep parts at the base of the skull and neck, and is joined in the submaxillary space by a communicating branch from the external jugular, the facial, and occipital veins.

Along the anterior border of the sterno-mastoid muscle is a small vein, formed by branches from the superficial parts on the front of the neck. It is often of large size, and is named *anterior jugular*.

The *Subclavian artery*, on the right side (*fig. 42. 5.*) arises from the arteria innominata, 4., opposite the sterno-clavicular articulation, and on the left, 10., from the arch of the aorta, 2. The right is consequently shorter than the left, and situated on a plane superficial to it.

The *course* of the artery is divided into three portions, first, second, and third.

The *First portion* on the *right side*, 5, passes *obliquely* outwards to the inner border of the scalenus anticus. On the *left side*, 10., it ascends *perpendicularly* to the inner border of the scalenus anticus; the remainder of the course of the artery is the same on both sides.

The *Second portion*, 6. 11., passes *transversely* outwards between the two scalmi.

The *Third portion*, 7. 12., *downwards* and *outwards* over the first rib.

From the superficial and deep position of the two arteries, the

1. The ascending aorta. 2. Its arch. 3. The descending aorta. 4. The arteria innominata. 5. The right subclavian, the first, or obliquely ascending portion of its course. 6. The second, or transverse portion. 7. The third, or obliquely descending portion. 8. The right carotid artery. 9. The left carotid. 10. The left subclavian artery; the first, or perpendicular portion. 11. The second, or transverse. 12. The third, or oblique portion. 13. The right pneumogastric nerve, giving off the recurrent * around the subclavian artery. 14. The left pneumogastric, sending its recurrent branch * around the arch of the aorta. ** The two recurrent laryngeal nerves.

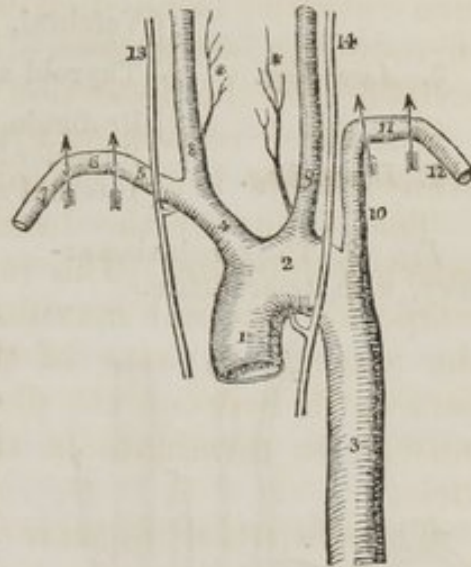
right lies in front of the pleura which covers its posterior surface, whilst the *left* is situated near the vertebral column, behind the pleura. The innominata vein is in front of the artery on both sides, lying parallel to it on the right, and crossing it at the upper part on the left.

In consequence of the oblique direction of the artery on the right side, it is *crossed* by the pneumogastric, 13., cardiac, and phrenic nerves, and the recurrent winds around it, whilst on the left side they all run parallel with it. The thoracic duct is placed immediately behind and parallel with the first portion of the artery on the left side.

The *Second portion* of the artery is situated between the two scalmi muscles, and is separated from the subclavian vein by the scalenus anticus.

The *Third portion* has the brachial plexus almost in con-

Fig. 42. The arch of the aorta, with its branches, and the course of the subclavian arteries.

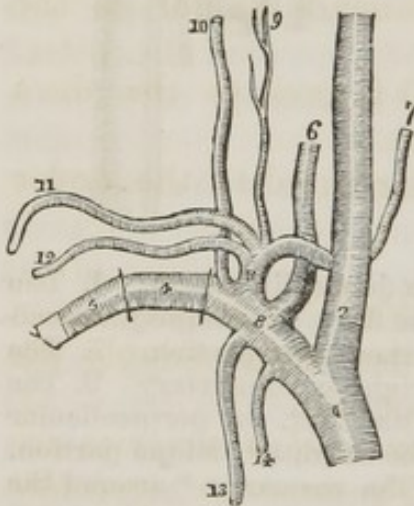


tact with it above, the subclavian vein in front, and the first rib below.

BRANCHES.—The *Branches* of the subclavian artery (*fig. 43.*) are given off from its *first portion*; they are five in number.

3. <i>Ascending.</i>	{	Vetebral, <i>fig. 43.</i> 6.	{	Inferior thyroid, 7.
		Thyroid axis, 8,		Supra-scapular, 12.
2. <i>Descending.</i>	{	Profunda cervicis, 10.	{	Posterior scapular, 11.
		Superior intercostal, 14.		Superficialis cervicis, 9.
		Internal mammary, 13.		

Fig. 43. The subclavian artery, with its branches.



The *Vetebral artery* (*fig. 43.* 6.) ascends through the foramina in the transverse processes of all the cervical vertebræ, excepting the last, then winds backwards around the articulating process of the atlas, and piercing the dura mater, enters the skull through the foramen magnum. The two arteries unite at the lower border of the pons Varolii to form the *basilar artery*, which runs forwards to its anterior border, and divides into four terminal branches.

1. The arteria innominata, dividing into, 2. The right common carotid artery, and 3. The right subclavian artery, the first part of its course, from which all the branches are given off. 4. The second part of its course. 5. The third part of its course. 6. 7. The two visceral branches of the subclavian artery, 6. The vertebral. 7. The inferior thyroid. 8. The thyroid axis, giving off its four branches. 9. 10. The two cervical branches of the subclavian;—9. The cervicalis superficialis, 10. The cervicalis profunda. 11. 12. The two scapular branches;—11. The posterior scapular. 12. The supra-scapular. 13. 14. The two thoracic branches;—13. The internal mammary artery, 14. The superior intercostal.

The *branches* of the *Vertebral artery* are—

Branches.

<i>Vertebral</i> {	Lateral spinal,
	Anterior spinal,
	Posterior spinal,
	Posterior meningeal,
	Inferior cerebellar.

Basilar { Transverse,
Superior cerebellar,
Posterior cerebral.

The *Lateral spinal* branches enter the intervertebral foramina, and are distributed to the dura mater of the spinal cord.

The *Anterior spinal* is a small branch which unites with its fellow of the opposite side, on the front of the medulla oblongata. The artery formed by the union of these two vessels descends along the anterior aspect of the spinal cord, to which it distributes branches as far as the cauda equina.

The *Posterior spinal* is a small branch running down the posterior surface of the spinal cord, parallel with its fellow of the opposite side, and distributing branches as far as the cauda equina.

The *Posterior meningeal* is a small branch to the dura mater, lining the inferior occipital fossæ.

The *Inferior cerebellar* artery is distributed to the under surface of the cerebellum.

BASILAR ARTERY.—*Branches.*

The *Transverse* branches of the basilar artery supply the pons Varolii, and adjacent parts of the brain.

The *Superior cerebellar* and *Posterior cerebral* arteries are the terminal branches of the basilar. The *superior cerebellar* is distributed to the upper surface of the cerebellum, and the *posterior cerebral* to the posterior lobes of the cerebrum, inosculating on the corpus callosum with the anterior cerebral arteries. They are separated from each other at their commencement by the third nerve.

The THYROID AXIS (*fig. 43. 8.*) is a short trunk which immediately divides into its four branches.

The INTERIOR THYROID ARTERY (*fig. 43. 7.*) passes behind the sheath of the carotid vessels, to the inferior part of the thyroid gland, to which it is distributed. It also gives branches to the trachea, lower part of the larynx and œsophagus. It is in relation with the middle cervical ganglion of the sympathetic, which rests upon it.

The SUPRA-SCAPULAR ARTERY, 12., (*transversalis humeri*) passes obliquely backwards behind the clavicle, and across the ligament of the notch, to the supra-spinatus fossa. It is distributed to the muscles on the dorsum of the scapula, and

inosculates with the posterior scapular, and beneath the acromion process with the dorsal branch of the subscapular artery.

The POSTERIOR SCAPULAR ARTERY, 11., (*transversalis colli*,) passes transversely across the subclavian triangle at the root of the neck, to the superior angle of the scapula. It then descends along the posterior border to its inferior angle, where it inosculates with the subscapular artery, a branch of the axillary.

Relations.—It passes behind, and sometimes in front of the scalenus anticus, between the nerves forming the brachial plexus, and beneath the levator anguli scapulae rhomboideus minor and major muscles.

Branches.—Some ascending branches are given off at the superior angle of the scapula, which inosculate with the profunda cervicis.

The SUPERFICIALIS CERVICIS ARTERY, 9., is a small vessel, which ascends upon the anterior tubercles of the transverse processes of the cervical vertebrae, and distributes branches to the muscles on the anterior aspect of the vertebral column in the neck.

The PROFUNDA CERVICIS, 10., passes backwards between the transverse processes of the sixth and seventh cervical vertebrae, and then ascends the back part of the neck, between the complexus and semi-spinalis colli muscles. It inosculates above with the princeps cervicis of the occipital artery, and below with the posterior scapular.

The SUPERIOR INTERCOSTAL ARTERY, 14., descends behind the pleura upon the necks of the first two ribs. Its branches supply the first two intercostal spaces.

The INTERNAL MAMMARY ARTERY, 13., descends by the side of the sternum, resting upon the costal cartilages, to the diaphragm: it then pierces the anterior fibres of the diaphragm, and enters the sheath of the rectus, where it inosculates with the epigastric artery, a branch of the external iliac.

The *Branches* of the internal mammary are,—

Anterior intercostal—mammary,
Comes nervi phrenici,
Mediastinal,
Pericardiac,
Musculo-phrenic.

The *Anterior intercostals* supply the intercostal spaces on

the front part of the chest, and inosculate with the aortic intercostal arteries. They give off several large branches to the mammary gland, which anastomose freely with the thoracic branches of the axillary artery.

The *Comes nervi phrenici* is a long and slender branch which accompanies the phrenic nerve.

The *Mediastinal* and *pericardiac* branches are small vessels distributed to the anterior mediastinum and pericardium.

The *Musculo-phrenic* artery winds along the attachment of the diaphragm to the ribs, supplying it with branches.

If we now proceed to an analysis of the distribution of the branches of the subclavian artery, we shall find that two,

Internal mammary (*fig. 43. 13.*),

Superior intercostal, 14.,

are distributed to the parieties of the thorax; two,

Supra-scapular, 12.,

Posterior scapular, 11.,

are distributed to the shoulder; two others,

Superficialis cervicis, 9.,

Profunda cervicis, 10.,

supply the neck; and of the remaining two, one is distributed to the thyroid gland,

Inferior thyroid, 7.,

and the other to the spinal cord and brain,

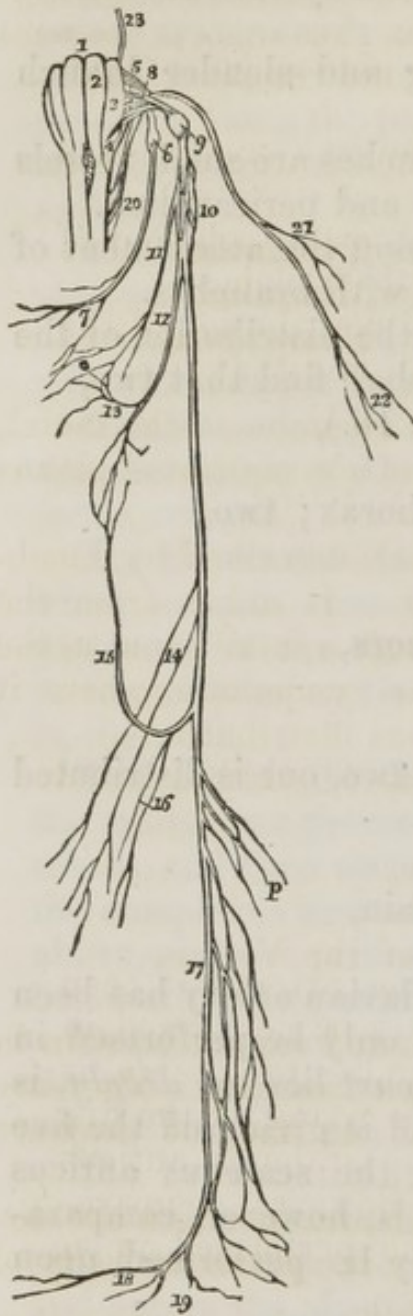
Vertebral, 6.

The operation for ligature of the subclavian artery has been already described. This operation can only be performed in the *third part* of its course. The *first part* lies too *deeply*, is surrounded with important *relations*, and is giving off the five *branches*; and the second lies behind the scalenus anticus muscle. The third part of the artery is, however, comparatively superficial, and the operation may be performed upon it with perfect security.

NERVES OF THE NECK.

Having now considered all the vessels of the neck, we must next turn our attention to the nerves which occupy this region; they are the *eighth* and *ninth* pairs of cerebral, the *sympathetic*, and the *eight cervical nerves*.

Fig. 44. Origin and distribution of the eighth pair of nerves of the left side.



The EIGHTH PAIR (*fig. 44.*) of cerebral nerves consists of the *glosso-pharyngeal*, 6., *pneumogastric* or *vagus*, 10., and *spinal accessory*, 21. They arise from the respiratory tract of Bell, the two former, 5. 8., between the corpus olivare and restiforme; the latter, 20., from the spinal cord, opposite the fourth cervical vertebra: hence its cognomen, *spinal*. The spinal accessory ascends from its origin between the anterior and posterior roots of the spinal nerves, to join the other two, and the three together escape from the skull, through the foramen lacerum posterius, lying to the inner side, and rather in front of the jugular vein.

The GLOSSO-PHARYNGEAL NERVE presents a gangliform swelling, the ganglion of Andersch,* *fig. 44.* 6. (ganglion petrosum,) upon that portion of its cylinder which is situated in the jugular fossa. It then passes forwards between the jugular vein and internal carotid artery, to the stylo-pharyngeus muscle, and descends along its inferior border to the hyo-glossus, beneath which it passes to be distributed to the mucous membrane of the tongue, and to the mucous glands of the mouth and tonsils.

1. The medulla oblongata. 2. The corpus pyramidale of the left side.
3. The corpus olivare. 4. The corpus restiforme. 5. The origin of the glosso-pharyngeal nerve. 6. The ganglion of the glosso-pharyngeal nerve, or of Andersch. 7. A branch from the glosso-pharyngeal nerve to the pharyngeal plexus. 8. The origin of the pneumogastric nerve. 9. The upper ganglion of the pneumogastric. 10. The lower or plexiform ganglion of the nerve. 11. The pharyngeal nerve, descending to form the pharyngeal plexus.* 12. The superior laryngeal nerve. 13. A branch to the pharyngeal

* Charles Samuel Andersch. Tractatus Anatomico-Physiologica de Nervis Corporis Humani Aliquibus, 1797.

plexus. 14. Cardiac nerves. 15. The recurrent laryngeal nerve. 16. Cardiac branches from the recurrent. 17. Œsophageal plexus. 18. Branches to the stomach. 19. A branch which joins the solar plexus. 20. The origin of the spinal accessory nerve. 21. Its branches to the sterno-mastoid muscle. 22. Terminal branches to the trapezius. 23. The origin of the facial nerve. *p.* The branches forming the pulmonary plexuses.

Its *Branches* may be thus arranged:

Communicating branches with the

Facial,	Tympanic,
Pneumogastric,	Muscular,
Spinal accessory,	Pharyngeal.
Sympathetic,	

The *Branches of communication* are common to the facial, eighth pair, and sympathetic; they form a complicated plexus at the base of the skull.

The *Tympanic* is a remarkable branch described by Jacobson, and hence called Jacobson's nerve. It arises from the ganglion of Andersch, and passes through a small canal in the petrous bone to the internal wall of the tympanum, where it divides into six branches, which are thus distributed:—

1. To the fenestra rotunda,
2. To the fenestra ovalis,
3. To the Eustachian tube,
4. To the carotid plexus,
5. To the cranial branch of the Vidian,
6. To the otic ganglion.

These filaments are extremely small, and cannot be seen in the adult tympanum, unless by a lucky section. They are best dissected in the ear of the foetus. In the cat they are very distinct and easily demonstrated.

The *Muscular* branch divides into filaments, which are distributed to the stylo-pharyngeus and to the posterior belly of the digastricus and stylo-hyoideus muscle.

The *Pharyngeal* branches, 7., are two or three filaments sent to the side of the pharynx and pharyngeal plexus.

The PNEUMOGASTRIC NERVE (vagus) forms a short rounded ganglion (*fig. 50. 9.*) as it passes through the foramen lacerum posterius. Having escaped at this opening, it presents a second gangliform swelling, 10., nearly an inch in length, and surrounded by an irregular plexus of white nerves, which communicate with each other, with the other divisions of the eighth pair, and with the trunk of the pneumogastric below

the ganglion. This second, or *plexiform ganglion*, (ganglion of the superior laryngeal branch of Sir Astley Cooper,) is situated, at first, behind the internal carotid artery, and then between that vessel and the internal jugular vein. The pneumogastric nerve then descends the neck within the sheath of the carotid vessels, lying behind and between the artery and vein to the root of the neck. Here the course of the nerve at opposite sides becomes different.

The *right* passes between the subclavian artery and vein to the posterior mediastinum, then behind the root of the lung to the œsophagus, which it accompanies to the stomach, lying on its posterior aspect.

The *left* enters the chest parallel with the left subclavian artery, crosses the arch of the aorta, and descends behind the root of the lung, and along the anterior surface of the œsophagus, to the stomach.

The two nerves communicate freely with each other on the stomach, and with the solar plexus.

The *Branches* of the pneumogastric nerve are the following:—

Communicating branches with the	
Facial,	Cardiac,
Glosso-pharyngeal,	Inferior or recurrent laryngeal,
Spinal accessory,	Pulmonary anterior,
Lingual,	Pulmonary posterior,
Sympathetic,	Œsophageal,
Pharyngeal,	Gastric.
Superior laryngeal,	

The *Branches of communication* are the same, with the addition of the lingual, as those we before noticed in connexion with the glosso-pharyngeal.

The *Pharyngeal* nerve (*fig. 44. 11.*) arises from the pneumogastric, close to the foramen lacerum posterius, and descends behind the internal carotid artery to the upper border of the middle constrictor, upon which it forms the *pharyngeal plexus* (*fig. 44.,**) assisted by branches from the glosso-pharyngeal, superior laryngeal, and sympathetic.

The *Superior laryngeal nerve* (*fig. 44. 12.*) arises from the inferior ganglion of the pneumogastric, of which it appears almost a continuation; hence the ganglion has been named by Sir Astley Cooper, "*the ganglion of the superior laryngeal branch.*" The nerve descends behind the internal carotid

artery to the opening in the thyro-hyoidean membrane, through which it passes with the superior laryngeal artery, and is distributed to the mucous membrane of the larynx, communicating on the arytenoid muscle, and behind the cricoid cartilage, with the recurrent laryngeal nerve. Behind the internal carotid it gives off the *external laryngeal branch*, which sends a branch to the pharyngeal plexus, and then descends to supply the inferior constrictor and crico-thyroid muscles and thyroid gland, and communicates by two or three branches with the recurrent laryngeal, and sympathetic nerves.

Mr. John Hilton, demonstrator of anatomy at Guy's Hospital, who has made some able dissections of the nerves of the larynx, for which we refer the student to a masterly description in the 2d vol. of the Guy's Hospital Reports, concludes that the superior laryngeal nerve is the *nerve of sensation* to the larynx, being distributed solely (with the exception of its external laryngeal branch) to the mucous membrane, cellular tissue, and glands. If this fact be taken in connexion with the observations of Sir Astley Cooper, and the dissections of the origin of the nerve by Mr. Edward Cock, we shall perceive that, both in the ganglionic origin of the nerve, and in its distribution, we have striking evidence of its sensitive function. The recurrent, or superior laryngeal nerve, is the proper motor nerve, and is distributed to the muscles of the larynx.

The *Cardiac* branches, 14., one or two in number, cross the lower part of the common carotid to communicate with the cardiac branches of the sympathetic, for the supply of the heart.

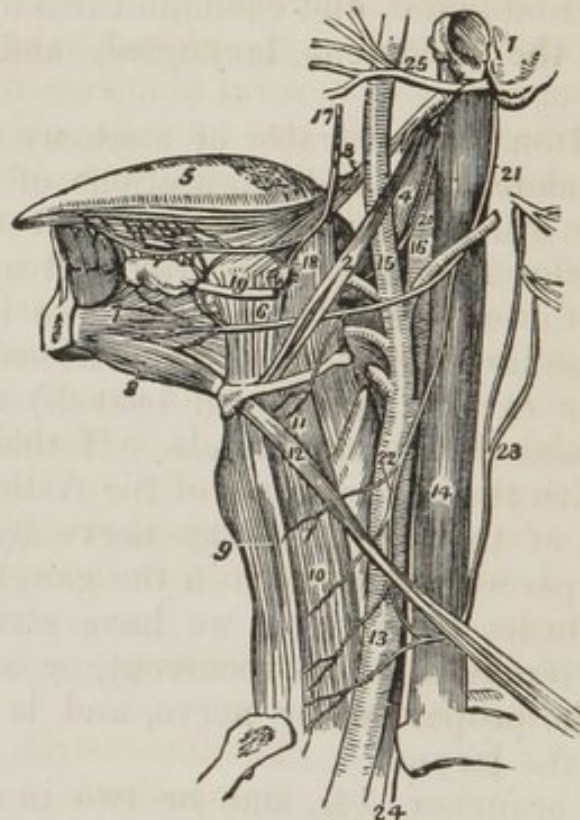
The *Recurrent laryngeal*, or inferior laryngeal nerve (*fig. 44. 15.*), curves around the subclavian artery on the right (*fig. 42. 13.**) and the arch of the aorta on the left side (*fig. 42. 14.**) It ascends in the groove between the trachea and œsophagus, and piercing the lower fibres of the inferior constrictor muscle, enters the larynx close to the articulation of the inferior cornu of the thyroid with the cricoid cartilage. It is distributed to all the muscles of the larynx, with the exception of the crico-thyroid, and communicates with the superior laryngeal nerve. As it curves around the subclavian artery and aorta, it gives branches (*fig. 44. 16.*) to the heart and root of the lungs; and, as it ascends the neck, it gives

branches to the œsophagus and trachea, and communicates with the external laryngeal nerve and sympathetic.

In function it is the proper motor nerve of the larynx.

The remaining branches of the pneumogastric have been described with the anatomy of the thorax.

Fig. 45. The anatomy of the side of the neck, showing the nerves of the tongue.



1. A fragment of the temporal bone containing the meatus auditorius externus, mastoid, and styloid process. 2. The stylo-hyoid muscle. 3. The stylo-glossus. 4. The stylo-pharyngeus. 5. The tongue. 6. The hyoglossus muscle; its two portions. 7. The genio-hyo-glossus muscle. 8. The genio-hyoideus; they both arise from the inner surface of the symphysis of the lower jaw. 9. The sterno-hyoid muscle. 10. The sterno-thyroid. 11. The thyro-hyoid, upon which the hyoid branch of the lingual nerve is seen ramifying. 12. The omo-hyoid, crossing the common carotid artery (13,) and internal jugular vein (14.) 15. The external carotid giving off its branches. 16. The internal carotid. 17. The gustatory nerve giving off a branch to the submaxillary ganglion (18,) and communicating a little farther on with the hypoglossal nerve. 19. The submaxillary, or Wharton's duct, passing forwards to the sublingual gland. 20. The glosso-pharyngeal nerve. 21. The hypoglossal nerve curving around the occipital artery. 22. The descendens noni nerve, forming a loop with (23) the communicans noni, which is seen to be arising by filaments from the upper cervical nerves. 24. The pneumogastric nerve, emerging from between the internal jugular vein and common carotid artery, and entering the chest. 25. The facial nerve, emerging from the stylo-mastoid foramen, and crossing the external carotid artery.

The SPINAL ACCESSORY NERVE, on escaping from the foramen lacerum posterius, passes backwards behind the internal jugular vein, and descends obliquely to the upper part of the sterno-mastoid muscle, which it pierces (*fig. 44. 21.*) It then passes obliquely across the side of the neck to the trapezius muscle, to which it is distributed, 22. It communicates, like the preceding nerves, with the other branches of the eighth pair, and with the sympathetic. Its branches supply the sterno-mastoid and trapezius muscles.

The LINGUAL NERVE (ninth, hypo-glossal,) the true motor nerve of the tongue, arises by several filaments from the side of the corpus pyramidale of the medulla oblongata, and escapes from the skull through the anterior condyloid foramen. It then passes forwards behind the internal jugular vein, and descends along its outer border to a point parallel with the angle of the lower jaw. It next curves inwards around the occipital artery, with which it forms a loop, and crosses the lower part of the hyo-glossus muscle to the genio-hyo-glossus, in which it terminates. It is distributed to the muscles of the tongue, and principally to the genio-hyo-glossus. It is separated from the lingual artery by the hyo-glossus muscle, and, while resting on this muscle, presents a flattened appearance.

The *Branches* of the lingual nerve are,—

Communicating branches with the

Pneumogastric,
Sympathetic.

Descendens noni,

Hyoidean branch,

Communicating filaments with the

Gustatory nerve.

The *Communications* between the lingual nerve, the eighth pair, and the sympathetic, are situated at the base of the skull, as we have before noted for the divisions of the eighth pair.

The *Descendens noni* is a long slender nerve which quits the lingual just as it is about to form its arch around the occipital artery, and descends upon the sheath of the carotid vessels. Just below the middle of the neck, it forms a loop with a long branch (*communicans noni*) from the second and third cervical nerves. From the convexity of this loop, branches are sent to the depressor muscles of the larynx. If

the descendens noni be traced to its connexion with the lingual nerve, and examined with care, it will be found to be formed by two filaments, one from the lingual, the other, of larger size, from the first and second cervical nerves.*

The *Hyoidean branch* is a small branch distributed to the insertions of the depressor muscles of the larynx.

The *Communicating filaments*, with the gustatory nerve, are two or three small branches which ascend upon the anterior part of the hyo-glossus muscle, and join corresponding branches sent downwards by the gustatory.

The SYMPATHETIC NERVE, in the neck, descends from the carotid foramen in the temporal bone, behind the internal carotid artery and sheath of the common carotid and internal jugular vein, to the head of the first rib, where it forms the first dorsal ganglion, and becomes thoracic. In its course downwards it rests upon the rectus anticus major and longus colli muscles, and forms three ganglia,—superior, middle, and inferior.

The Superior cervical ganglion is long and fusiform, extending from near the carotid foramen to opposite the bifurcation of the common carotid.

All the ganglia and nerves of the sympathetic present a peculiar reddish-gray appearance and pearly lustre. Since the time of Bichât, the ganglia have been regarded as so many distinct centres, from which nerves are given off in all directions. These directions may, for the convenience of arrangement and description, be reduced to four, viz. superior, inferior, external, and internal. The *superior* branches communicate with the ganglion above. The *inferior*, with the ganglion below. The *external*, with the spinal nerves at their exit from the intervertebral foramina. The *internal* branches, however, are distributed to the viscera.

The *Branches* of the superior cervical ganglion are, therefore, *superior, inferior, external* and *internal*: to which may be added, as proper to this ganglion, *anterior*.

The *Superior* branch enters the carotid canal and divides into two branches, which form frequent communications with each other (*carotid plexus*) and are ultimately distributed with the terminal branches of the internal carotid artery.

* The connexion between the lingual and cervical nerves is subject to much irregularity.

They communicate also with the sixth nerve in the cavernous sinus.

The carotid plexus, formed by the communicating filaments passing between these two branches, is augmented by the reception of a branch from the Vidian, and another from the tympanic branch of the glosso-pharyngeal.

The *Inferior* branch, often double, communicates with the middle cervical ganglion: it also sends filaments to the third and fourth cervical nerves.

The *External* branches are the branches of communication with the facial, glosso-pharyngeal, pneumogastric, spinal accessory, and lingual nerves; also with the first and second cervical nerves.

The *Internal* branches are, *pharyngeal*, filaments communicating with the pharyngeal plexus upon the middle constrictor muscle; *laryngeal*, to communicate with the external laryngeal nerve; and a long branch, which descends to the thorax, and is distributed to the heart; the *Superior cardiac nerve* (n. superficialis cordis.)

The *Anterior* branches are small soft filaments called *nervi molles*, which accompany the ramifications of the external carotid artery.

The *Middle cervical ganglion* is of small size, and situated upon the inferior thyroid artery (hence, thyroid ganglion,) opposite the fifth or sixth vertebra: sometimes it is behind the artery, or altogether wanting.

Branches.—*Superior*, communicating with the first cervical ganglion.

Inferior, communicating with the third cervical ganglion.

External, communicating with the third, fourth, and fifth cervical nerves.

Internal, a large branch which descends to the heart; the *Middle cardiac nerve* (n. cardiacus magnus.)

The *Inferior cervical ganglion*, of a semilunar form, is situated immediately behind the vertebral artery, supported by the transverse process of the seventh cervical vertebra.

Branches.—*Superior*, to communicate with the second cervical ganglion.

Inferior, to communicate with the first dorsal ganglion.

External, to communicate with the fifth, sixth, and seventh cervical nerves; and one or two small filaments which ascend along the vertebral artery.

Internal, several branches to communicate with the recurrent nerve; and a branch to the heart, the *Inferior cardiac nerve*.

The cardiac nerves are very irregular, both in origin and course: they cross the innominate artery on the right, and the left carotid on the left side, and pass in front of the trachea to the base of the heart.

The CERVICAL NERVES are eight in number, and increase in size from above downwards. The first (sub-occipital) passes out of the spinal canal between the occipital bone and the atlas; the last, between the last cervical and first dorsal vertebræ. Each nerve, at its escape from the intervertebral foramen, divides into an anterior and posterior branch. The anterior branches of the four upper cervical nerves form the *cervical plexus*; the posterior branches, the *posterior cervical plexus*.

The anterior branches of the four inferior cervical and first dorsal form the brachial plexus.

The CERVICAL PLEXUS is formed by loops of communication which pass from one nerve to another; the communicating branch between the first and second nerves is very small; the others have several communicating branches which are larger in size. The plexus rests upon the levator anguli scapulæ and posterior scalenus muscles.

Its *Branches* may be arranged into three groups, *ascending*, *descending superficial*, and *descending deep*.

<i>Ascending</i>	{	Superficialis colli, Auricularis magnus, Occipitalis minor.						
<i>Descending</i>	{	<table style="border: none;"> <tr> <td style="vertical-align: middle; padding-right: 10px;"><i>Superficial</i></td> <td style="font-size: 1.5em; vertical-align: middle;">{</td> <td style="padding-left: 10px;">Acromiales, Claviculares.</td> </tr> <tr> <td style="vertical-align: middle; padding-right: 10px;"><i>Deep</i></td> <td style="font-size: 1.5em; vertical-align: middle;">{</td> <td style="padding-left: 10px;">Communicans noni, Phrenic, Muscular.</td> </tr> </table>	<i>Superficial</i>	{	Acromiales, Claviculares.	<i>Deep</i>	{	Communicans noni, Phrenic, Muscular.
<i>Superficial</i>	{	Acromiales, Claviculares.						
<i>Deep</i>	{	Communicans noni, Phrenic, Muscular.						

The *Superficialis colli* (fig. 38. 11.) crosses the sternomastoid muscle obliquely, and divides into two branches; *one* is distributed to the integument on the side of the neck, the *other* ascends to the submaxillary region, and forms a plexus with the cervical branches of the facial.

The *Auricularis magnus* (fig. 38. 13.,) the largest of the three, curves around the posterior border of the sternomastoid, and ascends by the side of the jugular vein to the

external ear, supplying that organ and the integument over the parotid gland and side of the face. It communicates in the parotid gland with the facial nerve.

The *Occipitalis minor* (fig. 38. 14.) ascends along the posterior border of the sterno-mastoid muscle, and is distributed to the integument on the posterior part of the head.

The *Claviculares* (fig. 38. 15.) and *acromiales* are several large branches which descend over the clavicle, and are distributed to the integument of the chest and shoulder.

The *Communicans noni* is a long branch formed by filaments from the second and third cervical nerve: it descends and forms a loop with the *descendens noni* over the sheath of the carotid vessels.

The *Phrenic nerve* is formed by filaments from the third, fourth, and fifth cervical nerves, receiving also a branch from the sympathetic. It descends to the root of the neck, resting upon the scalenus anticus muscle, then crosses the first portion of the subclavian artery, and enters the chest between it and the subclavian vein. Within the chest it passes through the middle mediastinum, between the pleura and pericardium to the diaphragm to which it is distributed, and communicates in the abdomen with the phrenic and solar plexus, particularly on the left side. The left phrenic nerve is rather longer than the right, from the inclination of the heart to the left side.

POSTERIOR CERVICAL PLEXUS.—The posterior branches of the first, second, and third cervical nerves, send branches of communication between each other, which form a small plexus beneath the complexus muscle. All the branches of the *posterior cervical plexus* are distributed to the muscles on the back part of the neck, with the exception of a large ascending branch of the second cervical nerve, the *occipitalis major*. This nerve pierces the complexus, and ascends with the occipital artery, to be distributed to the integument on the posterior part of the head. It supplies no muscles.

ORGAN OF VOICE.

The *Larynx* is situated at the forepart of the neck between the trachea and the base of the tongue. It is composed of *cartilages, ligaments, muscles, vessels, and nerves, and mucous membrane.*

The *Cartilages* are, the

Thyroid,
Cricoid,

Two Arytenoid,
Epiglottis.

The *Thyroid* ($\thetaυρρεος$ — $ειδος$, like a shield) is the largest cartilage of the larynx; it consists of two lateral portions or *alæ*, which meet at an acute angle in front, and form the projection which is known by the name of *pomum Adami*. Where the *pomum Adami* is prominent, a *burso mucosa* is often found between it and the skin.

Each *ala* is quadrilateral, and forms a rounded border posteriorly, which terminates above, in the *superior cornu*, and below, in the *inferior cornu*.

Upon the side of the *ala* is an *oblique line*, into which the sterno-thyroid muscle is inserted, and from which the thyrohyoid takes its origin. Behind this is a *vertical line* which gives origin to the inferior constrictor muscle.

In the *receding angle* formed by the meeting of the two *alæ* upon the inner side of the cartilage, and near to its lower border, are attached the epiglottis, the *chordæ vocales*, the thyro-arytenoid, and the thyro-epiglottidean muscles.

The *Cricoid* ($κρικος$ — $ειδος$, like a ring) is a ring of cartilage, narrow in front and broad behind, where it is surmounted by *two rounded surfaces*, which articulate with the arytenoid cartilages. Upon the middle of line, posteriorly, is a *vertical ridge* which gives attachment to the œsophagus. On each side of the ridge are the depressions which lodge the crico-arytenoidei postici muscles. On either side of the ring is a *glenoid cavity*, which articulates with the inferior cornu of the thyroid cartilage.

The *Arytenoid cartilages* ($αρυταινα$,* a pitcher) two in number, are triangular in form. They are broad below, where they articulate with the upper border of the cricoid, and give attachment to the crico-arytenoidei postici, crico-arytenoidei laterales, and thyro-arytenoidei muscles, and *chordæ vocales*; and pointed above, where they articulate with two little curved cartilages, called *cornicula laryngis* (*capitula laryngis*). On the posterior surface they are concave, and lodge the arytenoideus muscle.

* This derivation has reference to the appearance of both cartilages taken together and covered by mucous membrane. In animals, which were the principal subjects of dissection among the ancients, the opening of the larynx with the arytenoid cartilages bears a striking resemblance to the mouth of a pitcher having a large spout.

The *Epiglottis* (*ἐπιγλωττίς*, upon the tongue) is a fibro-cartilage of a yellowish colour; studded with a number of small mucous glands, which are lodged in shallow pits upon its surface. It is shaped like a cordate leaf, and is placed immediately in front of the opening of the larynx, which it closes completely when the larynx is drawn up beneath the base of the tongue. It is attached by its point to the *receding angle*, between the two alæ of the thyroid cartilage.

Two small cartilaginous tubercles (cuneiform) are often found in the folds of the mucous membrane which bound the opening of the larynx laterally.

LIGAMENTS.—The *ligaments* of the larynx are numerous, and may be arranged into four groups: 1. Those which articulate the thyroid with the os hyoides. 2. Those which connect it with the cricoid. 3. Ligaments of the arytenoid cartilages. 4. Ligaments of the epiglottis.

1. The ligaments which connect the thyroid cartilage with the os hyoides are three in number.

The two *Thyro-hyoidean ligaments* pass between the superior cornua of the thyroid and the extremities of the greater cornua of the os hyoides: a sesamoid bone is found in each.

The *Thyro-hyoidean membrane* is a broad membranous layer, occupying the entire space between the thyroid cartilage and os hyoides. It is pierced by the superior laryngeal nerve and artery.

2. The ligaments connecting the thyroid to the cricoid cartilage are also three in number:—

Two *Capsular ligaments*, with their synovial membranes, which form the articulation between the inferior cornua of the thyroid and the sides of the cricoid, and the *crico-thyroidean membrane*, through which the operation of laryngotomy is performed. The latter is sometimes crossed by a small artery.

3. The ligaments of the arytenoid cartilages are four in number:—

Two *Capsular ligaments* and synovial membranes, which articulate the arytenoid cartilages with the cricoid; and the *thyro-arytenoid ligaments*, or *chordæ vocales*, which pass backwards from the receding angle of the thyroid cartilage, near to its lower border, to be inserted into the bases of the arytenoid cartilages. The space between these two ligaments is the glottis, or rima glottidis.

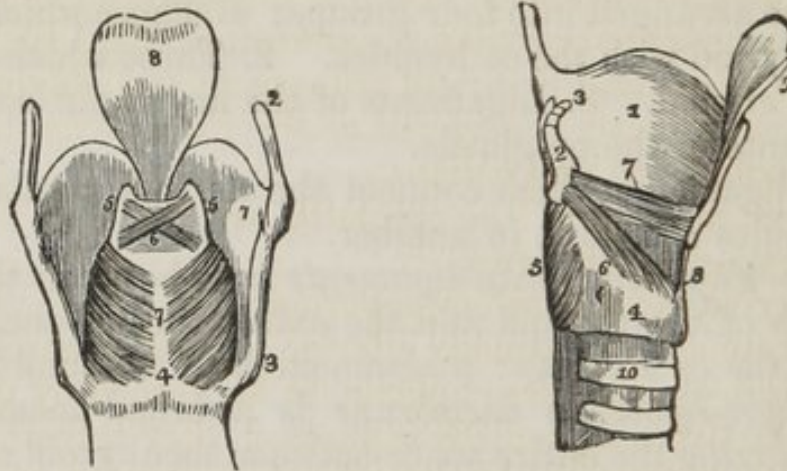
4. The ligaments of the epiglottis are five in number:—

1. Three folds of mucous membrane, one at the middle, and one at each side, called *fræna epiglottidis*, which hold the epiglottis back to the tongue. 2. *Epiglottis-hyoidean ligament*, which connects the epiglottis to the posterior surface of the os hyoides. 3. The ligament which attaches the epiglottis to the receding angle of the thyroid cartilage.

Fig. 46.

A posterior view of the larynx.

A side view of the larynx: one ala of the thyroid cartilage has been removed.



1. The thyroid cartilage. 2. One of its ascending cornua. 3. One of the descending cornua. 4. 7. The cricoid cartilage. 5. 5. The arytenoideus cartilages. 6. The arytenoideus muscle, consisting of oblique and transverse fasciculi. 7. The crico-arytenoid postici muscles. 8. The epiglottis.

1. The remaining ala of the thyroid cartilage. 2. One of the arytenoid cartilages. 3. One of the cornicula laryngis. 4. The cricoid cartilage. 5. The crico-arytenoideus posticus muscle. 6. The crico-arytenoideus lateralis. 7. The thyro-arytenoideus. 8. The crico-thyroidean membrane. 9. One half of the epiglottis. 10. The upper part of the trachea.

The MUSCLES of the larynx are eight in number; the five larger are the muscles of the chordæ vocales and rima glottidis; the three smaller are muscles of the epiglottis.

The five muscles of the chordæ vocales and rima glottidis are the

Crico-thyroid,
Crico-arytenoideus posticus,
Crico-arytenoideus lateralis,
Thyro-arytenoideus,
Arytenoideus.

The *Crico-thyroid* muscle arises from the anterior surface

of the cricoid cartilage, and is *inserted* into the lower and inner border of the thyroid.

The *Crico-arytenoideus posticus* arises from the depression on the posterior surface of the cricoid cartilage, and is *inserted* into the base of the arytenoid.

The *Crico-arytenoideus lateralis* arises from the upper border of the side of the cricoid, and is *inserted* into the base of the arytenoid cartilage.

The *Thyro-arytenoideus* arises from the receding angle of the thyroid cartilage, close to the outer side of the corda vocalis, and passes backwards parallel with the chord, to be *inserted* into the base of the arytenoid cartilage.

The *Arytenoideus* muscle occupies the posterior concave surface of the arytenoid cartilages, between which it is stretched. It consists of several planes of transverse and oblique fibres: hence it was formerly considered as several muscles, under the names of *transversi* and *obliqui*.

The three muscles of the epiglottis are the

Thyro-epiglottideus,

Aryteno-epiglottideus superior,

Aryteno-epiglottideus inferior (Hilton's muscle).

The *Thyro-epiglottideus* appears to be formed by the upper fibres of the thyro-arytenoideus muscle: they spread out upon the external surface of the sacculus laryngis, on which they are lost; a few of the anterior fibres being continued onwards to the side of the epiglottis.

The *Aryteno-epiglottideus superior* consists of a few scattered fibres, which pass forwards in the fold of mucous membrane, forming the lateral boundary of the entrance into the larynx, from the apex of the arytenoid cartilage to the side of the epiglottis.

The *Aryteno-epiglottideus inferior*.—This muscle was discovered by Mr. Hilton, and is very important in relation to the sacculus laryngis, with which it is closely connected. It may be found by raising the mucous membrane immediately above the ventricle of the larynx. It *arises* by a narrow and fibrous origin from the arytenoid cartilage, just above the attachment of the chorda vocalis; and passing forwards, and a little upwards, expands over the upper half, or two-thirds of the sacculus laryngis, and is *inserted* by a broad attachment into the side of the epiglottis.

ACTIONS.—The crico-thyroid and arytenoid muscles are *contractors* of the rima glottidis: the crico-arytenoideus posticus and lateralis, and the thyro-arytenoideus, are *dilators*.

The crico-thyroid muscles elongate, and thereby bring together the chordæ vocales, by drawing the thyroid cartilage downwards and forwards; their posterior attachment at the arytenoid cartilages being fixed. The arytenoid muscles approximate the arytenoid cartilages, and consequently the chordæ vocales, directly.

The crico-thyroidei postici being attached to the outer side of the base of the arytenoid cartilages, draw them from each other, and stretch the chordæ vocales. The crico-arytenoidei laterales draw the arytenoid cartilages from each other, but relax the chordæ vocales; and the thyro-arytenoidei increase the width of the glottis, by directly relaxing the chordæ vocales.

The thyro-epiglottideus acts principally by compressing the glands of the sacculus laryngis and the sac itself: by its attachment to the epiglottis it would act feebly upon that valve. The aryteno-epiglottideus superior serve to keep the mucous membrane of the sides of the opening of the glottis tense, when the larynx is drawn upwards, and the opening closed by the epiglottis. Of the aryteno-epiglottideus, the "functions appear to be," writes Mr. Hilton, "to compress the subjacent glands which open into the pouch; to diminish the capacity of that cavity, and change its form; and to approximate the epiglottis and the arytenoid cartilage."

Mucous membrane.—The larynx is lined by the mucous membrane, which is continued from the mouth and pharynx, and prolonged onwards through the trachea and bronchi to the bronchial cells. The chordæ vocales form two horizontal projections of the mucous membrane, and constitute the lateral boundaries of the *glottis*, or *rima glottidis*. Immediately above the horizontal projection of the chorda vocalis, at each side, is a depressed fossa, the *ventricle of the larynx*. The superior boundary of the ventricle is an arched border of mucous membrane, which is very incorrectly termed the *superior chorda vocalis*. If the rounded extremity of a probe be introduced into the ventricle of the larynx, and then directed upwards, it will enter a considerable pouch, which has been recently described by Mr. Hilton which great care, as the

sacculus laryngis.* From the ventricle of the larynx the sacculus is continued upwards, nearly as high as the upper border of the thyroid cartilage, and sometimes beyond it. When dissected from the interior of the larynx, it is found covered by the aryteno-epiglottideus muscle and a fibrous membrane, which is attached to the superior chorda vocalis below; to the epiglottis in front; and to the upper border of the thyroid cartilage above. If examined from the exterior of the larynx, it will be seen to be covered by the thyro-epiglottideus muscle. On the surface of its mucous membrane are the openings of sixty or seventy small follicular glands, which are situated in the sub-mucous tissue, and give its external surface a rough and ill-dissected appearance. This mucous secretion is intended for the lubrication of the chordæ vocales, and is directed upon them by two small valvular folds of mucous membrane, which are situated at the entrance of the sacculus.

The *Entrance of the larynx* is formed by two folds of mucous membrane, stretched between the apices of the arytenoid cartilages and the sides of the epiglottis. The arytenoid glands and superior aryteno-epiglottidean muscles are situated within these folds.

The GLANDS of the larynx are, 1. The *epiglottic*—most improperly named—for it consists merely of a mass of fat

* This sac was discovered and described by Mr. Hilton before he was aware that it had already been pointed out by the older anatomists. We ourselves made a dissection, which we still possess, of the same sac in an enlarged state during the month of August 1837, without any knowledge either of Mr. Hilton's labours, or Morgagni's account. The sac projected considerably above the upper border of the thyroid cartilage, and the extremity had been snipped off on one side in the removal of the muscles. The larynx was presented to us by Dr. George Moor of Camberwell: he had obtained it from a child who died of bronchial disease; and he conceived that this peculiar disposition of the mucous membrane might explain some of the symptoms by which the case was accompanied. Cruveilhier made the same discovery in equal ignorance of Morgagni's description, for we read in a note at page 677, vol. ii. of his *Anatomie Descriptive*,—"J'ai vu pour la première fois cette arrière cavité chez un individu affecté de phthisie laryngée, où elle était très-développée. Je fis des recherches sur le larynx d'autres individus, et je trouvai que cette disposition était constante. Je ne savais pas alors que Morgagni avait indiqué et fait représenter la même disposition." Cruveilhier compares its form very aptly to a "*Phrygian casque*," and Morgagni's figure, *Advers. 1. Epist. Anat. 8. plate 2. fig. 4.*, has the same appearance. But neither of these anatomists notice the follicular glands described by Mr. Hilton.

situated between the convexity of the epiglottis and the thyrohyoid membrane; 2. The *arytenoid* glands, some small granules found in the folds of mucous membrane near the apex of the arytenoid cartilage.

VESSELS AND NERVES.—The *arteries* of the larynx are derived from the superior and inferior thyroid. The *nerves* are the superior laryngeal and recurrent laryngeal; both branches of the pneumogastric. The two nerves communicate with each other freely; but the superior laryngeal is distributed principally to the mucous membrane at the entrance of the larynx; the recurrent, to the muscles.

In children, and in the female, the larynx is less developed than in the adult male; the thyroid cartilage forms a more obtuse angle, and is less firm: in the male the angle is acute, and the cartilage often converted into bone.

The TRACHEA extends from opposite the fifth cervical vertebra to opposite the third dorsal, where it divides into two bronchi. The *right bronchus*, larger than the left, passes off nearly at *right angles*, to the upper part of the corresponding lung. The *left* descends *obliquely*, and passes beneath the arch of the aorta, to reach the left lung.

The *Trachea* is composed of

Fibro-cartilaginous rings,	Muscular fibres,
Fibrous membrane,	Glands.
Mucous membrane,	

The *Fibro-cartilaginous rings* are from fifteen to twenty in number, and extend for two-thirds around the cylinder of the trachea. They are deficient at the posterior part, where the tube is completed by fibrous membrane. The last ring has usually a triangular form in front. The rings are connected to each other by a membrane of *yellow elastic fibrous tissue*, which in the space between the extremities of the cartilages, posteriorly, forms a distinct layer.

The *Muscular* fibres form a thin layer, extending transversely between the extremities of the cartilages. On the posterior surface they are covered in by a cellulo-fibrous lamella, in which are lodged the *tracheal glands*. These are small flattened ovoid bodies, situated in great number between the fibrous and muscular layers of the membranous portion of the trachea, and also between the two layers of elastic fibrous tissue connecting the rings. They pour their secretion upon the mucous membrane.

Thyroid Gland.

The *Thyroid gland* consists of two lobes, which are situated one on each side of the trachea, and are connected with each other by means of an *isthmus*, which crosses its upper rings. There is considerable variety in the situation and breadth of this isthmus; which should be recollected in the performance of operations upon the trachea. The gland is larger in young subjects, and in females, than in the adult and males. It is the seat of an enlargement called bronchocele, goitre, or the Derbyshire neck.

A muscle is occasionally found connected with its upper border or with its isthmus, and attached, superiorly, to the body of the os hyoides. It was named by Sæmmering the "*Levator glandulæ thyroideæ.*"

Vessels and Nerves.—It is abundantly supplied with blood by the superior and inferior thyroid arteries. Sometimes an additional artery is derived from the arteria innominata, and ascends upon the front of the trachea to be distributed to the gland. The wounding of this vessel in tracheotomy, might be fatal to the patient.

The *Nerves* are derived from the superior laryngeal and sympathetic.

THE ORBIT.

The student should now direct his attention to the anatomy of the orbit, and of the fifth pair of nerves.

To open the orbit (the calvarium and brain having been removed) the frontal bone must be sawn through at the inner extremity of the orbital ridge; and externally, at its outer extremity. The roof of the orbit may then be comminuted with the hammer; a process easily performed, on account of the thinness of the orbital plate of the frontal bone and lesser wing of the sphenoid. The superciliary portion of the orbit may now be driven forwards by a smart blow, and the broken fragments of the roof of the orbit removed. The periosteum will then be exposed unbroken and undisturbed.

Remove the periosteum from the whole of the upper surface of the exposed orbit, and the muscles, vessels, and nerves may then be examined.

The contents of the orbit are, 1st. The globe of the eye appended to the extremity of the optic nerve. 2d. The six

muscles which move the eyeball, four recti and two obliqui, and the elevator muscle of the upper eyelid. 3d. The ophthalmic artery, with its numerous branches. 4th. The ophthalmic vein with its tributaries. 5th. The nerves, which consist of three branches of the ophthalmic—frontal, lachrymal, and nasal; the third, fourth, and sixth, to the muscles and the ciliary ganglion with its branches. 6th. The lachrymal gland.

We shall pursue the plan of the examination of the orbit, that we have heretofore followed in the examination of the neck. Studying the muscles and the more prominent relations of the various structures on the one side, and the vessels and nerves on the opposite.

In the middle line is the levator palpebræ muscle, and resting upon it the frontal nerve, with its accompanying artery, the supra-orbital. To the inner side is the obliquus superior, and running along its border the fourth nerve posteriorly, and the infra-trochlear branch in front. To the outer side is the upper border of the external rectus supporting the lachrymal artery and nerve, and in front the lachrymal gland.

If now the levator palpebræ muscle, and with it the frontal nerve and artery be divided through the middle and turned aside, the superior rectus will be seen occupying the middle place, and if the obliquus superior be also divided and its ends thrown aside, the upper margin of the internal rectus will occupy the inner side supporting the infra-trochlear nerve.

Next divide the superior rectus through the middle, and draw its ends asunder, in doing which some branches of the third nerve may be seen entering its under surface, and a third plane will be brought into view. This requires to be freed of a large quantity of fat, before the structures situated in it can be fully seen. The student must work cautiously and unweariedly, until he has removed every particle of this fat, which however is not difficult to do from its being contained in areolæ of loose cellular tissue.

In the middle line he will now perceive the optic nerve, crossed from without inwards by the ophthalmic artery and nasal nerve, and having to its outer side the ascending branch of the third nerve, the ciliary ganglion with its branches, the ciliary arteries, and a little more externally, in contact with the external rectus muscle, the sixth nerve.

Next divide the optic nerve through its middle, and draw

it forwards, when a layer will be observed, which is formed by the inferior rectus muscle supporting the long branch of the third nerve in the middle line; and in front, the inferior oblique muscle connected with the globe of the eye.

A tabular arrangement of these structures will probably enable the student to learn their respective relations with more facility. The plan represents the right orbit.

The student should now commence the examination of the muscles of the orbit; and, in order to render them tense and more easy of dissection, he should inject the globe of the eye with tallow or wax. This is easily done by pushing a probe through the optic nerve into the globe of the eye, in order to break down the cribriform plate of the sclerotic coat, and then inserting an injection pipe.

The *Muscles of the orbit* are seven:—

Levator palpebræ,	Internal rectus,
Superior rectus,	Superior oblique,
Inferior rectus,	Inferior oblique.
External rectus,	

The *Levator palpebræ* arises from the common tendon. This tendon is common to all the muscles of the orbit, with the exception of the inferior oblique, and is attached to the bones immediately around the optic foramen. The muscle is *inserted* into the tarsal cartilage of the upper eyelid.

The *Superior rectus* arises from the common tendon, and is *inserted* into the upper surface of the globe of the eye.

The *Internal rectus* arises from the common tendon, and is *inserted* into the outer surface of the globe of the eye.

The *External rectus* arises by two heads, one from the common tendon, the other from the edge of the greater ala of the sphenoid bone. It is *inserted* into the outer surface of the globe of the eye.

The *Inferior rectus* arises from the common tendon, and is *inserted* into the under surface of the globe of the eye.

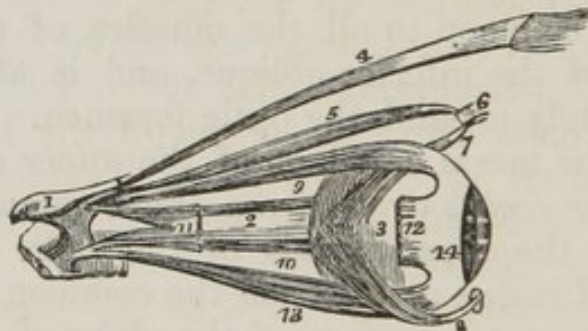
The *Obliquus superior* arises from the common tendon, and runs forwards to the pulley beneath the internal angular process of the frontal bone. Its tendon is thence reflected to its *insertion* upon the posterior and external surface of the globe of the eye, beneath the superior rectus.

The *Inferior oblique* arises from the nasal process of the superior maxillary bone, and passes outwards beneath the in-

ferior rectus and eyeball, to be *inserted* into its posterior and external surface beneath the external rectus.

ACTIONS.—The levator palpebræ raises the upper eyelid. The four recti, acting singly, pull the eyeball in the four directions of upwards, downwards, inwards, and outwards. Acting by pairs, they carry the eyeball in the diagonal of these directions, viz. upwards and inwards, upwards and outwards, downwards and inwards, or downwards and outwards. Acting all together, they retract the globe within the orbit, as occurs in cholera. The superior oblique muscle, acting alone, rotates the globe inwards and forwards, and carries the pupil outwards and downwards to the lower and outer angle of the orbit. The inferior oblique, acting alone, rotates the globe outwards and upwards, and carries the pupil outwards and upwards to the upper and outer angle of the eye. Both muscles acting together, draw the eyeball forwards, and give the pupil that slight degree of eversion which enables it to receive the largest field of view.

Fig. 47. The muscles of the eyeball; the view is taken from the outer side of the right orbit.



1. A small fragment of the sphenoid bone around the entrance of the optic nerve into the orbit. 2. The optic nerve. 3. The globe of the eye. 4. The levator palpebræ muscle. 5. The superior oblique muscle. 6. Its cartilaginous pulley. 7. Its reflected tendon. 8. The inferior oblique muscle, the small square knob at its commencement is a piece of its bony origin broken off. 9. The superior rectus. 10. The internal rectus almost concealed by the optic nerve. 11. Part of the external rectus, showing its two heads of origin. 12. The extremity of the external rectus at its insertion; the intermediate portion of the muscle having been removed. 13. The inferior rectus. 14. The tunica albuginea, formed by the expansion of the tendons of the four recti.

The opposite orbit should now be opened in the way already directed, with a view to study the distribution of the nerves and vessels.

Nerves of the Orbit.

The student should remove with a chisel as much of the outer wall of the orbit as possible, and break away the anterior clinoid process. Then let him remove the thin layer of dura mater that forms the outer boundary of the cavernous sinus. He will thus expose the four nerves passing by the side of the "sella turcica" to enter the orbit through the sphenoidal fissure. These should be separately and carefully traced through their course: they are the

- Third or motor oculi (*fig. 49. 3.*)
- Fourth or patheticus, 4.,
- Ophthalmic or first division of the fifth, 13.,
- Sixth or abducens, 6.

They are placed in the above order from above downwards, at their *entrance* into the cavernous sinus; but the ophthalmic nerve soon divides into its three branches, *frontal*, *lachrymal*, and *nasal*, and the relative situation of the others is also changed with regard to each other. At the sphenoidal fissure, the six nerves are disposed in two sets, a *superior* consisting of

- Fourth (*fig. 49. 4.*)
- Frontal, 16.,
- Lachrymal, 17.,

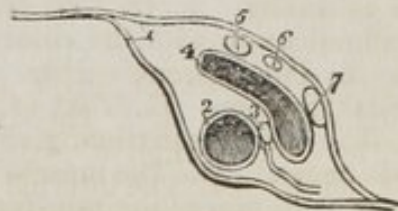which enter the orbit above the origin of the levator palpebræ muscle; and an *inferior set*, the

- Nasal (*fig. 49. 18.*)
- Third, 3.,
- Sixth, 6.,

which enter the orbit between the two heads of the external rectus muscle.

While passing by the side of the sella turcica, the third, (*fig. 48. 5.*) fourth, 6., and ophthalmic, 7., nerves, are situated in the outer wall of the sinus, 4.; the sixth, 3., and internal carotid artery, 2., being placed in the inner wall.

Fig. 48. A transverse section of the cavernous sinus of the right side.

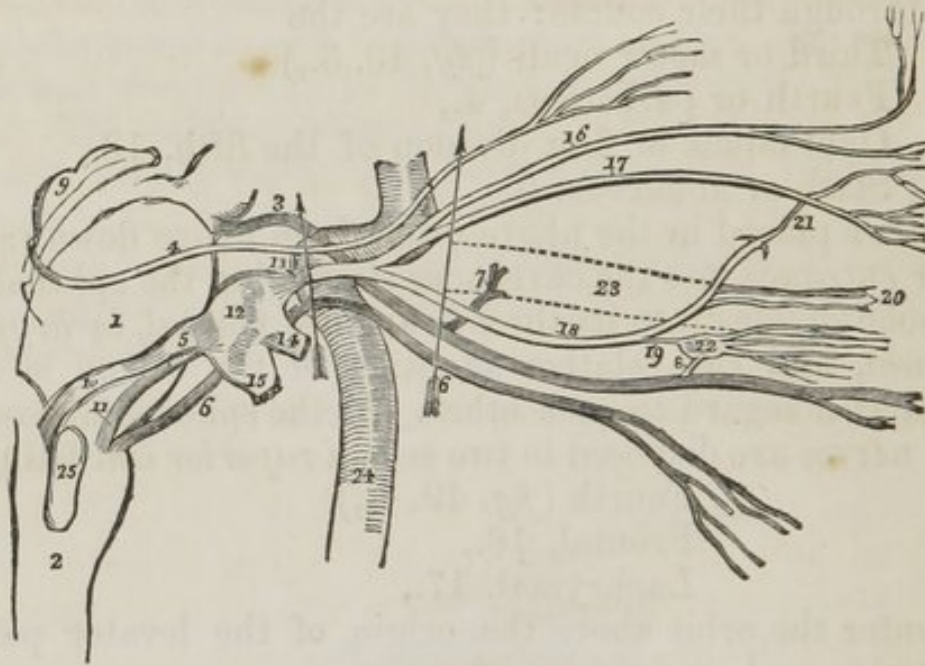


1. The dura mater, splitting to enclose the vessels and nerves. 2. The internal carotid artery. 3. The sixth nerve, receiving a branch from the sympathetic. 4. The cavernous sinus. 5. The third nerve. 6. The fourth nerve. 7. The ophthalmic division of the fifth nerve.

The OPHTHALMIC NERVE (*fig. 49. 13. fig. 50. 2.*) arises from

the Casserian ganglion, beneath the dura mater, and passes forwards through the outer wall of the cavernous sinus, lying externally to the other nerves, and divides into its three branches. Previously to its division, it gives off a small *recurrent nerve*,* that passes backwards between the two layers of tentorium, as far as the lateral sinus.

Fig. 49. The origin, course, and distribution of the nerves of the orbit. The pons Varolii, and medulla oblongata are in outline, and the horizontal portion of the carotid artery marks the situation of the cavernous sinus.



1. The pons Varolii. 2. The medulla oblongata. 3. The third nerve, arising from the crus cerebri. 7. Its ascending branch. 8. Its communication with the ciliary ganglion. 4. The fourth nerve, arising from the valve of Vieussens, immediately below the corpora quadrigemina, 9. 5. The fifth nerve, arising by two roots. 10. The posterior root from the corpus restiforme. 11. The anterior root from the corpus pyramidale. 12. The Casserian ganglion. 13. Its ophthalmic division. 14. Its superior maxillary division. 15. Its inferior maxillary division. 16. The frontal branch of the ophthalmic nerve. 17. The lachrymal branch. 18. The nasal. 19. Its communication with the ciliary ganglion. 20. Its ciliary branches. 21. The infra-trochlear branch, given off just as the nerve enters the anterior ethmoidal foramen. 6. 6. The sixth nerve, arising from the corpus pyramidale. 22. The ciliary ganglion, giving off ciliary nerves. 23. The outline of the optic nerve. 24. The internal carotid artery. 25. The corpus olivare. The arrow at 3. marks the relative situation of the four nerves of the orbit, as

* This recurrent nerve to the dura mater is sometimes a branch of the fourth nerve, of which distribution the author has a preparation now before him. Arnold of Heidelberg, an authority of great weight, assigns it solely to the ophthalmic, and has displayed its distribution in a beautifully dissected preparation which the author has also attentively examined. It was from this preparation that his beautiful plate was drawn.

they enter the cavernous sinus. The third is the highest, then the fourth, next the ophthalmic division of the fifth, and then the sixth. The arrow at 6. marks the relation of the six nerves as they enter the sphenoidal fissure;—the three superior, fourth, frontal, and lachrymal enter the orbit above the origin of the levator palpebræ;—the three inferior, nasal, third, and sixth, pass between the two heads of the external rectus.

The *Branches* of the ophthalmic nerve are, the

Frontal,
Lachrymal,
Nasal.

The *Frontal* nerve (*fig.* 49 16.) mounts above the levator palpebræ, and runs forwards, resting upon that muscle to the supra-orbital foramen, through which it escapes upon the forehead, and supplies the integument of that region.

It gives off one small branch, the *supra-trochlear* (*fig.* 50. 4.,) which passes inwards above the pulley of the superior oblique muscle, and is distributed to the integument at the inner angle of the eye and root of the nose.

The *Lachrymal* nerve* (*fig.* 49. 17.) is the smallest of the three. It inclines slightly outwards to the upper border of the external rectus muscle, along which it runs to the lachrymal gland and upper eyelid, to which it is distributed. A small branch pierces the malar bone, and communicates with the facial nerve.

The *Nasal* nerve (*fig.* 49. 18.) passes forwards between the two heads of the external rectus muscle, crosses the optic nerve in company with the ophthalmic artery, and enters the anterior ethmoidal foramen (*fig.* 50. 8.) immediately above the internal rectus. It then traverses the upper part of the ethmoid bone to the cribriform plate, and passes downwards through the most anterior of its foramina into the nose, where it divides into two branches, *one* supplying the mucous membrane, near the anterior openings of the nares; the *other*, passing out between the fibro-cartilages, is distributed on the integument at the extremity of the nose.

Branches.—Within the orbit it gives off three branches.

* Mr. Swan, in his dissections of the nerves, has found the *lachrymal* nerve to be formed by a branch from the ophthalmic and one from the fourth nerve; and he describes this mode of formation as its normal origin. We have sometimes seen the lachrymal nerve arising in this manner, but more frequently proceeding directly from the ophthalmic, without any communication with the fourth nerve.

A *ganglionic* branch (*fig. 50. 7.*) (given or received) from the superior angle of the ciliary ganglion.

One or two *ciliary* filaments (*fig. 49. 20.*) which leave the nerve as it crosses the optic nerve. They pierce the sclerotic, and pass between that tunic and the choroid to the iris.

The *Infra trochlear* (*fig. 50. 9.*) is given off just as the nerve is about to enter the anterior ethmoidal foramen. It passes along the superior border of the internal rectus to the inner angle of the eye, where it is distributed.

The **FOURTH NERVE** (*fig. 49. 4.*) (patheticus,) the smallest of the cerebral nerves, arises from the valve of Vieussens, and enters the cavernous sinus through a canal in the tentorium, close to the opening which transmits the fifth nerve. It is at first placed below the third nerve, but ascends above it as it passes forwards and crosses the levator palpebræ to be distributed on the orbital surface of the superior oblique muscle.

The **THIRD NERVE** (*fig. 49. 3.*) (motor oculi) arises from the crus cerebri, and enters the cavernous sinus by an opening in the dura mater, close to the posterior clinoid process. It then descends to the space between the two heads of the external rectus, and, entering the orbit, divides into two branches, a superior and an inferior branch: it also communicates with the ciliary ganglion by means of a short trunk.

The *Superior branch*, 7., mounts above the optic nerve to supply the superior rectus, levator palpebræ, and internal rectus.

The *Inferior branch* runs forwards upon the inferior rectus muscle, and is distributed to it and the inferior oblique.

The *Ganglionic branch*, 8., short and thick, passes to the inferior angle of the ciliary ganglion.

The **SIXTH NERVE** (*fig. 49. 6.*) (abducens) arises from the upper part of the corpus pyramidale. It pierces the dura mater on the basilar process of the sphenoid bone, and enters the cavernous sinus behind the ophthalmic nerve, by which it is concealed in its whole course. Passing between the two heads of the external rectus muscle, it soon enters its substance, and is distributed to that muscle. It is the only nerve situated in the inner wall of the cavernous sinus.

Branches.—The two ascending branches of the carotid plexus pass upwards by the side of the internal carotid artery, and communicate with this nerve in the cavernous sinus. See page 164.

The CILIARY GANGLION (*fig. 49. 22.*) (lenticular) is a small square-shaped ganglion, situated close to the outer side of the optic nerve. It receives branches at its two posterior angles, from the nasal branch of the ophthalmic and inferior branch of the third nerve.

Branches.—From its anterior border it gives off eight or nine filaments, which arrange themselves into two sets: a *superior* set pierce the sclerotic slightly above the entrance of the optic nerve, and an *inferior* set below it. A posterior filament is described by Arnold as passing backwards from the ganglion to the cavernous sinus, and following the course of the carotid artery to its plexus.

Vessels of the Orbit.

THE OPHTHALMIC ARTERY is a branch of the internal carotid: it enters the orbit through the foramen opticum, immediately to the outer side of the optic nerve. It then crosses the optic nerve, and runs along the inner wall of the orbit to the inner angle of the eye, where it divides into two branches, the frontal and nasal: the latter inosculates very freely with the *angular artery*.

Branches.—Its branches may be arranged into three groups:—1st, those distributed to the circumference of the orbit; 2d. Muscular branches; 3d. Branches supplying the globe of the eye.

- 1st. Lachrymal,
Supra-orbital,
Posterior ethmoidal,
Anterior ethmoidal,
Palpebral,
Frontal,
Nasal.
- 2d. Muscular—anterior ciliary.
- 3d. Ciliary,
Centralis retinae.

The *Lachrymal* is the first branch of the ophthalmic artery, and is usually given off before that artery enters the optic foramen. It follows the course of the lachrymal nerve, along the upper border of the external rectus muscle, and is distributed to the lachrymal gland and upper eyelid.

The *Supra-orbital* artery follows the course of the frontal

nerve, resting on the levator palpebræ muscle: it passes through the supra-orbital foramen, and is distributed to the muscles and integument of the forehead.

The *Ethmoidal* arteries, *posterior* and *anterior*, pass through the ethmoidal foramina, and are distributed to the ethmoidal cells and nasal fossæ.

The *Palpebral* arteries, superior and inferior, encircle the eyelids to which they are distributed.

The *Frontal* artery, one of the terminal branches of the ophthalmic, emerges from the orbit at its inner angle, and is distributed upon the middle of the forehead.

The *Nasal* artery, the other terminal branch of the ophthalmic, distributes a branch to the ridge of the nose, and inosculates with the *angular artery*.

The *Muscular branches*, usually two in number, *superior* and *inferior*, supply the muscles of the orbit; and upon the anterior aspect of the globe of the eye give off the *anterior ciliary* arteries, which pierce the sclerotic near its margin of connexion with the cornea, and supply the iris. It is the congestion of these vessels that gives rise to the vascular zone around the cornea in iritis.

The *Ciliary arteries* are divided, according to their extent, into short, long, and anterior.

The *Short ciliary*, very numerous, pierce the sclerotic around the entrance of the optic nerve, and supply the choroid coat and ciliary processes. The *long ciliary*, two in number, pierce the sclerotic upon opposite sides of the globe of the eye, and pass forwards between it and the choroid to the iris to which they are distributed. The *anterior* have been described.

The *Centralis retinæ* artery pierces the optic nerve, and passes forwards in the centre of its cylinder to the retina, where it divides into branches, which form the inner layer of that membrane. It supplies the retina, hyaloid membrane, and capsule of the lens, by means of a branch sent forwards through the centre of the vitreous humour.

The OPTHALMIC VEIN collects the venous blood from all parts of the orbit, and forms a large trunk, which crosses the optic nerve with the ophthalmic artery, and passes between the two heads of the external rectus, to open into the cavernous sinus.

FIFTH PAIR OF NERVES.

The student should now proceed to the dissection of the fifth pair of nerves. For this purpose the contents of the orbit should be entirely removed, and its external wall sawn through nearly to a level with its floor. Then reflect the dura mater from the anterior surface of the petrous bone, so as to expose the Casserian* ganglion and its three divisions.

The *Fifth nerve* (trigeminus, trifacial) arises by two roots, *one* from the corpus pyramidale (*fig.* 49. 11.;) the *other*, 10., from the corpus restiforme. The nerve pierces the dura mater at the insertion of the tentorium into the extremity of the petrous bone, and forms the large ganglion of a semilunar form called *Casserian* (*fig.* 49. 12., *fig.* 50. 1.) The ganglion immediately divides into the three large nerves, the ophthalmic, superior maxillary, and inferior maxillary.

The *Ophthalmic* has just been described with the contents of the orbit. We must now examine the maxillary nerves.

The SUPERIOR MAXILLARY NERVE (*fig.* 50. 10.) passes forwards to the foramen rotundum, crosses the sphenomaxillary fossa, and enters the canal in the floor of the orbit, along which it runs to the infra-orbital foramen. Emerging on the face, beneath the levator labii superioris muscle, it divides into a lash of branches, 16., which are distributed to the muscles and integument of the cheek, and form a plexus with the facial nerve.

Branches :—

In the sphenomaxillary fossa.

Two from Meckel's ganglion, <i>fig.</i> 50.	12.
Orbital - - - - -	11.
Posterior dental - - - - -	13.

In the infra-orbital canal.

Middle dental - - - - -	14.
Anterior dental - - - - -	15.

On the face.

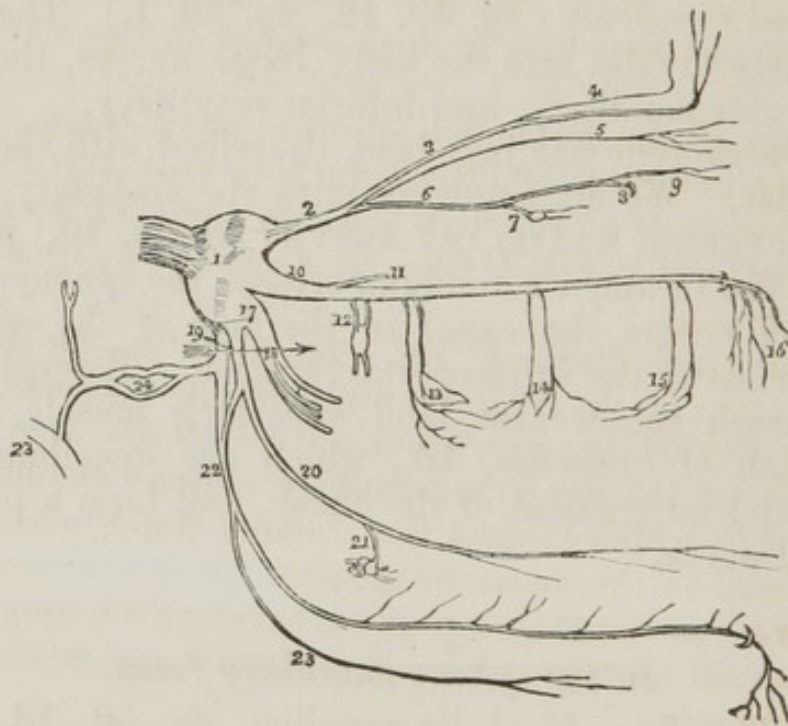
Muscular } - - - - -	16.
Cutaneous }	

* Julius Casserius was appointed to fill the Anatomical Chair in Padua, in 1609. He died in 1627.

The *Two branches* (fig. 50. 12.) from Meckel's ganglion ascend from that body to join the nerve, as it crosses the sphenomaxillary fossa.

The *Orbital branch* (fig. 50. 11.) enters the orbit through the sphenomaxillary fissure, and divides into two branches; *lachrymal*, which ascends along the outer wall of the orbit to the lachrymal gland, and communicates with the lachrymal nerve; *temporo-malar*, which passes forwards and divides into two branches, one piercing the malar bone, and distributed to the integument of the cheek; the other escaping through the outer wall of the orbit, to supply the temporal muscle.

Fig. 50. The branches of the fifth nerve.



1. The Casserian ganglion. 2. The ophthalmic nerve. 3. The frontal nerve. 4. Its supra-trochlear branch. 5. The lachrymal nerve. 6. The nasal nerve. 7. Its branch of communication with the ciliary ganglion. 8. The passage of the nerve through the anterior ethmoidal foramen. 9. The infra-trochlear nerve. 10. The superior maxillary nerve. 11. Its orbital branch. 12. The branches of communication with Meckel's ganglion. 13. The posterior dental branches. 14. Middle dental branches. 15. The anterior dental branches. 16. The infra-orbital branches. 17. The inferior maxillary nerve. 18. Its external or muscular division. 19. The internal division of the inferior maxillary nerve. The arrow marks the separation of these two divisions of the nerve by the external pterygoid muscle. 20. The gasserian ganglion. 21. The branch of communication with the submaxillary ganglion. 22. The inferior dental nerve, arising by two roots. 23. Its mylo-hyoidean branch. 24. The auricular nerve. 25. Its branch of communication with the facial nerve.

The *Posterior dental* branches (*fig. 50. 13.*) pass through small foramina, in the posterior surface of the superior maxillary bone, and supply the posterior teeth.

The *Middle* and *Anterior dental* branches (*fig. 50. 14. 15.*) descend to the teeth, the former beneath the lining membrane of the antrum, the latter through distinct canals in the walls of the bone.

The INFERIOR MAXILLARY NERVE (*fig. 50. 17.*) is the largest of the three divisions of the Casserian ganglion, and is augmented in size by the anterior root of the fifth, which passes behind the ganglion, and unites with the inferior maxillary, previously to its exit from the foramen ovale. By turning up the ganglion, this portion of the nerve may be easily seen, as a white rounded cord, altogether different in appearance and structure from the ganglion, against which it lies.

Escaping at the foramen ovale the nerve divides into two portions, an external, 18., into which is traced the whole of the anterior root of the fifth, and an internal, 19.; the two portions being separated from each other by the external pterygoid muscle.

The *External* division, 18., obtaining the whole of the motor function of the fifth, by means of its anterior root, immediately divides into five branches, which are distributed to the muscles of the temporo-maxillary region: these are—

Masseteric, which crosses the sigmoid notch with the masseteric artery to the masseter muscle.

Temporal, two branches passing between the upper border of the external pterygoid muscle and the temporal bone to the temporal muscle.

Buccal, a large branch which pierces the fibres of the external pterygoid, to reach the buccinator muscle.

External pterygoid, to the external pterygoid muscle.

Internal pterygoid, to the internal pterygoid muscle.

To see the branches of the internal division requires a little additional dissection. The external wall of the orbit having been already removed to trace the superior maxillary nerve, the student should make a section through the great ala of the sphenoid bone to near the foramen rotundum. Another incision should be carried parallel with the margin of the petrous bone to near the foramen ovale, and the intervening portion of bone broken away with the hammer. The chisel

and hammer will complete the removal of the remaining bone, if the nerve be not already exposed as it is passing through the foramen ovale. The external pterygoid muscle, which has hitherto protected the nerves from the saw and hammer, is then to be removed, and the nerves, as they lie upon the internal pterygoid, cleared of fat and cellular tissue.

The *Internal division* (*fig. 50. 19.*) of the inferior maxillary nerve divides into three large branches:—

Gustatory,	Auricular.
Inferior dental,	

The GUSTATORY NERVE (*fig. 50. 20.*) descends between the two pterygoid muscles to the side of the tongue, where it becomes flattened, and divides into numerous filaments, which are distributed to the papilæ and mucous membrane.

Relations.—It lies at first between the two pterygoid muscles, next between the internal pterygoid and ramus of the jaw, then between the stylo-glossus muscle and submaxillary gland; lastly, it runs along the side of the tongue, resting upon the hyo-glossus muscle, and covered in by the mylo-hyoideus and mucous membrane.

Branches.—While between the pterygoid muscles, it receives the chorda tympani, which joins it at an acute angle. At the submaxillary gland, the chorda tympani, 21., quits the nerve to enter the submaxillary ganglion. While resting on the hyo-glossus muscle, it sends filaments of communication (*fig. 40. **) to the lingual nerve, which is also situated upon this muscle.

The INFERIOR DENTAL NERVE (*fig. 50. 22.*) arises from the inferior maxillary by two nervous cords, between which passes the anterior meningea media. It descends to the dental foramen with the inferior dental artery, between the internal lateral ligament and the ramus of the lower jaw. It then runs along the canal in the inferior maxillary bone, distributing branches to the teeth, and emerges upon the chin at the mental foramen, where it communicates with branches of the facial nerve, and is distributed to the integument.

It gives off but one branch, the *mylo-hyoidean*, 23., which leaves the nerve just as it is about to enter the dental foramen. This branch pierces the insertion of the internal lateral ligament, and descends along a groove in the bone to the external surface of the mylo-hyoid muscle, to which it is distributed.

The AURICULAR NERVE (*fig. 50. 24.*) passes directly backwards behind the articulation of the lower jaw, against which it rests. In this situation it divides into two branches, which reunite, and form a kind of plexus. From the plexus two branches are given off—one, 25., to communicate with the facial nerve in the parotid gland. The *other*, or *temporal branch*, ascends upon the root of the zygoma in front of the external ear, and is distributed to the pinna, the meatus, and the integument of the temple. It is pressure upon this nerve, which produces the agony of pain in abscess in the meatus.

CRANIAL GANGLIA OF THE SYMPATHETIC.

Six sympathetic ganglia are described as existing in the head: they are, the

Ganglion of Ribes,	Naso palatine, or Cloquet's,
Ciliary ganglion,	Otic, or Arnold's,
Spheno-palatine, or Meckel's,	Submaxillary ganglion.

The *Ganglion of Ribes* is a small ganglion of communication between the sympathetic filaments of the anterior cerebral arteries. It is situated on the anterior communicating artery.

The remaining five ganglia are situated in relation with the fifth nerve and its branches. Thus,

The *Ciliary ganglion* communicates with the nasal branch of the ophthalmic nerve.

The *Spheno-palatine* is the sympathetic ganglion of the superior maxillary nerve.

The *Naso-palatine* ganglion (if it exist) is a dependence on the spheno-palatine.

The *Otic ganglion* is situated on the internal pterygoid nerve, in relation with the motor root of the inferior maxillary nerve.

The *Submaxillary ganglion* communicates with the gustatory nerve.

We shall describe them here,* in the order in which they are best dissected; the ganglion of Ribes belongs to the consideration of the brain; and the ciliary has been already noticed, page 183.

* A more minute description of these ganglia, with an engraving, will be found in the Chapter "On the Sympathetic Nerve."

OTIC GANGLION.—A small ganglion discovered by Arnold, of Heidelberg, is situated in contact with the internal surface of the inferior maxillary nerve, near to the foramen ovale. A good demonstration of this ganglion requires a fresh subject and an especial dissection. In an ordinary dissection it will be best seen by dividing the inferior maxillary nerve at the foramen ovale, and drawing it outwards with hooks. The student should then dissect its inner surface carefully, under a strong light, and he will perceive a small ash-coloured body upon the course of the internal pterygoid nerve. Its filaments are too small to be seen in this dissection; they communicate with the motor root of the inferior maxillary, the auricular, tympanic, facial, and sympathetic nerves, and two are distributed to the two muscles, tensor tympani and tensor palati.

The spheno-palatine ganglion should next be examined: for this purpose the root of the pterygoid process must be broken away with the chisel. A glance at the base of the skull will show the student how far this incision should be carried. The two descending branches from the superior maxillary nerve are the proper guides to the ganglion.

The **SPHENO-PALATINE** ganglion (Meckel's) is the largest of the cranial ganglia, and is situated in the pterygo-maxillary fossa. It gives off branches in four different directions.

Upwards, two branches to communicate with the superior maxillary nerve.

Downwards, the posterior palatine nerves.

Inwards, spheno-palatine or nasal branches.

Backwards, the Vidian nerve.

The *Posterior palatine* nerves, three in number, descend through the palatine canal to the posterior palatine foramina, distributing branches to the mucous membrane of the nose, Eustachian tube, and palate.

The *Nasal branches* pass into the nose through the sphenopalatine foramen, supplying the mucous membrane, covering the turbinate bones and septum. One of the latter, longer than the rest, (*naso-palatine branch*,) descends by the side of the septum to the naso-palatine canal, where it communicates with the naso-palatine ganglion.

The *Vidian** nerve passes directly backwards through the

* Vidus Vidius, Professor of Anatomy in the College of France, in 1542,

pterygoid canal, and divides into two branches, *carotid* and *petrosal*.

The *Carotid branch* enters the carotid canal, and communicates with the carotid plexus. (Page 164.)

The *Petrosal branch* enters the skull through the foramen lacerum basis cranii, and passes backwards beneath the Casserian ganglion to the hiatus Fallopii, on the anterior aspect of the petrous bone, where it unites with the facial just as that nerve is forming its angular bend. Near to the stylo-mastoid foramen, it is reflected backwards from the facial nerve, and crosses the tympanum in a curved direction between the handle of the malleus and long process of the incus, and assumes the name of *chorda tympani*. Escaping from the tympanum through the fissura Glaseri, it descends to the gustatory nerve, which it joins at an acute angle; and at the submaxillary gland it quits that nerve to enter the submaxillary ganglion.

The SUBMAXILLARY GANGLION is situated in the submaxillary gland, close to the gustatory nerve, to which it is connected by the nerve above described, and by several smaller branches. It sends off a number of filaments, which are distributed upon the ducts of the submaxillary gland.

The NASO-PALATINE GANGLION (Cloquet's) is described by Cloquet as occupying the naso-palatine canal, giving branches, *anterior palatine* to the palate, and communicating with Meckel's ganglion by means of the *naso-palatine* nerve.

Its existence is denied by Arnold, who has shown the naso-palatine passing as a distinct nervous filament through the naso-palatine canal to the papilla on the palate behind the incisor teeth. Cruveilhier, also, has been unable to find this ganglion. The sympathetic system will be found described as a whole in Chapter XI.

PHARYNX.

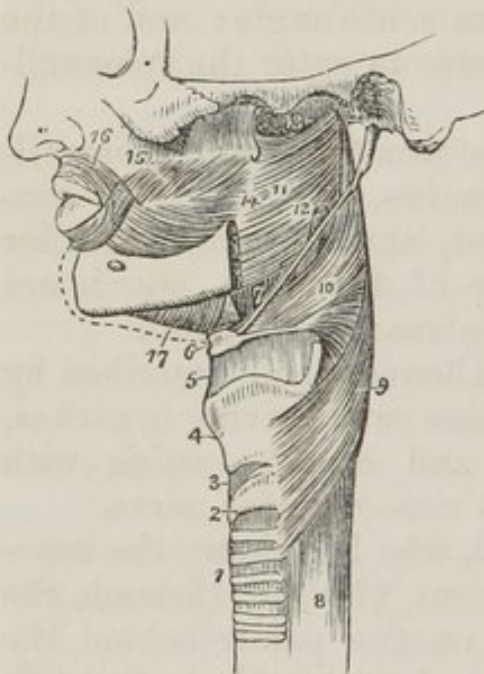
The student should now proceed to examine the remainder of the muscles of the neck, together with the anatomy of the pharynx and larynx. For this purpose the following preparation must be made. The trachea and œsophagus are to be cut through at the lower part of the neck, and drawn up-

and in Pisa, in 1547. He was the predecessor of Sylvius, in the College of France. His "Anatomia Corporis Humani" was published, in 1611, at Venice, after his death.

wards by dividing the loose cellular tissue which connects the pharynx to the vertebral column. The saw is then to be applied behind the styloid processes, and the base of the skull sawn through. The vessels and loose structures should be removed from the preparation, and the pharynx stuffed with tow or wool for the purpose of distending it, and rendering the muscles more easy of dissection.

The *Pharynx* is a musculo-membranous sac, situated upon the vertebral column, and extending from the base of the skull to a point parallel with the cricoid cartilage, where it becomes constricted to form the œso-

Fig. 51. A side view of the muscles of the pharynx.



1. The trachea. 2. The cricoid cartilage. 3. The crico-thyroid membrane. 4. The thyroid cartilage. 5. The thyro-hyoidean membrane. 6. The os hyoides. 7. The stylo-hyoidean ligament. 8. The œsophagus. 9. The inferior constrictor. 10. The middle constrictor. 11. The superior constrictor. 12. The stylo-pharyngeus muscle passing down between the superior and middle constrictor. 13. The upper concave border of the superior constrictor; at this point the muscular fibres of the pharynx are deficient. 14. The pterygo-maxillary ligament. 15. The buccinator muscle. 16. The orbicularis oris. 17. The mylo-hyoideus.

The *Constrictor medius* arises from the great cornu of the os hyoides, from the lesser cornu, and from the stylo-hyoidean ligament. It radiates from its origin upon the side of the pharynx, its lower fibres descending and being overlapped by

phagus.
The *Muscles* of the pharynx are, the Constrictor inferior, Constrictor medius, Constrictor superior, Stylo-pharyngeus, Palato-pharyngeus.

The *Constrictor inferior* arises from the two upper rings of the trachea, from the cricoid, and the side of the thyroid cartilage. It is *inserted* into the tendinous *raphé* overlapping the middle constrictor. This muscle must be removed before the next can be examined.

In dissecting the surface of the next muscle, the pharyngeal plexus will require to be removed.

the constrictor inferior, its upper fibres ascending so as to cover in the constrictor superior. It is *inserted* into the *raphé* and basilar process of the occipital bone.

The upper portion of this muscle must be turned down, to bring the whole of the superior constrictor into view; in so doing, the stylo-pharyngeus muscle will be seen passing beneath its upper border.

The *Constrictor superior* arises from the extremity of the molar ridge of the lower jaw, from the pterygo-maxillary ligament, and from the lower half of the internal pterygoid plate. Its fibres curve around the pharynx, to be *inserted* into the *raphé* and basilar process of the occipital bone. It is overlapped by the middle constrictor. The upper part of the pharynx, on each side between the base of the skull and the upper curved border of the superior constrictor, is deficient of muscular fibres, being completed only by the mucous membrane.

The *Stylo-pharyngeus* muscle arises from the inner side and base of the styloid process: it descends between the superior and middle constrictor muscles, and is *inserted* into the posterior border of the thyroid cartilage. This muscle is the guide in dissection to the glosso-pharyngeal nerve, which runs along its lower border, and crosses it opposite the root of the tongue. Lower down it is in relation with the pharyngeal branch of the pneumogastric nerve, which passes to the middle constrictor to form the pharyngeal plexus.

The *Palato-pharyngeus* is described with the muscles of the soft palate. It arises from the soft palate, and is *inserted* into the inner surface of the pharynx.

ACTIONS.—The three constrictor muscles contract upon the morsel of food as soon as it is received by the pharynx, and convey it gradually downwards into the œsophagus. The stylo-pharyngei draw the pharynx upwards and widen it laterally. The palato-pharyngei also draw it upwards, and narrow the opening of the fauces.

Interior of the Pharynx.

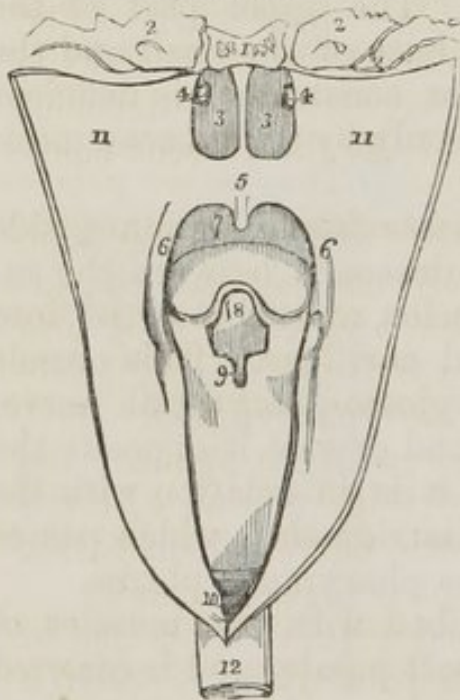
After examining the exterior of the pharynx with its muscles, it should be laid open in order to examine the interior. For this purpose, an incision should be made along the middle line posteriorly, and the sides drawn out and pinned aside.

There are *seven openings* in the pharynx:—

Posterior nares, two,	Larynx,
Eustachian tubes, two,	Œsophagus.
Mouth,	

The *Posterior nares* (*fig. 52. 3. 3.*) are the two large openings at the upper and front part of the pharynx. On either side is the irregular depression in the mucous membrane, marking the entrance of the *Eustachian tube*, 4. Beneath the posterior nares is the large opening into the *mouth*, 7., and beneath it the opening of the larynx, 8. The *œsophageal* opening, 10., is the lower constricted portion of the pharynx.

Fig. 52. The openings into the pharynx.



The opening into the mouth is partly concealed by a moveable curtain, which is called soft palate, or *velum pendulum palati*: the opening itself is named *fauces*.

SOFT PALATE (*fig. 52. 5.*)—Hanging from the middle of the soft palate, is a rounded process, the uvula. From the uvula, on each side, the soft palate forms an arch, which is continued into two projecting pillars or half arches that are continuous below with the sides of the base of the tongue and pharynx. Between the projecting pillars is a niche lodging the tonsil.

1. The basilar process of the occipital bone. 2. 2. The petrous portion of the temporal bone. 3. 3. The posterior nares, separated by the vomer. 4. 4. The openings of the Eustachian tubes. 5. The soft palate. 6. 6. The posterior arches of the soft palate. 7. The opening from the mouth. 8. The epiglottis. 9. The opening into the larynx. 10. The opening into the œsophagus. 11. 11. The sides of the pharynx drawn open. 12. The œsophagus.

FAUCES.—The boundaries of the fauces are the soft palate above the tongue below, and on either side these two *pillars of the soft palate*, with the the intervening tonsil.

The *Muscles* of the soft palate are, *Azygos uvulæ*, *Levator palati*, *Tensor palati*, *Palato-glossus*, *Palato-pharyngeus*.

If the mucous membrane be carefully raised from off the soft palate, these muscles will be brought distinctly into view.

The *Azygos uvulæ* is not a single muscle, as might be inferred from its name, but a pair of small muscles, placed side by side in the middle line of the soft palate. They *arise* from the spine of the palate bone, and are *inserted* into the uvula.

The *Levator palati* *arises* from the extremity of the petrous bone and Eustachian tube, and spreads out in the structure of the soft palate. This muscle must be turned down from its origin on one side, and removed, and the superior constrictor dissected away from its pterygoid origin, to bring the next muscle into view.

The *Tensor palati* (circumflexus) *arises* from the scaphoid fossa at the base of the internal pterygoid plate and from the Eustachian tube, and descends to the hamular process around which it turns, and expands into a tendinous aponeurosis, which is *inserted* into the transverse ridge on the palate plate of the palate bone, and into the *raphé*. The tensor palati is separated from the levator by the Eustachian tube and pterygoid origin of the superior constrictor.

These three muscles are placed in the reverse order of their description from before backwards; the tensor palati being the most anterior, next the levator palati, and then the azygos uvulæ.

The two next muscles are brought into view by raising the mucous membrane from off the pillars of the soft palate at each side.

The *Palato-glossus* (constrictor isthmi faucium) is a small fasciculus of fibres that *arises* in the soft palate, and descends to be *inserted* into the side of the tongue. It is the projection of this small muscle that forms the anterior pillar of the soft palate. It has been named constrictor isthmi faucium from a function it performs in common with the palato-pharyngeus, viz. of constricting the opening of the fauces.

The *Palato-pharyngeus* forms the posterior pillar (*fig. 52. 6. 6.*) of the fauces; it *arises* from the soft palate, and is *inserted* into the muscular structure of the pharynx.

ACTIONS.—The azygos uvulæ shortens the uvula. The levator palati raises the soft palate, while the tensor spreads it out laterally so as to form a septum between the pharynx and posterior nares during deglutition. The palato-glossus and pharyngeus constrict the opening of the fauces, and press the food from the dorsum of the tongue into the pharynx.

The larynx is described in Chap. VII., on the organs of sense.

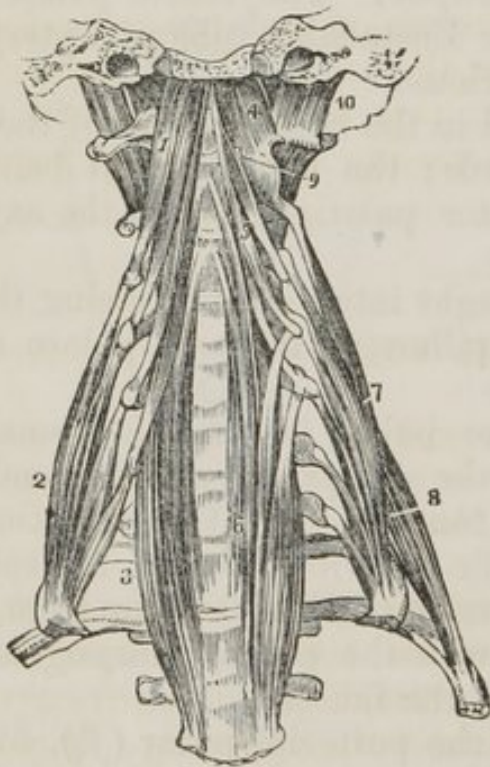
Prævertebral Region.

The remaining region of the neck is the prævertebral, which is provided with a group of five muscles. They have been already exposed by the removal of the pharynx; they are the Rectus anticus major, Rectus anticus minor, Scalenus anticus, Scalenus posticus, Longus colli.

The *Rectus anticus major* arises from the anterior tubercles of the transverse processes of the third, fourth, fifth, and sixth cervical vertebræ, and is *inserted* into the basilar process of the occipital bone.

The *Rectus anticus minor* arises from the anterior border of the atlas, and is *inserted* into the basilar process.

Fig. 53. The prævertebral group of muscles of the neck.



1. The rectus anticus major muscle. 2. The scalenus anticus. 3. The lower part of the longus colli of the right side; it is concealed superiorly by the rectus anticus major. 4. The rectus anticus minor. 5. The upper portion of the longus colli muscle. 6. Its lower portion; the figure rests upon the seventh cervical vertebra. 7. The scalenus posticus. 8. The rectus lateralis of the left side. 9. One of the intertransversales muscles.

The *Scalenus anticus* appears like a continuation of the rectus anticus major; it *arises* from the anterior tubercles of the transverse processes of the third, fourth, fifth, and sixth cervical vertebræ, and is *inserted* into the tubercle upon the first rib.

The phrenic nerve and subclavian vein lie upon the scalenus anticus and the subclavian artery behind it.

The *Scalenus posticus* arises from the posterior tubercles of all the cervical vertebræ excepting the first. It is *inserted* by two fleshy slips into the first and second ribs.

The *Longus colli* consists of two portions. The *upper* arises from the anterior tubercle of the atlas, and is *inserted*

into the transverse processes of the third, fourth, and fifth cervical vertebræ. The *lower* portion *arises* from the bodies of the second, third and fourth, and transverse processes of the fourth and fifth, and passes down the neck to be *inserted* into the bodies of the three lower cervical and three upper dorsal vertebræ. We should thus arrange these attachments in a tabular form:—

		<i>Origin.</i>	<i>Insertion.</i>
Upper portion.	}	Atlas - - -	{ 3d, 4th, and 5th transverse processes.
Lower portion.	}	2d, 3d, and 4th bodies. 4th and 5th transverse processes.	{ 3 lower cervical vertebræ, bodies. 3 upper dorsal, bodies.

In general terms, the muscle is attached to the bodies and transverse processes of the five superior cervical vertebræ above, and to the bodies of the last three cervical and first three dorsal below.

ACTIONS.—The rectus anticus major and minor preserve the equilibrium of the head upon the atlas. The longus colli flexes the anterior part of the vertebral column, and the scaleni are inspiratory muscles raising the first and second ribs.

CHAPTER VIII.

ORGANS OF SENSE.

The Nose and Nasal Fossæ.

THE organ of smell consists essentially of two parts: one external, *the nose*; the other internal, the *nasal fossæ*.

The NOSE is the triangular pyramid projecting from the centre of the face, immediately above the upper lip. Superiorly, it is connected with the forehead, by means of a narrow bridge; inferiorly, it presents two openings, the *nostrils*, which overhang the mouth, and are so constructed that the odour of all substances must be received by the nose, before they can be introduced within the lips. The septum between the openings of the nostrils is called the *columna*. Their entrance is guarded by a number of stiff hairs (*vibrissæ*), which project across the openings, and act as a filter in pre-

venting the introduction of foreign substances, such as dust, or insects, with the current of air intended for respiration.

The anatomical elements of which the nose is composed are,—1. The integument; 2. Muscles; 3. Bones; 4. Fibro-cartilages; 5. Mucous membrane; 6. Vessels and nerves.

1. The *Integument* forming the tip (*lobulus*) and wings (*alæ*) of the nose is extremely thick and dense, so as to be with difficulty separated from the fibro-cartilage. It is furnished with a number of *sebaceous follicles*, which by their oily secretion, protect the extremity of the nose in excessive alternations of temperature. The sebaceous matter of these follicles becomes of a dark colour upon the surface, from the attraction of the carbonaceous matter floating in the atmosphere: hence the spotted appearance which the tip of the nose presents in large cities. When the integument is firmly compressed, the inspissated sebaceous secretion is squeezed out from the follicles, and retaining the form of their interior, has the appearance of small white maggots with black heads.

2. The *Muscles* are brought into view by reflecting the integument: they are the *pyramidalis nasi*; *compressor nasi*; *levator labii superioris alæque nasi*; and *depressor labii superioris alæque nasi*. They have been already described with the muscles of the face.

3. The *Bones* of the nose, are the nasal, and nasal processes of the superior maxillary.

4. The *Fibro-cartilages* give form and stability to the outward of the nose, providing at the same time, by their elasticity, against injuries. They are five in number, the

Cartilage of the septum,
Two lateral cartilages,
Two alar cartilages.

The *Cartilage of the septum*, somewhat triangular in form, divides the nose into its two nostrils. It is connected above with the nasal bones and lateral cartilages: behind with the ethmoidal septum and vomer; and below with the palate processes of the superior maxillary bones. The alar cartilages and *columna* move freely upon the cartilage of the septum, being but loosely connected with it by perichondrium.

The *Lateral cartilages* are also triangular; they are connected, along the *middle line*, with the cartilage of the septum: *above*, with the nasal bones; *behind*, with the nasal

processes of the superior maxillary: and *below*, with the alar cartilages.

Alar cartilages.—Each of these cartilages is curved in such a manner as to correspond with the opening of the nostril, to which it forms a kind of rim. The inner portion is loosely connected with the same part of the opposite cartilage, so as to form the *columna*. It is expanded and thickened at the point of the nose to constitute the *lobe*; and, upon the side, expands into the oval form of the *ala*.

Besides these, there are some small irregular cartilaginous plates, which will be discovered in the course of the dissection, but which are unworthy a separate description.

The whole of these cartilages are connected with each other, and to the bones, by perichondrium, which, from its membranous structure, permits of the freedom of motion existing between them.

5. The *Mucous membrane*, lining the interior of the nose, is continuous with the skin externally, and with the pituitary membrane of the nasal fossæ within. Around the entrance of the nostrils it is provided with the *vibrissæ*.

6. *Vessels and Nerves.*—The *arteries* of the nose are the *lateralis nasi* from the facial, and the *nasalis septi* from the superior coronary.

Its *Nerves* are the facial, infra-orbital, and nasal branch of the ophthalmic.

NASAL FOSSÆ.

To obtain a good view of the *nassal fossæ*, the face must be divided through the nose by a vertical incision, a little to one side of the middle line.

The *Nassal fossæ* are two irregular, compressed cavities, extending backwards from the nose to the pharynx. They are bounded, *superiorly*, by the sphenoid and ethmoid bones. *Inferiorly*, by the hard palate, and in the middle line they are separated from each other by a bony septum.

Upon the outer wall of each fossa, in the dried skull, are three projecting processes, termed spongy bones. The two superior belong to the ethmoid, the inferior is a separate bone. In the fresh fossæ these are covered with the mucous membrane, and serve to increase its surface by their projection and by their convoluted form.

The space intervening between the two superior spongy

bones is the *superior meatus*; the space between the superior and middle bones is the *middle meatus*; and that between the inferior and floor of the fossa is the *inferior meatus*.

These *Meatuses* are passages which extend from before backwards, and it is in rushing through and amongst these, that the atmosphere deposits* its odorant particles upon the mucous membrane.

There are several *openings* into the nasal fossæ; thus, in the *superior meatus*, are the openings of the sphenoidal and posterior ethmoidal cells; in the *middle*, the anterior ethmoidal cells; the frontal sinuses, and the antrum maxillare; and, in the inferior meatus, the termination of the nasal duct. In the dried bone there are two additional openings, the sphenopalatine and the anterior palatine foramen, the former being situated in the superior, and the latter in the inferior meatus.

The *Mucous membrane* of the nasal fossæ is called *pituitary* or *Schneiderian*. The former name being derived from its secretion, the latter from Schneider, who was the first to show that the secretion of the nose proceeded from the mucous membrane, and not from the brain, as was formerly imagined. It is continuous with the general pulmono-digestive mucous membrane, and may be traced through the openings into the meatuses, into the sphenoidal and ethmoidal cells, into the antrum maxillare, through the nasal duct to the surface of the eye, where it is continuous with the conjunctiva, along the Eustachian tubes into the tympanum and mastoid cells, to which it forms the lining membrane, and through the posterior nares into the pharynx and mouth, and thence through the lungs and alimentary canal.

Vessels and Nerves.—The *arteries* of the nasal fossæ are the anterior and posterior ethmoidal, from the ophthalmic and sphenopalatine, and pterygo-palatine from the internal maxillary.

The *Nerves* are, the olfactory, the sphenopalatine branches of Meckel's ganglion, and the nasal branch of the ophthalmic.

The *Olfactory* is the special nerve of smell. Its bulb gives off a considerable number of branches, which pass through the cribriform foramina, and spread upon the osseous surface of the mucous membrane, some passing to the septum, and others to the superior and middle spongy bones.

The *Sphenopalatine nerves* are branches of Meckel's gan-

gion, which enter the fossæ through the sphenopalatine foramen, and are distributed to the mucous membrane; one branch, larger than the rest, crosses to the septum, and descends by its side to the anterior palatine canal, where it communicates with the naso-palatine ganglion. These nerves associate the organ of smell with the organs of sense and of nutrition, by means of the sympathetic nerve.

The *Nasal nerve* enters the nasal fossæ through the most anterior of the openings in the cribriform lamella, and divides into two branches, one of which is distributed to the mucous membrane of the septum and around the nostril; the other passes between the cartilages of the nose, and is distributed to the integument on its exterior.

Practical Observations.—The mucous membrane is rendered an organ of smell by the contact of the odorant particles. If the secretion be deficient, the contact is not appreciable, and there is loss of smell. Or, if the membrane be swollen and thickened, there is likewise loss of smell; both of these conditions are consequences of common cold.

When hæmorrhage occurs from the mucous membrane, it may proceed to so great an extent as to endanger life. In such a case the nasal fossæ must be stopped from behind, by drawing a piece of dry sponge against the posterior nares. This is effected by introducing an instrument, carrying a curved spring with an eye at the end of it, along the inferior meatus to the pharynx. The spring is then pressed onwards, and is directed by its curve into the posterior part of the mouth; the thread bearing the sponge is passed through the eye of the spring, and the instrument with the thread is withdrawn through the nose. The sponge is then carefully directed beneath the soft palate, and drawn gently against the posterior openings of the nose.

Growths of various kinds (polypi) proceed from the mucous membrane, and increase to a great size, impeding nasal respiration, forcing the bones out of their places, and doing great mischief. They are generally attached by a narrow pedicle, and may be removed with the polypus forceps. In performing this operation, the direction of the meatuses must be recollected, otherwise there would be danger of entangling the instrument, and pulling away one of the spongy bones.

When the tube of the stomach-pump cannot be passed through the mouth, it may be introduced into that viscus by

passing it along the inferior meatus of the nose. Patients, with extensive injury to the jaws, have been nourished for a long time solely by liquid food poured into the stomach in this way.

In obstruction of the nasal duct, it is often of great consequence to introduce a probe into it from the inferior meatus. This operation should therefore be practised upon the subject.

THE EYE WITH ITS APPENDAGES.

The form of the eyeball is that of a sphere, having a segment of a smaller sphere ingrafted upon its anterior surface, which increases its antero-posterior diameter. The axes of the two eyeballs are parallel with each other, and do not correspond with the axes of the orbits, which are directed outwards. The optic nerves follow the direction of the orbits, and therefore enter the eyeballs to their nasal side.

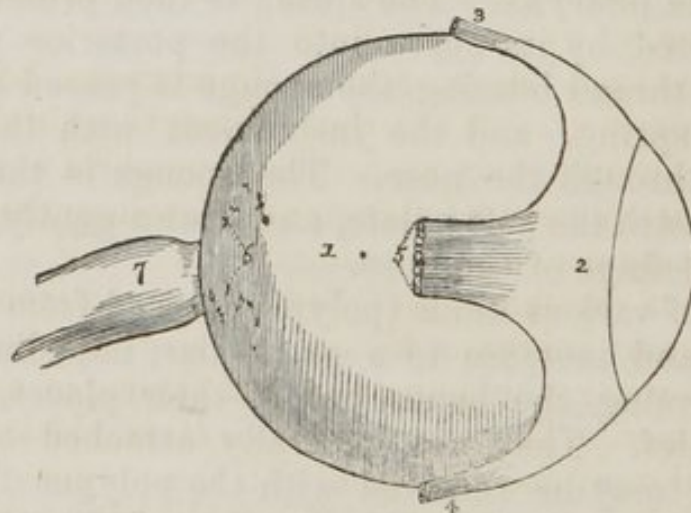
The *Globe of the eye* is composed of *tunics* and *humours*. The *tunics* are three in number, the

1. Sclerotic and cornea,
2. Choroid, iris, and ciliary processes,
3. Retina and zonula ciliaris.

The *Humours* are also three :—

Aqueous, Crystalline (lens,) Vitreous.

Fig. 54. The external tunic of the eye.



1. The sclerotic coat. 2. The tunica albuginea, formed by the expansion of the tendons of the four recti muscles. 3. The insertion of the superior rectus. 4. The insertion of the inferior rectus. 5. The insertion of the external rectus. 6. Small openings in the sclerotic for the passage of the ciliary arteries and nerves. 7. The optic nerve, which becomes constricted at its point of entrance into the globe of the eye. 8. The cornea.

1. The *Sclerotic* and *cornea* form the external tunic of the eyeball, and give to it its peculiar form. Four-fifths of the globe are invested by the sclerotic, the remaining fifth by the cornea.

The *Sclerotic* (*fig. 54. 1. fig. 57. 1.*) (*σκληρός*, hard) is a dense fibrous membrane, thicker behind than in front. It is continuous, posteriorly, with the sheath of the optic nerve, which is derived from the dura mater, and it is pierced by that nerve as well as by the ciliary nerves and arteries. Anteriorly it presents a *bevelled edge*, which receives the cornea in the same way that a watch-glass is received by the groove in its case. Its anterior surface is covered by a thin tendinous layer, the *tunica albuginea* (*fig. 54. 2.*) derived from the expansion of the tendons of the four recti muscles. By its posterior surface it gives attachment to the two oblique muscles. The *tunica albuginea* is covered, for a part of its extent, by the mucous membrane of the front of the eye, the conjunctiva. And, by reason of the brilliancy of its whiteness, gives occasion to the common expression, "The white of the eye."

At the entrance of the optic nerve, the sclerotic forms a thin *cribriform lamella* (*fig. 54. 2.*) (*lamina cribrosa*), which is pierced by a number of minute openings for the passage of the nervous filaments. One of these openings, larger than the rest, and situated in the centre of the lamella, is the *porus opticus* through which the *arteria centralis retinae* enters the eye.

The *Cornea* (*fig. 54. 8., fig. 57. 3*) (*corneus*, horny) is the transparent projecting layer that forms the anterior fifth of the globe of the eye. In its form it resembles a watch-glass. In structure it consists of five or six thin lamellæ, connected to each other by a delicate cellular tissue. It is covered by the conjunctiva in front, and lined by the membrane of the aqueous humour behind. By its edge, which is sharp and thin, it is received within the bevelled border of the sclerotic, to which it is very firmly attached. It is thicker than the anterior portion of the sclerotic.

The cornea is not perfectly circular, the transverse diameter being slightly greater than the vertical. This form is particularly evident in animals. The opacity of the cornea, produced by pressure on the globe, results from the infiltration

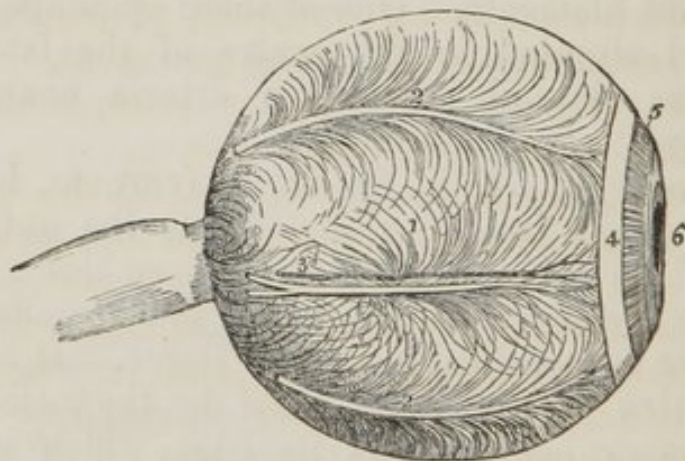
of fluid into the cellular tissue connecting its layers. This appearance cannot be produced in a sound living eye.

The sclerotic and cornea are now to be dissected away from the second tunic; this, with care, may be easily performed, the only connexions subsisting between them being at the circumference of the iris, the entrance of the optic nerve, and the perforation of the ciliary nerves and arteries. Pinch up a fold of the sclerotic near its anterior circumference, and make a small opening into it, then raise the edge of the tunic, and with a pair of fine scissors, having a probe point, divide the entire circumference of the sclerotic, and cut it away bit by bit. Then separate it from its attachment around the circumference of the iris by a gentle pressure with the edge of the knife. The dissection of the eye must be conducted under water.

In the course of this dissection the *ciliary nerves* and *long ciliary arteries* will be seen passing forwards between the sclerotic and choroid, to be distributed to the iris.

2. The *Second tunic* (*fig. 55.*) of the eye-ball is formed by the *choroid* and *iris*; the *ciliary processes* being an appendage developed from its inner surface.

Fig. 55. The second tunic of the eye.



1. The choroid membrane upon which are seen the curved lines marking the arrangement of the *venae vorticosae*. 2. 2. Ciliary nerves. 3. A long ciliary artery and nerve. 4. The ciliary ligament. 5. The iris: the two sets of fibres are very distinctly seen, the external, radiating towards the centre, and the internal, circular, surrounding the pupil 6.

The *Choroid* (*fig. 55. 1., fig. 57. 4.*) is a vascular membrane of a rich chocolate brown colour upon its external sur-

face, and of a deep black colour within. It is connected to the sclerotic externally by an extremely fine cellular tissue, and by the passage of nerves and vessels. Internally it is in simple contact with the third tunic of the eye, the retina. It is pierced posteriorly for the passage of the optic nerve, and is connected anteriorly with the iris, ciliary processes, and junction of the cornea and sclerotic, by a dense white structure, the *ciliary ligament*, which surrounds the circumference of the iris like a ring.

The choroid membrane is composed of three layers,—1. an *external venous*, which consists principally of veins arranged in a peculiar manner: hence they have been named *venæ vorticosæ*. The marking upon the surface of the membrane produced by these veins resembles so many centres, to which a number of curved lines converge. It is this layer which is connected with the ciliary ligament. 2. The *middle*, or *arterial layer* (*tunica Ruyschiana*) is formed principally of the ramifications of minute arteries, and secretes upon its surface the pigmentum nigrum. It is reflected inwards at its junction with the ciliary ligament, so as to form the ciliary processes. 3. The *internal layer* is a delicate membrane (*membrana pigmenti*) which retains the pigmentum nigrum in its place. This membrane presents a beautiful appearance beneath the microscope, being composed of regular hexagonal plates, and resembling a tessellated pavement.

In animals the pigmentum nigrum is replaced by a layer of metallic brilliancy, called the tapetum.

The *Ciliary ligament*, or circle (*fig. 55. 4., fig. 57. 5.,*) is the bond of union between the external and middle tunics of the eye, and serves to connect the cornea and sclerotic with the iris and external layer of the choroid. It is also the point to which the ciliary nerves and vessels proceed previously to their distribution, and it receives the anterior ciliary arteries through the anterior margin of the sclerotic. A minute vascular canal is situated within the ciliary ligament, called the ciliary canal, or the canal of Fontana, from its discoverer.

The *Iris* (*fig. 55. 5., fig. 57. 6.*) (iris, a rainbow) is so named from its variety of colour in different individuals: it forms a septum between the anterior and posterior chambers of the eye, and is pierced in its centre by a circular opening, which is called the pupil (*fig. 55. 6., fig. 57.**) By its peri-

phery it is connected with the ciliary ligament, and by its inner circumference forms the margin of the pupil: its anterior surface looks towards the cornea, and the posterior towards the ciliary processes and lens.

It is composed of two layers, an *anterior* or *fibrous*, consisting of *radiating* fibres which converge from the circumference towards the centre, and have the power of dilating the pupil, and *circular*, which surround the pupil like a sphincter, and by their action produce contraction of its area. The posterior layer is of a deep purple tint, and is thence named *uvea*, from its resemblance in colour to a ripe grape.

The *Ciliary processes* may be seen in two ways, either by removing the iris from its attachment to the ciliary ligament, when a front view of the processes will be obtained, or by making a transverse section through the globe of the eye, when they may be examined from behind.

The ciliary processes consist of a number of triangular folds, formed apparently by the plaiting of the internal layer of the choroid. They are, according to Zinn, about sixty in number, and may be divided into large and small, the latter being situated in the spaces between the former. The base of each triangle is situated towards the circumference of the eye, the apex towards the centre. The periphery is connected with the ciliary ligament, and is continuous with the internal layer of the choroid. The central border is free, and rests against the circumference of the lens. The anterior surface corresponds with the uvea; the posterior receives the folds of the zonula ciliaris between its processes, and thus establishes a connexion between the choroid and hyaloid membrane. The ciliary processes are covered by a thick layer of pigmentum nigrum, which is more abundant upon them and upon the anterior part of the choroid than upon the posterior. When the pigment is washed off, the processes are of a whitish colour.

3. The *Third tunic* (*fig. 56.*) of the eye is the *retina*, which is prolonged forwards to the lens by the *zonula ciliaris*.

Dissection.—If, after the preceding dissection, the choroid membrane be carefully raised and removed, the eye being kept under water, the retina will be seen very distinctly.

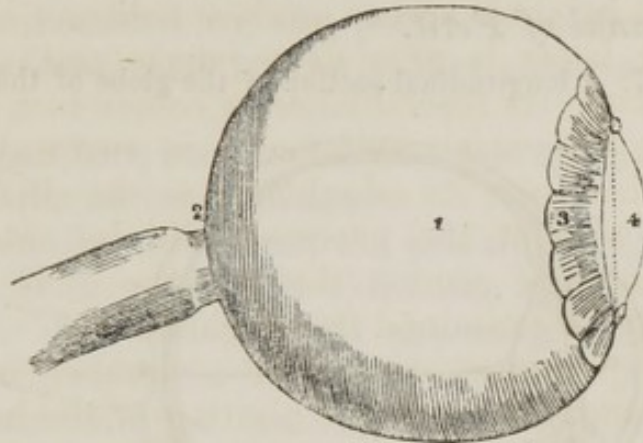
The *Retina* (*fig. 56. 1., fig. 57. 8.*) is composed of three layers:—

External, or Jacob's membrane,

Middle, Nervous membrane,
Internal, Vascular membrane.

Jacob's membrane is extremely thin, and is seen as a flocculent film when the eye is suspended in water. It is the supporting membrane to the nervous substance of the second layer. Dr. Jacob considers it a serous membrane.

Fig. 56.—The third tunic of the eye.



1. The retina terminating anteriorly in a scalloped border. 2. The foramen of Sæmmering. 3. The zonula ciliaris. 4. The lens.

The *Nervous membrane* is the expansion of the optic nerve, and forms a thin semi-transparent bluish white layer, which envelopes the vitreous humour, and extends forwards to the commencement of the ciliary processes, where it terminates in an abrupt scalloped margin.

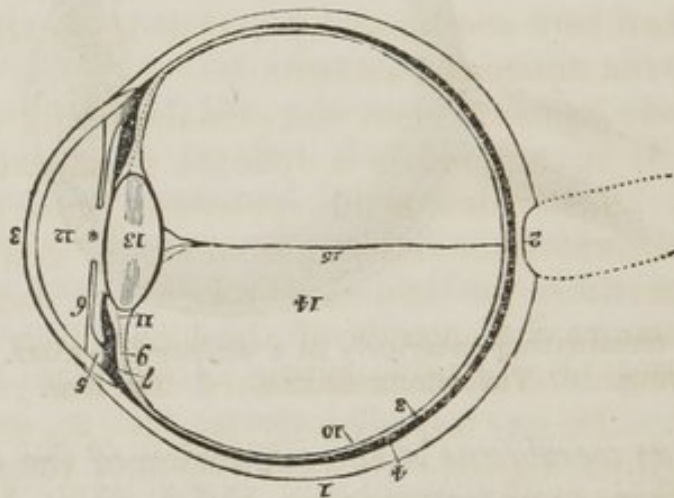
The *Vascular membrane* consists of the ramifications of a minute artery, the arteria centralis retinae, which pierces the optic nerve and enters the globe of the eye through the porus opticus, in the centre of the lamina cribrosa. This artery may be seen very distinctly by making a transverse section of the eyeball. Its branches are continuous anteriorly with the zonula ciliaris.

The retina is deficient posteriorly at a spot corresponding with the axis of the globe of the eye. This spot is called the *foramen of Sæmmering*, (fig. 56. 2,) and is surrounded by a yellow halo, the *limbus luteus*. It exists only in animals having the axis of the eyeballs parallel with each other, as man, quadrumana, and some reptiles.

The *Zonula ciliaris*, (fig. 56. 6. fig. 57. 9., (Zonula of Zinn,) is a thin vascular layer which connects the anterior margin of the retina with the circumference of the lens. It

presents upon its surface a number of small folds corresponding with the ciliary processes, between which they are received. These processes are arranged in the form of rays around the lens, and the spaces between them are stained by the pigmentum nigrum of the ciliary processes. They appear to derive their vessels from the vascular layer of the retina. The under surface of the zonula is in contact with the hyaloid membrane, and around the lens forms the anterior fluted wall of the *canal of Petit*.

Fig. 57. A longitudinal section of the globe of the eye.



1. The sclerotic, thicker behind than the front. 2. The lamina cribrosa; the thin layer of the sclerotic, which is pierced with holes for the passage of the nervous substance of the optic nerve. 3. The cornea, which is seen to be inserted into the border of the sclerotic coat. 4. The choroid membrane (the dark layer.) 5. The ciliary ligament. 6. The iris. *The pupil. 7. The ciliary processes. 8. The retina (the white layer.) 9. The dotted line represents the zonula ciliaris, which is continued from the anterior border of the retina to the capsule of the lens. 10. The innermost line is the hyaloid membrane, which may be followed behind the lens. 11. The canal of Petit. 12. The anterior chamber of the eye. The narrow space between the iris and the ciliary processes and lens is the posterior chamber. 13. The lens enclosed in its capsule. 14. The posterior cavity of the globe, in which the vitreous humour is lodged. 15. A minute artery, a branch of the anterior centralis retinae, which traverses the centre of the vitreous humour to reach the capsule of the lens.

The connection between these folds and the ciliary processes, may be very easily demonstrated by dividing an eye transversely into two portions, then raising the anterior half, and allowing the vitreous humours to separate from its attachment by its own weight. The folds of the zonula will then be seen to be drawn out from between the folds of the ciliary processes.

The *Humours* of the eye are each provided with its proper membrane.

The *Aqueous humour* is situated in the anterior and posterior chambers of the eye.

The *Anterior chamber* (*fig. 57. 12.*) is the space intervening between the cornea in front, and the iris and pupil behind.

The *Posterior chamber*, smaller than the anterior, is the narrow space bounded by the posterior surface of the iris and pupil in front, and by the ciliary process and lens behind.

The two chambers are lined by a thin layer, the *secreting membrane of the aqueous humour*.

The *Vitreous humour* forms the principal bulk of the globe of the eye. It is enclosed in a delicate membrane, the *hyaloid* (*fig. 57. 10.*), which sends processes into its interior, forming cells in which the humour is retained. A small artery, 15., may sometimes be traced through the centre of the vitreous humour to the capsule of the lens. It is surrounded by a sheath of the hyaloid membrane, which is reflected forwards with it. This vessel is easily injected in the fœtus.

The *Crystalline humour* or *lens* (*fig. 57. 13.*) is situated immediately behind the pupil, and is surrounded by the ciliary processes, which slightly overlap its margin. It is more convex on the posterior than on the anterior surface, and is embedded in the anterior part of the vitreous humour, from which it is separated by the hyaloid membrane. It is invested by a proper capsule, which contains a small quantity of fluid called *liquor Morgagni*, and is retained in its place by the attachment of the zonula ciliaris.

The *lens* consists of concentric layers, of which the external are soft, the next firmer, and the central form a hardened nucleus. These layers are best demonstrated by boiling, when they separate easily from each other. Another division of the lens takes place at the same time: it splits into three triangular segments, which have the sharp edge directed towards the centre, and the base towards the circumference.

Immediately around the circumference of the lens is a triangular canal, the *canal of Petit*, (*fig. 57. 11.*), which is bounded in front by the flutings of the zonula ciliaris, behind by the hyaloid membrane, and within by the border of the lens.

The **VESSELS** of the globe of the eye are the long and short and anterior ciliary arteries, and the *arteria centralis retinae*. The *long ciliary arteries*, two in number, pierce the posterior part of the sclerotic, and pass forward on each side between that membrane and the choroid, to the ciliary ligament, where they divide into two branches, which are distributed to the iris. The *short ciliary arteries* pierce the posterior part of the sclerotic coat, and are distributed to the internal layer of the choroid membrane. The *anterior ciliary* are branches of the muscular arteries. They enter the eye through the anterior part of the sclerotic, and are distributed to the iris. It is the increased number of these arteries in iritis that forms the peculiar red zone around the circumference of the cornea.

The *Arteria centralis retinae* enters the optic nerve at about half an inch from the globe of the eye, and passing through the *porus opticus* is distributed upon the inner surface of the retina, forming its vascular layer; one branch pierces the centre of the vitreous humour, and supplies the capsule of the lens.

The **NERVES** of the eyeball are the optic, two ciliary nerves from the nasal branch of the fifth, and the ciliary nerves from the lenticular ganglion.

Observations.—The sclerotic is a tunic of protection, and the cornea a medium for the transmission of light. The choroid supports the vessels destined for the nourishment of the eye, and by its *pigmentum nigrum* absorbs all loose and scattered rays that might confuse the image impressed upon the retina. The iris, by means of its powers of expansion and contraction, regulates the quantity of light admitted through the pupil. If the iris be thin, and the rays of light pass through its substance, they are immediately absorbed by the uvea, and if that layer be insufficient, they are taken up by the black pigment of the ciliary processes.

In Albinos, where there is a deficiency of *pigmentum nigrum*, the rays of light traverse the iris and even the sclerotic, and so overwhelm the eye with light, that sight is destroyed, except in the dimness of evening, or at night.

In the manufacture of optical instruments, care is taken to colour their interior black, with the same object, the absorption of scattered rays.

The transparent lamellated cornea and the humours of the eye have for their office the refraction of the rays in such

proportion as to direct the image in the most favourable manner upon the retina. Where the refracting medium is too great, as in over convexity of the cornea and lens, the image is thrown beyond the retina (presbyopia, long-sightedness;) and where it is too little, the image falls short of the nervous membrane (myopia, short-sightedness.) These conditions are rectified by the use of spectacles, which provide a differently refracting medium external to the eye, and thereby correct the transmission of light.

APPENDAGES OF THE EYE.

The *Appendages of the eye* (*tutamina oculi*) are the *eyebrows*, *eyelids*, *eyelashes*, *conjunctiva*, *caruncula lachrymalis*, and the *lachrymal apparatus*.

The *Eyebrows*, (*supercilia*,) are two projecting arches of integument covered with short thick hairs, which form the upper boundary of the orbits. They are connected beneath with the orbicularis, occipito-frontalis, and corrugator supercilii muscles; their use is to shade the eyes from a too vivid light, or protect them from particles of dust and moisture flowing over the forehead.

The *Eyelids* (*palpebræ*) are two valvular layers placed in front of the eye, which defend it from injury by their closure. When they are drawn open they leave between them an elliptic space, the angles of which are called *canthi*. Near to the inner canthus two small projections, (*fig. 58. 5.*) are observed on both lids, upon which are seen the openings of the lachrymal ducts (*puncta lachrymalia*.) Hence they are named *lachrymal tubercles*.

The eyelids have, entering into their structure, *integument*, *orbicularis muscle*, *tarsal cartilages*, *Meibomian glands*, and *conjunctiva*.

The tegumentary cellular tissue of the eyelids is remarkable for its looseness and entire absence of adipose substance. It is particularly liable to serous infiltration. The fibres of the orbicularis muscle covering the eyelids, are extremely thin and pale.

The *Tarsal cartilages* are two thin lamellæ of fibro-cartilage, which give form and support to the eyelids. The *superior* (*fig. 58. 1.*) is of a semilunar form, broad in the middle, and tapering to each extremity. Its lower border is

broad and flat, its upper is thin, and gives attachment to the levator palpebræ and to the fibrous membrane of the lids.

The *Inferior fibro-cartilage* (fig. 58. 2.) is a narrow elliptical band situated in the substance of the lower lid. Its upper border is flat, and corresponds with the flat edge of the upper cartilage. The lower is held in its place by the fibrous membrane. The cartilages do not extend quite so far as the angles of the lids.

The *Fibrous membrane* of the lids is firmly attached to the periosteum, around the margin of the orbit, by its circumference, and to the tarsal cartilages by its central margin. It is thick and dense on the outer half of the orbit, but becomes thin to its inner side. Its use is to retain the tarsal cartilages in their place, and give support to the lids; hence it has been named the *broad tarsal ligament*.

The *Meibomian glands* are embedded in the internal surface of the cartilages, and are very distinctly seen on examining the inner surface of the lids. They have the appearance of parallel strings of pearls, about twenty or twenty-four upon each cartilage, and open by minute foramina (fig. 58. 1. 2.) upon the edges of the lids. They correspond in length with the breadth of the cartilage, and are consequently longer in the upper than in the lower lid.

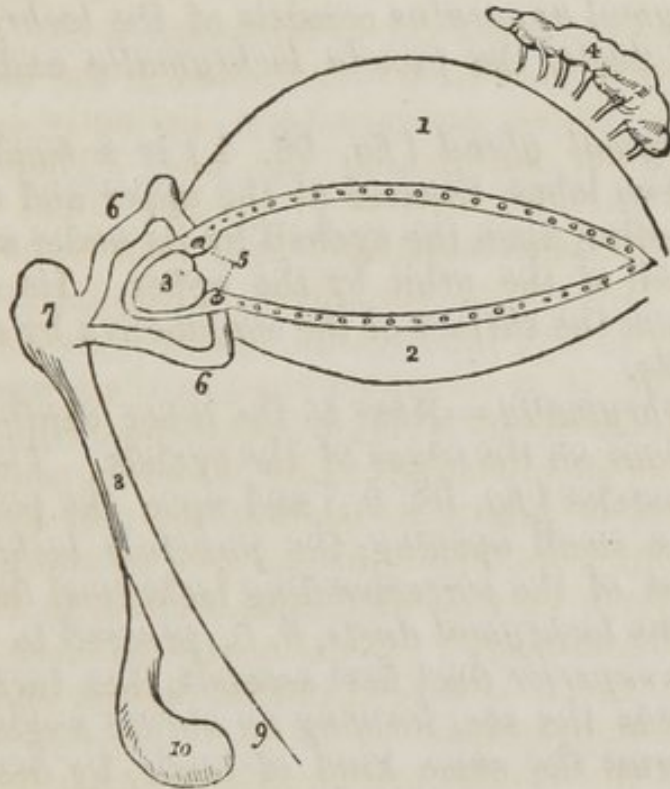
Each gland consists of a single lengthened follicle or tube, into which a number of small rounded follicles open; the latter are so numerous as almost to conceal the tube by which the secretion is poured out upon the margin of the lids. They are figured, after a very careful examination, in Dr. Quain's "Elements of Anatomy." Occasionally an arch is formed between two of them, as is seen in that figure, and produces a very graceful appearance.

The edges of the eyelids are furnished with a triple row of long thick hairs, which curve upwards from the upper lid, and downwards from the lower, so that they may not interlace with each other in the closure of the eyelids, and prove an impediment to the opening of the eyes. These are the *eyelashes* (*cilia*), important organs of defence to the sensitive surface of so delicate an organ as the eye.

The *Conjunctiva* is the mucous membrane of the eye. It covers the whole of its anterior surface, and is then reflected upon the lids so as to form their internal layer. It is very thin, and closely adherent where it covers the cornea, and no

vessels can be traced into it. Upon the sclerotica it is thicker and less adherent, and to the inner surface of the lids is connected by loose cellular tissue. It is continuous with the general pulmono-digestive mucous membrane, and sympathizes in its affections, as may be observed in various diseases. From the surface of the eye it may be traced through the lachrymal ducts into the lachrymal gland, along the edges of the lids; it is continuous with the mucous lining of the Meibomian glands, and at the inner angle of the eye may be traced through the puncta lachrymalia into the lachrymal sac, and thence downwards through the nasal duct into the inferior meatus of the nose.

Fig. 58. The lachrymal apparatus and tarsal cartilages of the eyelids.



1. The tarsal cartilage of the upper lid. 2. The tarsal cartilage of the lower lid;—the openings along the edges of the lids are those of the Meibomian ducts. 3. The caruncula lachrymalis. 4. The lachrymal gland pouring out its secretion by seven small ducts. 5. The lachrymal tubercles with the openings of the lachrymal ducts called puncta lachrymalia. 6. 6. The lachrymal ducts. 7. The lachrymal sac. 8. The nasal duct. 9. Its termination in the inferior meatus of the nose. 10. The inferior turbinate bone.

The *Caruncula lachrymalis* (fig. 58. 3.) is the small reddish body which occupies the inner angle or canthus of the eye. In health it presents a bright pink tinge, in sickness it

loses its colour and becomes pale. It consists in an assemblage of mucous follicles, and is the source of the whitish secretion which so constantly forms at the inner angle of the eye. It is frequently found studded with short hairs.

Immediately to the outer side of the caruncula, is a slight duplicature of the conjunctiva, called *plica semilunaris*, which is the rudiment of the third lid of animals, the *membrana nictitans* of birds.

VESSELS AND NERVES.—The palpebræ are supplied internally with *arteries* from the ophthalmic, and externally from the facial and transverse facial. Their *nerves* are branches of the fifth and of the facial.

LACHRYMAL APPARATUS.

The *Lachrymal apparatus* consists of the *lachrymal gland* and *excretory ducts*, the *puncta lachrymalia* and *lachrymal sac*.

The *Lachrymal gland* (*fig. 58. 4.*) is a small flattened body having two lobes, situated at the upper and outer angle of the eye, resting upon the eyeball by its under surface, and against the wall of the orbit by the upper. Its secretion is poured out upon the surface of the conjunctiva by seven small excretory ducts.

Puncta lachrymalia.—Near to the inner canthus are two slight projections on the edges of the eyelids. These are the lachrymal tubercles (*fig. 58. 5.*) and upon the point of each may be seen a small opening, the *punctum lachrymale*, the commencement of the corresponding lachrymal duct. From these points the *lachrymal ducts*, 6. 6., proceed to the lachrymal sac. The *superior* duct first ascends, then turns suddenly inwards towards the sac, forming an abrupt angle. The *inferior* duct forms the same kind of angle, by descending at first, and then turning abruptly inwards. They are dense and elastic in structure, and remain constantly open, so that they act like capillary tubes in absorbing the tears from the surface of the eye. The two fasciculi of the tensor tarsi muscle are inserted into these ducts, and serve to draw them inwards.

The *Lachrymal sac* (*fig. 58. 7.*) is the upper extremity of the nasal duct, and is not more dilated than any other portion of the canal. It is lodged in the groove of the lachrymal bone, and is often distinguished internally from the nasal

duct by a semilunar or circular valve. It consists of mucous membrane, but is covered in and retained in its place by a fibrous expansion, derived from the tendon of the orbicularis, which is inserted into the ridge on the lachrymal bone. It is also covered by the tensor tarsi muscle, which arises from the same ridge, and in its action upon the lachrymal ducts may serve to compress the lachrymal sac.

The *Nasal duct* (fig. 58. 8.) is a short canal directed downwards and backwards and a little inwards to the inferior meatus of the nose, where it terminates. It is lined by the mucous membrane, which is continuous with the conjunctiva above and the pituitary membrane of the nose below. Obstruction to this duct gives origin to the disease called fistula lachrymalis.

VESSELS AND NERVES.—The lachrymal gland is supplied with blood by the lachrymal branch of the ophthalmic artery, and with nerves by the lachrymal branch of the ophthalmic and orbital branch of the superior maxillary.

THE ORGAN OF HEARING.

The *Ear* is composed of three parts,—1. *external ear*; 2. *middle ear*, or *tympanum*; 3. *internal ear*, or *labyrinth*.

The *External ear* consists of two portions, the *pinna* and *meatus*; the former representing a kind of funnel which collects the vibrations of the atmosphere, called sounds, and the latter a tube which conveys the vibrations to the tympanum.

The *Pinna* presents a number of folds and hollows upon its surface, which have different names assigned to them. Thus the external folded margin is called the *helix* (ἑλίξ, a fold.) The elevation parallel to and in front of the helix is called *antihelix* (ἀντι, opposite.) The pointed process, projecting like a valve over the opening of the ear from the face, is called the *tragus* (τραγός, a goat,) probably from being sometimes covered with bristly hair like that of a goat; and a tubercle opposite to it is the *antitragus*. The lower dependent and fleshy portion of the pinna is the *lobulus*. The space between the helix and antihelix is named the *fossa innominata*. Another depression is observed on the upper extremity of the antihelix, which bifurcates and leaves a triangular space between its branches called the *scaphoid fossa*; and the large central space to which all the channels converge is the *concha*, which opens directly into the *meatus*.

The pinna is composed of *integument*, *fibro-cartilage*, and *muscles*.

The *Integument* is thin, and closely connected with the fibro-cartilage.

The *Fibro-cartilage* gives form to the pinna, and surrounds the commencement of the meatus. It is firmly attached to the external auditory process, and is deficient in the lobulus.

The proper *Muscles* of the pinna are the

Major heliçis,	Antitragicus,
Minor heliçis,	Transversus auriculæ.
Tragicus,	

The *Major heliçis* is a narrow band of muscular fibres situated upon the anterior border of the helix, just above the tragus.

The *Minor heliçis* is placed upon the posterior extremity of the helix.

The *Tragicus* is a thin layer of muscular fibres, situated upon the tragus.

The *Antitragicus* arises from the antitragus, and is inserted into the posterior part of the helix.

The *Transversus auriculæ*, partly tendinous and partly muscular, extends transversely from the convexity of the concha to that of the helix, on the posterior surface of the pinna.

These vessels are rudimentary in the human ear, and deserve only the title of muscles in the ears of animals. Two other muscles are described by Mr. Tod,* the *obliquus auris* and *contractor meatus*, or *trago-helicus*. There are also a number of ligaments which connect the opposite borders of the fissures in the fibro-cartilage.

The *meatus auditorius* is a canal partly cartilaginous and partly osseous, about an inch in length, which extends inwards and a little forwards from the concha to the tympanum. It is narrower in the middle than at each extremity, and forms an oval cylinder, the long diameter being vertical; and is slightly curved upon itself, the concavity looking downwards.

It is lined by an extremely thin pouch of cuticle, which, when withdrawn after maceration, preserves the form of the meatus. Some stiff short hairs are also found in its interior,

* "The Anatomy and Physiology of the Organ of Hearing," by David Tod, 1832.

which stretch across the tube, and prevent the ingress of insects and dust. Beneath the cuticle are a number of small *ceruminous follicles*, which secrete the wax of the ear.

VESSELS AND NERVES.—The pinna is plentifully supplied with *arteries*; by the anterior auricular from the temporal, and by the posterior auricular from the external carotid.

Its *Nerves* are derived from the auricular branch of the fifth, and the auricularis magnus of the cervical plexus.

TYMPANUM.—The tympanum is an irregular bony cavity, compressed from without inwards, and situated within the petrous bone. It is bounded *externally* by the meatus and membrana tympani; *internally*, by its inner wall; and in its *circumference* by the petrous bone and mastoid cells.

The *Membrana tympani* is stretched obliquely from above downwards across the extremity of the meatus auditorius, and gives attachment by its centre and inner surface to the handle of the malleus. It is depressed towards the centre, and is concave towards the meatus, and convex towards the tympanum. It is composed of *three layers*, an *external* cuticular, *middle* fibrous and muscular, and *internal* mucous, derived from the mucous lining of the tympanum.

The tympanum contains four small bones, *ossicula auditus*, viz. the

Malleus,	Orbiculare,
Incus,	Stapes.

The *Malleus* (*hammer*) consists of a head, neck, handle, (*manubrium*), and two processes, *long* (*processus gricilis*) and *short* (*processus brevis*.) It is attached by the manubrium to the membrana tympani, the extremity of the handle extending to the centre of that membrane. Its connexion is effected by being inserted between the mucous lining and the fibrous and muscular layer. Its long process descends to the fissura Glaseri, and gives attachment to the laxator tympani muscle. Into the short process is inserted the tendon of the tensor tympani, and the head of the bone articulates with the incus.

The *Incus* (*anvil*) is named from an imagined resemblance to an anvil. It has also been likened to a bicuspid tooth, having one root longer, and widely separated from the other. It consists of two processes, which join each other nearly at right angles, and at their junction form a flattened body, which articulates with the head of the malleus. The short process is free; the long process descends nearly parallel

with the handle of the malleus, and curves inwards, near to its termination, to articulate with the os orbiculare.

The *Os orbiculare* is a small spherical bone, distinct in the foetus, but ankylosed to the long process of the incus in the adult, and appearing only as a process of that bone. It articulates with the head of the stapes.

The *Stapes* is shaped like a stirrup, to which it bears a very close resemblance. Its head articulates with the os orbiculare, and the two branches are connected at its extremity by a flat oval-shaped plate, representing the foot of the stirrup, which fits accurately the opening from the tympanum into the vestibule, the *fenestra ovalis*. The neck of the stapes gives attachment to the stapedius muscle.

The *Muscles* of the *tympanum* are also four, the
 Tensor tympani, Laxator tympani minor,
 Laxator tympani, Stapedius.

To these Mr. Tod has added five others, the *posterior mallei*, *superior capitis mallei*, *obliquus incudis externus posterior*, *triangularis incudis*, and *musculus*, or *structura stapedius inferior*; for the history of which we must refer the lover of minute anatomy to the work previously quoted.

The *Tensor tympani* arises from the petrous portion of the temporal bone, and from the Eustachian tube, and passes forwards in a distinct canal separated from the tube by the *processus cochleariformis*, to be *inserted* into the short process of the malleus.

The *Laxator tympani* arises from the spinous process of the sphenoid bone, and passes through an opening in the *fissura Glaseri*, to be *inserted* into the long process of the malleus.

The *Laxator tympani minor* arises from the upper margin of the meatus, and is *inserted* into the handle of the malleus.

The *Stapedius* arises from the interior of the pyramid, and escapes from its summit to be *inserted* into the neck of the stapes.

The openings in the tympanum are ten in number, *five large* and *five small*; they are the

Large openings.

Meatus auditorius,
 Fenestra ovalis,
 Fenestra rotunda,
 Mastoid cells,
 Eustachian tube.

Small openings.

Entrance of the chorda tympani,
Exit of the chorda tympani,
For the laxator tympani,
For the tensor tympani,
For the stapedius.

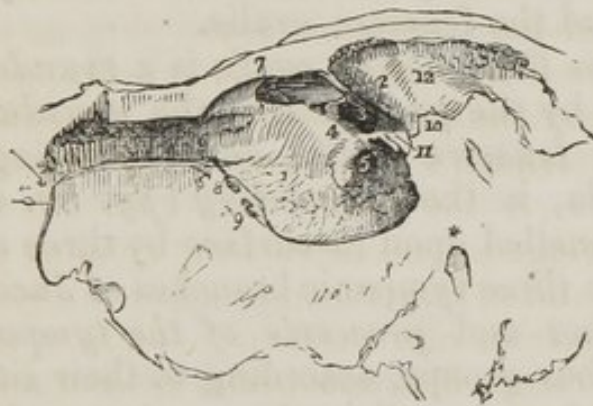The opening of the *Meatus auditorius* has been already described.

The *Fenestra ovalis* (fig. 59. 3.) is an oval opening, situated in the upper part of the inner wall of the tympanum, directly opposite the meatus; it is the opening of communication between the tympanum and vestibule, and is closed by the foot of the stapes and by the lining membranes of both cavities.

The *Fenestra rotunda* (fig. 59. 5.) is somewhat triangular in its form, and situated in the inner wall of the tympanum, below and rather posteriorly to the fenestra ovalis, from which it is separated by a bony elevation, called the *promontory*, 4. It serves to communicate the tympanum with the cochlea. In the fresh subject it is closed by a proper membrane, as well as by the mucous lining of both cavities.

The *Mastoid cells* are very numerous, and occupy the whole of the interior of the mastoid process, and part of the petrous bone. They communicate by a large irregular opening (fig. 59. 12.) with the upper and posterior circumference of the tympanum.

Fig. 59. The tympanum of the left ear.



1. Its inner wall. 2. A convex ridge marking the situation of the aqueductus Fallopii; the star shows its termination on the face of the section, in its course downwards to the stylo-mastoid foramen. 3. The fenestra ovalis. 4. The promontory. 5. The fenestra rotunda. Anteriorly (6.) is the entrance of the Eustachian tube. 7. The opening for the tensor tympani. 8. The opening for the laxator tympani; and (9.) the opening of exit for the chorda tympani nerve. Posteriorly (10.) is the opening of entrance for the chorda tympani; and (11.) the pyramid with the small opening at its apex which gives passage to the tendon of the stapedius muscle. Superiorly is a large opening (12.) leading backwards to the mastoid cells.

The *Eustachian tube* (fig. 59. 6.) is a canal of communication extending obliquely between the pharynx and the an-

terior circumference of the tympanum. In structure it is partly fibro-cartilaginous and partly osseous, is broad and expanded at its pharyngeal extremity, and narrow and compressed at the tympanum.

The *Smaller openings* serve for the transmission of the chorda tympani nerve, and three of the muscles of the tympanum.

The *Opening* (*fig. 59. 10.*) by which the *chorda tympani* enters the tympanum, is near the root of the pyramid, at about the middle of the *posterior wall*.

The *Opening of exit* (*fig. 59. 9.*) of the *chorda tympani*, is at the fissura Glaseri in the *anterior wall* of the tympanum.

The *Opening for the laxator tympani muscle* (*fig. 59. 8.*) is also situated in the fissura Glaseri, in the *anterior wall* of the tympanum.

The *Opening for the tensor tympani muscle* (*fig. 59. 7.*) is in the *anterior wall*, immediately above the opening of the Eustachian tube.

The *Opening for the stapedius muscle* is at the apex of a conical bony eminence, called the pyramid (*fig. 59. 11.*) which is situated on the *posterior wall* of the tympanum, immediately behind the fenestra ovalis.

Directly *above* the fenestra ovalis is a *rounded ridge* (*fig. 59. 2.*) formed by the projection of the *aqueductus Fallopii*.

Beneath the fenestra ovalis, and separating it from the fenestra rotunda, is the *promontory* (*fig. 59. 4.*) a rounded projection channelled upon its surface by three small grooves, which lodge the three tympanic branches of Jacobson's nerve.

The *Foramina* and *processes of the tympanum* may be arranged into four groups, according to their situation.

1. In the *External wall* is the *meatus auditorius*, closed by the *membrana tympani*.

2. In the *Inner wall* (*fig. 59.*) from above downwards, are the

Ridge of the aqueductus Fallopii, 2.,

Fenestra ovalis, 3.,

Promontory, 4.,

Grooves for Jacobson's nerve,

Fenestra rotunda, 5.

3. In the *Posterior wall* are the

Opening of the mastoid cells, 12.,

Pyramid, 11.,

- Opening for the stapedius,
Apertura chordæ (entrance,) 10.
4. In the *Anterior wall* are the
Eustachian tube, 6.,
Opening for the tensor tympani, 7.,
Opening for the laxator tympani, 8.,
Apertura chordæ (exit,) 9.

The tympanum is lined by a *vascular mucous membrane*, which invests the ossicula and chorda tympani, and forms the internal layer of the membrana tympani. From the tympanum it is reflected into the mastoid cells, which it lines throughout, and passes through the Eustachian tube to become continuous with the mucous membrane of the pharynx.

VESSELS AND NERVES.—The *Arteries* of the tympanum are derived from the internal maxillary, internal carotid, and posterior auricular.

Its *Nerves* are—1. Minute branches of the *facial*, which are distributed to the muscles. 2. The *chorda tympani*, which leaves the facial nerve near the stylo-mastoid foramen and arches upwards to enter the tympanum at the root of the pyramid; it then passes forwards between the handle of the malleus and long process of the incus, to the opening in the fissura Glaseri. 3. The *tympanic branches of Jacobson's nerve*, which are distributed to the membranes of the fenestra ovalis and fenestra rotunda, and to the Eustachian tube, and form a plexus by communicating with the carotid plexus and otic ganglion.

INTERNAL EAR.

The *Internal ear* is called *labyrinth*, from the complexity of its communications, and consists of a series of cavities which are channelled through the substance of the petrous bone. It is situated between the cavity of the tympanum and the meatus auditorius internus.

The *Labyrinth* (*fig. 60.*) consists of the
Vestibule, Cochlea.
Semicircular canals,

The *Vestibule* is a small oval cavity, situated immediately within the inner wall of the tympanum. It is named vestibule, from being, as it were, the hall of communication between the other cavities of the ear. It therefore presents a number of openings corresponding with these different cavities.

They may be arranged, like those of the tympanum, into *large* and *small*.

The *Large openings* are seven in number, viz. the
Fenestra ovalis,
Scala vestibuli,
Five openings of the three semicircular canals.

The *Small openings* are the
Aqueductus vestibuli,
Openings for small arteries,
Three openings for branches of the auditory nerve.

The *Fenestra ovalis* (*fig. 59. 3. fig. 60. 2.*) is closed by the lining membrane of the vestibule, and by the foot of the stapes. It is the opening into the tympanum.

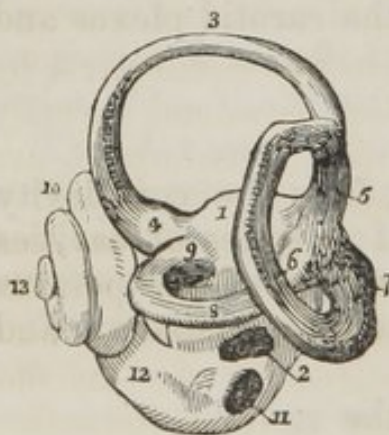The opening of the *Scala vestibuli* is the communication between the vestibule and the cochlea.

The *Aqueductus vestibuli* is the commencement of the small canal which opens upon the posterior surface of the petrous bone. It gives passage to a small vein, which terminates in the superior petrosal sinus.

The *Openings* for the *arteries* and *nerves* are situated in the internal wall of the vestibule, and correspond with the termination of the meatus auditorius internus.

The *Semicircular canals* are three bony passages which communicate with the vestibule; one is *perpendicular* (*fig. 60. 3.*) in its direction

Fig. 60. The labyrinth of the left ear.



and corresponds with a tubercle upon the anterior surface of the petrous bone; another is *oblique*, 6.; and the third is *horizontal*, 8. Each canal presents a dilatation at one extremity, which is called *ampulla*, 4. 9. 7. The two undilated extremities of the perpendicular and oblique canals unite to form a single tube, 5.; all the others open singly into the vestibule, hence the *five openings* of the *three canals*.

1. The vestibule. 2. The fenestra ovalis, in its natural position, looking from the meatus auditorius externus; the entrance into the vestibule from the tympanum. 3. The perpendicular semicircular canal. 4. Its ampulla. 5. Its union with the oblique canal. 6. The oblique semicircular canal. 7. Its ampulla. 8. The horizontal semicircular canal. 9. Its ampulla. 10. The cochlea, internal to and rather in front of the vestibule. 11. The fenestra rotunda, the entrance into the scala tympani of the cochlea.

12. The canal of the cochlea leading from the fenestra rotunda to make its first turn. 13. The extremity of the canal called the cupola.

The vestibule contains two sacs formed by the expansion of the auditory nerve. The larger of these is the *utricle communis*, the smaller the *sacculus proprius*. The semicircular canals contain tubes of nervous membrane, which communicate with the utricle communis, and form three dilatations corresponding with the ampulæ at the extremities of the canals. These sacs, together with the nervous tubes lodged in the canals, contain a limpid secretion, which is called *liquor of cotunnus*.* The sacs likewise contain a calcareous deposite, which is analagous to the otolithes or calcareous crystalline masses found in the vestibular sac of fishes. This deposite has been recently described by Breschet, and is called by him *Otoconite* (*ovis, ωτος*, the ear—*ovis*,) dust.

The sacs and membranous canals do not completely fill the cavities of the bone, but leave a space which is occupied by another fluid, the liquor of Scarpa or *aqua labyrinthi*.

The vestibule and semicircular canals are lined by a thin *mucous membrane* which secretes the *aqua labyrinthi*.

The *Cochlea* (*fig. 60. 10.*) (*snail shell*) is a spiral canal, which describes two turns and a half around a central pillar which is called *modiolus*. It is situated in the anterior part of the petrous bone, its base being directed backwards and inwards, and corresponding with the termination of the cul-de-sac of the meatus auditorius internus.

The canal of the cochlea is divided into two equal parts by a thin bony lamina, *lamina spiralis*, which is wound spirally around the modiolus. The two half canals, thus formed, are called *scala tympani* and *scala vestibuli*.

At the apex of the cochlea the two scalæ communicate and form a dilated cavity, which is termed the *cupola* (*fig. 60. 13.*) The *Lamina spiralis* is not continued entirely across the canal of the cochlea, but is completed by the mucous membrane which lines its interior. Near to the termination of the *scala tympani* is the opening of a small canal *aqueductus cochleæ*, which passes backwards to the jugular fossa. It transmits a small vein from the cochlea, which opens into the commencement of the internal jugular vein.

* Dominico Cotunnus, an Italian physician; his dissertation "De Aquæductibus Auris Humanæ Internæ," was published in Naples, in 1761.

The cavity of the cochlea is lined throughout by a thin mucous membrane, which is continuous with that of the vestibule, but which closes the fenestra rotunda. It is filled with the aqua labyrinthi.

The *Openings* into the cochlea are, the fenestra rotunda from the tympanum, the opening into the vestibule, the aqueductus cochleæ, and the openings for the branches of the auditory nerve.

AUDITORY NERVE.—When the auditory nerve reaches the extremity of the meatus auditorius internus, it divides into two branches, 1. The larger or *anterior* to the cochlea. 2. The smaller or *posterior* to the vestibule and semicircular canals.

The *Anterior branch* divides into a number of minute filaments which pierce the base of the cochlea, and expand in its mucous lining: others enter the modiolus, which is hollowed into canals, to receive them, and pass off through small openings in its circumference to expand in the mucous membrane covering the lamina spiralis.

The *Posterior or vestibular portion* of the nerve divides into three branches, which are distributed—1. The larger to form the utriculus communis, and the membranous tubes of the perpendicular and horizontal canals. 2. To form the sacculus proprius. 3. The smallest to form the membranous tube of the oblique canal.

The *Arteries* of the labyrinth are derived principally from the auditory branch of the inferior cerebellar artery.

ORGAN OF TASTE.

The *Tongue* is composed of muscular fibres, which are distributed in layers arranged in various directions: thus some are disposed *longitudinally*, others *transversely*, others again *obliquely* and *vertically*. Between the muscular fibres is a considerable quantity of adipose substance.

The *tongue* is *connected* posteriorly with the os hyoides by muscular attachment, and to the epiglottis by mucous membrane, forming the three folds which are called *fræna epiglottidis*. On either side it is held in connexion with the lower jaw by mucous membrane, and in front a fold of that membrane is formed beneath its under surface, which is named *frænium linguæ*.

The surface of the tongue is covered by a dense layer

analogous to the corium of the skin, which gives support to the papillæ. A *raphé* marks the middle line of the organ, and divides it into symmetrical halves.

The *Papilla* of the *tongue*, are the
 Papillæ circumvallatæ,
 ——— fungiformes,
 ——— conicæ,
 ——— filiformes,

The *Papillæ circumvallatæ* are of large size, and from fifteen to twenty in number. They are situated on the dorsum of the tongue near its root, and form a row upon each side, which meets its fellow at the middle line, like the two branches of the letter A. They resemble cones attached by the apex to the bottom of a cup-shaped depression: hence they are also named papillæ *calyciformes*. This cup-shaped cavity forms a kind of fossa around the papillæ, hence their name *circumvallatæ*.

At the meeting of the two rows of these papillæ upon the middle of the root of the tongue, is a deep mucous follicle called *foramen cæcum*.

The *Papillæ fungiformes* are irregularly dispersed over the dorsum of the tongue, and are easily recognized amongst the other papillæ by their rounded heads and larger size.

The *Papillæ conicæ* and *filiformes* cover the whole surface of the tongue in front of the circumvallatæ, but are most abundant upon its tip. They are conical and filiform in shape, and have their points directed backwards.

Behind the papillæ circumvallatæ, at the root of the tongue, are a number of *mucous glands*, which open upon the surface. They have been improperly described as papillæ by some authors.

The papillæ are covered with cuticle, which forms minute sheaths around them. The cuticular sheaths become enormously enlarged and lengthened in some fevers. Dr. Henle, of Berlin, has recently shown the cuticular covering, or epithelium, to be formed of irregularly quadrilateral scales, having a nucleus in the centre of each.

VESSELS AND NERVES.—The tongue is abundantly supplied with blood by the lingual arteries.

The *Nerves* are three in number, and of large size—1. The *gustatory* branch of the fifth, which is distributed to the papillæ and is the nerve of common sensation. 2. The *glosso-pharyn-*

geal, which is distributed to the mucous membrane, follicles, and glands of the tongue, and has been shown by the experiments of Panizza to be the true nerve of taste. This nerve also associates the tongue with the pharynx and larynx. 3. The *lingual*, which is the motor nerve of the tongue, and is distributed to the muscles.

The *Mucous membrane*, which invests the tongue, is continuous with the cutis along the margins of the lips. On either side of the frænum linguæ, it may be traced through the sublingual ducts into the sublingual glands, and along Wharton's ducts into the submaxillary glands; from the sides of the cheeks it passes through the openings of Stenon's ducts to the parotid gland; in the fauces, it forms the assemblage of follicles called tonsils, and may be thence traced downwards into the larynx and pharynx, where it is continuous with the general pulmono-digestive mucous membrane.

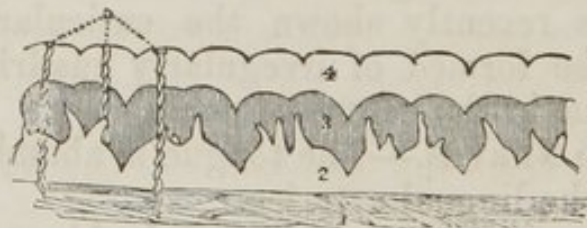Beneath the mucous membrane of the mouth are a number of small *glandular granules*, which pour their secretion upon the surface. A considerable number of them are situated within the lips, in the palate, and in the floor of the mouth. They are named from the position which they may chance to occupy, *labial, palatine glands*, &c.

ORGAN OF TOUCH.

The *Skin* is composed of three layers: viz. the
 Cutis, Cuticle.
 Rete-mucosum,

The *Cutis* (dermis) or true skin covers the entire surface of the body, and is continuous with the mucous membrane which lines its cavities. It consists of two layers, a deep one called *corium*, and a superficial or *papillary layer*.

Fig. 61. A section of the skin.



1. The corium. 2. The papillary layer of the cutis. 3. The rete mucosum modelled upon the papillæ. 4. The cuticle. 5. Spiral sweat ducts, opening at the pores upon the ridges of the cuticle.

The *Corium* (*fig. 61. 1.*) is the base of support to the skin, and owes its density of structure to an interlacement of fibrous bands which form a firm and elastic web. On its under surface it presents a number of areolæ, in which are lodged cells of adipose tissue. It is connected by this surface with the general superficial fascia of the body.

On the upper surface, the fibres are more closely aggregated, and form a smooth plane for the support of the papillary layer.

The corium differs very much in thickness in different parts of the body; thus, on the lips, eyelids, and scrotum, it is extremely thin. On the head, back, soles of the feet, and palms of the hands, it is very thick, and on the more exposed parts of the body it is much thicker than on those which are protected.

The *Papillary layer* (*fig. 61. 2.*) is soft, and formed by minute papillæ which cover every part of its surface. On the body generally, the papillæ are irregular in their form and distribution: they are best seen in the palm of the hand or sole of the foot, where they are distributed in linear ridges, as is indicated by the linear markings on the cuticle.

In these situations each papilla resembles a molar tooth, having four tubercles, one of them being generally longer than the others. Between each of the papillæ is the opening for the perspiratory duct.

The papillæ beneath the nail have a peculiar arrangement and structure. At the root of the nail the papillæ are numerous, but small and very vascular; opposite to the part of the nail called *lunula*, they are scarcely raised above the surface, and less vascular, but beyond this point they form lengthened vascular plicæ, which afford a large surface for secretion. These lengthened papillæ deposite the horny secretion in longitudinal lamellæ, which give to the nail the ribbed appearance it presents on its surface.

VESSELS AND NERVES.—The papillæ are abundantly supplied with vessels and nerves, the former to enable them to perform the office of secretion in the production of the cuticle, the latter to give them the sensibility necessary to an organ of touch.

The *Rete mucosum* (*fig. 61. 3.*) is a distinct layer, interposed between the cuticle and cutis, and is the seat of the colour in the negro and the darker tribes of mankind. The

name rete mucosum given to it by Malpighi conveys a very inaccurate notion of its structure, for it is neither a network, nor is it mucous. It is thin upon the general surface of the body, but is thick in the palm of the hand and sole of the foot, where it may be easily separated as a distinct layer. Examined beneath the microscope, it is seen to be moulded accurately upon the papillæ, being thick in the spaces between these, and thin over their convexities; hence arises the appearance of a network. In the rete mucosum from the hand, these depressions are seen to be arranged in a linear series, as are the papillæ; in other situations they are more irregular, but correspond always with the distribution of the papillæ. There is no rete mucosum beneath the nails.

The colouring particles are situated in the rete mucosum, and are most abundant upon the ridges which correspond with the furrows between the papillæ.

VESSELS AND NERVES.—The rete mucosum has been injected by Mr. Cruikshank, and in a case of small-pox by Sir Astley Cooper. No nerves have been traced into the substance of the rete.

The *Cuticle* (*fig. 61. 4.*) (epidermis, scarf-skin) is the horny unorganized lamella secreted by the cutis, which covers and protects the entire surface of the more delicate layers of the skin. At the entrance to the cavities it is continuous with the epithelium or cuticular covering of the mucous membrane.

In situations exposed to pressure, as the palm of the hand and sole of the foot, it is very thick; on other parts it forms only a thin layer. The cuticle is marked on the surface by a net-work of lines: these are more numerous and larger near to joints, where they form deep wrinkles on account of the inelastic nature of its structure. Their appearance differs in different regions of the body, but every where depends upon the same cause, the inelasticity of the cuticle.

Upon the palms of the hands and soles of the feet the cuticle presents a number of linear elevations which correspond with the rows of papillæ in those parts. This is particularly evident upon the tips of the fingers, where there is a circular arrangement of papillæ.

Upon the inner surface of the cuticle a number of depressions and linear furrows are seen corresponding with the projections of the papillæ. A number of conical processes are also observed on this surface, which correspond with the pass-

age of hairs through the cuticle, and with the openings of the perspiratory ducts.

The *openings in the cuticle* are the *pores* or openings for the perspiratory ducts, the openings for the passage of the hairs, and those of the sebaceous follicles.

The *Appendages to the skin* are the *nails, hairs, sebaceous follicles,* and *perspiratory ducts.*

The *Nails* are parts of the cuticle secreted in the same manner, composed of the same material, but disposed in a peculiar way to serve an especial purpose—the protection of the tactile extremities of the fingers. The white semilunar mark at the base of the nail is called the *lunula*. The cuticle is closely connected with it all round, and in maceration the nail comes off with that layer.

The *Hairs* have a very different structure and arrangement from that of the nails: they grow by roots which are implanted in the corium, and traverse the papillary layer, the rete mucosum, and the cuticle, to reach the surface. As they pass through the rete mucosum and cuticle, they receive a reflected covering from each, and the cuticle is closely adherent around the cylinder of the hair before it emerges from the surface.

The hair is homogeneous in structure, having no canal in its interior: it is supplied with the means of nutrition by the vessels at its root.

The *Sebaceous follicles* are abundant in some parts of the skin, as in the armpits, the nose, &c. They are small perpendicular pouches secreting a peculiar oily matter, and lined by a thin layer of cuticle.

The *Perspiratory ducts* (*fig. 61. 5.*) are spiral tubes commencing apparently in the corium, and proceeding upwards between the papillæ, to terminate by open pores upon the surface of the cuticle. They are easily seen by examining with the microscope a thin section of skin made perpendicularly to the surface. Their origin is not yet clearly made out. Breschet asserts that they proceed from distinct globular glands. Analogy is opposed to his view, but we have not yet succeeded in ascertaining their origin satisfactorily. If a portion of skin be scalded with hot water, and the cuticle raised, the perspiratory ducts may be seen most distinctly extended in straight lines between the separating layers.

The *Pores* are best observed during perspiration, when the

fluid is seen oozing through their minute openings. In the hand and sole of the foot they are easily seen by the naked eye without this assistance. They are disposed at regular distances along the ridges of the cuticle, and give rise to the appearance of lines cutting the ridges transversely.

CHAPTER X.

ANATOMY OF THE PERINEUM.

THE *Perineum* is the inferior part of the trunk of the body in which are situated the two great excretory outlets, the urethra and the termination of the alimentary canal. These are parts of delicate and complicated structure, and largely supplied with vessels and nerves. They are also peculiarly liable, from the nature of their functions, to causes of irritation and disease. Indeed, disease is more frequent and various in this region, than in any other of the body. Nearly the whole of the affections admit of relief or cure from operative procedure. Hence the perineum is the most important surgical region of the entire system, and incisions are made through it to great depth and in various directions. A good knowledge of its component structures and relations is therefore highly necessary to the surgeon, for a misdirected incision, by wounding important parts, would involve the most serious consequences, and probably prove fatal to the patient.

The anatomical composition of the perineum is the same as that of any other part of the body, consisting of *integument, superficial fascia, deep fascia, muscles, vessels, and nerves*. But to suit the peculiar functions of this region, they are somewhat differently distributed and arranged.

To obtain a clear and precise idea of the nature of the perineum, the student must take in his hand a pelvis in which the sacro-ischiatic ligaments have been left in their proper positions. Let him now turn to the outlet of the pelvis, and he will be enabled to trace the *boundaries of the perineum*. *In front* he will have the arch of the pubis, *on each side* the ramus and tuberosity of the ischium and great sacro-ischiatic ligaments and *behind* the coccyx.

If he draw a line transversely across this outlet from the

anterior extremity of one tuberosity of the ischium to the same point on the other, he will divide the opening into two parts of nearly equal size. The *anterior space* belongs to the organs of generation, the *posterior* to the termination of the alimentary canal. Let us first examine the *anterior* or *genital space*.

A strong, fibrous membrane is stretched across this anterior space from the ramus of the pubis and ischium on one side to the same parts on the opposite side. This is called the "*Deep perineal fascia*." It is a septum of division between the interior and the exterior of the pelvis, between the internal organs of generation and the external. The deep perineal fascia is not, however, a single membrane, but consists of *two layers*, between which are situated the membranous portion of the urethra, the compressor urethræ muscle, part of the internal pudic arteries, the arteries of the bulb, and Cowper's glands.

Externally to the deep fascia is the *penis*, which is composed of three lengthened bodies, the two corpora cavernosa above, and the corpus spongiosum below. The corpora cavernosa are firmly attached to the ramus of the pubis and ischium on each side, by two diverging processes, called *crura penis*. The corpus spongiosum is the medium of transmission for the urethra, which enters that body immediately that it escapes from the deep perineal fascia, and takes its course through its interior to its termination at the meatus urinarius.

The extremity of the corpus spongiosum, which receives the urethra, is considerably enlarged, and is called the *bulb*; at its opposite extremity it is again enlarged, and forms the *glans penis*.

The penis is moved by three pairs of muscles, which are the *muscles of the perineum*. It is supplied with blood-vessels and nerves from the internal pudic artery and nerve. The muscles, vessels, and nerves, are in immediate relation with the commencement of the penis, and *directly external* to the deep perineal fascia.

Then the whole of these parts are covered in and held firmly in their places by the *superficial perineal fascia*, which is continuous with the deep perineal fascia posteriorly, and is firmly attached on each side to the ramus of the pubis and ischium, whilst anteriorly it is continuous with the cellular

base of the common superficial fascia of the scrotum and abdomen.

So that the genital portion of the perineum consists of two layers of fascia, which are connected posteriorly and at the sides, and enclose a triangular space, in which are contained the root of the penis, with its muscles, vessels, and nerves. Externally to the superficial perineal fascia, is the common superficial fascia of the body and the integument.

The *Posterior or anal portion of the perineum*, instead of a resisting membranous partition, like the deep perineal fascia, is divided from the cavity of the pelvis by a convex muscular septum, the levator ani muscle, which arises from nearly the whole circumference of the interior of the pelvis, and is inserted around the extremity of the rectum. A broad band of muscular fibres embraces the lower end of the intestine, forming the internal sphincter; and superficially to it is the flat ellipse of the external sphincter, which is covered by the common superficial fascia and integument.

Dissection.—To dissect the perineum the subject should be fixed in the position for lithotomy, that is, the hands should be bound to the soles of the feet, and the knees kept apart. An easier plan is the drawing of the feet upwards by means of a cord passed through a hook in the ceiling. Both of these means of preparation have for their object the full exposure of the perineum. And as this is a dissection which demands some degree of delicacy and nice manipulation, a strong light should be thrown upon the part. Having fixed the subject, and drawn the scrotum upwards by means of a string or hook, carry an incision from the base of the scrotum along the ramus of the pubis and ischium and tuberosity of the ischium, to a point parallel with the apex of the coccyx; then describe a curve over the coccyx to the same point on the opposite side, and continue the incision onwards along the opposite tuberosity, and ramus of the ischium, and ramus of the pubis, to the opposite side of the scrotum, where the two extremities may be connected by a transverse incision. This incision will completely surround the perineum, following very nearly the outline of its boundaries. Now let the student dissect off the integument carefully from the whole of the included space, and he will expose the fatty cellular structure of the common superficial fascia, which exactly resembles the superficial fascia in every other situation.

Having exposed the *Common superficial fascia*, the student repeats the incision by which he divided the integument, and dissects off the common superficial fascia in the same way as the preceding layer.

This dissection displays the *superficial perineal fascia*, which is analagous to the deep fascia of other regions; but, from the circumstance of another layer in the perineum assuming the title of *deep*, we must for the present submit to this apparent departure from the unity of plan which we have heretofore had ample evidence of in the pursuit of our dissections.

The *Superficial perineal fascia* is very tough and resisting in the genital region, thin and ill-defined in the anal region. The latter portion scarcely deserves our attention; the former requires careful examination. It is firmly attached to the ramus of the pubis and ischium on each side, nearly as far back as the tuberosity, where it becomes continuous with the deep perineal fascia. In front it is continuous with the covering of the scrotum, called dartos.

It follows from this arrangement, that if urine had escaped from the urethra at the point where that tube had just traversed the deep perineal fascia, it would be unable to follow the laws of gravity, and pass backwards towards the anus, on account of the communication between the superficial perineal fascia and the deep perineal fascia. It could not pass outwards into the thighs, on account of the connexion of the superficial perineal fascia to the ramus of the pubis and ischium. It would, therefore, burrow among the muscles at the root of the penis, and be constrained to follow the direction of the penis forwards into the scrotum and thence upwards into the cellular tissue of the lower part of the abdomen.

An abscess in this situation is excessively painful, on account of the tension and resistance of the superficial perineal fascia; and, unless speedily opened by the surgeon, might give rise to consequences dangerous to life.

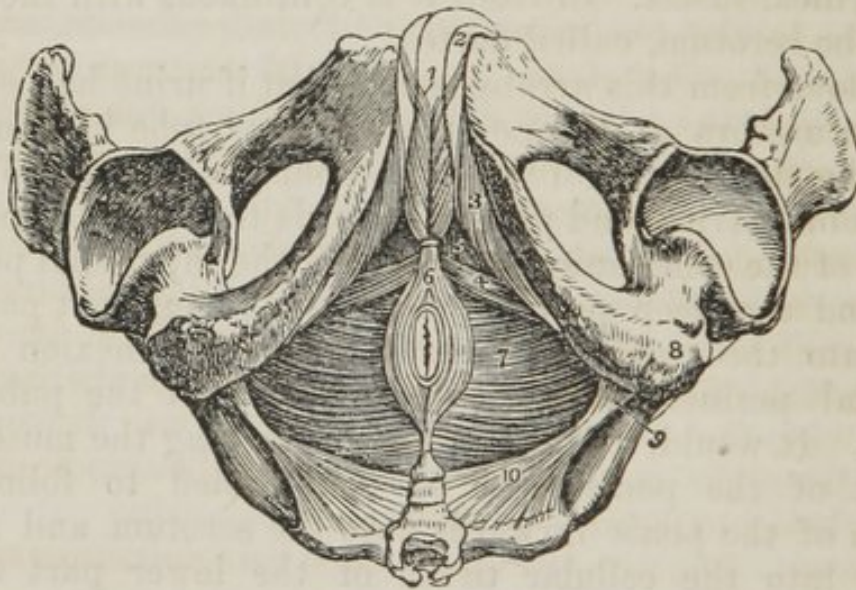
The best manner of dissecting the superficial perineal fascia is to make an incision from the middle point of the upper incision to the tuberosity of the ischium on each side. We thus form a \wedge shaped flap, which on being turned downwards (*fig.* 66. 4.) displays very distinctly the continuity of this fascia with the deep perineal fascia (6.) The two side flaps (5. 5.)

are then to be dissected outwards, and the firm connexion between this fascia and the ramus of pubis and ischium demonstrated.

When the student has thus satisfied himself of the connexions of the superficial perineal fascia, he must proceed to remove the fat and cellular tissue, which conceal from view the muscles and superficial vessels of the perineum. In the middle line is the projection of the corpus spongiosum, and on each side the commencement of the corpora cavernosa (crura penis.) Upon these bodies are situated two pairs of muscles, and, between them, the superficial perineal vessels and nerves. To see the muscles clearly, the vessels and nerves on one side had better be dissected away with the fat and cellular tissue.

The *Muscles of the genital region of the perineum*, are the Acceleratores urinæ, Erectores penis, Transversi perinei.

Fig. 62. The muscles of the perineum.



1. The acceleratores urinæ muscles; the figure rests upon the corpus spongiosum penis. 2. The corpus cavernosum of one side. 3. The erector penis of one side. 4. The transversus perinei of one side. 5. The triangular space through which the deep perineal fascia is seen. 6. The sphincter ani; its anterior extremity is cut off. 7. The levator ani of the left side; the deep space between the tuberosity of the ischium (8) and the anus, is the ischio-rectal fossa; the same fossa is seen upon the opposite side. 9. The spine of the ischium. 10. The left coccygeus muscle. The boundaries of the perineum are well seen in this engraving.

The *Acceleratores urinæ* arise from a tendinous point in the centre of the perineum and from the raphé. From these origins the fibres diverge like the plumes of a pen; the in-

ferior fibres are *inserted* into the ramus of the pubis and ischium; the middle completely encircle the corpus spongiosum, and meet upon its upper side; and the anterior spread out upon the corpus cavernosum on each side, into which they are inserted.

The insertions of these muscles may be seen by carefully raising one muscle from the corpus spongiosum and tracing its fibres.

The *Erector penis* arises from the ramus and tuberosity of the ischium and is *inserted* into the corpus cavernosum on each side.

The *Transversus perinei* arises from the tuberosity of the ischium on each side, and is *inserted* into the central tendinous point of the perineum.

The *Anal portion of the perineum* must now be examined. When the superficial fascia is dissected off, a thin layer of muscular fibres will be observed, surrounding the anus like an ellipse: this is the *external sphincter ani*. It is attached anteriorly to the tendinous point of the perineum, and posteriorly to the point of the coccyx. If this muscle be carefully removed, the edge of a flat band of muscular fibres will be found embracing the lower extremity of the rectum; this is the *sphincter ani internus*.

Surrounding the anus is a quantity of loose cellular tissue, containing adipose matter and some small arterial branches,—the external hemorrhoidal: this is the seat of the burrowing sinuses which often occur in this region. When the fat is dissected away, the fibres of the levator ani will be seen converging from the circumference of the pelvis, to be inserted into the lower extremity of the rectum.

ACTIONS.—The acceleratores urinæ being continuous at the middle line, and attached on either side to the bone, will support the spongy portion of the urethra, and acting suddenly, will propel the last drops of urine or the semen from the canal. The erector penis is rather a depressor than an erector muscle. The erection of this organ results from internal distention. The muscle tends to draw it downwards while in this state, and probably serves the purpose of a stay, to direct its course in its appropriate function. The transverse muscles serve to steady the tendinous centre, that the muscles attached to it may obtain a firm point of support.

The *External sphincter* contracts the integument around the anus, and by its attachment to the tendinous centre, and to the point of the coccyx, assists the levator ani in giving support to the opening during expulsive efforts. The *internal sphincter* contracts the extremity of the cylinder of the intestine. The levator ani acts in unison with the diaphragm, and rises and falls like that muscle in forcible respiration. Yielding to the propulsive action of the abdominal muscles, it enables the outlet of the pelvis to bear a greater force than a resisting structure, and on the remission of such actions, it restores the perineum to its original form.

Arteries.—The perineal arteries are branches of the internal pudic, one of the terminal divisions of the internal iliac.

The INTERNAL PUDIC ARTERY leaves the pelvis through the great sacro-ischiatic foramen below the pyriformis muscle, crosses the spine of the ischium, and re-enters the pelvis through the lesser sacro-ischiatic foramen; it then crosses the internal obturator muscle to the ramus of the ischium, being situated at about an inch from the margin of the tuberosity, and bound down by the obturator fascia; it next ascends the ramus of the ischium, enters between the two layers of the deep perineal fascia, lying along the border of the ramus of the pubis, and at the symphysis pierces the anterior layer of the deep perineal fascia, very much diminished in size, and reaches the dorsum of the penis, along which it runs, supplying that organ under the name of dorsalis penis. Its branches are—

Within the pelvis—

Middle hemorrhoidal;

In the perineum—

External hemorrhoidal (3 or 4.)

Superficialis perinei,

Transversalis perinei,

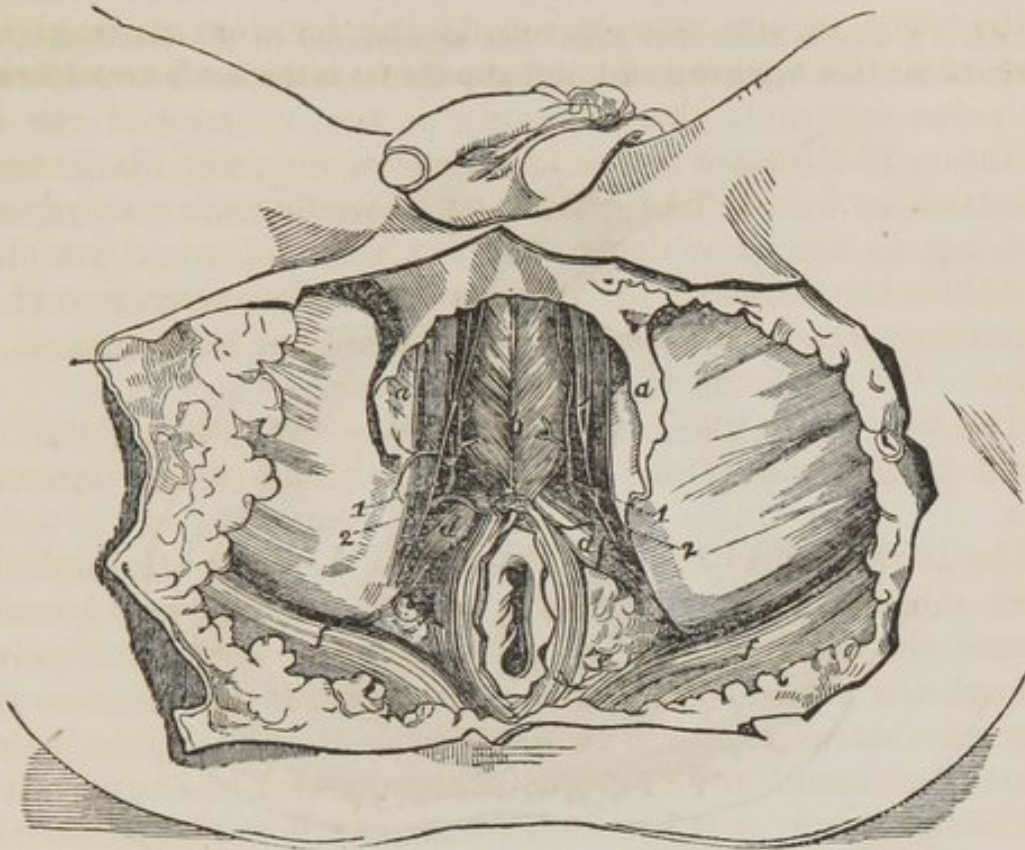
Arteria bulbosi,

Arteria corporis cavernosi,

Arteria dorsalis penis.

The *External hemorrhoidal arteries* are three or four small branches given off by the internal pudic while behind the tuberosity of the ischium. They are distributed to the anus, and to the muscles and fascia in the anal region.

Fig. 63. The perineum and part of the thighs after the skin and a portion of the superficial fascia had been removed.



a. Superficial fascia. *b.* Accelerator urinæ. *c.* Erector penis. *d.* Transversus perinei. *e.* Upper point of sphincter ani. *f.* The edge of the gluteus maximus.—1. Superficial perineal artery. 2. Superficial perineal nerve.

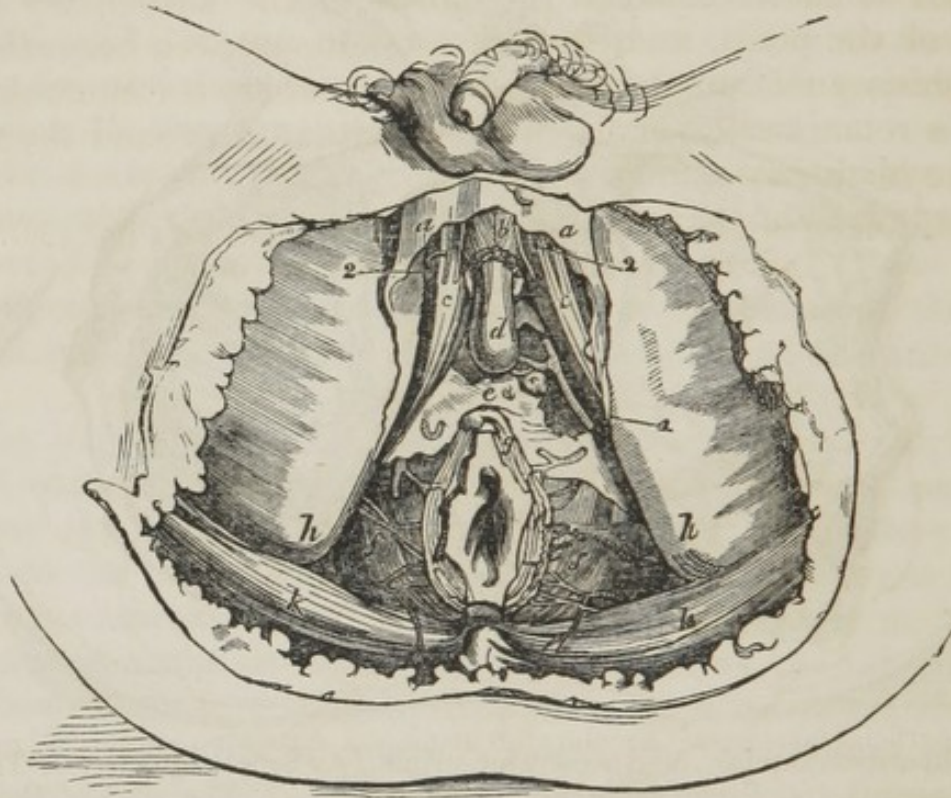
The *Superficial perineal artery* is given off near the attachment of the crus penis: it pierces the connecting layer of the superficial and deep perineal fascia, and runs forwards in front of the transversus perinei muscle, and along the groove between the accelerator urinæ and erector penis to the scrotum, to which it is distributed. It gives nutrient branches to the perineum as it passes forwards. One of these, larger than the rest, crosses the perineum, resting on the transversus perinei muscle: and is therefore named *transversalis perinei*.

The three remaining arteries are the proper vessels of the penis; they are distributed to the corpus spongiosum, corpora cavernosa, and dorsum penis.

The *Artery of the bulb* (*fig. 66. 13*) is given off from the pudic nearly opposite the opening for the transmission of the urethra: it passes obliquely inwards between the two layers

of the deep perineal fascia, and pierces the anterior layer to enter the corpus spongiosum, to which it is distributed.

Fig. 64. A deeper dissection than that represented in the last figure, the perineal muscles being removed, and also the fat in the ischio-rectal fossa.



a. Superficial fascia. *b.* Accelerator urinæ. *c.* Crus penis. *d.* The bulb. *e.* Triangular ligament of urethra. *f.* Levator ani. *g.* Sphincter. *h.* Tuberosity of ischium. *k.* Glutæus maximus. *Cowper's gland of the left side. 1. Pudic artery. 2. Superficial perineal artery and nerve. The inferior hemorrhoidal arteries and the artery of the bulb are likewise shown.

The *Artery of the corpus cavernosum* (*fig. 66. 14.*) pierces the crus penis, and runs forwards in its interior, supplying its cellular structure.

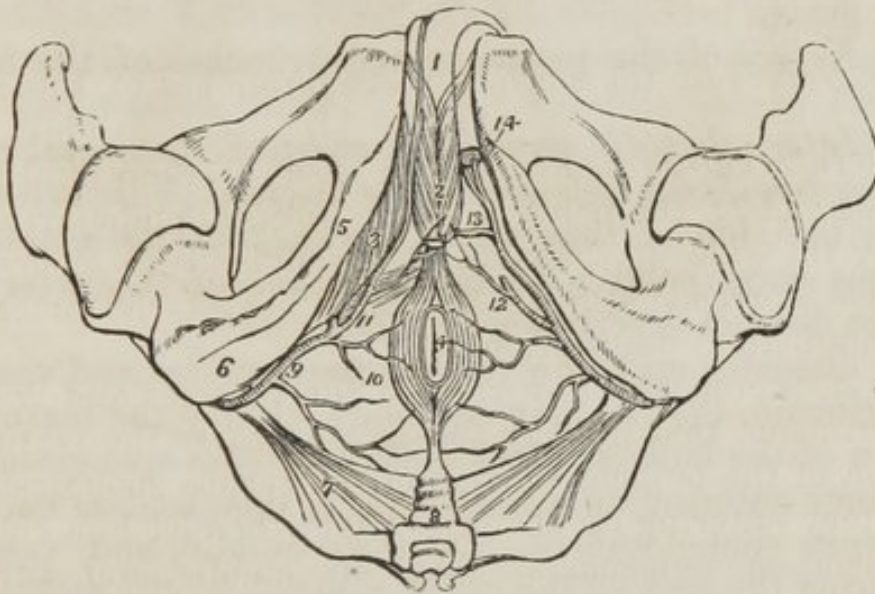
The *Dorsal artery of the penis* (*fig. 66. 15.*) ascends between the two crura and the symphysis pubis to the dorsum penis, and runs forwards by the side of the suspensory ligament in the groove between the corpora cavernosa to the glans, distributing branches in its course to the body of the organ and to the integument.

The *Veins* of the perineum require no distinct notice: they maintain the same relation to the arteries that the smaller veins do in other parts.

The principal vein of the penis, the *great dorsal vein*, is remarkable both for its mode of origin and for its size. It

commences by a number of veins, which return the blood from the glans penis, and which converge to form a vessel of considerable bulk, which runs in the groove between the dorsal arteries, and receives veins from the corpora cavernosa in its course: it passes between the fibres of the suspensory ligament of the penis, and through a tendinous arch beneath the symphysis pubis, to the prostate gland, where it communicates with a remarkable plexus of veins, situated around the neck of the bladder.

Fig. 65. The arteries of the perineum; on the right side the superficial arteries are seen, and on the left the deep.



1. The penis, consisting of corpus spongiosum and corpus cavernosum. The crus penis on the left side is cut through. 2. The acceleratores urinæ muscles, enclosing the bulbous portion of the corpus spongiosum. 3. The erector penis, spread out upon the crus penis of the right side. 4. The anus, surrounded by the sphincter ani muscle. 5. The ramus of the ischium and os pubis. 6. The tuberosity of the ischium. 7. The lesser sacro-ischiatic ligament, attached by its small extremity to the spine of the ischium. 8. The coccyx. 9. The internal pudic artery, crossing the spine of the ischium, and entering the perineum. 10. External hæmorrhoidal branches. 11. The superficialis perinei artery, giving off a small branch, transversalis perinei, upon the transversus perinei muscle. 12. The same artery on the left side cut off. 13. The artery of the bulb. 14. The two terminal branches of the internal pudic artery; one is seen entering the divided extremity of the crus penis, the artery of the corpus cavernosum; the other, the dorsalis penis, ascends upon the dorsum of the organ.

The numerous veins which converge from the glans to form the dorsal vein have a peculiar arrangement, and form a kind of plexus upon the neck of the penis.

In the dog, the dorsal vein is embraced by a muscle of

considerable size, while passing beneath the arch of the pubis, the *compressor venæ dorsalis*. This muscle has been described by Mr. Houston, of Dublin, as existing in the human subject. It *arises* from the ramus of the pubis on each side, and, arching upwards, unites by a thin tendon with its fellow of the opposite side, over the dorsal vein. The two muscles, when in action, would therefore draw down the tendon, and compress the vein against the root of the penis.

The dorsal vein of the penis is so large, and its communications with the pelvic veins so free, that we have frequently succeeded in injecting the right side of the heart and veins of the neck by placing the injecting-pipe in the dorsal vein of the penis.

The *Nerves* of the perineum are branches of the internal pudic.

The *Internal pudic nerve* is an offset of the sacral plexus: it passes out of the pelvis with the internal pudic artery, and lies by the side of that vessel throughout its course. Its branches correspond with the branches of the artery, and need no distinct description.

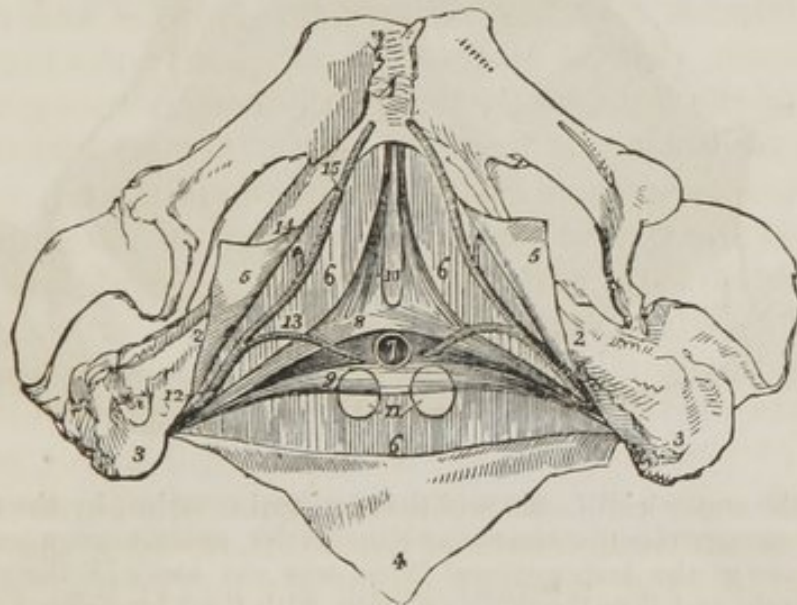
The dissector may now remove the muscles and vessels of the perineum, that he may see more clearly the texture and position of the bulbous portion of the corpus spongiosum with the artery entering its posterior part; then let him cut across the corpus spongiosum at about its middle, and, turning it down from the rest of the penis, remove it altogether by dividing the urethra close to the deep perineal fascia. This proceeding displays the convergence of the crura penis, and the round opening in the deep perineal fascia, through which the urethra passes. The student must then carefully dissect off the anterior layer of the deep perineal fascia, which will bring into view the membranous part of the urethra, the compressor urethræ muscle (*fig. 66. 8. 9. 10.*) the artery of the bulb, (13.) the internal pudic artery (12.) at each side, and two small yellowish bodies (11.) about the size of lentils, placed immediately beneath the urethra, Cowper's glands.

The *Compressor urethræ** muscle, *fig. 66.*, [Wilson's and Guthrie's muscles,] consists of two portions: one of which is

* For the opportunity of giving the description of this muscle, we are indebted to the liberality and courtesy of Mr. Guthrie, and also to Mr. Charles Guthrie, who removed the preparation from its bottle that we might examine it thoroughly.

transverse in its direction, and passes inwards to embrace the membranous urethra; the other is *perpendicular*, and descends from the pubis. The *transverse portion*, discovered by Mr. Guthrie, *arises*, by a narrow tendinous point, from the upper part of the ramus of the ischium, on each side, and divides into two fasciculi, 8. 9., which pass inwards and slightly upwards, and embrace the membranous portion of the urethra and Cowper's glands. As they pass towards the urethra, they spread out and become fan-shaped, and are *inserted* into a tendinous raphé upon the upper and lower surfaces of the urethra, extending from the apex of the prostate gland, to which they are attached posteriorly, to the bulbous portion of the urethra, with which they are connected in front. When seen from above, these portions resemble two fans, connected by their expanded border along the middle line of the membranous urethra, from the prostate to the bulbous portion of the urethra. The same appearance is obtained by viewing them from below.

Fig. 66. The structures contained between the two layers of the deep perineal fascia.

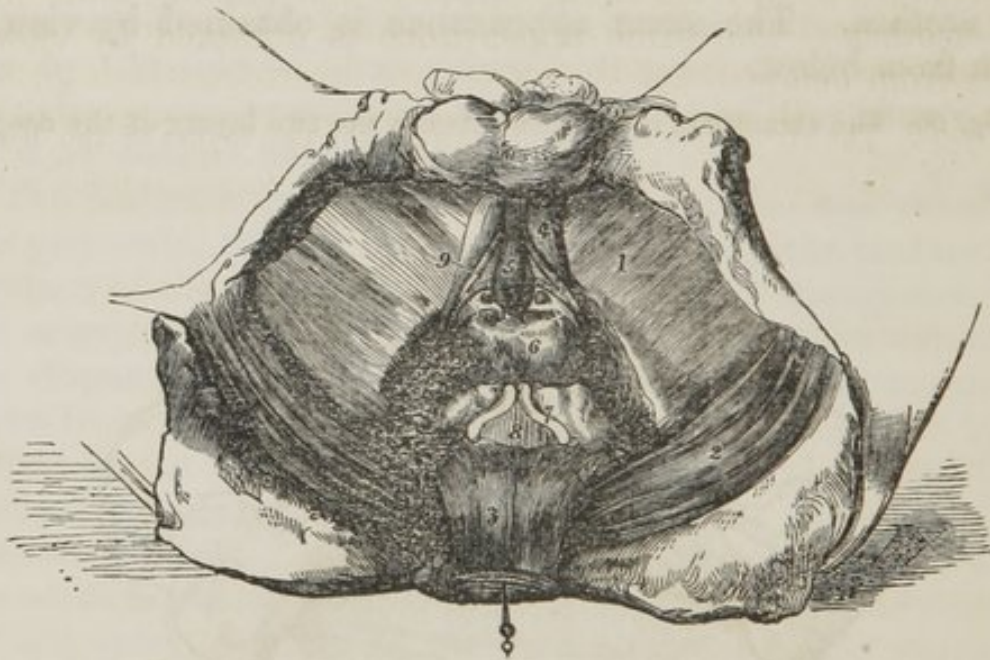


1. The symphysis pubis. 2. 2. The ramus of the pubis and ischium. 3. 3. The tuberosities of the ischia. 4. A triangular portion of the superficial fascia turned down, and shown to be continuous with the deep fascia (6.) 5. 5. Two portions of the superficial perineal fascia, showing its connexion to the ramus of the pubis and ischium. 6. 6. The posterior layer of the deep perineal fascia, the anterior layer having been removed. 7. The membranous portion of the urethra cut across. 8. The superior fasciculus of the compressor urethrae muscle of one side. 9. The inferior fasciculus of the compressor urethrae. The two fasciculi, (8.) and (9.,) constitute Guthrie's muscle of one side. 10. The pubic portions of the compressor

urethræ, Wilson's muscles. 11. Cowper's glands, partly embraced by the lower fasciculus of the compressor urethræ muscle. 12. The internal pudic artery passing posteriorly to the crus of the compressor urethræ. 13. The artery of the bulb. 14. The artery of the corpus cavernosum. 15. The arteria dorsalis penis.

The *Perpendicular portion* (*fig. 66. 10.*,) described by Mr. Wilson, *arises* by two tendinous points from the inner surface of the arch of the pubis, on each side of, and close to the symphysis. The tendinous origins soon become muscular, and descend perpendicularly to be *inserted* into the upper fasciculus of the transverse portion of the muscle; so that it is not a distinct muscle surrounding the membranous portion of the urethra, and supporting it as in a sling, as was described by Mr. Wilson, but merely an upper origin of the more important muscle discovered by Mr. Guthrie.

Fig. 67.



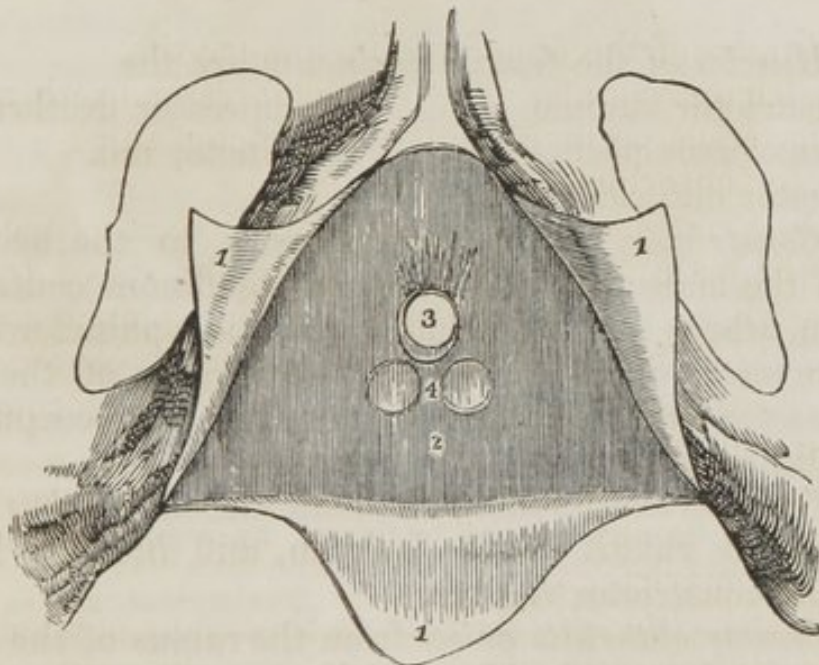
Besides the superficial fascia and the perineal muscles, by the removal of which the spongy erectile tissue and the crura penis were uncovered, the anterior layer of the deep perineal fascia was cut away in the preparation for this sketch, and thus the pudic arteries, with their branches for the bulb. and Cowper's glands have been laid bare. The rectum, too, having been dissected from its connexions and drawn back, the prostate gland, the seminal vesicles, and part of the urinary bladder have been brought into view.— 1. Fascia lata covering the adductor muscles of the thigh. 2. Gluteus maximus. 3. Rectum. 4. Crus penis of left side. 5. Corpus spongiosum urethræ. 6. Prostate. 7. Vesicula seminalis and vas deferens of left side. 8. A small part of urinary bladder. 9. Right dorsal artery, with the artery of the bulb and Cowper's gland resting against the inner layer of the deep perineal fascia. The last-named parts are at considerable depth, but the size within which it was necessary to restrict the drawing, did not admit of the appearance of depth being sufficiently preserved in this representation.

The compressor urethræ may be considered either as two symmetrical muscles meeting at the raphé, or as a single muscle: we have adopted the latter course in the above description, as appearing to us the more consistent with the general connexions of the muscle, and with its actions.

The internal pudic artery (*fig. 66. 12.*) lies behind the transverse portion of the muscle at each side, near its attachment to the ischium. The artery of the bulb, 13., is given off from the pudic above the transverse portion, and passes inwards in front of the muscle, to enter the posterior part of the bulb.

ACTIONS.—Taking its fixed point from the ramus of the ischium at each side, “it can,” says Mr. Guthrie, “compress the urethra so as to close it; I conceive completely, after the manner of a sphincter.” The transverse portion will also have a tendency to draw the urethra downwards, whilst the perpendicular portion will draw it upwards towards the pubis. The inferior fasciculus of the transverse muscle, enclosing Cowper’s glands, will assist them in evacuating their secretion.

Fig. 68. The pubic arch with the attachments of the perineal fascia.



1, 1, 1. The superficial perineal fascia divided by a Λ shaped incision into three flaps; the lateral flaps are turned over the ramus of the os pubis and ischium at each side, to which they are firmly attached; the posterior flap is continuous with the deep perineal fascia. 2. The deep perineal fascia. 3. The opening for the passage of the membranous portion of the urethra, previously to entering the bulb. 4. Two projections of the anterior layer of the deep perineal fascia, corresponding with Cowper’s glands.

Cowper's glands (*fig. 66. 11. fig. 69. 16.*) are two small clusters of mucous follicles, which pour their secretion by two slender ducts into the bulbous portion of the urethral canal. They are enclosed by the fibres of the compressor urethræ muscle, by which they are assisted in the excretion of their proper fluid.

The rest of the anatomy of this region belongs to the viscera of the pelvis.

Perineum in the Female.

The structures in the female perineum are the same as in the male, but somewhat modified to suit the difference of form in the organs of generation. The integument and superficial fascia are thrown into folds, called labia, to prepare for the enormous distention to which this part is submitted in parturition. The entrance of the vagina is encircled by a sphincter, which is not unlike the accelerator urinæ of the male. The clitoris is the penis of the female, composed of its two corpora cavernosa, and therefore provided with erectores clitoridis analogous to the erectores penis. The transversus perinei, sphincters, and levator ani, are precisely the same as in the male.

The *Muscles* of the *female perineum* are the

Constrictor vaginæ,	Compressor urethræ,
Transversus perinei,	Sphincter ani.
Erector clitoridis,	

The *Constrictor vaginæ* is analogous to the accelerator urinæ of the male: it *arises* from the tendinous centre of the perineum, where it is continuous with the sphincter ani, and passes forwards on each side of the entrance of the vagina, to be *inserted* into the ramus of the pubis and corpus cavernosum clitoridis.

The *Transversus perinei* is a small muscle *arising* on each side from the ramus of the ischium, and *inserted* into the side of the constrictor vaginæ.

The *Erector clitoridis* *arises* from the ramus of the ischium, and is *inserted* on each side into the crus clitoridis.

The *Compressor urethræ* has the same origins and insertions, and exercises the same functions in the female as in the male.

The *Sphincter ani* surrounds the lower extremity of the rectum, as in the male.

The *Levator ani* is inserted into the side of the vagina and rectum.

The *Arteries* of the perineum are branches of the internal pudic, and are distributed as in the male : they are the

External hemorrhoidal,
Superficialis perinei,
Vaginal arteries,
Artery of the corpus cavernosum,
Artery of the dorsum clitoridis.

The *Nerves* accompany each of the branches of the artery, and are also derived from the internal pudic and from the hypogastric plexus.

CHAPTER XI.

PELVIS AND ORGANS OF GENERATION.

THE student must now turn his attention to the study of the viscera of the pelvis; therefore, after examining their relative position from above, he should proceed to separate the os innominatum of the left side; so as to obtain a side view of these organs. For this purpose he must divide the pubis with the saw on the left side, a little external to the symphysis. Then let him cut through the psoas muscle and iliac vessels opposite the sacro-iliac symphysis, and divide the ligaments $\frac{1}{2}$ of that articulation. Next cut away with the scalpel the structures adhering to the inner surface of the pubis and ischium of the same side, force the os innominatum outwards and remove it altogether. We shall first consider the contents of the male, and then of the female pelvis.

The *Viscera* of the *male pelvis* are the

Bladder,	Vesiculæ seminales,
Prostate gland,	Rectum.

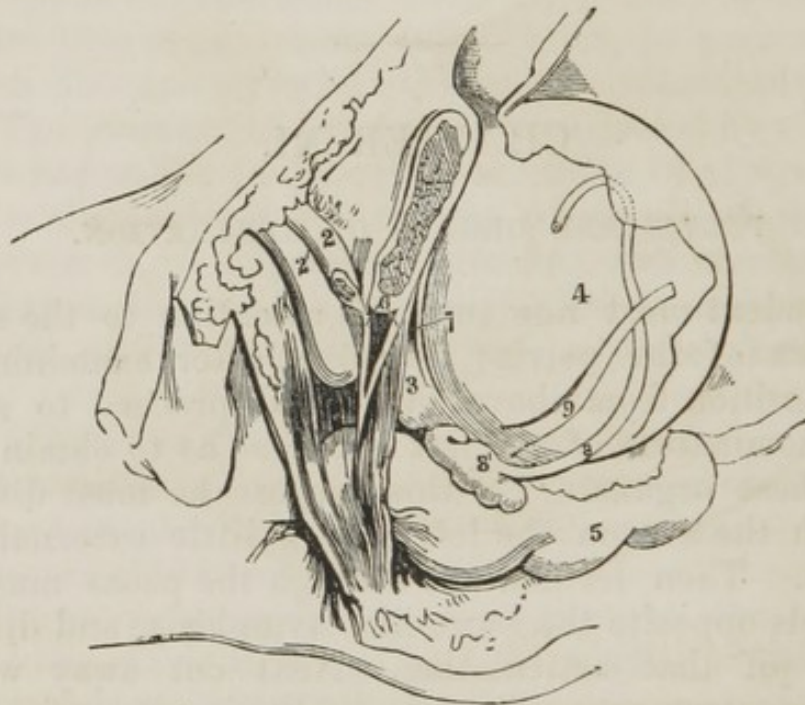
A careful dissection of the side of the pelvis, when the os innominatum has been removed, will bring these organs distinctly into view.

BLADDER.—The *Bladder* is an oblong membranous viscus, situated behind the pubis and in front of the rectum. It is larger in its vertical axis than from side to side. It is divided into *body*, *fundus*, *base*, and *neck*. The *body* (*fig. 69. 4.*)

comprehends the middle zone of the organ; the *fundus*, its upper segment; the *base*, the lower broad extremity, which rests upon the rectum; and the *neck* the narrow constricted portion which is applied against the prostate gland. The bladder is retained in its proper situation by ligaments.

The walls of the pelvis, in addition to the bones by which they are formed, are lined internally by the peritoneum; the pelvic fascia, (*fig. 69. 7.*) which is continued downwards from the iliac fascia, and is attached below to the sides of the bladder and rectum; the levator ani muscles, the obturator fascia, and the internal obturator muscle.

Fig. 69. The pelvic viscera of the male seen on the left side.



1. The body of the left pubes sawed through. 2. Corpus cavernosum penis. 2'. Corpus spongiosum. 3. Prostate gland, with a portion of the levator ani covering its fore part. 4. Urinary bladder. 5. Intestinum rectum. 6. Deep perineal fascia—its two layers. 7. Cut edge of the pelvic fascia, extending from the pubes to the back part of the prostate. 8. Vas deferens. 8'. Vesicula seminalis. 9. Ureter. The cut edge of the peritoneum is seen jagged over the bladder and the rectum. 510

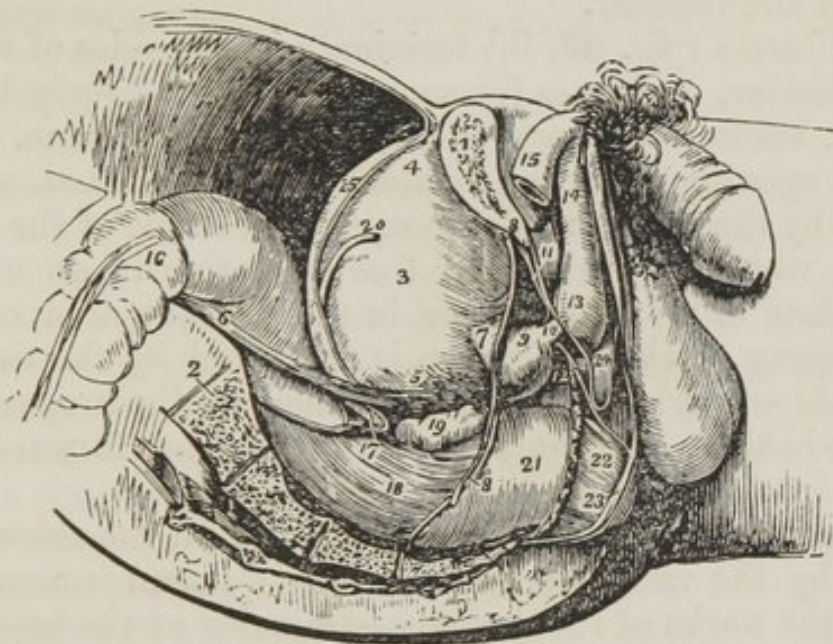The *Ligaments of the bladder* are the *true* and *false*; the *true ligaments* are seven in number, two posterior, two anterior, two umbilical ligaments, and the urachus. The *false ligaments* are four in number, and are formed by the peritoneum.

The two *Posterior ligaments* are formed by the reflection of the pelvic fascia upon the sides of the base of the bladder.

The *Anterior ligaments* (fig. 69. 7.) are also formed by the pelvic fascia, which passes from the inner surface of the pubis, on each side of the symphysis, to the front of the bladder.

The *Umbilical ligaments* are the fibrous cords which result from the obliteration of the umbilical arteries of the fœtus; they pass forwards on each side of the fundus of the bladder, and ascend beneath the peritoneum to the umbilicus.

Fig. 70. A side view of the viscera of the male pelvis in situ. The right side of the pelvis has been removed by a vertical section made through the os pubis, near to the symphysis: and another through the middle of the sacrum.



1. The divided surface of the os pubis. 2. The divided surface of the sacrum. 3. The body of the bladder. 4. Its fundus; from the apex is seen passing upwards the urachus. 5. The base of the bladder. 6. The ureter. 7. The neck of the bladder. 8. 8. The pelvic fascia; the fibres immediately above 7 are given off from the pelvic fascia and represent the anterior ligaments of the bladder. 9. The prostate gland. 10. The membranous portion of the urethra, between the two layers of the deep perineal fascia. 11. The deep perineal fascia formed of two layers. 12. One of Cowper's glands between the two layers of deep perineal fascia, and beneath the membranous portion of the urethra. 13. The bulb of the corpus spongiosum. 14. The body of the corpus spongiosum. 15. The right crus penis. 16. The upper part of the first portion of the rectum. 17. The recto-vesical fold of peritoneum. 18. The second portion of the rectum. 19. The right vesicula seminalis. 20. The vas deferens. 21. The rectum covered with the descending layer of the pelvic fascia, just as it is making its bend backwards to constitute the third portion. 22. A part of the levator ani muscle investing the lower part of the rectum. 23. The external sphincter ani. 24. The interval between the deep and superficial perineal fascia; they are seen to be continuous beneath the figure.

The *Urachus* is a fibrous cord formed by the obliteration of a tubular communication in the embryo; it is very strong and is attached to the apex of the bladder, and thence ascends to the umbilicus.

The umbilical ligaments and urachus guide the ascent of the bladder in retention of urine.

The *False ligaments* are folds of the peritoneum.

The two *Posterior* correspond with the passage of the ureters from the pelvis to the base of the bladder; and the two *lateral* are formed by the vasa deferentia, as they pass inwards from the internal abdominal ring to the sides of the fundus of the bladder.

The *Ureters* (*fig. 69. 9.*) terminate in the sides of the base of the bladder, and pass for some distance obliquely between its coats, before they open on the mucous membrane.

Their openings into the bladder are constricted, and surrounded by the thick and dense submucous issue of the trigone vesicale, which prevents their free dilatation in an over distended state of the bladder, or in the passage of a calculus. The obliquity of their entrance is preserved by the two *muscles of the ureters*, which are attached to their openings of entrance behind, and converge as they advance forwards to be inserted into the fibrous tissue of the uvula.

The ureters are crossed in their course on the sides of the bladder by the vasa deferentia, which descend internally to them to the necks of the vesiculæ seminales at the base of the prostate gland.

The *Coats of the bladder* are three—a partial external coat, derived from the *peritoneum*, a *muscular coat*, and an internal lining membrane, or *mucous coat*. The *peritoneal coat* covers the posterior surface and sides of the bladder, from about opposite the point of termination of the two ureters to its summit, whence it is guided to the anterior wall of the abdomen by the umbilical ligaments and urachus. The *muscular coat* consists of two layers of muscular fasciculi, which are disposed around the bladder in various directions, and cross each other in their course. Those of the *external layer* are longitudinal; they commence upon the upper surface of the prostate, where they are clustered together, and are firmly connected with the anterior ligaments of the bladder. Hence the lower fibres of these ligaments are sometimes called the *tendons of the bladder*. They then pass upwards

upon the anterior surface of the organ, turn around its fundus, and return upon the posterior surface to the base of the prostate gland, where they are inserted into the fibrous tissue of the neck of the bladder. The lateral fibres pass off obliquely upon the sides of the organ, and some form loops of support to the ureters at their entrance between the coats of the bladder. The *internal layer* is best dissected by removing the mucous membrane from the inner surface of the bladder: it may also be demonstrated by dissecting off the longitudinal layer. The internal layer consists of muscular fibres, which are disposed in an oblique, spiral, and transverse direction, and cross each other frequently. They cease almost entirely at the neck of the bladder, and very few transverse fibres can be detected in this situation, so that the term "*sphincter vesicæ*" is very incorrect. This has been very clearly proved by the investigations of Mr. Guthrie.

The aggregate of the muscular fibres of the bladder is called *detrusor urinæ*.

The *mucous coat* is thick and smooth, and in a contracted state is thrown into a number of rugæ. It lines the interior of the bladder, is continuous, by means of the ureters, with the mucous lining of the kidney and uriniferous tubuli, and, through the urethra, with the prostatic cœca, seminiferous tubuli, and Cowper's glands. It is but loosely connected with the muscular coat, and is sometimes, as in violent exertion, or in the continued efforts arising from the irritation of stone, or old stricture, forced between its fibres, and made to form a protrusion externally to the bladder. This is *encysted bladder*, and several of these cysts may exist in the same individual. Sometimes they contain calculi; and, when a stone has escaped into one of these sacs, it ceases to be a source of irritation to the patient.

The *Submucous tissue* is moderately thick throughout the whole of the bladder; but around the openings of the ureters, at the trigone vesicale, and around the neck of the bladder and urethra, it becomes still thicker, more dense, and "elastic, and is continuous with the elastic membrane of the urethra." Mr. Guthrie considers it as a "superadded structure," which by becoming thickened in chronic disease of the bladder, gives rise to the formation of a "bar or dam," quite independent of any enlargement of the prostate gland, and forms

a considerable, and even fatal obstruction to the passage of the urine.

Upon the inner wall of the *base of the bladder*, is a triangular smooth surface called "*trigone vesicale*," which is the most sensitive part of the whole organ, so that when rough calculi become placed against it, they give rise to extreme pain. The apex of the angle is situated at the commencement of the urethra, and corresponds with the projection of mucous membrane called *uvula vesicæ*; the posterior angles are formed by the openings of the ureters. The sides are bounded by two elevated ridges of mucous membrane, produced by two muscular bands, which pass from the extremities of the ureters to the commencement of the urethra; these are the *muscles of the ureters*; they consist partly of muscular and partly of elastic tissue. The three sides of the trigone are about an inch and a quarter in length.

The external surface of the *trigone vesicale* is also triangular, and is closely adherent to the rectum. It is bounded behind by the fold of peritoneum that passes from the rectum to the bladder; on each side by the vasa deferentia and vesiculæ seminales, and the apex, by the third lobe of the prostate gland. It is through this triangle that the opening is made in the recto-vesical operation for puncture of the bladder. The operator must therefore be careful in selecting the centre of the space: if he push the trochar too near the prostate, he may wound that gland and not enter the bladder; if to either side, the vasa deferentia or vesiculæ seminales may be transfixed; and if too far posteriorly he may wound the peritoneum, and anticipate all the dangers of peritoneal inflammation. The adhesion between the bladder and rectum might also be separated by an inexperienced operator.

The URETHRA is the excretory canal of the bladder, it commences at the neck of that organ, and terminates at the meatus upon the glans penis. It is about nine inches long, and is divided into three portions; the *prostatic*, *membranous*, and *spongy*.

The *Prostatic urethra* is the most dilated part of the canal, and is a little more than an inch in length. It is situated in the prostate gland, one-third nearer to the upper than to the lower surface of that body. Upon its inferior wall or floor is a lengthened fold of mucous membrane, called *caput gallina-*

ginis, (cockscomb) or *veru montanum*. At the commencement of this fold is a pouch of the mucous membrane, the *sinus pocularis*, and into this pouch open the two *ejaculatory ducts* from the *vesiculæ seminales*. On either side of the *veru montanum* are a number of openings, the terminations of the *prostatic ducts*.

The *Membranous portion* of the urethra is the narrowest part of the canal, is a little less than an inch in length, and is situated within the two layers of the deep perineal fascia. Its coverings are, the mucous lining; an elastic fibrous coat; a muscular covering from the compressor urethræ muscle; and a fibrous investment from the deep perineal fascia. Immediately that it escapes from the deep perineal fascia, it is received into the upper part of the bulb of the urethra, and becomes the spongy portion.

The *Spongy portion* of the urethra is named from being enclosed by the corpus spongiosum penis. The commencement of the corpus spongiosum forms the *bulb*, hence the included urethra is called the *bulbous portion*. Next to the prostatic portion, the bulbous is the most dilated part of the canal. In the body of the corpus spongiosum, the canal diminishes in size, but, within the glans penis, it forms a third dilatation called *fossa navicularis*, and, at the meatus contracts so much as to be smaller than at any other part of the tube.

The bulbous portion has, opening into it, the two small excretory ducts of *Cowper's glands*. These small bodies, (*fig. 66. 11.*) about the size of peas, are situated immediately beneath the membranous portion of the urethra, between the two layers of the deep perineal fascia, and are covered by the inferior fasciculus of the compressor urethræ muscle. They are composed of mucous follicles and their ducts, about three quarters of an inch in length, pass forwards to open into the bulbous urethra.

In the mucous membrane are a number of mucous follicles or *lacunæ*. These are most numerous upon the upper wall of the canal, and have their openings directed forwards so as to catch the point of a catheter in its passage into the bladder, and give rise to a temporary impediment. In a case of this kind the instrument should be withdrawn a little, and then pushed gently on, with a slight depression of the point.

One of these *lacunæ*, larger than the rest, is called *lacuna*

magna; it is situated at about an inch and a half from the meatus. It is said to be the seat of the secretion of the drop of matter which is squeezed from the urethra in old gonorrhœa.

PROSTATE GLAND.—The *Prostate gland* (*fig. 69. 3.*) surrounds the upper surface of the neck of the bladder, and is situated within the pelvis. It has the shape and size of a Spanish chestnut; the base being directed backwards towards the bladder, the apex forwards to the deep perineal fascia; the flat side upwards, and the convex side downwards. The latter lies in contact with the rectum, and may be distinctly felt through its coats.

It is retained in its place by the two tendons of the bladder, which are continuous with the anterior ligaments of the bladder, by the attachments of the pelvic fascia below, and by a process of the internal layer of the deep fascia, which forms a sheath around the membranous urethra, and is inserted into the prostate.

It consists of three lobes, *two lateral* and *a middle lobe*; the latter is a small transverse process connected with the base of the gland. It supports the elastic tissue which forms the projection of mucous membrane at the commencement of the urethra, called *uvula vesicæ*, and when enlarged presses the uvula inwards towards the interior of the bladder, and produces a great impediment to the flow of urine.

The *Ducts* of the prostate, from twenty to twenty-five in number, open into the prostatic urethra on each side of the *veru montanum*.

The urethra, in passing through the prostate, lies nearer to its upper than its lower surface.

VESICULÆ SEMINALES.—At the base of the prostate gland are the *vesiculæ seminales* (*fig. 69. 8.*) each formed by the convolutions of a single dilated tube, and enclosed in a dense fibrous membrane. Their larger extremities are directed backwards, and are separated from each other by a considerable interval; the smaller converge to a point anteriorly, and almost meet at the base of the prostate gland. They form in this manner the lateral boundaries of a triangular space, which corresponds with the triangle on the inner surface of the bladder, called *trigone vesicale*.

VASA DEFERENTIA.—The *Vas deferens* (*fig. 69. 8.*) from each testicle enters the abdomen at the internal abdominal

ring, and passes inwards to the side of the fundus of the bladder; it then descends along its posterior surface, and crosses the direction of the ureter to the base of the prostate gland. When it reaches the vesicula seminalis it becomes connected by cellular tissue to its inner border, and terminates by a small duct, which unites with a similar duct from the vesicula seminalis, to form the *ductus ejaculatorius*. The *ejaculatory duct* is about three quarters of an inch in length, and passes forwards between the prostate gland and the lining membrane of the urethra, to terminate near its fellow of the opposite side in the sinus pocularis.

If the bladder and rectum be separated from their lateral connexions and turned down, the attachments of the pelvic fascia and the levator ani muscle may next be seen and examined.

The *Pelvic fascia* is continuous with the iliac fascia along the border of the pelvis, and is prolonged downwards, so as to line the interior of its cavity. At its lower part it is reflected from the sides of the pelvis upon the rectum, the base of the bladder, and prostate gland, forming the *lateral true ligaments of the bladder*. In front it forms its *anterior true ligaments*. If this fascia be carefully raised, a thin layer of muscular fibres will be seen beneath it, which should now be dissected.

The *Levator ani* is a thin plane of muscular fibres situated on each side of the pelvis. It *arises* from the inner surface of the pubis, from the spine of the ischium, and between those points from the angle of union between the obturator and the pelvic fascia. Its fibres descend to be *inserted* into a raphé in front of the coccyx, into the lower part of the rectum, base of the bladder, and prostate gland.

Wilson's and Guthrie's muscles (the compressor urethræ) are situated between the two layers of the deep perineal fascia, and are described with the perineum.

ACTIONS.—The use of the levator ani is expressed in its name. It is the antagonist to the diaphragm and the rest of the expulsive muscles, and serves to support the rectum and vagina during their expulsive efforts. In the operation for lithotomy on children and emaciated persons, its action is often very remarkable, contracting spasmodically, and producing a fluttering which is very annoying to the operator.

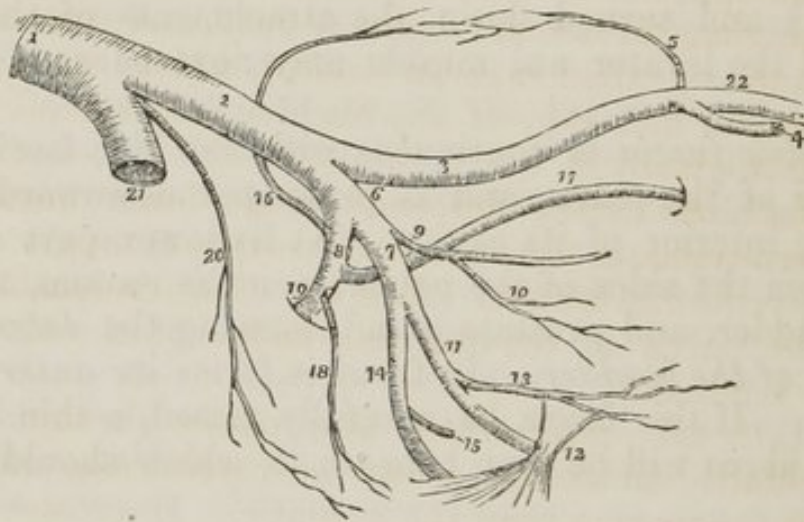
If the levator ani muscle be separated from its origin, and

turned downwards, the *obturator fascia* will be seen beneath, and the mode of origin of the middle fibres of the muscle may be examined. The obturator fascia binds down the internal obturator muscle, and covers in the internal pudic vessels and nerve.

The *Arteries and Nerves of the pelvis* should now be dissected. This is easily done by taking the trunk of the internal iliac as a guide to its branches.

The *Nerves* forming the sacral plexus may be traced from the anterior sacral foramina.

Fig. 71. The distribution and branches of the iliac arteries.



1. The aorta. 2. The left common iliac artery. 3. The external iliac. 4. The epigastric artery. 5. The circumflexa ilii. 6. The internal iliac artery. 7. Its anterior trunk. 8. Its posterior trunk. 9. The umbilical artery giving off [10] the superior vesical artery. After the origin of this branch, the umbilical artery becomes converted into a fibrous cord—the umbilical ligament. 11. The internal pudic artery passing behind the spine of the ischium (12) and lesser sacro ischiatic ligament. 13. The middle hemorrhoidal artery. 14. The ischiatic artery, also passing behind the anterior sacro ischiatic ligament to escape from the pelvis. 15. Its inferior vesical branch. 16. The ilio-lumbar, the first branch of the posterior trunk (8) ascending to inosculate with the circumflexa ilii artery (5) and form an arch along the crest of the ilium. 17. The obturator artery. 18. The lateral sacral. 19. The gluteal artery escaping from the pelvis through the upper part of the great sacro-ischiatic foramen. 20. The sacra-media. 21. The right common iliac artery cut short. 22. The femoral artery.

The INTERNAL ILIAC ARTERY, as soon as it enters the pelvis, divides into two trunks, an anterior and posterior; the *anterior division* has connected with it the remains of the umbilical artery, and then divides into the ischiatic and internal pudic arteries; the *posterior division* gives off the smaller

pelvic branches, and passing out of the pelvis becomes the gluteal artery. The *branches* may be thus arranged.

Anterior Trunk.

Umbilical,
Ischiatic,
Internal pudic,

Posterior Trunk.

Ilio-lumbar,
Obturator,
Lateral sacral,
Gluteal.

The *Umbilical* is the commencement of the fibrous cord, which passes forwards by the side of the fundus of the bladder, and then ascends converging to the urachus, and its fellow of the opposite side, as far as the umbilicus.

It is pervious for a short distance only, and gives off several small branches, called *superior vesical*, which are distributed to the fundus and side of the bladder, and extend as far as the prostate gland.

The *Ischiatic artery* descends to the lower border of the great sacro-ischiatic foramen, and escapes from the pelvis below the pyriformis muscle. It gives off a few small branches within the pelvis to the rectum, fundus of the bladder, and vesiculæ seminales.

The *Internal pudic artery* also passes through the great sacro-ischiatic foramen, below the pyriformis muscle, but nearer to the sacrum than the ischiatic. It crosses the spine of the ischium, and re-enters the pelvis through the lesser sacro-ischiatic foramen; it then crosses the tuberosity of the ischium at about an inch from its lower border, resting upon the obturator muscle, and bound down by the obturator fascia. It next ascends along the edge of the ramus of the ischium and pubis, between the two layers of the deep perineal fascia, giving off branches to the perineum and penis, and terminates in the dorsalis penis artery. Its branches within the pelvis are the middle hemorrhoidal.

In the female it is distributed in the same manner to the perineum and external organs of generation.

The *Ilio-lumbar artery* ascends beneath the psoas muscle to the posterior part of the crest of the ilium, along which it takes its course, supplying the adjoining muscles. It inoscules with the lumbar arteries and with the circumflexa ilii.

The *Obturator artery* passes forwards a little below the brim of the pelvis, to the upper border of the obturator foramen. It enters the thigh through an opening in the obturator

ligament, and is distributed to the muscles of the upper and inner part of the thigh, and to the hip joint.

The *Lateral sacral* is a small artery which runs by the side of the anterior sacral foramina, and sends branches into them for the supply of the sacral nerves. It anastomoses with the sacra-media.

The *Gluteal artery* passes directly outwards through the upper part of the great sacro-ischiatic foramen, above the pyriformis muscle, and is distributed to the gluteal muscles.

SACRAL PLEXUS OF NERVES.—The *Sacral plexus* is formed by the anterior branches of the last lumbar and four upper sacral nerves, and receives filaments from the sympathetic ganglia. The last lumbar nerve is called *lumbo-sacral*; it gives origin to the *gluteal nerve*.

The *Branches* of the sacral plexus are, the *visceral*, which are distributed to the viscera of the pelvis, viz., the bladder, prostate gland, uterus, rectum, &c., and communicate very freely with the termination of the hypogastric plexus; and the *external*, which are three in number.

Internal pudic,
Lesser ischiatic,
Greater ischiatic.

The *Gluteal nerve* passes out of the pelvis with the gluteal artery, through the great sacro-ischiatic foramen, above the pyriformis muscle, and is distributed with the branches of that artery.

The *Internal pudic nerve* passes out of the pelvis through the great sacro-ischiatic foramen, below the pyriformis muscle, and follows the course and distribution of the internal pudic artery.

The *Lesser ischiatic nerve* passes out of the pelvis through the great sacro-ischiatic foramen, in company with the great ischiatic nerve, and is distributed to the muscles of the ischiatic region, and to the integument on the posterior aspect of the thigh.

The *Great ischiatic nerve* is formed by the union of all the nerves which form the sacral plexus. It is a thick nervous band of considerable breadth. It leaves the pelvis through the great sacro-ischiatic foramen, below the lower border of the pyriformis muscle, and is distributed to the lower extremity.

The last two sacral, or rather, the *Coccygeal nerves*, are dis-

tributed to the lower extremity of the rectum, and perineum, and communicate with branches of the hypogastric plexus.

The SYMPATHETIC NERVE within the pelvis is composed of four or five small ganglia on each side, which terminate on the coccyx in a single ganglion, called *ganglion impar*. The sacral ganglia give filaments to each of the sacral nerves and visceral filaments, which are distributed to the viscera of the pelvis, and communicate with the filaments of the hypogastric plexus.

External Organs of Generation in the Male.

PENIS.—The *Penis* is composed of three lengthened bodies, closely united to each other, the two *corpora cavernosa* and the *corpus spongiosum*.

The *Corpora cavernosa* (*fig. 69. 22.*) are firmly attached at their commencement to the ramus of the ischium and pubis, where they form the *crura penis*; they then pass forwards, and meeting in the middle line, become intimately united, and constitute the chief bulk of the body of the penis. They consist of cellular structure enclosed in a very dense fibrous investment, and are separated by an incomplete partition, which is named *septum pectiniforme*. They terminate anteriorly in a rounded extremity, which is received into a depression on the posterior part of the glans penis.

The *Corpus spongiosum* (*fig. 69. 19.*) is situated in the groove upon the under surface of the two *corpora cavernosa*. It commences posteriorly, by a considerable enlargement, which is called the *bulb*, 21., and terminates, anteriorly, in a rounded extremity, named the *glans penis*, 20. The *bulb* is attached to the anterior layer of the deep perineal fascia, by a process which is sent forwards to enclose the membranous portion of the urethra. The corpus spongiosum is connected to the *corpora cavernosa* by means of cellular tissue, and the glans is applied against their extremity and attached to it by the same medium. The urethra enters the bulb as soon as it escapes from the deep perineal fascia, and runs forwards through the corpus spongiosum to the meatus.

The corpus spongiosum is named from its spongy cellular structure, which resembles that of the interior of the corpus cavernosum. It is enclosed in a thin layer of fibrous membrane.

The *Glans penis* (*fig. 69. 20.*) is covered by a very thin

cuticle, and is surrounded by an elevated ridge, called *corona glandis*. A number of sebaceous glands, the *glandulæ odoriferæ*, or Tyson's glands, are situated around the *corona*. The glans is protected by a duplicature of integument, called the *prepuce*, which is retained in connexion with the under surface of the glans, by a thin fold called the *frænum preputii*. There is a deep fossa around the *corona glandis*, between it and the attachment of the *prepuce*, in which syphilitic sores occasionally occur; when this is the case, they are extremely troublesome, and often burrow beneath the *corona* to a considerable depth.

The integument of the penis is remarkable for its looseness, and for the absence of adipose substance in its cellular tissue.

The penis is supported by a ligament, *Ligamentum suspensorium* (*fig. 56. 23.*) which descends from the symphysis pubis, to be inserted by two portions into the corpora cavernosa.

VESSELS AND NERVES.—The *Arteries* of the penis are derived from the internal pudic; they are the arteries of the bulb, of the corpora cavernosa, and of the dorsum of the penis. The *Veins* return the blood by the sides of the arteries to a plexus situated around the neck of the bladder. The *dorsal vein* is of very large size, and runs from before backwards in the groove on the dorsum of the penis. It passes between the two portions of the suspensory ligament, and beneath the pubic symphysis, to open into the vesical plexus.

The *Lymphatics* pass outwards to the inguinal glands.

The *Nerves* are branches of the internal pudic nerve and hypogastric plexus, and accompany each branch of the arteries.

SCROTUM.—The *Scrotum* (purse, leather bag) is the tegumentary fold which contains the testicles. It consists of two layers, the *integument* and *dartos*.

The *Integument* is extremely thin, and in very large quantity. It is covered with hairs issuing obliquely from the skin, and having prominent roots. Along the middle line it is marked by a raphé.

The *Dartos* is a contractile fibrous layer, situated immediately beneath the integument, and forming a distinct covering. It also divides the cavity of the scrotum into two equal chambers by a septum (*septum scroti*) of the same structure.

The *Structure of the dartos* is intermediate between muscle

and elastic fibrous tissue, and is called by some authors "*dartoid tissue.*"

TESTICLE.—The *Testicles* are lodged within the two cavities formed by the dartos, and are surrounded by an extremely loose and abundant cellular tissue, which contains no adipose substance.

The *Coverings* of the *spermatic cord* and *testicle* are the
 Spermatic fascia, Fascia propria.
 Cremasteric,

The *Spermatic fascia* is the intercolumnar fascia derived from the external abdominal ring, which is carried downwards with the testicle in its descent in the fœtus.

The *Cremasteric covering* (*erythroid*) is formed by the expansion of the fibres of the cremaster muscle, which are also carried down in the descent of the testicle.

The *Fascia propria* consists of the transversalis fascia, carried down by the testicle in its descent.

The *Proper coverings of the testicle* are, the *tunica vaginalis*, and *tunica albuginea*.

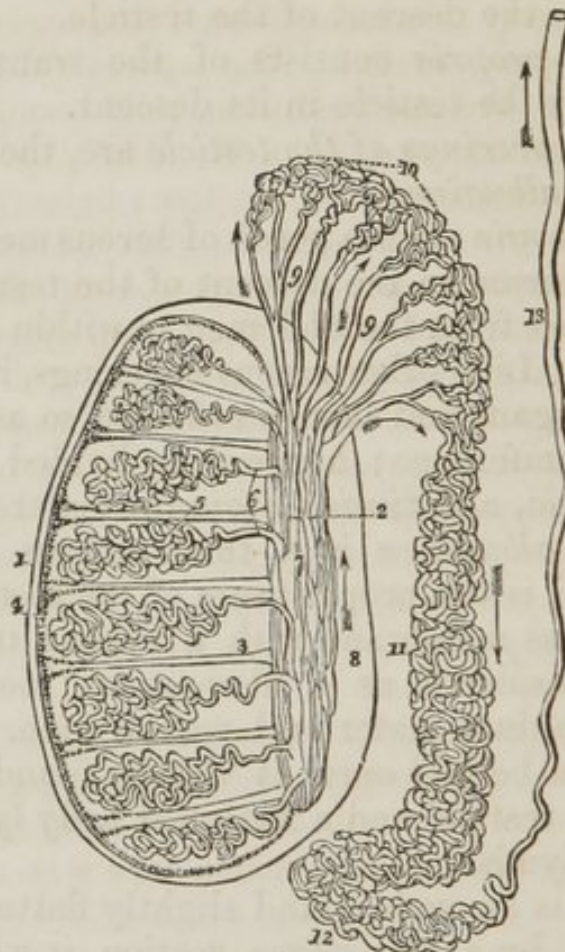
The *Tunica vaginalis* is a porch of serous membrane derived from the peritoneum in the descent of the testicle, and afterwards obliterated from the abdomen to within a short distance of the testicle. Like other serous coverings, it is a shut sack investing the organ, and thence reflected so as to form a bag around its circumference; hence it is divided into the *tunica vaginalis propria*, and *tunica vaginalis reflexa*.

The *Tunica albuginea* is a thick fibrous membrane of a white color, and is the proper tunic of the testicle. From the union of a serous membrane with a fibrous tunic, the tunica vaginalis is considered as a fibro-serous membrane, and is ranged with the dura mater and pericardium. If the tunica vaginalis reflexa be laid open, it will be found to contain, in its interior, the testicle and a flattened body lying to its outer side, the epididymis.

The *Testicle* is an ovoid gland slightly flattened at its sides. If it be divided by a transverse section, it will be observed that the tunica albuginea, (*fig. 72. 1.*), after investing it completely, is reflected inwards along its posterior border, so as to form a projecting ridge in its interior, called *mediastinam testis*, 2., (*corpus Highmorianum.*) From the mediastinum, a number of *fibrous cords*, 3., pass off and radiate in all directions towards the inner surface of the tunic to which they are

firmly attached. For a knowledge of the use of this arrangement, as of many other very important structures in the body, anatomists are indebted to Sir Astley Cooper, who has shown that this simple disposition is beautifully adapted to the purpose of preventing the compression of the substance of the testicle: and, truly, we know of no structure in the animal economy that evinces more striking evidence of design than does this. In the section of the mediastinum testis, two groups of minute foramina will be observed, one near the external surface of the mediastinum, consisting of divided arteries and veins; the other near to its inner edge,—of the divided tubes of the rete testis.

Fig. 72. The anatomy of the testicle.



1. The tunica albuginea. 2. The mediastinum testis, or corpus Highmorianum. 3. A fibrous cord passing between two of the lobules from the mediastinum to the inner surface of the tunica albuginea. Similiar cords are observed between the other lobules. 4. The tunica vasculosa or pia mater testis. 5. Two of the lobules of which the substance of the testicle is composed. They are seen to consist of the convolutions of minute tubes, tubuli seminiferi. 6. The small straight tubes by which the tubuli seminiferi ter-

minate, vasa recta. 7. The rete testis, an aggregation of tubuli situated in the anterior half of the mediastinum. The posterior half (8.) is occupied by the arteries and veins. 9. 9. The vasa efferentia. 10. The conical convolutions of tubuli called conii vasculosi. This portion of the organ being of large size, and situated externally to the testicle, is the globus major of the epididymis. 11. The body of the epididymis. 12. The globus minor of the epididymis. 13. The vas deferens, ascending to the external abdominal ring. The arrows mark the course of the secretion along the tubes.

Upon the inner surface of the tunica albuginea, is the *tunica vasculosa testis*, (*fig. 72. 4.*) the nutrient membrane of the testicle. It sends vascular processes inwards between the lobules. Sir Astley Cooper has compared the tunica albuginea to the dura mater, and the tunica vasculosa to the pia mater of the brain.

The *Substance of the testis* is composed of minute tubes (*tubuli seminiferi*) very much convoluted and arranged in lobules, (*fig. 72. 5.*) (*lobuli testis.*) The apices of the lobules are directed towards the mediastinum, and terminate in small, straight ducts called *vasa recta*, 6. The vasa recta form a net-work of minute tubes, running from below upwards within the substance of the mediastinum, which is called the *rete testis*, 7. The ducts forming the rete, quit the testis at its upper and posterior part under the name of *vasa efferentia*, 9. 9., which are eight or ten in number, and the vasa efferentia become convoluted into cones, called *conii vasculosi*, 10. The convolutions of the vasa efferentia, external to the testicle, constitute the *epididymis*. The upper end of the epididymis is of large size, from the great assemblage of convoluted tubes in the conii vasculosi; hence it is named *globus major*, 10. The middle portion or body of the epididymis, 11., is formed by the convolutions of a single tube, and the lower portion, or *globus minor*, 12., consists of the convolutions of the vas deferens, previously to commencing its ascending course. The convolutions of these tubes in the epididymis are secured by a fibrous membrane, which is covered by the tunica vaginalis.

The *Vas deferens* (*fig. 72. 13.*) commences, therefore, in the globus minor epididymis at the lower part of the testicle, and ascends along the posterior part of the spermatic cord to the external abdominal ring. It then passes along the spermatic canal, and through the internal abdominal ring, to the side of the fundus of the bladder. It next descends along the posterior wall of the bladder, crossing the

direction of the ureter, and terminates at the base of the prostate gland by uniting with the duct of the vesicula seminalis to form the ejaculatory duct.

The *Spermatic cord* consists of the vessels and nerves passing to and from the testicle, enclosed in several tunics or fasciæ. The left cord is a little longer than the right: hence the left testicle is the lower of the two. The cord is placed behind the testicle, so that the convexity of the testis looks forwards and a little outwards.

VESSELS AND NERVES.—The arteries of the cord are the *spermatic*, from the aorta; *cremasteric*, from the epigastric; and *deferential*, from the vesical artery. The *Veins* are numerous, and have valves at very short distances. They are sometimes called *vasa pampiniformia*, from the peculiar tendril-like arrangement of the smaller vessels. The *Lymphatics* are beautifully shown in the injections made by Sir A. Cooper: they terminate in the lumbar glands.

The *Nerves* are derived from the *spermatic plexus*, and from the *genito-crural* and *ilio-scrotal* branches of the lumbar plexus.

The *Coverings* of the cord are the *fascia spermatica*, *cremaster*, and *fascia propria*.

Surgery of the Testicle and Spermatic Cord.

When the tunica vaginalis remains unclosed, the intestine being forced into it, lies in contact with the testicle: this is *Congenital hernia* (*fig. 13. page 35.*)

Hydrocele, in infants and young children, often communicates with the cavity of the abdomen from the same deficiency of closure.

When the tunica vaginalis is closed at the upper point only and the hernial sac descends behind it, we have a case of *Encysted hernia* (*fig. 14. page 35.*) If the hernial sac were to descend *into* the tunica vaginalis, instead of behind it, the serous membrane rising all around it, that also would be a form of encysted hernia.

When the tunica vaginalis is closed from point to point only, fluid may collect in the unobliterated portions, and form one or more sacs. This is the *Hydrocele of the cord*.

If the fluid collect in the tunica vaginalis itself, the case is *common Hydrocele*. If blood in place of serous fluid occupy the tunica vaginalis, the case is one of *Hematocele*.

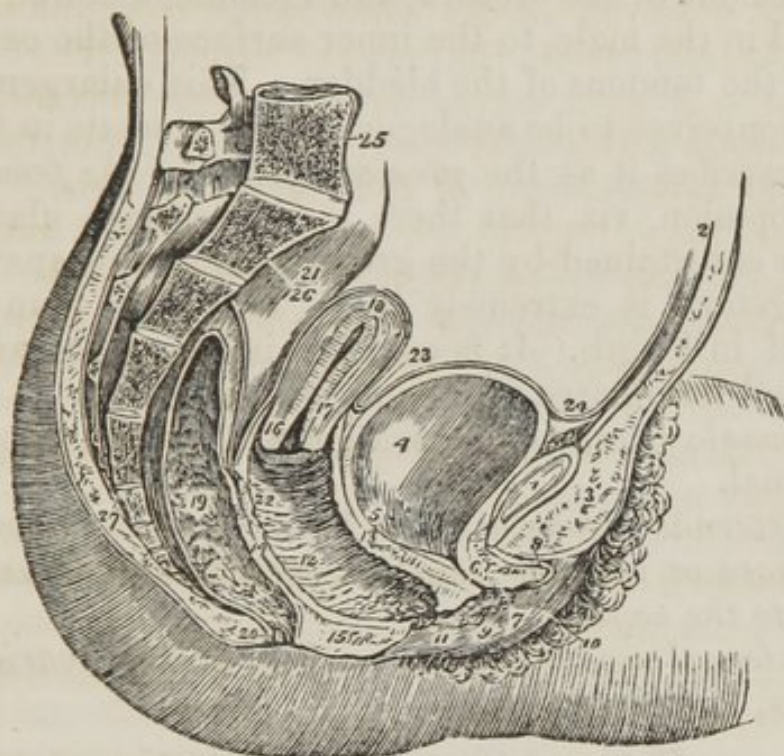
If the veins of the cord be enlarged and tortuous, or varicose, the case is one of *Varicocele*, or spermatocele.

Swelled testicle is often called *Hernia, humoralis*; and inguinal hernia, descending into the scrotum, forms *Scrotal hernia*.

FEMALE PELVIS AND ORGANS OF GENERATION.

The contents of the female pelvis are the *bladder, vagina, uterus*, with its appendages, and *rectum*.

Fig. 73. A side view of the viscera of the female pelvis.



1. The symphysis pubis; to the upper part of which the tendon of the rectus muscle is attached. 2. The abdominal parietes. 3. The collection of fat, forming the projection of the mons Veneris. 4. The urinary bladder. 5. The entrance of the left ureter. 6. The canal of the urethra, converted into a mere fissure by the contraction of its walls. 7. The meatus urinarius. 8. The clitoris, with its præputium, divided through the middle. 9. The left nympha. 10. The left labium majus. 11. The meatus of the vagina, narrowed by the contraction of its sphincter. 12. The canal of the vagina, upon which the transverse rugæ are apparent. 13. The thick wall of separation between the base of the bladder and the vagina. 14. The wall of separation between the vagina and rectum. 15. The perineum. 16. The os uteri. 17. Its cervix. 18. The fundus uteri. The cavities uteri is seen along the centre of the organ. 19. The rectum, showing the disposition of its mucous membrane. 20. The anus. 21. The upper part of the rectum, invested by the peritoneum. 22. The recto-uterine fold of the peritoneum. 23. The uteros vesical fold. 24. The reflection of the peritoneum, from the apex of the bladder, upon the urachus to the internal surface of the abdominal parietes. 25. The last lumbar vertebra. 26. The sacrum. 27. The coccyx.

The **BLADDER** is in relation with the pubis in front, and with the vagina beneath. Its form corresponds with that of the pelvis, being broad from side to side, and often bulging more on one side than the other. This is particularly evident after frequent parturition.

The *Coats* of the bladder are the same as those of the male.

The *Muscular coat* has its two layers, the *external* and the *internal*; the longitudinal fibres of the former are attached to a ring of thickened submucous tissue, which surrounds the commencement of the urethra, and is connected, like the prostate gland in the male, to the inner surface of the os pubis by means of the tendons of the bladder. This enlargement, Mr. Guthrie conceives to be analogous to the prostate in the male; and he describes it as the *prostate gland of the female*. An opposite opinion, viz. that there is no prostate gland in the female, is entertained by the greater number of anatomists.

The *Urethra* is extremely short, not more than an inch and a half in length. It is enclosed in the upper wall of the vagina, and terminates at its anterior extremity.

The *Female organs of generation* are divided into external and internal.

The *External organs* are the *Mons Veneris*, *labia maiora*, *labia minora* or *nymphæ*, *clitoris*, *meatus urinarius*, and the *entrance to the vagina*.

The *Internal organs* are the *vagina*, *uterus*, *ovaries*, *Fallopian tubes*, and *ligaments*.

External Organs of Generation.

The *Mons Veneris* is an eminence of integument, situated upon the pubis. Its cellular tissue is loaded with adipose substance, and the surface covered with hairs.

The *Labia majora* are two large longitudinal folds of integument, consisting of fat and loose cellular tissue. They enclose an elliptic opening called the *vulva*, and are united posteriorly by a thin commissure called the *fourchette*, which is always ruptured in parturition. Immediately within this commissure is a small cavity, the *fossa navicularis*.

The breadth of the perineum is measured from the fourchette to the margin of the anus, and is usually not more than an inch across.

The external surface of the labia is covered with hairs;

the inner surface is smooth, and lined by mucous membrane, which contains a number of sebaceous follicles, and is covered by a thin epithelium. The use of the labia majora is to favour the extension of the vulva during parturition; for, in the passage of the head of the child, the labia are completely unfolded and effaced.

The *Labia minora*, or *nymphæ*, are two smaller folds situated within the labia majora. Superiorly they are divided into two processes, which surround the glans clitoridis and form its prepuce, *preputium clitoridis*. Inferiorly, they diminish gradually in size, and are lost on the sides of the opening of the vagina.

The nymphæ consist of mucous membrane, covered in by a thin epithelium. They are provided with a number of sebaceous follicles, and contain, in their interior, a thin layer of erectile tissue.

The *Clitoris* is a small elongated organ, situated in front of the pubis, and supported by a suspensory ligament. It is formed by the union of two small bodies, which are analogous to the corpus cavernosa of the penis, and, like them, arise from the ramus of the pubis and ischium on each side, by two *crura*. The extremity of the clitoris is called its *glans*. It is composed of erectile tissue, enclosed in a dense layer of fibrous membrane, and is susceptible of erection. Like the penis, it is provided with two small muscles, the *erectores clitoridis*, which arise from the ramus of the ischium, and are inserted into the crura.

At about an inch beneath the clitoris is *the entrance of the vagina*, an elliptic opening, marked by a projecting margin. The entrance to the vagina is closed in the virgin by a membrane called the *Hymen*, which is stretched across the opening. Sometimes the membrane forms a complete septum, and gives rise to great inconvenience by preventing the escape of the menstrual effusion. It is then called an *imperforate hymen*. The *hymen* is not by any means a necessary accompaniment to virginity, for it does not constantly exist. When present it assumes a variety of appearances: it may be a membranous fringe, with a round opening in the centre, or it is a semilunar fold, leaving an opening in front; or a transverse septum, having an opening both in front and behind.

The rupture of the hymen or its rudimentary existence,

gives rise to the appearance of granulations around the opening of the vagina: these are called *carunculæ myrtiformes*.

The triangular smooth surface between the clitoris and the entrance of the vagina, which is bounded on each side by the upper portions of the nymphæ, is the *Vestibule*.

At the upper angle of the vagina is an elevation formed by the projection of the upper wall of the canal: and immediately in front of this tubercle, and surrounded by it, is the opening of the urethra, the *Meatus urinarius*.

Internal Organs of Generation.

VAGINA.—The *Vagina* is a membranous canal, leading from the vulva to the uterus, and corresponding in direction with the axis of the outlet of the pelvis. At the commencement it is constricted, but near the uterus becomes considerably dilated. Its length is very variable; but it is always longer upon the posterior than upon the anterior wall. The former is usually about five or six inches in length, and the latter four or five. It is inserted into the cervix of the uterus, which projects into the upper extremity of the canal.

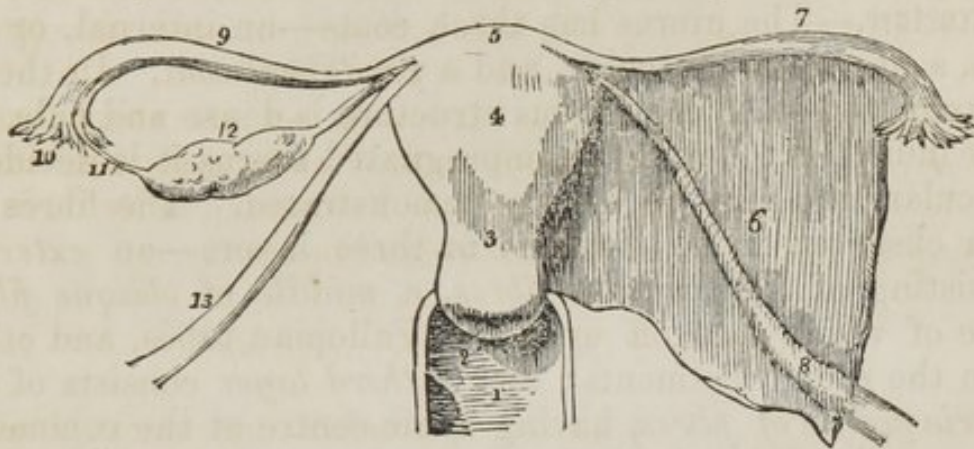
In *Structure* the vagina is composed of a *mucous lining*, a layer of *erectile tissue*, and an external tunic of a *fibrous* structure, resembling the dartos of the scrotum. The upper half of the posterior wall of the vagina is covered, on its pelvic surface, by the peritoneum; and, in front, the peritoneum is reflected from its upper part to the posterior surface of the bladder.

The *Mucous membrane* presents a number of *transverse papillæ* or *rugæ* upon its upper and lower surfaces, which extend outwards on each side from a middle *raphé*. The transverse papillæ and raphé are more apparent upon the upper than upon the lower surface, and the two raphé are called the *columns of the vagina*. The mucous membrane is covered by a thick epithelium, which is continued from the labia, and terminates by a fringed border at the inner margin of the os uteri.

The *External or dartoid layer* of the vagina, serves to connect it to the surrounding viscera. Thus, it is very closely adherent to the under surface of the bladder, and drags that organ down with it in prolapsus uteri. To the rectum it is

more loosely connected, which is therefore less frequently affected in prolapsus.

Fig. 74. The female internal organs of generation.



1. The upper part of the vagina. 2. The os uteri, projecting into the vagina; the posterior lip is seen to be longer and larger than the anterior. 3. The cervix uteri. 4. The body of the uterus. 5. Its fundus. 6. The broad ligament of the left side, having enclosed between its layers (7.) the Fallopian tube, and (8.) the round ligament. On the right side the broad ligament is removed, so as to bring more clearly into view the structures which it contains. 9. The Fallopian tube. 10. Its fimbriated extremity. 11. One of its fimbriæ attached to the ovary. 12. The ovary attached by its ligament to the upper angle of the uterus. 13. The round ligament.

UTERUS.—The *Uterus* (fig. 74. 4.) is a flattened organ of a pyriform shape, having the base directed upwards. Its direction corresponds with the axis of the inlet of the pelvis; it therefore forms a considerable angle with the direction of the vagina. It is about three inches in length, two in breadth across its broadest part, and one in thickness. It is divided into *fundus*, *body*, *cervix*, and *os uteri*.

The *Fundus* (fig. 74. 5.) and *Body*, 4., are enclosed in a duplicature of peritoneum, which is connected with the two sides of the pelvis, and forms a transverse septum between the bladder and rectum. The folds on either side of the uterus are the *broad ligaments*, 6. They contain several important parts.

The *Cervix*, 3., gives attachment to the vagina, and the *os uteri*, 2., projects into the upper part of the vagina, and presents a transverse opening. Within and around the os uteri are occasionally found some small vesicles, which are called the *ovula of Naboth*. These are dilated mucous follicles, having the openings closed by adhesion. The posterior lip of the os uteri is thicker and more projecting than the anterior.

The *Cavity of the uterus* is triangular in its form, the upper angles corresponding with the commencement of the Fallopian tubes. In the cervix of the organ is an arborescent arrangement of folds, which is called *arbor vitæ uterina*.

Structure.—The uterus has three coats—an internal, or *mucous*, a *fibrous* or muscular, and a *peritoneal coat*. In the unimpregnated state the fibrous structure is dense and pale, and very indistinct; but in the impregnated uterus it is decidedly muscular, and may be clearly demonstrated. The fibres are then observed to be disposed in three layers—an *external*, consisting of *longitudinal fibres*, a *middle* of *oblique fibres*, some of which pass off upon the Fallopian tubes, and others upon the round ligaments; and a *third layer* consists of *concentric circles of fibres*, having their centre at the commencement of the Fallopian tubes. In the cervix uteri the fibres are circular.

VESSELS AND NERVES.—The *Arteries* of the uterus are the uterine from the internal iliac, and the spermatic from the aorta. The *Veins* are very large and remarkable; in the impregnated uterus they are called sinuses, and consist of canals channelled through the substance of the organ, and are merely lined by the internal membrane of the veins.

The *Nerves* are derived from the hypogastric and spermatic plexuses, and from the sacral plexus.

The *Appendages of the uterus* are enclosed by the lateral duplicatures of peritoneum, called the broad ligaments. They are the *Fallopian tubes* and *ovaries*.

The **FALLOPIAN TUBES** (*fig. 74. 7.*) are two tubular prolongations which pass off on each side from the upper angles of the uterus. At their commencement (*ostium uterinum*) they are small, but they gradually increase as they pass outwards, and terminate by expanded *fimbriated extremities*, 10. (*ostium abdominale*.) One of these fringes, 11., longer than the rest, is attached to the ovary, and serves to guide the tube in its seizure of that organ.

The tube is lined by mucous membrane, which is continuous with that of the uterus, and at the fimbriated extremity is in connexion with the peritoneum. This is the only instance in the human being of a natural opening existing in a serous membrane.

The **OVARIES** (*fig. 74. 12.*) are two oblong flattened bodies of a yellowish colour, situated in the posterior folds of the

broad ligaments. They are connected to the upper angles of the uterus at each side by a rounded cord, the *ligament of the ovary*.

The *Structure* of the ovary is a spongy vascular tissue, containing *serous vesicles* (*Graafian*), and enclosed in a dense, fibrous tissue, covered by peritoneum. These vessels are simple cysts, containing a limpid fluid, of various size, and from ten to fifteen in number in each ovary. They are the ova in which the future embryo is developed. Bauer states, that the vesicles which are nearest the surface have a minute floating body in their interior, which is the rudiment of the germ.

After conception, a yellow spot is often found in one or both ovaries, and has been named the *corpus luteum*. It is formed of yellow, condensed substance, deposited in the place of the ovum, which has escaped. This was formerly considered a certain evidence of conception having taken place; but nothing can be more fallacious. It does not always exist in women who have borne children, and it has been found in virgins, and even in a child five years of age.

VESSELS AND NERVES.—The *Arteries* of the ovaries are the spermatic. Its *Nerves* are derived from the spermatic plexus.

The uterus is held in its place by two *round ligaments*, which are connected with the angles of the uterus, and pass forwards beneath the peritoneum to the internal abdominal ring: they then follow the course of the spermatic canal on each side to the labia majora. While in the spermatic canal they have the same relations as the spermatic cord, which they represent in the female.

They are accompanied by a small artery, and several filaments of the spermatic plexus of nerves.

CHAPTER VII.

REGION OF THE BACK.

It is customary in most dissecting rooms to turn the body upon its face after the lapse of a few days, that the student may have an opportunity of studying the muscles of the back and the posterior parts of the limbs. The student must, therefore, endeavour to accommodate his dissection to these rules.

The *region of the back* is, from its extent, common to the neck, the upper extremities, and the abdomen. The muscles of which it is composed are numerous, and may be arranged into six layers.

First Layer.

Trapezius,
Latissimus dorsi,

Transversalis colli,
Trachelo-mastoideus,
Complexus.

Second Layer.

Levator anguli scapulæ,
Rhomboides minor,
Rhomboides major.

Fifth Layer.

(Dorsal Group.)
Semi spinalis dorsi,
Semi spinalis colli,
(Cervical Group.)

Third Layer.

Serratus posticus superior,
Serratus posticus inferior,
Splenius capitis,
Splenius colli.

Rectus posticus major,
Rectus posticus minor,
Rectus lateralis,
Obliquus inferior,
Obliquus superior.

Fourth Layer.

(Dorsal Group.)

Sacro lumbalis,
Longissimus dorsi,
Spinalis dorsi.

Sixth Layer.

Multifidus spinæ,
Levatores costarum,
Supra-spinales,
Inter-spinales,
Inter-transversales.

(Cervical Group.)

Cervicalis ascendens,

Posterior Thoracic Region.—First Layer.

Trapezius,
Latissimus dorsi.

If the subject be turned upon its face, the posterior muscles of the shoulder and arm may be examined. Two of these form the superficial layer of muscles of the back, the trapezius and latissimus dorsi.

Dissection.—They are to be dissected by making an incision along the middle line of the back, from the tubercle on the occipital bone to the sacrum. From the upper point of this incision carry a second along the side of the neck, to the middle of the clavicle. Inferiorly, an incision must be made from the extremity of the sacrum, along the crest of the ilium, to about its middle. For the convenience of dissection, a fourth may be carried from the middle of the spine to the acromion process. The integument and superficial fascia, together, are to be dissected off the muscles, in the course of their fibres, over the whole of this region.

The *Trapezius* muscle (trapezium, a quadrangle with unequal sides) *arises* from the superior curved line on the occipital bone, from the ligamentum nuchæ, spinous processes of the last two cervical and all the dorsal vertebræ. The fibres converge from these various points, and are *inserted* into the scapular third of the clavicle, the acromion process, and the whole length of the upper border of the spine of the scapula. The inferior fibres become tendinous near to the scapula, and glide over the triangular surface of the posterior extremity of its spine, being separated from it by a bursa mucosa. When the trapezius is dissected on both sides, the two muscles resemble a trapezium or a diamond-shaped quadrangle on the posterior part of the shoulders: hence the muscle was formerly named cucullaris (cucullus, a monk's cowl.) The cervical and upper part of the dorsal portion of the muscle is tendinous at its origin, and forms with the muscle of the opposite side a kind of tendinous ellipse.

The *Latissimus dorsi* muscle covers the whole of the lower part of the back and loins. It *arises* from the spinous processes of the six inferior dorsal vertebræ, all the lumbar and sacral, from the posterior third of the crest of the ilium, and from the three lower ribs by muscular slips, which indigitate with the external oblique muscle of the abdomen. The fibres converge as the muscle passes upwards and crosses over the inferior angle of the scapula, to be *inserted* with the teres major into the posterior bicipital ridge of the humerus. A synovial bursa is interposed between the muscle and the lower

angle of the scapula : sometimes it has a muscular connexion with the scapula at this point.

The latissimus dorsi is occasionally thrown off the inferior angle of the scapula, a painful and puzzling accident, and not easy of reduction. The bursa too is liable to become inflamed, when a tumour of very large size may be found in this situation resulting from the distention of the synovial sac.

The trapezius muscle may now be removed, by cutting it away from its insertion, and turning it to the opposite side ; and the latissimus dorsi, by dividing it near to its tendon, and turning it down.

Posterior Thoracic Region.—Second Layer.

We thus bring into view a group of three muscles, forming the second layer of muscles of the back, which belong in their actions to the scapula :—

Levator anguli scapulæ,
Rhomboideus minor,
Rhomboideus major.

The *Levator anguli scapulæ* arises by distinct slips from the posterior tubercles of the transverse processes of the four upper cervical vertebræ, and is *inserted* into the upper angle and posterior border of the scapula, as far as the triangular smooth surface at the root of its spine.

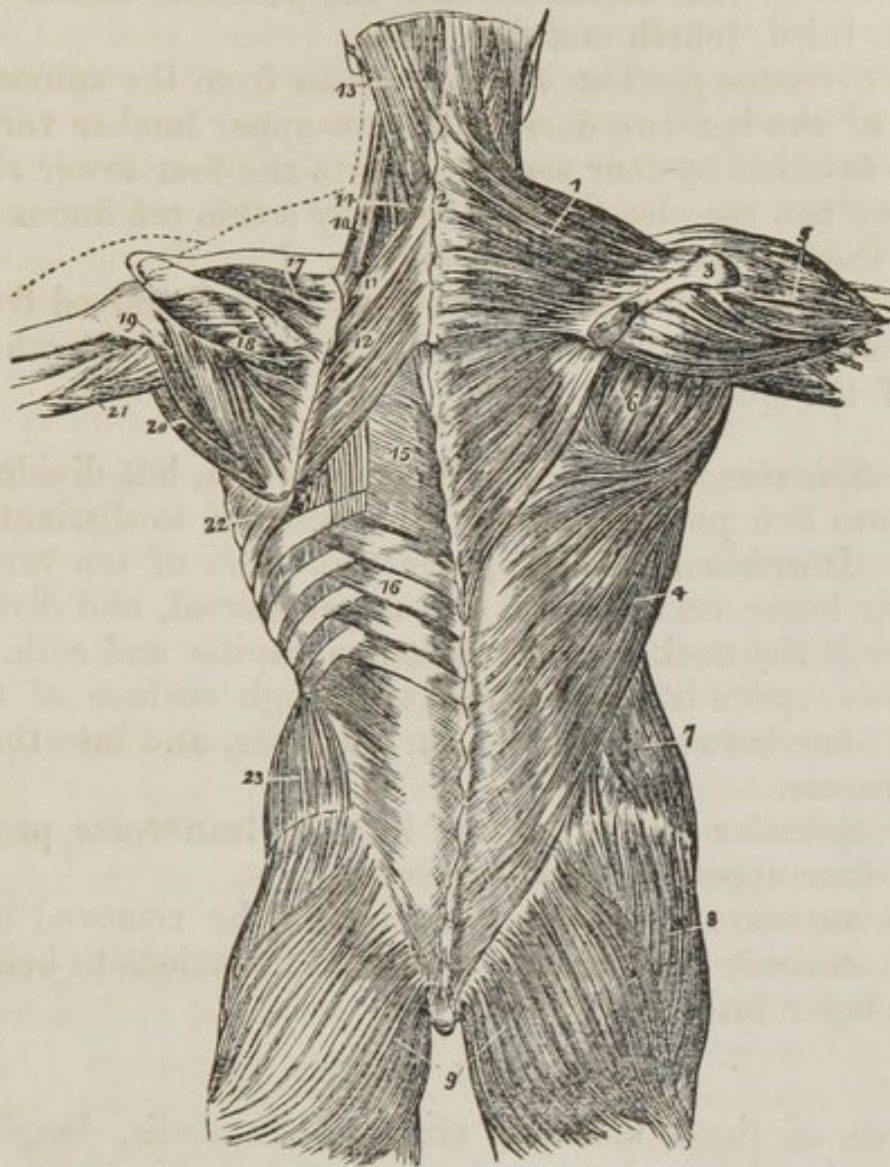
The *Rhomboideus minor* (rhombus, a parallelogram with four equal sides) is a narrow slip of muscle detached from the *Rhomboideus major* by a slight cellular interspace. It arises from the spinous processes of the last two cervical vertebræ and ligamentum nuchæ, and is *inserted* into the edge of the triangular surface on the posterior border of the scapula.

The *Rhomboideus major* arises from the spinous processes of the four upper dorsal vertebræ and their supra-spinous ligaments, and is *inserted* into the posterior border of the scapula as far as its inferior angle.

THIRD LAYER.

The *Third layer* consists of muscles which arise from the spinous processes of the vertebral column, and pass outwards. It is brought into view by dividing the levator anguli scapulæ near its insertion, and reflecting the two rhomboid muscles upwards from their insertion into the scapula, and removing them altogether.

Fig. 75. The first and second part of the third layer of muscles of the back; the first layer being shown upon the right, and the second on the left side.



1. The trapezius muscle. 2. The tendinous portion which, with a corresponding portion in the opposite muscle, forms the tendinous ellipse on the back of the neck. 3. The acromion process and spine of the scapula. 4. The latissimus dorsi muscle. 5. The deltoid. 6. The muscles of the dorsum of the scapula, infra-spinatus, teres minor, and teres major. 7. The external oblique muscle. 8. The gluteus medius. 9. The glutei maximi. 10. The levator anguli scapulæ. 11. The rhomboideus minor. 12. The rhomboideus major. 13. The splenius capitis; the muscle immediately above, and overlaid by the splenius, is the complexus. 14. The splenius colli, only partially seen; the common origin of the splenius is seen attached to the spinous processes below the lower border of the rhomboideus major. 15. The vertebral aponeurosis. 16. The serratus posticus inferior. 17. The supra-spinatus muscle. 18. The infra-spinatus. 19. The teres minor muscle. 20. The teres major. 21. The long head of the triceps, passing between the teres minor and major to the upper arm. 22. The serratus magnus, proceeding forwards from its origin at the base of the scapula. 23. The internal oblique muscle.

The *Serratus posticus superior* arises from the spinous processes of the last two cervical and upper dorsal vertebræ, and is inserted by four serrations into the posterior surface of the second, third, fourth and fifth ribs.

The *Serratus posticus inferior* arises from the spinous processes of the last two dorsal and two upper lumbar vertebræ, and is inserted by four serrations into the four lower ribs.

These two muscles are connected by a thin tendinous fascia, called the intervertebral aponeurosis.

The serratus posticus superior must be removed from its origin and turned outwards, to bring into view the whole extent of the splenius muscle.

The *Splenius muscle* is single at its origin, but divides soon after into two portions, which are destined to distinct insertions. It arises from the spinous processes of ten vertebræ, the four lower cervical and six upper dorsal, and divides as it ascends the neck into the splenius capitis and colli. The *Splenius capitis* is inserted into the rough surface of the occipital bone between the two curved lines, and into the mastoid process.

The *Splenius colli* is inserted into the transverse processes of the four upper cervical vertebræ.

The two serrati and two splenii must be removed by cutting them away from their origins and insertions to bring the fourth layer into view.

FOURTH LAYER.

Three of these muscles, viz. sacro-lumbalis, longissimus dorsi, and spinalis dorsi, are associated under the name of erector spinæ. They occupy the lumbar and dorsal portion of the back. The remaining four are situated in the cervical region.

The *Sacro lumbalis* and *Longissimus dorsi* arise by a common origin from the posterior third of the crest of the ilium, from the posterior surface of the sacrum, and from the lumbar vertebræ: opposite the last rib a line of separation begins to be marked between the two muscles. The *Sacro-lumbalis* is inserted by separate tendons into the angles of the six lower ribs. On turning the muscle a little outwards, a number of tendinous slips will be seen taking their origin from the ribs, and terminating in a muscular fasciculus, by which

the sacro-lumbalis is prolonged to the upper part of the thorax. This is the *musculus accessorius ad sacro-lumbalem*: it arises from the angles of the lower ribs, and is inserted by separate tendons into the angles of the six upper ribs.

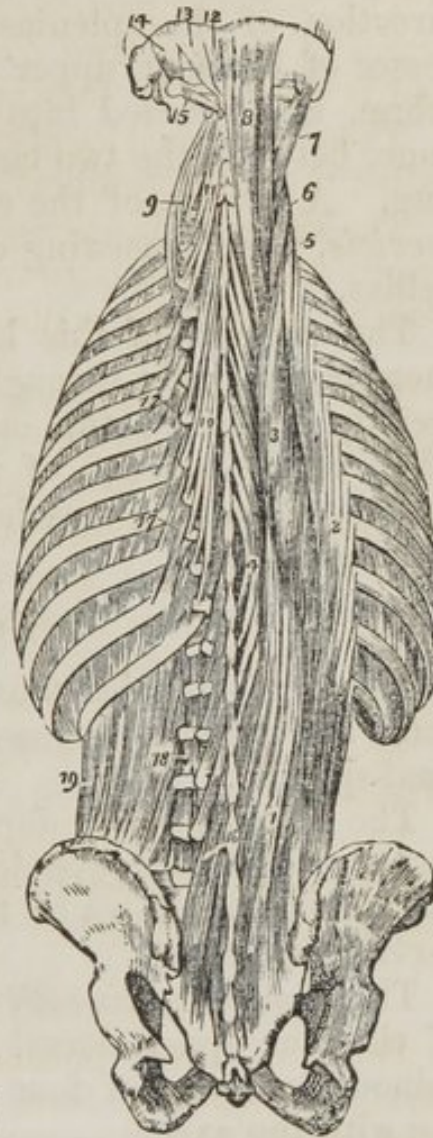
The *Longissimus dorsi* is inserted into all the ribs, between their tubercles and angles.

The *Spinalis dorsi* arises from the spinous processes of the two upper lumbar and two lower dorsal vertebræ, and is inserted into the spinous processes of all the upper dorsal vertebræ, the two muscles form an ellipse, which appears to enclose the spinous processes of all the dorsal vertebræ.

CERVICAL GROUP.—The *Cervicalis ascendens* appears to be the continuation of the sacro-lumbalis upwards into the neck. It arises from the angles of the four upper ribs, and is inserted into the transverse processes of the four lower cervical vertebræ.

The *Transversalis colli* would appear to be the continuation upwards into the neck of the longissimus dorsi, it arises from the transverse processes of the four

Fig. 76. The fourth and fifth, and part of the sixth layer of the muscles of the back.



1. The common origin of the erector spinæ muscle. 2. The sacro-lumbalis. 3. The longissimus dorsi. 4. The spinalis dorsi. 5. The cervicalis ascendens. 6. The transversalis colli. 7. The trachelo-mastoideus. 8. The complexus. 9. The transversalis colli, showing its origin. 10. The semi-spinalis dorsi. 11. The semi-spinalis colli. 12. The rectus posticus minor. 13. The rectus posticus major. 14. The obliquus superior. 15. The obliquus inferior. 16. The multifidus spinæ. 17. The levatores costarum. 18. Intertransversales. 19. The quadratus lumborum.

upper dorsal vertebræ, and is inserted into the transverse processes of the four middle cervical vertebræ.

The *Trachelo-mastoid* is likewise a continuation upwards from the longissimus dorsi. It is a very slender and delicate

muscle, *arising* from the transverse processes of the four upper dorsal, and four lower cervical vertebræ, and inserted into the mastoid process.

The *Complexus* is a large muscle, and with the splenius forms the great bulk of the back of the neck. It crosses the direction of the splenius, *arising* from the transverse processes of the four upper dorsal, and four lower cervical vertebræ, and *inserted* into the rough surface on the occipital bone, between the two curved lines near to the spinous process. A portion of the complexus muscle is named *Biventer cervicis*, from consisting of a central tendon, with two fleshy bellies.

The muscles of this layer are best removed by dividing them transversely through the middle, and turning one extremity upwards, the other downwards. In this way the whole of the muscles of the fourth layer may be got rid of, and the remaining muscles of the spine brought into a state to be examined.

FIFTH LAYER.

The Semi-spinales muscles are connected with the transverse and spinous processes of the vertebræ, hence their name semi-spinalis.

The *Semi-spinalis dorsi* arises from the transverse processes of the six lower dorsal vertebræ, and is *inserted* into the spinous processes of the four upper dorsal, and two lower cervical vertebræ.

The *Semi-spinalis colli* arises from the transverse processes of the four upper dorsal vertebræ, and is *inserted* into the spinous processes of four upper cervical vertebræ, commencing with the axis.

OCCIPITAL GROUP.—This group of small muscles is intended for the varied movements of the cranium on the atlas, and the atlas on the axis. They are extremely pretty muscles in appearance.

The *Rectus posticus major* arises from the spinous process of the axis, and is *inserted* into the inferior curved line, on the occipital bone.

The *Rectus posticus minor* arises from the spinous tubercle of the atlas, and is *inserted* into the rough surface of the occipital bone, beneath the inferior curved line.

The *Rectus lateralis* is interposed between the transverse

process of the atlas and the occipital bone; it *arises* from the transverse process of the atlas, and is *inserted* into the rough surface of the occipital bone, external to the condyle.

The *Obliquus inferior* arises from the spinous process of the axis, and is *inserted* into the extremity of the transverse process of the atlas.

The *Obliquus superior* arises from the extremity of the transverse process of the atlas, and is *inserted* into the rough surface of the occipital bone, between the curved lines.

SIXTH LAYER.

The semi-spinales muscles must both be removed to obtain a good view of the multifidus spinæ which lies beneath them, and fills up the concavity between the spinous and transverse processes, the whole length of the vertebral column.

The *Multifidus spinæ* consists of a great number of fleshy fasciculi, extending between the transverse and spinous processes of the vertebræ, from the sacrum to the axis. Each fasciculus *arises* from a transverse process, and is *inserted* into the spinous process of the first or second vertebra above.

The *Levatores costarum* arise from the transverse processes of the dorsal vertebræ, and are *inserted* into the rough surface between the tubercle and angle of the rib below them.

The *Supra-spinales* are little fleshy bands lying on the spinous processes of the vertebræ in the cervical region.

The *Inter-spinales* are a succession of little pairs of muscles, lying between the bifid tubercles of the spinous processes of the cervical vertebræ.

The *Inter-transversales* are also arranged in pairs, and pass between the bifid tubercles of the transverse processes of the cervical vertebræ. They are sometimes found in the lumbar region.

With regard to the origin and insertion of the muscles of the back, the student should be informed that no regularity attends their attachments. At the best a knowledge of their exact connexions, even were it possible to retain, would be but a barren information, if not absolutely injurious, as tending to exclude more valuable learning. We have, therefore, endeavoured to arrange a plan, by which they may be more easily recollected, by placing them in a tabular form, that the student may see, at a single glance, the origin and insertion

ORIGIN.

LAYERS.	SPINOUS PROCESSES.	TRANSVERSE PROCESSES.	RIBS.	ADDITIONAL.
<i>1st Layer.</i>				
Trapezius	{ last cervical, 12 dorsal	}	{ occipital bone, and lig. nuchæ
Latissimus dorsi ..	{ 6 lower dorsal, 5 lumbar	}	3 lower	sacrum and ilium ..
<i>2d Layer.</i>				
Levator anguli scapulæ	4 upper cervical
Rhomboideus min.	{ lig. nuchæ, 2 lower cervical.	}
Rhomboideus major	4 upper dorsal
<i>3d Layer.</i>				
Serratus posticus superior	{ 2 lower cervical . 2 upper dorsal }	}
Serratus posticus inferior	{ 2 lower dorsal 2 upper lumbar }	}
Splenius capitis ...	{ 4 lower cervical, 6 upper dorsal }	}
Splenius colli
<i>4th Layer.</i>				
Sacro-lumbalis	sacrum and ilium . .
—accessorius ad sacro-lumbalem }	{ angles of 6 lower }
Longissimus dorsi	lumbar vertebræ
Spinalis dorsi	{ 2 lower dorsal, 2 upper lumbar }	}
Cervicalis ascendens	{ angles of 4 upper }
Transversalis colli	4 upper dorsal
Trachelo-mastoideus.	{ 4 upper dorsal . 4 lower cervical. }
Complexus	{ 4 upper dorsal . 4 lower cervical. }
<i>5th Layer.</i>				
Semi-spinalis dorsi	6 lower dorsal
Semi-spinalis colli	4 upper dorsal
Rectus posticus maj	axis
Rectus posticus min	atlas
Rectus lateralis	atlas
Obliquus inferior ...	axis
Obliquus superior	axis
<i>6th Layer.</i>				
Multifidus spinæ	{ from sacrum to 3d cervical, }
Levatores costarum	all the dorsal
Supra-spinales	cervical
Inter spinales	cervical
Inter-transversales	cervical

INSERTION.

SPINOUS PROCESSES.	TRANSVERSE PROCESSES.	RIBS.	ADDITIONAL.
.....	{ clavicle and spine of the scapula. posterior bicipital ridge of the humerus.
.....	
.....	{ angle and base of the scapula. base of the scapula. base of the scapula.
.....	
.....	
.....	2d, 3d, 4th, and 5th.	
.....	4 lower ribs.	
.....	{ 4 upper cervical.	{ occipital bone between the curved lines.
.....			
.....	angles of 6 lower.	
.....	angles of 6 upper.	
.....	{ all the ribs between the tubercles and angles.	
8 upper dorsal			
.....	4 lower cervical.		
.....	4 middle do.		
.....	mastoid process.
.....	{ occipital bone between the curved lines.
{ 4 upper dorsal, 2 lower cervical.			
{ 4 upper cervical, except atlas.			
.....	occipital bone.
.....	occipital bone.
.....	occipital bone.
.....	atlas.	occipital bone.
.....	
{ from last lumbar to axis.	{ all the ribs between the tubercles and angles.	
.....			
cervical.			
cervical.			
.....	cervical.		

of each, and compare the natural grouping and similarity of attachments of the various layers. In this manner, also, their actions will be better comprehended, and learnt with greater facility. See table, pp. 278, 279.

In examining this table, the student will observe the constant recurrence of the number *four* in the origin and insertion of the muscles. Sometimes the *four* occurs at the top or bottom of a region of the spine, and frequently includes a part of two regions, and takes two from each, as in the case of the serrata. Again, he will perceive that the muscles of the upper half of the table take their origin from spinous processes, and pass outwards to transverse, whereas the lower half arises mostly from transverse processes. To the student, then, we commit these reflections, and leave it to the peculiar tenour of his own mind to make such arrangements as will be best retained by his memory.

ACTIONS.—The first two layers are muscles of the shoulder and arm, to move which their efforts are directed. Their actions have been described, with those of the shoulder.

The two serrati are respiratory muscles acting in opposition to each other—the *serratus posticus superior*, drawing the ribs upwards, and thereby expanding the chest; and the *inferior*, drawing the lower ribs downwards and diminishing the cavity of the chest. The former is an inspiratory, the latter an expiratory muscle.

The *Splenii muscles* draw the head backwards and to one side, so as to direct the face towards the shoulder. Both muscles, acting together, will draw the head directly backwards. They are the natural antagonists of the sterno-mastoid muscles.

The *Sacro-lumbalis*, with its *accessory muscle*, the *longissimus dorsi* and *spinalis dorsi*, are known by the general term of *erector spinæ*, which sufficiently expresses their actions. They keep the spine supported in the vertical position by their broad origin from below, and through their insertion by distinct tendons into the ribs and spinous processes. Being made up of a number of distinct fasciculi, which alternate in their actions, the spine is kept erect without fatigue, even when they have to counterbalance a corpulent abdominal development. The continuations upwards of these muscles into the neck preserve the steadiness and uprightness of that region. When the muscles of one side act alone, the neck is

rotated upon its axis. The *complexus*, by being attached to the occipital bone, draws the head backwards, and counteracts the muscles on the anterior part of the neck. It assists also in the rotation of the head.

The *Semi-spinales* and *multifidus spinæ* muscles act directly on the vertebræ, and contribute to the general action of supporting the vertebral column erect.

The four little muscles situated between the occiput and the first two vertebræ, effect the various movements between these bones; the *recti* producing the antero-posterior actions, and the *obliqui* the rotatory motions of the atlas on the axis.

The actions of the remaining muscles of the spine, the *supra* and *interspinales* and *intertransversales*, are expressed in their names. They approximate their attachments, and assist the more powerful muscles in preserving the erect position of the body.

The *Levatores costarum* raise the posterior parts of the ribs, and are probably more serviceable in preserving the articulation of the rib from dislocation, than in raising them in inspiration.

SPINAL CORD.

The dissection of the spinal cord requires that the spinal column should be opened throughout its entire length by sawing through the laminae of the vertebræ, close to the roots of the transverse processes, and raising the arches with a chisel, after the muscles of the back have been removed.

The *Spinal column* contains the *spinal cord*, or *medulla spinalis*; the *roots* of the *spinal nerves*; and the membranes of the cord, viz. *dura mater*, *arachnoid*, *pia mater*, and *membrana dentata*.

The *Dura mater* (*fig. 77. 1.*) (*theca vertebralis*) is continuous with the *dura mater* of the skull: it is closely attached around the border of the occipital foramen, particularly in front, to the posterior common ligament. In the vertebral canal it is connected only by loose cellular tissue, containing an oily fluid, somewhat analogous to the marrow of long bones. On either side, and below, it forms a sheath, 2. 2., for each of the spinal nerves, to which it is closely adherent.

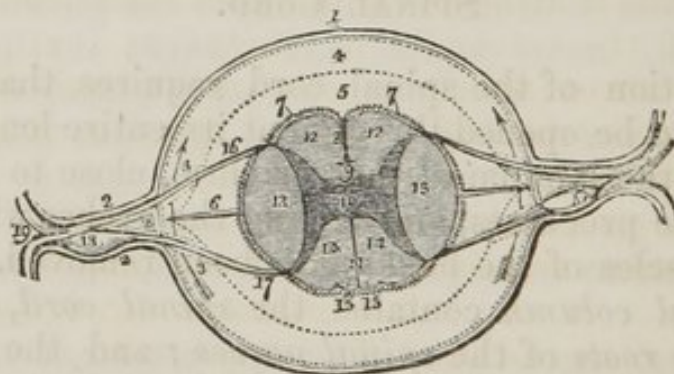
Upon its inner surface it is smooth, being lined by the

arachnoid; and on either side may be seen the double opening for the two roots of each of the spinal nerves.

The *Arachnoid* (*fig. 77.*) is a continuation of the serous membrane of the brain. It encloses the cord very loosely, being connected to it only by long slender cellular filaments; passes off on either side with the spinal nerves, to which it forms a sheath; and is then reflected upon the dura mater, to constitute its serous surface. A connexion exists in several situations between the arachnoid of the cord and that of the dura mater.

The space between the arachnoid and the spinal cord is identical with that already described as existing between the same parts in the brain, the *Sub-arachnoidean space* (*fig. 77. 4.*) It is filled in both with a serous fluid, sufficient in quantity to expand the arachnoid, and fill completely the cavity of the theca vertebralis. The *Sub-arachnoidean fluid* keeps up a constant and gentle pressure upon the entire surface of the brain and spinal cord, and yields with the greatest facility to the various movements of the cord, giving to those delicate structures the advantage of the principles so usefully applied by Dr. Arnott in the hydrostatic bed.

Fig. 77. Section of the spinal cord with its membranes.



1. The dura mater. 2. 2. The dura mater, forming a sheath for each of the roots of a spinal nerve, and afterwards a sheath for the nerve itself. The dotted line represents the arachnoid membrane. 3. 3. A sheath formed by the arachnoid around each of the roots of the spinal nerve during its passage through that membrane. 4. The space between the two layers of the arachnoid; an arrow at each side shows that this space is continuous all around the spinal cord, and that the disposition of the membrane at 3. 3. is a mere sheath. 5. The space between the arachnoid and pia mater, the sub-arachnoidean space, in which is lodged the sub-arachnoidean fluid. 6. One of the dentations of the ligamentum denticulatum. 7. 7. The pia mater of the cord. 8. The sulcus longitudinalis. 9. The white commissure, connecting the two lateral halves of the cord. 10. The gray commissure, connecting the two semilunar processes of gray. 11. The sulcus longitudinalis posterior. 12. 12. The two anterior or motor columns of the spinal cord.

13. 13. The two lateral columns. 14. 14. The two posterior or sensitive columns. 15. 15. The posterior median columns, bounded by two shallow fissures. 16. The origin of the anterior or motor root of a spinal nerve. 17. The origin of its posterior or sensitive root. 18. The ganglion on the posterior root. 19. The spinal nerve dividing into its two primary branches, anterior and posterior.

The *Pia mater* (*fig. 77. 7. 7.*) is the immediate investment of the cord, and, like the other membranes, is continuous with that of the brain. It is not, however, like the pia mater cerebri, a vascular membrane, but is dense and fibrous in its structure, and contains very few vessels. It invests the cord closely, and sends a duplicature into the sulcus longitudinalis anterior, and another, extremely delicate, into the sulcus longitudinalis posterior. It forms a sheath for each of the filaments of the nerves, and for the nerves themselves; and, inferiorly, at the conical termination of the cord, it is prolonged downwards, and forms a slender ligament, which descends through the centre of the cauda equina, and is attached to the dura mater lining the canal of the sacrum.

The *Membrana dentata* (*fig. 77. 6.*) is a process of the pia mater sent off from either side of the cord throughout its entire length, and separating the anterior from the posterior roots of the spinal nerves. Between each of the nerves it forms a serration, which is attached to the dura mater, and unites the two layers of the arachnoid membrane at that point. The processes are about twenty in number at each side. Their use is to maintain the position of the spinal cord in the midst of the fluid by which it is surrounded.

The *Spinal cord* extends from the pons Varolii to opposite the second lumbar vertebra, where it terminates in a rounded point; it is not of the same thickness throughout, but presents three enlargements. The uppermost of these is the *medulla oblongata*, the next corresponds with the origin of the nerves destined to the upper extremities; and the lower enlargement is situated near to its termination, and corresponds with the attachment of the nerves which are intended for the supply of the lower limb.

In form, the spinal cord is a flattened cylinder, and presents on its anterior surface a groove (*fig. 77, 8.*) which extends into the cord to the depth of one-third of its diameter. This is the *sulcus longitudinalis anterior*. If the sides of the groove be gently separated, they will be seen to be connected at the bottom by a layer of medullary substance, 9.

On the posterior surface another fissure (*fig. 77. 11.*) exists, which is so narrow as to be hardly perceptible without careful examination. This is the *sulcus longitudinalis posterior*. It extends much more deeply into the cord than the anterior sulcus, and terminates in the gray substance of the interior. These two fissures divide the medulla spinalis into two lateral cords, which are connected to each other only by the white layer, 9., which forms the bottom of the anterior longitudinal sulcus.

On either side of the *sulcus longitudinalis posterior* is a slight line, which bounds on either side the posterior median columns (*fig. 77. 15.*) These are most apparent at the upper part of the cord, near to the fourth ventricle, where they are separated by the point of the *calamus scriptorius*.

Two other lines are observed on the medulla, the anterior and posterior lateral sulci, corresponding with the attachment of the anterior and posterior roots of the spinal nerves.

The *Anterior lateral sulcus* is a mere line, marked only by the attachment of the filaments of the anterior roots.

The *Posterior lateral sulcus* is more evident; and is formed by a narrow grayish fasciculus derived from the gray substance of the interior.

These sulci divide the medulla into four fasciculi or cords, viz.—

Anterior columns,
Lateral columns,

Posterior columns,
Median columns.

The *Anterior* (*fig. 77. 12. 12.*) are the *motor columns*, and give origin to the motor roots of the spinal nerves. They are continued upwards into the medulla oblongata, under the name of *corpora pyramidalia*.

The *Lateral columns* (*fig. 77. 13. 13.*) are divided in their function between motion and sensation; and contain the fasciculus described by Sir Charles Bell as the respiratory tract. Some anatomists consider the anterior and lateral column on each side as a single column, under the name of *antero-lateral*.

The *Posterior* (*fig. 77. 14. 14.*) are the *columns of sensation*, and give origin to the sensitive roots of the spinal nerves. Their superior terminations are named *corpora restiforma*.

The *Median posterior columns* (*fig. 77. 15. 15.*) have no function at present assigned to them.

If a transverse section (*fig. 77.*) of the spinal cord be made,

its internal structure may be seen and examined. It would then appear to be composed of two hollow cylinders of white matter, placed side by side, and connected by a narrow white commissure, 9. Each cylinder is filled with gray substance, which is connected by a commissure of the same matter. The form of the gray substance, as observed in the section, is that of two half moons placed back to back, and joined by a transverse band, 10. The horns of the moons correspond to the sulci of origin of the anterior and posterior roots of the nerves. The anterior horns do not quite reach this surface, but the posterior appear upon the surface, and form a narrow gray line.

SPINAL NERVES.—There are *thirty-one pairs* of spinal nerves, each arising by two roots, an interior or motor root, and a posterior or sensitive root.

The *Anterior roots* (*fig. 77. 16.*) arise from a narrow white line, and approach nearer to the middle line as they descend.

The *Posterior roots* (*fig. 77. 17.*), more regular than the anterior, arise from a narrow gray band formed by the internal gray substance of the cord. These roots are larger, and the filaments of origin more numerous, than these of the anterior roots. A ganglion, 18., is formed upon each of the posterior roots in the intervertebral foramina. The first cervical nerve forms an exception to these characters; its anterior root is larger than the posterior, and there is frequently no ganglion on its posterior root.

After the formation of the ganglion, the two roots unite, and constitute a spinal nerve (*fig. 77. 19.*), which escapes through the intervertebral foramen, and divides into an anterior branch, for the supply of the front half of the body, and a posterior branch, for the posterior half.

The *Spinal nerves* are divided into

Cervical	-	-	8 pairs
Dorsal	-	-	12
Lumbar	-	-	5
Sacral	-	-	6

31

The *Cervical nerves* pass off transversely from the spinal cord; the *dorsal* are oblique in their direction; and the *lumbar* vertical; and form the large assemblage of nerves at the termination of the cord called *cauda equina*.

The ARTERIES of the spinal cord are, the anterior, posterior, and lateral spinal, which are derived from the vertebral; and branches from the intercostal and lumbar arteries, which enter the canal through the intervertebral foramina.

The VEINS of the vertebral column are divided into three sets:—

Dorsi-spinal,
Meningo-rachidian,
Medulli-spinal.

The *Dorsi-spinal* form a plexus around the spinous, transverse and articular processes and arches of the vertebræ. They receive the returning blood from the dorsal muscles and surrounding parts, and convey it into the meningo-rachidian veins.

The *Meningo-rachidian* veins are situated between the theca vertebralis and the vertebræ. They communicate freely with each other by means of a complicated plexus. In front they form two longitudinal trunks which extend the whole length of the column on each side of the posterior common ligament, and are joined on the body of each vertebra by transverse trunks, which pass beneath the ligament, and receive the large vertebral veins from the interior of each vertebra. They pour their blood into the vertebral veins in the neck, into the intercostal and azygos veins in the thorax, and into the lumbar and sacral veins in the loins and pelvis, by means of communicating trunks, which escape at the intervertebral foramina.

The *Medulli-spinal* veins are situated between the pia mater and arachnoid; they communicate freely with each other, and form plexuses, and send branches through the intervertebral foramina with each of the spinal nerves, to join the veins of the trunk.

CHAPTER VIII.

THORAX.

THE *Thorax* is the conical cavity situated at the upper part of the trunk which contains the chief organs of respiration and circulation.

Dissection.—Its dissection consists of dividing the ribs on each side from the second to the fifth, and removing the anterior wall of the chest by separating its muscular connexions, and sawing across the sternum.

The *Boundaries* of the chest are the *ribs*, *intercostal muscles*, *vertebral column*, and *sternum*, which form its circumference. The *first rib*, and *thoracic fascia* above, and the *diaphragm* below. It is much deeper on the posterior than on the anterior wall, in consequence of the obliquity of the diaphragm.

The *Muscles* of the chest are the *intercostals* and *triangularis sterni*.

The *intercostals* consist of muscular and tendinous fibres, which are directed obliquely between the ribs. They are disposed in two planes, the external and internal, and cross each other in the direction of their fibres.

The *External intercostals*, eleven on each side, commence posteriorly at the vertebral column, and advance forwards to within a few inches of the sternum, becoming gradually thin and aponeurotic. Their fibres are directed obliquely downwards and inwards, pursuing the same line with those of the external oblique muscle of the abdomen.

The *Internal intercostals*, eleven on each side, commence anteriorly at the sternum, and extend backwards to within a short distance of the vertebral column. Their fibres are directed obliquely downwards and backwards, and correspond in direction with those of the internal oblique muscle of the abdomen.

The intercostal vessels and nerves pursue their course between the two planes of muscles.

The *Triangularis sterni*, situated upon the inner wall of the chest, *arises* by a thin aponeurosis from the side of the

sternum and sternal extremities of the costal cartilages, and is *inserted* by fleshy digitations into the cartilages of the third, fourth, fifth, and sixth ribs, and often into that of the second.

ACTIONS.—The intercostal muscles raise the ribs when they act from above, and depress them when they take their fixed point from below. They are, therefore, both inspiratory and expiratory muscles. The *triangularis sterni* draws down the costal cartilages.

The *Thoracic fascia* is a dense layer of cellulo-fibrous membrane stretched horizontally across the superior opening of the thorax. It is firmly attached to the concave margin of the first rib, and to the inner surface of the sternum. In front it leaves an opening for the connexion of the cervical with the thoracic portion of the thymus gland; and behind it forms an arch across the vertebral column, to give passage to the œsophagus.

At the point where the great vessels and trachea pass through the thoracic fascia it divides into an ascending and descending layer. The *ascending layer* is attached to the trachea, and becomes continuous with the sheath of the carotid vessels and with the deep cervical fascia; and the *descending layer* descends upon the trachea to its bifurcation, surrounds the large vessels arising from the arch of the aorta and the upper part of the arch itself, and is continuous with the fibrous layer of the pericardium. It is connected also with the *venæ innominatæ* and superior cava, and is attached to the cellular capsule of the thymus gland.

“The thoracic fascia,” writes Sir Astley Cooper, “performs three important offices:—

1st. It forms the upper boundary of the chest, as the diaphragm does the lower.

2d. It steadily preserves the relative situation of the parts which enter and quit the thoracic opening.

3d. It attaches and supports the heart in its situation through the medium of its connexion with the aorta and large vessels which are placed at its curvature.”

Vessels and Nerves. The *Arteries* of the parietes of the chest are the aortic intercostals; superior intercostals, from the subclavian; anterior intercostals, from the internal mammary; and the thoracic branches from the axillary.

The *Nerves* are the intercostal and thoracic branches.

VISCERA OF THE THORAX.

The contents of the chest are the *lungs* and *heart*, with their *investing membranes*, and the *great vessels*.

The LUNGS occupy the sides of the chest. In the healthy state they are of a pinkish gray colour mottled with black.

The *Right lung* (*fig. 78. 1.*) is larger than the left, in consequence of the inclination of the heart to the left side: it is also shorter, from the encroachment of the liver upon the right side, which presses the diaphragm upwards considerably above the level of the left.

The right lung has three *lobes*, of which the middle is the smallest, and is placed anteriorly. The *left lung* has only two.

Each lung is retained in its place by its *root* (*fig. 78. 3. 3.*) which is formed by the pulmonary artery and veins and bronchial tubes, together with the bronchial vessels and pulmonary plexuses of nerves.

The large vessels of the root of the lung are arranged in the same order from before, backwards on both sides, viz.—

Pulmonary veins,
Pulmonary artery,
Bronchus.

From above, downwards, on the *right* side, this order is exactly reversed. On the *left* side the bronchus has to stoop beneath the arch of the aorta, which alters its position to the vessels. They are thus disposed on the two sides:—

<i>Right.</i>	<i>Left.</i>
Bronchus,	Artery,
Artery,	Bronchus,
Veins.	Veins.

Structure.—The lungs are composed of the ramifications of the bronchial tubes, which terminate in bronchial cells (air cells,) of the ramifications of the pulmonary artery and veins, bronchial artery and veins, lymphatics and nerves. The whole of these structures being held together by cellular tissue, which forms their *parenchyma*.

Bronchial tubes.—The fibro-cartilaginous rings which are observed in the trachea become incomplete and irregular in the bronchi, and in the bronchial tubes are lost altogether. At the termination of these tubes the fibrous coat ceases, and

the cell is formed solely by the lining mucous membrane. The ramification of the bronchial tubes is effected by a binary subdivision.

Vessels and Nerves.—The nutrition of the lungs is performed by the bronchial arteries. The *lymphatics* terminate at their roots in the *bronchial glands*. These glands are very numerous at the bifurcation of the trachea, and around the bronchi. In early life they resemble lymphatic glands in other situations; but in the adult, and in old age, they are quite black, and filled with carbonaceous matter, and often with calcareous deposits.

The *Nerves* are derived from the pneumogastric and sympathetic. They form two plexuses; 1. *anterior pulmonary plexus*, situated upon the front of the root of the lungs; 2. *posterior pulmonary plexus*, on the posterior aspect of the root of the lungs. The branches from these plexuses follow the course of the bronchial tubes, and are distributed to the bronchial cells.

PLEURA.—Each lung is enclosed in a serous membrane (*fig. 78. 5. 4. 4.*) which invests it as far as the root, and is then reflected upon the parietes of the chest. That portion of the membrane which is in relation with the lung is called *pleura pulmonalis*, and that in contact with the parietes, *pleura costalis*. The reflected portion, besides forming the internal lining to the ribs and intercostal muscles, also covers the diaphragm and the thoracic surface of the vessels at the root of the neck.

The pleura must be dissected from off the root of the lung to see the vessels of which it is formed and the pulmonary plexuses.

MEDIASTINUM.—The approximation of the two reflected pleuræ in the middle line of the thorax forms a septum which divides the chest into the two pulmonary cavities. This is the mediastinum. The two pleuræ are not, however, in contact with each other at the middle line in the formation of the mediastinum, but leave a space between them which contains all the viscera of the chest excepting the lungs.

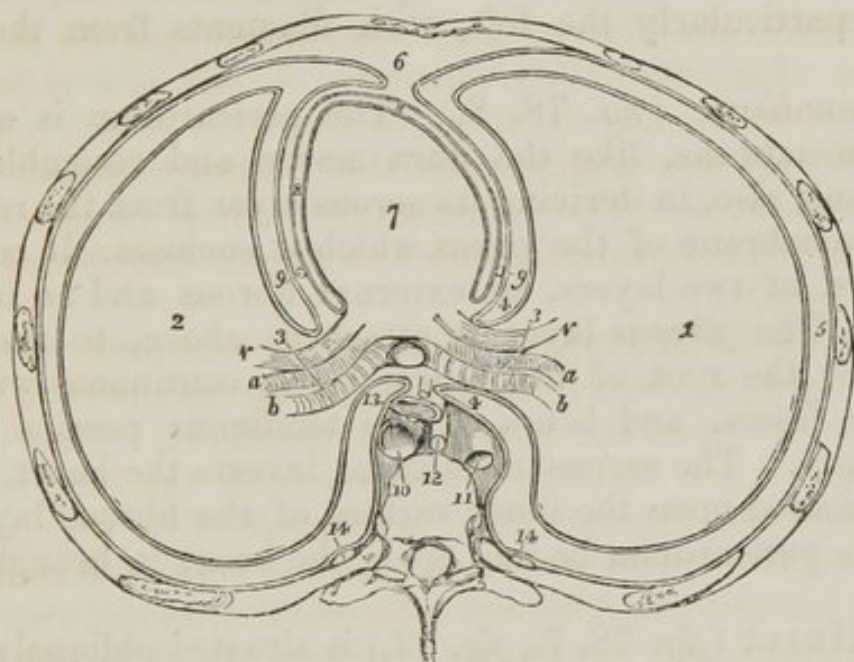
The mediastinum is divided into the *anterior, middle, and posterior*.

The *Anterior mediastinum* (*fig. 78. 6.*) is a triangular space bounded in front by the sternum, and on either side by the pleura. It contains a quantity of loose cellular tissue, in

which are found some lymphatic glands and vessels passing upwards from the liver; the remains of the thymus gland, the origins of the sterno-hyoid and sterno-thyroid muscles, and the internal mammary vessels.

The *Middle mediastinum* (*fig. 78. 7.*) contains the heart enclosed in its pericardium, 8. 8.; the ascending aorta; the bifurcation of the trachea; the superior vena cava; and the phrenic nerves, 9. 9.

Fig 78. A diagram representing a transverse section of the chest, and the relative position of the viscera.



1. The right lung. 2. The left lung. 3. The root of the lungs, with the order of vessels from before backwards, shown. *v.* The pulmonary vein. *a.* The pulmonary artery. *b.* The bronchus. 4. 4. The point of reflection of the pleura, from the root of the lung upon the parietes. 5. The cavity of the pleura: that which is in contact with the lung is the pleura pulmonalis, and that with the wall of the chest, pleura costalis. 6. The anterior mediastinum, bounded by the sternum in front, and by the pleura at each side. 7. The heart, in the middle mediastinum. 8. The cavity of the pericardium. 9. 9. The phrenic nerves lying between the pleura and pericardium, in front of the root of the lungs. 10. The descending aorta. 11. The vena azygos. 12. The thoracic duct. 13. The oesophagus, accompanied by the two pneumogastric nerves. These parts, from No. 10. to 13., are all within the posterior mediastinum, which is bounded on each side by the pleura, and behind by the vertebral column. 14. 14. The sympathetic nerve at each side.

The *Posterior mediastinum* is bounded behind by the vertebral column, in front by the pericardium, and on each side by the pleura. It contains the descending aorta (*fig. 78. 10.*;) the greater, 11., and lesser azygos veins, and superior

intercostal vein; the thoracic duct, 12.; the œsophagus and pneumogastric nerves, 13.; and the great splanchnic nerves.

Previously to opening the pericardium, if the sides of the middle mediastinum be examined, the *phrenic nerves*, 9. 9., will be seen shining through the pleura in front of the roots of the lungs. The left phrenic nerve is a little longer than the right, in consequence of having to curve around the convexity of the heart, and from the greater depth of the diaphragm on the left, than on the right side. The phrenic nerves arise from the third, fourth, and fifth cervical nerves, and are distributed to the diaphragm, where they communicate, particularly the left, with filaments from the solar plexus.

Pericardium. (*fig. 78. 8.*) The pericardium is a fibrous membrane, like the dura mater, and resembles that membrane, also, in deriving its serous layer from the reflected serous membrane of the viscus which it encloses. It consists, therefore, of two layers, an external fibrous and an internal serous. The *fibrous* layer is attached, above, to the great vessels at the root of the heart, being continuous with the thoracic fascia, and below to the tendinous portion of the diaphragm. The serous membrane invests the heart, and is then reflected upon the inner surface of the fibrous layer.

If the pericardium be laid open, the heart is brought into view.

The HEART (*fig. 78. 7., fig. 79.*) is situated obliquely in the chest, the *base* being directed upwards and backwards towards the right shoulder; the *apex* forwards, and to the left, points to the space between the fifth and sixth ribs, at about two or three inches from the sternum. Its *under side* is flattened, and rests upon the tendinous portion of the diaphragm; its *upper side* is rounded and convex, and formed principally by the right ventricle, and partly by the left. Surmounting the ventricles are the corresponding auricles, whose auricular appendages are directed forwards, and slightly overlap the root of the pulmonary artery. The pulmonary artery is the large anterior vessel at the root of the heart: it crosses obliquely the commencement of the aorta. The heart consists of two auricles and two ventricles, which are respectively named, from their position, right and left. The right is the venous side of the heart; it receives into its auricle the venous blood from every part of the body, by the superior and inferior

cavæ and coronary vein. From the auricle the blood passes into the ventricle, and from the ventricle through the pulmonary artery, to the capillaries of the lungs. From these it is returned as arterial blood to the left auricle; from the left auricle it passes into the left ventricle; and from the left ventricle is carried through the aorta, to be distributed to every part of the body, and again returned to the heart by the veins. This constitutes the course of the *adult circulation*.

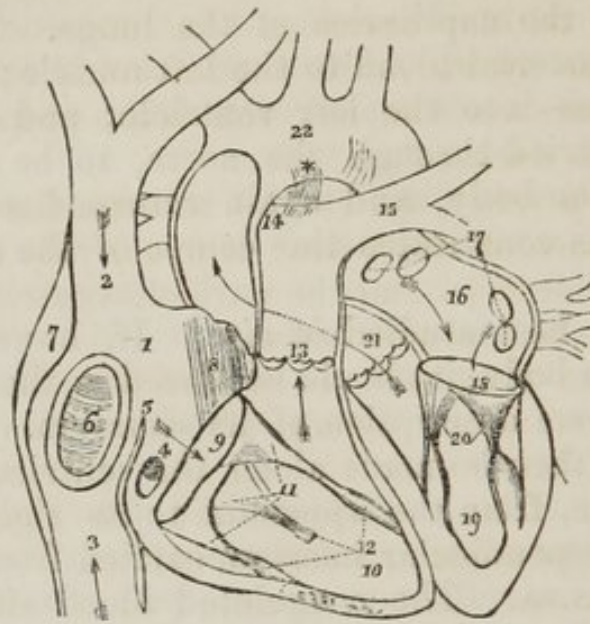
The heart is best studied *in situ*. If, however, it be removed from the body, it should be placed in the position indicated in the above description of its situation. A transverse incision should then be made along the ventricular margin of the right auricle, from the appendix to its right border, and crossed by a perpendicular incision, carried from the superior to the inferior cava. The coagulated blood should be withdrawn. Sometimes some fine specimens of white fibrine are found with the coagulum, at other times it is yellow and gelatinous. This appearance deceived the older anatomists, who called these substances "polypus of the heart;" they are also frequently found in the right ventricle, and sometimes in the left cavities.

The RIGHT AURICLE (*fig. 79. 1.*) is larger than the left, and is divided into a principal cavity, and an appendix auriculæ, 8. The interior of this auricle presents for examination five openings; two valves; two relicts of fœtal structure; and two peculiarities in the proper structure of the auricle. They may be thus arranged.

Openings - - - -	{ Superior cava, Inferior cava, Coronary vein, Foramina Thebesii, Auriculo-ventricular opening.
Valves - - - -	{ Eustachian valve, Coronary valve.
Relicts of fœtal structure	{ Annulus ovalis, Fossa ovalis.
Structure of the auricle	{ Tuberculum Loweri, Musculi pectinati.

The *Superior cava* (*fig. 79. 2.*) returns the blood from the upper half of the body, and opens into the upper and front part of the auricle.

Fig. 79. The cavities of the heart.



1. The right auricle. 2. The entrance of the superior cava. 3. The entrance of the inferior cava. 4. The opening of the coronary vein, half closed by its valve. 5. The Eustachian valve. 6. The fossa ovalis, surrounded by the annulus ovalis. 7. The tuberculum Loweri. 8. The musculi pectinati. 9. The auriculo-ventricular opening. 10. The right ventricle. 11. The tricuspid valve, attached by the chordæ tendinæ to the carnæ columnæ, 12. 13. The pulmonary artery, guarded at its commencement by three semilunar valves. 14. The right pulmonary artery, passing beneath the arch and behind the ascending aorta. 15. The left pulmonary artery, crossing in front of the descending aorta. *The remains of the ductus arteriosus, acting as a ligament between the pulmonary artery and arch of the aorta. The arrows mark the course of the venous blood through the right side of the heart. Entering the auricle by the superior and inferior cavæ, it passes through the auriculo-ventricular opening into the ventricle, and thence through the pulmonary artery to the lungs. 16. The left auricle. 17. The openings of the four pulmonary veins. 18. The auriculo-ventricular opening. 19. The left ventricle. 20. The mitral valve, attached by its chordæ tendinæ to two large columnæ carnæ, which project from the walls of the ventricle. 21. The commencement and course of the ascending aorta behind the pulmonary artery, marked by an arrow. The entrance of the vessel is guarded by three semilunar valves. 22. The arch of the aorta. The comparative thickness of the two ventricles is shown in the diagram. The course of the pure blood through the left side of the heart is marked by arrows. The blood is brought from the lungs by the four pulmonary veins into the left auricle, and passes through the auriculo-ventricular opening into the left ventricle, from whence it is conveyed by the aorta to every part of the body.

The *Inferior cava*, 3., returns the blood from the lower half of the body, and opens into the lower and posterior wall, close to the partition between the auricles (septum auricula-

rum.) The direction of these two vessels is such that a stream forced through the superior cava would be directed towards the auriculo-ventricular opening. In like manner, a stream rushing upwards by the inferior cava would force its current against the septum auricularum; this is the proper direction of the two currents during foetal life.

The *Coronary vein* (*fig. 79. 4.*) returns the venous blood from the substance of the heart; it opens into the auricle between the inferior cava and the auriculo-ventricular opening, under cover of the coronary valve.

The *Foramina Thebesii** are minute pore-like openings, by which the venous blood exhales directly from the muscular structure of the heart into the auricle, without entering the venous current. These openings are also found in the left auricle, and in the right and left ventricles.

The *Auriculo-ventricular opening* (*fig. 79. 9.*) is the large opening of communication between the auricle and ventricle.

VALVES.—The *Eustachian valve* (*fig. 79. 5.*) is a part of the apparatus of foetal circulation, and serves to direct the placental blood from the inferior cava, through the foramen ovale into the left auricle. In the adult it is a mere vestige and imperfect, though sometimes it remains of large size. It is formed by a fold of the lining membrane of the auricle, and is situated between the opening of the inferior cava and the auriculo-ventricular opening. It is generally connected with the *Coronary valve*, 4., which is a semilunar fold of the lining membrane, stretching across the mouth of the coronary vein, and preventing the reflux of the blood in the vein during the contraction of the auricle.

The *Annulus ovalis* is situated on the septum auricularum, opposite the termination of the inferior cava. It is the rounded margin of the septum, 6., which occupies the place of the foramen ovale in the foetus.

The *Fossa ovalis* (*fig. 79. 6.*) is an oval depression corresponding with the foramen ovale in the foetus. This opening is closed at birth by a thin valvular layer, which is continuous with the left margin of the annulus. The depression or fossa in the right auricle results from this arrangement. There is no fossa ovalis in the left auricle.

* Adam Christian Thebesius. His discovery of the openings now known by his name is contained in his "Dissertatio Medica de Circulo Sanguinis in Corde," 1708.

The *Tuberculum Loweri* (*fig. 79. 7.*) is the portion of auricle intervening between the openings of the superior and inferior cavæ. Being thicker than the walls of the veins, it forms a projection, which was supposed, by Lower, to direct the blood from the superior cava into the auriculo-ventricular opening.

The *Musculi pectinati*, 8. are small muscular columns situated in the appendix auriculæ. They are very numerous, and are arranged parallel with each other; hence their cognomen, "*pectinati*," like the teeth of a comb.

The RIGHT VENTRICLE, 10., is triangular and three-sided in its form. Its anterior side is convex, and forms the larger proportion of the front of the heart. The inferior side is flat, and rests upon the diaphragm; and the inner side corresponds with the partition between the two ventricles, *septum ventriculorum*.

The right ventricle is to be laid open by making an incision parallel with, and a little to the right of, the middle line, from the pulmonary artery in front, to the apex of the heart, and thence by the side of the middle line behind, to the auriculo-ventricular opening.

It contains, to be examined, two openings, the auriculo-ventricular and that of the pulmonary artery; two apparatuses of valves, the tricuspid and semilunar; and a muscular and tendinous apparatus belonging to the tricuspid valves. They may be thus arranged:—

Auriculo-ventricular opening,
Opening of the pulmonary artery,
Tricuspid valves,
Semilunar valves,
Chordæ tendineæ,
Columnæ carneæ.

The *Auriculo-ventricular* (*fig. 79. 9.*) is surrounded by a fibrous ring, covered by the lining membrane of the heart. It is the opening of communication between the right auricle and ventricle.

The *Opening of the pulmonary artery*, 13., is situated close to the *septum ventriculorum*, on the left side of the right ventricle, and upon the anterior aspect of the heart.

The *Tricuspid valves* (*fig. 79. 11.*) are three triangular folds of the lining membrane, strengthened by a thin layer of

tendinous fibres. They are connected around the auriculo-ventricular opening by their base. Their sides and apex are thickened, and give attachment to a number of slender tendinous cords; called *chordæ tendineæ*. The *chordæ tendineæ* are the tendons of the thick muscular columns (*columnæ carneæ*,) 12., which stand out from the walls of the ventricle, and serve as muscles to the valves. A number of these tendinous cords converge to a single muscular attachment. The tricuspid valves prevent the regurgitation of the blood into the auricle during the contraction of the ventricle, and they are prevented from being themselves driven back by the *chordæ tendineæ* and their muscular attachments.

This connexion of the muscular columns of the heart to the valves, has caused their division into active and passive.

The *Active* valves are the tricuspid and mitral; the *Passive* the mere folds of lining membrane, viz. the semilunar, Eustachian, and coronary.

The *Columnæ carneæ* (fleshy columns) is a name expressive of the appearance of the internal walls of the ventricles, which seem formed of muscular columns interlacing in almost every direction. They are divided into three sets, according to the manner of their connexion. 1. The greater number are attached by the whole of one side, and merely form convexities into the cavity of the ventricle. 2. Others are connected by both extremities, being free in the middle. 3. And a few are attached by one extremity only to the walls of the heart, the other giving insertion to the *chordæ tendineæ*.

The *Semilunar valves* (*fig. 79. 13.*) are three folds of the lining membrane, situated around the commencement of the pulmonary artery. They are attached by their convexities, and free by the concavities, which are directed upwards in the course of the vessels, so that, during the current of the blood along the artery, they are pressed against the sides of the cylinder, but if any attempt at regurgitation ensue, they are immediately expanded, and effectually close the entrance of the tube.

In the centre of the free margin of each of the valves, is a small fibro-cartilaginous tubercle, called *corpus Arantii*, which locks in with the two others during the closure of the valves, and secures the triangular space that would otherwise be left by the approximation of three semilunar folds.

Between the semilunar valves and the cylinder of the

artery are three pouches, called the *pulmonary sinuses*. Similar sinuses are situated beneath the valves at the commencement of the aorta, and are much larger and more capacious than those of the pulmonary artery.

The *Pulmonary artery* commences by a scolloped border, corresponding with the three valves, which are attached along its edge. It is connected to the ventricle by fibrous tissue, and by the lining membrane of the heart.

The **LEFT AURICLE** (*fig. 79. 16.*) is somewhat smaller than the right; of a cuboid form, and situated more posteriorly. The *appendix auriculæ* is constricted at its junction with the auricle, and has an arborescent appearance. It is directed forwards towards the root of the pulmonary artery, to which the auriculæ of both sides appear to converge.

The left auricle is to be laid open by a **I** shaped incision, the horizontal section being made along the border which is attached to the base of the ventricle.

It presents for examination five openings, and the muscular structure of the appendix are these:

Four pulmonary veins,
Auriculo-ventricular opening,
Musculi pectinati.

The *Pulmonary veins* (*fig. 79. 17.*), two from the right lung, and two from the left, open into the corresponding sides of the auricle. The two left pulmonary veins terminate frequently by a common opening.

The *Auriculo-ventricular opening*, 18., is the aperture of communication between the ventricle and auricle.

The *Musculi pectinati* are fewer in number than in the right auricle, and are situated only in the appendix auriculæ.

LEFT VENTRICLE.—The left ventricle is to be opened, by making an incision a little to the left of the septum ventriculorum, and continuing it around the apex of the heart, to the auriculo-ventricular opening behind.

The left ventricle (*fig. 79. 19.*) is conical, both in external figure, and in the form of its internal cavity. It forms the apex of the heart, by projecting beyond the right ventricle, while the latter has the advantage in length towards the base. Its walls are about seven lines in thickness, those of the right ventricle being about $2\frac{1}{2}$ lines.

It presents for examination, in its interior two openings,

two valves, and the tendinous cords and muscular columns; they may be thus arranged.

Auriculo-ventricular opening,
Aortic opening,
Mitral valves,
Semilunar valves,
Chordæ tendineæ,
Columnæ carneæ.

The *Auriculo-ventricular opening*, 18., is a dense fibrous ring, covered by the lining membrane of the heart, but smaller in size than that of the right side.

The *Mitral valves*, 20., are attached around the auriculo-ventricular opening, as are the tricuspid in the right ventricle. They are thicker than the tricuspid, and consist of only two segments, of which the larger is placed between the auriculo-ventricular opening and the commencement of the aorta, and acts the part of a valve to that foramen, during the filling of the ventricle. The difference of size of the two valves, both being triangular, and the space between them, has given rise to the idea of a "*bishop's mitre*," after which they are named.

These valves, like the tricuspid, are furnished with an apparatus of tendinous cords, *chordæ tendineæ*, which are attached to two very large *columnæ carneæ*.

The *Columnæ carneæ* admit of the same arrangement into three kinds, as on the right side. Those which are free by one extremity are only two in number, and much larger than those on the opposite side.

The *Semilunar valves*, 21., are placed around the commencement of the aorta, like those of the pulmonary artery, and, like them, are attached to the scalloped border, by which the aorta is connected with the ventricle. The tubercle in the centre of each fold is larger than those in the pulmonary valves, and it was these that Arantius particularly described; but the term "*corpora Arantii*," is now applied indiscriminately to both. The fossæ between the semilunar valves and the cylinder of the artery are much larger than those of the pulmonary artery; they are called the "*sinus aortici*."

STRUCTURE OF THE HEART.—The muscular fibres of the heart are divided into proper and common. The *proper fibres* of the auricles form a thin muscular layer over its surface,

their extremities being attached to the fibrous rings of the auriculo-ventricular openings. The *common fibres* are wound transversely around both auricles, and serve to bind them together.

The *proper fibres* of the ventricles are oblique, in their direction, and are wound spirally round and round, so as to form two irregular conical cylinders, open at both extremities.

The *common fibres* take their origin from the fibrous rings of the auriculo-ventricular openings, and descend obliquely from the right towards the left, in front, and from the left to the right behind, to the apex of the heart. Here they are reflected inwards, through the opening in the inferior extremity of the cylinder of the proper fibres, and form the inner muscular stratum of the ventricles. They terminate by being inserted, as they arose, into the fibrous rings of the auriculo-ventricular openings.

Thus it is, that the common fibres hold both the auricles and ventricles together, the common point of insertion being the zones of the auriculo-ventricular openings. They form, therefore, the superficial layer of the heart, passing from one ventricle across to the other, and by a peculiar turn upon themselves at the apex are reflected inwards through the inferior openings of the conical cylinders, so as to form the internal or deep layer of the ventricles, enclosing between their two layers the cylinders of the proper fibres.

VESSELS.—The *Arteries* of the heart are the right and left coronary.

The *Left* or *anterior coronary* passes forwards, between the pulmonary artery and left appendix auriculæ, and runs along the line of union of the two ventricles to the apex of the heart, where it inosculates with the right coronary. It supplies the left auricle and the adjoining sides of both ventricles.

The *Right* or *posterior coronary* passes forwards, between the root of the pulmonary artery and the right auricle, and winds along the auriculo-ventricular groove, to the posterior median furrow, where it descends upon the posterior aspect of the heart to its apex, and inosculates with the left coronary. It is distributed to the right auricle and to the posterior surface of both ventricles.

Both coronary arteries arise from the root of the aorta in the sinus aortici, behind the semilunar valves.

The *Veins* accompany the arteries, and empty themselves by the common coronary vein into the right auricle.

The *Lymphatics* terminate in the glands about the root of the heart.

NERVES.—The *Nerves* of the heart are derived from the cardiac plexuses, which are formed by communicating filaments from the sympathetic and pneumogastric.

GREAT VESSELS OF THE HEART.

The *vessels* at the root of the heart may be thus arranged:—

Superior and inferior cava,	Four pulmonary veins,
Pulmonary artery,	Aorta.

As all these vessels bear a certain relation to the aorta, we shall therefore commence by describing that trunk.

The *Aorta* (*fig.* 69. 21. 22.) arises from the left ventricle, at the middle of the root of the heart. It ascends at first to the right, then curves backwards and to the left, and descends on the left side of the vertebral column to the fourth lumbar vertebra. Hence it is divided into the ascending arch, and descending aorta.

RELATIONS.—The *Ascending aorta* has in relation with it, in front, the trunk of the pulmonary artery, thoracic fascia, and pericardium; behind, the right pulmonary veins and artery; to the right side, the right auricle and superior cava; and to the left, the left auricle and trunk of the pulmonary artery.

ARCH.—The upper border of the arch is parallel with the second dorsal vertebra, and it terminates opposite the lower border of the third.

The anterior surface of the arch is crossed by the left pneumogastric nerve, and the cardiac branches of that nerve, and of the sympathetic.

The posterior surface of the arch is in relation with the bifurcation of the trachea, and great cardiac plexus, the cardiac and left recurrent nerves, and the thoracic duct.

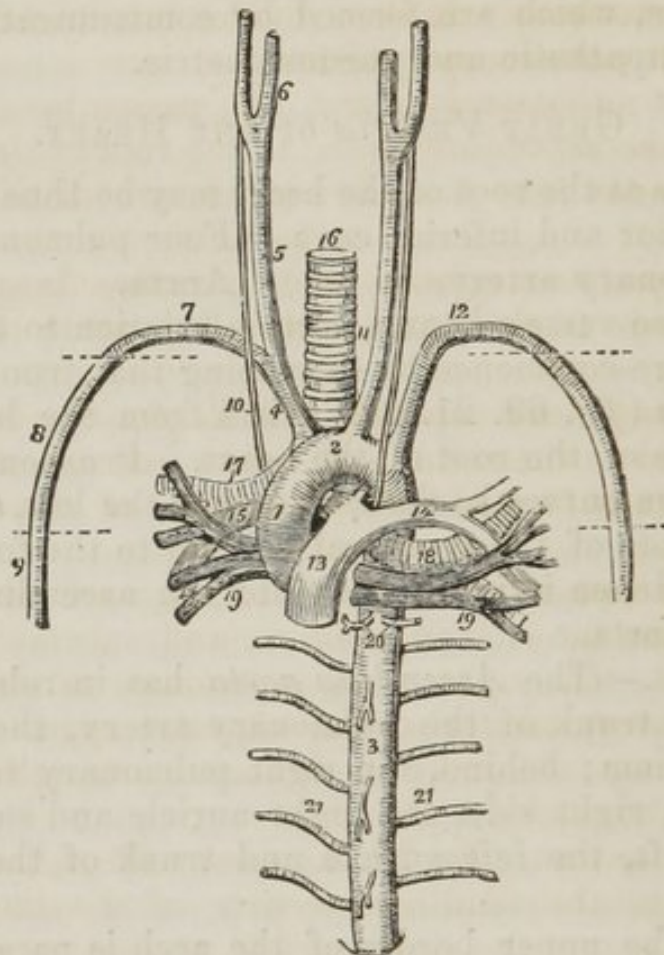
The superior border gives off the three great arteries, viz. the innominate, left carotid, and left subclavian.

The inferior border or concavity of the arch is in relation with the remains of the ductus arteriosus, the cardiac ganglion and left recurrent nerve, and has passing beneath it the right pulmonary artery and left bronchus.

The *Descending aorta* is situated in the posterior mediasti-

num, and rests upon the vertebral column. Its relations will be described with that space.

Fig. 80. The large vessels which proceed from the root of the heart, with their relations; the heart has been removed.



1. The ascending aorta. 2. The arch. 3. The thoracic portion of the descending aorta. 4. The arteria innominata dividing into, 5, the right carotid, which again divides at 6, into the external and internal carotid; and 7, the right subclavian artery. 8. The axillary artery; its extent is designated by a dotted line. 9. The brachial artery. 10. The right pneumogastric nerve running by the side of the common carotid, in front of the right subclavian artery, and behind the root of the right lung. 11. The left common carotid, having to its outer side the left pneumogastric nerve, which crosses the arch of the aorta, and as it reaches its lower border is seen to give off the left recurrent nerve. 12. The left subclavian artery becoming axillary, and brachial in its course, like the artery of the opposite side. 13. The trunk of the pulmonary artery connected to the concavity of the arch of the aorta by a fibrous cord, the remains of the ductus arteriosus. 14. The left pulmonary artery. 15. The right pulmonary artery. 16. The trachea. 17. The right bronchus. 18. The left bronchus. 19. 19. The pulmonary veins. 17. 15. and 19; on the right side, and 14, 18, and 19, on the left, constitute the roots of the corresponding lungs, and the relative position of these vessels is carefully preserved. 20. Bronchial arteries. 21. 21. Intercostal arteries, the branches from the front of the aorta above and below the number 3 are pericardiac and œsophageal branches.

The *Pulmonary artery* (*fig. 79. 13.*) arises from the upper part of the left side of the right ventricle, in front of the origin of the aorta. It crosses the root of the aorta somewhat obliquely to the under surface of the arch, to which it is connected by a ligamentous cord (*fig. 79.**), the remains of the ductus arteriosus. It then divides into two branches, the right and left pulmonary arteries.

The *Right pulmonary artery*, 14., passes beneath the arch and behind the ascending aorta, to the root of the right lung, where it divides into branches which are distributed to its three lobes.

The *Left pulmonary artery*, 15., rather larger than the right, passes in front of the descending aorta to the root of the left lung.

The *Superior vena cava* (*fig. 79. 2. fig. 81. 1.*) is a short trunk situated to the right, and rather in front of the ascending aorta. It is formed by the junction of the two *venæ innominatæ*.

The *Venæ innominatæ* (*fig. 81. 2, 3.*) are formed by the junction of the internal jugular, 4., and subclavian veins, 5., at each side. The right *vena innominati* is short, and descends almost vertically to the superior cava. The left is long, and crosses obliquely the branches arising from the arch of the aorta.

The *Inferior cava* (*fig. 79. 3.*) passes through a quadrilateral opening in the tendinous centre of the diaphragm, and immediately enters the right auricle, so that its extent within the chest is not more than half or three quarters of an inch.

PULMONARY VEINS.—The *Right pulmonary veins*, anterior to the other vessels in the root of the lung, pass behind the right auricle to open into the right side of the left auricle.

The *Left pulmonary veins*, also anterior to the other vessels in the root of the lung, pass in front of the descending aorta to open into the left side of the corresponding auricle.

TRACHEA and BRONCHI.—Behind the arch of the aorta, the trachea divides into the two bronchi. The *right bronchus* passes off at right angles, and enters the upper part of the right lung. It crosses behind the superior cava, and has the *vena azygos* curving around it to terminate in that vein. The *left bronchus* is oblique in its direction, having to stoop beneath the arch of the aorta to reach the root of the lung. It enters the lung, therefore, at the middle, and not at the up-

per part, as does the right. Hence the difference of relation of the two bronchi in the roots of the lungs.

POSTERIOR MEDIASTINUM.—If the lungs be removed near to their roots, or thrown to one side, the posterior mediastinum may be dissected and examined.

The contents of the *posterior mediastinum*, are the

Descending aorta,	Thoracic duct,
Vena azygos major,	Œsophagus,
Vena azygos minor,	Pneumogastric nerves,
Superior intercostal vein,	Great splanchnic nerves.

The *Descending* or *Thoracic aorta* (*fig.* 78. 10.) is situated to the left side of the vertebral column, but approaches the middle line as it descends, and at the aortic opening of the diaphragm is altogether in front of the column. After entering the abdomen, it again falls back to the left side.

RELATIONS.—It is in relation, behind, with the vertebral column and lesser vena azygos; in front, with the œsophagus and right pneumogastric nerve; to the left side, with the pleura; and to the right, with the thoracic duct.

BRANCHES.—Its branches are pericardiac, bronchial, œsophageal, and intercostal arteries.

The *Pericardiac* are a few twigs to the posterior part of the pericardium.

The *Bronchial*, *two superior* and *two inferior*, arise from the upper part of the artery, and pass to the roots of the lungs, to be distributed with the bronchial tubes. They are the nutritious arteries of the lungs.

The *Œsophageal* are several small branches given off from the front part of the aorta to the œsophagus.

The *Intercostal*, or posterior intercostal branches are ten in number on each side, the two superior spaces being supplied by the superior intercostal artery, a branch of the subclavian. The right intercostals are longer than the left, on account of the position of the aorta. They cross the vertebral column behind the thoracic duct, vena azygos major, and sympathetic nerve, to the intercostal spaces, the left passing beneath the lesser vena azygos and sympathetic. In the intercostal spaces, or rather upon the external intercostal muscles, each artery gives off a dorsal branch for the supply of the muscles of the back. It then comes into relation with its vein and nerve, the former being above, and the latter below, and divides into two branches, which run along the borders of the contiguous ribs between the two planes of intercostal

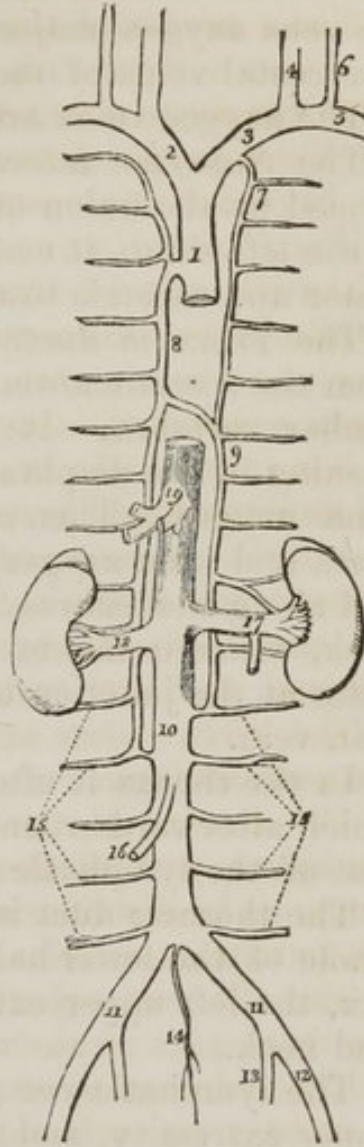
muscles, and anastomose with the anterior intercostal arteries, branches of the internal mammary. The branch corresponding with the lower border of the rib is the larger of the two. They are protected from pressure during the action of the intercostal muscles, by little tendinous arches thrown across and attached by each extremity to the bone.

The *venæ azygos* and superior intercostal vein, form a kind of system of themselves for returning the venous blood from the parietes of the chest and vertebral column, in the vacant interval left by the two cavæ, as they advance forwards to be connected with the heart. They likewise establish a communication between those two trunks.

The *Vena azygos major* (fig. 81. 8. fig. 78. 11.) arises in the lumbar region by a communication with the lumbar veins; sometimes it is joined by a branch directly from the inferior vena cava, or by one from the renal vein. It passes through the aortic opening in the diaphragm, and ascends upon the right side of the vertebral column to the third dorsal vertebra, where it arches forwards over the right bronchus, and terminates in the superior cava. It receives all the intercostal veins of the right side, together with the bronchial and *vena azygos minor*.

1. The superior vena cava. 2. The right vena innominata. 3. The left vena innominata. 4. The internal jugular vein of the left side. 5. The subclavian vein of the left side. 6. The external jugular vein. 7. The superior intercostal vein. 8. The great vena azygos, communicating inferiorly with one of the lumbar veins. 9. The lesser vena azygos, communicating inferiorly with a lumbar and with the left renal vein. 10. The inferior vena cava. 11. 11. The two common iliac veins. 12. The right external iliac. 13. The internal iliac vein. 14. The vena sacra media. 15. 15. The lumbar veins. 16. The right spermatic vein. 17. The left renal vein, into which is seen opening from below the left spermatic vein. 18. The right renal vein. 19. The hepatic veins.

Fig. 81. The veins of the trunk.



The *Vena azygos minor* (*fig.* 81. 9.) commences in the lumbar region, on the left side, by a communication with the lumbar or renal veins. It passes beneath the border of the diaphragm, and ascending upon the left side of the vertebral column, crosses the fifth or sixth dorsal vertebra to open into the vena azygos major. It receives the six or seven lower intercostal veins of the left side.

The azygos veins are said to have no valves.

The *Superior intercostal vein* (*fig.* 81. 7.) is the trunk formed by the union of the five or six upper intercostal veins of the left side. It communicates below with the vena azygos minor and ascends to terminate in the left vena innominata.

The *Thoracic duct* (*fig.* 78. 12.) arises in the abdomen from the *receptaculum chyli*, which is situated on the second lumbar vertebra. It enters the thorax through the aortic opening in the diaphragm, behind and between the aorta and vena azygos. Then ascends perpendicularly between the aorta and vena azygos, passes behind the arch of the aorta, and along the course of the left subclavian artery into the neck, where it makes a sudden turn downwards, and terminates at the junction of the left jugular with the left subclavian vein.

In the thorax it often divides into two or three branches, which afterwards reunite. It is provided with valves like the rest of the lymphatic system.

The thoracic duct is the common lymphatic trunk of the whole of the lower half of the body, the left side of the thorax, the left upper extremity, and the left side of the head and neck.

The lymphatic vessels of the right side of the thorax, right upper extremity, and right side of the head and neck, unite to form the *ductus lymphaticus dexter*, which opens into the junction of the right jugular and subclavian veins.

The *Œsophagus* (*fig.* 78. 13.) commences on a level with the lower border of the cricoid cartilage, opposite to the fifth cervical vertebra. It descends upon the vertebral column, a little to the left of the trachea, and passing down behind the arch of the aorta, becomes placed immediately in front of the descending aorta upon which it lies. Near to the lower part of the chest it advances forwards, and passes through a muscular opening in the diaphragm to terminate in the stomach. It is accompanied by the pneumogastric nerves.

PNEUMOGASTRIC NERVES.—The *Right pneumogastric nerve*, after its entrance into the chest, between the right subclavian artery and vein, descends obliquely behind the superior cava and behind the root of the lungs, to the posterior surface of the œsophagus, along which it runs to the stomach.

The *Left pneumogastric nerve* runs parallel with the left subclavian artery at its entrance into the chest, crosses the arch of the aorta, then passes behind the root of the left lung to the anterior surface of the œsophagus, along which it proceeds to the stomach.

BRANCHES.—At their entrance into the chest they both give off *cardiac branches* (*fig. 44. 14.*) to the cardiac plexuses. The left (*fig. 42. 14.*) while crossing the arch of the aorta, gives off the *left recurrent nerve* which winds around the arch close to the cord of the ductus arteriosus, and ascends by the side of the trachea to be distributed to the larynx.

At the roots of the lungs some branches are distributed upon their anterior aspect, forming the *anterior pulmonary plexuses*, and a larger number behind, constituting by their communications the *posterior pulmonary plexuses*. (*Fig. 44. p.*) The pulmonary plexuses, particularly the anterior, are augmented by branches from the great cardiac plexus. The branches of these plexuses are distributed with the bronchial tubes to the bronchial cells.

On the œsophagus the nerves divide into a number of branches, which communicate with each other and constitute the *œsophageal plexus*. (*Fig. 44. 17.*) Near to the pylorus they collect into two principal trunks, which form a kind of nervous collar around the lower end of the œsophagus, from which branches are distributed to the stomach. The left pneumogastric supplies chiefly the anterior surface of the stomach. The right supplies the posterior surface, and terminates in the solar plexus.

The great splanchnic nerves are derived from the dorsal portion of the sympathetic, with which they are described.

All these parts contained in the posterior mediastinum are held together by a loose cellular tissue, in which are contained a number of lymphatic glands.

The *Sympathetic nerve* (*fig. 78. 14. fig. 115.*) in the chest consists of a chain of ganglia, extending along each side of the vertebral column. The ganglia, twelve in number, rest

upon the heads of the ribs, and are covered by the pleura costalis.

Each ganglion, considered as a centre, gives off four sets of branches—1. to join the ganglion above: 2. to join the ganglion below: 3. to each of the intercostal nerves: 4. to the viscera of the thorax and abdomen. The latter consist of branches to the cardiac and pulmonary plexuses and posterior mediastinum, and of two named branches, the greater and lesser splanchnic nerves.

The *Greater splanchnic nerve* (fig. 115. 12.) is formed by the union of filaments from the sixth, seventh, eighth, ninth, and tenth ganglia. It passes inwards to the posterior mediastinum, resting upon the side of the vertebral column, and pierces the crus of the diaphragm to join the semilunar ganglion in the abdomen.

The *Lesser splanchnic nerve*, 14., is formed by the union of filaments from the tenth and eleventh ganglia. It pierces the diaphragm and joins the renal plexus.

The *Intercostal nerves*, twelve in number, issue from the intervertebral foramina, and divide into two branches:—1. A posterior branch which passes backwards between the ribs, and is distributed to the muscles of the back; 2. An anterior branch (intercostal) which follows the course of the intercostal artery between the two intercostal muscles. It gives off numerous branches in its course, and near to the sternum pierces the external intercostal muscle, to be distributed to the pectoralis major and integument. At the great convexity of the chest it gives off a *cutaneous branch*, which pierces the muscles, and is distributed to the integument on the side of the trunk.

Cardiac ganglion and plexuses.—Beneath the arch of the aorta to the right of the ligament of the ductus arteriosus is a large sympathetic ganglion, the *cardiac ganglion*. It receives the superior cardiac nerve (*superficialis cordis*) from each side, and branches from the pneumogastric and recurrent nerves, and gives off a number of filaments, which form a plexus by their communications—the *anterior cardiac plexus*. The branches of this plexus pass downwards on the right side of the pulmonary artery to the left coronary artery, where they receive the name of *anterior coronary plexus*, and are distributed to the anterior aspect of the heart.

The inferior and middle cardiac nerves converge to the *great cardiac plexus*, which is situated upon the bifurcation of the trachea, behind the arch of the aorta, and above the right pulmonary artery. From this plexus proceed two sets of branches—1. *Anterior*, which pass forwards between the aorta and pulmonary artery, and are distributed principally to the right auricle, communicating with the anterior coronary plexus; 2. *Posterior*, more numerous, which follow the course of the right coronary artery, and form the *posterior coronary plexus*. The branches of this plexus are distributed to the left auricle and posterior surface of the ventricle.

Besides those to the heart, numerous branches are sent from the cardiac plexuses to the pulmonary plexuses, particularly to the anterior.

When these nerves have been examined, the student should apply himself to observe the relations of the large vessels and tubes at the upper part of the thorax. He will find the left vena innominata the most superficial, lying obliquely across the three branches of the arch of the aorta, as it descends to form the superior cava with the vena innominata of the right side. It receives the superior intercostal and inferior thyroid veins.



CHAPTER IX.

THE UPPER EXTREMITY.

THE upper extremity is the member developed from the upper part of the thoracic arch, as the lower extremity is the member developed from the pelvic arch. It consists of an apparatus of bones, joints, muscles, vessels, and nerves, and is covered by the common investments of the entire body, viz. the deep and superficial fascia, and the integument.

The *bones* of the upper extremity are the clavicle, scapula, humerus, radius and ulna, carpal, metacarpal, and phalanges. The *clavicle* is the medium of connexion between the upper extremity and the rest of the skeleton; it is the fulcrum of action of the entire limb, and is prominently characteristic of animals possessing great power in their arms, as man, the bat, the mole, birds, &c. The *scapula* is a flat bone, and

affords by its construction peculiar advantages; giving origin by its extensive surface, to a number of muscles, and being itself moveable on the convexity of the thorax. This is the bone which secures the connexion of the arm to the trunk, and provides for all that diversity of movement so characteristic of the upper extremity, and which entitles it to the designation of a "universal joint." The next bones, the *humerus*, *radius*, and *ulna*, have for their office the extension of the limb, for the purpose of supplying to the beautiful apparatus of the hand all the advantages which are to be obtained by a voluntary approximation or extension from the body. They are, therefore, denominated *long* bones, and like all bones of this class are divisible into a shaft, an upper and a lower extremity. The shaft is more or less cylindrical and smooth, whilst the extremities are projected into processes which serve as levers for the attachment and action of muscles. The *carpus* is an assemblage of small bones belonging to the class of *short* bones. They are all slightly moveable upon each other, and bestow pliancy and strength by means of the mutual yielding which exists between them. The *metacarpal bones* and *phalanges* are *long* bones, of a length proportionate to the arm and to the moving powers which are intended for their action; they give breadth and extent to the hand, and facility in all the movements which that important organ is destined to perform.

The *Muscles* are naturally divided into groups, which concur mutually in certain actions that are obviously necessary to the effective movements of the limb. The distribution of these groups, with their corresponding duties, will be best seen in a tabular analysis, thus:—

Anterior Thoracic Group. *Posterior Thoracic Group.*

Pectoralis major.	Trapezius.
Pectoralis minor.	Levator anguli scapulæ.
Subclavius.	Rhomboideus major.
Serratus magnus.	Rhomboideus minor.

Humeral Group.

Subscapularis.	Latissimus dorsi.
Supra-spinatus.	Pectoralis major.
Infra-spinatus.	Deltoid.
Teres minor.	Coraco-brachialis.
Teres major.	

Anterior Brachial Group. Posterior Brachial Group.

Biceps.

Brachialis anticus.

Triceps.

Anconeus.

FORE-ARM.

Anterior Group

Pronator radii teres.

Pronator radii quadratus.

Flexor carpi radialis.

Flexor carpi ulnaris.

Flexor digitorum sublimis.

Flexor digitorum profundus.

Flexor pollicis longus.

Palmaris longus.

Posterior Group.

Supinator radii longus.

Supinator radii brevis.

Extensor carpi radialis longior.

Extensor carpi radialis brevior.

Extensor carpi ulnaris.

Extensor communis digitorum.

Extensor minimi digiti.

Extensor ossis metacarpi pollicis.

Extensor primi internodii pollicis.

Extensor secundi internodii pollicis

Extensor indicis.

HAND.

Radial Group.

Flexor ossis metacarpi.

Flexor brevis pollicis.

Abductor pollicis.

Adductor pollicis.

Ulnar Group.

Palmaris brevis.

Flexor ossis metacarpi.

Flexor brevis minimi digiti.

Abductor minimi digiti.

Palmar Group.

Lumbricales.

Interossei palmares.

Interossei dorsales.

The *Anterior* and *posterior thoracic groups* preserve the fixity and steadiness of the shoulder, and render it capable of supporting heavy weights and becoming the point of resistance to the actions of the humeral muscles. They also move the scapula freely on the chest, and afford all the advantages of the strongest articulation by bone. The *humeral group* carries the arm throughout all that circle of motion which is so necessary to a universal joint, and so valuable in application to its extensive uses. The muscles of the *anterior brachial group* are the flexors of the elbow, the perfect flexion of the joint being procured by an advantageous attach-

ment to both the radius and ulna. The *posterior brachial group* is the antagonist to the former, and extends the fore-arm. Now, it is fair to anticipate, that as the bones increase in number, and the limb is carried farther from the centre, the movements will increase in proportionate ratio. The movements of the *shoulder* were those of totality: motions of the *scapulo humeral joint* were of the most simple kind, such as would result from the application of a round ball against a shallow socket; those of the *elbow* were in one direction only, flexion and extension; but the *wrist* requires an apparatus for the action of the powerful twist which is so remarkable in that joint. And this is provided for by two pairs of the muscles of the fore-arm, the *pronators* and *supinators*, the former throwing the wrist and hand inwards, the latter outwards. Now this action could not be effectively produced without the exertion of muscular force upon the axis of support to the wrist; and we therefore find that the radius alone articulates with the wrist, and administers to all its movements, while the ulna is reserved as the especial agent in the motions of the elbow. Besides pronation and supination, the wrist possesses powerful flexion and extension, and to this office are assigned the next muscles, *flexores* and *extensores carpi*. The fingers are simply supplied for all their numerous movements of flexion and extension, by three *flexors* situated in the fore-arm, and six *extensors*; one flexor and three extensors being intended for the especial use of the thumb. The remaining muscle, the palmaris longus, is an extensor of the palmar fascia, which provides by its strength and elasticity for a powerful resistance to shocks received upon the surface of the hand. The muscles of the *hand* are, *flexors*, *abductors*, and *adductors*. The short flexors of the thumb and little finger are necessary to the strength of grip so characteristic of the human hand. All the remaining muscles are abductors and adductors (see *fig. 94.*) with the exception of the palmaris brevis, which contracts the integument on the side of the hand, and the lumbricales, which are accessory in their actions to the deep flexor. The abductor and adductor of the thumb are known by those names; the analogous muscle of the index finger are the first dorsal and first palmar interossei; of the middle finger the two next dorsal interossei; of the ring finger the fourth dorsal and second palmar; and of the little finger the abductor minimi digiti

and third palmar interosseus. These movements of abduction and adduction are highly valuable in the grasp of large or irregular bodies, or in the contraction of the bulk of the hand in various important surgical manipulations.

The main *artery* for the supply of the upper extremity commences within the thorax, and, arching over its brim, passes *beneath* the *clavicle*; hence it is named *subclavian*. On quitting the side of the chest, it is received into the space which intervenes between the scapula and ribs, and acquires the name of that space, *axillary*. It then runs along the *arm* to the bend of the elbow, under the name of *brachial*. Now it is an established principle in the distribution of arteries, that they always select the most projected situations for their course. Thus they are constantly placed on the inner side of the limb, and studiously avoid the convexities of joints, where they would be subjected to injury, both from external pressure and over extension. The brachial artery is therefore placed along the inner side of the arm, as is the femoral in the thigh; the brachial dips deeply into the space of the elbow, as does the popliteal into the space of the ham.

Arrived at the bend of the elbow, the brachial artery accommodates itself to the augmented lateral breadth of the fore-arm, and its increased number of components, the *radius*, the *ulna*, and the *intermediate space*, by dividing into three branches corresponding with these three parts, the two bones and the interosseous. Its branches, therefore, are radial, ulna, and interosseus; as in the leg we find the posterior tibial and fibular corresponding with the two bones, and the anterior tibial with the interosseous space.

The *Radial artery* supplies all the parts placed upon the *radial* side of the fore-arm, and passing between the two heads of the first dorsal interosseous muscle, is distributed to the thumb and deep structures in the hand, under the name of the *deep palmar arch*. The *Ulnar* supplies all the parts placed upon the *ulnar* side of the fore-arm, and in the hand forms the *superficial palmar arch*, from which the branches pass off, which are distributed to the fingers.

In the supply of branches, the *muscles* necessarily come in for a large share, which receive no names unless they assume a remarkable magnitude, as the profunda arteries. Other named branches owe their names to peculiarity of structure,

and are, therefore, easily remembered. But the *joints* which are exposed to pressure and are uncovered, except by integument, derive an abundant supply of branches from all the surrounding sources. For instance, the elbow joint is provided with eight nutrient branches, the superior profunda, and its posterior articular branch, inferior profunda, anastomotica magna, radial recurrent, anterior and posterior ulna recurrents, and interosseous recurrent. The knee has seven named branches, the wrist three, and the ankle four.

Thus it may be shown that the principle of arrangement of the arteries, as of the muscles and the rest of the systems, is the same throughout the entire body; the exceptions are individualities that associate objects of importance and interest with their existence.

The *Veins* of the upper extremity are the superficial and the deep: the former are placed between the two layers of the superficial fascia, the latter are associated with the arteries. All the arteries of the limbs and trunk which are below the second magnitude are accompanied by two veins, "*Venæ comites*;" thus the radial, ulnar, interosseous, and brachial arteries, with their branches, have each their corresponding *venæ comites*. The axillary and subclavian have each a single vein.

The *Lymphatic vessels* are rarely seen in an ordinary dissection, excepting under very favourable circumstances, as in anasarca, when they are sometimes observed, as white opaque threads, traversing the transparent jelly like cellular substance, and entering the lymphatic glands at all points of their circumference. They follow in their course the direction of the veins to which they bear a remarkable analogy. The *lymphatic glands* are accumulated in the loose cellular tissue of the axilla, and two or three may be met with in the course of the basilic vein.

The *Nerves* of the upper extremity are derived from the brachial plexus which is formed by the last four cervical and the first dorsal nerves. A *plexus* is the means by which nervous branches destined to a single apparatus are associated in their structure previously to distribution, so that the sensations of each filament may harmonize with all the rest, and produce the unity of impulse which is necessary to perfect action. For it is evident that if an impression were received

by the terminal filament of any one nerve, and excited a reflex movement, without a simultaneous impression upon the other nerves of the same limb and consequent muscular movement, that an opposition of action would result; which is inconsistent with natural and healthy function. We are, therefore, interested in the complex interlacements and union of a number of nerves in the formation of a plexus, when we reflect upon the important benefits which such a disposition confers.

The branches which are given off by the brachial or axillary plexus are, 1st., those distributed to the shoulder and neighbouring part of the chest; and 2d, those destined to the arm. The former are named *thoracic* and *scapular*; the latter consist of six nerves;—one, which supplies the muscles about the shoulder joint, the *circumflex*; two, going to the integument of the arm, *external* and *internal cutaneous*; and three, like the three arteries, supplying the fore-arm and hand, *musculo-spiral*, *ulnar*, and *median*.

Let us now proceed to the *dissection* of the upper extremity.

Dissection.—Make an incision along the line of the clavicle, from the upper part of the sternum to the acromion process; a second along the lower border of the great pectoral muscle, from the lower end of the sternum to the insertion of its tendon into the humerus; and connect the two by a third, carried longitudinally along the middle of the sternum. The integument and superficial fascia are to be dissected off the fibres of the muscle together, and always in the direction of their course. For this purpose the dissector, if he have the right arm, will commence with the lower angle of the flap; if the left, with the upper angle. He will thus expose the pectoralis major muscle in its whole extent.

MUSCLES OF THE SHOULDER AND UPPER ARM.

Anterior Thoracic Region.

Pectoralis major.

Pectoralis minor.

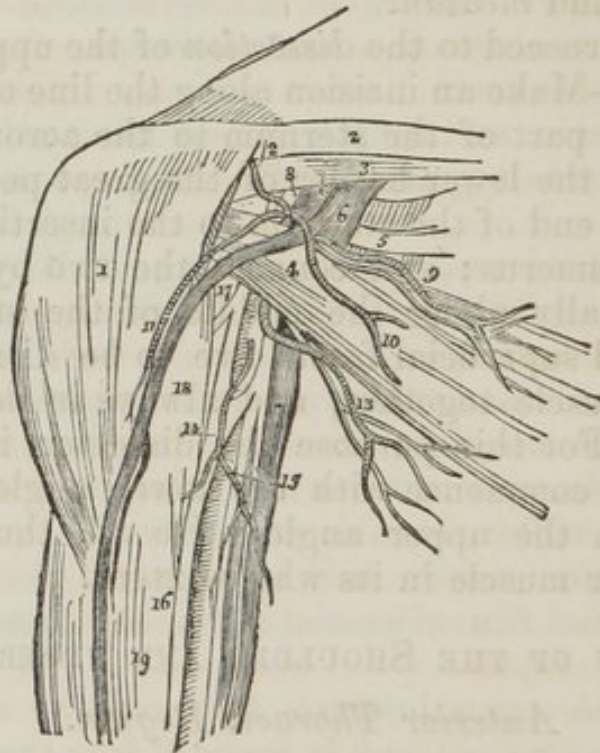
Subclavius.

The *Pectoralis major* muscle arises from the sternal two-thirds of the clavicle, half of the sternum its whole length, and from the cartilages of all the true ribs, excepting the

first. It is *inserted* by a broad tendon into the anterior bicapital ridge of the humerus.

That portion of the muscle which arises from the clavicle, is separated from that connected with the sternum by a distinct cellular interspace; hence we speak of the *clavicular* portion and *sternal* portion of the pectoralis major. The fibres from this very extensive origin converge towards a narrow insertion, giving the muscle a radiated appearance. But there is a peculiarity about the formation of its tendon which must be carefully noted. The whole of the lower border is folded inwards upon the upper portion, so that the tendon is doubled upon itself. Another peculiarity results from this arrangement; the fibres of the upper portion of the muscle are inserted into the lower part of the ridge, and those of the lower portion into the upper part.

Fig. 82. The vessels and nerves of the deep pectoral region.



1. The deltoid muscle. 2. The clavicle. 3. The subclavius muscle, covered in by the costo-coracoid membrane. 4. The pectoralis minor muscle. 5. The triangular space, in which the subclavian artery is tied below the clavicle; and which contains, 6. The subclavian vein. 7. The subclavian artery. 8. The brachial plexus of nerves. 9. The superior thoracic artery and nerve. 10. The thoracic branch of the thoracico-acromialis, artery. 11. The descending branch of the thoracico-acromialis, descending by the side of the cephalic vein. 12. The acromial branch of the thoracico-acromialis. 13. The inferior thoracic artery and nerve.

14. The thoracico-alaris branch of the axillary artery. 15. The internal cutaneous and ulnar nerves resting on the axillary vein. 16. The median nerve embracing the axillary artery, with its two heads. 17. The external cutaneous nerve, piercing the coraco brachialis muscle. 18. The coraco-brachialis. 19. The biceps muscle.

The pectoralis major muscle is separated from the deltoid by a deep cellular interspace, in which are seen the cephalic vein and the descending branch of the thoracico-acromialis artery. (*Fig. 82. 11.*)

Dissection.—The pectoralis major is now to be removed by dividing its fibres along the lower border of the clavicle, and then carrying the incision perpendicularly downwards, parallel to the sternum, and at about three inches from its border. Divide some loose cellular tissue, and several small branches of the thoracic arteries, and reflect the muscle outwards. We thus bring into view a region of considerable interest, from which the fat and cellular tissue must be carefully removed.

In the middle of this region is the pectoralis minor muscle (*fig. 82. 4.*) and above it a triangular space bounded superiorly by the costo-coracoid membrane, 3., which covers in the subclavius muscle, and by the second rib and two adjoining interspaces internally. In this triangular space, 5., are found, the subclavian vein, 6., the subclavian artery, 7., and the brachial plexus of nerves, 8., all resting on the first rib; the acromial thoracic, 10., and superior thoracic arteries, 9., with their veins and nerves, and the cephalic vein, 11. Below the pectoralis minor, the axillary artery is seen embraced by the two heads of the median nerve 16., having to its inner side the axillary vein, and in front the inferior thoracic, 13., and axillary thoracic, 14., branches.

The *Pectoralis minor* arises by three digitations from the third, fourth, and fifth ribs, and is *inserted* into the coracoid process of the scapula.

The *Subclavius* muscle arises by a round tendon from the cartilage of the first rib, and is *inserted* into the under surface of the clavicle. This muscle is concealed by the costo-coracoid membrane, an extension of the deep cervical fascia, by which it is invested.

Lateral Thoracic Region.

Serratus Magnus.

The *Serratus magnus* (serratus, indented like the edge of a saw,) *arises* by fleshy serrations from the nine upper ribs excepting the first, and extends backwards upon the side of the chest, to be *inserted* into the whole length of the base of the scapula. It indigitates by means of its five lower serrations with the obliquus externus abdominis.

Subscapular Region.

Subscapularis.

The *Subscapularis* muscle *arises* from the whole of the under surface of the scapula, excepting the superior angle, and terminates by a broad and thick tendon, which is *inserted* into the lesser tuberosity of the humerus. The tendon of this muscle forms a part of the capsule of the joint, and is lined by its synovial membrane.

Acromial Region.

Deltoid.

The convexity of the shoulder is formed by a large triangular muscle, the *Deltoid* (Δ , delta; εἶδος, resemblance,) which *arises* from the outer third of the clavicle, from the acromion process, and from the whole length of the spine of the scapula. The fibres from this broad origin converge to the middle of the outer side of the humerus, where they are *inserted* into a rough triangular elevation. This muscle is remarkable for its coarse texture, and the combination of tendinous and muscular fibres. The deltoid muscle may now be cut away from its origin, and turned down for the purpose of bringing into view the muscles and tendons placed immediately around the shoulder joint. In so doing, a large bursa will be seen between the under surface of the muscle and the head of the humerus.

BEND OF THE ELBOW.

Before, however, proceeding any farther with the dissection of the shoulder, it would be advisable to study the super-

ficial anatomy of the bend of the elbow. With this view an incision should be made through the integument, along the middle of the biceps muscle, to about three inches below the elbow, and bounded at its extremity by a transverse incision. The integument is next to be dissected carefully back, and a second incision carried in the same direction to divide the external layer of the superficial fascia. This operation must be conducted with care, for a number of superficial nerves and veins occupy this region of the arm; they may be thus arranged:—

Internal cutaneous nerve.
 Intercosto-humeral, or nerve of Wrisberg.
 External cutaneous nerve.
 Spiral cutaneous nerve.
 Posterior ulnar vein.
 Anterior ulnar vein.
 Basilic vein.
 Radial vein.
 Cephalic vein.
 Median vein.
 Median cephalic vein.
 Median basilic vein.

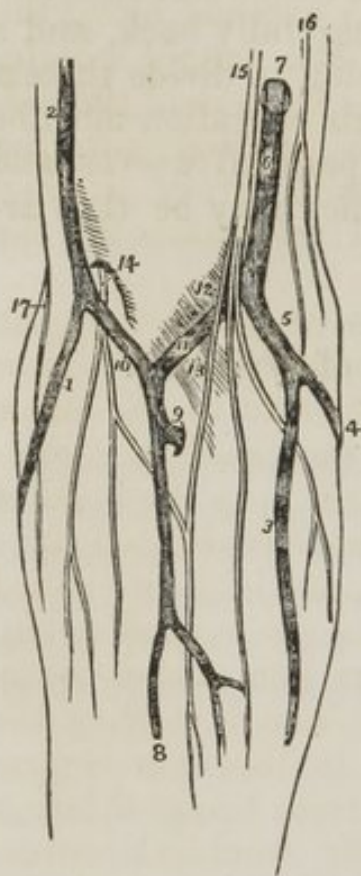The *Internal cutaneous nerve*, (*fig.* 83. 15.) is one of the internal and smallest of the branches of the axillary plexus: it pierces the fascia immediately below the axilla, and runs down the inner side of the upper arm, to the bend of the elbow, where it divides into several branches, which pass *in front* of the median basilic vein, and are distributed to the integument on the inner side of the fore-arm as far as the hand, communicating in their course with the external cutaneous.

The *Intercosto-humeral cutaneous nerves* are the external branches of the first, second, and third intercostal nerves: they pierce the external intercostal muscle, and supply the parts in the axilla and the integument on the inner side of the arm. That from the second intercostal nerve is the longest of the three, and extends as far as the elbow; it is sometimes called the nerve of Wrisberg, 16.

The *External cutaneous nerve*, 14., pierces the deep fascia just above the bend of the elbow, where it emerges from be-

neath the tendon of the biceps. It passes *behind* the median

Fig. 83. The superficial cephalic vein, and divides into several anatomy of the bend of branches, which supply the integument the elbow.



on the outer side of the fore-arm as far as the hand, communicating with the internal cutaneous.

The *Spiral cutaneous nerve*, 17., is a branch of the musculo-spiral: it pierces the deep fascia immediately below the insertion of the deltoid muscle, and runs down the outer side of the fore-arm to the integument of which it is distributed.

Two veins return the blood from the inner side of the hand and fore-arm, the *anterior*, 3., and *posterior ulnar*, 4., veins; the latter commences by the vein of the little finger, *vena salvatella*. They ascend the ulnar border of the fore-arm, one on the anterior surface, the other on the posterior, and near to the elbow unite to form a *common ulnar vein*, 5. At the bend of the elbow, the common ulnar vein is joined by the

median basilic, and the common trunk is called the basilic vein.

1. The radial vein. 2. The cephalic vein. 3. The anterior ulnar vein. 4. The posterior ulnar vein. 5. The common ulnar vein. 6. The basilic vein. 7. The point at which the basilic vein pierces the fascia. 8. The median vein. 9. The communication between the deep veins of the fore-arm and the median. 10. The median cephalic vein. 11. The median basilic vein. 12. A slight convexity of the deep fascia, formed by the brachial artery. 13. The slip of fascia derived from the tendon of the biceps, which separates the median basilic vein from the brachial artery. 14. The external cutaneous nerve, piercing the fascia and dividing into two branches, which pass behind the median cephalic vein. 15. The internal cutaneous nerve dividing into branches, which pass in front of the median basilic vein. 16. The nerve of Wrisburg. 17. The spiral cutaneous nerve, branch of the musculo-spiral nerve.

The *Basilic vein*, 6. (*βασίλικος*, royal, or principal,) runs for a short distance along the inner side of the upper arm, then pierces the fascia, and continues upwards in front of the brachial artery to the axilla, where it becomes the axillary, and afterwards the subclavian vein.

The *Radial* vein (*fig.* 83. 1.,) collects the returning blood from the back of the hand, and runs up the outer side of the fore-arm to the bend of the elbow, where it is joined by the median cephalic, and becomes the cephalic vein.

The *Cephalic* vein, 2. (*κεφαλη*, the head,) ascends along the outer side of the arm, to the insertion of the deltoid muscle, it enters the groove between the adjoining borders of the deltoid and pectoralis major, and gets in relation with the descending branch of the thoracico-acromialis artery. It then crosses the pectoralis minor muscle, and terminates in the subclavian vein.

The *Median* vein, 8., is so named from its position in the middle of the fore-arm. It receives the returning blood from the front of the hand and fore-arm, and near to the elbow forms a trunk of moderate size, which is increased by a communicating branch, 9., from the deep veins. At the bend of the elbow, the median divides into two branches of equal size: one passes inwards to join the basilic vein, and is thence called *median basilic*, 11., the other outwards to the cephalic vein, thence *median cephalic*, 10. The former immediately overlays the brachial artery, being separated from it only by the deep fascia. Hence, in theory, bleeding in this vein is prohibited; in practice it is usually chosen, from being of larger size and more conveniently opened. We would, however, caution the young practitioner, or the unsteady hand, to choose the side of security, even with the prospect of a less elegant operation.

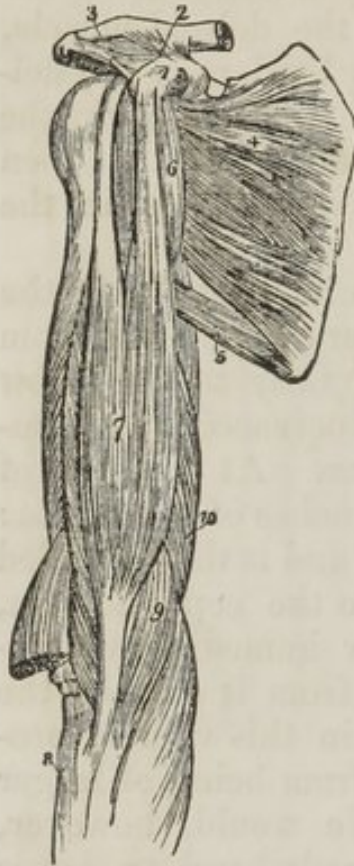Anterior Brachial Region.

The *Deep fascia* of the upper arm may now be dissected back; this will bring into view the muscles of the *anterior brachial region*: these are the Coraco-brachialis, Biceps, Brachialis anticus.

The *Coraco-brachialis*, a name composed of its points of origin and insertion, *arises* from the coracoid process in common with the short head of the biceps, and is *inserted* into a rough line on the inner side of the middle of the humerus.

The *Biceps* (*bi*—*κεφαλη*, two heads) *arises* by two tendons, one the *short head* from the coracoid process in common with the coraco-brachialis; the other the *long head*, from the upper part of the glenoid cavity. The muscle is *inserted* by a rounded tendon into the tubercle of the radius. The long head, a long

slender tendon passes through the capsular ligament of the shoulder-joint enclosed in a sheath of the synovial membrane; after leaving the cavity of the joint it is lodged in the deep groove that separates the two tuberosities of the humerus, the bicipital groove. A small synovial bursa is interposed between the tendon of insertion, and the tubercle of the radius. *At the head of the elbow, the tendon of the biceps gives off from its inner side a narrow tendinous band (fig. 83. 13.,) which protects the brachial artery, and is continuous with the fascia of the fore-arm.*



5. The teres major .6. The coraco-brachialis. 7. The biceps. 8. The upper end of the radius. 9. The brachialis anticus. 10. The internal head of the triceps.

The *Brachialis anticus* muscle arises by two fleshy serrations from the depressions on either side of the insertion of the deltoid, and from the anterior surface of the humerus. Its fibres converge to be *inserted* into the coronoid process of the ulna.

1. The coracoid process of the scapula. 2. The coraco-clavicular ligament (trapezoid,) passing upwards to the scapular end of the clavicle. 3. The coraco-acromial ligament, passing outwards to the acromion. 4. The subscapularis muscle.

Posterior Scapular Region.

We now proceed to examine a group of muscles, situated upon the dorsum of the scapula, the *posterior scapular region*: these are the Supra-spinatus, Infra-spinatus, Teres minor, Teres major.

The *Supra-spinatus* muscle (supra, above; spina, the spine,) arises from the whole of the supra-spinous fossa, and is *inserted* into the uppermost depression on the great tuberosity of the humerus. The tendon of this muscle cannot be well seen without cutting away the acromion process with a saw.

The *Infra-spinatus* (infra, beneath; spina, the spine,) is covered in by a layer of tendinous fascia, which must be re-

moved before the fibres of the muscle can be seen, the deltoid muscle having been previously turned down from its scapular origin. It *arises* from the whole of the infra-spinous fossa, and is *inserted* into the middle depression upon the greater tuberosity of the humerus.

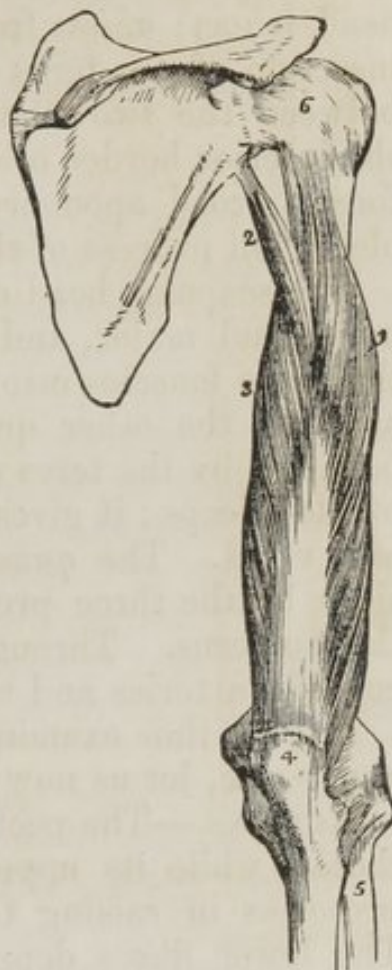The *Teres minor* muscle (teres, round,) *arises* from the middle third of the inferior border of the scapula, and is *inserted* into the lower depression on the great tuberosity of the humerus. The tendons of these three muscles, with that of the subscapularis, are in immediate contact with the joint, and form part of its ligamentous capsule, thereby preserving the solidity of the articulation. They are therefore the structures most frequently ruptured in dislocation of the shoulder-joint with violence.

The *Teres major* muscle *arises* from the lower third of the inferior border of the scapula, encroaching a little upon its dorsal aspect, and is *inserted* in common with the tendon of the latissimus dorsi, into the posterior bicipital ridge.

A large triangular space exists between the two teres muscles, which is divided into two minor spaces by the long head of the triceps.

1. Its external head. 2. Its long, or scapular head. 3. Its internal, or short head. 4. The olecranon process of the ulna. 5. The radius. 6. The capsular ligament of the shoulder-joint.

Fig. 8. A posterior view of the upper arm, showing the triceps muscle.



Posterior Brachial Region.

The remaining region of the shoulder and upper arm is the *posterior brachial*, in which only one muscle is found, the triceps extensor cubiti.

The *Triceps* (tria—κεφαλαι, three heads,) *arises* by three heads. Considered in relation to their length, these heads have been named long, short, and middle, and, in reference to their position, internal, external, and middle; the term

middle, in the former case, referring to the external head, and in the latter case to the long head. This has given rise to much confusion and misunderstanding. We shall, therefore, confine ourselves to the designations derived from their relations. The external head *arises* from the humerus immediately below the insertion of the teres minor. The internal head (short) *arises* from the humerus immediately below the insertion of the teres major. The scapular head (long) lies between the two others, and *arises* from the upper third of the inferior border of the scapula. The three heads unite to form a broad aponeurotic tendon, which is *inserted* into the olecranon process of the ulna.

The scapular head of the triceps passes between the teres minor and major, and divides the triangular space between those two muscles into two smaller spaces, one of which is triangular, the other quadrangular. The *triangular space* is bounded by the teres minor, teres major, and scapular head of the triceps; it gives passage to the dorsalis scapulæ artery and veins. The *quadrangular space* is bounded on three sides by the three preceding muscles, and on the fourth by the humerus. Through this space pass the posterior circumflex arteries and veins and circumflex nerve.

Having thus examined all the muscles of the shoulder and upper arm, let us now inquire into their functions.

ACTIONS.—The pectoralis major draws the arm against the thorax, while its upper fibres assist the upper part of the trapezius in raising the shoulder, as in supporting weights. The lower fibres depress the shoulder with the aid of the latissimus dorsi. Taking its fixed point from the shoulder, the pectoralis major assists the pectoralis minor, subclavius, and serratus magnus, in drawing up and expanding the chest. The pectoralis minor, in addition to this action, draws upon the coracoid process, and assists in rotating the scapula upon the chest. The subclavius draws the clavicle downwards and forwards, and thereby assists in steadying the shoulder. The serratus magnus is the great external inspiratory muscle, raising the ribs when the shoulders are fixed, and thereby increasing the cavity of the chest. Acting upon the scapula, it draws the shoulder forwards, as we see to be the case in diseased lungs, where the chest has become almost fixed from apprehension of the expanding action of the respiratory muscles. The trapezius muscle carries the entire shoulder

upwards and backwards, and is assisted in this action by the levator anguli scapulæ, rhomboideus minor, and rhomboideus major. Acting in the opposite direction, they flex the vertebral column towards the shoulder. The lower fibres of the trapezius unite with the latissimus dorsi, in drawing the shoulder and arm downwards and backwards. When the arms are fixed, as by crutches, or seizing the branch of a tree, the latissimi dorsi muscles lift the entire trunk and carry it forwards.

The supra-spinatus, infra-spinatus, teres minor, and subscapularis, are the circumductur muscles of the arm; they regulate the movements of the head of the humerus against the glenoid cavity. The deltoid is the elevator muscle of the arm in a direct line; and, by means of its extensive origin, can carry the arm forwards or backwards so as to range with the hand a considerable segment of a large circle. The arm, raised by the deltoid, is a good illustration of a lever of the third power, so common in the animal machine, by which velocity is gained at the expense of power. In this lever the weight (hand) is at one extremity, the fulcrum (the glenoid cavity) at the opposite end, and the power (the insertion of the muscle) between the two, but nearer to the fulcrum than the weight.

The muscles of the anterior brachial region are flexors; the coraco-brachialis flexing the humerus on the scapula, and carrying it inwards. The biceps and brachialis anticus flex the fore-arm upon the arm. The former possesses also the additional action of supinating the fore-arm, by means of the obliquity of its insertion into the tuberosity of the radius. The triceps is an extensor of the fore-arm; hence its title, triceps extensor cubiti.

AXILLA.

THE *Axilla* (arm-pit) is the space between the side of the chest and shoulder. In form it resembles a triangular cone, the apex being above at the clavicle, the base below at the lower borders of the pectoralis major and latissimus dorsi. It is bounded in front by the two pectoral muscles; behind, by the subscapularis, teres major, and latissimus dorsi; and,

internally, by the serratus magnus and side of the chest. The axillary space contains the

Axillary artery with its seven branches,
Axillary vein,
Axillary plexus of nerves,
Long thoracic or external respiratory nerve,
Three intercosto-humeral nerves,
Lymphatic glands imbedded in cellular tissue.

AXILLARY ARTERY.

The *Axillary artery* forms a gentle curve through the axillary space from the lower border of the first rib to the lower border of the latissimus dorsi.

The artery is separated from its anterior relations by cellular tissue above, and below by the two heads of the median nerve. The axillary vein lies at first to its inner side, and then gets in front of the artery.

A slight inspection of this artery and its numerous relations, will serve to show that its ligature would be an extremely injudicious and dangerous operation, warranted only by the pressure of extreme circumstances. But the student may be called upon to give the steps of the operation; he must, therefore, reflect upon the position, depth, and relations of the artery. A superficial vessel requires only a short incision, the length increasing with the depth of the artery.

BRANCHES.—The branches of the *Axillary artery* are seven in number :—

Thoracico-acromialis,	Subscapular,
Superior thoracic,	Circumflex anterior,
Inferior thoracic,	Circumflex posterior.
Thoracico-axillaris,	

The thoracico-acromialis and superior thoracic, are found in the triangular space above the pectoralis minor.

The inferior thoracic and thoracico-axillaris, below the pectoralis minor.

And the three remaining branches below the lower border of the subscapularis.

The *Thoracico-acromialis* (*fig. 82.*) is a short trunk that ascends to the space above the pectoralis minor muscle, and divides into three branches,—*thoracic*, 10., which is distributed to the pectoral muscles and mammary gland; *acromial*, 12., passing outwards to the acromion; *descending*, 11., to the

space between the deltoid and pectoralis major that lodges the cephalic vein.

The *Superior thoracic*, 9. (short) runs along the upper border of the pectoralis minor, and is distributed to the pectoral muscles and mammary gland.

The *Inferior thoracic*, 13. (long) runs along the lower border of the pectoralis minor, and is distributed to the pectoral and serratus muscles, and mammary gland.

The *Thoracico-axillaris*, 14., is a small branch distributed to the plexus of nerves and glands in the axilla.

The *Subscapular artery*, the largest of the branches of the axillary, runs along the lower border of the subscapularis muscle, to the inferior angle of the scapula, where it inosculates with the posterior scapular, a branch of the subclavian. It supplies the muscles on the under surface, and inferior border of the scapula, and side of the chest. At about an inch and a half from the axillary, it gives off a large branch, the *dorsalis scapulæ*, which passes backwards through the triangular space bounded by the teres minor, teres major, and scapular head of the triceps, and beneath the infraspinatus to the dorsum of the scapula, where it is distributed, inosculating with the supra-scapular and posterior scapular arteries.

The *Circumflex arteries* wind around the neck of the humerus. The *anterior*, very small, passes beneath the coracobrachialis and short head of the biceps, and sends a branch upwards along the bicipital groove to supply the shoulder-joint.

The *Posterior circumflex*, of larger size, passes backwards through the quadrangular space bounded by the teres minor and major, the scapular head of the triceps and the humerus, and is distributed to the deltoid muscle and joint: sometimes this artery is a branch of the superior profunda of the brachial. It then ascends behind the tendon of the teres major, and is distributed to the deltoid without passing through the quadrangular space.

BRACHIAL ARTERY.

The BRACHIAL ARTERY runs down the inner side of the arm, from the lower border of the latissimus dorsi to the bend of the elbow.

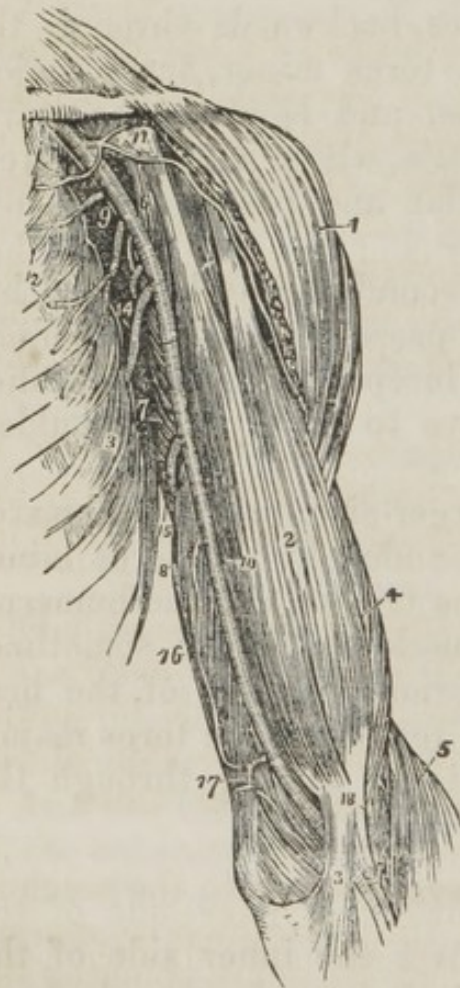RELATIONS.—In its course downwards, it rests upon the coraco-brachialis muscle, internal head of the triceps, and brachialis anticus. To its outer side are the coraco-brachialis and biceps muscles, and in front it has the basilic vein, and is crossed by the median nerve. Its relations, within its sheath, are the venæ comites.

BRACHIAL ARTERY—*Branches* :

Superior profunda—Posterior articular,
Inferior profunda,
Anastomotica magna.

The *Superior profunda* winds around the humerus, between

Fig. 86. The axillary and brachial artery, with their branches.



the triceps and the bone, to the space between the brachialis anticus and supinator longus, where it inosculates with the radial recurrent branch. It accompanies the musculospiral nerve. In its course it supplies the triceps muscle, and gives off one remarkable branch (*posterior articular*) which descends to the joint, and inosculates with the posterior interosseous recurrent branch.

The *Inferior profunda* descends to the space between the inner condyle and olecranon in company with the ulnar nerve, and inosculates with the posterior ulnar recurrent.

The *Anastomotica magna* is given off at right angles from the brachial, at about two inches above the joint. It passes directly inwards, and divides into two branches which inosculate with the anterior ulnar recurrent, and inferior profunda.

1. The deltoid muscle. 2. The biceps. 3. The tendinous process given off from the tendon of the biceps, to the deep fascia of the fore-arm. It is this process which separates the median basilic vein from the brachial artery. 4. The outer border of the brachialis anticus muscle. 5. The supinator longus. 6. The coraco-brachialis. 7. The middle portion of the triceps muscle. 8. Its inner head. 9. The axillary artery. 10. The brachial artery;—a dark line marks the limit between these two vessels. 11. The thoracica acromialis artery dividing into its three branches; the number rests upon the coracoid process. 12. The superior and inferior thoracic arteries. 13. The serratus magnus muscle. 14. The subscapular artery. The posterior circumflex and thoracica axillaris branches are seen in the figure between the inferior thoracic and subscapular. The anterior circumflex is observed, between the two heads of the biceps, crossing the neck of the humerus. 15. The superior profunda artery. 16. The inferior profunda. 17. The anastomotica magna inosculating inferiorly with the anterior ulnar recurrent. 18. The termination of the superior profunda, inosculating with the radial recurrent in the interspace between the brachialis anticus and supinator longus.

AXILLARY PLEXUS.

The *Axillary plexus* of nerves is formed by the communications of the anterior branches of the last four cervical and first dorsal nerves. The plexus is broad in the neck, but narrows as it approaches the axillary artery, lying at first external to that vessel, then getting behind it, and at about the middle of the axilla completely surrounding it. At this point it divides into six ultimate branches. The branches given off from the plexus, previously to its division, are thoracic and scapular.

The *Short thoracic* nerves (*fig.* 82. 9. 13.,) two or three in number, are distributed to the muscles and integument at the upper part of the thorax accompanying the superior and inferior thoracic arteries.

The *Long thoracic* (external respiratory of Bell) is a long branch arising from the fourth and fifth cervical nerves, immediately after their escape from the intervertebral foramina. It passes down behind the plexus and upon the side of the chest, resting on the serratus magnus muscle, to which it is distributed.

The *Supra-scapular* nerve passes backwards to the notch in the superior border of the scapula, through which it emerges into the supra-spinous fossa, supplying the supra-spinatus and neighboring muscles.

The *Subscapular* nerves are three in number; they pass inwards, and supply the subscapularis muscle. One of them, larger than the others, accompanies the subscapular artery, and distributes branches to the adjoining muscles.

The terminal branches of the plexus are arranged in the following order—the external cutaneous, and one head of the median to the outer side of the artery; the other head of the median, internal cutaneous, and ulnar, upon its inner side; and the circumflex and musculo-spiral behind.

The *External cutaneous* nerve (*fig. 82. 17., fig. 83. 14.*) (musculo-cutaneous, perforans Casserii) pierces the coracobrachialis muscle, then passes between the biceps and brachialis anticus, to the outer side of the bend of the elbow, where it perforates the fascia, and divides into branches, which run behind the median cephalic vein, and supply the integument on the outer side of the fore-arm as far as the hand. It communicates on the fore-arm with branches of the internal cutaneous.

The *Median* nerve (*fig. 82. 16.*) is so called, because it runs along the middle of the arm to the palm of the hand, and is, therefore, intermediate in position, between the radial and ulnar nerves. It commences by two heads, which embrace the axillary artery; lies at first to the outer side of the brachial artery, which it crosses at its middle, and descends on its inner side to the bend of the elbow. It then passes between the two heads of the pronator radii teres and flexor sublimis digitorum muscles, and runs down the fore-arm, between the flexor sublimis and profundus, and beneath the annular ligament, to the palm of the hand.

The *Internal cutaneous* nerve (*fig. 83. 15.*) is intended for the supply of the integument, on the inner side of the fore-arm as far as the hand: it has already been described in the superficial anatomy of the bend of the elbow. (See page 321.)

The *Ulnar* nerve runs down the inner side of the arm, to the groove between the internal condyle and olecranon, resting upon the internal head of the triceps, and accompanied by the inferior profunda artery. At the elbow it is superficial, and supported by the inner condyle, against which it is easily compressed, giving rise to the thrilling sensation along the inner side of the fore-arm and little finger, ascribed to striking

the "funny bone." At this point the nerve passes between the two heads of the flexor carpi ulnaris muscle.

If these nerves, together with the brachial artery, be drawn aside, the two posterior branches of the plexus, circumflex and musculo-spiral, are brought into view.

The *Circumflex* nerve passes over the border of the subscapularis muscle, and winds around the neck of the humerus, with the posterior circumflex artery, supplying the deltoid muscle and shoulder-joint.

The *Musculo-spiral* nerve is the largest branch of the plexus: it winds around the humerus in the spiral groove, accompanied by the superior profunda artery, to the space between the brachialis anticus and supinator longus muscles, and thence onwards to the bend of the elbow, where it divides into two branches, the posterior interosseous and radial nerve.

Its *branches* in the upper arm are, 1. *Muscular* to the triceps, hence its designation "musculo;" "spiral" being applied to its course. 2. *Spiral cutaneous* nerve, (*fig.* 83. 17.,) which pierces the deep fascia, between the deltoid and external head of the triceps muscle, and supplies the integument on the outer side of the fore-arm, as far as the wrist. It is described at page 313.

The course of the median, ulnar, and radial nerves in the fore-arm will be described in the next section.

FORE-ARM.

Dissection.—The dissection of the fore-arm has been partially commenced in the examination of the bend of the elbow. It must now be continued by carrying the incision along the middle of the fore-arm and over the wrist to the root of the middle finger, where it may be terminated by a transverse incision made across the heads of the metacarpal bones. The integument is then to be turned to either side. In performing this operation on the ulnar side of the hand, care must be taken to avoid raising the thin layer of muscular fibres which forms the palmaris brevis muscle. An incision is to be carried along the middle of the palmar surface of each of the fingers, and the integument turned aside from these to show the flexor

tendons, and the artery and nerve at either border of the finger.

The superficial fascia is next to be dissected off, and the cutaneous nerves traced downwards between its layers to the hand. The superficial veins may also be cleared of the surrounding fat and cellular tissue.

The *Deep fascia* of the fore-arm is dense and thick, and very different from the thin layer of the upper arm. Towards the inner condyle, it has a muscular connexion, and is strengthened by the band of fascia (*fig. 83. 13.*) derived from the tendon of the biceps. It presents all the general characters of deep fascia; surrounding all the muscles of the fore-arm, being attached to the prominent points of bones, forming sheaths for the numerous muscles, and by its inner surface giving origin to muscular fibres. At the wrist it becomes much thickened, and is attached to the projecting points of the scaphoid and trapezium bones on one side, and to the pisiform and unciform bones on the other, forming the *anterior annular ligament*; posteriorly it forms another band less thick than the anterior. It is attached to the bones by each extremity of the *posterior annular ligament*, and binds down the extensor tendons as they pass forwards to the hand.

In the palm of the hand is a dense tendinous fascia, the *palmar*, which is analogous to the dense layer which we previously examined in the sole of the foot, the plantar fascia. The *Palmar fascia* is narrow towards the wrist, and attached to the annular ligament. Approaching the base of the fingers it becomes broad, and divides into four slips, each of which is subdivided into two smaller slips, which are inserted into the sides of the bases of the first phalanges, giving passage to the flexor tendons. The point of division of these slips is strengthened by a strong interlacement of transverse fibres.

MUSCLES OF THE FORE-ARM.

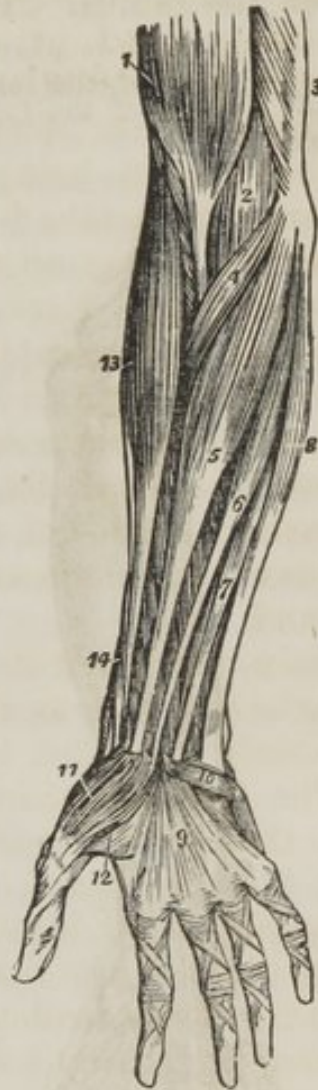The deep fascia of the fore-arm may now be divided and turned aside, and the superficial layer of muscles of the fore-arm examined. There are eight muscles on the anterior aspect of the fore-arm, all *flexors* and *pronators*, five in the superficial layer, and three in the deep. The superficial muscles in their order, from radius to ulna, are

ANTERIOR ASPECT.—*Superficial Group.* Pronator radii teres, Flexor carpi radialis, Palmaris longus, Flexor sublimis digitorum, Flexor carpi ulnaris.

The *Pronator radii teres* arises by two heads, one from the inner condyle of the humerus and fascia of the fore-arm, the other from the coronoid process of the ulna; the median nerve passing between them. Its tendon is *inserted* into the middle third of the oblique ridge of the radius. The two heads of this muscle are best seen, by cutting away that which arises from the inner condyle, and turning it aside. The second head will then be seen with the median nerve lying across it.

The *Flexor carpi radialis* arises from the inner condyle and the sheath of fascia which surrounds it. Its tendon passes through a groove in the scaphoid bone, to be *inserted* into the base of the metacarpal bone of the index finger.

Fig. 87. Superficial layer of muscles of the fore-arm.



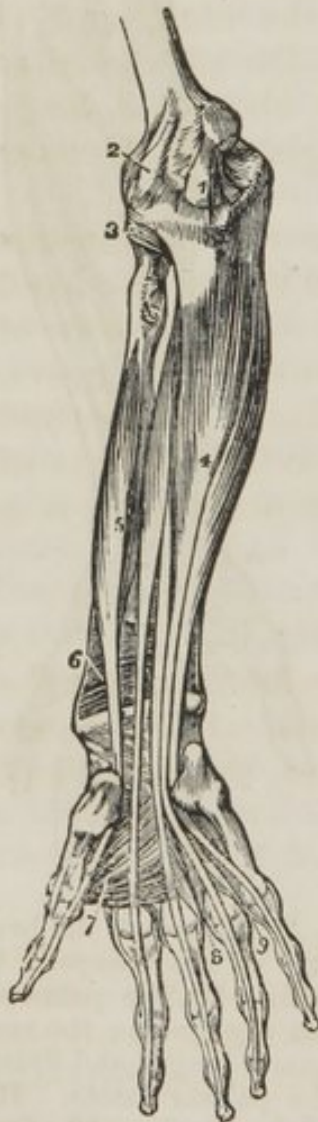1. The lower part of the biceps, with its tendon.
2. A part of the brachialis anticus, seen beneath the biceps.
3. A part of the triceps.
4. The pronator radii teres.
5. The flexor carpi radialis.
6. The palmaris longus.
7. One of the fasciculi of the flexor sublimis digitorum; the rest of the muscle is seen beneath the tendons of the palmaris longus and flexor carpi radialis.
8. The flexor carpi ulnaris.
9. The palmar fascia.
10. The palmaris brevis muscle.
11. The abductor pollicis muscle.
12. One portion of the flexor brevis pollicis; the leading line crosses a part of the abductor pollicis.
13. The supinator longus muscle.
14. The extensor ossis metacarpi, and extensor primi internodii pollicis, curving around the lower border of the fore-arm.

The *Palmaris longus* muscle arises from the inner condyle, and from the sheath of fascia which surrounds it. It is inserted into the palmar fascia.

Cut the flexor carpi radialis and palmaris longus from their origins, in order to obtain a good view of the whole extent of origin of the flexor sublimis digitorum.

The *Flexor sublimis digitorum* (perforatus) arises from the inner condyle, coronoid process of the ulna, and oblique line of the radius. The median nerve and ulnar artery pass between its origins. It divides into four

Fig. 88. The deep layer of muscles of the forearm.



tendons, which are inserted into the base of the second phalanges of the fingers, splitting at their terminations to give passage to the tendons of the deep flexors; thence its designation *perforatus*.

The *Flexor carpi ulnaris* arises by two heads, one from the inner condyle, the other from the olecranon and two thirds of the inner border of the ulna. The ulnar nerve passes between its two heads. Its tendon is inserted into the pisiform bone.

Remove the flexor sublimis, and draw the pronator teres upwards with hooks, the deep layer will then be exposed: it consists of the

Deep Group.—Flexor profundus digitorum, flexor longus pollicis, pronator quadratus.

The *Flexor profundus digitorum* (perforans) arises from the upper two-thirds of the ulnar and part of the interosseous membrane, and terminates in four tendons, which pass beneath the annular ligament, and between the two slips of the flexor sublimis, (hence its designation *perforans*,) to be inserted into the base of the last phalanges.

Four little muscular fasciculi, called

1. The internal lateral ligament of the elbow-joint. 2. The anterior ligament. 3. The orbicular ligament of the head of the radius. 4. The flexor profundus digitorum muscle. 5. The flexor longus pollicis. 6. The pronator quadratus. 7. The abductor pollicis muscle. 8. The dorsal in-

terosseous muscle of the middle finger, and palmar interosseous of the ring-finger. 9. The dorsal interosseous muscle of the ring-finger, and palmar interosseous of the little finger.

lumbricales, are connected with the tendons of this muscle in the hand,

They will be described with the muscles of the hand.

The *Flexor longus pollicis* arises from the upper two-thirds of the radius, and part of the interosseous membrane. Its tendon passes beneath the annular ligament to be *inserted* into the base of the last phalanx of the thumb.

If the tendons of the last two muscles be drawn aside or divided, the third muscle of this group will be brought into view, lying across the lower part of the two bones.

The *Pronator quadratus* arises from the ulna, and is *inserted* into the lower fourth of the oblique line on the outer side of the radius. This muscle occupies about the lower fourth of the two bones, is broad at its origin, and narrower at its insertion.

ACTIONS.—The pronator radii teres and pronator quadratus muscles rotate the radius upon the ulnar, and render the hand prone. The remaining muscles are flexors:—two flexors of the wrist, flexor carpi radialis and ulnaris: two of the fingers, flexor sublimis and profundus, the former flexing the second phalanx, the latter the last; one flexor of the last phalanx of the thumb, flexor longus pollicis. The palmaris longus is a tensor of the palmar fascia.

ARTERIES OF THE FORE-ARM.

The *Arteries* on the anterior aspect of the fore-arm are the radial, ulnar, and interosseous. The brachial artery at the bend of the elbow divides into two branches, the radial and ulnar.

RADIAL ARTERY.

The *Radial artery* runs along the radial side of the fore-arm, from the bend of the elbow to the wrist; it there turns around the base of the thumb, beneath its extensor tendons, and passes between the two heads of the first dorsal interosseous muscle, into the palm of the hand. It then crosses the metacarpal bones to the ulna side of the hand, forming the deep *palmar arch*, and terminates by inosculating with the superficial palmar arch.

In the upper half of its course, the radial artery is situated between the supinator longus muscle, and pronator radii tere in the lower half between the tendons of the supinator longus, and flexor carpi radialis. It rests in its course downwards, upon the insertions of the supinator brevis, and pronator radii teres, radial origin of the flexor sublimis, flexor longus pollicis, and pronator quadratus, and is covered in by the integument and fasciæ.

The *Branches* of the *Radial artery* may be arranged into four groups :—

<i>Elbow</i>	- -	Recurrent radial.
<i>Fore-arm</i>	-	Muscular branches.
		{ Superficialis volæ.
		{ Carpalis anterior.
<i>Wrist</i>	-	{ Carpalis posterior.
		{ Metacarpalis.
		{ Dorsales pollicis.
		{ Princeps pollicis.
<i>Hand</i>	-	{ Radialis indicis.
		{ Interosseæ.
		{ Perforantes.

The *Recurrent* branch turns upward in the space between the supinator longus and brachialis anticus to supply the structures about the joint. It inosculates with the superior profunda artery

The *Muscular branches*, as in every other part of the body, supply the muscles adjacent to the artery.

The *Superficialis volæ* is given off from the radial artery while at the wrist. It passes between the fibres of the abductor pollicis muscle, and inosculates with the termination of the ulnar artery, completing the superficial palmar arch.

The *Carpal* branches are intended for the supply of the wrist, the anterior carpal in front, and the posterior, the larger of the two, behind.

The *Metacarpal* branch runs forwards on the second dorsal interosseous muscle, and is distributed to the adjoining sides of the index and middle fingers. Sometimes it is of very large size.

The *Dorsales pollicis* are two small branches, running along the sides of the dorsal aspect of the thumb.

The *Princeps pollicis* descends along the border of the

metacarpal bone, between the abductor indicis and abductor pollicis to the base of the first phalanx, where it divides into two branches, which are distributed to the two sides of the palmar aspect of the thumb.

The *Radialis indicis* is also situated between the abductor indicis and abductor pollicis, and runs along the radial side of the index finger, forming its collateral artery.

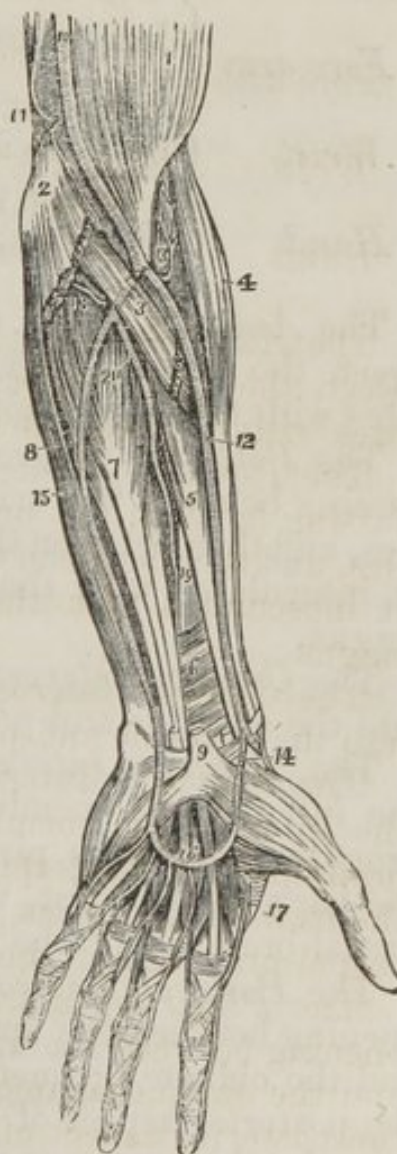
The *interossee* and *perforantes* are branches of the deep palmar arch, the former supplying the interosseous muscles, the latter passing between the two heads of the dorsal interossei, to inosculate with the carpal and metacarpal branches.

1. The lower part of the biceps muscle.
2. The inner condyle of the humerus with the humeral origin of the pronator radii teres and flexor carpi radialis divided across.
3. The deep portion of the pronator radii teres.
4. The supinator longus muscle.
5. The flexor longus pollicis.
6. The pronator quadratus.
7. The flexor profundus digitorum.
8. The flexor carpi ulnaris.
9. The annular ligament with the tendons passing beneath it into the palm of the hand; the figure is placed on the tendon of the palmaris longus muscle divided close to its insertion.
10. The brachial artery.
11. The anastomotica magna inosculating superiorly with the inferior profunda, and inferiorly with the anterior ulnar recurrent.
12. The radial artery.
13. The radial recurrent artery inosculating with the termination of the superior profunda.
14. The superficialis volæ.
15. The ulnar artery.
16. Its superficial palmar arch giving off digital branches to three fingers and a half.
17. The magna pollicis and radialis indicis arteries.
18. The posterior ulnar recurrent.
19. The anterior interosseous artery.
20. The posterior interosseous, as it is passing through the interosseous membrane.

ULNAR ARTERY.

The *Ulnar artery* crosses the arm obliquely to the commencement of its middle third, it then runs down the ulnar side of the fore-arm to the wrist, crosses the annular ligament, and forms the superficial palmar

Fig. 79. The arteries of the fore-arm.



arch, which terminates by inosculating with the superficialis volæ.

RELATIONS.—In the upper or oblique portion of its course, it lies between the superficial and deep layers of muscles of the fore-arm. In the second part of its course, it is placed between the flexor carpi ulnaris, and flexor sublimis digitorum. While crossing the annular ligament, it is protected from injury by a strong tendinous arch, thrown over it from the pisiform bone; and in the palm it rests upon the tendons of the flexor sublimis, being covered in by the palmar fascia.

The *Branches* of the *Ulnar artery* may be arranged into four groups:—

<i>Elbow</i>	{	Anterior ulnar recurrent.
	{	Posterior ulnar recurrent.
<i>Fore-arm</i>	{	Interosseous {
		{ Ant. inteross.
		{ Post. inteross.—recurrent.
	{	Muscular
<i>Wrist</i>	{	Carpalis anterior.
	{	Carpalis posterior.
<i>Hand</i>		Digitales, <i>four</i> .

The *Anterior ulnar recurrent* returns upon the elbow, between the pronator teres and brachialis anticus and inosculates with the anastomotica magna.

The *Posterior ulnar recurrent* returns upon the elbow, by passing beneath the origins of the superficial layer of muscles, and then between the two heads of the flexor carpi ulnaris. It inosculates with the inferior profunda and anastomotica magna.

The *Common interosseous* is a short trunk, which divides into the anterior and posterior interosseous arteries.

The *Anterior interosseous* runs down the fore-arm upon the interosseous membrane, and at the upper border of the pronator quadratus pierces that membrane, and descends to the back of the wrist, where it inosculates with the posterior carpal branches of the radial and ulnar.

The *Posterior interosseous* artery passes back through an opening between the upper part of the interosseous membrane and the oblique ligament, and is distributed to the muscles on the posterior aspect of the fore-arm. It gives off a *recurrent branch*, which returns upon the elbow beneath the anconeus

muscle, and anastomoses with the posterior articular branch of the superior profunda.

The *Muscular branches* supply the muscles situated on the ulnar border of the fore-arm.

The *Carpal branches, anterior and posterior*, are distributed to the anterior and posterior aspects of the wrist joint. The posterior is the largest.

The *Digital branches* supply the collateral branches to the little, ring, and middle fingers, and the ulnar side of the index finger.

The *Superficial palmar arch* receives the termination of the deep arch, near to the carpal extremity of the little finger, and terminates in the superficialis volæ, upon the ball of the thumb.

NERVES OF THE FORE-ARM.

The *Nerves* of the fore-arm are the cutaneous, the median, ulnar, radial, and posterior interosseous. The cutaneous nerves, derived from the external cutaneous, internal cutaneous and spiral cutaneous, have been already described. (See pages 319, 320.)

MEDIAN NERVE.

The *Median nerve* runs down the anterior aspect of the fore-arm, from the bend of the elbow to the hand, where it divides into its five terminal branches.

RELATIONS.—At the bend of the elbow, it passes between the two heads of the pronator radii teres and flexor sublimis digitorum muscles.

In the fore-arm, it lies between the flexor sublimis and profundus, and at the wrist it passes with the tendons of these two muscles beneath the annular ligament into the palm of the hand.

BRANCHES.—The branches of the median nerve may be arranged in two groups, there being none given off in the upper arm.

<i>Fore-arm</i>	{	Muscular.
	{	Anterior interosseous.
<i>Hand</i>	{	Superficial palmar.
	{	Five digital.

The *Muscular branches* are distributed to the muscles on the anterior aspect of the fore-arm.

The *Anterior interosseous* is a large branch, accompanying the anterior interosseous artery, and supplying the deep layer of muscles in the fore-arm. It passes beneath the pronator quadratus muscle, and pierces the interosseous membrane near to the wrist. On reaching the posterior aspect of the wrist, it joins a large and remarkable ganglion, which gives off a number of branches for the supply of the joint.

The *Superficial palmar branch* arises from the median nerve immediately above the annular ligament, and is distributed to the integument in the palm of the hand.

The *Digital branches* are five in number; two pass outwards to the thumb; one to the radial side of the index finger; one subdivides for the supply of the adjoining sides of the index and middle fingers; and the remaining one, for the supply of the adjoining sides of the middle and ring fingers.

ULNAR NERVE.

The *Ulnar nerve* runs along the ulnar side of the fore-arm to the wrist, crosses the annular ligament with the ulnar artery, and divides into two branches, superficial and deep palmar.

RELATIONS.—At the elbow the nerve lies in the groove between the inner condyle of the humerus and olecranon, and between the two heads of the flexor carpi ulnaris muscle. At the commencement of the middle third of the fore-arm, it becomes applied against the artery, and lies to its ulnar side, as far as the hand.

BRANCHES.—The branches of the ulnar nerve may be arranged into four groups:—

<i>Upper arm</i>	-	To the triceps muscle.
<i>Fore-arm</i>	-	Muscular.
<i>Dorsum of hand</i>		Dorsal branch.
<i>Palm of hand</i>	{	Superficial palmar.
	{	Deep palmar.

A few filaments are given to the short head of the triceps.

The *Muscular branches* supply the muscles on the ulnar side of the fore-arm.

The *Dorsal branch* passes beneath the tendon of the flexor carpi ulnaris, at the lower third of the fore-arm, and divides into branches which supply two fingers and a half on the posterior aspect of the hand, and communicate with the radial nerve.

The *Superficial palmar* branch divides into four filaments, which are distributed to the ulnar border of the hand, to the ulnar side of the little finger, to the adjoining borders of the little and ring fingers, and a communicating branch is sent to join the median nerve.

The *Deep palmar* branch passes between the abductor and flexor minimi digiti, to the deep palmar arch, supplying all the deep parts in the palm of the hand.

MUSCULO-SPIRAL NERVE.

The *Musculo-spiral* nerve, at the bend of the elbow, divides into two branches of nearly equal size, the radial and posterior interosseous.

The *Radial* runs along the radial side of the fore-arm to the commencement of its lower third; it then passes beneath the tendon of the supinator longus to the back of the wrist and hand, where it supplies two fingers and a half, and communicates with the dorsal branch of the ulnar nerve. It gives off a few branches to the muscles on the radial side of the fore-arm.

RELATIONS.—In the upper third of the fore-arm it lies beneath the border of the supinator longus muscle. In the middle third it is in relation with the radial artery, lying to its outer side. It then quits the artery, and passes beneath the tendon of the supinator longus, to reach the back of the hand.

The *Posterior interosseous* nerve separates from the radial at the bend of the elbow, pierces the supinator brevis muscle, and emerges from its lower border on the posterior aspect of the fore-arm, where it divides into branches which supply the whole of the muscles on the posterior aspect of the fore-arm. One branch, longer than the rest, descends to the posterior part of the wrist-joint, where it forms a large gangliform swelling (the common character of nerves which supply joints,)

from which numerous branches are distributed to the wrist joint.

The *branches* of the *Musculo-spiral* nerve may be thus arranged:—

<i>Upper-arm</i>	{	Muscular, Spiral cutaneous.
<i>Fore-arm</i>	{	Radial, Posterior interosseous.

If we make an analysis of the supply of nerves to the muscles of the upper extremity, from the various sources above described, we shall find them disposed according to the following arrangement:—

Deltoid muscle—Circumflex nerve.

<i>Upper-arm</i>	{	<i>front</i> —External cutaneous. <i>back</i> —Musculo-spiral.
<i>Fore-arm</i>	{	<i>front</i> —Median, ulnar, and radial. <i>back</i> —Radial and posterior interosseous.
<i>Hand</i>	{	<i>front</i> —Median and ulnar. <i>back</i> —Radial and ulnar.

POSTERIOR REGION OF THE FORE-ARM.

No new dissection is required for this region: the integument already thrown back from the anterior region is now to be removed altogether, and with it the superficial fascia: in this proceeding the posterior ulnar vein may be seen throughout its course, taking its origin inferiorly from the vein of the little finger, "*vena salvatella*." On the radial side, the radial vein may be observed commencing by the veins on the back of the hand, and winding around the radial border of the fore-arm to the bend of the elbow. The posterior branches of the internal cutaneous nerve are distributed along the course of the posterior ulnar vein, and the external cutaneous and spiral cutaneous, on the radial border of the fore-arm. At the lower third of the fore-arm, the radial nerve is seen piercing the fascia, to reach the back part of the hand; and, just above the wrist, the dorsal branch of the ulnar emerges from the fascia to the same destination. On removing the deep fascia, the superficial layer of muscles is brought into view.

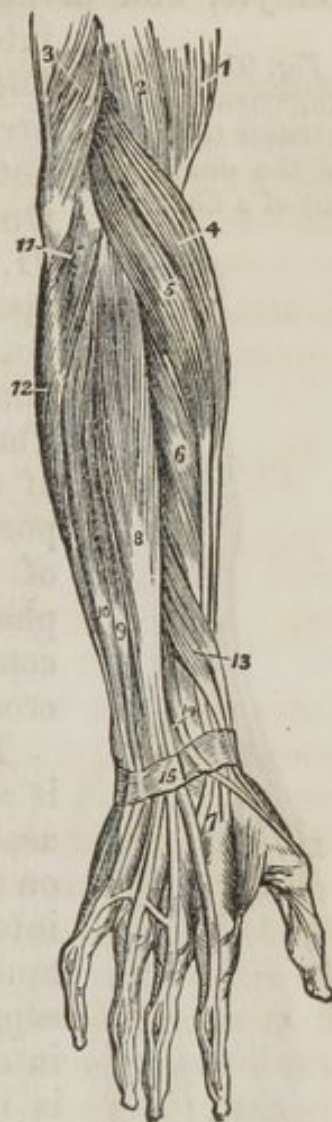The *Supinator longus* muscle is placed along the radial border of the fore-arm. It *arises* from the external condyloid ridge of the humerus, nearly as high as the insertion of the deltoid, and is *inserted* into the base of the styloid process of the radius.

This muscle must be divided through the middle, and the two ends turned to either side to expose the next muscle.

The *Extensor carpi radialis longior* *arises* from the external condyloid ridge below the preceding. Its tendon passes through a groove in the radius, immediately behind the styloid process, to be inserted into the base of the metacarpal bone of the index finger.

The *Extensor carpi radialis brevior* is seen by drawing aside the former muscle. It *arises* from the external condyle of the humerus, and is *inserted* into the base of the metacarpal bone of the middle finger. Its tendon is lodged in the same groove of the radius with the extensor carpi radialis longior.

Fig. 90. The superficial layer of muscles of the posterior aspect of the fore-arm.



1. The lower part of the biceps.
2. Part of the brachialis anticus.
3. The lower part of the triceps, inserted into the olecranon.
4. The supinator longus.
5. The extensor carpi radialis longior.
6. The extensor carpi radialis brevior.
7. The tendons of insertion of these two muscles.
8. The extensor communis digitorum.
9. The extensor minimi digiti.
10. The extensor carpi ulnaris.
11. The anconeus.
12. Part of the flexor carpi ulnaris.
13. The extensor ossis metacarpi and extensor primi internodii muscle, lying together.
14. The extensor secundi internodii; its tendon is seen crossing the two tendons of the extensor carpi radialis longior and brevior.
15. The posterior annular ligament. The tendons of the common extensor are seen upon the back of the hand, and their mode of distribution on the dorsum of the fingers.

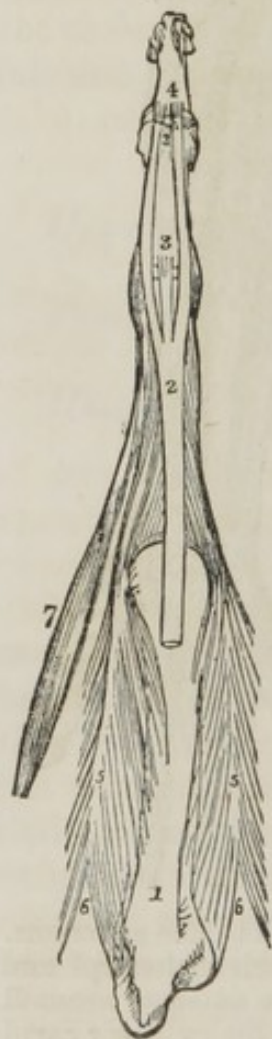POSTERIOR ASPECT.—*Superficial Layer:*

Supinator longus,
 Extensor carpi radialis longior,
 ———— carpi radialis brevior,

Extensor communis digitorum,
 ———— minimi digiti,
 ———— carpi ulnaris,
 Anconeus,

The *Extensor communis digitorum* arises from the external condyle, and divides into four tendons, which are inserted

Fig. 91. The arrangement of the extensor tendon upon the dorsal surface of a finger.



into the second and third phalanges of the fingers. The same peculiarities exist in the arrangement of these tendons as was before noticed in the extensor tendons of the foot. Opposite the first phalanx, the tendon (fig. 91. 2.) spreads out so as to form a broad aponeurosis, which covers the whole of the posterior aspect of the finger. At the first joint the aponeurosis divides into three slips. The middle slip, 3., is inserted into the base of the second phalanx, and the two lateral portions are continued onwards on each side of the joint, to be inserted into the last phalanx, 4. Little oblique tendinous slips connect the tendons of this muscle as they cross the back of the hand.

The *Extensor minimi digiti* (auricularis) is an off-set from the extensor communis. It assists in forming the tendinous expansion on the back of the little finger, and is inserted into the last two phalanges. It is to this muscle that the little finger owes its power of separate extension, and from being called into action when the point of the little finger is introduced into the meatus of the ear for the purpose of removing unpleasant sensations, or producing titillation: the muscle was called by the older writers "auricularis."

1. The metacarpal bone of the middle finger. 2. The extensor tendon expanding into a broad aponeurosis, which divides into three slips. 3. The middle slip, inserted into the base of the second phalanx. 4. The two lateral slips, inserted into the base of the third phalanx. 5. 5. Two dorsal interossei, showing their bifid origin, 6. 6., and inserted by an aponeurotic expansion into the sides of the extensor tendon. 7. The second lumbrical muscle, also inserted into the side of the extensor tendon.

The *Extensor carpi ulnaris* arises from the external con-

dyle and the upper two-thirds of the border of the ulna. Its tendon passes through the posterior groove in the ulna, to be *inserted* into the base of the metacarpal bone of the little finger.

The *Anconeus* arises from the outer condyle, and is *inserted* into the olecranon and triangular surface on the upper extremity of the ulna.

When these muscles have been examined, the extensor communis digitorum and extensor minimi digiti should be removed, and the extensor carpi ulnaris drawn aside, to bring into view the deep layer, which consists of five muscles.

Deep Layer.

Supinator brevis,
Extensor ossis metacarpi pollicis,
——— primi internodii pollicis,
——— secundi internodii pollicis,
——— indicis.

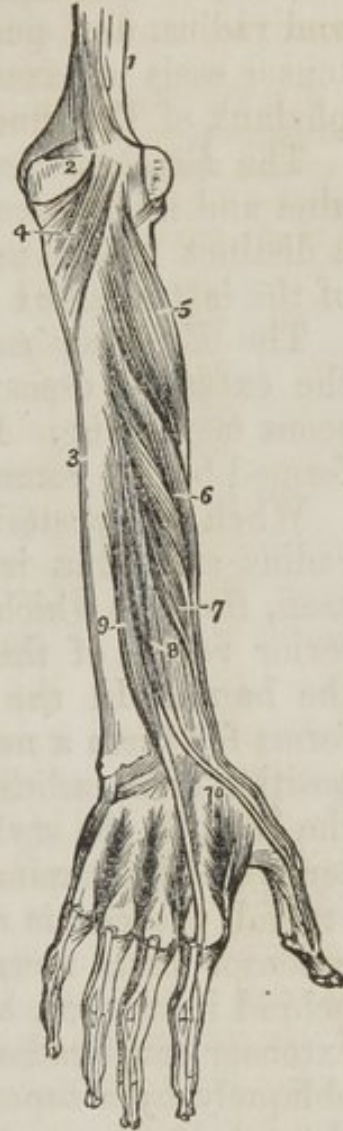The *Supinator brevis* cannot be seen in its entire extent, until the radial extensors of the carpus are divided from their origin. It *arises* from the external condyle and external lateral ligament, and winds around the upper part of the radius to be *inserted* into the upper third of its oblique line. The posterior

1. The lower part of the humerus. 2. The olecranon. 3. The ulna, 4. The anconeus muscle. 5. The supinator brevis muscle. 6. The extensor ossis metacarpi pollicis. 7. The extensor primi internodii pollicis. 8. The extensor secundi internodii pollicis. 9. The extensor indicis. 10. The first dorsal interosseous muscle. The other three dorsal interossei are seen between the metacarpal bones of their respective fingers.

interosseous artery and nerve are seen perforating the lower border of this muscle.

The *Extensor ossis metacarpi pollicis* is placed immediately below the supinator brevis. It *arises* from the ulna, interosseous membrane, and radius, and is *inserted*, as its name implies,

Fig. 92. The deep layer of muscles on the posterior aspect of the fore-arm.



into the base of the metacarpal bone of the thumb. Its tendon passes through the groove immediately in front of the styloid process of the radius.

The *Extensor primi internodii pollicis*, the smallest of the muscles in this layer, arises from the interosseous membrane and radius, and passes through the same groove with the extensor ossis metacarpi, to be inserted into the base of the first phalanx of the thumb.

The *Extensor secundi internodii pollicis* arises from the ulna and interosseous membrane. Its tendon passes through a distinct groove in the radius, and is inserted into the base of the last phalanx of the thumb.

The *Extensor indicis* arises from the ulna as high up as the extensor ossis metacarpi pollicis, and from the interosseous membrane. Its tendon is inserted into the aponeurosis formed by the common extensor tendon of the index finger.

When the posterior surface of the lower extremities of the radius and ulna is examined, a number of grooves will be seen, through which the tendons of the muscles of the posterior region of the fore-arm pass to their destination upon the hand. In the subject, the posterior annular ligament forms for them a number of distinct sheaths. Their relative position from radius to ulna must be attentively studied. Into the base of the styloid process of the radius is inserted the tendon of the supinator longus. Immediately in front of the styloid process, is a groove which lodges the tendons of the extensor ossis metacarpi and primi internodii; immediately behind it another, broad and shallow, for the tendons of the extensor carpi radialis longior and brevior, which are crossed obliquely by a superficial sheath in the annular ligament for the extensor secundi internodii. Farther inwards is a small groove for the tendon of the extensor indicis, and a large one for the extensor communis. Upon the ulna is a groove for the extensor minimi digiti and extensor carpi ulnaris. They may be thus arranged in a tabular form:—

{ Extensor ossis metacarpi,
 { ———— primi internodii.

Styloid process, the insertion of the
 tendon of the supinator longus.

{ Extensor secundi internodii,
 { ———— carpi radialis longior,
 { ———— carpi radialis brevior.

Extensor indicis.

{ Extensor communis digitorum,
 ———— minimi digiti,
 ———— carpi ulnaris.

ACTIONS.—The anconeus is associated in its action with the triceps extensor cubiti: it assists in extending the fore-arm upon the arm. The supinator longus and brevis effect the supination of the fore-arm, and antagonize the two pronators. The extensores carpi radialis, longior, and brevior, and ulnaris, extend the wrist in opposition to the two flexors or the carpus. The extensor communis digitorum restores the fingers to the straight position, after being flexed by the two flexors, sublimis and profundus. The extensor ossis metacarpi, primi internodii, and secundi internodii pollicis, are the especial extensors of the thumb, and serve to balance the actions of the flexor ossis metacarpi, flexor brevis, and flexor longus pollicis. The extensor indicis gives the character of extension to the index finger, and is hence named indicator, and the extensor minimi digiti supplies that finger with the power of exercising a distinct extension.

PALMAR REGION.

The *Muscles of the hand* are arranged in three groups: a radial group belonging to the thumb; an ulnar group to the little finger; and a palmar group situated in the middle of the palm of the hand.

The muscles of the *Radial group* are the

Abductor pollicis,
 Flexor ossis metacarpi (opponens,)
 Flexor brevis pollicis,
 Abductor pollicis.

The *Abductor pollicis* arises from the scaphoid bone and annular ligament. It is *inserted* into the base of the first phalanx.

Cut this muscle from its origin, and turn it upwards; you will then see

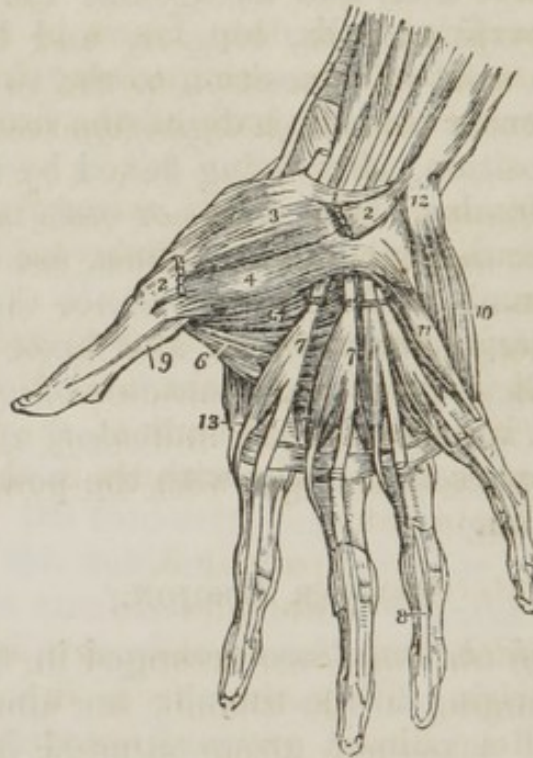
The *Flexor ossis metacarpi* (opponens;) it *arises* from the trapezium and annular ligament, and is *inserted* into the whole length of the metacarpal bone.

The flexor ossis metacarpi may now be divided from its origin and turned aside, in order to show the next muscle.

The *Flexor brevis pollicis* consists of two portions, between

which lies the tendon of the flexor longus pollicis. The external portion *arises* from the trapezium and annular ligament; the internal portion from the trapezoides and os magnum. They are both *inserted* into the base of the first phalanx of the thumb, having a sesamoid bone in each of their tendons to protect the joint.

Fig. 93.



1. The annular ligament. 2. 2. The origin and insertion of the abductor pollicis muscle; the middle portion has been removed. 3. The flexor ossis metacarpi, or opponens pollicis. 4. One portion of the flexor brevis pollicis. 5. The deep portion of the flexor brevis pollicis. 6. The adductor pollicis. 7. 7. The lumbricales muscles, arising from the deep flexor tendons, upon which the numbers are placed. The tendons of the flexor sublimis have been removed from the palm of the hand. 8. One of the tendons of the deep flexors passing between the two terminal slips of the tendon of the flexor sublimis to reach the last phalanx. 9. The tendon of the flexor longus pollicis, passing between the two portions of the flexor brevis to the last phalanx. 10. The abductor minimi digiti. 11. The flexor brevis minimi digiti. The edge of the flexor ossis metacarpi, or adductor minimi digiti, is seen projecting beyond the inner border of the flexor brevis. 12. The prominence of the pisiform bone. 13. The first dorsal interosseous muscle.

The *Adductor pollicis* is a triangular muscle; it *arises* from the os magnum and metacarpal bone of the middle finger; the fibres converge to its *insertion* into the base of the first phalanx.

Ulnar group. The muscles of the little finger are the
Abductor minimi digiti,

Flexor brevis minimi digiti,
Flexor ossis metacarpi (adductor).

On removing the integument from the ball of the little finger, a thin layer of muscular fibres is found between the two layers of superficial fascia. This is the *Palmaris brevis*. Its fibres *arise* from the palmar fascia, and pass transversely inwards to be *inserted* into the integument on the inner border of the hand.

When the superficial and deep fascia is removed, the *Abductor minimi digiti* will be seen *arising* from the pisiform bone. It is *inserted* into the base of the first phalanx of the little finger.

The *Flexor brevis minimi digiti* *arises* from the unciform bone and annular ligament, and is *inserted* into the base of the first phalanx.

The *Flexor ossis metacarpi* (adductor,) *arises* from the unciform bone and annular ligament, and is *inserted* into the whole length of the metacarpal bone of the little finger.

Middle palmar region.—The muscles in this region are the Lumbricales,

Interossei { palmar 3.
 dorsal 4.

The *Lumbricales*, four in number, are accessories to the deep flexor muscles. They *arise* from the radial side of the tendons of the deep flexor, and are *inserted* into the aponeurotic expansion of the extensor tendons (*fig.* 91. 7.) on the radial side of the fingers.

The *Palmar interossei*, three in number, are placed upon the metacarpal bones, rather than between them. They *arise* from the base of the metacarpal bone of one finger, and are *inserted* into the base of the first phalanx and aponeurotic expansion of the extensor tendon of the same finger. The first (*fig.* 94. 4.) belongs to the index finger; the second, 6., to the ring finger; and the third, 8, to the little finger. The middle finger being excluded.

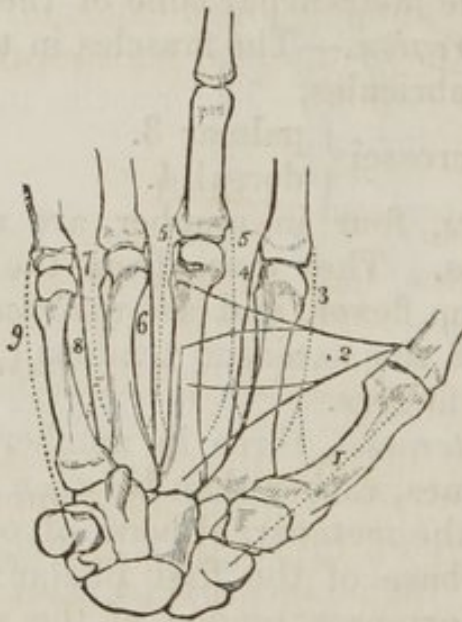
On turning to the dorsum of the hand, the four *dorsal interossei* are seen in the four spaces between the metacarpal bones. They are bipenniform muscles, (*fig.* 91. 5. 5.,) and *arise* by two heads, 6. 6., from the adjoining sides of the base of the metacarpal bones. They are *inserted* into the base of the first phalanges, and aponeurosis of the extensor tendons.

The first (*fig.* 94. 3.) is inserted into the index finger, and

from its use is called abductor indicis; the second and third (*fig. 91. 5. 5., fig. 94. 5. 5.,*) are inserted into the middle finger, compensating its exclusion from the palmar group; the fourth, (*fig. 94. 7.*) is attached to the ring finger; so that each finger is provided with two interossei, with the exception of the little finger, as may be shown by a table.

<i>Index finger</i>	{	one dorsal, (abductor indicis,) <i>fig. 94. 3.</i>
		one palmar, <i>fig. 94. 4.</i>
<i>Middle finger</i>		two dorsal, <i>fig. 94. 5. 5.</i>
<i>Ring finger</i>	{	one dorsal, <i>fig. 94. 6.</i>
		one palmar, <i>fig. 94. 7.</i>
<i>Little finger</i>		remaining palmar, <i>fig. 94. 9.</i>

Fig. 94. A diagram showing the abductor and adductor muscles of the hand, and the attachments and actions of the interossei. The middle finger is made longer than the rest, in order to mark the central axis of the hand, to which the movements of abduction and adduction are referrible. The dotted lines represent the six abductor muscles, and the plain lines the four adductors.



1. The abductor pollicis, arising from the scaphoid bone. 2. The adductor pollicis, arising from the whole length of the middle metacarpal bone. 3. The first dorsal interosseus, the abductor of the index finger: all the dorsal interossei arise by two heads, as is seen in the diagram. 4. The first palmar interosseous, the adductor of the index finger. 5. 5. The second and third dorsal interossei muscles, both abductors of the middle finger. 6. The second palmar interosseous, adductor of the ring-finger. 7. The fourth dorsal interosseus, abductor of the ring-finger. 8. The third palmar interosseous, adductor of the little finger. 9. The abductor of the little finger, arising from the pisiform bone.

The radial artery passes into the palm of the hand between the two heads of the first dorsal interosseous muscle and the

perforating branches of the deep palmar arch, between the heads of the other dorsal interossei.

ACTIONS.—The actions of the muscles of the hand are expressed in their names. Those of the radial group belong to the thumb, and provide for three of its movements, *abduction*, *adduction* and *flexion*. The ulnar group, in like manner, are subservient to the same motions of the little fingers, and the interossei are abductors and adductors of the second finger. The lumbricales are accessory in their actions to the deep flexors: they were called by the earlier anatomists, *fiducinae*, *i. e.*, fiddlers' muscles, from an idea that they might effect the fractional movements by which the performer is enabled to produce the various notes on that instrument.

In relation to the axis of the hand, (*fig. 94.*.) the four *dorsal* interossei are *abductors*, and the three palmar, *adductors*. It will, therefore, be seen that each finger is provided with its proper adductor and abductor, two flexors, and (with the exception of the middle and ring fingers) two extensors. The thumb has moreover a flexor and extensor of the metacarpal bone; and the little finger a flexor of the metacarpal bone without an extensor.

CHAPTER X.

THE LOWER EXTREMITY.

BEFORE commencing the dissection of the lower extremity, the student will carefully reflect upon the objects of his proposed dissection, and particularly upon the practical application of the information which he is seeking to acquire. The *lower extremity* comprises all that portion of the body which forms the lower limb, and is bounded above by the external surface of the pelvis. It consists of a thigh, leg, and foot—of the hip, knee, ankle, tarsal, metatarsal, and digital joints—of a complicated apparatus of muscles—of the femoral, popliteal, tibial, pedal, and plantar arteries—of veins, lymphatics, nerves, bones, and ligaments.

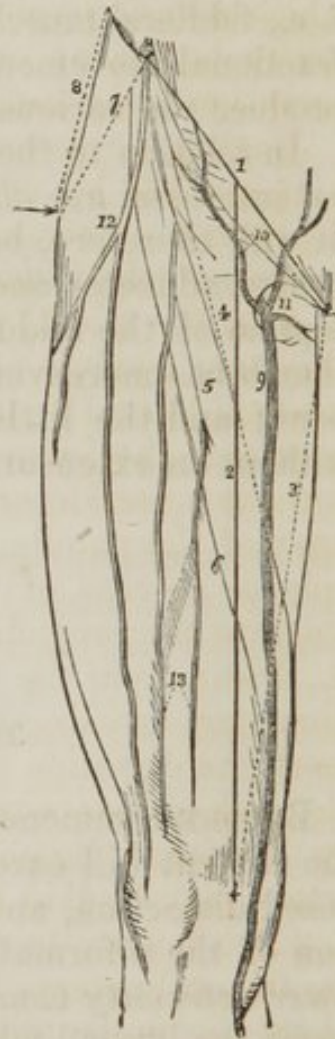
Now all these structures are liable to injury; and the surgeon, upon such an occurrence, is called upon to remedy the accident—to apply the knowledge that he shall have gained,

through the aid of his eyes and hands, in the dissecting room. Suppose the accident be one involving deep and important parts without affecting the surface, or exposing to the eyes the structure which may be injured: in such a case the surgeon has recourse to the comparative form and position of the adjoining limb; but circumstances may render this comparison unavailing; and he is then obliged to recall the observations he may chance to have made during his anatomical studies. Depend upon it, that a sound knowledge of the relations of the different portions of the limb will ever be found of the highest possible value to the practitioner who is suddenly called to the aid of a wounded fellow-creature. Indeed, such a knowledge should be considered as the leading characteristic of the accomplished surgeon.

Starting with reflections such as these, the student will perceive that other observations are necessary to him in addition to those which arise out of the mere dissection of the component parts of the limb which he is about to study. The thigh may be dislocated at the hip, or at the knee; the muscles, or their tendons, may be ruptured; the arteries may be wounded or diseased, requiring that incisions of considerable extent or depth should be made in their course, and a ligature placed around them; or nerves may be ganglionated, and demand removal; lastly, the whole limb may be disorganized, and call for amputation.

1. A line drawn from the anterior superior spine of the ilium to the spine of the pubis; these two points are represented by crosses. 2. A second line extended from the middle of the preceding to the tubercle on the inner condyle of the femur. This line marks the direction of the femoral artery. 3. A third line, drawn from the spine of the pubis to the tubercle on the inner condyle of the femur. 4. A fourth line drawn from the spine of the ilium to the middle of line three; this line marks the upper border of the sartorius muscle, and is the direction for the incision in securing the artery in the upper third of its course. 5. The outline of the sartorius muscle. 6.

Fig. 95. The thigh turned upon its outer side as in dissecting it.



The direction of the incision in operating upon the femoral artery, below the sartorius muscle, shown by a dotted line. 7. A line drawn from the trochanter major to the spine of the ilium. 8. Another line drawn from the trochanter major to the crest of the ilium. 9. The internal saphenous vein. 10. The superficial epigastric and superficial circumflexa ilii veins, converging to open into it previously to its entrance into the saphenous opening. 11. The saphenous opening in the fascia lata. 12. The external cutaneous nerve. 13. The middle cutaneous nerves, branches of the interior crural.

In each and every of these circumstances, relief is simply and effectually bestowed, if the operator be well acquainted with the situation and dissection of the various structures which may be implicated in the accident or disease; and these are to be learnt only in the dissecting room by careful observation and manipulation.

Having the lower extremity extended on the table before him, and the leg everted, let the student carry a line (*fig.* 95. 1.) from the extreme point of the anterior superior spinous process of the ilium to the symphysis pubis, and then another, 2. from the middle of the preceding to that projection upon the inner condyle of the femur, which gives attachment to the internal lateral ligament of the knee-joint; this will mark the course of the femoral artery. If the leg be perfectly straight, without inversion or eversion, the line must be carried to the apex of the patella. Again, if a line, 3., be drawn from the spinous process of the pubis along the inner border of the thigh to the projection on the internal condyle, a second line, 4., drawn from the anterior superior spinous process of the ilium, and crossing the former at the middle of the thigh, will mark the direction of the upper margin of the sartorius muscle, and enclose a triangular space, which is bounded above by Poupert's ligament. Within this triangle, the femoral artery may be laid bare and secured, in any part of the line 2. which marks its course; the usual situation for ligature of the femoral artery, in popliteal aneurism, being at the point where the upper margin of the sartorius crosses its course, the border of this muscle forming the natural guide for the direction of the incision. At the pubic angle of this triangular space, is situated the saphenous opening, 11., through which the sac of femoral hernia is protruded. In rare cases, the femoral artery is tied below the lower border of the sartorius muscle; under such circumstances, a space, varying from one inch to one inch and a half, and parallel to the oblique line, should be allowed for the breadth of the sartorius,

and the incision commenced immediately below this border, 6., still following the original line of its course.

Besides these, there is another point of equal importance to the surgeon, in the consideration of the proper projections on the surface of the limb, viz., the apophysis named trochanter major. For it is this prominence that marks the altered position of the limb in dislocations or diseases of the hip-joint, or fractures about the neck of the femur. It is a point liable to variation from strength or muscularity of the limb; but is necessarily more prominent and more sharply defined in an emaciated individual. A line, 8. drawn from the upper point of the trochanter major, to the most convex part of the crest of the ilium, and another, 7., extended from the same point to the anterior superior spinous process, may be compared with the same admeasurements on the opposite limb.

An important measurement of the thigh, for the detection of dislocation, is obtained by extending a line from the anterior superior spinous process of the ilium to the apex of the patella, and comparing its length with that on the opposite limb. If shortening be found to exist, whilst the distance, 8., between the trochanter major and the crest of the ilium is the same on both sides of the body, then the cause of the diminution of length must exist in the bone, and be the result of fracture. This may be determined by another admeasurement, made between the apex of the trochanter major and the lower point of the patella.

Let it not be said that these directions are too obvious to deserve attention; they must be followed carefully; and before the student commence his dissection, he should have himself made and repeated the observations here advised; have impressed well upon his memory the relative position of each landmark; and have cut down upon the artery at various points. By such means he will gain confidence in his knowledge and precision in the performance of surgical operations. Again, in displacement of the ends of the bone from fracture of the femur, it is of the greatest importance to their proper adjustment, that he be well acquainted with the position of the patella in relation to the spines of the ilium and pubis.

The lower extremity is divided anatomically into several distinct compartments or regions, the separate and relative study of which serves materially to facilitate the student's apprehension of the whole. The regions of the thigh are,

the anterior femoral, internal femoral, gluteal, posterior femoral, and popliteal; of the leg, the anterior tibial, fibular, sural, or superficial posterior tibial, and deep posterior tibial; of the foot, the dorsal and plantar regions.

Anterior Femoral Region.

The dissection of the anterior femoral region is best commenced by making an incision (*fig. 95. 1.*) from the anterior superior spinous process of the ilium along the line of Poupert's ligament to the spinous process of the pubis, then carrying a second, 2. along the course of the femoral artery to the inner condyle of the femur, and bounding it inferiorly by a third, carried transversely across the head of the tibia. The student then nips up the integument with his forceps at the upper angle, and dissects back that layer so as to expose the superficial fascia, beneath, and form a broad flap upon the outer side of the limb. He then turns to the opposite side, and repeats the same proceeding.

But the student who handles a scalpel for the first time, will not find its application so easy as this description would lead him to infer. If he examine the edge of his blade attentively with a lens, he will perceive that it is actually a microscopic saw. Now a saw divides by being drawn across the material to be cut; and no direct force applied to the saw, would carry it through the substance without this motion. Let him apply this reasoning to his scalpel, it must be handled lightly, and drawn without pressure across the textures to be divided: if he use force and pressure, the best edge would be useless in his hands. The art of dissecting with neatness and operating with dexterity, owes much to the good understanding existing between the knife and the hand; and the best operators have ever been the best dissectors.

If the student have reflected the integument *well*, he will have exposed the superficial fascia, which may be known by its soft yellow surface, studded with vesicles of fat, surrounded with the white areolæ of cellular tissue in which they are contained. The under surface of the integument, the corium of the skin, will appear quite white, and present a number of depressions, corresponding with the fatty depositions in the superficial fascia.

The *superficial fascia* is composed of two layers, between which are situated the cutaneous vessels and nerves. To ex-

amine these, incisions may be made through its superficial layer in the same direction with those previously described, and this structure dissected back. The parts to be examined in the superficial fascia are

Inguinal glands,
 Superficial circumflexa ilii artery,
 ———— epigastric artery,
 ———— external pudic artery,
 Internal saphenous vein, and its tributaries,
 External, middle, and internal cutaneous nerves.

The *inguinal glands* are situated in clusters along the line of Poupart's ligament, and near the termination of the saphenous vein. They receive the cutaneous lymphatic vessels from the lower extremity, lower part of the abdomen, and genital organs.

The three small *arteries*, the *superficial circumflexa ilii*, the *superficial epigastric*, and the *superficial external pudic*, are the first branches of the femoral artery. They pierce the deep fascia immediately beneath Poupart's ligament, and are distributed to the skin and superficial fascia; the circumflexa ilii taking its course along Poupart's ligament towards the crest of the ilium; the epigastric ascending upon the abdomen towards the umbilicus; and the pudic passing inwards to the scrotum, or labia pudendi.

The internal *saphenous vein*, *fig. 95. 9.*; (*σαφηνης*, perspicuous, obvious) of considerable size, sometimes consisting of two parallel trunks, receives its current of blood from the superficial veins of the inner side of the foot, leg and thigh, along which it runs, and terminates in the femoral vein near the pubic extremity of Poupart's ligament, by passing through an aperture in the deep fascia, named from this office, *saphenous opening*, 11. Just as the vein curves inwards to enter this opening, it receives a number of small veins, 10., which converge from the abdomen, hip, and genital organs. These vessels play a conspicuous part in femoral hernia, and, therefore, must not be passed over without remark. The saphenous vein is accompanied by superficial lymphatic vessels throughout the whole of its course.

The *external cutaneous nerve*, *fig. 95. 12.* (*cutis*, the skin) is derived from the second lumbar nerve, and pierces the fascia lata at about two inches below the anterior superior spine of the ilium, where it divides into two sets of branches,

one of which crosses the tensor vaginæ femoris muscle to the outer and posterior side of the thigh; the other, consisting of two or three nerves, is distributed along the external and anterior border of the thigh, as far as the knee.

The *middle cutaneous nerves*, 13, two or three in number, are branches of the anterior crural nerve: they pierce the deep fascia, at variable distances, below Poupart's ligament, to be distributed to the superficial fascia and integument on the front of the thigh as low down as the knee.

The *internal cutaneous nerve* is the crural division of the genito-crural nerve; it pierces the deep fascia at about four inches below Poupart's ligament, and runs down the inner side of the thigh towards the knee.

When these structures have been well examined, the deep layer of superficial fascia may be removed, in order to bring into view the deep fascia.

The *deep fascia* of the thigh, from being the most extensive in the body, is named *fascia lata* (latus, broad). It is an extremely dense membrane, consisting of glistening tendinous fibres, disposed longitudinally and circularly around the limb; is thickest upon the outer side of the thigh, and thinner upon its inner side. The fascia lata envelopes the whole of the muscles of the thigh, and sends processes inwards, which form distinct sheaths for each. It is attached *above* to the prominent points about the pelvis, viz., to the pubis, Poupart's ligament, crest of the ilium, sacrum, and ischium; *below*, to the condyles of the femur and patella; and *behind*, to the linea aspera. Besides these, it has two muscular attachments, one by means of the tensor vaginæ femoris; the other through the gluteus maximus. It is perforated at several points for the passage of the cutaneous nerves, and near to the pubis is the saphenous opening.

The existence of this opening, *fig. 95. 11.*, causes the division of the upper part of the fascia lata into two portions, an iliac portion situated towards the ilium, and a pubic portion towards the pubis. The *iliac portion* is attached along Poupart's ligament, as far as the spine of the pubis; from this point it is reflected downwards, in a curved direction, forming a sharp edge, called the *falciform process* (falx, a sickle). The edge of the falciform process immediately overlays and is reflected upon the sheath of the femoral vessels; and the lower extremity of the curve is continuous with the pubic portion.

The *pubic portion* is also attached to the spine of the pubis, and along the pectineal line, as far as the inner border of the psoas muscle; here it divides into two layers, which embrace that muscle and the iliacus, and are then lost in the facial coverings surrounding the different muscles on the outer side of the thigh.

From this description it will be obvious that the *iliac portion*, being attached to Poupart's ligament, must be on a plane considerably anterior to the *pubic portion*, which is attached to the bone; and it is between the two that the femoral vessels are placed, enclosed in their sheath. It follows also from this disposition that the saphenous opening is oblique in its direction with regard to these two layers of fascia. It is, moreover, closed by some dense cellular tissue, which is perforated by a number of minute openings for the transmission of the superficial lymphatic vessels of the lower extremity, and is hence named *cribriform fascia* (cribrum, a sieve). This cribriform fascia would be altogether unworthy the notice of the dissector, were it not for the arbitrary importance attached to every fibre of membrane or process of fascia that may possess the slightest relation to the protrusion of intestine from the cavity of the abdomen. For this reason it is that the saphenous opening is so urgently recommended to the student's attention; and the cribriform fascia, from its position, must necessarily form one of the coverings of the femoral hernia. The student may now remove the fascia lata, by dissecting it from its loose cellular attachment to the muscles, following always the course of their fibres. If the student would dissect well, he must treasure this rule as a golden maxim,—“*muscles must always be dissected in the course of their fibres.*” And, let us remind him again (for we cannot too strenuously insist upon the application of the principles of dissection to the operations of surgery) that, in the living body, the same rule must be rigidly adhered to, if a successful issue be desired.

Muscles of the Anterior Femoral Region.

The muscles of the anterior femoral region are arranged in two groups, an *anterior group*, consisting of six muscles—

Tensor vaginæ femoris,	Vastus internus,
Sartorius,	Vastus externus,
Rectus,	Crureus.

And an *internal group* of seven, viz:—

Iliacus internus,	Adductor brevis,
Psoas magnus	Adductor magnus,
Pectineus,	Gracilis.
Adductor longus,	

As soon as these two tables are got by heart, the student may commence the dissection of the muscles which they represent.

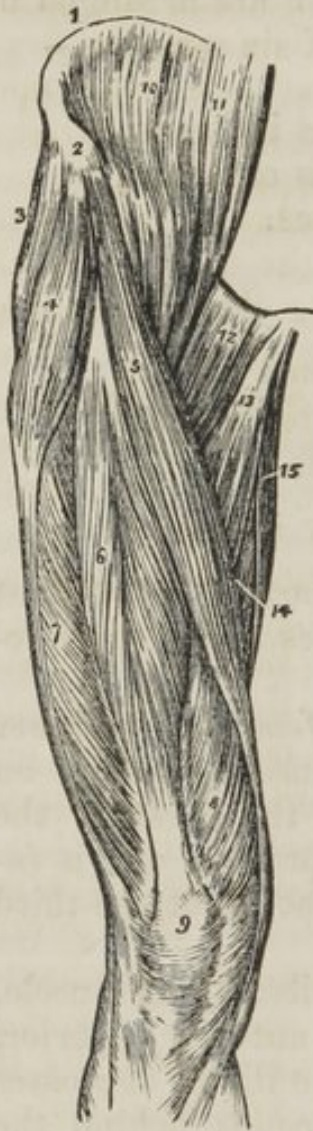ANTERIOR GROUP.—The *Tensor vaginæ femoris* (stretcher of the sheath of the thigh) is a short flat muscle, situated on the outer side of the hip. It *arises* from the crest of the ilium, near to its anterior superior spinous process, and is *inserted* between two layers of the fascia lata at about one-third down the thigh.

The *Sartorius* (tailor's muscle) is a long riband-like muscle, *arising* from the curved notch, between the anterior superior, and anterior inferior spinous processes of the ilium: it crosses obliquely the upper third of the thigh, descends behind the inner condyle of the femur, and is *inserted* by an aponeurotic expansion into the inner tuberosity of the tibia. This expansion covers in the insertion of the tendons of the gracilis and semitendinosus muscles. The upper border of the sartorius muscle is the guide to the operation for tying the femoral artery in the middle of its course.

The *Rectus* (straight) muscle is fusiform in its shape and bipenniform in the disposition of its fibres: it *arises* by two round tendons—one from the anterior inferior spinous process of the ilium, the other from the upper lip of the acetabulum. It is *inserted* by a broad and strong tendon into the upper

border of the patella. It is more correct to consider the patella as a sesamoid bone, developed within the tendon of the rectus; and the ligamentum patellæ as the continuation of the tendon to its insertion into the spine of the tibia.

Fig. 96. The muscles of the anterior femoral region.



The rectus must now be divided through its middle, and the two ends turned aside, to bring clearly into view the next muscles.

The three next muscles are generally considered collectively under the name of triceps extensor cruris. Adopting this view, the muscle surrounds the whole of the femur, except the rough line (linea aspera) upon its posterior aspect. Its division into three parts is not well defined; the fleshy mass upon each side being distinguished by the names of vastus internus and externus, the middle portion by that of crureus.

The *Vastus externus*, narrow below and broad above, *arises* from the outer border of the patella, and is *inserted* into the femur and outer side of the linea aspera, as high as the base of the trochanter major.

The *Vastus internus*, broad below and narrow above, *arises* from the inner border of the patella, and is *inserted* into the femur and inner side of the linea aspera as high up as the trochanter minor.

1. The crest of the ilium. 2. Its anterior superior spinous process. 3. The gluteus medius. 4. The tensor vaginæ femoris; its insertion into the fascia lata is shown inferiorly. 5. The sartorius. 6. The rectus. 7. The vastus externus. 8. The vastus internus. 9. The patella. 10. The iliacus internus. 11. The psoas magnus. 12. The pectineus. 13. The adductor longus. 14. Part of the adductor magnus. 15. The gracilis.

The *Crureus* (crus, the leg,) *arises* from the upper border of the patella, and is *inserted* into the front aspect of the femur, as high as the anterior inter-trochanteric line.

When the crureus is divided from its insertion, a small muscular fasciculus is often seen upon the lower part of the femur,

which is inserted into the pouch of synovial membrane, that extends upwards from the knee-joint, behind the patella. This is named, from its situation, *suberureus*, and would seem to be intended to support the synovial membrane.

ACTIONS.—The tensor vagina femoris renders the fascia lata tense, and slightly inverts the limb. The sartorius flexes the leg upon the thigh, and continuing to act, the thigh upon the pelvis, at the same time carrying the leg across that of the opposite side, into the position in which tailors sit; hence its name. Taking its fixed point from below, it assists the extensor muscles in steadying the leg for the support of the trunk. The other four muscles have been collectively named *quadriceps extensor*, from their similarity of action. They extend the leg upon the thigh, and obtain a great increase of power by their attachment to the patella, which acts as a fulcrum. Taking their fixed point from the tibia, they steady the femur upon the leg, and the rectus, by being attached to the pelvis, serves to balance the trunk upon the lower extremity.

INTERNAL GROUP.—The origins of the iliacus and psoas muscle being situated within the abdomen, the entire muscles cannot be seen in this dissection; but as a part of them quit that cavity to be inserted into the femur, that portion necessarily belongs to the anatomy of the thigh.

The *Iliacus internus* is a flat, radiated muscle: it *arises* from the inner concave surface of the ilium, and, after joining with the tendon of the psoas, is *inserted* into the trochanter minor of the femur.

The *Psoas magnus* (ψα, lumbus, a loin,) situated by the side of the vertebral column in the loins, is a long fusiform muscle. It *arises* from the intervertebral substances, part of the bodies and bases of the transverse processes, and from a series of tendinous arches thrown across the constricted portion of the last dorsal and four upper lumbar vertebræ. These arches are intended to protect the lumbar arteries and sympathetic filaments of nerves from pressure, in their passage beneath the muscle. The tendon of the psoas magnus unites with that of the iliacus, and the conjoined tendon is *inserted* into the posterior part of the trochanter minor.

Two synovial bursæ are found in relation with the last two muscles: the first of considerable size is situated between their under surface and the border of the pelvis; the other much

smaller is interposed between the conjoined tendon and the anterior part of the trochanter minor.

The *Pectineus* is the flat quadrangular muscle which *arises* from the pectineal line (pecten, a crest) of the os pubis, and is *inserted* into the line leading from the trochanter minor to the linea aspera.

The *Adductor longus* (adducere, to draw to,) the most superficial of the three adductors, *arises* by a round tendon from the angle of the os pubis, and, assuming a flattened form, is *inserted* into the middle third of the linea aspera.

The pectineus must be divided near its origin and turned outwards, and the adductor longus through its middle, turning its ends to either side to bring into view the adductor brevis.

The *Adductor brevis*, placed beneath the pectineus and adductor longus, is fleshy, and thicker than the adductor longus: it *arises* from the body and ramus of the os pubis, and is *inserted* into the upper third of the linea aspera. It is pierced by the middle perforating artery, and supports the anterior branch of the obturator nerve and artery.

The adductor brevis may now be divided from its origin and turned outwards, or its inner two-thirds may be cut away entirely, after separating the anterior branches of the obturator artery and nerve from its surface. This exposes the entire extent of the adductor magnus, and a fleshy mass of muscle which covers in the obturator foramen,—the obturator externus.

The *Obturator externus* muscle (obturare, to stop up,) *arises* from the obturator membrane, and from the surface of bone immediately surrounding it, viz., from the body and ramus of the os pubis and ischium: its tendon passes behind the neck of the femur, to be *inserted* with the external rotator muscles, into the digital fossa of the trochanter major. Although this muscle belongs properly to another group (glutæal region,) it has been deemed consistent with the object of this work to describe every organ which may come beneath the observation of the student in the progress of his dissection, in the precise situation which it actually occupies.

The *Adductor magnus* is a broad and extensive muscle, forming a septum of division between the muscles situated on the anterior, and those on the posterior aspect of the thigh. It *arises* by fleshy fibres from the ramus and side of the tuberosity of the ischium, and radiating in its passage outwards,

is *inserted* into the whole length of the linea aspera, and inner condyle of the femur. The adductor magnus is pierced by five openings: the three superior, for the three perforating arteries, and the fourth for the termination of the profunda. The fifth is the large, oval opening in the tendinous portion of the muscle, that gives passage to the femoral vessels.

The *Gracilis* (slender) is situated along the inner border of the thigh: it *arises* by a broad, but very thin, tendon, from the edge of the ramus of the pubis and ischium, and is *inserted* by a rounded tendon into the inner tuberosity of the tibia, beneath the expansion of the sartorius.

ACTIONS.—The iliacus, psoas, pectineus, and adductor longus muscles bend the thigh upon the pelvis, and, at the same time, from the obliquity of their insertion into the lesser trochanter and linea aspera, rotate the entire limb outwards: the pectineus and adductors adduct the thigh powerfully; and, from the manner of their insertion into the linea aspera, they assist in rotating the limb outwards: the gracilis is likewise an adductor of the thigh, but contributes also to the flexion of the leg, by its attachment to the inner tuberosity of the tibia.

Vessels of the Thigh.

The *arteries* of the anterior aspect of the thigh are next to be examined: they are best dissected by following the branches through their ramifications from the main trunk. The scalpel may be carried along the side of their cylinder without danger of dividing their coats; but if it be turned in the opposite direction, they must inevitably be cut across. They are easily separated from the cellular tissue and adipose substance, and from the smaller veins which surround them. All the veins, excepting the main trunks, had better be removed at once, otherwise their intricacy and bleeding will greatly interfere with the student's progress, and confuse his dissection.

Femoral Artery.

The arteries situated on the anterior aspect of the thigh are the femoral and its branches: they may be thus arranged:—

Femoral artery.	<i>Branches.</i>
	Superficial circumflex ilii.

Superficial epigastric.

external pudic.

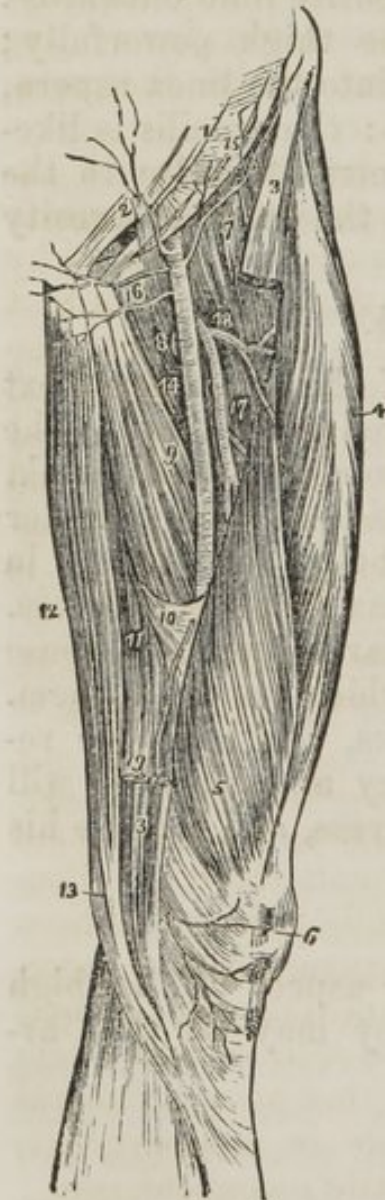Deep external pudic.

Profunda. { External circumflex.
Internal circumflex.
Three or four perforating.

Muscular.

Anastomotica magna.

The femoral artery and vein are enclosed in a sheath of condensed cellular substance. The sheath is broad and funnel-shaped above, but narrows considerably in its descent, and becomes more closely applied about the vessels. At the upper third of the thigh, two nerves become placed upon the sheath: these are the long and short saphenous branches of the anterior crural nerve. The larger of the two pierces the sheath and accompanies the femoral vessels within its interior. The smaller lies upon the sheath till it arrives opposite the vastus internus muscle, to which it is distributed.



Operation.—These nerves are found to observe the above relation to the femoral artery, in the operation for tying that vessel. The *integument* is first divided, then the *superficial fascia*, next the *deep fascia*; then the edge of the sartorius muscle is drawn aside, and the *sheath* of the vessels exposed, upon which lie these two saphenous nerves, and the operator is careful in opening the sheath to avoid injuring them.

The FEMORAL ARTERY runs down the inner side of the thigh, from Poupart's ligament, at a point exactly midway between the anterior superior spinous process of the ilium and symphysis pubis, to the hole in the adductor mag-

1. The lower part of the aponeurosis of the external oblique muscle; its inferior margin is Poupart's ligament. 2. The external abdominal ring. 3, 3. The upper and lower part of the sartorius muscle; its middle portion having been removed. 4. The rectus. 5. The vastus internus. 6. The patella. 7. The iliacus and psoas; the latter being nearest the artery. 8. The pectineus. 9. The adductor longus. 10. The tendinous canal for the femoral artery formed by the adductor magnus, and vastus internus muscles. 11. The adductor magnus. 12. The gracilis. 13. The tendon of the semi-tendinosus. 14. The femoral artery. 15. The superficial circumflexa ilii artery taking its course along the line of Poupart's ligament, to the crest of the ilium. 2. The superficial epigastric artery. 16. The two external pudic arteries, superficial and deep. 17. The profunda artery giving off 18, its external circumflex branch; and lower down the three perforantes. A small bend of the internal circumflex artery (8) is seen behind the inner margin of the femoral, just below the deep external pudic artery. 19. The anastomotica magna, descending to the knee, upon which it ramifies (6.)

nus, at the junction of the middle with the inferior third of the thigh. The femoral vein is at first to the inner side, and upon the same plane with the artery, but lower down; the vein becomes placed behind the artery, and retains that relation throughout the rest of its course.

RELATIONS.—The upper third of the femoral artery is superficial, being covered only by the integument and superficial and deep fasciæ. The lower two-thirds are covered by the sartorius muscle. To its outer side the artery rests first against the psoas, next against the rectus, then against the vastus internus. Behind it has, first, the body of the pubis, then the tendon of the psoas and iliacus; it is next separated from the pectineus by the femoral vein, profunda vein and artery, and then lies on the adductor longus to its termination: near the lower border of the adductor longus, it is placed in an aponeurotic canal, formed by an arch of tendinous fibres, thrown from the border of the adductor longus, and the border of the opening in the adductor magnus, to the side of the vastus internus.

BRANCHES.—The superficial circumflexa ilii, superficial epigastric, superficial and deep external pudics, are four small arteries given off from the femoral, immediately below Poupart's ligament. The distribution of the first three has been described at page 355. The superficial epigastric and superficial pudic are important, from their connexion with hernial tumours occurring in this region: we have seen both of them crossing an inguinal, and the latter ramifying upon a femoral hernia. In the operation they are liable to division; but, from their small size, would cause very little inconvenience.

The *deep external pudic* is so named from being placed beneath the fascia lata: it is given off from the femoral about an inch below the superficial pudic, and, at the inner border of the thigh, pierces the fascia, to be distributed to the integuments of the scrotum and labium pudendi.

The PROFUNDA FEMORIS artery is given off from the femoral, at two inches below Poupart's ligament. From its large size, it may be considered as a division of the femoral rather than a branch: and, in this view, the short trunk has been called the common femoral, (*femoralis communis*,) and its two divisions, *femoralis superficialis* and *femoralis profunda*; the superficial femoral being intended for the supply of the knee and leg, while the profunda is distributed to the thigh. The profunda artery is best examined by removing the superficial femoral, and dissecting away the femoral and profunda veins, that conceal the artery from view. The adductor longus would also be dissected from its insertion with advantage.

The *Course* of the profunda artery is downwards and backwards, and a little outwards, behind the adductor longus muscle: it then pierces the adductor magnus, and is distributed to the ham-string muscles.

RELATIONS.—It rests successively upon the conjoined tendon of the psoas and iliacus, the pectineus, adductor brevis, and adductor magnus muscles. To its outer side, the tendinous insertion of the vastus internus muscle intervenes between it and the femur, and in front it is separated from the femoral artery above by the profunda vein and femoral vein; and below by the adductor longus muscle.

The *branches* of the profunda artery are the external circumflex, internal circumflex, and three perforating arteries.

The *External circumflex* artery passes outwards between the divisions of the crural nerve, then between the rectus and crureus muscles, and divides into three branches; *ascending*, which inosculates with the terminal branches of the gluteal artery; *descending*, which inosculates with the superior external articular artery; and *middle*, which continues the original course of the artery around the thigh, and anastomoses with branches of the ischiatic, internal circumflex, and superior perforating arteries. It supplies the muscles on the anterior and outer side of the thigh.

The *Internal circumflex* artery winds around the inner side of the neck of the femur, passing between the pectineus and

psoas, and along the border of the external obturator muscle, to the space between the quadratus femoris and upper border of the adductor magnus, where it anastomoses with the ischiatic, external circumflex, and superior perforating arteries. It supplies the muscles on the upper and inner side of the thigh, anastomosing with the obturator artery, and sends a small branch through the notch in the acetabulum into the hip-joint.

The *Superior perforating* artery passes backwards between the pectineus and adductor brevis, pierces the adductor magnus, and is distributed to the posterior muscles of the thigh; inosculating freely with the circumflex and ischiatic arteries, and with the branches of the middle perforating artery.

The *Middle perforating* artery pierces the adductor brevis and magnus, and is distributed like the superior; inosculating with the superior and inferior perforantes. It gives off the nutritious artery of the femur.

The *Inferior perforating* artery is given off below the adductor brevis, and pierces the adductor magnus, supplying it and the flexor muscles, and inosculating with the middle perforating artery above, and the articular branches of the popliteal below. It is through the medium of these branches, that the collateral circulation is maintained in the limb after ligature of the femoral artery.

We now return to the superficial femoral: its *muscular branches* are distributed on either side to the adjacent muscles.

The *Anastomotica magna* arises from the femoral, while in the tendinous canal formed by the adductors and vastus internus. It runs along the tendon of the adductor magnus to the inner condyle, and inosculates with the superior internal articular artery: some of its branches are distributed to the vastus internus muscle, and the crureus, and terminate by anastomosing with the descending branches of the external circumflex and superior external articular artery.

When the pectineus muscle is divided through its origin and turned down, a small artery will be seen issuing from the opening in the upper part of the obturator membrane; this is the obturator artery, a branch of the internal iliac.

The *Obturator* artery, after passing through the obturator foramen, divides into two branches; *anterior*, which rests upon the adductor brevis, supplying that muscle, together with the pectineus and adductor longus: and *posterior*, which

follows the direction of the obturator externus muscle to the space between the gemellus inferior and quadratus femoris, where it inosculates with the ischiatic artery. It sends a branch through the notch in the acetabulum to the hip-joint.

The *Veins* in this region, as in every other of the body, are superficial and deep. The *superficial*, are the internal saphenous, and its tributaries. The *deep*, are the femoral and profunda, with their tributaries. The *femoral vein* commences at the hole in the adductor magnus, and ascends behind the artery to within two inches of Poupart's ligament, where it receives the profunda vein; it then becomes placed to the inner side of the artery, and continues in that position to Poupart's ligament. After passing beneath the ligament, it receives the name of external iliac vein. The *profunda vein*, commencing with the ultimate ramifications of the profunda artery, ascends in front of that vessel to its origin from the common femoral artery, when it joins the femoral vein. The tributary veins are those accompanying the branches of the main arteries. They are usually two to each branch, one on either side; hence they are called *venæ comites*. They communicate freely across the cylinder of the artery by short transverse trunks. Veins are considerably larger than the arteries which they accompany.

Nerves of the Anterior Femoral Region.

The student will now direct his attention to the nerves of this region, *fig. 98*. They are all derived from the lumbar plexus: and are the

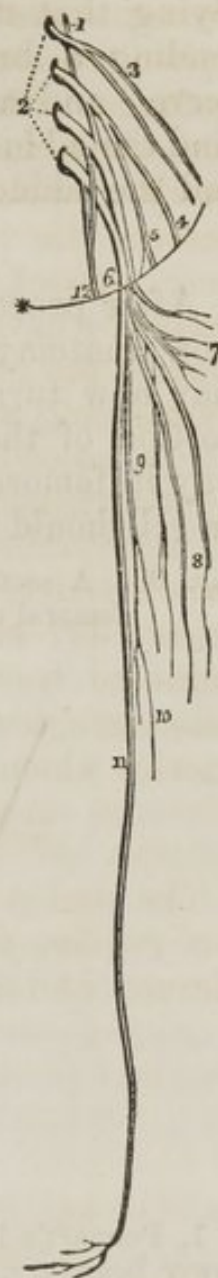
External cutaneous,	
Genito-crural,	
Crural.	{
	Cutaneous branches,
	Muscular,
	Saphenous.
Obturator.	

The *External cutaneous* nerve, 4., is described with the superficial layer at page 357. The *crural* portion of the *genito-crural* nerve, 5., forming the internal cutaneous nerve of the thigh, has also been described (page 357.)

The *Crural or femoral nerve*, 6., is the largest of the branches from the lumbar plexus. It is formed by the union of the second, third, and fourth lumbar nerves, passes beneath

the outer border of *psoas magnus* muscle, and runs downwards in the groove between that muscle and the *iliacus internus* to *Poupart's* ligament. It is there separated from the femoral artery by the breadth of the *psoas* muscle, usually not more than half an inch wide; and immediately below *Poupart's* ligament divides into three sets of branches:—*Cutaneous*—*fig. 95. 13. fig. 98. 8.*; three or four in number which pierce the deep fascia to supply the integument, forming the middle cutaneous nerves on the forepart of the thigh. One or two of these will be seen to pass through the *sartorius* muscle. *Muscular*—*fig. 98. 7.*, distributed to the muscles on the forepart of the outer side of the thigh; and *Saphenous*—*fig. 98. 9.* Two long branches larger than the others, which incline inwards to the sheath of the vessels, upon which they rest for some distance. The smaller of the two is the *short saphenous* nerve, 10.; it leaves the sheath at the lower third of the thigh, and is distributed to the *vastus internus* muscle. The larger is the *long* or *internal saphenous* nerve, 11.; it usually enters the sheath and accompanies the artery, until that vessel is about to pass through the opening in the *adductor magnus*. The nerve then pierces the aponeurotic canal of the artery, passes between the tendons of the *sartorius* and *gracilis*; and gets into relation with the *internal saphenous vein*, by the side of which it descends along the inner side of the leg, in front of the inner ankle, and along the inner border of the foot and side of the great toe, supplying it and the integuments in its course.

Fig. 98. The lumbar plexus with its branches.



1. The dorsal lumbar nerve. 2. The four upper lumbar nerves. 3. The two musculo cutaneous nerves, branches of the first lumbar nerve. 4. The external cutaneous nerve. 5. The genito crural nerve. 6. The crural or femoral nerve. 7. Its muscular branches. 8. Its cutaneous branches, middle cutaneous. 9. Its descending or saphenous branches. 10. The short saphenous nerve. 11. The long or internal saphenous. 12. The obturator nerve.

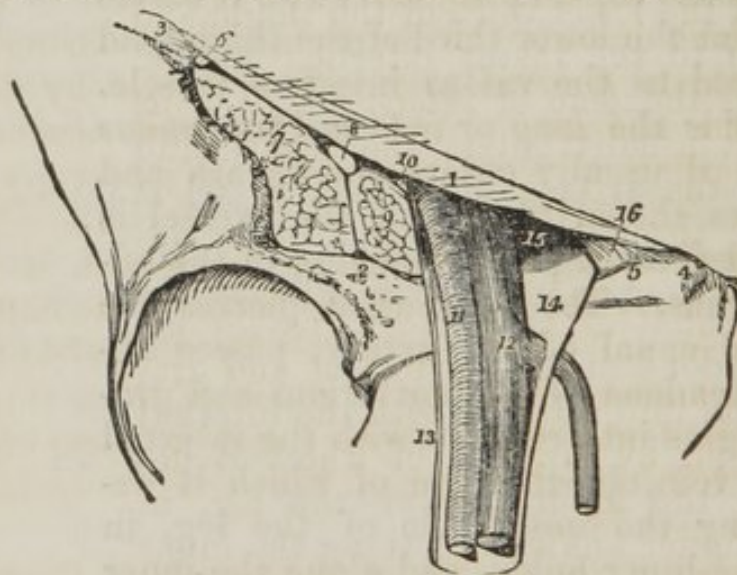
The *Obturator nerve*, 12., is formed by a branch from the

third, and another from the fourth lumbar nerve. The nerve runs along the inner border of the brim of the pelvis, to the obturator foramen, where it joins the obturator artery. Having escaped from the pelvis, it divides into two branches—*anterior*, which passes in front of the adductor brevis, supplying that muscle, the pectineus, and adductor longus, and sending a branch downwards to join the long saphenous nerve; and a *posterior* branch which passes downwards behind the adductor brevis, supplying it, the obturator externus, and the adductor magnus.

Femoral Hernia.

After proceeding, as we have here directed, with the common anatomy of the anterior femoral region, the student may now turn his attention to the special anatomy of that portion of the region through which the intestine finds its way in femoral hernia. With this object the sheath of the vessel should have been left undisturbed.

Fig. 99. A section of the structures which leave the pelvis through the femoral arch;—the vessels and their sheath only, being left.



1. Poupart's ligament, the upper boundary of the femoral arch. 2. Its lower boundary, the border of the pubis and ilium. 3. The anterior superior spine of the ilium. 4. The spine of the pubis. 5. The pectineal line of the pubis. 6. The external cutaneous nerve. 7. The iliacus muscle. 8. The crural nerve. 9. The psoas magnus muscle. 10. The crural branch of the genito-crural nerve. 11. The femoral artery. 12. The femoral vein, receiving the internal saphenous vein, which pierces the sheath to open into it. 13. The external portion of the sheath of the femoral vessels, lying in contact with the artery. 14. The large funnel-shaped cavity in the sheath, to the inner side of the vein, which receives the sac of femoral hernia. 15. The femoral ring, bounded in front by Poupart's ligament, behind by the pubis, externally by the femoral vein, and internally by (16.) Gimbernat's ligament.

If now the scalpel be carried along the line of Poupart's ligament, cutting through the intervening structures down to the bone, and leaving only the common femoral artery and vein enclosed in their sheath (*fig. 99.*) it will be seen that Poupart's ligament, which is extended from the anterior superior spine of the ilium to the spine of the pubis, forms a considerable arch over the concave border of the pelvis. This is the *femoral arch*, and beneath it will be seen to pass a number of important structures. They are disposed in the following order from without, inwards:—

The external cutaneous nerve, 6.

Iliacus internus muscle, 7.

Anterior crural nerve, 8.

Psoas magnus muscle, 9.

Crural division of the genito-crural nerve, 10.

Femoral artery, 11.)

Femoral vein, 12.)

Lymphatic vessels,)

} enclosed in a common sheath.

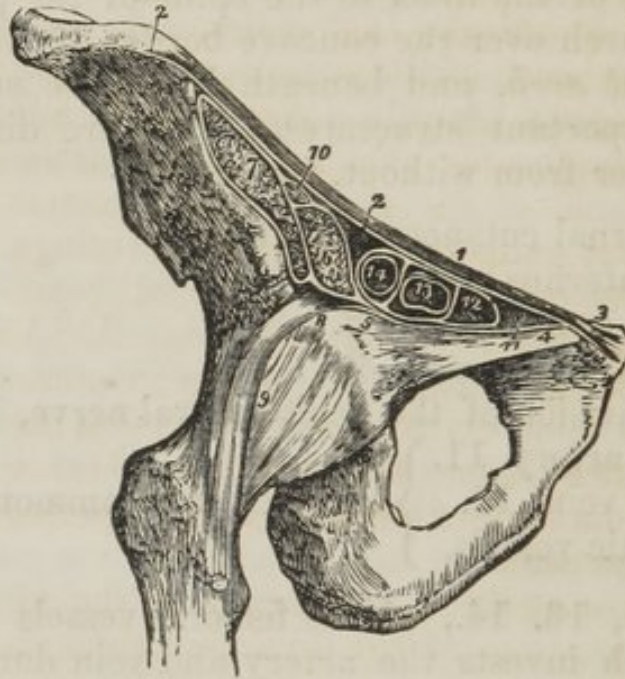The *sheath*, 13. 14., of the femoral vessels is the fibrous covering which invests the artery and vein during their passage beneath the femoral arch. It is formed by the internal lining of the abdomen; and as this has received various names, according to the situations it may occupy, as *transversalis fascia*, *iliac fascia*, *pelvic fascia*, although actually but one and the same membrane, so the sheath is said to be formed in front by the transversalis fascia to the outer side, by the iliac fascia, and to the inner side by the pelvic fascia; for Poupart's ligament is the line of union of these three regions of the internal abdominal fascia; and in escaping immediately beneath Poupart's ligament the vessels necessarily carry with them a part of each.

The breadth of the sheath of the vessels at Poupart's ligament is two inches, and in the female more; but at four inches, below the ligament, the sheath has diminished to three quarters of an inch.

Now it is obvious that the artery and vein, placed side by side, cannot occupy an area two inches in breadth, and therefore that there must be either some other structure situated within the sheath, or an imperfectly filled space. The latter is the fact; for, if we open the sheath, we shall see a space, 14, to the inner side of the vein, which is only occupied by

loose cellular tissue, lymphatic vessels, and a lymphatic gland. So that the inner wall of the sheath is separated by a considerable interval from the vein, while the outer wall, 13, is in close contact, and adherent to the artery.

Fig. 100. A section of the structures which pass beneath the femoral arch.



1. Poupart's ligament. 2. 2. The iliac portion of the fascia lata, attached along the margin of the crest of the ilium, and along Poupart's ligament, as far as the spine of the os pubis (3.) 4. The pubic portion of the fascia lata, continuous at 3 with the iliac portion, and passing outwards behind the sheath of the femoral vessels to its outer border at 5, where it divides into two layers; one is continuous with the sheath of the psoas (6) and iliacus (7;) the other (8) is lost upon the capsule of the hip-joint (9.) 10. The femoral nerve, enclosed in the sheath of the psoas and iliacus. 11. Gimbernat's ligament. 12. The femoral ring, within the femoral sheath. 13. The femoral vein. 14. The femoral artery: the two vessels and the ring are surrounded by the femoral sheath, and thin septa are sent between the anterior and posterior wall of the sheath, dividing the artery from the vein, and the vein from the femoral ring.

The lymphatic gland is placed immediately under Poupart's ligament, and may be easily pushed into the cavity of the abdomen by using very slight pressure with the finger.

The *opening*, 15., thus produced by the finger is the *femoral ring*: it is bounded in front by Poupart's ligament, 1., behind by the body of the pubis, 2., to the outer side by the femoral vein, 12, and to the inner side by Gimbernat's ligament, 16. This ligament is one insertion of Poupart's ligament, which expands in a radiated form to be attached along the sharp edge of the pectineal line.

If the student, before passing his finger through the femoral ring from the sheath, should attempt to press it from within the abdomen, after tearing away the peritoneum, he will find an obstacle in a thin cellular membrane which is spread across the opening at its entrance: this is the *septum crurale*.

Now the *course* which the intestine follows in femoral hernia may be thus described. It *first* descends through the femoral ring into the sheath of the vessels, carrying with it the peritoneum and septum crurale. *Secondly*, it advances forwards through the saphenous opening in the fascia lata, this being the weakest side of the sheath of the vessels. In this part of its course it gains two additional coverings, viz. the sheath of the vessels called "*fascia propria*," and the perforated cellular tissue before described (page 358.) as forming the *cribriform fascia*. *Thirdly*, coming in contact with the numerous small veins which open at this point into the saphenous vein, and spread before the descending hernia like a net, it is prevented from farther descent, and is pressed upwards over Poupart's ligament.

To return it again to the cavity of the abdomen we must pursue the converse of the direction which is followed in its descent, *i. e.*, we must press it first *downwards* below Poupart's ligament, then *backwards* through the saphenous opening, then *upwards* through the femoral ring.

But should the intestine be strangulated, that is, nipped in its passage, so as to arrest the progress of the aliment, and by distention and pressure cause obstruction to the circulation of the blood, and endanger the life of the patient, we must have recourse to an operation for its relief. This operation consists in dividing carefully all the structures covering the hernia, down to the intestine. The surgeon must, therefore, know well what parts are likely to meet his knife in the living dissection. Two of these are common to the whole body, and must be divided in every operation; the others are peculiar to the region; they are

The integument,
Superficial fascia,
Cribriform fascia,
Fascia propria (sheath of the vessels,)
Septum crurale,
Peritoneal sac.

After opening the peritoneal sac, the surgeon examines the

intestine and feels for the stricture. This is generally at the margin of the femoral ring; and, introducing his finger nail beneath this margin, he divides it slightly with a blunt-pointed bistoury, and returns the intestine into the abdomen, after having satisfied himself of its uninjured condition.

Now the student might ask, What structure produces the stricture? or what band, being thus slightly divided, so immediately liberates it? Let him make this experiment on the dead body. Cut through Poupart's ligament while the finger is forced through the femoral ring: the constriction is not removed. Cut Gimbernat's ligament, the inner boundary of the ring, the constriction still remains; but cut a thin fibrous band which crosses the vessels beneath Poupart's ligament, and the ring falls instantly flaccid. This is the margin of the unopened sheath of the vessels, and therefore must be the seat of the stricture.

This is the anatomical principle of practice in every case of femoral hernia; and pursued in this way no danger is incurred to the patient. But if the operator be a bad dissector, and, by a necessary consequence, a bad operator, he may, instead of loosening the ring by the slight manœuvre here described, carry his incision altogether through Poupart's ligament, or very likely still farther, and cut across the spermatic or epigastric artery, and so complete the operation with the life of his patient.

Such an operator should be forewarned that a variety in the distribution of the arteries sometimes occurs in the vicinity of the femoral ring; and unless he be guarded, his reputation may be for ever destroyed by an unfortunate complication of this kind. This variety consists in the origin of the obturator artery, from the epigastric immediately above the femoral ring. The artery arising in this situation, descends most frequently in contact with the external iliac vein, and would therefore be placed to the *outer* side of the hernial sac, and be comparatively safe. But sometimes the obturator encircles the ring in its course to the obturator foramen, winding along on the margin of Gimbernat's ligament, and would necessarily occupy a very dangerous position in the operation, actually *encircling the neck of the hernial sac*, and might be wounded by the most skilful operator. Therefore the safety of the patient demands that the surgeon should always conduct his operation as if his patient were the sub-

ject of this anomalous distribution, and he may then reflect upon his conduct even after an unsuccessful issue with confidence and satisfaction.*

Gluteal Region.

The subject being turned on its face, and a block placed beneath the pubis to support the pelvis, the student commences the dissection of this region, by carrying an incision from the apex of the coccyx along the crest of the ilium to its anterior superior spinous process, or vice versâ, if he be on the left side. He then makes an incision from the posterior fifth of the crest of the ilium, to the apex of the trochanter major; this marks the upper border of the gluteus maximus; and a third incision from the apex of the coccyx along the fleshy margin of the lower border of the gluteus maximus, to the outer side of the thigh, about four inches below the apex of the trochanter major. He then reflects the integument, superficial fascia, and deep fascia, which latter is very thin over this muscle, from the gluteus maximus, following rigidly the course of its fibres; and having exposed the muscle in its entire extent, he dissects the integument and superficial fascia from off the deep fascia which binds down the gluteus medius, the other portion of this region.

The muscles of the *gluteal* region are,

Gluteus maximus,	Obturator internus,
——— medius,	Gemellus inferior,
——— minimus,	Obturator externus,
Pyramiformis,	Quadratus femoris.
Gemellus superior,	

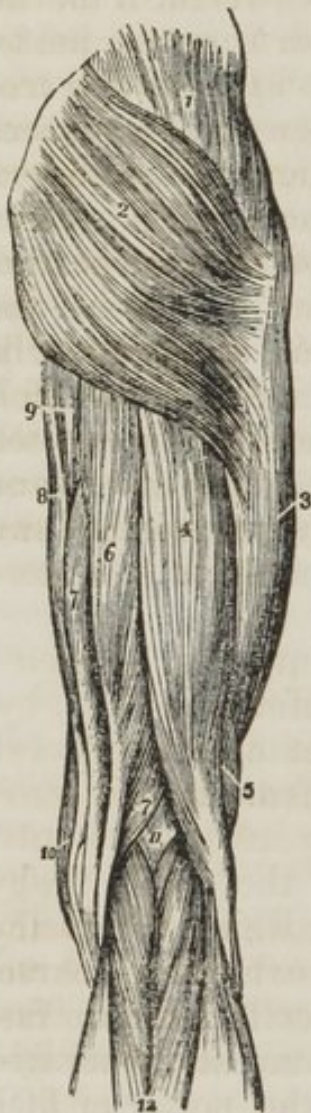The *Gluteus maximus* (*γλουτος*, nates,) is the thick, fleshy mass of muscle, of a quadrangular shape, which forms the convexity of the nates. In structure, it is extremely coarse, being made up of large fibres, which are collected into fasciculi, and these again into distinct muscular masses, separated by deep cellular furrows. It *arises* from the posterior fifth of the crest of the ilium, from the border of the sacrum and coccyx, and from the great sacro-ischiatic ligament. It passes

* The author has met with five or six instances of this dangerous distribution in about 300 bodies, which is a large average. In a preparation now before him, a large branch of communication between the epigastric and obturator arteries takes that remarkable course along the margin of Gimbernat's ligament, leaving the femoral ring to its outer side.

obliquely outwards and downwards to be *inserted* into the rough line leading from the trochanter major to the linea aspera, and is continuous by means of its tendon with the fascia lata, covering the outer side of the thigh.

After this muscle has been sufficiently studied, it must be turned down from its origin. Its dissection, however, from the parts beneath demands considerable care, as a number of arteries and nerves are situated immediately below it.

Fig. 101. The muscles of the posterior femoral and gluteal region.



The *Gluteus medius* is placed in front rather than beneath the gluteus maximus, and is covered in by a process of the deep fascia, which is very thick and dense. It *arises* from the outer lip of the crest of the ilium for four-fifths of its length from the surface of bone between that border, and the superior curved line on the dorsum illi, and from the dense fascia above-mentioned. Its fibres converge to the upper part of the trochanter major into which its tendon is *inserted*.

This muscle should now be removed from its origin and turned down, so as to expose the next which is situated beneath it.

The *Gluteus minimus* (*fig. 103. 1.*) is a pretty, radiated muscle, *arising* from the surface of the dorsum illi, between the superior and inferior curved lines: its fibres converge to the anterior border of the trochanter major, into which it is *inserted* by means of a rounded tendon.

To understand the exact relations and origins of the next muscles, the student

1. The gluteus medius. 2. The gluteus maximus. 3. The vastus externus covered in by fascia lata. 4. The long head of the biceps. 5. Its short head. 6. The semi-tendinosus. 7. The semi-membranosus. 8. The gracilis. 9. A part of the inner border of the adductor magnus. 10. The edge of the sartorius. 11. The popliteal space. 12. The gastrocnemius muscle; its two heads. The tendon of the biceps forms the outer hamstring; and the sartorius with the tendons of the gracilis, semi-tendinosus, and semi-membranosus, the inner hamstring.

should consult his skeleton. Upon the posterior and lateral aspect of the pelvis, he will find a considerable vacuity. This is broken in upon by a sharp spinous process projected from the border of the ischium, the *spine* of the ischium: the excavated sweep immediately above this spine is called the *great sacro-ischiatic notch*, in contra-distinction to another sweep beneath the spine, named the *lesser sacro-ischiatic notch*; and the lesser sacro-ischiatic notch is bounded inferiorly by a thick tubercle, the tuberosity of the ischium. In the subject, the narrow extremity of a radiated ligament is attached to the spine of the ischium, while its expanded end is connected to the side of the sacrum and coccyx: hence it is named *sacro-ischiatic*, and is known by the cognomina, *lesser* and *anterior*, which serve to distinguish it from another ligament, radiated at each extremity, attached by the broader end to the posterior spinous process of the ilium, the side of the sacrum and coccyx, and by its smaller end to the inner border of the tuberosity of the ischium. This ligament is necessarily longer than the former, and more posterior: hence it is named the *posterior* or *great sacro-ischiatic* ligament. These two ligaments convert the notches into foramina, which are thence called the *superior* or *great sacro-ischiatic foramen*, and the *inferior* or *lesser sacro-ischiatic foramen*. Let us now proceed to the muscles, *fig. 103*.

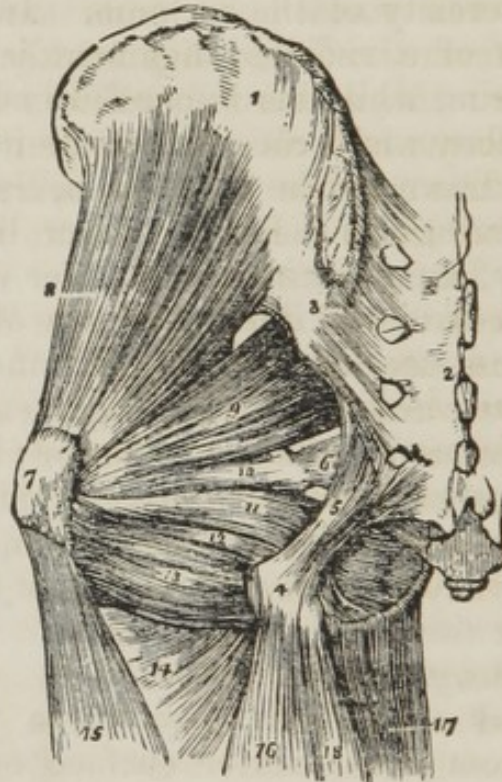The *Pyriformis* muscle, 3., (pyrum, a pear, *i. e.* pear-shaped) *arises* from the anterior surface of the sacrum, by little slips that are interposed between the anterior sacral foramina. It passes out of the pelvis, through the great sacro-ischiatic foramen, and is *inserted* by a rounded tendon into the digital fossa of the trochanter major.

Immediately below the pyriformis is a small slip of muscle, the *Gemellus superior* (gemellus, double, twin:) it *arises* from the spine of the ischium, and is *inserted* into the upper border of the tendon of the obturator internus, and into the digital fossa of the trochanter major.

The *Obturator internus* *arises* from the inner surface of the anterior wall of the pelvis, being attached to the margin of bone around the obturator foramen, and to the obturator membrane. It passes out of the pelvis through the lesser sacro-ischiatic foramen, and is *inserted* by a flattened tendon into the digital fossa of the trochanter major. The lesser sacro-ischiatic notch, over which this muscle plays as through a

pulley, is faced with cartilage, and provided with a synovial bursa to facilitate its movements. The tendon of the obturator is supported on each side by the two gemelli muscles (hence their names,) which are inserted into the sides of the tendon, and appear to be auxiliaries or superadded portions of the obturator internus.

Fig. 102. The deep muscles of the gluteal region.



1. The external surface of the ilium. 2. The posterior surface of the sacrum. 3. The posterior sacro-iliac ligaments. 4. The tuberosity of the ischium. 5. The great or posterior sacro-ischiatic ligament. 6. The lesser or anterior sacro-ischiatic ligament. 7. The trochanter major. 8. The gluteus minimus. 9. The pyriformis. 10. The gemellus superior. 11. The obturator internus muscle, passing out of the lesser sacro-ischiatic foramen. 12. The gemellus inferior. 13. The quadratus femoris. 14. The upper part of the adductor magnus, 15. The vastus externus. 16. The biceps. 17. The gracilis. 18. The semi-tendinosus.

The *Gemellus inferior* arises from the posterior point of the tuberosity of the ischium, and is *inserted* into the lower border of the tendon of the obturator internus, and into the digital fossa of the trochanter major.

Placed deeply between the gemellus inferior and the quadratus femoris, may be seen the tendon of the obturator externus, becoming more superficial as it passes outwards to its *insertion* into the digital fossa of the trochanter major: it

arises from the external surface of the obturator ligament, and from the margin of bone immediately surrounding it. (Page 362.)

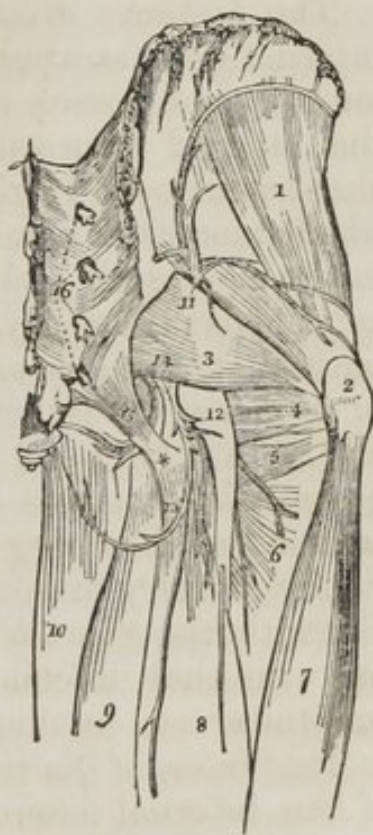The *Quadratus femoris*, 5. (square-shaped) *arises* from the external border of the tuberosity of the ischium, and is *inserted* into a rough line on the posterior border of the trochanter major, which is thence named *linea quadrati*.

ACTIONS.—The glutei muscles are abductors of the thigh, when they take their fixed point from the pelvis. Taking their fixed point from the thigh, they steady the pelvis on the head of the femur: this action is peculiarly obvious in standing on one leg: they assist also in carrying the leg forward, in progression. The gluteus minimus being attached to the anterior border of the trochanter major, rotates the limb slightly inwards. The gluteus medius and maximus, from their insertion into the posterior aspect of the bone, rotate the limb outwards: the latter is, moreover, a tensor of the fascia of the thigh. The other muscles rotate the limb outwards, everting the knee and foot; hence they are named external rotators.

The gluteal artery and nerve (*fig. 103. 11.*) are found immediately above the pyriformis muscle; the other vessels and nerves, 12. 14., immediately beneath that muscle.

The *Gluteal artery* is a branch of the internal iliac; it passes out of the pelvis through the great sacro-ischiatic foramen, above the pyriformis muscle, and immediately divides into three branches. 1st. A *superficial* branch directed backwards, and distributed to the gluteus maximus. 2. A *deep superior* branch, which passes along the superior curved line of the dorsum of the ilium, between the

Fig. 103. A deep posterior view of the anatomy of the hip; showing the muscles, vessels, and nerves, which are exposed by the removal of the gluteus maximus muscle.



1. The gluteus minimus muscle. 2. The trochanter major of the femur.
3. The pyriformis muscle. 4. The tendon of the obturator internus muscle, bounded above by the gemellus superior, and below by the gemellus inferior.

5. The quadratus femoris muscle. 6. The adductor magnus. 7. The vastus externus muscle. 8. The long head of the biceps. 9. The semi-tendinosus. 10. The gracilis. 11. The gluteal artery and nerve, escaping from the pelvis above the pyriformis muscle. 12. The great ischiatic nerve. 13. The lesser ischiatic nerve, and between the two the ischiatic artery. 14. The pudic artery and nerve. All these vessels and nerves pass out from the pelvis below the pyriformis muscle. 15. The great or posterior sacro-ischiatic ligament. The tuberosity of the ischium. 16. The posterior branches of the sacral nerves.

gluteus medius and minimus, to the anterior superior spinous process, where it terminates by anastomosing with the superficial circumflexa illi and external circumflex arteries. It is distributed to the gluteus medius and minimus muscles. 3. A *deep inferior* branch, which descends obliquely upon the gluteus minimus muscle to the trochanter major, and inosculates with the external circumflex artery.

The arteries in this region, are all branches of the internal iliac within the pelvis, and the nerves are derived from the sacral plexus; hence, a part of their course cannot, at present be seen. They all quit the pelvis through the great sacro-ischiatic foramen.

The *Ischiatic artery*, one of the terminal branches of the internal iliac, escapes from the pelvis beneath the pyriformis muscle, and passes downwards with the ischiatic nerves, in the interval between the tuberosity of the ischium and trochanter major. It gives off three branches. 1st. *Coccygeal*, which pierces the sacro-ischiatic ligament, and is distributed to the coccygeus and levator ani muscles, and to the integument about the coccyx. 2. *Inferior gluteal*,—several muscular branches supplying the lower part of the gluteus maximus. 3. *Comes nervi ischiatici* (companion to the ischiatic nerve,) a small but long and regular branch, which accompanies the great ischiatic nerve.—Besides these, branches are distributed to the neighbouring muscles, the external rotators. The ischiatic artery inosculates with all the surrounding arteries, viz. with the gluteal, internal pudic, obturator, the external and internal circumflex, and superior perforating of the profunda.

The *Internal pudic artery*, 14., the other terminal branch of the internal iliac, also issues from the pelvis, through the great ischiatic foramen below the pyriformis, to disappear immediately beneath the great sacro-ischiatic ligament, and pursue its course within the pelvis.

From the description usually given of this artery, the student might imagine that its course was extremely eccentric, going out of the pelvis and then going in. But if he refer again to his skeleton and to the subject, he will see that the artery forms the most gentle curve imaginable in this part of its course; and that its various relation to the pelvis depends entirely upon the projection inwards of the spine of the ischium, upon which the artery, with its vein and nerve, rest in this region.

Upon entering, then, the lesser ischiatic foramen, the internal pudic artery crosses the lower part of the obturator internus muscle to the ramus of the ischium, along which, and the ramus of the pubis, it ascends to the symphysis. Its branches are distributed to the perineum.

The *Veins*, as in all the secondary arteries of the body, are placed by the sides of the arteries in pairs, which are called "*venæ comites.*"

Nerves of the Gluteal Region.

The *Gluteal nerve* (*fig. 103. 11., fig. 107. 2.*) is a branch of the lumbo-sacral (5th lumbar:) it leaves the pelvis with the gluteal artery, and distributes filaments with each arterial branch.

The *Lesser ischiatic nerve* (*fig. 103. 13., fig. 107. 6.*) is a branch of the sacral plexus; it passes out of the pelvis through the great sacro-ischiatic foramen beneath the pyriformis muscle, and divides into four sets of branches. 1st. *Inferior gluteal*, supplying the lower part of the gluteus maximus. 2. *Internal posterior cutaneous*, a branch that winds around the tuberosity of the ischium, and supplies the integument of the perineum and of the inner and posterior side of the thigh. 3. *Middle posterior cutaneous*, one or two branches of which pierce the fascia, and run down the middle of the posterior aspect of the thigh, supplying the integument. 4. The proper continuation of the nerve upon the flexor muscles as far as the popliteal region.

The *Great ischiatic nerve* (*fig. 103. 12., fig. 107. 7.*) is the largest in the body; it is formed by the sacral plexus, or rather it is a prolongation of the plexus. At its exit from the great sacro-ischiatic foramen beneath the pyriformis, it measures three quarters of an inch in breadth. It descends through the middle of the space between the trochanter

major and tuberosity of the ischium into the thigh. In its course it rests on the gemellus superior tendon of the obturator internus, gemellus inferior, and quadratus femoris muscles, and in the thigh upon the adductor magnus muscle; it is covered in by the three flexor muscles of the leg. While in the gluteal region, it gives off merely a few muscular branches.

This nerve is sometimes formed of two portions, one of which pierces the piriformis muscle. At other times, the two portions remain separate all the way down the thigh.

The *Internal pudic nerve* (fig. 103. 14., fig. 107. 5.,) also a branch of the sacral plexus, follows the course and distribution of the internal pudic artery, giving off filaments with each of its branches.

Posterior Femoral Region.

Carry an incision along the middle of the posterior aspect of the thigh, as far as the bend of the knee. Bound it in this situation by a transverse incision, and reflect the integument to either side. In the superficial fascia will be seen the two cutaneous branches of the lesser ischiatic nerve, and two or three cutaneous branches from the great ischiatic.

Upon removing the superficial fascia, the *deep fascia* will be found to be extremely thin; and, on turning it aside, we bring into view the three muscles of this region, the flexors of the leg—

Biceps.

Semi-tendinosus.

Semi-membranosus.

The *Biceps flexor cruris* (bi, double—caput head) *arises* by two heads, one by a common tendon with the semi-tendinosus; the other muscular, and much shorter, from the lower two-thirds of the external border of the linea aspera. This muscle forms the outer ham-string, and is *inserted* by a strong tendon into the head of the fibula.

The *Semi-tendinosus*, remarkable for its long tendon, *arises* in common with the long head of the biceps from the tuberosity of the ischium. It is *inserted* into the inner tuberosity of the tibia.

These two muscles must be dissected from the tuberosity of the ischium to bring into view the origin of the next.

The *Semi-membranosus*, remarkable for the tendinous expansion upon its anterior and posterior surfaces, *arises* from

the tuberosity of the ischium, in front of the common origin of the two preceding muscles. It is *inserted* into the posterior part of the head of the tibia; at its insertion, the tendon splits into three portions, one of which is inserted in a groove on the inner side of the head of the tibia, beneath the internal lateral ligament. The second is continuous, with an aponeurotic expansion that binds down the popliteus muscle; the popliteal fascia; and the third turns upwards and outwards to the external condyle of the femur, forming the posterior ligament of the knee-joint (ligamentum posticum Winslowii.)

The tendons of the last two muscles, viz., the semi-tendinosus and semi-membranosus, with those of the gracilis and sartorius, form the inner hamstring.

If the semi-membranosus muscle be turned down from its origin, the student will bring into view the broad and radiated expanse of the adductor magnus, upon which the three flexor muscles above described rest.

ACTIONS.—These three hamstring muscles are the direct flexors of the leg upon the thigh; and, by taking their origin from below, they balance the pelvis on the lower extremities.

Arteries of the Posterior Femoral Region.

The *Arteries* of this region are the terminal branches of the external and internal circumflex, the three perforating, the termination of the profunda femoris, and the popliteal.

The branches of the *external circumflex* are seen piercing the upper part of the vastus externus, to inosculate with the internal circumflex, ischiatic, and superior perforating arteries. The *internal circumflex* makes its appearance between the upper border of the adductor magnus, and the lower border of the quadratus femoris. It inosculates with the external circumflex, ischiatic, and superior perforating arteries.

The three perforating arteries emerge on the posterior aspect of the thigh, by passing through tendinous arches between the adductor magnus and the linea aspera. They anastomose with each other, with the circumflex and ischiatic arteries above, and with the articular branches of the popliteal below. The profunda escapes through the adductor magnus, close to the linea aspera, and is protected from pressure by a tendinous arch which is thrown across the bone. It makes its appearance at about an inch above the commencement of the popliteal artery.

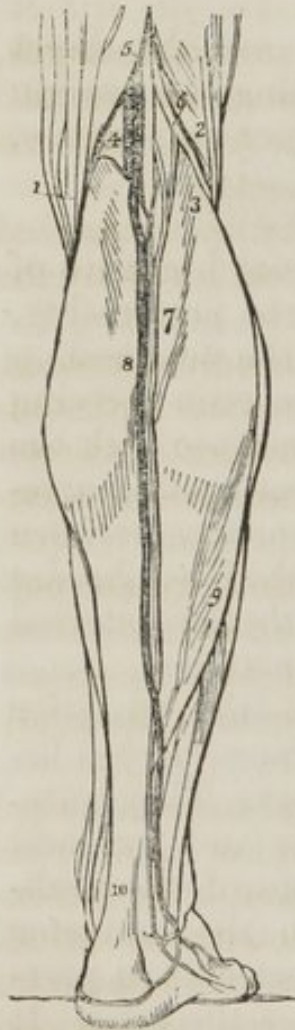The *Nerves* in this region are the greater and lesser ischiatic. The continuation of the lesser ischiatic is seen upon the semi-tendinosus muscle.

The *Great ischiatic nerve* (*fig. 107. 7.*) runs down the middle of the posterior femoral region, being situated between the flexor muscles and the adductor magnus. At the lower third of the thigh it divides into two nerves of nearly equal size, the *popliteal*, 9., and *peroneal*, 8. Its branches are simply muscular and cutaneous.

Popliteal Region.

The lower part of the posterior femoral region is a surgical region of some importance, the popliteal. We shall, therefore, describe it separately.

Fig. 104. The popliteal region, and the superficial anatomy of the calf of the leg.



The popliteal region (*fig. 104.*) is a diamond-shaped space, bounded above on each side by the two hamstrings 1. 2., and below by the two heads, 3. 3., of the great muscle of the calf, the gastrocnemius. On dissecting back the integument, a large vein, 8., which runs up the middle of the posterior part of the leg, *the external saphenous*, is seen between the layers of the superficial fascia. To this several cutaneous veins converge, which must be divided in making an incision for the purpose of reaching the artery. If the superficial fascia be dissected away, the external saphenous vein will be seen passing through an oval foramen in the deep popliteal fascia, to terminate in the popliteal vein.

The *deep popliteal fascia* is thin, and will be removed without being observed, unless the dissector proceed cautiously. It is a part of the common deep fascia investing the entire limb. Beneath the deep fascia is a quantity of adipose substance which fills up the whole popliteal space, from the bone and joint to the surface, and protects and supports the popliteal vessels and nerves.

1. The inner hamstring. 2. The outer hamstring. 3, 3. The two heads of the gastrocnemius muscle. 4. The popliteal artery, vein, and nerve, in

their relative position from within outwards; the artery being the deepest, next the vein, and the nerve quite superficial. 5. The termination of the ischiatic nerve dividing into the popliteal nerve, and 6. the peroneal. 7. The external saphenous nerve, formed by the union of the *communicans peronei*, from the peroneal, and *communicans poplitei* from the popliteal nerve. 8. The external saphenous vein. 9. The outer border of the soleus muscle. 10. The tendo Achillis.

It will be recollected, that at the upper part of this popliteal space the great ischiatic nerve divides into two branches of nearly equal size—the popliteal and peroneal. The popliteal, 4., runs along the middle line of this space, from apex to apex of its diamond-shaped area. It is placed near to the surface, and is easily found on slightly separating the adipose tissue. This nerve divides the region into two equal halves: in the external one will be found two small nerves, branches of the popliteal and peroneal, called *communicans poplitei* and *communicans peronei*, and the peroneal nerve itself, 6., lying along the tendon of the biceps muscle.

To the *inner* side of the popliteal nerve, at a variable depth, is the *popliteal vein*, to which the external saphenous vein will serve as a guide, and to the *inner* side of the vein, and still deeper, resting on the femur, is the *popliteal artery*.

The *floor* of the popliteal space is formed by the expanded inferior extremity of the femur, by the knee-joint, and by the popliteal muscle immediately below the joint.

The *Popliteal artery* (*fig.* 103. 5.) runs obliquely outwards, through the middle of the popliteal space, *from* the tendinous opening in the adductor magnus, *to* the lower border of the popliteus muscle, where it divides into the anterior and posterior tibial arteries.

RELATIONS.—It rests first on the femur, then on the posterior ligament of the knee-joint, then on the fascia covering the popliteus muscle: superficial and external to it is the popliteal vein, and still more superficial and external, the popliteal nerve.

The *Superior articular* arteries, *external* and *internal*, wind around the femur immediately above the condyles, to the front of the knee-joint, anastomosing with each other, with the external circumflex, the *anastomotica magna*, the inferior articular and the recurrent of the anterior tibial. The external passes beneath the tendon of the biceps, and the internal through an arched opening beneath the tendon of the abductor magnus.

The *Azygos articular* artery pierces the posterior ligament

of the joint, ligamentum posticum Winslowii, and supplies the synovial membrane, in its interior.

The *Inferior articular* arteries wind around the head of the tibia, immediately below the joint, and anastomose with each other, the superior articular arteries, and the recurrent of the anterior tibial. The external passes beneath the two external lateral ligaments of the joint, and the internal beneath the internal lateral ligament.

The *Sural* arteries (sura, the calf) are muscular branches of large size and variable number, distributed to the gastrocnemius and soleus muscles.

Popliteal nerve (*fig.* 104. 4., *fig.* 107. 9.) runs through the middle of the popliteal space, from the division of the great ischiatic nerve to the lower border of the popliteus muscle, where it passes with the artery beneath the arch of the soleus, and becomes the posterior tibial nerve. It is superficial in the whole of its course, and lies externally to the vein and artery.

Its *branches* are *muscular* or *sural* (*fig.* 107. 10.,) which are distributed to the muscles of the calf; and the *communicans poplitei*, which unites with a similar branch, *communicans peronei*, from the peroneal nerve, to form the external saphenous nerve, (*fig.* 104. 7., *fig.* 107. 16.)

The *Peroneal nerve* (*fig.* 104. 6., *fig.* 107, 8.) descends by the side of the tendon of the biceps to the head of the fibula, pierces the origin of the peroneus longus muscle, and divides into two branches, the anterior tibial, (*fig.* 107. 13.) and musculo-cutaneous, 14. It gives off but one branch in its course, the *communicans peronei* which unites with the *communicans poplitei*.

Dissection of the Leg.

The leg is naturally divided into three regions, *anterior tibial*, *fibular*, and *posterior tibial*. Each region is composed of its appropriate muscles, vessels, and nerves. Those of the anterior tibial region may be thus arranged:

Superficial to the fascia.

Tibial recurrent artery,
Peroneal cutaneous nerve,
Internal saphenous vein,
Internal saphenous nerve,

Beneath the fascia.

Tibialis anticus,
Extensor longus digitorum,
Peroneus tertius,
Extensor proprius pollicis,
Anterior tibial artery,
Anterior tibial nerve.

The student will find it convenient, before commencing the dissection of the leg, to separate the limb from the rest of the body, by dividing the muscles, and sawing across the femur at about its middle. This step is better than disarticulating at the hip-joint, as it gives him an opportunity, at an after period, of studying the ligaments of the hip. The dissection of the anterior tibial region is to be commenced by carrying an incision along the middle of the leg, midway between the tibia and the fibula, from the knee to the ankle, and bounding it inferiorly by a transverse incision, extending from one malleolus to the other. And to expose the tendons on the dorsum of the foot, the longitudinal incision may be carried onwards to the outer side of the base of the great toe, and be terminated by another incision directed across the heads of the metatarsal bones.

When the integument of these two regions has been turned aside, a small artery must be sought for near the head of the tibia, which pierces the deep fascia, and turns upwards upon the knee-joint, to inosculate with the articular arteries. This is the *recurrent branch* of the *anterior tibial* artery.

The *superficial fascia* may now be dissected from off the deep fascia. At the lower third of the leg, this separation must be conducted with care, for two nerves of considerable size will be found piercing the deep fascia near to the fibula, and running downwards in the superficial fascia to the dorsum of the foot. These are the *peroneal cutaneous nerves*, (*fig. 107. 15.*) the cutaneous division of the musculo-cutaneous branch of the peroneal. These branches must be traced with care, following each filament, and separating it from the adhering cellular tissue. They are distributed to all the toes. The *external*, the larger of the two, will be found supplying three toes and a half; the *internal*, the great toe, and one-half the second.

If the inner flap of the integument in the leg be dissected farther back, so as to expose the inner condyle of the femur and the superficial fascia behind the tibia and internal malleolus, the course of a vein of considerable size will be exposed in its entire length. Below, it will be seen resting on the internal malleolus, and collecting its blood by numerous small branches from the inner side of the dorsum of the foot. This is the commencement of the *internal saphenous vein*. It next runs upwards along the inner side of the leg, behind the inner

condyle of the femur, and may be traced along the inner side of the thigh (*fig. 95. 9.*) to the saphenous opening.

Immediately beneath the inner condyle of the femur, the *internal saphenous nerve* (*fig. 98. 11.*) a branch of the anterior crural, will be seen piercing the deep fascia, after having passed between the tendons of the sartorius and gracilis muscles. The nerve descends by the side of the vein, giving off cutaneous branches in its course, crosses the inner malleolus, and is distributed to the inner side of the foot and great toe, and communicates with the internal cutaneous branch of the fibular cutaneous.

The *deep fascia* is strong and tendinous, and firmly attached to the tibia and fibula. By its internal surface it gives origin to the muscles of this region, and between the two malleoli it forms a dense band, called *anterior annular ligament*, which binds down the tendons of the extensor muscles in their passage forwards to the dorsum of the foot.

An incision may now be made through the deep fascia, in the course of a line drawn from the midpoint between the head of the fibula and spine of the tibia, to midway between the inner and outer malleolus. This will mark the course of the anterior tibial artery: and an incision made in any part of this line will expose that vessel in its course between the muscles. The structures to be divided, are the same as in any other part of the body.

The deep fascia is easily separated from the muscles in the lower part of the leg, but above it is closely connected to them, and cannot be removed without dividing some of their fibres.

Muscles of the anterior tibial region:

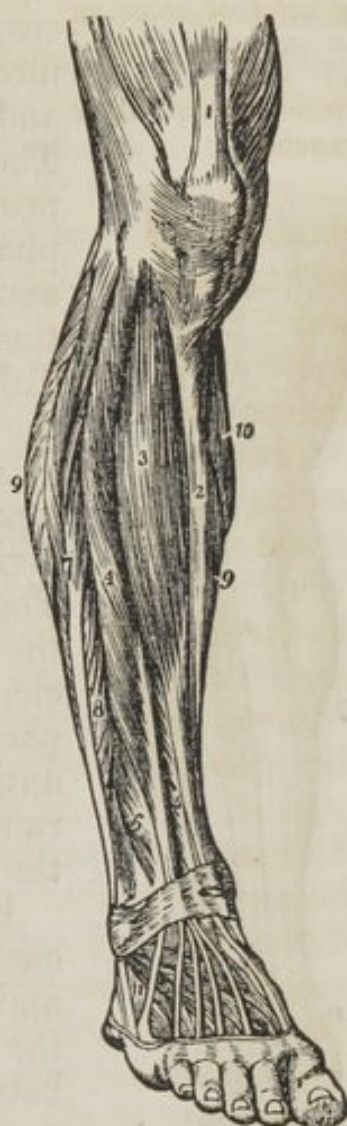Tibialis anticus,
Extensor communis digitorum,
Peroneus tertius,
Extensor proprius pollicis.

The *Tibialis anticus* muscle (*flexor tarsi tibialis*) arises from the upper two-thirds of the tibia, from the interosseous membrane, and from the deep fascia; its tendon passes through a distinct sheath in the annular ligament, and is *inserted* into the inner side of the internal cuneiform bone, and base of the metatarsal bone of the great toe.

The *Extensor longus digitorum* arises from the head of the tibia, from the upper three-fourths of the fibula, from the interosseous membrane, and from the deep fascia. Below it divides into four tendons, which pass beneath the annular ligament, to be *inserted* into the second and third phalanges of the four lesser toes. The mode of insertion of the extensor tendons, both in the hand and in the foot, is remarkable (*fig. 81.*;) each tendon spreads into a broad aponeurosis over the first phalanx; this aponeurosis divides into three slips, the middle one is inserted into the base of the second phalanx, and the two lateral slips are continued onwards to be inserted into the base of the third.

The *Peroneus tertius* (flexor tarsi fibularis) arises from the lower fourth of the fibula, and is *inserted* into the base of the metatarsal bone of the little toe. Although it appears to be merely a part of the extensor longus digitorum, it may be looked upon as analogous to the flexor carpi ulnaris of the fore-arm. Sometimes it is altogether wanting.

Fig. 105. The muscles of the anterior tibial region.

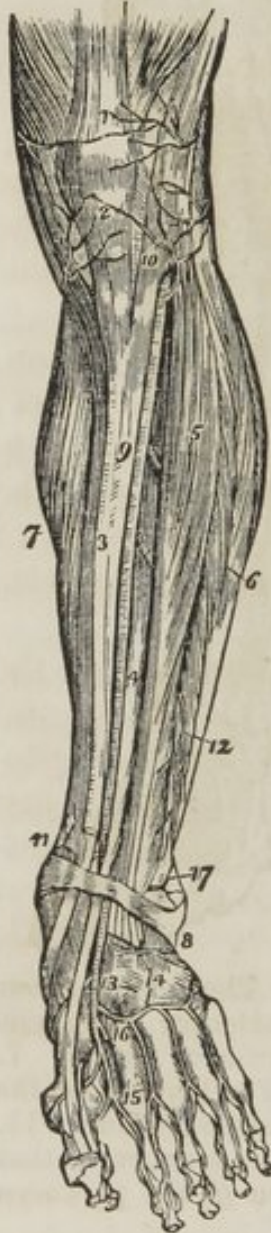

1. The extensor muscles inserted into the patella. 2. The subcutaneous surface of the tibia. 3. The tibialis anticus. 4. The extensor communis digitorum. 5. The extensor proprius pollicis. 6. The peroneus tertius. 7. The peroneus longus. 8. The peroneus brevis. 9. 9. The borders of the soleus muscle. 10. A part of the inner belly of the gastrocnemius. 11. The extensor brevis digitorum; the tendon in front of this number is that of the peroneus tertius; and that behind it, the tendon of the peroneus brevis.

The *Extensor proprius pollicis* lies between the tibialis anticus and extensor longus digitorum. It *arises* from the lower two-thirds of the fibula and interosseous membrane. Its tendon passes through a distinct sheath in the annular ligament, and is *inserted* into the base of the last phalanx of the great toe.

ACTIONS.—The tibialis anticus and peroneus tertius are

Fig. 106. The anterior aspect of the leg and foot, showing the anterior tibial and dorsalis pedis arteries, with their branches.



direct flexors of the tarsus upon the leg, acting in conjunction with the tibialis posticus, and peroneus longus and brevis; they direct the foot either inwards or outwards, and preserve its flatness in progression. The extensor longus digitorum, and extensor proprius pollicis, are direct extensors of the phalanges: but continuing their action, they assist the tibialis anticus and peroneus tertius, in flexing the entire foot upon the leg. Taking their origin from below, they increase the stability of the ankle.

Anterior tibial artery.—We have seen in a previous section, that the popliteal artery divides into the anterior and posterior tibial. The *anterior tibial* passes forwards between the two heads of the tibialis posticus muscle, then through the opening in the upper part of the interosseous membrane, to the anterior tibial region. From this point it runs down the anterior aspect of the leg to the ankle joint.

RELATIONS.—It rests upon the interosseous membrane, the lower part of the tibia, and the anterior ligament of the joint. In the upper third of its course it is situated between the tibialis anticus and extensor communis digitorum, lower down between the tibialis anticus and extensor proprius pollicis; and just before it reaches the ankle it is crossed by the tendon of the extensor proprius pollicis, and becomes placed between that tendon and the tendons of the extensor longus digitorum.

1. The tendon of insertion of the quadriceps, extensor muscle. 2. The insertion of the ligamentum patellæ into the lower border of the patella. 3. The tibia. 4. The extensor proprius pollicis muscle. 5. The extensor longus digitorum. 6. The peronei muscles. 7. The inner belly of the gastrocnemius and the soleus. 8. The annular ligament beneath which the extensor tendons and the anterior tibial artery pass into the dorsum of the foot. 9. The anterior tibial artery. 10. Its recurrent branch inosculating with (2) the inferior articular, and (1) the super articular artery, branches of the popliteal. 11. The internal malleolar artery. 17. The external malleolar inosculating with the anterior peroneal artery, 12. 13. The dorsalis pedis

artery. 14. The tarsea and metatarsa arteries; the tarsea is nearest the ankle, the metatarsa is seen giving off the interosseæ. 15. The dorsalis hallucis artery. 16. The communicating branch.

The *Branches* of the anterior tibial artery are the following:—

Anterior tibial.	{	Recurrent, Muscular, External malleolar, Internal malleolar.
------------------	---	---

The *Recurrent* branch passes upwards to the front of the knee-joint upon which it is distributed, anastomosing with the articular arteries. It pierces the origin of the tibialis anticus muscle.

The *Muscular* branches supply the muscles of this region.

The *Malleolar arteries* are distributed to the ankle joint; the *external* passing beneath the tendons of the extensor longus digitorum and peroneus tertius, and inosculating with the anterior peroneal artery; the *internal* beneath the tendons of the extensor proprius pollicis and tibialis anticus, inosculates with branches of the posterior tibial artery.

The *Anterior tibial nerve* (fig. 97. 13.) commences at the bifurcation of the peroneal upon the head of the fibula, and passes beneath the upper part of the extensor longus digitorum, to reach the outer side of the anterior tibial artery, just as that vessel has passed through the opening in the interosseous membrane. It descends with the artery, lying at first to its outer side, and then in front of it, and near the ankle becomes again placed to its outer side. It supplies the muscles of the anterior tibial region, and terminates in the dorsalis pedis nerve.

Dorsal Region of the Foot.

The deep fascia in this region is extremely thin, and can hardly be said to exist; the muscles on the dorsum of the foot are,

Extensor brevis digitorum,	
4 Dorsal interossei	{
	bicipital
	{
	1 adductor,
	3 abductors.

The *Extensor brevis digitorum* muscle arises from a tubercle on the outer side of the os calcis, crosses the foot obliquely, and terminates in four tendons, the innermost of which is inserted into the base of the first phalanx of the great toe, and

the other three into the sides of the long extensor tendons of the second, third, and fourth toes.

The *Dorsal interossei* muscles are placed between the metatarsal bones; they resemble the analogous muscles in the hand in *arising* by two heads from the adjacent sides of the metatarsal bones; their tendons are *inserted* into the base of the first phalanx, and into the digital expansion of the tendons of the long extensor.

The *First dorsal interosseous* is *inserted* into the inner side of the second toe, and is therefore an *adductor*; the other three are *inserted* into the outer side of the second, third, and fourth toes, and are therefore *abductors*.

Communicating arteries (perforantes,) between the dorsum and sole of the foot, pass between the bifid origins of these muscles.

The *Artery* of the dorsum of the foot, *Dorsalis pedis*, is the continuation of the anterior tibial: it runs along the dorsum of the foot, from the ankle to the base of the metatarsal bone of the great toe: here it divides into two branches, the *communicating*, which passes between the two heads of the first dorsal interosseous, and inosculates with the termination of the external plantar artery and the *dorsalis hallucis*, which runs forwards upon the first dorsal interosseous muscle, and at the base of the first phalanx divides into two branches, which supply the adjacent sides of the great and second toes.

RELATIONS.—The *dorsalis pedis* is situated along the outer border of the tendon of the extensor proprius pollicis; on its fibular side is the tendon of the extensor longus digitorum, and near to its termination it is crossed by the inner tendon of the extensor brevis digitorum.

BRANCHES :

Dorsalis pedis,
 Tarsea,
 Metatarsea,—interosseæ,
 Communicating,
 Dorsalis hallucis,—collateral digital.

The *Tarsea* arches transversely across the tarsus, supplying the articulations of the tarsal bones and the outer side of the foot; it anastomoses with the external malleolar and posterior peroneal arteries.

The *Metatarsea* forms an arch across the base of the metatarsal bones, and supplies the outer side of the foot; it sends branches (interosseæ) to the dorsal interossei muscles, and re-

ceives communicating branches (perforates) from the plantar arch.

The *Nerves* supplying the dorsum of the foot are five in number :

Internal peroneal cutaneous,
External peroneal cutaneous,
Anterior tibial,
External saphenous,
Internal saphenous.

The *Peroneal cutaneous* nerves have been described at page 375.: they communicate with the three other nerves.

The *Anterior tibial* nerve accompanies the dorsalis pedis artery, supplying the extensor brevis digitorum and the great toe, and communicates with the internal peroneal cutaneous.

The *External saphenous* nerve passes from the posterior part of the leg behind the outer malleolus, and is distributed to the outer border of the foot, accompanying the branches of the external saphenous vein. This nerve usually communicates with the external peroneal cutaneous by means of a large branch.

The *Internal saphenous* nerve crosses the inner ankle by the side of the internal saphenous vein, and is distributed to the inner border of the foot and great toe. It sends, or receives a communicating branch from the internal peroneal cutaneous.

Fibular Region.

If the leg be turned upon its inner side, and the deep fascia be removed from over the fibula, two muscles will be exposed which arise from that bone; these are the peroneus longus and brevis.

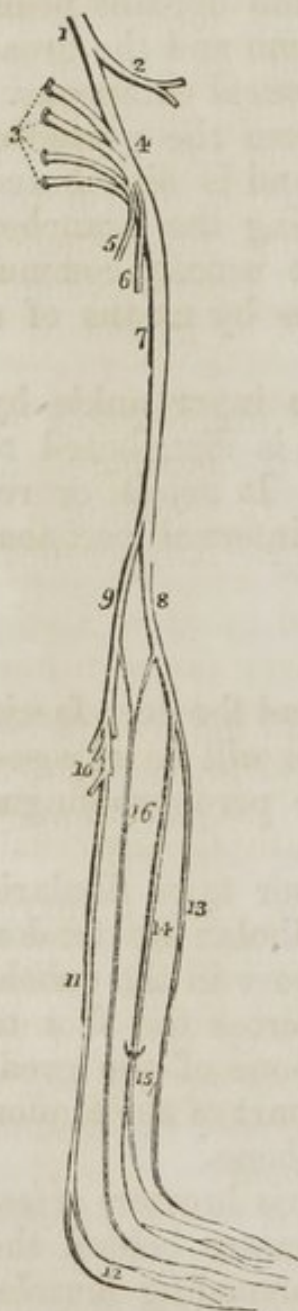
The *Peroneus longus* ($\pi\epsilon\rho\omega\nu\eta$, fibula, extensor tarsi fibularis longior) arises from the upper third of the fibula: its tendon passes behind the outer malleolus to a groove in the cuboid bone, through which it proceeds obliquely across the foot to be *inserted* into the base of the metatarsal bone of the great toe. A sesamoid bone is developed in that part of the tendon which is lodged in the groove of the cuboid bone.

The *Peroneus brevis* (extensor tarsi fibularis brevior) arises from the lower two-thirds of the fibula, passes behind the external malleolus, with the tendon of the preceding muscle, and is *inserted* into the base of the metatarsal bone of the little toe.

ACTIONS.—The peronei muscles are extensors of the foot conjointly with the tibialis posticus. They antagonize the tibialis anticus and peroneus tertius, which are flexors of the foot. The whole of these muscles acting together tend to maintain the flatness of the foot, so necessary to security in walking.

There is no artery in this region; but if the peroneus longus be carefully turned down from its origin, the peroneal nerve and its branches will be exposed.

Fig. 107. A diagram showing the formation and branches of the sacral plexus.



The *Peroneal nerve* (*fig. 107. 8.*) descends from the division of the great ischiatic nerve, along the tendon of the biceps, to the head of the fibula, where it pierces the origin of the peroneus longus muscle. At this point it divides into two branches, anterior tibial, 13., and musculo-cutaneous, 14.

The *Anterior tibial nerve*, 13. passes through the upper part of the extensor longus digitorum muscle, and accompanies the anterior tibial artery, lying at first to the outer side and then resting upon that vessel. Upon the dorsum of the foot it lies by the side of the dorsalis pedis artery, and is distributed to the adjoining sides of the great and second toes, after having supplied the muscles on the dorsum of the foot.

The *Musculo-cutaneous nerve*, 14., passes for a short distance between the peroneus longus and extensor longus digitorum, both of which muscles it supplies; hence its title "musculo." At the lower third of the leg it pierces the deep fascia, and divides into the two peroneal cutaneous nerves of the foot; hence "cutaneous."

The *Peroneal cutaneous nerves*, 15., are distributed to the integument on the dorsum of the foot, and to all the toes; the *internal* supplying one and a half, and the *external* three and a half.

1. The lumbo sacral nerve, descending to join the sacral plexus, and giving off a large branch. 2. The gluteal nerve. 3. The anterior branches of the four upper sacral nerves. 4. The sacral plexus. 5. The internal pudic nerve. 6. The lesser ischiatic nerve. 7. The great ischiatic nerve. 8. The peroneal nerve. 9. The popliteal nerve. 10. Its sural branches. 11. The posterior tibial nerve dividing inferiorly into the two plantar nerves, 12. 13. The anterior tibial nerve. 14. The musculo-cutaneous nerve, its muscular portion. 15. Its cutaneous portion. 16. The external saphenous nerve, formed by the union of the *communicans poplitei*, and *communicans peronei*.

Posterior Tibial Region.

This region is best dissected by making an incision from the middle of the popliteal space, down the middle of the posterior part of the leg, to the tuberosity of the os calcis, bounding it inferiorly by a transverse incision to each malleolus. Turning aside the two flaps of integument, the superficial fascia is brought into view, and between its two layers in the middle line of the calf, the external saphenous vein and nerve.

The *External saphenous vein* (*fig. 104. 8.*) commences by small branches on the outer border of the foot, ascends *behind* the external malleolus towards the groove between the two bellies of the gastrocnemius, and terminates by piercing the deep fascia in the middle of the popliteal space, and opening into the popliteal vein.

The *External saphenous nerve* (*fig. 104. 7., fig. 107. 16.*) will be found lying by the side of this vein. It is formed by the union of two branches, *communicans poplitei* and *communicans peronei*, from the two divisions of the great ischiatic nerve. The nerve thus formed pierces the deep fascia below the fleshy part of the gastrocnemius muscle, and descends by the side of the external saphenous vein, supplying the integument in its course to the outer border of the foot to which its branches are distributed, communicating with the external peroneal cutaneous nerve.

The *Deep fascia*, in the upper part of this region, is thin: below it becomes thicker. It is connected on each side with the tibia and fibula, and at the ankle forms the internal and external annular ligaments. If the deep fascia be turned aside, the three muscles forming the superficial group of this region will be brought into view.

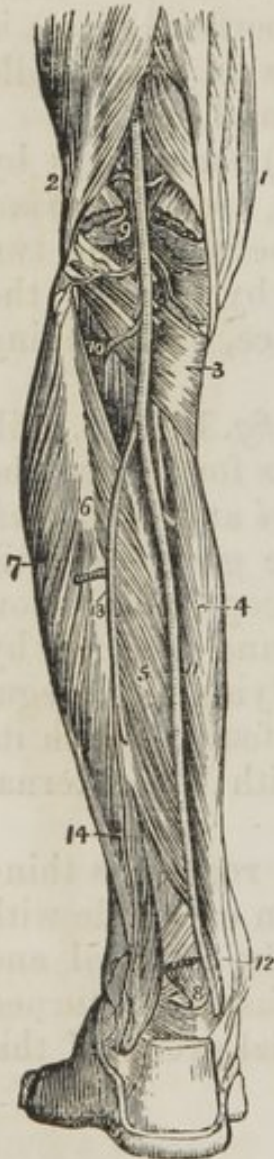Gastrocnemius,
Plantaris,
Soleus.

The *Gastrocnemius* (*γαστροκνημιον*, the bellied part of the leg) arises by two heads from the two condyles of the femur, the

inner head being the longest. They unite to form the beautiful muscle so characteristic of this region of the limb. It is *inserted*, by means of the tendo Achillis, into the lower part of the tuberosity of the os calcis, a synovial bursa being placed between the tendon and the upper part of the tuberosity. The gastrocnemius must be removed from its origin, and turned down, in order to expose the next muscle.

The *Plantaris* (planta, the sole of the foot), an extremely diminutive muscle, situated between the gastrocnemius and soleus, *arises* from the outer condyle of the femur, and is *inserted* by its long and delicately slender tendon, into the tuberosity of the os calcis, by the side of the tendo Achillis.

Fig. 108. The superficial muscles of the posterior aspect of the leg.



Between the fibular and tibial origins of this muscle is a tendinous arch, beneath which the popliteal vessels and nerve pass into the leg. The soleus muscle must now be divided along its extensive origin, and turned down.

The *Soleus* (solea, a sole) is the broad muscle upon which the plantaris rests. It *arises* from the head and upper third of the fibula, from the oblique line, and middle third of the tibia. Its fibres converge to the tendo Achillis, by which it is *inserted* into the tuberosity of the os calcis.

ACTIONS.—The three muscles of the calf draw powerfully on the os calcis, and lift the heel; continuing their action, they raise the entire body. This action is attained by means of a lever of the second power, the fulcrum (the toes) being at one end, the weight (the body supported on the tibia) in the middle, and the power (these muscles) at the other extremity.

They are therefore the walking muscles, and perform all movements that require the support of the whole body from the ground, as dancing, leaping, &c. Taking their fixed point from below, they steady the leg upon the foot.

1. The biceps muscle forming the outer hamstring. 2. The tendons forming the inner hamstring. 3. The popliteal space. 4. The gastrocne-

mius muscle. 5. 5. The soleus. 6. The tendo Achillis. 7. The posterior tuberosity of the os calcis. 8. The tendons of the peroneus longus and brevis muscles passing behind the outer ankle. 9. The tendons of the deep layer passing into the foot behind the inner ankle.

DEEP GROUP.

An *Intermuscular fascia* serves to separate the superficial from the deep group, and by its strong attachments to the bones at each side, binds down the muscles closely in their places. On removing this fascia, the muscles are brought clearly into view—

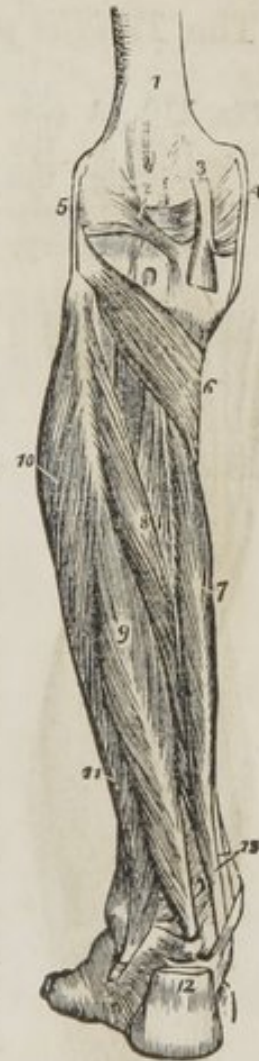Poplitens,
Flexor longus digitorum,
Flexor longus pollicis,
Tibialis posticus.

The *Popliteus* muscle (poples, the ham of the leg) forms the floor of the popliteal region at its lower part, and is bound tightly down by a strong fascia derived from the middle slip (page 384.) of the tendon of the semi-membranosus muscle. It *arises* by a rounded tendon from a deep groove on the outer side of the external condyle of the femur, beneath the external lateral ligament. It spreads obliquely over the head of the tibia, and is *inserted* into the surface of bone above its oblique line. This line is often called, from being the limit of insertion of the popliteus muscle, popliteal line.

The *Flexor longus pollicis* is the most superficial of the three next muscles. It *arises* from the lower two-thirds of the fibula, passes through a distinct tendinous canal into the sole of the foot, and is *inserted* into the base of the last phalanx of the great toe.

1. The lower extremity of the femur. 2. The ligamentum posticum Winslowii. 3. The tendon of the semi-membranosus muscle dividing into its three slips. 4. The internal lateral ligament of the knee-joint. 5. The external lateral ligament. 6. The popliteus muscle. 7. The flexor longus digitorum. 8. The tibialis posticus. 9. The flexor longus pollicis. 10. The peroneus longus muscle. 11. The peroneus brevis. 12. The tendo Achillis divided at its insertion into the os calcis. 13. The tendons of the tibialis posticus and flexor longus digitorum muscles, just as they are about to pass beneath the internal annular ligament of the ankle; the interval between the latter tendon and the tendon of the flexor longus pollicis is occupied by the posterior tibial vessels and nerve.

Fig. 109. The deep layer of muscles of the posterior tibial region.

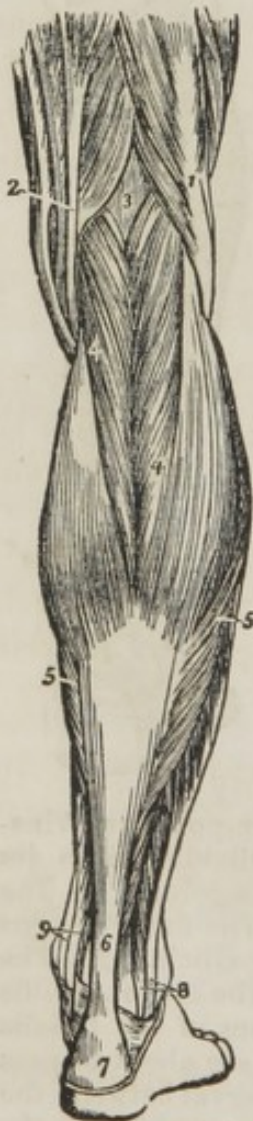

The *Flexor longus digitorum* (perforans) arises from the surface of the tibia, immediately below the popliteal line. Its tendon passes through a sheath common to it and the tibialis posticus behind the inner malleolus into the sole of the foot, where it divides into four tendons, which are inserted into the base of the last phalanx of the four lesser toes, perforating the tendons of the flexor brevis digitorum.

The flexor longus pollicis must now be removed from its origin, and the flexor longus digitorum drawn aside, to bring into view the entire extent of the tibialis posticus.

The *Tibialis posticus* (extensor tarsi tibialis) lies upon the interosseous membrane, between the two bones of the leg. It arises by two heads from the adjacent sides of the tibia and fibula their whole length, and from the interosseous membrane. Its tendon passes inwards beneath the tendon of the flexor longus digitorum, and runs in the same sheath, but internal to it, into the sole of the foot, to be inserted into the tuberosity of the scaphoid and internal cuneiform bone.

Fig. 110. A posterior view of the leg, showing the popliteal and posterior tibial artery.



The student will observe that the two latter muscles change their relative position to each other in their course. Thus, in the leg, the position of the three muscles from within outwards, is flexor longus digitorum, tibialis posticus, flexor longus pollicis. At the inner malleolus, the relation of the tendons is tibialis posticus, flexor longus digitorum, both in the same sheath; then a broad groove, which lodges the posterior tibial artery, venæ comites, and nerve; and lastly, the flexor longus pollicis.

The arteries of the posterior tibial region are,—

Post. tibial	{	peroneal	{	anterior peroneal,
				posterior peroneal.
		muscular.		

The *Posterior tibial artery* runs down the tibial side of the leg, from the lower border of the popliteus muscle to the inner ankle.

1. The tendons forming the inner hamstring. 2. The tendon of the biceps forming the outer hamstring. 3. The popliteus muscle. 4. The flexor longus digitorum. 5. The tibialis posticus. 6. The fibula; immediately below the figure is the origin of the flexor longus pollicis; the muscle has been removed in order to expose the peroneal artery. 7. The peronei muscles, longus and brevis. 8. The lower part of the flexor longus pollicis muscle with its tendon. 9. The popliteal artery giving off its articular and muscular branches; the two superior articular are seen in the upper part of the popliteal space passing above the two heads of the gastrocnemius muscle, which are cut through near to their origin. The two inferior are in relation with the popliteus muscle. 10. The anterior tibial artery passing through the angular interspace between the two heads of the tibialis posticus muscle. 11. The posterior tibial artery. 12. The relative position of the tendons and artery at the inner ankle from within outwards, previously to their passing beneath the internal annular ligament. 13. The peroneal artery, dividing into two branches; the anterior peroneal is seen piercing the interosseous membrane. 14. The posterior peroneal.

RELATIONS.—It rests, 1st, upon the tibialis posticus; 2dly, upon the flexor longus digitorum; 3dly, upon the tibia, and is covered in by the intermuscular fascia.

BRANCHES.—The *Peroneal artery* is given off from the posterior tibial, at about two inches below the lower border of the popliteus muscle; it inclines outwards, and runs along the inner border of the fibula to its lower third, where it divides into its two branches, anterior and posterior peroneal.

RELATIONS.—It rests upon the tibialis posticus, and is covered in by the flexor longus pollicis, having the fibula to its outer side.

The *Anterior peroneal* artery, at the lower third of the leg, pierces the interosseous membrane, and is distributed on the front of the outer malleolus, anastomosing with the external malleolar and tarsal arteries.

The *Posterior peroneal* continues onwards to the posterior aspect of the outer malleolus, anastomosing with the anterior peroneal, tarsal, external plantar, and posterior tibial arteries.

The *Muscular branches* are distributed to the muscles in the course of the posterior tibial artery.

The *Posterior tibial nerve*, which is the only nerve in this region, is a continuation of the popliteal: it lies at first to the outer side of the artery, rests upon it in the middle of its course, and then gets to its outer side again, in which situation it enters the sole of the foot.

Sole of the Foot.

Dissection.—The sole of the foot is best dissected by carrying an incision around the heel, and along the inner and outer borders of the foot, to the great and little toes. This incision should divide the integument and superficial fascia, and both together should be dissected from the deep fascia, as far forward as the base of the phalanges, where they may be removed from the foot altogether.

The *Superficial fascia* is closely adherent to the integument; and, when thus turned up, has the appearance of a dense cushion of fat held down at numerous points by strong cellular tissue.

The *Deep, or plantar fascia*, is a beautiful structure stretched between the under surface of the tuberosity of the calcaneum and the bases of the first phalanges of the toes. It thus serves a double purpose, being mainly instrumental in preserving the convexity of the arch of the foot, while it protects from injurious pressure the soft parts between it and the bones. This fascia is divided into three portions, a middle and two lateral. The *middle portion* is very dense, and is made up of strong tendinous fibres, closely interlaced with each other. It occupies the middle of the sole, and terminates towards the toes in five slips. Each of these slips is subdivided into two smaller slips, which are inserted into the sides of the base of the first phalanx of each toe, and give passage to the flexor tendons. The *lateral portions* are comparatively thin. They cover the muscles on the sides, and are continuous with the deep fascia on the dorsum of the foot. At the junction of the middle with the lateral portions, two septa are sent inwards, and are attached to the under surface of the tarsal bones. These two partitions divide the muscles into three groups, a middle and two lateral.

The lateral portions of the plantar fascia are easily removed from the muscles. The middle portion must be divided through its middle, and each extremity raised separately; the anterior towards the toes, from which it may be divided; the posterior towards the os calcis: this, however, cannot be effected without dividing many of the muscular fibres of the flexor brevis digitorum, which arise from the surface of the fascia.

The muscles of the sole of the foot may be arranged in four layers:—

First Layer.

Abductor pollicis,
Abductor minimi digiti,
Flexor brevis digitorum.

Second Layer.

Tendon of the flexor longus pollicis,
Tendons of the flexor longus digitorum,
Accessorius,
Lumbricales (4.)

Third Layer.

Flexor brevis pollicis,
Adductor pollicis,
Flexor brevis minimi digiti,
Transversus pedis.

Fourth Layer.

Three plantar interossei (all adductors).

The *Abductor pollicis* lies along the inner border of the foot; it *arises* by two heads, between which the tendons of the long flexors, arteries, veins, and nerves enter the sole of the foot. One head *arises* from the inner side of the tuberosity of the calcis, the other from the internal ligament and tuberosity of the scaphoid bone. *Insertion*, into the base of the first phalanx of the great toe.

The *Abductor minimi digiti* lies along the outer border of the sole of the foot. It *arises* from the outer side of the os calcis, and from the base of the metatarsal bone of the little toe, and is *inserted* into the base of the first phalanx of the little toe.

The *Flexor brevis digitorum* (perforatus) is placed between the two preceding muscles. It *arises* from the under surface of the os calcis and plantar fascia, and is *inserted* by four tendons into the base of the second phalanx of the four lesser toes. Each tendon divides, previously to its insertion, to give passage to the tendon of the long flexor: hence its cognomen perforatus.

These muscles are to be divided posteriorly from their origin, and anteriorly through their tendons, and removed. This will bring into view the second layer, and the external plantar artery and nerve, which lie obliquely across it.

At the point where the tendons of the long flexors cross each other, a communicating slip is sent between them which associates their action.

The *Musculus accessorius* arises by two slips from either side of the tuberosity of the os calcis; the inner slip being fleshy, the outer tendinous. It is inserted into the outer side of the tendon of the flexor longus digitorum.

Fig. 111. The first layer of muscles in the sole of the foot; this layer is exposed by the removal of the plantar fascia.

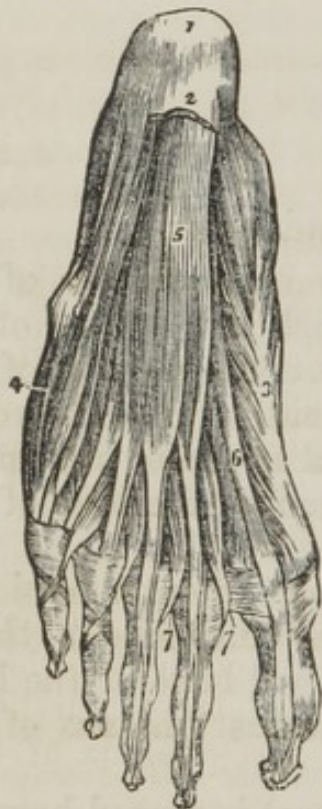

Fig. 112. The third and a part of the second layer of muscles of the sole of the foot.

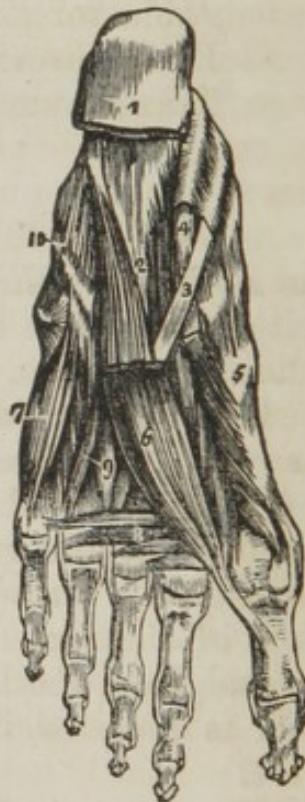

Fig. 111. 1. The os calcis. 2. The posterior part of the plantar fascia divided transversely. 3. The abductor pollicis. 4. The abductor minimi digiti. 5. The flexor brevis digitorum. 6. The tendon of the flexor longus pollicis. 7. 7. The lumbricales. On the second and third toes, the tendons of the flexor longus digitorum are seen passing through the bifurcation of the tendons of the flexor brevis digitorum.

Fig. 112. 1. The divided edge of the plantar fascia. 2. The musculus accessorius. 3. The tendon of the flexor longus digitorum, previously to its division. 4. The tendon of the flexor longus pollicis. 5. The flexor brevis pollicis. 6. The adductor pollicis. 7. The flexor brevis minimi digiti. 8. The transversus pedis. 9. Interossei muscles, plantar and dorsal. 10. A convex ridge formed by the tendon of the peroneus longus muscle in its oblique course across the foot.

The *Lumbricales* (lumbricus, an earthworm) are four little muscles arising from the tibial side of the tendons of the flexor longus digitorum, and inserted into the expansion of the extensor tendons, and into the base of the first phalanx of the four lesser toes.

Dissection.—To expose the third layer of muscles without disturbing the vessels; cut the tendons of the long flexors across through the insertion of the accessorius, and draw that muscle with the tendon backwards, by means of hooks, and snip off the digital extremities of the tendons. A little cleaning of fat and cellular tissue will then bring clearly into view the third layer of muscles. In this dissection the branches of the internal plantar nerve will run considerable risk, unless the student be careful,

The *Flexor brevis pollicis* arises by a pointed tendinous process from the side of the cuboid, and from the external and middle cuneiform bones, and is inserted by two heads into the base of the first phalanx of the great toe. Two sesamoid bones are developed in the tendons of insertion of these two heads, and the tendon of the flexor longus pollicis lies in the groove between them.

The *Adductor pollicis* arises from the cuboid bone, from the sheath of the tendon of the peroneus longus, and from the base of the third and fourth metatarsal bones. It is inserted into the base of the first phalanx of the great toe.

The *Flexor brevis minimi digiti* arises from the base of the metatarsal bone of the little toe, and from the sheath of the tendon of the peroneus longus. It is inserted into the base of the first phalanx of the little toe.

The *Transversus pedis* arises by fleshy slips from the heads of the metatarsal bones of the four lesser toes. Its tendon is inserted into the base of the first phalanx of the great toe.

The plantar interossei muscles (page 405.) must be left until the arteries and nerves have been dissected and studied.

ACTIONS.—The actions of the muscles in the sole of the foot are implied in their names. See analysis (page 406.)

Arteries of the Sole of the Foot.

The *Arteries* of the sole of the foot are the internal and external plantar, the terminal branches of the posterior tibial artery. Their distribution may be thus expressed in a tabular form:—

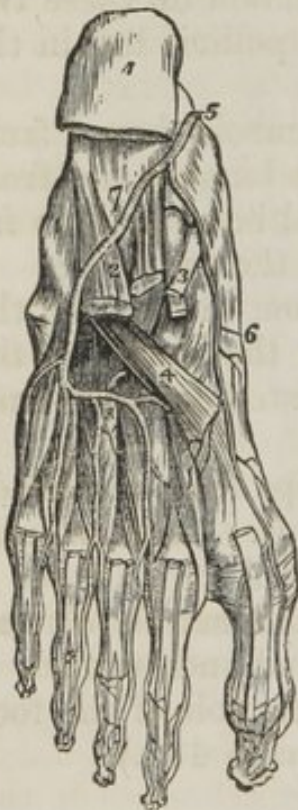Posterior tibial.	{	internal plantar.	{	muscular.	{	anterior perforating.
		external plantar.		digital		collateral.
				posterior perforating.		

The posterior tibial artery immediately behind the inner maleolus divides into its two terminal branches.

The *Internal plantar*, the smaller of the two, runs along the inner border of the foot between the abductor pollicis and flexor brevis digitorum muscles, and supplies the inner border of the foot and great toe.

The *External plantar artery* passes obliquely outwards between the first and second layer of plantar muscles to the fifth metatarsal space. It then turns horizontally inwards between the second and third layers to the first metatarsal space, where it inosculates with the communicating branch from the dorsalis pedis. The horizontal portion of the artery describes a slight curve, having the convexity forwards. This is the plantar arch.

Fig. 113. The arteries of the sole of the foot; the first and a part of the second layer of muscles having been removed.



It then turns horizontally inwards between the second and third layers to the first metatarsal space, where it inosculates with the communicating branch from the dorsalis pedis. The horizontal portion of the artery describes a slight curve, having the convexity forwards. This is the plantar arch.

BRANCHES.—1st. *Muscular*, to the muscles in the sole of the foot. 2d. The *digital*, four in number, pass forwards to the cleft between the toes, and divide into collateral branches, which supply the sides of the three external toes, and the outer side of the second. At the bifurcation of the toes, a small branch is sent upwards from each digital artery to inosculate with the interosseous branches of the metatarsa; these are the *anterior perforating* arteries.

3d. The *Posterior perforating* are three small branches which pass upwards between the heads of the three external dorsal interossei muscles, to inosculate with the arch formed by the metatarsa artery.

1. The under and posterior part of the os calcis; to which the origins of the first layer of muscles remain attached. 2. The musculus accessorius. 3. The long flexor tendons. 4. The tendon of the peroneus longus. 5. The termination of the posterior tibial artery. 6. The internal plantar. 7. The

external plantar artery. 8. The plantar arch giving off four digital branches, which pass forwards on the interossei muscles to divide into collateral branches.

Nerves of the Sole of the Foot.

The *Nerves* of the sole of the foot are, like the arteries, the internal and external plantar (*fig.* 107. 12.) terminal branches of the posterior tibial.

Posterior tibial	{	internal plantar	{ three toes and a half.
		external plantar	{ one toe and a half. sole of the foot.

There is a difference in the distribution of the nerves in this region, as contrasted with the arteries, which it is difficult to explain. However, as far as the student is concerned, it may be possibly as easy to recollect by a mnemonic of opposition as of resemblance.

Thus the external plantar artery supplies three toes and a half, and the nerve one and a half. The internal plantar artery supplies half a toe, and the nerve three and a half.

The *Internal plantar nerve*, larger than the external, lies in the fissure between the abductor pollicis and flexor brevis digitorum, and divides into four branches, which pass forwards between the first and second layers of muscles to be distributed to the three inner toes and one side of the fourth.

The *External plantar nerve*, the smaller of the two, follows the course of the external plantar artery, to the outer border of the musculus accessorius, beneath which it sends several large muscular branches to supply the sole of the foot. It then gives branches to the outer border of the foot, and sends forwards two digital branches to supply the little toe and one half the next.

When the arteries and nerves have been examined, the muscles may be removed which impede the view of the plantar interossei. The *plantar interossei muscles* are three in number, and are placed *upon* rather than between the metatarsal bones. They *arise* from the base of metatarsal bones of the three outer toes, and are inserted into the inner side of the extensor tendon and base of the first phalanx of the same toes. In their action they are all *abductors*.

When the anatomy of the muscles, vessels, and nerves of the sole of the foot is completed, and the student is pre-

paring to study the ligaments, he should lay open the groove in the cuboid bone by dividing the ligamentous sheath in which it is contained, and expose the tendon of the peroneus longus in its passage across the foot, to its insertion into the base of the metatarsal bone of the great toe. In that portion of the tendon which lies in contact with the cuboid, he will find a sesamoid bone. In some instances the deposit of bone has not taken place and the thickening in that portion of the tendon is merely fibro-cartilaginous.

Analysis of the Arrangement and Actions of the Muscles of the Lower Extremity.

The lower extremity is composed of, 1st. the femur; 2d. the tibia and fibula; 3d. the tarsus; 4th the toes. The trunk is the fixed point from which arise the muscles that move the thigh. The articulation of the hip is a universal joint; hence the movements are very numerous, but they may all be referred to the four primary directions, *forwards, backwards, inwards, outwards*, to which is added *rotation* on its axis.

The articulation of the femur with the tibia is a hinge joint, and is therefore applicable only to *flexion* and *extension*: the muscles performing these actions, arise from the pelvis and femur. But as we descend, we find the length of the bones diminishing while their numbers increase. The foot is a compound organ made up of a number of parts, each part performing distinct movements. We are therefore prepared to find a number of muscles destined to supply these demands. But numerous as they really are, they may, by a careful analysis, be arranged and grouped under a few simple actions.

The movements of the tarsus may be referred to four heads, *flexion, extension, adduction, abduction*, the latter two actions being very imperfect. The muscles performing these movements are the following:—

Flexion.

Tibialis anticus,
Peroneus tertius.

Extension.

Tibialis posticus,
Peroneus longus,
———— brevis, and where
forcible action is required
as in walking,
Gastrocnemius,
Plantaris.
Soleus.

Adduction.

Tibialis anticus,
 ——— posticus.

Abduction.

Peroneus longus,
 ——— brevis.

The movements of the toes may in the same manner be reduced to precisely the same simplicity of action thus:—

Flexion.

Flexor longus digitorum,
 ——— brevis digitorum,
 ——— accessorius,
 ——— minimi digiti.

Extension.

Extensor longus digitorum.
 ——— brevis digitorum.

Adduction.

Interossei, { 1 dorsal.
 { 3 plantar.

Abduction.

Interossei, 3 dorsal.
 Abductor minimi digiti.

The great toe, like the thumb in the hand, enjoys an independence of action, and is therefore provided with distinct muscles to perform its movements. But even here the direction of the actions is nothing more than is possessed by each of the other toes, and may be referred to the same plan, thus:—

Flexion.

Flexor longus pollicis,
 ——— brevis pollicis.

Extension.

Extensor proprius pollicis,
 ——— brevis digitorum.

Adduction.

Adductor pollicis.

Abduction.

Abductor pollicis.

The only muscles excluded from this table are the lumbricales, four small muscles, which, from their attachments to the tendons of the long flexor, appear to be assistants to their action; and the transversus pedis, a small muscle placed transversely in the foot across the heads of the metatarsal bones, which has for its office the drawing together of the toes.

CHAPTER XI.

ON THE LIGAMENTS.

THE mechanism by which the different bones of the skeleton are connected with each other is called a "joint." Every bone in the body articulates with one or more bones, and as each differs from the other in its form and in its use, we are prepared to expect a great variety in the forms of joints. They may all, however, be reduced to three classes—1. Synarthrosis; 2. Amphiarthrosis; and 3. Diarthrosis.

SYNARTHROSIS (*συν*, together; *αρθρωσις*, articulation,) is that form of joint in which the bones are intimately and *immoveably* connected with each other. There are four kinds of synarthrosis.

1. *Harmonia* (*αρω*, to adapt,) in which the bones merely lie in opposition with each other; as in the palate processes of the superior maxillary and palate bones with those of the opposite side, and with each other; the basilar process of the occipital bone with that of the sphenoid; the nasal bones with each other, and with the superior maxillary bones.

2. *Schindylesis* (*σχινδυλησις*, a fissure,) in which a projection of one bone is inserted into a groove or fissure in another; as in the articulations of the vomer with the rostrum of the sphenoid, and with the central lamella of the ethmoid bone.

3. *Gomphosis* (*γομφος*, a nail,) a mode of articulation, of which the insertion of the teeth into the alveolar processes is the only example; their roots being fixed into the alveoli, like nails into a board.

4. *Sutura* (*sutura*, a seam,) is the most solid of the four forms of synarthrosis: it is that which is employed for the articulation of the flat bones of the skull with each other. It presents two varieties *sutura serrata*, which is illustrated in the serrated union of the frontal with the parietal bones, the parietal bones with each other, or with the occipital; and *sutura squamosa*, the scale-like connexion of the temporal bone with the parietal.

AMPHI-ARTHROSIS (*αμφι*, both, *αρθρωσις*,) is a form of joint

which receives its name from being intermediate between synarthrosis or the fixed form of articulation and the diarthrosis or moveable joint.

It is characterized by having an intervening substance between the contiguous ends of the bones, and permitting of only a slight or obscure degree of motion.

The instances of this articulation are, the connexion between the bodies of the vertebræ, the union of the first two pieces of the sternum and the sacro-iliac and pubic *symphysis* (*συν*, together; *φύω*, to grow.)

DIARTHROSIS (*δια*, through; *αρθρωσις*), is the moveable form of articulation, and constitutes the greater proportion of the joints of the body. The degree of motion permitted by these articulations has given rise to their division into three groups.

1. *Arthrodia*, in which the extent of motion is limited; as in the articulations of both extremities of the clavicle, and ribs; in the articulations of the radius with the ulna; of the fibula with the tibia; of the articular processes of the vertebræ; and of the bones of the carpus and tarsus with each other, and with the metacarpal bones.

2. *Ginglymus* (*γυγγυμοσ*, a hinge,) or hinge-joint, is the movement of bones upon each other in two directions only, viz: forwards and backwards; but the degree of motion may be very considerable. The instances of this form of joint are numerous; they comprehend the elbow, wrist, metacarpal and phalangeal joints in the upper extremity; and the knee, ankle, metatarsal and phalangeal joints in the lower extremity. The lower jaw may also be admitted in this category, as partaking more of the character of the hinge-joint than the less moveable arthrodia.

The form of the ginglymoid joint is somewhat quadrilateral and each of its four sides is provided with a ligament, which is named from its position, *anterior*, *posterior*, *internal*, or *external lateral*. The *lateral ligaments* are thick and strong, and are the chief bond of union between the bones. The *anterior* and *posterior* are thin and loose in order to permit of the required extent of movement.

3. *Enarthrosis* (*εν*, in; *αρθρωσις*) is the most extensive in its range of motion of all the moveable joints. From the manner of connexion and form of the bones in this articulation, it is called the ball and socket joint. There are three instances in the body, viz. the hip, the shoulder, and the articu-

lation of the metacarpal bone of the thumb with the trapezium.

The ball and socket joint has a circular form, and, in place of the four distinct ligaments of the ginglymus, is enclosed in a bag of ligamentous fibres, called a *capsular ligament*.

The *Joints* may, for the convenience of the student, be divided into those of the *trunk*; those of the *upper extremity*; and those of the *lower extremity*.

LIGAMENTS OF THE TRUNK.

The *Ligaments of the trunk* will be considered and described in the following order:—

1. Of the Vertebral column.
2. Of the Atlas, with the Occipital bone.
3. Of the Axis, with the Occipital bone.
4. Of the Atlas, with the Axis.
5. Of the Lower Jaw.
6. Of the Ribs, with the Vertebrae.
7. Of the Ribs, with the Sternum, and with each other.
8. Of the Vertebral column, with the Pelvis.
9. Of the Pelvis.

1. *Articulation of the vertebral column*.—The vertebrae are divided into—*body, arches, articular, spinous, and transverse processes*; and their ligaments admit of precisely the same arrangement.

The ligaments of the *bodies* are the

Anterior common ligament,
Posterior common ligament.

Of the *arches*,

Ligamenta subflava.

Of the *articular processes*,

Capsular ligaments,
Synovial membranes.

Of the *spinous processes*,

Inter-spinous,
Supra-spinous.

Of the *transverse processes*,

Inter-transverse.

The *Anterior common ligament* is a broad and riband-like band of ligamentous fibres, extending along the front surface of the vertebral column, from the axis to the sacrum. It is intimately connected with the intervertebral substances, and less closely with the bodies of the vertebræ.

It is composed of three layers of fibres which are closely interwoven with each other; the *first layer*, consists of short fibres, which cross the intervertebral substances from each vertebra to the next; the fibres of the *second layer* pass from each vertebra to the third above or below it; and those of the *third* or *superficial layer*, from each vertebra to the fourth or fifth vertebra above or below it.

The *Posterior common ligament* lies upon the posterior surface of the bodies of the vertebræ, and extends from the axis to the sacrum. It is broad opposite the intervertebral substances, to which it is closely adherent; and narrow and thick over the bodies of the vertebræ, from which it is separated by the communicating branches between the great spinal veins.

The *Intervertebral substance* is a disc of fibro-cartilage, interposed between each of the vertebræ from the axis to the sacrum. It is composed of concentric layers, which diminish in density from the circumference to the centre, where it is soft, pulpy, and elastic. When examined from the exterior, each layer is found to consist of oblique fibres, which alternate in their direction, proceeding from left to right in one layer, and from right to left in the next, and so on for the rest.

ARCHES.—The *Ligamenta subflava* are situated between the arches of the vertebræ from the axis to the sacrum, and are composed of yellow elastic tissue. They are attached below to the posterior surface of the arches, and are inserted into the anterior surface of the arches of the vertebra above. They meet upon the middle line, but are not continuous with each other at that point.

ARTICULAR PROCESSES.—The ligaments of the articular processes of the vertebræ are loose *capsules*, which surround the articulating surfaces. They are lined on their interior with *synovial membrane*, which is continued over the cartilaginous surfaces of the bones.

SPINOUS PROCESSES.—The *Inter-spinous* ligaments are thin

and membranous, and are extended between the spinous processes in the dorsal and lumbar regions.

The *Supra-spinous* are short, thick, ligamentous bands, passing from the apex of one spinous process to the next. They exist, like the inter-spinous, only in the dorsal and lumbar regions.

TRANSVERSE PROCESSES.—The *Inter-transverse* are thin and membranous: they are found only between the transverse processes of the lower dorsal vertebræ.

2. *Articulation of the atlas with the occipital bone.*—The ligaments of this articulation are *four* in number,

Anterior occipito-atloid, Two capsular.
Posterior occipito-atloid,

The *Anterior ligament* is a thin membranous layer, which is thicker in the middle than at each side. It is attached above to the margin of the occipital foramen, and below to the anterior arch of the atlas.

The *Posterior ligament* is also thin and membranous; it is attached above to the margin of the occipital foramen, and below to the posterior arch of the atlas. It is closely adherent to the dura mater by its inner surface, and forms a ligamentous arch for the passage of the vertebral arteries.

The *Capsular ligaments* are the thin and loose ligamentous capsules which surround the synovial membranes of the articulations, between the condyles of the occipital bone and the superior articular processes of the atlas.

3. *Articulation of the axis with the occipital bone.*—The ligaments of this articulation are *four* in number,

Anterior occipito-axoid, Two odontoid.
Posterior occipito-axoid,

The *Anterior ligament* is a narrow band of fibres ascending from the body of the axis to the basilar process, close to the foramen magnum.

The *Posterior ligament* (apparatus ligamentosus colli) is a broad band, and apparently a continuation of the posterior common ligament: it is attached below to the posterior surface of the body of the axis, and spreads out superiorly to be inserted into the inner surface of the basilar process. It covers in the odontoid process and alar ligaments.

The *Odontoid ligaments* (alar) are two short and thick fasciculi of fibres that pass outwards from the apex of the odon-

toid process to the sides of the occipital foramen and condyles.

4. *Articulation of the atlas with the axis.*—The ligaments of this articulation are *five* in number :—

Anterior atlo-axoid,	Two capsular,
Posterior atlo-axoid,	Transverse.

The *Anterior ligament* is a membranous layer, passing between the lower border of the anterior arch of the atlas, and the body of the axis.

The *Posterior ligament* is a membranous layer, passing between the posterior arch of the atlas, and the arches of the axis.

The *Capsular ligaments* surround the articular processes of the atlas and axis, and are provided with synovial membranes.

The *Transverse ligament* is a strong ligamentous band, crossing the area of the ring of the atlas from the inner surface of one articular process to the other. It serves to retain the odontoid process of the axis, in connexion with the anterior arch of the atlas. As it crosses the odontoid process, some fibres are sent downwards to be attached to its root, and others pass upwards to be attached to the basilar process of the occipital bone; hence the ligament has a cross-like appearance, and is sometimes called *cruciform*. A synovial membrane is situated between the transverse ligament and the odontoid process; and another between that process and the inner surface of the anterior arch of the atlas.

5. *Articulation of the lower jaw.*—The ligaments of this articulation are *three* in number; to which may be added, as appertaining to the mechanism of the joint, an inter-articular fibro-cartilage, and two synovial membranes:

External lateral,
Internal lateral,
Capsular.

Inter-articular fibro-cartilage,
Two synovial membranes.

The *External lateral ligament* is a short band of fibres, passing from the tubercle of the zygoma, to the external surface of the neck of the lower jaw.

The *Internal lateral ligament* is a thin band of ligamentous fibres, extending between the extremity of the spinous process

of the sphenoid bone to the margin of the dental foramen. It is pierced at its insertion by the mylo-hyoidean nerve.

A triangular space is left between the internal lateral ligament and the neck of jaw, in which are situated the internal maxillary artery and auricular nerve, and inferior dental artery and nerve.

The *Capsular ligament* is thin and loose, and completely surrounds the joint. It is lined upon its inner surface by the synovial membranes, and is firmly connected with the inter-articular cartilage, which it serves to keep in its place.

The *Inter-articular fibro-cartilage* is a thin oval plate, thicker at the edges than in the centre, placed horizontally between the head of the condyle of the lower jaw and the glenoid cavity. It is connected by its circumference with the capsular ligament, and is sometimes incomplete in the centre. It divides the joint into two distinct cavities, one above and the other below the cartilage, which are each lined by a synovial membrane; hence *the two synovial membranes*.

Besides the lower jaw, there are several other joints provided with a complete inter-articular fibro-cartilage, and, consequently, with two synovial membranes; they are, the *sterno-clavicular articulation*, the *acromio-clavicular*, and the *articulation of the ulna with the cuneiform bone*.

The inter-articular fibro-cartilages of the *knee-joint* are partial, and there is but one synovial membrane.

The articulations of the heads of the ribs with the vertebræ have two synovial membranes, separated by an inter-articular ligament without fibro-cartilage.

DISLOCATIONS.—The dislocations of the lower jaw are *three*—1. Complete; 2. Partial; and 3. Subluxation.

In *Complete dislocation*, both condyles are thrown forwards into the zygomatic fossæ.

In *Partial dislocation*, one condyle is thrown forwards into the zygomatic fossa.

In *Subluxation*, the condyle is displaced from its inter-articular fibro-cartilage.

6. *Articulation of the ribs with the vertebræ*.—The ligaments of these articulations are divisible into two groups—1st, those connecting the *head of the ribs* with the *vertebræ*; and, 2d, those connecting the *neck and tubercle of the rib* with the *transverse processes*. They are,

1st Group.

Anterior costo-vertebral, or stellate,
Capsular,
Inter-articular ligament,
Two synovial membranes.

2d Group.

Anterior costo-transverse,
Middle costo-transverse,
Posterior costo-transverse.

The *Anterior costo-vertebral* or *stellate ligament* consists of three short bands of ligamentous fibres that radiate from the anterior part of the head of the rib. The *superior band* passes upwards and is attached to the vertebra above; the *middle fasciculus* is attached to the inter-vertebral substance; and the *inferior* to the vertebra below.

The *Capsular ligament* is a very thin layer of ligamentous fibres that surrounds the joint in the interval left by the anterior ligament, and protects the synovial membranes.

The *Inter-articular ligament* passes between the sharp crest on the head of the rib and the inter-vertebral substance. It divides the joint into two cavities, which are each furnished with a separate *synovial membrane*. The *first, eleventh and twelfth ribs* have no inter-articular ligament, and consequently but one synovial membrane.

The *Anterior costo-transverse ligament* is a broad band, which ascends from the neck of the rib to the transverse process immediately above it.

The *Middle costo-transverse ligament* is an interosseous ligament passing directly between the posterior surface of the neck of the rib, and the transverse ligament against which it rests.

The *Posterior costo-transverse ligament* is a small but strong fasciculus, passing from the tubercle on the rib to the apex of the transverse process. The articulation between the tubercle of the rib and the transverse ligament is provided with a small synovial membrane.

There is no anterior costo-transverse ligament between the first and second ribs; and no posterior costo-transverse to the eleventh and twelfth ribs.

7. *Articulation of the ribs with the sternum, and with each other.*—The ligaments of the costo-sternal articulations are,

Anterior costo-sternal,
Posterior costo-sternal.

The *Anterior costo-sternal ligament* is a thin band of ligamentous fibres that passes in a radiated direction from the extremity of the costal cartilage to the anterior surface of the sternum, and intermingles its fibres with those of the ligament of the opposite side.

The *Posterior costo-sternal ligament* is much smaller than the anterior, and consists of only a thin fasciculus of fibres situated on the posterior surface of the articulation.

This articulation is provided with a synovial membrane. —

The sixth, seventh, and eighth, and sometimes the fifth and ninth costal cartilages, have articulations with each other, and a perfect synovial capsule. They are connected by ligamentous fibres which pass from one cartilage to the other, *external and internal ligaments*.

The ninth and tenth are connected at their extremities by ligamentous fibres, but have no synovial membranes.

8. *Articulation of the vertebral column with the pelvis.*—The last lumbar vertebra is connected with the sacrum by the same ligaments with which the various vertebræ are connected with each other; viz., the anterior and posterior common ligaments, inter-vertebral substance, ligamenta subflava, capsular ligaments, and inter and supra-spinous ligaments.

There are only *two* proper ligaments connecting the vertebral column with the pelvis; they are, the

Lumbo-sacral,
Lumbo-iliac.

The *Lumbo-sacral ligament* is a thick triangular fasciculus of ligamentous fibres, connected above with the transverse process of the last lumbar vertebra, and below with the upper border of the sacrum.

The *Lumbo-iliac ligament* passes from the apex of the transverse process of the last lumbar vertebra to the posterior part of the crest of the ilium.

9. *The Articulations of the pelvis.*—The ligaments belonging to the articulations of the pelvis are divisible into four groups—1st., those connecting the *sacrum* and *ilium*; 2d., those passing between the *sacrum* and *ischium*; 3rd., be-

tween the *sacrum* and *coccyx*; and 4th., between the *two pubic bones*.

1st. *Between the Sacrum and Ilium.*

Sacro-iliac anterior,
Sacro-iliac posterior,
Sacro-iliac interosseous.

2d. *Between the Sacrum and Ischium.*

Sacro-ischiatic anterior (*short.*)
Sacro-ischiatic posterior (*long.*)

3d. *Between the Sacrum and Coccyx.*

Sacro-coccygean anterior,
Sacro-coccygean posterior.

4th. *Between the Ossa Pubis.*

Anterior pubic,
Posterior pubic,
Superior pubic,
Sub-pubic,
Inter-articular fibro-cartilage.

1. The *Anterior sacro-iliac ligament* consists of short ligamentous fibres, passing from bone to bone on the anterior surface of the joint.

The *Posterior sacro-iliac ligament* is composed of stronger fasciculi, passing in the same direction on the posterior aspect of the joint. One of these, longer and larger than the rest, is distinguished by the name of the *oblique sacro-iliac ligament*. It is attached by one extremity to the posterior superior spine of the ilium; and by the other, to the posterior surface of the third piece of the sacrum.

The *Interosseous ligament* consists of a number of strong ligamentous fibres, which pass horizontally between the two rough surfaces, on the *posterior half* of the sacro-iliac articulation. The ligament is the principal bond of connexion between the sacrum and the ilium.

The surfaces of the two bones forming the sacro-iliac articulation, are partly covered by cartilage, and partly rough and connected by the interosseous ligament. The *anterior half* is coated with cartilage, which is thicker on the sacrum than the ilium. The surface of the cartilage is irregular, and is

provided with a very delicate synovial membrane, which cannot be demonstrated in the adult; but is apparent in the young subject, and in the female during pregnancy.

2. *Between the sacrum and ischium.*—The *Anterior sacro-ischiatic ligament* is triangular in its form; it is attached by its apex to the spine of the ischium, and by its broad extremity to the side of the sacrum and coccyx.

The *Posterior sacro-ischiatic ligament*, considerably larger and more posterior than the preceding, is narrower in the middle than at each extremity. It is attached by its smaller end to the inner margin of the tuberosity and ramus of the ischium, where it forms a falciform process which protects the internal pudic artery and is continuous with the obturator fascia. By its larger extremity it is inserted into the side of the coccyx sacrum, and posterior inferior spine of the ilium.

It forms a part of the lateral boundary of the perineum and is pierced by the coccygeal artery. The two ligaments convert the sacro-ischiatic notches into foramina.

3. *Between the sacrum and coccyx.*

The *Anterior sacro-coccygean ligament* is a thin fasciculus passing from the anterior surface of the sacrum to the front of the coccyx.

The *Posterior sacro-coccygean ligament* is a thick ligamentous layer which completes the lower part of the sacral canal, and connects the sacrum with the coccyx posteriorly.

Between the two bones is a thin disc of soft intervertebral substance. In females there is frequently a small synovial membrane.

4. *Between the ossa pubis.*

The *Anterior pubic ligament* is composed of ligamentous fibres, which pass obliquely across the union of the two bones from side to side, and form an interlacement in front of the symphysis.

The *Posterior pubic ligament* consists of a few irregular fibres uniting the pubic bones posteriorly.

The *Superior pubic ligament* is a thick band of fibres connecting the angles of the pubic bones superiorly, and filling the inequalities upon the surface of the bones.

The *Sub-pubic ligament* is a thick arch of fibres connecting the two bones inferiorly, and forming the upper boundary of the pubic arch.

The *Interarticular fibro-cartilage* unites the two surfaces of

the pubic bones in the same manner that the intervertebral substance connects the bodies of the vertebræ. It resembles the intervertebral substance also in being composed of concentric layers, which are more dense towards the surface than near the centre. It is broad in front, and narrow behind. A thin synovial membrane is sometimes found in the posterior half of the articulation.

The *Obturator ligament* or *membrane* is not a ligament of articulation, but simply a tendino-fibrous membrane stretched across the obturator foramen. It gives attachment by its surfaces to the two obturator muscles; and it leaves a space in the upper part of the foramen for the passage of the obturator vessels and nerve.

LIGAMENTS OF THE UPPER EXTREMITY.

The *Ligaments of the upper extremity* may be arranged in the order of the articulations between the different bones; they are, the

1. Sterno-clavicular articulation.
2. Scapulo-clavicular articulation.
3. Ligaments of the scapula.
4. Shoulder joint.
5. Elbow joint.
6. Radio-ulnar articulation.
7. Wrist joint.
8. Articulation between the carpal bones.
9. Carpo-metacarpal articulation.
10. Metacarpo-phalangeal articulation.
11. Articulation of the phalanges.

1. The *Sterno-clavicular articulation*. The ligaments of this articulation are,

- Anterior sterno-clavicular,
- Posterior sterno-clavicular,
- Interclavicular,
- Costo-clavicular (*rhomboid*),
- Interarticular fibro-cartilage,
- Two synovial membranes.

The *Anterior sterno-clavicular ligament* is a broad ligamentous layer, covering the anterior aspect of the articulation.

The *Posterior sterno-clavicular ligament* is a broad fasciculus covering its posterior surface.

The *Interclavicular ligament* crosses from the extremity of

one clavicle to the other, and is closely connected with the upper border of the sternum.

The *Costo-clavicular ligament (rhomboid)* is a thick fasciculus of fibres connecting the sternal extremity of the clavicle with the cartilage of the first rib. It is situated obliquely between the rib and the clavicle. It is the rupture of this ligament in dislocation of the sternal end of the clavicle, that gives rise to the consequent deformity.

The *Interarticular fibro-cartilage* is circular in form, and thicker at the edges than in the centre. It is attached above to the clavicle, and below to the cartilage of the first rib. It divides the joint into two cavities, which are lined by *two synovial membranes*.

2. The *Scapulo clavicular articulation*.—The ligaments of the scapular end of the clavicle are, the

Superior acromio-clavicular,
Inferior acromio-clavicular,
Coraco-clavicular (*trapezoid* and *conoid*),
Interarticular fibro-cartilage,
Two synovial membranes.

The *Superior acromio clavicular ligament* is a thin plane of fibres passing between the extremity of the clavicle and the acromion, upon the upper surface of the joint.

The *Inferior acromion clavicular ligament* is a thin plane situated upon the under surface.

The *Coraco clavicular ligament (trapezoid conoid)* is a thick fasciculus of ligamentous fibres passing obliquely between the base of the coracoid process and the under surface of the clavicle, and holding the end of the clavicle in firm connexion with the scapula. When seen from *before* it has a quadrilateral form, hence it is named *trapezoid*; and examined from *behind* it has a triangular form, the base being upwards; hence another name *conoid*.

The *Interarticular fibro-cartilage* is often indistinct from having partial connexions with the fibro-cartilaginous surfaces of the two bones between which it is placed. The *synovial membranes* are very delicate.

3. The *Proper ligaments of the Scapula* are, the
Coraco-acromial,
Transverse.

The *Coraco acromial ligament* is a broad and thick band which is attached to the coracoid and acromial processes of

the scapula, and forms a protecting arch over the shoulder joint.

The *Transverse* or *coracoid ligament* is a narrow fasciculus which crosses the notch in the upper border of the scapula, and converts it into a foramen.

4. The *Shoulder joint*.—The ligaments of the scapulo-humeral articulation are, the

Capsular,
Coraco-humeral,
Glenoid.

The *Capsular ligament* completely encircles the articulating head of the scapula and the head of the humerus, and is attached to the neck of each bone. It is thick above, where resistance is most required, and is strengthened by the tendons of the supra-spinatus, infra-spinatus, teres minor, and subscapularis muscles: below it is thin and loose. The capsule is incomplete at the point of contact with the tendons of the muscle, so that they obtain upon their inner surface a covering of synovial membrane.

The *Coraco-humeral ligament* is a broad band which descends obliquely from the coracoid process to the neck of the humerus, and serves to strengthen the capsular ligament.

The *Glenoid ligament* is formed by the splitting of the tendon of the long head of the biceps, which divides at its origin into two slips, which are attached around the margin of the glenoid depression, and deepen its cavity.

The cavity of the articulation is traversed by the long tendon of the biceps, which is enclosed in a sheath of synovial membrane in its passage through the joint.

5. *Elbow joint*.—The ligaments of this articulation are *four* in number:—

Anterior,	Internal lateral,
Posterior,	External lateral.

The *Anterior ligament* is a broad and thin membranous layer, descending from the anterior surface of the humerus immediately above the joint, to the coronoid process of the ulna and annular ligament.

The *Posterior ligament* is a broad and loose fold passing between the posterior surface of the humerus to the anterior surface of the base of the olecranon.

The *Internal lateral ligament* is a thick triangular layer, attached above, by its apex, to the internal condyle of the

humerus; and below, by its expanded border, to the margin of the greater sigmoid cavity of the ulna, extending from the coronoid process to the olecranon.

The *External lateral ligament* is a strong and narrow band, which descends from the external condyle of the humerus, to be inserted into the annular ligament.

The *Synovial membrane* is extensive, and is reflected from the cartilaginous surfaces of the bones upon the inner surface of the ligaments.

6. The *Radio-ulnar articulation*.—The radius and ulna are firmly held together by ligaments which are connected with both extremities of the bones, and with the shaft; they are, the

Annular,	Anterior inferior,
Oblique,	Posterior inferior,
Interosseous,	Interarticular fibro-cartilage.

The *Annular ligament (orbicular coronary)* is a firm band that surrounds the head of the radius, and is attached by each end to the extremities of the lesser sigmoid cavity. It is lined on its inner surface by the synovial membrane of the shoulder joint, and gives attachment to the external lateral ligament of that articulation.

The rupture of this ligament permits of the dislocation of the head of the radius.

The *Oblique ligament* is a narrow slip of ligamentous fibres, descending obliquely from the base of the coronoid process of the ulna, to the side of the radius.

The *Interosseous ligament* is a broad and thin plane of ligamentous fibres passing obliquely from the sharp ridge on the radius to that on the ulna. It is perforated at its lower part for the passage of the anterior interosseous artery.

The *Anterior inferior ligament* is a thin fasciculus of fibres passing transversely between the radius and ulna.

The *Posterior inferior ligament* is also thin and loose, and has the same disposition on the posterior surface of the articulation.

The *Interarticular triangular fibro-cartilage* acts the part of a ligament between the lower extremities of the radius and ulna.

It is attached by its apex to the inner surface of the styloid process of the ulna, and by its base to the edge of the radius.

This fibro-cartilage is lined upon its upper surface by a

synovial membrane, which forms a duplicature between the radius and ulna, and is called the *membrana sacciformis*. By its lower surface it enters into the articulation of the wrist-joint.

7. The *Wrist joint*.—The ligaments of the articulation of the wrist are *four*, the

Anterior,	Internal lateral,
Posterior,	External lateral.

The *Anterior ligament* is a broad membranous layer which passes between the lower part of the radius and ulna, and the scaphoid, semilunar, and cuneiform bones.

The *Posterior ligament*, also thin and loose, passes between the posterior surface of the radius, and the posterior surface of scaphoid, semilunar, and cuneiform bones.

The *Internal lateral ligament* extends from the styloid process of the ulna to the cuneiform bone.

The *External lateral ligament* is attached by one extremity to the styloid process of the radius, and by the other to the side of the scaphoid bone and trapezium.

The *Synovial membrane* of the wrist-joint lines the under surface of the radius and interarticular fibro-cartilage above, and the first row of bones of the carpus below.

8. *Articulation between the Carpal bones*.—The ligaments connecting together the different bones of the carpus, are, the

Dorsal,	Interosseous,
Palmar,	Anterior annular.

The *Dorsal ligaments* are ligamentous bands that pass from bone to bone in every direction, upon the dorsal surface of the carpus.

The *Palmar ligaments* are fasciculi of the same kind, and having the same disposition upon the palmar surface.

The *Interosseous ligaments* are situated between the adjoining bones in each rank: in the upper rank they close the upper part of the spaces between the scaphoid, semilunar, and cuneiform bones; in the lower rank they leave spaces through which the synovial membrane is continued to the metacarpal bones.

The *Anterior annular ligament* is a firm ligamentous band which connects the bones of the two sides of the carpus. It is attached by one extremity to the trapezium and scaphoid, and by the other to the unciform process of the unciform and the base of the pisiform bone, and forms an arch over the an-

terior surface of the carpus, beneath which the tendons of the long flexors and median nerve pass into the palm of the hand.

The *Articulation of the pisiform bone* with the cuneiform, is provided with a distinct synovial membrane, which is protected by ligamentous fibres which form a kind of capsule around the joint.

Synovial membranes.—There are *five synovial membranes* entering into the composition of the articulations of the carpus:—

1. The *first* is situated between the lower end of the ulnar and the interarticular fibro-cartilage; it is called *sacciform*, from forming a sacculus between the lateral articulation of the ulna with the radius.

2. The *second* is situated between the lower surface of the radius and interarticular fibro-cartilage *above*, and the first rank of bones of the carpus *below*.

3. The *third* is the most extensive of the synovial membranes of the wrist; it is situated between the two rows of carpal bones, and passes between the bones of the second rank, to invest the carpal surfaces of the four metacarpal bones of the fingers.

4. The *fourth* is the synovial membrane of the articulation of the metacarpal bone of the thumb with the trapezium.

5. The *fifth* is situated between the pisiform and cuneiform bones.

The carpal bones have numerous articulations;—thus the scaphoid articulates with five bones, the semilunar with five; the cuneiform with three, and the pisiform with one;—forming together, in the order of position from the radial to the ulnar side, the cipher 5531.

Of the bones of the second row, the trapezium articulates with four, the trapezoides with four; the magnum with seven, and the unciform with five; which form in the same order, the cipher 4475.

9. The *Carpo-metacarpal articulation.*—The second row of bones of the carpus articulates with the metacarpal bones of the four fingers by *dorsal* and *palmar* ligaments; and the metacarpal bone of the thumb with the trapezium by a true *capsular ligament*.

The *Dorsal ligaments* pass from the carpal to the metacar-

pal bones, and transversely between the bases of the metacarpal bones.

The *Palmar ligaments* are arranged upon the same plan on the palmar surface.

The *Synovial membrane* is a continuation of the great synovial membrane of the two rows of carpal bones.

The *Capsular ligament* of the thumb is one of the three true capsular ligaments of the skeleton; the other two being the shoulder-joint and hip-joint. The articulation has a proper *synovial membrane*.

The metacarpal bones have a variable number of articulations with the carpal bones: the *first* articulates with the trapezium only; the *second* with the trapezium, trapezoides, and magnum; the *third* with the magnum only; the *fourth* with the magnum and unciform; and the *fifth* with the unciform bone only; the cipher resulting from this arrangement is 13121.

10. The *Metacarpo-phalangeal articulation*.—The ligaments of this articulation are *four*; the

Anterior,
Two lateral,
Transverse.

The *Anterior ligaments* are thick and almost fibro-cartilaginous, and form part of the articulating surface of the joints.

The *Lateral ligaments* are strong narrow fasciculi, holding the bones together at each side.

The *Transverse ligaments* are strong ligamentous bands passing between the anterior ligaments, and connecting together the heads of the metacarpal bones of the four fingers.

The expansion of the extensor tendon over the back of the fingers takes the place of a posterior ligament.

11. The *Articulation of the Phalanges*.—The phalanges are articulated with each other by *three* ligaments;

Anterior,
Two lateral.

The *Anterior ligament* is firm and fibro-cartilaginous.

The *Lateral ligaments* are very strong; they are the principal bond of connexion between the bones.

The extensor tendon takes the place and performs the office of a posterior ligament.

LIGAMENTS OF THE LOWER EXTREMITY.

The *Ligaments of the lower extremity*, like those of the upper, may be arranged in the order of the joints to which they belong; they are, the

1. Hip-joint.
2. Knee-joint.
3. Articulation between the tibia and fibula.
4. Ankle-joint.
5. Articulation of the tarsal bones.
6. Tarso-metatarsal articulation.
7. Metatarso-phalangeal articulation.
8. Articulation of the phalanges.

1. *Hip-joint*.—The *Ligaments* of the ilio-femoral articulation are *five* in number; they are, the

Capsular,	Cotyloid,
Ilio-femoral,	Transverse.
Teres,	

The *Capsular ligament* is a strong ligamentous capsule attached around the acetabulum and around the neck of the femur, and connecting the two bones firmly together. It is much thicker upon the upper part of the joint, where more resistance is required, than upon the under part. It likewise extends farther upon the neck of the femur on the anterior, than on the posterior side.

The *Ilio femoral ligament* is an accessory band, which descends from the anterior inferior spinous process of the ilium to the neck of the femur, and strengthens the anterior surface of the capsular ligament.

The *Ligamentum teres* is somewhat triangular in form; it is attached by its base to the lower part of the cup of the acetabulum, and by a rounded apex into the depression upon the middle of the head of the femur.

The *Cotyloid ligament* is a strong ligamentous cord attached to the margin of the acetabulum, which it serves to deepen.

The *Transverse ligament* is the extension of the cotyloid ligament across the notch in the acetabulum. It forms an arch across the notch, beneath which the articular branches of the internal circumflex and obturator arteries enter the joint.

In the bottom of the acetabulum is a deep depression, which is filled with fat covered by synovial membrane, which serves

as a kind of elastic cushion to the head of the bone. This was formerly considered as the synovial gland of the joint.

The *Synovial membrane* is extensive; it invests the head of the femur, and is continued around the ligamentum teres into the acetabulum, and is thence reflected upon the inner surface of the capsular ligament.

2. *Knee-joint*.—The ligaments of the knee-joint are *thirteen* in number; they are,

- Anterior or ligamentum patellæ,
- Posterior or ligamentum posticum Winslowii,
- Internal lateral,
- Two external lateral,
- Anterior or external crucial,
- Posterior or internal crucial,
- Transverse,
- Two coronary,
- Ligamentum mucosum, } *false*
- Ligamenta alaria, }
- Two semilunar fibro-cartilages,
- Synovial membrane.

The first *five* are *external* to the articulation; the next *five* are *internal* to the articulation; the three remaining are mere folds of mucous membrane, and have no title to the name of ligaments. In addition to the ligaments there are two fibro-cartilages which are sometimes very erroneously considered among the ligaments; and a synovial membrane, which is still more improperly described by some authors as a *capsular ligament*.

The *Anterior ligament*, or *ligamentum patellæ*, is the prolongation of the tendon of the extensor muscles of the thigh downwards to the tubercle of the tibia. It is, therefore, no ligament; and as we have before stated, in our first chapter, that the patella is simply a sesamoid bone, developed in the tendon of the extensor muscles for the defence of the front of the knee-joint, it has no title to consideration, either as a ligament of the knee-joint or as a ligament of the patella.

A small *Bursa mucosa* is situated between the ligamentum patellæ, near to its insertion, and the front of the tibia.

The *Posterior ligament*,—*ligamentum posticum Winslowii*, is a broad band of ligamentous fibres, passing obliquely across the back part of the knee-joint, from the posterior part of the inner head of the tibia to the space between the two condyles

of the femur. It is former chiefly by the ascending slip of the tendon of the semi-membranosus muscle: see page 383.

The *Internal lateral ligament* is a broad diamond-shaped layer of ligamentous fibres, which descends over the inner side of the joint to be inserted into the head of the tibia. It is crossed at its lower part by the tendons of the inner hamstring, and covers in the anterior slip of the semi-membranosus tendon and the inferior internal articular artery.

The *External lateral ligaments* descend from the projection on the external condyle of the femur to the head of the fibula. The *posterior* is shorter than the anterior, but the division into two is often indistinct. They are covered by the tendon of the biceps, and have passing beneath them the tendon of origin of the popliteus muscle, and the inferior external articular artery.

The true ligaments *within the joint* are the crucial, transverse, and coronary.

The *Anterior*, or *external crucial ligament*, arises from the depression upon the head of the tibia in front of the spinous process, and passes upwards and backwards to be inserted into the inner surface of the outer condyle of the femur.

The *Posterior*, or *internal or crucial ligament*, arises from the depression upon the head of the tibia, behind the spinous process, and passes upwards and forwards to be inserted into the inner condyle of the femur.

The *Transverse ligament* is a small slip of fibres which extends transversely between the two semilunar cartilages, and connects them anteriorly.

The *Coronary ligaments* are the short fibres by which the convex border of the semilunar cartilages is connected to the head of the tibia, and to the ligaments surrounding the joint.

The *Semilunar fibro-cartilages* are the two falciform plates of fibro-cartilage, situated around the margin of the head of the tibia, and serving to deepen the surface of articulation for the condyles of the femur. They are thick along their convex border, and thin and sharp along the concave edge.

The *Internal semilunar fibro-cartilage* forms an oval cup for the reception of the internal condyle: it is connected by its convex border to the head of the tibia, and to the internal and posterior ligaments, by means of its coronary ligament; and by its two extremities is firmly implanted into the depressions immediately in front and behind the spinous process.

The *External semilunar fibro-cartilage* bounds a circular fossa for the external condyle: it is connected by its convex border with the head of the tibia, and external and posterior ligaments, by means of its coronary ligament; and by its two extremities is inserted into the depression between the two projections which constitute the spinous process of the tibia. The two extremities of the external cartilage being inserted into the same spot, form almost a complete circle, and being somewhat broader than the internal, nearly cover the cartilaginous surface of the tibia.

The two fibro-cartilages are connected anteriorly by the transverse ligament.

The *ligamentum mucosum* and *ligamenta alaria* are the *false* ligaments of the knee-joint: they are mere folds of the synovial membrane.

The *Ligamentum mucosum* is a small cylindrical process which crosses from the apex of the patella to the space between the two condyles.

It encloses a small quantity of fat; hence it has been called "adipose ligament."

The *Alar ligaments* are two fringed folds of the synovial membrane, situated on either side of the patella, to which they give the semblance of wings.

The *Synovial membrane* of the knee-joint is the most extensive in the entire skeleton. It invests the cartilaginous surfaces of the condyles of the femur, of the head of the tibia, and of the inner surface of the patella; it covers both surfaces of the semilunar fibro-cartilages, and is reflected upon the crucial ligaments, and upon the inner surface of the ligaments which form the circumference of the joint. On each side of the patella, it lines the tendinous aponeuroses of the vastus internus and vastus externus muscles, and forms a pouch of considerable size between the extensor tendon and the front of the femur. It also forms the folds in the interior of the joint, called "*ligamentum mucosum*," and "*ligamenta alaria*."

When the knee-joint becomes distended with fluid from effusion into the synovial cavity, a remarkable swelling is observed upon each side of the patella, particularly upon its inner side. This appearance results from the distention of the two lateral portions of the membrane, which line the inner surface of the aponeurosis of the vasti muscles. A third

swelling is also perceived immediately above the patella, from the filling of the superior pouch of the synovial membrane.

The superior pouch of the synovial membrane is supported and raised during the movements of the limb by a small muscle, the *subcrureus*, which is inserted into it; see page 360.

A quantity of oily fat is situated between the tendon of the patella and the synovial membrane, which pushes the membrane inwards towards the joint.

3. *Articulation between the Tibia and Fibula.*—The tibia and fibula are held firmly connected by means of *seven* ligaments: viz.

Anterior,	}	above.	Anterior,	}	below.
Posterior,			Posterior,		
Interosseous superior,			Transverse.		
Interosseous inferior,					

The *Anterior superior ligament* is a thin fasciculus passing between the anterior surface of the head of the fibula and the inner tuberosity of the tibia.

The *Posterior superior ligament* is disposed in the same manner upon the posterior surface of the articulation.

The *Superior interosseus ligament* is a broad layer of ligamentous fibres passing obliquely downwards and outwards, from the sharp ridge on the tibia, to the inner edge of the fibula. There is an opening in its upper part, through which the anterior tibial artery takes its course forwards to the anterior aspect of the leg.

The *Inferior interosseous ligament* consists of short and strong fibres, which hold the bones firmly together interiorly, where they are nearly in contact.

The *Anterior inferior ligament* is a broad fasciculus that passes obliquely across the anterior aspect of the articulation of the two bones, at their inferior extremity.

The *Posterior inferior ligament* is a similar band upon the posterior surface of the articulation.

The *Transverse ligament* is a narrow band of ligamentous fibres, which passes transversely across the back of the ankle joint, between the two malleoli.

4. *Ankle-joint.*—The ligaments of the ankle joint are three in number:—

Anterior,
Internal lateral,
External lateral.

The *Anterior ligament* is a thin membranous layer, passing from the margin of the tibia and fibula, to the astragalus in front of the articular surface.

The *Internal lateral ligament*, or *deltoid*, is a triangular layer of fibres, attached superiorly by its apex to the internal malleolus, and inferiorly by an expanded base to the astragalus and os calcis.

The *External lateral ligament* consists of three strong fasciculi, which proceed from the inner side of the external malleolus, and diverge in three different directions. The *anterior fasciculus* passes forwards, and is attached to the astragalus; the *posterior*, backwards, and is connected with the astragalus posteriorly; and the *middle*, longer than the other two, descends to be inserted into the outer side of the os calcis.

The transverse ligament of the tibia and fibula occupies the place of a posterior ligament.

The *Synovial membrane* invests the cartilaginous surfaces of the tibia and fibula, sending a duplicature upwards between their lower ends and the upper surface and two sides of the astragalus. It is then reflected upon the anterior and lateral ligaments, and upon the transverse ligament posteriorly.

5. *Articulation of the Tarsal bones*.—The ligaments which connect the seven bones of the tarsus to each other are of three kinds,—

Dorsal,
Plantar,
Interosseous.

The *Dorsal ligaments* are small, flattened fasciculi, which pass from each bone to all the neighbouring bones with which it articulates.

The *Plantar ligaments* have the same disposition on the plantar surface of the foot; three of them, however, are of large size and have especial names, viz. the

Calcaneo-scaphoid, Short calcaneo-cuboid.

Long calcaneo-cuboid,

The *Calcaneo scaphoid ligament* is a broad and dense band of ligament which passes forwards, from the anterior border of the os calcis to the edge of the scaphoid bone. In addition to connecting the os calcis and scaphoid bone, it supports the astragalus, and forms part of the cavity in which its rounded head is received. It is lined upon its upper surface

with the synovial membrane of the astragalo-scaphoid articulation.

The *Long calcaneo-cuboid*, or *ligamentum longum plantæ*, is a long band of ligamentous fibres, which proceeds from the under surface of the os calcis to the rough surface on the under surface of the cuboid bone, its fibres being continued onwards to the bases of the third and fourth metatarsal bones.

It forms the inferior boundary of a canal in the cuboid bone, through which the tendon of the peroneus longus passes to its insertion into the base of the metatarsal bone of the great toe.

The *Short calcaneo-cuboid*, or *ligamentum breve plantæ*, is situated beneath the long plantar ligament; it is broad and extensive, and ties the under surfaces of the os calcis and cuboid bones firmly together.

The *Interosseous ligaments* are short and strong ligamentous fibres situated between the adjoining bones, and attached to all their rough surfaces. One of these, the *Calcaneo-astragaloid*, is lodged in the groove upon the upper surface of the os calcis, and the lower of the astragalus. It is large and very strong, and serves to unite the calcis and astragalus solidly together.

The Os calcis articulates with *two* bones; the external cuneiform with *six*; and the five other bones of the tarsus with *four* each.

6. The *Tarso-metatarsal articulation*.—The ligaments of this articulation are,

Dorsal,	Interosseus.
Plantar,	

The *Dorsal ligaments* connect the metatarsal to the tarsal bones, and the metatarsal bones with each other.

The *Plantar ligaments* have the same disposition on the plantar surface.

The *Interosseous ligaments* are situated between the metatarsal bones of the four lesser toes, and also between the base of the second metatarsal bone, and the internal and external cuneiform bones.

The metatarsal bone of the great toe has a distinct synovial membrane.

The metatarsal bone of the second toe is implanted by its base between the internal and external cuneiform bones. This

disposition must be recollected in amputation at the tarso-metatarsal articulation.

7. *Metatarso-phalangeal articulation*.—The ligaments of this articulation, like those of the articulation between the first phalanges and metacarpal bones of the hand, are,—

Anterior or plantar, Transverse.
Two lateral,

The *Anterior or plantar ligaments* are thick and fibro-cartilaginous, and form part of the articulating surface of the joint.

The *Lateral ligaments* are short and very strong, and situated on each side of the joints.

The *Transverse ligaments* are strong bands, which pass transversely between the anterior ligaments.

The expansion of the extensor tendon supplies the place of a dorsal ligament.

8. *Articulation of the phalanges*.—The ligaments of the phalanges are the same as those of the fingers, and have the same disposition; they are, therefore,

Anterior or plantar, Two lateral.

CHAPTER XII.

SYMPATHETIC NERVE.

THE *Sympathetic nerve* consists of a chain of ganglia, extending along the side of the vertebral column from the head to the coccyx; communicating with all the other nerves of the body; and distributing branches to all the internal organs and viscera.

It communicates with the other nerves immediately at their exit from the cranium and vertebral canal. The fourth and sixth nerves, however, form an exception to this rule, for with these it unites in the cavernous sinus; and with the olfactory, optic, and auditory, at their ultimate expansions.

The branches of distribution accompany the arteries which are distributed to the different organs; and form communications around them, which are called *plexuses*; and take the name of the artery with which they are associated: thus we have the mesenteric plexus, hepatic plexus, splenic plexus,

&c. All the *internal organs* of the head, neck, and trunk are supplied with branches from the sympathetic, and some of them exclusively; hence it is considered a nerve of *organic life*.

It is called the *ganglionic nerve*, from the circumstance of being formed by a number of *ganglia*; and from the constant disposition which it evidences, in its distribution, to communicate and form small knots or ganglia.

There are *six* sympathetic ganglia in the head: viz., the *ganglion of Ribes*; the *ciliary*, or lenticular; the *naso-palatine*, or Cloquet's; the *spheno-palatine*, or Meckel's; the *submaxillary*; and the *otic*, or Arnold's; *three* in the neck; *superior*, *middle*, and *inferior*: *twelve* in the *dorsal region*; *four* in the lumbar region; and four or five in the *sacral region*.

Each ganglion may be considered as a *distinct centre*, giving off branches in four different directions, viz., *superior* or *ascending*, to communicate with the ganglion above; *inferior* or *descending*, to communicate with the ganglion below; *external*, to communicate with the spinal nerves; and *internal*, to communicate with the sympathetic filaments of the opposite side, and to be distributed to the viscera.

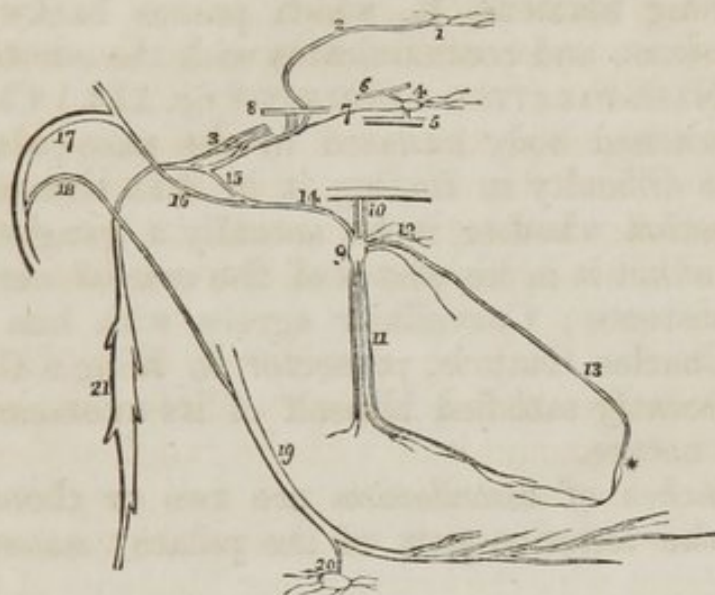
CRANIAL GANGLIA.

Ganglion of Ribes,
Ciliary or lenticular ganglion,
Naso-palatine, or Cloquet's ganglion,
Spheno-palatine, or Meckel's ganglion,
Submaxillary ganglion.
Otic, or Arnold's ganglion.

1. The GANGLION OF RIBES (*fig. 114., 1.*) is a small ganglion situated upon the anterior communicating artery, and formed by the union of the sympathetic filaments, 2. which accompany the ramifications of the two anterior cerebral arteries. These filaments are derived from the carotid plexus at each side; and, through their intervention, the ganglion of Ribes is brought in connexion with the carotid plexus, 3., and with the other ganglia of the sympathetic. This ganglion, though of very small size, is interesting, as being the superior point of union between the sympathetic chains of opposite sides of the body.

2. The CILIARY GANGLION (*lenticular*) (*fig. 114. 4., fig. 49. 22.*) is a small quadrangular flattened ganglion situated within the orbit, between the optic nerve and the external rectus: it is in close contact with the optic nerve, and is surrounded by a quantity of fat, which renders its dissection difficult.

Fig. 114. The cranial ganglia of the sympathetic nerve.



1. The ganglion of Ribes. 2. The filament by which it communicates with the carotid plexus (3.) 4. The ciliary or lenticular ganglion, giving off ciliary branches for the supply of the globe of the eye. 5. Part of the inferior division of the third nerve, receiving a short thick branch from the ganglion. 6. Part of the nasal nerve, receiving a longer branch from the ganglion. 7. A slender filament sent directly backwards from the ganglion to the sympathetic branches in the cavernous sinus. 8. Part of the sixth nerve in the cavernous sinus, receiving two branches from the carotid plexus. 9. Meckel's ganglion (spheno-palatine.) 10. Its ascending branches, communicating with the superior maxillary nerve. 11. Its descending branches, the posterior palatine. 12. Its anterior branches, spheno-palatine or nasal. 13. The naso-palatine branch, one of the nasal branches. * The point where Cloquet imagined the naso-palatine ganglion to be situated. 14. The posterior branch of the ganglion, the Vidian nerve. 15. Its carotid branch, communicating with the carotid plexus. 16. Its petrosal branch, joining the angular bend of the facial nerve. 17. The facial nerve. 18. The chorda tympani nerve, which descends to join the gustatory nerve. 19. The gustatory nerve. 20. The submaxillary ganglion, receiving the chorda tympani nerve from the gustatory. 21. The superior cervical ganglion of the sympathetic.

Its *Branches of distribution* are the *ciliary*, which arise from its anterior angles by two groups; the upper group consisting of about four filaments; and the lower, of five or six. They accompany the ciliary arteries in a waving course, and divide into a number of branches previously to piercing the

sclerotic around the optic nerve: they supply the tunics of the eye. A small filament is said, by Tiedeman, to accompany the arteria centralis retinæ into the globe of the eye.

Its *Branches of communication* are three: 1. from the posterior superior angle to the *nasal* branch, 6., of the ophthalmic nerve; 2. a short thick branch from the posterior inferior angle to the inferior division of the *third nerve*, 5; and 3., a long filament, 7., which passes backwards to the cavernous sinus, and communicates with the *carotid plexus*.

3. The NASO-PALATINE GANGLION (*fig. 114.*) Cloquet's, is a small lengthened body situated in the naso-palatine canal. There is no difficulty in finding it in that situation, but it is still a question whether it be actually a ganglion. Arnold refuses to admit it in his plates of the cranial nerves, and denies its existence; Cruveilhier agrees with him in opinion. But Mr. Charles Guthrie, prosector in King's College, London, has recently satisfied himself of its existence and of its ganglionic nature.

Its *Branches of distribution* are two or three small filaments to the anterior part of the palate; *anterior palatine nerves*.

Its *Branches of communication* are two long delicate filaments, 13., which ascend upon the septum narium, beneath the mucous membrane, and pass across the posterior part of the roof of the nares, and through the sphenopalatine foramina, to terminate in the sphenopalatine ganglion at each side.

4. The SPHENO-PALATINE GANGLION (*fig. 66. 9.*) (Meckel's) occupies the pterygo-palatine fossa, and is of considerable size.

Its branches are divisible into four groups: *ascending*; *descending*; *anterior* or *internal*; and *posterior*.

The *Branches of distribution* are, the *internal* or *nasal*, 12., four or five in number, which enter the nose through the sphenopalatine foramen, and supply the mucous membrane on the outer wall of the nares; and the *descending* or *posterior palatine*, 11., branches, three in number, which pass downwards through the posterior palatine canal, and are distributed to the mucous membrane of the nose and antrum maxillare, to the vellum palati, and to the palate.

The *Branches of communication* are the *ascending*, 10.,

two small branches which pass upwards to join the superior maxillary nerve; and the *posterior branch*, or *Vidian nerve*.

The *Vidian nerve* (*fig.* 66. 14.) passes directly backwards from the sphenopalatine ganglion, through the pterygoid or Vidian canal, to the foramen lacerum basis cranii, where it divides into two branches, the *carotid* and *petrosal*. The *Carotid branch*, 15., enters the carotid canal, and joins the carotid plexus. The *Petrosal branch*, 16., enters the cranium through the foramen lacerum basis cranii, and passes backwards beneath the Casserian ganglion, and beneath the dura mater, lying in a groove upon the anterior surface of the petrous bone, to the hiatus Fallopii. Entering the hiatus Fallopii, it immediately joins the facial nerve, just as that nerve is making its angular bend, previously to winding back along the inner wall of the tympanum. The petrosal branch accompanies the facial nerve, 17., along the aqueductus Fallopii, enclosed in its neurilema, to within a few lines of the stylo-mastoid foramen. It then quits the facial nerve, returning upon itself at an acute angle, and enters the tympanum near the base of the pyramid. It now takes the name of *chorda tympani*, 18., and crosses the tympanum enveloped in mucous membrane, between the handle of the malleus and long process of the incus to the fissura Glasseri: passing through a small opening in this fissure, it descends behind the condyle of the lower jaw, and behind the auricular and inferior dental nerves to the gustatory nerve, 19., which it joins at an acute angle. Accompanying the gustatory, enclosed in its neurilema, to the submaxillary gland, it quits that nerve and communicates with the submaxillary ganglion, 20.

The petrosal branch of the Vidian nerve receives a branch from the tympanic nerve while in the hiatus Fallopii.

The Vidian nerve thus becomes the medium of communication between the sphenopalatine ganglion and submaxillary ganglion; and between both of these ganglia and the carotid plexus; and through the tympanic nerve with the glosso-pharyngeal and pneumogastric nerves: and if the fusion of nervous substance be admitted, between the whole of these and the facial, the auditory, and the gustatory nerves.

5. The SUBMAXILLARY GANGLION (*fig.* 114. 20.) is of small size, but very distinct, and is situated in the submaxillary gland.

Its *Branches of distribution* are numerous, and ramify upon the ducts of the gland, and upon Wharton's duct.

Its *Branches of communication* are, 1., one or two small branches which join the gustatory nerve; and, 2. several minute branches which communicate with the sympathetic filaments ramifying upon the facial artery. It is associated with the carotid plexus, and the other cranial ganglia, by the petrosal branch of the Vidian.

6. The OTIC GANGLION (Arnold's) is a small red body, resting against the inner surface of the inferior maxillary nerve, immediately below the foramen ovale; it is in *relation externally* with the trunk of the inferior maxillary nerve, just at the point of union of the motor root; *internally*, it rests against the cartilage of the Eustachian tube and tensor palati muscle; and, *posteriorly*, it is in contact with the arteria meningeae media. It is closely adherent to the internal pterygoid nerve, and appears like a swelling upon that branch.

The branches of the otic ganglion are seven in number; two of distribution, and five of communication.

The *Branches of distribution* are—1. a small filament to the tensor tympani muscle; and, 2. one to the tensor palati muscle.

The *Branches of communication* are—1. two or three small branches to the motor root of the inferior maxillary nerve; 2. two branches to the auricular nerve; 3. a filament to the facial nerve; 4. a long filament, the *nervus petrosus superficialis minor*, to communicate with the tympanic nerve (Jacobson's) in the tympanum; and, 5. one or two small branches which join the sympathetic filaments of the arteria meningeae media artery.

CAROTID PLEXUS.—The ascending branch of the superior cervical ganglion enters the carotid canal with the internal carotid artery, and divides into two branches, which form several loops of communication with each other around the artery. This constitutes the *carotid plexus* (fig. 114. 3.) They also form, frequently, a small gangliform swelling upon the under part of the artery, which is called the *carotid ganglion*. It is not, however, constant; and, as it performs no especial function, we have not included it amongst the cranial ganglia of the sympathetic. A continuation of the carotid plexus onwards with the artery by the side of the sella turcica, is often called the cavernous plexus: this is an unneces-

sary and useless complication, and we therefore abstain from giving it a place in our description.

The carotid plexus is the centre of communication between all the cranial ganglia; and being derived from the superior cervical ganglion, between the cranial ganglia and those of the trunk, it also communicates with the greater part of the cerebral nerves, and distributes filaments with each of the branches of the internal carotid, which accompany them in all their ramifications.

Thus, the *Ganglion of Ribes* is formed by the union of the filaments which accompany the anterior cerebral arteries, and which meet on the anterior communicating artery. The *ciliary ganglion* communicates with the plexus by means of the long branch, which is sent back to join it in the cavernous sinus. The *spheno-palatine*, and with it the *naso-palatine ganglion*, joins the plexus by means of the carotid branch of the Vidian. The *submaxillary ganglion* is also connected with it through the Vidian. And the *otic ganglion* is brought in relation with it by means of the tympanic nerve and Vidian.

It communicates with the third nerve in the cavernous sinus, and through the ciliary ganglion; with the Casserian ganglion; with the *ophthalmic* division of the fifth in the cavernous sinus, and by means of the ciliary ganglion; with the superior maxillary, through the spheno-palatine ganglion; and with the inferior maxillary, through the chorda tympani and Vidian. It sends two branches directly to the sixth nerve, 8., which unite with it as it crosses the cavernous sinus: it communicates with the facial and auditory nerves, through the medium of the petrosal branch of the Vidian; and with the glosso-pharyngeal and pneumogastric nerves, through the *nervus petrosus superficialis minor*, a branch from the otic ganglion to the tympanic nerve.

CERVICAL GANGLIA.

The *Superior cervical ganglion* (*fig. 114. 21., fig. 115. 1.*) is long and fusiform, of a grayish colour, and smooth on the surface, and of considerable thickness; extending from within an inch of the carotid foramen in the petrous bone, to opposite the lower border of the third cervical vertebra. It is in relation, in front, with the sheath of the internal carotid artery and internal jugular vein; and, behind, with the rectus anticus major muscle.

Its *Branches*, like those of all the sympathetic ganglia in the trunk, are divisible into *superior*, *inferior*, *external*, and *internal*; to which may be added, as proper to this ganglion, *anterior*.

The *Superior*, 2., is a single branch which ascends by the side of the internal carotid, and divides into two branches; one lying to the outer side, the other to the inner side of that vessel. The two branches enter the carotid canal, and communicate by means of several filaments sent from one to the other, to constitute the *carotid plexus*.

The *Inferior* or descending branch, 3., sometimes two, is the cord of communication with the middle cervical ganglion.

The *External branches* are numerous, and may be divided into two sets: 1. Those which communicate with the glosso-pharyngeal, pneumogastric, and lingual nerves; and, 2. those which communicate with the first three cervical nerves, 4.

The *Internal branches* are three in number: 1. *Pharyngeal*, to assist in forming the pharyngeal plexus; 2. *Laryngeal*, to join the superior laryngeal nerve and its branches; and, 3. The *superior cardiac nerve*, 6., or *nervus superficialis cordis*.

The *Anterior branches* accompany the carotid artery with its branches, around which they form intricate plexuses; they are called, from the softness of their texture, *nervi molles*.

The *Middle cervical ganglion* (thyroid ganglion) is of small size, and is sometimes altogether wanting. It is situated opposite the fifth cervical vertebra, and rests upon the inferior thyroid artery. This relation is so constant, as to have induced Haller to name it the "thyroid ganglion."

Its *Superior branch*, 3., or branches, ascend to communicate with the superior cervical ganglion.

Its *Inferior branches* descend to join the inferior cervical ganglion.

Its *External branches* communicate with the third, fourth, and fifth cervical nerves.

Its *Internal branch*, 7., is the *middle cardiac nerve*, *nervus cardiacus magnus*.

The *Inferior cervical ganglion* (vertebral ganglion) is much larger than the preceding, and is constant in its existence. It is of a semilunar form, and is situated upon the base of the transverse process of the seventh cervical vertebra, immediately behind the vertebral artery: hence its title to the designation "*vertebral ganglion*."

Its *Superior branches* communicate with the middle cervical ganglion.

The *Inferior branches* pass some before and some behind the subclavian artery, to join the first thoracic ganglion.

The *External branches* consist of two sets; one which communicates with the sixth, seventh, and eighth cervical nerves; and one which accompanies the vertebral artery along the vertebral canal, forming the *vertebral plexus*. This plexus sends filaments to all the branches given off by the artery, and communicates in the skull with the filaments of the carotid plexus accompanying the branches of the internal carotid artery.

The *Internal branch*, 8., is the *inferior cardiac nerve*, *nervus cardiacus minor*.

CARDIAC NERVES.—The *Superior cardiac nerve*, (*fig. 115. 6.*) (*nervus superficialis cordis*) arises from the lower part of the superior cervical ganglion; it then descends the neck behind the common carotid artery, and, parallel with the trachea, crosses the inferior thyroid artery, and accompanying the recurrent laryngeal nerve for a short distance, passes behind the *arteria innominata* to the concavity of the arch of the aorta, where it joins the *cardiac ganglion*.

In its course it receives branches from the pneumogastric nerve, and sends filaments to the thyroid gland and trachea.

The *Middle cardiac nerve*, 7., (*nervus cardiacus magnus*) proceeds from the middle cardiac ganglion, or, in its absence, from the cord of communication between the superior and inferior. It is the largest of the three nerves, and lies nearly parallel with the recurrent laryngeal. At the root of the neck, it divides into several branches, which pass some before and some behind the subclavian artery; it communicates with the superior and inferior cardiac, and with the pneumogastric and recurrent nerves, and descends to the bifurcation of the trachea, to the *great cardiac plexus*.

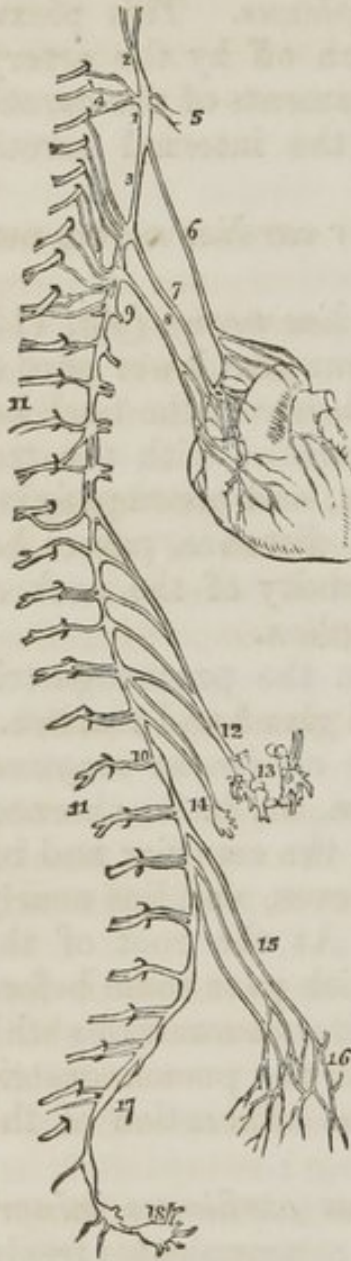
The *Inferior cardiac nerve* (8.) (*nervus cardiacus minor*) arises from the inferior cervical ganglion, communicates freely with the recurrent laryngeal and middle cardiac nerves, and descends to the front of the trachea to join the *great cardiac plexus*.

The *Cardiac ganglion* is a ganglionic enlargement of variable size, situated beneath the arch of the aorta, to the right side of the ligament of the ductus *arteriosus*. It receives the

superior cardiac nerves of opposite sides of the neck, and a branch from the pneumogastric nerve, and gives off numerous branches to the cardiac plexuses.

The *Great cardiac plexus* is situated upon the bifurcation of the trachea, above the right pulmonary artery, and behind the arch of the aorta. It is formed by the convergence of the middle and inferior cardiac nerves, and by branches from the pneumogastric nerve.

Fig. 115. The sympathetic nerve, its entire length.



The *Anterior cardiac plexus* is situated in front of the ascending aorta, near to its origin. It is formed by the communications of filaments that proceed from three different sources; 1stly, from the superior cardiac nerves, crossing the arch of the aorta; 2ndly, from the cardiac ganglion beneath the arch; and 3dly, from the great cardiac plexus, passing between the ascending aorta and the right auricle. The anterior cardiac plexus supplies the anterior aspect of the heart, distributing numerous filaments with the left coronary artery, which form the *anterior coronary plexus*.

The *Posterior cardiac plexus* is formed by numerous branches from the great cardiac plexus, and is situated upon the posterior part of the ascending aorta, near to its origin. It divides into two sets of branches; one set accompanying the right coronary artery in the auriculo-ventricular sulcus; the other set joining the artery on the posterior aspect of the heart. They both together constitute the *posterior coronary plexus*.

1. The superior cervical ganglion. 2. Its ascending or carotid branch, which divides into two branches. 3. Its descending branch. 4. Its external branches, communicating with the first, second, and third cervical nerves. 5. Internal branches to communicate with the facial eighth and ninth pairs, and with the pharyngeal plexus. 6. The superior cardiac nerve, superfi-

cialis cordis. 7. The middle or great cardiac nerve, arising from the second cervical ganglion. 8. The inferior cardiac nerve, from the inferior cervical ganglion. 9. The first dorsal ganglion. 10. The last dorsal ganglion. 11. Spinal nerves. 12. Great splanchnic nerve. 13. The two semilunar ganglia, which form by their communications the solar plexus. 14. The lesser splanchnic nerve, forming the renal plexus. 15. Branches from the lumbar ganglia. 16. The hypogastric plexus. 17. Sacral ganglia. 18. The last ganglion or the sympathetic, ganglion impar.

The great cardiac plexus likewise gives branches to the *auricles* of the heart and others, to assist in forming the *anterior and posterior pulmonary plexuses*.

THORACIC GANGLIA.

The *Thoracic ganglia* (*fig. 115, 9. 10.*) are twelve in number. They are flattened and triangular or irregular in form, and present the peculiar gray colour and pearly lustre of the other sympathetic ganglia: they rest upon the heads of the ribs, and are covered in by the pleura costalis. The first two and the last ganglia are usually the largest.

Their *Branches* are superior, inferior, external and internal.

The *Superior* and *inferior* are prolongations of the substance of the ganglia rather than branches; the *former* to communicate with the ganglion above, the *latter* with that below.

The *External branches*, two or three in number, to each of the spinal nerves, 11. 11.

The *Internal branches* of the five upper ganglia are *aortic*, and follow the course of the intercostal arteries to that trunk; the branches of the lower ganglia unite to form the two *splanchnic nerves*.

The *Great splanchnic nerve*, 12., arises from the sixth dorsal ganglion, and receives branches from the seventh, eighth, ninth, and tenth, which augment it to a nerve of considerable size. It descends in front of the vertebral column, within the posterior mediastinum, pierces the diaphragm immediately to the outer side of each crus, and terminates in the *semilunar ganglion*.

The *Lesser splanchnic nerve* (*renal*), 14., is formed by filaments from the tenth, eleventh, and sometimes, from the twelfth dorsal ganglia. It pierces the diaphragm, and descends to join the *renal plexus*.

The *semilunar ganglion*, 13., is a large, irregular, gangli-form body, pierced by numerous openings, and appearing like

the aggregation of a number of smaller ganglia, having spaces between them. It is situated by the side of the cœliac axis, and communicates with the ganglion of the opposite side, both above and below that trunk, so as to form a gangliform circle, from which branches pass off in all directions, like rays from a centre. Hence the entire circle has been named the *solar plexus*.

The *Solar plexus* receives the great splanchnic nerves; part of the lesser splanchnic nerves; the termination of the right pneumogastric nerve; some branches from the right phrenic nerve; and sometimes, one or two filaments from the left. It gives off numerous filaments, which accompany, under the name of *plexuses*, all the branches given off by the abdominal aorta. Thus, we have derived from the solar plexus the

Phrenic plexuses,	Renal plexuses,
Gastric plexus,	Superior mesenteric plexus,
Hepatic plexus,	Spermatic plexus,
Splenic plexus,	Inferior mesenteric plexus.
Supra-renal plexuses,	

The *Renal plexus* is formed chiefly by the lesser splanchnic nerve, but receives many filaments from the solar plexus.

The *Spermatic plexus* is formed principally by the renal plexus.

The *Inferior mesenteric plexus* receives filaments from the aortic plexus.

LUMBAR GANGLIA.

The *Lumbar ganglia* are four in number, of the peculiar pearly gray colour, fusiform, and situated upon the anterior part of the bodies of the lumbar vertebræ.

The *Superior* and *inferior branches* of the lumbar ganglia are branches of communication with the ganglion above and below as in the dorsal region.

The *External branches*, two or three in number, communicate with the lumbar nerves.

The *Internal branches* consist of two sets; of which the upper pass inwards in front of the abdominal aorta, and form around that trunk a plexiform interlacement, which constitute the *aortic plexus*; the lower branches, 15., cross the common iliac arteries, and unite over the promontory of the sacrum, to form the hypogastric plexus, 16.

The *Aortic plexus* is formed by branches from the lumbar

ganglia, and receives filaments from the solar and superior mesenteric plexuses. It sends filaments to the inferior mesenteric plexus, and terminates in the hypogastric plexus.

The *Hypogastric plexus* (*fig. 115. 16.*) is formed by the termination of the aortic plexus, and by the union of branches from the lower lumbar ganglia. It is situated over the promontory of the sacrum, between the two common iliac arteries, and bifurcates inferiorly into two lateral portions, which communicate with the sacral ganglia and sacral plexuses of the spinal nerves. It distributes branches to all the viscera of the pelvis, and to the branches of the internal iliac artery.

SACRAL GANGLIA.

The *Sacral ganglia*, 17., are four or five in number. They are situated upon the sacrum, close to the anterior sacral foramina, and resemble the lumbar ganglia in form and mode of connexion, although they are much smaller in size.

The *Superior* and *inferior branches* communicate with the ganglia above and below.

The *External branches* communicate with the sacral and coccygeal nerves.

The *Internal branches* communicate very freely with the lateral divisions of the hypogastric plexus, and are distributed to the pelvic viscera. The last sacral ganglia of opposite sides give off branches which join a small ganglion, situated on the first bone of the coccyx, called the *ganglion impar*, or *azygos*, 18. This ganglion resembles in its position and function the ganglion of Ribes, serving to connect the inferior extremity of the sympathetic nerve, as does the former ganglion its upper extremity. It gives off a few small branches to the coccyx.

...and various ... from the ... and ...
... It is ... to the ...
... is ... by the ...
... and ... of ...
... It is ... over the ...
... of the ...
... and ... into two ...
... of the ...
... It ... to all ...
... the ... of the ...

Section 10

The ... of the ...
... in the ...
... of the ...
... of the ...

The ... of the ...
... of the ...
... of the ...
... of the ...
... of the ...
... of the ...
... of the ...
... of the ...
... of the ...
... of the ...

INDEX

- Abdomen, 18
 Acini, 58
 Alimentary canal, 42
 Amphi-arthritis, 408
 Annulus ovalis, 295
 Anti-helix, 215
 Anti-tragus, ib
 Aorta, abdominal, 68
 arch, 301
 descending, ib
 Aponeurosis, 15
 Appendices epiploicæ, 41
 Appendix vermiformis cœci, 44
 Aqueductus cochleæ, 223
 Aqueous humour, 209
 Arachnoid membrane, 85, 282
 Arbor vitæ, 105
 uterina, 268
 Arch, femoral, 370
 palmar superficial, 335
 Axilla, 325
- ARTERIES, 16**
 anastomotic femoralis,
 356
 magna,
 367
 angular, 144
 aorta, 68
 articular azygous, 385
 inferior, 386
 superior, ib
 posterior, 145
 axillary, 312, 326
 basilar, 55
 brachial, 313, 327
 bronchial, 304
 carotid common, 140
 internal, 151
 carpal ulnar anterior, 339
- ARTERIES,**
 carpal ulnar posterior, 339
 radial anterior, 335
 posterior, ib
 centralis retinae, 184
 cerebellar inferior, 155
 superior, ib
 cerebral anterior, 87
 middle, ib
 posterior, 155
 cervicis superficialis, 156
 profunda, 156
 ciliary, 184
 circumflex anterior, 327
 external, 366,
 383
 ilii superficialis,
 356
 internal, 366
 posterior, 327
 cœliac, 52, 70
 colica dextra, 350
 media, 51
 sinistra, 52
 comes nervi phrenici, 157
 communicans cerebri an-
 terior, 87
 posterior, 88
 coronaria dextra, 300
 labii inferi-
 oris, 145
 superi-
 oris; ib
 sinistra, 300
 corporis bulbosi, 237
 cavernosi, 238
 cremasteric, 262,
 cystic, 53
 dental inferior, 149

ARTERIES,

dental superior, 150
 digitales manus, 339
 pedis, 404
 dorsales pollicis, 336
 dorsalis linguæ, 144
 pedis, 392
 penis, 238
 scapulæ, 327
 epigastric superficial, 356
 ethmoidal, 183
 facial, 144
 femoral, 364
 frontal, 183
 gastric, 52
 gastro-duodenalis, ib
 epiploica dextra, ib
 sinistra,
 58
 glutæal, 379, 256
 hæmorrhoidal external,
 236
 superior,
 52
 hepatic, 53, 56
 iliac internal, 254
 ilio-colic, 58
 lumbar, 255
 infra-orbital, 150
 intercostal, 304
 superior,
 156
 interosseous, 338
 anterior,
 ib
 interosseous posterior,
 338
 ishiatic, 380, 255
 lachrymal, 183
 laryngeal, 143
 lingual, 144
 lumbar, 68
 malleolar external, 391
 internal, ib
 mammary internal, 156
 masseteric, 145
 mastoid, ib
 maxillary internal, 147
 mediastinal, 157
 meningeal anterior, 152
 inferior, 146
 media, 149
 parva, ib
 posterior, 155
 mesenteric, 50, 68

ARTERIES,

mesenteric inferior, 51
 metatarsæ, 392
 nasal, 183
 obturator, 367, 255
 occipital, 146,
 ophthalmic, 152, 183
 palatine inferior, 145
 palpebral, 183
 pancreatica magna, 53
 pancreaticæ parvæ, ib
 pancreatico duodenalis,
 56
 perforantes femoralis,
 361
 plantaris,
 403
 pericardiac, 157
 perinei superficialis, 237
 peroneal, 399
 anterior, ib
 posterior, ib
 pharyngea ascendens,
 150
 phrenic, 68
 plantar external, 404
 internal, ib
 popliteal, 385
 princeps cervicis, 146
 pollicis, 336
 profunda femoris, 366
 inferior, 328
 superior, ib
 pterygo-palatine, 150
 pudic external, 236, 366
 internal, 255, 236,
 380
 pulmonary, 298, 303
 pyloric, 53
 radial, 313, 335
 radialis indicis, 337
 recurrens interosseæ, 338
 radialis, 336
 tibialis, 391
 ulnaris, ante-
 rior, 338
 ulnaris poste-
 rior, ib
 renal, 68
 sacra media, ib
 lateralis, 256
 scapular posterior, 156
 sigmoid, 52
 spermatic, 68, 262
 spheno-palatine, 150

- ARTERIES,**
 spinalis anterior, 88, 155
 posterior,
 ib.
 splenic, 53
 subclavian, 152, 313
 sublingual, 144
 submental, ib
 subscapular, 155, 327
 superficialis volæ, 336
 supra-orbital, 183
 renal, 68
 sural, 386
 tarsea, 392
 temporal, 146
 anterior, ib
 media, ib
 temporal posterior, 146
 thoracica acromialis, 326
 axillaris, 327
 inferior, ib
 superior, ib
 tibialis antica, 391
 postica, 398
 transversalis faciei, 146
 tympanic, 149, 152
 ulnar, 327
 umbilical, 255
 vasa brevia, 53
 vertebral, 154
 Vidian, 150
 Arytæmoid cartilages, 168
 glands, 174
 Auricles of the heart, 294, 296
 Auriculo-ventricular openings, 294,
 296
 Axilla, 325

 Base of the brain, 105
 Bladder, 245, 264
 Bones, 15
 Brain, 92
 Bronchial tubes, 289
 Bronchi, 303
 Brunner's glands, 47
 Bulb of the corpus spongiosum, 231
 Bulbous part of the urethra, 250

 Calamus scriptorius, 103
 Calices, 72
 Canal of Petit, 208
 Canthi, 211
 Capsule of Glisson, 40
 Capsules supra-renal, 71
 Caput-gallinaginis, 250

 Cartilages inter-articular of the
 clavicle, 418
 inter articular of the jaw,
 413
 semi-lunar, 428
 Caruncula lachrymalis, 213
 Carunculæ myrtiformes, 266
 Casserian ganglion, 117
 Centrum ovale minus, 92
 majus, 93
 Cerebellum, 104
 Cerebro-spinal axis, 90
 Cerebrum, 92
 Chordæ tendineæ, 297
 vocales, 169
 Willisii, 80
 Choroid membrane, 205
 plexus, 96, 103
 Cilia, 212
 Ciliary ligament, 206
 processes, ib
 Circle of Willis, 89
 Circulation, adult, 293
 Clitoris, 265
 Cochlea, 223
 Cœcum, 44
 Colon, 44
 Columnæ carneæ 297,
 Commissures, 90
 anterior, 102
 great, 96
 soft, 102
 posterior, ib
 Concha, 215
 Coni vasculosi, 261
 Conjunctiva, 212
 Corium, 227
 Cornea, 203
 Cornu ammonis, 96, 97
 Cornua ventriculorum, 95
 Corpora albicantia, 102, 118
 Arantii, 297
 cavernosa, 231, 257
 olivaria, 111
 pyramidalia, 284
 quadrigemina, 102
 restiforma, 109, 111
 striata, 95
 Corpus callosum, 93
 fimbriatum, 96
 Highmorianum, 259
 spongiosum, 257
 striatum, 95
 Cowper's glands, 244
 Cricoid cartilage, 168

- Crico-thyroid membrane, 169
 Crura cerebelli, 106
 cerebri, 108
 penis, 232
 Crystalline lens, 209
 Cuticle, 14, 228
 Cutis, 15, 226
 Cystic duct, 57
- Dartos, 258
 Deep fascia, 15
 Dermis, *ib*
 Detrusor urinæ, 249
 Diaphragm, 73
 Diarthrosis, 409
 Dorsi-spinal veins, 286
 Ductus ad nasum, 215
 arteriosus, 301
 communis choledochus, 54
 cysticus, 57
 ejaculatorius, 262
 hepaticus, 56
 pancreaticus, 67
 prostaticus, 251
 thoracicus, 306
 Duodenum, 43
 Dura matter, 80, 281
- Ear, 215
 Encephalon, 90
 Epidermis, 14
 Epididymis, 261
 Epiglottic gland, 173
 Epiglottis, 169
 Epithelium, 46
 Eustachian tube, 219
 valve, 295
- Eye, 202
 brows, 211
 globe, 202
 lashes, 212
 lids, 211
- Falciform process, 357
 Fallopian tubes, 268
 Falx cerebelli, 81
 cerebri, *ib*
 Fascia, cervical, deep, 125
 superficial, 124
 Fascia, cribiform, 358
 deep, 15
 dentata, 98
 inter-columnar, 22
 lata, 251
 palmar, 332
- Fascia, pelvic, 253
 perineal, deep, 230
 superficial, 231
 plantar, 400
 propria, 259
 spermatice, *ib*
 superficial, 14
 thoracic, 288
- Fauces, 194
 Femoral hernia, 369
 ring, 374
 Fenestra ovalis, 219, 222
 Fimbriæ, Fallopian, 268
 Fissure of Sylvius, 92
 Foramen commune anterius, 102
 posterius, *ib*
 of Monro, 99
 of Sæmmering, 207
 of Winslow, 40
 Foramina Thebesii, 295
 Fornix, 99
 Fossa innominata, 215
 navicularis vaginæ, 264
 ovalis, 295
 scaphoides, 215
 Fourchette, 264
 Fræna epiglottidis, 170
 Frænum linguæ, 224
 præputii, 258
 Fundus, 267
- Gall-bladder, 57
 Ganglia, cervical, 439
 cranial, 434
 lumbar, 444
 sacral, 445
 semi-lunar, 67, 443
 thoracic, 443
 Ganglion of Andersch, 158
 azygos, 445
 cardiac, 308, 441
 carotid, 438
 Casserian, 117
 ciliary, 183, 189, 435
 lenticular, 183, 435
 Meckel's, 436.
 naso-palatine, 189, 191,
 436
 of Ribes, 189, 434, 439
 otic, 190, 438
 spheno-palatine, 190, 436
 submaxillary, 189, 191,
 437.
 thyroid, 440
 vertebral, *ib*

- Gimbernat's ligament, 21, 372
 Gland, epiglottic, 173
 lachrymal, 214
 parotid, 131
 pineal, 102
 pituitary, 108
 prostate, 252
 thyroid, 175
 Glands, arytenoid, *ib*
 Brunner's, 47
 Cowper's, 240.
 inguinal, 356
 Meibomian, 212
 Pacchionian, 80
 Peyer's, 47
 salivary, 138, 139
 solitary, 47
 sublingual, 139
 submaxillary, 138
 Glandulæ odoriferæ, 258
 Pacchioni, 80
 Tysoni, 258
 Glans clitoridis, 265
 penis, 231, 257
 Glisson's capsule, 40
 Globus major epididymis, 261
 minor epididymis, *ib*
 Glottis, 169
 Gomphosis, 408

 Hair, 229
 Harmonia, 408
 Heart, 292
 Helix, 216
 Hernia, 29
 congenital, 35
 encysted, 36, 262
 femoral, 370
 inguinal, 30, 33
 umbilical, 29
 ventral, 30
 Hippocampus major, 97
 minor, *ib*
 Hyaloid membrane, 209
 Hymen, 265

 Neum, 44
 Incus, 217
 Infundibula, 71
 Infundibulum, 108
 Integument, 13
 Intestinal canal, 45
 Iris, 205

 Iter ad infundibulum, 102
 a tertio ad quartum ventricu-
 lum, 102

 Jacob's membrane, 207
 Jejunum, 44
 Joint, ankle, 430
 elbow, 421
 hip, 426
 lower jaw, 413
 knee, 427
 shoulder, 419
 wrist, 423

 Kidneys, 71

 Labia majora, 264
 minora, 265
 Labyrinth, 221
 Lachrymal ducts, 214
 gland, *ib*
 puncta, *ib*

 Lacteals, 51
 Lacunæ, 252
 Lamina cribrosa, 203
 spiralis, 223
 Larynx, 167
 LIGAMENTS, 16
 acromio-clavicular superior,
 419
 acromio-clavicular inferior, *ib*
 alar, 429
 annular ankle, anterior, 423
 radius, 422
 wrist, anterior, 423
 annular wrist, posterior, 423
 arcuatum externum, 73
 internum, *ib*
 atlo-axoid anterior, 413
 posterior, *ib*
 calcaneo-astragaloid, 432
 cuboid, long, *ib*
 short, *ib*
 scaphoid, 431
 capsula of the hip, 423
 jaw, 414
 rib, *ib*
 shoulder, 421
 thumb, 424
 carpus dorsal, 423
 palmar, *ib*
 common anterior, 410
 posterior, *ib*
 coracoid, 421
 coraco acromial, *ib*

LIGAMENTS,

coraco clavicular, 421
 humeral, ib
 coronary, 56
 of the knee, 428.
 costo-clavicular, 420
 sternal anterior, 416
 posterior, ib
 transverse anterior, 415
 middle, ib
 posterior, ib
 vertebral anterior, 416
 cotyloid, 426
 crucial, 428
 dorsal of the tarsus, 430
 of the elbow, 421
 glenoid, ib
 hip joint, of the, 426
 ilio-femoral, ib
 inter-articular of the ribs, 416
 inter-clavicular, 420
 osseous, astragalo-calca-
 neoid, 432
 peroneo-tibial, 430
 interosseous peroneo-tibial in-
 ferior, 430
 interosseous, radio ulna, 422
 inter-spinous, 411
 inter-transverse, 412
 inter-vertebral, 411
 lateral of the ankle, 431
 elbow, 421
 jaw, 413
 knee, 427
 wrist, 423
 lumbo-iliac, 416
 sacral, ib
 metacarpus dorsal, 424
 palma, 425
 mucosum, 429
 oblique, 422
 obturato, 419
 occipito-atloid anterior, 412
 posterior, ib
 axoid, anterior, ib
 posterior, ib
 odontoid, 412
 of the liver, 55
 patella, 427
 peroneo-tibial anterior supe-
 rior, 430-31
 posterior supe-
 rior, ib
 anterior infe-
 rior, ib

LIGAMENTS,

peroneo-tibial posterior, infe-
 rior, ib
 phalanges, of the foot, 433
 plantar, long, 432
 short, ib
 posticum Winslowii, 427
 pubic anterior, 418
 posterior, ib
 superior, ib
 rhomboid, 419
 rotundum, hepatis, 56
 sacro-coccygean anterior, 417
 posterior, ib
 sacro-iliac anterior, ib
 oblique, ib
 posterior, ib
 ischiatic anterior, 417
 posterior, ib
 stellate, 415
 sterno-clavicular anterior, 419
 posterior, ib
 sub-flava, 411
 sub-pubic, 418
 supra spinous, 410
 suspensorium hepatis, 56
 penis, 258
 tarsal dorsal, 432
 plantar, ib
 tarso-metatarsal, ib
 teres, 426
 transverse of the acetabulum,
 426
 of the atlas, 413
 of the metatarsus, 432
 of the scapula, 420
 of the semilunar cartilages,
 428
 trapezoid, 414
 Linea alba, 20
 Lineæ transversæ, 20, 103
 semi-lunares, 20
 Linguetta laminosa, 105
 Liquor Cotunnii, 223
 Morgagni, 209
 of Scarpa, 223
 Liver, 54
 Lobules of the liver, 58
 Lobuli testis, 261
 Lobulus caudatus, 55
 pneumo-gastricus, 104
 quadratus, 55
 Spigellii, ib
 Locus niger, 93
 per.oratus, 109

Lungs, 289
 Lymphatic vessels, 16
 Lyra, 99

Malleus, 217
 Mastoid cells, 219
 Meatus auditorius externus, 216
 urinarius, female, 266
 male, 251
 Meatuses of the nares, 200
 Meckel's ganglion, 436
 Mediastinum anterior, 290
 middle, 291
 posterior, 291, 304
 testis, 259
 Medulla oblongata, 109
 Meibomian glands, 212
 Membrana dentata, 283
 pigmenti, 206
 tympani, 217
 Membrane, choroid, 205
 hyaloid, 207
 Jacob's, ib
 Membranous part of the urethra, 251
 Mesenteric glands, 51
 Mesentery, 41
 Meso-cola, ib
 Meso-rectum, ib
 Mitral valves, 299
 Mons Veneris, 264
 Mucous membrane, structure, 46
MUSCLES, 15
 abductor minimi digiti, 349
 abductor minimi pedis, 401
 abductor pollicis, 347
 pedis, 401
 accelerator urinæ, 234
 accessorius, 401
 adductor brevis, 362
 longus, ib
 magnus, ib
 pollicis, 348
 anconeus, 345
 anti-tragicus, 216
 arytenoideus, 171
 aryteno-epiglottideus, inferior, ib
 aryteno-epiglottideus, superior, ib
 attollens aurem, 120
 attrahens aurem, 121
 azygos uvulæ, 195
 biceps flexor cruris, 382
 cubiti, 322
 Biventer cervicis, 276

MUSCLES,
 brachialis anticus, 322
 buccinator, 122
 cervicalis ascendens, 275
 circumflexus palati, 195
 complexus, 276
 compressor nasi, 119
 compressor urethræ, 240
 venæ dorsalis
 penis, 240
 constrictor inferior, 192
 isthmi faucium, 195
 medius, 192
 superior, 193
 vaginæ, 244
 coraco-brachialis, 321
 corrugator supercillii, 119
 cremaster, 25
 crico-arytænoideus lateralis, 171
 crico-arytænoideus posticus, ib
 thyroideus, 170
 crureus, 360
 deltoid, 318
 depressor anguli oris, 120
 depressor labii inferioris, ib
 depressor labii superioris
 alæque nasi, ib
 detrusor urinæ, 249
 diaphragm, 73
 digastricus, 127
 erector clitoridis, 244
 penis, 235
 extensor carpi radialis brevis, 343
 carpi radialis longior, ib
 carpi ulnaris, 344
 digiti minimi, ib
 digitorum brevis, 391
 digitorum communis, 344
 digitorum longus, 389
 extensor indicis, 346
 ossis metacarpi
 pollicis, 345
 primi internodii
 pollicis, 346
 pollicis proprius, 388
 secundi internodii
 pollicis, 346
 flexor brevis digiti minimi, 349

MUSCLES,

flexor brevis digiti minimi
pedis, 401
carpi radialis, 333
ulnaris, 334
digitorum brevis, 401
profundus,
334
digitorum sublimis, ib
longus digitorum pe-
dis, 397
longus pollicis pedis,
ib
ossis metacarpi dig.
min. 349
ossis metacarpi pol-
licis, 346
pollicis brevis, ib
pedis,
391
longus, 335
gastrocnemius, 395
gemellus inferior, 378
superior, 377
genio-hyo glossus, 129
hyoideus, ib
gluteus maximus, 375
medius, 376
minimus, ib
gracilis, 363
helicis major, 216
minor, ib
hyo-glossus, 129
iliacus, 75, 361
infra-spinatus, 322
inter-costal external, 287
internal, ib
interossei manus, 349
pedis dorsales,
392
pedis plantares,
406
inter-spinales, 277
inter-transversales, ib
latissimus dorsi, 271
laxator tympani major, 218
minor, ib
levator anguli oris, 120
scapulæ, 272
ani, 253
labii inferioris, 120
superioris, ib
superioris, al-
æque nasi,
120

MUSCLES,

levator palati, 195
palpebræ, 177
levatores costarum, 277
lingualis, 129
longissimus dorsi, 274
longus colli, 196
lumbricales manus, 349
pedis, 401
masseter, 121
multifidus spinæ, 277
mylo-hyoideus, 129
obliquus abdominis exter-
nus, 21
obdominis inter-
nus, 24
inferior, 277
superior, ib
oculi inferior, 177
oculi superior, ib
obturator externus, 362
internus, 377
occipito-frontalis, 78
omo-hyoideus, 127
opponens pollicis, 398
orbicularis oris, 119
palpebrarum, ib
palato-glossus, 130, 195
pharyngeus, 194, 195
palmaris brevis, 350
longus, 334
pectineus, 367
pectorales major, 315
minor, 316
peroneus brevis, 393
longus, ib
tertius, 388
plantaris, 395
platysma myoides, 124
popliteus, 397
pronator quadratus, 335
radii teres, 326
psaos magnus, 75, 361
parvus, ib
peterygoideus externus, 122
internus, 122
pyramidalis nasi, 119
pyriformis, 377
quadratus femoris, 379
lumborum, 76
rectus capitis anticus major,
196
anticus minor,
ib
lateralis, 276

MUSCLES,

rectus capitis posticus
 major, ib
 posticus,
 minor, ib
 rectus femoris, 359
 oculi externus, 177
 rectus oculi inferior, ib
 internus, ib
 superior, ib
 retrahens aurem, 121
 rhomboideus major, 272
 minor, ib
 sacro-lumbalis, 274
 sartorius, 359
 scalenus anticus, 196
 posticus, ib
 semi-spinalis colli, 276
 dorsi, ib
 membranosus, 382
 serratus magnus, 318
 posticus inferior,
 280
 serratus posticus superior,
 ib
 soleus, 396
 sphincter ani externus, 236
 internus, ib
 splenius capitis, 274
 colli, ib
 stapedus, 218
 sterno-cleido-mastoideus,
 126
 hyoideus, 127
 thyroideus, ib
 stylo-glossus, 130
 hyoideus, 128
 pharyngeus, 193
 subclavius, 317
 subcrureus, 415
 subscapularis, 317
 supinator radii brevis, 345
 longus, 343
 supra-spinales, 277
 supra-spinatus, 325
 temporalis, 121
 tensor palati, 195
 tympani, 218
 vaginæ femoris, 360
 teres major, 323
 minor, ib
 thyro-arytenoideus, 171
 epiglottideus, ib
 hyoideus, 127
 tibialis anticus, 388

MUSCLES,

tibialis posticus, 398
 trachelo-mastoideus, 275
 tragicus, 216
 transversalis abdominis, 27
 colli, 274
 transversus auriculæ, 216
 pedis, 403
 perinei, 235
 trapezius, 271
 triangularis sterni, 287
 triceps extensor cubiti,
 323
 vastus externus, 360
 internus, ib
 zygomaticus, major, 120
 minor, ib

Musculi pectinati, 296

Nails, 229

Nasal duct, 214
 fossæ, 199

NERVES, 16

abducentes, 115
 auditory, 114, 224
 auricularis magnus, 136,
 189
 posterior, 134
 buccal, 187
 cardiac, 441
 cardiacus inferior, ib
 magnus, 441
 cardiacus medius, ib
 superior, ib
 cervico-facial, 134
 chorda tympani, 218
 134, 437
 circumflex, 331
 claviculares, 167
 communicans poplitei, 385
 peronei, 385
 noni, 167
 cruralis, 77, 368
 cutaneus externus bra-
 chialis, 330
 externus fe-
 moralis, 357,
 368
 dental anterior, 187
 dental inferior, 188
 posterior, 187
 descendens noni, 163
 digastric, 134
 fascial, 116, 133
 femoral, 368

NERVES,

fifth pair, 117, 185
 first pair, 113
 fourth pair, 116, 182
 genito-crural, 77
 glosso-pharyngeal, 116, 158
 gluteal, 381, 256
 gustatory, 188, 225
 hypo-glossal, 116
 infra-trochlear, 181
 inguino-cutaneous, 77
 intercostal, 308
 interosseus anticus, 340
 posticus, 341
 ischiaticus major, 256, 381,
 384
 minor, 256
 lachrymal, 182
 laryngeal inferior, 161
 superior, 160
 lingual, 116, 163, 225
 lumbo-sacral, 256
 masseteric, 187
 maxillaris inferior, 187
 superior, 185
 median, 341, 330
 motor-oculi, 115, 182
 musculo-cutaneous, leg, 394,
 77
 musculo-spiral, 341, 331
 nasal, 181, 200, 436
 obturator, 370, 77
 occipitalis minor, 136, 167
 olfactory, 113
 ophthalmic, 179, 185
 optic, 113
 orbital, 186
 palatine posterior, 436, 437
 pathetici, 116
 peroneal, 386, 392, 394
 pharyngeal, 160, 161, 440
 phrenic, 167
 plantar external, 404
 internal, ib
 pneumogastric, 307, 159
 popliteal, 386
 portio dura, 133
 mollis, 114
 pterygoid, 187
 pudic internal, 256, 381
 radial, 331, 344
 saphenus externus, 393, 309
 major, 369
 minor, ib
 second pair, 113

NERVES,

sixth pair, 115, 182
 spinal accessory, 117, 163
 splanchnicus major, 67, 443,
 308
 minor, 443, 309
 subscapular, 330
 superficialis colli, 136
 trochlear, 336
 sympatheticus major, 434,
 164
 temporales profunda, ib
 temporo-facial, 134
 third pair, 115, 182
 thoracic short, 329
 long, ib
 tibialis anticus, 388, 393, 394
 posticus, 397
 triangularis sterni, 287
 trifacial, 117, 185
 trigeminus, ib
 trochlear, 116
 tympanic, 158
 ulnar, 330, 340
 vagus, 116
 Vidian, 437

Nose, 197

Œsophagus, 42, 306

Omentum great, 41
 lesser, 40

Omentum splenic, 42

Optic commissure, 107
 thalami, 101

Orbiculare os, 218

Ossicula auditûs, ib

Ovaries, 268

Ovula, Graafiana, 269

Ovula of Naboth, 267

Palpebræ, 211

Pancreas, 66

Papillæ, 225

 calyciformes, ib

 circumvallatæ, 225

 conicæ, ib

 filiformes, ib

 fungiformes, 225

Parotid gland, 131

Penis, 231, 257

Pericardium, 292

Perineum, 230

Peritoneum, 37

Perspiratory ducts, 229

Pes accessorius, 97

- Pes hippocampi, 97
 Pharynx, 42, 191
 Pores, 229
 Pia mater, 86, 283
 Pineal gland, 102
 Pinna, 215
 Pituitary gland, 200
 Pleura costalis, 290
 pulmonalis, *ib*
 Plexus, aortic, 444
 axillary, 313, 329
 cardiac, 375, 442
 carotid, 438
 cervical anterior, 166
 posterior, 167
 choroid, 96
 coronary anterior, 443
 posterior, *ib*
 hypogastric, 445
 lumbar, 76
 mesenteric inferior, 444
 mesentric superior, 51
 oesophageal, 307
 pulmonary anterior, 291, 307
 posterior, 291, 307
 renal, 444
 sacral, 256
 solar, 444
 spermatic, 444
 submaxillary, 443
 vertebral, 441
 Plica semi-lunaris, 214
 Pomum Adami, 168
 Pons Tarini, 108
 Varolii 108, 112
 Portio dura, 133
 mollis, 114
 Porus opticus, 203
 Poupart's ligament, 21
 Prepuce, 258
 Processus è cerebello ad testes, 103,
 105
 vermiformes inferior, 105
 superior, *ib*
 Promontory, 220
 Prostate gland, 252
 Prostatic part of the urethra, 250
 Pulmonary artery, 298
 veins, 303
 Puncta lachrymalia, 214
 Pylorus, 42

 Raphe corporis callosi, 95
 Receptaculum chyli, 306
 Rectum, 44

 Respiratory tract, 109
 Renal capsule, 71
 Rete mucosum, 227
 Retina, 206

 Saphenous opening, 358
 vein, internal, 357
 external, 384
 Scala vestibuli, 222
 Schindylesis, 408
 Sclerotic coat, 203
 Scrotum, 258
 Sebaceous follicles, 229
 Semicircular canals, 222
 Semilunar valves, 297
 Septum lucidum, 99
 Sheath of the rectus, 30
 Sigmoid valves, 297, 298
 Sinus basilar, 85
 cavernous, 84
 circular, 85
 fourth, 83
 lateral, *ib*
 longitudinal inferior, 82
 superior, *ib*
 occipital anterior, 83
 posterior, *ib*
 petrosal inferior, 84
 superior, 85
 rectus or straight, 83
 transverse, 85
 Skin, 226
 Soft palate, 194
 Spermatic cord, 25, 262
 Spinal cord, 281
 nerve, 285,
 Spleen, 66
 Spongy part of the urethra, 251
 Stapes, 218
 Stenon's duct, 132
 Stomach, 42
 Sub-arachnoidean fluid, 86
 space, 282
 Sublingual gland, 139
 Submaxillary gland, 138
 Substantia perforata, 106
 Sulcus longitudinalis anterior, 283
 superior, 284

 Supercilia, 211
 Superficial fascia, 14
 Supra-renal capsules, 70
 Suspensory ligament of the liver, 56
 penis, 258
 Sympathetic nerve, 67, 157
 Synarthrosis, 408

- Tenia semicircularis, 95
 Tarsal cartilages, 211
 Tendo Achillis, 395
 Tendon, 15
 Tentorium cerebelli, 81
 Testicles 259
 Thalami optici, 96, 101
 Thoracic duct, 306
 Thorax, 287
 Thyro-hyoid membrane, 169
 Thyroid cartilage, 168
 gland, *ib*
 Tongue, 224
 Tonsils, 105
 Torcular Herophili, 84
 Trachea, 174, 303
 Tragus, 215
 Tricuspid valves, 296
 Trigone vesicale, 250
 Tuber cinereum, 107
 Tubercula quadrigemina, 102
 Tuberculum Loweri, 296
 Tubuli seminiferi, 261
 uriniferi, 72
 Tunica albuginea oculi, 203
 testis, 259
 erythroides, *ib*
 vaginalis, 259
 vasculosa testis, 261
 Tympanum, 217
 Tyson's glands, 258

 Urachus, 248
 Ureters, 72, 248
 Urethra, female, 263
 male 250
 Uterus, 267
 Uvula palati, 194
 vesicæ, 250

 Vagina, 266,
 Valve, arachnoid, 103
 Eustachian, 296
 of Vieussens, 103
 mitral, 299
 semi-lunar, 297
 sigmoid, *ib*
 tricuspid, 296
 Vasa pampiniformia, 262
 recta, 261
 Vas deferens, 252, 261
 Veins, 16
 azygos, 305
 minor, 306
 basilic, 320
 Veins, cava inferior, 70, 294, 303
 superior, 294, 303
 c phalic, 321
 coronary, 295
 dorsalis penis, 238
 dorsi-spinales, 286
 femoral, 367
 Galenii, 100
 gastric, 54
 hepatic, 56, 70
 innominatæ, 303
 jugular, external, 136
 internal, 152
 median, 321
 basilic, 320
 cephalic, 321
 medulli-spinal, 286
 meningo-rachidian, 286
 ophthalmic, 184
 portal, 56
 profunda femoris, 368
 pulmonary, 298, 303
 radial, 321
 renal, 71
 sacra media, 70
 salvatella, 320
 saphena interna, 357
 externa, 384, 395
 spermatic, 70
 splenic, 54
 ulnar anterior, 329
 posterior, *ib*
 Velum interpositum, 100
 pendulum palati, 194
 Ventricle of Arantius, 103
 Ventricles of the brain,
 fifth, 99
 fourth, 102
 lateral, 95
 third, 101
 of the heart, 295, 299
 larynx, 172
 Vermiform processes, 104
 Veru montanum, 251
 Vesiculæ seminales, 252
 Vestibule, 221
 Vestibulum vaginæ, 266
 Vibrissæ, 197
 Villi, 46
 Vitreous humour, 209
 Vulva, 264

 Wharton's duct, 138
 Zonula ciliaris, 207

