

Rhinoplastic operations : with some remarks on the autoplastic methods usually adopted for the restoration of parts lost by accident or disease / by J. Mason Warren.

Contributors

Warren, Jonathan Mason, 1811-1867.
National Library of Medicine (U.S.)

Publication/Creation

Boston : Clapp, 1840.

Persistent URL

<https://wellcomecollection.org/works/qengsftq>

License and attribution

This material has been provided by This material has been provided by the National Library of Medicine (U.S.), through the Medical Heritage Library. The original may be consulted at the National Library of Medicine (U.S.) where the originals may be consulted.

This work has been identified as being free of known restrictions under copyright law, including all related and neighbouring rights and is being made available under the Creative Commons, Public Domain Mark.

You can copy, modify, distribute and perform the work, even for commercial purposes, without asking permission.



Wellcome Collection
183 Euston Road
London NW1 2BE UK
T +44 (0)20 7611 8722
E library@wellcomecollection.org
<https://wellcomecollection.org>


WV

W291r

1840








RHINOPLASTIC OPERATIONS.

WITH SOME REMARKS ON THE

AUTOPLASTIC METHODS

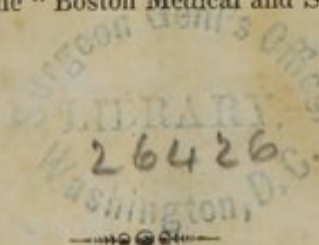
USUALLY ADOPTED FOR THE

RESTORATION OF PARTS LOST BY ACCIDENT OR
DISEASE.



BY J. MASON WARREN, M.D.

Republished from the "Boston Medical and Surgical Journal."



BOSTON:

D. CLAPP, JR.—184 WASHINGTON STREET.

1840.

WV
W291m
1840

RHINOPLASTIC OPERATIONS.

CASE I.

THE history of the patient who was the subject of this operation, we shall give very briefly, as follows.

J. T. 28 years of age. Three years ago last spring, while scuffling with one of his companions, he received a violent blow on the nose, which dislocated the cartilage, driving it at the same time over to the left side. Some inflammation came on in the nose at the time of the accident, which very shortly subsided; and as he was out of town, and at a distance from medical advice, nothing was done to replace the cartilage, which remained in the situation into which it had been driven by the blow.

In the following spring, while pursuing his ordinary occupations, a small red spot appeared on the right cheek just below the eye; this very soon increased in size, the inflammation gradually spread, first attacking the lip, and from thence extending to the nose, which became red, swollen, and finally ulcerated.

It will be unnecessary to go further into the details of the case; suffice it to say, that in the course of eighteen months the whole nose, cartilages, septum, bones, &c. were successively attacked, and finally completely destroyed; the ulceration had also extended to the cheek of the opposite side. Subsequently to this, cicatrization gradually took place, leaving the patient in the state in which I saw him, six months after his recovery from the disease.

At this period, having accidentally come across a description of the Taliacotian operation, in an old magazine, he applied to know whether anything of a similar kind could be done to remedy his frightful deformity. The following was his state as he appeared on the first examination.

The nose, as described above, was completely destroyed, leaving in the place it originally occupied an opening about an inch in dia-

meter, bordered by a firm cicatrice ; the septum of the nostrils was destroyed, and the two nasal cavities thrown into one ; externally a small cicatrix descended from the lower and left edge of this opening to the angle of the mouth. In the course of the disease the four front teeth had been lost, and this, together with the absorption of the alveolar processes, had caused the upper lip to sink nearly an inch below the level of the lower one. An opening also existed between the lip and upper jaw, through which a probe might be passed from the mouth into the nasal cavities. The sense of smell was quite lost, and he was subject to a frequent flowing of tears over the face, arising undoubtedly from the too sudden contact of the air with the lachrymal ducts.

A thorough examination of his case having been made, and finding there was no positive obstacle against the possibility of the success of an operation, the difficulties of such an operation as would be required were distinctly stated to him, the improbability of its succeeding so as to restore the organ in such a manner that the deformity should not be known, that the new nose might become very much flattened, and perhaps on the appearance of cold weather gangrene might take place, and finally, that even his life might be endangered by it. I felt it my duty to state the case plainly, having seen all these accidents occur abroad from the operation, and death in two cases being the consequence, from severe erysipelatous inflammation of the scalp.

Notwithstanding all these objections, he said he was ready to incur any risk which would give him the least chance of having the deformity under which he labored obviated, as life in his present state was hardly desirable.

His case was certainly a hard one. A young man, in the prime of life, in other respects of a good appearance, was, by this frightful calamity, not only entirely cut off from society, but prevented from gaining the means of subsistence.

Having determined to submit himself to an operation, it was thought expedient to delay it a few weeks, in order to watch the case a little, and prepare him for it by a course of diet and regimen.

At the end of six weeks, his health being perfectly good, and he still persisting in the determination of having an operation performed, preparations were made to do it as soon as possible, as on account of the approach of cold weather, no time was to be spared. At this period he was seen by my friend Dr. Peace, of Philadelphia, who was

present with me at one or two operations of the kind practised by Dieffenbach in Paris, and he declared it, as his opinion, that the appearance of the patient offered every chance for success. The favorable circumstances were—the healthy state of the integuments surrounding the opening of the nasal fossa, the great height of the forehead, the whiteness and delicacy of the skin, and, added to this, the good state of his general health. All the preparations having been made, the operation was performed on the seventh of September.

A piece of pasteboard, cut in the shape of the letter V, that is, of a triangular form, and with a projection from its base, corresponding to the columna of the nose, was placed upon the forehead, and a trace made around it with the nitrate of silver; this being used in preference to ink, as recommended by Lisfranc, in order that it might not be liable to become effaced by the blood. A trace was also made around the opening of the nasal fossa, at the points where it would be necessary to remove the integuments for planting the new skin taken from the forehead. This was done on the night previous, in order to prevent any undue delay on the day of the operation.

All unnecessary articles of clothing being removed, the patient was placed on a table in a recumbent position, his face towards the window, and the operator behind so as to have the full command of the head. The traces made by the nitrate of silver were about two thirds of an inch apart between the eyebrows, each side of the triangular portion of skin was three inches and a quarter in length, with a base of three and a half inches, and the projection for the columna of the nose, which was to be taken entirely from the scalp, previously shaved, was an inch and a half long and two thirds of an inch wide.

The head being firmly supported by two assistants, the incision was commenced between the eyebrows, and the flap of the skin dissected up so as entirely to isolate it from the skin of the forehead, except where, for the purpose of nutrition, it was left adherent at the root of the nose. The incision on the left side between the eyebrows was extended a little farther down than on the right, the better to facilitate the twisting of the flap. This included the skin, subcutaneous cellular tissue, and a portion of the occipito-frontalis muscle, care being taken not to raise the periosteum, from fear of necrosis.

The flap thus dissected and twisted round to the left side, was carefully wrapped in a compress of linen cloth, and before the opera-

tion was proceeded farther in, attention was given to diminishing the large wound made in the scalp. Little hemorrhage had taken place, and the temporal arteries which had been cut, very soon retracted and ceased bleeding. The angles of the wound were first brought together by the twisted suture, two pins being employed on either side. Its edges between the eyebrows were also approximated in a similar manner; by this means the wound in the forehead was diminished at once to less than half its original size; it was still farther reduced by the use of a few strips of adhesive plaister, and a little scraped lint filled up the remainder of the wound. Some lint spread with cerate was spread over the whole surface, a pledget, and the whole secured by a bandage round the head.

The next object was to fix the borrowed skin in its place. In order to do this, it was necessary to freshen the borders around the opening of the nasal fossa, the traces of which, as stated above, had been previously made with nitrate of silver. For this purpose a short narrow knife, somewhat similar to a cataract knife, was used, and a strip of integument a third of an inch in breadth, removed, including all that portion which had been at all indurated during the cicatrization of the ulcerations. The knife was also passed between the lip and upper jaw, in which existed, as before stated, an opening large enough to pass a probe, and the adhesions between the two, for the space of an inch, entirely cut away. This was done for the double purpose of giving the columna of the nose a more deep and firm adhesion, and, in the inflammation which would subsequently ensue, to close up the unnatural communication between the mouth and nasal cavity.

The flap was now brought down into its place, its angles a little rounded with the scissors, the better to simulate the alæ of the nose, and the whole secured in its place by pins and points of the interrupted suture. From that portion of the skin which was to form the columna of the nose, the epidermic side was pared a little, so that it might form an adhesion not only underneath to the jaw, but on its sides to the quadrangular wound made for it in the upper lip.

A little scraped lint was now placed under the ends of the pins, and a strip of oiled lint introduced into each nostril to prevent adhesion; another strip was placed upon the nose to preserve its temperature. The dressings were secured by a band of adhesive plaister fixed to the forehead above, and partially divided in the middle, so that it might descend on each side of the nose to the lip.

During the whole of this long and painful operation the patient kept up his courage, and not a cry was uttered, nor the least struggle made that could at all impede the motions of the operator. Not much blood was lost, and his strength was so little exhausted that he was able to run up stairs to his chamber. He was ordered to go to bed immediately, to keep perfectly quiet, and a watcher left with him, who had directions, in case of his falling asleep, to prevent him from either rolling over on his side, or raising his hand to the nose so as to derange the dressings; also to wake him immediately should he breathe through the nose. To have arrow-root or gruel and lemonade, for nourishment.

On visiting him in the afternoon he was found comfortable; the new nose was warm, and had bled a little from the edges which formed the nostrils, both showing that the circulation was not at all impeded.

Sept. 10th. Passed a good night, slept well, pulse seventy-nine, complains of no pain, the nose of about the natural temperature. The gentleman who watched with him thinks that the lint on the right side of the nose was occasionally raised a little during expiration, when the patient slept soundly; he awoke him once or twice on this account. A purgative was ordered of the sol. sulph. magnes. and liquid farinaceous diet. A piece of cork was confined between the teeth, so as to keep the mouth open, it being hoped that this might prevent him from closing his lips during sleep and breathing through the nose.

11th. Quite as well, passed a quiet night, has a good appetite, pulse eighty. Watcher says that he occasionally made a motion to raise his hand to the nose, but, as if instinctively aware of the impropriety of it, withdrew it again without touching the dressings. The introduction of the cork had entirely effected its object, by keeping the mouth open, and preventing the passage of air through the nose.

12th. The first dressing took place four days after the operation, and the following was found to be the state of the parts.

The dressings on the forehead, after being well soaked were first removed. The angles of the wound were found to have united throughout, so that two of the pins were at once dispensed with. Union had also taken place in its lower part, just above and between the eye brows; the remainder of the wound, that is, its central part, in which union by the first intention could not take place, was suppurating well, and filled with healthy granulations.

The nose was next attended to. Upon the lint being removed, which had become very much hardened and caked in by the coagulated blood, it was found that entire union had taken place on both sides. The alæ of the nose and lower edges could not easily be seen without making use of too much violence in removing the dressings, which at present was not thought necessary. The columna was curved inwards, and the sutures concealed. The nose was of the natural color and temperature, and the circulation through it seemed uninterrupted.

Two strips of lint dipped in oil were laid over the cicatrix on each side of the nose, and no other dressings used. The patient was allowed to sit up a little, and to take any article of food of the liquid kind he might fancy.

On the 13th he was quite as well, with the exception of a little œdema of the upper eyelids, arising, undoubtedly, from the pressure of the bandages and other dressings on the forehead. One of the pins was removed from the forehead on the 13th, and another, the only remaining one, on the following day. The dossils of lint which had been placed in the nostrils still remained there, firmly caked in by the drying of the pus, blood, &c. These were not removed until the 16th, when their places were supplied by two pieces of hollow sound. Some difficulty was found in the introduction of the tube into the right nostril, which had become partially filled with granulations.

On the 14th a quantity of hair began to appear on that portion of the skin forming the columna of the nose, which, as will be remembered, was taken from the scalp; this hair, from time to time, required to be removed with the scissors. He was put upon a nourishing diet, with the caution to use the jaws as little as possible. He stated that occasionally, when he swallowed, he had a sensation as though he would "swallow his nose."

15th. The remaining pins were removed from the side of the nose, and the two sutures which confined the alæ; and on the 17th, ten days after the operation, the two ligatures, which confined the columna in its place, were also removed.

At this period, the following was the state of the parts. The wound in the forehead, from the adhesion by the first intention which had taken place, and subsequent contraction, had diminished to a third its original size, and the small triangular space which remained, together with that portion of the scalp from which the columna of

the nose had been taken, was filled with healthy granulations. From the wound to the root of the nose was a linear cicatrix nearly two inches in length, and continuous with the cicatrix on the left side. Adhesion of the integuments had taken place on both sides of the nose; at the right alæ, however, the union was not quite so perfect as at the left; that is to say, the whole thickness of the skin did not appear to have united. To assist the union, the skin of the face which lay under it was slightly scarified with the point of a lancet.

The columna of the nose was a little curved, and its edges had retracted inwards upon themselves. The inside of the nose was suppurating well, and at its upper part adhesion seemed to have taken place between the two bleeding surfaces which had been opposed to each other. The tip of the nose was well defined, and its edges were curved inwards so as well to simulate the natural appearance of the alæ, and just above the alæ, apparently from atmospheric pressure, a depression was taking place, forming their superior boundary. This was assisted by the patient making an occasional pressure with his fingers at these points. He feels well, has a good appetite, and sits up all day. He breathes freely through the tubes placed in the nostrils, which require to be daily removed in order to clear out the obstructions which collect in them.

At the end of a month the wound in the forehead had contracted to about a quarter of its original size; adhesion of the nose was perfect in all points; the openings of the nostrils were regularly rounded, and simulated well the natural appearance; the tip of the nose is well preserved, and a regular curve takes place from its root to the end of the organ.

At the end of six weeks he was able to go out, but as the weather became cold he was advised to confine himself to the house, as cold evidently had a very great effect in retarding the cicatrization of the wound on the forehead. By reference to the second figure on the plate which accompanies this paper, a pretty correct idea will be formed of the state of things six weeks after the operation.

At the end of two months it was thought time to proceed to the second operation, which was required to remove the twist existing at the root of the nose. It will be easily conceived by referring to the plate, that underneath the pedicle which connected the nose with the forehead, a small portion of sound skin existed, and that of course no adhesion had taken place between this portion and the pedicle

lying over it. The method usually adopted by operators has been to cut the pedicle, after sufficient union of the nose has taken place below to justify the separation of it from its source of nutrition, and to fix it down at the root of the nose, in a transverse incision made for it at that point.

To this method there are some serious objections. First, the danger of inflammation in separating the pedicle ; second, of sloughing of the organ on the vessels being cut which have hitherto supplied it with blood ; and lastly, the very perceptible transverse cicatrix left after the operation. The method resorted to in the present case is liable to none of these objections, except, perhaps, the first one, in which the danger is much diminished.

This operation was as follows. An incision was made, commencing opposite the internal angle of the eye, and extending to that part of the base of the nose where adhesion had not been able to take place ; a corresponding incision was also practised on the pedicle. The skin being well dissected up, a small portion of integument was removed from the upper angle of the wound, where it had become wrinkled from the twist in the pedicle ; the edges were then brought together by three points of the interrupted suture. The same operation was to be performed at a future day on the other side, where, however, the opening was of about half the size, and not so perceptible. Union took place, throughout, by the first intention. Some trouble was experienced, however, by the formation of a small abscess in the new cicatrix, which suppurated and discharged itself.

The third drawing, executed four months after the operation, when the cicatrization had become complete at all points, gives a very good idea of his present appearance. He now declares himself entirely well, no secretion takes place from the nostrils, and on looking into those cavities a new skin is found to line them throughout. The nose itself has gradually diminished, so that by the first contraction of the integuments, and subsequently from suppuration, it has decreased to about two thirds the size of the flap which was taken from the forehead. Contraction also seems to be going on in its longitudinal axis, so that the distance between the tip of the nose and the mouth, daily increases. This will be much more perceptible, and the whole appearance of the nose much improved, when the four front teeth, which have been lost, are replaced ; this will bring out the under lip, and at the same time raise the tip of the

nose. The cicatrix in the forehead has become very small, and is gradually assuming the color of the surrounding integuments; the scalp from which the columna was taken is lost in the hair; the nose is quite firm, of a good form, and the cicatrix on each side hardly perceptible; at the root of the nose on the left side, and at that portion which formed the pedicle, a small fissure still remains, which is for the present concealed by a strip of court plaster.

The health of the patient has never been better, his sense of smell is returning, and the tears no longer run over the face, and he, as well as his friends, congratulate themselves both on the moral and physical effects of the operation. He is now able to make his appearance during the daytime, which he has not done before during the last two years, and no person would observe anything remarkable in the nose, without a minute examination, when it would be difficult to explain the remarkable anatomical changes which have taken place.

Remarks.—In an operation like the present, of comparative rarity in this country, it will not perhaps be considered amiss, if a few remarks are offered on some of the most interesting points connected with its history, and of the chief difficulties which may occur to prevent its success.

The operation of Rhinoplastie is originally of very ancient date. For various reasons, however, it had fallen into most unmerited disrepute until of late years, when it has been again revived in Europe by the brilliant successes of Graffe, Dieffenbach, and Labat on the Continent, and Liston in Great Britain. Dieffenbach, in his late visit to Paris, where, with the accustomed liberality of the French, all the hospitals were thrown open to him for practising his celebrated operations for the restoration of lost parts, has, perhaps, done more than any other operator towards giving it its proper standing in surgery.

In the ancient operations of this kind, the lost organ was restored at the expense of the integuments in its immediate neighborhood; advantage being taken of the extensibility of the skin of the cheeks, the integuments were dissected up on both sides of the nasal fossa, brought forward, and united in the centre by points of the interrupted suture. In case of the extensibility of the integuments not being sufficiently great, incisions were made on both sides in front of the ears, so as to diminish the tension of the skin at these parts, the wounds thus made being afterwards allowed to fill up by granulation. This operation, however, did not, as will be easily

perceived, restore the form of the lost organ, and the only advantage gained was a flap of skin to cover the existing deformity.

The operation which was afterwards adopted, and which now bears the name of the author, was that of Taliacotius, which consisted in taking the skin required, from the arm. The given shape of the nose being marked out on the place determined upon, the flap was dissected up, except at its base, and the integument thus taken was confined in a place prepared for it around the nasal fossa. In this operation, it was required that the arm, in case it was taken from that part, should be confined in contact with the face, for the space of ten or fifteen days, or until union had taken place; and it was not until then that the arm was released from its situation. The disadvantages of this method are at once manifest; the length of time required to keep the limb in this painful situation, so as in some cases to produce partial paralysis, and the danger that ensued in the too early separation of the transplanted skin from its source of nutrition, were, of themselves, reasons of sufficient weight to cause this method to fall into disuse.

The operation which has attained the most celebrity, is that which goes by the name of the Indian Method, in which the flap is taken from the forehead. This has been most frequently practised in France and England, and it is this method, which, it will be perceived, has been adopted, with some modifications, in the present case.

Having thus briefly referred to the history of the operation, some remarks will now be made on the chief difficulties which occur in the course of it, and the means taken to obviate them.

No operation, perhaps, requires more attention to the nice points of detail, than that now under consideration; and it is on these that the ultimate success of the operation, in a great measure, depends. For information on this subject, we cannot do better, than by referring to the work of M. Labat, one of the most valuable monographs for reference on *rhinoplastie* yet published. The author, in the description of one of his cases, after having referred to the trouble which he experienced from hemorrhage, while dissecting up the flap of skin from the forehead, goes on to state, "But an inconvenience much more embarrassing, and to which it was necessary to be resigned, from the impossibility of remedying it, was occasioned by the great quantity of blood, which, entering the throat, was violently expelled from the mouth every time that the pain of the operation

forced the patient to cry out. But what was much more troublesome still, was its being repeatedly received in the eyes of the operator, so as once or twice to oblige me to discontinue the operation for the space of some seconds."

The difficulty which the author here complains of, was remedied in the present instance by a very simple means. Instead of placing the patient in an upright position, he was made to lie upon his back on a table, the operator standing behind him; the blood was thus conducted off on each side of the face, instead of passing over the nasal fossa and mouth, and entering the throat. To guard against any possibility of this accident taking place, plugs were confined in the opening of the nasal cavities, during the dissection of the flap, and the time occupied in closing up the wound on the forehead. When the operation was commenced around this opening, and the entrance of the blood was unavoidable, the patient, who maintained sufficient coolness throughout, was requested to keep the blood as long as possible in the mouth, and an assistant directed to clear out, with a small sponge, what had collected, as occasion required.

We give the account of another trouble, in the author's own lively description, which, fortunately, was avoided in the present instance.

"But an accident of much more gravity, and which placed me in a very critical position, presented itself at a moment, when, after having detached from the forehead the flap of integument, I was about to bring it down into the place it was destined to occupy. Previous to making this twist of the new flap, it was thought necessary, as I have before stated, to prolong the incision on the left side as far as the medium line of the root of the nose, in order to facilitate the torsion of the pedicle; the patient experienced, at this moment, such a violent pain by the inevitable division which it was necessary to make of some of the ramifications of the frontal branch of the ophthalmic nerve of Willis, that he escaped from the hands of the assistants, rushed towards the door, and was determined not to undergo the remaining part of the operation. At this moment, his physiognomy presented a most frightful aspect; his forehead covered by a large wound, the borders of which, retracted by pain, had greatly augmented its extent, and all the rest of the face, his neck, and garments, inundated with blood. But a sight which was much more horrible to behold was the flap of palpitating integuments, which at every moment were jerked from one side of the face to the other."

In the present instance, no particular suffering was observed by

the extension of the incision down between the eyebrows; and in case of any difficulty of this kind, the complete command in which the patient was held, from the position adopted, would have prevented any of the evils complained of by M. Labat.

One of the greatest difficulties of the operation, and that which, in its consummation, occupied the most time, was the introduction of the pins which were to close the wound in the forehead, and to continue the new nose in its situation. To remedy this as much as possible, the pins to be employed, which were the long pins, generally used by naturalists, were previously sharpened; and for introducing them, a little instrument was constructed, somewhat similar to the aneurismal forceps of Dr. Physick, made with a small groove to receive the head and upper third of the shaft of the pin. With this instrument the pins were readily seized, and pushed through the skin, and the ligature being applied, their ends were cut off by the scissors or cutting pliers.

At that part of the flap which was to simulate the alæ of the nose, as it was necessary that the integuments should be directed inwards, the pins, of course, could not be used, and here a plan recommended by M. Labat was adopted, which was followed by partial success. A thread being passed first through the integument of the face, and then through the flap, at about two lines distant from their edges, the ligature was so tied as to produce, as it were, a fold at that point; and the better to effect this object, a small piece of adhesive plaister, rolled up into the form of a cylinder, was confined under the threads, so as to make a strong impression on the wound and to force the edges into their places. This succeeded completely on one side; on the other, however, the union, at first, was not so entire, the skin adhering only by about half its thickness.

During the whole of the treatment it was necessary to keep the openings of the nostrils distended by small tubes. The substance which seemed to answer the best for this purpose, was a portion of the barrel of a quill, the end which was to remain in the nose, being stopped up with a little melted sealing wax, and a small aperture cut in the side through which the air could freely pass. These were ingeniously constructed by the patient himself, who, after a time, was able to manage them without difficulty. The tendency to contraction at these points was very great, so that at one period, the tubes being left out during the night, it required considerable force to replace them.

From the new nose being formed entirely of skin, it will perhaps be supposed, that the integuments composing it are flaccid, and the form of it easily destroyed. This, however, from reasons easily appreciable, is not the case. The integuments of the scalp being naturally of great thickness, by the suppuration which took place from the inner side, assumed a firmness almost similar to fibro-cartilage; and at the root of the nose, the internal surfaces coming in contact, contracted adhesions so as to make the nose perfectly solid at that part. The size, also, of the columna, which doubled upon itself and contracting deep adhesions during the inflammatory process, formed a round and solid pillar to support the tip of the nose.

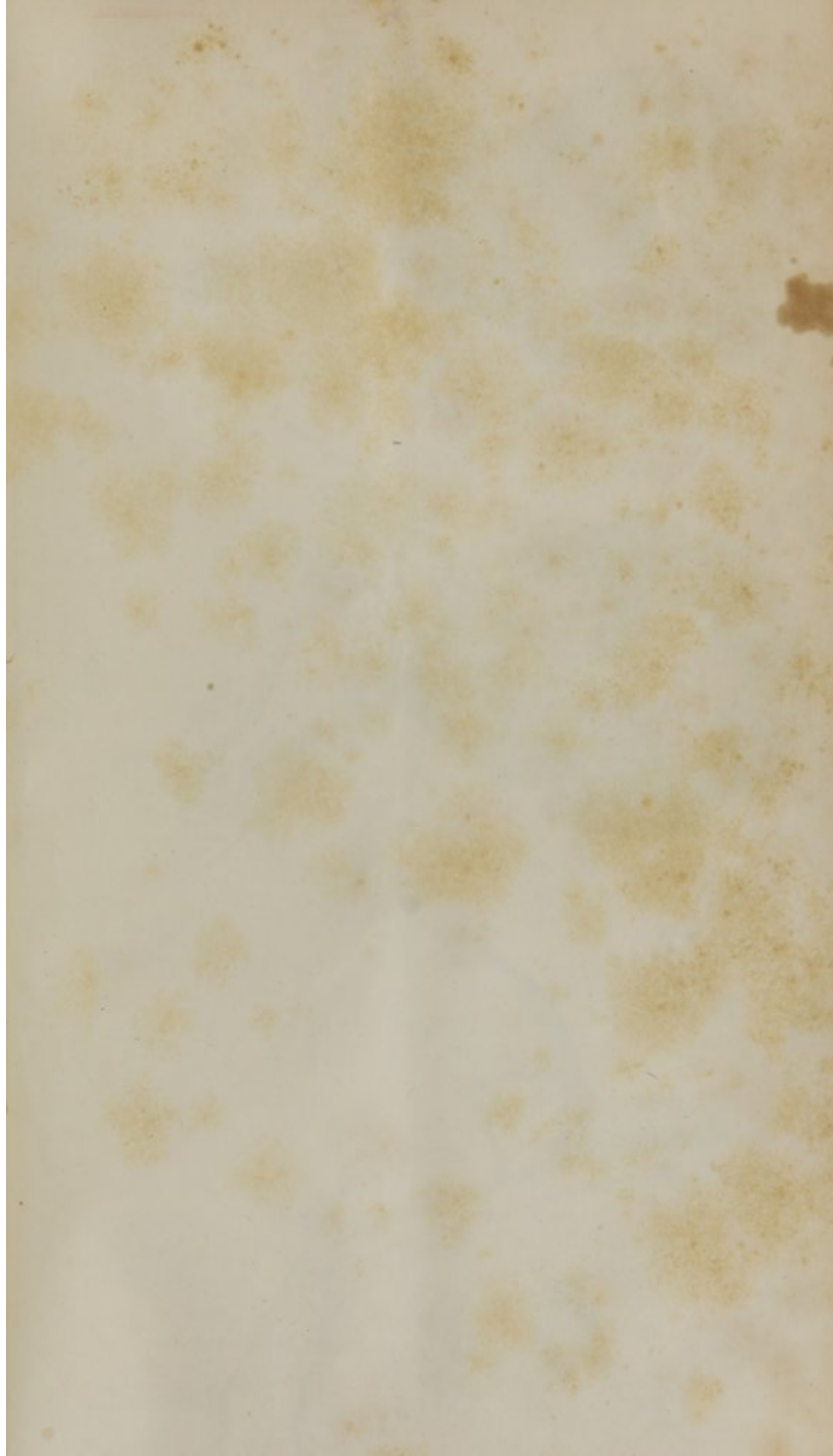
Great precautions had been taken to guard against exposure to the cold, which, by stopping the circulation, might at once defeat the whole object of the operation. As soon, however, as adhesion had taken place, it was perceived that no danger from this source was to be apprehended; and although during the past winter he has slept in a room in which water has frequently frozen, and has been since repeatedly exposed during some of the coldest days, he finds that the temperature of the organ is never greatly diminished.

The cicatrization of the wound in the forehead was greatly retarded by the cold weather, and less than half the time would have been required, had the operation been performed during a warmer season; when it had diminished to a small size, and cicatrization, as frequently is the case in the filling up of large wounds, seemed to have been arrested, great benefit was found from the use of an ointment composed of six drops of creosote to an oz. of simple ointment. On the application of this to the wound, the effects were at once apparent. A small pellicle formed over its whole surface, which was shortly replaced by a firm, consistent cicatrix.

In one or two cases operated upon by Dieffenbach, much swelling took place in the new formed nose the day after the operation, arising from the difficulty of the blood, which had entered by the arteries, being conducted off by the veins. In one case the nose became so enormously distended, that it was feared the adhesions would be entirely destroyed, and it was only by the repeated application of leeches, 70 or 80 being employed in the course of 48 hours, that this danger was finally avoided. In the present case, from the extension given to the incision on the left side, care being taken that traction should not be made too forcibly on the part, so as to compress the pedicle at its base, the circulation was, from the first, unobstructed.

In the account of the foregoing case, it has been attempted to bring forward some of the most important points which might be of service as a guide to future operators ; and if the author has been so fortunate as to throw any new light, however small, on the operation, he will feel that he has rendered a service to science and to humanity.

Boston, March, 1837.





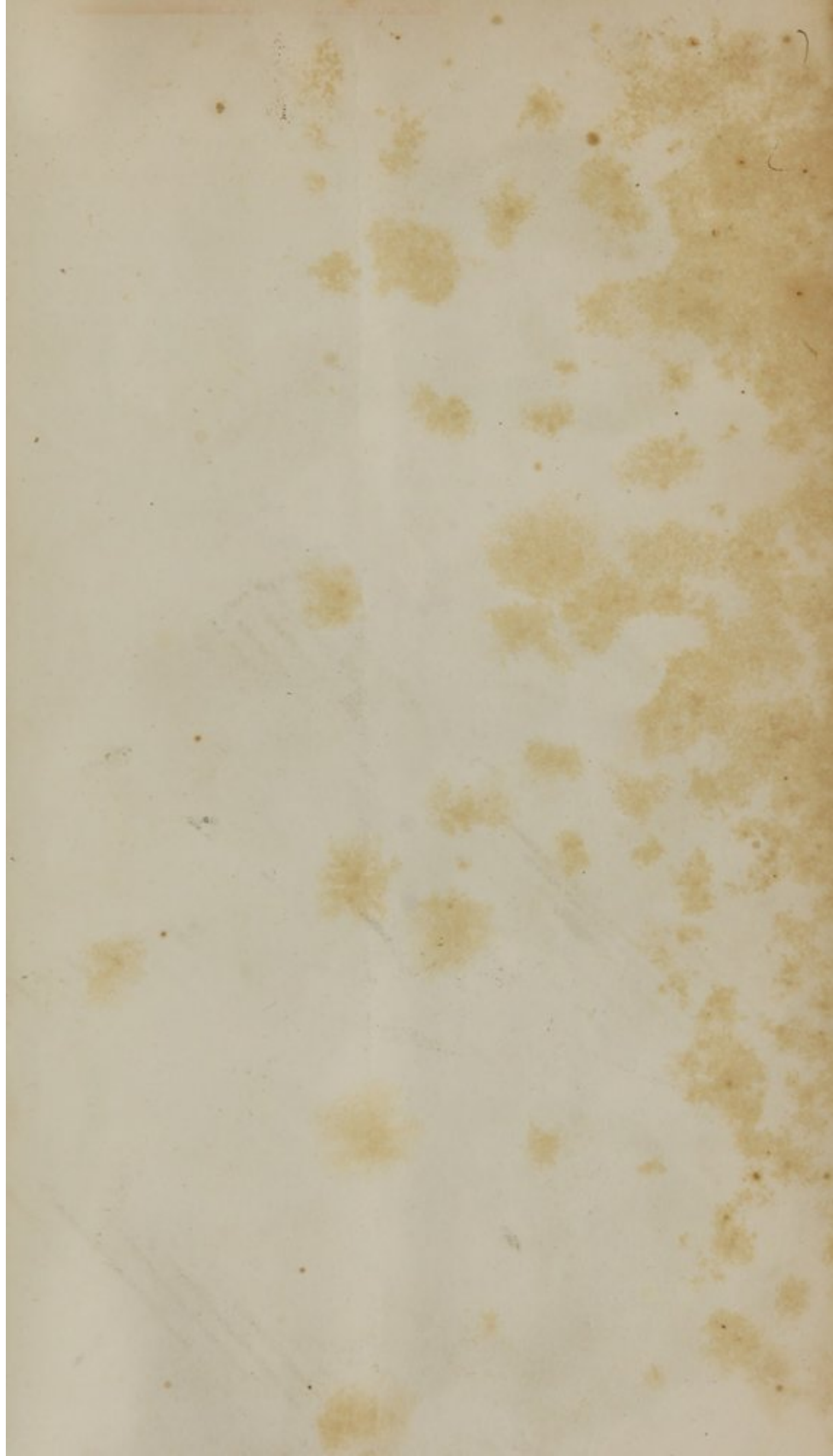




Fig 1



Fig 2



Fig 3

Moore's Lida Boston

CASE II.

THE young man who was the subject of this operation had been affected for 15 years with a very troublesome disease, which bears many of the marks presented by what has usually been described under that form of lupus, which proves destructive by interstitial absorption. The commencement of this affection was by a spot on the very tip of the nose, which gradually extended, becoming finally of a livid red color, and having its surface covered by numerous elevations of a tubercular appearance. In his ordinary state of health, and when perfectly quiet, the only sensation in the affected part was that of an uncomfortable heat and itching; but on the slightest derangement of the system, and upon any extraordinary exertion, particularly when engaged in his ordinary occupations, which are those of a farmer, an intense burning and stinging sensation was produced not only in the nose itself, but extending to the surrounding integuments, and this often so insupportable as to oblige him to desist from his work, and have recourse to some cold topical application, in order to gain a temporary relief. He has gone through a great variety of treatment, continued for a number of years, but without the slightest alleviation to his sufferings. A year since he had a caustic application made to the part, which destroyed the skin for the space of one or two lines, and the subjacent cartilage, the greater portion of the disease remaining undisturbed.

He came to Boston under these circumstances, determined to have the part removed, and the loss of substance supplied by the Taliacotian operation. At this period the nose had a very pinched appearance, the skin being of an intense red towards the tip, and having in its substance a number of hard, tubercular bodies. A slight redness extended over the ala nasi of the right side. In the centre was a depression and loss of substance, where the caustic application had been made.

He was seen, previous to the operation, by a number of medical gentlemen well informed in the diagnosis of diseases of the skin, and the only name which could be given to this affection was that which has been already stated; though it differed materially from lupus in many particulars, especially in its long-continued freedom from ulceration, the great suffering attending it, and the absence of any affection of the mucous membrane of the nose.

The operation was performed on the 8th of April, in presence of Dr. Salisbury, Dr. Gordon, Dr. Mifflin, and some other medical gentlemen. The disease, which extended up as far as the nasal bones, was very carefully removed, and the cartilages below, not destroyed by the caustic, found to be in a perfectly healthy state.

The dimensions of the flap necessary to supply this loss of substance were now carefully taken, and marked out on the fore-arm. The traces were made on the radial side of the left arm, about two inches from the styloid process of the radius, and extended over to the space midway between the bones of the fore-arm. This flap was dissected up, including, with the skin, the sub-cutaneous cellular membrane, and was secured in its new situation, in contact with the face, by means of five points of the interrupted suture, the arm being firmly fixed in this position by appropriate bandages. An elastic tube was given to the patient, to use whenever he required to take nourishment—the mouth being so covered up as to prevent food being directly introduced into it. He was placed in bed, and supported in a sitting posture by means of a common bed-chair.

I saw him in the evening, and found him much less disturbed than could have been expected, considering the very restrained position which it was necessary for him to maintain.

On the following day, the 9th, there was some appearance of erysipelatous inflammation on the bridge of the nose; he had been pretty quiet, and had slept a little, but required constant watching to prevent him from slipping down and doubling himself up in the bed, to which there was a constant tendency. He complained much of a want of solid support to the elbow, and for this purpose a wooden apparatus was constructed and placed across the bed, which served as a firm resting place for the arm, and enabled him to maintain more easily the proper position. The pulse was 60, and throughout the whole period of his confinement it remained below the ordinary standard. On the 10th he complained less of his arm, but was exceedingly restless. During the day he was removed to an easy-chair, and the change afforded great relief.

The state of things varied little from that already described until the 5th day, the period appointed for separating the connection between the arm and face. On this day the base of the flap was divided, and a perfect adhesion was perceived to have taken place between the parts which had been placed in apposition.

The wound in the arm was dressed, and a small portion of the skin

which projected bound down in its place by adhesive straps. The irregular portions of skin being removed, a slight compression was exercised on the edges around the nostrils, by means of small strips of adhesive plaster.

The arm, on being relieved from its confinement, was at first somewhat stiff, but not so painful as might have been expected, and what was not a little curious, obstinately refused to be raised up again to the position it had so long unwillingly occupied. This, in a great measure, arose from a loss of power in the flexor muscles, from want of exercise of their functions; in the course of a few days, however, it regained its healthy state of feeling and motion.

By the 20th of April the newly transplanted skin had contracted to nearly the natural size, the line of union with the skin of the nose was perfectly lineal, all the abrupt and useless portions of skin on the lower edge of the nose had sloughed off, leaving a perfectly even and rounded edge to the nostrils.

On the 23d I was surprised, on removing the green cot which covered the dressings, to find that the whole cuticle of the restored part had peeled off, leaving the surface quite raw and covered by the green-coloring matter of the silk. This at first seemed a circumstance destined to embarrass the case and prolong the period of recovery, but in its termination proved of material benefit; a slight suppuration commenced, which brought down the skin to a natural thickness, and rounded off, in the most perfect manner, every inequality on its surface, and seemed also to melt the skin into the adjacent integuments so as almost to destroy the traces of the transverse line of union. A new cuticle rapidly formed, and by the end of the month he was quite well, and was presented at one of the meetings of the Society for Medical Improvement. The newly restored part still remains somewhat wanting in color, but in all probability by exposure to air and sun, it will soon assume the appearance of the surrounding integuments. Even now it requires that attention should be particularly directed to the part, to show that any operation has ever been performed.

Remarks.—It will be perceived that in this case, the old operation, as performed by Taliacotius, of taking the desired integument from a distant part of the body, was preferred to the Indian method, in which the skin is borrowed from the forehead and hairy scalp. The reasons for this will be perfectly obvious. The loss of substance to be supplied was, in the case under consideration, small, when compared with those in which the

whole organ has been destroyed ; by the course resorted to, a scar on the forehead was entirely avoided, and that made on the arm, from the great extensibility allowed in bringing together the parts, has now become so small as to be scarcely perceptible.

The operation was not precisely that recommended by the Italian surgeon. Taliacotius preferred taking the skin from the arm near the insertion of the deltoid muscle, and by adopting this method the limb can be much more securely fixed in contact with the head. In the present case, the patient was desirous of having the operation performed as speedily as possible, so as not to be detained from his occupation longer than was absolutely necessary, and fear was entertained that if the arm was suddenly brought up to the required position, without previous training, the suffering produced might not only be insupportable, but that paralysis of the limb might be the final result.

This operation differed also from that of Taliacotius in the early period at which the transplanted skin was separated from its connections—that is, on the fifth instead of the fourteenth or fifteenth day ; and as the principal objection to this method is the position in which the arm is so long and painfully confined, this is certainly a very important consideration. It will also be remembered that the Italian surgeon did not at once dissect up the flap and confine it in the situation it was finally destined to occupy ; but it was raised gradually, and thus allowed to suppurate and contract, and by this means become better adapted for the formation of the new nose ; the most important point, however, the adhesive process, must by this means have been rendered much less to be depended on.

The print accompanying this paper will afford some idea of the position of the patient while the process of adhesion was going on. No drawing has been added of the appearances of the disease before the operation, as this could only be represented by a very highly-colored engraving.

Shortly after the above was written, the patient having exposed himself to the sun during a walk out of town, experienced considerable itching in the right ala of the nose, where, it will be remembered, there was a slight redness remaining. He came to me, very desirous to have the skin of this part at once removed, as he greatly feared that he might be troubled with it hereafter. He was also anxious that the experiment should be tried of cutting a piece of skin from the arm and immediately placing it in the wound to supply the loss of substance. Although I

did not consider this part of the operation necessary, as the wound, in all probability, would have filled up by the granulating process, I yielded to his desire and made the attempt. The skin covering the ala nasi was removed so as to leave no appearance of redness remaining, and a piece of skin being immediately dissected from the fore arm, was confined in the wound by means of lint moistened in blood, which answered a much better purpose than the common adhesive plaster.

On removing the dressing, at the end of four days, a perfect union was found to have taken place.

Boston, May, 1840.

CASE III.

RHINOPLASTIC OPERATION.—The publication of the following case has been delayed until the present, in order that sufficient time might elapse to enable us to form a judgment of the final effects of the operation. As eighteen months have now passed, and no material change will probably hereafter take place in the restored organ, it seems an appropriate time to give the facts to the public.

The patient, a young woman 27 years old, from Maine, applied to me under the following circumstances. Nearly sixteen months previous, having been troubled by a wart on the end of the nose, she was induced by her friends to apply for advice to one of those quacks, styled *cancer doctors*, who easily persuaded her that the affection was of a cancerous nature. A caustic application was advised, which produced so great a degree of inflammation as to alarm her and oblige her again to have recourse to him. His answer was that the application should be continued—not only to the wart itself, but over the adjacent parts—“so that none of the *roots* of the disease might escape.” It was therefore persevered in, and so faithfully, that at the end of a fortnight all the fleshy part of the nose sloughed off, leaving the patient in a most deplorable condition. On re-application to the quack, as to what was to be done under these circumstances, he assured her that it was a most happy termination of the disease, which by these means had been wholly eradicated, and that the nose, in the course of time, would *grow out again*, and be perfectly restored.

These assurances, as may well be conceived, were not destined to be realized; the edges of the wound gradually cicatrized, leaving her in the state in which I saw her sixteen months after the occurrence of this calamity.

The state of the patient was much as follows:—The end of the nose, together with the *alæ nasi* and corresponding portion of the septum, was entirely destroyed, leaving the nasal passages wholly exposed; the *ossa nasi*, with a small portion of skin covering them, remained entire—their edges being lined with a firm, and somewhat vascular cicatrix. In other respects, the patient was a good-looking woman, and her health as little disturbed as could have been expected, considering the sedentary life she had led since this misfortune.

It was with much reluctance that I undertook to give her any encouragement, for reasons which will be easily appreciated. In the first place, the probability of success in an operation so as to realize the hopes entertained by the patient, was very doubtful; in the second place, the long confinement necessary for an operation of this character; and, finally, the great suffering attendant on it.

By these representations, however, she was not at all daunted—if any reasonable hope could be entertained of having her condition improved by an operation, she was determined to have the attempt made. She was advised, therefore, to return home for the present, and to come to Boston again at a period of the year more favorable for the operation than the heat of summer.

Two methods of operation presented themselves in this case:—the Indian method, in which the skin of the forehead is employed in the construction of the new nose; and the Italian method, of borrowing it from some other part of the body. After much deliberation, the former was decided upon as being the most certain where the skin required to be transplanted was so large in size, and also as being the one in which I had the most experience.

The patient did not arrive in town until the first week in November, and the operation was performed on the 17th, in the presence of Dr. Hayward and Dr. Hale of Boston, Dr. McKean of Brunswick, Dr. John C. Warren, and a number of medical students. The patient was placed in a recumbent position, with her head well supported by pillows. The dimensions of the flap to be removed were traced on the forehead, nearly one third larger in size than was necessary for the formation of the new nose; this included all that portion of the skin of the forehead lying between the temporal processes, ascending almost to the commencement of the hair, and the portion to be used in the formation of the columna of the nose was almost exclusively taken from the hairy scalp. The flap, thus marked out, was carefully dissected up, and every precaution taken to leave the pedicle of the skin, between the eyebrows, sufficiently large to allow of a free vascular communication being maintained with the adjacent parts. Care was also taken to leave the angular arteries unwounded, as upon these the principal means of support to the flap depended. Before proceeding farther, the edges of the wound in the forehead were approximated by means of the twisted suture. This was facilitated by the incision in the scalp being prolonged to a pyramidal form.

The cicatrix covering the nasal bones was now removed, the flap twisted round and secured in its place by means of a number of points

of the interrupted suture. The strip which was to form the columna of the nose was deeply implanted in an opening made for it in the upper lip; the whole was supported by small strips of adhesive plaster, and covered with lint, for the purpose of preserving, as much as possible, its temperature; small tubes were introduced into each nostril, to prevent the adhesion of the opposed surfaces.

The whole of this long and painful operation was supported with the most admirable fortitude; and not a single groan was extorted throughout the whole course of it—so that considerable anxiety was experienced, at some periods, that she had fainted, and it was necessary to make frequent inquiries to determine whether or not this was the case.

During the operation, a number of arteries were cut, and bled freely; but as it was desirable to avoid the use of ligatures, they were allowed to bleed, until they voluntarily ceased. The patient was directed to keep in bed, to remain perfectly still, and to breathe through the mouth; in order to favor this, a wedge of cork was secured between the teeth whenever any disposition to sleep was manifested.

I saw her four hours after the operation. She then complained of some sense of tension in the scalp, and a slight hemorrhage had occurred from the free edges of the new nose.

On the following day the nose was considerably swollen; pulse 72; she was rather restless. Some inflammation, apparently of an erysipelatous character, made its appearance about the forehead towards evening; this was attributed, partly, to the want of free ventilation in the room. On the following morning, however, not finding any abatement of the inflammation, I removed all the dressings from the head, together with the pins which confined the edges of the wound in contact. On the 21st, the sutures were removed from the nose, and an entire union to the adjacent parts had taken place. Upon questioning the patient as to the sensibility in the new-made organ, she states that it is nearly natural, and but slightly referred to the part from which the skin had been transplanted, as was the fact in the case formerly reported in this Journal. The form of the new nose is good, with a regular curved outline; the alæ nasi, also, are well defined; the whole, however, still much swollen. The nostrils are kept open by means of the small tubes, which are removed daily, and cleansed from the mucous and purulent secretions which tend continually to obstruct their passage.

The wound in the forehead was dressed daily with the creosote ointment, which remedied, in some measure, the fœtor arising from the supuration of so extensive a wound. The patient also derived much comfort from a creosote gargle for the purpose of purifying the mouth.

On the columna of the nose, which, it will be remembered, was taken from the scalp, hair still continued to grow ; but it was easily removed by scissors, so as to be hardly perceptible.

From this period she gradually gained in strength, so as to be able, in a few days, to sit up. The wound in the forehead slowly cicatrized, and the nose assumed a more natural appearance. At the end of two months, the third drawing, which accompanies this paper, was made, and affords a good idea of her appearance. A small opening still remained at each side of the nose, which, together with the slight wrinkling caused by the twist in the flap, it was proposed to remedy at a future period, when all the parts had fully come to their bearings. She was, therefore, advised to return home to her friends, and in the following spring I performed the comparatively trifling operation which was required for confining the pedicle down in its place. The cicatrix of the forehead was then quite firm and easily concealed by the hair ; her health tolerably good, though she suffered somewhat from confinement. She seemed to be quite satisfied with the results of the operation. The following extract from a letter, written lately by her physician, dated April 6th, will give some idea of her state at the present moment.

“Her general health is much better than when she returned home (except a slight cold which has called me to visit her to-day), and the restored part has improved in its appearance. It has diminished a little in size, and the color has become more like the other parts of the face. The sensation is quite natural, but very little referred to the forehead, and the circulation good. The sense of smell the same as before, and not at all affected by the operation. The hair yet grows on the end of the nose, but more scattering than at first ; she will, I think, be able to destroy it entirely. She covers nearly all the scar on the forehead with the hair, and were it not for that made by the suture between the eyebrows, it would hardly be noticed. A small fissure still remains open at the right side of the nose, which is not noticed but by a close examination ; it might be closed by taking out a small strip, and it would improve the appearance over the nasal bones, which are rather loose.”

He also states that there is still a disposition in the nostrils to become closed. This might easily be remedied by a slight operation, consisting in the removal of a strip from the circumference of the nostril.

Remarks.—The operation, in this case, with some slight exceptions, resembled the one reported in this Journal two years since. It will be remembered that in the first operation the twisted suture was used for

confining the new nose in its place, according to the method of Dieffenbach. In the present instance, however, the interrupted suture was substituted, and answered a much better purpose, the points of ulceration on the removal of the threads being less.

The sensations in the new nose being referred to the place from which the skin has been borrowed, has been denied by some writers. In both of these cases, however, this morbid state of the sensations existed, but much less in the latter, from the very free vascular communication which was preserved by means of the large pedicle of skin connecting the nose with the neighboring parts.

It may not be uninteresting to those of the profession whose attention has been attracted to the first case, which was published in March, 1837, to learn the present state of that patient. We saw that young man a few days since, and do not find that any sensible alteration has taken place in the restored part since the case was reported. The shape of the nose is perfectly preserved, and none of that flattening has taken place which has usually been brought forward by the opponents of this operation, as one of the greatest objections to be preferred against it. In those cases where this finally occurs, it almost universally arises from the flap, in the first place, being too small in size ; and the internal surfaces not being well opposed, adhesion fails, and as soon as all swelling subsides, the nose is left flat and deformed. In the present instance, the operation has been almost a new life to the patient, restoring him to the society of his friends, and enabling him to establish himself in business, which, in his previous situation, was utterly impossible.

The result of the above cases fully establishes the propriety of the operation, and the possibility of so far restoring the lost organ, as to make it difficult to discover the traces of the restoration, unless the attention be particularly directed to it.

Autoplastic operations for the restoration of parts that have been lost either by disease or from accident, are now attracting much attention both at home and abroad, and they may be had recourse to in a number of cases which previously had been given up as wholly incurable. It would be going too far beyond the limits of this paper to mention all the cases to which these operations might be applied ; we therefore refer to a few only. Among the most important of these, may be instanced the operations for restoring the lower lip and the eyelid after the ablation of cancerous tumors, frequently practised by Dieffenbach ; and in cases of

fistulous openings of the larynx and trachea, of the vagina and urethra, cases where the mere bringing the parts together, or making raw their surfaces, as in the hare-lip operation, almost invariably fails in performing a cure. The autoplasmic method which has been most generally adopted as applicable to these cases, is that in which the flap required is taken in the immediate neighborhood of the part destroyed, slid along, and confined in the desired situation by the twisted suture. This has been called, by the French, "*autoplastie par glissement du lambeau.*"

The following cases operated on during last year will serve to illustrate this method. The first patient was a young man who had lost a portion of one side of the nose from a burn, the septum and bones of the nose being destroyed by the same accident, and the external opening of the nasal cavities entirely obliterated in the subsequent cicatrization of the parts. The operation was commenced by removing as much as possible of the cicatrix covering the nostrils. A flap of skin, of a triangular shape, was then dissected up from that part of the cheek immediately adjoining the ala nasi which was to be restored; this was slid along and confined, by means of sutures, to the edges of the nose, from which a slip of integument had been previously removed. Union by the first intention took place, and at the end of a week the base of the flap was divided by a circular incision, which, besides diminishing [the tension of the parts, simulated pretty well the circular depression on the cheek which bounds the alæ nasi. The operation was terminated after a fortnight's confinement; the appearance of the young man was much improved, and the power of breathing through the nostrils restored. The bridge of the nose, from the partial destruction of the bones, still remains depressed, but the circumstances of the patient not allowing of a long detention from business, it was not thought advisable to proceed to any further operation for the present.

The second case, a congenital fissure of both the hard and soft palate, will be viewed with some interest from the novelty of the operation.

The young man who was the subject of it, was 24 years of age, and his speech so much affected by this unfortunate conformation as to make him scarcely intelligible, except to those accustomed to his manner of speaking.


The operation was commenced by making raw the edges of the soft palate, after the method usually employed in cases of staphyloraphy, and three points of suture introduced. The mucous membrane covering the roof of the mouth was then carefully raised on each side of the fissure in the hard palate, brought across this opening, and confined by means of


the interrupted suture. The flap formed by the mucous membrane of the mouth, it should be understood, was continuous with that of the soft palate. A firm union took place throughout the whole extent, with the exception of a small portion at its upper angle; the suture being torn away at this point on the third day succeeding the operation, from violent efforts in coughing.

The patient has now returned to the country, and has been recommended to touch the edges of the small opening which remains with the nit. argenti, with the hopes of obliterating it by this means; if, however, this should fail to succeed, a second operation is proposed for repeating the same process in the remaining part of the fissure.

This case will be given in detail hereafter, when the proposed operation has been put into execution. It will serve for the present to illustrate the points under consideration, and also establishes the fact of the possibility of an adhesion in cases of fissure in the soft palate, although complicated with an extensive separation of the bones—a point hitherto denied by writers on this subject.

Boston, May, 1840.







AUG 10 1961

NATIONAL LIBRARY OF MEDICINE



NLM 01182135 4