

A treatise on operative ophthalmic surgery / by H. Haynes Walton.

Contributors

Walton, H. Haynes 1816-1889.
Littell, S 1803-1886.
National Library of Medicine (U.S.)

Publication/Creation

Philadelphia : Lindsay & Blakiston, 1853.

Persistent URL

<https://wellcomecollection.org/works/vs3hrkv4>

License and attribution


This material has been provided by This material has been provided by the National Library of Medicine (U.S.), through the Medical Heritage Library. The original may be consulted at the National Library of Medicine (U.S.) where the originals may be consulted.


This work has been identified as being free of known restrictions under copyright law, including all related and neighbouring rights and is being made available under the Creative Commons, Public Domain Mark.


You can copy, modify, distribute and perform the work, even for commercial purposes, without asking permission.




Wellcome Collection
183 Euston Road
London NW1 2BE UK
T +44 (0)20 7611 8722
E library@wellcomecollection.org
<https://wellcomecollection.org>









A TREATISE
ON
OPERATIVE
OPHTHALMIC SURGERY.

BY H. HAYNES WALTON,

FELLOW OF THE ROYAL COLLEGE OF SURGEONS IN ENGLAND, SURGEON TO THE CENTRAL LONDON
OPHTHALMIC HOSPITAL, AND ASSISTANT SURGEON TO ST. MARY'S HOSPITAL.

First American,
FROM THE FIRST LONDON EDITION.

ILLUSTRATED BY

ONE HUNDRED AND SIXTY-NINE ENGRAVINGS ON WOOD.

EDITED BY

S. LITTELL, M.D.,

AUTHOR OF A MANUAL OF THE DISEASES OF THE EYE; SURGEON TO WILLS HOSPITAL FOR THE EYE
AND LIMB; FELLOW OF THE COLLEGE OF PHYSICIANS OF PHILADELPHIA, ETC., ETC.



PHILADELPHIA:
LINDSAY & BLAKISTON.

WW
W239t
1853a
c.1
film no. 10737. Gem

C. SHERMAN, PRINTER,
19 St. James Street.

TO

WILLIAM COULSON, ESQ.,

MEMBER OF THE COUNCIL OF THE ROYAL COLLEGE OF SURGEONS

IN ENGLAND,

SENIOR SURGEON TO ST. MARY'S HOSPITAL, ETC.,

This Work

IS DEDICATED IN ACKNOWLEDGMENT OF MANY ACTS OF FRIENDSHIP,

BY HIS FAITHFUL FRIEND AND COLLEAGUE,

H. HAYNES WALTON.

WILLIAM CHURCHILL

OF THE ORDER OF THE BATH

IN 1811

BY HIS EXCELLENCY THE EARL OF ABERDEEN

IN 1811

OF THE ORDER OF THE BATH

IN 1811

BY HIS EXCELLENCY THE EARL OF ABERDEEN

IN 1811

IN 1811

IN 1811

IN 1811

IN 1811

IN 1811

IN 1811

IN 1811

IN 1811

IN 1811

IN 1811

IN 1811

PREFACE

TO THE AMERICAN EDITION.

THE want of a treatise on Operative Ophthalmic Surgery, written in the light of modern science, insures for the work of Mr. Walton a favorable reception, which its intrinsic merits will abundantly justify. It is evidently the production of a thoughtful and independent observer, thoroughly acquainted with his subject, and capable of imparting to others, clearly and plainly, the knowledge which he possesses. The information it contains is, for the most part, accurate and precise, and its preceptive teaching practical and judicious. The reader is not perplexed by the necessity of determining for himself the relative value of different modes of procedure, but is authoritatively instructed in that which experience has proved to be the most appropriate for the accomplishment of his purpose. The sound principles of pathology which it inculcates, derived from the best school of English Ophthalmology, naturally lead to a rational and conservative treatment. It embodies the results of extensive literary research and close personal observation, under circumstances of rare opportunity; and though of unequal excellence—some parts being more carefully written and more fully developed than others, with occasional discussions also of topics not strictly included in its title—is alike creditable to the author,

and a valuable contribution to ophthalmic surgery. It has been very favorably noticed by the leading medical journals of Great Britain, and is the subject of especial commendation by a distinguished authority. "In the whole range of ophthalmological literature," says Dr. Mackenzie, in a review which is not sparing of criticism, "we know of no work that, on the whole, better deserves a place in the library of the surgeon. It is full of sound and practical views, and shows the rapid advances which are being made in this department of the medical art. Most of the cases have occurred to the author himself, and prove him to be an observing and able practitioner. His style is good, being perspicuous and unaffected; and any errors in the book are few and trivial in comparison of the mass of accurate information which it contains."

At the request of the American publishers, we consented to revise the proof-sheets of their edition in its passage through the press, and to exercise such editorial supervision as might be practicable in the brief time allowed for that purpose. Little, indeed, remained to be accomplished in this way. A chapter on the History of Ophthalmic Surgery has been omitted, as possessing little interest in itself, and being, moreover, an inappropriate introduction to such a treatise; a few notes have been added; and some inaccuracies, chiefly typographical, corrected; but in other respects the book is a faithful and beautiful reprint from the London copy, and, with the illustrations carefully engraved by Gihon, will bear, it is thought, no unfavorable comparison with the original.

S. L.

PHILADELPHIA, June, 1853.

P R E F A C E.

As an untried writer, I cannot be otherwise than anxious for the success of this work. I have spared no pains in my attempt to make it of practical value, and I have laid under contribution all the literature that has come within my reach or my knowledge, whether English or foreign, on the subject of Ophthalmic Pathology and Surgery. I have given at length my own personal experience. It remains for me to particularize some of those to whom I feel myself especially indebted.

First of all I mention the venerable Dr. John Richard Farre, who, in conjunction with Mr. John Cunningham Saunders, established the first public institution in this kingdom for the treatment of ophthalmic diseases.

To this great physician, full of years and of honor, I am indebted for the advice to study Ophthalmic Medicine and Surgery, and by him I was introduced as a pupil into this department of science.

Having had the good fortune to be both pupil and, for a short period, acting house-surgeon of the Ophthalmic Institution, under the superintendence of Mr. Tyrrell, Mr. Scott, and Mr. Dalrymple, I must record my admiration of the zeal, the practical skill, and the advanced science which characterized the practice of those illustrious men, whose premature death is a loss as well to the public as to the medical profession. To Mr.

Lawrence, also, eminent alike as a scholar and as a surgeon, I am under deep obligations for the knowledge which I gained on ophthalmic subjects, while acting under him as dresser and house-surgeon.

To Dr. Mackenzie, of Glasgow, I am much indebted, and have compared my own observations with his valuable experience, as detailed in his excellent work on the diseases of the eye.

No one who is at all acquainted with Ophthalmic Surgery is ignorant of the immense value of the profoundly scientific and eminently practical researches of Dr. Jacob, of Dublin: his writings I have studied with care.

To Mr. Wilde, of Dublin, I must also pay my tribute of thanks and admiration; and no less to my friend Mr. Browne, of Belfast, who has greatly assisted me by many important suggestions.

My colleague, Dr. Taylor, has rendered me most important assistance by working with me, and taking many of the sketches that adorn this volume.

I am under obligations to others whom I name not in detail, that I may escape the charge of parading the catalogue of my kind friends. To all and each, I tender my warm and respectful thanks.

The illustrations, one hundred and sixty-nine in number, by the Messrs. Bagg, will doubtless fully sustain the high character which these artists have acquired.

H. HAYNES WALTON.

69 BROOK STREET, HANOVER SQUARE,
December 31st, 1852.

CONTENTS.

	PAGE
CHAPTER I.	
The use of Chloroform in Ophthalmic Surgery,	17
CHAPTER II.	
Ophthalmic Instruments in general,	23
CHAPTER III.	
Injuries from Mechanical and Chemical Agents, Burns and Scalds, Ecchymosis, Blows, Wounds, Chemical Injuries,	32
CHAPTER IV.	
Foreign Bodies on the Surface of the Eye. Larvæ of Insects under the Lids. Foreign Bodies within the Eyeball. Ossification of the Ocular Tissues,	69
CHAPTER V.	
Affections of the Eyelids. Diseases of the Lachrymal Passages. Abscess of Lid. Complete or partial Adhesion of the Eyelids to the Eyeball. Adhesion of the edges of the Eyelids. Encroachment of the Skin on the corner of the Eye. Falling of the Upper Eyelid. Trichiasis. Entropium. Entropium with Trichiasis. Ectropium. Obstruction of the Meibomian Ducts. Conjunctival Calculi,	89
CHAPTER VI.	
Affections of the Puncta, the Canaliculi, and the Lachrymal Tube,	177

CHAPTER VII.

Caries of the Orbit,	PAGE 201
--------------------------------	-------------

CHAPTER VIII.

Nævi Materni. Dilated and Tortuous Veins. Aneurism by Anastomosis,	208
--	-----

CHAPTER IX.

Incision of the Conjunctiva, and of the Subjacent Cellular Tissue in Chemosis from Purulent Ophthalmia,	238
---	-----

CHAPTER X.

Strabismus or Squint. Internal Squint. External Squint,	247
---	-----

CHAPTER XI.

Tumors of the Eyelid. Tumors of the Conjunctiva. Tumors involving the Cornea and the Sclerotica. Tumors of the Orbit. Enlargement of the Lachrymal Gland. Tumors connected with the Lachrymal Gland,	275
--	-----

CHAPTER XII.

Protrusion of the Eyeball. Protrusion from causes within the Orbit. Protrusion from Anæmia. Rheumatic Inflammation of the Ocular Sheath. Abscess and Inflammation within the Orbit. Periostitis of the Orbit, and Disease of the Optic Nerve,	331
---	-----

CHAPTER XIII.

Staphyloma of the Sclerotica, and of the Cornea. General Enlargement of the Eyeball with Disorganization,	350
---	-----

CHAPTER XIV.

Conical Cornea,	366
---------------------------	-----

CHAPTER XV.

Removal of Opacities of the Cornea by Operation. Transplantation of the Cornea,	373
---	-----

CONTENTS.

xi

CHAPTER XVI.

	PAGE
Cataract. Varieties of Cataract. Cause of Cataract. Nature of Lenticular Cataract. Hard Cataract. Soft Cataract. Capsular Cataract. Distinctions between Cataract and Amaurosis. Cataract and Glaucoma. Operations for Cataract. Preparation of Patient. Operation for Extraction. Operation for Displacement. Operation for Solution. Operation for Capsular Cataract. Operation for Drilling. Spectacles necessary after loss of Crystalline Lens,	383

CHAPTER XVII.

Entozoa within the Eyeball, and about the Ocular Appendages. Cysts within the Chambers of the Eyeball,	477
--	-----

CHAPTER XVIII.

Artificial Eyes,	489
----------------------------	-----

CHAPTER XIX.

Malignant Affections of the Eye. General Considerations, including Definition of Cancer; Microscopic Character of Cancer; Origin and Physiology of Cancer in connexion with Treatment; Question of liability of the Eye to Cancer. Encephaloid Cancer of the Eyeball. Melanosis. Scirrhus. Cancer of the Orbit. Cancer of the Eyelids. Cancer of the Lachrymal Gland. Question of the propriety of Operating in the several Varieties of Cancer about the Eye,	492
--	-----

CHAPTER XX.

Artificial Pupil. Conditions under which an Operation may be undertaken, and those which contra-indicate it. Relative advantages of the several positions in the Iris for a Pupil. Size of the Pupil. Shape of the Pupil. Classification of the principal Morbid States of the Eye requiring a Pupil, with the most appropriate Operations. Concluding General Remarks,	549
---	-----

CHAPTER XXI.

Extirpation of the Eyeball. Removal of the entire Contents of the Orbit. Removal of the Eyeball alone,	589
--	-----

CHAPTER XVI

CHAPTER XVI

The first of the two main divisions of the work is the history of the people of the country, from the earliest times to the present day. The second division is the history of the country, from the earliest times to the present day.

CHAPTER XVII

The first of the two main divisions of the work is the history of the people of the country, from the earliest times to the present day. The second division is the history of the country, from the earliest times to the present day.

CHAPTER XVIII

The first of the two main divisions of the work is the history of the people of the country, from the earliest times to the present day. The second division is the history of the country, from the earliest times to the present day.

CHAPTER XIX

The first of the two main divisions of the work is the history of the people of the country, from the earliest times to the present day. The second division is the history of the country, from the earliest times to the present day.

CHAPTER XX

The first of the two main divisions of the work is the history of the people of the country, from the earliest times to the present day. The second division is the history of the country, from the earliest times to the present day.

CHAPTER XXI

The first of the two main divisions of the work is the history of the people of the country, from the earliest times to the present day. The second division is the history of the country, from the earliest times to the present day.

ILLUSTRATIONS.

FIG.	PAGE
1. Drum for Testing the Points of Instruments,	25
2. Scalpel,	27
3. Dissecting Forceps,	28
4. Tenaculum Forceps,	28
5. Lid-retractor,	29
6. Straight Suture Needle,	30
7. Curved Suture Needle,	30
8. Curved Scissors,	31
9. Wound of the cornea with laceration of the iris,	50
10. Wound of the cornea with prolapse of the iris,	57
11. Laceration of the lower eyelid,	61
12. Instrument for removing foreign bodies from the surface of the cornea,	69
13. General adhesion of the lower eyelid to the eyeball,	91
14. Partial adhesion of the lower eyelid to the eyeball,	93
15. Partial adhesion of the edges of the eyelids,	98
16. Encroachment of skin on the corners of the eyes,	101
17. Ptosis,	104
18. Diagram of a bit of skin removed from the eyelid for ptosis,	105
19. Ptosis from hypertrophy of skin and cellular tissue,	107
20. Ptosis from paralysis of the occipito-frontalis,	108
21. Cilia forceps,	109
22. Trichiasis,	111
23. Trichiasis with thickening of the edge of the eyelid,	113
24. Operation for removal of skin from the eyelid in trichiasis,	118
25. Eye after operation for trichiasis, by the removal of skin from the eyelid,	119
26. Display of the cilia by dissection,	121
27. Section of the eyelids,	121
28. Operation for partial removal of cilia,	122
29. Eye after partial removal of cilia,	122
30. Operation for the entire excision of cilia,	123
31. Eye after excision of cilia from both eyelids,	124
32. Operation for the excision of cilia without loss of skin,	125
33. Diagram of tarsal cartilages,	129
34. Diagram of dislocation and turning in of the lower tarsal cartilage in entropium,	130
35. Dissection of the tensor tarsi muscle,	134
36. Operation for entropium,	136
37. Profile view of entropium of upper eyelid,	145
38. Profile view of an eye after the operation for entropium of the upper eyelid,	145
39. Eyes contrasting the appearances left after different operations for entropium,	146

FIG.	PAGE
40. Partial entropium of lower eyelid of one eye, and total entropium of the other,	147
41. Lower eyelids after operation for entropium,	148
42. Ectropium of lower lid,	153
43. Diagram of incisions for operating on ectropium,	154
44. Eye after the operation for ectropium,	154
45. Diagram of incisions for the operation for ectropium; after Dieffenbach,	155
46. Diagram illustrating the manner of excising a portion of the tarsal cartilage for ectropium,	156
47. Sketch, illustrating ectropium of the upper eyelid, with plan of incision,	157
48. Diagram, illustrating the manner of bringing the wound together after the operation for ectropium,	158
49. Sketch, showing plan of incision for ectropium of the outer corner of the eye,	159
50. Plan for plastic operation, by twisting the skin,	160
51. Ditto,	160
52. Ectropium of the lower lid remedied by a plastic operation,	162
53. Ditto,	163
54. Diagram for plastic operation by sliding the skin,	164
55. Ectropium of lower lid, from ulceration of the tarsus,	170
56. Partial ectropium of the lower lid,	171
57. Case after operation for ectropium,	171
58. Ectropium of the lower lid from thickening of the conjunctiva,	172
59. Ditto after operation,	172
60. Probe for puncta and canaliculi,	177
61. Partial dissection of the lachrymal tube,	179
62. Knife for lachrymal tube,	182
63. Fistula lachrymalis,	184
64. Style,	186
65. Sketch of the orbit illustrating the relations of the nasal duct,	187
66. Style, showing the effects of corrosion,	189
67. Syringe for lachrymal tube,	190
68. Probe for lachrymal tube,	197
69. Anatomical view of the lachrymal tube and its nasal aperture,	198
70. Ectropium of the upper eyelid, from caries of the orbit,	203
71. Sketch, showing cicatrization after caries of the orbit,	204
72. Ectropium of the lower eyelid, from caries of the orbit,	205
73. Nævus of the brow and eyelids,	215
74. Diagram, showing the manner of tying an elongated nævus,	218
75. Author's noose for strangulating nævi,	219
76. Illustration of the manner of tying the same,	220
77. Subcutaneous method of tying nævi,	221
78. Remains of a nævus after an operation by caustic seton,	223
79. Illustration of aneurism by anastomosis in the orbit, for which the common carotid artery was tied,	231

ILLUSTRATIONS.

XV

FIG.	PAGE
80. Knife for dividing chemosis,	238
81. Scissors for strabismus,	247
82. Blunt hook for strabismus,	248
83. Illustration of optical experiment for detecting squint,	255
84. Ditto,	255
85. Ditto,	256
86. Illustration of operation for strabismus,	261
87. Glandiform tumor,	278
88. Steatomatous tumor,	279
89. Vesicular tumor,	279
90. Tarsal tumor of upper eyelid,	281
91. Tarsal tumor of lower eyelid,	282
92. Tumors of conjunctiva and upper eyelid,	285
93. Pterygium,	289
94. Ditto,	292
95. Tumors of the sclerotica,	294
96. Encysted tumor of the edge of the orbit,	301
97. Dissection of the sheath of the eyeball,	304
98. Fibro-cystic tumor within orbit,	305
99. Tumor about the head and orbits from tuberculous deposit,	314
100. Exostosis of the orbit,	319
101. Exostosis of both orbits,	321
102. Osteo-sarcoma occupying the orbit,	322
103. Diagram, illustrating the position of the lachrymal gland,	329
104. Chemosis from inflammation of the orbital cellular membrane,	341
105. Protrusion of the eyeball,	348
106. Staphyloma of the cornea,	352
107. Eye after an operation for staphyloma of the cornea,	356
108. Staphyloma of the sclerotica,	360
109. Enlargement of the eyeball,	363
110. Conical cornea,	366
111. Cataract knife,	415
112. Diagram of cornea with lines indicating plans of incision,	416
113. Curette,	416
114. Guarded curette,	417
115. Secondary cornea knife,	417
116. Sharp hook,	417
117. Diagram, showing the operation for extraction,	420
118. Diagram, showing the manner of expelling the cataract,	422
119. Case of prolapsus of the iris after the operation for extraction,	437
120. Grooved knife for the extraction of a soft lens,	440
121. Needle for reclinatio,	441
122. Diagram, illustrating "depression,"	442
123. Diagram for "reclinatio"	442
124. Diagram of Egerton's plan of "reclinatio,"	443

FIG.	PAGE
125. Operation for "displacement,"	444
126. Straight needle for "solution,"	449
127. Diagram, showing the position of the crystalline lens,	450
128. Curved needle for "solution,"	451
129. Operation for "solution,"	452
130. Blunt canula forceps	465
131. Sharp canula forceps,	466
132. Delicate cross-spring forceps,	467
133. Coarse cross-spring forceps,	467
134. Eye with bands of opaque capsule across the pupil,	469
135. Eye with opaque capsule in the pupil,	470
136. Cysticercus cellulosæ in its cyst,	477
137. Magnified head of cysticercus,	477
138. Cysticercus of natural size without its cyst,	478
139. Cysticercus with the head and body retracted within the tail vesicle,	478
140. Cysticercus within the eye,	480
141. Artificial eye,	489
142. Encephaloid cancer in the neighborhood of the orbits,	527
143. Epithelial cancer of the orbit,	528
144. Sharp iris scissors,	557
145. Probe-pointed iris scissors,	557
146. First sized iris knife,	558
147. Second sized iris knife,	558
148. Third sized iris knife,	558
149. Tyrrell's blunt hook,	559
150. Blunt barbed hook,	559
151. Blunt hook,	559
152. Iris canula scissors,	560
153. Operation for artificial pupil by "incision" with the knife,	562
154. Closed pupil by prolapse of the iris,	563
155. Artificial pupil by "incision" with the knife,	564
156. A contracted pupil closed by opaque capsule,	565
157. Pupil after operation by "incision" with the knife,	565
158. Two pupils made by "incision with extension,"	568
159. Diagram illustrating "incision" with the scissors,	569
160. A pupil made by "incision" and "excision" combined,	570
161. Diagram, illustrating a pupil made by tearing away a central piece of the iris,	574
162. A pupil made by "excision,"	575
163. Needle-hook,	577
164. Two diagrams, illustrating an operation for incising the pupillary margin,	580
165. A pupil made by "incision" with the knife and the scissors,	581
166. A pupil made by "separation,"	583
167. A pupil made by "separation,"	584
168. Prolapse of the iris closing the pupil,	585
169. A pupil made by "incision,"	587

OPERATIVE OPHTHALMIC SURGERY.

CHAPTER I.

THE USE OF CHLOROFORM IN OPHTHALMIC SURGERY.

ONE of the great improvements in the surgery of our times, as a means of ameliorating human suffering, is the use of anæsthetic agents; and happily the benefits of this improvement extend themselves to operations on the eye.

It is scarcely possible to overrate the value of a discovery which tranquillizes the mind of the patient by banishing the anticipation of pain, deadens the sensibility, and prevents the reality of suffering; while to the operator it brings the inestimable advantage of quieting the struggles of children, or of irresolute adults, which are so apt to frustrate all the care, foresight, and dexterity that the most assiduous application to practical surgery can command.

It is well known that the merit of the first discovery of an anæsthetic agent, sufficient to banish the sense of pain, belongs to the New World. In the autumn of 1846, Drs. Jackson and Morton, of Boston, ascertained that by the inhalation of the vapor of sulphuric ether, insensibility to the suffering attendant on tooth-extraction, and other surgical operations, was produced. The tidings of this discovery, fraught with so much interest to the suffering part of mankind, spread with unusual rapidity over the world, and in an incredibly short period, ether had been inhaled in the most remote quarters of the globe.

Early in the following year, the fluid termed chloric ether, which is a solution of chloroform in spirit, was by the recommendation of Mr. Jacob Bell, of Oxford Street, employed to a limited extent for the same purpose, and it appears that it is still used in America.

In November of the same year, Professor Simpson of Edinburgh, who had from the first extensively employed ether in obstetric cases, began to try the effects of other anæsthetic agents; and out of the great number of substances of which he made trial he selected, as the best, chloroform, which Mr. Waldie of the Liverpool Apothecaries' Hall, had the good fortune to suggest to him as likely to succeed. Dr. Simpson's account of the trials made with chloroform in Edinburgh, backed by the testimony of many medical men in that city, soon drew general attention to this agent; and its more certain and rapid effects, its smaller bulk and more agreeable odor, have established it as the most suitable of all the anæsthetic agents which have been proposed for suspending the consciousness of pain during surgical operations.

Chloroform is much more powerful than ether; but its administration is not devoid of danger, so that it requires to be used with proper precaution and care. Those accidents which have occurred, appear to have been the result of insufficient purity in the chloroform, or of carelessness in its application. The use of a proper inhaler insures the dilution of the chloroform with a sufficient quantity of atmospheric air; so that its effects are produced with greater regularity, and the proper time for its discontinuance readily noticed. If the vapor be administered in too concentrated a form, so much of it may become accumulated in the lungs at the moment when the inhalation is discontinued, that injurious or even fatal effects may ensue; and this result seems more likely to occur when a handkerchief, rather than a proper inhaler is employed. Nevertheless, in experienced and careful hands, chloroform is attended with very little danger, and is so manageable that there is no kind of constitution which really

forbids its use in moderation. In making this assertion I am fully supported by the authority of Dr. Snow. Even where the heart was diseased, I have administered it. I have resorted to it in cases occurring in general surgery demanding operation, where the system was so enfeebled, that without its influence, the patient would most probably have sunk under the suffering caused by the severity of the surgical measure.

I have frequently seen it given with advantage when the lungs were diseased. A few weeks prior to writing this, I attended, with Mr. Coulson, a phthisical patient, who would not allow a bandage to be removed from a diseased leg without first deadening his sensibility by the influence of chloroform. This was repeated about three times a week for nearly three months. The distressing cough was always allayed for many hours after inhalation.

Mr. Spencer Wells has, by the special and dying request of a nobleman whom he attended during the ravages of phthisis, brought before the Medico-Chirurgical Society of London the important fact of the relief derived from the use of chloroform in that malady. A notice of this is to be found in the "*Medical Times*" for May 5, 1847. The extreme violence of the cough and the very oppressive dyspnœa, uncontrolled by the usual remedies, suggested the trial of chloroform. The inhalation was successful; every repetition of it equally so; and during the remaining seven months of the patient's life great alleviation of suffering, without any discoverable ill effects, was obtained by its frequent employment. I mention these circumstances to subdue, in the minds of those who have delicate lungs, fears respecting the inhalation of chloroform.

The points to which attention must be chiefly directed in the administration are: that the chloroform be largely diluted at the commencement of the inhalation; that its strength be gradually increased by a diminution in the supply of air; that as soon as the breathing becomes stertorous, the inhalation is to be stopped or suspended: and, that the chloroform

be sufficiently, pure, a condition which may almost always be secured by obtaining it from a respectable chemist. The following hints, however, may be useful. Its formula is $C^2 H Cl^3$. Its specific gravity was fixed at 1.480 by Liebig, but it is now constantly produced at 1.496 by Souberain. Dr. Simpson gives it as 1.500. It is frequently empirically prepared by persons who know nothing of its composition, and it is seldom that an absolutely pure sample can be obtained. In different specimens there have been discovered alcohol, chlorine, hydrochloric acid, and hydrochloric ether, compounds of methyle, besides water, and fixed substances. Chloroform may be depended on that has a sp. gr. of 1.480, a higher density is to be preferred, and which will stand the following tests. When poured on the hand it should evaporate entirely without leaving any odor. It should not give any reaction with red or blue litmus paper or nitrate of silver. When shaken with twice its weight of distilled water, and allowed to stand two or three hours in a graduated tube, it should not sensibly diminish in bulk. When placed in contact with concentrated sulphuric acid, the acid should not become blackened. If it will stand this examination, it may be safely relied upon for inhalation. It should be kept in a well-stopped bottle, and excluded from the light.

The time to commence an operation is the moment voluntary motion is suspended, and the proof of this is the loss of the sensibility of the conjunctiva; for as long as there remains sensibility in that membrane, there will be contraction of the eyelids, when the globe of the eye is touched.

No non-professional person, or one who has not previously studied the effects of chloroform and the mode of administration, and has not acquired some practical acquaintance with its peculiarities, should be allowed to superintend its inhalation.

Except the operation for the extraction of cataract, or the division of the cornea to a like, or nearly equal, extent, for any other purpose, there is no operation on the eye in which well-founded objections exist to the previous use of chloroform, or

ether, as anæsthetic agents. In the exceptions mentioned, the objection arises from the fear of vomiting, and the loss of the vitreous humor. It is true that vomiting is but an occasional effect of the use of these agents, and it can nearly always be prevented by emptiness of the stomach previous to inhalation, and which is secured by enjoining a strict fast for four or five previous hours; but, after every precaution, vomiting may occur, or severe retching, which is equally injurious. Dr. Fleming, of Dublin, suggests that the patient should have, on the morning of the operation, a little milk beaten up with an egg and some brandy or wine; this, he says, has been found to obviate the sickness occasioned by the exhibition of chloroform on an empty stomach. Rather, therefore, than run even a slight risk of an event so untoward, it is better in these operations, to forego the advantage of anæsthetic substances. There are a few exceptions where this risk is to be preferred to the great danger of operating without the inhalation: for instance, in extraction of a cysticercus or a foreign body, or an opaque capsule from a child; or for similar operations on an adult, including besides the extraction of a dislocated lens, when pain and irritability of the eye would render extraction in the ordinary way hazardous, from the impossibility of steadying the eyeball except by undue pressure.

Chloroform may be administered to persons of all ages, from a few months, or weeks old, to extreme age. I have given it several times at six weeks, and once at a month old, and a medical friend reports that he has kept a child of ten weeks old under its influence for more than half an hour, without any unpleasant result whatever.

Among those who have devoted themselves to the extension of our knowledge of the precautions under which chloroform should be employed, Dr. Snow stands pre-eminent. His extensive researches, and his numerous and scientific experiments, have been conducted with a degree of accuracy, hardly to be surpassed; and the results have been so important as to place the medical profession under the greatest obligations to him. To

operate when the patient has been narcotized by one so conversant with all the peculiarities of its action on the human body, is to obtain an advantage as regards the success of the final result, heretofore unknown in surgery.

For further particulars on this important subject, I would refer to Dr. Snow's communications in the "Medical Gazette," during the period from 1847 to 1850; to No. 180 of the "Edinburgh Journal of Medicine," for April, 1847; and to the "Medical Times," for August 31st, 1850; to Mr. Druitt's excellent "Surgeon's Vade-mecum," whose chapter on the use of Chloroform, and the other means of procuring insensibility to pain, will well repay a perusal. It is clear, comprehensive, and highly practical. Lastly, to the Appendix to Professor Miller's Principles of Surgery, entitled "Surgical Experience of Chloroform."

CHAPTER II.

OPHTHALMIC INSTRUMENTS IN GENERAL.

It is easy to comprehend the extent of influence exerted over the success of a surgical operation by the perfection or imperfection of the instrument with which it is performed. It may even happen that the defects of the instrument shall amount to a prohibition of obtaining by means of it, the effects which it is intended to accomplish; and if this be the case in surgery at large, it is more particularly true in ophthalmic operations.

To lessen the defects of an instrument is tantamount to an improvement in the branch of surgery to which it belongs. Simplicity and due adaptation to the purpose intended are the qualities which a surgeon who operates on the eye should endeavor to acquire for his implements. The improvement of those in our day contrasts advantageously with the coarseness of form, and inferiority of workmanship in times past. For these reasons alone I should deem it proper to dwell somewhat on the subject of instruments; but further, I take this view of the matter, that in treating of any department of operative surgery, a great opportunity of communicating practical instruction is lost, when hints and observations on the instruments concerned are omitted.

The plan proposed is to introduce the several instruments with the subjects requiring their use and to describe them apart from the operations, as it possesses the advantage of allowing a fuller attention for them than if they were spoken of digressively; while the subsequent details of the operations themselves, being uninterrupted, will then most readily command the

attention of the reader. Some few in general use, will be given at the end of this chapter.

As each instrument will be illustrated by an engraving which will convey the most exact ideas of it, little more than those points only which deserve especial attention will be dwelt on in the description, or which the figure less prominently sets forth. The instruments that are introduced are those I am actually in the habit of using, and which appear to me to be the most appropriate to each occasion, and the most convenient for the several purposes which they are intended to fulfil.

With ophthalmic instruments, lightness is an element of the highest importance. The lighter they are, the greater is the delicacy with which they can be applied. With light instruments the resistance to be overcome is better appreciated, as well as the amount of the force required for that purpose. The blades should not be of greater size than the use intended requires: but in a far greater degree the same property is attained by exchanging the ivory handle so generally adopted, notwithstanding the nicer appearance, for one of light wood. In all other respects the minimum of the dimensions compatible with the kind of instrument, should be made the rule. In successive years, as I have required to renew my instruments, I have gradually had their size reduced, and the effect has been to adapt them better to the several operations. Besides remedying the clumsiness and awkwardness which attach to those of greater bulk, in several instances positive evils arising from inordinate size have been avoided.

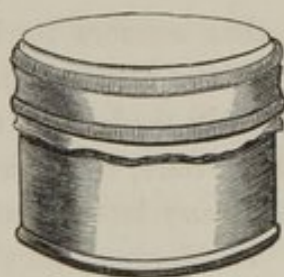To all small instruments, such as cataract knives, cataract needles, and the like, I prefer round handles, for when of this form they can be held with more ease and freedom, while stiffness and constraint are overcome, and a more individual independent control is thus given to the fingers. I am also of opinion that the handles of such should be smooth and not cross cut. There can be no other reason why the handle of a surgical instrument should be roughened, and thereby rendered

unpleasant to the touch, as well as less suitable for delicate use, than that surgeons, having been careless about the subject, have permitted the instrument-maker to indulge his fancy merely to give an air of finish to his workmanship. I believe it to be true, and if so, it is a fact of much significance, that there is no other manual art in which rough-handled instruments are used.

All instruments designed to puncture the cornea should have such a form, from the gradual increase of thickness from the point, as to act on the principle of a stopper in the aperture that is made; the effect of which is to retain the aqueous humor as long as possible, so that the natural prominence of the cornea is for a time preserved, the danger of prolapse of the iris is obviated, and the subsequent steps of the operation are facilitated. The gradual augmentation of size sufficient for this purpose, while a proper stiffness of point is preserved, need not, in needles, exceed at the largest part from 1-36th to 1-40th of an inch.

Sharpness of point, and keenness of edge are here of paramount importance, and these qualities of a perfect instrument

Fig. 1.



should be carefully sought after, and ascertained by delicate processes. To test the point, the best criterion I know is the little drum made of the cuticle stripped from the softest kid skin, and stretched over a metallic cylinder, of which the above figure is a representation. A less perfect method is, to stretch the cuticle across the fingers. In either case, if the point be in proper order, the mere weight of the instrument should

cause it insensibly to penetrate the tissue. If, on the contrary, the point be dull, it requires to be forced through; if otherwise defective, by being turned; and if broken, in addition to the force required to make it penetrate, a sharp cracking sound is emitted. In consequence of the natural pores in the cuticle, several punctures should be made to insure the passage of the point of the instrument through an unbroken space.

The edge should be tried on some part of the hand where the cuticle is thinnest, for instance, on the ball of the thumb; and I cannot express myself more concisely than by saying, that with a slight drawing motion it should at once enter, or bite, as instrument-makers say.

Properly tempered instruments may always be secured by dealing at some highly respectable London shop, such as that of Messrs. Weiss, or Whicker and Philp, where each, from the largest to the smallest, is separately hardened, and individually tempered, and where the extent of sale is such, as to enable the maker to maintain in constant employment a workman whose sole occupation it is to manufacture delicate instruments of this class; for by such exclusive attention alone can the highest perfection be reached.

It is necessary, also, that scissors be inspected. Their efficiency depends not only on the blades being properly sharpened, but, besides, on being lightly made and securely riveted. The simplest, and, at the same time, the surest test, is to close the blades gently, and without any lateral pressure, on a very thin piece of wetted paper. If effectual, they will readily divide it; if not, they will close over it without cutting.


I cannot refrain from adding a remark on sponges. It is hardly conceivable that the success of an operation can, in any degree, be dependent on the mere purity of a sponge; yet I have the strongest reason to suspect, that in many cases the partial or entire failure of the process of adhesion after incisions, has depended on the transmission of particles of sand from the sponges to the edges of wounds. The impossi-

bility of buying a new sponge that is not loaded with earthy particles, is well known. To remove these, time is requisite; washing, necessary as it is, cannot at once cleanse them. The best method of procuring them free of grit, is to employ the best sponges of the shops for common domestic purposes for several months, taking care that on frequent occasions, when dry, they are beaten for some time.

SCALPEL.

An instrument of such general use, and so well known, would have been passed over in silence, were it not that the kind here advocated is reduced considerably below the size of scalpels in general. The ordinary ones are decidedly too large for all dissecting operations on a small scale, especially such as those on the eyelids, where precision and neatness are imperatively demanded; and those for the removal of tumors about the eye and its appendages, particularly when encroaching upon, or actually lying within the orbit. The point is placed centrally, and this position, while it allows of a requisite amount of curve, renders it better adapted for minute dissection, than when it is in a line with the back of the blade; and in a central point there may be the union of the greatest fineness with the greatest strength. In nearly all operations with the scalpel, it is the point of the blade that is principally available, and to its properties the value of the knife is chiefly due. The breadth of the handle is of some consequence, for if carried beyond a certain extent, it is not readily fingered. I also recommend that the parts to which the points of the fingers are applied should be rounded. The length may be what fancy suggests, unless, as is the case with myself, the instrument be held in a particular manner, as a common table-knife is held, my fingers being placed near the

Fig. 2.



blade, a method which demands shortness of handle. This mode of holding it I adopt for almost all purposes, finding that it combines the greatest freedom of motion with the greatest power, and the lightest touch.

Fig. 3.



FORCEPS.

The proper length is such as allows them to rest on the hand between the thumb and the finger, when held in the ordinary manner. Any length beyond this is useless, and increases their weight. The blades should be slightly bowed, well hardened, and of a

Fig. 4.



substance, in thickness rather than in breadth, that will not allow them to slip on each other, or bend under any force of pressure that can be required during their use; for, were their extremities to gape, which they surely would if the centres of the blades were weak, they must cease to be effectual. The spring should not be made stronger than sufficient to sustain their weight.

Round points are, I think, superior to any other form. The holding, or interior surfaces of the extremities, should be raised, and obliquely cut for at least a quarter of an inch, the serratures being large, and exactly fitting. This roughness is quite compatible with an accuracy of edge adapted for minute purposes.

It is frequently required to use tenaculum forceps in operations about the ocular appendages, for the ordinary ones do not lay hold with sufficient firmness. The lesser figure, representing merely the points, shows the direction the teeth should have. When

so placed, they seize very readily, although they cannot retain their grasp quite so securely as when made to meet at a right angle. In order to be effectual their blades should be stout enough to enable sufficient pressure to be made at the points. When shut without an intervening substance, the teeth necessarily cross. A catch-spring, like that usually added to tenaculum forceps, and originally introduced for Amussat's treatment of bleeding arteries by torsion, is not only useless for dissection, but a decided impediment.

LID-RETRACTOR.

Of the many instruments in use for the purpose of retracting the eyelids, whether to procure an examination of the eye, or to facilitate the performance of operations, I give the preference to this, which is designed to be inserted under the lid, and which is of full size for an adult. For infants and children a smaller one is necessary. Its length and lightness are such as to enable it to be applied with delicacy, and to be maintained in the desired position without the exercise of force. The bent portion deserves attention. It should not be longer, or more obtuse than sufficient to secure and confine the edge of the lid, otherwise its action might be detrimental; because if the sinus or sulcus of the lid were reached, on its introduction, a resistance would be immediately encountered, which would not only prevent the lid from being properly raised, but be a source of pain, owing to the dragging and violence then requisite to effect any degree of retraction.

Fig. 5.



SUTURE NEEDLES.

That the stitching of wounds is very often the most painful part of an operation, is a fact early impressed upon the student of surgery. Without doubt, much of the suffering is too frequently to be attributed to the imperfection of the needle. Good surgical needles are rarely to be met with, merely because their manufacture is in general neglected, and they are not rendered hard enough to bear proper sharpening. The point, or cutting part, should be large enough to make a channel through which the shaft can glide with ease, or at least pass without force sufficient to stretch or tear the skin. These requisites seem to be fully united in the well-formed glover's needle, which has three edges, of which this is an illustration.

Fig. 6.



The stoutness should be proportionate to the thread which is required, by which standard the size of a needle should invariably be regulated. The length is a matter of convenience. Where circumstances admit of choice, I always prefer the straight form, because a straight needle enters more readily, and is more easily guided than a curved one.

A different body is desirable for a bent needle. The front, or concave part should be quite flat from side to side, and the posterior, or convex side, oval across. If both are oval, the edges cannot be made thin enough, consistently with smallness and strength. This pattern illustrates the description.

Fig. 7.



The figures represent the size of those I employ. Besides there being no advantage derivable from shorter ones, there is

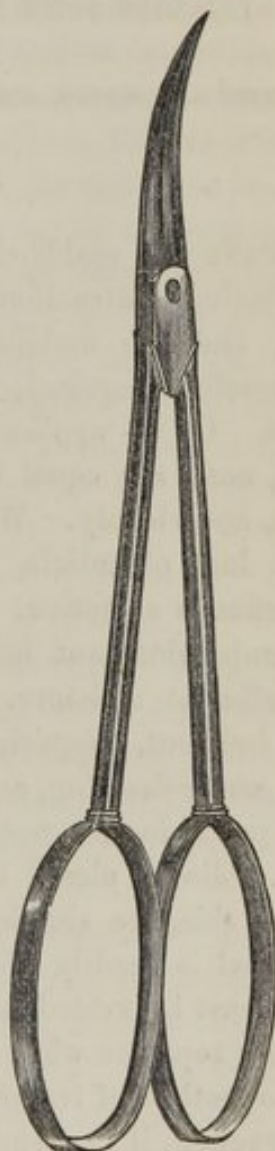
a positive disadvantage attached to lesser length, arising from difficulty in use. A variety of porte-aiguilles have been invented to obviate this, all of which may be dispensed with by employing a proper needle.

CURVED SCISSORS.

The slight bend in the blades of these scissors renders them very useful on many occasions, and the ophthalmic case is scarcely perfect without them. The points should be of a certain width, and not too delicate, in order to insure proper strength.

Within the last two years, Messrs. Weiss have registered two kinds of joints for scissors, and other double-bladed instruments of the same class. The one is called the lever joint, the rivet being placed at the side in an angular projection; by which, it is said, that greater power is given, and the mode of cutting is rather improved, and a substance is less likely to slip from between the blades. The other is a sort of lock-joint, a screw not being used, and the advantage of which is, that the blades do not become loose, as often happens, but ever keep their degree of tightness, and the instrument can be the more readily used with either hand, and easily unlocked for the purpose of being cleaned.

Fig. 8.



CHAPTER III.

INJURIES FROM MECHANICAL OR CHEMICAL AGENTS.

BURNS AND SCALDS, ECCHYMOSIS, BLOWS, WOUNDS, CHEMICAL INJURIES.

BURNS AND SCALDS.

BURNS and scalds of the lids are generally followed by very distressing contraction from the thinness and looseness of the skin, and the mobility of the tarsi. Paramount attention is therefore required, to prevent or to lessen the suppurative stage. Of all applications that I have myself tried and seen used, none are equal to nicely dressed cotton wool; it is soft, light, and cleanly. Where there is merely an abraded surface from loss of cuticle, it excludes the air and soaks up any superfluous secretion. If suppuration should exist, it absorbs the superabundant fluid, while enough is left for the purpose of sufficient moisture. With it, the sore does not grow flabby and indolent, requiring stimulants, as so frequently happens with water-dressing, and the granulations are kept in a condition that precludes the necessity for escharotics. I have frequently seen ordinary ulcers that had resisted other applications heal under this, the simplest of all means. The changing of this material is readily effected; any portion adhering to the sound skin must be wetted, and that over the raw surface will always readily separate when surcharged with moisture.

No method of treatment that is known will prevent subsequent contraction, if the true skin, the cutis vera, be much damaged or destroyed; and all that can then be done towards lessening the deformity, is to check the period of suppuration.

When the injury is superficial and small, it may be well to endeavor to obtain incrustation and healing of the raw surface by the modelling process of Macartney, which may be effected by unirritating powdered substances, or brushing it over with nitrate of silver, and covering all with goldbeaters' skin or gum, in preference to collodion, which is too painful an application. Professor Miller of Edinburgh has used successfully a thick semi-fluid aqueous solution of gum tragacanth; he lays it gently and uniformly on the raw surface, and reapplies it, should any portion become imperfect. Being transparent, complete surveillance of the part is permitted. Should these means not prove successful, the parts are not in a less favorable condition for other treatment. It is better not to cut blisters, for the cure goes on more readily when the fluid is absorbed and the cuticle not broken. A greasy application of any sort is useful, for the cuticle will remain longer unbroken under it. The special indication arises, if the edges of the lids be involved, to prevent their edges from uniting, and this may be with certainty fulfilled, if the corners have escaped injury. For further remarks on the subject, I must refer to Chapter VI.

ECCHYMOSIS.

The ready production of ecchymosis about the eye is, of course, due to the superficial position of the bones of the orbit, and the contusion that the skin receives from a slight blow; while the considerable tumefaction which is so common after a blow, is due to another peculiarity of the orbital region, the looseness of the skin.

I question whether any means, except gentle friction, can hasten the natural process of absorption. The employment by pugilists of briony root, and Solomon's seal, scraped and made with bread into a poultice, or of rosemary and arnica infusions, has induced medical men to recommend these applications. But it is not a fact that the prize-fighters can disperse these results of their savage encounters, for they last in them as in other

people; but as their accustomed personal exhibitions after fights are at night, most of the color, especially the lighter hues, are invisible; and hence the popular assumption of the potency of their remedies: and if it be true that in this class of persons the extravasation is quickly dispelled, it is more probably owing to the perfection of the nutrient and absorbent processes which exist in their high bodily condition.*

There does not appear to be satisfactory evidence, that depressing the temperature of the surface by frigorific mixtures hastens absorption; and theoretically speaking, I should rather expect it to retard nature in her operation. There are, however, degrees of ecchymosis, some of which demand treatment, and neglect of which may be followed by injury to the lid. The extravasation may be increasing, the infra- or supra-orbital vessels, or other arterial twigs, may continue to ooze, and recourse must be had to pressure or cold, reducing the heart's action by the loss of blood, or by a smart purge, and above all, perfect rest. When the extravasation is considerable, the probability of suppuration is to be borne in mind, and the state of the system must be looked after, and all febrile threatenings attended to. Neither incisions nor punctures should be made with the intention of turning out coagula; for suppuration would be almost certain to follow. The knife should be withheld unless sloughing is impending, or has commenced. Leeches on the injured part are worse than useless; they do not imbibe coagulated blood, while they add to the local injury. The feelings of the patient must sometimes guide us in the choice of local applications; when the extravasation is considerable, there may be pain, which can be relieved only by warm opiate lotions. Ecchymosis of the conjunctiva is very persistent, but need not excite the slightest anxiety unless combined with much tumefaction.

* The process of absorption, suspended, or more slowly performed, during the continuance of inflammation, resumes its wonted activity after this has subsided, and hence the apparent efficacy of various measures in removing the discoloration.—Ed.

BLOWS.

A blow on the eye from a grain of shot or a cork may considerably injure or annihilate vision, scarcely leaving a trace of mechanical violence, and the effect is then attributed to concussion of the retina.

Beer records an instance of a man having lost his sight from a person who, being behind him, suddenly covered his eyes with his hands, using at the same time some pressure; yet severe injuries may occur without affecting the nervous apparatus.

Loss of the peculiar property of the retina from a blow, is rarely unaccompanied with symptoms of degeneration of other parts of the eye; the pupil is dilated, and sometimes to such an extent as to give rise to the supposition that the iris has been totally destroyed. If this excessive dilatation does not ensue, the iris is likely to become tremulous, shaking with every movement of the eye, while the vitreous body will probably become dissolved, a condition indicated by the globe feeling soft and flabby. This may be the beginning of a change which ends in atrophy of the entire eye. But all these effects may result from a blow on the brow, without the eyeball having been touched. I have known a stroke on the temple from a stick, which, although not followed by a bruise, has nearly destroyed vision in the contiguous eye. When an engineer was striking a bar of iron with a sledgehammer, a piece of the metal broke off, was projected against his face, and fractured his nasal bones. I saw the man three days after the accident; the conjunctiva of the left eye was slightly ecchymosed, and the pupil dilated to a degree that left merely a narrow band of iris, whose color was natural; but vision was extinct.

The treatment in these cases is to keep the patient quiet for a few days; to enjoin rather low diet, and abstinence from alcoholic drinks; and to apply cold by means of thin rag dipped in cold water, and frequently changed. Should these means fail, recourse must be had to opiates, at first locally, and afterwards, if necessary, be exhibited internally. The watery extract of

opium, reduced to a proper consistence by the addition of water, and rubbed on the brow or temple, or applied as a plaster with an adhesive margin, forms an excellent topical application.

Pain is a necessary consequence of a severe blow on the eye; but does not alone indicate active treatment. So long as swelling of the lids, especially of the upper one, and flashes of light, with scalding tears, accompanied by headache, disturbance of the digestive organs, and feverishness or restlessness, and want of sleep, do not supervene, a cold lotion will suffice, and frequently prevent the development of urgent symptoms. I consider that the application of cold is a remedy that has not been fully appreciated; and I shall frequently have occasion to recommend it, especially in describing the after-treatment of operations.

In the case of the engineer previously mentioned, for whom cold lotions alone were used, improvement of sight was evident in a week; in four months he could see bodies held laterally, and some months later he could read large type. The pupil was less dilated, though it never recovered its natural size, and the iris remained slightly tremulous. But this was an extreme case, the lesser injuries are those that are more frequently met with. It requires judgment not to be deceived by a patient's exaggerated expressions, by mere conjunctival redness, ecchymosis, or chemosis; for, so long as the cornea keeps clear, and the iris is bright, all is well. Whether the change of color, not uncommon in the iris after a severe blow on the eye, ever ensues without evidence of inflammation, I am not prepared to state positively. I am disposed, however, to think it does not: and certainly it does not occur after operations.

As an example of a severe case, I may mention that of a young woman, who was struck in the eye, but not violently, by the corner of a baker's tray; very active inflammation soon followed, for which no particular treatment was adopted. Some months afterwards, when I was applied to, I found the iris discolored, and partly adherent to an opaque capsule. The lens had been entirely or nearly absorbed, the globe was soft, and not the slightest perception of light remained. Another circumstance

connected with the case is worth noting. A band of lymph united the capsule to the cornea, to admit of which, the capsule must have been at some time in contact with the cornea, and the connecting medium must have been gradually elongated as the lens was absorbed. Here a particular course was required, perhaps from the first, and I therefore pass on to consider the treatment necessary in such cases.

Dr. Jacob has published a valuable volume on inflammation of the eyeball,—a reprint from papers in the Dublin medical press, which contains more original matter and sound practical precepts than any other work that I have read. He uses the term inflammation of the eyeball in a very wide sense, that in which I shall use it, and advances an opinion to which I fully subscribe, that a discolored iris and a red sclerotica, are not evidences of inflammation of the iris alone, but of the whole eyeball. He further asserts what I consider to be true, that the attempt to describe inflammation as isolated or confined to particular structures, has not by any means proved serviceable; for we find in practice that these distinctions vanish, and we discover only a progressive inflammation of the whole organ, though it may have been in the commencement more conspicuous in some particular tissue. I believe that the only exception to this rule will be found in acute idiopathic inflammation of the retina, a disease of very rare occurrence. Supplied by the *arteria centralis retinae*, this membrane was long supposed to have no direct vascular connexion with other portions of the eyeball, until within the last seven years, when Professor Van Der Kolk succeeded in demonstrating a series of very minute vessels proceeding from the *corona ciliaris*, and connecting the retina and hyaloid membrane with the other tissues. This anatomical fact explains how retinitis, arising in the back part of the eye, has no tendency to involve the rest of the organ; whereas, when it occurs in the vicinity of the *corona ciliaris*—as almost always happens in traumatic cases, the inflammation becomes general. This point has been fully discussed and explained by my colleague, Dr. Taylor, in a paper in the

"Medical Times and Gazette" for June 5th, 1852. Heretofore, inflammation of the eyeball has been considered to be that stage of disease which is followed by suppuration.

General bloodletting is frequently necessary, and is particularly applicable at the commencement of inflammation. It is especially indicated when there is rapidly-declining vision, together with congestion or effusion in the posterior part of the eye, which is rendered probable by the bulging of the lens and iris towards the cornea, even though there should not be much external evidence of inflammation. It must be borne in mind that extravasation of blood will throw the lens forward. Local bleeding will frequently be sufficient, and is often the only remedy to which the pain, that may be very distressing, will yield. Still no precise rule can be given as to whether the bleeding should be general or local: the practitioner must be guided by the individual peculiarities of each case. The necessity of moderation in the abstraction of blood cannot be too energetically urged. The quantity should be regulated by the local symptoms, and the age and general condition of the patient; otherwise, destructive, rather than conservative effects may result. Disease cannot be bled out of the eye, as some surgeons seem to think. At the same time when bleeding is indicated, a decided effect must be obtained. It is seldom that a few leeches will suffice, except during the earlier periods of life; nevertheless, we find in routine practice that few inflamed eyes escape the application of two or three leeches; in the robust, such practice is insignificant; while in the debilitated it is worse than unnecessary.

Dr. Jacob well observes, that the destructive consequences of inflammation are not proportioned to the acuteness of the attack, whether from accident or otherwise, but are frequently seen in a very remarkable degree, where the inflammatory action is languid—a fact not less common in ophthalmic, than in general surgery, although, unfortunately, not generally recognised.

Another excellent remark resulting from Dr. Jacob's experience, is, that patients are generally not seen until after the ves-

sels have become permanently enlarged, and the inflammatory condition has been firmly established; then it is that the propriety of bleeding comes to be questionable. Again, the redness or increased vascularity may be but a consequence of inflammatory action, which has ceased or been subdued. As a rule, Dr. Jacob says that bleeding should only be resorted to at the very commencement of an attack, when a hope may be entertained that by weakening the heart's action, and reducing the size of the capillaries, the disorganizing process of inflammation may be prevented; and most assuredly to delay it until that stage arrives in which there is diminution in quantity, or deterioration in quality of the circulating fluid, might rather retard than promote the cure. This trustworthy observer, however, does not hesitate, in the progress of a case, to repeat the bleeding if acute symptoms should return; a practice I would strongly recommend to the practitioner.

There is an excellent paper, that bears forcibly on this subject, published in the 23d volume of the "Medico-Chirurgical Transactions," by my lamented friend the late Mr. Dalrymple, on the rapid organization of lymph in cachexia; the author commences by stating that it is of high importance in a physiological, as well as a practical point of view, to ascertain whether effusion of the organizable materials of the blood become vitalized by the production of new vessels more readily and sooner in cachexia, than in robust states of the constitution.

The conclusion he arrived at is, that in those who are enfeebled and depressed, effusions from the capillary vessels are more speedily and completely organized, with vessels capable of being permeated by minute injections, than in the more vigorous and plethoric, in whom inflammation is more acute in the outset, and passes through more speedy and determined stages. The greater tendency to the effusion and organization of fibrine on the surface of the iris in syphilitic cases, than in those of idiopathic iritis, is noticed; and the remark is made, that there will be no difficulty in admitting that the specific cases occur at least in London, in far greater proportion, in enfeebled constitutions,

and in those debilitated by excess and irregular habits, or the mal-administration of mercury for the primary disease.

A well-marked case of syphilitic iritis, peculiarly valuable and well worthy of perusal, is given in support of this view, and further evidence is adduced of the rapid organization of lymph in other instances of disease where life has been nearly extinct.

But loss of blood may not control the disease ; and opacity or suppuration of the cornea, or the effusion of pus into the anterior chamber, or discoloration of the iris and contraction of the pupil with unnatural vascularity of the sclerotica, may declare still more plainly that the entire eyeball is implicated. But suppose some of these symptoms of advanced inflammation have set in without bloodletting having been admissible ; or that the patient is seen for the first time in this state. Mercury, which is unfortunately as much abused in ophthalmic as in other affections, but which possesses powerful influence in checking inflammation of the eyeball, and in removing some of its products, must then be resorted to. It must not be lauded as a specific ; for disease may continue to increase, even although the system be fully under its influence. Thus an eye which has heretofore been healthy, may, while a patient is under the influence of mercury, become diseased. This I have frequently witnessed in syphilitic disorders ; among the instances, a case occurred in one of Mr. Lawrence's syphilitic wards at St. Bartholomew's, while I was dresser. The woman was salivated for syphilis, and iritis supervened ; cupping and leeching were tried, but in vain, and the eye was lost. Discrimination and judgment are as much called for in giving mercury as in bloodletting ; and on this point I must again refer to Dr. Jacob's experience. After showing the impropriety of treating all injuries of the eye by antiphlogistics ; pointing out that the destructive processes of inflammation are in many cases disproportionate to the injury sustained ; and that a scratch or puncture of the cornea often causes destruction of the whole eye, while an extensive wound, with laceration and contusion, will sometimes be repaired without extension of the inflammation to the rest of the eye, he lays down the important rule, that traumatic inflammation so far from being invariably of the same type, is espe-

cially liable to be modified by the existing diathesis, and that it will be intense and rapid, or languid and chronic, according to the condition of the patient. He farther asserts, that it will assume the rheumatic, scrofulous, or even syphilitic character in patients who are suffering from those affections. These are important principles, and should form the key to our treatment.

Here, then, a wide field is open for the exercise of practical skill. In some cases of great urgency, with strong constitutional powers, it is allowable and even requisite, to give mercury till its effect on the mouth tells that the drug is exercising its specific action; in others it must be but sparingly administered, and its influence assisted by the simultaneous support of the system by tonics: or it may be necessary to combine it with other medicines; or altogether to suspend its exhibition. Dr. Jacob shows that destructive ulceration, or abscess of the cornea from slight injury, is uniformly accompanied by derangement of the digestive, assimilating, and nutritive functions, almost uniformly taking place in aged persons of feeble frame, or in an unhealthy state of body induced by excesses in diet, and in younger persons who are imperfectly nourished. In these cases he directs attention, first, to the regulation of the functions of the body; nevertheless, he does not hesitate to bleed should plethora exist, nor to administer mercury, should the inflammation not speedily yield. Traumatic inflammation of the cornea, especially in the poor, should be carefully attended to, and no indication of constitutional impairment pass unheeded. The state of the skin is too often overlooked; but as this work is intended for those who are supposed to have already acquired the principles of their profession, it is unnecessary to enlarge on the several modes of general treatment to which I have alluded.

In my own practice, I am in the habit of using mercury in very small quantities, and almost always prescribe the *hydrargyrum cum cretâ* in doses of two, two and a half, or three grains, combining it with hyoseyamus or conium as the bowels may require, and repeating it according to the urgency of the case; but never more frequently than four times in the twenty-four hours, and

rarely so often. While this form is equal in potency to any other preparation of mercury, it is more under control, and it will be comparatively seldom that active salivation from its use may not be checked,—no small advantage in debilitated constitutions. I regard salivation as the poisonous influence of mercury; and I believe that the highest curative effect is to be obtained short of that state. At the same time, if a disease does not yield, and its violence be not lessening under its use, I should give the mercury till the mouth was in some degree affected, to insure that the system was fully under its influence.

The potency and the manageableness of this form of the drug cannot be imagined by those who have not used it; and to those who are disposed to give it a trial, I would recommend that they should select cases of syphilitic iritis to commence with; for then its effects can be readily watched, and the results appreciated; and in them, moreover, the fact may be learned that the disease will readily cease without the mouth being made sore.

Within a very recent period I was requested to meet, in a case of syphilitic iritis, a well-known surgeon, who uses a great deal of mercury in his large syphilitic practice; the disease was far advanced, and the pupil contracted and irregular, the iris discolored, the cornea hazy, in fact all the symptoms of inflammation of the eyeball were present, and vision nearly extinct. The patient was sixty years of age, fat and feeble. I ordered him the chalk and mercury in two-grain doses, three times a day, which this surgeon considered to be worse than useless. Five days after this, I saw the patient with Mr. Austin, of Rotherhithe, the regular family surgeon, who had been present at the consultation, and we found that the mouth was sore, and the iritis yielding. The quantity of mercury was now lessened, and its administration so regulated that salivation was kept under, and when I again saw him, at the end of a fortnight, the iris had quite recovered, the pupil acted well and dilated fully, a little redness of the sclerotica and of the conjunctiva alone remaining, and vision was nearly perfect. Here no blood was lost; indeed it was necessary to support the patient with good diet. I am

certain that relapses are very much less frequent under this cautious use of the mineral, than when it is lavishly administered.

The artificial dilatation of the pupil should be effected whenever there is a tendency of the iris to adhere to the capsule of the lens, for the pupillary margin is very close to the capsule, indeed it is almost certain, that in the earlier years of life they are in actual contact, and at no healthy period can there be any but the slightest space intervening between them; in inflammation of the eyeball, the iris and the capsule of the lens will adhere unless the pupillary edge is drawn outwards and towards the circumference of the lens, where the surfaces are necessarily separated. I rarely use the extract of belladonna around the lids, according to general custom, for it is a filthy application; the sulphate of atropia, in the proportion of two or three grains to an ounce of water, a drop or two applied three times a day, on the conjunctiva of the outer part of the lower lid, will produce all the effects of dilatation. The atropia may be also applied to the lids, in an ointment composed of a grain to a drachm of lard or of glycerine. It is cleaner, more manageable, and more readily renewed than the belladonna, which soon dries and becomes inert. With the use of this drug, when disease is disappearing, the pupil will often appear irregular; the result of some parts of the iris being more advanced to a healthy state than the others. The parts, however, which remain inactive are generally supposed to be adherent, and their yielding to the atropia is regarded as an indication of the adhesion giving way. But I believe the rupture of adhesions to be of rare occurrence, and rather attribute its supposed frequency to the causes now assigned.

The extent of dilatation of the pupil will generally be in proportion to the integrity of the iris; and if its texture be much infiltrated, dilatation cannot be obtained. The use, however, of the atropia should not be regulated by the appearance of the iris; for it may be influential when not expected, and in all instances of inflamed iris it should be employed. While I write, I have a patient in whose pupil no inconsiderable dilatation is produced,

although there are two nodules of lymph on the iris, one above the pupil, the other below, and both near the margin.

The evacuation of the aqueous humor has been proposed in inflammation of the eyeball; it was practised a long while ago by Mr. Wardrop, and the manner in which he spoke of its advantages and the force of his authority, caused it to be for a time extensively adopted in most inflammatory affections of the eye; and reported cases of its utility in the purulent ophthalmia of infants, in gonorrhœal ophthalmia, aquo-capsulitis, inflammation of the cornea, ulceration of the cornea, abscess in the anterior chamber, iritis, and general inflammation of the eyeball, are very numerous. The theory is to lessen or remove tension of the globe by the withdrawal of the humor, so as to admit of reparative action taking place; the same good effects being produced, whether tension of the eyeball be lessened by diminution in the size and number of blood-vessels, or by the discharge of the aqueous humor. With reference to any danger arising from the diseased state of the eye, Mr. Wardrop remarks, that in those cases where the practice of evacuating the humor is judiciously had recourse to, although the operation may create some temporary irritation, yet its good effects will become immediately perceptible, and in most cases will be permanent; that considerable improvement in vision, particularly in those cases where there is a cloudiness in the anterior chamber, will take place; that the sense of fulness of the eyeball, and pain in the eye and in the head, will cease; that in some cases a very remarkable change in the size of the inflamed vessels will occur; and that where the discharge of the aqueous humor has been found beneficial, it is not even necessary to suppose that its natural quantity is increased. I must not omit to state that Mr. Wardrop does not recommend it as a sole remedy in every case of ophthalmia, but as a powerful auxiliary in some, and in others, as a sure and perhaps the only means of preventing the total destruction of the vision. The paper entitled "the effects of evacuating the aqueous humor in inflammation of the eyes, and in some diseases

of the cornea," to which I allude, is in the fourth volume of the "Medico-Chirurgical Transactions."

I believe that this evacuation is seldom practised in the present day, and that for many years it has been discontinued. Mr. Lawrence writes forcibly against it, prefacing his objections with stating that he has tried it in some instances, but with so little benefit that he has not been induced to persist in the practice; and that he has been the less inclined to do so in severe inflammations, because the ordinary antiphlogistic treatment enables us to control them. Dr. Jacob thinks that it is a measure that should not be resorted to; and, although I do not deny its utility in certain instances, I should be loth to practise it when the cornea is much inflamed, or contains pus between its layers, lest I should aggravate the mischief. Mr. Tyrrell was strongly in its favor, in some cases, and in connexion with other local and general means. He practised it in inflammation of the aqueous membrane, not only when the size of the chambers was manifestly augmented, but when the globe felt very tense and tender, and there was much ophthalmia or sclerotitis; and he testified to the fact that he had several times known the operation not only produce immediate relief of suffering, but to be followed by a rapid subsidence of disease. The result of his observations induced him to advise that all the humor should not be allowed to escape, in which case the iris is pressed against the cornea, and severe suffering continues till these parts are again separated; and when a repetition of the process is called for, from a recurrence of symptoms, he considered it proper to choose a fresh place in the cornea, for the introduction of the instrument.

Should chloroform not be used, considerable difficulty will be found in exposing and steadying the globe. When the patient is insensible, the operation is very simple. The humor should be let out with the smallest possible puncture, with a needle, one rather broader than the straight solution needle, or with the point of a cataract or iris knife. The operator stands behind the patient, who may be sitting or lying down, and proceeds as if about to operate for cataract, by raising the lid with the forefinger, fixing the globe with the point of that, and of the middle

finger, while an assistant depresses the lower lid. The globe thus steadied, the point of the instrument is introduced close to the edge of the cornea, and when fairly through the cornea, turned on its axis to make the wound gape, when the aqueous humor will flow out.

With precision in operating, the iris is not in danger of being wounded; but with the least carelessness in not holding the instrument parallel to it, or acting too quickly, such an accident may occur. Unless the point of the instrument is carried imprudently far, the capsule of the lens is out of the reach of injury.

Pus may accumulate in the anterior chamber from abscess of the iris, from ulceration at the back of the cornea, or from inflammation of the lining membrane. It would be imprudent to attempt its evacuation; for it is always absorbed if inflammation is arrested; and opening the cornea in that stage of inflammation would, I fear, be followed by destruction of the eye. I find in my case-book an example of hypopium, headed "rapid effusion and absorption of the pus." The anterior chamber was a third filled, and in ninety-six hours every particle was removed—purgation and counter-irritation behind the ears being the remedies. The presence of the pus does not seem to be injurious, when it occupies but a part of the chamber. I have never seen it rise to the level of the pupil without general suppuration of the globe. I have, however, been told by a surgeon in large ophthalmic practice, that he has seen the whole of the iris hidden by it, but that ultimately it was removed by absorption, and tolerable sight regained.

Opening the texture of the cornea to evacuate matter there collected has been much censured. I have never practised it nor seen it done. Mr. Tyrrell approved of it when the abscess was extensive, and the pain severe with a distressing sensation of tension; but he recommended it in these cases rather with the view of relieving suffering than of hastening the cure, for he says that the matter is rarely so fluid as to escape by a small aperture, and the larger portion of it appears to be absorbed. The general

opinion is, that the pus is infiltrated or diffused in the corneal tissues; but Dr. Jacob says that more frequently it is lodged in a distinct cavity, and recommends that if the accumulation be large, it should be opened, cautioning the operator to be prepared for prolapsus of the iris, and reminding him that such an occurrence should not be attributed to this act, as the operation, if done at the right time, often prevents the mischief; and when it does not prevent prolapse, renders it less injurious. An iris knife would be the best instrument for performing the operation.

The unfortunate occurrence of suppuration of the contents of the globe can scarcely be mistaken. The symptoms are, great constitutional disturbance, with fever, and, perhaps, rigors, redness, and sometimes enormous swelling of the lids, especially the upper, effusion of pus into the texture of the cornea, or into the chambers of the eye, chemosis, and above all, agonizing pain in the eye, with throbbing in the orbit and in the temple. This suffering lasts till the eye perishes by the giving way of the cornea and the escape of pus, and often of the disorganized lens and some of the altered vitreous humor, when immediate relief follows. But the period of the patient's suffering should always be shortened by a free opening in the cornea, and timely exit given to the pus. This advanced stage of inflammation of the globe is generally treated by authors as a distinct affection, in consequence of the great subdivision of ophthalmic inflammations, and the erroneous supposition, that one or other of the ocular structures becomes inflamed independently of the rest. I have never seen an eye saved after the earliest evidence of suppuration having commenced; indeed, when inflammation has arrived at that height in which suppuration quickly follows, the organ is already destroyed; and when it has actually suppurated, it is positively cruel to bleed and purge a patient nearly to death, or to involve him in all the horrors of a salivation, where there is not any chance of benefit.

The only advantage to be obtained from local applications, is the assuagement of pain, and the only virtue which they possess, consists in the warmth or cold which they impart. I am rather

sceptical about the virtue of the so-called medicated fomentations, thinking that they cannot exert more influence on the surface of the body than plain water, rather imputing their good effects merely to moisture and to warmth. But few persons would be satisfied unless poppy-heads or something else were added to a fomentation; and a lotion of cold water alone would be thought too common and inert. If suppuration has ensued, a light poultice, kept together by a bit of muslin, seems most grateful. All medicaments and opiates intended to act endermically should be used with the lids closed, and the degree of temperature must be left to the patient's feelings. But more certain relief in deep-seated inflammation is to be obtained from the watery extract of opium on the brow, after the manner already described.

The advantage of counter-irritation behind the ears or on the temple, has been questioned by some practical men; and the supposed process of metastasis, which it is employed to imitate, is now boldly denied, and I think, successfully controverted. On this point I would especially refer to Dr. James Bird's "Practical Treatise on the Pathology and Treatment of Rheumatism, Neuralgia, and Cognate Diseases, usually called Syphiloid." I have not been able to satisfy myself of the efficacy of blisters in ophthalmic diseases; and although I may use them to give a patient every chance of benefit, I restrict their employment to cases not complicated with fever and constitutional suffering. It is the fashion, at present, in this metropolis, to prescribe blisters not larger than half an inch in diameter; and these are said to be equally potent with the largest.*

Blows on the globe of the eye may cause rupture of its coats, or the separation or dislocation of some of its internal parts. Bursting of the globe is no uncommon occurrence; and the anterior portion of the sclerotica, or the cornea may be the part that

* Our own experience coincides with that of the author. Blisters, though sometimes useful, are rarely productive of all the benefit that is anticipated from them; and even under the circumstances to which their employment is very properly restricted in the text, are often the cause of much unnecessary suffering.—Ed.

yields. So much damage is produced either by concussion, the mutilation of important parts, or the escape of a large part of the vitreous humor, that the organ is always destroyed, and the only indication then is to alleviate pain. A wound of the sclerótica, even when unattended with violence, is very likely to be fatal to vision; and a large one is the more dangerous from the likely complication of prolapse of the choroid and retina, and probably also of the vitreous humor. Treatment is unavailing.

Effusion of blood in the chambers of the eye is not unfrequent after a blow, and must always be due to the mechanical lesion of some part, although the breach may not be apparent. I have never adopted the practice which has been recommended by some surgeons, of evacuating the blood by opening the cornea, even when both chambers have seemed to be quite full of it; and I have never been disappointed in seeing it absorbed. A man, fifty-two years old, walking in a street on a Saturday night, was struck on his eye by a stone, and lost his sight; and on Sunday he was brought to me. The chambers of the eye were so discolored with blood that neither the iris nor pupil was visible. Cold lotion and a cathartic were ordered, and alcoholic drinks proscribed. On Tuesday evening the pupil was visible, the aqueous fluid still turbid, and a clot of blood was at the bottom of the anterior chamber. Sight was returning. On Thursday, at noon, the chambers were clear, and a light-colored clot was noticed, by Dr. Taylor, lying across the capsule of the lens. The iris was thrown forward nearly in contact with the cornea, a state which was attributed to effusion of blood posteriorly. Just a fortnight later, the eye had completely recovered the injury, the anterior chamber was restored, and vision had returned.

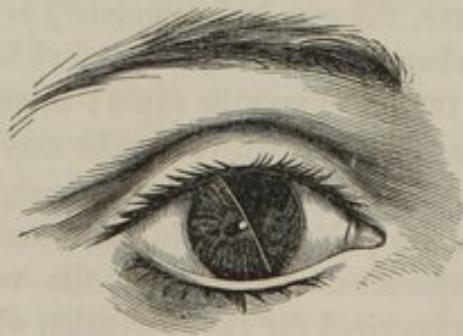The removal of the blood may be rapid; in twenty-four hours a small quantity has disappeared, yet weeks may be required for the accomplishment of the same process, if coagulation ensues. Thus Mr. Bowman has pointed out in his lectures on the parts concerned in the operations on the eye, the very marked difference in the time required for the absorption when the blood is effused into chambers occupied by serum, the consequence of pre-

existing disease. He watched a clot during six months under these circumstances, before it lost its shape or characteristic hue, and it was undergoing very slow absorption at the end of twelve months. Opportunities of noticing this interesting phenomenon are often afforded when an artificial pupil is made, or when the iris is wounded after any operation.

The iris is apt to suffer from blows on the eye, to be torn, and even more or less separated from the ciliary attachment. About four years ago, Mr. Dixon related to the Royal Medico-Chirurgical Society an instance of the crystalline lens and the iris having been forced through the ruptured coats of the eye. The point of exit seemed to have been just behind the upper edge of the cornea, where there was a mark about half an inch long, like a cicatrix. The catoptrical test showed the lens to be wanting. The retina could be distinctly seen. Vision was greatly impaired.

I have several times witnessed partial detachment, so that a second pupil was formed, and I have seen a few instances of splitting of the iris, from the pupil to the circumference, with partial detachment of the flaps. I am indebted to my friend Mr. Browne, of the Belfast Ophthalmic Institution, for the following remarkable illustration. A sharp chip of metal wounded the cornea and the iris, and produced extravasation of blood in the chambers of the eye, and when absorption had cleared the aqueous fluid, the eye exhibited nearly half the muscular fibres of the iris torn away from the uvea, and rolled up, as this sketch shows.

Fig. 9.



These peculiar effects of violence, unattended as they may be

with destruction of sight, are very remarkable. They remind us of other instances of most delicate results, produced by accidents, and not admitting of imitation by art. It would be useless to multiply examples; enough has been cited to give the general characters of these accidents, and which, unfortunately, do not come within the scope of treatment. The edges of a rent will retract, and a partially detached iris will remain separated.

The displacement of the crystalline lens is sometimes another effect both of blows on the eye and on the head. Dislocation forwards is that most usual; and the lens may be either accompanied by the capsule, or not. If the lens is thrown against the back of the iris, and does not become opaque, the nature of the accident may be overlooked, especially if the dislocation has occurred, as it may, a day or two, or even longer, after the blow. This partial displacement is generally most painful. The pupil may be occupied by the lens, but rarely for any length of time, since it either falls behind the iris, or what is more likely, into the anterior chamber. This accident must be regarded as of the same kind as the presence of a foreign body; it differs from it only in degree, and it is subject to the same general rules of treatment, and it matters not whether the lens retains its transparency.

In a subject more than forty years of age, when the lens has increased in density, and its removal by quick absorption cannot occur, I should perform the operation of extraction or depression, according to the rules given for this special occurrence, in the Chapter on Cataract.* Between the age of puberty and

* This is a question which should not be determined by years alone. If the capsule were ruptured, and if, moreover, the dislocated lens were producing no irritation, there would be no necessity for interference at any age. The density of the crystalline cannot always be certainly known, and instances of its ready absorption at a much more advanced period of life than that mentioned by the author are of daily occurrence. Neither would it be safe, where irritation exists, to delay interference until opacity had revealed the presence of the capsule; for if this investment be entire, the lens may preserve its transparency slightly impaired for an indefinite period.—ED.

thirty, I should not interfere if the lens were in the anterior chamber without its capsule, and lying harmless; but where accompanied with irritation and with pain, I should extract or recline it, according to circumstances. Under puberty, I should trust entirely to nature. I saw a case of dislocation of the lens into the anterior chamber of a child three months old, from a fall. Absorption was accomplished without the least disturbance in the eye.

A dislocated lens accompanied by an unbroken capsule, should be removed from the chambers of the eye at once—that is, as soon as there is proof by opacity that the capsule is present, for then there is every reason to doubt whether absorption of the lens will occur; and even if it were to do so before the eye has been destroyed, the capsule might prove a source of much trouble, and perhaps the seat of calcareous deposit. Mr. Lawrence mentions a patient who occasionally visited the London Ophthalmic Infirmary, with the lens surrounded by its capsule in the anterior chamber, where it had been for twenty-eight years; the general state of the eye is not given.

If the lens should be driven into the vitreous humor, and becoming opaque, remain in the axis of vision, reclinacion is of course the remedy.

The lens may be driven completely through the sclerotica, and lie under the conjunctiva, the rupture being generally at the upper part near the cornea. With the rupture of the anterior part of the eye, the iris is pretty sure to be extensively damaged, and blood poured out into the chambers; yet notwithstanding this amount of injury, vision may not be lost. Removal of the lens is the proper course; the simple process of raising the conjunctiva and snipping it off is readily effected. It has been suggested by Mr. France in the seventh volume of the Guy's Hospital Reports, not to remove the lens till a fortnight after the accident, so that an opportunity may be afforded for the healing of the sclerotica, and a simple rupture, as he expresses it, may not be converted into a compound one, and the chances of recovery perhaps materially diminished. There has

been no loss of the vitreous humor in those instances of which I have any personal knowledge. Spontaneous dislocation of the lens, consequent on disease of the eye, will be discussed in the Chapter on Cataract.

The following remarkable case of traumatic lesion of the globe of the eye, related by Dr. Rivand Landreau, of Lyons, in the "*Gazette Médicale de Lyon*," for 14th of Feb. 1849, is also in the first volume of the "*London Journal of Medicine*," p. 586, from which I take it:—"On the 14th August, 1847, Madame Peyronnier, a portress, in endeavoring to separate two men who were fighting, received from one of them a blow with the fist, in the left eye. The immediate consequence was abolition of vision, and the production of swelling at the internal angle of the eye; this was followed by ecchymosis of the membranes of the globe of the eye and the palpebral tissues. Severe pain was at the same time felt in the injured organ. Medical assistance having been immediately procured, leeches were applied around the orbit, and cold lotions to the eye, and an opiate mixture was ordered. Some days after, a purgative was administered, and a blister applied behind the right ear. These means having produced no relief, the patient consulted M. Landreau on the 21st of the month. On examination he found at the internal angle of the eye, close to the junction of the cornea with the sclerotica, and very near the centre of the palpebral opening, an ovoid tumor of the size of a round pea, with a reddish base, and a slightly flattened summit, presenting a well-marked yellowish tint. Entirely surrounding the base of the tumor was a large violet-colored ecchymosis embracing the whole of the larger angle. In the anterior chamber, at its inner and lower part, were some drops of florid blood. The tomentum covering the anterior surface of the iris was dull and grayish, and towards the lower part, and a little internal to this membrane, there was a partial laceration of the iris of about the size of a millimetre (about 1-25th of an inch), having the form of a reversed V. The pupil was dilated to about double its usual dimensions, black and perfectly immovable; vision was destroyed from amaurosis. The

transparent cornea was healthy, and the deeper humors of the eye appeared to be uninjured. The sclerotic and conjunctiva, at the smaller angle, showed no injection; the eyelids had the yellowish tint which usually follows bruises. The patient complained of violent pains in the injured organ, and in the whole of the corresponding side of the head. The tumor, before described, felt hard and resisting, but gave sensation of slight fluctuation at the summit, which, with its yellowish tint, indicated the presence of pus. M. Landreau, however, hesitated to open it, being uncertain as to its nature; and, on attentively examining the globe of the eye, he thought he perceived the absence of the crystalline lens, from an unusual depth of the posterior chamber, together with an oscillatory movement of the iris. Here he imagined that the blow on the eye might have produced rupture of some of the fibres of the sclerotica, and thereby occasioned an aperture sufficiently large to allow of the escape of the crystalline lens. It was probably, then, this latter body which produced the tumor under the layer of the conjunctiva. Acting on this hypothesis, he made a small opening over the tumor with a cataract knife; a drop of pus escaped, and he drew out, at the end of his instrument, a body which he recognised as the crystalline lens, in an entire state. The tumor immediately disappeared, and there only remained some puffiness of the conjunctiva. The eye was ordered to be kept wet with cold lotions, and a purgative to be taken the next day. The patient was completely free from pain at the end of forty-eight hours, and there was little or no consecutive inflammation. The ecchymosis followed the usual course; and, in about eight days, all traces of it, or of inflammation, had disappeared.

“The permanent effects of the injury have been perfect immovability of the pupil and mydriasis, both resulting from the injury of the iris, which has resisted all means tried to remedy it. The laceration still exists, but is somewhat smaller. The retina has, under the influence of stimulant remedies, so far recovered its power as to enable the patient to see with the aid of cataract glasses.

“M. Landreau explained the phenomena of this case by supposing that the blow on the eye was perpendicular, and in a direction from the temple towards the nose. Its immediate effect was compression of the globe, and the crushing of the humors from without inwards. The sclerotica at the inner angle was forcibly compressed against the bony floor of the orbit, and its fibres were thereby distended and torn. The crystalline lens, violently detached from its suspensory ligaments, was forced through the laceration in the sclerotica, and by the motion and return of the humors from their state of compression, was lodged under the conjunctiva membrane. The violence of the blow, also, explains in a very natural manner, the rupture of the ciliary attachments of the lower part of the iris, and the partial laceration of that membrane. The effusion of blood in the anterior chamber, no doubt arose from the rupture of some of the vessels of the iris when it was lacerated. It is also evident that the instantaneous paralysis of the retina and the mydriasis, were effects of the compression and of the blow. There are two remarkable circumstances in this case: first, the absence of acute ophthalmitis, either external or internal; and secondly, the complete restoration of the function of the retina, after such a sudden and complete amaurosis.”

WOUNDS.

Wounds of the cornea, accompanied by prolapse of the iris, are by far more common than any of the injuries just treated of, scarcely a month passing without one or more presenting themselves among the patients at the Ophthalmic Hospital. Children are very liable to them from being allowed to play with sharp-pointed instruments. But the time for any benefit has generally passed before the surgeon is consulted. The cornea is rarely ever accidentally divided without a part of the iris escaping; indeed it is forced out and wedged in the aperture, and hence the general impossibility of spontaneous retraction, and the almost equal impossibility of forcing it back through the same aperture

without unjustifiable and destructive violence. In the great majority of cases, the injury causes the lens and capsule to lose their transparency, and the opacity may commence in a few hours, or not be manifested for days, weeks, or even months.

The effect on the pupil is always marked. I have seen that aperture quite lost, from the greater part of the iris prolapsing at the margin of the cornea, through a wound inflicted by a bit of glass, and carrying with it the pupillary edge, the remainder of the iris being tightly stretched across the chambers; yet it is seldom with a lateral wound of the cornea that any part of the pupil is involved.

With a central corneal wound a very slight prolapse may destroy the pupil; and the worst class of cases is where there is a considerable rent of the cornea, as Fig. 10, where the anterior chamber is destroyed, and the iris lies in contact with the cornea.

Although attempts at reduction are not always so fruitless as some surgeons state, yet success must be regarded as a rare exception; and it is only with slight prolapse that it can ever be attained. It is the tightness with which the iris is held in the wound that forms the difficulty. In some of the operations for artificial pupil, in which a portion of the iris is purposely prolapsed, temporary failure may ensue from the spontaneous return of the part; and this is so likely to happen that the judicious surgeon guards against it by cutting off the portion of iris that has been withdrawn, and the only difference between the accidental, and the surgical production of the prolapse, is in the relative proportions between the aperture and the mass of iris embraced.

In no slight case of prolapse, therefore, that is seen a few days after the accident, should one abstain from attempts at reduction; and the readiest and therefore first method, should be to rub the cornea gently through the medium of the upper lid for a few seconds, to push back the iris, and then suddenly to expose the eye to a bright light, and to repeat this several times in succession, taking care that the sound eye is shaded while the fric-

tion is employed, and simultaneously exposed to the light with the injured one. I have never myself thus succeeded; but the plan is practical and founded, no doubt, on the fact that an immediate prolapse, after the operation of extraction of a cataract, may be so reduced.*

Fig. 10.



With belladonna, or its neutral salt, the sulphate of atropia, the object may be attained, and I do not restrict its use to prolapse of the pupillary edge, as has been recommended, but employ it also when the circumference of the iris has been forced out; for dilatation of the pupil cannot be produced without traction being exerted on that part of the iris which is strangulated, be the hernia where it may, and with the greatest attainable degree of artificial dilatation, the edge of the pupil is much within the circumference of the cornea. I repeat what I said on the use of atropine in general, that its greatest influence upon the pupil is to be obtained by a drop of a strong solution applied to the con-

* The prolapsus is rarely reduced in this manner. If the iris, distended by the aqueous humor, protrude in the form of a bag, the tension of the membrane may be temporarily lessened by puncture with a cataract needle, and greater opportunity thus afforded of regaining its normal position. Should this, however, be ineffectual, and all reasonable attempts at replacement fail, the sensibility of the part may be lessened, and cicatrization promoted, by touching it every second or third day with a pencil of the nitrate of silver. When the prolapsus is considerable, it will be better to excise the protruding portion rather than allow it to remain a source of constant irritation. Appropriate measures should be adopted to moderate the resulting inflammation; both eyes should be closed, and the injured one covered by a compress wetted with cold water.—Ed.

junctiva. I saw a young gentleman in less than a quarter of an hour after he had wounded the outer part of one of his corneæ with a scalpel; a portion of the iris was just embraced by the lips of the wound, to which the pupil was pulled; it was irregular, but did not protrude. A drop or two of a solution of a grain of atropine to two drachms of water, was at once used in the manner directed, and in three quarters of an hour the pupil was well dilated and perfectly round, showing that the iris was quite extricated. The dilatation was kept up for several days, till the wound was healed, and a small scar on the cornea is the only trace of the accident. The friction of the globe with the sudden exposure to light, may be tried at the same time with atropine.

Prolapsus iridis from accident may, I believe, under favorable circumstances, be returned by a probe; it must be remembered that many manœuvres on the eye that could not formerly be done, except at a great risk, are, since the introduction of chloroform, easily and efficiently executed. I am not sure that it would always be impracticable to enlarge the corneal wound, although I fully admit that it would require the most delicate surgery, and that its performance is next to impossible, unless the patient be chloroformed. A distinguished member of society, and of considerable military fame, was fortunate enough to have a prolapsus of one of his irides, from accidental wound, returned by the surgeon of his household, with a common probe.

M. Desmarres, who has gone minutely into the subject of prolapsus iridis, proposes the reduction of hernia of the iris by simple cauterization with the nitrate of silver. His remarks seem to apply to escape of the iris from ulceration of the cornea only; but I suppose that the process is applicable also to prolapsus from a wound; he declares that he has had so many cases, I presume of success, that he has ceased to count them.

The following are the data on which the practice is founded.

"The prolapsed part is not disorganized for several days.

"The hernia, irritated by its contact with tears, and with the air, by the rubbing of the upper lid, and also by the borders of the ulcerated cornea in which it is imprisoned, tends for some

days to increase in volume, and the irritation and swelling prevent mortification, and stop the process of cicatrization. The continuation, or the increase, of the prolapse through the ulcer, is proved by these facts: that if the recent hernia be touched with an irritating body, it instantly triples in size, and in the progress of cicatrization the pupil diminishes by degrees, and often disappears.

"Adhesions are established between the cornea and the iris before the prolapsed part is disorganized. In the commencement, at least for some days, they are very weak, and may be entirely destroyed by augmenting the activity of the vascular supply to the parts, and by the development of fresh inflammation in some other part of the eye.

"The materials of repair are at first supplied by the cornea, which is unhealthy at the spot of ulceration.

"The materials are derived from the divided vessels of the ulcer, the bases of which vessels are at the circumference of the cornea.

"To irritate the parts in which the bases of the vessels ramify, is to augment the secretion of the borders of the ulcer; also, to produce around the hernia a liquid secretion, which will destroy some adhesions as yet not firm: and, also, give to the iris the means of slipping through the ulcer which is augmented by the secretion.

"By using belladonna prior to the production of the irritation, a power is obtained behind the cornea, acting in a direction from before backwards, and capable of reducing the hernia."

For the manner of operating, it is recommended that the lids be opened, the globe fixed, and a pencil of caustic applied energetically in three or four places, close to the cornea, in the direction of the hernia, taking care that the conjunctiva is not penetrated too deeply. Sometimes, instead of making these dots, a circular cauterization is made in the neighborhood of the hernia, or even, in some cases, where at first cauterization has failed, at intervals of two or three days, the same process is repeated a second, a third, or fourth time upon the cornea itself,

care being taken that the caustic does not extend to the iris; for, should this happen, the hernia will instantly augment. As soon as the cauterization is done, the patient is to bathe his eye with cold water, and continue the application of belladonna. If the hernia is not reduced after two or three days, the cauterization is to be renewed.

M. Desmarres adds, that the aspect of the cornea and the conjunctiva would rather create alarm to one who had never adopted the cauterization, large elevated whitish spots being developed, which, however, soon disappear without leaving a trace. He has applied the caustic as many as eight times before being successful. Usually, however, reduction of the hernia is effected after the first, second, or third cauterization. I regret that I cannot add my testimony in support of M. Desmarres' practice.

Wounds of the lids are, for the most part, detrimental from disarrangement attending the mal-approximation of their edges, and by which there may ensue trichiasis, entropium, ectropium, with or without displacement of the puncta lachrymalia. The most careful adaptation of the divided surfaces is then of the first importance, and unless the integuments are lacerated, sutures should be used; plaster alone should never be depended on, and is not often required except temporarily to support or to raise a part.

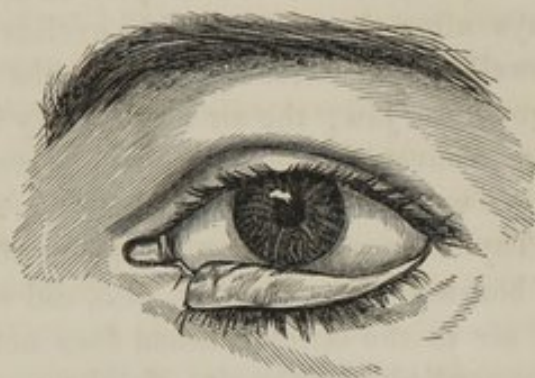Wounds of the integuments about the edge of the orbit, resulting from blows, partake of the character of incised wounds, and should be treated by suture; if primary union does not follow, the after result is none the worse for the attempt.

If the lid has been torn through, or a commissure divided, the edges should be trimmed and brought together. A cook fell on the brass arm that suspended a bottle-jack over the fire-place, and tore the lower lid away from the corner of the eye, without injuring the canaliculus, in the manner shown in the following sketch (Fig. 11).

She did not apply at the Ophthalmic Hospital till the rent had quite healed. I pared its edges and brought them together by suture, and keeping the lid rather pulled up by semicircular strips of plaster passed from the root of the nose to the temple

for eight days accomplished perfect restoration. When sutures are contra-indicated, water-dressing must be used, and the process of cicatrization is materially assisted where there has been any

Fig. 11.



loss of substance, by drawing together the contiguous surfaces by plaster, or bandage and compress. Care should be taken that extraneous bodies are removed. Particles of grit will be best extricated by a douche of water from a strong syringe.

Broad and unsightly cicatrices may sometimes be advantageously dissected out, and a palpable disfiguration exchanged for a scar very much less disfiguring, or scarcely noticeable.

The division of the canaliculi is a serious accident, inasmuch as their complete function is, I believe, for ever lost. If one only suffers, the aspect is less severe, for one will nearly suffice for the natural office of these ducts. It is a common recommendation to pass a bristle or bit of wire to maintain the aperture during the healing process, but subsequent contraction cannot be prevented. With the integrity of a small portion next to the lachrymal tube, the office may be partially restored, as I shall show when describing the affections of these channels.

A rupture of some portion of the lachrymal tube above the bony canal in which it lies, is one of the accidents incidental to injury in this region, and, as far as I know, produces but temporary inconvenience. Charles Porter, a young man, received a slight scratch on the inner corner of one eye in a scuffle; he

thought no more of it till the evening, when he blew his nose, and felt a puff of air in the corner of the eyelids. Rather amused by the novel sensation, he continued to inflate his nostrils, till he found that his eyes were nearly closed, and his face much swollen. When he came to Dr. Taylor at the Ophthalmic Hospital two days after the accident, his eyelids were almost closed, and the swelling had extended down to the cheek as far as the under edge of the jaw; the air could easily be pressed in different directions, conveying a fine crepitating sensation to the finger: he soon got well without any treatment. Another case came under Dr. Taylor's notice, where a rupture of the sac followed the act of blowing the nose: this, also, did well of itself. If the supply of air to the cellular tissue does not soon cease, pressure should be applied over the site of injury.

Laceration of the tube within the bony canal, from fracture of the bone, is the more severe accident, and it may be advisable to maintain the aperture by a style, or occasionally to pass a probe from the nose.

In surgical operations about the lid, the incisions should be planned with reference to the least deformity, and where there is necessarily much loss of texture, some allowance may frequently be made for improvement by plastic operation; the likelihood also of ptosis from injury to the levator palpebræ should be remembered.

A surgeon may be compelled to remove parts of the lids, or even to perform their entire amputation, after the bite of rabid animals. The experiments of Youatt go far to show that the nitrate of silver and sulphuric acid have power in neutralizing or destroying the poison; yet it is not considered safe to trust to them alone. Bites about the face, or indeed any uncovered part of the body, are the more serious from the free contact of the dangerous saliva, and with this greater chance of the morbid development, no well-assured method of treatment should be neglected.

An intelligent and healthy lad, eight years old, was brought to St. Bartholomew's Hospital, on the 11th of October, 1841, by

an elder sister, in consequence of injuries received from having been knocked down by a strange dog while at play with his school-fellows. On the upper lid of the right eye was an abrasion about three-quarters of an inch long, and half an inch broad, and all the information that could be collected was, that the dog leaped at him and knocked him down. As one knee bore the evidence of a fall, and the face was covered with mud, the eyelid was supposed to have suffered from the same cause; some simple dressing was applied, and directions sent to the mother to make inquiries about the dog. On the 13th of December of the same year, the poor lad was brought to the hospital with hydrophobia, and died the day after. At the inquest a question was raised about the neglect of removing the lid; but I was able to prove that the probability of danger was pointed out to the sister, and it further appeared that the mother had learned a day or two after, that the dog was killed as rabid, but was persuaded by a neighbor not to let the knife be used. To have resorted to such a severe measure as the removal of a lid without any evidence that the part had been bitten, would have been as culpable as to neglect it, had I been in the possession of all the facts of the case.

It has been a subject of much discussion, whether injury to the frontal nerve as it issues out of the supra-orbital foramen, will produce amaurosis. Some surgeons attribute the loss of sight consequent on any blow on the brow to concussion of the retina, and support their opinion by the fact which I have already stated, that amaurosis may ensue from a blow even of a comparatively slight nature at a part of the orbit not traversed by that nerve. Dr. Marshall Hall tells me that he thinks he has had sufficient evidence that the lesion of the nerve alone may produce it. Mr. Lawrence gives a case to illustrate the influence which this nerve may exercise on the eye when its circumference is morbidly affected. A cancerous ulcer of the right eyebrow and right frontal region, in which the bone had somewhat participated, and of some years' duration, was followed by inflammation with destructive ulceration of the

cornea, as in the cases of disease affecting the trunk of the nerve; but parts within the cranium may have been implicated.

Again, a *post mortem* examination has revealed a ruptured optic nerve from violence to the orbit, when the blindness was attributed to some other cause.

The division of the supra- and infra-orbital nerves, and particularly the latter, has of late years been frequently practised for *tic douloureux*, and the operation has been repeated several times on the same individual without affecting the eye.

Wounds of the conjunctiva are of little consequence. The operation for squinting has fully established the fact, that an unfavorable result is not to be feared from extensive division of this membrane, opening of the cellular sheath of the eyeball, and exposure of the sclerotica. Prior to this operation, if a person had received a wound of the conjunctiva, which was followed by an equal amount of inflammation and swelling, the rigor of strict antiphlogistic measures, and long confinement to a dark room, would have been thought requisite. As a rule, sutures are not required here, at least success does not depend on them, although where the membrane has been irregularly torn and more or less detached, a considerable portion that would otherwise perish, may, I believe, be saved by them. I have seen a few instances of union of the conjunctiva by the first intention after a well-executed operation for squint, and this might, I imagine, frequently ensue if the divided edges were brought together by suture, a practice advocated by some surgeons.

Chemosis, or swelling of the conjunctiva and of the subconjunctival cellular tissue from serous effusion, is a common sequence of injury to any of the ocular appendages, and is very likely to excite alarm, but is innocuous; existing with a copious purulent discharge, in which case the effusion is supposed to be of a fibrinous nature, and which state will be considered in the chapter on gonorrhœal ophthalmia, danger is at hand. The extent of the chemosis need never create alarm; the brightness of the cornea,

and the integrity of sight, must be taken as certain assurances of the absence of any danger to the eye. I have seen the cornea nearly covered by it, from a blow on the eyebrow, and the swelling has entirely disappeared in a few days without any remedy, and I have never used any remedy besides a cold lotion. Different forms may be assumed according to the extent or position of the swelling, but these are of no particular importance. I have observed very extensive chemosis, with protrusion from between the lids, and yet neither lid was everted, but the lower was so tightly pressed against the globe that I could not depress it; this peculiarity was evidently from the conjunctiva of the lower palpebral sinus alone being affected. A blow on the eye had produced the mischief.

CHEMICAL INJURIES.

Strong chemical agents applied to the eye very rapidly exert their influence, but an effort should always be made to limit their action by the removal, as far as it may be, of the substance, or that part of it which may not have exhausted its power.

When the carbon that results from the ignition of gunpowder enters the conjunctiva,—and I doubt whether the unexploded grain is ever driven in, and if it be, the circumstances do not materially differ—the only method of getting rid of it, is by picking out the particle before that membrane has healed over it. I cannot say that I have ever done this. I question whether but a very small portion of any individual particle can actually be removed without excision of the conjunctiva in which it may be lodged, and that would be a very unjustifiable measure. Fortunately, fine carbonaceous matters seem to be received on the surface of the eye without any other effect than the permanent stain, except on the cornea, where the transparency is spoiled even around the deposit. There is not any means of acting on pure carbon, except by intense heat combined with oxygen.

Strong acids and alkalies, in a fluid state, almost immediately expend their violence. With these, the very first treatment should be free ablution of the eye with water, by a syringe, or poured from a vessel with a nozzle or spout, the eye being placed in a convenient position. It may appear scientific to introduce decomposing substances, and much time is often spent in seeking for them, but in reality the period of their usefulness is in general too short to be available. When quicklime, or lime in mortar enters the eye, chemistry may be available to an extent in limiting the injury; for water is then but a very sparing solvent, and not capable of holding much in solution, and cold water takes up more than hot; a pint at 32° dissolves 13.25 grains, at 60° —11.6, and at 212° —6.7. Vinegar and water, or dilute acetic acid should be immediately applied. Until that can be procured, water should be used, and as much of the lime removed by washing as possible, and any adherent bits picked away. The proper strength of the acid lotion, is a drachm of the acidum aceticum of the London Pharmacopœia, to seven drachms of water—a less proportion of the acid cannot be depended on—and for free use, a greater quantity would render it too pungent to be borne. In the same manner may the acetic acid and water be resorted to when alkaline escharotics have entered the eye. When acids have been applied it may be as well, even after the employment of water, to use a solution of the bicarbonate of soda; for, although it may appear too late for neutralizing substances to be of actual service, still the chance should be afforded, and their application is satisfactory, from the knowledge that all has been done which science could suggest.

When the eye has suffered from the contact of any heated substance, either in a state of burning glow, or of fusion, our means of immediate relief are very limited, for the sum of all that can be done, is to remove the offending body. Among injuries from heated metals, burns from melted lead are most common, and thin plates or scales of it have been taken from between the lids. A patient applied to Dr. Taylor, with the lids of one

eye soldered together by the entanglement of the cilia in lead-solder; the eye, nevertheless, escaped unhurt.

In these accidents every degree of injury is displayed, from the mere irritation that rapidly passes away, or the slight abrasion which may produce some alteration in the conjunctiva, to the total destruction of the eye. The treatment is very simple, and chiefly consists in great watchfulness to assist the reparative efforts of Nature. Total rest of the eye, with hot or cold narcotic lotions,—in short, anything that gives relief, is indicated. I believe that any application which causes the slightest increase of pain is injurious. The use of very cold or iced water, for a limited period, I have found to be very grateful, though occasionally objected to from mere prejudice. Common olive-oil dropped on the conjunctiva is sometimes soothing. But when one application fails, another must be tried; and the general treatment left to the discretion of the medical attendant. It is a rule never to be departed from, that in all injuries of the eye from the introduction of foreign bodies, the entire extent of the conjunctiva must be examined, for any fragments that may remain impacted; and the search will be imperfect unless the lids are everted and their recesses well surveyed.

The results of these accidents are justly dreaded. Opacity of the cornea cannot be remedied, and little more can be said of the removal of contractions by which the natural configuration of the eye is destroyed, and which defy all attempts to control them. It is generally the lower lid that suffers; and the effects of all burns and scalds, and of all escharotics upon the conjunctiva are similar. Granulations here, as elsewhere, contract as they heal, and draw together contiguous parts. It is usual to enjoin great care in the attempt to obviate these results, and the lavish use of sulphate of copper, nitrate of silver, and other stimulants are recommended. The value of these applications, and other means usually adopted to prevent contracted cicatrices, I shall hereafter consider in my Chapter on Operations for Palpebral Adhesions. I may here briefly remark that in my opinion, the less the healing surfaces are irritated, the quicker cicatrization can be com-

pleted, and the shorter the suppurative period the less will be the contraction, and the smaller and fewer the bands and bridges. The only local application that seems to be contraindicated when the cornea is ulcerated or excoriated, is the acetate of lead, on account of the deposit from decomposition being likely to adhere and produce opacity. This has been questioned; but it appears to me that Dr. Mackenzie has demonstrated its truth by actually removing from the cornea, after the application of the lotion, a scale of the precipitate. Even if there were doubts on the matter, why employ lead lotion? No proof whatever has been afforded of its superior qualities, and if astringents be required, many are preferable to it.*

* There can be no doubt on the subject. Persons of little experience in Ophthalmic Surgery have sometimes undertaken to treat granular conjunctiva by the application of the acetate of lead in powder, and we have repeatedly witnessed the deposit from this article thus improperly employed, and also as a precipitate from the liquor plumbi acetatis, both upon the lids and on the ulcerated cornea. The constitution of the lachrymal secretion is not uniform. In some individuals it is strongly impregnated with saline ingredients, a copious precipitation ensues on admixture with various solutions, and under such circumstances, the deposit, which moreover requires for its arrest an ulcerated surface, will almost certainly take place. Opacity from this cause when of recent occurrence will sometimes disappear under the use of a weak collyrium of acetic acid.—ED.

CHAPTER IV.

FOREIGN BODIES ON THE SURFACE OF THE EYE.
 LARVÆ OF INSECTS UNDER THE LIDS. FOREIGN
 BODIES WITHIN THE EYEBALL. OSSIFICATION OF
 THE OCULAR TISSUES.

INSTRUMENT FOR REMOVING FOREIGN BODIES FROM
 THE SURFACE OF THE CORNEA.

THE miniature gouge here figured is the twentieth
 part of an inch broad. It is hollowed or scooped,
 round at its extremity, bevelled and sharp.

FOREIGN BODIES ON THE SURFACE OF THE EYE.

The intrusion of bodies in the eye is of very com-
 mon occurrence, and the effects vary according to
 their size and the manner in which they impinge.

An almost microscopic particle of matter may ad-
 here, slightly irritate the eye, be readily dislodged by
 the movements of the lids, and washed away by the
 tears, or, perhaps, removed by the fingers from the
 corner of the eye; or, a body may be projected with
 great violence, become impacted in the eye, and de-
 stroy it either at once—or, ultimately, from secon-
 dary causes.

The excretory lachrymal channels must frequently
 convey away minute substances; for whatever is be-
 low the diameter of the punctum may be so carried
 away, if its length do not interfere. One of my late
 colleagues at the St. Pancras Royal General Dispen-

Fig. 12.



sary, suffered from irritation of his eye which was to him inexplicable. Three days before he applied to me, while sitting in his drawing-room, he felt a very sharp pricking in the eye; but neither could he discern the cause, nor could another surgeon succeed in discovering it. The semilunar fold was swollen and very red, and the entire conjunctiva inflamed; while the end of a hair, protruding just sufficiently to allow of being laid hold of with a pair of forceps, was visible from the upper punctum. This was easily drawn out; it was half an inch in length, and evidently a portion of his own hair that had been hanging about his person, after having been cut.

When a foreign body is lodged within the lids, the patient may be able to define its exact seat—a matter of some moment; but when he cannot, and a survey of all the exposed part of the eye fails to detect it, the lids should be retracted, and a greater surface of the globe exposed—the entire cornea, and some of the sclerotica beyond it being rendered visible. Should that not suffice to reveal it, the interior of the lids must be searched—the under by depressing it and pulling it from the globe, which should be directed upwards; the upper by reversing it, that is, turning it inside out; which may be easily done by holding some of the central cilia and the edge of the corresponding portion of the tarsus, drawing the lid down and away from the eyeball, resting a probe or any small instrument above the cartilage, and folding the tarsus upwards and backwards over it. The reversion may be adroitly effected with the forefinger and thumb. Yet with all this, a small substance may still remain concealed as the recess of the upper lid has not yet been exposed, and to unfold or open it to view, a narrow spatula, or paper knife, is required. When the object is perceived, its detachment is generally easy. But with all diligence of investigation, a minute particle may still escape observation, especially by artificial light; for the peculiarity of the recess prevents perfect and satisfactory exposure. In this case a jet of tepid water thrown upon the eye from a syringe having an angular tube, projected with sufficient force, should be employed. Some surgeons use,

as an instrument of search, a camel-hair brush; or what is better, as it is stiffer, one of sable.

There are occasions when, from the multitude of the particles, the syringe cannot be dispensed with. Thus a lad was brought into St. Bartholomew's Hospital at night, having both eyes filled with cement powder; here it was necessary to use the syringe for a quarter of an hour, the lids being all the while held apart, before the foreign matter could be removed.

The patient's sensations are not an infallible guide to the presence of bodies within the lids; with a full persuasion that something yet lingers in the eye, he may be mistaken. Again, he may be entirely deceived, not any substance having entered the eye, the whole source of discomfort arising from a few enlarged conjunctival vessels about the outer angle; and it is well known that one of the symptoms of inflammation of the conjunctiva is the sensation of sand, or grit, as it is usually expressed, in the eye. On the other hand, it is not impossible that the error is on the side of the surgeon, who imagining the substance to have been removed, directs his treatment against the supposed consecutive inflammation, while the true cause is still extant. The following is a case in point:—A gentleman, perceiving that something had entered his eye, and having, in vain, tried to remove it, applied to his usual medical attendant; nothing was found, but his suffering continued. On the following day inflammation and pain rendered him unable to attend his duties. He was cupped, confined to a dark room, and salivated. Six weeks of misery were passed in implicit obedience to the rules of his adviser, who now became not only very anxious, but actually alarmed, and requested a consultation with some one more conversant with eye-diseases. This was granted, the upper lid was everted, and a portion of cigar ash removed from about the centre of the cartilage, the usual seat of small particles under the lid. Relief was instantaneous, the symptoms declined rapidly, and the cloudy cornea recovered its transparency.

When the less sensitive part of the conjunctiva is involved—I mean the recess of the lid—and where there is little motion,

even when the foreign body is large, its presence may be overlooked by the slight disturbance it occasions; and it may not be discovered until suppuration ensues, or a small fungus surrounds it and becomes visible. This latter is sufficiently common to have been observed by all who have seen much public ophthalmic practice. Mr. Lawrence removed a bit of twig, from the bough of a tree, that had been under the lid for several weeks without the patient being aware of its having entered the eye. He gives another example of a gentleman who consulted him on account of uneasiness in his eyes, into one of which a small insect had flown a few weeks before, although the patient was not disposed to attribute all his sufferings to that circumstance. Within the under lid was found one of the elytra (the wing cover) of a minute species of beetle, and within the upper, the corresponding one.

The following remarkable instances of fungous growth are from Monteath's translation of Weller's "Manual of the Diseases of the Human Eye," quoted by Dr. Mackenzie. A young girl had a soft red fungus growing out of her eye, as large as a filbert, it was of some weeks' standing, and was attributed to a hurt inflicted by a straw striking the eye. The fungus originated in the conjunctiva, where it is reflected from the lower lid to the eyeball. It was cut away, but in three weeks was as large as ever. It was again removed, and at the angle of reflection of the conjunctiva, a bit of straw half an inch in length was observed and extracted; the cure was complete in a few days. A man consulted Dr. Monteath on account of an inflamed state of his eye, induced by a fall five months before, among some bushes in descending a steep mountain. He felt at the moment that some part of the eye was wounded; and although he had applied a great variety of remedies, it had, from that period, remained in a tender state. On everting the upper eyelid a fungous state of the conjunctiva was discovered very high up, in the angle of reflection of that membrane, and on examination with a probe it was evident that a foreign body remained there. It was seized with a pair of forceps, and when extracted proved to be a portion of twig from a bush, three-fourths of an

inch in length, and nearly as thick as a crow-quill. This substance had remained in the upper fold of the conjunctiva for five months, and had got into that situation without wounding the eye.

The first time I saw a fungus proceeding from such a cause I was for a while deceived, not having been assisted in my diagnosis by information from the patient, the morbid growth alone having attracted his attention.

The treatment in these cases is evidently to remove the fungus at the base, and seek for the foreign body. It is one of the first principles of surgery to search carefully for extraneous bodies and to remove them. When these lie on the surface of the eyeball the importance of the rule is increased, for the consequences of secondary effects may be fatal to vision. When a small hard substance enters the eye, perhaps in nineteen cases out of twenty it adheres to and becomes impacted in the cornea, buried in the conjunctival portion, or in the true corneal tissue; and even here there may be such local changes as shall mask the truth, and induce us to diagnose a pustule or some other disease.

Mr. Wardrop, in his pathology of the human eye, correctly observes—it sometimes happens, that, after a body is imbedded in the cornea, a layer of new substance is produced over it, so that it does not excite inflammation, but remains through life in a kind of sac. He quotes a curious case in which the hard elytra of a beetle traversed in two years from the upper part of the eyeball to the centre of the cornea, immediately opposite the pupil, finally lodging there. In the case of a patient at the Ophthalmic Hospital, a bit of wire was impacted at the lower part of the cornea; there was a dark brown deposit, in the centre of which appeared a dark spot. The injury was received sixteen years before, but as it did not occasion the least inconvenience I did not interfere. But such phenomena are rare.

The minuteness of bodies within the lids may cause them to be overlooked; and sometimes they cannot be discerned, except in a particular light, by the loss of polish of that portion of the cornea upon which they rest. When they merely adhere to the cornea they are easily removed, the chief difficulty being in

fixing the eye, which should be done as if the extraction of a cataract were about to be performed. This is among the nicest manœuvres of ophthalmic surgery, and the difficulty is increased by the involuntary and strong action of the orbicularis muscle, occasioned by the irritability of the eye. In most instances there must be more than mere adhesion, or else I think foreign bodies would not remain so long in one spot, but be moved about, or actually wiped off the cornea by the lids. When fairly imbedded some perseverance is required to extricate them. A cataract-needle is generally employed for the dislodgment. It would be better to use some implement with a broader point. A small scoop, such as I have figured at p. 69, is superior to everything else that I have tried. The foreign body is sooner withdrawn with it, and remaining on the end of the instrument is readily removed, and very much less injury is inflicted on the eye than in the usual, and repeated attempts with needles, cataract-knives, or other angularly pointed blades.

It has been implied that when an attempt to remove a foreign body thus impacted is not readily successful, the endeavor should be relinquished, and the separation left to the process of ulceration.* This is a very dangerous doctrine, and if literally acted on, would cause the sacrifice of many eyes. So long as a body has not passed beyond the cornea we should not abandon it, except under very peculiar circumstances. It is true, that there is a possibility of its becoming encysted, but that is an unlikely contingency; or a natural exfoliation by the process of ulceration or sloughing may ensue; both

* When the particle is very minute, and firmly implanted in the cornea, more injury might be inflicted by persevering efforts at detachment than would probably arise from the irritation produced by its presence. In such cases it would be better to wait before renewing the attempt until incipient ulceration had somewhat loosened the offending body,—introducing meanwhile a little mucilage beneath the lids, and restraining their motion by compresses wetted with cold water. We have been obliged to adopt this alternative in several instances, and with results uniformly favorable.—ED.

processes, however, should be avoided, since they are decidedly fraught with danger to sight. I have seen ulceration of the cornea, and prolapse of the iris, occasioned by the presence of a particle of iron that had entered a week before, but which was so diminutive that a surgeon did not detect it; and a patient had general inflammation of the globe, from a minute bit of iron that had been lodged in the cornea for three weeks; it was readily removed, but the other eye sympathized in the inflammation. I could quote many parallel cases of danger to the eye, even when the foreign body had been superficially placed. There is ever some natural effort to rid the eye from intruding substances, and it is by those attempts that the organ is so likely to perish. Indeed, these consequences, as they are called, are rarely unattended with injurious effects, and perhaps never, when the cornea has lost some of its substance—an opacity or partial staphyloma being the least evil. Even when a body does become encysted, this does not necessarily form an exception, and I have known the accompanying unhealthy action prove fatal to sight. But the form of a body and the peculiarity of its impaction may, as Dr. Mackenzie observes, prevent its either escaping, or becoming encysted; and a case of Mr. Wardrop's, reported in the "*Lancet*," is adduced as an example. A bit of gold wire had entered the cornea, and a small part protruded, while the larger portion was impacted within, where it had been fourteen weeks, before it was removed with a pair of forceps; but in the meantime the eye was nearly lost, and the pupil was adherent to the cornea when the patient applied to Mr. Wardrop. The portion of wire was fully three lines in length; one extremity had entered the anterior chamber, and the aqueous humor escaped at the extraction.

I must say that I have never regretted the persevering attempt to remove a foreign body from the cornea; and I make the statement after ample opportunities of practice; for from the immense establishment of Messrs. Cubitt, with its numerous workshops and manufactories, scarcely a week passes without

workmen applying to me at the Ophthalmic Hospital on account of such accidents; while the neighboring parish of Clerkenwell, swarming with those who exercise trades whereby they are peculiarly exposed to similar injuries of the eye, affords a wide field of observation. I am sometimes obliged, as it were, to dig into the cornea; and I find the repair is usually complete; and no opacity follows when the conjunctiva only has been removed.

When, however, a minute substance is deeply bedded in the cornea, and some days have elapsed without any ill effects arising, the surrounding portion of the cornea not being hazy, and pain, vascularity, and lachrymation absent, it should be left alone—a practice the more imperative should it seem likely that prolapse of the iris would follow the removal. A coach-maker, a young man, received a minute splinter of wood in the cornea, over the pupil, the entire thickness of which was penetrated; it caused little inconvenience, and had been lodged a week when I first saw him. The attempts to remove it failed; and it appeared that it could not be extracted without risking the protrusion of a part of the iris. A week after he returned with no other bad effect than slight intolerance of light; and he had been to work as usual. Three weeks later he again made his appearance, saying, he was determined to have it removed, since there was constant lachrymation, the eye was inflamed, and mischief seemed at hand. I contrived to get it out, Dr. Taylor assisting me. The aqueous humor escaped; but the iris did not protrude, and the case did well.

Although ulceration round a substance may facilitate its removal, it would, indeed, be very bad surgery to encourage such assistance.

Some metallic particles, but particularly those of iron and steel, oxidize and stain the cornea around them. Carbonized and other substances act similarly, and without a knowledge of this, unnecessary injury may be inflicted with the view of removing it. Chemical reagents have been suggested for iron

rust; but the proper course is not to meddle with it. I have known vegetable matter produce stain.

In the "*Medical Times and Gazette*," of April 24th, 1852, Dr. H. Jeanneret very ingeniously proposes to dissolve particles of iron from the cornea, by the chemical action of a solution of sulphate of copper, of the strength of from one to three grains to the ounce of water. This method should not give place to that of mechanical removal, but it may be of great value when a surgeon is not at hand, and relief cannot otherwise be obtained. An eye-glass filled with the solution, and held to the eye, is the proper mode of using this agent.

The conjunctiva may be penetrated, and a particle of matter remain between it and the sclerotica. Mr. Wardrop tells us, that he has found a bit of whinstone enclosed in a sac of cellular membrane, lying close to the sclerotic coat, which had remained for ten years prior to the person's death, without occasioning the least uneasiness or even suspicion of its presence. The sclerotica itself is often penetrated and retains bodies without much inconvenience. I have several times removed them when troublesome, by snipping through the conjunctiva, raising it from its attachment and then accomplishing the desired end. Generally it has been metal that entered, and forceps have been required for the extraction. A young man received a portion of a percussion cap in the sclerotica, just outside of the cornea, and after a week of inconvenience he returned to his work. The druggist to whom he applied detected nothing, and prescribed a wash. Nine months after, he came to me at the Ophthalmic Hospital, complaining of an occasional pricking in the lid. In the centre of a granulation at the site of the old injury, I saw an angle of the piece of copper and extracted it. He had experienced no inconvenience till within a few days previous. The broken cap seemed to be working its way out. I have seen not less than five eyes destroyed by percussion caps during the last year, and not in a single instance were the caps used in shooting; but two persons received their injury by exploding the caps between pieces of iron; and three

from snapping them for nuts at a fair. The caps of the nut-sellers are highly dangerous, being peculiarly constructed; since the copper is not cleft as in ordinary caps, but entire, to concentrate the force of the ignition. Thus they split with violence and fly about, not merely to the injury of those who are using them, but to others.

The following case of the impaction of metallic particles occurred in the practice of my friend Mr. Browne, of Belfast, and illustrates many practical points. The entire surface of the cornea, and the greater portion of the conjunctiva sclerótica, were literally paved by fine particles of iron. A young man in an iron foundry was drilling a hole in the cylinder case of a steam engine; he stooped down to observe his progress, and holding a lighted candle, there was an explosion of some gas that had collected between the cylinder and case. The eye was scorched, and the particles from the drilling thrown on its surface. The cornea was scraped of its epithelium, and the particles of iron removed to an extent that saved the eye, and rendered it useful. Deformity, however, remained from the stains on the cornea, and the presence of some of the iron in the conjunctiva, from which but a small quantity of the filings was extracted. Some of the metal was even under the conjunctiva.

The employment of magnets has repeatedly been suggested as an easy and effectual means of extracting particles of iron and steel; and various shapes have been given to them—some pointed, some crescented, and so on; but they are mere playthings, and not of any practical value.

After-treatment is seldom required, the symptoms disappearing as readily as they were manifested. When inflammation has been severe, and there is pain with heat and intolerance of light, a fold of thin rag, large enough to cover the lids, dipped in cold water, laid on, and renewed every few minutes, will soon give relief. The addition of some narcotic to the water may be useful. This, with rest to the eye, quiet of body,

moderate abstinence, and slight purgation, amply suffice for every case.

LARVÆ OF INSECTS UNDER THE EYELIDS.

The larvæ of insects are sometimes deposited beneath the eyelids. In the fifteenth volume of the "*Annales d'Oculistique*," p. 133, it is told by M. Armand Bouilhet, that a young woman while cutting rye, felt something impinge on the eye, and immediately began to suffer pain. M. Bouilhet thought he had to deal with some foreign body. After opening the lids he perceived a whitish point, put it on a pin to show it to the patient, and to his astonishment saw that it moved: he examined it attentively, and discovered it to be a little worm. Remembering that some flies deposit their larvæ in different parts of animals, he thought this little insect might not be the only one. He poured three drops of olive oil upon the globe of the eye, and drew out, successively, ten worms.

A child, of ten to eleven years of age, who since the preceding evening had experienced great uneasiness in the eye, applied to M. Bouilhet. The symptoms had come on immediately after a fly had flown into the eye, though it scarcely remained a moment. The patient was sure that an insect had come in contact with the eye. M. Bouilhet examined it attentively, and discovered little worms in the recess of the upper lid. The same means were employed as in the first instance, and six worms were drawn out. As the case was spoken of as something extraordinary, a physician went to see the child, and detected other worms; he immediately sent the child back to M. Bouilhet, who took away two more.

This unique case is related by Cloquet in his "*Pathologie Chirurgicale*:" A man, fifty years of age, who was drunk, fell asleep in the fields; flies (*musca carnaria*) deposited their ova at the orifice of the nostrils and ears, between the eyelids, and on the prepuce. The larvæ made their way into the body in these several situations; the eyes were completely destroyed, for on

removing the larvæ, the lenses escaped through the perforations they had effected in the cornea. Under the cranial integuments they formed large deposits, from which they could be pressed in thousands through ulcerated openings. The miserable mortal survived for about a month in a state of imbecility; the bones of the skull were partly necrosed, and the corresponding parts of the dura mater and arachnoid membrane were in a state of inflammation.

FOREIGN BODIES WITHIN THE EYEBALL.

The cornea may be penetrated and the foreign body thrown into one of the chambers of the eye, where it may remain either loose or be embedded in any of the surrounding parts. Here, as on the surface of the globe, there is the possibility of its becoming encysted. Mr. Tyrrell knew of a small particle of granite, and in two instances, of minute portions of copper caps, thus fortunately covered; but these and a few similar examples that have been published, bear an insignificant proportion to the usual result of such accidents. An endeavor should be made to extract the substance that has entered, except when it has passed out of sight, in which case the eye must be left to take its chance; as likewise when it is so small that it is scarcely probable that it can be seized; or when it is of a nature that is likely to be absorbed; or is a soft substance which, though insoluble, could not be removed, as gunpowder or its residue. This applies, also, to the penetration of the lens, with the certainty of a body being there. The lens, which is sure to become opaque, should be extracted, for otherwise, in all probability, the eye will be ultimately lost. I have much pleasure in introducing an example of the correctness of this practice, the particulars of which were forwarded to me by Mr. Browne, of Belfast. "A lad, employed in a machine-shop, had a chip of brass, weighing seven grains, forcibly propelled into his eye while he was observing a workman cutting the metal with a chisel and heavy hammer. It was night when he was brought to me, and he was suffering so much pain

that I could scarcely obtain any examination of the eye; however, I observed that the cornea presented, on its lower and outer aspect, a ragged wound about a quarter of an inch in extent, and I saw behind the pupil the bright shining metal fixed in the lens. In consequence of the pain and irritation, I could not then do more than advise soothing applications, and an anodyne internally. Next day I found that the pain had considerably abated, so as to permit a more accurate survey of the injury. The outer margin of the pupil was torn, and the lens penetrated from its outer and anterior surface, while the metallic substance seemed deeply sunk into its structure. The aqueous humor having entirely escaped, the iris was brought nearly in contact with the posterior surface of the cornea, thus almost obliterating the anterior chamber. I saw at once that an effort must be made to remove the foreign body; I determined to extract the wounded lens at the same time. Of course I perceived the difficulty there would be in completing a sufficient section of the cornea, without cutting away a portion of the iris. An assistant having carefully steadied the eye, I passed a probe in at the wound on the external side of the cornea, and across the chamber, till its point fixed between the iris and cornea on the inner side. Having thus drawn the cornea forwards, I passed a fine narrow cataract-knife in at the wound, and completed nearly a half section of the cornea, without injuring any portion of the iris; and a little manipulation sufficed to extract the lens and the foreign body along with it. The lids were then brought together, as after ordinary extraction, and the wound healed without any undue inflammation having occurred. The lacerated margin of the iris, however, became attached to the corneal section, by which the pupil was obliterated, and the outer part of the cornea was opaque where its substance had been torn. As the centre of the cornea was clear, and the eye otherwise offering no impediment to an operation, after some months I made an artificial pupil, by incision with your broad iris-knife; an excellent pupil was the result, with tolerable vision." From the statement of Mr. Lawrence, that the point of a cataract-knife which was broken, and

remained in the anterior chamber, soon disappeared without any injurious consequences, there is some encouragement to leave minute particles of steel alone ; yet, that solitary case must not be taken for more than it is worth, and allowed to weaken the broad principle laid down. The details of the operation must be regulated by the individual peculiarities of the substances to be removed. The retraction of the lids, the steadying of the globe, and the opening of the cornea, must all be attended to as in extracting a cataract ; for which, together with certain modifications in the operation suited to these emergencies, I must refer to my chapter on the subject. The cornea should not be incised to a greater extent than the bulk of the body to be withdrawn, or the instrument to withdraw it actually requires. The position and mode of attachment of the foreign body, are to be the data in selecting the spot for the incision. The nearer to the cornea the opening is made, the less will be the danger of protrusion of the iris ; and whether forceps, hook, or curette be used, its extremity should be rather blunted to avoid injuring the textures it may come in contact with, especially the capsule of the lens ; for, if that be torn or scratched, opacity will ensue. The spoon of the curette will be found very serviceable.

Effusion of lymph around a substance, so as to encyst it, does not absolutely secure immunity from future disturbance. Thus Mr. Tyrrell alludes to a case of Mr. Scott's, in which that gentleman deemed it imperative to operate, because of the growth of an enclosing cyst. A bit of iron entered the iris of a blacksmith's apprentice, and after several weeks of active disease, he recovered good vision, notwithstanding a disfigured pupil. Some months after, a small cyst formed in connexion with the injured part, and grew, with a white and tendinous-like structure, to the size of a pea, when it was thought fit to operate : the result is supposed to have been unfavorable. Assuredly, without cogent reasons, these cysts should not be meddled with. Mr. Middlemore states in his work, that a piece of metal which had been driven into the anterior chamber and covered with a semitransparent matter, was set loose two years after by a rupture of the cyst

from a blow on the eye, and impending destruction of the eyeball from severe inflammation, induced him to remove it.

The length of time that may have elapsed since a foreign body entered the eye should be no reason against endeavoring to extract it, if its presence be injurious; for successful instances have been recorded after the interval of days and weeks, nay, after several years. Thus, in "Ammon's Zeitschrift," vol. iii., p. 103, we are told that, a splinter of a small glass ball, which had been filled with spirits of wine, and as a joke put into the fire, flew into the left eye of a female, and became fixed in the middle of the cornea. Next day a surgeon was called, who, in attempting to extract the splinter, unfortunately drove it into the anterior chamber. For a whole year the woman suffered the severest pain. The cornea continued transparent for about six months, and her husband asserted that during that time the glass splinter was visible, free, floating, and movable in the anterior chamber, but that, subsequently, the eye became more and more opaque, and acquired a pannus-like condition. The patient went to Vienna, where she applied to many surgeons, none of whom, however, believed in the existence of any foreign substance, as it was no longer visible. By degrees the cornea became clear, and vision returned; but the severe pain, extending from the eye towards the head, remained unmitigated. At the end of five years of suffering, she again repaired to Vienna, and saw Dr. Carl Jäger, who made an incision in the cornea with a common cataract-knife, and with various forceps, probes, and other instruments, endeavored, but in vain, to extract the body, which in consequence of bleeding from the iris was now hidden. The eye was soon in the same condition as before the operation, although less painful. In a few months, however, her sufferings returned, and again she applied to Dr. Carl Jäger, who now succeeded in detecting the piece of glass, which was of a triangular shape, measuring in its greatest diameter about five lines, and covered with a light brown colored mucus, and extracted it with a pair of forceps.

No injurious consequences followed, and vision was scarcely impaired.

In the sixth volume of the "Dublin Medical Press," we also find an account of a nail in the eye: Mary Barron, admitted on the evening of the 29th May, 1841, into the Richmond Surgical Hospital, stated, says the reporter, that about two hours previously, when shaking a carpet, a small nail, which had been concealed in it, was jerked against the centre of her right eye. The shock it caused was very great, and slight nausea and general weakness followed. A nail supposed to have done the injury, was found in the carpet. Very shortly afterwards she observed, on her apron, a small glairy substance, which from her replies to questions respecting it, was probably the crystalline lens. The palpebræ of the right eye were much inflamed and swollen, the chemosis being so extensive as almost to cover the cornea, which presented a depressed appearance with a slight oozing of blood. Not the slightest trace of anything like a foreign body in the eye could be discovered. Up to the 15th of June there was scarcely any alteration in the state of the eye, notwithstanding the vigorous antiphlogistic measures which had been pursued; and on the evening of this day the eyeball was found greatly enlarged, very painful, and, apparently, hopelessly disorganized. Under these circumstances Dr. O'Beirne thought it advisable to make a free opening into the cornea; the incision was followed by a considerable discharge of purulent matter mixed with serum, and the patient expressed herself relieved. Whilst making this incision, Dr. O'Beirne felt the point of the lancet grate against some hard resisting body, and at the moment stated his decided opinion to the class, that there was some foreign body in the eye. He thought proper, however, to desist from any further examination on this day; but two days after, having by a careful examination satisfied himself of the presence of a foreign substance, he proceeded to extract it with a pair of long-limbed forceps, and readily succeeded in drawing from the eye a small black nail of about three-quarters of an inch in length, having

a broad and flattened head very nearly a quarter of an inch in diameter. It is a singular fact, that the point of the nail was in front. Immediately on the withdrawal of the irritating body, the distressing symptoms ceased.

Putting aside the endeavor to save an eye thus injured, it may be necessary to remove a foreign body from a collapsed globe, not only to mitigate suffering, but to rescue the other eye from the effects of sympathy; and no one has demonstrated this so fully as Mr. Barton, of Manchester, whose cases are reported by Mr. Crompton, in the twenty-first volume of the "London Medical Gazette." In seven of these cases a fragment of copper cap was driven into the anterior chamber of the eye; but immediately after the accident the changes produced in the eye, and the symptoms, were so like those observable in penetrating wounds of that organ when no foreign body remains, that it was impossible to ascertain whether the cap was in the eye or not. Vision was not immediately lost in those cases where the copper went through the sclerotica, and did not injure the transparent parts of the eye; but in a period from a few days to a month after the accident, and while the patient seemed in a fair way of recovery, inflammation and pain suddenly came on, and vision was soon lost. The fellow eye also soon become impaired, and incapable of bearing ordinary light. In one case the iris changed color, the pupil became adherent, lymph was deposited on the capsule of the lens, and, but for judicious management, the eye would have been lost. In the treatment of the wounded eyes Mr. Barton, suspecting the nature of the cases, excised the cornea and applied a poultice, in the hope that the cap would escape, and the cause of irritation, with its attending threatenings in the other eye, be removed. In all of the seven cases this occurred, and in a few days the copper was either in the coagulum of the wound, or in the poultice.

The value of the practice does not end here—the principle extends further. A male, aged thirty, who had lost his right eye for some years, applied to Dr. Taylor at the Ophthalmic Hospital, desiring to get the other eye attended to, as its failing

powers had deprived him of employment. The history was, that the partially shrunken eye had for three months been very painful, scarcely allowing a night's rest; that all treatment had been useless; and that the left eye began to fail soon after the occurrence of pain in the right. The cause of suffering was at once traced to the opaque lens, which seemed cretaceous, was partially dislocated downwards, and shook about with every motion of the eye. Reasoning on Mr. Barton's cases, and knowing pain to be an occasional consequence of a lens so changed, we decided that it should be removed. I therefore freely opened the cornea, divided an adhesion that the lens had formed to the iris, and with a pair of forceps completed the extraction. The man left the Hospital in a week. The diagnosis proved to be correct; for the left eye soon began to improve, and in three weeks the man resumed his avocations.

Mr. Quekett, who examined the morbid part, informs me that the entire capsule and all the lens, with the exception of a minute portion at the posterior surface, were ossified.

Whenever there is ossification, or calcareous matter in the capsule of the lens, or when the lens itself is so affected, the symptoms of a foreign body in the eye may be attributed to those causes. A capsule or lens so altered is, in fact, a foreign body, and should be removed. In every instance that I have seen of this osseous change, most of the other parts of the eye have been disorganized, and vision lost; and several times the altered lens has been more or less adherent to the iris. The usual manner of starting a lens, as in the operation for extracting a cataract, by pressing or squeezing the eye, is not applicable here; for the vitreous humor, now very thin and watery, would flow out, leaving behind the part to be removed, and still more difficult to be withdrawn. The cornea must be sufficiently opened at a well-chosen spot, any adhesions that may exist between the iris and the capsule of the lens divided, and the cross-spring forceps, scoop, curette, or whatever instrument may seem the more fitted, applied. Any fragments that may separate must also be disengaged.

It is just possible, as we learn from the rich stores of Mr. Wardrop's "Morbid Anatomy of the Eye," that ossification of other parts may call for extraction. In one case a bit of bone, which Mr. Wardrop considers to have been a partial ossification of a part of the posterior lamina of the cornea—the capsule which lines the cornea, as he terms it—was removed from the anterior chamber. He has several times also observed thin laminae of bone discharged from the anterior chamber through ulcers in the cornea; and that portion of the capsule of the aqueous humor, which is reflected over the iris, almost entirely converted into a long shell. The choroid and hyaloid membranes, the retina, in fact all the textures of the eye, have been found more or less ossified, and calcareous concretions within the eye have been several times observed. The following specimens are to be seen in the pathological collection of the Museum of the Royal College of Surgeons :

From a man who was blinded by lightning forty years before death. The choroid membrane contains several small thin plates of bone at its posterior part; the lens is absorbed, and its capsule ossified.

The eye of a blind man, in which large plates of earthy matter or bone are formed in parts of the retina and on its inner surface. There is a second specimen similar to this.

Parts of an eye dried; the lens, converted into a mass of white compact earthy substance, nearly retains its natural size and form; some irregular portions of earthy substance extend also from it into the vitreous humor.

The sclerotica has been found partially ossified. Mr. Middlemore alludes to the *post-mortem* examination of an idiot boy, at St. Bartholomew's, where ossification of the greater part of the globe of each eye existed.

In the museum of St. Bartholomew's Hospital, there are sections of the eye of an adult, showing that the retina has disappeared and its place become occupied by a thick layer of dense osseous substance.

A remarkable case of the impaction of a grain of duck-shot in

the optic nerve, where it lodged for six years and six months, is recorded in the "London Medical Gazette," for 1834, vol. xiii. The shot entered the eye at the inner side of its surface, near the cornea. Occasional and intense pain, for four years and a half, and the serious disturbance of the functions of the other eye, induced the patient, contrary to medical advice, to have the body sought for. The lens, which is said to have been partly bony, partly calcareous, was removed with the hope of affording relief, but without benefit; pain continued, and the sight of the other eye being endangered, an attempt to find the shot was made, but unsuccessfully. The sufferer now determined to have the eye extirpated, and the shot was found impacted, as the report says, in that part of the optic nerve which expands and forms the retina. The right eye was daily getting into health when the last communication was sent to Dr. Butter, the operator.

CHAPTER V.

AFFECTIONS OF THE EYELIDS.—DISEASES OF THE LACHRYMAL PASSAGES.

ABSCESS OF LID.

THE lids are liable to abscess, and to considerable injury, unless the pus be early evacuated. Common phlegmonous abscess is not likely to be overlooked; but, from the peculiar looseness of the palpebral skin, which is favorable to the extension of fluid, a chronic abscess may simulate mere swelling of the lid, and be mistaken for œdema; and following this cause I have seen some severe cases of ectropium of the upper lid. Even with slight symptoms of suppuration, a puncture should be made; for in the situation in question it is frequently by this means alone that abscesses are detected.

In erysipelatous inflammation of the face, the palpebræ are apt to suffer from sloughing of the cellular tissue, and vigilance is required not to allow the first stage to pass without the necessary incisions being made. The surgeon must not be deterred from making the incision sufficiently free by a dread of wounding the eyeball. Instances have been recorded of such accidents, and we read of an unfortunate physician who had both globes evacuated by a colleague in opening abscesses of the lower lids. The position of the canaliculi should be ascertained, and care taken to avoid them. The course of the lachrymal ducts, and the strip of gland that accompanies them, should also be remembered, lest they be cut, and a lachrymal fistula ensue. If an abscess "points," the spot for opening it is of course indi-

cated; but wherever the incision is made, it should be transversely, or parallel to the natural folds of the lid, in order to lessen after-deformity.

COMPLETE OR PARTIAL ADHESION OF THE EYELIDS TO THE
EYEBALL, OR SYMBLEPHARON.

When the conjunctiva is burned or scalded, or severely acted upon by escharotics, or receives a lesion that is followed by loss of substance, sloughing, or ulceration, contraction ensues; and, according to the extent of the implication, the lid is more or less united to the globe, which is accordingly restricted in its movements, or rendered motionless. Any operations that involve the removal of the conjunctiva, particularly above or below the horizontal axis of the eye, may produce this effect; although it must be remarked, that the amount of contraction which follows from this cause by a surgical operation is very different to that produced by accident. Severe ophthalmia is said to be the cause of one form of the affection. A patient at St. Mary's hospital, a man of thirty, had the entire surfaces of both lids intimately adherent to the globe, the remainder of the conjunctiva oculi being cuticular and dry. It was attributed to a severe attack of purulent ophthalmia. I suspect that the treatment of ophthalmia by escharotics may sometimes play no unimportant part in producing these adhesions, knowing, as I do, that nitrate of silver is often used in substance, and in very strong ointments, in a most lavish manner; a practice which I have known to produce sloughing. M. Desmarres, who is fully alive to this abuse of caustic, says, he has been informed, by Dr. Furnari, that "during his stay in Africa, he had seen and operated on so large a number of symblepharons from that cause, that he was quite tired of them."

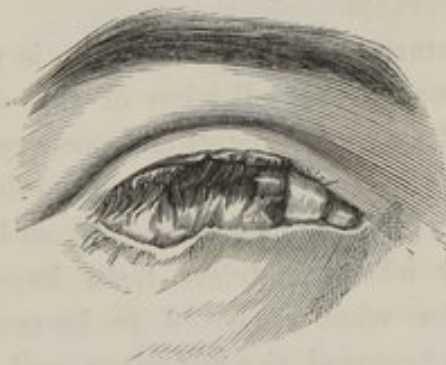Congenital symblepharon has been met with; and Mr. Wardrop has recorded a case in which it seemed owing to a cuticular condition of the conjunctiva. — "Dublin Journal of Medical Science," vol. xxviii.

With few exceptions, all the examples of symblepharon that

have come under my notice, were occasioned by the action of quick-lime or mortar.

The accretion always takes place slowly, is extensive in proportion to the original injury, may occur even when not expected, and is not necessarily attended with the process of sloughing of the texture of the conjunctiva. Twice I have watched the effects of quick-lime from the commencement; and like every one else, I believe, who has attempted it, totally failed in stopping the accustomed after-effects. In each case the injury was partial, and confined to the lower part of the globe. The entire conjunctiva became intensely red, except where the lime had rested, which was white or whitish, from the chemical action that had taken place; this spot soon swelled, its epithelium separated in shreds, and contraction commenced. In the following very aggravated example resulting from a burn, the lid was

Fig. 13.



not only universally and closely adherent to the eyeball, but was also drawn much over the cornea, which had been injured in the greater part of its extent, and the eyeball was motionless, and the outer part of the edge of the upper lid, although scarred, was not adherent.

The upper lid may be adherent to a considerable extent without any inconvenience.

The treatment of every variety of adhesion is difficult, and rarely successful—improvement, even, must depend on the ex-

tent and nature of the adhesion, and on the state of the cornea; for if that has become opaque, the question of operating should not be entertained, except, according to Dr. Mackenzie, when circumstances induce us to operate, not with any hope of restoring sight, but merely to relieve pain and a feeling of dragging, which restrains in some measure the motions even of the sound eye.

Interference is perfectly useless when the adhesion is very extensive, and perhaps also when slight or limited, if the proper tissue of the conjunctiva, with more or less of the cellular tissue, have perished, and bands of lymph form the connexion. Experience has fully convinced me of the truth of this assertion, and the general expression of English authors is to the same effect. Mr. Tyrrell believed that little could be done either by medical or surgical aid.

My own practice has not furnished me with an example of the bridle form of adhesion spoken of by some writers: the prognosis is said to be favorable.

Failure or the return of the agglutination is not, according to my observation, due to the adhesion of the opposed surfaces, which I believe to be a very exceptional occurrence; the divided parts come together by means of the contraction of the granulations through which they are healed, just as happens in other parts of the body when cicatrices from burns are removed. Several times, under what appeared to be most favorable circumstances, I have removed the cicatrices, and dissected off the bands and bridles, but the contraction has returned to the same or even greater extent. Indeed, in two instances only, have I obtained a good result. In the first I was partially successful: the band which tied the centre of the lid to the globe encroached a little on the cornea, and was narrow, soft, and loose; I merely divided it twice, and each time it returned to its former state. I then removed a small central portion of what appeared to be the cicatrix of the band, and brought the edges of the divided conjunctiva, on the lid and on the globe, severally together by sutures, and the result was very gratifying. The last time

I saw the patient, several months after the operation, there was but a slight contraction at the lower part of the interior of the lid:—a spot where there would, I suppose, be a certain amount of puckering, in most of these cases, under any plan of treatment. The globe of the eye was no longer unnaturally covered by the lid, and the feelings of restraint to its movements were lost.

In the second I was still more fortunate, for perfect success ensued. The patient, who was twenty-six years old, had, when a lad, accidentally received some quick-lime in his eyes; and the usual process of adhesion of the lids to the globe, followed cicatrization of the conjunctival slough. The annexed sketch

Fig. 14.



accurately expresses his state before operation. The connecting medium, which seemed to consist entirely of conjunctiva, was long and nearly isolated. Putting the lid on the stretch, I divided the band vertically through its entire thickness, carried the incision into the tissue below, and brought the edges of each side severally together by three sutures. In four days the stitches were removed.

I suspect that, unless there be a sufficiency of conjunctiva in a band of adhesion to allow the edges of the wound to be readily approximated after this plan, little can be hoped for by any surgical measure.

There is a notice in the "*Gazette Médicale*," of 1846, of an operation by M. Blandin that should be mentioned. The foreman of a foundry at Nevers received a burn on the lower part of the right eye from a drop of burning metal, and ex-

tensive ulceration of the conjunctiva of the eyeball and lower lid followed. The wound was neglected, the cartilage of the lid was destroyed, and adhesions formed between the globe and the lid; the lower half of the cornea was covered by a semi-elliptical, bluish white cicatrix, while the upper half remained clear, and allowed a view of the interior of the eye, which was healthy. The eye thus united to the eyelid had lost in a great measure its mobility, and occasioned a feeling of constraint which was very fatiguing to the patient. M. Blandin determined on dissecting the cicatrix from above downwards, destroying the adhesion which converted the eyeball and eyelid into one organ, turning the dense bluish white structure, already described, inwards, so as to form a substitute for the palpebral mucous membrane, and thus to prevent a new adhesion from taking place. This plan was carried out with complete success. The inferior palpebral sinus was filled up by a dense fibrous cicatrix; this M. Blandin succeeded in dividing, and as soon as the mobility of the eye was completely restored, he doubled down the cicatrix in the form of a hem, which he retained in position by the glover's suture. The two extremities of the thread were carried horizontally to the right and left, and fixed with a certain amount of tension to the corresponding temples, so as to keep the border of the lid free of the cornea, and assist in obviating any faulty cicatrization. The sutures were removed on the fourth day. The patient was dismissed from the hospital about three weeks after the operation, in the following condition. The eye had quite recovered its mobility, and could be directed at will towards any object; the part of the cornea, which was formerly covered by the cicatrix, was now covered only by a delicate film of cellular tissue, which did not granulate, but daily decreased in thickness and opacity. The new eyelid had a rounded border, it was rather short, but could be approached, without difficulty, to the upper lid, and effectually defended the eye from the action of the light. The ingenuity of the proceeding is most laudable, and the correctness of the description of the state of the eye at the time of the patient's dismissal

from the hospital cannot be questioned. Yet it would be incorrect to conclude that the operation had answered. Sufficient time had not elapsed to judge of its effects; the early favorable results might have been counteracted by subsequent contraction, as too often happens in parallel instances. The report, and others of a similar character, although instructive, are therefore far from being perfect.

The four following methods have been collected by M. Desmarres, and are given in his "*Traité des Maladies des Yeux*;" only one of them—that of M. Amussat—has been practised in this country.

After having freely divided all existing bridges, the point of a pin, or of a cutting instrument, is daily carried to the very extremity of the division, and the pyogenic, or false membrane, torn; and this is continued until the surfaces are cicatrized, and can no longer adhere to each other.

M. Desmarres adds, that for seven years he has seen M. Lisfranc daily practice this manœuvre with his nail on the prepuce of individuals operated on for phymosis, and that he is fully satisfied of the efficacy of this method in certain cases; but he remarks, however, that the tearing of the wound sometimes produces erysipelas; that it demands continued perseverance and attention on the part of the operator for several weeks; and that the patient is often tired out before cicatrization takes place.

The second is the ligature process, of M. Petrequin. A double thread is passed at one spot through the adhesions; the one is tied close to the sclerotica with great firmness, the other towards the lid with a less degree of tightness. The strangulation and sloughing occurring earlier at the constriction next the eyeball, that part heals before the other, and the cicatrization becomes too forward to admit of a new adhesion with the outer part.—"*Supplement des Annales Oculistiques*," vol. iii. p. 66.

The third is that of Professor Ammon. Two converging incisions, commencing at the free edge, and carried through the entire thickness of the lid, are made to circumscribe, and thereby

detach that portion to which the adhesions are connected; the incisions of course fall together in the form of the letter V. The lateral parts of the lid are then brought together by the hare-lip suture, and the central bit, that has been shut out from them, remains fixed to the eye, and lies between the globe and the lid. After the pins have been removed, and the union of the parts perfected, which at the soonest is in about fourteen days, the detached fragment is cut off. Two figures are given, the first to show the lines of the cuts, the second the appearance of the eye when the lips of the wound have been brought together.

Lastly, there is the very ingenious proposal of Professor Dieffenbach. It consists of folding the lid inwards, and placing the cuticle for a while against the globe. One incision is made from the internal angle of the eye by the side of the nose, and another equally vertical, from the external angle, to the corresponding border of the orbit. The lid is detached from the globe of the eye, the cilia are cut off, and the quadrilateral piece is then turned inside to rest against the margin of the orbit, and secured by sutures which are carried from within outwards, and *vice versâ*, tied together, and further bound by small adhesive straps. When the wound on the globe is sufficiently cicatrized, the temporary and artificial entropium is removed, the lid is released, and whatever adhesion it may have formed on itself is destroyed; it is carried back to its original position, and there retained by the twisted suture. The eyeball being then covered with the peculiar tissue from granulation, cannot renew its connexion with the recent surface of the lid, which, in its turn, acquires a solid cicatrix. This applies to the lower lid; the upper lid is treated in the same manner.

It is evident that the attention of authors is principally directed to overcome the adhesion of the surfaces; for they appear to consider the reunion of the divided tissue the common source of failure. This opinion I much question. Many mechanical contrivances have been resorted to for the prevention of adhesion, and plates of metal and other substances have been inter-

posed. Numerous surgeons have recorded their attempts and their failures. It is to be regretted that early treatment is fruitless in preventing the occurrence of contraction, and the subsequent union of the parts; and Mr. Tyrrell, after telling how the granulating surfaces should be exposed, three or four times a day, and any junction of granulation destroyed by a probe, the practice being continued till a new mucous or secreting membrane is formed—a state of surface which I suspect would never arrive—says, one evil that follows these injuries, which the utmost care and attention of the surgeon cannot prevent, is the contraction of the new formation as it becomes organized, so as to produce a frænum, or band, between the surfaces of the globe and the eyelid.

Professor Miller's summary of the process of repair after burns, applies to these cases:—that they heal slowly and much more by the contraction of the old surfaces, than by the formation of new; that the new matter is imperfectly organized and liable to absorption; and, consequently, contraction continues for some time after the completion of the cicatrix.

ADHESION OF THE EDGES OF THE EYELIDS, OR
ANCHYLOBLEPHARON.

This rare affection, which is seen both as a congenital defect and as the result of disease and injury of the lids, may be produced by any of the causes which occasion adhesion of the lids to the eyeball. Of the first, an interesting example is given by M. Rognetta, in his "*Cours d'Ophthalmologie*," 1839, in which the lids were united by means of the palpebral conjunctiva, so as to form a sort of movable veil, of about three lines in breadth, over the cornea, the tears flowing through a little aperture at the external angle.

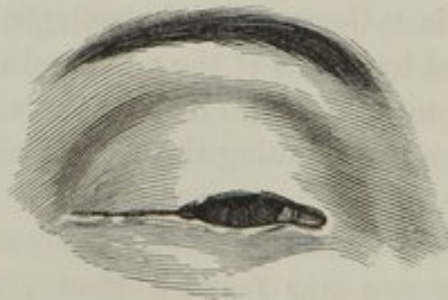Mr. Travers briefly alludes to a remarkable case of it in a full grown boy, whose eye was found perfect after the division, though he had been thus blind from infancy. From his remarks it seems, in this instance, to have been similar to the co-adhesion of the nymphæ or labia pudenda in infants. Mr. Middlemore,

who alludes to the experience of many authors in this deformity, has himself seen three cases in which the tarsal margins had been coherent from birth. The defect occurred in both eyes, the lashes were not formed, and in the situation of the edges of the lid there was a narrow sulcus lined by a delicate vascular portion of skin, which admitted of extension, but not absolute separation. In one case the eyeball appeared imperfectly developed, but seemed adherent to the lids.

In the "Lancet," for 1840, vol. ii., the late Dr. Hocken, in his admirable ophthalmic papers, speaks of a child who was brought to the Exeter Eye Infirmary, with a small filamentary portion of the integuments causing adhesion of the left eyelid. The band which occupied the site of the junction of the outer with the middle third of the lid, was of the size of a common sewing thread, round, and consisting of integument. In all other respects the eye was healthy. It would be out of place here to consider the physiological bearings of this arrest of development, and to those interested in the matter, I would recommend Mr. Wilde's writings, in vol. xxvii. of the "Dublin Journal of Medical Science."

A youth, exhibiting a tolerably well-marked instance of the second kind, or what may be distinguished as the accidental form, applied at the Central London Ophthalmic Hospital to my colleague, Dr. Taylor, who took the following sketch.

Fig. 15.



Those parts of the lid not in contact were quite raw; and the union that existed must have been very recent, from the ease

with which the separation was effected by a common dressing probe. The ointment of the red oxide of mercury was used, and the surfaces cicatrized singly, and successfully.

It is generally stated, that, in what is called complete adhesion, there is always an aperture, however small, through which the lachrymal secretions pass. This is not, however, the case; for in May of this year, a man was sent to me with entire adhesion of the left eyelids, and in which not the least aperture existed. The accidental explosion of gunpowder had destroyed the globe, and in a few weeks the lids had united. There was not any inconvenience produced by the lachrymal secretion not having an outlet for escape; and I suspect that in its absence, there is always imperfection or destruction of other parts of the eye, and especially of the conjunctiva.

The mere separation of the lids is simple enough, even when a director and a scalpel are required; and where there is not a passage for the entrance of the director, one must be made at the internal angle. The point to which attention is specially demanded, is the prevention of fresh adhesion; and it is towards the corners of the lids that there is the greatest danger of its return. The preventive means usually prescribed are stimulating ointments, escharotics, and desiccative powders. Some have thought it advisable that sleep should be prohibited for twenty or more hours; or if the patient be allowed to go to bed that he be awake at intervals, and the local application, whatever it may be, reapplied. The application of gold-beater's skin, or touching the surfaces with collodion, after they have been well dried, would, perhaps, be superior to any other method. Probably the depression of the lower lid, by strips of plaster, and the elevation of the upper, would be a valuable adjunct; care being taken to protect the eye from dust, and where the upper lid has not been left free, it may be requisite to moisten the cornea with oil.

Stœber has very ingeniously proposed that after the disunion

of the lids, a portion of conjunctiva should be raised, drawn forward to the lip of the wound and fastened by sutures.

Dr. Mackenzie makes a distinction between close and intimate adhesion by the inosculation of ulcerated surfaces, and a bond of connexion by the intervention of coagulable lymph; and he directs in operating on the latter, that the first incision should be made close to the edge of the under lid, leaving the whole of the pseudo-membrane attached to the upper lid, from which it is to be dissected with a pair of scissors.

Growing together of the lids when their surfaces are raw, must no doubt be favored by their contact during sleep, or by any affection of the eye itself, whereby the lids are unnaturally kept together; thus in Dr. Taylor's case, there was considerable intolerance of light from strumous ophthalmia, while several instances of union of the lids have occurred to me when the globe had collapsed. In all probability both conditions are due to the same cause:—the margins of the lids having become raw, speedily united when favorably placed together.

We must not operate in this affection when the lids adhere to the globe, a complication easily ascertained by the movements of the organ, or by any aperture that may exist; neither must we do so when the cornea is opaque, a point less easily determined unless it can be seen; here, however, the power of discerning light must be made the test:—where one eye is perfect it should be closed, and a comparison of the light-detecting power of the two may decide the question.

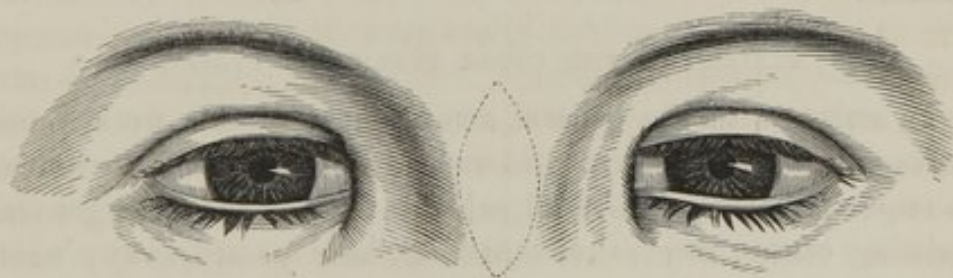
ENCROACHMENT OF THE SKIN ON THE CORNER OF THE EYE,
OR EPICANTHUS.

In this defect, first described and named by Von Ammon, of Dresden, the inner canthus is covered by a crescentic fold of skin passing from the nose and covering the caruncle. Although a slight degree of this deformity is not uncommon, an aggravated state is rare among Europeans. There are,

however, varieties of our race in whom it is very frequent, and in an article on the malformations and congenital diseases of the organs of sight, in vol. xxvii. of the "Dublin Journal," Mr. Wilde gives it as his opinion, from what he has seen of the Mongolian race, and from the examination of a great number of their crania, that the epicanthus, which we regard as a congenital malformation in the European and the Caucasian races, is the natural condition of the Chinese and the Calmuc.

The abnormal fold may interfere with vision; or trichiasis in the upper lid, a marked example of which in an infant has lately come under my notice, may result. The accompanying representation of the affection (Fig. 16), is from a child nine months old, in whom the deformity was readily relieved. The fold may be reduced or pulled aside, by forcibly pinching up the intervening integuments of the nose; and hence is founded the operation of taking away a portion of skin to produce permanently such an effect. The required size of the piece to be removed, is readily ascertainable by the amount that must be

Fig. 16.



pinched up to clear the lids. The lines on the nose in the above sketch mark the direction of the incisions, and the size of the piece of skin that I removed.

After the piece is taken out, the edges of the wound should be a little raised, to allow of their easy approximation; or else from the natural tightness of the skin in this part, there will be a strain which may endanger union by the first intention, and which is so essential to success. The hare-lip suture must be

used, and the pins should be entered the eighth of an inch from the edge, carried entirely through the skin, and brought out at a corresponding distance on the opposite side; two will suffice. Instead of the ordinary coarse, clumsy, and expensive pin, I use sharp ones of soft steel, tipped with sealing-wax. Common toilet pins would answer as well, and might be used, were it not for the popular objection to them on the score of their festering properties—not groundless, perhaps, when the plating is lost. At least five days should elapse before the pins are withdrawn, or else separation is risked.

The defect may exist in one eye, and should an operation be required, the above proceeding must be a little modified. One incision must be straight and in the middle line, the other in the form of a curve towards the affected side. It is a commonly received, but very erroneous opinion, that a child may grow out of the deformity.

Epicanthus may be acquired, that is, may result from the cicatrix of a wound displacing the lids, and pulling the skin over the corner of the eye, in which case the nature of the operation required, will of course depend on a variety of circumstances.

FALLING OF THE UPPER EYELID, OR PTOSIS.

In unison with the general arrangement of this work, those cases only of ptosis are considered, in which surgical treatment is requisite; that is, when all palpable or even supposed general existing causes, cerebral or otherwise, have passed away; when the affection is congenital, with deficiency of development, or with paralysis; or when it results from direct injury to the levator palpebræ, as mechanical resistance to action of that muscle, or from feebleness of power, as in the aged. While the probability of a cure by medicine exists, operative measures should be kept in abeyance; and should the ptosis be confined to one eye, and there coexists that disordered state of the optical apparatus, whether in the recti muscles or in the optic nerve, which produces double vision or confusion of sight when the lid is raised, an operation is inadmissible.

The remedial measure is simple; it consists in taking away a portion of the palpebral skin, the extent of which should be determined according to the class to which the case belongs. Where there is partial loss of power the removal of a portion of skin, merely to tuck the lid up, is sufficient; where the levator palpebræ is motionless, or nearly so, the lid must be brought under the influence of the occipito-frontalis to supply its movements, and for which, it must be more shortened than in the other instance, by the loss of a much larger bit of skin. Under one or other of these, must all cases of ptosis fall which can be remedied by operation. To insure success there should be integrity of the orbicularis palpebrarum; for it is called on to exercise exaggerated power to overcome the defect occasioned by the shortening of the lid, and the closure of the eye being principally effected by raising the lower lid above the ordinary level, to meet the upper. Without that, the lids would be more or less permanently open, and the eyeball exposed.

Besides the difference of circumstances in the two kinds of cases to guide us in the amount of skin to be removed, and the varying degrees of the depression or falling of the lid in these classes, the condition of the skin itself must be taken into account—whether it is unnaturally thickened, or healthy, or loose and baggy. Of kindred importance also, is the state of the brow, whether lax or tense, and the usual action of the occipito-frontalis of the individual; for in some persons it seems motionless, while in others its contractions are remarkable. From inattention to these points must be attributed the unsatisfactory results that are sometimes said to attend the operation.

The portion whence the slip is to be taken, should be as near the edge of the orbit as circumstances will permit, or else the edge, rather than the body of the lid, will be influenced. The dissection should be made with a scalpel, the skin merely raised, and the orbicularis left entire; for in proportion to its destruction must the power of closing the lids be reduced. It is generally recommended, in order to be exact, that a portion of skin

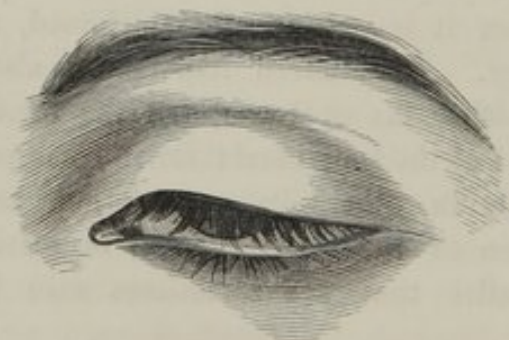should be first pinched up with a pair of forceps constructed for the purpose; but for any information that may be so gained, the use of the finger and thumb will suffice. When the instrument is employed, the desired amount is pinched up and cut off with scissors, or sometimes, but very rarely, with a scalpel. Independently of the inaccuracy of this proceeding, a disfiguring scar is the inevitable result.

Should there be any doubt about the extent of skin to be excised, it should be fixed at the supposed minimum, for a fault on the other side would be serious. In the earlier operations of surgeons, generally too little is removed; and it is only after considerable practice that a proper estimate of the amount can be made.

The examples which I shall give, are—congenital defect—want of power in the levator palpebræ—hypertrophy of the skin, and subjacent cellular tissue. And I shall add an allied state from falling of the brow.

Mr. W. B., aged twenty-two, a student of New College, called on me Jan. 18th, 1851, with ptosis. The eye could be

Fig. 17.



closed with ease, and when shut differed in no respect from its fellow. The eyebrows were in a line with each other, and the skin of each lid alike wrinkled. When the eyes were opened to their utmost and directed to a body on their level, the cornea of the left was not half shown, the iris being about two-thirds concealed. In that attitude was the preceding illustration taken.

The globes were parallel, the recti muscles perfect, and vision unimpaired. When the patient was depressed in spirits or fatigued, the lid always drooped more. The defect was congenital. I operated on the 19th, having fixed the lid after the manner shown in the operation for trichiasis, and when the skin which was removed was spread out it was of this size.

Fig. 18.



Four sutures were applied ; and as circumstances obliged him to return home next day, they were withdrawn just before his departure, having been in only twenty-seven hours. Three weeks after, he wrote to me, saying, that there was great improvement in the usefulness and appearance of the eye ; and although the lid was not quite as high as the other, the abstraction of any more skin would have prevented the eye closing.

A young woman, aged twenty-two, applied to the Central London Ophthalmic Hospital, Jan. 7th, 1847 with ptosis of the left eyelid. It had existed according to her account from childhood ; and the unwrinkled and elongated lid peculiar to complete ptosis was well displayed. With great effort a little of the globe could be exposed ; the vision was slightly impaired, being misty ; the recti muscles were sound. I dissected off a large semilunar piece of skin, the extent of which will be better understood by describing the preliminary incisions. The upper one extended upwards in a curve from opposite to, and within a quarter of an inch of, each angle of the lids, to within about the eighth of an inch of the eyebrow ; the lower one was across the lid, and met the other at the extremities. On the third day the sutures were removed. I did not see my patient for a year, and the success of the operation was very great ; there was but a faint mark of the wound ; the lid could be raised to the same height as its fellow, and when

closed, only differed from it by not descending so low—the lower lid rising a little to meet it, and the edge being straight and not curved.

Some deficiency in the development of the lid has been long noticed in congenital cases. Dr. Mackenzie says that in some he had met with, the lid was the reverse of being swollen, it rather appeared atrophied, as if the levator muscle had either been originally deficient, or had wasted from disease. I am not aware if dissection has confirmed the suspicion. M. Caffé also has noticed the fact; his observations are to be found in the "*Dictionnaire des Etudes Médicales.*" On the 19th of October last year, I operated at St. Mary's Hospital, on a child three years old, in whom this state of lid seemed to exist.

A woman, aged sixty-four, infirm, and with ptosis of both eyes, applied at the Ophthalmic Hospital. There was feebleness of the levators, rather than paralysis; for with an earnest endeavor, which she could not long maintain, both eyes could be sufficiently opened for sight. To enable her to move about or see anything, in which she might be engaged, it was necessary to keep one of the lids raised with the finger. Less skin was removed than in the last-mentioned case, and the poor old woman relieved from her distressing condition. This is the only opportunity I have had of performing the double operation.

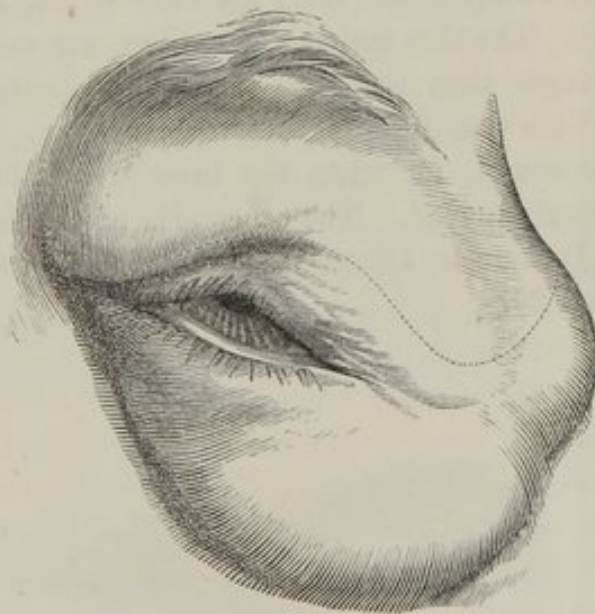The following case of ptosis from hypertrophy of skin and cellular tissue I alluded to in my published lectures ("*Medical Times,*" vol. xxii. p. 449.) The history, which I now give in the patient's words, runs thus:—

"The lid of my left eye was first observed to droop when I was about two years old, and as years passed by it continued to droop and to enlarge, but I felt little inconvenience, as I had the use of the eye in part until I was about the age of twelve, when the swelling had so much increased, that it became a source of annoyance from the constant inquiries of persons. Then, although I could yet see downwards, I took to wearing a shade, and continued to do so till the age of twenty, and on the 19th July,

1837, I was operated on. The hemorrhage was considerable, and stopped by pressure; stooping on the second night caused it to burst open and bleed very considerably. While the size was a little reduced by this, the appearance was still offensive, and after a year or two I again paid a visit to my former operator to know if he thought anything more could be done for me, when he kindly took me to a neighboring professional friend, and after about half an hour's consultation, they informed me that they thought it was possible he might be able still further to relieve me, but it would be attended with risk. Under such circumstances I declined having anything done, but in the year 1845 I was introduced to Mr. Smee."

In consultation with Mr. Smee, my colleague at the Ophthal-

Fig. 19.



mic Hospital, we determined to attempt to reduce the mass, lessen the deformity, and render the eye useful. At this time, the whole of the skin of the lid, and the outer part of that of the brow, and a portion of the temple was swollen into a mass that hung over the eye, and nearly concealed it,—its weight closing

the lid, and preventing its being elevated by natural efforts. A considerable portion of it, all that was pendulous, was circumscribed by transverse elliptical incisions, by Mr. Smee, and removed. Very active bleeding ensued, and several ligatures were required.

The appearance of the mass was like the sarcomatous thickening and enlargement of the scrotum, which take place in hot climates, being hypertrophy of the skin and the subjacent cellular tissue. The result was not unsatisfactory; for the deformity was greatly lessened, and the lid could be sufficiently raised to render the eye available. Figure 19 shows the present state of the case; the dotted line marks the course of the incisions, and which is now occupied by a cicatrix.

During my house-surgeonry at St. Bartholomew's Hospital in 1842, there was in attendance as an out-patient, a man of thirty, whose eye was nearly closed from the brow of the left side falling on the lid. The skin was not unhealthy, nor could I observe any other changes than paralysis of the occipito-frontalis muscle. He told me that he was born in that state. The levator palpebræ was sound, for when the brow was held up the lid could be properly moved. The other side of the face was unaffected. Mr. Delamotte, Librarian to the Hospital, took a sketch of it, as in fig. 20.

Fig. 20.



The patient was at the time sitting and looking directly at the draughtsman, who was on the same level. The depression would have been better shown by introducing the other eye for contrast,

and that was my intention, but by accident half of the original drawing was destroyed.

Some foreign surgeons regard mere looseness or relaxation of the skin as a cause of ptosis; but it is not easy to see how that can have any influence, unless increased weight is added to relaxation. Undue ponderance in any of the tissues of the lid will affect its movements. It would seem to be a fashion to attribute all alterations in the lid to relaxation of the skin, and the most opposite states, entropium and ectropium, are ascribed to it.

When the eyeball is a little less in size than its fellow, from congenital defect, or from atrophy consequent on disease, the eyelid droops, the state of ptosis is simulated, and operation will materially improve the personal appearance by raising the lid and exposing more of the globe of the eye. A young woman availed herself of this improvement at the Central London Ophthalmic Hospital, in May of this year. The eyeball was congenitally reduced, and the narrow aperture of the lids gave the usual disagreeable appearance. Dr. Taylor, whose patient she was, removed a portion of skin with very marked benefit.

CILIA FORCEPS.

These, on their points, have a broad fine cross-cut, or file-like surface, for taking secure hold. The edges are so much rounded that they cannot cut; the points also are rounded; and, further, the blades are strong enough to admit of proper pressure being exerted at their extremities.

Fig. 21.



TRICHIASIS.

Trichiasis signifies that misdirection of the cilia or eyelashes, whereby their natural position is changed and they are turned towards the globe of the eye, and touch or rest on it more or less; thus, practically, the term is not applicable until the mal-direction has arrived at that state and occasions some injury.

Trichiasis, although one of the most common affections of the eye that call for surgical relief, demands as serious attention as any in the Ophthalmic catalogue; for, although it does not rapidly destroy the eye, yet if allowed to proceed unchecked, or if merely partially relieved, it becomes, from the constant irritation and inflammation which it causes, one of the most destructive diseases.

The number of poor persons, for in that grade of society it is most common, who from this cause are doomed to blindness, or impairment of sight, is by no means small; unfortunately the long-protracted arrival of the distressing climax of trichiasis is apt to engender a misappreciation of its importance, and the certain results are not sufficiently considered or dreaded, perhaps not generally known, and thus palliative rather than radical remedies are too much recommended and adopted.

The disease is peculiarly common among the lowest orders of Irish, in their own country, and may be justly ascribed to the irritation in their eyes, caused by the acrid smoke of their miserable hovels, their neglect of ablution, the filth amidst which they exist, and the exposure to wind and weather, to which the many wretched pursuits attendant on poverty subject them.

Trichiasis varies in degree from a slight deflection of some of the cilia, just sufficient to touch the globe in one or more parts of the lid, to the inveterate implication of all of them, except the smaller ones at the corners of the lids, which are usually exempt.

I here show (Fig. 22) a good specimen of a genuine type. A few of the cilia just touch the cornea, and a small bunch rests

on the sclerotica; others are regularly disposed: the edge of the lid is natural and not in the least turned in.

Fig. 22.



The manner in which the more internal of the cilia deviate either in a limited number in one or more places, or along the greater length of the lid, has induced some surgeons to think that there is actually a new production of an inner set of cilia; and to suppose that in this distichiasis, as it is called, there is a supplemental development of hairs proceeding from a more internal part of the lid. It has been a question much discussed, whether this is or is not the case—whether new cilia have sprung forth, or old ones have turned in. I have not myself been able to gather any facts that support the secondary creative theory; all the evidence that I can collect is adverse to it. The supposed independent, or new row, is a mere deception, arising partly from the irregular, though natural manner in which the cilia are placed at the edges of the lid, owing to the different planes in which their follicles lie; a fact which seems to be frequently overlooked, although noticed by the earlier anatomists, and partly from the isolated position of those which are most internal when their extremities are turned in or inverted from their fellows that are set more externally on the lid. This so styled distichiasis may be artificially produced, and the permanent misdirection accurately imitated in a perfectly healthy lid, by separating the inner row of the cilia, and bend-

ing them towards the globe. Again, the usual number of cilia in a healthy lid is not exceeded in a case of trichiasis; and this can be made a matter of demonstration, when one eye only is affected, by comparing it with the other. But the crowning argument against the growth of supplemental hairs is, that there is no such thing as a secondary formation of hair in any part of the surface of the body, the hair follicles being all of primary development. It is well known that hair is occasionally found in the ovaries, and other situations where it is not a natural product; still this is no argument for its abnormal growth on the lids. The growth of hair on parts that have been repeatedly blistered, has suggested the idea that hairs may likewise be generated in the lids as a result of chronic inflammation. Experience does not support this theory, which is advanced in ignorance of the fact, that the surface of the human body at the time of birth equals if not surpasses, in the number of hair-follicles, that of any other animal; and when from accidental causes in after life new hairs appear, it is owing merely to hyper-nutrition of original germs.

The most that can be urged is that, in the lid an animating influence on dormant bulbs may be exerted; but the arrangement of the lid renders most doubtful the existence of such an occult capability.

Some surgeons, who are not disposed to believe in the creation of new hairs, assert that the displaced cilia are growths from old follicles, which pierce the lid in the wrong place. But this is both anatomically and pathologically incorrect; for the internal cilia are close against the cartilage, and issue by the side of the edge, as close to it as it is possible.

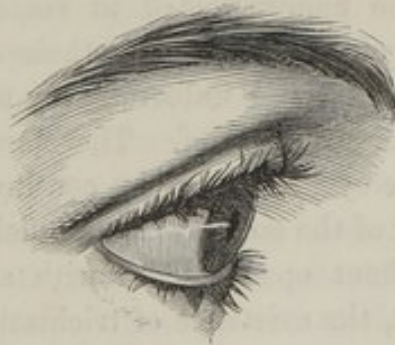Excluding chemical and traumatic injuries to the lids, most of the causes, direct and remote, that produce trichiasis, are palpable. The inversion may be but a permanent state of an accidental distortion of the cilia, by some mechanical means, without any diseased condition of them whatever, of which entropium may be mentioned as an example; or the matting together of the cilia in long-continued purulent discharges from

the conjunctiva, and the attendant misdirection of them, is another mechanical cause—although here it cannot always be certain that the cilia-bulbs are not rendered unhealthy.

As an idiopathic affection, it is due to certain pathological changes in the lid itself, nearly all of which arise from strumous inflammation. It may not be too arbitrary to speak of idiopathic trichiasis as occurring in two forms; in the one, as a disarrangement of the lashes; in the other, disarrangement, together with imperfect development.

I believe that the first, that is disarrangement, nearly always takes its origin in unhealthy changes in the fibro-cellular tissue in which the cilia-follicles lie. There would seem to be an exception to this rule in cases where a few of the cilia, though emerging correctly from the lid, touch the globe from having acquired an unnatural curvature. Thickening or other apparent disease of the lid, is not a necessary accompaniment, but when the disarrangement of the cilia is very great, there is a display of it; this is shown in the sketch (Fig. 23) taken from a lad fourteen years of age.

Fig. 23.



The upper lid, the only one affected, had been involved in chronic inflammation for three years, and was much thickened at the edge. The cilia were healthy, none of them were lost, or imperfectly formed, but they were remarkably scattered. There were two well-marked rows, the upper of which, from its unnaturally high position, had as much the appearance of a new

row, as the under, from its inner position, had of a supernumerary growth. Not the least interesting fact is, that a year after the sketch was taken, when the inflammatory symptoms had declined, and the edge of the lid was nearly reduced to a natural state, the cilia had in a great measure regained their lost relations, and the duplex arrangement was no longer recognisable, a mere bushiness remaining.

The second form of trichiasis—the disarrangement of the cilia with imperfect development—combines with the last more or less disease of the hair-follicles, arising from unhealthy states of the edge of the lid, or from frequent pulling out of the cilia. When a malady is so apparent, it might, perhaps, seem superfluous to speak of its effect on the eyeball, as a means of diagnosis, on the supposition that whenever these effects have attracted notice, the cause also would be self-evident. But such is not universally, even if it is generally the case; were it otherwise, there would be an end of that misdirected, and injurious local and general treatment so frequently adopted, in the desire to dissipate many inflammatory affections of the eye, ascribed to various causes, but in reality owing to the presence of trichiasis. The cilia that fret the eye may be so minute as to escape the observation of those unaccustomed to search for them. Even with a knowledge of their presence, their exact position may not readily be detected, and unfortunately minuteness does not diminish their powers of mischief. Therefore with the sensation of something in the eye, attended by continued inflammation of the conjunctiva, or of the cornea, or superficial ulceration of the cornea with or without opacity, and with any of these states, intolerance of light, the existence of trichiasis may be suspected. It is no uncommon circumstance for the individual who suffers from its effects, to be ignorant of its presence. The following case, one of the many that I have met with, exemplifies how the true cause of opacity of the cornea may be overlooked; and also shows what slight mechanical causes will produce the loss of lustre of that part.

A man, aged thirty-one, presented himself at the Central

London Ophthalmic Hospital, on one of my days of attendance, to be treated for inflammation of the right eye. My attention was first directed to the condition of the left cornea, which was densely opaque in the upper half, and hazy in the remainder; and the cause of which I quickly discovered, in two inverted cilia of the upper lid about the eighth of an inch apart, that rested on the cornea. There was scarcely any power of vision remaining. To use the man's words, the sight had been failing for several years, all the treatment directed to it was ineffectual, and as it was becoming more and more dim, he regarded the eye as lost. He was totally unconscious that cilia were inverted, and was sure that none had ever been plucked out in treatment; a proof that the true nature of the cause had been overlooked. Professor Miller remarks in his "Practice of Surgery," that in Mr. Liston's museum there was a preparation exhibiting four or five delicate eyelashes, which not only cost the patient her sight, but were the cause of ruin to her constitution, through the use of fruitless antiphlogistics to subdue the inflammation that they produced.

The treatment of trichiasis is palliative and temporary, or radical and permanent. Of the palliative, that alone is worthy of notice, which is so naturally resorted to, the pulling out of the cilia by forceps. Of a means so generally adopted, and apparently so universally applicable, it is well to ascertain in what species of implication of the cilia it is advisable to be practised, and how long in any instance it may be persevered in. The condition of the cilia that irritate, and the state of the lid on which they are seated, should be taken into consideration. When the irritation is occasioned by a few well-formed, but inverted cilia proceeding from a healthy lid, there cannot be a doubt about the propriety of using the cilia-forceps; because there may not be a return of the inversion, and even if the hairs so treated on their reproduction show a tendency to become distorted to a like degree, their injurious effect can be anticipated, and the process of extraction repeated. It thus becomes a mere matter of consideration to the patient

whether he shall submit to the periodic repetition of the process, or to a rather more severe but effectual plan, resulting in a cure. But when the extraction is followed by an increase in the number of inverted cilia, or by abortive ones, the application of the cilia-forceps has reached its limit, and as a rule, should be discontinued. There cannot be a doubt that the continued removal of the cilia by force is very frequently hurtful to their follicles, renders the direction of them more perverse, causes abortive productions, tends to involve the contiguous follicles, and so to multiply the trichiasis, and should not be persevered in except at the particular request of the patient. So also, where the lid is unhealthy, and the offending cilia, although few in number, are abortive, and grow directly inwards, extraction is contraindicated; some effectual treatment only is admissible. For in the majority of such cases, with all the vigilance of both patient and surgeon, and weekly extraction practised, there will be an impossibility of keeping the globe of the eye exempt from their contact. The majority of such fine cilia are not in reality plucked out, but are broken off, and with any accession of growth, again exert their injurious effect, long before the eye recovers from the last irritation. Notwithstanding the gradual deterioration of the state of the eye under this palliative treatment, patients will still desire a continuance of it; and the careful use of the forceps will greatly prolong the arrival of its worst effects, while their careless application will hasten it. The proper way of using this instrument is to press on the upper or under part of the tarsus, according to the lid affected, evert its edge, apply their points close to the cilium as it emerges, and pull it out in the direction of its growth.

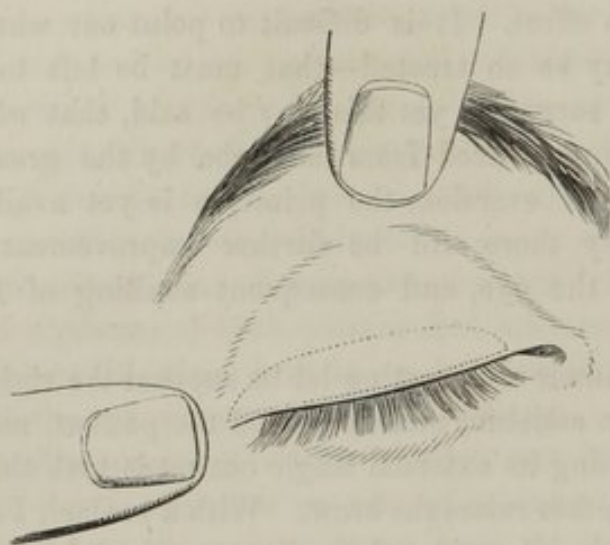
The radical cure consists in the adoption of some operative measure by which the maldirection of the cilia is influenced, or by which they are removed or amputated. The excision of a portion of the palpebral skin to give a slight outward position to the edge of the tarsus, is a very valuable resource, applicable frequently to the upper lid, and nearly always practicable in

the lower. Its adoption should depend on the direction that the inverted cilia take. It is suited to those cases in which they retain their proper size, are merely slightly misdirected, and just touch the globe, and exceptionally to abortive cilia that do not grow as much towards the eyeball as usual; and it may be, its greatest extent of application is to be found when the central cilia are affected. Its adaptation to any given case is readily decided by rendering the skin of the lid tense, and observing the effect. It is difficult to point out what degree of inversion may be so treated—that must be left to the judgment of the surgeon; yet this may be said, that whenever the cilia can be just cleared from the globe by the greatest admissible amount of eversion, the principle is yet available, for in all probability there will be further improvement when the irritation of the eye, and consequent swelling of the lid has ceased.

For my manner of operating let us suppose the right upper lid affected. An assistant stands behind the patient, makes the lid tense by drawing its external angle outwards with the one hand, and with the other raises the brow. With a scalpel, I cut through the skin in the direction of the lines on the lid in the diagram (Fig. 24), making the under incision first, and with the aid of the forceps dissect off the flap, commencing at the inner angle, and without interfering with the subjacent muscle. The sponge, if required, should be used by a third person. The edges of the wound having been brought together by three or four sutures, the operation is completed. Any local application, such as water-dressing, or greased lint may be used. I apply nothing unless the lid is unhealthy, when one or the other is chosen; the latter when it is likely that trouble will not be taken to renew the wet lint sufficiently often, and to apply it neatly and properly. It is next best to water. The upper incision is not so readily accomplished as the under; and I recommend those who are not in the constant habit of operating to lay hold of the centre of the upper portion of the skin with the forceps, after the first incision has been made, and draw it downwards, and thus secure it for the

second cut. In operating on the right eye, as a matter of convenience the dissection should be made from the inner to the outer corner of the flap. The operation on the under lid in no wise differs in principle from that on the upper. The variation in the detail of the position of the assistant, and the advantage of making the under incision first, include the dissimilar points.

Fig. 24.



Should circumstances render it necessary that the operation be performed in a recumbent position, it may be found more convenient to stand behind than at the side of the patient. All that the alteration of position requires, is to reverse the order of incisions, making the upper in each lid the first.

A young woman who was obliged to leave her situation from the effects of trichiasis, was sent to me at the Central London Ophthalmic Hospital. The central cilia of the upper lid and the outer ones of the lower, were inverted, and rested on the cornea. The cilia-forceps had been repeatedly used. I operated on each eye by the removal of a portion of skin and with perfect success. The sketch (Fig. 25) shows the state of the eyelids seven months after the operation, and it exemplifies the peculiar adaptation of the principle to the lower lid, where the cilia that were completely reversed are made to clear the globe.

Trichiasis, according to Mr. Wilde's observation, has been seen at birth, being congenital, but it is very seldom that the affection occurs under puberty. The following severe case is an

Fig. 25.



exception:—J. O., aged eleven years, came to the Central London Ophthalmic Hospital, Dec. 1, 1849; his mother's account of him was, that soon after an attack of measles in infancy his eyes became weak and never regained strength; for the last seven or eight years he has suffered from intolerance of light and lachrymation, while the inability to use his eyes has prevented his learning to read, and incapacitated him from attending to any kind of employment. In the left eye two bunches of cilia, one from the outer part of the lid, where in this instance the cilia were large and long, and the other from the centre, rested on the globe. The cornea was opaque, the greater part densely so, with adhesion of the iris, in consequence of former ulceration. The pupil was nearly closed; the conjunctiva was highly inflamed, and vision almost extinct.

In the right eye a single bunch of cilia from the central part of the lid touched the globe; the whole surface of the cornea was ulcerated, but without being opaque; the conjunctiva was nearly like that of the other eye, and vision was very imperfect. In both there was thickening of the tarsi. The removal of skin on each lid was sufficient to separate the cilia from the globes. The first time I saw this lad after the operation, which was on the third day, he expressed great relief. He came only twice

afterwards to the hospital. What might have been the nature of the early affection, or how long the trichiasis had existed, or in what order the several changes of the globe occurred, it is impossible to say.

It must be apparent that only with a knife can the skin be incised with that accuracy and closeness along the edge of the tarsus which are necessary; but even if the scissors could be equally efficacious, the conspicuous scar that is inseparable from their use, is more than enough to proscribe them.

M. Desmarres has recommended in partial trichiasis with simple misdirection of the lashes, and after ineffectual evulsion, that a small fold of skin close to the edge of the lid and directly opposite the inversion, be taken up with a double hook, and the oval portion shaved off with a knife. The wound is left to itself.* It is, as he expresses it, accomplished without any inconvenience to the patient, and may be done several times on the same lid. I allude to this with much pleasure, the principle being the same as in my own practice, the execution only differing. The effect of so minute a loss of skin must be less sensible, and applicable only, I imagine, to very slight inversion of a very few cilia. The removal of a continuous slip, where many cilia are turned in, must be preferable.

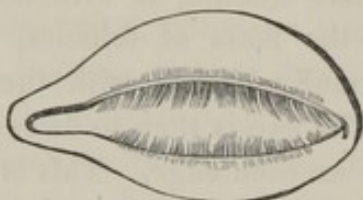The excision of the cilia is, of course, an effectual remedy in all stages of their inversion, but the operation possesses the great defect of producing deformity. Disfiguration about the face is secondary in importance only to disease; and the unavoidable injury that is inflicted on the Meibomian glands—a relative consequence, it is true, to the evil it abolishes, and by some supposed to be of little importance—should induce us to reserve excision as a last or only resource. It is a very common impression that with care the glands may be avoided, but I cannot understand how a dissection on the living subject that shall remove

* A simpler plan and one equally effectual, is to raise the fold of skin by the entropium forceps and excise it with the curved scissors; the edges of the wound being approximated by a single suture, or left to heal as proposed by Desmarres, according to the extent of the part removed.—Ed.

the cilia in an effectual manner, can fail also to bring away a portion of the cartilage, and to a greater or lesser extent destroy Meibomian glands by cutting across their orifices. But this can operate to a prejudicial extent only when the greater part, or the whole number of them are so cut, and can scarcely apply to a limited or partial operation of excision, which may so often be advantageously resorted to when it is expedient to get rid of a cluster of lashes.

This display of the cilia, in Fig. 26, by the removal of the

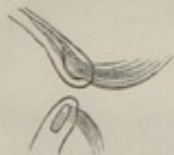Fig. 26.



integuments and muscle, may usefully remind surgeons of their position on the cartilages. The lids are supposed to be laid flat, and the lower cilia are turned up to afford the best view. The irregular manner in which they are planted in the dense fibro-cellular tissue, admits the entire extent of only the most superficial to be exposed. The specimen was taken from an adult female, and the natural size has been preserved.

This second diagram shows the edge of the lids in profile, and exhibits the relations of the several parts.

Fig. 27.



For partial excision of the cilia, the lid should be secured as in the operation for the removal of skin; an incision is then to be made on either side of the bunch to be taken away, long

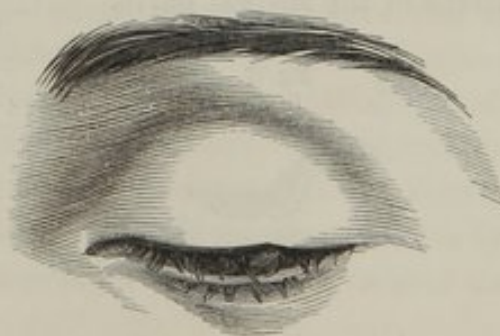enough to reach beyond their follicles and through the skin and orbicularis muscle, and a third transversely, at the very edge of the lid, falling in with the two vertical ones, as in Fig. 28. The little flap is raised and intrusted to the care of an

Fig. 28.



assistant, who keeps it turned up with an instrument or his finger, at the same time treating it with delicacy; directly the bleeding is checked, the mass of follicles, with the investing tissue, should be carefully hooked with the tenaculum forceps and dissected out. The flap is then to be restored and retained by three sutures, one on each edge. This is somewhat different to Vaccà Berlinghieri's plan. Unless the skin is raised to a greater extent on all sides than will merely uncover the cilia, there would be a deficiency of space for efficient operating, and the base of the flap would not be of sufficient breadth to insure its vitality, and I generally make it broader than the apex. The destruction of healthy cilia is inevitable; no one who has dissected the edge of the lid, and made himself conversant with the relations of the cilia, will credit any method of operating by

Fig. 29.



which it is proposed to remove a given number of irregular lashes, without injuring contiguous ones. I hold that more may be saved in this manner, in the method I have described, than

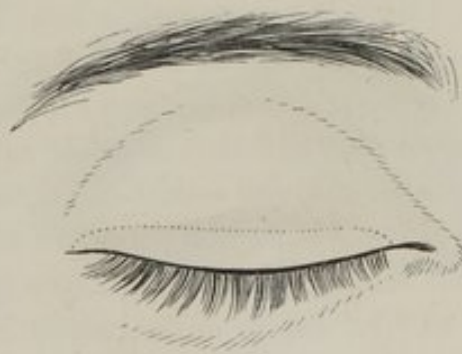by any other yet advocated. The above illustration of partial removal was taken four months after operation.

The patient, a female forty years of age, had been long tormented by ten or twelve cilia that rested on the globe; they were very minute and white, and grew directly inward; she had given a long trial to the cilia-forceps. The removal of a bit of skin to turn out the tarsus was not applicable.

It is an operation of old date to remove a portion of the entire thickness of the lid with the cilia, and occasions much deformity. M. Tyrrell, who had much experience, after advising the measure, where several cilia are inverted together, says, "Such a plan is not, however, advisable when there are many cilia remaining, as the contraction of the new cicatrix is very likely to produce inversion of some of the neighboring hairs. The patient must therefore be contented with having them extracted with forceps whenever their growth occasions the slightest irritation."

The entire excision of the cilia is called for where there is inversion of the hairs in more than one place; when one partial excision would be insufficient; or when there is inversion to

Fig. 30.



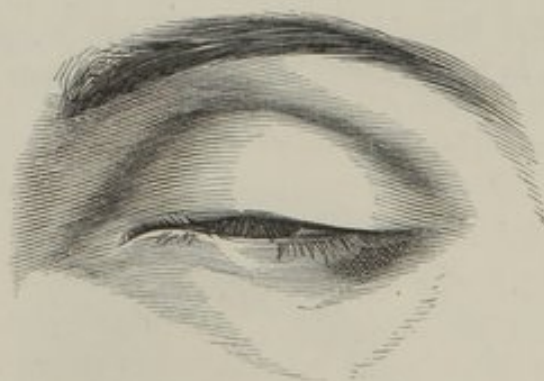a considerable extent. The indications are to remove the cilia with as little damage as possible to the tarsal cartilage, and to leave the punctum lachrymale untouched. The preliminary fixing of the lid is to be accomplished precisely as in the foregoing operation; supposing the eye to be the right, an incision is made, as in Fig. 30, through the skin and the muscle, at about

the eighth of an inch beyond the margin of the lid from opposite the most external cilia at the outer angle, nearly to the punctum; the inner end is then to be held with the forceps, made tense, and the skin, muscle, and cilia dissected off in a vertical direction. The dotted line in the engraving expresses the direction to be taken.*

The execution is necessarily slow from the frequent demand for the sponge, and the care that is required for the safety of the cartilage. Should any of the cilia-bulbs escape detachment, a point ascertained by scrutinizing the denuded surface, they must be removed. It is seldom that a few fine hairs at the inner corner of the lid are not left; indeed such must happen when they grow over and a little beyond the punctum; but it matters little, as they are very rarely inverted; and may be eradicated if they cause any inconvenience. The edge of the cartilage and that of the skin, are brought together with accuracy by a few sutures.

Here is an example of incision in both lids; in the lower, which was operated on by a surgeon since deceased, the inten-

Fig. 31.



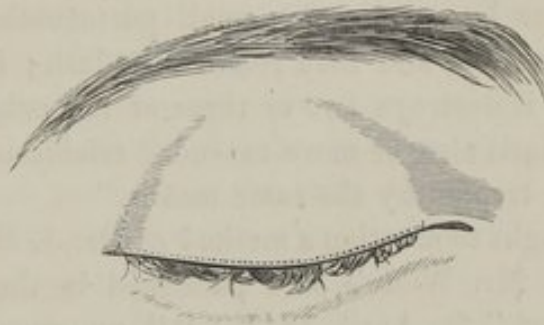
tion was not quite fulfilled, for the greater number of the cilia escaped the knife, the central ones only having been removed,

* This operation is also recommended by Professor Jaeger as a radical cure for complete Trichiasis, and should be so performed as to include the bulbs of the cilia, without involving the mucous edge of the lid.—Ed.

and when there was a fresh growth of those that had been merely cut across, trichiasis was re-established. The removal of a portion of the skin from that lid rectified the evil. The upper lid was operated on by myself. It was considered that a sketch with the lids approximated, would give the best representation.

I have lately practised an operation which I consider an improvement on this the most usual method, since it saves the skin and preserves the natural appearance of the edge of the lid. Three incisions are made after the manner indicated in the diagram (Fig. 32), one at each corner, and one close along the mar-

Fig. 32.



gin of the lid; the flap of skin is then raised and held back, the cilia dissected off, and a few sutures applied. It requires great caution not to allow some of the cilia to escape; and unless the tenaculum forceps are used, and the sponge is nicely employed by the assistant, so that the operator may clearly see the several steps of his course, some lashes are likely to be left behind.

Other methods of treatment have during centuries accumulated into a long catalogue. They consist for the most part in different kinds of cauterization of the lid,* or of the cilia-bulbs,

* As benefit is sometimes derived in slight cases of trichiasis from cauterization with nitric acid, it may be well briefly to state that in performing the operation, the head, properly supported, being thrown backwards over a chair, a pencil of wood of the size of a crow-quill is cautiously drawn along the lid near its margin, and the process repeated until an eschar is formed of sufficient depth, about one-fifth of an inch broad in the centre, and of a length corresponding with the inversion. It is a mode of treatment more painful than excision, and better adapted to the upper than to the lower lid, because of the greater sensibility of the latter.—ED.

with the actual cautery, or escharotics; but the greater part of them are obsolete, and need not be further mentioned. Others are, in my judgment, far inferior to those I have advanced, with the exception of that of Mr. Wilde, which I have not tried. In a paper on entropium and trichiasis, in the "Dublin Journal of Medical Science," for 1844, that excellent surgeon writes: "A single lash, or one or two lashes, will sometimes turn in upon the eye and produce the greatest annoyance; the patient gets tired of plucking them out, and applies for surgical relief. In such cases, placing the horn-spatula within the lid I make an incision with a small knife down to the root of the inverted lash, and, having waited till the hemorrhage has ceased, I apply a point of nitrate of silver by means of a small portcaustic, down to the bottom of the wound, and then remove the lash; it seldom fails, but frequently it destroys two or three of the neighboring cilia. Partial distichiasis also, or more extended trichiasis may likewise be successfully treated by the same means."

Perhaps I ought to mention a method of Dr. J. Hunter's somewhat allied to Mr. Wilde's, and published in the "Edinburgh Monthly Journal," for April, 1841. "A puncture is made over the bulbs of the cilia that offend, and tartar emetic is introduced on a probe, which is charged with this substance by first coating it with a thin layer of sealing-wax, and dipping it when hot into the powder. The cilia are then plucked out. Subacute inflammation is induced, and the cilia-follicles perish."

I do not formally propose to improve a patient's appearance by supplying cilia for those that have been removed either by the surgeon's hand, or by the disease; but it may not be amiss to introduce a passage on the subject, which occurs in a review of "Dieffenbach's Operative Surgery," in vol. xxi. of the "British and Foreign Medical Review," under the heading, "Transplantation of the Eyelashes."

"It has been established by experiment that strong hairs freshly plucked, take root when they are inserted into small oblique punctures, and protected by slips of plaster. The hair must be strong and young, not just about to fall away. Gray-

ness of the hair is of no consequence, as it is the age of the hair, not the individual that is to be considered. Dzondi was the first to apply these physiological facts in practical surgery, planting a row of cilia upon an artificial eyelid. Dieffenbach does not appear to have followed his example, but he says, to increase the satisfaction of the patient in a case of successful blepharoplasty, the necessary quantity of cilia might be plucked from the other eye by forceps, and inserted in small oblique punctures half a line in depth, made along the border of the lid, the parts being then covered by fine straps of plaster."

If the follicles are perfect at their base, there is no reason why the hairs should not draw a parasitical life from the living tissues in which they are embedded. The experiments of Duhamel, who frequently succeeded in fixing the amputated spurs of one cock upon the comb either of the same animal or of another; and those of John Hunter, who at one time engrafted human teeth upon the same nidus, and at another produced adhesion between the extracted testicle of a cock and the peritoneal cavity of a hen, seem to favor the supposition.

Again, it is to be borne in mind that the bulb of the hair is an extra-vascular and extra-nervous organ, and in its normal position obtains its nutritive fluid by endosmosis; it is, in fact, a growing epithelial organ.*

ENTROPIUM.

Entropium, or turning in of either of the eyelids, may arise from various causes, such as wounds, injuries, and abnormal growths. There is, however, so little remarkable in this affection, so little to be said in the way of generalization, and the treatment always so obviously in accordance with the general principles of surgery, that I pass it over, and proceed to idiopathic entropium, about which there are numerous theories and dissimilar views, both as to the mode of production and treatment.

* We should hardly have expected to find in a work like the present, favorable notice of a proposition so impracticable as that of the transplantation of the cilia.—ED.

Of the many opinions respecting the presumed origins of this derangement, some are obsolete, and need not be recounted; but others, such as relaxation of the skin of the lid, thickening of the palpebral conjunctiva, shrinking of the tarsal cartilages, occasional faulty action of the orbicularis palpebrarum muscle, combined with one or other of those states, are entertained, and are ingeniously advocated by their several propounders. I question the soundness of these speculations, but admit that there is reasonable probability in that which ascribes the disease to faulty muscular action.

To say, that looseness of the skin allows inversion of the tarsus, would be to affirm that, in a healthy eye, the skin is antagonistic to some power acting on the lids; a statement unphysiological and erroneous. The skin of the lid is never tense, but always loose, as a natural provision for their unrestrained movements; and this is especially exemplified in the upper lid, where the motions are freer than those of the under. Moreover, it is singularly thin, and apparently devoid of elasticity; or, at most, possesses it in a minimum degree; and were it required to show more than this, I might point to the baggy and even sometimes pendulous state of it in advancing life, coexistent with the perfect integrity of the ocular appendages.

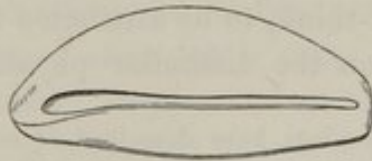
The supposed influence of the palpebral conjunctiva in producing inversions, has been taught for more than two hundred years; and the same view has of late been put forth by Mr. Wilde, in a clever and highly instructive communication to the "Dublin Medical Journal," for March 1844, and since published as a pamphlet, by Messrs. Hodges and Smith. But it appears to me, that the morbid changes the conjunctiva may exhibit in these cases, are merely the effect of the general irritation of the eye, due to the inversion; for in incipient entropium, when the irritation of the cilia is confined to the conjunctiva of the globe, I have not been able to satisfy myself of any condition of the palpebral conjunctiva that may not be seen in a healthy eye. After a time, which varies according to

circumstance, when the entire conjunctiva is involved in that general inflammation which is sure to ensue in the progress of the affection, the lids exhibit various morbid appearances, which, as far as I can make out, differ in no respect from those the result of inflammation from other causes, and from which the lid does not become curved.

That the unnatural state of the lid may depend on some primary change in the shape of the tarsal cartilage, seems most probable, and is that most generally received as true. To examine into its correctness is a matter of some difficulty; cases should be chosen for the investigation in which the tarsal cartilages have not suffered from disease, and there will be no difficulty in finding such.

It will simplify the inquiry even more to look principally to an inverted lower lid, because that lid offers a greater facility for observation, as the natural direction of its border is outwards and away from the globe; and any change in its direction can be better appreciated than in the upper, where the margin inclines somewhat inwards. Besides, there is a very marked difference in the size of the two cartilages, and which may throw additional light on the inquiry, the upper being considerably broader than the under, as the outline of them in Fig. 33 shows.

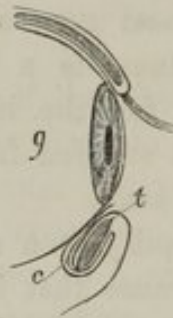Fig. 33.



In the most marked or aggravated stage of entropium in the under lid, the tarsus does not rest against the globe as though it bound it, because it is contracted; but the lid is so completely turned on itself that the cilia are hidden, and the narrow cartilage rolled up in the lid, and its position completely reversed. It is dislocated in a manner which I attempt to explain by the following diagram.

It is evident, from the narrowness of the cartilage, that no curve of it, nor any kind of contraction could produce these changes in the lid. But, more than this, I have never been able to satisfy myself that the cartilage is ever altered or modified; and if not, it cannot have any degree of influence in producing the inversion.*

Fig. 34.



g. The eyeball. *c.* The cilium. *t.* The tarsal cartilage.

In entropium of the upper lid, the inverted cartilage rests against the globe, and the convexities of the cilia are then on the cornea, while their extremities are directed outwards, a position that their ends assume from the handkerchief being used in that direction during the frequent calls for its application. In some aggravated cases they lie spread out on the globe of the eye. Now, this difference in the direction of the edges of the lids ought not, I think, to be attributed to dissimilar causes, but to those acting on the dissimilar physical constructions of

* The variety of entropium here described is evidently caused by the action of the orbicularis muscle, and differs from the more chronic or inflammatory inversion in several important particulars:—it is confined to the lower lid, which can easily be made to resume temporarily its natural position; is unaccompanied by any change of structure; is never complicated with trichiasis; and occurs for the most part in old persons in whom the integuments are relaxed and the lining membrane thickened, or in children as the result of strumous conjunctivitis. Dr. Jackson, of Northumberland, records the case of his own son, a lad four years of age, in whom the lid became completely inverted from this cause, and was retained in its malposition by the concurring action of the globe and orbicularis for the period of several months. The involution is attended with less irritation than the partial inversion.—Ed.

the lids. Thus the upper cartilage is curved on itself because its breadth does not allow it to be rolled up, like the cartilage of the lower lid.

The influence of muscular power in causing entropium has been regarded merely as a partial and secondary cause, blended with some one of the supposed primary causes that I have examined; the general opinion is, that its detrimental action is induced by tegumentary disarrangements, by relaxation, or by swelling of the skin over the upper part of the lid, by which its influence in supporting the muscular fibres of that part is lost, while the remainder of the muscle on which the skin yet acts continues its function, and rolls the edges of the lids inward. The assertion that the action of the orbicularis depends on the binding of the skin is thoroughly untenable.

The similarity of curvature in every case of entropium, the implication of the whole lid, and the symmetry of the deformity, induced me to attribute all forms of the affection to one and the same cause—that of muscular action; but doubting the power of that part of the muscle situated on the edge of the lid, which is described as the thinnest portion of the orbicularis, to exercise such an action,—and from that part alone could such effect be produced,—I made dissections, to satisfy myself of its real nature. I found that over the edges of the lids, for about the sixth of an inch, the muscle is thicker, perhaps twice as thick as over the remainder of them, as is usual in a sphincter; the fibres also were redder, larger, and more compact. In the lower lid this marginal portion is greater, and the fibres lie irregularly in bundles.

This fact seems to have been overlooked by modern anatomists, although it was noticed and even figured by the sagacious Albinus, and I suspect that he was the first author with whom originated the name, *musculus ciliaris*, thereby signifying a distinct muscle. Although this term has been retained, it is not generally used in the sense to which Albinus restricted it. Thus the late Mr. Dalrymple, in his “Anatomy of the Human Eye,” says :—

"The few pale and horizontal fibres which immediately cover the tarsal cartilages, and which are continued to the edge of the palpebral fissure itself, have received the name of *musculus ciliaris*." Albinus's muscle, on the contrary, is confined to the edge of the lids.

About the time that I was investigating this muscular origin of entropium, one of my colleagues at the Central London Ophthalmic Hospital showed me that he could, by the influence of the will, invert the edges of both his lower lids, produce the most complete entropium, and conceal his long and numerous cilia. Of course this greatly strengthened my opinion, and I did not hesitate to regard my idea of the cause of entropium as correct. After that I made some dissections to ascertain the relation of the tensor tarsi muscle to the orbicularis, and was not a little surprised to find that it has an extensive connexion with that muscle, and may justly be considered a part of it—that part which has a bony attachment. The correct anatomy, and the relations of the supplemental portion of the muscle, have hitherto not been correctly understood; but the existence of it was well known to the older and generally more minute anatomists, in proof of which I would merely quote Duverney's "*Œuvres Anatomiques*," Paris, who wrote and lectured in 1761. But it came to be neglected or overlooked, with much of the minute anatomy of the times of Santorini, Morgagni, De Graaf, and a host of others, until public attention was again called to its existence by Rosenmüller, Thiele, and Horner.

Duverney, in describing the lachrymal sac, and the fibres of the orbicularis muscle connected with it, says, tom. i. p. 130, "Besides these fibres, there is a small muscle within the greater angle which arises from the anterior point of the os planum, and is inserted or attached to the internal curvature of the common tendon of the opposite side of the orbicularis. It is a small muscle which I observed a long time ago." Horner, who has for a great many years claimed the discovery, which, as I have shown, was made and published before he was born, appears to be ignorant of its exact bearings. In his latest writings that I

can meet with, apparently the last edition of his work on Anatomy, bearing date 1846, after the principal description of the muscle, which is made to end at the puncta lachrymalia, he adds, "The superior fork, however, has a few of its fibres blended with the orbicularis."

In Arnold's beautiful "*Tabulæ Anatomicæ*," the muscle is noticed as a small triangular slip, with the apex towards the corner of the lids, where it is made to terminate.

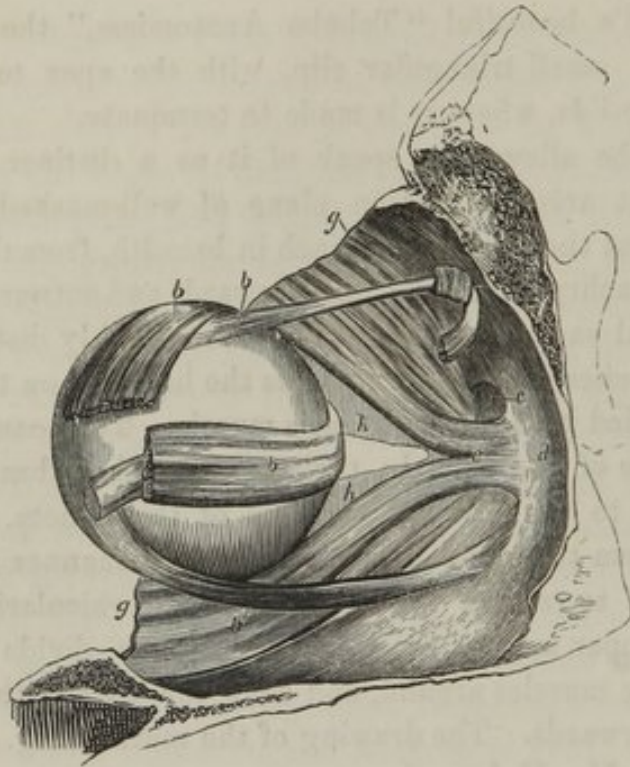
If I may be allowed to speak of it as a distinct muscle, I should say it arises as a thin plane of well-marked muscular fibres, of about the fourth of an inch in breadth, from the vertical ridge on the lachrymal bone, passes forwards and outwards towards the lachrymal sac, and bifurcates in a remarkably distinct manner, the branches proceeding towards the lids, and on their edges become blended with the orbicularis muscle. They can be traced to the middle of the lid. In their passage, their branches distribute fibres to the posterior surfaces of the puncta, and some few would seem to surround them. The best manner of tracing the muscle is to remove the skin from the orbicularis, then to detach the upper and outer walls of the orbit, divide the optic nerve and the muscles around, and draw the back of the eye outwards and forwards. The drawing of the muscle (Fig. 35), taken by my friend Mr. Hulme, gives a very accurate representation of its relations; it was here remarkably developed, indeed the subject was on that account chosen for the purpose of illustration from five which were dissected.

It also shows its relations, the blending with the orbicularis on the one side and the bony attachment on the other. It displays the source of power that acts on the edges of the lids, and enables an idea to be formed of its probable pathological influence. So great is the variation in the development of this muscle, and also of the *musculus ciliaris*, that occasionally it is scarcely possible with the naked eye to recognise the muscularity of their fibres.

It is not surprising that, as the anatomy of the tensor tarsi had not been ascertained, its physiology was only partly under-

stood, and no pathological state conceived. As far as I can ascertain, with the exception of Dr. Physick, who took the most extended view of its action, and justly supposed that it must

Fig. 35.



Back view of the orbit; the vessels and nerves have been removed, and the eye drawn outwards, to show the origin of the tensor tarsi muscle.

a, Globe of the eye.

b b b b, Superior oblique, inferior oblique, internal and superior recti.

c, Lachrymal sac.

d, Muscular origin of tensor tarsi.

e, The bifurcation of the muscle, the branches of which give a few fibres to the puncta, and after coasting the edge of the lid, blend with the fibres of the orbicularis.

g g, The orbicularis palpebrarum.

h h, Tarsal cartilages, on the anterior surface of which the united tensor tarsi and orbicularis muscles pass.

exert some influence on the movements of the lids, writers have confined its use to the apparatus for conveying away the tears.

In the last edition of Dr. Quain's "Anatomy," by Dr. Sharpey, 1848, it is called *musculus sacci lachrymalis*.*

Although now satisfied as to the true cause of entropium, it is as difficult, nay, impossible to decide what are the circumstances that bring about such unequal and prejudicial action of the orbicularis, as to account for squinting, or any other deformity, the result of perverted muscular action. These occur without the perceptible influence of any cause; and the most that can be said of them is, that sometimes they follow other pathological phenomena of common occurrence. They are then regarded as exci-

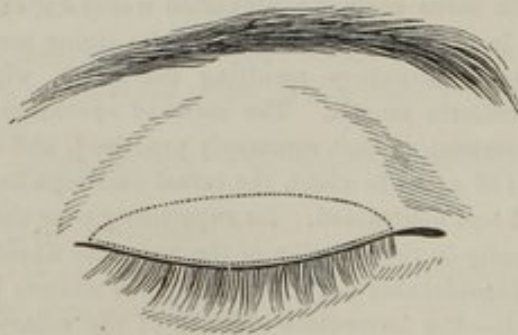
* If the muscle delineated by Mr. Hulme be not greatly exaggerated, it must have been unusually developed in this particular instance, and a rare or abnormal condition is no proper foundation for a theory, however ingenious it may be. The late Dr. Horner, to whom the credit is due of having recalled the attention of anatomists to a long-forgotten fact, speaks of the blending of a few of its fibres with the orbicularis; Rosenmüller has occasionally observed several delicate fibres extending as far as the lachrymal canals; Mackenzie describes a few thin fasciculi running along the lachrymal canals, and terminating near the puncta; and the Author states that the variation in its development is so great that it is sometimes scarcely possible with the unassisted eye to recognise the muscularity of its fibres. Dr. Physick suggested that one object of the muscle, besides its action on the lachrymal sac, was to maintain the lid in contact with the globe; but how far it may be instrumental in producing the incurvation of entropium, is a question which, we conceive, still remains to be decided. The more correct explanation would appear to be, that this affection originates in chronic inflammation of the lining membrane of the lid and the alterations of structure resulting therefrom, with the concurring agency of the orbicularis muscle. The mode of operation proposed by Mr. Walton is an improvement on that commonly practised, and is applicable to all that numerous class of cases in which the tarsal cartilage has not become permanently indurated and contracted. Its superiority over the ordinary method may consist principally in the ablation of the muscular fibres, but it is attributable also, in no inconsiderable degree, to the place whence the excision of the integuments is made—the immediate vicinity of the ciliary border—and the more exact and effectual manner in which the removal is accomplished. In regard to the division of the cartilage, excision of the cilia, &c., though we have never had occasion to adopt these procedures, it may be observed, that it is easy to imagine cases of inveterate perversion, in which the *modified* expedients of Ware, Crampton, Wilde, and others, so summarily discarded by the author, and often, we doubt not, unnecessarily performed, might be the only practicable resort.—ED.

tant, and, in the case of entropium, conjunctival inflammation would seem to stand in that relation.

I have founded the treatment on what appears to me to be the pathological interpretation of the affection, and of which the indications are, to overcome the means of the inversion by dissecting away the thick marginal portion of the orbicularis, supposing that part of the muscle to be entirely, or nearly all that is at fault; and also to remove as much of the skin of the lid as may be necessary to produce such tension as shall overcome the deformity which other tissues of the lid may have acquired, from the irregular position into which they have been thrown by the muscle, and which has been made more or less permanent by the changes induced by inflammation.

Now as to the manner of operating:—let us suppose that the right eye is to be rectified. An assistant stands behind the patient, and having made the lid tense, by drawing it outwards and raising the brow, as is shown in the operation for trichiasis, the surgeon should make two incisions through the skin and muscle, in the course indicated by the lines in the diagram (Fig. 36).

Fig. 36.



The flap thus isolated should be forcibly drawn forwards and slowly dissected by vertical strokes of the knife from the one side to the other, and not taken away by horizontal strokes, or else the muscular portion will not be effectually removed. The wound should be very carefully sponged during the operation.

Any arterial jet must be checked by temporary pressure with the finger. I have never found a ligature to be necessary. The exposed surface must be inspected, and if any muscular fibres have escaped, the forceps and knife must be reapplied. The assistant should continue the proper retraction of the skin till the knife has been laid aside, as essential to steady and effectual dissection. Three or four sutures should be used, and if a patient desires some local treatment, water-dressing may be employed. I have operated in about fifty cases, and not in a single instance have any bad symptoms supervened. In all there has been union by first intention. Various moral and physical states of individuals require different constitutional treatment. Those who are nervous and highly excitable had better be kept quiet for a day or two, with the lid in as perfect a state of rest as possible. One class of patients will resume their usual avocations directly after the operation, while another will require a cessation from all activity.

The surgeon and his assistant must take their positions according to the eye to be operated on. Sometimes, and especially if the patient be lying, the operator may find it better to stand behind, and the left eye may thus be more readily reached.

The cilia might appear to be in danger of being dissected off, but in reality they are not. A part only of the dissection is over them; and the muscle is readily raised, in consequence of its looseness, from the dense fibro-cellular tissue in which the cilia lie.

I shall cursorily review the usual methods of operative treatment; for I think that, not only do the preceding observations demand it, but the advantage of the operation I have given will be better set forth, while an opportunity will be afforded for examining several further points. The operation most commonly resorted to, is the removal of a transverse portion of skin, by pinching it up with the finger, or by an instrument invented for the purpose, entropium forceps, as they are called, and cutting it off with a pair of scissors; or by destroying the skin

by a caustic, or the actual cautery, and thereby producing contraction.

That some improvement occasionally follows such contraction of skin, and that more frequently in the lower than in the upper lid, I am perfectly aware; but it is apparent in incipient cases only, and then it is for the most part temporary. In all well-marked instances, the above-mentioned methods scarcely improve them in the least. It is true that excision of the skin from the lower lid, to a considerable extent, may always be effectual in removing an entropium from it, owing to the configuration of its cartilage, as pointed out. But then to bring about this alteration by the removal of the skin alone, the lid must actually be depressed or everted; and thus one evil would be exchanged for another.

Then there is the division of the lid at the outer angle, or the vertical division of the cartilage at the centre, after the manner of Ware. Also the vertical division of the lid on each side, the horizontal incision of the conjunctiva, and the elevation of the lid by an instrument called the suspensorium palpebrarum, a sort of elevator, during the healing process, after Sir Philip Crampton's plan; or the still severer method of dividing the tarsal cartilage of the upper lid longitudinally as well as vertically, of the under lid vertically only, taking away a fold of the skin of the lid besides, and fastening the lid to the brow, or to the cheek, as the case may be, by means of ligatures passed through its edge, and then secured by strips of plaster, for the space of eight or ten days, as recommended by Mr. Guthrie, followed up by frequently touching the incision with sulphate of copper to prevent any union except by granulation. But all are uncertain in confirmed entropium; for, with the cicatrization, the power of the muscle is wont to be renewed, and the entropium returns. This was proved nearly forty years ago by Mr. Saunders, who, after frequent trials, abandoned them, and recommended, when the upper lid was affected, excision of the whole tarsal cartilage. Mr. Wilde has recently and most ably taken similar views. One of his cases, in the person of a young female, had been under

the hands of Mr. Guthrie himself. The upper lid curled up, the lower lid fell down, and the patient suffered from all the horrors of a double ectropium. From my own personal knowledge, I could advance several instances of its utter failure,—in all the upper lid had been affected. When it does succeed, and which is only, as several authors seem to admit, in incipient entropium, there is danger when the portion of the orbicularis muscle over the lids does not, in some measure, recover its integrity, as Mr. Wilde has shown by a remarkable instance narrated and figured, of the sphincter power of the lids being lost.

Another mode of treatment is the excision of the cilia; and this not only removes the principal and direct source of irritation, but may also withdraw the cause of the misdirection of the cilia, by the correction of the distorted tarsus. But the loss of the cilia is an evil; and by their removal mischief arises of perhaps greater moment from injury or destruction of the Meibomian glands. As I said with regard to trichiasis, it is not possible, in the living subject, to avoid such a result.

In answer to the objection concerning the efficiency of this operation to influence the inversion of the cartilage, it has been said that the edge of an inverted cartilage in no way affects the eye except by means of the hairs set upon it. I cannot admit such an unqualified assertion. In some cases of entropium of the upper lid the edge of the tarsus undergoes certain changes, and is rendered thick and hard, and there cannot be a doubt that such a state is in itself a source of irritation to the eyeball. I have had several such cases in adults, in whom the cilia had been lost in childhood, from the same cause that affected the structures of the tarsi, and on whose opaque corneæ the symptoms of entropium were manifested. To prove that I attributed the effect to the proper cause, I may mention that in three of the cases in which I operated, one was soon enabled to walk alone to the hospital, and of two, who had been so incapacitated for work as to seek refuge in the St. Pancras Workhouse, one has happily left for her usual avocation, and the other has gained as much benefit as the power of reparation could afford, in the state to which the

cornea had been reduced, and the improvement was beyond anticipation. During the last year I operated for the same cause on a lower lid of a female, from whom the cilia had been excised five years before.

The discrepancy between these statements and those of Mr. Wilde, may, I think, be in a great measure, if not entirely reconciled. With the removal of the cilia after his method, on the upper lid especially, he must frequently, in milder cases remedy the curvature of the tarsus; since the excision of them cannot be effected without also removing a large portion of the musculus ciliaris and skin—doubtless enough in many instances to influence the entropium, and remove the cilia from the globe when uncomplicated with trichiasis. Again, a portion of the edge of the lid is also removed; for, as I have observed, it is quite impracticable to excise the cilia without doing that much. Hence it is apparent how, in the early state of entropium of the upper lid, with yet but slight alteration in the cartilage, that the operation in question may be effectual, and how it may be remedial even when the edge of the lid is unhealthy and thickened. And as regards the under lid, the effect of entropium is generally so slight, compared with that of the upper, and so much of its severity depends on the contact of the cilia on the globe, that after their removal the case is exceptional which produces more than slight inconvenience. Thus, then, it would appear that this is the best of all the old operations, and such it certainly is; yet it possesses very serious drawbacks in the loss of the cilia, the somewhat shortening of the lid, and the destruction to a greater or less extent of the Meibomian glands. There is yet an explanation needed regarding the supposed frequent success of various kinds of operations for entropium. I hope to be pardoned if I offend in giving what appears to be the solution. A large proportion of the so-called entropia are in reality cases of trichiasis. In the upper eyelid of the aged the skin is apt to overhang the cilia at their bases and simulate entropium, and if with that there be trichiasis, an incorrect diagnosis is very probable. And a somewhat similar deception is likely to occur in the young, when with the inversion

of the hairs only, the skin of the lid is swollen from the inflammation that the trichiasis excites.

Cutting off the edge of the lid along with the cilia partakes of the imperfections of ordinary amputations; and in its kind even surpasses them in evil from the physiological relation of the lid, and the adaptation of its edge, to the other parts of the visual apparatus: as a general principle it would be even worse than removing a thigh to cure popliteal aneurism, or a leg to remedy a distorted foot. Although its general application is to be reprobated, the peculiarity of a case, and the limitation of our resources, may render its especial adoption expedient, and even to be preferred to the last operation. If any case calls for such an extreme measure, I imagine it to be that of severe curvature of the tarsal cartilage of the upper lid with considerable and extensive changes in the physical character of the edge of the lid from long-continued inflammation, by which it has been rendered very thick and very hard, and unlikely to yield to other means of remedy. I cannot conceive that excision of any portion of the tarsus can ever be required in the lower lid.

This exception is founded on the case of a female thirty-two years of age, that occurred at the Ophthalmic Hospital last summer. Both the lids of each eye were inverted, the lower ones were but very slightly affected; however, with the upper only is the present question concerned. In the left eye the cornea had a ligamentous appearance, the last condition of the effects of entropium, and the globe was collapsed. There was that exemption from pain which follows such a state, yet enough of uneasiness to render remedy desirable. The conjunctiva of the lid was granular, the edge of the lid uncommonly thick and very hard, the margin of the cartilage was involved, and eversion was not readily effected. I deemed it prudent to excise the edge of the tarsus. In the right eye the cornea was ulcerated and semi-opaque. There was the same amount of inversion of the lid, and the entire edge of the tarsus was in a manner affected like that of its fellow,

although somewhat less in degree, yet approaching it sufficiently to offer nearly the same resistance to eversion. I trusted to the operation I have so strongly advocated, to overcome the inversion, and the lid was necessarily raised by loss of skin to an extent that equalled in effect the removal of cartilage in the other. Had it equalled the left in disease in all respects, excision of the edge of the tarsus would have been, I imagine, the proper expedient.

Heretofore, when an operation for entropium has been undertaken with the design of removing any part of the orbicularis palpebrarum muscle, it has been executed on different principles, and in a manner very different from that I now advocate, and with results most dissimilar. The marginal part of the muscle, the musculus ciliaris, has been untouched, and only a portion on the centre of the lid has been snipped out. The only exception I know of is in the practice of Mr. Key. I am astonished that the notice of the operation he performed, and which is in the "Lancet," for 1825, p. 235, should have escaped the attention of English writers on ophthalmic surgery. It is very lately that I became acquainted with it, long after I had matured my own views. I cannot say whether he continued to execute it, and what were his ideas on the subject in later years. The report runs thus,—“Mr. Key considered the inverted state of the tarsus to arise from the action of the orbicularis palpebrarum muscle. With that view he determined on laying bare the substance of the lower tarsus, and dissecting off the fibres of the orbicularis. The operation was performed by first turning out the lid, and then making an incision through the skin along the whole length of the lower eyelid, at a few lines’ distance, and below the ciliary ridge; the integuments were carefully elevated by means of dissecting forceps, and the fibres of the orbicularis thus exposed, were as carefully removed. There was considerable bleeding from the parts; the portion of skin which had been raised was laid down, and the wound dressed by means of adhesive straps, with a compress applied on the skin.” The result is said to be successful. Mr. Tyrrell and

Mr. Travers had operated previously, the first by cauterization, the second by removing a portion of skin, without success.

M. Desmarres has not overlooked the influence of the orbicularis in producing inversion, and gives a case which he thinks solely due to it; but he does not recognise its general operation, and he significantly indicates how little he appreciates the principle of Mr. Key, and the triumphant issue of the case, by asking in a commentary on the proceeding, "Is it to the incision of the skin, or the excision of the muscle that the success is owing?" Spasmodic action of the muscle is spoken of by foreign authors, but with much difference of opinion concerning its frequency in producing entropium.

The usual continental mode of operating on the orbicularis, is subcutaneous incision, which seems to have been unsuccessful; and M. Janson de Lyon cuts out several vertical portions of skin, including some fibres of the orbicularis.

Dr. Mackenzie, in his only notice of operating on the muscle, informs us that it may be proper after removing the cutaneous fold, to snip off a few fibres of the muscle, so as to form a firmer cicatrix, actually fixed to the cartilage; and Mr. Lawrence, a much later author, echoes the same thing when he writes,— "In an incipient case, it may be sufficient to excise a portion of skin; this remedy will, at least, answer the purpose for a time. To make the operation more effectual, a portion of the orbicularis should be removed also, that a firmer cicatrix may be produced; or the acid may be employed, using it more freely, so that its action may extend deeper, and a solid scar be the result."

Mr. Middlemore seems to approach somewhat nearer to my own views. He writes,— "The method of curing entropium arising from hypertrophy of the orbicularis muscle consists in cutting through the palpebral integument quite down to that muscle, and removing a portion of its fibres corresponding to the extent of the entropium, with the curved scissors." Here the fault is evidently attributed to the whole of the muscle on the lid, and a state spoken of, hypertrophy, the existence of

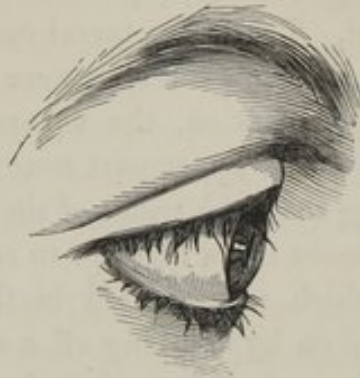which I very much question. From Mr. Middlemore's description of the operation, I cannot conclude that the *musculus ciliaris* is to be dissected away, but rather, a strip of the muscle on the body of the lid, in amount corresponding to the extent, that is, the severity, or the degree of the inversion.

Inversion of the upper eyelid produces severer symptoms than that of the under lid; because of the constant contact of the cilia with the globe in all the stages of the affection, and in certain cases from increased irritation due to thickening and induration of the tarsal edge. A feeling of something in the eye, followed by ulceration and opacity of the cornea, and either partial destruction of the eye for visual purposes, or loss of vision from opacity of the cornea, or of changes in its entire parts, resulting from general inflammation, followed by atrophy, are its symptoms. A common termination is, after months, or it may be years of suffering, for the conjunctiva to become thickened and insensible,—a kind of natural cure, or at least a conservative effect. But the course depends on the degree of the entropium, the condition of the cilia, the state of the edge of the lid, and the constitution on which the local irritation acts.

F. B., a pale, thin, and lax-fibred girl, aged twenty, with abundant lachrymation, and intolerance of light, suffered from entropium of both upper lids; the right was more turned in of the two, and the cilia of each, except a few fine ones at the corners of the lids, rested on the globes. The conjunctivæ oculorum were highly inflamed. The edges of the lids were not in the least thickened, nor was trichiasis present, so that when the lids were turned out, the lashes were nearly in their natural position, being necessarily a little deranged. The upper parts of both corneæ were hazy, the left being the less affected. The effects of the entropia were here very much less developed than would have been expected from the existing cause of irritation, and especially if it be true, which it most probably is, that the entropia had been of long standing. According to her own account she had had bad eyes all her life, and her present con-

dition had existed as long as she could remember. But the mildness of the symptoms was evidently attributable to the paucity of the cilia, their delicacy and their shortness, for few of them were of ordinary length; and to which also must be ascribed her immunity from pain. She had been at several medical charities, and was sent from Clapham to me at the Central London Ophthalmic Hospital, by some ladies on whose bounty she was living.

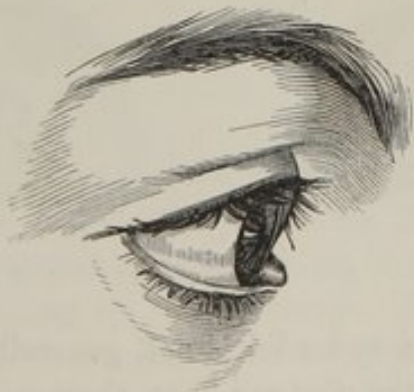Fig. 37.



The Fig. (37) is an accurate representation of the right eye in profile, taken October 24th, 1850, the day before I operated.

I removed rather more skin from this eye than from the left. On the third day the sutures were removed, and patient left the hospital for home.

Fig. 38.

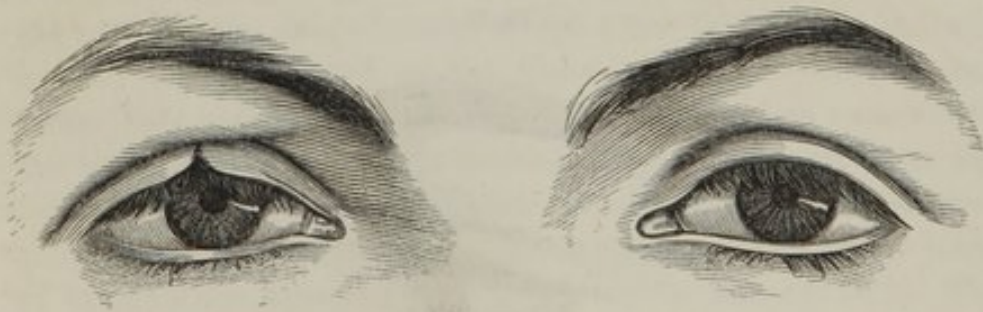

On the 19th of December of the same year, she called to

show herself. Faint scars merely indicated the operations. The lachrymation and intolerance of light, and the conjunctival inflammation had passed away. The right cornea had much improved in transparency, and the left was nearly natural, there being only a little loss of lustre. I now discovered that she was near-sighted. The effect did not arise from any appreciable changes in the cornea. The second sketch (Fig. 38) was taken at the period of the above date; it shows the lid everted, and the cilia raised from the globe.

E. H., a female, aged thirty, a patient at the Central London Ophthalmic Hospital. The upper tarsal cartilage of the left eye was inverted, and nearly all the cilia were resting on the globe, causing considerable irritation, the cornea was ulcerated and hazy. The lid bore on its upper part near the orbit a large and peculiarly disfiguring scar, the result of the removal of a portion of the skin with scissors in an attempt to remedy the deformity. The right eyelid, which was divided in the middle, had been successfully operated on by snipping off a small portion of skin, subsequent applications of nitric acid, and central division of the tarsus. I operated on the left lid, after the manner I have advocated, and with great success, as shown in the following figure (39) of the two eyes.

Fig. 39.

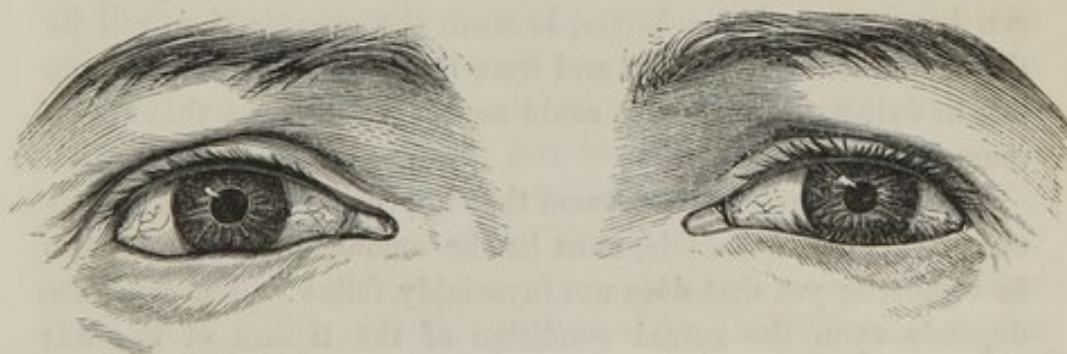

Entropium of the under lid is not, generally speaking, a very serious affection; the cilia are finer, shorter, and less numerous than those of the upper lid, and from their mode of insertion, and

the lowness of the lid, they rarely come in contact with the cornea. When they do encroach on it, opacity is seldom produced, and their presence on the conjunctiva of the sclerotica is less irritating. In well-marked cases there may be no more inconvenience than conjunctival inflammation, with slight lachrymation, and gumming together of the lids at night. Even with perfect inversion the globe does not suffer as in that of the upper lid; because the cilia no longer recline upon it, and the lid being folded inwards, they are put out of the way, and lie between its outer surface and the fold of conjunctiva, which passes from the bottom of the lid to the globe—the sinus, as it is called—a position shown in Fig. 34. But before this state of perfect inversion arrives, generally the globe has become more or less tolerant to the contact of the cilia; because very slight structural change in the conjunctiva, which is soon set up, is sufficient to defend it from their irritation.

The following sketch (Fig. 40), taken from an old man, represents a case of inversion, in which the right lid was completely

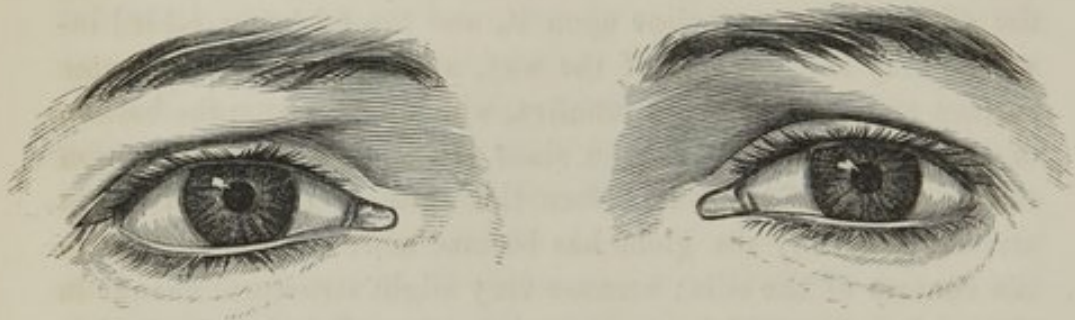Fig. 40.



turned in, and the left only tilted or half inverted, with the cilia on the globe:—M. H., aged sixty-seven. In the left eye the cilia were thrown against the globe, some of which rested on the cornea without sullyng its transparency. The conjunctiva was much inflamed; there was constant lachrymation, a white seed-like secretion at the edges of both the lids, and a sensation of something in the eye. The integument just under the tarsal

cartilages bulged in a singular manner. In the right eye the edge of the lid was completely inverted, there was only slight conjunctival inflammation, trifling lachrymation, and but little uneasiness. Each affection had existed a year and a half. The figure (41) was taken three months after operation.

Fig. 41.



In a very incipient case of entropium, the removal of the muscle alone would probably suffice, but how is such to be detected? It is always the result of an advanced state—the contact of the lashes on the globe of the eye—that induces the patients to apply for relief. The earlier, however, the operation can be performed the better, because the greater then will be the subsequent perfection; and from the after-appearance of the lids in well-treated cases, it could never be imagined that entropium had existed.

It would be natural to assume that in proportion to the degree of incurvation of the lids, must be the amount of integument to be removed; yet that does not invariably follow. The sequence depends upon the actual condition of the tissues of the lid; and in proportion to their relaxed state, must be the means of resistance we create to overcome the tendency to inversion; and in the upper lid especially, the state of the cartilage is of importance, for much depends upon its flexibility being perfect, or impaired. In many cases very little loss of skin will enable us to remove the required portion of muscle. The first case is a good example of this. The principal exceptions are to be found where the edge of the lid is thickened and indurated and not

easily acted upon; and in the entropium of the aged, where, from the retraction and reduction of the eye, perhaps also of the proper tissues of the lid, and the natural tendency to tegumentary folding, the skin cannot be made tense unless a larger portion is removed, but never more than is necessary to reduce the edge of the lid to its correct position. It is wholly unnecessary to produce eversion. The cause of the deformity being taken away, there cannot be a return of the dislocation. I strongly suspect that in many cases disease of the dense fibro-cellular tissue, in which the cilia-bulbs lie, plays no inconsiderable part in producing the permanent curvature of the lids, in which is to be found much of the resistance that is offered.

It is seldom that any trace of the operation is seen after the interval of a few months—sometimes weeks—provided that the edges of the skin have been brought neatly together, and the sutures taken out on the second or third day, and not allowed to be thrown off by ulceration.

The only indication of the former existence of entropium that the lids exhibit, and especially the upper, is the irregular disposition, and staring arrangement that the cilia acquire from having been in contact with the globe, and subjected to its movements. The greater their length, the more abundant their growth; and the longer the duration of the inversion the more is this apparent. Besides this common derangement, which operates principally on their extremities, the frequent plucking out of them in the usual, but ill-directed attempts to benefit the entropium, must damage their follicles, and induce an unhealthy condition and perverted direction, which, although unsightly, and not detrimental when slight, yet when aggravated, cause the serious complication of

ENTROPIUM WITH TRICHIASIS.

With inversion of the upper lid there is not unfrequently decided trichiasis; and, whether the two affections are due to the same exciting cause, or the trichiasis has been the original affec-

tion, or merely an effect of the inversion, it matters nothing so far as the treatment is concerned; yet it may be remarked, that with severe entropium, the edge of the lid can rarely escape being affected by the general inflammation, and hence the cilia will retain any unnatural position in which they may be placed. I am, however, inclined to regard trichiasis more frequently as an effect, because it is generally of one form—that of a separation or twisting in of the innermost of the cilia from their fellows, without any alteration or degeneration in the individual hairs; and because the removal of the entropium is generally sufficient to clear the globe of them. Although, practically speaking, such a degree of trichiasis matters little, it is important before operating on any case of entropium, to ascertain whether there is also trichiasis, and whether the restoration of the lid to its natural position will, or will not, counteract the maldirection of the cilia. Should it not be sufficient, then more skin must be taken from the lid than would otherwise have been necessary, and a slight degree of eversion of the centre of its edge produced, but which must necessarily have its limit. When it is apparent that such moderate eversion will not suffice, the treatment must depend on the degree of the trichiasis; for if it be general, the entropium and the trichiasis must be attacked by one operation, and the cilia excised at the same time, after the rules given under the head of trichiasis. But when the trichiasis is partial—and for the most part it is—the skin and the muscle should first be dissected away, and then the irregular cilia sought for and removed. When there is doubt about the necessity of removing them, the entropium should be alone attended to, and the result observed; because it is not always possible, before the operation for the entropium has been performed, the lid restored, and recovered from any inflammation and swelling that the inversion may have induced, to ascertain with exactness to what extent the trichiasis may be benefited. If, as is commonly the case, a patient applies to be treated for entropium with many of the cilia broken, and some just about to be

reproduced after having been plucked out, it cannot be known what direction they may assume when growing out, and such cases should be watched.

It can be very seldom that the removal of entropium from the lower lid does not at the same time separate any irregular cilia from contact with the globe, for a single exception only has occurred to me. The following case will illustrate some of the foregoing points:—A. C., a female aged forty, with entropium and trichiasis of both upper eyelids of three years' standing; the corneæ are clouded over their entire extent, and studded with minute ulcers. Some of the cilia had been pulled out at various times by another surgeon; but getting worse, and her sight being nearly lost, she came to the Ophthalmic Hospital.

I removed more skin than was sufficient to restore the lids to their natural position, and thereby everted their centres a little, to get the lashes away from their globes; for in nearly all cases of partial trichiasis the central lashes offend. In the right eye the intention was answered; but in the left a central bundle of cilia still encroached on the globe, and which four weeks afterwards I extirpated. In six weeks she was gaining her bread as a charwoman. I have never seen the least unpleasant result from this slight degree of eversion of the centre of the edge of the lid. Excision of the cilia does not admit of being compared with it as a remediable means.

It is only by observation that an adequate idea can be formed of the rapidity and extent of the recovery of the eye, and especially the cornea, from the effects of entropium. From the moment that the cilia cease to irritate all the distressing symptoms begin to yield; and so quickly is repair exhibited, that on the third day, the period when I remove the sutures, cases have not been directly recognised by gentlemen who have assisted me with the operation; the conjunctiva having lost its vascularity, and lachrymation been subdued.

After-treatment is wholly unnecessary, a fact that confirms the statement that the pathological changes in the conjunctiva

are merely the consequences of the entropium, and not an independent affection.

The imperfect closure of the lids is unproductive of any inconvenience. The upper lid having been a little shortened is prevented from completely meeting its fellow; but after a time this is usually compensated for by increased power of elevating the lower lid. But I have seen a failure in this without any perceptible inconvenience.

It may be mentioned as a matter of pathological interest, that Mr. Wilde has met with congenital entropium, which he attributes to inflammation occurring in utero.

ECTROPIUM.

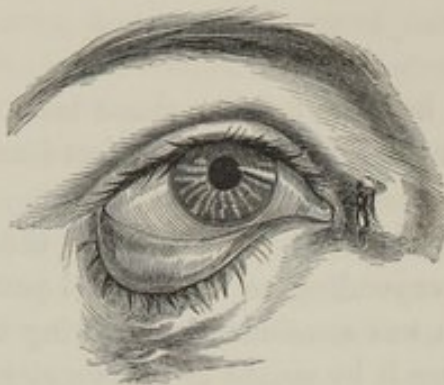Ectropium, or turning out of the eyelid, is the reverse of entropium, and compared with it, is not only more rare, but very much less severe in its effects. In aggravated cases, and especially when both the lids are everted, the eyeball may suffer from want of necessary moisture. In ordinary, or the less severe states, and where only one lid is everted, disfiguration and flowing of the lachrymal secretions over the cheek are the immediate evils. But in every degree of eversion there is a remote risk of the injurious effects of inflammation of the eyeball, from perpetual exposure of the eye, and the inability of the lids to wipe off or brush aside intruding particles; the exposed palpebral conjunctiva is ever unnaturally and highly vascular, and so is frequently the ocular also, yet it is surprising how seldom such influences are absolutely detrimental to vision.

The causes of ectropium may be referred to two classes, that arising from accidental circumstances, and that which springs from some morbid change within the lids.

The first includes abscesses about the orbit, usually at the circumference, burns, scalds, ulcerations, either simple or specific, as from syphilis, lupus, sloughing after erysipelas, wounds, contusions, and surgical operations. Of these, the effect of the abscess through cicatrization is by far the most frequent, and the

most accustomed seat of suppuration is the lower and outer part of the edge of the orbit.

Fig. 42.




Here (Fig. 42) is a well-marked instance of ectropium in the lower lid in a child four years old. The scar on the side of the nose points out the remains of an abscess coeval with that on the cheek.

I have selected the case to illustrate the appropriate treatment of this kind of eversion. It is apparent that the great object is to procure a supply of healthy tissue to replace that which has been lost; so that when the lid is liberated and replaced, there shall be a continuity of healthy structure. The actual loss of skin from the abscess in such cases is, in fact, very slight; it is mainly the cellular tissue that is destroyed by suppuration, the contraction from the loss of which pulls aside the skin, and ties, or binds it down. Merely to release the lid from its adhesion by any plan of dissection, and to leave the wound to be filled up and healed by granulation, according to the method of the ancients, would be perfectly useless; nay, the attempt might aggravate the ectropium and add to the scar.

The operation in this instance was performed as follows:—The cicatrix was sparingly removed, and from either extremity of the small oval wound two straight incisions were made after the plan in Fig. 43; the surrounding skin was then separated from its attachments to a considerable extent, especially on the cheek, by

which it admitted of transposition, and made to serve the place of that which had been destroyed.

Fig. 43.

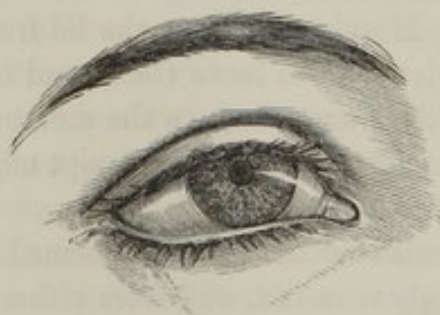

So extensively had the cellular tissue been destroyed by long suppuration, that the lid could not be freed and replaced till the dissection had reached nearly to the margin. A portion of conjunctiva was next removed from between the lid and the globe, at the sinus, corresponding to the everted portion of the tarsus, and the operation was concluded by drawing up the lid as far as possible, and fixing it by means of narrow slips of plaster passed circularly from the nose to the temple.

Cicatrization was rapid, and the improvement satisfactory. Some deformity remained, owing to the curved cartilage which could not be made to accommodate itself to the globe, and a few weeks later I removed the bent portion, laying hold of it with the tenaculum forceps, and using the scalpel; two sutures were used. By one not aware of the nature of the operation, I am sure that the former condition of the eye could never have been imagined.

The correct likeness in the following sketch, Fig. 44, shows the alteration that was effected.

Fig. 44.



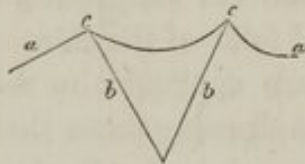
Other methods embodying the same principle, and differing only in the direction and extent of the cuts, have been proposed

and practised; but this is superior on account of the limited division of the skin, the smallness of the subsequent scar, and from the absence of angular flaps, the greater certainty of healing by the first intention. The peculiarity, the size, and the position of the cicatrix, and the presence of more than one, will require modifications in the direction, number, and extent of the incisions.

In an article in the "British and Foreign Medical Review," for April, 1839, on plastic operations, is the following sketch of Dieffenbach's plan, by which the same point is sought, but with considerable division of the skin.

The triangular flap being raised, the sections *a a* are extended freely on either side to allow of the ready approximation of the two sides *b b*; these being then fixed by sutures, the two cut margins *a c* and *c a* are connected with the corresponding margins of the lower lid included between *c c*. The whole lid is thus raised, and the parts are made to assume a natural and healthy character.

Fig. 45.

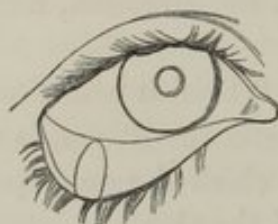

It may not be always necessary to shorten the tarsus, nor perhaps to excise any conjunctiva; but when either process is required, it should be executed simultaneously with the transposition of the skin. I suspect that the tarsus with its attachments, is not ever in reality much stretched. I doubt not that they yield somewhat, but the depression must be due principally to displacement of the skin of the face; for when the tarsus is much pulled down, and apparently lengthened, the upper lid is lowered.

For the removal of cartilage to be effectual, the piece must be large enough to shorten the lid a little under the natural dimensions, and the following diagram gives the size of the portion

that was taken in the case before us, marks its position, and shows the shape, which differs from that usually recommended; the curved sides come easily together, and do not form a retiring

Fig. 46.



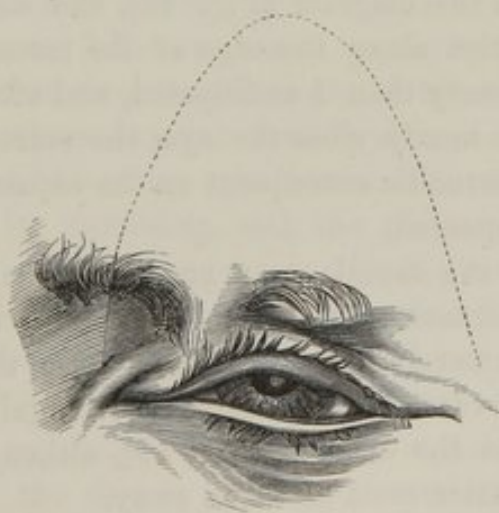
angle when united, but make the edge level. I may add that the portion was taken just where the tarsus was bent and irregular, and had acquired a form not to be overcome by means that would ever bring the rest of the border to the correct line. The removal of a portion of cartilage from the outer angle, as suggested by Dieffenbach, is to be preferred when circumstances will admit of it, and when there is not a necessity for taking it at a given spot, because the scar which may follow is somewhat hidden by the natural folds of the skin.

The same details are applicable to the upper lid; very great care must be taken in drawing down the borrowed skin, and the eye should not be opened until adhesion is supposed to be perfect. The cartilage also may be adherent to the bone, when of course it must be detached. The dissimilar anatomical arrangements of this lid, and the usual depth of the abscess from the surface, render it less favorable for amelioration, and the result must almost always depend on the site of the cicatrix; the more external it is, the more promising will be the issue.

In the "London Medical Gazette," for 1836, vol. xviii. p. 224, Mr. Jones published a plan of treatment that had been pursued upon the upper lids of a female, and repeats the case in his "Manual of Ophthalmic Surgery," where it is stated, that the peculiarity of the plan consists in these particulars. The eyelid is set free by incisions made in such a way that when the lid is

brought back into its natural position, the gap which is left may be closed by bringing its edges together by suture. The flap of skin embraced by the incisions is not separated from the subjacent parts; but advantage being taken of the looseness of the subcutaneous cellular tissue, the flap is pressed downwards, and thus the eyelid is set free. The success is said to depend very much on the looseness of the cellular tissue; and it is recommended that for some days before the operation, the skin should be moved up and down, in order to render the cellular tissue more yielding. It would seem that the essential difference between this, and that which I practise is, that in the one the skin is actually detached from its connexion and carried to another spot; in the other, it is merely pressed down to an amount limited by the yielding of the cellular tissue. It is difficult to conceive how any result can be attained by the latter process; and that some dissection is effected is evident by the details of the operation, where mention is made of "pressing down the triangular flaps thus made, and cutting all opposing bridles of cellular tissue, but without separating the flap from subjacent parts."

Fig. 47.

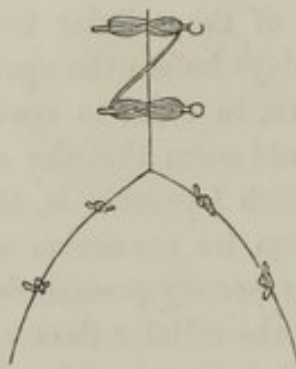


Mr. Gay, requested me to meet him in consultation on a case of ectropium of the upper lid, caused by the accidental contact

of strong sulphuric acid. The above sketch shows the eye closed to the utmost that could be effected.

In the ordinary state there was a stare, the lid was everted, and a portion of the cartilage shown. At my recommendation

Fig. 48.



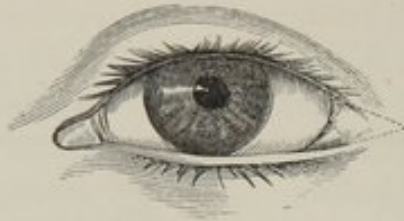Mr. Gay shaved the irregular hairs of the eyebrow, made an incision corresponding to the curved line, and dissected off the flap, which allowed the lid to descend; then freely separating the edges of the skin on either side, he brought them together over the exposed surface, and retained them by sutures after the manner shown in the diagram (Fig. 48), and dissected away a piece of conjunctiva along the edge of the tarsus. The result was more satisfactory than I anticipated, and after four months the patient could nearly close the eye, the ectropium being removed, and the corneitis consequent on the exposure of the eyeball having disappeared.

Cicatrices on the temple may produce more or less partial eversion of the corners of the lids; or they may not fairly evert their edges, but merely pull them away from the globe. The defect must be reduced by removing a triangular bit after the manner shown in the diagram (Fig. 49), although generally, a much greater portion must be taken away.

I think that all remedial examples of ectropium from abscess may be treated on the plan I have described. When, however, contraction is extensive, or absolute destruction of the skin by

burns, scalds, extensive ulcerations, or other physical causes, everts the lid, transposition will seldom suffice, and skin must be borrowed by a plastic operation from a spot where its loss can-

Fig. 49.

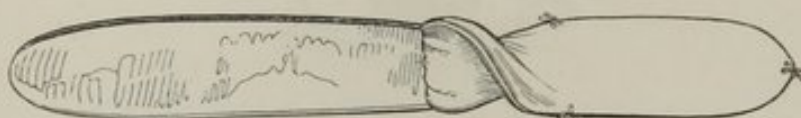

not ultimately influence the lid. But even this may be impracticable; for healthy skin may be out of reach. In a lad of eleven years of age, who was scalded in infancy, the right cheek was a mass of cicatrices, and the alteration of the features actually defied immediate recognition of the exact nature of the change. The upper tarsus was dragged down below the level of the under one, and beneath it was a plane surface about an inch square, at first supposed to be an ulcer, but which was the conjunctiva, and below that and the distorted side of the mouth, a short and irregularly disposed row of cilia marked the inferior tarsus. The poor fellow was sent to me by Mr. Arrowsmith, with the hope that some benefit might be afforded.

Plastic operations demand considerable nicety, and require for their effectual execution a well-tutored hand. Every circumstance should be promising, and the patient in good health. There are two means of operating: in the one, skin is raised from an adjacent part and twisted round to the required spot; in the other, with the maintenance of a connecting slip, the skin is slid laterally from a contiguous site. The adoption of either must be regulated by circumstances, the situation of the part at which the skin is required, the extent of the demand, and the position from which the skin may be taken. The first is most used, because more generally applicable, and it is executed in the following manner.

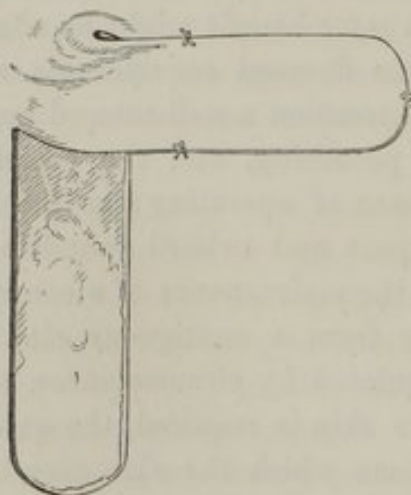
After the cicatrix has been dissected out as symmetrically as possible, and with the greatest preservation of sound skin, and the lid liberated and carried to its place, a flap of skin, cellular and even adipose tissue of the required size, is to be raised and carried to the place made to receive it, as is shown in the following diagram.

Fig. 50.



It may be in a line with the spot for which it is destined, when there must be a sufficient strap or isthmus left uncut; or, what is better, borrowed from a nearer point, so as to reduce the twist; because that interferes less with the circulation and affords greater security to the preservation of vitality, while it, moreover, facilitates coaptation. I think that it would be still preferable to avoid the isthmus of skin by an arrangement of the following kind. The flap being taken from below or above, as occasion may require.

Fig. 51.



It is well not to wait till bleeding has ceased, but at once to

adapt the parts and apply the sutures, as that will stop all hemorrhage, and the risk, from the exposure and chilling of the surfaces and the exsanguine state of the flap, is avoided. Indeed in all operations about the lids, I approximate the surfaces that are to come together as quickly as possible, irrespective of bleeding; and numerous instances of uninterrupted success confirm the propriety of so doing. Perhaps the rule will hold good in all cutaneous operations. The gap that is left should be diminished in whatever manner may seem most expedient; if the edges can be brought together by suture, so much the better, while, if healing by granulation is inevitable, cotton-wool is the best dressing. When the skin has been turned completely round, or nearly so, the root may subsequently require to be divided, and made flat.

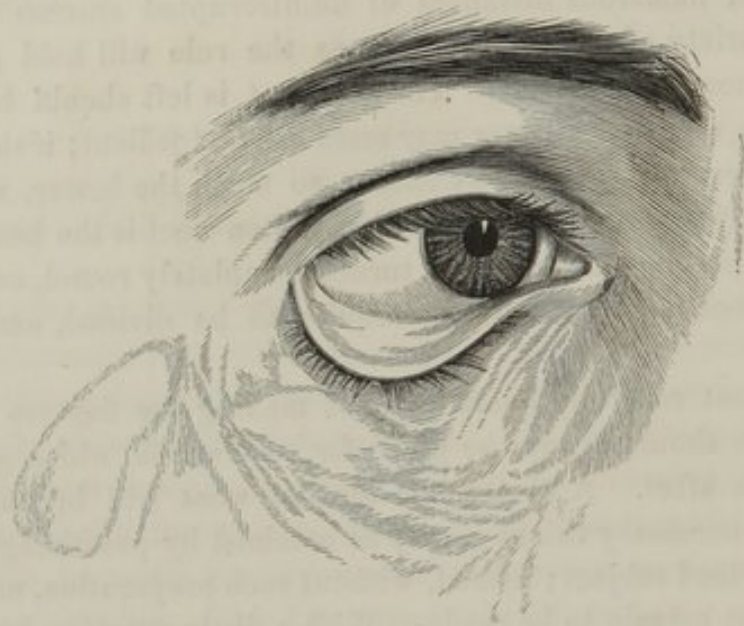We must carefully guard against making the flap too small; allowance should always be given for contraction, which goes on for weeks after. A pretty just idea of what will be required, with the necessary twisting, may be attained by practising on the recently dead subject; indeed, without such preparation, mistakes are almost certain to be made. With a little practice, however, rules of proportions will readily suggest themselves. In the case, Fig. 50, the place to be filled was an inch long, but the length of the flap was two inches; less would not have been enough for the twist, and attachment sufficient to insure vascular supply. In the second, Fig. 51, where there was neither twist nor isthmus, the proportions were different; the flap to fill the same sized wound was an inch and three quarters. It is well to trace out with tincture of iodine the size of the flap to be raised.

The following illustration of the operation on the living body, Fig. 52, shows the usual result of insufficiency of flap both in length and in breadth; in other respects the operation was well executed.

The patient had, in childhood, fallen into the fire; the scars about the cheek indicate the extent of injury; the outline of the flap and the spot from which it was taken, are just visible. The transplantation was made at an hospital in London when the man

was thirty years old, and according to his statement, half the turned-down lid, that is, half the deformity was removed. The tarsus had not been shortened, nor was the conjunctiva excised.

Fig. 52.



In May last I assisted Dr. Taylor in operating in the very inveterate case of ectropium which is given in the chapter on Caries of the Orbit, to which I refer the reader. The edge of the tarsus and the conjunctiva were carefully dissected up, and the flap, which, in consequence of scars on the cheek, was taken from a spot directly opposite, placed between the tarsus and the skin. The proportions which I have given were observed, and answered well. At a later period, a part of the conjunctiva was removed. The only untoward circumstance was sloughing of a small part of the end of the flap, but that did not foil the operation, as the likeness, Fig. 53, shows. The twist in the flap has adjusted itself so nicely, that an operation on it is unnecessary; Dr. Taylor ultimately proposes to effect still further improvement.

The upper lid does not offer the same facilities for operation, although the effects of its retraction are more distressing, from

the loss of covering to the eyeball; for failure through imperfect union of the flap is much more likely to ensue; yet it has succeeded several times in the hands of the late Mr. Tyrrell.

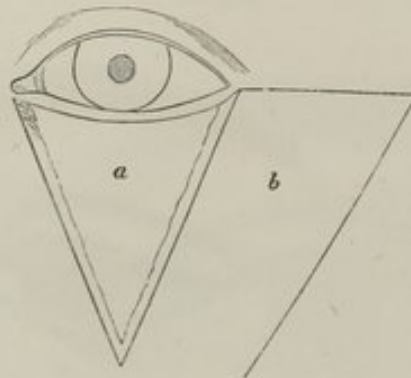
Fig. 53.



With Dieffenbach's mode of operating on the lids by lateral sliding, I have no practical acquaintance, nor do I know that any English surgeon has followed it. In vol. vii. of "The British and Foreign Medical Review," an account of this often-cited improvement will be found, with much practical information upon plastic operations by Blandin, Zeiss, Dieffenbach, and Liston. I have borrowed the diagram, Fig. 54, from "Ammon's Zeitschrift," vol. iv., where it originally appeared. The account of the invention was first published in Casper's "Wochenschrift" for 1835; and it appears that Ammon was the first to operate on the lower lid. The particulars of his proceedings are noticed in vol. iv. of "The British and Foreign Review." The operation is commenced by two incisions, one extending from either commissure of the tarsus, and which, when the lower lid is the subject of restoration, are so inclined towards each other as to meet at an acute angle on the cheek; and above the eyebrow, when the upper lid is defective. This triangular flap, of which the third side is the remnant of the former lid, is then dissected up and completely removed; care being taken to spare as much as possible the neighboring nervous filament. The space *a* thus

left is that intended to be occupied by the transplanted flap, *b*. The next step, whether for the upper or lower lid, is to carry a

Fig. 54.



horizontal incision from the external canthus over the zygoma, and in a straight line towards the external auditory meatus; and this incision must in any case, exceed in length the breadth of the defect in the eyelid. From the extreme outer point of this incision another is carried; when the lower lid is required, downwards upon the cheek, and for the upper lid, upwards upon the temple. In either case the incision must be nearly parallel to the outer line of the removed flap; its termination being on a level with, though slightly approximated to, the point of the same. Here, then, everything is arranged for replacing the lid. The new flap is gently raised, and after a careful cleansing of the space prepared for it, removed to its new position. The twisting of the broad pedicle which is thus placed inferiorly, is very slight in this operation; for that which formed the superior margin of the flap becomes the edge of the lower lid, the converse being the case in the upper operation. The same course as regards sutures, is pursued in this as in the rhinoplastic operation. The importance of saving the ciliary margin, in the preliminary dissection is self-evident. When that is out of the question, or when it has been originally lost, a great effort must be made to procure a conjunctival lining for the edge of the flap; some dissection of that membrane towards the globe may render

more of it available. The conjunctiva and the skin must be adapted by sutures.

In the "London and Edinburgh Monthly Journal" for 1843, p. 359, is an extract from the "Annales de la Chirurgie Française et Etrangère" for January 7th, 1843, of two cases of lid restoration. One was by Dr. Baumgarten, in a child six months old, laboring under aneurism by anastomosis on the right lower eyelid, whose rapid increase, encroachment on the cheek, great size, and the threatening of bursting, induced its extirpation. The flap was borrowed from the temple, and slipped laterally into the required place; the upper edge was fixed to the tarsus by means of four points of suture, the inner by six, the outer remained free: union by the first intention followed, and on the fourth day the last suture was removed. In a week the loss of substance in the temple was repaired, and the eyelid presented a good appearance. The other was performed by Dr. Ammon. The loss of the lower eyelid was involved in the excision of a suspicious-looking tumor; the flap in this instance was also taken from the temple; primary adhesion was not effected, yet the flap survived and in five weeks adhered by granulations.

Not until all activity of the disease that had produced ectropium has ceased, and the lid has reached its maximum of eversion, should an operation be undertaken. At the same time I must observe, that it would be injudicious to delay operative measures when the proper time has arrived; because the less sure or perfect would be the issue, from the longer disturbance of the tarsus. Whenever dissections are to be made over the supra- or infra-orbital foramina, care should be taken to avoid the vessels and nerves which they transmit.

There may be a loss of sensibility of the borrowed flap; this has occurred in all cases of plastic operations that I have seen, but it has been temporary. In a few weeks, or a few months, sensation has returned, and should it have been restored prior to the division of the twist, this little operation will again suspend it.

A certain degree of puffiness attends the best executed of

these operations, and that, too, becomes less and less, and may even quite disappear.

The hair-follicles on the borrowed part, may, from a cause difficult to explain, be stimulated into activity, and produce hair of considerable length.

I believe that the operation of transplantation, that strictly so called, I mean the Taliacotian, has never been applied to the lids.

M. Jobert, in a recent work, entitled "*Traité de Chirurgie Plastique*," proposes to supply the lost eyebrow, with scalp hair; an art not likely to improve personal appearance, nor is his representation of a case prepossessing.

I have much pleasure in referring to some very excellent cases of restoration of lost parts by Dr. Richard Mackenzie, of the Royal Infirmary of Edinburgh, in the "*Monthly Journal of Medical Science*," and especially to one in the number for January, 1852, embodying restoration of the upper lip, cheek, and eyelid, which I subjoin. In the original there are two woodcuts, showing the former and the present state of the face.

"Letitia Jones, aged seven, admitted into the hospital May 31st, 1851. The deformity of the face was the result of mortification occurring during the early stage of convalescence from scarlet fever, from which she had suffered about five years previously. The sloughing had, as is usual in such cases, proceeded rapidly, nearly the entire cheek and lower eyelid of the right side of the nose and the right half of the upper lip, being destroyed and detached in the course of a fortnight. Necrosis of the exposed bones followed, and the nasal bones, along with the greater part of the right superior maxillary, were detached some time afterwards.

"When admitted into the hospital under my care, the child was in perfect health, and the parts in the neighborhood of the extensive cicatrix in a perfectly sound condition. The absence of the lower eyelid had given rise to a vascular condition of the conjunctiva of the right eye, and the part of the cornea which was exposed, was dull and slightly nebulous. In addition to the

deformity of the features, the twisting and displacement of the mouth rendered her articulation very indistinct.

"On the 6th of June, I attempted to restore the lost parts by bringing up a large flap, consisting of the lower lip (saving the *prolabium* in the manner I have formerly described, see 'Monthly Journal,' 1851, p. 350, Fig. 3), and of the integuments over the base of the jaw, so as to fill up the whole gap at once. The operation, however, failed from an unforeseen accident. From the effects of the chloroform, which had been pretty freely administered during the time of the operation, the poor child vomited with little cessation for thirty-six hours. From the long-continued drag thus made on the sutures, and the constant movement of the transplanted parts, union failed in the entire extent of the wound, and the flap, in spite of all means used to keep the edges together, retracted, and receded from the surface, to which it had been attached. The contracted flap, however, was retained, as far as possible, in the situation of the upper lip, and this object was so far obtained as to bring the parts into a condition nearly similar to that of simple hare-lip.

"On the 19th of July, by the same mode of proceeding as that practised in the operation for hare-lip, the edges of the cleft were brought into apposition; perfect union was obtained, and the natural appearance of the upper lip was thus nearly quite restored.

"The deformity of the face, however, although much diminished by the restoration of the upper lip and the replacement of the lower lip to its natural situation, was still very great, from the absence of the nose, eyelid, and greater part of the cheek; and, as the child herself and her parents were anxious that something more should be done to improve her appearance, a third operation was performed, so as to remedy, as far as possible, the remaining deficiency. This, however, was delayed for some time, in order to allow the parts to assume the position which their subsequent contraction might give them.

"On the 18th of October, the gap was filled by a large flap of skin brought from over the ramus of the jaw, the neck of the flap

being situated over the upper part of the malar prominence, and its extremity corresponding to the angle of the jaw. This flap was attached by twisted and interrupted sutures to a cut surface extending from between the eyebrows along the mesial line in the former situation of the nose, and along the upper border of the new upper lip. The large flap thus transplanted retained its vitality in its entire extent, and primary union was obtained along the whole line of incision. The edges of the wound made in dissecting up the flap were united by one or two sutures at the lower extremity of the incisions. The remainder of the surface was left to granulate, and healed quickly. In addition to the improved appearance of the features, her articulation has been rendered much more distinct, an advantage which was contemplated in deciding at first as to the expediency of surgical interference.

“The child, nothing daunted by what she had undergone (the different operations were performed while she was under the influence of chloroform), was now anxious to have her appearance still further improved by the formation of a nose. This proposal, I need scarcely say, was negatived: the modified Taliacotian operation being one, which is apparently applicable only in adults.”

The second class of cases of ectropium, the consequence or termination of disease of the lid itself, and occurring principally in the under lid, is owing generally to inflammation of the eye, and almost always of a strumous kind. The conjunctiva is first inflamed, lachrymation follows, with more or less intolerance of light; afterwards the Meibomian glands are involved, and the entire edge of the lid being implicated, the cilia drop out, or become stunted, that state called lippitudo generally occurs, and the eversion follows. In this form there seems to be not only actual loss of substance of the lid in the rounding of the edge, but the cartilage and the tarsal ligament shrink. This appears to me to receive corroboration in the circumstance that in the lippitudo which generally precedes, it is not uncommon to observe inability to close the lids, except with great effort. Perhaps one

may venture to surmise that the inflammation which lingers so long about the lid may so far alter that portion of the orbicularis on the edge, as to impair its supporting or binding influence. It is generally supposed that the eversion is owing to the contraction of the skin of the lid from the excoriating influence of the tears. Ulcerations that penetrate the skin sufficiently to produce a scar, would, doubtless, be followed by such an effect, be the cause of that ulceration what it may; but ulceration of the exterior of the lid is not usually associated with ectropium. Roughness and even excoriation of the skin is, according to my observation, a frequent effect of eversion, and both are common in lippitudo, where eversion is absent. The direction of the tarsus somewhat indicates also, that it is not entirely influenced by tension of the skin; for it is not so much pulled down or away from the globe as turned outwards. The bright red villous and puffy condition of the conjunctiva is generally the result of its constant exposure, and cannot be a cause of the eversion when only a small portion of the membrane, and as much only as is permanently exposed, is so altered.

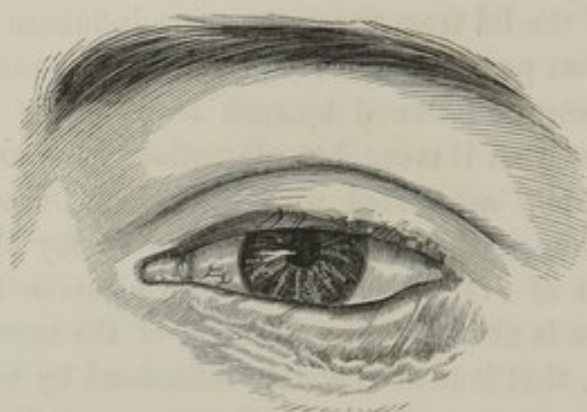
Certain changes of thickness in the entire palpebral portion may alone revert the tarsus, the edge of the lid with the cilia and the glands, remaining entire. In all of these cases that have come under my inspection, irritating substances had been used for conjunctival affections, and had, I believe, been the cause of the eversion.

Fig. 55, is a representation of entropium, with considerable disease of the lid, and was taken from a young man of nineteen, a patient at the Ophthalmic Hospital.

Both eyes were similarly diseased. Having been the most marked case that had been at the Hospital for some months, it was chosen for representation before treatment by operation, with the intention of contrasting it with the after improvement; but the patient declined my assistance. A better illustration of an aggravated case could not be desired. All the conjunctiva on the everted lid was thickened, and the edge of the tarsus ragged

from former ulceration. In the upper lid also, there was slight eversion, and most of the cilia were lost.

Fig. 55.

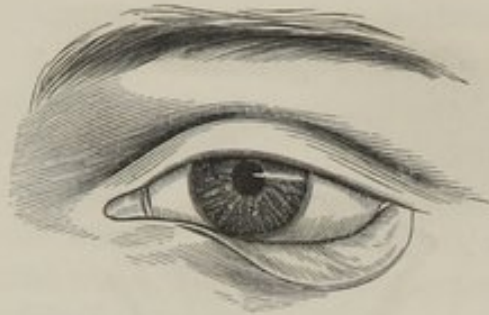


Improvement may be effected in slight cases by general and local treatment, by improving the health, and the use of mild astringents; but, in general an operation is required. Escharotics strong enough to produce slough have been recommended to supersede the knife, but they are objectionable on the score of danger, it being difficult or even impossible to limit their action. By removing the thickened conjunctiva the lid is pulled into its place by the contraction that ensues. The lids having been duly separated by an assistant, the part to be taken away is seized with the tenaculum forceps, circumscribed with the scalpel, and dissected out. The outer incision should be carried to the edge of the tarsus, along the length of the eversion, or the operation is imperfectly done. There is always free bleeding, requiring the frequent use of the sponge. Sutures are unnecessary. The amount of conjunctiva to be removed should be regulated by circumstances which practice alone can teach; and it must be recollected that instances are related of eversion having been changed to inversion, by too lavish a dissection.

The following sketch was taken from a girl, fifteen years old, with partial ectropium of both lower lids, from long-existing strumous ophthalmia, which had also destroyed all the cilia.

The greater part of the exposed membrane was dissected away, and with such an effect that, four months after, the eye was in

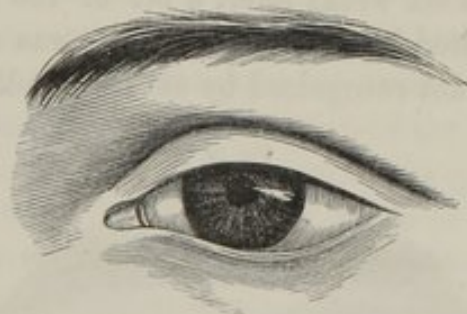Fig. 56.



that state which the second sketch (Fig. 57) accurately represents.

For so perfect a result the lid must have escaped ulceration, and the tarsal cartilage been but little damaged; and then all trace of the operation is a bridle of conjunctiva, which is a part of the ocular membrane, uniting the lid to the globe, but which

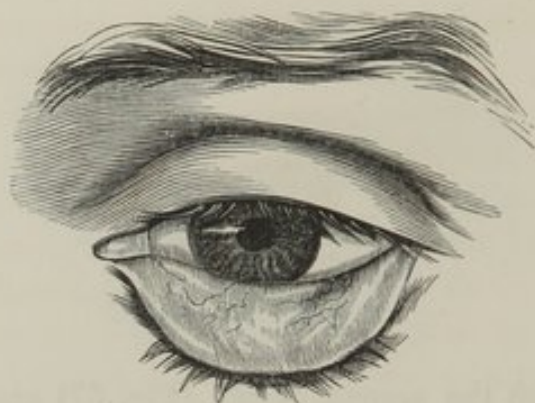Fig. 57.



does not interfere with the movements of the eye. In the above cases, removal of conjunctiva only was admissible; the eversion would not have been improved by taking a bit out of the tarsus, but rather made worse. In those of eversion from thickening of the conjunctiva, of which Fig. 58 is an example, the double operation is required; the contraction from the loss of conjunctiva, besides pulling the lid from below upwards, and drawing it from

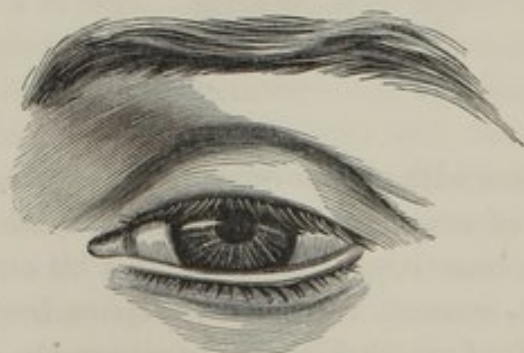side to side, making a slight pucker, which must be removed by the excision of a triangular bit of the tarsus. The patient in

Fig. 58.



this instance was a soldier, who had been discharged for some inflammatory affection of the eye, and who assures me, that when he left the army the lid had not turned out, and that the ectropium came on a few months after the regular application of sulphate of copper three times a week, for nine months, when he could no longer submit to it. A large portion of the membrane was removed, and six weeks later, a bit of the tarsus taken out, and the edges united by suture. So great was the improvement, that the eye was not recognised by several medical men who had

Fig. 59.



seen it prior to the first operation, and the sketch (Fig. 59) was taken ten days after the second.

Perhaps I ought not to omit to notice, that displacement of the lids occasionally recurring in purulent ophthalmia, and more commonly in the adult, which is, strictly speaking, eversion. The lids are turned inside out by the infiltrated conjunctiva, chiefly of the globe; but except that scarifications are sometimes called for, it does not fall within the domain of operative surgery. I am averse to excision of any part of the chemosed conjunctiva, because I think that the contraction which must ensue might induce entropium; moreover, the practice is unnecessary, for as the severity of the disease is subdued, the lids regain their wonted position. But when the protrusion does not show evidences of decline, or when it is very large, free incisions are demanded.

Ectropium from paralysis has not, as far as I know, received relief from operative surgery.

The ectropium of the aged, which seems chiefly to depend upon the loss of sustaining power, or the support of the orbicularis muscle to the tarsus, and relaxation also of the tarsal connexions, is generally, in this country at least, not submitted to operation. The lid falls away from the globe rather than turns out. The removal of vertical portions of skin, provided sufficient be taken, may be beneficial. M. Desmarres supposes that there is some actual change in the relative position of the orbicularis, in consequence of relaxation of the skin; that there is a transposition of a part of the muscle, the greater portion of the ciliary fibres being carried to the lower, or adherent border of the tarsus by the cutaneous folds, and that the tarsus so circumstanced, swings about during their contraction; and he says he has proved this pathological change in a great number of cases by actual dissection. He states also that ectropium can be produced by spasmodic action of the orbicularis, an opinion to which I cannot subscribe.

This author, when writing of cauterization in certain mild cases of idiopathic ectropium, lays down some rules for using nitrate of silver that are worthy of dissemination; and, although I do not approve of this caustic in a pure state in ectropium,

there are occasions when this escharotic is required, and I quote his valuable practical hints.

The patient being seated, and his head supported by an assistant, the surgeon depresses the lid to the utmost, that the diseased surface may be exposed; then by a curette, or any delicate instrument, a pellet of cotton thoroughly impregnated with oil is placed in the sinus of the lid, between the thickened part of the conjunctiva and the eye, and from the one angle to the other, in order to protect the globe from the caustic. Should the part to be cauterized be accidentally greased, it must be carefully wiped with a bit of thin rag, and afterwards slightly wetted or moistened with sponge and water. The nitrate of silver is then carefully to be applied, taking care to avoid the punctum. After waiting a sufficient time for the caustic to exercise its power, the part should be washed with dilute hydrochloric acid to neutralize any superfluities. The eschar is now to be covered with oil, and the lid replaced. A direction is given, that the acid be that which smokes, by which is meant that it be pure. This is not an unnecessary precaution, even in England, since the ordinary acid of the shops, which is colored instead of being like water, is very impure. Water-dressing is to be applied, and after the space of an hour, the cotton to be removed.

OBSTRUCTION OF THE MEIBOMIAN DUCTS.

Abscesses and concretions in the ducts, causing deformity or irritation, call for surgical assistance. The natural secretion may block up and close the ducts, and be mistaken for calcareous matter. In two instances, when I thought I had removed calculi, minute examination proved the dense masses to be hardened secretion.

Mr. Dalrymple removed a small tumor from beneath the tarsal cartilage of the upper lid of a middle-aged man, larger than a pea, and composed of concentric layers of hard earthy material. Its pressure had caused absorption of the cartilage, and ulcera-

tion of the conjunctiva, and the friction produced pain, inflammation of the conjunctiva scleroticæ and opacity of the upper part of the cornea. The microscope disclosed epithelium scales, closely agglutinated, thickened and hard, and containing granular earthy molecules, phosphate of lime, with a trace of the carbonate of the same earth, which could not be removed by immersion in weak muriatic acid. No amorphous earthy deposit existed around, or among the scales. The case is in vol. xxvi. of the "Medico-Chirurgical Transactions."

CONJUNCTIVAL CALCULI.

The formation of calculi on the free surface of the conjunctiva is very questionable, and many stories of the ossification of the tears are too wonderful to be repeated. All concretions found between the lids, having probably descended from the lachrymal gland, as appears to have taken place in a well-reported case of Mr. R. H. Meade, in vol. xv. of the "London Medical Gazette." A girl of nineteen, who had been in bad health, and suffered severe headache and pain over the left eye, was bled and leeches without relief. Inflammation suddenly appeared in the left eye, with lancinating pain in the upper and outer part of the orbit, accompanied with sudden and profuse discharge of tears. Something which resembled a fragment of mortar was removed from the conjunctiva. The pain ceased, but returned in an hour after, and another bit came away. During the four following days, as many as twenty-three similar pieces were discharged, after which the pain and inflammation abated. Neither abrasion nor ulceration of the conjunctiva was observed. There was tenderness in the situation of the lachrymal glands. The calculi were small, rough, very hard, and of a dirty white color, the largest being a line in diameter. Through a microscope they looked like rough pieces of chalk embedded with small portions of silex. They consisted principally of phosphate of lime, with a small quantity of carbonate of lime, and traces of animal matter. The author very shrewdly suspects that the calculi were formed in the lach-

rymal duct, and that producing irritation they were dispelled with the tears which they excited. To this cause I refer a very remarkable case of the double affection, related by Walther, in Grafe and Walther's "Journal," 1820. The rapidity of the formation of the calculi, which were in the lower sinus, was wonderful; in one eye, the first affected, they were removed twice, and even three times a day. But the most remarkable occurrence is their rapid cessation, under the administration of five grains of carbonate of potass four times a day, with syrup and common water, and also an infusion of *viola tricolor*. Some years after the disease returned, the upper sinus of one eye was the seat of the deposit, and potass again cured them. The terms which Walther applied to these concretions, that of *Dacryolites*, has come into general use.

M. Desmarres has written very extensively on *dacryolites* and *rhinolithes*, in vols. vii., viii., and ix. of "*Les Annales d'Oculistique*."

A calculus has been removed from the caruncle.


CHAPTER VI.

AFFECTIONS OF THE PUNCTA, THE CANALICULI, AND THE
LACHRYMAL TUBE.

PROBE FOR PUNCTA AND CANALICULI.

AN instrument of this shape and strength is more manageable, and can be used with greater safety and precision, than the thin and flexible piece of silver wire that surgical instrument-makers generally supply.

Fig. 60.



One extremity is rather larger than the other, and more conical.

Very much finer and more delicate points would be apt to inflict injury on the delicate passages that are to be probed, yet a smaller instrument may sometimes be required.

Excepting mechanical injury, and contractions from ulcerations and burns, the puncta and canaliculi are peculiarly free from obstruction, being rarely affected by disease; and when inflammation does invade them, it is nearly always of the acute kind. From their minuteness they would be constantly exposed to the danger of obstruction, were their mucous surface liable to thickening. The formation of minute abscesses in their immediate vicinity declares that they are not exempt from irritation,

and instances of fistula have been met with. Congenital fistula is mentioned in Blasius' "Zeitschrift" for 1837.

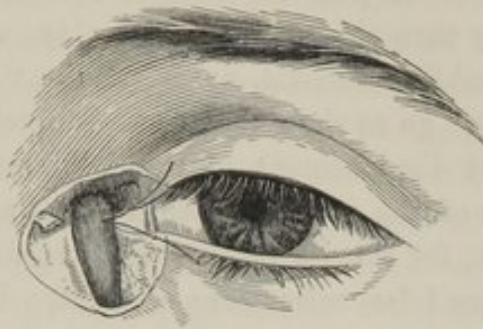
I am inclined to ignore the idea that a patulous state of the puncta interrupts the passage of the secretions, and I must confess that I am not familiar with such a pathological change in these openings. The watery eye of the aged is commonly assigned to this cause; but would it not be more correct to attribute it to failure in those mechanical movements of the lids, that are so necessary to bring the puncta into proper play; and perhaps also to the more or less displacement of parts from those alterations inseparable from age; and may not this senile lachrymation be more often due to an unhealthy condition of the lachrymal gland, than is supposed?

Contraction of the puncta, and consequent obstruction to the excretions, is spoken of by writers as no uncommon occurrence; but this has not fallen under my observation, or I have failed to detect it. I find that Mr. Tyrrell speaks of it as being rare; he had seen it only in persons naturally of an irritable temperament, and who had been rendered additionally so from debility. The treatment he had found beneficial was to relieve the nervous irritation, and lessen the debility. Local applications and the use of a probe were unavailing.

Obstruction of the canaliculi is said to be more common than contraction of the puncta; and some surgeons frequently pass a probe under the impression of its necessity, and as often use this instrument to seek for stricture. We should be careful to meddle in this manner as little as possible, because the canals are so readily injured. I have met with closure of the lower duct in its internal half; the external portion was remarkably small, and the punctum so fine that the naked eye could just recognise it. I regarded the imperfection as a congenital defect. The other canal was much larger than natural, the punctum also being unusually open. The subject, a young man who died of consumption, had not suffered from the defect; here one exit sufficed to convey away the secretions, as it frequently does, when the

other is destroyed. The accompanying sketch may assist in the consideration of the anatomy of these channels.

Fig. 61.



All the parts covering the corner of the eye have been dissected away, and the course of the canaliculi and the head of the lachrymal tube, above the bony channel, made apparent. A part of the tendo oculi is left attached to the bone.

The canaliculi opened in this instance into the tube separately; sometimes they communicate by a common aperture. Their irregular course is altered by the bristles that were inserted, and they are made to assume a straight line, whereas, to reach the surface, each bends almost at a right angle, forming an elbow, and then turns a little inwards—a beautiful provision, whereby the puncta are the more certainly adapted to their office. This bend should be remembered while using a probe, and the little impediment thereby offered overcome by drawing the lid out, and straightening the canal. The distance that the probe can be carried is the criterion of the patency of the canal. To Mr. Bowman I am indebted for the hint, that when there is obstruction close to the tube, and pressure is made by the probe, the outer wall of the sac, with the skin over it, is moved towards the nose, and an elastic resistance is felt; whereas, if the passage is clear, the probe enters the tube, arrives at its inner part, and the skin is not moved.

The displacement of a punctum is not attended with any more

disadvantage in the quiescent state of the eye, than common obstruction from any cause; but the loss is felt whenever there is increased secretion, and the eye may become very troublesome. If ectropium be the cause, removal of the eversion may effect a cure. Mr. Bowman has pointed out that even slight divergence of a punctum may turn this orifice out of play, and his observations, which are published in vol. xxxiv. of the "*Medico-Chirurgical Transactions*," go to show that there is much inconvenience to vision, by slight displacement of the lid from arrest of the tears on the front of the eye; because they cannot escape, as in decided ectropium, for the lid retains them against the cornea, where they produce false refractions of light. He asserts that a close examination is necessary to detect this cause of epiphora. The lid is either in its natural position, or recedes slightly from the globe when that is turned up. However, the prominence on which the punctum is placed has disappeared, the orifice lying on a flattened, rounded, cutaneous surface at a little distance from the mucous lining of the lid, much reduced in size, and not wetted by the tears, but dry. The causes of this displacement are, slight chronic inflammation of the conjunctiva near the punctum, producing thickening and eversion; chronic affection of the skin of the lower lid, somewhat resembling eczema, by which a contraction of it ensues, and the punctum is drawn outwards.

Mr. Bowman then shows what extremely slight displacement outwards will destroy the function of the lower punctum, from this aperture, together with the neighboring mucous surface becoming greasy and cuticular with the sebaceous secretion, which he thinks a provision for maintaining a greasy state of the surface of the cuticle at the margin of the lid, to prevent the tears from escaping over the cheek; so that the tears are prevented from coming up to it, but collect in a drop at the caruncle, and adds, that, in some instances, a margin of one-sixteenth of an inch of greasy membrane on the conjunctival side of the punctum, is enough to destroy its function. His operation is to slit up the canal from the punctum, to a length sufficient to carry backward the orifice to that part of the mucous surface where

the tears are collected. A probe is introduced and a scalpel used. It appears necessary a day or two afterwards to pass the probe and separate the margins of the slit, which adhere, and would otherwise remain closed. He does not advise the proceeding in recent cases of displaced puncta, nor where milder means will suffice: however, there is not any visible deformity from it.

The puncta may be wanting from congenital defect, as many writers testify; in vol. xxvii. of the "Dublin Journal of Medical Science," Mr. Wilde alludes to a case mentioned by Morgagni in his "Epistolæ," in which all four puncta were closed, and gives an instance, lately seen by himself, of a young girl without a punctum on the left upper lid, or the papilla on which this little aperture is usually situated.

Again, the puncta may be destroyed by accident. Mr. Dixon had a patient in whom they were closed on one side, from ulceration and adhesion of the greater portion of the lids; the distressing lachrymation induced him to extirpate the lachrymal gland. Mr. Bowman's operation may be applicable in some cases of this class, and no opportunity for trying it should be lost, for surgeons are unanimous as to the difficulty of maintaining an artificial passage from the eye to the nose; and it is evident, as Mr. Bowman remarks, that the canaliculus should itself furnish the channel, and this can be accomplished only in those instances in which the point of obstruction is sufficiently far from the sac, to allow of the canal being slit up in the interval, and through the conjunctiva. According to this author, two methods of operating offer themselves: one, by cutting transversely across the direction of the canal, close to the obstruction on the side towards the sac, and then slitting up the canal with a probe; the other, supposing no orifice can be found after this transverse section, by opening the sac below the tendo oculi, and then slitting up the canal near the obstruction on a probe run into it from the opening in the sac; the orifices of the canaliculi within the sac being so large that a skilful surgeon could readily accomplish this, if he had previously taken pains to acquaint himself with the anatomy of the parts.

Several authors make mention of obstruction of the canaliculi by polypi; calculi have also been met with. Mr. Travers says, that in more than one instance, he has turned out a considerable quantity of calcareous matter wedged in these tubes, like the calculi of the salivary ducts. M. Desmarres gives a most voluminous description of the chemical analysis of one removed by himself from the lower punctum. Epithelium scales also have been found choking them up.

Fig. 62.

KNIFE FOR LACHRYMAL TUBE.

The requisites here are sufficient narrowness, length, and strength of blade. The artist has exceeded, by a trifle, the breadth of the original. It is better for the trustworthiness of so slight an instrument that it be without a shoulder, a spot at which delicate knives frequently break. The upper part of the blade is quite round, and the next oval, till within about half an inch of the point, which is like that of an ordinary knife, and sharp.

OBSTRUCTION OF THE LACHRYMAL TUBE.

I regard this disease as generally of scrofulous origin; for not only does the state of the patient's health frequently declare the fact, but the local manifestations of struma are very often co-existent. The common occurrence of symmetrical disease, both tubes being involved, is likewise significant of this. Prostration of the system may induce it; and in children the severer exanthemata are occasionally precursors. I believe that the entire tract of the mucous surface of the tube, from the canaliculi to the outlet in the nose, is always more or less invaded by the morbid action, and the calibre of some part reduced, either by swelling or the exudation of some inflammatory product. The encasement of the greater portion by bone, precludes the exhibition of those results that are manifested in its



upper and free end, and hence the idea that the upper part alone is generally diseased.

Very slight narrowing of the tube is perhaps attended with interruption to its functions; for although the amount of the fluid passed off is not large, it is probable that the means of escape is not much greater than required, and swelling, thickening, or deposit of any kind may cause an obstruction. In the healthy condition any augmentation of the excretions produces an overflow; and with the slightest stricture the ordinary amount must be too much for the transit. The obstruction usually begins imperceptibly, and increases insensibly, till a watery eye and distension of the upper part of the tube, by tears and by secretion thrown out by the tube itself, disclose its existence.

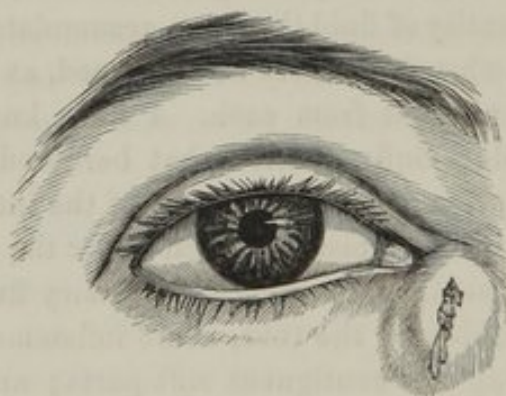With the suspicion of stricture I invariably press on the tube, and if tears, mingled with any morbid secretion, or tinged with blood, escape through the puncta, I consider that obstruction exists. The quantity of fluid that may accumulate is surprising; on one occasion, when both tubes were stopped, at least a drachm of thick humor escaped from each. I have known distension from mucus produce inflammation that bordered on sloughing, and probably in a few hours the vitality of the integument would have been lost had not a bistoury, used under the suspicion of an abscess being present, given vent to the glairy fluid. After reduction in the calibre of the tube, acute inflammation generally succeeds, involving the contiguous soft parts; and the common history of these cases is, that for an indefinite period there has been a watery eye, sometimes particularly troublesome, united perhaps with the occasional escape of mucus or pus through the puncta, and dryness of the nostril; attacks of inflammation supervene, an abscess forms and bursts externally. The position of the opening is determined by accidental circumstances, and may be at some distance, even on the cheek; the common situation is over the head of the tube, as portrayed in the following sketch, Fig. 63.

Although these stages are usually spread over months, sometimes even years, there may be such rapid succession of them, as

to induce the belief that the attack is due to acute primary inflammation in the tube, an occurrence which I suspect to be of great rarity. Except for these paroxysms, which disclose the severity of the affection, a person does not generally seek advice, unless perhaps the conjunctiva is secondarily involved, and the Meibomian secretion is vitiated; and these derangements, which are so frequent, are often considered to be the cause of the obstruction.

According to the extent of the suppuration, and the degree of accompanying inflammation, will be the size of the fistula; should the maxillary bone become carious, it may be very large. A lad thirteen years of age, with suppurating cervical glands, had lost from ulceration, the greater portion of the bone in front of the tube.

Fig. 63.



As there is seldom any discharge from the puncta while the tumefaction lasts, even when the tube is pressed upon, a common, but incorrect inference is, that all mischief is external to the mucous surface. I think that a circumscribed abscess over this great lachrymal conduit, without a visible cause, should be referred to disease of the tube, and induce that examination which may discover its nature. Obstruction of the tube is not an ordinary termination of strumous or other kinds of inflammation of the conjunctiva; indeed it is remarkably seldom seen as such, although there is no apparent reason why both surfaces should

not be affected at the same time ; however, I strongly suspect extension of inflammation from the interior of the nose to the tube, to be rather common.

The treatment of obstructed tube, after the reduction of acute symptoms, is twofold. Constitutional means are required to conquer the cause of the local disease ; and some mechanical measure is demanded to dilate the narrowed channel, or open it when completely occluded.

The severity of the local symptoms may be subdued by a few lancet punctures, and the frequent application of a cold lotion. Matter should be evacuated immediately that its presence is detected, and the knife should enter the head of the tube.

Leeching has not, according to my observation, afforded more than temporary relief.

To impress the importance of the influence of health over the local disorder, I may mention that I have seen a very marked case of obstruction that got well by a change of climate alone. A scrofulous youth was brought to me with symptoms that left no doubt of the complete obstruction of the tube, but abscess had not supervened. The lower lid was partially everted, and a constant discharge of secretions from the lid and the tube had excoriated the cheek. Eighteen months in the West Indies established his health ; and with the disappearance of glandular swellings about the neck, the tube regained its patent condition.

The mechanical treatment embraces the important considerations of the period for its adoption, the kind of means to be employed, and the term of its duration.


When there is a fistulous opening, the course to be pursued is plain. The channel is completely obstructed, and must be re-established.* Prior to that advanced state there may be dif-

* Even when a fistulous opening exists a spontaneous restoration of the natural passage will sometimes take place. We were consulted in the winter of 1851-2, by a lady who had long had a chronic affection of the lachrymal sac, which had terminated in suppuration and a fistulous orifice, from an attack of acute inflammation supervening during her confinement, a few months previously. As she was of feeble constitution, her strength still further impaired by lactation, and the season moreover unpropitious for an

ferences of opinion as to the stage of disease that imperatively calls for physical measures; but I think it may be laid down as a rule, that when the obstruction involves the necessity of emptying the tube of its accumulations by pressure, the time to employ them has arrived; and to delay their use until, from continued morbid action, there is material structural change in the tube, must tend very much to lessen their advantage, and to favor the formation of abscess, and its common result, fistula.

The solid nail-headed silver style is, according to the present state of our knowledge, the most appropriate local adjunct, notwithstanding its drawbacks of slight disfiguration, and rather unscientific manner of application. The subjoined sketch gives

Fig. 64.



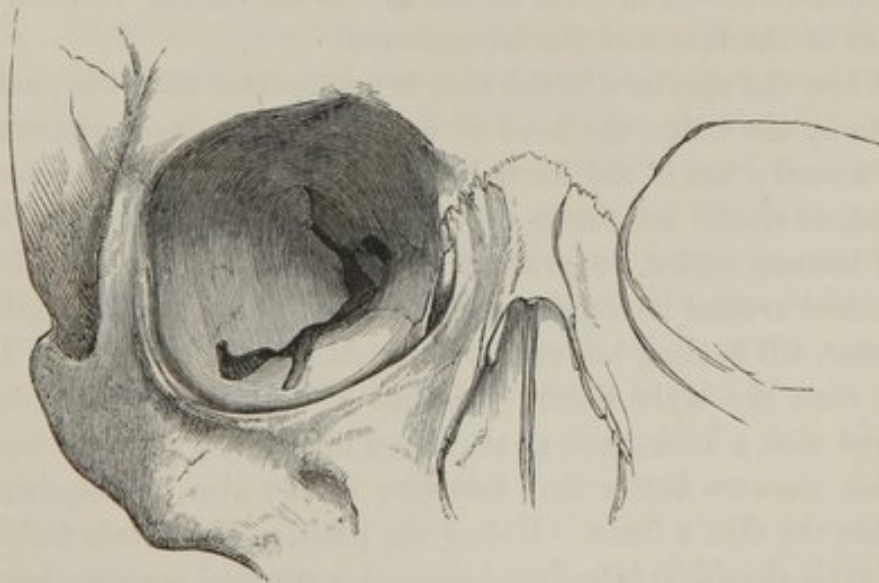
the size of that which is required for an adult, and measures an inch and a quarter in length, and the thirteenth of an inch in diameter. The head should be thick enough for the edges to be obtuse. For children the dimensions should be reduced. The bend causes it to sit better, and prevents the lower edge of the head from resting on, and irritating the skin. Styles are sometimes fluted or perforated in a part of their extent, under the supposition that the tears will pass more readily; but that form of construction, which is a modification of the metallic tube of Wathen, which used to be placed within the palpebral aperture,

operation, we declined to interfere, and recommended her to wait until the ensuing summer,—adopting meanwhile appropriate measures for the improvement of her health,—when, we expressed the opinion, that the fistula would probably close, and the tears resume their wonted course without surgical agency. Our advice was followed, and the event justified the prognosis;—by midsummer all traces of disease had disappeared. It is almost superfluous to remark, that in the treatment of fistula lachrymalis regard should be had to the state of the system, and the actual condition of the parts,—time being allowed for vascular excitement to subside, and also for the correction, as far as practicable, of any constitutional aberration.—Ed.

is decidedly objectionable: the secretions will flow readily between the smooth metal and the walls of the tube.

It requires some tact to introduce this little instrument readily and neatly. The usual direction to find the spot for insertion, by pulling the lids outwards, and making tense the *tendo oculi*, is not applicable when disease exists. Indeed, with much swelling and induration there is not any landmark absolutely trustworthy; but so long as the lower and internal angle of the orbit can be felt, it may form an unerring guide. The correct place for the aperture corresponds externally to a spot a little below and internal to the inferior punctum. With the forefinger of the left hand placed on that part of the edge of the orbit that stands in front of the bony canal, to give the idea of the level and of the distance of the tube from the surface, the knife, with the edge outwards, should be entered below and internal to the punctum, carried a little inwards behind the ridge of bone, and then downwards, inclining slightly outwards

Fig. 65.



and backwards, to the required extent. A reference to this sketch of the orbit, which is for the purpose of showing the relations of the bony canal, the ductus ad nasum, may be useful.

It is needless to attempt to pass the knife while the point is in contact with bone, for the right course has been missed. When the instrument is adroitly used, a bony surface is not touched.

The inclination of the facial angle in influencing the direction of the nasal duct should be remembered; in the Ethiopian variety of our race it inclines very much forward; in our own or the Caucasian, it inclines backwards. Very much resistance is often encountered in the tube, the obstruction being often far more than the symptoms indicated; but I have never met with any degree of obstruction short of ossification, that I have not penetrated. One unaccustomed to the resistance that may be met with, especially where there is a fistula, would scarcely, on a first occasion, have the confidence to persist and to use the required force. After the blood is sponged away, the style, which should be oiled, is to be passed without the previous introduction of a director or any other guide, which is unnecessary. The proof of correct entrance is the direction of the style, and escape of blood from the nose when the handkerchief is used, or sometimes without it. It is a very common error for the knife to be thrust through the lachrymal bone, or even in front of the ductus ad nasum, between the bones of the face and the integuments.

When the aperture in the skin is not greater than the passage made by the knife, the head of the style will remain external to the wound; but if the knife be larger than that which I recommend, or should a fistulous opening exist, it is likely to slip down and become buried, to prevent which a bit of thread should be attached around its neck and fastened to the forehead or nose by plaster, till healing has reduced the size of the aperture. If at any time the style should pass out of view, it may be readily raised with a hook, such as that used in the operation for squint, which answers better than forceps; it may also be requisite to divide the skin a little. Unless the position of a fistula forbid it, the style should be introduced through a surgical opening, because that heals much more readily after the style is taken out; but there may not be a choice, in which case the fistulous tract must be entered, and care must be taken that the head of the style

does not rest on the ulcerated surface, to prevent which, the form of the head may require to be modified, to be made globular, linear, or round, or it may be necessary to alter the bend of the neck, or the length of the body, so that the point shall rest on the palatine process of the superior maxillary bone, and keep the head from all contact with the surface. Sinuses may co-exist with fistula; they should be divided and made to heal from the bottom. Fungous granulations are not uncommon about all fistulæ, and may be readily removed by a mild escharotic, such as the powder of the red oxide of mercury. When there is caries of the maxillary bone, the gouge should be used, and the unhealthy surface cut away; necrosed bone must not be allowed to remain. Should there be ulceration either of the soft parts or the bones, the silver style is tarnished or even receives a deposit and corrodes:—even the decomposition of the tears may affect it. I met with an unusually marked example of this in a patient in whose case the style had not been periodically withdrawn and cleaned; and when I saw him after the lapse of two years, it was almost impossible to take out the instrument from the enormous mass of accumulation, especially on its lower part. Suspecting that the incrustation was something rather unusual—for my patient had during the last year taken great quantities of mercury for syphilis—I sent it to Dr. Garrod for analysis. His answer was, “The style I examined, and find to be coated to a considerable depth with sulphuret of silver, which rendered it exceedingly brittle. The sulphuret is doubtless formed from the sulphur compounds contained in the lachrymal secretions acting gradually on the metal.” This is the appearance of the style after the deposit had been burned off.

Fig. 66.




It will be seen that the neck was nearly corroded through.

When expense is not a consideration, a style silver-gilt, or of solid gold, or of platinum, should be preferred.*

Syringing the lachrymal tube through the style-hole is often useful, indeed, I may say almost requisite, if there have been disease of the bone, or copious suppuration. I subjoin a sketch of the syringe that I use, reduced a third less than the original. The lesser figure, marked with a star, gives the real size of the nozzle.

Fig. 67.



It is well to have nozzles of various sizes and lengths, for different cases.

The secretion from the nose is apt to collect on the end of the style, if it project below the nasal aperture of the tube, and the only certain way of ascertaining what should be the minimum length in any instance is, to withdraw the style and look to the point. Patients naturally desirous of disguising all blemishes, ask how the head of the style may be best concealed. White metal is certainly conspicuous, and a bit of black or colored wax, melted smoothly on the roughened head tends to render it less so. Instrument-makers usually put on paint or enamel; but neither wears well, and as any one can apply the wax, a clean unbroken surface can always be commanded. Gold is less conspicuous, and if the head of a gold style be reduced, as it may with safety after a few weeks' wearing, nearly to the diameter of the body, very little unsightliness remains.

Respecting the period of wearing the style I should say that as a rule, it may be removed when the lachrymal secretions pass readily into the nose, and all trace of inflammation of the tube

* Mr. Mackenzie prefers under such circumstances, a style of gold or platinum; those silver-gilt producing constant uneasiness by exciting galvanic action.—Ed.

has passed away, pressure failing to force out any secretion, and when the palpebral conjunctiva of the lower lid is no longer unnaturally vascular. The following case, besides illustrating a good example of success, shows how long it may be before such results are brought about.

Miss C. M., seventeen years old, and in delicate health, showed symptoms of obstructed tubes soon after an attack of small-pox, and about seven years before seeing me. All the misery of obstruction, from the overflow of tears on the cheeks, was present. The conjunctivæ were much inflamed; the puncta discharged pus and mucus, large quantities of which could be forced out of the tubes by pressure. Styles were passed. My patient was in occasional attendance for three years, and from time to time took those medicines, and adopted that regimen, which her depressed vitality required. Very soon after the styles were introduced, improvement in the state of the tubes commenced, and the restoration was gradual, although slow. It is now rather more than a year since they have been withdrawn, and she continues well.

At this time a young woman has returned to the Ophthalmic Hospital to ask leave to remove a style that she has been wearing for nine months. The other tube, in which a style had been worn for fifteen months, continues well after the interval of a year. I venture to add a brief account of another case in which there was fistula. A female, forty years old, an Ophthalmic Hospital patient, was brought on the 10th of April, 1846, with the palpebræ of the right eye closed from swelling, and a copious sanious discharge issuing from a small fistula lachrymalis. She was greatly depressed, the circulation feeble, and the tongue thickly furred. Five years previously, the eye began to water, and gave more or less annoyance, especially when she took cold; pus occasionally flowed from the puncta, and during the last twelve months it constantly escaped. Six weeks before she applied, the fistula formed. The bone around the head of the tube was denuded, a part also of the nasal duct was bare, and while exploring with the probe, a copious fœtid discharge ran into

the nose and issued also from the fistula. A tonic course of treatment was adopted. In a week, sloughs separated from the fistula, and more bone was exposed. A healthy action ensued, and in a month, when the style was applied, a bony surface could not be felt. The fistula healed, and on the 21st of July, she persisted in her determination of suspending all treatment, local and general, as she thought herself well. I am ignorant of her subsequent history. This case illustrates the difference between caries, and the mere exposure of bone by the loss of soft parts, while there is not disease of it, from which state it quickly recovers. The information that the probe affords is not sufficient for a diagnosis; the symptoms and the history of the case must also be guides.

It is not unusual for inflammation to linger in the head of the tube, and a glairy fluid to be secreted after the rest of the passage would seem to be healthy; and here I have generally found that pressure on this spot forces the secretion through the upper punctum alone. I do not know how to account for this, as the puncta open so closely to each other.

The less favorable result of treatment remains to be told. The style may have been discontinued under the apparent cessation of symptoms, but relapse discloses the necessity for its re-introduction. Yet I have generally found that the annoyance does not return with its former severity, especially if the patient empties the tube once or twice a-day. In another set of cases, where disease has spent its destructive power on the tube, and destroyed the greater part, or so injured it that complete repair is impossible, it will be necessary to continue wearing the style.

After removal of the style a slight depression, with sometimes a bluish tint, due, I presume, to a deposit from the tarnished silver, may mark the spot where it had been inserted. The aperture generally heals readily; indeed, as far as I know, I have seen but few cases, in which it has remained patent. But it must be observed that in public practice, the great source of my knowledge in this affection, patients very frequently cease attendance prematurely, or never return after the style is passed,

and thus an after-knowledge of their state is seldom acquired. In one instance, in a young lady, after the removal of the style, which had been worn for six months, there remained a minute hole, through which a delicate teardrop exuded when the tube was pressed. Nothing was done, the patient not deeming it necessary. In another case, that of a gentleman, in whom a style had been recently improperly placed, not only was the entrance badly chosen, but the lachrymal bone had been penetrated. As the annoyances of the obstructed tube remained, I withdrew the style and entered it correctly, little doubting that the aperture would heal; but in this, as well as every other attempt to effect its closure, I was disappointed. The edges were pared, raised, brought together, and retained by suture, the muscles of the face kept quiet, and the use of the handkerchief for a few days laid aside, that air might not be blown up the tube; all necessary precautions were taken, but to no purpose. Escharotics also were unavailing. Transplantation alone was left untried, and that would have been done had he not suddenly left me and placed himself under the care of another surgeon whose endeavors were equally fruitless.

It is but right to mention, in addition to these incidental occurrences, the case of a private patient, in whom, within an hour after the style was passed, profuse hæmorrhage from the nose took place, which could only be arrested by plugging the anterior and posterior nares. On a few occasions the style has seemed to produce irritation, when I have withdrawn it and in a week or two replaced it with benefit, and without the least appearance of its being injurious. A style that escapes accidentally from blowing the nose, or that has been struck out, should be replaced at once, otherwise the knife will be required to re-divide the integuments.

Without actual disease of the tube itself, its function may be arrested by external causes, as pressure from tumors in any of the neighboring cavities, the orbit, the antrum, and especially those of the nose, a single example of which will be enough to illustrate the whole of this class of obstructions. A girl, eigh-

teen years old, came to the Central Ophthalmic Hospital in July, 1845, with a large fistula of each tube of several months' duration. Till there were these free apertures, she had frequent abscesses attended with much discharge of pus through the puncta. The bridge of the nose was enlarged, and the integuments very red. Both nostrils contained polypi, and on the right side part of one protruded. The treatment was very apparent,—to remove the obstructions, wait the results, and in case the fistulæ did not heal, to pass styles. Strangely enough she indignantly refused to have the nose touched, but was not the least unwilling for the fistulæ to be treated. More than once a polypus has been removed from the tube itself.

Actual bony deposit may occlude a part of the nasal duct, and several instances have been met with. Mr. Travers says, "I have often found the canal completely obliterated by ossific inflammation at its upper orifice in skulls, and I know cases of enlargement of the ossa nasi, and of periosteal inflammation and thickening, marked by habitual overflowing of the tears, and occasionally by erysipelatous inflammation of the surface, in which the canal is evidently destroyed."

A young man who applied to me to be treated for an obstructed tube, was the subject of the tertiary form of syphilis, having nodes on several of the bones. There was a deposit of bone on the orbital ridge that quite obstructed the nasal duct. I here adopted that course which should always be followed if practicable, whatever be the cause of the deposit, whether specific, as in this instance, or arising from simple exostosis—I carried the style through the obstruction, a practice which is preferable to perforating the lachrymal bone, an expedient that should be resorted to only in cases of the greatest emergency. A small hydrocele trochar was used, and after a short penetration the tube was reached.

An instance of supposed congenital fistula lachrymalis is mentioned by Mr. Lawrence. It occurred in a boy at school, in whom it seemed to be a natural peculiarity, as no inflammation or any other affection of the part had been noticed. A small

drop of clear fluid appeared frequently on the surface of the skin, just below the tendon of the orbicularis. Mr. Middlemore appears to have seen this defect several times, for he speaks of it as the most frequent congenital deficiency of the lachrymal apparatus he has witnessed; in all the cases both tubes were affected, and the tears flowed over the cheeks. The question of treatment in such examples must depend on the inconvenience that is produced; and means should be the same as for the closure of a style aperture. It would be well in all instances to examine the tube from the nose.

A more remarkable defect is that of absence of the nasal duct. A man, twenty-one years of age, was admitted into the Hospital Necker, on account of congenital fistula lachrymalis, which discharged a limpid transparent fluid; there was constant epiphora. When the angle of the eye was pressed in the morning, a mucopurulent fluid flowed from the fistulous orifice and the puncta. An artificial nasal duct was made by piercing the os unguis, after the manner of Woolhouse. The inferior border of the internal portion of the tendon of the orbicularis was laid bare by incision, and a trochar directed downwards, backwards, and inwards, perforating the inner wall of the orbit. A silver canula, half an inch long, and enlarged at both its extremities, was introduced. Three days after the operation the small wound had cicatrized. In two months, the patient having neglected the directions of the surgeons—what they were is not stated—returned with epiphora; the canula was changed, and the case is said to have done well.—“British and Foreign Medical Review,” vol. xii. quoted from the “Bulletin Général de Therapeutique.”

I find in the work of M. Desmarres, p. 891, in connexion with this subject, the following remarkable passage, which is placed under the head of occlusion of the natural passages. “This method appears to me likely to prove serviceable in some cases of obstinate fistula. It is founded upon this observation, that if the lachrymal conduits do not exist congenitally, as has been observed by many surgeons, or if they have been destroyed accidentally, which is certainly still more frequent, the patients are

not on that account afflicted with epiphora. I have seen many fistulæ, dressed with Scarpa's nail for several years, cured by obliteration of the upper part of the sac. This method encouraged me in some difficult cases to imitate Nannoni, the inventor of this method, and I have had every reason to be satisfied that I did so. Among other examples, the following especially seems to deserve attention. A lady of Rheims had for many years suffered from a lachrymal fistula, and had been several times operated on, but unsuccessfully. I also operated and used Scarpa's nail, but I effected nothing more than those who had preceded me. Taught by former facts the difficulty of closing the lachrymal passages by introducing a piece of nitrate of silver, I now proposed to destroy them by Vienna caustic, and in presence of my colleague, who had sent me the patient, I deposited a certain quantity in the upper part of the sac, where I left it a few moments. Cauterization was deep, extensive, and followed by so free a suppuration, that for some days I feared there would be no other result than a deformity towards the great angle, but on the contrary, the wound cicatrized perfectly, and the disease was cured. This lady is now free from fistula, as also from the epiphora, which has completely disappeared. Frequently since, I have employed cauterization of the lachrymal sac with Vienna caustic, but with greater precaution, and I have had good reason to be satisfied. Nevertheless, however good may be the results obtained by Delpech, Bosche, M. Caffort de Narbonne, many other surgeons, and myself, I think one ought not to have recourse to the closing of the nasal canal except as a last resource, and that, if it can be cured by any other means, they should be preferred."

PROBE OR SOUND FOR THE LACHRYMAL TUBE.*

The form of instrument represented, about the average for an adult, I find to be the best adapted for introduction into

* The mode of designation employed by the author is probably intended to express more accurately the shape of the part, but confusion is apt to arise from changing familiar appellations for others, even though perhaps more strictly correct.—Ed.

the lachrymal tube. As the nasal duct and the parts around vary at different periods of life, instruments of corresponding dimensions are demanded. Each nostril requires one for itself, and this belongs to the left. The metal should be soft, or virgin silver, admitting of easy adaptation by the fingers, or a pair of pliers, to any figure. The round and delicate handle almost insures gentle usage, and is an improvement on a broad flat one, which affords considerable leverage, and is besides awkward. The lesser figure is a front view of the bent portion of the instrument.

Fig. 68.

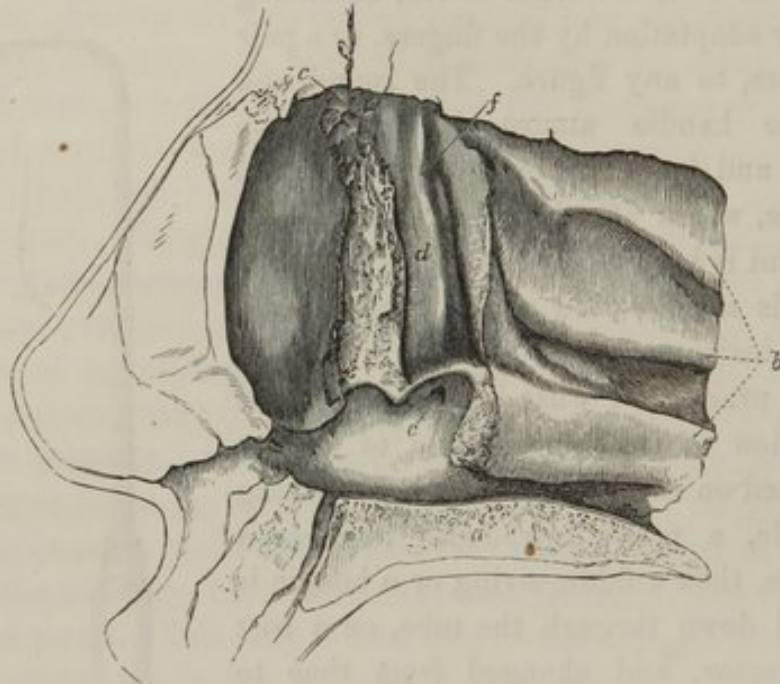


The practice of what is termed gradual dilatation of the tube, seems to be yet practised on the Continent. An opening is made, a probe introduced to force a passage, then a fiddle-string or a bougie is carried down through the tube, on a sort of director, and changed from time to time for one of a larger size. This is a modification of the conical coil of catgut used by Beer, and passed through the tube like a seton, one end at the eye, the other at the nose, and pulled daily that a larger portion should enter. Other similar means, among which is the mesh seton, have been in vogue. It appears to me that this meddlesome surgery may be beneficially dispensed with. Gradual dilatation with fiddle-string, bougie, or anything else, is unnecessary; for when the tube requires to be opened, a full-sized style might at once be passed.

The frequent passage of instruments of any kind must be in-

jurious, and if there be a necessity for a long or permanent use of a foreign body to maintain a channel, neither catgut nor any soft material will answer.

Fig. 69.



a, The palatine process of the superior maxillary bone.

b, The turbinated bones: the anterior half of the lowest one has been cut away to show the opening of the tube (*e*) in the lowest chamber of the nose.

c, The surface left after a part of the nasal process of the superior maxillary bone has been cut away to exhibit more clearly the tube (*d*), the entire surface of which is bared of its bony parietes.

f, The point at which two bristles, that were passed through the puncta, met; all above that, to the bone, is the head of the tube.

A probe passed through one of the canaliculi can never, from its necessary smallness, be of much use, if indeed of any, in removing an obstruction of the tube.* Quicksilver injections and

* This opinion is too confidently expressed. It has been abundantly proved that the puncta and canaliculi may be dilated by a series of graduated probes to such a degree as to admit the introduction into the sac of a style equal in thickness to those commonly used in restoring the patency of the nasal duct. This is the mode of operating employed by our colleague, Dr. Hays, and as he

ordinary injections through the puncta by a syringe, I must dismiss with merely remarking that they are useless, and cannot overcome obstruction. The use of escharotics I also condemn. I pause, however, a little, to examine La Forest's nasal catheterism, and at the same time it may be useful to glance at the surgical anatomy of the nasal aperture of the tube.

The preceding sketch, which is of the natural size, was taken from an adult female.

In many examinations that I have made of the nasal opening of the tube, the aperture has not been discoverable, as might be imagined, after the inferior turbinated bone had been cut away, but the minute slit has always required to be searched for with a probe. Indeed, to make the aperture apparent for the sketch, it was a little ruptured and opened. There is variation in its position perpendicularly and horizontally. Sometimes, too, it is on a depression in the wall of the antrum, or on a projection.

The proposed method of La Forest is, the frequent introduction of a sound into the tube through the nasal end, and occasional injections through a catheter. These have many times been abandoned and renewed; and to the late Mr. Morgan is due their last resuscitation in England. The difficulty of the proceeding from the anatomical intricacies of the part, and the necessary tortuosity of the instrument, and the injury to the tube that is inseparable from the operation, are more than sufficient to banish them from practice. It must not be supposed that because a sound can be forced into the passage in the dead body, that a similar proceeding can with impunity be done on the living. I do not think that the daily passage of the sound, if so devoted a patient could be found, would be enough; for with decided obstruction, nothing short of the presence of a body in the tube for a long period will suffice. I was not a little amused to read of a recommendation from an advocate of catheterism, that it should

states, with very gratifying results. We have not adopted it in our practice, because it not only makes too great a demand on the time and patience of the surgeon, but has also appeared to us to be attended with more suffering than the ordinary method.—ED.

form part of the morning toilet. But the sound is not without its uses, or I should have dismissed it with a few words; it may afford information of value, relative to the degree and the position of a stricture, and especially in connexion with morbid growths that encroach on the tube. I shall describe the manner of using it. The point should be introduced into the nose horizontally, and carried along its floor to a distance that will insure the position of the tube being reached, when it should be turned upwards and outwards under the turbinated bone, and against the wall of the antrum, and moved about till it is engaged in the aperture. The usual cause of failure in its entrance consists in not carrying the instrument sufficiently low to insure its being in the proper chamber of the nose, and in attempting to find the orifice before it has been carried far enough back. It is to be feared that the membranous wall of the tube is more often entered than its orifice. When the sound is passed, the end may be felt at the angle of the orbit. The entire proceeding,—the introduction and the withdrawal,—requires much delicacy of touch.

CHAPTER VII.

CARIES OF THE ORBIT.

By the term caries, I understand interstitial absorption or softening of bone, followed by ulceration and suppuration. This may occur in any portion of the orbit, but every part is not equally liable to suffer; the circumference is most commonly involved, and distortion of the palpebræ, injury to the conjunctiva, and, in aggravated cases, damage even to the eyeball from exposure, are almost certain consequences. Besides these results, extension of the disease to the interior of the skull, by which the brain or its membranes may become involved, should be enumerated.

I shall not detail the several stages by which caries is developed, it is sufficient to record the fact that it may be induced by inflammation of the contiguous soft tissues, including the periosteum, or that it may commence in the bone itself. Of the predisposing causes struma is the most frequent, indeed if syphilis and the abuse of mercury be put aside, there are comparatively few cases that cannot be traced directly to its influence.

The following is one of the very few instances that I have seen of caries, commencing fairly within the orbit, and it is the only fatal one with which I have been concerned. A remarkably robust and powerful carter, forty-two years old, applied to me in May, 1844, with impaired vision and slight protrusion of the left eyeball, without lateral displacement. The integuments of the external canthus and of the cheek were swollen and indurated, without either redness or pain. The other portions of the lids were healthy. The protrusion of the ball and the mistiness of

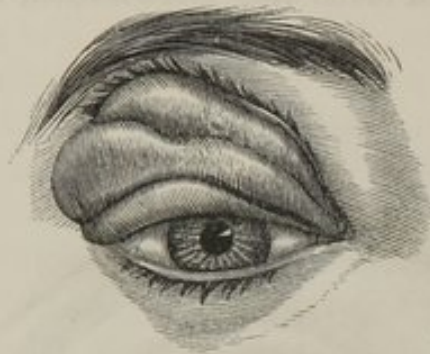sight commenced three years prior to his applying to me, but the swelling was of recent occurrence. He assured me that from time to time as many as eight hundred leeches had been applied, partly by the direction of a surgeon and partly by his own desire. I lost sight of him till January, 1845, when paroxysms of pain induced him to return; the eyeball was now more prominent, its movements were restricted, vision decidedly worse, the tumefaction greater, and the parts inflamed. He was emaciated and very weak. Even now I could not be certain that suppuration existed, but I made a puncture over the outer and lower edge of the orbit, apparently the most favorable spot, and deepened the cut through the brawny tissue to the bone before the pus flowed, about a dessert-spoonful escaping. Much temporary relief ensued; he became very debilitated, went into the King's College Hospital, and after much nervous excitement, a delirium, and fits of an epileptic character, coma supervened, and he died on the 27th of February. I attended the *post-mortem* examination, which was performed in the presence of Dr. Todd and Mr. Fergusson: no trace of disease could be found within the cranium, and the interior of the orbital parietes did not show any signs of inflammation. There was an abscess at the outer and lower angle, which passed outwards, and involved the malar bone in its orbital and its outer aspect, these surfaces being carious, and a small sinus not involving the bone, had burrowed through the spheno-maxillary fissure into the zygomatic fossa. The chest was not examined. The abdominal organs seemed healthy. The duration of the disease was very remarkable.

I am indebted to my friend Mr. W. O. Chalk, the late surgeon to the Margate Sea Bathing Infirmary, who has had extensive experience in diseases of bone, for the sketch (Fig. 70) from a patient under his charge with caries of the edge of the orbit. I exhibit it to show to what degree the lid may be influenced when the caries proceeds unchecked for years, as it did in this young man. It is the most marked example I have seen of ectropium of the upper lid, from this cause.

In patients affected with caries it is useless to attempt local

measures, without attending carefully to the general health, which is always seriously impaired.

Fig. 70.



Modern surgery teaches us that the process of cure may be much facilitated by removing the carious portion, which is incapable of repair, and which is never cast off except by a very tedious process. The necessity of cutting beyond the diseased portion into the new bone, which is thrown out by nature for the purpose of repairing the lesion, is well known; yet surgeons do not in general carry out the practice in caries of the orbit, and disease, that may be cut short in a few months or weeks, is allowed to continue for years. The gouge is the instrument that must be used for carious bone about the orbit, and, as it is almost needless to observe, with the greatest care about those parts of the skull that are contiguous to the brain.

Necrosis frequently accompanies caries, and may be a natural step towards cure, the point of separation being at a spot where there is capability of healing. Here, as in other parts of the bony frame, the sequestrum may be so locked in, that mechanical relief is demanded.

A patient of mine at St. Mary's Hospital, a lad eleven years of age, with a scrofulous diathesis, had caries of the upper edge of the orbit, and the surrounding soft parts being in that quiescent state that warranted interference with the bone, I scraped away the carious portion from the outer side, and while applying

the gouge for a similar purpose to the inner, I discovered a necrosed piece as big as a pea, which was detached, and a few touches of the gouge to the enclosing cavity were requisite before it could be removed.

I subjoin a sketch taken after cicatrization, to show how little deformity remains.

Fig. 71.



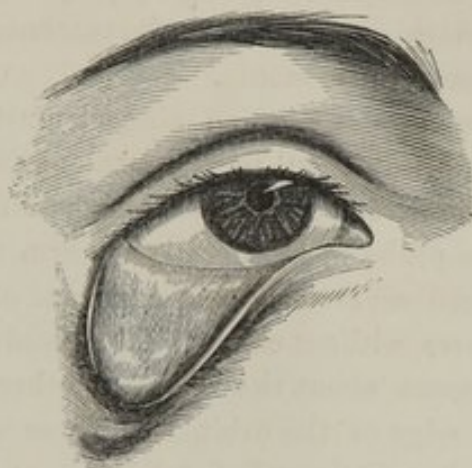Had there been neglect in this case a distressing ectropium must have been inevitable.

Mr. Chalk has at this time under his care a girl with ectropium of the lower lid from caries, in which there has been a compensation to some extent for the lost bone. A sharp toothlike process has been thrown out from the edge of the orbit, which wonderfully ameliorates the original depression of the tarsal edge. This is the only instance that I have seen of such repair.

The following case of caries of the orbit was attended with the most remarkable depression of the lid I have ever witnessed from such a cause. L. P., aged fourteen years, at the age of three years, had necrosis of the right thumb, and afterwards, in succession, of the left foot, right lower jaw, right malar bone, and, to a small extent, of the outer edge of the left orbit, from each of which places small pieces of bone came away at intervals. In consequence of the ulceration and subsequent cicatrization attendant on the disease of the cheek, the right lower eyelid was completely destroyed, with the exception of its ciliary margin,

which was drawn down and firmly fixed at the bottom of a deep depression half an inch below the margin of the orbit. The eye had been in this state for six years, when she applied to Dr. Taylor at the Central London Ophthalmic Hospital. I subjoin a sketch of the deformity.

Fig. 72.



Transplantation of skin was done with success, and the lid somewhat restored. The eye after operation is given in the sixth chapter, under the subject of Ectropium.

Dilute nitric and phosphoric acids may be employed with advantage in those cases in which the gouge cannot be used. Mr. Bransby Cooper strongly recommends phosphoric acid diluted with an equal weight of water, as being useful in facilitating the removal of sequestra, converting the phosphate of lime into a biphosphate, which is more soluble and more readily acted on by the pus. Much may be done in the way of checking the extension, or even preventing the occurrence of caries, when the disease commences in the soft parts, by the timely evacuation of abscesses by free incisions, and after-care in preventing sinuses.

Chemistry and the microscope now assist us to diagnose disease of bone. According to Mr. Bransby Cooper, an appreciable quantity of phosphate of lime in an ounce of pus, taken from a lumbar or psoas abscess, is an indication of a carious condition

of the vertebræ. As but a small quantity of purulent fluid can be collected from an orbital abscess, I asked Mr. Cooper for an appropriate test, and he kindly tells me that, if necrotic pus be placed under the microscope, an amorphous deposit will be seen, which will disappear on the addition of dilute acetic acid; or if the pus be burnt away in a platinum spoon, the phosphate of lime will be left in the form of a grayish powder, which may be dissolved in muriatic acid without effervescence, and then precipitated by an excess of ammonia.

Mere exposure of bone from an abscess must not be mistaken for caries. Acrid, thin, and fœtid purulent discharges with unhealthy granulations, are pretty sure signs of the bone being diseased, and the probe will generally confirm these indications.

I have witnessed several cases of exposure of the edge of the orbit from abscesses, without caries. The child of a noble family had several abscesses about the body, together with one at the lower and outer edge of the orbit, which was opened by a very small puncture; but little relief followed, and as the lids remained swollen, the eye inflamed, and bare bone was felt by the probe, it was supposed that caries existed. I made a free incision through the swollen and boggy tissues, giving a proper exit to the pus, and for a few days maintained an opening by introducing a strip of lint. The improvement was most marked, and in less than three weeks the child left town with the abscess nearly cicatrized.

I have received some hints from Mr. Field, the present surgeon to the Margate Royal Sea Bathing Infirmary, respecting the lessening of the scar consequent on suppuration about the orbit. Mr. Field's vast opportunities of practical experience in this matter, and his accurate observation, entitle his recommendation to the highest respect. On the importance of the early evacuation of pus he is emphatic; and he tells me, what my lesser experience confirms, that strumous abscesses in the immediate neighborhood of the orbit, when left to themselves, are always followed by a greater or less degree of ectropium. An important part of his treatment, when the bone is unaffected, is to use

the caustic potass, and destroy the entire wall of the abscess, the results of which are the removal of the ill-conditioned textures, and the stimulation of the surrounding parts, whereby abundant healthy granulations are thrown out, and thus more rapid healing, and less deformity. He has even used the potass to open small abscesses, and the rapidity of cure has, he thinks, shown the value of the plan. The following is one of many similar cases. J. S., the subject of scrofulous disease in several parts of the body, had a painful swelling, apparently of the periosteum, extending around the outer half of the right orbit. A concentrated solution of iodine was daily applied for nearly four months, together with general treatment, with the effect of somewhat reducing the swelling, but an abscess pointed at the lower part, and this was opened with potassa fusa; a slough rather less than a sixpence separated in about a week, granulations sprang up in great abundance, and the ulcer quickly cicatrized, and did not produce ectropium.

CHAPTER VIII.

NÆVI MATERNI.—DILATED AND TORTUOUS VEINS.—
ANEURISM BY ANASTOMOSIS.

NÆVI.

THIS affection, which is now generally restricted in its application to those congenital marks or tumors characterized by peculiar vascularity, and distinguished from the mole or mother-spot, is not, as is commonly supposed, a mere exaggeration or hypertrophy of blood-vessels. Vascularity is certainly the great characteristic, and there is an inducement to arrange them under arterial and venous kinds, according to the supposed sort of blood with which they are filled, without reference to the nature of the vessels that contain it; but this would apply almost exclusively to those on the surface. It is better for surgical purposes to speak of them according to the positions they occupy in the body, as subcutaneous, cutaneous, and mixed. The subcutaneous is generally more or less defined, but may be without definite limits, and, according to its depth from the surface, is of a light bluish tint, or colorless. When deep, it is in all respects like a common fatty tumor; and its true nature may be so obscure as to be overlooked; and our best surgeons have been deceived. It is recorded in vol. xxvi. of "The Medico-Chirurgical Transactions," that Mr. Liston proceeded, after careful examination, to extirpate from the ham what he supposed to be a fatty tumor, but which proved to be made up of erectile tissue, as he termed it. The case is well worth perusal. Mr. Fergusson gives in his "Practical Surgery" a somewhat similar instance that occurred to himself. A

supposed cyst in the cheek proved to be a subcutaneous vascular tumor. I could quote another instance that happened at one of our London Hospitals, and doubtless, many surgeons have been similarly deceived.

The cutaneous variety is particularly well-marked, and varies in extent and in level—sometimes being a stain of varying breadth, or like a conglomerate mass of vessels forming a tumor.

In most instances of these two kinds, and especially in the cutaneous, when pressure is applied, the blood-vessels are more or less emptied, and when it is remitted they refill. The sensation conveyed to the finger, and the rapidity of the change, are worth little as a diagnostic of the nature of a vascular tumor.

Little was heretofore known of the structure of nævi: the difficulty attending the means of procuring proper specimens for research has, no doubt, been the bar to our knowledge; and even at this time, few dissections have been made. Mr. Birkett, somewhat recently, made an elaborate examination of a subcutaneous one furnished to him by Mr. Curling; his masterly description is in vol. xxx. of the "Medico-Chirurgical Transactions." He tells us that it is composed of areolar, uniting or fibrous tissue, capillary vessels, and vessels of larger calibre, and he details the manner of their disposition. With regard to their histological relations, he concludes that there is no more reason to give them the title of vascular or blood-vessel tumors, than many others which have received very different names; that they consist neither of small arteries, small veins, nor of a mixture of these vessels. They do not consist of erectile tissue, but more closely resemble the corpus cavernosum than any other tissue; and Mr. Birkett classes them with the fibrous tissues, and considers that they are probably developed like them, and possess cells that are in communication with larger or smaller veins, and are nourished by arteries that may differ greatly in size.

Mr. Paget is inclined to consider nævi as erectile tumors, and meets the objection advanced in the valuable "Lectures on Surgery," by Mr. Humphrey, of Cambridge, that they possess no power of filling themselves with blood, as if by some internal

force, with the shrewd remark, that since the power of true erectile tissue depends as much on the accessory structure of nerves and muscles as on the tissue itself, we may, perhaps, apply the term erectile to these tumors, remembering only, that, for this, as for other structures occurring in tumors, the imitation of the natural tissue is imperfect or partial. He also states, that the likeness which these tumors bear to the erectile tissue, as exemplified in the corpus cavernosum penis, is sometimes in general appearance perfect. A well-marked specimen in the Hunterian Collection is alluded to in illustration; and he adds, that what he has seen, and the description which more fortunate watchers have recorded, leave him little doubt that this imitation of erectile tissue is a frequent character of such tumors. As further evidence, he remarks, "the descriptions by Mr. Wardrop and Mr. Cæsar Hawkins, and the more minute accounts of structure by Mr. Goodsir, Mr. Liston, and Rokitansky, confirm this view; and neither Mr. Birkett's, nor any other that I have met with is discordant to it." Mr. Paget's lecture, from which this is taken, the eighth of the course, is in the "Medical Gazette," for August, 1851.

Mr. Simon, in his "Lectures on General Pathology," classes nævi under the head of vascular tumors, and describes cutaneous nævi, as consisting of adventitious cavernous structure with the interlaced columnar appearance of ordinary erectile tissue, coated with tessellated epithelium continuous with that of the adjoining vessels; the hollow intercolumnar spaces communicating, and appearing to be altered capillary channels of the part.

There is nothing positively known of the mode of their development. Rokitansky thinks that they arise as excavations in a blastema deposited in a solid form, and that the reticular structure then communicates with the original vessels of the part by penetration of their walls, and forms a diverticulum from the circulation. Mr. Simon discredits this, and considers them as a proof of true growth in the original blood-vessels of the affected part. Whether they are always congenital is still somewhat disputed; but the solution is not of any surgical moment.

Concerning pulsation in them, there is difference of opinion. My own belief is, that a simple nævus, however large, does not pulsate, and for arterial thrill to be present, it must be more or less mixed with aneurism by anastomosis.

Strange as it may appear, there are persons who discountenance any treatment for nævi, trusting rather to a natural cure; but it should be remembered that in no kind of this, or indeed of any other vascular tumor, is there certainty of natural cure, nor is a case wholly unattended with danger from accidental bleeding.

A mere stain, whether of an arterial or a venous character, need create little apprehension, and if it remain stationary there is no call for treatment, unless it be small, and a slight scar deemed preferable. Although there is very little tendency in mere stains to increase, there is little chance of their disappearing. I have met with some of these stains on the conjunctiva. With the bluish superficial nævus there is greater probability of natural resolution than with the scarlet kind. That the vitality of nævi is low is a well-known fact, and accidental injury will sometimes be followed by sloughing or ulceration. In vol. xxii. of the "London Medical Gazette," page 795, is a case by Mr. Curling, of extensive nævus of the upper extremity, spontaneously cured by sloughing. The subject, a child, was fourteen days old when Mr. Curling saw it. The nævus extended from a little below the middle of the arm on the outer side, over the whole of the forearm, except a little strip at the inner side, and covered the back and the greater part of the palm of the hand, and the posterior part of the fingers as far as the second articulations. It was slightly elevated above the level of the skin, and of a bright scarlet color, except towards the centre of the fore-arm, where it gradually assumed a purple tinge around a small sloughing ulcer about the size of a sixpence. The mother stated that this sore appeared five days after birth, as a small pimple, and had since gradually increased. The nævus, however, did not increase. For several weeks sloughing went on at the expense of the morbid vascular

tissue, and continued till it arrived at the sound skin, no part of which was destroyed, the slough ceasing as soon as that was reached; then reparation set in and advanced with rapidity. A debilitated constitution is favorable to their disappearance; and nævi also show different tendencies to disappear according to the parts in which they are placed, being more likely to decline about the neck and trunk than elsewhere; and increase is more certain when seated upon, or in contiguity to, mucous membrane.

My own course of proceeding is unhesitatingly to adopt some treatment when a nævus, however small, shows any symptoms of increase, be its nature what it may; and this is under the knowledge that the increase may be temporary. If at any time surgical proceedings be delayed for the sake of watching the growth, the slightest augmentation should be the signal for acting; but when time is thus allowed for an increase, it is as likely as not, that the augmentation may be subcutaneous, and that without affording external evidence of spreading. This applies especially to nævi on and about the eye and its immediate vicinity, where from the functional derangement they may cause, independently of ordinary evils, they require a strictness of attention scarcely demanded in any other part of the body, and certainly not in many.

Extirpation, sloughing, suppuration and adhesion of their intimate structure, are the available processes of cure, and we should endeavor to couple the removal of the disease, with the least subsequent deformity and with the slightest disturbance or destruction to the surrounding parts. It is an advantage to possess several resources of treatment, from which, according to the peculiarity of the disease, there may be a selection.

The most simple means that can be adopted is that of pressure, but its use should be restricted to localities that will allow of counter pressure, by an opposing surface. Many methods are employed, but no one can so generally be depended on, as that produced by a metallic spring, after the manner of a truss, and by which bandages, which are always objectionable, are super-

seded. Mr. Abernethy was in the habit of applying cold washes along with pressure by bandage, and sometimes the growth was checked; the nævi shrank and were no longer of consequence. Dieffenbach also employed pressure by means of a piece of tea-lead, or of a small silver coin. But pressure may irritate and eventually augment the growth instead of effecting a cure; moreover it can never be thoroughly relied upon, while it requires long perseverance, is troublesome in application, and irksome and annoying to the patient. Combined with Dr. Marshall Hall's plan of breaking up the interior of the tumor with a needle through one place of puncture, it may be more effectual.

Intense cold is an agent that may be very serviceable. Dr. James Arnott tells me that he employed it with benefit, in a nævus, the size of a sixpence, on the forehead of a child about three years old; enlarged vessels led to it, and the very rapid growth induced the mother to bring the child to the Brighton Dispensary. It was congealed, as Dr. Arnott terms it, by the common frigorific mixture of ice and salt, applied in a small network bag for about three minutes, on three occasions, with intervals of a week. The effect was to reduce the enlargement one half, and apparently to remove all vascular excitement. The vessels which had previously led to it were no longer visible after the third application.

A plan of cutting and searing nævi, by means of a piece of platinum wire made red hot by a galvanic battery, as proposed by Mr. Marshall, of University College, is now being generally tried: the application of heat, however, has long been practised. M. Carron du Villards passes long pins through the greatest diameter of the tumor, bending them till their heads meet, unites them by a metallic knot, and then applies the flame of a candle to the pins till they are of a white heat, moistening the tumor during the while with oil—a practice, together with the actual cautery of M. Cloquet, not likely to be generally followed

in England. Galvano-puncture has been recommended by Rognetta.

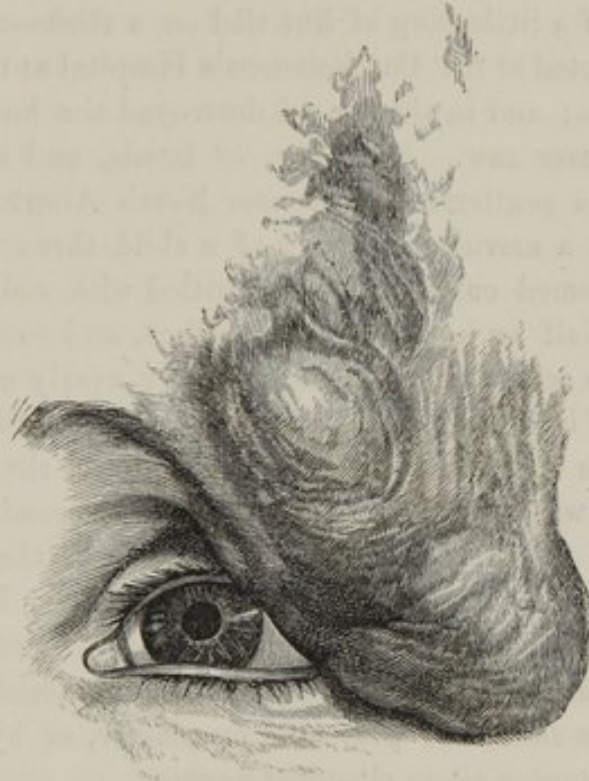Removal by extirpation is of old date; it is somewhat dangerous, and not lightly to be undertaken. Allan Burns, in his "Surgical Anatomy of the Head and Neck," gives an instance of a cutaneous nævus that he removed from the eye, temple, and side of the face in a middle-aged man. A part of the upper eyelid, and the outer part of the eyeball, including the conjunctiva and the sclerotica, were involved. Extirpation was performed, the operation being undertaken because of the growth increasing, especially in its ocular portion, and threatening to obscure the eye, and the patient's anxious desire to be relieved of it. A very tedious and intricate dissection was required, the tumor dipping in, and forming attachments that could not be foretold. Success crowned his efforts, and the only resulting inconvenience was some alteration in the position of the upper lid, in consequence of adhesion to the globe, and a restriction of its movement.

It would not be easy to produce a better example of a congenital cutaneous nævus about the eye than that shown in the following figure, taken from a man forty years old. It was at first a mere dot upon the brow, and the increase had been very slow. It was raised about three quarters of an inch throughout its entire extent, was dark blue, apparently filled with venous blood, dense, cold, and pulseless, did not admit of much reduction in bulk or in color by pressure, and was subject to periodic pains.

Although extirpation may be admissible when the tumor is small and probably circumscribed, and the surrounding parts healthy, there are not many cases in which it should be preferred. Several children have died under the operation; and the possible, and very probable recurrence of severe hemorrhage must always be a bar to this practice. If it should seem advisable to adopt it, John Bell's maxim of not cutting into the mass, but of cutting it out, and keeping as wide away from the

tumor as possible without unnecessarily destroying skin, should be observed.

Fig. 73.



Vaccination, like every other kind of irritation, and every class of irritants that has been applied to nævi, has occasionally succeeded; yet, I have seen a great increase in several which had been submitted to the vaccine virus. The cases to which it seems most applicable are those in which a single pustule would circumscribe the nævus. Dr. Gregory, of the Small-Pox Hospital, tells me that from the frequent failures he has met with, he has ceased to treat any in this manner.

Escharotics form a very powerful and efficient class of remedies, and are frequently used; potassa fusa and the strongest nitric acid being preferred. They are chiefly applicable when the disease is limited to the skin, and is superficial rather than deep.

Both the potass and the acid are exceedingly painful, and several applications are often necessary. During the several years I was Mr. Lawrence's pupil, he employed nitric acid in the treatment of all the cases of nævi that came to the hospital, applying it by means of a little mop of lint tied on a stick—a plan most generally adopted at St. Bartholomew's Hospital at the period of my attendance; and in this way I destroyed the largest cutaneous nævus I ever saw. Mr. Hey, of Leeds, and myself, were summoned to a gentleman's seat near North Allerton, in Yorkshire, to treat a nævus on the leg of a child three months old. The nævus seemed cutaneous, was mottled with red and purple, raised about half an inch from the surface, and occupied rather more than the central third of the leg, very nearly encircling it: a thin strip of integument at the back part was sound. At birth, it was the size of a five-shilling piece, and till the child was a month old it was nearly level, and had not spread. A single application of the acid sufficed. The whole of the eschar did not separate till the expiration of three months; I did not see the child from the day of the consultation till two years after in London, when not a trace of the disease remained. The surrounding parts should be protected by plaster, or by substances that will decompose these chemical agents.

Caustic, combined with subcutaneous puncture, first introduced by Mr. Wardrop, has been extensively employed by Sir Benjamin Brodie and other surgeons, in nævi of very large extent. Sir Benjamin punctures the tumor in several places with a narrow flat-bladed knife, breaks up the tissue, introduces a flat probe coated with nitrate of silver, and moves it about in the torn mass. He repeats this at intervals, according to the effect; and he has thus destroyed a very large subcutaneous nævus, with a very slight amount of disfiguration. This treatment may extend over a long period, perhaps over several months.

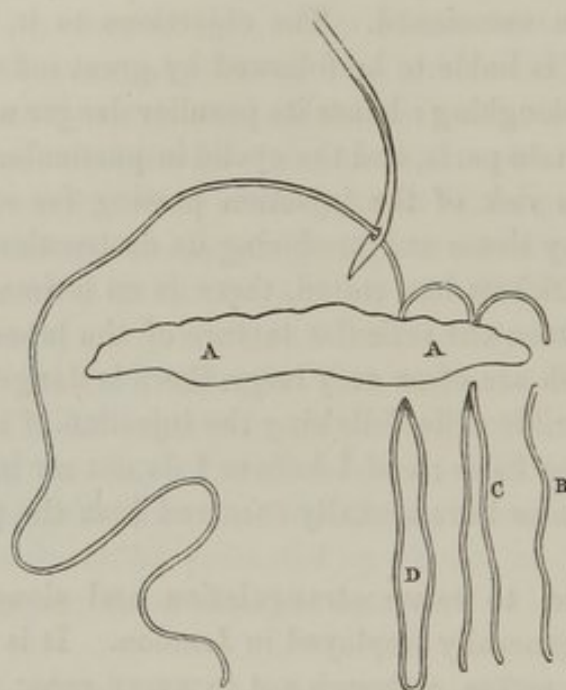
In the year 1836, Mr. Lloyd published in the "Medical Gazette," vol. xix., p. 13, his mode of treatment by injecting irri-

tating fluids, having, as he states, been led to its adoption for the purpose of overcoming the danger of the knife, the insufficiency of the ligature, and the disfiguration produced by escharotics. A puncture is made at some distance from the tumor, the nozzle of a syringe introduced, and the fluid injected. He considers the principal advantages to be, its applicability to nævi so large and so situated as to be wholly irremediable by other means, the absence of deformity and of constitutional disturbance, and the slight pain occasioned. The objections to it, however, are grave; for it is liable to be followed by great inflammation, ulceration, and sloughing: hence its peculiar danger when nævi are situated in certain parts, and the eyelid in particular; and, again, there is always risk of the injection passing for some distance into the healthy tissue and producing its destruction. Moreover, since, as Mr. Birkett has stated, there is an intimate connexion subsisting between the reticular texture of the lobes of nævi and the veins, which are often very large, there is danger of phlebitis with all its terrible evils, following the injection of these growths with stimulating fluids; and I believe I do not err in stating that several fatal cases have actually occurred from the practice.

The ligature, to cause strangulation and sloughing, is the remedy most generally employed in London. It is applicable to every kind of nævus, although not to every case; while it may be used in combination with other modes. The most simple means of application is to introduce one or more pins of soft steel across the bottom of the tumor, and with a string of suitable strength, and sufficiently long to be securely held, to tie it very tightly, cutting off, of course, the pin points. Some surgeons leave the part tied to ulcerate off; but the cure is equally well effected, and a less scar is left, by releasing the ligature, and withdrawing the pins at an early period, that is, so soon as the surface of the nævus is blackened over, and the superficies evinces a loss of vitality, at which period the entire nævus is generally destroyed. As tying the skin would cause great pain, and may in children produce constitutional disturbance, unless a nævus be

small, a channel should be cut for the ligature. A single ligature will suffice only when the nævus is superficial and small; if large, the centre cannot be constricted; then more than one must be used, after the following manner. A double ligature is passed under the nævus with a needle set in a handle, and each half separately tied; and when it is required to subdivide and submit

Fig. 74.



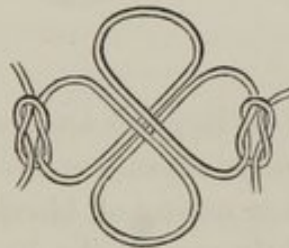- A, A, Projecting nævus to be tied.
 B, Single ligature passed beyond the limits of the growth.
 C, Cut extremity of the first loop to form a knot with B.
 D, Third loop, uncut.

smaller portions to strangulation, more ligatures must be used, and the needle passed crucially, or even in other directions, so that the entire growth may be traversed and every part included within the circles of the ligatures.

The above diagram, taken from a paper by Mr. Curling, in the London "Medical Gazette," for January, 1850, represents a case so treated.

If a nævus be superficial, there is not any difficulty in treating it in this manner; but, if deep, the ligatures must be kept down by being tied under pins previously introduced as deeply as it is necessary that the ligatures should act. Certain forms of noose may, in particular instances, especially when the mass is round, be preferable to a multiplication of ligatures. Mr. Fergusson has suggested one, and Mr. Druitt has figured it in his work on "Surgery." This I have modified a little so as to make it more symmetrical; for double ties work better when made uniformly, and by my arrangement of the threads, there is less likelihood of a mistake being made by the wrong ends being taken up. The annexed diagram shows the arrangement of the noose, which is tied in the following manner:—A nævus needle, with

Fig. 75.

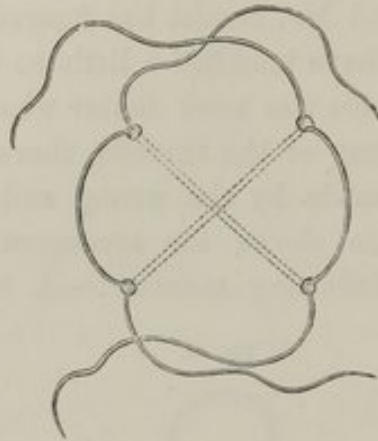


an eye sufficiently large to be readily threaded, armed with a double thread, is passed obliquely from left to right across and under the mass. The bow of the thread is divided, the thread disengaged, and the needle withdrawn; the needle is again threaded with the upper end of the thread on the right side, brought round on the right, entered midway between the two punctures, and carried transversely across; the thread is disengaged, the needle not yet withdrawn, but first threaded with the lower end of the thread, on the left side of the first puncture, and then drawn back. If these directions have been correctly followed, the tie will have the form shown in the diagram on next page.

For the subcutaneous class, tying is peculiarly adapted. The late Mr. Liston was most successful with it, reflecting the skin, usually by a cross incision, and then strangulating the nævus. After the tumor has been exposed, it should be pulled well up

before being tied. The bleeding is not usually to the extent that might be expected, deep nævi being generally surrounded by a sort of fibrous capsule which isolates them, and renders the integument easy to be detached. Mr. Henry Smith, of Caroline

Fig. 76.



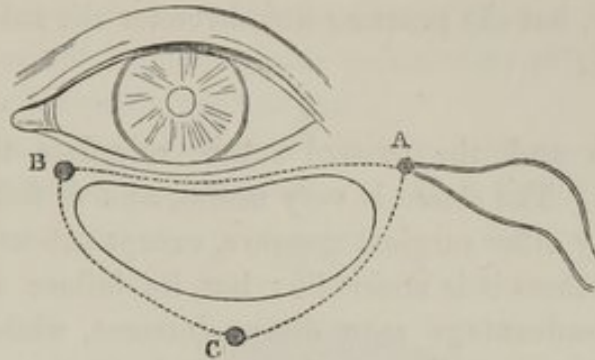
Street, operated on one as large as an orange, situated on the scapula, in which this fibrous capsule or investment was very distinct. To check any after oozing of blood, Mr. Liston used to wrap a piece of lint tightly around the base of the tumor, and secure it by a single knot.

Another method that may be adopted when the tumor is small, and does not lie very deep, is to cut through the surface and make a channel for the ligatures to sink into. Either of these plans must be selected according to existing circumstances:—the state of the skin, the depth, the form, the extent, and the position of the nævus being the points for guidance.

Mr. Curling has tied nævi without breaking the skin, except where the ligature was introduced (*op. cit.*); and to him is due the credit of introducing, in this country, a plan said to have originated in France, and ascribed to M. Ricord. The diagram on next page, which I copy from Mr. Curling's paper, is intended to show a mixed nævus of the lower eyelid so treated. Setons had failed in his hands, and another surgeon had applied an escharotic several times.

Of the case he writes, "I took a slightly curved needle, armed with a strong silk ligature, and inserted it at the outer margin of the lid, passed it close beneath the skin transversely across near the margin of the palpebra, bringing it out at the inner

Fig. 77.



- A, Point at which the ligature was introduced.
 B, Point at which the ligature was brought out and again inserted.
 C, Second point of exit and third of insertion.
 The dotted line marks the course of the ligature subcutaneously.

side of the swelling. I then reinserted it at the point of exit, carrying it in like manner close underneath the skin downward and bringing it out below the lowest part of the nævus. The needle was again introduced at the point of exit, and carried upwards beneath the skin to the point at which it was first inserted, thus encircling subcutaneously the whole of the morbid growth. The ligatures were then drawn tight."

The nævus was entirely obliterated; the lid felt at one part a little solid, but resumed its natural appearance, all redness having disappeared, there was a little tumefaction which was gradually subsiding.

Mr. Startin has lately tied nævi under the skin in a manner which differs from the above only in the slowness of the process. An elastic band is tied to the ligature, which is merely passed round the nævus, and by the action of which the ligature cuts its way out in few days.

Like the ordinary superficial ligature the subcutaneous one

may be multiplied when the size of the nævus would seem to require it. I suspect that certain favorable conditions should exist to render the subcutaneous tying efficient, and especially those of unusual prominence with little depth, of the part to be tied. The insertion of pins for the ligature to pass under would in a measure overcome the tendency to embrace only the superficies of the tumor, but the practice would render the subcutaneous tie very difficult.

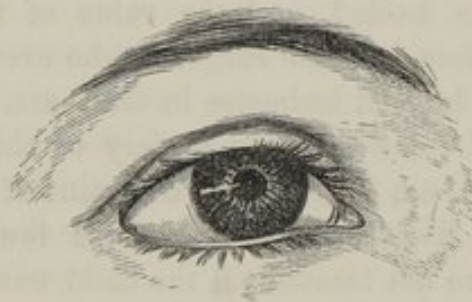The seton and the twisted suture complete the means in general use. The seton is very useful, and is followed by less scar than any other surgical measure, except subcutaneous tying. Like many others it is uncertain; but its failure is unattended with any disadvantage save disappointment, while it does not render the nævus at all worse for other treatment. It is applicable to all species of nævus, and, as with all setons used to induce inflammation, the amount of vascular action can generally be regulated. Threads of various materials and size are passed by a needle in several directions, and at different depths, and some surgeons charge them with stimulating fluid, such as a solution of lunar caustic, caustic potass, castor oil, or tincture of cantharides. It is usually stated as a precaution against hemorrhage, that the seton should fill the wound made for it.

A remarkable instance of the usefulness of the seton on a large scale is given by Mr. Fergusson in his "Practical Surgery," second edition. A tumor was situated between the trochanter major and the external condyle, of three or four inches at least in diameter, its exact limits being indefinite, with large pulsating vessels passing into it at all sides. Small ulcers formed, and bled on any unusual effort; excision was out of the question, and incision equally so, while its breadth, flatness, and supposed depth, prevented any attempt to produce sloughing by ligature. The parts were not favorable for pressure, and vaccination or caustic seemed insufficient for the bulk of the disease. The twisted suture had been used with some effect, but still a formidable part of the disease remained. Mr. Fergusson passed

several large cords as seton; these had a favorable influence, but the affection was far from being cured, sufficient inflammation not being excited. By means of long slender needles, single threads were introduced in all directions, more active inflammation ensued, the tumor became smaller and firmer, the pulsation was less and the thrill lost. The lad was watched for a year and a half, but there was no indication of disease likely to trouble him. Several small vascular points were still visible on the surface; he afterwards went to sea.

In contrast to the severity of the last case may be mentioned that of the infant daughter of a medical friend, born with a

Fig. 78.



nævus at the inner angle of the eye, not larger than a pin's head, which increased rapidly, and in six weeks had acquired the size of a bean. Three twisted threads, which had been moistened in a solution of caustic potass, were passed into it with a curved needle, and retained for three days. Very slight inflammation was excited, a healthy eschar formed, and the nævus was cured. Neither contraction of surrounding skin, nor of the cartilage of the lid ensued; the lachrymal tube was uninjured, and the scar is just perceptible, as the Figure 78 indicates.

Very little contraction of the soft parts at the internal angle of the eye would have drawn the puncta lachrymalia away from the globe, and might besides, if the contraction had been considerable, have been injurious to the lachrymal apparatus.

The twisted suture—the same as what is called the hare-lip

suture—is often resorted to by some surgeons. A pin is passed through the tumor, and a thread carried over it in a figure of 8. If the object is to cut off the supply of blood, several pins are generally used, and made to circumscribe the base of the nævus. This suture should not be used merely as a means of exciting inflammation, since it is less effective for this purpose than the seton, and is sure to be attended by a well-marked scar, should the pin be allowed to separate by ulceration.

In this review of remedies, little more than slight allusion has been made to the mixed nævus, the tumor involving the skin and the subcutaneous tissue, and which is most difficult to be eradicated. The following condensed notes of such a case show how all treatment was baffled, and the value of this example is enhanced by the fact, that the surgeons who exercised their skill had attained the highest eminence in their art, and were in the frequent habit of treating every variety of the disease. Two distinct red spots, not larger than the point of a pin, were discovered fourteen days after birth, on the lower eyelid; they increased, but were not treated till the child was nine weeks old. June 11th, 1849, Mr. Key applied potassa fusa without decided effect, a very small portion only having been used, through fear of the escharotic entering the eye. June 18th, the potass was again applied, and repeated on the 21st, the 26th, and the 30th of June, and on the 5th and 9th of July. Mr. Key now considered it necessary to use nitrate of silver from time to time. The family left town for another residence, and as the nævus still increased, Mr. Key was written to, and he ordered the tincture of iodine. On the 13th August, Mr. Key being sent for, was greatly surprised to find how much the nævus had augmented. Before the next appointed consultation, this able surgeon was removed from his sphere of usefulness. Mr. Coulson was now consulted, and employed the ligature, endeavoring to strangulate the greater part of the growth, and succeeded in destroying a considerable portion. He afterwards used nitric acid, which unfortunately excited a violent ophthalmia, followed

by an abscess within the lid. March 13th, Sir Benjamin Brodie and Mr. Coulson attended, and the baronet's method of puncturing and using caustic, was four times adopted; April 6th being the period of the last application; still the disease crept on. By Mr. Coulson's request I was now consulted. I found the cheek much scarred, and the cutaneous portion of the nævus nearly destroyed; but the subcutaneous part was in full activity; the space from the external angle of the eye to the angle of the mouth, and to the side of the nose was occupied by it; the bridge of the nose was also traversed, and a narrow portion was stealing under the other eyelid. It was no easy matter to decide on what should be done, from the very great extent, the peculiarly irregular outline, and the position of the disease, and the probability of eversion of the lid should sloughing ensue. There had been a slight amount of eversion after the ligature by Mr. Coulson, but that had passed away. I decided on passing some fifteen or twenty threads in many directions as a first trial. The day was arranged for this, but afterwards postponed, as the child had a severe and dangerous attack of measles, and since then I have not heard of it.

Tying the common carotid artery on the side corresponding to a nævus has been practised when the position of the disease about the head or face, or other circumstances forbade the adoption of any of the foregoing means; or when local measures alone have been unsuited, or have been unavailing—the probability of coagulation within the cells being the theory on which the practice is founded. Mr. Wardrop informs me, that, of six instances in which he tied this artery, three were for nævi. Two proved unsuccessful. The third was the person of an infant five months old; the disease covered one half of the root of the nose, the eyebrow and the upper eyelid, which could not be sufficiently raised to expose the eyeball, nor could the precise limits of the tumor in the orbit be traced, yet it seemed to penetrate deeply. The color was pale blue, and numerous tortuous veins were in the integument. It did not pulsate, was

doughy and inelastic, and pressure greatly diminished it. Complete success ensued.

Dr. Arenat's case, communicated to the Medico-Chirurgical Society by Mr. Wardrop, is illustrative of the prudence of tying the carotid in some cases, as a preparatory means to other treatment. A man who had from birth several *nævi* in different parts of his body, received a blow on one of them, situated on the right temple. It increased rapidly in size, acquiring a prodigious bulk in the space of two hours after the injury. The carotid artery was tied. The tumor burst during the operation, and the loss of blood was calculated at not less than eight pounds. On the next day the tumor was entirely empty of blood, a considerable portion of skin was cut away, and about twelve small arteries tied. Success followed.

The severity of some cases has necessitated the tying of both carotids. Möller practised it on a child four years old with success; and in a child of three years old, Mott obtained only imperfect results from tying one common carotid artery, and subsequently tied that on the other side. It would be useless to multiply examples, for enough has been advanced to prove the legitimacy of this proceeding, which has been frequently successful. Sometimes when the disease has not been removed, it has been checked, and reduced to a harmless state, yet in some few, the arrest of blood through the carotid, with the adoption of local measures, has entirely failed.

DILATED AND TORTUOUS VEINS.

Diseased veins may resemble *nævi*, and are not unlikely to be confounded with them, whether on the skin or beneath it; and the parts about the eye are as likely to be the seat of such morbid changes as other regions of the body. A delicate young man, aged twenty, an undergraduate of Oxford, consulted Mr. Lawrence, for an oblong, pulseless, blue-colored vascular tumor of four years' duration, situated in front of the abdomen over the inferior ribs of the right side; it was firm, having been frequently

cauterized; and the blood when squeezed out by pressure did not readily flow in again. The whole mass, including some diseased integument was extirpated; the bleeding was inconsiderable, and one small cutaneous artery only was tied. The tumor consisted of a number of tortuous and dilated vessels, which, from the thinness of their walls, the collapsed state of the cut extremities, the want of pulsation during life, and the general varicose appearance, were concluded to be veins; they contained a thin watery yellowish-red fluid, which, under the microscope, was seen to contain blood-disks in small quantity, altered in shape and jagged at their edges; granules, probably the remains of decomposed blood-disks, epithelium, and fatty matter. The wound healed without a bad symptom, and the gentleman left town in a fortnight. (See a paper by Mr. Coote, in "The Transactions of the Abernethian Society, St. Bartholomew's Hospital.") In these venous growths, phlebolites, or the calcareous concretions formed from the coagulation of blood, may be found.

There can be little doubt that other non-pulsating and non-malignant vascular tumors are met with about the body that do not fall strictly under any of the denominations now considered.

In connexion with this subject, I must allude to a clinical lecture by Mr. Lawrence in the "Medical Times" for 1850 on cystic tumors, their frequent connexion with diseased vessels, and their supposed development from congenital *nævi*. In a tumor to all appearance consisting entirely of veins, and involving the greater portion of one side of the head, Mr. Storks, whose retirement from the profession all who knew him must deplore, tied the common carotid artery with the effect of greatly diminishing the mass, which it was necessary afterwards to attack with the twisted suture, by which it was entirely destroyed. A drawing illustrative of the case is in the fifth edition of Mr. Druitt's "Surgery."

I have not myself met with *nævi* on the eyeball alone, but such examples have been recorded by Von Ammon; in one instance it was hereditary, both parents having the same defect.

Mr. Wormald lately met with a *nævus* on the iris, that bled re-

gularly at the menstrual period. I am sorry that I am not in possession of the facts of this interesting case, and cannot obtain them in time for this work, but Mr. Wormald intends to give them to the profession.

ANEURISM BY ANASTOMOSIS.

It is fifty years since John Bell drew attention to the true nature of this disease of the vascular system, which previously had been wholly misunderstood and frequently confounded with unallied affections, not excepting even those of a malignant nature. The name that he assigned to it,—“Aneurism from Anastomosis,”—has been justly retained; yet it is tolerably certain, that, under the new term, John Bell included morbid growths of a contrary nature; at least to my mind that conclusion is inevitable from his remark, that often in the course of the disease various sacs are formed, which sometimes contain serum, sometimes blood, &c. Again he speaks of some of these tumors as cellular and stringy, with uniform firmness; one is described as bursting and discharging three pounds of serum and no blood; and others as superficial, and of large dimensions, without pulsation, or exhibiting it only at times. Farthermore, the description of some of his dissections would oblige us to believe he had really examined the subcutaneous *nævus* with its peculiar arrangement of fibrous tissue and capillary vessels, in which there is so close an imitation of the true erectile tissue; otherwise we must admit that he mistook the convolutions and ramifications of arteries for cells. How else are we to receive the statement, that an aneurism by anastomosis consists of small active arteries, absorbing veins and intervening cells? Yet it is within only a very recent period that his views have not been quoted, and his dissections referred to as the sum of our knowledge on the nature of the subject,—a fact which significantly points to the difficulties attendant on an investigation.

Although even now some practical surgeons retain Bell's name—aneurism from, or by anastomosis—for all vascular tumors, and

define *nævus* to be a mole or mother's spot, anatomical research, as far as it has gone (for it is as yet meagre), does convince us that there are important varieties of vascular tumors, and that Mr. Bell's term should be restricted to the arterial tumor, or that which is made up chiefly of arteries. If so, the characteristic of an aneurism by anastomosis, sufficiently large to form a tumor, should, I imagine, be pulsation, so long as it is sufficiently superficial or exposed for that to be recognised, and arterial *souffle*. The latest and most perfect examination of such a tumor that I know of, is by Mr. Holmes Coote, who inspected a pulsating tumor, said to be congenital, and taken from the lip of a gentleman, aged forty-four, by Mr. Lawrence, in 1847. It consisted of arteries—of the natural diameter, about that of a large pin—dilated for about an inch of their course into sinuses or canals, the cavities of which equalled that of the radial artery in the adult. They communicated freely with each other, and were lodged in the natural structure of the lip, to which they were attached by loose areolar tissue. Upon the divided surfaces there were the cut orifices of eight arteries, some of them of considerable size. The walls of the dilated vessels were thin. Microscopical examination failed in detecting anything remarkable. It is probable, that here are the main features of organization of the whole of this class of pulsating tumors; but more research is needed. Other observers have spoken of convolutions with dilatation of the vessels.

A question arises concerning the state of the accompanying veins, and it might be conjectured, that the ordinary mode of injecting would scarcely declare it, since the colored fluid might pass from the arteries into them, and all vessels so filled would be regarded as arteries.

John Bell, who was a bold surgeon in the true sense of the word, scarcely recognised the danger of extirpating these aneurisms; he gives some admirable and practical accounts of his operations, and recommends us to proceed so as at once to reach the source whence the tumor receives its supply, to disregard the bleeding from the first incision, and save blood ultimately by

making the operation rapid. Success must depend mainly on the sudden alteration of the blood-vessels, from that state of dilatation which constitutes the disease to their natural calibre; when the vessels are shaded off in their varicose condition to some distance around, extirpation is attended with great danger. The circumstances calling for extirpation must be peculiar, and therefore rare.

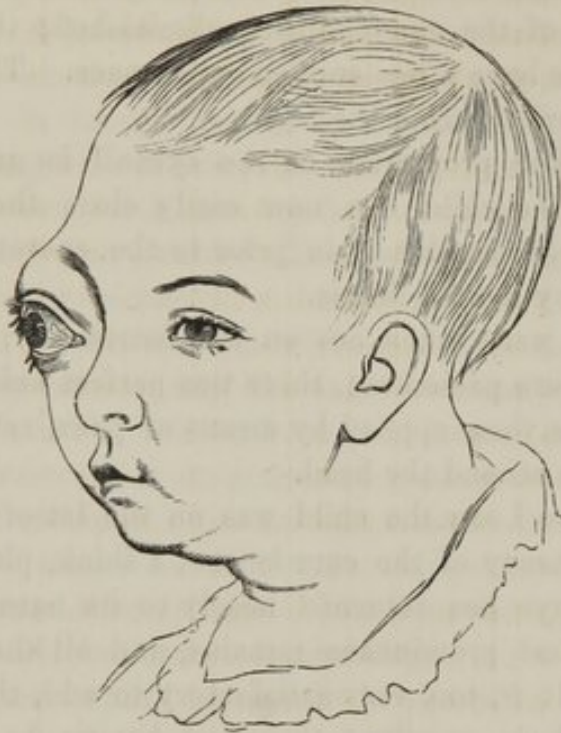When neither strangulation, pressure, nor any local measure is applicable, or when all are insufficient, the bolder method of placing a ligature around the main artery supplying the region of the body on which the growth is situated, must, if possible, be practised. This would seem to be most frequently required when the disease is about the eye, and it thus falls within the domain of ophthalmic surgery.

In the following case existing circumstances precluded me from attacking the disease locally, and I therefore tied the common carotid artery.

A remarkably fine girl, two months old, was brought to me at the Central London Ophthalmic Hospital, in 1851, with a slight prominence of the right eye, discovered within a month after her birth. There was no indication of any particular disease, and after a few visits, the infant was not again brought till she was four months old. At that time the eye was prominent, the lids swollen, the cheek puffy, and the conjunctiva thickly set with large bright-red vessels. Pressure on the eyeball lessened the protrusion for a few seconds, while crying rendered the eye more vascular, and caused great temporary protrusion. In a fortnight there was an increase of all the symptoms: pulsation was not distinctly felt, at least, I could not satisfy myself of it; however, several surgeons declared that they felt it, and the stethoscope applied over the eye detected an arterial souffle, not heard at the other orbit. Those of my colleagues at St. Mary's Hospital, who kindly examined the case, agreed with me that there was an aneurism by anastomosis. Cold lotion had been constantly applied for three weeks without effect. It was not considered prudent to apply pressure, from the pain which it seemed to pro-

duce. The following figure conveys a good idea of the prominence of the eye.

Fig. 79.



On the 5th of June, when the child was four months and three weeks old, with the assistance of Mr. Coulson, Mr. Browne, of Belfast, and Dr. Taylor, I proceeded to tie the common carotid artery, Dr. Snow administering chloroform. The incision was made an inch and three quarters long over the course of the artery. The undeveloped state of the muscles of the neck, and the adhesion of their surfaces peculiar to infancy, rendered the use of the knife necessary for their separation: only a very small portion of the internal jugular vein was seen. The ligature was passed, but not tied till the effect of the chloroform had subsided. This was observed as a precautionary measure, but there was not the slightest perceptible effect on the brain when the circulation was checked. Only a few drops of blood were lost.

As soon as the child had become insensible under the influ-

ence of chloroform, the protrusion of the eyeball was greatly lessened.

June 6th. The protrusion remains the same.

7th. The wound seems to have healed by the first intention. The protrusion of the eye is sensibly diminished; the surrounding integuments have a less swollen appearance. The child was sick twice or thrice during the night.

June 10th. The protrusion of the eyeball is gradually decreasing, and the child can now easily close the lids when asleep, which she could not do prior to the operation. There has not been any more sickness.

The sutures were taken out on the fourth day, and except where the ligature passed out, there was perfect union.

Pressure was then applied by means of pads, retained by an elastic bandage around the head.

The last time I saw the child was on the 1st of July, 1852, and the permanency of the cure is now, I think, placed beyond a doubt; the eye has returned nearly to its natural position, only the slightest prominence remains, and all the movements are perfect. It is, too, very satisfactory to add, that my little patient's health is excellent, there not having been the least ill result from the operation.

An objection to my procedure in this case was taken by some surgeons, who thought that the rapidity of the establishment of the collateral circulation at that early period of life, would render the operation useless, and that the disease would progress uninterruptedly. The result has fortunately disproved the apprehension, and certainly adds value to the remarks of Professor Miller concerning the deligation of arteries in such cases, "that the circulation is weakened in the tumor, not arrested; and coagulation may partly occur, causing obliteration; but it is more probable, that the dilated vessels merely recover their normal calibre, and remain pervious. Immediately after the main artery's deligation, they are comparatively empty, and remain so until the collateral circulation is fully established; and, their tone never having been lost, they natu-

rally contract, and accommodate themselves to their reduced contents. By the time the circulation is fully restored they may have become confined in their diminished bulk; the heart's impulse being still modified, re-distension will not occur."

Examples of failure, after tying local vessels, if those going directly into an aneurism by anastomosis may be so called, are to be found in cases recorded by Messrs. Lawrence, Warren, Bell, Sir Benjamin Brodie, and others; and probably because all the important ones had not been secured, although there is no positive certainty, that if all to which a ligature could be applied, were so treated, the desired end even then would be attained. It is necessary, in all instances where a cure is to be attempted by interrupting the vascular supply, that the vigor of the circulation of the entire region should be influenced. It is not necessary here to give any special directions for the management of a patient, after deligation of the carotid artery, except that, if the period of life allow it, the force of the general circulation should be reduced. In infancy it might not be prudent to do more than insure tranquillity.

Mr. Travers, whose operation is recorded in the second volume of the "Medico-Chirurgical Transactions," was the first surgeon in this country who tied the carotid artery for disease of the orbit. His patient was a female, aged thirty-four, far advanced in pregnancy, in whom a sudden snap on the left side of the forehead, attended by pain, and followed by a copious effusion of serous fluid into the cellular substance of the eyelids on the same side with a smart ophthalmia, had ushered in the disease; to this there succeeded a protrusion of the globe which affected the sight, and a circumscribed elastic tumor as large as a hazel nut appeared upon the infra-orbital ridge, and another softer and more diffused swelling arose above the tendon of the orbicularis palpebrarum. The lower tumor communicated the pulsation of the larger arteries, and could be emptied or pressed back into the orbit, the pulsation becoming violent, while insupportable pain ensued. The upper gave the sensation of a strong vibratory thrill. The globe of the eye was gradually forced

upwards and outwards, and its motions were considerably impaired. There was a constant noise in her head resembling the blowing of a pair of bellows. Compression of the temporal, angular, and maxillary arteries, produced no effect, but when the finger was placed over the trunk of the common carotid, the pulsation ceased altogether. The operation produced immediate good results and ultimate cure.

In the sixth volume of the same transactions, the late Mr. Dalrymple, of Norwich, another distinguished man of his age, has given a similar case. This patient, of forty-four years old, was also a pregnant woman. She was seized in the middle of the night with the attack, suddenly and instantaneously; hearing a noise as of the cracking of a whip, and feeling at the same moment an extraordinary pain in the globe of the left eye; she awoke in great alarm, and leaped out of bed. Considerable swelling of the lids ensued, with inflammation of the eye. During labor, seven weeks after, there projected between the eyelids, a bright red tumor of an oblong form, which for seven or eight days gradually enlarged, till it occupied, in a vertical direction, almost the whole space between the superciliary ridges, reaching horizontally from the external angle of the eye, across the root of the nose, to nearly the internal canthus of the right eye. It had been punctured several times and bled freely, and was reduced to a certain extent. Vision was lost, and the eyeball was thrust forwards, outwards, and upwards; for the character of the pulsation and other particulars, I must refer my reader to the original paper. The carotid artery was tied in April, 1813. The effects were immediate and decisive; and notwithstanding two recurrences of secondary hæmorrhage, she recovered. Dr. Warren tied the carotid artery with success for an aneurism by anastomosis at the inner angle of the eye; the anastomosing branch of the ophthalmic artery had been previously tied, and the facial artery cut across and compressed without effect. The special value of this case is, that the disease had appeared on the opposite side of the face, and was extending to the whole arterial system of both; and after bleeding, leeching, starvation, quiet,

and the use of digitalis, all to no purpose, one carotid artery was tied. The pulsations of the corresponding side were immediately relieved, and those of the opposite side slowly subsided. In 1822, Professor Pattison tied the common carotid artery for aneurism by anastomosis of the cheek and the side of the face.

Dr. Mussey, of America, as we are told in Mr. Cooper's "Surgical Dictionary," tied both common carotid arteries, with an interval of twelve days, for a large pulsating congenital tumor upon the head of a man, and was obliged ultimately to dissect away the tumor; and Chelius mentions that Macgill in the space of one month, tied both carotid arteries for tumors of both eyes; several months after the operations the swellings had subsided, and the patient was well. Lastly, I find in the "*Bibliothèque du Médecin Practicien*," that for aneurism by anastomosis in the orbit, the carotid artery was tied in two cases in Paris, in July, 1839, within three days of each other, and that both patients did well; one operation was by Jobert, the patient being sixty years old; the second was by Velpeau, the patient being thirty.

ANEURISM IN THE ORBIT.

There are few instances of this affection on record, and the three following instructive cases scarcely require comment. The first is taken from the second edition of Mr. Guthrie's work on the "Operative Surgery of the Eye." The symptoms were similar to those of Messrs. Travers and Dalrymple, spoken of as aneurism by anastomosis, but no tumor could be perceived during life. The eye had gradually protruded until it seemed to be exterior to the orbit, but vision was scarcely affected. A hissing noise in the head was attributed to aneurism. On the death of the patient an aneurism of the ophthalmic artery was discovered on each side, of about the size of a large nut; the vena ophthalmica cerebialis was greatly enlarged, and obstructed near where it passes through the foramen lacerum orbitale superius. A great increase in size of the four recti muscles, accompanied by an

almost cartilaginous hardness, added to the protrusion of the eye. The disease existing in both sides prevented, it is said, an operation on the carotid being proposed, to which, indeed, the patient would not have submitted. The narrative would have been more perfect if the immediate cause of death had been mentioned.

The following case, treated by Mr. Busk, is recorded in full in vol. xxii. of the "Medico-Chirurgical Society." A seaman, aged twenty, was admitted into the Seaman's Hospital, July 13th, 1835, with severe concussion of the brain. The eyelids and integuments about the left eye were swollen from serous effusion, the pupil dilated and motionless, and the orbital muscles paralysed. The eye was inflamed from constant exposure through the palsy of the orbicularis, and the cornea suffered from ulceration, and the deposit of pus between its laminae. Some months after the accident, the eye became prominent, and the eyelids were swollen. On the 1st February distinct pulsation was, for the first time, discovered, and close investigation detected a firm pulsating tumor in the upper and inner part of the orbit, immediately within the superciliary ridge. The pulsation was accompanied by a very distinct thrill, and the stethoscope conveyed a loud whizzing sound, which could be heard even around the region of the orbit. Temporary pressure on the carotid artery stopped the pulsation and the accompanying sounds. February the 2d, the common carotid was tied; on the 15th the ligature came away; on the 28th of March the eye was hardly prominent, and the patient was discharged. A few years afterwards, when he was seen by Mr. Busk, there was no trace of the tumor, neither could pulsation be detected about the orbit.

In a postscript to this case, Mr. Busk gives the following one of aneurism in the orbit, evidently of the diffused kind, which resulted from injury; it occurred under the late Mr. Scott.

A boy who had fallen into a ship's hold was brought to the London Hospital with concussion of the brain, contusion and swelling of the right side of the face, and protrusion of the right eye, which was fixed and motionless, the pupil being dilated and vision lost. He gradually recovered from the concussion of the

brain, the eye becoming more prominent. The displacement of the eye immediately after the accident, without symptoms of cerebral compression, proved that it arose from extravasation of blood within the orbit, and the continued protrusion rendered it probable that the aperture in the vessel from which the blood escaped had not closed. As the external symptoms became more apparent, pulsation was felt, and when the lids were separated, the eye was evidently propelled forwards at each impulse of the heart. Local pressure was attempted, but occasioned so much pain that it was discontinued after two days.

Directly subsequent to an examination of the eye, profuse arterial hemorrhage proceeded from the nose, and was commanded by pressure on the common carotid artery, which was then tied, with the effect of curing the aneurism.

CHAPTER IX.

Fig. 80.


INCISION OF THE CONJUNCTIVA, AND OF THE SUBJACENT CELLULAR TISSUE IN CHEMOSIS FROM PURULENT OPHTHALMIA:

KNIFE FOR DIVIDING CHEMOSIS.

It is sometimes necessary entirely to divide the conjunctiva; and this cannot be effectually done except with a curved knife, such as that represented in the accompanying figure.

Any cause that is capable of producing active inflammation of the conjunctiva of an adult, whether mechanical injury, atmospheric influence, inoculation with poison, or the circulation of virus in the system, may be followed by a purulent discharge, and by that degree of chemosis, which requires the conjunctiva and the subjacent cellular tissue to be freely divided. One of these causes, in particular, inoculation, very seldom gives rise to the ophthalmic affection without there being necessity for operating; and with a very few exceptions, all the cases of purulent ophthalmia under my own care that have demanded this proceeding, have been from the contact of gonorrhœal matter with the conjunctiva.

The gonorrhœal—fortunately not a common disease—is the most terrible of all the purulent ophthalmiæ, and may be selected to illustrate the severity of this class of affections. Moreover, it is



by far the most dangerous of ophthalmic diseases. The rapid destructiveness of this purulent affection causes it to be greatly dreaded; cases have been seen, where in twenty-four hours all chance of a recovery has been lost. The danger does not depend on the whole globe being involved in inflammation, followed by disorganization—although this may happen—but on the effects which it produces in the cornea; such as ulceration, sloughing, and deposit of pus between its layers; the termination being penetration of the cornea, with more or less loss of the humors of the eye, and prolapse of the iris; opacity of the cornea, the remains of reparation, after some of its superficies has been lost; or atrophy of the globe. The period between the first evidence of infection, and the stage which immediately precedes destruction, is uncertain: in one of my patients it was seventeen days. Dr. Mackenzie mentions an instance that came under his care thirteen days after inoculation, where partial recovery ensued: when he saw the patient the left eye was violently inflamed and chemosed, there was a great discharge of purulent fluid, and the cornea was totally opaque; under treatment the cornea cleared beyond expectation, and a considerable share of vision was preserved.

The severity of the attack is indicated by the condition of the lids, the amount of chemosis, and the state of the cornea,—great tumefaction of the lids with pain, showing great danger. Before the cornea perishes it becomes hazy, still shining a little; but when its vitality is destroyed, the polish is lost and this stage is quickly succeeded by sloughing. The whole cornea is rarely destroyed, and the sloughs do not always penetrate its entire thickness.

As to the connexion between the disease and gonorrhœa, there exists diversity of opinion; but it is a fact fully confirmed, that purulent discharge from the urethra, or gonorrhœal matter, when applied to the conjunctiva, will produce violent inflammation of that membrane with purulent discharge, whether the matter be from the same individual, or from another. Some pathologists have, in absence of direct proof of inoculation, attri-

buted it to metastasis; and what is stranger still, authors have described gonorrhœal ophthalmia, without metastasis or inoculation, expressions which I shall not stop to consider. I do not see why because we may not be always able to trace the application of gonorrhœal matter to the eye, we should overlook or discard the fact of inoculation.

It does not always happen that the system at large participates with the ophthalmic affection, and the constitutional symptoms, when they do occur, may not, even in the commencement, be those of febrile excitement; but I have never seen a case under any treatment in which there was not a prostration of the vital powers, as the disease advanced.

A young practitioner will, doubtless, be at a loss to know how gonorrhœal ophthalmia is to be distinguished from the other purulent discharges of the eye, and in what respect it differs. In the absence of any proof to the contrary, and from its resemblance, it would seem that it is one and the same kind of disease, notwithstanding the mode of origin; differing only in degree or intensity, there being no determinable pathological difference. It is closely allied to the purulent ophthalmia of adults from other causes, and even to the purulent ophthalmia of infants, and the diagnosis must rest on the history of the case; no set of symptoms that can be strictly relied upon are proper to either, especially at a late period. But a diagnosis, if it can be made, is valuable, for we are then better prepared to treat this destructive malady. It is important to be able to tell the friends of a patient when his disease is such as to excite apprehensions; and the co-existence of a gonorrhœa, with a severe purulent ophthalmia, is most unquestionably one of the strongest confirmations of its specific nature. It is commonly stated that the purulent ophthalmia of adults commences with inflammation of the conjunctiva of the lids and then spreads to that of the globe; but in the gonorrhœal form, the reverse is the case; an opinion which seems to be generally correct: and hence, perhaps, the greater amount of chemosis in the latter, and therefore, the greater probability of sloughing, or ulceration of the cornea; hence, also, the lids in gonorrhœal ophthalmia are generally not

so much swollen. But this diagnostic sign is lost when the disease has advanced.

Within the last few years, since the treatment is better understood, the termination of severe purulent ophthalmia in the adult has been more favorable; and it is not now considered necessary to reduce a patient to death's door by depletion, in order to endeavor to cure his complaint. For this, and, indeed, for much that is valuable in the treatment of diseases of the eye, we are greatly indebted to Mr. Tyrrell. It is surprising, however, with what tenacity the strict antiphlogistic system of treatment, of which bloodletting is the principal means, is still adhered to by some; and there are yet disciples of the late Mr. Morgan, who used to tell his pupils that to control this disease, it was necessary to produce a degree of depression very little short of that occasioned by profuse and continued hemorrhage. When the application of stimuli and astringents, together with judicious general treatment have failed, or what more generally happens, when at the time that the case is first seen, the cornea is nearly covered with the chemosed conjunctiva, and the only visible part is losing, or has actually lost its transparency—incisions are all-important; for if the eye can be saved, the free division of the conjunctiva will rescue it.

Incision of the conjunctiva and the subjacent cellular tissue to relieve the strangulation of the vessels from which the cornea is nourished, was strongly insisted upon, and its benefits lucidly expressed by the late Mr. Tyrrell; whether the manner of making the incisions, by dividing the conjunctiva longitudinally, and not circularly, originated with him, is uncertain; I must mention in justice to Mr. Middlemore, that he had advocated the same principle in his work several years before Mr. Tyrrell's opinions were publicly expressed, and the only difference in their views is, that Mr. Tyrrell put implicit faith in the direction and locality of the incisions, believing it essential to make them between the attachments of the recti muscles, "avoiding immediately the transverse and perpendicular diameters of the globe; that the larger vessels, passing to the cornea, might not be injured;"

whereas, Mr. Middlemore directs the incisions to be distant half a line from each other. I am fully satisfied that the value of the method lies in the extent and the number of the cuts, and that the fear of doing injury to the cornea by wounding any large vessels in the transverse and perpendicular diameters of the eye, is quite groundless.

The operation may be readily performed by standing behind the patient, who should be seated on a low chair, raising the upper lid with a retractor, while an assistant depresses the lower, introducing the point of the knife nearly vertically, at the spot of reflection of the chemosed conjunctiva on the cornea, and carrying it along the sclerotica to the sinus of the lid; then depressing the handle, and including within the curve of the blade the swollen conjunctiva of the lid. I generally endeavor to make four such incisions at equal intervals. The division of the upper part of the chemosis is not so readily effected as that of the lower, since the knife cannot be carried so far on the lid; but it may be done by applying the retractor first on one side of the lid to make room for the knife, and then shifting it to the other. A sponge should be used, and the place for the entrance of the knife made apparent. With common care, the sclerotica will be uninjured. It is so imperative to make these incisions thoroughly, that unless there is a certainty of the patient being submissive, chloroform should be administered.

Should a case retrograde, and chemosis recur, secondary incisions must be practised; and, as the progress of the disease will probably be under surveillance, they may be done early, and a less number of them will then suffice.

A portion of the margin of the cornea is generally channeled, or furrowed, in a peculiar manner, as if a bit of its substance had been gouged out, having very much the appearance of a long and deep ulcer, without any opacity or attempt at repair. In some cases the groove has seemed as if on the verge of passing through the cornea; and that it must sometimes involve all its layers, and be the means of penetration, is probable enough from the known frequency of a disruption at that part. Even should

the anterior chamber be opened at the margin of the cornea, and a part of the circumference of the iris protrude, a useful eye may be secured. An amount of prolapse of the iris at the circumference of the cornea, which would ultimately be of little importance, might at the centre be fatal to the eye by involving the pupil.

As regards treatment, I employ cold lotions and opiates to assuage pain, as mentioned in my fourth chapter; and the astringent I generally use is a solution of alum, of four grains to the ounce of water, and when nitrate of silver is employed, the strength is one or two grains to the same quantity of water. I believe that these substances are, as I have already stated, most effective when so used, and I feel assured that all applications to the conjunctiva that produce severe or prolonged pain, are injurious. I attach great importance, at all periods of the complaint, to the frequent syringing with astringent lotions; and their effect will be more certain if the secretion is, as far as practicable, previously removed with warm water, the lids being well separated during the washing. I do not abstract blood when there is the slightest depression. In the young, robust, and plethoric patient, with an excess of arterial action, purgation and antimony will suffice, unless a very sudden depletion seems called for, and then I prefer opening a vein in the arm. Should it seem expedient to take blood locally, the cupping-glass is better than leeches, as it acts effectually and quickly, and gives less annoyance to the patient. In the intervals of using the astringent, the edges of the lids should be kept greased to prevent partial adhesion, and cleanliness will be best insured by cutting off the cilia.*

* When there is much purulent secretion, the weak solution of the nitrate of silver mentioned in the text would exert very little influence on the inflamed membrane; being immediately diluted and washed away by the profuse discharge. In severe cases occurring in persons of ordinary vigor, our practice has been, after moderate depletion, general or local as circumstances may require, to apply in the first instance, by means of a camel-hair pencil, a solution of the salt in the proportion of a scruple to an ounce of water, to the whole

The case of a young man, twenty-one years old, a portmanteau-maker, furnishes a marked example of purulent ophthalmia with-

surface of the conjunctiva, diminishing the strength of the application as the inflammation subsides. The cautious avoidance by the author of undue depression of the system is worthy of all commendation; the treatment generally erring on the side of activity, and the disease, from the impairment of the recuperative energies, being sometimes rendered more destructive than it would otherwise have been. Opiates in full doses at night ought not to be omitted, and when the cornea is threatened, recourse should be had without delay to incision of the chemosed conjunctiva.

A morbid condition of the palpebral lining, with hypertrophy of its villous tissue, known under the designation of granular conjunctiva, is a sequel of gonorrhœal and purulent ophthalmia frequently seen in our sanatory institutions, and often in a very aggravated form, with all its sad consequences of vascular cornea, opacity, &c. It is an intractable complaint, extremely liable to relapse from atmospherical vicissitudes; and, though not strictly within the province of the work, a few remarks on a subject of so much interest may not be deemed misplaced. In its local management we are careful not to employ measures of such potency and character as produce much reaction, or might destroy or permanently injure the texture of the part;—the cure being sometimes rendered hopeless, or protracted through an indefinite period, by empirical and unskilful treatment. The nitrate of silver is the most efficacious remedy, and a solution of ten grains to the ounce of water, applied to the everted lid by repeated touches of the brush every second day, will ordinarily be sufficient to repress the morbid growth and abate the irritation which it occasions; in many instances a still weaker preparation daily applied, will be adequate to that purpose; but if the affection be more chronic and the granulations large, solutions of greater strength, as of twenty or thirty grains, may be prescribed, and the applications less frequently repeated,—time being allowed for the subsidence of the vascular excitement thus temporarily increased, and also for the production of the expected curative impression. The sulphate of copper lightly employed in substance, is perhaps the article next in order of utility, and is especially adapted to cases of thickening of the conjunctiva unaccompanied by much vascularity or irritability. Other astringents may also be used with occasional benefit, but the two mentioned, are those on which we have been accustomed chiefly to rely with a confidence that, with time and favoring circumstances, has rarely been disappointed. It sometimes happens that all applications appear to act as irritants, and should either be suspended, or employed only in weak dilution. Scarifications may be performed with advantage when the membrane is the seat of much vascular congestion; but the practice of cutting across or excising enlarged vessels running on the globe cannot be too strongly condemned; these serve to maintain the integrity of the cornea under the irritation to which it is constantly subjected, and gradually contract and disappear

out specific origin:—at least he had no gonorrhœa, nor was there any evidence of gonorrhœal origin, and, therefore, I attributed the disease to debility occasioned by overwork, and the sudden change from the pure air of Cheltenham to the emanations of a narrow back street, near Maiden Lane, King's Cross. For two nights previous to the attack, he had not gone to bed—his employer, to meet an order, demanding a certain amount of work in a given time. The right eye was first attacked; on the third day there was considerable chemosis, and superficial sloughs in two spots on the cornea; and he then applied to Dr. Taylor, who divided the chemosis. The poor fellow would not come into the Hospital, and did not re-apply as an out-patient. On the sixth day, he was visited at his miserable lodgings, and induced to become an in-patient. At this time the right iris was prolapsed, and the cornea of the left eye hazy and surrounded by chemosis, having become so on the morning of the previous day. His prostration, mental and physical, was very great: he was unable even to walk. The chemosis in the left eye was freely divided, and for the second time in the right, which, however, seemed destroyed; alum lotion, quinine, porter, ammonia, and strong broths were prescribed, and any nutritious article of diet that he might fancy. On the third day of his hospital residence, the chemosis in the left had subsided sufficiently to expose the margin of the cornea, which was furrowed at the upper part for about a third of its circumference, and penetrated apparently by ulceration, sufficiently to allow of a slight prolapse of the iris. The haziness still remained. The eye progressed satisfactorily, the patient improved daily and was soon able to take solid food,

as that is removed. This structural degeneration, which would be less common if due attention were given to the state of the lids in the inflammations in which it originates, being generally associated with an impaired condition of health, the constitutional treatment becomes of primary importance; and whatever tends to restore and sustain the vital powers may be usefully called into requisition. Exercise in the open air, a generous diet, quinine, the chalybeates, &c., &c., are essential to the cure, and, as a nutritive agent, the oleum morrhue is often very beneficial.—ED.

but continued so weak that on the first time he left his bed he fainted. He quitted the Hospital at the end of a fortnight, and could then see his way about. Three months afterwards he came up to visit the Great Exhibition, and called on Dr. Taylor, who has furnished me with the following note of his state:—

“The pupil is slightly displaced upwards, and shaded towards the sclerotic margin by a faint superficial opacity of the cornea, which becomes gradually more dense towards the point of penetration. Vision is almost perfect, and is daily becoming stronger. The cornea of the right eye is replaced by a dense cicatrix, and vision is completely lost.”

CHAPTER X.

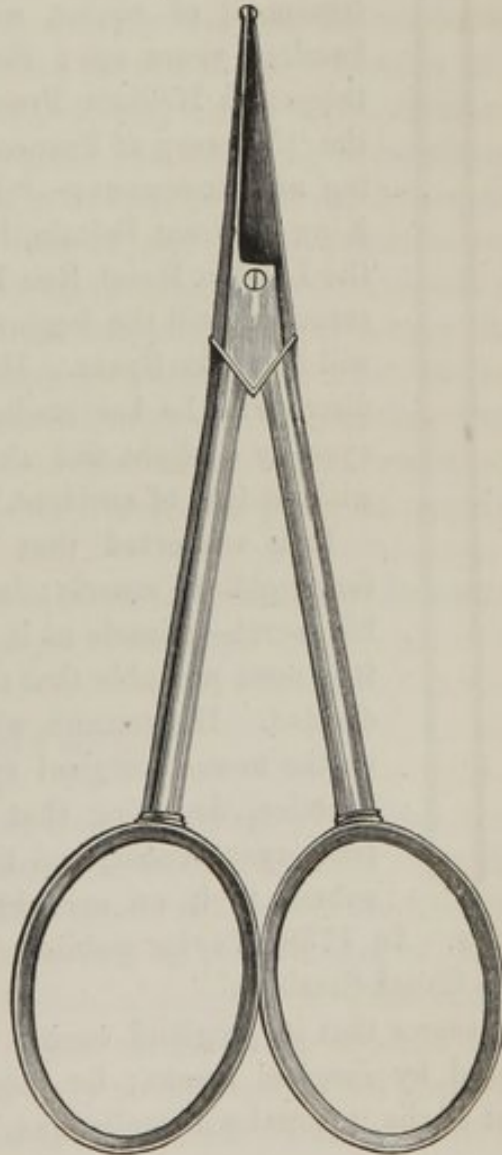
STRABISMUS OR SQUINT.

INTERNAL SQUINT. EXTERNAL SQUINT.

SCISSORS.

Fig. 81.

THE obtuseness of the points of these scissors interferes in no degree with their power of cutting; while it effectually prevents injury to the globe of the eye—a circumstance that might arise from the restlessness of a patient, or from other occurrences incidental to the use of sharp points. Large bows facilitate their use by allowing them to be held easily, and in a line with the fingers; and the shortness of the handle insures greater steadiness in directing them.



BLUNT HOOK.

Fig. 82.



The curvature of this hook ought not to be greater than will allow of the ready passage of the instrument, under the muscle while it should, at the same time, be sufficient to allow its being used as a hook. The point should be round and smooth.

The earliest application of practical surgery to the treatment of squint, was by Taylor, more than a hundred years ago; for, according to the "*Bibliothèque du Médecin Practicien*," for 1849, there is in the "*Mercury of France*" for June, 1737, the following announcement:—"Dr. Taylor, oculist to the King of Great Britain, has just arrived at Paris, at the London Hotel, Rue Dauphine, where he purposes remaining till the beginning of July, after which he will leave for Spain. He requests us to publish the discoveries he has made, of straightening squinting eyes by a slight and almost painless operation, and without fear of accident."

It is suspected that Taylor operated on the inferior oblique muscle; but being a charlatan he kept his secret—miracle as it was called—to himself, and it is most probable that the lateral recti muscles were divided. Heuermann, who wrote at Leipsic, in 1756, on the newest surgical operations, criticises Taylor's practice, declaring that it was attended with only temporary benefit, and that patients would scarcely submit to it, on account of the pain and uncertain results. In 1738, Taylor published a pamphlet, entitled, "*De Verâ Causâ Strabismi*."

It seems that in England squint was at a very early period treated by surgical means; for, according to the first supplement of the "*Annales d'Oculistique*," p. 258, the following sen-

tence occurs in the "Dissertation" of Verkeyden, 1767:—"Strabones, permultos ferro sanatos apud Anglicos vidi."

It is well known that Mr. Anthony White, of the Westminster Hospital, suggested twenty-three years ago, the division of the recti muscles. Stromeyer, in the year 1838, appears to have been the next to propose it; and Pauli, of Landau, performed it on a girl, but failed—the first successful case being reserved for Dieffenbach, on the 26th of October, 1839. Many aspirants for the honor of the suggestion have appeared; but it is universally conceded, that we are indebted for its introduction to Dieffenbach. The new operation was quickly adopted and zealously advocated; Mr. Duffin's excellent papers in the "London Medical Gazette," contributed considerably to its rapid diffusion, and it has long since been recognised as belonging to legitimate surgery. It may be said that it is singularly successful, equaling in its permanent effects, that of any other operation, and surpassing most of those which are practised for the removal of deformity; yet, some professional men still speak of it very disparagingly, and would even deny its utility; and when we consider the discredit into which it fell after its introduction, from indiscriminate application and ineffectual execution, we cannot be surprised that it holds no very favorable place in popular regard.

The literature of the subject is enormous; and most dissimilar principles and results fill the pages of authors.

INTERNAL SQUINT.

From early infancy, and even from birth, the eyes have been observed to lose their parallelism, and to turn inwards; but the age at which squinting generally appears is between the fifth and ninth years, agreeing with the period of the diseases of early life, to which it is so frequently due, although it is often impossible to trace the connexion. When the deformity appears suddenly, and persons are brought early under professional observation, the causes may sometimes be discovered. Derangement in

the visual apparatus, opacity of the cornea or lens, and affections of the encephalon, comprise the circumstances that induce it; but in the majority of cases there is nothing to guide us in our diagnosis, and hence the reputed causes are often as fanciful as they are varied and absurd. It may be that the balance of antagonistic muscular power in the orbital muscles is, from their mechanical disposition, nicer in them than in other muscles; and that they are peculiarly susceptible of disturbance in their harmony, from causes within and without, or more influenced by nervous agency—a cause commonly assigned for the deformity, but one of which we know nothing.

A squint which has existed a few months, or even less, seldom disappears spontaneously or under general treatment—at least an exception is a rare occurrence. I think it questionable whether a permanent squint is ever relieved except by operation. Cases are published of persons who have squinted from resting the head in a certain attitude, and who have recovered when the position was changed; but these are not veritable instances of defective action of the muscles of either eye, but simply that of an acquired habit of looking side-ways, in one or other direction, and which endures only while the cause remains. The attempts to cure squinting by goggles, side-glasses, side-reading, by binding up one eye, by patches of black sticking-plaster on the point of the nose, &c., have certainly not been successful, although commonly recommended.

It is reasonable enough to infer that the squint may be prevented from getting worse, by the early removal of the cause; and it is well known that certain circumstances ameliorate the amount of inversion. I have seen improvement result from the renovation of health in children, whose vital powers have been much impaired from teething, worms, and disorders of the abdomen; and adults, who have been affected from childhood, may have their squint more marked when out of health, and particularly with depression of power.

An operation is contra-indicated when certain causes are present, such, for instance, as inflammation of the eyeball, or its

appendages; when there is an opacity of the cornea, so that the obliquity is a provision for enabling the patient to see—the other eye being lost; or when caused by tumors, cicatrices from wounds, contractions after abscess, or, indeed, any accidental mechanical means that pushes, or draws the eye from its axis. After it has been ascertained that the case is a proper one for operation, I cannot see that there is any advantage in delay, for preparatory treatment is not called for. When I have advised immediate operation, I have frequently been asked if there is not a chance of a child outgrowing the deformity. There is certainly a feeling both in and out of the profession, that an operation should be delayed till after puberty; but there is much to be said against, and nothing that I am aware of, for the postponement—for increase in age does not remove a squint, and imperfection of vision when a result of the obliquity, may be improved or actually removed by an early operation.

Internal squint may affect both eyes, but so seldom, that the occurrence is the rare exception; yet without examination the reverse would seem to be the truth—and this arises from what may be seen in nearly all cases of single squint, an occasional apparent participation of both eyes in the deformity; or even from the squint being, as it were, sometimes completely transferred from the one eye to the other. Now in this apparent participation there is often a deceptive appearance merely, but there may be a perversion of the natural action of the muscles of both eyes, although only one eye can strictly be said to squint; that is, the eye which may be called sound—in which there is no individual loss of antagonistic force among its muscles—is actually affected, as I believe, through the influence of the associated movements of the lateral recti, and partakes of the greater amount of volition which is required for the play of the muscles of the deformed eye. For instance, the right eye squints: to look to the right with that eye a much greater volition is needed, and more muscular power called into action than if it were straight; and that extra-exercise of power is, by the associated movements of the eyes, unavoidably transferred or directed to

the associate muscles of the other eye, the left, and especially to its internal rectus, overmatching the antagonizing muscles, and turning it unduly inwards. This must hold good whether the squint arises from a defect of power in the external rectus, or an excess of it in the internal muscle. To avoid intricacy and minute detail the lateral recti alone are here taken into consideration, although all the orbital muscles are more or less involved. When the squint would seem to be completely transferred from one eye to the other, I believe that the appearance is due to the exaggerated associated movement; and if this be correct, it fully explains the fact, that a single operation, the division of the internal rectus of one eye, will restore to parallelism eyes in which the obliquity has appeared to alternate, while it also accounts for the common error, that one operation may rectify two squinting eyes.

But the effect of the associated movements is not observed unless a person has power to turn out the squinting eye, and there is good vision in it; for even if there be the muscular power, while the sight is imperfect, the employment of the eye is soon neglected, its front part remaining buried in the corner, except there be considerable effort to place it correctly, and with such effort the abducting muscles soon tire.

It is not an easy matter to determine which is the defective eye, and the sound eye is sometimes operated on. When this cannot be readily ascertained, I place the patient in front of me, at the distance of two or three yards, and direct him to cover one eye, say the left, and look at me with the other, keeping the head straight—the right eye will be in the centre of the orbit; I then direct him to uncover the left. Now if the right, which has not been closed, is normal, it will keep its central position, while the left is turned inwards; but if it be deformed it will turn in, while the left will become straight. The experiment should be reversed.

To be thus able to determine which eye squints, must depend on the power that a patient can exercise in the movements of the squinting eye; and the less that power departs from health,

the less quickly is the squint detected; for when the power is little impaired, it is necessary that the patient's attention be directed from a fixed gaze, and volition interrupted, by causing him to wink a few times, or to close the eye for a few seconds, and then open them, and quickly to look at an object. Cases are met with which are scarcely embraced by this test, and in which the greatest nicety is required to detect the faulty eye. When there is neither visual defect, nor inability freely to turn the eye out at will, the squint will appear during examination to shift from the one eye to the other, and remain in either so definitely that it requires a long acquaintance with such cases not to be convinced that both are equally affected. But it is not impossible to discover that one differs from the other in its movements, having a greater tendency to remain adducted, if the experiments which are made be sufficiently varied, carefully conducted, and often repeated. A squinting eye when at rest is invariably adducted; and if seen by the surgeon while thus undisturbed, much trouble and doubt will be spared. When, however, a patient is under examination, he is generally excited, and exerts the orbital muscles unnaturally; and then it is out of the question to obtain a sight of the squinting eye even in a moderately quiescent state—and hence I have sometimes been obliged to wait until a second visit to detect the faulty eye. A case much to the point occurred in a young gentleman in whom I had decided upon the squinting eye without any difficulty; but when I took him into an adjoining room to be operated on, my assistant remarked that one eye seemed to squint as badly as the other; he had become frightened, and I could not then really perceive that either eye was worse than the other. However I operated upon the eye I had named, and proved to be correct. It will greatly assist in dispelling doubt, if it can be ascertained that the one eye turns in more than its fellow when the tip of the nose is looked at; or, that one cannot be turned out to an extent equal to its fellow; or differs from it in focal range; or deviates from the horizontal position; or is retracted a little within the orbit. The necessity for these tests shows that even the patient

may be ignorant of the seat of his affection. Whenever we find so much difficulty in forming a diagnosis, which is, indeed, rare, it is probable that each eye is defective; yet, should an operation on both eyes be determined upon, it would be imprudent to operate on either indiscriminately. That which appears the worst should be selected; for it has happened to others and to myself, to be deceived as to the implication of both eyes; so great is the influence of one squinting eye on its fellow.


It might with sufficient plausibility be assumed, that the exaggerated associated action of the internal rectus of the sound eye, will in time produce in it a new and independent sphere of contraction, and render it an undue antagonist for the external muscle, causing, in fact, a confirmed squint; yet if such is ever the case it must be very seldom, for it is well known that one eye may squint for very many years without the other eye becoming affected. I have operated on patients who have squinted in one eye for above thirty years, in whom were those conditions that may be considered favorable for the implication of the other eye, namely, good abducting power and good sight, enabling the squinting organ to be used freely, and consequently the internal rectus of the other eye to be unduly acted upon, and yet the second eye has escaped deformity.

Mr. J. D. Macdonald has instituted some very scientific experiments to determine the earliest deviation of the co-ordinate action of the muscles of the eye: I subjoin the details, which are published in the "Medical Times" for September, 1849, under the head of "Remarks on an Optical Experiment, adapted as a means of ascertaining the Relative Powers of the Eyes, and indicating the first onset of Morbid Changes interfering with Vision."

"It is a fact but little observed, that when a stratum of dust is laid upon the surface of a mirror, each particle and its reflection so lie, one with respect to the other, that a line drawn through them both will be, in every case, as the radius of a circle, whose centre is in the pupil of one of the observer's eyes as seen in the glass; so that an appearance of rays is thus pro-


duced, seeming to emanate from that point. The matter in itself is trivial, but, from what follows, it will be found to afford a delicate test for discovering the relative strength or visual capacity of one eye compared with the other, hitherto a desideratum in ophthalmic surgery.

Fig. 83.



“If the right eye be illuminated by a candle while the left remains in shadow, the experimenter will perceive, by looking into a mirror, prepared as above, that the irradiation proceeds from the pupil of the shaded eye ; and this without reference to its position.

Fig. 84.




“Placing the light on the opposite side (the left) the physical

circumstances are altered, and the appearance is just the reverse of the former case.

“But, should two candles be employed, one on either side of the observer’s head, the lines formed by the dust particles, and their reflections, will either seem to irradiate from both eyes, as centres, or to spread from each side mutually across the opposite eye.

Fig. 85.



“In explanation of these facts the writer finds, that when any circumstance incapacitates either eye from discharging its functions perfectly (as the light in the first and second experiments cited), the unaffected organ appears to have dominion, and this is manifested by the radiation of the particles seeming to take place from its pupil in the mirror, and overpowering those of the other eye. In consequence of the sympathy existing between the optic nerve and iris, when a strong light falls upon the latter, the pupil diminishes in size, so as to regulate the amount of light impinging on the nerve, according to its sensibility. When one eye is thus influenced, its powers are lessened considerably, for, while it is directed to the image in the glass, the iris cannot admit a sufficient amount of light to impinge upon the retina from that quarter, having a much stronger stimulus in active operation to contend with from another. This state of things is quite reversed in a shaded eye, because the iris is free from the action of a powerful light, and has only to discharge its office in allow-

ing the ingress of as many rays from the dust particles or their reflections as the delicacy of the optic nerve can bear, which fully accounts for the strength of the impression overpowering that of the weakened eye.

“When two candles are employed, as in the third experiment, both eyes are equally influenced, receiving a similar distribution of light, and are, consequently alike fitted (*cæteris paribus*) for the performance of their respective functions, so that the lines necessarily appear to irradiate from both eyes.

“Now, the practical application of the experiments alluded to (if properly conducted) is this, that the least inequality of the powers of one eye when contrasted with those of the other, is instantly discovered, and the earliest onset of cataract, amaurosis, &c., is at once detected; for, if both eyes are similarly situated before a light which falls equally upon each, the patient will himself discover where the defect lies, independent of any other proof, agreeably to the explanations above given.

“A very close relationship exists between the co-ordination of the muscular movements of the eyeballs and the function of adaptation to distance, and also an intimate connexion between this latter and the condition of the retina. Thus, if the retina of one eye be in any state of debility, the adaptive changes do not take place equally in both eyes, and, as a necessary result, the co-ordination of the muscular actions which so wonderfully effects the consentaneous movements of the eyeballs is disarranged, and strabismus (or squinting) is, under such circumstances, satisfactorily accounted for. If, then, in consequence of debility of one of the retinae, whether from disease (as is usually the case), or from whatever cause, there is a tendency to squint, the eye so disposed may be instantly detected by the foregoing experiment, in which it also assumes its wonted position. This test has been successfully tried by the writer in the case of an individual who had been subject to an occasional strabismus, frequently resulting from long concentration of the eyes on one plane, as in reading. There was a loss of co-ordination both in the muscular movement of the globes and the power of adaptation

to distance, and, in short, a want of balance in the tone of both organs. On looking into the mirror, as before explained, with an evenly adjusted amount of light on each eye, he observed the rays emerging from the left eye to cross and obliterate those from the right, which indicated to his own feelings and convictions, that the latter was the organ affected.

“The advantage of such a test as the present to the ophthalmic surgeon, must be obvious, when we consider that the sound eye has been frequently operated on in cases of strabismus, in consequence of incompetent diagnosis.”

Of double squint I have seen but few examples; if by the double affection is meant, that the adductors of each eye have acquired a new and independent sphere of action, whereby both eyeballs are turned inwards at the same time. The discrepancy between my statement and that of other surgeons, concerning the infrequency of the implication of both eyes may, I think, be reconciled by taking into account that the state which I have described as single squint, with a secondary and wholly different condition of the other eye, and admitting of being cured by one operation, is usually regarded as double squint.

According to my observation, in the double affection both eyes have not been equally inverted, and there has been a disparity of vision. The abduction of either, beyond the centre of the orbit, and particularly that most deformed, required much effort, and was attended with most remarkable inversion of the other.

It has so happened in some cases, in which it was difficult to decide which eye should be operated upon, that after the operation the other eye has exhibited a squint; and here I had certainly surmised the necessity of a double operation; but this is just one of those practical points that cannot be brought within the compass of rule. On the other hand, I should mention that a double operation has several times been deemed necessary when one has sufficed.

I hope that I have proved that one operation cannot cure two squinting eyes; that when a person has both eyes turned inwards, two operations are absolutely necessary, just as much so

as if each eye was in a different individual: that if one eye only is turned inwards, an operation on that alone is sufficient. Dividing the internal rectus of a sound eye may, or may not, produce permanent abduction; but can, in no way, affect the fellow-eye that squints.

A squint may be occasional, occurring in apoplectic, epileptic, and inebriated persons, and then both eyes usually turn in; but it is more common in the occasional deformity to have one eye affected; and the inversion is more marked sometimes than at others. The term periodic, which is generally given to this state, is incorrect, for the squint does not return regularly at a certain period of time. There may always be a very slight inversion of the eye, with occasional aggravation; or the squint may be entirely occasional and of short duration.

A lad, thirteen years old, applied to me with chronic ophthalmia, and, while being questioned about his complaint, his right eye turned inwards, and in a few seconds was again straight. Although generally unconscious of the squint, he could produce it at will to an extent that concealed a part of the cornea, and this while the other eye remained straight, by looking intently at any object. All besides that could be ascertained about the peculiarity was, that the focal range of the eyes differed; the squinting eye possessing the shorter, and that for years he had occasionally seen double.

All the instruments necessary for the operation are a retractor, a pair of forceps (figured at pages 28 and 29), a blunt hook, and a pair of scissors. I have long dispensed with the sharp hook for holding or fixing the globe; it is not required and may be positively injurious.

When a patient possesses sufficient firmness not to offer resistance, an assistant may be dispensed with. I have often operated alone; it is, however, advisable always to have a second person, if only to counteract any untoward movements, and the operation is very much facilitated by the lids being fairly retracted. Children and unsteady persons must be effectually secured; or, what is better, rendered insensible by chloroform. I

have, on several occasions, with resolute patients, for the purpose of showing pupils the simplicity to which the whole proceeding may be reduced, laid aside all instruments but a pair of scissors and a blunt hook, an assistant raising the lid with his finger. But my usual method, and that which I recommend, is the following. With the patient seated, or lying, I insert the retractor under the upper lid, and transfer it to an assistant standing behind, depress the lower lid with the third or the little finger of the left hand, and with the forceps held in that hand, raise a fold of the conjunctiva opposite the lower edge of the internal rectus muscle, and a little posterior to its insertion into the sclerotica, then with the scissors cut it through vertically, together with the sub-cellular tissue, to an extent just sufficient to admit the hook, and afterwards one point of the scissors. Next I introduce the hook, pass it under the muscle, which is made prominent, and with the scissors divide its tendinous expansion between the hook and the eyeball, along with the conjunctiva that covers it. The whole process may be executed steadily and effectually in less than a minute. If the eye should not be sufficiently turned out to allow of the incision being made in the proper place, it can be readily everted by laying hold of some part of the ocular conjunctiva with the forceps.

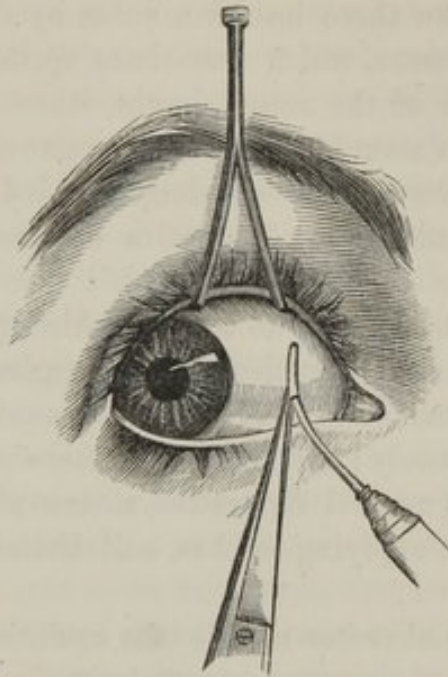
A probe passed vertically under the internal rectus muscle of an adult, and pressed against its point of attachment to the sclerotica, will reach to within nearly three-eighths of an inch of the cornea, and that is the spot where the conjunctiva should be opened. The release of the muscle at its very insertion into the sclerotica, with the little disturbance of it posteriorly, secures the new attachment to the globe at a spot not far from the natural one, and thereby insures the maximum of whatever advantage can accrue from this its new position.

The annexed figure shows the eye under the operation, the retractor raising the lid, the hook introduced, and the scissors about to be used.

It is a very common error to attempt to introduce the hook under the muscle before cutting through the subconjunctival cel-

lular tissue ; when this is thin and natural, the hook may readily be pushed through it—not so, when thickened, as is often the case in squint of some standing, or where there has been inflam-

Fig. 86.



mation of the conjunctiva ; indeed the thickened tissue is frequently divided, under the idea that it is muscle or tendon. But the difficulty, if such it can be called, may always be overcome by observing the rule not to use the hook until the tendon-like surface of the sclerotica is seen.

In order to secure effectually every portion of the tendinous expansion of the muscle, the hook should be passed a little below the level of the pupil in its ordinary state of dilatation, directed backwards to a sufficient distance, swept along the side of the globe, and its point made to project just a little above the level of the pupil. If there be doubt about the muscle having been divided, the hook should be passed a second time, and an inexperienced operator had better always do this. A sponge is not usually required during the operation, as bleeding is mostly subsequent to it.

As an after consequence, the eyelids may be ecchymosed, and the conjunctiva chemosed, but each passes away quickly, without treatment, and it is unnecessary to cover the eye with shade or bandage, unless to please the patient. In some hundreds of cases, I have never known the wound in the conjunctiva fail to heal kindly, and in a few there has been union by the first intention. A little granular mass, which sometimes springs up on one or other of the edges of the wound, ought, when it gets a narrow base or stalk, as it assuredly will, to be removed with a pair of scissors: escharotics should be strictly avoided; but this fungus seldom appears, unless the conjunctiva has been lacerated and detached.

Prior to the introduction of this valuable operation, any like injury to the eye, either accidentally or surgically inflicted, and followed by an equal amount of inflammation, would have been treated most rigorously; and even yet there are surgeons who cannot watch the natural reparative action after an operation for squint, without applying leeches, and irritating the eye with lotions.

When the internal rectus muscle of a squinting eye is divided, the eye will, as a rule, assume a central position in the orbit; but such a result is not always obtained—the eye may be as badly adducted as ever, or only more or less improved. The failure in such cases, partial or complete, is due to a want of power to abduct the organ, and that I believe nearly always to arise from defect in the abducting muscles, and which seems in most cases to be secondary. A mechanical obstacle, such as a tumor pressing on the eyeball, or an abnormal state of the muscles, is rare; and the following quotation from Mr. Wilde's "Ophthalmic Report," in vol. xxvii. of the "Dublin Journal of Medical Science," expresses all that is known of the latter changes:—"Since the adoption of the operation for strabismus much attention has been paid to the pathological condition of the muscles in the orbit; but few of the abnormal appearances described by authors appear to have been original and not acquired after birth. And those attachments of one to another, or the blending of two

muscles with one, as the levator palpebræ with the superior rectus, the trochleator with the internal rectus, and the trochleator itself with the trochlea, &c., appear to be also acquired pathological conditions (Morgagni and Wrisberg); but instances have recently been recorded, by good authorities, of decided false insertion, and also bifurcation of the internal rectus at its sclerotic extremity (Dieffenbach); of the external rectus being double (Zagorsky), and also the superior oblique (Albinus); while Caldanì saw, more than once, an additional muscle, which from its insertion and use, he has denominated *m. detractor palpebræ inferioris*; and both recti and both obliques have been found wanting, in cases of monstrosities, by Seiler and Colomb."

I question whether the loss of the power of abduction is to be referred to thickening of the conjunctiva and of the subjacent tissue, at all events to the extent that has been imagined. Some deficiency of this power in squinting eyes is not uncommon, and, according to its extent, the prognosis is uncertain, and we operate with some anticipation of failure. In several of my own cases of what appeared to be fixed eyes, that is, having no power of abduction, the division of their internal recti set them straight. When the patient can turn the eye outwards as far as the centre of the orbit, the operation may be undertaken with great confidence. Mr. Wilde has added to his "Monograph on Entropium and Trichiasis," extracted from the "Dublin Journal of Medical Science" for March, 1844, the description of a case of severe trichiasis and convergent squint of both eyes successfully treated by operation, and the application of ligatures on the recti muscles, which bears on this part of my subject—the loss of abduction. The patient, a female, was thirty years old. The right eye was first operated upon, and a primary difficulty was to bring any portion of the sclerotica internal to the cornea into view. Having satisfied himself that every fibre of the muscle was fairly divided, he examined both eyes together, and found that, while the position of the left eye continued unmoved, considerable convergence still remained in that on which he had operated. Again examining carefully and with the blunt hook, and receiving fur-

ther assurance that the operation was not at fault, he laid hold of the sclerotic extremity of the muscle with a pair of forceps, and passed a fine curved sewing needle, armed with a single silk ligature, through it in two places. Having obtained a direct purchase on the globe, he drew the eye towards the external angle, till the cornea was rather inclined outwards than directly forwards, and secured the ends of the ligature over the malar bone by adhesive plaster. This was done on the fourth of the month; on the morning of the seventh, the thread had cut its way through the end of the tendon, but the eye retained its new straight position. Nine days after, the other eye was similarly treated. On the evening of the second day the ligature was withdrawn, and both eyes were now in a natural position. There was temporary double vision. The woman was last seen after an interval of nine months, and her favorable state continued.

Other instances of the adoption of this method in double convergent and in diverged squint, are alluded to by Mr. Wilde, who states that he has employed these means with perfect success in seventeen cases of divergent squint, and thirteen of convergent, and in nine of the latter the ligature had been applied to both eyes. The length of time the ligature is allowed to remain, varies according to circumstances; but as a rule it should never be removed till the eye has righted itself. Luscitas, or fixture of the eye, in the straight position, has followed, especially in cases of divergence, where he had reason to believe that paralysis and atrophy of the internal rectus had previously existed.

Injunctions are given, that in fixing the ligature care should be taken to fasten it securely, for if any play be allowed, it will cut through before the effect is secured; and when its necessity is suspected, we are further enjoined to divide the muscle far back, and not to let the eye be encroached on by the crossing of the ligature, but to carry it without the lower lid, notwithstanding the globe is turned a little downwards.

Mr. Wilde, who seems to have been the first to apply the liga-

ture in divergent squint, was not, he says at the time (1841) aware of Dieffenbach's use of it in convergent squint.

A long and familiar acquaintance with the subject has convinced me, that to the operator is to be attributed the odium of failure in most of the unsuccessful cases occurring in early life. I have myself operated a second time on cases that have passed under the hands of other surgeons; in all I have succeeded—the second attempt being undertaken in each instance on account of the abducting power not being defective.

Over and over I have seen patients that have been operated on dismissed under the supposition that it was impossible to put their eyes right, when I have been certain that the internal rectus muscle had not been divided. That there is a greater liability to take up a portion only of the muscle than is supposed, any one may convince himself by operating on the dead subject, when he will find that, unless there be great precision, this error will be apt to occur. A partial separation will frequently lessen the squint; but for its entire removal not a portion of the muscle must remain undivided; and to this I know of no exception. After the muscle has been divided, the patient has not the power to adduct the eye in concert with the other.

An operator often thinks that a case has succeeded, and deceives himself, from not making a proper examination. The inability and often the unwillingness of the patient to open the eye, prevent a satisfactory inspection. These obstacles must be overcome by gently raising the lids of both eyes at the same time, and comparing the positions of the eyeballs.

Some operators have experienced an impediment to the return of the eye to its position, from adhesions between the muscle and the sclerotica. I have not met with this; and strongly suspect that the cellular sheath of the eyeball, which I shall describe in my chapter on tumors, is often mistaken for adhesions, and in its dissection a part of the muscle which had previously escaped division, is cut through. Mr. Duffin remarks, that bands of fibro-cellular connexion, passing between the sclerotica and the under surface of the muscle and its sheath, frequently retain the eye

in an abnormal position after the tendon has been divided, and render many cases only partially successful; that he has met with them very far back, even beyond the greatest diameter of the globe of the eye, and in two cases they were almost cartilaginous, and so unyielding, that the patients were wholly unable to move the pupil out of the inner canthus.

For any length of time to elapse before the eye assumes a central position after the division of the internal rectus, if the eye is ever to become straight, is a very rare occurrence. The first case of this deferred success I ever met with, was in a private patient, thirteen years old, who had squinted from infancy; both eyes were adducted, the right more than the left; either could be abducted as far as the centre of the orbit; the left had the better vision of the two. I performed the double operation at a sitting, assisted by Dr. Alleyne, of Gloucester Road, Hyde Park. The left was slightly improved, the right not at all. Diligent search was made in vain for any remaining muscular or cellular connexion. The case was considered a failure. On my visit next day, both eyes were in a straight position. There was inability to turn them simultaneously, or singly towards the nose, but they could be moved freely in other directions. The second happened in the practice of Mr. Lawrence, whom I assisted at the operation. The patient, a male adult, squinted in one eye. The operation produced no improvement. I saw him two months after, and the squint was gone. Nearly a week elapsed before the eye was straight.

When circumstances lead to a suspicion that an operation has been faulty, and a second attempt is determined on, much patience must be exercised to detach the conjunctiva, for the inflammation consequent on the first operation always makes it adhere intimately to the eyeball, and the undivided tag of muscle is difficult to find.

The occasional unfavorable effects of the operation must not be passed over. The most common is a vacancy at the inner corner of the eye from loss of the caruncle, which arises frequently from the division of the conjunctiva too far from the cornea, and

its unnecessary separation from the globe; sometimes the caruncle is cut across, or even cut away. Conjunctiva that has been torn from its cellular connexion, rarely reunites readily, and a portion of it is generally lost. Except the eye is very prominent, prevention of the vacancy is within the control of the operator, by observing the rule to divide the conjunctiva vertically, and not further back than opposite to the situation of the attachment of the muscle; and never to strip any part of it from the globe. Besides, the mere unsightliness of the eye when its inner corner is damaged, a more serious evil may result, if it be correct, as Mr. Bowman has suggested, that the probable use of the caruncle is to throw the tears into a little pool above it, where they may be taken up by the puncta, for the lower punctum glides above the caruncle in the winking movements of the lids. M. Cunier has advised, as a means of preventing the occurrence, that the lips of the conjunctiva should be raised by little hooks and a fine suture applied. He adds that it is necessary to avoid exact adaptation; for the lengthening of the conjunctiva is often as necessary for setting the eye straight as the division of the muscle itself, from which opinion I dissent. Among the advantages imputed to M. J. Guérin's subconjunctival division of the muscle, is that of preventing the dropping of the caruncle, and, if that be true, it is the sum of the superiority it can boast. I have not seen Mr. Guérin operate, and must not doubt his skill in preparing the eye, with the three hooks, and rendering the muscle so tense that the division is attended by a cracking noise, audible to the bystanders. At the same time it must be remarked that the subcutaneous operation has certainly not been very efficient in the hands of several surgeons in this country, who are not novices in operating. It appears to me that, although in particular cases, for instance, those in which the eye is very prominent, it may succeed, it is not generally applicable; the cases must be chosen for it, rather than it for them. The only accidents that have come to my knowledge in the division of the internal rectus have been where this operation has been adopted. The vitreous humor has been evacuated, and

two eyes have suppurated. Then there is generally severe ecchymosis, and several cases are given by continental authors, where it has been necessary afterwards to incise the conjunctiva and discharge the extravasated blood. Of this fact I am well assured, that in many of the so-called subconjunctival operations the conjunctiva is opened to a greater extent than that adopted in my operation. Incising the conjunctiva horizontally has been proposed to meet the defect in question.

Eversion, if it be very marked, is a severe defect, being then nearly or quite equal, to the original deformity. In a very slight degree it is common, and frequently greater immediately after the muscle is divided, becoming less in a day or two. I have been fortunate in never having it occur to a great extent in any of my cases. How far the manner of operating by dividing the tendon of the muscle, and not interfering with the cellular sheath of the eyeball, has contributed to its absence, might be conjectural, were it not for the uniform result among a great mass of cases, which would seem to reduce it to a certainty. If it be true that there is a greater tendency to eversion in children than in adults, the greater care should be used with them; and any objection to operating at an early time of life, must be met with the fact, that failures occur for the most part in later years, as has been already stated. The most distressing case of eversion that has come under my notice, was the patient of a surgeon who was an advocate for dividing the inner portion of the inferior rectus muscle, besides the entire thickness of the internal rectus. The eye was completely turned out, and extremely prominent. To remedy eversion after the operation, the division of the external rectus is the plan most commonly practised, and was, at one time, very frequently performed in London. I have seen four or five cases, after the second operation, and the prominence of the globe was a greater disfiguration than the degree of eversion which had been removed. In one instance it was so great that the lids could not be brought over the globe without great effort. When eversion comes on at a long interval after operation, an accident unknown to myself, it is said that Dieffen-

bach cut away the conjunctiva and subconjunctival tissue from the internal angle of the eye, divided the external muscle, attached a thread to the anterior portion, and fastened it to the nose with plasters for eight days. The treatment is founded on the supposition that the eversion is occasioned by a rupture of the attachments of the internal rectus. Some recommend the exercise of the eye in a contrary direction, while others apply escharotics to the conjunctiva to cause contraction, or cut out a piece and leave it to heal, or endeavor to draw the edges together by suture; and as if no conceivable method for good or for evil should be left untried, M. Bonnet has advised the division of the inferior oblique and the external rectus muscles.

Protrusion of the globe in some degree occurs in nearly every instance, but oftentimes so slightly that very close inspection is required to discover it. Naturally prominent eyes will display it more than those that are deeper set; in eyes that are popularly called small, it never constitutes a deformity. Some enthusiastic surgeon has recommended to make the sound eye prominent, to correspond with the other. Protrusion and eversion are usually combined, and the only means for relieving the latter that can be depended on, namely, the division of the external rectus, increases the former.

My own practical deduction concerning secondary interference with the view of removing eversion, is, that a worse state is pretty sure to follow nearly all the methods devised; and that with the exception of Mr. Wilde's of which I have not personal knowledge, all others are unjustifiable; yet for the sake of putting forth all the several devices, I mention that of M. Guérin, especially as it is thought well of by M. Desmarres, who says he had done it himself, and can verify the magnificent result. I quote from Desmarres:

A young woman eighteen years old, was operated on for double squint, both eyes became prominent and turned outwards. The external rectus was separated three times without benefit, the particular eye is not specified. After certain adhesions at the external angle were destroyed, the muscle was searched for,

discovered far back adherent to the sclerotica, and detached. The position of the internal rectus was in like manner sought for through dense cicatrices of consecutive vegetations; after a dissection, which is described as something desperate, it was found drawn within its sheath and the orifice obstructed, the sheath was opened, the muscle was drawn out, and applied against the sclerotica. Now was fulfilled the important indication of maintaining the eye inwards, to favor the insertion of the muscle and the fascia, at a point sufficiently anterior to prevent the former evil. A waxed thread was passed with a sewing needle through the fascia near to the cornea, and the eye thus secured was turned inwards about a centimetre, and so maintained, by attaching both ends of the thread to the back of the nose by plaster. In the afternoon of the next day the thread became loose, and, says the author, almost incredible to relate, the inward movement of the eye was re-established, but not the outer. The globe still turned in a little. In proportion as the wound at the external angle healed, the outward movement was restored, and in less than eight days the eye was in a correct position, and almost acquired its normal motions. The fate of the other eye is undeclared.

The last unpleasant result to be mentioned, which is rare, is double vision: it is common in eversion, but not a necessary concomitant with it; and I have met with few persons in whom it continued for any length of time after the operation; but it may be permanent. Like the double vision, one of the early symptoms of squint, it frequently disappears.

From personal experience I am quite unacquainted with relapse; yet it is no uncommon thing to hear of relapses. I question if in most of the supposed cases the muscle has ever been divided. It is possible that with a partial division, improvement has ensued, but for a period only. I have operated on several cases that have been attributed to return of the squint, and in each instance completed the previous imperfect operation. However, most authors speak of it, although as a very rare exception, and M. Desmarres alludes to two of his own, and adds,

that M. Malgaigne told him, he had seen a recurrence, more than a year after the operation.

Happily a very fair proportion of cases does not show a subsequent unfavorable effect, few to an extent constituting deformity, and so nearly do some of them reach to perfection, that a year or two after operation, very close inspection is required to determine which had been the faulty eye.

Very few dissections have been made of eyes that have been operated on for squinting, and one by Mr. P. Hewett, a month after the operation, in a patient who died of phthisis, and recorded in vol. xxvii. of the "London Medical Gazette," is the only instance that I know of, in this kingdom. Mr. Wilde informs us in his report in the "Dublin Journal of Medical Science" for 1847, that Herr Böhm of Berlin, dissected four eyes that had undergone the operation; and ascertained the fact, that the divided rectus may be attached to the sclerotica, or to the globe by the intervention of conjunctiva, or may lie free between the sclerotica and the conjunctiva, or be united to the conjunctiva alone.

EXTERNAL SQUINT.

This form of the distortion is very much less frequent than internal squint; it seldom appears before puberty, and often occurs in advanced age. A frequent cause is doubtless more or less paralysis of the adducting muscles; indeed, the evidence to this effect cannot be overlooked.

A single eye may be affected, yet both are by no means uncommonly implicated; and, as in the internal variety, there may be an occasional deception respecting the eye in which the deformity is situated. To illustrate this, suppose the right eye to be turned out; if a person looks to the left, the left eye will traverse the natural extent and arrive at the outer angle of the orbit, while the implicated right eye not correctly reciprocating in its movement, reaches perhaps but to the centre of its orbit, when to all appearance the left will be the squinting eye. But

slight examination will expose the deception. The influence of the associated movements of the recti muscles is no doubt exerted also in this kind of squint, and causes the sound eye to be turned unduly outwards, when an attempt is made to bring the squinting eye to the centre of the orbit.

The squint may depend on an enlargement of the external muscle. Mr. Middlemore has had the rare opportunity of dissecting the eye of a child who had an external squint, and found the external rectus unduly developed. But the common statements respecting these muscles, with regard to increased size and unnatural attachment, which are said to have been discovered during operation, should be received with great caution. Nothing short of the information obtained by a *post-mortem* examination, whereby comparison with the other muscles is afforded, ought to be considered as conclusive.

It is a fact, as difficult to be explained as the immediate cause of squint, that the same circumstances which at one time precede, and seem to determine an internal squint, shall at another be followed by the outward deviation of the globe. An eye is rendered useless, the vision destroyed by a blow, or by disease, and it may become misdirected on either side. Yet, I cannot call to mind any instance of the production of internal squint in the aged from cataract, although a slight outward deflection is not very uncommon. Respecting the result of operation, it must be confessed that here surgery has fallen very far short of what it achieves in internal squint; but the exceptions ought not to militate against the practice of operating, if any good result can be obtained, provided the fruitless attempts be harmless, and in judicious hands the operation is devoid of any risk. In a few instances, all of them single squints in young persons, I have seen success, and several times I have witnessed improvement. The result may be tolerably well conjectured beforehand, and who would knowingly operate where paralysis is present?

With the slightest double deformity, both eyes should be operated upon; and this may always be done at one sitting. It would be unnecessary to recapitulate the preliminary steps already

detailed, and common to both operations. The attachment of the external muscle being a little more posterior than the internal, the conjunctiva should be divided a little further back, and the hook used with still greater care, because of the greater tendinous expansion of the muscle. The position of the inferior oblique muscle in relation to the external rectus, demands a little attention, and the hook should be passed just below the external rectus muscle, and close to its attachment to the sclerotica, or the oblique is liable to be taken up. Although at first no good result may ensue from the division of the muscle, a day or two, or even later, may show the improvement.

Some surgeons have not been content with the division of the internal rectus alone, but have included other muscles in the operation.* I must express my dissent to this. I have seen most distressing protrusion consequent on the practice. It is said that the division of the inferior oblique and external rectus will suffice for success, and that M. Baudens, who has met with eighty-two examples of this affection, has come to this conclusion. I abstain from quotations in this matter, for the conflicting statements are truly bewildering; and without going into the much-disputed, and as yet unsettled question of the physiology of the oblique mus-

* In regard to the permanency of the rectification effected by the division of the internal rectus in strabismus convergens, on which point the result of careful observation by persons of competent experience and reliable authority has been wanting, the testimony of the author is valuable. A writer in the Dublin Medical Journal, who in reviewing the work of Mr. Walton suggests a freer division of the conjunctiva and subjacent cellular membrane than is practised by that gentleman, states that in his hands also, it has been perfectly and permanently successful in many hundred instances; and this assertion, he affirms, is not predicated of recent cases, but drawn from those operated upon several years before. According to the report of the Royal Westminster Ophthalmic Hospital for 1851, ocular myotomy for the cure of strabismus, performed on one hundred and twenty occasions during the year, had been productive of improvement in the personal appearance of nearly four thousand patients of that Institution. Nothing is said of the increase of retinal power, nor of the unfavorable consequences which sometimes follow the operation; it is probable indeed that most of the individuals subjected to it were never seen after their dismissal.—Ed.

cles, I venture to express my doubt of the inferior being an abductor. The muscles of the eye cannot be treated like those around a contracted joint; the conditions are dissimilar; there should be a limit to muscular section, and that limit should, I imagine, end with the external rectus. I discountenance any further attempts to straighten the eye, when the operation on the external rectus fails, except the use of the ligature after the method of Mr. Wilde.

The loss of the lateral movement of the globe after the operation for external squint is more apparent than when the internal rectus is divided.

CHAPTER XI.

TUMORS.

TUMORS OF THE EYELID. TUMORS OF THE CONJUNCTIVA.
 TUMORS INVOLVING THE CORNEA AND THE SCLEROTICA.
 TUMORS OF THE ORBIT. ENLARGEMENT OF THE LACHRYMAL
 GLAND. TUMORS CONNECTED WITH THE LACHRYMAL GLAND.

TUMORS OF THE EYELID.

STYE.

THIS miniature boil is too generally known to need much description ; its uniform appearance, and its accustomed position at the margin of the tarsus among the cilia, some of which are sure to be displaced, probably from its origin in one of the cilia bulbs, with soreness of the lid, and accompanying inflammation of the conjunctiva, render it little likely to be mistaken. Styne is generally an indication of an unhealthy constitution, and is common in strumous and enfeebled subjects, or in any class of individuals whose health is broken down ; with the predisposition of impaired health it is very prone to appear, if there be long-continued employment of the eyes by artificial light, and especially if there co-exist derangement of the digestive organs. It is only when the styne has nearly arrived at its climax that an opening is useful ; the usually slow and tedious suppuration, generally attended with a little slough of the cellular tissue, may then be considerably shortened by an incision, and the use of a stimulating ointment. The progress of a styne is usually sufficiently slow to allow of time for treatment and the prevention of suppuration ; we must enjoin rest of the eye, frequent appli-

cations of cold lotions to the exterior of the lid, sedatives to the conjunctiva, and such means as will recruit the system. Plucking out the cilia that seem most affected is said to be advantageous.*

HORNS.

I have met with a few specimens of the growths or deposits of inspissated sebaceous matter on the lids, that are called horns; they have all been small, time being wanting to give them the more marked characteristic horny appearance to which they owe their name, and of which the scalp furnishes the best examples.

It would be out of place to say more of their structure than that these dense appendages owe their existence to the drying and hardening, as fast as it escapes, of the contents of the encysted tumors, or of the sebaceous follicles that supply the soft material. To those who desire extended information on the pathology of this subject, I recommend the perusal of a very excellent paper by Mr. Erasmus Wilson, published in vol. xxvi. of the "*Medico-Chirurgical Transactions*," descriptive of a horn developed from the human body, with observations on the pathology of certain disorders of the sebaceous glands.

A single stroke with a knife will be sufficient to remove a horn from the lid. The excrescence being pulled forwards, the separation should be made through the integuments, that the cyst from which it grows may be entirely taken away, or a return of the disease is risked. A scar may be prevented by the use of sutures.

WARTS.

These growths are not very uncommon about the lids, and when on their margins are for the most part slender; a marked

* Without attempting resolution, we prefer to hasten suppuration by warm applications; and endeavor to prevent the recurrence of the complaint by rest of the eye, stimulating ointments, and the removal of any existing functional derangement.—Ed.

example of the entire edge of each lid thickly set with large ones, occurred in an old man, a patient at the Ophthalmic Hospital, under Dr. Taylor. Warts on the lids have been remarkable from their size; and Heister mentions one that was large enough to restrict the motions of the upper lid. Dr. Jacob showed a specimen to the Dublin Surgical Society, a full report of which is in the "Dublin Medical Press," of one taken from the lower lid, and at first supposed to be a malignant growth, but which after being carefully cleansed, proved to be a gigantic wart. The surface was covered with a cream-colored structure, made up of coarse fibres which stood out fully the eighth of an inch perpendicularly from the surface, and which he considered as a cuticular or epidermoid growth. The patient, who was eighty years of age, died after its removal, from erysipelas of the face consequent on the operation.

Except the base of a wart is very small, snipping it off is not sufficient unless the entire thickness of the skin is cut through, for it will return; some caustic must be applied in addition. When beyond the ordinary size, I think it better to try in the first instance, the effect of an escharotic, as less damage will accrue to the lid. One drachm of muriatic acid with three drachms of the muriated tincture of iron is said to be very effectual; many other applications will succeed. Excision should be the last resource, on account of the injury that must be inflicted on the tarsus.

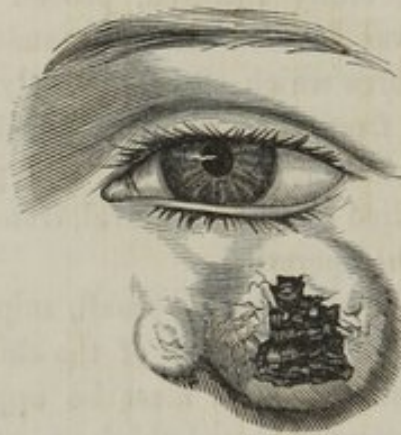GLANDIFORM TUMOR.

A kind of tumor common in children, and now generally called glandiform, being so named by Mr. Tyrrell from its resemblance to a salivary gland, occurs about the lids, and frequently also on the face coincidentally. It is never, I believe, solitary; there are always several seen in the different stages of development, some of them may have softened in the centre and suppurated, and, having burst their envelope, protrude, and become surrounded with an incrustation which makes them look

like warty growths. When fully formed its appearance is characteristic, being mottled, and the gland-like structure is at once recognisable. In a very recent state it resembles a sebaceous tumor.

The subjoined figure, from a girl seven years old, represents two of them in the lower lid, the larger of which was partly

Fig. 87.



covered with black incrustation, from beneath which a little pus escaped. The girl had no more than these; but her sister's face was covered with them, and a third member of the family, the mother, had also a few.

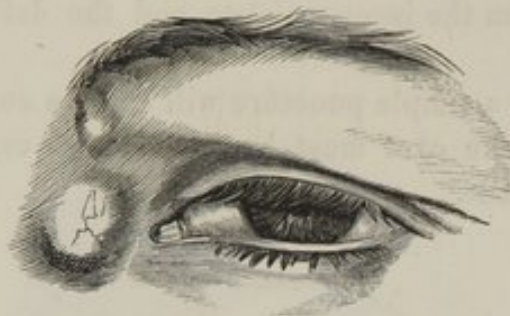The treatment consists in cutting the tumor across by a free incision, and squeezing out its contents with the thumb nails. If the cyst does not separate at the same time, the forceps must be used for its extraction. This same tumor is called albuminous by Dr. Mackenzie, and Mr. Lawrence seems to regard its transitory half-encysted stage as the original type, and supposes it to arise as a small smooth prominence, with a flattened surface, and a small pin-like hole in the centre.

STEATOMATOUS TUMOR.

This surface deposit of steatomatous matter, generally called milium, from its resemblance to a millet-seed, is not confined to

the eyelids; it appears also on the cheeks, and frequently in great numbers. Its size seldom exceeds that of a pin's head, except when it grows at the edge of the eyelid, about the junction of the cuticular and mucous membranes, or between the eye and the nose, when its usual limit may be far exceeded, as in this sketch, taken from a lady of seventy.

Fig. 88.

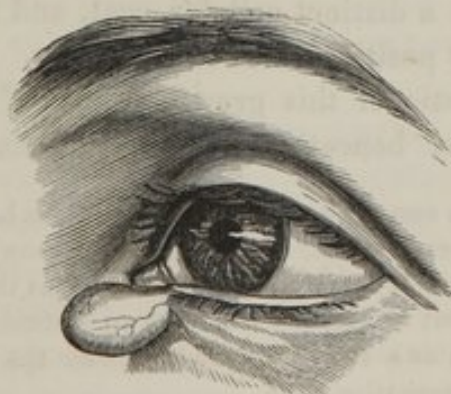

In this instance it was like a small bladder of lard, apparently covered only by cuticle, and retaining for a while any form into which it was pressed. Whether small or large the treatment is to cut it across, and squeeze out the contents.

VESICULAR TUMOR.

This is perhaps the best name for the small cyst containing fluid, and occurring about the lids. The contents vary, being

Fig. 89.



sometimes watery, sometimes glairy. I removed one about the

size of a pea, that had been growing for twenty-six years, and was filled with a glairy matter, from the surface of the upper lid of an elderly lady. Figure 89 shows one of a peculiar form, that had existed for five years, and was filled with serum. I have seen one at the outer corner of the eye which overlapped the edges of the lids, and interfered with sight; the old gentleman, who had carried it for a quarter of a century, could never make up his mind to have it removed, although he greatly wished to be relieved from the inconvenience and the deformity resulting from it.

When small, a simple puncture will effect a cure; but when of a certain size the cyst must be removed or cauterized, or the tumor may return.

TARSAL TUMOR.

This is the name now generally given to the tumor I am about to describe, which is considered by many surgeons to originate in some derangement of the Meibomian apparatus; the accuracy of this opinion, however, I question. To all appearance the growth is external to the cartilage, which does not seem to be involved till a late period of the affection, and then only by the process of absorption.* The nature of its contents varies, being sometimes glairy, sometimes curdy. In the Museum of the Royal College of Surgeons is a partial dissection of a lid, taken from the criminal Bellingham, with what seems to be one of these tumors, called by Sir A. Cooper, the dissector, a subcutaneous tumor. There is a distinct cellular coat, and no apparent connexion, except by position, with the tarsus.

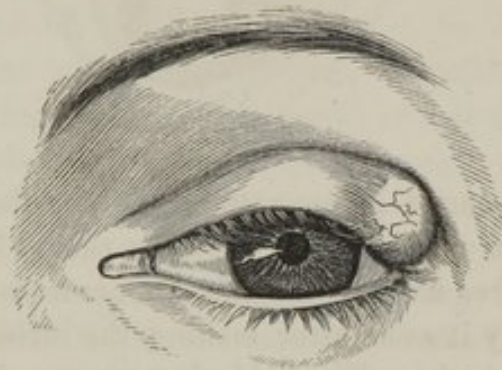The characteristic of this growth is that of a small rounded well-defined tumor beneath the skin, sometimes inflamed and

* This may be so in some cases, but our observations have inclined us to the belief that it originates in the tarsus; and we have known it to involve that of the upper lid in its whole extent. It seldom happens that these tumors tend to open externally, but we recently met with an instance in which the chalazion, nearly as large as a cherry, protruded under the integuments with its apex in a state of suppuration.—ED.

traversed by enlarged vessels, and apparently belonging to the exterior of the lid; frequently in the early stage there is no internal indication of it; later there is a spot of redness, or a little depression with discoloration, and in a very advanced stage there may be a fungus or vegetation. I believe the discoloration to be owing to the absorption of the tarsal cartilage.

The position differs from that of a styne in being above the edge of the tarsus, and clear of the cilia, as the figure (90) shows.

Fig. 90.



Debility of constitution favors its development; but its connexion with a vitiated state of health is not so marked as in styne, with which it may co-exist. Several may be on the same lid, and both eyes may be affected alike. It is of remarkably slow growth, and many months may elapse before one attains to the size of that depicted.

The illustration on the next page shows one on the lower lid, of unusual dimensions.

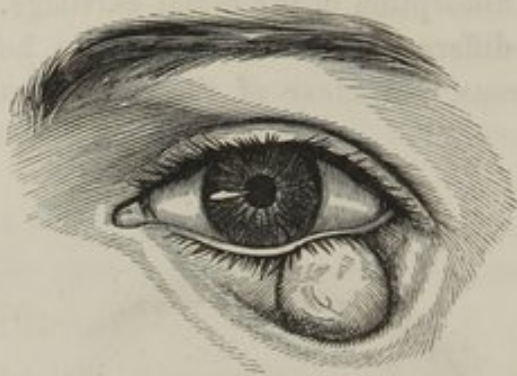Probably if left alone, the tarsal tumor would grow still larger, for spontaneous cure by suppuration or bursting is rare.

In the Hunterian Collection of the College of Surgeons is a cyst taken from an eyelid which is three-quarters of an inch in diameter, and certainly seems to be a tarsal tumor.

No effect can be produced by medical treatment, and therefore an early operation is necessary; which should be performed

within the lid to avoid a scar, and the contraction which might follow. The lid having been everted, a puncture is to be made with a scalpel or narrow knife, and the point of the instrument

Fig. 91.



moved about to excite inflammation, whereby the secreting surface will be destroyed. If the operator should fear puncturing the lid by the free use of the knife, an occurrence I have often seen, he may lay it aside after making the incision, and use the end of a silver probe. The fluid that escapes is not always in proportion to the volume of the tumor; the largest I ever opened, which was of the size of a cherry, situated in the upper lid, and of nine months' growth, contained but a small quantity, the remainder of the contents consisting of what would be called sarcomatous matter. In such cases a crucial incision should be made, and the mass freely broken up with the knife. A reduction in size does not quickly follow this treatment, and usually for two or three weeks there is no decrease. A patient should be forewarned of this, and even of the likely temporary increase, from bleeding within the tumor, and also that ecchymosis of the lid may ensue. It is rarely that a single attempt is not successful: the lapse of a month is sufficient time for testing its efficacy, and should there then be no diminution, the operation ought to be repeated. After-treatment is not called for, unless a fungus springs from the interior of the lid, an occurrence which, though unusual, should be looked for; I have seen such a growth from

the under lid, passing up in front of the cornea. When large and pedunculated, and capable of being snipped off, scissors should be used; but if small, the lid must be everted, and the growth carefully touched with a small portion of caustic potass, the spot then oiled, and the lid restored. When it seems necessary to cauterize the cavity of the tumor, the nitrate of silver had better be employed, being safer than the potass.*

In Mr. Wilde's ophthalmic report in the "Dublin Journal of Medical Science," for 1847, it is mentioned, without any reference to the original, that Dr. Sichel has noticed in the substance of the lid, and generally towards the internal angle, a small lipomatous tumor of a yellow hue, which he considers to be usually connected with diseased liver, especially with hypertrophy or fatty degeneration. Removal of it is unavailing, as it is always reproduced; and strangely enough it is said that removal of the predisposing cause is the only method of eradication.

With the view to prevent bleeding during the removal of tumors of the lids, M. Desmarres has invented an instrument, which consists of a kind of forceps with rings at the extremities, between which the lid is placed, the rings being made to press on it by a screw in the body of the instrument, which draws them together. This cannot be employed without much pain and some violence to the lid; and if it could, it would be still objectionable on account of being useless. I mention it because some of our instrument-makers have recommended it, and some surgeons, who have never used it, speak of it in high terms.

* Our usual method of treating chalazion is, with due attention to the improvement of the general health, in some depravation of which it almost always originates, to make a free incision from the inside of the lid, and press out its gelatinous contents. If the tumor return, which is rarely the case, the operation should be repeated, and measures adopted to subvert the morbid action of the part. A convenient mode of accomplishing this, is to dip a probe in nitric acid and cauterize the cavity with the nitrate of silver thus extemporaneously prepared.—Ed.

TUMORS OF THE CONJUNCTIVA.

POLYPI AND WARTS.

Growths and excrescences of all kinds from the conjunctiva are decidedly rare; I have met with warts on the palpebral portion of the membrane, and these may become quite gigantic, for instances are recorded of some having overspread the globe, and protruded from within the lids. A small flat red vegetation sometimes appears just within the margin of the lower lid, and if allowed to grow may rise about its level. It is most frequent just before adult age, and it is often supposed to be of a cancerous nature; it is readily and effectually destroyed by a few touches with any caustic substance. Mr. Tyrrell described an affection which seems identical with this, as an enlargement of the Meibomian glands.

A soft gelatinous mass, exactly like a nasal polypus growing with a narrow base from the ocular conjunctiva, was pointed out to me by Mr. Smee; a snip with the scissors readily separated it. There are growths which seem like vascular prolongations of conjunctiva, with long but very delicate pedicles, so slight that, in one instance which I have seen, during an examination of the body the pedicle broke. I once examined a small cartilaginous tumor that was developed in the substance of the conjunctiva, and lay near the caruncle. I have met two productions of the same kind in the dog.

A youth of eighteen had two peculiar tumors which appeared to have their seat in the conjunctiva; the one, of a red color, and having a mulberry, wart-like look, was on the inner surface of the upper lid, and overlapped and destroyed the punctum. The other, also red, and possessing more of a fungous appearance, overlapped and obscured a part of the cornea, but did not adhere to it; it was sufficiently wide to appear connected with the caruncle, but was found, when the tarsus was depressed, to have its base in the conjunctiva at the sinus of the lid, and to receive a remarkably large supply of blood-vessels from the sclerotic.

accuracy of delineation, in which he contrasted this abnormal product with the regular cells of healthy conjunctival epithelium. Nine months have elapsed since the operation, and there is not the least indication of the disease returning.

A man, aged sixty-four years, applied to the Central London Ophthalmic Hospital, in August, 1847, with a circumscribed black mass about the size of an almond, growing lengthwise on the interior of the left lower lid, which it partially everted; the attachment seemed slight, indeed the peculiarly well-defined base induced the idea that the mass might be readily pulled away from the lid, to which it seemed but to adhere. The conjunctiva around, and on the lower part of the globe, was of a dirty brown color. Vision was perfect. Two years prior, the disease was discovered as a little black pimple, and from its commencement to the date of his application, he had not felt the slightest pain, but merely inconvenience from the restriction to the movements of the lids. He had consulted several surgeons, among whom were Mr. Lloyd and Mr. Coulson. I did not again see the man until the 27th of May, 1850, when he reapplied at the Ophthalmic Hospital. In the interval he had been to many hospitals and dispensaries, where removal of the lid and the eyeball had been repeatedly advised. The growth had increased so as to cover the globe, while a piece, about the size of a nutmeg, protruded from between the lids, and was with some difficulty pulled aside to expose the cornea, which was hazy. I wished to admit him into the house, and then carefully to examine the eye while he was under the influence of chloroform, and he went home with the avowed intention of procuring some personal articles, but never returned: having left a wrong address I could not find him, and his fate is unknown to me. It is probable, but not certain, that the disease was melanosis. The duration of the affection, however, without the surrounding parts being implicated, the absence of pain, and the apparent isolation of the affection—for the absorbent glands about the face were unaffected—may be taken as some evidence against that opinion, although a strong suspicion of malignancy must still remain. This case bears upon

the writings of Dr. Jacob, of Dublin, in the "Dublin Medical Press," in which he urges surgeons to investigate more fully the nature of tumors of the eye and the orbit, it being his opinion, that many which are supposed to be malignant are not so in reality, although they may not be amenable to medical treatment, and would spread or grow to any size unless removed by the knife or escharotics. His remarks have particular reference to what we are accustomed to call melanotic tumors. He argues, that the blackness of a disordered mass affords no clue to its true character. He had seen, in old persons, deposits of black matter under the conjunctiva without disease; and the fact of a growth not healing, in no way proved the existence of a malignant disease, as he instances in sores and warts that continue to increase under any kind of medical treatment. In one of the two cases alluded to, a black spongy tumor, two inches in diameter, overlapped the lids in all directions, so as nearly to close the whole opening of the orbit. The surface was lobulated, and appeared to have been compressed by the bandage with which it had been covered, and bled slightly when the adherent dressing was removed. It appeared to be attached to the eyeball by a cylindrical stalk, which was slightly enclosed by the lids. Being prepared to remove the contents of the orbit, if necessary, Dr. Jacob drew his knife across this, as a preliminary step of the operation, and found that he had incised a healthy eyeball, the disease being confined to the conjunctiva of the cornea, and of the sclerotica—in fact it was a tegumentary growth from the front of the eye. The divided globe healed kindly. Sufficient time had not elapsed to enable him to pronounce as to the true nature of the disease, whether it was to be considered malignant or not. Its black color, spongy texture, and slightly lobulated appearance, did not convince him that it was a fungoid growth of a fatal nature; although it might have produced death by growing to a mass which could not be arrested or reduced by remedies. Pathology will certainly have advanced a step, when a means of accurate diagnosis shall be discovered, between melanosis of a malignant character, and black tumors that are not malignant. I shall have

occasion again to refer to malignant affections and the diseases which simulate them, in my chapter on malignant diseases of the eye.

The caruncle and the semilunar fold are very rarely the seat of surgical operation; except in abscess, I have never seen any necessity for the use of the knife. I have been applied to by a patient to have a part of both structures removed from enlargement following a long and severe attack of granular lids, and I had some difficulty in dissuading him from it. There was a diminution of the swelling on leaving off the escharotics that had been applied for its reduction, which were certainly causing it to increase.

Warty growths or polypi may issue either from the caruncle or the semilunar fold.

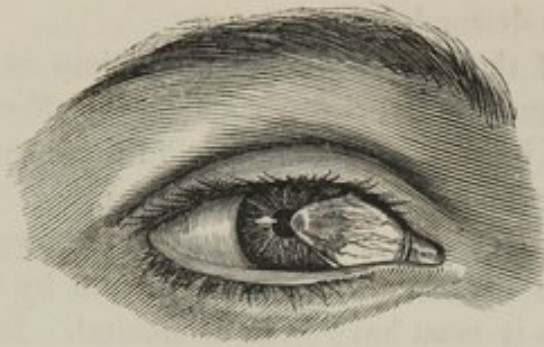
PTERYGIUM.

This affection, laboriously described by authors, derived its name from the supposed likeness to the wing of an insect, and has been divided into four varieties,—the cellular, the vascular, the fatty, and the fleshy; but pathology warrants no such arrangement, while distinction for the sake of description is useless. At different periods of its growth, different appearances may exist—one that is thin may become thick, and one half of the growth may be transparent and delicate, while the other is like a piece of muscle. The disease consists essentially of thickening of the conjunctiva and of the subconjunctival cellular tissue, with increased vascularity; and the various appearances it presents in thickness and in color depend on the greater or lesser degree of those changes. It must retard rather than advance the knowledge of the subject to speak of membranous, coriaceous, and cartilaginous pterygia, each of which is formally described by writers.

The following sketch (Fig. 93), taken from a colored man from the Island of St. Kitts, exhibits a specimen of a very marked pterygium.

The position is the ordinary one,—at the inner corner of the eye, with the base connected with the semilunar fold and ca-

Fig. 93.



runcle, from which it would seem to grow; the form also is that which is most usual. In other instances the edges may be unequal and indefinite, and the base may be at the cornea, as Mr. Tyrrell and others tell us; a bifurcated pterygium has been described by Weller. The extent or size also differs—the greater part of the sclerotica may be covered, and the whole of the cornea veiled. Then more than one may exist in the same eye; four have been seen several times, and Velpeau has described five. Both eyes may be symmetrically affected.

There is a peculiarity in warm climates that renders pterygium common. Rognetta says that it may be met with at every step in Calabria, and the large number of operations cited by some foreign authors shows that it abounds in certain countries. Nearly all that have come under my own notice, have been in natives of the tropics, Creoles, or those who have resided in hot latitudes; of two exceptions, one was in a girl, a Londoner, fourteen years old, the pterygium being situated at the inner corner of the eye, and encroaching on the cornea. The other was in a boy twelve years old, and arose from the irritation of some slaked lime that had entered the eye; months after the accident he was brought to me with a well-marked triangular pterygium, at the lower part of the globe, the rarest position for one to grow. There was not the slightest adhesion of the lid to the

globe, nor could any of my colleagues at the Ophthalmic Hospital, or myself, determine any difference between it and an ordinary pterygium, except in the rapidity of growth. I watched it for three months, using astringents, until the increase in the corneal portion demanded operation.

The origin of these adventitious productions is attributed to idiopathic inflammation of the eye, and to the effect produced by the entrance of irritating substances; and there can be no doubt about the general correctness of these views.

It is usually after the adult period that pterygium appears; yet it has been seen immediately after birth by Mr. Wardrop, when doubtless it must have been congenital. It is seldom, in these latitudes at least, that we have an opportunity of observing its commencement and progress. Mr. Wardrop, in his work on the eye, gives a drawing of one that he saw from a very early period, and watched for upwards of eight years; the first appearance was that of a small globule of fat near the junction of the cornea and the sclerotica; it then became larger, so that its base adhered to the semilunar fold, and its apex passed over the edge of the cornea.

The usual absence of any inconvenience in the earlier periods of this affection—for it arises and proceeds without any attendant symptoms, except inflammation of the conjunctiva—its slow growth, increasing but little in the course of years, and when it has overlapped the cornea, its tendency to progress still slower, or even to remain stationary, have induced some surgeons to recommend non-interference. If the disease should become stationary from change of climate, or from treatment, the question of operating may be left to be determined by the individual, for personal appearance alone is concerned; but when there are symptoms of augmentation, I advise an operation, for delay is unnecessary; the operation is more severe the longer it is postponed, and the result is less perfect.

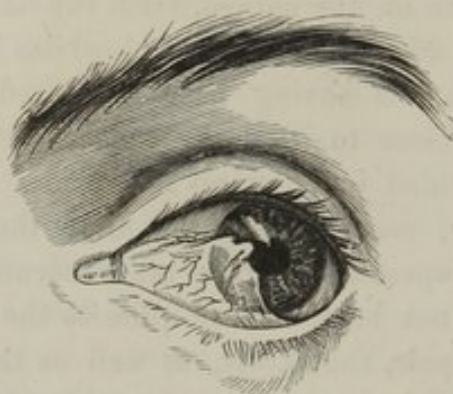Excision alone can be depended upon. A mere division by cutting across the pterygium is insufficient, and may irritate or prove injurious. Mr. Wardrop tells us of a young gentleman

who had a common triangular-shaped one from early life, which rapidly increased in growth and development, under repeated scarifications. The mass was so large as to separate the tarsi, and involve the semilunar fold and lachrymal caruncle. The greater part must be removed; yet it is advisable, I think, not to touch the portion on the cornea, from the danger of injuring that structure, for after the supply of blood has been cut off, that will decline. The lids having been separated, the pterygium should be seized close to its corneal attachment with the tenaculum forceps, divided just beyond the cornea, and dissected off towards the base, care being taken that the edges are cut through. When operating at the inner corner of the eye, the dissection should not be continued quite to the caruncle; for in the process of repair, that body, as well as the semilunar fold, would be lost. With a view to saving the conjunctiva, Scarpa advises that when internal pterygia have a very extensive base on the sclerotica, they should not be severed near the broader part. With a great loss of that membrane, an elevated cicatrix arises, and confines the ball of the eye to the caruncle, preventing freedom to its outward movement. When a pterygium is adherent to the sclerotica, it must be removed at the expense of denuding this coat of the eye. I have never known the operation fail when the centre of the growth was removed, even where the base has been very large.

A captain in the royal navy, who had been stationed in the West Indies, consulted me for a pterygium that had existed several years, and was gradually increasing; its peculiarities are shown in Fig. 94. It was irregular, and the portion involving the cornea was thicker than the rest. I operated, removing a portion around the circumference of the cornea. A dissection that would have embraced the whole of the sclerotic portion, must have been followed by considerable contraction of the conjunctiva; even with the very limited excisions, there was for a while a sense of stiffness when the eye was turned out, but this gradually passed off. As the corneal portion was diminishing rather slowly, I was induced to touch it with an escharotic to

hasten the process, and thereby to relieve my patient's anxiety. Here, as in every case in which I have operated, the cornea remained opaque nearly to the extent traversed by the growth. I

Fig. 94.



say nearly, for the cicatrix left from the decline of the growth is always less than the size of the original mass. I operated on a soldier four years ago, and now the mark on the cornea is a third less than the portion of pterygium left. Contrasted with this is the statement of Mr. Travers, concerning one of his operations; the disease, in that instance, originating from beneath the whole base of the upper eyelid, was of a triangular form, extending to the lower margin of the cornea, of sarcomatous density, about one line thick, and forming a fold when the eye was directed upwards: it was, he says, completely cured by the operation of dividing and detaching it at the base, and the patient recovered her sight and ultimately no vestige of the disease remained. The swelling and increased vascularity of the parts that are left, together with the slight inflammation caused by the operation, soon subside, and traces of the disease grow gradually less. The only after-treatment that I have ever used is a weak solution of alum, two or three grains to the ounce of water, and occasionally the application of a wet rag over the lids for a few days.

PTERYGIUM PINGUE.

This is the term applied to a whitish-yellow little tumor that is generally situated at the sclerotic coat, just internal to the cornea, although it may grow on the globe external to the cornea, and having its seat in the conjunctiva and sub-conjunctival cellular tissue. The name, like most of the names of diseases of the eye, is badly chosen and incorrect, indeed, in this instance it is doubly wrong, for the affection has not the least resemblance to a little wing, and it does not consist of fat, but, as Weller has shown, is of an albuminous nature. Like pterygium it is very common in tropical countries, yet it is not very uncommon in temperate latitudes. I meet with several examples of it yearly, yet I know but of one instance in which it encroached on the cornea, and then merely the margin of the cornea was overlapped. So inoffensive and innocuous are these growths, that it is a matter for the persons possessing them rather than the surgeon, to decide about their removal. There is involved merely the question of taking away a little blemish or deformity, and no risk of any kind attends the operation, which is simple enough; the tumor being seized with the tenaculum forceps, is drawn forwards, and cut off with the curved scissors.

TUMORS INVOLVING THE CORNEA AND THE SCLEROTICA.

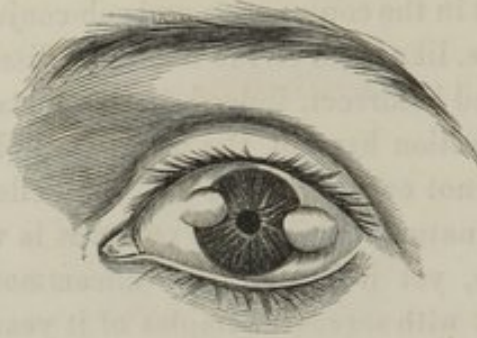
TUMORS OF THE SCLEROTICA.

Those tumors which are incorporated with the sclerotica, or with it and the conjunctiva, are not so readily got rid of as those involving the conjunctiva alone: nor is their removal unattended with danger. Figure 95 shows what would be called sclerotic tumors, from their commencing in the sclerotic coat, and from their intimate adhesion and similarity of structure to that tunic.

The conjunctiva was in this instance adherent, as it has been in all the cases of sclerotic tumors that I have seen. Here they were congenital, the cornea was not encroached on till

puberty; the individual is now thirty. While I was attending the practice of Mr. Tyrrell, a young man came to the London Ophthalmic Hospital with two of these growths in one eye, only

Fig. 95.



one of which encroached on the cornea. This case induced some remarks from my much-respected teacher on the manner of their incorporation with the sclerotica, to the effect, that twice he had seen attempts at their excision; in one instance, the vitreous humor escaped, and the eye collapsed; in the other, the operator desisted when he found the true nature of the tumor; but cases are recorded of surgeons having successfully extirpated them.

M. Lawrence gives in the second edition of his ophthalmic work, two cases of tumors of the sclerotica that admitted of removal. A child ten years old had a semi-transparent firm oval swelling about the size of a pea on the sclerotica, close to the margin of the cornea, of some years' duration. Evacuation of the contents had been tried; and now, in opposition to the opinion of other gentlemen who saw the case, the cyst was punctured, and the prominent part cut away with curved scissors. It was thin but tough, the sides being firm enough to retain the figure of the tumor. The interior was smooth, and a round aperture was observed in the middle of the basis, apparently passing through the sclerotica. The wound quickly healed. The next is a case of a larger growth. A gentleman, about thirty years of age, of full habit and robust frame, had a cyst on the sclerotica as large as an almond, producing irritation in the motions of

the globe and lids. An operation was performed as in the last case; but the patient was not seen again.

Dr. Mackenzie describes what he terms scrofulous tubercles growing from the sclerotica, and elevating the conjunctiva; they are whitish or yellowish, appear as if about to suppurate, but continue firm, increase slowly to perhaps the size of a hazel-nut, and burst through the sclerotica, but do not suppurate. If left to themselves they are apt to induce disorganization and atrophy of the eyeball. If extirpation is attempted the diseased mass is found to be soft and easily torn.

TUMORS OF THE CORNEA.

We learn, from the publication of several cases, that the true tissue of the cornea may remain uninfluenced by growths that appear upon it, the conjunctiva alone being implicated; and in a case that occurred to Mr. Travers, in which he extirpated the anterior half of the eyeball, the cornea and sclerotica proved to be entire; the morbid growth lay upon and adhered to the cornea. A small portion of the sclerotic surface had acquired a lobulated appearance, as if by degeneration of the conjunctiva; for delicate white bands, the only vestige of this membrane, were seen intersecting the lobules at irregular distances, in the form of septa. A case operated on by Sir A. Cooper, and mentioned in Mr. Travers's work, is nearly parallel, and other surgeons have met with similar examples.

In the fourth plate of the first volume of Mr. Wardrop's work on the eye, second edition, are two well-executed drawings of tumors involving the front of the globe. One is called tumor of the corneal conjunctiva; and here the growth covers one half of the corneal surface, having, as the author describes it, no regular form, and a fine granulated texture; the other consists of a warty excrescence of the conjunctiva, occupying two-thirds of the cornea, and having an unequal surface of a peculiar dark brown color, and of a soft texture. Other instances are recorded by authors, in some of which the tumor involved the whole cornea, and had attained the size of a hen's egg. In the Museum of the

Royal College of Surgeons, is the anterior half of an eye from Sir A. Cooper's museum, with a large and broad wart-like growth covering the superficies of the cornea, and a small portion of the sclerotica around, and standing out in relief for about half an inch.

We must endeavor to remove a growth when it involves the cornea, and threatens to overspread the pupil; there should be no delay when an excrescence is steadily increasing, or has already in any way interfered with vision. As much as possible should be excised with the knife or scissors; escharotics should be used only when positively demanded, for they are less admissible here than in any part of the human frame. Caustic potass and the mineral acids, are unsafe agents about the globe, for unless great care is exercised, they are apt to run beyond the spot to which they should be restricted. I have seen a surgeon apply the potass, to a little tumor of the sclerotica near the margin of the cornea, and although, as a precaution, he oiled the cornea, yet his endeavors were frustrated, for the caustic spread to the cornea, which became opaque. Again, strong escharotics may produce a deeper slough than is required, and however unimportant going a little beyond bounds might be in other parts of the body, precision must here be secured. The *potassa cum calce* of the London Pharmacopœia, is more manageable and safer, and should be used in preference to the *potassæ hydras*; but the milder caustics, such as nitrate of silver, sulphate of copper, and dilute acids should be first tried, and always when practicable with the precaution of shielding any transparent part of the cornea with oil, or with such substances as have the power of neutralizing the agent. During the process the lids should be held open by an assistant, and before they are set free, any superfluous portion of the escharotic should be wiped off; it is well to grease the surfaces that have been cauterized, lest they affect the parts with which they naturally come into contact.

When the entire cornea is covered by the tumor, an attempt should be made to restore, as far as may be, its transparency, by cautiously excising all that can be so treated, and leaving that

which cannot be removed without injuring the cornea to be further acted on by mild escharotics. It may be that a partial operation will suffice, the thin portion left behind may be removed by absorption.

An instance of warty opacity of the cornea relieved by operation, is given by Mr. Bowman in his lectures on the anatomy of the parts concerned in the operations on the eye. The growth is spoken of as an old-standing prominent opacity of the right cornea, lying in a transverse position, just below the centre, and extending across, corresponding to the interval between the lids, with a rough surface like that of a soft corn, and having the iris adherent to it; it fretted the lids, and kept up inflammation; was of four years' standing, and had followed a severe ophthalmia. Astringents were of no avail. The opacity was sliced off to the level of the cornea: it contained a great abundance of papillæ, covered with thick epithelium; the report concludes with saying, the part is much flatter, and the sight improved.

The testimony of British and Continental surgeons establishes the fact that the cornea may regain its transparency after the removal of a growth from its surface; I shall mention two examples in point in connexion with pterygium.* That it possesses considerable power of repair is a fact often manifested. I have seen its restoration by transparent matter, after partial loss of the entire thickness. In a girl twelve years old, an ulcer pene-

* A case was admitted into Wills Hospital, which exhibited what was supposed to be the epithelial scales of the conjunctiva cornæ in a state of unusual development. They were distinctly visible without the aid of the microscope, of a brownish color, spread uniformly over the entire superficies of the membrane, and both in shape and arrangement bore a close miniature resemblance to the imbricated scales on the cupule of the acorn. The whole epithelium was thickened to the extent of perhaps half a line, the transparency of the subjacent tissues concealed, and vision entirely lost. The disease was confined to one eye only, and the conjunctiva covering the sclerotica was unaffected. Under the use of the nitrate of silver, at first in substance, and afterwards in strong solution, the morbid growth rapidly disappeared, the cornea became clear, and though the cure was not quite completed, the patient left the House after a few weeks of treatment, rejoicing in the improvement which had been made.—ED.

trated the cornea, and let out the aqueous humor, and in five months there was not a trace of the ulcer; I have seen exactly the same result, but on a much larger scale, in gonorrhœal ophthalmia; and Mr. Tyrrell gives a good example occurring in the same disease, where the destruction of a considerable portion of each cornea was not followed by the formation of opaque cicatrices. In one eye, by the separation of the sloughs, the anterior chamber was opened, and a prolapse of the iris induced; nevertheless the cavities in both corneæ were gradually filled up with a perfectly transparent substance, resembling very much the original texture. The case is reported at p. 261 of the first volume of his work.

Many authors have recorded cases of hair growing from tumors on the surface of the eyeball. Mr. Wardrop has delineated a beautiful specimen; the tumor, the size of a horse-bean, appears to have been connected with the cornea only, for it is said that only a small portion of it adhered, and this seemed to grow from the cornea; the other portion rested on the white of the eye next to the temporal angle of the orbit, and contained upwards of twelve long and very strong hairs, which had appeared when the patient's beard began to grow. Hair has been met with on the caruncle and on the conjunctiva. This irregular development is not uncommon in the lower animals, and most museums possess specimens; in that of St. Bartholomew's Hospital, is the eyeball of an ox, in which there is a tumor on the outer half of the cornea and sclerotica, apparently made up of fat and condensed cellular tissue, and covered by skin, which is lost in the conjunctiva around, giving rise to long hairs, with their hair-bulbs. The other parts of the eye were healthy; I have seen similar examples in sheep.

Other tumors, which it would not be easy to classify, that are spoken of as fleshy, fatty, and albuminous, have been met with on the surface of the eyeball, some of which have attained to a very great size. One of a fungous kind, so large as to advance

like a mushroom and cover the whole eyeball, proceeded originally, as the author, Maitre Jean, describes, from the iris through an ulcer of the cornea. Bouttatz's celebrated case of tumor beneath the conjunctiva, mentioned by Abernethy in his surgical observations on tumors, was seven inches long and three and a half in circumference, and weighed two pounds and a half. It is supposed to have been the pancreatic sarcoma of Abernethy. It is remarkable that the cornea is frequently much less the seat of tumors of any kind than the sclerotica. Nothing further is required to be said of the surgical treatment of these diseases than is comprised in the principles already laid down:—that is to say, to remove by dissection, if possible, the whole of the morbid growth; but when the connexion with the cornea or sclerotica is such as to render that impracticable without cutting it through, to remove a part of the growth and trust to the reduction and disappearance of the remainder; or afterwards to apply an escharotic, as advised in the early part of this chapter.

TUMORS OF THE ORBIT.

Abnormal growths about the orbit constituting tumors, and capable of being extirpated, should be removed early, more particularly those that encroach on, actually enter, or are entirely within the orbit. The surgeon must determine what circumstances in any particular instance render a case exceptional; it may be remarked, that it would be bad surgery to undertake an operation for a comparatively insignificant tumor, one perhaps that merely protrudes the eye, but does not threaten mischief, when the effect would in all probability be injury or destruction of sight. At the same time the sacrifice of the eyeball must not be regarded, if cerebral symptoms should arise from pressure on the brain through the roof of the orbit, from expansion of that cavity, or from absorption of its walls by a tumor.

Much valuable time is frequently lost in attempts to disperse tumors by local applications and medicines; indeed, great faith in drugs is necessary to suppose that they can remove encysted, fatty, and osseous growths.

The size, figure, and position of the growth to be removed must determine the direction, the form, the number, and the extent of the incisions; and although no special rule can be laid down on this head, yet it may be stated generally, that the preliminary ones through the skin should be sufficiently extensive to facilitate the intended dissection, and that it is better to divide the lids at their external commissure, than vertically, while the latter is preferable to separation at the internal commissure; and further, the lids should be left intact whenever a tumor can be removed by dissecting within them. It may be observed that all external cuts should be made with reference to the least after-disfiguration, and this may for the most part be effected by horizontal incisions, a little curved, to correspond with the wrinkles about the eye.

Healthy integument scarcely ever requires to be removed, except in pendulous tumors; and it is important to save cellular tissue in order to lessen contraction during the healing process. The position of the levator palpebræ should be remembered, and an operation should not be commenced beneath it for the removal of a tumor which lies above, and *vice versâ*, for fear of ptosis following the division of the muscle. It is also advisable that the scalp should not be cut, on account of its great liability to erysipelas; nevertheless the superior palpebra may be so attenuated that an incision may risk its vitality, and thus the position or the extent of a tumor may require the division of the cranial integuments.

The scalpel which I have figured at page 27 is, from its size and shape, particularly adapted for operations about the orbit; and small as the blade is, I have found it safer when dissecting deep in the orbit, to blunt the greater part, and use the point alone, for picking rather than cutting.

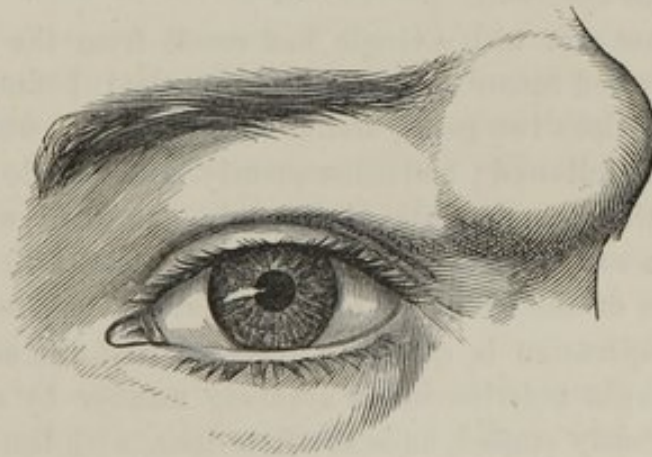
A syringe will be found very useful in deep orbital dissections; for a jet of water will often, by washing away the blood, expose parts when a sponge cannot.

A small bent metal spatula is necessary to pull aside the eyeball, and also at times to protect it from injury.

A tenaculum forceps with points of the size and shape that have been figured at page 28, together with curved scissors as at page 31, complete the instruments necessary for the removal of any tumor about the eye; and with them, operations that have been considered most difficult, and recorded as wonderful instances of practical surgery—which no doubt they were with the imperfect means employed—may be performed with comparative ease, and therefore with great safety.

The upper and outer part of the circumference of the orbit is the most frequent site of tumors, which are mostly encysted, and the steatomatous variety chiefly prevails; the cyst is usually thin, but may be very dense, and even semi-cartilaginous. The accompanying sketch conveys a good idea of the form and position of this type of tumor; the locality, however, may vary a little, and may be just within the orbital ridge.

Fig. 96.



They invariably grow slowly, are unattended with pain or redness, and seldom attain any great magnitude, though I have operated on some as large as a pigeon's egg, and have seen a few still larger; they are, I believe, congenital. So frequently do they adhere to the periosteum of the orbit that the occurrence should be expected and allowed for during their removal, by keeping the edge of the knife rather away from the surface after

the superficial dissection has been completed (which is contrary to the general rule for the extirpation of solid tumors), or in all probability the cyst will be cut into; this is very likely to happen even in the first incision, except to a practised hand, if the integuments are not pinched up and divided from within outwards. When the tumor is small a single central incision generally suffices; for by slipping the opening first on one side of the tumor and making a partial dissection, and then pulling it over to the other side, the removal is readily effected. By getting out the mass entire there is the assurance that all is taken away, an advantage that compensates for the more tedious dissection; for, if a portion be left, a return of the tumor is almost certain. Should the cyst unfortunately collapse, it must be seized with the tenaculum forceps, drawn forcibly forwards, and dissected out.

I have seen but few examples of the steatomatous tumor at the inner canthus, and all have contained hair, either loose and imperfectly formed and mixed with the fatty contents, or growing from the cyst-wall.

I have not met with a single bad result from the extirpation of an encysted tumor external to the orbit; I find that Mr. Tyrrell mentions two cases, and alludes to others where exfoliation of bone followed; and consequently he felt little disposed to meddle with those that were intimately connected with the periosteum, a condition which he thinks to be usually indicated by indentation of the bone. I have no fear of such consequences when the operation is carefully executed, and the edges of the wound brought together in an accurate manner by sutures, and not barbarously stuffed, as is so often done, with lint or charpie. I have always found the sensation of indentation of bone around the tumors to be deceptive, and to be of the same character as that which occurs when the scalp is elevated from the skull by effused blood; any little depression that may exist could never be detected by an external examination.

Other kinds of tumors of a solid nature grow about the circumference of the orbit, and like the encysted, are beneath the orbicularis muscle. Last summer I assisted Mr. Coulson to re-

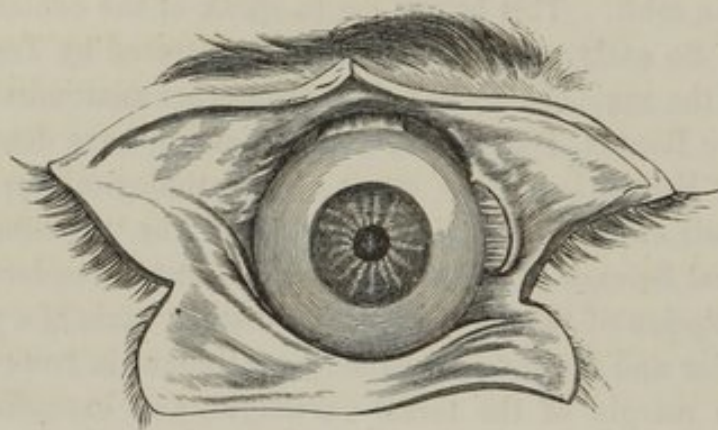
move a fibrous one that was firmly adherent to the external angular process.

When a tumor takes its rise within the orbit, much surgical and anatomical knowledge is required to decide, with any approach to correctness, what are its relations; but the difficulty of diagnosis has been diminished by Dr. O'Ferrall's investigation in connexion with the cellular sheath of the eyeball, and his researches should be known by all those who undertake operations within the orbit. This brings me to speak of the ocular cellular sheath. So early as 1804, it was demonstrated by Tenon, who called it the tunic of the eye; since then other anatomists, among whom are Bonnet, Dalrymple, and O'Ferrall, have described it, but to O'Ferrall is due the merit of a pathological application; his memoir on the subject is in vol. xix. of the "Dublin Journal of Medical Science." The following account is condensed from his description of the sheath. It is a distinct tunic of a yellowish white color and fibrous consistence, continuous in front with the posterior margin of the tarsal cartilages, and extending backwards to the bottom or apex of the orbit, where its consistence becomes less marked; the sharp end of a probe, or a director, will be sufficient to separate it from the eyeball, by breaking the fine cellular tissue which connects them.* Within, where the eye glides over it, the surface is smooth, the external or orbital part loose and cellular. The muscular portions of the recti muscles lie at the outside of this tunic, which isolates and protects the eye in the most perfect manner possible. Half an inch posterior to its anterior margin are six well-defined openings, through which the tendons of the muscles pass to their insertions in the

* The ocular fascia is not lost in the cellular tissue of the posterior part of the orbit, as might be inferred from the description in the text, but, as shown by Mr. Lucas, is intimately connected with the optic nerve as it enters the sclerotica; and upon this connexion, Dr. Mackenzie observes, its pathological effects chiefly depend. Effusion of sero-purulent fluid within the capsule prevents the motions of the eyeball, and not only protrudes it, but gives it a feeling of extreme hardness, and an appearance as if it were greatly enlarged. When notwithstanding the protrusion the globe retains its mobility, the cause of pressure is without the capsule.—ED.

sclerotic coat, and over which they play as through a pulley. The readiest way of exposing the sheath is to divide the palpebræ vertically, to turn back the separated parts, and to divide the conjunctiva at its angles of reflection, where it passed from the internal surfaces of the eyelids to the ball of the eye. The following drawing is taken from a dissection I made in this

Fig. 97.



manner. Two of the recti muscles only are visible; for as the eye was in this instance very deep in the orbit, the insertion of the other muscles could not be seen. In order to exhibit them it would have been necessary to cut away a portion of the orbit, and then the connexion of the sheath with the lids would have been destroyed.

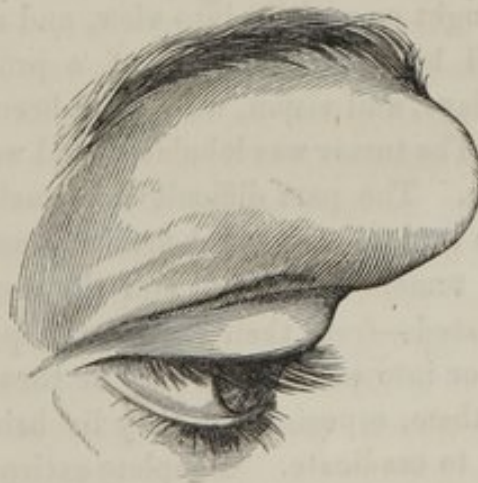Among other excellent observations Dr. O'Ferrall remarks that, in displacement of the eyeball, the projection of the palpebræ will not always suggest the exact locality of the tumor; the lid may be thrown forward in such a manner as to cause the supposition that the morbid growth is nearer to the orbit than the eyeball, and very little covered by soft parts; and if a careful examination be not premised, external appearances will mislead, and a tumor that is supposed to be superficial, may prove to be in actual contact with the eyeball: moreover, that tumors may form internally as well as externally to this ocular sheath.

When an encysted tumor, under which head I include all that

consist of cysts containing fluid, is not tense, its nature is unmistakable; but when tight or hard, it may very often be erroneously considered a solid mass.

Figure 98 is a profile view of a fibro-cystic tumor within the orbit of a female forty-two years old; it was at once recognised as situated between the roof of the orbit and the muscles. The ocular movements were not interfered with till the pressure from above thrust the eye downwards and outwards, when they were nearly altogether arrested. It was hard and immovable, projected far beyond the brow, which was raised, while the orbital limit passed beyond the reach of the finger. There had been an unsuccessful attempt at removal ten years before, and the patient now sought relief because the sight of the eye was nearly extinct; she deprecated the idea that the tumor was removable, and it required no little persuasion to induce her to submit to the operation. In May, 1848, with the assistance of Mr. R. G. Shute, of Mecklenburgh Square, to whom I am indebted for many similar acts of kindness, I divided the skin crucially, and

Fig. 98.



removed the mass entire. The orbital portion of the tumor was flattened, reached to the centre of the orbit, and adhered to the periosteum. The bleeding was very free, and was difficult to suppress.

My patient's recovery was slow, the wound being six weeks in healing; but before that time the position of the eye was quite restored, and vision had returned. Three years after, I had the gratification of learning that the cure was, up to that period, permanent.

Solid tumors in the orbit are less common than the encysted, and it is to be regretted that the usual description of most of them has been imperfect and indefinite; the expression sarcomatous has been too indiscriminately used. The following account of one so called, situated within the ocular sheath, is given by Dr. O'Ferrall, in vol. xix. of the "Dublin Journal." A woman, twenty-eight years old, had the right eyeball displaced upwards and inwards, and it was slightly prominent; the lower lid was thrown forward, and covered a firm tumor which could be felt through its substance, and under the conjunctiva when the lid was depressed. A free incision was carried along the inferior palpebral sinus, the tumor exposed, hooked, drawn forwards, and detached by a few slight touches of the scalpel. A process remained, which passed backwards in close contact with the globe; by drawing downwards and forwards the cellular sheath of the globe, it was brought more fully into view, and readily separated from the eyeball by the sharp end of a probe. The wound healed in a few days, and vision, which had been nearly lost, was soon regained. The tumor was lobulated, and well circumscribed by cellular tissue. The part difficult to detach lay behind the globe, within the tunic, but was not firmly attached to either.

Both kinds of tumors—the solid and the encysted, but particularly the encysted—from their extent, the positions in which they may grow, or into which they may be thrown by the resistance offered to them, especially if they lie behind the eyeball, are very difficult to eradicate. Complete extirpation is desirable here as well as in fatty and fibrous tumors; and without it there must always be an amount of uncertainty as to the result; yet unfortunately it is not always practicable. However, I have known some abandoned in despair, when a little more patience and courage on the part of the surgeon would have completed

the operation. It is a common error with those who are not in the constant habit of operating, to fancy parts of the body to be more superficial than they really are, and from the same false impression they often imagine tumors to be deeper seated than they prove to be.

The following history of an operation by Mr. Barnes, of Exeter, recorded in vol. xi. of the "Medico-Chirurgical Transactions," shows how much an able surgeon can effect within the narrow limit of the orbit.

A tumor occupied a considerable portion of the orbit, and pushed the eye upwards so as almost to be wholly hidden behind the upper lid; it appeared to extend to a considerable depth, and projected so much as to constitute a very striking deformity. A superficial groove, running obliquely across the upper surface, formed a slight line of division between the more prominent and movable part of the swelling, and that more immediately under the eyeball, and this front portion could be moulded into different shapes by the fingers; the posterior was more elastic. The swelling was observed in infancy, the patient being now seventeen years old, and was then not larger than a pea; the principal increase was within the last four or five years. It was painless, and the eyeball was sound, but vision was lost from the pupil being covered. The sac adhered firmly to the outer angle, and part of the lower edge of the orbit; in most other points it was but loosely connected with the surrounding parts. It extended to the bottom of the orbit, and occupied more of it than the eye itself; and as it was impracticable to proceed in the dissection far in the orbit, without greatly endangering the eye, the contents of the posterior division were partially evacuated to obtain room, and the sac separated from its deeper attachments. Towards the posterior point on the inner side, and more than an inch from the edge of the orbit, the sac felt as if it embraced a sharp bony process, projecting nearly in a perpendicular direction into the cavity of the orbit, and apparently attached to the periosteum; it proved to be a tooth, in form and size like one of the supernumerary teeth sometimes found in the palate. The crown,

with the enamel, was within the sac; the root, with its dental vessels, was attached to the orbit. The two cysts were distinct; the front one had a chalky matter on some parts of it, and contained a compact lardaceous yellow substance; the other, which in the interior was smooth, excepting a part near the tooth, contained a whey-colored fluid, and a yellow curdy substance. The patient did well; he could not move the eye downwards, or freely in any direction, but vision was perfect.

Even in the present day, when so much of the former difficulty of operating is removed by chloroform—a difficulty which Mr. Wardrop combated by bleeding his patient to fainting—and with all the advantages of superior appliances, and better knowledge of the anatomy of the ocular appendages, the relations of a tumor may render its detachment impossible, without some of the contents of the orbit being also taken away, not even excepting the globe of the eye. In the second volume of the “*Lancet*” for 1827–8, Dr. Bushe records an instance in which the right eye and a large encysted tumor were successfully removed. The connexions with the globe were inseparable, and during the operation it appeared that the superior and posterior part of the orbit had been absorbed by the tumor, which pressed on the anterior lobe of the brain. Alarming cerebral symptoms had arisen, and partial paralysis of the left side of the face and left upper extremity was established. In ten days the wound had nearly healed, and the little patient was walking about without any inconvenience.

Dr. Monteath, in his translation of “*Weller’s Manual*,” tells of a hard tumor, larger than the eyeball, and completely encircling the optic nerve, resting on the posterior surface of the eyeball, but not connected with it, except through the nerve and cellular tissue. Such connexions were inseparable, and when, in the course of dissection, this difficulty appeared, the eye, with the tumor, was extirpated.

A tumor intimately connected with the orbital contents is in the museum of St. Bartholomew’s Hospital, and is much more marked and peculiar in its relations than any I have seen; it is

firm, compact, and lobulated, and adheres to the back part and sides of the sclerotica; the optic nerve, which is elongated, passes through its axis, and the recti muscles, quite unaltered, adhere to it externally. The humors of the eye escaped through an ulcerated opening in the cornea. The retina and the choroid membrane are collapsed, and occupy the axis of the eye between the entrance of the optic nerve and the iris; and the space thus left between the choroid and the sclerotica contains a firm clot of blood. A fibrous tumor, preserved by Mr. Liston, and now the property of the College of Surgeons, filled the orbit, surrounded the optic nerve and eyeball, and extended forwards as far as the conjunctiva.

If a dense tumor does not actually surround the optic nerve, nor particularly adhere to the orbit, it may be drawn forward to an almost incredible extent, and its removal thereby facilitated. Encysted tumors may even pass beyond the orbit. Thus in the "London Medical Gazette," vol. v., Dr. Hall has given an abstract of a case that occurred to Delpech, where a tumor passed through the optic foramen into the cavity of the skull, and was imbedded in the left anterior lobe of the brain. Death ensued from the puncture of the cyst, which had formed a large projection between the lids. In another instance that occurred to Delpech, a cyst which followed the ocular movements, and seemed to belong to the globe, had also intimate connexions within the orbit.

Even with slight hopes of success, an attempt should be made to remove a cyst; I have known an instance in which, after the greater portion of the tumor has been detached, the evacuation of its contents has enabled the dissection to be completed, which would otherwise have been impossible. Whether in any instance the eyeball should be taken away with a morbid growth, must depend on the nature of the tumor, and other circumstances of the case; the probability of so dire a contingency should, as far as possible, be considered before operating. But this applies more especially to solid tumors; since the nature of the case must be peculiar which would necessitate extirpation of the eye

before trying the effect of the partial removal of the cyst or other means for its destruction. When fluctuation indicates the presence of an encysted tumor, which declares its depth and central position in the orbit by thrusting the eye directly forwards, the practice should be to make as free an incision as possible, and not merely to puncture. We must wait the result, which is ever uncertain; but it will be favorable or not according to the nature of the tumor, the state of its walls, and the character of its contents. The common termination of those that are thin-walled is the destruction of the secreting membrane by suppuration; a delicate cyst will break down rapidly, and it is said that the cyst-walls may adhere. I do not, in the first instance, attempt to produce suppuration by the introduction of lint and other substances, or the application of an escharotic; I rather trust to a natural process, lest the consecutive inflammation prove to be very severe; although I do not hesitate, when I think it necessary to prevent premature closure, to insert in the opening, for a day or two, a few shreds of lint.

A boy, fourteen years of age, had a protruding globe; and the suspicion of fluctuation induced the late Mr. Scott to make an exploratory puncture: a creamy fluid escaped, and for several weeks a purulent discharge continued, until the escape of a small cyst, which was evidently the sac of the original tumor much contracted, effected a cure.

It is a very prevalent plan at present in Paris, to inject orbital cysts with iodine, just as lumbar and other abscesses are treated; and notices of the practice have appeared of late in several journals. My personal knowledge of the treatment by injection is confined to a single case. In March of this year, Mr. Gay asked me to see with him a patient in whom he had opened an encysted orbital tumor, and I recollected at once, that the man had been under my own care some time before with the same complaint. His eye was then prominent, and thrust forwards and outwards, and, detecting a fluctuating tumor, I opened it. After a few attendances he ceased to see me, because the aperture healed, and the eye became less prominent. About a

year after, the globe again came forward, and when he applied to Mr. Gay it was most remarkably protruded, turned considerably outwards, and fixed. Vision was nearly extinct. It was about two months after the evacuation of the tumor by Mr. Gay, that I again saw him; the eye had receded but little, although the discharge, which was creamy, had lessened. The aperture was just above the upper lid, and near to the inner canthus. A probe could be passed to the apex of the orbit, and when bent with an elbow of half an inch, could be turned completely round, showing the extent of the cavity. I recommended the injection of sulphate of zinc, two grains to the ounce,—for I greatly prefer zinc to iodine,—to be used twice daily, and in a week the discharge ceased. The last time I saw the patient, a month later, the eye was very much less protruded, and vision was returning. Further information is needed to assign to this treatment its proper value.

Hydatids, acephalocysts, and the echinococci, have been met with in the orbit, where, of course, their nature was not determined till a puncture or an incision was made; for they produced symptoms the same as those arising from any other kind of fluid tumor. Mr. Lawrence met with an instance of one of these in a man forty-two years old; the globe was protruded, and the discovery of a small, firm, protuberance under the superciliary ridge, which seemed to be part of a deeply situated swelling, induced him to recommend extirpation as the only chance of relief. This was refused; the disease increased, the eyeball was turned completely out of the orbit, and sight was destroyed. A puncture was made, and clear watery fluid escaped, and in two days after, a soft opaque white substance, which protruded in the aperture, was extracted, and proved to be an hydatid; others were discharged, and ultimately, by enlarging the aperture and injecting water into the sac, half a teacup full was removed. The cyst suppurated. The opening closed in a month, the eye returned to its natural position, and all uneasiness ceased. A little motion of the iris, and slight perception of light

returned. The particulars of the case are in the "Medico-Chirurgical Transactions," vol. xvii.

Fatty tumors occur about the orbit; those that I have seen were on the outer part of the globe, corresponding to the space between the inferior and external recti, and the largest was not above the size of a pea. Their presence is indicated by prominence of the lid over them. I have always operated within the lid. If the conjunctiva is snipped, they may readily be drawn down and detached; when united to the conjunctiva, as they may be, the adherent portion should be detached with them. An interesting instance of symmetrical tumors of this kind, in both orbits, has been given by Mr. Bowman, in the "Provincial Medical and Surgical Journal of Medicine." The swelling was nearly limited to the outer half of each lid, and extended from the brow to within a quarter of an inch of the tarsal border, where it ceased by a groove, over which hung the relaxed and distended integument. Each was quite soft, as if from œdema of the parts subjacent to the skin, and pressure did not meet with any resistance, nor did indentation ensue. A seton was passed to produce consolidation of the parts, under the conviction of the cause being œdema, and afterwards medicines and low diet were enjoined. Subsequently an operation was undertaken to remove a piece of the supposed infiltrated tissues; the skin, orbicularis muscle, and fascia, were divided, and there fell forward a mass of fat as large as an almond, in pellets or lobes, resembling the fat in the orbit. Both eyes were operated upon, and both did well. The condition of the lids, as to bulging or distension is, as Dr. O'Ferrall has shown, and as I shall refer to more particularly in my chapter on prominent globes, diagnostic of disease in the cellular tissue of the orbit, external to and above that sheath.

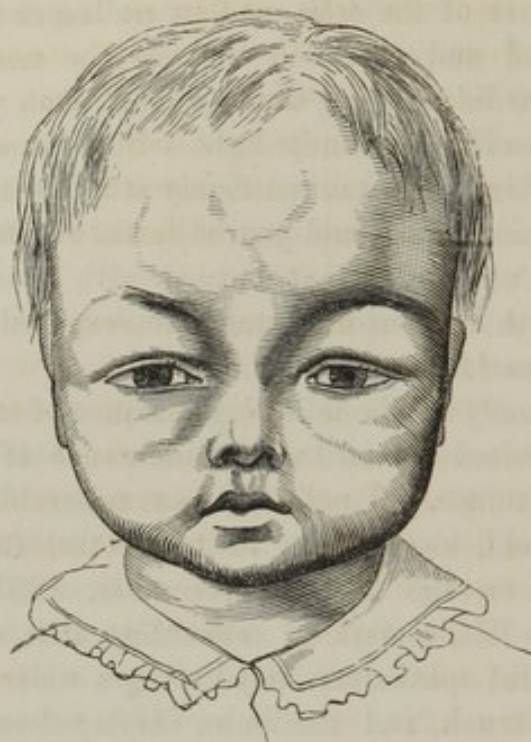A unique case of an encysted oily tumor in the orbit is copied into the Catalogue of the Museum of the Royal College of Surgeons, from a manuscript volume of cases in Medicine and Sur-

gery by Sir E. Home. A young gentleman had a small tumor in the upper part of the orbit, at first no larger than a pea, but which increased and extended towards the nose, and pressed down the upper lid, keeping the eye half shut, yet unattended with pain. Reading by candle-light induced uneasiness of the eye with throbbing. It was not firmly attached to the orbit, and evidently contained fluid, and poured forth, on puncture, pure oil perfectly clear and sweet, that burned with a very clear light, did not mix with aqueous fluid, and when exposed to cold became as solid as human fat.

I am aware only of the following instance of tuberculous matter being deposited around the circumference of the orbit, and constituting a tumor. A pale and most miserable-looking child, eight months old, was brought to the Central London Ophthalmic Hospital, on the 29th of December, 1851, with a hard swelling of the lids, something resembling that attendant upon infantile purulent ophthalmia, but having a wider circumference. The scalp, the trunk, and the limbs, displayed several swellings of similar physical characters; the lobes of the ears were enlarged, and very hard; the testicles were four or five times their natural size, and of stony hardness; and the foreskin was about as large as a pigeon's egg. A few weeks later, the orbital tumors increased and became livid, at which period the following sketch was taken.

I had no doubt of the tuberculous nature of the many swellings about the body, and the death of the child on the 17th of February following, confirmed my suspicion. Dr. Handfield Jones and Dr. Sieveking carefully examined some slices of the deposits, and pronounced them to be infiltrations of tuberculous matter in the cellular tissue. The heart was exhibited at the Pathological Society of London, as a rare specimen of tuberculous deposit in that organ. Except the lungs, which were healthy, every other internal organ gave manifestation of this remarkable example of mal-nutrition. The child was perfectly healthy till five months old, when the eyes began to be affected, and then the disease appeared in other parts of the body.

Fig. 99.



I was requested by Mr. Francis A. Bulley, of Reading, to meet him in consultation on the case of a patient who seemed in danger of having his eyes closed by a series of small tumors around the edge of each orbit, and to consider the propriety of a surgical operation for his relief. The palpebræ of each eye, but particularly of the left, were so pushed together, and the eyeball so covered, that vision was much interfered with. The tumors were irregular in form, of a stony hardness, varying in size,—the largest being about the bigness of a marble,—and appeared to arise just within the edge of the orbit; no attachments could be made out, and they were very movable. The symmetry of the disease was very striking. The orbital affection, however, was but a small portion of similar disease in many parts of the body. Mr. Bulley has very kindly furnished me with a history of the case, which I shall give in his own words.

“Mr. M., aged 46, consulted me on the 28th of December,

1846, on account of some very hard movable tumors occupying the lower part of the cheeks, and extending from the lobe of each ear some distance down the fore part of the neck towards the larynx. There were three or four of these on each side, the skin, of the natural color, being easily movable over them, and the swellings themselves, although closely in apposition, distinctly movable upon each other; they were as hard as ordinary scirrhus.

“There was a slight appearance of fulness of the upper eyelids at this time, but no perceptible deposit in their tissues. On examining the groins, which I understood were affected by the same kind of disease, I found a tumor of about the size of a hen’s egg, situated just below Poupart’s ligament, on each side, of the same scirrhus hardness as on the face, and perfectly movable, with the skin over them, as well as over those of the face, completely unaffected by disease. These latter tumors had a remarkably symmetrical appearance. There were several smaller subcutaneous deposits of the same nature in different parts of the body. His skin was clammy to the feel, and had a general anæmic appearance. The swellings on the face had commenced about five years before I saw him, and had been gradually increasing up to that time. Those in the groin had been more recently developed.

“He had never suffered any particular pain in any of the swellings, only a slight aching sensation at times.

“He was evidently suffering from great bodily weakness, his pulse being extremely feeble, and there was a certain hurry in his breathing, when he talked or exerted himself in the least. His extremities were habitually cold, an evidence of the languor of his circulating functions. He informed me that prior to the appearance of some secondary venereal symptoms, hereafter to be mentioned, he had always enjoyed robust health, and had never displayed the slightest symptom of any scrofulous contamination of his system; he had, however, suffered on several occasions from primary syphilitic disease, to which he seemed to have been peculiarly susceptible. On the last occasion of this

kind, he had had a chancre *apparently* cured by the application of the nitrate of silver, which being followed, as before mentioned, by secondary symptoms of the disease, he considered to be the remote cause of the unsightly deposits under which he was now suffering.

“He gave me the following details of the origin and progress of his complaint. He had been engaged for many years as a commercial traveller, and during this period had lived very freely, and been much exposed to vicissitudes of weather. Shortly after the apparent cure of the last chancre by the caustic, unequivocal symptoms of constitutional contamination presented themselves in the form of extensive ulceration of the cuticle over the whole body, but more particularly affecting the hairy scalp, sore throat, and wandering pains in the limbs, for which he underwent a course of mercury, while at the same time he continued his usual occupations as traveller, constantly exposed to bad weather, and living in the same free, careless manner as he had been used to do. The result of this carelessness was that the secondary symptoms were not improved, and he was attacked with pulmonary inflammation, which brought him into a state of great constitutional weakness. On his recovering from this, his venereal symptoms continuing, he consulted an eminent surgeon in London, who, notwithstanding his weakened state, administered mercury to such an extent that in a short time his gums became affected, and an unhealthy-looking ulcer, which ultimately acquired the size of a half-crown piece, appeared upon the inside of the left cheek; his throat became much sorer than it ever had been before; his face became puffed up and swelled in an extraordinary degree, but there was no salivation.

“Having now relinquished his occupation as a traveller, and partially recovered from the effects of the mercurial treatment, he found that, although the secondary symptoms were subdued, the swelling of the face did not entirely subside, and some small tumors began to be developed in the subcutaneous cellular tissue of the part, which had been gradually enlarging up to the time when I first saw him. I have not observed any particular altera-

tion in these tumors since I first attended him—now nearly five years—except that about two years ago they appeared to have become somewhat smaller. He has occasionally suffered from slight periosteal pains in the ulna and tibia, which have been subdued by the use of hydriodate of potash lotions, and he has been much troubled with night perspirations, which weakened him very much. It was about four or five months ago that these perspirations somewhat suddenly ceased, when I for the first time observed that a morbid deposit, of a similar character to those in the other parts of the body, but not quite so dense in its structure, had begun to be developed in the cellular tissue of the left upper eyelid, which was shortly afterwards followed by a similar appearance in the opposite lid, occasioning a considerable projection of the skin covering the lids, and causing great difficulty in uncovering the eyes.

“Immediately after this, other swellings formed in the cellular tissue of the lower lids, which, lifting their ciliary edges upwards, have caused their approximation to the upper lids to such an extent as almost to close the eyes. These tumors, placed external to the tarsi, are of a flattened shape, and movable, and extend some little distance beneath the superciliary ridges of the frontal bone; they are of a somewhat softer texture than those upon the face, and are entirely unattended by pain, but their contiguity to the eyeballs gives rise to occasional attacks of conjunctival irritation of their surfaces, which, extending to the ciliary margins of the lids, occasion a purulent discharge, by which they are glued together in the morning. I should mention that, simultaneously with the development of these tumors on the cessation of the profuse diaphoresis, to which the patient had previously been subject, the lowest portion of the cervical swellings also began to enlarge, and to press upon the larynx, occasioning an alteration in his voice, and some difficulty in respiration, which is now evidently impeded by the contiguity of the morbid growth.”

I regret that I could not procure a sketch of the patient, whose appearance, with tumors around the eyes, at the side of

the face, and under the jaws, was very remarkable. As some tumors on the chest had declined with the improvement of the general health, and others—especially the orbital ones—were just now stationary, it was decided that no operation should be undertaken on these unless there was a decided increase, whereby the eyes would be closed, but to adopt such general means as seemed necessary to improve his depressed state of vitality, for he was greatly depressed and very feeble. Some months have elapsed since I saw him, and I learn from Mr. Bulley, that he is decidedly better in health, and that there has been no increase in any of the tumors.

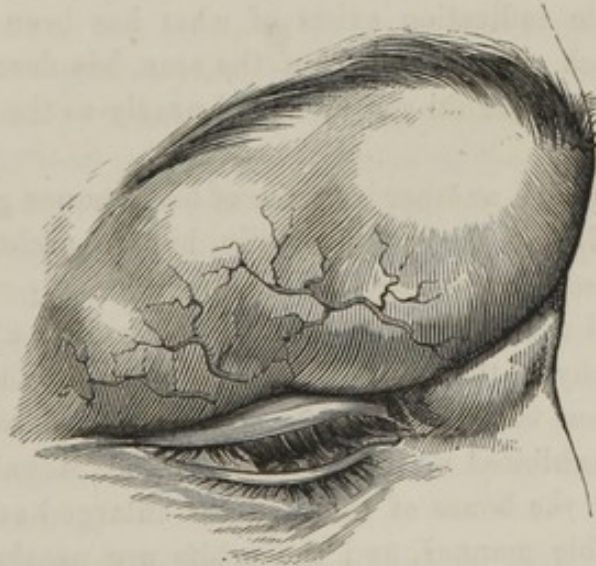
Exostosis of the orbit is very rare, few surgeons, even in large ophthalmic practice, having met with the disease. All parts of the orbit are alike liable to it, and, as with exostoses in other situations, it varies in size and other physical properties, in the mode of attachment—having a narrow or a broad connexion with the skull—and in density, whence the division into varieties according as it is ivory-like, made up of bone and cartilage, or of bone and fibrous tissue.

When an exostosis in the orbit is hidden from the touch, there is no point of diagnosis by which it can be distinguished from any other tumor that protrudes the eyeball. It may be painless, or very painful, this being determined by its position, whether pressing on a nerve or not. The slowness of growth is the only circumstance that may cause a suspicion of its nature. Neither can it always be determined whether an exostosis will admit of being removed till a portion of it has been exposed, and the nature and extent of its attachment ascertained. No very precise rules can be laid down for the manner of operating; but this may be said:—that, unless well exposed, more may be done with the bone forceps, especially if the connexion of the tumor with the orbit be small, than with any other instrument, and the forceps for such an occasion should have very short and narrow blades, and very long handles. It is judicious to be prepared with two pairs, one straight, the other with convex blades. In

addition to these, there should be provided a variety of small saws and gouges, of different shapes and sizes; in short, all the modern instruments that are used for operations on bones. The upper and inner walls of the orbit are parts that require the greatest care in operating, but in the orbit, as elsewhere, the surface throwing out an exostosis is generally thickened.

A carter, forty years of age, was admitted under my care at St. Mary's Hospital, with an exostosis growing from the upper edge of the orbit; it had a very broad base, and was flattened, and the greatest point of projection was two inches. The upper edge was covered by the eyebrow, which was considerably thrown up; the lower dipped into the orbit, touched the globe of the eye, and thrust it downwards and outwards, protruding it about half an inch beyond its fellow, thereby nearly destroying vision. The inner and outer boundaries were less marked. The surface was tuberculated, as hard as stone; the skin was movable, and traversed by a few vessels. Figure 100 gives an idea of its extent.

Fig. 100.



When quite a lad he had fallen down stairs, and pitched on the front of his head; two months afterwards a little swelling appeared on the orbital ridge, and gradually increasing, developed

the growth. There was no doubt as to its true nature; hardness, immobility, slow growth, continuity with the bone, and absence of pain and inflammation, sufficiently marked the nature of the case.

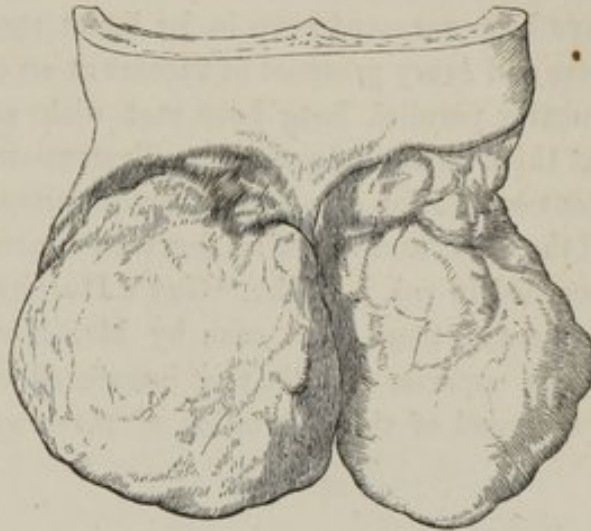
Chloroform having been administered, I made an incision in the line of the eyebrow, which had been previously shaved, along the entire superior edge of the tumor, a second from the inner extremity of that to the root of the nose, and a third from the outer extremity to a little below the level of the outer corner of the lid. I then dissected downwards the flap thus formed, till the lower part of the tumor was reached, when I passed a narrow saw between it and the eyeball, and sawed from below upwards in a circular line, endeavoring to follow the natural line of the brow. The texture of the mass was like ivory and a very long time was occupied in getting through it. The integuments were brought together by suture: union by the first intention followed, except at a central spot of the transverse cut, through which healthy pus was discharged for eight weeks. Now, after a year has passed, the eye is restored to its place, the sight has returned, and very little indication exists of what has been done. The eyebrow, which conceals much of the scar, has descended to its proper level, and the lid can be raised nearly to the extent of its fellow.

I have met with another instance of bony tumor growing from the orbital edge of the lower maxilla, but the patient ceased his attendance before anything was done for him.

The orbital cavities may be greatly reduced, or almost closed, by hypertrophy of the orbital bones, in common with the hypertrophy of other bones of the face and cranium. In the skull of a Peruvian exhibited in the museum of the Royal College of Surgeons, all the bones of the face are enlarged and thickened in a remarkable manner, and the orbits are nearly closed. In the same museum is another remarkable example of two osseous tumors which completely fill both orbits, Fig. 101; the cavities of the nose, and probably the antra, extend as far as the pterygoid plates of the sphenoid bone, project more than three inches

in front of the face, and jut out an inch beyond the malar bones. The tumors are symmetrical, of an irregular rounded form, deeply lobed, and somewhat nodulated, and their surfaces perforated apparently for bloodvessels.

Fig. 101.



The individual was a man of sixty; it was supposed that the disease began eighteen years before his death, in consequence of repeated blows received on the face in fighting; and during its growth he suffered much pain in the eyes, face, and head. His eyes projected from the orbits; the right, after inflammation and sloughing of the cornea, shrivelled; the left was accidentally burst by a blow while it was prominent and tumid with inflammation. During the last two years of his life he occasionally showed symptoms of insanity; and he died suddenly of apoplexy. The cranial bones were very thick and hard, and all their sutures were obliterated. The periosteal covering of the tumors was dense and hard.

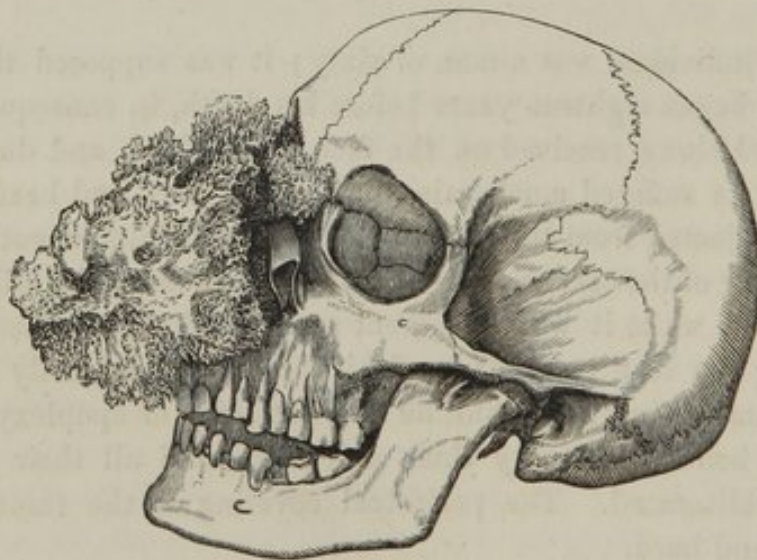A third specimen, in the same collection, Fig. 102, and more striking from its magnitude, exemplifies how a growth from a neighboring part may be of an equally serious nature with one originating in the orbit itself. The tumor, an osteo-sarcoma, is connected with the right side of the face, and has its origin in the

antrum. It was five years in progress, and had destroyed all the right orbit except its roof, and involved or destroyed the right malar, superior maxillary, and frontal bones. The part which remained after maceration consists of an oval mass of light cancellous bone about five inches in diameter, and four inches in length.

It might have been removed even in its latest stage, and certainly, with ease and every prospect of success at an early period. Other cases, nearly parallel, have been met with, and need not be dwelt on, as these examples suffice for illustration.

A spontaneous separation of a large exostosis situated between the nostril and the orbit, and weighing fourteen ounces and three-quarters, is recorded in vol. i. of the "Guy's Hospital Reports." In the same Journal there is a case by Mr. Morgan, of an exostosis from the superior maxilla that interfered with the eye. Instances are recorded of the exfoliation of these growths after

Fig. 102.



abandoned attempts at their removal; and it has been suggested always to endeavor to produce exfoliation as the means of cure, by exposing a part of the tumor and applying an escharotic.

The general result of operations about the orbit for the re-

removal of tumors, is much more favorable than might be anticipated from their peculiar locality and close proximity to the brain; the operations do not seem to be more dangerous than those in general about the head and upper part of the face, which are never devoid of risk. Nevertheless, death has followed simple puncture, partial removal, and complete extirpation of orbital tumors, both encysted and solid. The removal of exostoses is, perhaps, attended with the most danger, especially when growing from the orbital plate of the frontal bone.

To guard against an unsuccessful result from operations in these diseases, the utmost vigilance must be bestowed on the preparatory and after-treatment of the patient; and an essential part of the latter is perfect rest of the body and of the eye, which latter should be kept closed for many days. The slightest appearance of erysipelas should be carefully attended to, and any collections of matter early and freely evacuated.

The recovery of the position of the eye, after the cause of protrusion has been removed, and the restoration of sight, not only when impaired but when it seemed to have been lost, are truly astonishing, and establish important facts for the admissibility of operating; but both have their bounds, beyond which recovery is impossible. In one of the cases of orbital tumors related and figured by Dr. O'Ferrall, in the "*Dublin Hospital Gazette*,"—and all of his cases are very valuable,—the eyeball lay naked on the cheek an inch below the tarsal margin of the eyelid, was in constant movement, and productive of much pain. The elongation and tension of the muscles and nerves seemed to be the chief cause of the patient's great suffering; the dislocated globe was removed, and a decided amendment of all the symptoms followed. Even when an eye cannot, unaided, recover its position, the use of a compress in the direction of the axis of its protrusion may be perfectly successful.

So long as the structural integrity of the globe remains, the transparent media being unaffected, there may be hope of entire recovery of vision; and the greater the amount of vision that is left, the greater the chance of complete restoration.

ENLARGEMENT OF THE LACHRYMAL GLAND.

The lachrymal gland falls within the domain of practical surgery less frequently than the other ocular appendages; and the most common change requiring operation is that of enlargement with increase in density. The rarity of this condition in any degree, however, is very striking, and I have met with but few cases; in one instance both glands were enlarged; but not once has it been requisite to operate.

Our most experienced surgeons confirm the slight susceptibility of the lachrymal gland to disease. Mr. Tyrrell states in his work that he has met with but two cases. Other English writers give similar testimony as to its infrequency, but some Continental authors have spoken of it as rather common. All the specimens that I have examined seemed to be those of mere increase of size, and sometimes with induration also; two of them are in the museum at St. Bartholomew's, and both had been extirpated during life; one is enlarged so as to form an oval mass, an inch in length, and more than an inch in breadth; it retains its lobular form and glandular appearance, and there is apparently simple hypertrophy without any decided change of structure. The patient was forty-five years old, and the disease had been in progress for several years; she recovered from the operation. The other specimen will be spoken of presently, in the details of the case quoted from the work of Mr. Lawrence, who was the operator.

A tumor in the situation of the gland, protruding the eye, and thrusting it into a position according to the form and degree of its enlargement, is the symptom that indicates the nature of the affection; yet it is evident that this symptom is not unequivocal, for any other tumor may show the same signs, and the removal of several has been undertaken under the erroneous impression of an enlarged lachrymal gland being the disease.

There may, or may not, be subjective symptoms; pain or inconvenience of some kind is usually present; yet these may be

produced by a tumor contiguous to, or developed in the gland. Preternatural lachrymation, as an early attendant on a tumor in the situation of the gland, together with a lobulated surface of the tumor, seems to be the most probable diagnostic; but both may be absent, and a lobulated surface is not uncommon to adventitious growths.

EXTIRPATION OF THE GLAND IN A DISEASED AND IN A HEALTHY STATE.

When damaged vision or conspicuous deformity results from an enlarged gland, and general means have failed to reduce the swelling, removal of it by operation should be the remedy. It is a necessary precaution in operating, to proceed slowly and to endeavor carefully to ascertain the limit of the mass, and to confine the dissection to it; for if an adventitious growth only be present, and it touches or is attached to the gland, the latter may be saved; otherwise, through carelessness, it might be injured or actually removed. I have seen the gland sacrificed more than once, and Mr. Tyrrell mentions having witnessed the same accident; the operator, in that instance, considering the tumor to have been produced by a diseased gland, and being rapid in his execution, removed the healthy gland together with a steatomatous tumor. The rules already laid down in this chapter for the operations on orbital tumors in general, apply also to the extirpation of a diseased lachrymal gland, and need not be repeated.

A young man was struck violently on the eyelid with an apple; pain, swelling of the lid, and a copious lachrymal discharge followed; the globe was now protruded, and, covered by the extended lids, seemed to reach half way between the orbit and the nose. A hard unyielding tumor, with a lobulated surface, was found projecting at its upper and outer part, a little beyond the margin of the orbit, and whether it moved or not, was questionable. Mr. Lawrence made free incisions, exposed the tumor, and removed it from the surrounding connexions, which were

cellular, and it proved to be the lachrymal gland, very much enlarged, and altered to a compact homogeneous texture of a light yellow color, with an appearance of radiated fibres at one point. It is said that it approached in firmness to cartilage, and altogether closely resembled the firmest part of a scirrhus mammary gland. A large quantity of blood was lost, and one vessel was tied. The wound united by adhesion and the eye receded to its natural position and moved freely, its surface, and that of the lids being moist, as usual. The operation was performed in 1826, and in 1839 Mr. Lawrence saw the patient, when a hard swelling had formed about the cicatrix under the superciliary ridge, but no inconvenience resulted. The same authority gives the particulars of another patient, who came to him with a hard tumor in the situation of the lachrymal gland, projecting under the edge of the orbit, close to the bone, and hardly movable. The eye protruded about an inch beyond the level of the other, and was thrust downwards. The upper lid, which was swollen and covered the eye, still retained its power of motion. The disease commenced five years previously, with headaches, slight temporary pain about the eye, and an almost continual flow of tears. The largest print could not be distinguished with the affected eye. The diseased gland was removed; it was connected by loose cellular tissue to the surrounding parts, by a short close texture to the bone, and was equal in size to a large walnut, slightly tuberculated on the surface, of a light yellowish brown color, firm, and nearly homogeneous in texture, but not so hard as scirrhus. Free bleeding ensued, but no vessels were tied. In this case there was union by the first intention, and the patient was able to attend to his affairs in a week. In five months the position of the eye was nearly natural, and the sight was such as to allow the patient to read ordinary-sized print. The gentleman was seen two years after, and continued well.

A case by Mr. Pemberton in the "Dublin Journal" for 1847, possesses interest. The eye was quite concealed by a growth of ten years' standing, but not protruded. An operation was undertaken, and the removed mass, of the size of a large orange,

consisted of two lobules, the smaller lying deep in the orbit, and said to be made up of dense fibrous tissue of homogeneous structure and whitish color. The operation was easily performed, and very little blood lost. Several other instances of like operations are on record. In Mr. Travers's work a case is mentioned in which the lachrymal gland is said to have been greatly enlarged, and in a scirrhus state: the patient from whom it was removed continued well after the interval of some years. In one of Mr. Todd's cases, in the "Dublin Hospital Reports," the gland, almost as firm as cartilage but more elastic, had lobes with deep fissures between them, and contained cartilaginous cysts filled with glairy fluid, the interspaces containing a firm fatty substance, traversed by a few membranous bands. In Dr. O'Beirne's case, in the same Reports, the surface was granular, of a pink color, and the interior of the gland presented a cartilaginous centre, from which septa passed to the circumference: sanies was not perceptible. The particulars of many other cases are published, but the majority of them are recorded in such a manner as to render them useless, so far as pathology is concerned.

Several of the above cases exhibit changes that have been, and would be still called, by some surgeons, scirrhus, and therefore malignant. There cannot be a doubt that this term has been too indiscriminately applied to mere enlargement of the gland, and this is in keeping with the heretofore general latitude of expression, and looseness of description, concerning the supposed cancerous deposits in other parts of the body, arising from the imperfection of the means of defining and discriminating the new product. Those who reject the idea of malignant degenerations of the lachrymal gland, usually found their opinions on the want of the ordinary concomitants of cancerous disease, such as the ulceration, the enlarged absorbent glands, the adhesion to, and implication of the surrounding parts, and the absence of return of the disease after operation; and, certainly, if these be insisted upon as the data for diagnosis, the mass of evidence at command is against the existence of malignancy. What was the secondary formation in the first case, quoted from Mr. Lawrence, cannot be

determined; but for further inquiries on this matter, I must refer to my chapter on malignant affections of the eye.

I strongly suspect that tumors in the situation of the lachrymal gland are often mistaken for the gland itself in a state of disease; and unless glandular structure be made the criterion for diagnosis, imperfect as that criterion may be, I am unaware of any other proof which can decide the question whether a tumor removed from the orbit, be the gland, or some adventitious growth.

A knowledge of the state of the eye after the operation is interesting. Mr. Tyrrell states, in the first volume of his practical work, that he had thrice inspected the conjunctiva after the removal of the gland, when, of course, no secretion of tears could take place, and that in each instance the conjunctiva retained its usual brilliancy and moisture, proving that it secreted its own proper fluid, and that the humidity of the eye is not, as some have supposed, alone dependent on the secretion of the lachrymal gland.

Dr. Halpin, desirous, as he informs us in the "Dublin Journal of Medical Science," of ascertaining whether tears could flow from an eye deprived of its lachrymal gland, dipped the blunt end of a probe into tincture of opium and touched the conjunctiva with it: immediately the right eye, the sound one, became suffused with tears, which flowed over the cheek; in thirty seconds the probe was reapplied; after sixty seconds a drop of fluid fell from the left eye; in thirty seconds more, another drop.

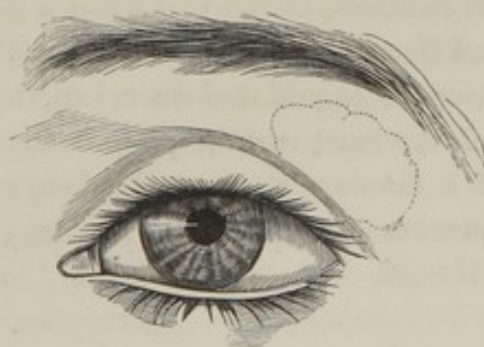Weeping must certainly be taken as the most conclusive proof that a lachrymal gland yet remains; but increased conjunctival secretion must not be mistaken for tears.

Extirpation of a healthy lachrymal gland may be required when the natural channels that convey away the tears are lost. Mr. Dixon informed me that he removed it in a patient whose lids were united at the corners, after an accident with gunpowder, so as to leave but a small central aperture, there being

no means of escape for the tears but over the cheek; and the operation has been performed by several other surgeons.

An incision in the lid, corresponding to the margin of the orbit opposite the centre of the orbital ridge, sufficiently external to avoid the frontal nerve, and ending a little below the superior and external angle, will afford ample room for the operation. The fibres of the orbicularis and the fascia beneath it being divided, a portion of the gland comes into view. It will be remembered that the gland possesses two lobes, the one, which may be called orbital, nearly three-quarters of an inch long, is in relation above to the lachrymal fossa of the frontal bone, and below to the upper and outer part of the eye and superior and external recti, and receives its vessels and nerves behind; the other being a palpebral portion, smaller, seated on the lid, reaching as far as the tarsal cartilage, and having a sort of capsule. If the orbital portion is drawn forwards with the tenaculum forceps, the separation of it is as easily effected as that of the smaller division, which is external. The annexed diagram of the eye, with the position of the gland traced in a dotted line, may be useful.

Fig. 103.



The lesser or palpebral portion may be overlooked during an operation. A surgeon being desirous of stopping the inconvenience of the entire flow of tears over the cheek from irremediable injury of the canaliculi by a burn, proceeded to remove the gland, and did not discover his insufficient anatomical knowledge

until the patient's continued power of weeping proved that a part had been left behind,—that which was in the lid.

MORBID GROWTHS CONNECTED WITH THE GLAND.

Cysts have been supposed to be developed in the lachrymal gland, and Schmidt describes them under the class of hydatids; but since he wrote, in 1803, little has been said on the subject, except to question the nature of the disease he describes, and the correctness of his pathological reasoning, which is too obsolete to be quoted. I suspect that his cases were merely cysts in the neighborhood of the gland, and more or less attached to it; and it matters little whether it be the one or the other, for there can be no distinct diagnostic symptom, and the treatment is identical.

The dilatation of the gland-ducts into a fluid tumor is said to occur, and there are conditions that would admit of it; we have, too, a parallel example in ranula. The tumor is described as a circumscribed elastic swelling without pain: and Desmarres speaks of it, according to Chelius, as of a size varying from a hazel-nut to a filbert. According to Stœber's account it is a circumscribed tumor, elastic, and painless, of the volume of a pigeon's egg, and becoming enlarged if a secretion of tears is called forth. The complete destruction of the dilated duct can alone be depended on for a cure, and the most certain plan is to dissect it away. The formation of a fistulous aperture is always to be dreaded, the worst consequences of which, however, may be avoided by operating within the lid.

CHAPTER XII.

PROTRUSION OF THE EYEBALL FROM CAUSES WITHIN THE ORBIT, INCLUDING THOSE ARISING FROM ANÆMIA. RHEUMATIC INFLAMMATION OF THE OCULAR SHEATH. ABSCESS AND INFLAMMATION WITHIN THE ORBIT. PERIOSTITIS OF THE ORBIT, AND DISEASE OF THE OPTIC NERVE.

PROTRUSION OF THE EYEBALL.

I VENTURE to group under the general head of protrusion of the globe several affections of the orbit, that are for the most part obscure, protrusion being the universal, and often the only apparent symptom; to class them otherwise would involve subdivisions and unnecessary repetitions without any practical advantage.

The projecting globes of the anæmic person, although not actually requiring practical surgery, ought not to be passed over here, as a knowledge of all the causes that may protrude the globe is essential for the correct diagnosis of surgical diseases of the orbit. I am indebted for much information on the etiology of the disease, and for many references on the subject, to an excellent communication by Dr. James Begbie, in the "Edinburgh Monthly Journal," for February 1849, under the head of "Anæmia and its consequences,—enlargement of the thyroid gland and eyeballs. Anæmia and goitre, are they related?" Dr. Begbie argues that they are related; since where goitre is endemic, the pallid face, prominent eyeballs, and generally exsanguine state of the goitred subject, mark them as belonging to the single cause of anæmia.

I have myself, for several years, been aware of the attendant

general derangement of health in these cases, but did not, till I read Dr. Begbie's paper, regard it as a cause of the protrusion; the theory, however, seems correct.

In 1847, when surgeon to the St. Pancras Royal General Dispensary, Dr. Ballard, one of my colleagues, transferred to me a female patient, whose eyeballs were so prominent that when in the street she was obliged to cover them to prevent the inquisitive gaze of the passengers. This person was twenty-two years of age, of a sandy complexion, and pale, possessing that peculiar hysterical manner of looking vaguely about, and rolling the eyes while speaking; the lids, which were puffy, could not be closed over the eyeballs, except the eyes were previously pressed upon for a few minutes, with the palm of the hand; the conjunctivæ were unnaturally vascular, and the pupils rather dilated: vision was unimpaired. The whole of the thyroid gland was enlarged; the impulse of the heart was great, and the sounds loud, being audible over the entire chest, and in the large vessels; and a systolic venous murmur was perceptible. The pulse was very quick, but its habitual state could not be judged of, for whenever I saw her she became excited. The important part in the history of the case is, that the ophthalmic symptoms, those of the heart, and of the thyroid body, all appeared about the same time. A tonic plan of treatment was agreed upon and prescribed, but the result is unknown to me, for a fortnight after the patient ceased to attend. These particulars are parallel with all the cases I have seen, and with two which Dr. Quain has kindly given me from his case-book; they also agree with those of which I have read. It seems from the cases which are published, that the majority have been persons under thirty years old; but one mentioned by Dr. R. Mac Donnell, in vol. xxvii. of the "Dublin Journal," a male, of whom a colored representation is given, was fifty-five.

When first consulted by this anæmic class of persons, it is difficult to believe, and yet more difficult to convince them that, most probably, the heart is not diseased, which it certainly is not in the majority, perhaps never primarily; nevertheless Sir

Henry Marsh, to whom is due the honor of first publicly drawing attention to the coexistence of the cordal and the ophthalmic affections, exhibited to the Dublin Pathological Society, in January, 1841, a specimen of organic disease in this organ, taken from one of these individuals.

I am under the impression that Mr. Tyrrell occasionally alluded to the complication of prominent globes with enlargement of the thyroid gland. Indeed, I think I remember a particular example selected for the instruction of his pupils.

I have not seen complete recovery in any case of the anæmic disease in question; nearly all whom I have seen have been public patients, who have prematurely ceased their attendance; but I have learned that improvement does follow treatment, although it is generally irregular; that retrogradation is not uncommon, and that cure is always remote. However, Dr. Begbie's paper contains several reports of successful cases, and I shall copy the chief particulars of the first, which is very valuable from its completeness.

A lady, thirty-two years old, who had previously been healthy, suffered from mental distress, and a profuse leucorrhœa, which induced anæmic symptoms, including protrusion of the eyeballs and enlargement of the thyroid gland. The inordinate pulsation of the heart was greatly increased by exertion, or by any cause that hurried the circulation, on which occasions the face flushed, and the protruded eyes felt distended. Vision was unimpaired. The pulse ranged from 100 to 130, and was small and jerking. There was breathlessness, frequent faintings, headache, vertigo, and tinnitus aurium. The ventricular contraction was prolonged and attended by a soft bellows murmur at the aortic orifice, and a corresponding bruit was discernible in the carotid and other large arteries. There was indigestion, and the catamenia were scanty and irregular. She had been bled and mercurialized, and had taken digitalis along with other medicines. Dr. Begbie's treatment comprised large doses of carbonate of iron with gentle aloetic purges; a full diet of animal food; sea air, and regular gentle out-door exercise. The health improved, the leucorrhœa

subsided, the eyes retracted, the cheeks regained a proper hue, and the heart recovered its natural movements. The author dwells on the necessity of long perseverance in the iron, remarking that it may for a time be discontinued, but must again be resorted to. If a choice of the preparations of this metal be allowed, I should prefer almost any to the carbonate. The elegant formulæ of iron just now in fashion are well known, equally efficient, and less disagreeable to take.

Of the actual nature of the change in the orbit causing the protrusion we are certainly ignorant. It has been attributed to inflammatory swelling of the orbital contents, not sufficiently active to produce suppuration, or to cause effusion into the orbital cellular texture; to venous congestion; and to loss of tonicity in the orbital muscles, so that the globes, as it were, drop forwards. The last is, perhaps, the least likely of all these unlikely things. There is not any loss of voluntary power, which I think would be inevitable, were there loss of tonicity of the orbital muscles; and the freest movements of the eyes may be combined with the greatest protrusion. Again, in the most debilitating diseases, with perfect muscular prostration, the eyeballs do not protrude. I do not see how there could exist venous congestion to such an extent as to protrude the eye, without some evidence of it about the conjunctiva and the sclerotica, and that is not generally present. Moreover, such a cause would bulge the lid rather than the globe, as it would be between the cellular sheath of the eye and the orbit. But at present all is mere guess-work. I am more disposed to attribute the cause to effusion into the ocular sheath than to any other yet suggested.*

* That the displacement is not owing to effusion within the ocular capsule, Dr. Mackenzie thinks is evident from the freedom of motion which the eyes possess in their protruded state, and we may further remark that, so far as we are informed, no reduction has followed an exploratory puncture made to determine its etiology; though the instrument, being guided by no definite pathological aim, may possibly not have penetrated the sheath. He is inclined to consider varicosity of the ophthalmic veins as the most probable cause of the protrusion, and this view would seem to be confirmed by the slow progress of im-

The knowledge which we possess on orbital affections, from the investigations of the anatomy of the contents of the orbit by Dr. O'Ferrall, goes far to assist in the diagnosis of the causes that protrude the eye; but it remains for me to mention, that the anatomy of the lid also is subservient to this end. Dr. O'Ferrall shows that under the orbicularis muscle is a distinct layer of fascia which covers the lid, and is the first element of the lid that enters the orbit; that there is another layer of fascia beneath the levator palpebræ, which also enters the orbit, and uniting with that above, forms a sheath for the accommodation and support of the muscle; and he points out the attachment of the cellular sheath to the orbital margin of the tarsal cartilages. This anatomical arrangement he then traces on the outer surface of the eyelid in the two portions separated by the fold, the upper portion constituting about one-third of the surface of the lid, the lower the remaining two-thirds; from which he makes the pathological deduction, that certain forms of disease within the orbit that are seated either in, or internal to the motor apparatus—that is, in the substance of, or within the cavity of the ocular sheath—extend their effects to the lower portion of the eyelid with which they are continuous, and that certain other affections situated external to the motor apparatus—which is, that part of the orbit containing the fat—will show themselves by inflammation or other changes in the upper division of the lid. A short notice of some of his cases in exemplification will add value to these original anatomical and pathological hints, and I shall give concisely the particulars of one of protrusion of the eyeball from rheumatic inflammation of the ocular sheath. A man, thirty-two years old, had violent inflammation, and considerable protrusion of the right eye; the cornea and iris seemed healthy, but vision was confused; the conjunctiva was chemosed, but not vas-

provement under treatment. An obvious indication is the restoration of the general health. We have been repeatedly consulted in cases of exophthalmus occurring in anæmic females, and have always observed gradual melioration to follow such measures as tended to cheer the mind and invigorate the system.—Ed.

cular; the lids were swollen and red, the upper one dusky with distended veins, and the lower part of it so much tumefied that the cilia appeared to grow at an unusual distance from each other, and its transverse diameter was considerably increased. From the superciliary ridge to the inflamed portion of the eyelid, there was an interval about half an inch deep along the whole breadth of the lid, where there was neither redness nor swelling. There was agonising pain in the eyeball, and while a little moderate pressure of the palm of the hand against the whole tumor gave some relief, the patient could not bear pressure by the finger of any other person, except when made gently on that portion of the palpebræ which has been described as being free from redness, and then slowly and not suddenly so as to shake the whole lid, and provided it was in a direction upwards towards the roof of the orbit. The report then shows that there had been a severe attack of rheumatism: loss of blood from the temporal artery, with calomel and opium, cured the ocular and general disease.

In another case of rheumatic inflammation of the sheath, both eyes were consecutively affected. The right eye, the first attacked, protruded three-quarters of an inch, and looked bright in the midst of an amber-colored chemosis, without vascularity. The upper lid was of the dusky color and tawny appearance of that in the above case, and as in it the orbital portion did not participate in the change—the two portions being separated by a very abrupt line of demarcation—pressure upon the upper division was not followed by pain. The second eye was invaded in precisely the same manner. Both were cured by the iodide of potass. Other parallel cases had been met with; and the following practical comment, which does not admit of condensation, is appended to Dr. O'Ferrall's valuable cases.

“Protrusion of the eyeball, which, when attempted to be explained by uncomplicated periostitis, requires some stretch of imagination, appears a very simple and inevitable result of inflammation of the tunica vaginalis oculi. There are here no soft parts to receive and divide the pressure or protect the globe.

The tunic is supported by other fibrous layers on its outside, as well as by the muscles, of which they constitute the sheaths. Inflammation of this capsule must then be immediately followed by pressure; and when we recollect its conical form, and that, as happens in the case of inflammation of other fibrous tissues, effusion at once takes place into the cellular membrane connecting it to the ball of the eye, we perceive there is nothing to prevent the dislocation of the latter.

“This effusion into the cellular tissue will make itself evident in another way. The conjunctiva at the place where it forms the fold, in being reflected from the eyelid to the eye, closes up the tunica vaginalis in front. At this point it will not only receive the pressure of the effused serum, but will become separated from its connexion with the sclerotic coat, by the extension of the infiltration; hence the amber-colored chemosis without vascularity of the conjunctiva. Chemosis originating in conjunctivitis, always presents, in addition to serous infiltration beneath, one or other of the forms of hyperæmia. The chemosis of which we treat is, in uncomplicated cases, the consequence of effusion from a deeper source. I can easily imagine the extension of inflammation from the fibrous structures of the lid to its conjunctival surface, and thence to the sclerotic conjunctiva; but this complication did not occur in the cases which I have related.

“The limitation of the redness and swelling to the lower two-thirds of the superior palpebra, is also a symptom inconsistent with the notion of mere periostitis, but which admits of an easy and natural explanation when the anatomy of the parts is clearly understood. The fibrous tissues of the upper eyelid, which we have traced into the orbit, belong to that portion only of the lid which is below the fold in the skin, or to its inferior two-thirds. The inflammation of the internal parts, being propagated to those portions of the lid alone, with which they are continuous, is, therefore, only manifested there, and thus becomes an additional aid to diagnosis. If the inflammation had possession of the general cellular tissues of the orbit, there is no reason to

suppose that the upper third of the lid, which corresponds to the part of the cavity where fat and cellular tissue most abound, should not exhibit its effects. If the disease were confined to the periosteum alone, it is, in fact, this upper portion of the palpebra which ought principally, if not solely, to give evidence of its existence.

"When pressure on this uninflamed portion of the palpebra, directed upwards towards the roof of the orbit, is not productive of pain, there can be no hesitation in deciding that the periosteum of the parietes is free from the disease. Should this experiment increase the patient's suffering, it would be a reason for supposing that the mischief had extended in that direction.

"In distinguishing those cases, I would not be supposed to mean, that inflammation of this tunic is disease apart and never combined with a similar condition of the periosteum or cellular tissue on the one hand, or inflammation of the eyeball itself on the other. I am aware they may exist together, for I have seen such cases. All I mean to assert is, that inflammation of the tunic described may be the primary affection, and the point of departure from which the diseased action may spread to the other fibrous layers in the orbit, and finally reach the periosteum; and that the attack may even be limited to the tunica vaginalis oculi—that it may here produce a train of symptoms of the most dangerous kind, and which have been hitherto supposed to reside in the periosteum, because the existence of other fibrous membranes in the cavity was not suspected. Presuming that there were no other tissues in the orbit to which to attribute the disease, practitioners naturally referred the majority of cases to one or other of those with which they were acquainted. The solution of such cases would have been less difficult if our clinical researches were based upon a more correct knowledge of the structures actually existing in the orbit."

This reasoning and research render lucid many of the heretofore anomalous cases given by authors, and several that have occurred to myself; some appearing after fever, or erysipelas, or other constitutional disturbance. An interesting girl of thirteen

was brought to me with slight protrusion of one eye, with the single accompanying symptom of slight chemosis of the conjunctiva, which had a dirty white metallic-like aspect, without a trace of vascularity. I watched the case for months, scarcely adopting any treatment, for no particular plan was indicated; that there was effusion in the ocular sheath can scarcely be doubted. In another instance with protrusion, the lower half of the conjunctiva was chemosed without vascularity. In a third the globe projected, with a sudden elevation of the conjunctiva, by serum, on the outer side of the cornea.

Prominence of the globe, with immobility, does not appear to have been understood till Dr. O'Ferrall revolutionized our diagnosis; and a case of this, styled by him adhesion of the tunica vaginalis—by which is meant the adhesion of the ocular sheath to the globe of the eye from inflammation—at once conveys the probably correct pathological state. Protrusion and violent inflammation of the eye with distracting pain, immovable and dilated, but regular pupil, imperfect vision, a tumid and slightly œdematous upper eyelid, and a motionless globe, were the symptoms. The immobility remained after the other symptoms had nearly passed away. Dr. O'Ferrall imagines that the real cause of such symptoms is adhesion of the sheath to the globe, as well as the consolidation of the several other fibrous layers which envelope it and form the thecæ of the muscles; and moreover, that the adhesion may be supposed to be accompanied by abnormal union of the tendons of the muscles to the edges of the openings through which they pass, the ocular movements being thereby impeded in proportion as the usual gliding motion of the parts is destroyed.*

An abscess may form within the ocular sheath, and the symp-

* For the coexistence of prominence of the globe with immobility of that organ it is not necessary that there should be adhesion of the ocular sheath to the sclerotica. This conjunction is frequently the result of effusion merely; and Dr. Mackenzie states, that he has witnessed the immediate removal of the protrusion, and restoration of the motion of the eyeball, by puncturing the capsule.—Ed.

toms would be, protrusion of the globe, and pouting or swelling externally between the lid and the eyeball. A lady had protrusion of the globe, with intense suffering and general symptoms of the formation of matter; several medical men were consulted, and more than once a puncture was made deep into the orbit, but ineffectually. The lancet seemed to have been directed away from the globe to avoid injury to it, or to the parts around. Her almost insupportable state and the loss of sight, induced the medical advisers to talk of extirpation; but Dr. Farre, who was now consulted, directed that a lancet should be passed through the distended conjunctiva by the side of the globe. A large quantity of pus flowed out, and in a few weeks the eye was perfectly restored. Experience of like cases led no doubt to a correct diagnosis.

Abscess may form in the orbital cavity without the ocular sheath, and whether acute, subacute, or chronic suppuration ensue, the physical characters will be the same, namely, the bulging of the orbital portion of the lid corresponding to the seat of the suppuration. The formation of pus is, according to my experience, a common orbital affection; and when, with protrusion, there are the usual constitutional symptoms attendant on abscess, the pain, with or without movement of the globe, the redness and puffiness of the lid, and the throbbing, we should early endeavor to discover fluctuation by an exploratory puncture, made, if practicable, within the lids, in the probable direction of the abscess.

In vol. ii. of the "Dublin Hospital Gazette," Dr. O'Ferrall gives a case of subacute orbital abscess, with depression of the globe without any appreciable protrusion, which he deems dependant upon the limitation of the abscess posteriorly by adhesive inflammation.

Mr. Tyrrell has narrated a case which illustrates a marked degree of vascular disturbance attendant on inflammation and abscess within the orbit. Symptoms of acute inflammation, with great protrusion of the palpebræ and globe of the eye, induced preparation to be made for the evacuation of pus, when it was

discovered that so strong a pulsation pervaded the whole swelling, even moving the eyeball, that the presence of an aneurism was suspected; but reviewing the history of the case, a different opinion prevailed, and it was decided that a small puncture should be made between the globe and lower eyelid, which was done by Mr. Scott, and the result was an immediate escape of blood, of an arterial character, in jets corresponding to the pulsatory movement of the swelling, which was synchronous with the pulse. Pressure stopped this, and when the compress was removed a day or two after, from the pain it occasioned, there was a free discharge of matter, and all the symptoms were greatly mitigated. A free incision was the proper treatment when mere phlegmonous disease was diagnosed, and would no doubt have at once evacuated the pent-up pus.

The inflammation may not run on to suppuration; and protrusion of the globe, with more or less chemosis, may exist as the physical symptoms; this is, I think, a more common affection than is supposed. I had lately under my care a child of two years old, with very marked circumscribed inflammation in the orbit, the upper part, to all appearance, alone suffering. The following illustration was taken when I first saw the child; it

Fig. 104.



gives the idea of chemosis of both lids, a state that I thought existed, till a careful examination proved that the upper lid only was affected; the groove in the swelling answers to the spot of

reflection of the conjunctiva from the globe to the upper tarsal cartilage. The poor child being most rebellious, chloroform was administered in order to examine the disease carefully, and to adopt any surgical measure that might be deemed requisite. The eyeball was slightly prominent, and the lower lid only slightly inflamed; attempts to reduce the tumor, and to keep the lid over it were fruitless, and no surgical operation, beyond a few incisions, was considered justifiable; excision of any part would probably have been ultimately followed by entropium.

Inflammation of the periosteum of the orbit, which must, I presume, be always more or less combined with inflammation of the bones, may protrude the globe; and although such disease may follow traumatic injury, constitutional causes, such as struma, and syphilis in particular, generally produce it; but whichever it may be, the diagnosis is seldom obscure, if proper investigations be instituted.

Disease of the optic nerve has been a cause of protrusion, as Böhm, of Berlin, observed in dissecting a young man who died of phthisis. Here a tumor on the optic nerve, of the size and shape of an olive, just a little behind the sclerotica, and consisting principally of thickened neurilemma, the nerve-tubes being unaltered, had displaced the eyeball upwards and outwards, and nearly destroyed vision.

PROTRUSION FROM CAUSES EXTERNAL TO THE ORBIT, INCLUDING MORBID CHANGES IN THE CRANIUM, ZYGOMATIC FOSSA, MAXILARY SINUS, NASAL FOSSA, AND SPHÆNOIDAL SINUS.

Protrusion arising from pressure external to the orbit is apt to be overlooked, unless the surgeon is aware of the probability of the occurrence, and the sources from whence the pressure may arise. The position of the orbit exposes it to encroachment on all sides. Diseases of each of the cavities and sinuses around may reduce its capacity, and protrude the eye. The most com-

mon example for a cerebral cause is to be found in chronic hydrocephalus : the roof of the orbit is pressed down, and the depth of the cavity much lessened. The cause is here at once palpable, and so are most of the disturbing cranial influences. Cerebral tumors may protrude the eye, and other changes in the cranium may displace it, as the following example shows. A thief jumping out of a window to escape detection, fractured his skull just above the left orbit; probably damaging the frontal sinus. A portion of the frontal bone which was loose, was removed; suppuration ensued, and there was a discharge of pus for a year. The eye protruded to about three-quarters of an inch beyond its fellow, and was in that state when I saw the man, six years after the accident. Vision was unaffected.

Where the physical causes, although cerebral, are less marked, and their seat is not perceptible, headache, loss of memory, fits, partial paralysis, or other indication of lesion in the great nervous mass, with the previous history of the case, will generally determine them.

I have met with an example of suppuration in the frontal sinus producing protrusion; distension with elasticity of the bone over the abscess declared its seat, and evacuation of the pus remedied all disturbance. Writers speak of hydatid and encysted tumors and polypi being found in these sinuses; but Dr. Mackenzie, in his extensive literary research on this matter, which I may safely assert has never been equalled, has not met with the particulars of any case in which a polypus was found in either of them, without the same disease existing in the neighboring cavities. This is a fact well worthy of remembrance, and its importance would not be much lessened by one or two exceptions.

I have seen an exostosis that appeared to have its origin in some part of the temporal or zygomatic fossa, throw the eye forwards; this is the only instance I know, of disturbance from this quarter.

The maxillary sinus or antrum of Highmore, is the seat of the

most frequent external cause of displacement, for it is frequently diseased, and a tumor of any magnitude, having its seat here, can scarcely fail to throw up the orbital floor sufficiently to affect the eye, and such a cause could rarely be occult; distension in some other direction, and some collateral symptom would coexist and determine it, and it matters not what may be the nature of the tumor, whether aneurism by anastomosis, polypus, or other soft growths of a mild, or of a cancerous nature, simple exostosis, or malignant affection of the bones,—all of these have been met with. Suppuration, however, may greatly enlarge the maxillary sinus, which in the natural state is very small, without throwing up the orbital boundary. I have met with several examples of this, and the most remarkable was in a patient in private, submitted to me for opinion in the spring of this year, by Mr. Coulson. The orbital, palatine, and nasal sides did not bulge, the expansion being externally, anteriorly, and posteriorly. An aperture was made by Mr. Coulson through the distended bone in front, and so great was the cavity, that my fore-finger could but just reach the back wall.

Simple accumulation of mucus has been known to distend the antrum and to displace the eye.

Nasal tumors, and I allude especially to polypi, could not advance and injure the orbit without detection: a careful examination of the nose would always render the cause apparent. Obstruction of the lachrymal tube, too, would surely usher in such intrusion. In treating of obstruction of this conduit, I gave an example of both nostrils being blocked up by polypus, and each lachrymal tube temporarily destroyed, page 194.

Notwithstanding that I cannot advance any instance of protrusion of the globe from a distended sphenoidal sinus, I would wish to impress the possibility of the occurrence; for the anatomical arrangement of the parts readily admits of it.*

* A melancholy case of this kind occurred in our practice many years ago, and was published at the time in the *Medical Intelligencer*, edited by Dr. Dunglison. Amaurosis was one of the earlier symptoms, and pain in the head indicated the cerebral origin of the complaint. Protrusion of the eyeballs fol-

THE POSITION OF THE EYEBALL A MEANS OF DETERMINING THE NATURE AND THE SITUATION OF THE CAUSE OF PROTRUSION.

In obscure cases of prominent globes, where there is not any indication to be gathered from the state of the lids, the direction of the protrusion might somewhat assist in diagnosing the nature of the cause by localizing it more certainly; still that evidence may be as frequently negative as positive, and in no instance can it be solely relied on, because of the irregularity in form and unequal development of morbid growths. I have mentioned in narrating the case of an enlarged lachrymal gland, that a posterior and smaller process went back far in the orbit, and would have pushed out the eye, but for an anterior portion, which was still larger, and thrust it back.

In estimating the value of doubtful physical signs, the dissimilar axes of the eyeballs and of the orbits demand attention; while the manner in which the globe is tied by the oblique muscles, and the anatomical relations of the optic nerve, will influence the direction it will assume from pressure posteriorly. Displacement of the globe inwards is more readily effected than in any other direction. When from the commencement the dis-

placed, and gradually proceeded to almost complete displacement. The brain became further implicated in the progress of the malady, and after lingering through several months, a pitiable object of human wretchedness, the patient expired about a year from its commencement. The autopsy revealed a morbid growth of irregular form, projecting from the body of the sphenoid for the space of an inch or more, into the sulcus, between the anterior and middle lobes of the brain, as far, on the right side, as the petrous portion of the temporal bone, to the surface of which it was closely adherent; occupying the sphenoidal and ethmoidal cells; filling up the posterior part of both orbits; and extending downwards to the floor of the nostrils. The delicate lamina of the ethmoid, still further attenuated by absorption, were situated in the middle of the tumor, and entirely involved by it; the cribriform plate was absorbed in its posterior margin to a considerable extent, as were likewise the orbital processes; the whole presenting a sharp, jagged, and irregular outline. The tumor was of various consistence: above, where it encroached upon the brain, it was of a semi-cartilaginous hardness; in its central division, it assumed more of a medullary character; and in the lower nasal passages, covered by epithelium, its appearance was not unlike that of a polypous excrescence. The patient was an Irishman, thirty years of age, and had been addicted to onanism.—Ed.

placement is lateral to the axis of the eyeball, it is reasonable to presume that the force also is lateral. Direct protrusion will, in general, prove the most embarrassing; for with bony and other growths at the side of the orbit, within certain limits of size, and situated rather posteriorly, the eyeball may be pushed forwards without any lateral displacement; this, I presume, must be attributed to the mechanical properties of the fat in the orbit. Yet if the only symptom be direct protrusion, until further evidence to the contrary, the cause must be considered to be seated at the back of the orbit; I will not say the apex, for that is indeed a very rare position.

FOCAL RANGE SUPPOSED TO BE SUBSERVIENT TO DIAGNOSIS OF THE POSITION OF AN ORBITAL TUMOR. STATE OF PUPIL IN PROTRUDED EYES. DISTINCTION BETWEEN MERE PROTRUSION OF AN EYE AND AN ENLARGED EYEBALL.

It has been supposed that an attention to the focal range may assist in ascertaining the position of pressure on the globe of the eye, the theory being, that if behind, the antero-posterior diameter will be lessened, and the range be shortened; if at the side, it will, on the contrary, be lengthened. I question the practical application of this; the imperfection of sight has, in all the cases that I have seen, resulted from decided loss of power in the retina.

With the greatest protrusion the pupil may be natural; but it may be dilated and movable, dilated and fixed, or of its natural size and motionless. I am not aware that any practical indication can be gathered from any of its assumed states.

A protruded eye is frequently mistaken for an enlarged globe, an error very excusable in the inexperienced. Congenital enlargement of the globe has been met with, but very rarely, and while the proportions of all parts remain the same, the greater absolute magnitude is very apparent. Enlargement from disease always carries the evidence of diseased action, if not in the altered form of the cornea, or in the increased size of the chambers of the eye from greater aqueous secretion, certainly in the bulging

and altered color of the sclerotica. With moderate knowledge of the subject, and a little care, a mistake is unlikely to occur.

Dr. J. O'Beirne, of Dublin, has written on the diagnosis of these two states in vol. xviii. of the "Dublin Journal," and the conclusion he arrives at is, that in mere protrusion of the eye without distinction of causes, the upper lid covers the eye, and hangs down lower than usual, is more or less paralytic and puffed, with its surface generally of a dusky red color, and traversed by large veins. On the other hand, in actual enlargement, the eye is remarkably uncovered, and presents a staring appearance, while the upper eyelid is merely pushed forward and retained in that position, but is in other respects unchanged.

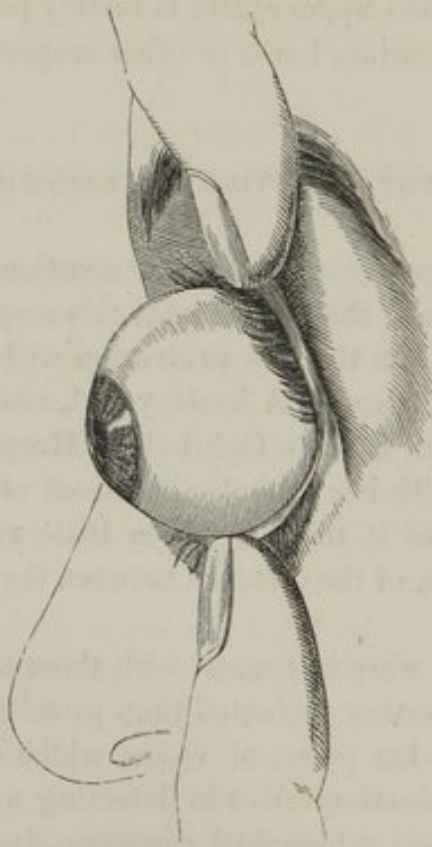
CASES NOT ADMITTING OF CLASSIFICATION.

The causes of protrusion heretofore mentioned do not embrace all that may protrude the eye, at least this seems to be the legitimate conclusion when there is protrusion without the apparent presence of any of them. A healthy girl, twelve years old, applied at the Central London Ophthalmic Hospital, in the course of the last year, with her eyeball almost out of its orbit. In the subjoined sketch of it the lids are a little retracted, to give a more adequate idea of the distance between the front of the globe and the orbit.

The movements were in concert with those of its fellow, which was natural, and rather retracted than prominent. Great pains were taken to test her power of vision, which was perfect. The most careful examination failed in detecting any other symptom than the prominence, which had commenced a year before, and gradually progressed. Mercury was tried, but in vain, and no success attended the use of iron and other tonics. Slight pressure was adopted for a time, and at first seemed beneficial, but ultimately proved to be inefficient; for in a day or two after remitting it the protrusion became as bad as before.

If there is any state justifying the suspicion of an increase of the orbital fat, unattended with changes in the vascular, nervous, and motor apparatus of the eye, surely this is it. Any dense substance at the apex of the orbit, large enough to protrude the eye, should, I presume, derange some of these structures that are so blended in that situation, and produce corresponding effects—pressure on the muscles and motor nerves, influencing motion, and pressure on the optic nerve, injuring vision.

Fig. 105.



Another remarkable, and perhaps unique, case of protrusion, that does not admit of classification, is related by Dr. Mackenzie. A man discovered that when he stooped forwards, if only for a few minutes, he had a sensation as if something was pressing

above his right eye, which immediately began to protrude, and when the head was raised, the protrusion was very striking, and he then saw indistinctly. The eye soon began to retire, and in a few minutes was replaced. There was not any loss of muscular power when the eye was in the natural position, and even when displaced he could move it considerably. The iris acted naturally. He complained of considerable pain in the orbit, which was removed by bleeding and purging. The peculiarity had existed for five years, and commenced after carrying a heavy load on the back.

CHAPTER XIII.

STAPHYLOMA.

STAPHYLOMA OF THE SCLEROTICA, AND OF THE CORNEA. GENERAL ENLARGEMENT OF THE EYEBALL WITH DISORGANIZATION.

THE term staphyloma is unhappily chosen, and is inadequate to express the two states of the eye that it is meant to include; for staphyloma of the cornea, and staphyloma of the sclerotica, are dissimilar.

When the cornea is destroyed in part or in whole, and its place supplied by a projecting opaque substance, there is said to be a staphyloma. Writers have described two forms, the globular and the conical, and employ besides the expression staphyloma racemosum when there are several projections, from their supposed resemblance to a bunch of black currants. The various appearances in form and color on the surface of staphylomata have been tediously detailed, but without any practical advantage, since nearly every individual case possesses dissimilar physical peculiarities.

Corneal staphyloma is the more common, is frequently caused by wounds from injuries or operations, may be said always to have a mechanical origin, and is the effect of a kind of natural repair. I receive Mr. Jones' explanation of its pathology as the correct one.

This excellent writer has clearly shown in a memoir published in the "London Medical Gazette," vol. xxi., page 847, that staphyloma is not a bulging of the cornea as is taught, and he explains its formation by pointing out that when the iris is partly

exposed by the loss of cornea, it becomes covered by an opaque firm tissue, the same as the tissue of a cicatrix, which is incorporated at the base of the tumor with the cornea, constituting a partial staphyloma, which consists of protruded iris covered by new tissue intended to supply the loss of corneal substance; and he remarks that the formation of a total staphyloma is precisely the same, the degree only differing, and the form of the tumor depending on the extent to which the cornea has been destroyed. This has been confirmed in a dissection by Mr. Bowman, the results of which are briefly given in his lectures on the parts concerned in the operations on the eye. The staphylomatous piece was unequal in thickness; the posterior surface to which the iris adhered, was irregularly pitted; the anterior surface was formed by a thickish coat of epithelium, somewhat resembling cuticle, being composed of eight or ten layers of cells, the deep ones globular, the superficial ones scaly, and more like epidermic cells than those of the healthy cornea; there was neither anterior nor posterior elastic lamina, and the entire remaining portion of structure consisted of a dense and most singular interweaving of white and yellow fibrous tissue, with imperfectly developed nuclei intermingled, and the meshes of the tissues, large, unequal, and open on all sides.

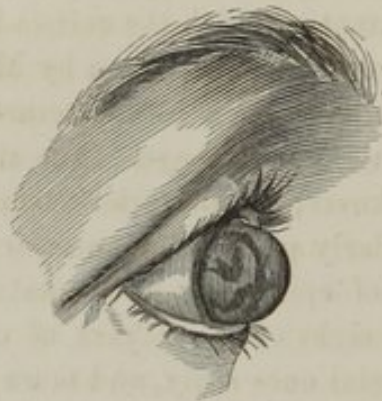Independently of the peculiar unsightliness of staphyloma corneæ, the inflammation which may be its result, or its sympathetic influence upon the other eye, may demand its reduction. These consequences, however, are not always in proportion to the size of a staphyloma, for some run their course, attain a great size, and burst, without having produced any uneasiness. Again, the pain of a staphyloma, which would seem to arise from mere distension, irrespective of bulk, may require the removal of the tumor.

Accompanying the staphylomatous state, there are occasionally changes in the crystalline lens, whereby it is ossified or rendered cretaceous; and although it is not possible to know when it is so changed, or to be able to refer with precision any set of symptoms to either of those alterations, proof is not wanting that a

calcareous lens is prejudicial, acting as a foreign body within the eye.

The physical characters of the affection in question are marked and unmistakable. The accompanying figure represents them well.

Fig. 106.



The individual in whom it occurred, aged sixty, received a wound of the cornea that was followed by prolapse of the iris: and when she came to me, six months after the accident, there was a small projection at the upper edge of the cornea, and the cornea itself was densely opaque and shrunken. I saw her again a year later, at which period the sketch was taken.

The greater opacity of some parts of the projection is well shown, and the ring around the base of the tumor represents a portion of the true cornea, which seems to have been gradually pushed aside by the new growth.

In complete staphyloma nothing short of the removal of a greater or lesser portion of the tumor will suffice to diminish its volume; and I believe that the period of operating is generally injuriously delayed; while by acting promptly and removing the staphyloma when small, the eyeball is less reduced than if the disease is allowed to grow large, when it necessarily demands a more extensive operation:—total collapse of the globe also may be thus prevented: and by an early operation the risk of unplea-

sant after-consequences from bleeding or suppuration is lessened, and the stump is better suited for a false eye.

As a rule, only the true staphylomatous portion of the tumor should be cut away, and every part of the corneal structure should be saved. Where the entire cornea has been lost, the excision should still be in front of the sclerotica; because there will be less bleeding, the operation is less severe, and the form of the eye is more likely to be preserved; although in so aggravated a case complete collapse is pretty certain.

The readiest mode of operating is for the operator to stand behind the patient and raise the upper lid; and after an assistant has transfixed the staphyloma with a curved needle, or seized it with a hook, to cut off the required portion with the scalpel. It may look neater for the operator to intrust the lids to an assistant, while he pierces the staphyloma; but then the assistant would, most likely, press too much on the globe, and squeeze out its contents. Care should be taken, in case the lens is in its place and healthy, to avoid injuring the capsule with the instrument that transfixes the staphyloma. I recommend this, because I am in the habit of leaving the lens: some surgeons, however, always remove it, under any condition, lest it should become the seat of calcareous matter; and if examples of such an occurrence can be adduced, the rule for the removal should be absolute. Nevertheless, my impression is, that after the irritation of the eye has been removed by the operation, all unhealthy action is at end, and the lens is not likely to become osseous or cretaceous, and I leave it as a sort of preventive to the escape of the vitreous humor; and that it may exert some such influence is proved by the following case, related by Mr. Brodhurst, in his work on the crystalline lens and cataract:—"Professor Jäger operated on a young person for staphyloma, but omitted to rupture the crystalline capsule. Cicatrization, however, proceeded, and the capsule played the part of the cornea, so that a very fair degree of sight was enjoyed. All parties were pleased, for the case advanced favorably, and with a probable issue totally opposed to that usually observed, for cicatrization appeared to be

now almost complete. However, the capsule of the lens was but a poor substitute for the cornea, and little able to resist pressure. Having dropped a needle on the floor, the girl immediately stooped to search for it, and straining her eye to compass so small an object, out flew the lens."

The loss of the entire contents of the eye would seem inevitable when a staphyloma is operated upon; but, unless the vitreous humor be unhealthy, this accident may generally be prevented by gentleness and delicacy of touch. The lids should be closed directly, and cold water applied, by means of bits of rag, for some time after, as a safeguard against bleeding, and the patient should be watched for several hours that such an occurrence may be promptly met, for it is prone to occur; and from neglect I have known a child nearly bleed to death. The operation is very painful, far exceeding what would be expected; and the collection of blood within the remaining tunics of the globe, over which we have no control, may cause prolonged suffering. All that can be done, besides the assiduous application of cold water and the observance of quiet, is to remove any protruding clots, or to cut them off on a level with the lids, and to employ opiates. The hyaloid membrane may hang out filled with blood, and the choroid and the retina have been found protruding, and encasing clots. With such after-consequences there is necessarily a collapse of the globe. Very active inflammation may follow the excision. In the case of a medical student, operated upon by Mr. Lawrence for staphyloma consequent on gonorrhœal ophthalmia, very acute suffering came on soon after the operation, and violent chemosis and purulent discharge ensued, with acute pain in the head and the eye. The case is instructive in showing, at least in this instance, the utter uselessness of the antiphlogistic plan to assuage the suffering, for Mr. Lawrence mentions that the patient was bled copiously, and other means of depletion were put in force; and although his diet had been low for some time before the operation, that these means did not diminish the pain, and it was necessary to give opium largely. I invariably give an opiate after operating; and should pain supervene, re-apply the cold, and repeat the narcotic. Suppuration is not a common

after-consequence, but does occasionally occur ; and whether pus form within the tunics, or around them, a free outlet should be early given to the matter.

The best after-precaution we can exercise against collapse of the globe, is to keep the patient confined to his room, with the lids closed till cicatrization has fairly set in. Eight to ten days may be considered about the maximum time required ; and to secure the constant closure of the lids, they had better always be retained together by a strip of some unirritating plaster.

The operation once well performed suffices, for the firm mottled cicatrix does not yield. Some exuberant granulations may arise, but they are not of consequence, for if they do not decline of themselves, the use of an astringent lotion, or the application of a mild escharotic, as the nitrate of silver, or red oxide of mercury, will reduce them.

A remarkable instance of the occurrence of sympathetic inflammation from staphyloma, and the good results of an operation, occurred in a child six years old, who had lost an eye from purulent ophthalmia. From that which was staphylomatous, there proceeded a constant purulent discharge. The other was so weak that ordinary light could not be borne, and the vision so imperfect that only large bodies could be distinguished ; yet in six weeks after I had removed the staphyloma, this eye had quite recovered ; the purulent discharge in the staphylomatous one ceased ; and, moreover, the health of the child, which had been bad, was much improved, and that without any medicine having been taken. The following case shows how long after the receipt of the original injury, the effects of a staphyloma may be manifested, and it would add interest to the particulars if it could be known whether the symptoms ensued on a staphyloma that had long existed, or whether the staphyloma had lately arisen ; the man's testimony is in favor of the latter, but his evidence was not sufficiently clear to be accepted.

Jonathan Wood, aged twenty, a patient at the Central London Ophthalmic Hospital, on the 20th of December, 1851, when five years old was wounded in the left eye with a pair of scissors, and

the sight at once destroyed. Until within about six months previous, the eye had been free from uneasiness; but then, the pain around the brow, deep-seated, and more severe at night, and the imperfection of the other eye which soon followed, incapacitated him from working at his trade of shoemaking. There was a small conical staphyloma, which, with the conjunctiva of that eye, was much inflamed. The staphyloma was removed, and the lens which was transparent left untouched. Notwithstanding that the patient imprudently left the hospital early, cicatrization was not interfered with, and in five weeks, he was again at work. The last note of the case was on the 20th of February, 1852, and to the effect that the cicatrix had contracted, and was quite firm. This sketch, which was taken at that period, shows how little the

Fig. 107.



globe was reduced, and that it was well suited for an enamel eye, of which he has since availed himself.

Mr. Wilde recommends, in the operation for a conical staphyloma engaging the cornea alone, that we should pass a thread through the base of the cone, in order that, after the operation, the lips of the wound may be brought together, and the escape of the vitreous humor be prevented. Mr. Browne, of Belfast, also advises the same practice.

I have said that irritation of an altered lens could not, with staphyloma, be positively diagnosed; yet the fact of such an exciting cause sometimes existing is certain. The following case occurred under Mr. Tyrrell, at Moorsfield Ophthalmic Hospital, while I was acting house-surgeon. A cook, thirty years old, was

burnt in her eye by some boiling lard; a moderate-sized staphyloma followed, and remained for years without any inconvenience; then on a sudden, and without any perceptible cause, intolerable pain ensued. The staphyloma was removed; and the lens, which was black, very hard, and apparently consisting of earthy matter escaped; an analysis was not made of it, nor do I know the true nature of its change; but I have little doubt that it had been suddenly detached, or partially thrown from its position, in consequence of which it acted as a foreign body.

When a staphyloma is partial, and the part of the cornea that remains is clear enough for the transmission of light, although the pupil must always be displaced and irregular, and vision imperfect, a modified treatment may, it is said, be advantageously adopted; and it has been proposed thus to endeavor to rescue the eye, and prevent the further implication of the organ and the obliteration of whatever pupil may exist, by rendering the staphyloma stationary. Escharotics are the means recommended, the principle being to induce a certain degree of inflammation, and thereby a thickening and contraction of the prominent mass. There should be a proper selection of the true staphylomata for this; as the method could scarcely be expected to benefit an irregular prominence of the cornea from the yielding of its texture, consequent on pus having been deposited between its layers, or partial slough from any cause. I have not myself witnessed any satisfactory results, and am acquainted with a few instances in which the treatment did harm in increasing the corneal opacity; but as Mr. Tyrrell, in his ophthalmic work, gives very decided testimony in its favor, I feel it incumbent to notice his remarks, which I do in his own words:—

“I have succeeded, in several instances, in effecting a reduction of partial staphyloma, by the careful application of nitrate of silver, or hydrate of potash in substance: and have applied the escharotic first, at the base of the projection, taking care not to injure the remaining sound portion of the cornea—the effect has been the separation of a small slough; but previously to such separation, a deposit of fibrin beneath, by which the deeper part

has become more solid and strengthened; after the part has recovered from an application, I have made a second close to, but not upon the same spot, and nearer to the summit of the projection: again and again I have repeated this operation, acting upon the more prominent part, until a considerable or perfect reduction of the staphyloma has been accomplished; and this has enabled me, in a few cases, to form an artificial pupil subsequently, of much more utility to the patient. I prefer the hydrate of potash, unless the projection be very small: for its use is followed by a much larger deposit of fibrin, than results from the nitrate of silver."

If a partial staphyloma produce any of the deleterious effects of a total one, in which case there is almost a certainty that vision is lost, and if there is no possibility of reducing it by the means above described, it must be removed; and as in total staphyloma, a timely operation may render the globe more fitted for an artificial eye. The following case is an example of such treatment. A child lost an eye from purulent ophthalmia; nine months after, a small and well-defined staphyloma stood out in bold relief from the centre of an opaque and somewhat irregular cornea. A month's watching assured me of its increase, and I shaved it off: the wound healed with a firm cicatrix, which was sound when I last saw the girl—eighteen months after—and the globe was but little reduced.

Singularly enough an artificial pupil has been formed, by the increase of a partial staphyloma; the iris having been torn away from its ciliary connexion by the expanding growth. A notice of such a case, with a drawing, is in Mr. Dalrymple's work on the "Pathology of the Human Eye." The pupil happened to be formed opposite to a transparent part of the cornea.

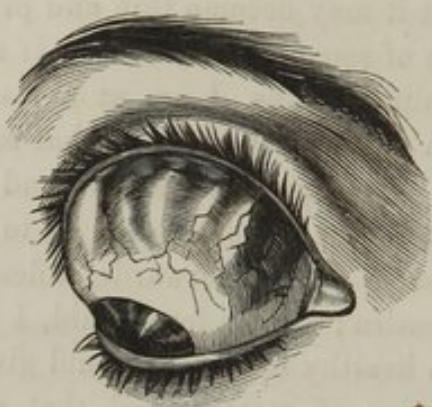Staphyloma of the sclerotica signifies an irregular distension of the sclerotic coat, in any part of its extent, but the most usual seat of enlargement is at a little distance around the cornea, nearly in correspondence with the ciliary body. The dark blue color of these projections renders them very conspicuous. Unlike staphyloma of the cornea, several tumors generally exist;

the cause also is wholly different. The sclerotica must be primarily at fault more commonly than is supposed, and its intimate structure must frequently suffer in the general inflammation of the globe, which in most instances precedes this affection. Mr. Tyrrell states, that it may become thin and projecting, from varicose enlargement of some of its vessels. If it does not become weakened in certain portions, I am at a loss to account for a partial staphyloma under circumstances that must produce equable pressure on all parts; nor can I understand how a staphyloma is formed in a part of the eyeball posterior to the lens, without the lens and iris being pushed forwards, unless the fault be primarily in the sclerotica; for the lens would, I imagine, be thrust forwards, before a healthy sclerotica would give way. The spot at which the effusion of watery fluid that may accompany a staphyloma occurs, whether between the sclerotica and choroid, or choroid and retina, or in the vitreous humor, matters nothing, practically speaking; for, with much bulging of the sclerotica, vision is, I believe, always lost. I never met with a case in which it was not. The general invasion of disease destroys the eye; the cornea being the tunic that suffers the least. The fact of the staphylomata of the sclerotica being so commonly in correspondence with the position of the posterior chamber, has induced some pathologists to attribute their formation to an undue secretion of the aqueous humor. Perhaps it would be more correct to assign the bulging in that locality to the greater thinness of the sclerotica there, and the consequent greater liability of that part to suffer from disease; even then, we must suppose that some portions of that thinner part are affected and more weakened than the rest, or the yielding would be general around the globe, and not partial—an occurrence that I have not met with.*

* Preternatural adhesion between the sclerotica and choroid, the consequence of inflammation, is assigned by Dr. Mackenzie as the cause of their protrusion; and he very properly remarks that there seems to be no just ground for distinction between choroidal staphyloma as exhibited in figure 108, and the state represented in figure 109, and described as an increase in the size of the entire globe; the cornea being frequently enlarged and rendered semi-opaque in long-continued sclerotico-choroiditis involving the whole organ.—Ed.

The following illustration of the affection was taken from a patient who was sent to me by Mr. Hulme, of Gower Street.

Fig. 108.



The globe is directed downwards, and the lid elevated to give a more extended view. The staphylomata were very tense, and nearly confined to the upper portion of the globe. There was not any vision. The crystalline lens was absorbed, and its capsule floated in the posterior chamber. The iris was not thrown forward. The state of the vitreous humor could not be judged of, unless extreme tension of the globe be a criterion of its destruction, and replacement by a fluid—greater in amount. The history of the case is, that from infancy the eye was amaurotic, but in a quiet state until a scratch on the cornea from the finger of an infant, some four or five years of age, excited intense inflammation, on which the staphyloma supervened. Mr. Hulme was not applied to from any uneasiness in the eye, for that had long ceased, but from the deformity alone, which was on the increase.

Whatever be the call for treatment, whether pain from distension, irritation, or deformity, the course is to remove a part of the staphyloma, and thus to reduce the size of the globe. As it is very probable that the globe will collapse from the escape of its altered contents, it is well that this should be effected with the least possible sacrifice of the ocular coats; for although the

stump which is left never equals that which follows the removal of a staphyloma corneæ, still a sort of button may be preserved for the adaptation of an artificial eye. A slit in the staphyloma may be enough to evacuate the globe, but the more certain way of proceeding is to take hold of a projecting point of the tumor with the tenaculum forceps, prick it with the scalpel, let out some of the fluid to make it flaccid, and then to remove what may seem requisite: or it may be better to remove a part of the cornea in order to obtain a more symmetrical stump.

So far as my knowledge goes, decided benefit cannot be expected in staphyloma with disorganization of the eye, from the evacuation of watery fluid wherever accumulated. Unless the whole globe is thereby emptied it is a mere temporary measure, for the accumulation will be sure to recur unless suppuration ensue.*

I have not had any personal experience of the efficacy of lunar caustic, combined with pressure, as recommended by some foreign authors.

Although the treatment of staphyloma does not fall within the province of this work till circumstances arising out of its size call for operation, yet in this instance I introduce, without apology, an interesting fact mentioned by Mr. Tyrrell. A staphylomatous projection at the upper and outer part of the globe, near to the cornea, occurring in acute choroiditis, quite subsided, and left the sclerotica thin and slightly flaccid at the part where it had existed, under general treatment alone. The patient had distinct perception of light with that eye.

Staphyloma of both cornea and sclerotica may exist at the same time, and the double affection needs no special observation; but there is an increase in size of the entire globe, closely allied to it, for which an operation may be required, that does not come

* An aggravated case of this kind, on which we expected shortly to operate, was cured in a more summary manner, by a reckless blow inflicted by a drunken man on the patient who was entirely blind. Profuse hemorrhage occurred, and was followed by complete collapse of the globe.—Ed.

strictly under the head of staphyloma, but which may, I presume, be most appropriately considered in this place.

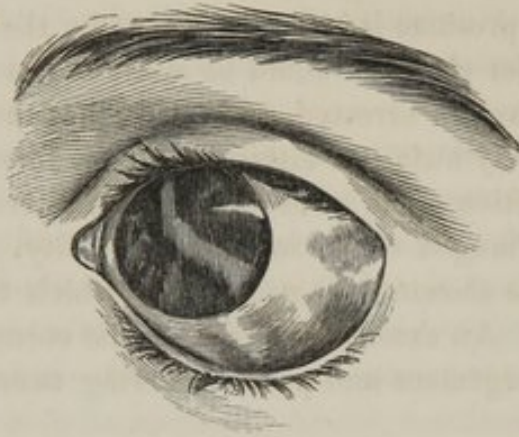In this affection the cornea is not lost, nor the iris covered by a plastic material; the former is generally enlarged, conical, and of a dark blue color; and the sclerotica does not generally yield in any one spot, but is uniformly distended in every part, with more or less loss of its whiteness, being dark blue or brown, or colored in spots. This state answers to what is called by systematic writers, dropsy of the globe or hydrophthalmia, and may be an idiopathic affection, in which case it is more frequently seen in strumous girls; or it may result from unhealthy action consequent on wounds. The choroid is now considered to be the tunic principally affected, hence the affection is said to arise from choroiditis; formerly the supposed origin was sclerotico-choroiditis. The fact is, that there is general inflammation of the whole eyeball, not one of its parts escaping, and each exhibiting changes which arise out of its peculiar organization.

The cornea generally suffers the least; its circumference alone may be opaque, and even though there be distension of the posterior part of the globe it may be but slightly influenced; perhaps only opaque, or both opaque and enlarged, or a part only may be thus changed, so that its implication is a matter of degree only. The demand for surgical aid may arise, as in true staphyloma of the cornea or sclerotica, from the great increase of the volume of the eye, and the consequent symptoms of irritation and sympathetic affection of the other eye; or what is more likely, from the mere pain, which is insupportable, and which seems to arise solely from distension; this result seems almost inevitable when the eye is much stretched, as is illustrated by the following example of the disease (Fig. 109).

The young woman from whom the drawing was taken received, at three years of age, an accidental blow from a beef bone thrown by her father, and sight was immediately lost. From the position and extent of the cicatrix on the cornea I conceive that the eye was burst. At fourteen the globe began to enlarge; it then became painful, and continued to increase and to ache for two

years, since which it has been stationary and nearly devoid of uneasiness. The cornea was enlarged and blue, except at the cicatrix, and the sclerotica generally enlarged with irregular dark

Fig. 109.



blue protrusions. The other eye was becoming sympathetically affected. The long interval in this case, between the receipt of injury and the enlargement, is remarkable.

Nothing, I believe, short of the evacuation of the contents of the globe, or the removal of some portion of its coats, can suffice to reduce an eye so affected, and remove the distressing symptoms that may arise.

In the first volume of the "Lancet" for 1850, Mr. Dixon has recorded some excellent examples of this affection occurring both from spontaneous inflammation, and as the result of wounds. A delicate boy, five years old, received a wound on the cornea; the iris prolapsed, and the lens and capsule became opaque. A little more than two years afterwards the whole globe was enlarged, and its forepart changed into a half-opaque, conical protuberance, of a dark bluish color. Five years later the eye was considerably larger, the cornea more nearly hemispherical, and its surface uneven from hypertrophy and vesication of the epithelium. The sclerotica was thinned and bluish in several places, and the eyeball had become very painful and unsightly. The central third of the cornea was cut off, and after various symp-

toms and consequences, that need not be detailed, the eye ultimately dwindled to a little less than the bulk of the sound one. Mr. Dixon remarks that the morbid changes which took place in the cornea itself, and in the chambers of the aqueous humor, appear the more unaccountable as the lens had undergone complete absorption. I presume it is inferred, that by the removal of the lens the posterior chamber would be more or less destroyed, and the aqueous secretion arrested. He adds that the pain seems to have been entirely owing to distension of the forepart of the eye from over-secretion of aqueous humor, the vitreous body being apparently unchanged either in bulk or quality. Another case is remarkable as showing the period over which the diseased action extended. An extensive wound of the cornea was followed by gradual enlargement and pain, occurring twenty-seven years later.

A female, thirty-seven years old, came under my care at the Central London Ophthalmic Hospital with inflammation of the whole eyeball of five months' standing. The globe was enlarged and the lens, which was opaque, was thrust against the hazy cornea which was just yielding at its circumference, where there was an ash-colored ring. Three months later there was considerable expansion at the circumference, and the cornea stood out almost square and greatly enlarged, and the sclerotica was now distended to a prodigious size and uniformly discolored.

Tapping the eye, with a broad needle, every two or three days, either through the cornea or posteriorly, with pressure by compress and bandage, has been recommended as likely to be serviceable in this enlargement of the globe, especially if done early; and its advantage is positively spoken of by some surgeons. I have not seen it afford the least benefit, except temporary relief from pain. In a few days, or weeks, there has been a re-accumulation of fluid and a return of the symptoms. In one case, after the second tapping, acute inflammation of the globe with suppuration, followed. In the young woman whose eye is represented at Fig. 109, this plan was fairly tried, and for a time was supposed to have been beneficial; but after the bandage had been

left off for a few days, and the vessels of the orbit had re-filled, it was evident that the globe had not been reduced. After this attempt I learned that another surgeon had tried pressure without tapping, for several weeks without any benefit. Dr. Mackenzie, however, speaks very confidently of curing a case of dropsy of the vitreous body resulting from an injury, in which the lens was opaque and displaced, by tapping repeatedly through the cornea.

Mr. Lawrence makes some very practical remarks concerning the nature of the distending medium in enlargement of the eyeball, expressing his inability, from the nature of the symptoms, to determine whether enlargement at the posterior part of the eye is caused by an effusion of watery fluid, or by an increase of the vitreous humor. In the only example of the increase of the vitreous body which he had seen, he did not discover the nature of the case till he had made a puncture behind the cornea for the purpose of lessening the size of the globe; in all the other instances of hydrophthalmia witnessed by him, the globe was distended with aqueous fluid. Hence he coincides with the following passage in Scarpa. "The generality of surgeons teach, that the immediate cause of the dropsy of the eye is sometimes the increase of the vitreous, at other times of the aqueous humor. In all the cases of dropsy of the eye, which I have operated upon, or have examined in the dead body, in different stages of the disease, I have constantly found the vitreous humor, accordingly as the disease was inveterate or recent, more or less disorganized, and in a state of dissolution; nor have I been able, in any instance, to distinguish, on account of the increased quantity, which of these two humors, vitreous or aqueous, had had the greater share in the formation of the disease." In two cases of enlargement of the globe after traumatic injury, in which I removed a part of the cornea, there was an increase of the vitreous humor; at least that seemed to be the state of the case, for vitreous fluid, apparently not in the least altered in consistence, filled the distended tunics.

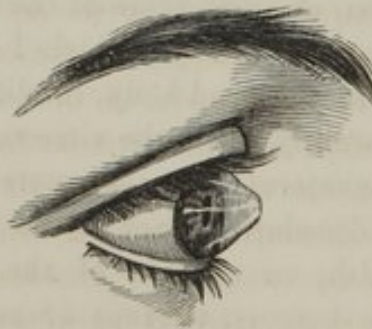CHAPTER XIV.

CONICAL CORNEA.

IN entering on the subject of Conical Cornea, I must confess my inability to suggest any practical measures for the cure of the distressing malady so denominated, which, in the present state of our knowledge, appears to be irremediable. However, the negative results of various experiments that have been made have their particular value, and these I shall give, according to the extent of my information, after speaking of the symptoms of the disease, and its physical peculiarities.

The first indication of the conical change, is short sight; im-

Fig. 110.



perfect vision follows, bodies are multiplied, or have zones around them, and the best sight is got by looking sideways; as the affection advances, the eye becomes quite useless. All this is very puzzling to the patient, who cannot discover any external alteration in his eye; even many surgeons, not particularly engaged in ophthalmic practice, fail to detect the earlier changes

in the cornea, which is not to be wondered at, for unless the eye be examined in profile, mere increase of lustre of the cornea is the only objective symptom. The appearance of the cornea when viewed sideways is as if a drop of water was placed on it. In exaggerated examples the cornea may become opaque at the summit, or dotted with opacity, or it may be ulcerated. The anterior chamber always looks augmented in proportion to the conical projection.

The preceding sketch was taken from an eye that was in an advanced stage; the cornea had not however lost any of its transparency.

It was long since pointed out by Sir David Brewster, that the cone is not quite regular, but more or less undulated; this is best shown by means of a lens.

The affection has been seen at birth, and has also occurred hereditarily; the slowness of its progress is striking, especially if bursting of the cornea be regarded as the necessary termination, for that may not happen in a long life, even when the disease commences in youth; yet I have more than once known it to occur before the fortieth year.

Both eyes are nearly always implicated, and the second is usually attacked after the abnormal change is well developed in the first, so that generally a long period intervenes.

It appears to me that we are in ignorance of any predisposing causes of this peculiar ocular change; it cannot be said that debility induces it, for it appears in the strong and robust; indeed, I have scarcely seen it except in healthy persons.

Regarding the direct cause, scarcely anything has been proved, and the opinions are very various. I have not been able to satisfy myself of any immediate preceding influence, in any instance of genuine conical cornea, in which there is nothing but the transparent central cone. Bulging of a part of the cornea, after partial ulceration or slough, should not be considered identical with the disease; neither should general increase in the convexity of the cornea, so common after inflammation of this part, and often I suspect regarded as conical cornea, whence the

supposed inflammatory origin; the form, however, is not pyramidal: there is mere increase in dimensions of the whole cornea. That there may sometimes be an approach to the pyramidal form I well know; indeed there may be, after corneitis with ulceration, a decided cone, but then there is more or less the appearance of staphyloma, and perhaps that state really exists. While I thus advance my own opinions, I do not ignore those of others to the contrary, attributing conical cornea to inflammation, and I willingly quote the following passage from Dr. Jacob's work on inflammation of the eyeball.

"The alteration in form is not always of the same shape. The surface is sometimes apparently spherical, sometimes an irregular spheroid, and sometimes projecting at one side more than another; but the most remarkable deviation is that wherein it becomes conical and acquires the peculiar form which in the sequel constitutes the very remarkable and singular result of disease called staphyloma pellucidum. I am prepared for a denial of the correctness of this statement, that the staphyloma pellucidum, or conical cornea, is owing to the disease under discussion, but I nevertheless venture to insist upon it, because I have seen and traced the change from its commencement to its termination more than once. That there should be doubt and difference of opinion on the subject is not surprising, because true corneitis is not a very common disease, and the change in shape to the conical is not a frequent consequence of it. The alteration takes place in childhood, for the disease generally occurs at that period of life; and after the inflammation has disappeared and the opacity has been dissipated, no defect, except this conical state, remains; which is not perceived until the young person is called on to apply the eyes to books, or to work requiring good sight. Then it is that the surgeon's attention is directed to the case, and he for the first time sees it, and, perhaps naturally enough, thinks that it is a disease in progress, and only recently commenced. Hence the difference of opinion respecting its nature, and the various speculations as to its origin. That I have seen the cornea become opaque from corneitis, then conical, and finally per-

fectly transparent, retaining its conical form, I am quite positive; but not only have I seen this, but also have I seen it become distinctly conical in a case of common idiopathic inflammation of the eyeball in a man of middle age, although not transparent or resembling the true *staphyloma pellucidum*."

We are still ignorant of the actual physical change which the cornea undergoes, for there has not yet been published, so far as I know, the result of a single careful and scientific dissection. The mass of evidence gathered from the superficial examinations that have been made goes to show that there is thinning of the substance of the cornea near the centre, and often an increase of thickness at the circumference. Whether other parts of the eye are also altered in form we are quite unaware.

I now approach the important topic of treatment, and I must deplore the barrenness of my own results; and happy should I be if the success of others could supply the desideratum. The discrepancy among authors as to the results of similar methods of treatment is certainly astonishing, and the more so as it relates to mechanical measures. Mr. Tyrrell tells us, in his practical work on the eye, that within the last six years, he has succeeded in giving relief to a considerable extent, by a plan so simple that he was surprised it has not been previously tried. It consists in altering the shape and position of the pupil, and removing it from beneath the centre of the cornea, or that part which has its figure most changed, to near the margin, where the least change has occurred. He performed this operation seven or eight times; in each case it benefited the vision, and in two cases considerably. No one besides Mr. Tyrrell has met with like success. I saw two cases that he operated on after the publication of his work, not only without the least benefit, but unfortunately with the disadvantage of adding to the confusion of vision. Many surgeons, encouraged by Mr. Tyrrell's writings, have followed his practice and failed.

Mr. Dalrymple, in his "Pathology of the Human Eye," gives his opinion on all operations for the disease in these words:—"Various have been the surgical measures for remedying this

deformity, and all with so little success as not to warrant us in the attempt to interfere by surgical means."

I have myself drawn the pupil sideways several times without the slightest benefit. In one of the cases the lens had been removed by the operation for solution under the hands of another surgeon. It is a physical impossibility that the loss of the lens can be attended with benefit, while the want of it may render vision worse, but I find that surgeons still persist in removing it.

Frequent evacuation of the aqueous humor has been tried more than any other operation, but the general testimony is against it. Desmarres, when speaking of tapping, says that if surgeons had joined to it a methodical, immediate, and long-continued compression, as he daily practises in opaque staphyloma, and as he has done with great advantage in two cases of transparent staphyloma, this method would perhaps have been followed with better results; he continues that, compression, which is thought by some practitioners to be dangerous and inefficacious, he, like Demours, has found, after long practice, to be of the greatest use in numerous cases. He has reason to think that those who blame it have never tried it, or if sometimes they have had recourse to it, that they have done so neither with perseverance nor method. For eighteen months he treated a little girl of eight years of age, whose right eye was lost in consequence of purulent ophthalmia, and in whose left there was an opaque staphyloma in the internal half; the cicatrix hardened daily, and the pupil, kept dilated by belladonna, was available on the outer side. Puncture of the cornea, followed by immediate compression, appears to him the best means actually known of treating this disease; but the compression ought to be light, accurately made, and kept up for a long period, and from time to time the centre of the tumor should be cauterized with nitrate of silver, and laudanum should be dropped into the eye.

Dilatation of the pupil I have known to confer benefit, but the advantage was lost when the cornea grew more prominent. I suspect that all the good a dislocated pupil is able to effect, may be got by dilatation with some of the preparations of belladonna.

Various appliances of art, optical and mechanical, have been tested, and I believe with better results than the means above enumerated. I was not a little pleased when, some years ago, I read this paragraph on conical cornea in Dr. Hull's work on the "Morbid Eye." "In as bad a case, as I ever saw, I have known most benefit received through an instrument made by a Mr. Abraham, an optician, in Bartlett Street, Bath. It is formed of two lenses, with an adjustment. The farthest and largest lens is convex. The lens near the eye is smaller and doubly concave." I immediately wrote to Mr. Abraham, but he had long been dead; his son, who has left Bath and carries on the same trade in Clifton, never heard of his father's ingenuity. Concave glasses will sometimes, in the incipient stage, afford relief: this I have witnessed.

The fact of a patient generally seeing better through a pin hole, from the reduction of the rays of light entering the eye, while the narrow aperture directs those that do enter, through the centre of the cornea, suggested the use of those diaphragms with small round apertures, or with slits of different forms and sizes, with which every optician of any repute is now acquainted. The diaphragm is affixed to a spectacle-frame, and an aperture is made in correspondence with that which has been found to suit best. Some opticians keep a kind of tryer in which the apertures may be graduated.

I believe that the adaptation of a concave glass behind one of these diaphragms, is rather of modern date, and I understand that several cases of conical cornea have been benefited by the contrivance, although several of my own patients, who have tried every variety of aperture, behind which was placed each number of both concave and convex glasses, have obtained no relief. The experiment is simple, and should always be adopted and conducted with great care and patience.

I have said nothing respecting the use of local applications simply because I have not the least faith in their potency, and cannot find sufficient authority for their recommendation.

Dr. Pickford's plan of emetics and purgatives ought not perhaps to be passed over, though I do not introduce it because I

can speak as to its results, for with them personally I am unacquainted; I mention it solely from the originality of his pathological theory, which I must confess is unintelligible to me. I have known of patients who have commenced, but could not possibly continue it; few persons, I am sure, would put sufficient faith in the remedy to submit to be vomited and purged daily for months in succession; most would discontinue their attendance before many weeks had passed over.

The following extract, which embodies his opinions and all his theory, is taken from his work.

"In conclusion, I may repeat, that I believe conical cornea to depend upon some disturbance in the function of the great sympathetic, spinal nerves, and par vagum; producing, through the medium of the lenticular ganglion and fifth pair of nerves, faulty action of the nutrient capillaries and absorbent vessels of the cornea itself: that emetics and purgatives, by the powerful influence they induce upon the gastric, associate, and consensual nerves, restore the healthy function of the weakened nutrient and absorbent vessels, the result of which is a slow but progressive retraction of the diseased corneal growth, and a consequent restoration of vision."

The treatment in one case was twenty-five grains of the sulphate of zinc early in the morning twice a week, afterwards repeated every morning. It is said that in six months the case was much relieved. In subsequent cases, purgatives were united. In one, the treatment was used daily for a year, and succeeded; however, the conical cornea returned, and a second cure was effected by the same means.*

* Thinning of the centre of the cornea appears to be the most common pathological alteration in this affection; and, though experience does not qualify us to express an opinion, we should suppose that the imperfect nutrition on which the attenuation probably depends, would be more rationally, if not more successfully, treated by the cod-liver oil, which has frequently been found useful in strumous corneitis and kindred diseases, than according to the plan quoted in the text. The complaint is more common in women than in men, and in young than in old persons; and it is only a few days since that we witnessed its coexistence in an anæmic female with the protracted irritation arising from inverted cilia.—Ed.

CHAPTER XV.

REMOVAL OF OPACITIES OF THE CORNEA BY OPERATION.
TRANSPLANTATION OF THE CORNEA.

THE ingenious proposal of restoring transparency to the cornea by removing that portion of its texture in which the opacity resides, is far from being of recent date, but the practice has been allowed to fall into oblivion, from a prevalent opinion that it could not be relied on. "The vulgar," writes Dr. Mackenzie, "have a notion that specks can be removed by operation, but by medical men that has generally been regarded as impossible. Mead, indeed (who wrote in 1762), speaks of paring specks every day with a knife; and Darwin (who wrote in 1801) of trephining them; while Dieffenbach has actually cut out a leucoma from the centre of the cornea, and brought the edges of the incision together with sutures. Notwithstanding such high authority, we may safely regard as generally impracticable any attempt to operate on specks of the cornea, except when the opacity is merely a crust of oxide or carbonate of lead deposited on the surface of an ulcer of the cornea, in consequence of a solution of acetate of lead having been employed as a collyrium. It sometimes happens that such a crust remains after the ulcer has cicatrized, and I have repeatedly succeeded in lifting it off with a sharp point of a probe, leaving the cornea beneath nebulous merely, and susceptible of clearing completely under the continued application of vinum opii."

Within a late period this operation of paring the cornea has been somewhat revived, and there has been even a controversy in the French capital concerning the priority of the claims to its

introduction. In the "London and Edinburgh Monthly Journal of Medical Science," for March 1844, is a memoir by Dr. R. Hamilton on this subject, in which it is stated that in the session 1833-4, Professor Rosas operated on two cases; in the one, the greater number of the layers of the cornea was taken away, and failure ensued; in the other, the external and opaque layers only were removed; the wound healed without opacity, and after six months the cornea was transparent. It appears, too, that in subsequent years the operation was performed without marked success. In 1841-2 Dr. Gulz drew public attention to the following case.

A tailor twenty-eight years of age, presented himself at the Vienna Clinic, under the care of Dr. Gulz, in the session of 1841-2, having been two years previously attacked with purulent ophthalmia. The left eye was staphylomatous. In the right, the external layers of the cornea had been more or less inflamed, ulcerated, or destroyed, and a whitish and opaque deposit was substituted in their place. There was ready discrimination between light and darkness. It was thought that the opacity did not extend through the whole depth of the cornea, and that the case was a fair one for slicing off the opaque portions. The operation was performed by Dr. Gulz, under the direction of M. Von Rosas, the instruments employed being the cataract knife of Rosas, with a double-cutting edge, and the pyramidal knife of Beer, together with a small-toothed forceps, and a delicate pair of scissors. The eyelids of the patient were fixed by the fingers of an assistant, and the knife, frequently introduced, was made to pass through the external layers, and gradually to the internal parts of the cornea, the hand following the motion of the eyeball. The manœuvre required to be repeatedly and adroitly performed, until the transparent part of the cornea was at length reached; when, by the help of the different instruments, it was bared to the extent of a line and a half in diameter, the innermost layers of the cornea being fortunately uninjured throughout; the anterior chamber was not opened. The operation occupied about a quarter of an hour, and after its completion vision

was improved to such an extent, that the patient could perceive different shades of colors, and small objects, such as the hands of a watch, with facility. The subsequent treatment consisted in the application of plasters over the eyelids to prevent their motion, and the application of cold and iced water. At the end of eight days the plasters were removed, and a collyrium first of a solution of hydrochlorate of potash (gr. 1 to the ounce), and subsequently of a solution of muriate of ammonia, was used. All went on promisingly for the first four weeks, after which the eye was attacked by ophthalmia, which was soon subdued, and in a few days, to the great joy of all parties, sight was found to be uninjured, and after a period of five months continued good. Near-sightedness was a result.

I learn from the same number of the "London and Edinburgh Journal," that Malgaigne has published a long and learned paper on the subject, in the "Journal de Chirurgie," in which he states, on the authority of Blandin, that a couple of travelling oculists in France have for fourteen years been in the habit of performing this operation with varying success, putting forth no claims to invention, but affirming that they only followed a practice which had been successful before their days. Two memoirs are alluded to, one by M. Rognetta, in "Les Annales de Thérapeutique," and one by M. Desmarres, in "Les Annales d'Oculistique." To Saint Ives is ascribed the first notice of the operation in medical records, and opinions laudatory and condemnatory of the practice are quoted. Baron Larrey thought it worth a trial, and believed that in opacities of the cornea of a certain degree of thickness, the membrane may be thinned down by repeated strokes of a long bistoury; he had performed the operation upon a young lady at Toulon, removing an old opacity which covered the whole extent of the cornea, and the patient ever after saw fairly.

I must warn those who are unaware of the almost incredible manner in which the cornea is capable of clearing by the natural process, not to attempt the removal of an opaque surface, so long as there is still evidence of inflammation remaining; for, with

few exceptions, so long as minute vessels traverse its substance, the power of nature may remove, or greatly reduce the opacity, and the process of restoration may continue for months and even years after their disappearance.*

Two excellent examples of the removal of earthy deposit from the cornea have been published by Mr. Bowman, in his anatomy of the parts concerned in the operations on the eye. One was under his own care, the other under that of Mr. Dixon, and there is so close a similarity between the two, that I shall give only that of Mr. Bowman, which is headed "Symmetrical opacity of both corneæ, extending horizontally over the central region and obstructing vision; consisting of an earthy deposit limited to the anterior elastic lamina." "On each cornea was a horizontal band, of brownish opacity, extending from side to side, and so much broader opposite the pupil as completely to hide it from view, unless the pupil was dilated, or was examined either from above or below, through the still transparent cornea. Both the iris and the pupil could then be seen to be perfectly natural and active. When the pupils were considerably dilated, he obtained some useful vision, especially with the left eye, where the opacity was not quite so extensive as on the right. The opaque part was very finely mottled with dark dots, some of which were only to be seen with a lens; its margins were shaded off rather abruptly, and the cornea beyond them was perfectly clear. The opacity had the appearance of occupying a superficial position, and of being very slightly raised, but the surface reflected the light as brilliantly as other parts. The shape of the opaque

* Ulceration of the cornea is frequently observed to heal without loss of transparency, when a different result had been apprehended; and this circumstance is owing to the arrest of that process while yet it has not penetrated beyond the anterior elastic lamina. When it has extended more deeply and involved the lamellated structure also, the organized lymph, generally, soon becomes permanently opaque; and restoration of the transparency of the part is no longer practicable. In opacity from interstitial deposition much may sometimes be accomplished by the action of the absorbents, but we should greatly fear that any attempt at removal by the knife would only tend to increase the mischief.—Ed.

tract was peculiar in being slightly inclined downwards from the inner side, so that its lower edge in each eye corresponded exactly with the margin of the lower lid, when the eyes were directed to a near object. The inner end of the opacity in the left eye was traversed by a narrow line, in which the cornea was as transparent as ever.

“The singularity of these opacities led me to inquire into the man’s history. He had had an ophthalmia ten years before, lasting only a fortnight, and leaving no blemish. After a period of about three years, his wife noticed that he had a speck on each eye, but as his sight was perfect, he doubted it. After two or three years more the specks were more evident to others, and he began to find that in a strong light his sight was clouded, so that he applied for relief at the Ophthalmic Hospital, and remained a patient there for about two years, during which he was treated with drops and lotions, but rather got worse than better; in fact, the opacity seemed confirmed and incurable, and was steadily encroaching over the front of the pupil. Within the last year he has been quite thrown out of work, able to see only in an obscure light, and then only objects on one side.

“Like those who had previously seen him, I regarded these opacities as indelible, but as he came from time to time, it occurred to me to make an attempt to shave off a portion of one of them, in order to examine its nature more completely. I accordingly made the patient come from the hospital to my house, where I could at once place any particle I might be able to detach under the microscope. The first scratch with the point of the lancet on the right eye (Jan. 20th) detached the epithelium, which seemed healthy, and brought me down upon the opacity, which felt hard to the instrument, and had a smooth surface. In scraping and trying to slice off a thin film of it, a thin flake cracked off and separated, leaving what seemed a hole through the cornea, but the aqueous humor did not escape, and I then saw that the pupil was visible through the perfectly transparent lamellated texture, behind the opacity. It was now easy to chip off the opaque film over a space corresponding to the pupil, and

when this was done he could see large letters plainly, for the exposed surface was nearly smooth.

"The pain attending this little operation was great, and the poor fellow fainted; but the subsequent inflammation was slight, and in a few days the epithelium was restored, without any return of opacity, and he could see very much better.

"The fragments which had been removed became of an opaque white when dry, and when examined under a sufficient magnifying power presented the appearance of an aggregation of rounded, highly refracting grains, disposed in a sort of network. They all lay nearly in one plane, and the epithelium which had covered them was perfectly healthy." The deposit, submitted to chemical analysis by Prof. Miller, consisted of phosphates of lime and magnesia, with a considerable portion of carbonate of lime.

"On the 22d of February, the area exposed by the operation on the right eye remaining clear, I performed the same operation on the left, and with precisely corresponding results, so that in a few days afterwards he could see almost as well as eight years before. With this eye he could, in fact, with some care, read the type called pearl type."

I have not myself met with such favorable instances for operation as the foregoing; on the two occasions that I attempted the removal of what I considered earthy deposit, the entire texture of the cornea proved to be pervaded, and I desisted when that was discovered. I have twice attempted to shave off circumscribed central opacities of the cornea, that were just large enough to interfere with vision, and found that their depth would not admit of it; in each case the opacity was lessened by the slight subsequent inflammation.

The fact of secondary inflammation, under certain circumstances, having the power to remove or reduce an opacity which seemed indelible, was long since known, but the practice of purulent inoculation, which has been proposed, is so dangerous that it is not justifiable when any power of vision exists. Scratching the cornea with a needle, so as to excite inflammation, is cer-

tainly of benefit, especially when the opacity is superficial. I have done it several times with marked success, and there has never been any ill result. I believe that so long as there is any trace of vascularity about the cornea, provided there be no staphyloma, the extent or the intensity of the opacity will be reduced, even when it results from cicatrices, and surgical interference is uncalled for. There is no better established fact in ophthalmic medicine, than that an opacity will become less, or be entirely removed, long after all trace of redness of the cornea has passed away; and sufficient time should always be allowed for natural restorative power, and the application of those medicines, generally and locally, which are known to aid it.

Some excellent observers say, that opacities, not the result of cicatrices from ulcers or abscesses, will in time entirely disappear. If this be not universally true, I am sure that the exceptions are rare.

Acupuncture, with partial or complete penetration of the cornea, has been practised for opacities, and it has even been recommended to charge the point of the needle with irritating substances.

TRANSPLANTATION OF THE CORNEA.

The rapid and perfect adhesion of the cornea after the operation for extraction, and the beautiful completion of the process, suggested most probably the operation of transplantation; and the premature announcement of results by the sanguine experimenters induced many to believe that the operation was successful. Further investigation, however—and the subject has, I think, been fully tested—removes all hope of its efficacy.

In the article *Kératoplastie*, under the head "*Académie des Sciences*," in the "*Gazette des Hôpitaux*," for August 21st, 1845, it is stated that M. le Docteur Plouviez had already made a communication on the subject in 1843; he had that day addressed to the Academy another work containing the result of his experiments, and was still continuing his researches.

He is of opinion that the possibility of transplanting corneæ is a question almost resolved, but that it is necessary to determine many points, the solution of which is important for its success. The most important is to know to what degree the new cornea retains its transparency. During the five or six years that he had been engaged in the operation of transplantation, and he had performed it a great many times, he had not been able in a single instance to secure transparency; in the best instances the new cornea has always remained more or less opaline. Although vision has been more or less established, it has always been incomplete. Among the cases reported there is one of a young woman of twenty-three, who was blinded when three years old by small-pox, in which, after separating the opaque cornea, he applied on the stump and secured by four sutures the cornea of a young dog that had just been killed. The grafting succeeded perfectly, but the result was not satisfactory; the only benefit from the operation was that the woman could distinguish day from night better than formerly, although still incapable of going about alone.

The following are the deductions of M. Feldmann, from the results of twenty experiments, made at the laboratory of M. Flourens, at the Jardin des Plantes. The original appeared in the "*Comptes Rendus des Séances de l'Académie*;" my extract is from vol. lxii. of the "*Edinburgh Medical and Surgical Journal*," p. 259.

"1. The union of the transplanted cornea, with that of the eye operated on, takes place either by the first or second intention, or partly by both. When the margins of the cornea are in contact, or only separated by a very trifling space, union takes place by the first intention. In this last case a distinct plastic exudation, furnished by the neighboring parts, but especially by the iris, unites the margins of the cornea. Union by the second intention takes place when the margins of the cornea are separated a considerable distance from each other.

"2. The vascular connexion, when the cornea unites by the first intention, takes place in the following manner: one or more

large vessels proceeding from the conjunctiva advance to the edge of the transparent cornea. The blood from these vessels is then seen to penetrate the new cornea, either by forming new vessels through it, or by filling the old ones, till then invisible. It always happens that at first these vessels are excessively fine, and have a radiated or arborescent distribution relative to the main trunk.

"3. The transparency of the transparent cornea, which subsists for a few days after the operation, disappears afterwards. The cornea changes its color in proportion as the vascular apparatus is more fully developed within it; it ends by becoming more or less opaque.

"4. The aqueous humor, lost during the operation, is quickly reproduced, so as in some cases to swell out the transplanted cornea to a globular form shortly after the operation.

"5. When a part of the cornea floats, as it were, in the purulent matters, secreted by the neighboring parts, and the eyelids are allowed to rub over its detached margins, it becomes softened, and soon loses its conjunctival covering. The cornea never in this case adheres.

"6. The cornea, after it has been fairly transplanted, ends by becoming shrivelled and useless, in consequence of the absorption of a half or more of its extent. It sometimes becomes flattened, sometimes globular. The points of cicatrization adhere to the iris."

I have not myself had the slightest personal experience of this operation, and shall conclude the subject by a case of Dr. Kissam's, from the "New York Journal of Medicine," for March 1844.

An Irishman, thirty-five years of age, with one eye completely destroyed, and the other suffering from staphyloma, with adhering iris, was the subject of this case. As transplantation of the cornea appeared the only mode of relief which afforded any chance of recovery of vision, that operation was resolved on. The cornea to be transplanted was obtained from a pig six months old, but before it could be cut off, it was found necessary to extract the whole eye from its socket. The central portion of the cor-

nea, nearly half as large as the thumb-nail, was cut out, placed on the end of a piece of cork, and two ligatures passed through its margins at opposite sides.

With Beer's cataract-knife, the necessary portion of the protruding opaque cornea of the patient was removed, the pig's cornea laid over the aperture in the eye, and secured in its position by the two ligatures which were on a line with the angle of the tarsi. The ligatures were cut short, and the eyelids closed. When the eye was opened twenty-four hours afterwards, violent chemosis was found to have occurred; but in twelve hours more this had so far subsided as to allow the state of the globe to be ascertained. As the transparent cornea was found adherent, the ligatures were removed. The chemosis was so great that the raised conjunctiva served as a cushion to protect the transplanted cornea from the irritation of the moving tarsi; but, more important still, it overlapped, and thus secured it in its place. This perhaps contributed to secure the adhesion, as, instead of cut edge being united to cut edge, the transplanted cornea was applied over the margin of the patient's cornea, so that its cut surface was lying on the conjunctiva.

The vision was improved immediately after the operation, but as the humors themselves were diseased, it was still imperfect. The cornea continued transparent for a fortnight, when it became opaque, and in the course of a month it was absorbed. The operation was performed in the autumn of 1838, in the presence of Drs. Paul, Roberts, J. B. Kissam, and Pratt.*

* The transplantation of the cornea, like that of the cilia, however ingenious in conception, is so evidently hopeless that the suggestion might well have been consigned to oblivion; more especially since its impracticability has been actually determined by experiment.—Ed.

CHAPTER XVI.

CATARACT.

VARIETIES OF CATARACT. CAUSE OF CATARACT. NATURE OF LENTICULAR CATARACT. HARD CATARACT. SOFT CATARACT. CAPSULAR CATARACT. DISTINCTION BETWEEN CATARACT AND AMAUROSIS — CATARACT AND GLAUCOMA. OPERATIONS FOR CATARACT. PREPARATION OF PATIENT. OPERATION FOR EXTRACTION. OPERATION FOR DISPLACEMENT. OPERATION FOR SOLUTION. OPERATION FOR CAPSULAR CATARACT. OPERATION FOR DRILLING. SPECTACLES NECESSARY AFTER LOSS OF CRYSTALLINE LENS.

VARIETIES OF CATARACT.

THIS disease is generally divided into the spurious and the true; by the spurious is meant various morbid deposits, for the most part the result of inflammatory action, on the capsule of the lens; hence we hear of the sanguineous, purulent, pigmented, and many other kinds of cataract; but these terms do not convey the true pathological states of the eye which they are meant to express, and it is more intelligible as well as more correct to say that there exists a deposit of lymph on the capsule of the lens, with more or less adhesion of the iris, &c., as the case may be. Besides, such a division makes so much confusion, by blending general diseases of the eye with what should be regarded as distinct and peculiar changes in certain textures, that it should be rejected, and the term cataract confined to those alterations in the crystalline lens and its capsule, whereby their transparency is destroyed. It is true that some of the pathological changes alluded to obstruct vision, demand an operation,

and are even sometimes themselves impediments to certain operations for cataract;—these will all be treated of in their proper places.

I shall describe then only two kinds of cataract, the lenticular and the capsular. The lenticular frequently exists alone; whether the capsule is ever singly affected, is not positively known; the received opinion, however is, that the transparency of the lens depends on the integrity of the capsule, and that when the capsule has lost its transparency, the lens must be similarly affected. To the double affection the appellation of capsulo-lenticular cataract is applied.

Several pathological states may be associated with this loss of transparency; the opaque lens may be enlarged or reduced, may degenerate into fluidity, or become stony from earthy deposit, and the opaque capsule may lose all its delicacy of structure, becoming thickened, and even cretaceous.

CAUSE OF CATARACT.

Although cataract may exist at all periods of life, no age being exempt, from the fœtus in utero to that beyond the natural limit of man's existence, it appears to belong, as an idiopathic affection, more properly to infancy, when it is mostly capsulo-lenticular, and to advanced years, when it is usually lenticular. Of the exact nature of the change that produces the opacity, and the processes that regulate it, we know little; experience teaches that cataract may follow certain states or circumstances which may be regarded as causes; thus, a wound of the capsule may in a few hours cause both capsule and lens to be opaque; and inflammation of the eye may produce the same effect. Idiopathic lenticular cataract cannot be accounted for; pathology and physiology do not afford any elucidation, and all the theories that have been advanced concerning it are untenable. It must be remarked, however, that we meet with it less frequently in an uncomplicated state, that is, as an affection by itself, than coexisting with other disease in the eye, either of an

active or of a low type; the complication is more frequent in one variety, the soft; yet we are not thereby enlightened as to its cause. Opacity of the capsule, also, often cannot be accounted for, yet it would seem, more commonly than that of the lens, to be owing to inflammation, from the changes of thickness and density that it frequently undergoes, which alterations bear an analogy to certain effects in other parts of the body, usually considered to have this origin. Besides, in traumatic cataract, the capsule is nearly always opaque, and although the opacity may follow the injury in a few hours, that is quite time enough for its production by inflammation, which, to a greater or lesser degree, is always excited. Even when the cataract results from mere concussion, without any wound, inflammation might still be the cause. Furthermore, except in congenital cataract, the capsule is rarely found opaque, without there being evidence of some degree of inflammation in the eye, and pathological changes in it are generally in proportion to the severity of the accompanying inflammation. Moreover, it is seldom altered in the uncomplicated cataract of the aged, or if changed, it is merely by the loss of transparency, which is often partial.

Whether these parts are ever the primary seat of inflammation, is a question that has been often mooted. Dr. Jacob, who discusses it in a most masterly manner in his work on "Inflammation of the Eyeball," says that he cannot, as he has done in the case of the cornea, show that red vessels make their appearance in the body of the lens, or that purulent matter is formed in its texture in consequence of inflammation originating in, and restricted to it. He sums up the discussion by expressing his belief that no insulated inflammation of the lens, originating in the part, and confined to it, so as to constitute a distinct variety or species,—to be enumerated in a nosological arrangement, under the title of *Lentitis*—ever takes place; and alluding to Dr. Walther's description of such isolated inflammation, remarks, that what Walther refers to, appears to him to be not an unusual effect of general inflammation of the contents of the eyeball, described, perhaps, with a little coloring,

and such accuracy of detail as the establishment of a new species of disease seems to demand. "That the capsule of the lens, and in many cases, ultimately, the lens itself, becomes implicated in the general inflammation of the eye, commonly called iritis, there can be no doubt, and this I am of opinion it is that Dr. Walther has been describing. Dr. Mackenzie says: 'Inflammation of the anterior hemisphere of the capsule is always accompanied by a slight change in the color of the iris and form of the pupil, the iris becoming a little darker and the pupil irregular, while the motions become sluggish and very limited.' Surely this is to say that the disease is accompanied by iritis, or coexists with it. He also says, that 'red vessels appear in the pupil itself;' and that 'other vessels seem to extend from the delicate membrane retaining the pigment of the iris in its place;' adding that, according to Professor Walther, 'vessels seem to be prolonged rather from the capsule into the posterior surface of the iris;' all which proves that the inflammation described extends from the iris in protracted or chronic inflammation of the eye, and especially in persons of rheumatic or scrofulous habit, where there have been frequent relapses, the margin of the pupil almost always forms extensive adhesions to the capsule of the lens, in which adhesions red vessels, visible to the naked eye, are often observed; but these red vessels are not derived in the first instance from an inflamed lenticular capsule, but from an inflamed iris. Of the 'much rarer' 'inflammation of the *posterior hemisphere* of the crystalline capsule,' I do not venture to give a very decided opinion, not having been fortunate enough to see many cases presenting appearances resembling those described. I will not deny that 'ramifications of the central artery of the vitreous humor' may not 'spread out upon the posterior capsule;' but I cannot say that I have seen them; and as to the 'little knots of a whitish-gray semi-transparent substance, evidently coagulable lymph,' I am equally uninformed from my own observation. I may venture to add, that it appears to me remarkable, that with all this inflammatory disorganization of the posterior hemisphere of the capsule, the lens should remain so transparent as to admit of a perfect view of them, and I am almost inclined

to suspect that in some cases at least the appearances described are owing to certain curiously-formed opacities which are sometimes to be seen in this structure or in the back of the capsule, constituting a peculiar form of cataract."

Any pathological reasoning respecting the ramifications of the central artery of the vitreous humor from injections of the foetal eye is untenable, because in the fully-developed eye that artery ceases to exist.

What are usually assigned as the remote, or predisposing causes of cataract, are so vague, I may almost say so absurd, as to forbid any notice of them, with the exception of hereditary tendency, the effect of which may be very palpable in the congenital form of the affection. A young female came under my care with congenital lenticular cataract in each eye; her three sisters, maternal aunt and uncle, and maternal grandfather had all been similarly affected. All ophthalmic writers, who have seen much practice, adduce similar instances from their own observation. We have not, however, parallel examples of the cataract of the aged being induced by consanguinity.

THE NATURE OF LENTICULAR CATARACT. CLASSIFICATION INTO HARD AND SOFT.

A cursory sketch of the natural alterations in the crystalline lens at different periods of life, may assist in the elucidation of some of the pathological conditions of lenticular cataract, and may add to the means of diagnosing of its varieties. In infancy it is nearly spherical, and softer than at any subsequent period; with maturing age its consistency increases, its form also undergoing change, and becoming less spheroidal; in the adult we find it to be a double convex body, less convex before than behind, and still more dense than in youth.* About the thirtieth year,

* The crystalline is generally described as being larger and more convex in infancy, though not perhaps as approaching so nearly to a spherical form as is intimated in the text. Dr. Mackenzie informs us that he has repeatedly examined it after it has escaped from the eye of infants in whom the whole cornea

sooner or later, it ceases to be colorless, its nucleus then acquiring a light yellow tint; after that period the color becomes more marked, and pervades the entire lens, which at a very advanced age, resembles a piece of amber; both surfaces have now become less curved, and with the diminished bulk and maximum hardness, its specific gravity is greater. On these changes essentially is founded the division of lenticular cataract into hard and soft. In the aged, the pupil is deprived of the blackness that always exists in youth, there being instead a yellowish tint, which seems to penetrate deeply; this is owing to the color the lens has acquired.

HARD CATARACT.

Hard lenticular cataract is merely grayness or opacity, appearing in an already discolored and somewhat dense lens, and the greater the discoloration of the lens, the less will be the amount of grayness required to obstruct vision. Mere opacity does not create hardness, and the cataract of an old person is not harder than the lens would be in the same individual, though the property of transmitting light had not been lost; hence hard cataract cannot occur before that time of life at which the lens begins to increase in density. The deeper color in the centre of the cataract must be due, I imagine, to the greater aggregation of the opaque particles there.

I believe that a cataract once formed never becomes harder except by calcareous deposit, and the time of life at which the cataract occurs, will be a guide, so far, as to its consistence; but a hard cataract may degenerate and become soft; this will be fully treated of when speaking of soft cataract.

It has long occurred to me whether the lenticular coloration of age is, in itself, ever intense enough to produce opacity of the

has been destroyed by ulceration, and has not found its lenticular double convex form to vary in any considerable degree from that of the adult lens. He does not state, however, whether it was still enclosed in its capsule; and, if otherwise, it is evident that its shape must have undergone some change in its transit, from the loss of its soft or semi-fluid exterior.—ED.

lens, in fact—a cataract; I think that it may, for how otherwise is the total absence of all appearance of grayness to be accounted for in cataracts which are occasionally extracted? Indeed, so far as I can judge, no difference is discernible between them and the lens in old age, except in the former being rather more colored. In confirmation of this, I would draw attention to the fact that the coloration is often so apparent in life, and especially in the dark races of men, that it may not at first sight be possible to say when cataract does, or does not exist. I have lately seen two aged mulattoes, with this amber change so apparent, that the most experienced surgeon might have been deceived, and have pronounced cataract to be present, if either of these persons had complained of defective sight. During the last year, in the case of a woman of color, an operation for what was supposed to be a cataract was proposed, by one, to whom, both as an author and as a practitioner, ophthalmic surgery in this country owes much of its advancement: the coloration was here so intense as to have deceived him, the defect of sight being due to presbyopia, and vitiated secretion from the Meibomian glands, in consequence of chronic ophthalmia.

As the opacity of cataract does not generally conceal the amber color of the lens, the ordinary characteristic appearance of hard cataract is that of a mixture of dark gray and amber, more deeply shaded in the centre; occasionally there is a mottling of gray and amber, or it may be amber-colored only.

Hard cataracts may even resemble dark mahogany in color, and it is said that they have been met with of so deep a hue, that without close inspection, they must have passed unobserved. I have seen a lens quite black, but then it was taken from a disorganized eye from which a large staphyloma was removed. The darkest colored cataracts, that is, those having most of the amber hue, are decidedly the hardest, and they are now and then so friable as to break in pieces under slight force, appearing to be preternaturally dry.

In a healthy lens, the exterior is soft, beneath is firmer, and within is the nucleus or hardest portion; in a state of cataract,

the same differences in consistency exist; however, the softer part separates more readily from the harder. When, therefore, we have extracted what seems to be a very small cataract, in which case it is nearly uniformly hard, we have, in fact, little more than the nucleus of the lens, the outer or softest part having been absorbed, or left in the eye.

There are other appearances that are common to it and to soft cataract, such as radii and streaks, dull or bright; and a mother-of-pearl aspect, owing to the reflection of light from different planes. Some other common characters exist; these will be spoken of presently, with the other variety of lenticular cataract.

SOFT CATARACT.

Soft cataract exists in two states. In the one it is produced by opacity invading a lens that has not become amber-colored, or in which the coloration is still slight; constituting the cataract of early years. In the other, it is associated with degeneration of the lens, being apparently due to changes arising out of and inseparable from disintegration of the lenticular tissue; when it is not restricted to any period of life.

A light gray color is the appearance presented by the first, and in proportion as the cataract occurs earlier in life the gray is more apparent; sometimes there is a bluish whiteness, resembling milk and water; there may be cloudiness, and the surface may resemble a piece of fractured spermaceti; the color is generally more intense in the centre, as in the hard variety, from the greater aggregation of opaque particles. Radii and streaks exist in soft cataract even more frequently than in the hard, and are brighter, sometimes even glistening. They may occupy the margin, the entire surface, or its centre, and are doubtless owing to the greater opacity of certain bundles of fibres in the superficies of the lens. "In soft cataract," writes Mr. Dalrymple, "if the iris be blue or gray, a dark black ring seems to surround the lens, which is due, however, to the uveal margin of the pupillary aperture seen contrasted against the white opaque lens. A

certain interval may also be remarked between the iris and the lens, especially when the pupil is dilated, due to the shadow thrown by the edge of the iris upon the capsule, and is seen on one or other side, according to the direction of the rays of light."

The size of the posterior chamber may indicate diminution or increase in the size of the opaque lens, a small chamber signifying that it is augmented, and *vice versâ*; but this can never be a certain criterion, because a cataract may be thrust forwards merely by an increase of vitreous humor, or by preternatural vascularity of the ciliary apparatus of the choroid; and we can never positively say, so long as a cataract is still in the eye, that it is larger than the lens was, when transparent.

Soft cataract, resulting from the degeneration of the lens, is for the most part of a dead white color, which is due to the breaking down of the lenticular structure. Mr. Dalrymple's description of that state is so excellent that I quote it.

"Fluid cataract is met with at all ages, but is a somewhat rare species. It appears to consist in a disintegration of the lens; and when it occurs in elderly persons, the nucleus of a hard lens is often found in the interior of the capsule. This latter investment may, or may not, be also opaque. When the capsule is entirely transparent, it will generally be seen on dilating the pupil, and if the eye has been a short time at rest, that the color is not wholly uniform—that at the lowest part the opacity is denser, while a certain degree of milky translucency may be seen at the upper part. If the eye be suddenly rolled about, or rubbed, the opacity becomes general and uniform, but clears at the upper part by rest and subsidence of the more opaque materials of which it will be found to be composed. It is by this means that we may distinguish a fluid from an ordinary soft cataract. On examining the contents of the capsule, when we have the somewhat rare opportunity of doing so, we find the fluid semi-opaque, containing the debris of the lens, which may easily be distinguished by the microscope; also many oil-globules, and sometimes plates of cholesterine. In old subjects, as I have before said,

the hard yellow nucleus will be found having resisted the disintegrating process, or fluid softening of the lens."

It is this pathological change in the lens that has given rise to the so-called Morgagnian cataract, defined as opacity of the fluid, which was supposed by Morgagni to exist naturally between the lens and its capsule. Now such a fluid does not exist. Dr. Jacob, a very great authority on the anatomy of the human eye, denies it, and when discussing the subject at length in his work on the inflammations of the eyeball, shows the source of the fallacy by a quotation from Todd and Bowman's Physiology, to the effect that the superficies of the lens in contact with the capsule consists of extremely transparent nucleated cells, forming an organized connecting medium, there being no interspace, and that after death, the cells become loaded with water, which is probably absorbed from the aqueous humor, and constitutes the aqua Morgagnii that has been supposed to exist naturally. The fluid is sometimes brown, approaching almost to a chocolate color. On one occasion, when I had ruptured the capsule of the lens in the operation for extraction, a dark fluid escaped, which for some time checked my progress by obscuring the iris.

With this pathological change the capsule is apt to quit its attachments; on two occasions, while I have been extracting, it has escaped entire, and was in each instance semi-opaque; the color of the fluid was light brown; the lenses were very much reduced, their nuclei were uniformly hard, and of a deep amber color. Both of these patients, as well as the one above alluded to, recovered excellent sight.

Partial, but not fluid, degeneration of the surface of the lens may materially interfere with our diagnosis of the nature of a cataract; for instance, it is not very uncommon for cataract in an old person not to exhibit any amber color, but to appear whitish or whitish-gray, like the soft variety; and after extraction to prove light-colored on the surface merely, there being a hard amber-colored nucleus beneath. I am not aware that there are any diagnostic distinctions between a hard lens, so altered, and soft cataract, except that the former is uniformly of a whitish color, and devoid of cloudiness, and that the capsule is rarely if ever

opaque ; and such as the size of the chambers may indicate. In hard cataract there is nearly always a posterior chamber in correspondence with the age of the person. In soft cataract, the posterior chamber is very frequently reduced, and may be obliterated, the iris being pushed forwards, and its movements impaired, and the anterior chamber reduced ; the cataract may even protrude through the pupil.

As the natural changes in the crystalline lens are gradual, its density increasing by slow degrees, we cannot always determine when a cataract should be classed as soft or hard, especially as there is such very great variation in different individuals in the arrival of those several changes of structure incidental to age. Authors tell us that hard cataract does not occur under the forty-fifth year, and this is, perhaps, true, if we require as the proof of hardness a well-marked amber, or amber-gray color.

The following anecdote illustrates the practical bearing of the matter. Some years since a clergyman, forty years of age, consulted the late Mr. Tyrrell for cataract. Mr. Tyrrell, who never used the knife when he could employ the needle for solution, determined in this instance to extract ; his sudden death, however, prevented the operation. The patient then applied to a surgeon who always extracts when it is admissible, and whose success has probably never been surpassed, and we may fairly infer that he thought the cataract not hard enough to demand extraction, for he operated by solution. Here we have two highly practical men, both in extensive ophthalmic practice, differing on the question of consistence, and preferring different operations.

I have said that soft cataract, as the result of degeneration of the lens, is not restricted to any period of life, and thus in the aged we may see a cataract, exhibiting all the characteristics of softness. It cannot be that a lens has departed from the natural law, remaining of the same consistence as in youth, and has become opaque from the same causes that would influence a hard lens ; but rather, that, in consequence of some pathological change, it has degenerated, the opacity being merely the inseparable consequence of that alteration ; and this view receives con-

firmation from the fact that the appearances of soft cataract in an old person are more like those of degenerated lens than of cataract in early life, when the consistence of the lens is unchanged.

A very marked difference in consistence may occur in the opaque lenses of the same individual. I extracted both from a female sixty-nine years old; one had a hard, amber-colored nucleus, surrounded by soft whitish-brown matter; the other did not exhibit the slightest amber tint, but was gray throughout, and softer. Another difference was, that with the former the posterior chamber was natural, with the latter it was lost, and the iris pressed forwards.

In both kinds of lenticular cataract the opacity appears less dense when viewed sideways than directly in front.

Opacity may at once invade both surfaces of a lens uniformly; it may commence in the centre, or which is, perhaps, most common, at the circumference, in the form of spots, or in branches, streaks, or radii of different lengths, the order of which, especially when at the circumference, may be very regular; a general opacity then follows, which may, or may not, render these invisible.

CAPSULAR CATARACT.

Capsular cataract, or opacity of the capsule of the lens, has almost invariably the appearance of a dead chalky whiteness, rarely ever shining, and always showing the same opacity in whatever position it is viewed; it may be partial, occurring in one or many patches. A partial opacity may be easily recognised by its definite outline, anterior position, and whiteness; and these characteristics are rendered more manifest by raising the upper lid, desiring the patient to look to the ground, and inspecting the capsule sideways.

Whether complete capsular cataract encloses a lens, is judged of principally by its volume; when the lens is absent, the symptoms are flatness of the capsule, greater size of the posterior

chamber, with more or less retraction of the iris; and, if the capsule has been long empty, shrinking at the sides from partial or entire separation from its ciliary connexions. The more or less ragged and irregular capsule that remains after operations, is readily recognised as such. Although it scarcely involves a practical point, I may mention that when opacity of the capsule occurs, in conjunction with partial opacity of the lens, the color of the two may so resemble each other, that without looking into the pupil obliquely in the manner I have described, an inexperienced observer will be deceived. The definite outline of the capsule will be well contrasted with the posterior, hazy, and diffused lenticular opacity.

The posterior part of the capsule, differing in structure from the anterior in being much thinner, has not the same tendency to become opaque; indeed the possibility of such an occurrence, without the lens being also opaque, has occasioned much controversy. The question scarcely possesses any surgical interest, for with deep-seated opacity in the pupil the lens is sure, sooner or later, to become opaque; yet, it may not be out of place to state my opinion that the deep opacity, which is usually called capsular, is in fact lenticular, because it frequently exhibits forms precisely like those seen in opacity on the front of the lens, which are never seen on the capsule. The duller aspect in the adult is occasioned by the opacity being viewed through a colored lens. I do not think that the extent to which the opacity does sometimes exist—corresponding to the entire surface of the lens—is compatible with capsular affection; for I cannot imagine that the lens could remain transparent after its capsule had undergone such a change.

The capsule is rarely so densely opaque throughout as to conceal the color of the lens it encloses, unless the opacity be caused by injury, or be congenital; some little spots, less altered than the rest, generally afford the information; and the age of an individual does not seem to influence its changes, as in lenticular cataract, for precisely the same conditions may be observed at any period of life. A slight degree of opacity, whether in a part

or in the entire capsule, is attended with but little loss of other physical properties, and does not interfere to any extent with operations on the lens.

Congenital cataract scarcely requires to be spoken of apart from disease of the lens and capsule; for, strictly speaking, the early and foetal existence of the affection is the only peculiarity; the same rules of diagnosis that are applicable to cataract at other periods of life, apply here also. In the majority of cases that I have seen, the capsule has been opaque and very much thickened, and contained either a small portion of the lens, or merely a milky fluid; yet, the lens only may be implicated, and in all respects just as in cataract occurring after birth. The partial lenticular opacity occasionally met with in young persons is, I imagine, often of congenital origin, though it is often overlooked; especially when it is very small and remains for a while stationary; and it would seem that exceptions to the general law of the ultimate implication of the entire lens, after a part has lost its transparency, occur most frequently in partial congenital lenticular opacity.

It is not uncommon for a central opacity of the lens to look like a little cataract surrounded by a black zone; indeed such a state is usually described as opacity of a lens in which there has been an arrest of development. I believe, however, that the lens is not deficient in volume, the central part only being opaque and the circumference transparent.

Mr. Dalrymple thus expresses himself on the subject:—"In those cases of congenital opacity of the lens, not unfrequently met with, in which partial vision exists for a considerable length of time, there appears to be an arrest of development at a period, varying in different cases, anterior to the birth of the infant: for if we see the patient for the first time, in youth or early manhood, we find, on dilating the pupil, that the lens is probably not more than two-thirds its natural bulk—that, in fact, a clear ring of black may be seen between the pupillary margin of the iris and circumference of the opaque lens. Tolerable vision is restored

by this means, and continues as long as the belladonna exerts its usual power.

“In these cases of imperfect cataract and ill-developed lens, the opacity is seldom complete, but the aspect is that of a milky semi-transparent body suspended behind the iris, and relieved or contrasted against the natural dark color of the pupil. Sometimes we see a little opaque tag or fibre, which seems to attach the capsule to the vitreous body, or more probably to the anterior layer of the zone of Zinn, as if the lens, not increasing with the general growth of the rest of the eye, its former natural connexions had been partially separated, leaving here and there points of adhesions which retain it in its central position.”*

The partial opacity of the lens, which sometimes appears after purulent ophthalmia, and must arise from the capsule of the lens having been in contact with the cornea, which is often similarly marked, may have an appearance like the congenital opacity. The capsule is always partially opaque, but not necessarily to an extent equalling that of the lens.

The tendency to absorption of the lens, that coexists with complete capsular opacity, is a striking pathological fact, and is very apparent in capsulo-lenticular congenital cataract, as is shown by the following table of forty-four cases of congenital cataract, taken from Mr. Saunders' treatise on some practical points relating to diseases of the eye. I believe, too, that the thicker the capsule the more certain is the absorption of the lens:—

“Solid opaque lens, with or without opacity of the capsule.

Three single, two double cataracts,	5
Solid lens, opaque in the centre, transparent in the circum-		
ference, with capsule in the same state.	Five double,	5

* Mr. Dalrymple's opinion is supported by the high authority of Dr. Mackenzie. That there are cases in which only the central portion of the lens is opaque, the circumference remaining transparent does not admit of doubt; but he contends also for the existence of a variety of cataract, in which the opaque crystalline is of small size, never having grown from birth, and in which, on dilating the pupil, it is seen surrounded by a dark striated zonula.—ED.

Soft opaque lens, with or without opacity of the capsule.	
Two single, two double,	4
Soft opaque lens, with solid nucleus. One single, two double,	3
Soft opaque lens, with dotted capsule, the spots white, the spaces transparent. Two double,	2
Fluid cataract, with opacity of the capsule. Two single,	2
Fluid cataract, with opacity of the capsule and closed pupil. Two double,	2
Opaque and thickened capsule, the lens being completely absorbed, or the remains of it being thin and squamose. Six single, twelve double,	18
Opaque and thickened capsule, with only a very small nucleus of the lens unabsorbed in the centre. Two single,	2
Opaque and thickened capsule in the centre, remains of the lens in the circumference. One double,	1"

The ages of the patients would have rendered the Table more valuable.

COMPLICATIONS OF CATARACT.

Opacity of the lens and its capsule being common results of disorganization of the eyeball, it becomes of great surgical importance to discriminate when a cataract owes its origin to such a cause and is unfit for operation, and when it is uncomplicated and gives fair prospects for successful treatment.

Perhaps the most generally applicable criterion for our guidance is afforded by the state of the iris; for whenever an eye is materially injured, this part does not escape implication—it loses color and lustre, ceases to be a freely-acting diaphragm, and as such is a certain index that the globe is unsound. Cataract itself undoubtedly causes some modification of the pupillary functions, for it acts as a veil to the retina, rendering it less sensitive to light; it is possible for a capsulo-lenticular

cataract, if the capsule be very much thickened, to efface external impressions sufficiently to render the pupil nearly motionless under considerable variations of light and shade ; but such instances are rather uncommon. If, after covering the eye and then exposing it to a moderately bright light, the pupil does not act, suspicion may be justly entertained of the unsoundness of the retina: the eye not experimented on should, of course, be covered all the while.

As a rule, there should be contraction and dilatation according to the opacity of a cataract, whether capsulo-lenticular, or lenticular only, for except the cataract, while incipient, press on the iris, and so impair its movements, there should be a marked action of the iris, scarcely, if at all, differing from that of a healthy eye. In certain forms of complete amaurosis the pupil may act freely, but this complication cannot lead to error, as the total loss of the perception of any degree of light, which can never occur from cataract, would alone declare the disease.

The ordinary habitual size of the pupil in different individuals must not be lost sight of in these examinations. There is a relation, I do not say invariable, but sufficiently constant to be recognised, between its accustomed dimensions and certain temperaments ; a fact too often overlooked ; hence our guide should rather be the relative, or proportionate, changes under different degrees of light, than the actual capacity ; generally, the smaller the natural size, the more limited will be its movements. The various degrees of activity of the iris in different persons must be remembered. I examined the eyes of a lady, eighty-one years of age, with full-formed lenticular cataracts, at the window, on an autumnal day, when the pupils were contracted to a degree that at first induced suspicion of some coexistent ocular affection, but further examination with different degrees of light, showed a variation in them that removed all doubt. She herself was well aware of the activity of her irides, and the disadvantage accruing from the pupillary contraction had induced her, since the commencement of the cataracts, to wear a large shade to shut out bright light. In youth the iris is generally more active

than in adult age. When only one eye has cataract, there is not any disparity in the pupils, unless some other disease exists in it, or the other eye is defective.

Variation of the pupillary apertures may arise from imperfect development of the iris, but this will be readily recognised as a congenital defect.

A dilated and motionless pupil is a pretty sure indication of ocular disease, and if with the dilatation there be irregularity, all doubt is removed. The opposite condition, contraction, may proceed from a like cause, but is very rare.

I believe that the use of belladonna may be rendered available in adding to our means of diagnosis from the state of the iris, for if a contracted pupil depends on structural changes in the iris, the result of general disease of the globe, the pupil will remain inert under its application; a dark-colored iris may undergo changes of structure that are not readily visible, certainly not as readily detected as in one of a light color. Dr. Mackenzie states that if belladonna be used, and cataract be present, the pupil will be dilated in half an hour; but in amaurosis, there is generally little dilatation after several hours. In individual instances of some kinds of amaurosis, attended with decided structural changes in the eye, this will hold good, but the rule is not universally applicable. Adhesions of the iris to the capsule of the lens will always be revealed under the employment of belladonna, so long as but a portion of the pupil is free; if universally tied down, the nature of the case is at once apparent.

Although it is impossible, in particular cases, to say with certainty whether the faintness of the perception of light be owing to intensity of the opacity of the cataract, or to a diseased retina, still, generally speaking, the degree of vision is in proportion to the opacity of the pupil, and its amount affords a pretty sure index of the health of that tunic.

A body such as a penknife, or the finger, should be passed between the patient's eye and the light, as a test of sight; if he perceives it, the retina may be considered sound, but unhealthy, in proportion as only larger bodies can be discerned. An ope-

ration undertaken when it evinces feebleness, must ever be attended with doubtful results; with total loss of power, any practical surgical proceeding is inadmissible.

Certain conditions of the globe, indicative of pathological changes in the vitreous humor, go so far towards rendering operations abortive, that their detection is very essential. These are softness or flaccidity, or the opposite state, unnatural hardness. Tremulousness of the iris is frequently seen in connexion with an unhealthy condition of this humor.

Discoloration, or unusual vascularity of the sclerotica, especially if the vessels be large and tortuous, diminution of the eyeball, and a diminished cornea, are all unfavorable prognostics for operating, and any one of these may be sufficient to contraindicate it. Without proceeding further in detail it may be stated, that any deviation whatever from what would be considered a state of health, in any of the textures composing the globe, except the lens, is a complication rendering an eye more or less unfit for any operation for cataract.

Inflammatory affections of the ocular appendages, and mechanical changes in the lids, that may in any way produce irritation of the cornea, or interfere with their proper motions over the globe, fall within the same category of objections to operating.

DISTINCTIONS BETWEEN CATARACT AND AMAUROSIS—
CATARACT AND GLAUCOMA.

It is only in the incipient stages of cataract and of amaurosis that there can arise any doubt as to which of the two affections is present; and if amaurosis be defined as imperfection or loss of vision, consequent on lesion of the nervous apparatus of the eyeball, I am not aware of any objective symptoms that can be considered diagnostic, besides imperfect motions of the pupils, and loss of parallelism in the eyeballs, and these furnish exceptions. The paleness, or light-yellowness that exists behind the pupil after middle life, is often thought to be symptomatic of amaurosis; it is, however, but the effect of the coloration of the

lens, and is seen with or without defective nervous power : young persons with amaurosis never exhibit this appearance. It is this coloration that produces so much difficulty in diagnosis in adults. If a young person who is losing sight shows a dark pupil, we then at once declare that cataract is absent ; but with impaired vision at the middle period of life, and in the aged, the question is not so readily determined ; the natural color of the pupil renders it difficult to discriminate the disease, and I do not hesitate to say that from this it may be impossible, unless other symptoms exist, at once thoroughly to understand a case ; hence it is that surgeons, most experienced in ophthalmic disease, fall into error, sometimes pronouncing cataract to be present when amaurosis exists, and *vice versâ*.

The coloration of the pupil has been attributed to loss of color in the pigment of the choroid ; I do not think this correct, on the ground that, after the removal of a cataract from an old person, the pupil is never discolored, but black, as in youth. The following passage from Mr. Dalrymple's work, while it gives his opinion on this matter, testifies to the difficulty of recognising early the existence of opacity of the lens in middle life. "Incipient hard cataract is not easily detected, and there are appearances in elderly persons that greatly simulate this disease. When individuals become gray-headed, the choroidal pigment also becomes lighter, or perhaps deficient, as well as the coloring matter of the hair, and hence the membrane (the choroid) no longer absorbs all the rays of light which penetrate the eye, and the pupil, instead of the intense blackness of earlier life, appears grayish. If at the same time there be any defect of vision, arising from any other cause, some of the more obvious symptoms of early cataract appear, and give rise to erroneous opinions as to the nature of the disease. It is, indeed, probable that many of the reported cures of incipient cataract are due to the improvement of slight functional amaurosis, or impaired vision, coincident with this appearance of the pupil. If, however, the pupil be well dilated with atropine, the experienced eye will recognise, from the greater apparent depth of the opacity, that it exists, not in the

body of the lens, but further back, as if in the vitreous humor itself."

In amaurosis the movements of the iris are generally impaired or lost, directly that vision is affected, and dilatation of the pupil with irregularity is common. Yet in some cases of total blindness, where the disease lies in the brain, or behind the retina, the pupil may act as in health. Amaurotic eyes have a tendency to lose their parallelism, and turn outwards, and have that indefinite movement which seems to proclaim that they are not under the control of volition. In uncomplicated cataract, the globes are parallel, and their motions regular, and in unison with the general movements of the body. The subjective symptoms of the two are also different. Cataract forms slowly, vision declines in proportion, and objects are enveloped in mist. A dull or subdued light is preferred, because with an expanded or dilated pupil, vision is less imperfect. In amaurosis, the sight may be gradually lost, but, as frequently, it departs quickly, it may be, suddenly; *muscæ volitantes*, flashes, coruscations, pains about the orbits, headache, or other cerebral disturbances, will probably accompany the failing vision, and a bright light is generally sought. Of the *muscæ*, of which our knowledge is so imperfect, I must remark, that in consequence of their common existence, they do not afford indications of any particular affection; they may occur in any diseased state of the eye, and they may exist alone, and remain during a long life with the most perfect sight. The amaurotic person may be better one day and worse another, the extreme degrees being very great, and bodies may be discernible only when viewed laterally. Luminous objects generally appear distorted, or broken up into rays or stars.

Cataract may be combined with amaurosis, and only a very close investigation and careful discrimination can unravel the complexity of the symptoms; unless it be remembered, that with cataract the refraction of light may be very much interfered with and luminous bodies multiplied or even rendered fantastic in form, it might be supposed that amaurosis is present. A late patient of mine, who had well-formed cataract in one eye, and incipient

cataract in the other, was in the habit, when in London, of going out at night to be amused with the multiplication and refraction of the street lights; the pyrotechnic effect was beautiful; looking at the long train of lamps in Piccadilly was his greatest treat. A perfectly successful operation on each eye proved that this peculiarity was due to the cataract alone.

Glaucoma, which is not uncommon in elderly persons, but I believe rarely, if ever, seen in very early life, denotes a green or greenish state of the pupil, accompanied by other changes in the eye, especially hardness, and is generally grafted on amaurotic symptoms. Ultimately the pupil dilates, and the retina becomes wholly insensible to light. The loss of sight, however, is generally very gradual, and is sometimes attended, at least for a time, by diminution in the size of the pupil. About the nature of Glaucoma there is considerable discrepancy of opinion, and without doubt different diseases are classed under it by different writers. Some speak of it as synonymous with chronic retinitis; and Mr. Tyrrell, in particular, who makes the term glaucoma applicable when the disease has extended to the vitreous body, occasioning a change by which the humor assumes a green appearance, speaks of implication of the lens in the green or dirty yellow color, as a further extension of the affection. Mr. Lawrence treats of it as chronic arthritic inflammation of the internal ocular tunics, and, like Mr. Tyrrell, speaks of the opacity of the lens as consecutive, and describes its color as greenish, yellowish, or dirty white. Dr. Mackenzie considers the lens to be the sole seat of the glaucomatous appearance, having formed his opinion from dissections which he made of the eyes of persons pretty far advanced in life; but it appears to me that the particulars he gives of the greater number of the cases, are just those that might in general be found in the eyes of aged people, and are not indicative of any special disease. My own opinion is, that the state of the eye which is usually considered glaucomatous, is due to chronic inflammation of the eyeball, involving the lens, which then exhibits changes depending for the

most part, on the previous natural alterations in it, and I never saw the glaucomatous state, either in man or in the lower animals, without general disorganization of the eye. Any actual green tint is really very rare. Dr. Jacob says that the greenish or opaline opacity of the lens, which causes the appearance commonly called glaucoma, appears to take place more frequently from the gouty than from other forms of inflammation; yet he has seen common blue or milky cataracts, both uniform and stielated, caused by this disease.

The catoptrical or candle test of Sanson may assist in diagnosis, but I have not found it so generally applicable, or so certain as I had been led to anticipate: it is founded on the optical law, that if a lighted candle or taper be held a few inches in front of the pupil of a healthy eye, three images appear each behind the other; the anterior erect, the middle inverted, and the posterior erect. The anterior, the most distinct, is formed by the cornea; the inverted or middle, the smallest, by the posterior segment of the capsule of the lens; and the posterior, the most indistinct, by the anterior surface of the lens. A person unaccustomed to the test will not readily see these, unless the candle be moved about, and perhaps not even then, unless the pupil be dilated.* Opacity of the lens or its capsule from any cause, to a degree that interferes with the transmission of light, obliterates all but the anterior image, which will remain as long as the cornea is clear. The middle and posterior images will be affected according to the degree of opacity in the surfaces that produce them. Thus far it is an unerring guide, but it is proposed to decide on the nature of the two diseases, glaucoma and cataract, according to changes in these images, on the grounds that incipient cataract obliterates the inverted image, and obscures the deep-seated one, and that glaucoma always renders the posterior erect image more distinct, and obliterates the inverted one only when much advanced.

* The images will be more distinctly seen if the room be darkened, and the observer so situated that he may look somewhat downward and laterally into the eye, otherwise his own vision will be confused by the light.—Ed.

The difficulty that I find in accepting this theory, is, that an eye, which would appear from the test to be glaucomatous, may at a later period prove to have cataract. Of this I am positive, for I watched a patient sixty years old through this change ; the posterior erect image was blurred, but rendered more apparent ; then the inverted image was lost, and ultimately only the corneal reflection remained ; in fact, at the end of eighteen months from the time I saw this man with imperfect vision, there was well-formed cataract in the eye first affected. I operated on that eye, and now his sight is so good that he works at his old employment as journeyman optician. The other eye is following precisely the same course as the first, and is nearly dark.

Within a few days of writing this, Mr. Gay sent me a private patient with what should in strictness of terms be called glaucoma, for there was greenness of the pupil. In the left eye the globe was disorganized, the pupil greatly dilated and irregular, and the lens most indubitably of a greenish color ; this eye was without the least perception of light, and the opacity of the lens prevented the formation of the images with the candle. The right eye was passing through the several stages of disease that had occurred in the other. It is by no means the case, as some of the advocates of the candle test affirm, that the opacity of cataract always commences, and may reside entirely, in the surface of a lens. I believe the variations in the reflections of the candle-flame to be produced by greater or lesser opacity in different parts of the lens, the position of which may, so to speak, be accidental : and that in what is called the glaucomatous state, according to the candle-test, the central part of the lens is opaque. This view seems corroborated by the fact of the influence which mere coloration of the lens has on the reflection of light in the eye, for when the amber change is very decided, the supposed glaucomatous appearance is induced, and the posterior erect image is of a greater size because it is seen through the colored medium of the lens, acting as a foil to it.

The value of the candle-test is to be found chiefly in its application to the eye prior to the amber change in the lens; for then, if amaurosis be present, the three images will be seen clear and not blurred; if incipient cataract, the images within the eye must be affected according to the degree and seat of the existing opacity. In the aged it may enable us to compare the degree of opacity with the imperfection of vision; but in them, in consequence of the amber change, the detection of incipient cataract is beyond its power.

It is a cardinal point in ophthalmic surgery not to operate on an eye for the removal of cataract, so long as it may be rendered available for ordinary purposes, whether by optical appliances or by dilatation of the pupil with belladonna. The advantage to be derived from temporarily widening the pupil is remarkable, and not less available when there is slight yet general opacity, than when the opacity is partial but denser, and that, whether the lens or the capsule, or both be involved. The benefits of the dilatation are usually more lasting in partial cataract, because the partial affection may be stationary. I have seen a housemaid, eighteen years old, with partial capsulo-lenticular cataract that almost blinded her when the pupil was in the natural state, but when it was kept dilated by a solution of belladonna applied three times a week, she executed her work so efficiently that her employer was unaware of her defect. The belladonna had been used since childhood. It is one of the peculiarities of this drug that its effects do not wear out, the same quantity always producing the same result at any interval, or for any prolonged period. Its neutral salt, the sulphate of atropia, is the most elegant preparation, and the formula for its use will be found at page 43. Its employment for the purpose under consideration, need not be oftener than every second or third day.

OPERATION FOR CATARACT.

The several conditions of lenticular cataract require different

operations, and the choice of any one should rest solely on the circumstances of the case.

The hard cataract must be extracted, that is, removed from the eye; or displaced, by being pressed into the vitreous humor. A hard lens may not become absorbed for many months, or even years, but the chief reason why an attempt ought not to be made to produce absorption, is the very great risk of destruction to the eye from general inflammation of the eyeball.

Soft cataract, while allowed to remain in place, should be lacerated, or so broken, as to admit of the process of absorption, to which its softer texture readily yields; with this simple operation, the natural powers are quite capable of causing its complete dissipation.

Capsular cataract must, as a rule, be removed from the eye, but there are exceptions, where it may be torn through, or broken.

There are several circumstances that regulate the choice of either of the operations for hard cataract. Subsequent to the middle period of life, from the changes incidental to age, the anterior chamber may be so reduced in size, that the cataract knife cannot be used without wounding the iris to a considerable extent, and extraction is therefore contra-indicated; the same accident is likely to occur with diminished capacity of the anterior chamber from a bulging iris, resulting from pressure behind the cataract. A preternaturally small palpebral aperture, by preventing sufficient exposure of the eyeball, or a very deep-set eye, may each be a hindrance to extraction. Entire adhesion of the pupillary margin likewise forbids it, but partial adhesion, when very limited, does not; and this elicits the question, with what amount of adhesion may extraction be undertaken? It is difficult to answer hypothetically, yet I believe I may say, that whenever extensive use of the scissors would be required for the liberation of the iris, either in one or more places, a successful result could scarcely be expected. Under such circumstances the most fortunate termination would probably be closure of the

pupil from consequent inflammation, with a chance at some subsequent period of an artificial aperture being made.

Adhesion of the iris to the cornea may forbid extraction, either from the extent of the connexion, or the part of the iris implicated; yet if merely an inconsiderable portion of the margin of the pupil were adherent, I should not hesitate to divide it while making the section of the cornea, provided I could so direct the knife that the remainder of the iris would escape injury; or there may be a preliminary operation for this purpose.

The white ring around the cornea, known as the *arcus senilis*, is no impediment to extraction; an incision in it heals as readily as in a transparent part. The discovery by Mr. Canton of the fatty nature of this change, the particulars of which are published in an able paper in the "*Lancet*" for Jan. 11th, 1851, is among the most recent additions to the pathology of the eye.

The operation for displacement is essentially a bad one, because the cataract is then rendered a foreign body within the eye; it is only applicable when extraction would be dangerous, or is positively unsuitable, and ought, I think, to be regarded merely as an operation of expediency. Besides the objections to extraction already mentioned, which would call for displacement as a resort, are chronic cough and unhealthiness of the vitreous humor; disorganization of the vitreous humor is, perhaps, the circumstance most frequently demanding it in preference to extraction, from the danger of the loss of that body when the eyeball is opened; but this condition is also very unfavorable for displacement, from the difficulty of keeping the cataract in the desired position. That there will, after all, be a choice between these operations, according to the tact that different surgeons may possess in overcoming physical difficulties in the operation for extraction, arising out of certain peculiarities, is evident enough: I have seen extraction performed in a skilful manner where the narrow dimensions of the anterior chamber seemed to forbid such a result; and I have observed the same in cases of narrowed palpebral fissure, and in those of deep-set eyeball. I should say that to those accustomed to extract, these mechanical difficulties are rarely insurmountable,

especially if a smaller knife be used, than that which I shall figure. The greater degree of manual dexterity demanded for this operation than for that of displacement, which is very much easier, has induced many surgeons to assign to extraction a secondary place, but I cannot allow that such a standard should regulate the decision. Cataract is not a disease of emergency, in which one is suddenly called on to operate, and I hold it to be the imperative duty of every surgeon who undertakes the practical surgery of the eye, to qualify himself for the efficient execution of those operations that are most certain, and confer the most lasting benefits.

PREPARATION OF THE PATIENT.

Operations implicating the globe of the eye, demand for their success a state of health in which a wound can be inflicted on a delicate and sensitive organ with the greatest impunity. In the operation for extraction, unless union of the cornea be quickly effected by adhesion, success must always be more or less imperfect, and destruction of the organ may ensue. Surgeons differ about the requisite condition of system; I believe a state of depression to be as bad as that of plethora, which should always be avoided. An accustomed eye soon detects the habit of body that is popularly called "rude health," and a person exhibiting it, should be reduced by regulation of diet, exercise, and gentle purgation if necessary, till those symptoms disappear, and the force of the circulation is a little subdued. On the other hand, a debilitated constitution requires to be improved to the highest standard that the natural idiosyncrasy of the person will allow.

Dr. Jacob, in his brochure on the operation for cataract with the fine needle, makes the following excellent remarks concerning the preparation of a patient, which are not less practical than original:—

"The value of preparatory and after-treatment as part of the surgeon's care in cataract operations has been fully appreciated, and, in practice, amply made available; but the value of a re-

spectful consideration of all the functions of the animal economy upon which health depends has not been so well understood. It is assumed that a patient should be prepared for an operation by taking physic and abstaining from food, yet a rational man acquainted with the consecutive operation of each apparatus provided for the growth, repair, and preservation of the living being may well doubt the correctness of such a view. The universal faith reposed in the practice of giving and taking physic has led practitioners not only to place too much reliance on that resource, but to resort to it sometimes to the injury of the patient; as I find in the case under consideration. In preparing a patient for operation, I do not act on the belief that empty bowels are essential to health, or that what are called *faeces* should not be found in the intestinal canal; on the contrary, I proceed on a conviction totally different. If a patient be in good health, notwithstanding an habitual retention of the contents of the bowels beyond the prescribed periods, I do not wish to risk an interruption of health by disturbing the natural functions of the stomach and bowels, and I therefore refrain from giving physic. But if the patient be not in good health, I of course endeavor to bring him into that condition by every means in my power, and resolutely resist every attempt to induce me to operate until I have accomplished that object. Above all things, the state of the digestive organs should be carefully studied, and if found defective, if possible, repaired. Nothing seems to require more attention than the state of the tongue as indicative of the state of the stomach and bowels. If it be white or coated with discolored adhesive mucus, the functions of assimilation and nutrition are probably imperfectly performed, and a resulting tendency to destructive inflammation from local injury is engendered.

“It is usual in preparing for this and other operations to make great alterations in diet, substituting liquid for solid, and vegetable for animal aliments. This, however, must be done with caution, leading as it inevitably does to disturbance of the digestive function and interruption of the assimilating and nutritious

processes, if suddenly or exclusively adopted. Without digestible nutritious food, good chyle and blood cannot be produced, and without good blood local injuries are liable to suffer from destructive inflammation."

The whitish and rather coated tongue of the aged, should not be mistaken for a symptom of unhealthiness; in the old this organ is not so ready an index of the state of health as in early years; attention should therefore be paid to the urine, the deposition of uric acid, or of the urate of ammonia, being a sure indication of dyspepsia, or excess of nitrogenized food, or of fever, and that of phosphate of lime or the triple phosphate, of the opposite states of prostration and nervous depression. The abdominal evacuation should be examined for evidence of the hepatic state, and for information respecting the digestion of food, particularly in the aged, because it is in them that these functions are mostly at fault, and all kinds of operations less successful. In the majority of persons far advanced in years, who have passed through operations under my hands, it has been necessary to increase, or, if I may so call it, force the circulation, by tonics and stimulants. Towards the limit of the natural term of life, we should not, without ample necessity, cut off the accustomed amount of daily nourishment or the usual stimuli.

The presence of specific inflammation, as the strumous, gouty, syphilitic or rheumatic, in any part of the body, would contraindicate an operation; nor would it be prudent to operate on an eye that had recently been inflamed from any cause; a very long interval should be allowed to pass after the last trace of such disturbance.

Organic disease in the chest, provided it be not attended with cough, is scarcely an impediment. While I was attending the practice of Mr. Tyrrell, he operated by extraction on the eye of a female, fifty-seven years old, who had valvular disease of the heart, ascites, and anasarca; the operation was quite successful, and the patient returned home on the eleventh day after its performance. Her heart had been diseased for five years.

Advanced age is not in itself an objection to operating if no-

thing else forbid; the best attainable results have followed extraction after ninety. The late Mr. Scott operated successfully by extraction on a female between ninety and a hundred, and I have several times performed the same operation after the eightieth year, and once as late as the eighty-sixth.

Whether one eye should be operated on, while the other is yet sound, is a question not difficult to determine. The only reasons that can be given for the affirmative are, that a personal deformity is removed, and that any amount of sight that can be made available for viewing bodies situated laterally, and out of reach of both eyes at the same time, is advantageous; while opposed to this is the probability of confusion of vision when the same bodies are viewed with two eyes of a different range; this confusion, however, exists only in some instances, in others it is absent. It would, in idiopathic cataract, be unwarrantable to operate in anticipation of the implication of the other eye, for it is ever most uncertain when it may be affected; my own experience has supplied examples of very distant intervals, and a lifetime may not bring it about. But when the second eye is incipiently affected with cataract, there can generally be no reason for delay; although even then the kind of cataract must be taken into consideration, the soft quickly becoming generally opaque after opacity has appeared in a part, and sight being more quickly destroyed, the hard forming very slowly.

It is not yet generally agreed on by surgeons whether only one eye at a time should be operated on, or both at once; if extraction be the operation, my practice is to do one at a time, and to let it recover before the other is touched; there is thereby less shock to the system, nor is there any risk of sympathetic influence, as when both are done together; besides, at a first operation, there may be discovered some constitutional peculiarity of bad tendency, which may in some measure be removed or reduced at the second.

The season most fitted for operating has also, and especially of late years, occupied attention. I have operated at all periods, with, as far as I could judge, equal success. With reference to

needle operations, I suspect it matters not; nor, perhaps, is any operation in our climate, influenced by the mere degree of temperature, which is rarely in either extreme. I believe, only great thermometrical extremes are prejudicial; however, in extracting in cold weather, I have the room to which the patient is confined kept at a uniform temperature, not lower than 60° Fahrenheit for the first few days. The prevalence of easterly winds, or of damp and rainy weather at any time, would be objectionable for operating. Many very excellent surgeons never extract in winter, and Mr. Tyrrell thought the best time for that operation to be between March and October. Where a choice is permitted, I should, as a rule, prefer that period, because regular exercise, prior to the operation, is less likely to be interfered with, from the greater certainty of settled weather;—while the apartment can be better ventilated, and the patient will be able sooner to take out-door exercise, and recover his lost strength and spirits, the consequence of anxiety and confinement.*

OPERATION FOR EXTRACTION.

CATARACT KNIFE.

Beer's Cataract Knife is that which has obtained the approbation of the majority of ophthalmic surgeons, the triangular blade peculiarly fitting it for fulfilling the desired object of cutting a flap in the cornea by one continuous movement. Mr. Tyrrell judiciously reduced its length five-sixteenths of an inch, allowing its breadth to remain unaltered. I have found it


* There is not so much to be apprehended from extremes of temperature merely, as from variations in the electrical constitution of the atmosphere; and we are careful, therefore, besides selecting the season when these are least frequent, not to perform an operation while a storm is impending. After the rain begins to fall, the electrical equilibrium is restored, and the danger from this cause is over. It will generally be prudent, even with the needle, to operate on one eye only at a time, as the danger of inflammation is less, and opportunity is thus afforded for the avoidance of any untoward circumstance which may have occasioned an unsuccessful result.—Ed.

advantageous to diminish even his proportions. The annexed knife, so altered, measures from the point to the shoulder, eight-tenths of an inch, and across the broadest part, four-tenths. When these dimensions are exceeded, it is uselessly large, frequently inconvenient, and, it may be, even dangerous, from its liability to wound the parts at the corner of the eye, when the narrowness of the palpebral commissure prevents the lids being sufficiently opened.*

* There is some discrepancy of statement respecting the angle which the oblique cutting edge of Barth's, or Beer's knife as it is more commonly termed, forms with the back of that instrument. According to Mr. T. Wharton Jones it is 18° ; Dr. Mackenzie in his *Practical Treatise* makes it 17° ; but in his review of Mr. Walton's work it is more correctly given, as we find on reference to Weller's *Manual*, at 15° , and its length from point to shoulder along the cutting edge at one inch and two-tenths. Mr. Tyrrell reduced the length one-tenth of an inch, and increased the angle to 19° ; and Mr. Walton, with a still further reduction, extends the angle to 27° . Dr. Mackenzie expresses a decided preference for the instrument as originally devised; since by it, puncturation and counter-puncturation are easily performed, and the incision completed with very little pressure,—the narrowness of the blade facilitating the steps of the operation, and preventing the lid from being injured. By the alteration of Mr. Tyrrell,—which has been not unfavorably received by others—he regards it as having been rendered at once more difficult and more dangerous to use; while of Mr. Walton's modification, this veteran practitioner does not hesitate to express his conviction, "That no study nor practice can obviate the disadvantages attendant on the employment of such an instrument."

In addition to the characteristics mentioned above as belonging to Beer's knife, it may be stated, that its point should be double edged for the space of an inch; the rest of the back, though blunt, should be thin, and the thickness of the blade, which is greatest in a line near to this part, should gradually increase from point to heel. Mr. Jones recommends the removal in a curved line of a portion of the heel, to the extent of the tenth of an inch at the angle; and this is an improvement in the instrument represented by him, as the lid is less liable to be wounded, and the extreme breadth at that point is quite unnecessary.—Ed.

Fig. 111.



The following diagram, which represents a cornea of full size, displays in the dotted lines the course the knife should take, and any breadth of instrument greater than is required to accomplish such an incision, is superfluous. A new knife may be a little larger, to allow the reduction consequent on the necessary repair after use; and for eyes that are large and very

Fig. 112.



favorable for extraction, slight extra size matters nothing; but otherwise it is important to employ one no larger than the dimensions of the cornea absolutely require: the average size of the cornea in adults is about seventeen-fortieths of an inch; in old persons it is less. The thickness of the knife should be nicely regulated: there ought to be a slight increase from the point, which should be stiff, to the shoulder. The back should neither be square nor obtusely rounded, but rolled off gradually from the middle of the blade to an edge sufficiently thin, without being sharp.

Fig. 113.



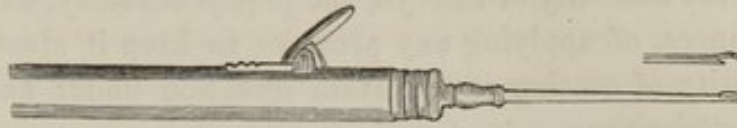
CURETTE.

Both of the extremities of this instrument are considerably modified from the usual forms. The spoon-like silver end peculiarly suits the purposes demanded of it; the other, or needle limb, is curved only as much as is actually required, for the less the deviation from a straight line the greater is the facility in using it, and the less risk is there of injurious contact with the iris or the cornea. A side view cannot, of course, convey an idea of the breadth, which is nearly that of the stem within a short distance of the point. The very extremity only is sharp.

GUARDED CURETTE.

In one that I have lately had executed by Messrs. Weiss, there is a sharp limb more fitted for the

Fig. 114.



peculiar work of a curette; the point is concealed by a little guard, so that when the instrument is closed it is dull, in con-

Fig. 115.



sequence of which it can, with great ease and great safety, be carried to the required spot, where it is opened by pressure on the trigger in the handle, used, then allowed to close by remission of the pressure, and withdrawn.

The larger figure (114) shows the instrument shut; the lesser a little open. Certainly, one difficulty in extracting a cataract is greatly reduced by this contrivance. The ordinary curette is frequently improperly introduced, injury inflicted on the iris in its passage, blood poured out, and its application to the capsule prevented, because of that part being obscured; or if these steps are well executed, mischief is often done in its withdrawal.

Fig. 116.



SECONDARY KNIFE.

Notwithstanding my very limited experience in the use of such a knife, I give the preference to one of this form (Fig. 115). The point is rounded and blunt. A straight blade requires less force than a convex or concave one to direct it with effect; moreover, it is capable of receiving a keener edge, and these are advantages of high importance here, because the occasion which calls for the secondary knife, offers peculiar difficulties,

owing to the flaccidity of the eye, the impracticability, under the circumstances, of applying any pressure to keep it steady, and the necessity of cutting in a certain direction under unusually limited restrictions.

SHARP HOOK.

This instrument (Fig. 116) is commonly called a lens hook. The point should be sharp, yet the hook itself ought not to be very fine, for a very delicate extremity is not sufficiently retained by the lens, and is more apt to become entangled in the parts over which it passes, or with which it comes in contact, and to scratch or otherwise injure them. A guard might perhaps be advantageously placed on this, as on the curette.

Extraction is frequently referred to as one of the most difficult operations in surgery; while I fully admit that for accurate execution, great nicety and tact are needed (and these are within the reach of most surgeons), I do not hesitate to assert that its difficulties are greatly exaggerated.

Putting aside those whose total want of manual tact, or great nervousness, disqualifies them for any manipulations in operative surgery requiring delicacy, I believe that with proper training and practice on the dead body, any surgeon may become a successful operator. Of course there have been, and ever will be, degrees of excellence, owing to the differences of natural aptitude, and of dexterity acquired by diligent study and practice. One of the best operators we have ever had in this kingdom was, in the first instance, so unsuccessful in extracting cataract, that he was restrained from operating for two years at the institution to which he was attached, and during that time he was literally confined to the minor operations only. He had the good sense to submit with patience to this decree, and the issue was, that he became one of our very best operators for cataract. This valuable man was prematurely cut off, but he has left behind him for our example, his patience under temporary eclipse, his unwearied perseverance in overcoming his natural impediments, and his

modesty and quiet dignity, when great and deserved success crowned his labors and his zeal.

My first immediate preparation of a patient is the administration of some mild purgative the day before operating, solely that the necessary quiet after the operation may not be disturbed for a day or two by the natural action of the bowels; for the probability is, that they will not act for a few days after the effect of the purgative is over.

The state of the pupil, whether artificially dilated or not, can have little effect, either in placing the iris out of the reach of the knife, or throwing it in the way. It has been said, that if dilated, the iris is less manageable after the extraction, but this is very questionable indeed.

Whether a patient be sitting or lying down during the operation is of no particular moment, if he be quiet; but if likely to be restless, he ought to be placed on his back.

The importance of a properly-regulated light is evident, and an operator will, of course, choose that which, according to the arrangement of the room, suits him best.

It is customary to bind up the eye not to be operated on if it have any sight; I object to the practice, because it possesses no advantage, and the formality tends to unnerve a patient.

It is well to have all the principal articles of clothing taken off, the patient prepared to go to bed, and a morning gown put on, to prevent the inconvenience of undressing after the operation.

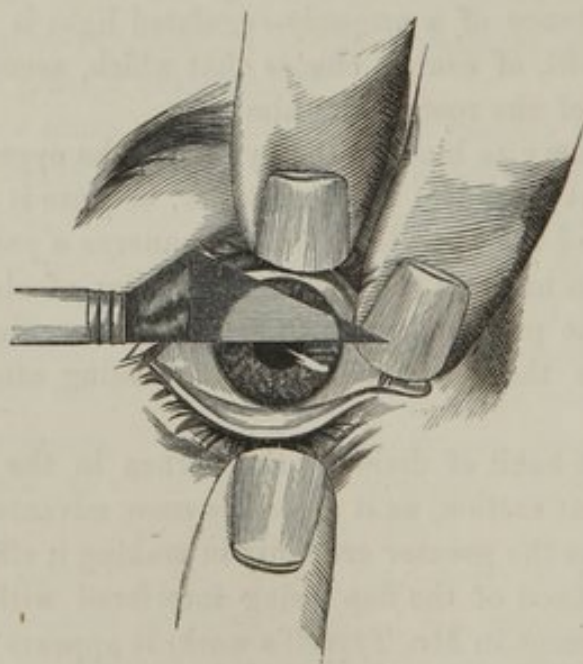
I am in the habit of dividing the cornea in the upper part, preferring that section, as it possesses some advantages over the lower—such as the greater certainty in making it effectually, and the less likelihood of the flap being interfered with by the lid. From a statement in Mr. Tyrrell's work, it appears that he preferred an oblique section, dividing the cornea downwards and outwards, and that he founded his choice on the superior position the pupil would hold should there be prolapse of the iris. I saw this admirable operator extract very frequently, before and after

these views were published, yet never once did he adopt any other than the upper section.

I think it better to stand behind the patient in making the section in any direction, as it gives much greater command over the globe of the eye; but if want of practice, or deficiency of confidence disqualifies the left hand, the operator must stand in front of his patient when the cornea of the left eye is to be incised, and trust the retracting of the upper lid and the steadying of the globe to an assistant, while he himself further secures the eyeball, and makes that kind of section which he prefers.

It is notorious that extraction in the left eye is much more frequently attended by failure than in the right, and the occurrence is of course attributable to the greater difficulty offered by the left eye.

Fig. 117.



The preliminaries having been arranged, an assistant gently draws down the lower lid, resting his finger on the malar bone, so that the globe is not pressed: the operator, standing behind

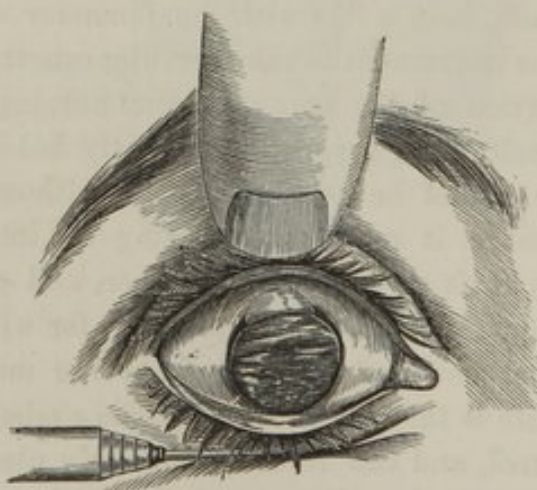
the patient's head, which is of course at a convenient height, places his hand on the forehead, and with the forefinger elevates and draws forward the upper lid, locking it under the edge of the orbit, and with the tip of the finger, which should be a little below the tarsus, presses gently against the globe to prevent any upward motion, while he places his middle finger on the inner side of the globe to counteract any movements in an inward direction; neither finger should encroach on the cornea, but be kept away as far as possible. His other hand is rested against the side of the face, the thumb and first two fingers unrestrained, to allow of free play with the knife, which being held lightly, is entered at the central and external part of the cornea, about half a line anterior to the sclerotica, passed rapidly through the anterior chamber, and the point brought out on the inner side, at a spot as nearly as possible opposite to the entrance. The diagram (Fig. 117) delineates these several steps executed on the right eye.

It matters not if the point of the knife be entered higher or lower than the centre of the cornea, provided that the counter-puncture correspond to it. It is a very common error for the operator to hold his knife in such a position that the edge, instead of the back, is in a line with the diameter of the cornea, which causes the instrument to take a wrong course, not including a sufficient portion of the cornea: from not being practically aware of this fault, some surgeons frequently fail in extracting.

As the globe cannot be kept motionless without an injurious amount of pressure, it rolls a little during the introduction and passage of the knife through the chamber, and great nicety is required to adapt the hand to this yielding, for without this precaution a proper counter-puncture cannot be made: after the point of the knife is through the cornea, the eyeball is under the operator's control, and can then be correctly placed if it have rolled too much inwards. The remainder of the cut ought to be executed slowly, and with the same continued thrust or push of the knife, taking care so to direct the edge in its entire course, that it shall pass at a uniform distance from the sclerotica. As

the knife advances, the pressure with the finger should be lessened, and entirely cease before it is free, prior to which, also, the assistant had better relax his hold. When the last portion of the cornea is divided, a jerk will occur, if not avoided by proceeding particularly slowly. I have found assistance from placing the end of the finger, or the back of the nail, against the last resisting part, as a check or support. After the incision is completed, the upper lid must be gradually released, and the eye closed. Subsequent to a brief repose, the lid is to be again raised, but only sufficiently to expose the cornea, the patient told to look towards his feet, so that the globe may be directed downwards, the curette introduced beneath the corneal flap, and the capsule lacerated crucially. The cataract is now to be started by pressing on the globe, above, through the medium of the lid, with the finger used as a wedge between it and the orbit, and below, with the curette, after the manner exemplified in the following diagram. The pressure should be increased till the opening of the lips of the cornea by the bulging of the iris, indicates that the cataract has left its position, and steadily kept up till

Fig. 118.



the cataract has fairly protruded, when it should be remitted, as the elasticity of the cornea will then suffice for the expulsion. The operation is now over, and if well done is bloodless.

A complication may arise by the iris falling in the way of the knife, an occurrence that may be produced by the premature escape of the aqueous humor from undue pressure on the globe; from not making a continuous onward movement with the knife, by which it is kept adapted to the incision; or from what, in fact, amounts to the same thing, twisting it about, and causing the edges of the wound to gape. If the aqueous humor escape prior to the counter-puncture, the knife should be withdrawn, and the operation delayed; if when the cornea is nearly divided, a considerable portion of the iris should be in the way, the instrument should be taken out, and the section completed with the secondary knife, the blade of which must be passed under the remaining tag, and used in the most convenient direction. A small bit of the iris, especially of the pupillary margin, in contact with the edge of the knife, should not be regarded, and the operation ought to be completed without hesitation. If a second pupil be made, the isthmus should at once be divided by the blunt-pointed iris scissors. It is recommended by several surgeons, always to attempt to free an entangled iris, by pressing it between the cornea and the knife; but I have seen many such efforts made without a single successful issue. The fingers of the operator are so engaged that he cannot well shift them from their occupation, and there is such a want of consent between those of an assistant and his own, that in the majority of instances, the safer plan is, I believe, from what I have seen, to proceed and inflict a slight wound rather than attempt the extrication. I feel perfectly sure that some of the rules laid down on this head by writers, cannot, with safety to the eye, be reduced to practice; however, I wish it to be understood, that I do not doubt the possibility of the iris being shaken off the edge of the knife, for the fact has been mentioned to me by surgeons who have done it.

The iris may or may not bleed when wounded, but the presence of blood in the chambers of the eye, need not occasion any anxiety.

If the cornea has been divided as I have directed, there will

be ample room for the cataract to pass out, but in proportion as the incision is smaller, will there be difficulty in its exit; and when under a certain size it cannot escape at all. A faulty section may arise from entering the knife too much above the transverse axis of the cornea, or too far from the sclerotica, or from running the point for some distance between the laminae of the cornea; or with a good entrance, the counter-puncture may have been in the wrong place. Again the cornea may have been admirably transfixed, but instead of the edge of the knife having been kept parallel with the iris, it has been directed forwards and brought out too far from the sclerotica. All of these mistakes are equally bad; the most common, and therefore, that to be most guarded against, is an imperfect counter-puncture, to obviate which very ingenious, but very useless, and even injurious instruments have been invented to fix the globe, an act that can be done effectually and safely only with the fingers.

When the incision is inadequate, a fault which is always readily recognised by the cataract having partly passed through the pupil, and yet not escaping, the use of the secondary knife is the correct expedient, for any attempt to squeeze out the cataract would be fruitless, and likely to be fatal to the eye from the vitreous humor rushing out. It is well to pause a little and allow the eye some repose before the application of the secondary knife, the employment of which demands the greatest nicety. The blade should be kept forwards with the extremity against the cornea, that the iris be not injured, and the cutting should be done by a succession of outward strokes on the outer extremity of the incision. A surgeon who operates even tolerably well will very seldom have to enlarge the incision; a proceeding which is certainly one of some danger, for according to my own experience, when it has been adopted, there has been a large average of failures, which is doubtless attributable to the cornea having been jagged, and the iris more or less bruised. Still, enlarging the wound is far preferable to forcing the cataract through a small aperture, for an easy exit is a very great essential to success.

The importance of thoroughly lacerating the capsule is in ge-

neral hardly sufficiently estimated, and the neglect of it is next in frequency to a defective corneal incision. The curette, introduced with the concavity upwards, should be run across the capsule from side to side, and from above to below, as far as the pupil will allow, and unless this be done lightly, the cataract is in danger of being displaced; on withdrawing the instrument its direction should be reversed; attention to these precautions will save the cornea and the iris from injury; but they are unnecessary when the guarded curette is used.

Should the cataract not move forwards or evince some signs of displacement after the requisite degree of pressure, and should there be no impediment except that which may be attributed to adhesion to the capsule, it must be removed with the lens hook; this little instrument being entered like the curette, is passed through the pupil and implanted in the cataract, or it may be required to pass it behind. Except in the hands of a most expert manipulator this is certain to be attended with loss of the vitreous humor, from pressure in attempts to steady the globe, and only long practice in operating on the ball of the eye can give the delicacy of touch, the confidence, and the coolness, that are required. The lens hook is also requisite, when from pressure on the globe, the vitreous humor escapes by the side of the cataract, irrespective of the causes just enumerated, and solely from unhealthiness of the vitreous humor. If the cataract is displaced in using the hook, it may still be secured, but if far away from the pupil, or sunk out of sight, which is likely with a disorganized vitreous humor, it should be abandoned. A case is recorded of a surgeon, who certainly displayed more perseverance than prudence, groping for three-quarters of an hour for a sunken cataract. Hemorrhage may follow this lifting out of the cataract, but I have not myself met with an example, and I quote from Mr. Tyrrell, who informs us that in some cases where he has had to remove a cataract which had been displaced by the use of the curette, there has been subsequent hemorrhage, without injury of the iris, to an extent that destroys the eye, arising, as he supposed, from the central artery of the retina; but most

likely it was from the ciliary apparatus. In one case there was positive assurance that the iris was uninjured, from the hemorrhage commencing as soon as the cataract was displaced. I may here remark that hemorrhage, coming on some minutes after the operation, has been known to follow extraction, when there has not been displacement of the cataract into the vitreous humor. Soon after I had commenced attending the practice at Moorfields, Dr. Farre pointed out to me a case of Mr. Tyrrell's, in which hemorrhage did not appear for some time after the extraction, and, it was supposed, not until after the cornea had healed, for the chambers of the eye were filled with blood, without there having been any escape of this fluid; success ensued, without any treatment having been adopted.

The symptoms of an imperfectly ruptured capsule, and those of adhesion between the capsule and the cataract, being the same, namely, bulging of the iris and expansion of the pupil, without the escape of the cataract, the more likely of these causes and that which is the easier remedied, the imperfect laceration of the capsule, should be supposed to exist, and the curette again applied, unless the operator be certain of the contrary.

Adhesion of the iris to the capsule may, by restricting the expansion of the pupil, prevent the cataract from escaping; the iris will bulge, and, perhaps, the pupil may partly dilate, but further progress is stayed. Ignorance of the existence of this complication would be inexcusable, and could arise only from not having previously dilated the pupil. If the position of the slight connexion between the iris and the capsule has been previously noted, the scissors should be used promptly.

The cataract may fall in pieces while emerging from the cornea, and some fragments may remain in the anterior chamber. The spoon of the curette should be used to withdraw any of these that may lie between the iris and the cornea, or that interfere with the adaptation of the corneal flap; but any that occupy the pupil may safely be left alone. If the circumference or soft part merely, of the cataract remain, it should be left untouched,

unless it occupy the incision of the cornea, for it is rapidly removed by absorption. The capsule of the cataract should be left, except very opaque, when the canular or other delicate forceps must be employed for its extraction.

The iris does always recover itself and contract after the escape of the cataract, but may prolapse and be unmanageable. If after gently touching the globe a few times, or rubbing it through the closed lids, waiting a little, and again repeating the rubbing, the prolapsed portion be not removed, the spoon of the curette must be called to our aid in replacing it. The evacuation of some of the vitreous humor has been advised in obstinate cases of prolapse; but I consider it safer rather to leave the iris protruded; for, independently of the chance of spontaneous return after all our efforts have failed, the success of the case is not very materially interfered with. The most troublesome prolapses are those complicated with escape of the hyaloid membrane; then all attempts at reduction fail, and the hyaloid membrane should be cut off with the scissors close to the iris, without injuring the latter; that which remains in the incision does not seem to interfere with adhesion. Even with this misadventure a case is far from being hopeless.

Except when the vitreous humor is dissolved, when no operative skill can invariably prevent a partial loss, escape of any of it must be placed to the account of bad operating; and unless it be to cover this defect, I cannot understand why it has been stated, that depriving the eye of a part of this fluid is advantageous. The abstraction of a small quantity, certainly, does not seem to be generally followed by a decidedly bad effect; yet there has never been a proper comparison made between eyes in which this has occurred, and those in which the integrity of the eye has been preserved. An operator ought to be most careful to prevent the accident, for when any portion has run out, very slight circumstances will occasion a further discharge, and prolapse of the iris is imminent. It is a common accident with beginners, for the cataract and some of the vitreous humor to burst out directly that the cornea is divided. Spasmodic

action of the muscles of the globe generally bears the blame. Some authors undertake to tell the effect that will be produced on vision according to the amount lost, and speak of a third, fourth, or fifth; all this is mere conjecture: how is the quantity which has escaped to be decided on?

Adjustment of the flap of the cornea is the last particular of the operation requiring attention; for, with a prominent eye, the lid may displace it, turning it down. Instead of attempting replacement with the curette, which is always troublesome, the eye should be opened, the cilia taken hold of, and the lid raised and lifted over. Inversion of the flap, which, it is said, may occur, would certainly require the curette, or some blunt instrument, to replace it.

Judicious after-treatment is no less essential to success than careful preparation and good operating. I prefer sending my patient to bed immediately that the operation is over, and keeping the eye closed for a certain period, that the adaptation of the cut surfaces may be maintained; of course both eyes are to be shut. I have for some years discontinued the usually prescribed practice of binding the eyes with a compress and bandage, for I believe the practice to be bad, as any degree of pressure on a wounded eye must be injurious, and the heat and discomfort inseparable from coverings must often give a disposition to, if it does not directly set up inflammatory action. Sometimes to produce a moral effect, when the patient is nervous, and fancies that without a bandage he would unconsciously open the eye, I attach a bit of cloth to the night-cap, so as to fall over the eyes, and then pass very lightly over them a single turn of a common roller. Even this has a disadvantage, for the aqueous humor, and the lachrymal and conjunctival secretion may wet the rag, causing it to adhere to the face, and producing discomfort sufficient to disturb, or even prevent sleep. When the bandage is not insisted on, another manner of relieving the patient's fears, and the best method of preventing the opening of the eyes in an unruly person, is to bring the lids together by a slip of court-plaster. As a necessary protection to the eye from accident, I employ a very

large square stiff shade, a little padded where it rests on the forehead, reaching from temple to temple and to the tip of the nose, and sustain it in position by elastic bands, one around, and two in a cross direction over the head. This appliance has guarded many eyes from destruction, and obviates the necessity and irksomeness of the patient keeping in one position, besides relieving his mind, as well as that of the operator, from much anxiety, by the fact that the eye cannot be accidentally struck. This renders unnecessary also the annoyance of fastening the hands, so that they cannot reach to the head. A celebrated ophthalmic surgeon of a past generation was operated on by his pupil and successor, and lost his eye by striking it while asleep.

Darkness of the apartment is a necessary condition well recognised, but it is too common to combine imperfect ventilation with it; the bed-curtains are drawn, every window is shut, the door kept closed, and a foul atmosphere is generated. Absolute darkness is unnecessary; there may be a degree of light that will enable a person to move about the room, without being injurious, and ventilation should always be secured.

Special instructions must be given to the patient to endeavor to keep the eyeball quiet, and to repress any inclinations to sneeze or to cough, and he should be apprised that there will be for a day or two an occasional gush of fluid from between the lids—aqueous humor, combined with lachrymal fluid—or the unexpected occurrence will excite alarm.

A trustworthy and judicious nurse must be provided—one who will observe quiet, not talk unnecessarily with the patient, so as to excite him, although she may read to him; who will not communicate subjects likely to create anxiety or produce mental emotion, and who will obey to the letter all orders respecting the patient's diet.

If at the usual bed-time of the first day there be restlessness and disinclination to sleep, I give an opiate, usually hyoscyamus, unless I find that narcotics are apt to disagree.

The nature of the aliment during the first few days is important; the usual practice is to prescribe slops, more under the

idea, I believe, that mastication is hurtful to the eye than anything else. In man, the action of the muscles of mastication cannot, I should say, in any way influence the eyeball. The more I see of practice, the more I am confirmed in the propriety of allowing the usual diet at the usual times, only in less quantities. An old person who is confined and fed on slops is almost certain to have his digestive organs deranged, and if so, will most assuredly suffer from injurious prostration of strength, which may, more or less, interfere with success. I have had proof enough that starvation is no safeguard against inflammation, while it seems frequently to retard or to prevent reparation. I am not aware that wholesome food given in a state of system capable of assimilating it will produce diseased action. In operating on the eyes of elderly persons at different periods, I have had several opportunities of comparing the effects of a low, and of a generous diet. Accustomed stimuli should not be absolutely prohibited; in some cases they may be requisite from the first. Aged persons may have a degree of prostration directly after the operation that demands stimulants followed by full diet.

From day to day the corners of the eye and the lower lid should be carefully cleaned with a bit of rag folded to form an angle, and dipped in warm water, and the surfaces afterwards wiped dry. Unless the edges of the lids absolutely require cleansing, the quiet of the eye will be better secured by leaving them untouched; their adhesion I regard as an advantage. The action of the bowels must be looked after, and if the third day arrives without an evacuation, a mild purgative, such as the compound rhubarb pill, a dose of castor oil, or any particular medicine known to agree, must be given, or an enema should be administered.

When five clear days have been passed without unfavorable symptoms, success is pretty certain, and on the seventh, after the edges of the lids have been thoroughly moistened with warm water, the patient may be allowed to open the eye in a subdued light, to test the result of the operation. The bed must then be resigned for the couch or arm-chair.

I am aware that so long a confinement to bed may be considered useless; but nowhere is a patient so secure from any accident to the eye. When it is remembered what is at stake, a few days passed in a recumbent posture should not be considered burdensome. I have found that when the bed is left, there is a risk of the patient acting imprudently. After the second day I have no objection to his rising to allow the bed to be made.

The pernicious practice of opening the eye at an early period cannot be too strongly deprecated. An examination of this kind must be useless if the progress is favorable; if otherwise, it is certain to aggravate the mischief, and in no instance can it disclose symptoms for guidance more certain and more valuable than those of the patient's sensations, and the state of the lids, particularly of the upper. Without any valid reason there is often a desire to see the cornea, but as this cannot be exposed by the patient voluntarily, the upper lid, which is always very tender, is raised, pain is produced, and involuntary resistance follows, attended by spasmodic action of the orbital muscles. Several times I have observed the first bad symptoms immediately after this unhappy mistake. If nothing worse ensues pain is sure to follow, which may last for hours or days. Should the cornea not be healed, prolapse of the iris by a gush of aqueous humor is most probable, and if already prolapsed there will almost certainly be an increase in the protrusion; but what is most to be feared is the accession of acute inflammation.

The admission of light to the eye must be carefully regulated and a large shade should be worn for some weeks. Exercise should be taken directly that circumstances will admit.

The occasional rapidity with which the cornea heals is astonishing.

An hospital patient, aged sixty-five, who submitted to operation on the 22d of the month, told me on the 25th that he had been trying his eye, and could see. The incision was united, and the chambers were filled with aqueous fluid, and on the 27th, contrary to my order, he left the house. A second patient, a female, aged eighty-two, finding on the third day, at

which period the cornea had united, that she could see well, was with difficulty kept in the hospital a day longer.

Restoration to sight after extraction is very often effected without any inconvenience beyond the necessary confinement; indeed, much pain rarely attends a successful case. Acute inflammation is the most common cause of failure: it usually appears early within the first twenty-four hours. It is generally thought that the conjunctiva is first attacked, and afterwards the proper textures of the globe. Almost suddenly, acute pain is felt in the eyeball, then in and around the orbit, and the lids begin to swell and inflame, and are soon very red. Purulent discharge follows, and the vascular and nervous systems become deranged. The worst result is the infiltration of the cornea with pus, and suppuration within the globe. The accompanying pain is generally, in spite of all treatment, most intense. A less distressing termination is thickening of the capsule of the lens with adhesion of its divided portions; or adhesion of the capsule to the iris; or closure of the pupil from inflammation. In every particular this state resembles that of acute inflammation consequent on accidental injury, the treatment of which, already given in Chapter III., must be followed here, with the exception of the use of antimony, as this drug may induce vomiting; for the same reason, too, venesection should not be allowed to produce fainting. It is said that mercury will interfere with the healing of the cornea, and is, therefore, contra-indicated: that this mineral does not check the healing process, or suspend repair in the eye, or elsewhere, is now too well known to require proof in this place. Except as a purgative, however, it is scarcely ever available, for if the acute inflammatory action be not cut short at once, there is little chance of saving the eye, as general inflammation of the eyeball of traumatic origin very rapidly attains that intensity which disorganizes the eye. Bloodletting and the sedative effect of the local application of the watery extract of opium, purgation after the principles already laid down, low diet, and cold applications, all of which should be

regulated by the severity of the attack, are the means, in the present state of our knowledge, most to be relied on; but in spite of the judicious use of all the therapeutic means at our disposal, an accession of violent inflammation is almost beyond our control, and is sure to produce more or less damage to the eye. If, at the first onset of inflammation, decisive and energetic treatment do not subdue it, all hopes of success must be resigned, and the importance of not unnecessarily depleting a patient should be taken into full consideration. Inflammation may appear some days after the operation; such an attack is generally considered to be iritis, because the most palpable termination is closure of the pupil, but it is in fact inflammation of the whole eyeball, and here, in conjunction with depletion, mercury is available. A slight attack of conjunctival inflammation is not very uncommon when patients begin to move about, or expose themselves imprudently to noxious influences, such as the heat of the fire, fatigue, excitement, and undue indulgence in drinking; and, unless the symptoms be threatening, I generally rely on cold applications and the recumbent posture. These slight paroxysms are often misunderstood, and supposed to be the commencement of a violent attack, and the patient treated accordingly; but so long as pain is not the leading symptom, there need not be any apprehension.

Subacute inflammation, which seems to be determined by the low state of the patient's vitality, demands, if possible, more attention than the last, because it is more common, is frequently mistaken for the acute, and is more under the control of remedies. To Mr. Tyrrell is due the credit of first clearly pointing out that there are two distinctly recognisable forms of inflammation that attack the eye after operation, both equally painful and destructive, and each requiring distinct treatment: a fact which he never lost an opportunity of endeavoring to impress on his pupils. The acute inflammation appears at an earlier period; the lids are bright red, and the secretion is purulent. The subacute comes on some days after the operation; the swollen lids have scarcely a blush of inflammation, being rather of a darkish hue,

and infiltrated with serum, the upper one exhibiting this the most. The cornea is generally hazy, the wound not healed, and its edges ragged. The secretion is thin, and the conjunctiva, although chemosed, scarcely vascular. These characters will offer sufficient guidance for treatment, and render it unnecessary to open the eye to see what are the changes within. The state of the system is the reverse of that in the acute attack; the circulation is feeble and languid, and the extremities devoid of their natural warmth. I repeat here that the habitual hard pulse of the aged should not be allowed to deceive, when the condition of the lids and the feelings of the patient, indicate that general power is required. In no other set of cases narrated in Mr. Tyrrell's work is the effect of treatment more clearly and certainly shown, than in those of subacute inflammation occurring after extraction. His practice was to give strong broth or other nutritious matter in solution, with beer, wine, or spirits; medicinally he prescribed carbonate of ammonia, and, when there was restlessness, he combined opium. But I do not confine the aliment to fluid substances when the digestive organs can receive solid food, for then there is the advantage of giving a more mixed and varied diet.

As the well-marked extremes of the acute and subacute forms of inflammation do not, of course, always exist, the local and general symptoms may not afford sufficient criterion for the precise line of treatment, and it is here that bloodletting and purgatives to subdue pain, may seal the fate of the eye. To test the genuineness of such doubtful cases, Mr. Tyrrell used to give large doses of the carbonate of ammonia—eight, or even ten grains, with or without opium, as might be thought proper; by this he found the acute disease aggravated, and the subacute at once relieved. If a patient complains of more soreness and uneasiness about the eye than is generally inseparable from the operation, I order a full dose of hyoscyamus and wait the result. The feelings of a patient after taking food may in some measure furnish evidence of the condition of his system; for example, in the case of a private patient who complained of pain, it was

rather questionable what plan of treatment should be pursued, but all doubt was dispelled when he told me that the pain in the eye and the headache were for a time dissipated by food, and that this had occurred three times; the hint was acted on, and the rather spare rations advantageously augmented. Cinchona is a valuable medicine in the subacute forms of inflammation with depression of the system, and the "*infusum cinchonæ spissatum*" of the present London Pharmacopœia, is an excellent preparation, far superior to the preparations by Battley, which have been considerably over-estimated, and possesses very much less virtue than they are reputed to have.

Prolapsus of the iris is the most frequent cause both of temporary failure and imperfect success, and this whether the prolapsus occur at the period of the operation, or subsequently. With protrusion of the iris the pupil is necessarily displaced, altered in form, and restricted in motion, and the nearer it is dragged to the margin of the cornea, and the smaller the opening that remains, the less perfect will vision be. The prolapse may entirely destroy the pupil; or, on the other hand, though displaced and irregular, it may be enlarged much beyond its natural size, especially when the iris, without protruding, contracts an adhesion to the line of incision of the cornea; the chief disadvantage of this accident is, that the pupil is a little irregular, and cannot contract and dilate freely with varying degrees of light. Such an adhesion frequently follows a wound of the iris. The principal causes of secondary protrusion are rough handling of the eye; opening it, or allowing the patient to open it before the corneal section is healed; subacute inflammation; straining efforts; pressure of any sort on the eye, or sudden action of the orbital muscles; but it may frequently happen when there does not seem to have been any reason for it. Surgeons are now and then surprised to find the prolapse appear after the patient has been allowed to move about, the cornea being supposed to have healed, but evidently in such instances the wound has not united thoroughly. To prevent this the patient should be restrained from using the eye until the anterior chamber is of the natural

size, for that is the only test of the cornea having healed. So long as the iris is in contact with the cornea, unless there is a prolapse, the aqueous fluid is passing away, and the closure of the wound is yet imperfect.

With prolapse of the iris tedious recovery is a pretty sure consequence, owing to the delay of the healing process, which, in such cases, will depend more on the position in which the iris lies, and the degree to which the edges of the cornea are separated, than on the amount of the protrusion.

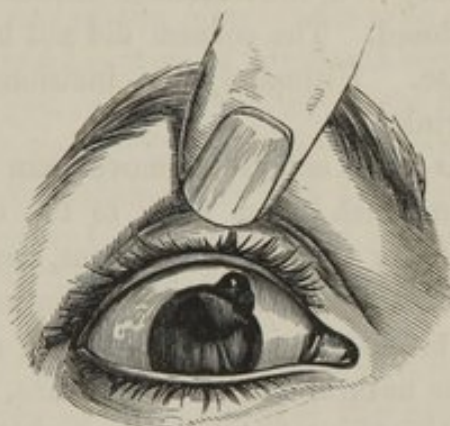After watching very carefully, many cases of prolapse, both after extraction, and the result of accidents in which the cornea has been divided or ruptured, and after noticing the different kinds of treatment that have been adopted by surgeons, I feel as certain as one can be on such a point, that those in which there has been no additional irritation, produced either by the use of nitrate of silver in substance or solution, or of any other drug, make the best recoveries.* I have, therefore, left off all local applications, endeavoring merely to keep the eye quiet. Nor do I snip away any of the protruding membrane, for whatever is not needed in the formation of a proper cicatrix, is sure to be neatly and efficiently removed by a natural process, and with a better result than if interfered with by art. The only occasion in which I venture to interfere is when, in a recent case, the iris bulges considerably by the pressure of the aqueous fluid, and forms what is called *staphyloma iridis*; then pricking the tumor and giving vent to the fluid as often as it reaccumulates may be followed by reduction. In very aggravated cases of prolapse, accompanied by considerable projection of the flap of the cornea, so effectual may be the reparation in a few months that all trace of the tumor may disappear, a slight cicatrix at the edge of the cornea being all that testifies to the alteration. Good vision is not incompatible with very marked prolapse; the

* In *prolapsus iridis* from ulceration of the cornea, the iris recedes as the vascular turgescence subsides; and no interference is required, beyond the application of belladonna over the brow, keeping both eyes closed, and such general measures as tend to restore the tone of the system.—ED.

following figure, which shows a very remarkable displacement, with considerable separation of the edges of the cornea, illustrates this.

The subject was a lady who had been operated on by Mr. Tyrrell, about sixteen years prior to my having the sketch taken; the other eye was lost; with this eye she sees to read and write, notwithstanding that the greater part of the pupil is covered when the upper lid is free. The protruded iris, which

Fig. 119.



is coated by a delicate white cicatrix, forms a boundary of the anterior chamber.

Irregularity of the pupil sometimes occurs after extraction, without prolapse of the iris, or adhesion of it to the cornea, in consequence of the injury sustained from stretching, during the escape of the cataract. The irregularity generally corresponds to the spot over which the cataract has passed, just, in fact, where the greatest stretching has occurred, and is therefore in the direction of the incision of the cornea.

Imperfect union of the cornea is the last cause of failure to be examined. The period at which union is effected varies from the second to the fourth or fifth day, and if this limit be exceeded, the eye is in danger of subacute inflammation and prolapse of the iris. There may not, at the end of this time, be the slightest attempt at union, the cornea appearing as it does

immediately after the operation, or it may be a little hazy. The kind of inflammation which follows seems to indicate that the fault is constitutional.

On the 30th of November, 1843, I performed the double operation of extraction in an elderly female, who seemed to make favorable progress, but when the eyes were opened, the corneæ were not united. On the 31st of December the right cornea had not quite healed, and the aqueous humor spirted out in a fine stream through a kind of fistula. In the left eye there was even less adhesion. Very low inflammation attacked each eye, and the pupils were closed. The corneæ did not become opaque as is usually the case. Ultimately the incisions closed, and the globes did not shrink.

An eye that has had a cataract removed can never be restored to the condition in which it was prior to the disease; the artificial compensation for the loss of the lens, cannot enable it to exercise that rapid adaptation of focus from near to distant objects, which is so essential for accurate vision, and so beautifully provided for in the natural state. There are, however, degrees of favorable result, ranging from excellent vision—the eye being capable of seeing any body however minute, or however far, that could be discovered before it was affected with cataract—to sight enough for the ordinary purposes of life, but scarcely sufficient for viewing minute objects. Glasses of two foci are always required, the one for reading, writing, or examining near objects, the other for looking at distant ones. These facts should always be pointed out to the patient or his friends, for the popular idea of cataract is that a scale or film grows over the eye, on the removal of which the organ may be as good as ever, and the necessity for spectacles is not generally understood.

A surgeon should be cautious, even under the most favorable circumstances, never to overrate the chances of success of any operation for cataract, nor to allow it to be thought that any is infallible; and above all, when there is the slightest indication which would render the result questionable or imperfect, owing

to individual peculiarity, or constitutional taint, hereditary or acquired, it is essential that all the particulars for and against operating, should be stated clearly and intelligibly. The following case illustrates a happy escape of the eye from the effects of constitutional disorder:—

At the commencement of the spring, a man, sixty-two years old, who applied at the Central London Ophthalmic Hospital with hard cataracts, showed the remains of gout about his hands by the presence of chalk-stones in every finger; I was unwilling to operate, and explained my objections to him, but as there had not been a paroxysm of the disorder for nine months, and as his health was good and his state of blindness could not be worse, I extracted in one eye. On the evening of the third day his hands were severely attacked by the old enemy, but fortunately the eye was not in the least inflamed, and on the eighth day, when he was allowed to try it, I ascertained that he had excellent sight. He continued well, and he was soon able to pursue his trade.

The operation of extraction may be required under the less favorable condition of dislocation of the cataract; for certain changes in the eye, by which the vitreous humor is degenerated, and the suspensory ligament is ruptured, may cause the opaque lens to fall into the anterior chamber, or to rest on the iris, and produce a degree of irritation that demands removal. These are not common cases, but any one who sees large numbers of ophthalmic patients will occasionally meet with them. In an instance, under my own care, of a female seventy years old, the cataract was partly detached, and swung by a lateral connexion; sometimes being just behind the pupil, sometimes nearly out of the field of vision. This state had probably existed three months when I saw her, and the eye now began to suffer from the occasional pressure of the cataract on the iris. There could be little doubt that in the other eye, about a year before, the cataract had dropped into the vitreous humor. The vision in each eye was tolerably good. I lost sight of my patient after a few visits.


Among other cases related by Mr. Bowman, in his "Anatomy

of the parts concerned in the operations on the Eye," is one in which there was loosening of the suspensory ligament of the lens in both eyes, with dislocation of one of the lenses into the anterior chamber, and singular mobility of the other, which fell out of the axis of vision in certain positions of the head, but yet retained its transparency, as proved by the catoptrical test. If the displaced body be in the posterior chamber, I recommend an attempt to bring it forwards through the pupil, and the kind of needle with which this should be done whether straight or curved, as well as the place of its introduction, whether through the cornea or sclerotica, must in a great measure depend on the circumstances of the case, and be left to the judgment of the operator: the anterior operation should be preferred when practicable. When the lens is in the anterior chamber, the opening in the cornea for its removal should, if possible, be made at a spot opposite to the site it occupies, and be ample; the peculiar circumstances demanding a very easy exit for it.

Extraction may also be required for the removal of the nucleus of a lens, or of portions of it, or for the extrication of foreign bodies, and as this almost certainly requires the employment of the curette, a hook, or some similar instrument, an aperture in the cornea, larger than would be supposed, is needed. Here, as in the extraction of a cataract, success depends mainly on the facility with which the body is removed.

The late Mr. Walker recommended the use of a grooved

Fig. 120.



needle-knife for the extraction of a soft lens when dislocated into the posterior chamber, and Mr. Wilde, in the "Dublin Journal" for 1847, speaks highly of it, and gives the following case of traumatic injury to the eye of a man aged thirty-two, in which he used it with success. The iris was bulged forwards by the lens, which had been broken and softened, and partly protruded

through the pupil, overlapping its edge so as to give it an irregular and deformed appearance. The violence of the symptoms demanded the extraction of the lens, and the grooved needle was introduced at the under and outer side of the cornea, pushed through the centre of the lens, and through the posterior capsule. The effect was instantaneous. The aqueous fluid and the opaque and softened lens were immediately discharged along the groove in the knife. Great relief followed, and the report, twelve days after, states—"Sight nearly as good as ever, inflammation almost gone, no pain, nor any uneasiness; capsule disappearing."

The preceding figure represents the needle now sold by Messrs. Weiss as Mr. Walker's, but it is smaller than that figured by Mr. Wilde, and the groove is very much narrower.

The irritability of the eye in these cases may induce an voluntary resistance that renders it impossible to operate with any chance of success, unless the patient is narcotised; the risk of injury to the eye from vomiting, is not to be compared to the danger of operating without chloroform.

OPERATION FOR DISPLACEMENT.

NEEDLE FOR RECLINATION.

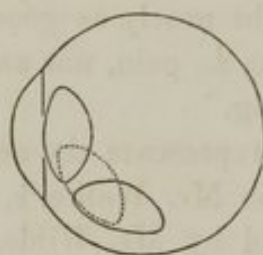
It is obvious that a curved needle is better adapted to displace the lens into the vitreous humor below the level of a pupil, than a straight one, and were this the only circumstance to be regarded, the form of the curve would matter little; but the important condition in the operation,—that the point of the needle be disengaged from the cataract when displaced, without further influencing its position,—establishes, I think, a ground of preference in favor of the instrument I here

Fig. 121.



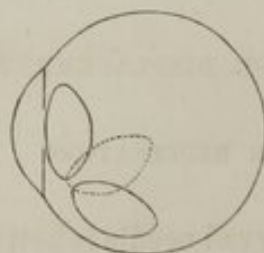show. A gradually curved extremity, while it affords great facility for readily disengaging the point, allows the needle to enter the eye very easily, and renders it less dangerous to be used. The entire length need not exceed three-quarters of an inch, and the breadth of the broadest part, the thirty-fifth of an inch. The point only should be sharp, the extremity wedge-shaped, and the body conical.

Fig. 122.



There are three ways of producing displacement: the oldest and now almost exploded method, "depression," is to press the cataract downwards till it disappears, as is meant to be shown in the above diagram.

Fig. 123.



The second, "reclination," disposes of the cataract by tilting it backwards, and carrying the upper edge downwards, after the manner illustrated in the second diagram.

In the third, the cataract is pierced, and carried down in an oblique position, as represented in the following figure.

These diagrams must be regarded as demonstrating merely

the theory of the several operations, for, in reality, the cataracts do not pass through the many positions that are figured, so as ultimately to rest just at the desired situations; there is the greatest uncertainty where they may actually go, especially in depression, an operation that I shall not describe, since, owing to the difficulty of pushing the cataract below the pupil,

Fig. 124.



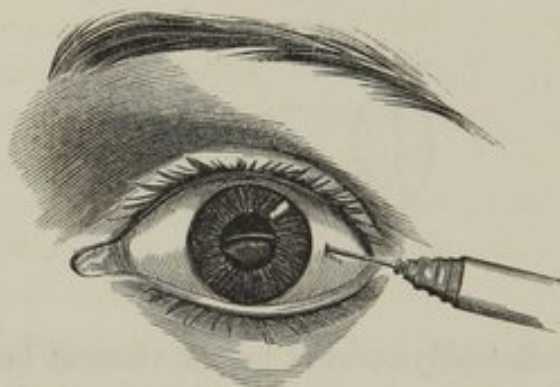
and getting it sufficiently covered by the vitreous humor without forcing it against the nervous coat of the eye, it is now superseded. Although the retina is very much less likely to be touched by a reclined, than by a depressed cataract, the vitreous humor suffers more lesion by reclination, especially if it be healthy.

For the performance of reclination the curved needle alone is required. It is indispensable that the pupil be fully dilated. An anterior operation through the cornea has been proposed and adopted, but is most inappropriate: it is only by passing the instrument through the sclerotica that sufficient command can be obtained for proper displacement. The position of the patient, that of the operator, and the manner of securing the lids and fixing the eye, are precisely the same as if extraction were to be performed.

The needle, which should be held with the convexity upwards, and the handle a little depressed, to render the entrance of the curve more easy, is introduced exactly in the transverse axis of

the globe, about the sixteenth of an inch behind the cornea,* in which position injury will not be inflicted on the ciliary processes, retina, or long ciliary arteries, which vessels bifurcate posteriorly; it is directed inwards to the centre of the vitreous humor, the point carried forward, and made to appear between the upper part of the cataract and the iris, when it is turned,

Fig. 125.



and its concavity applied just above the centre of the cataract, which must first be tilted, and afterwards pressed backwards and downwards, as is shown in the illustration, Fig. 125, and made to assume a position as nearly as possible resembling that represented in the diagram, Fig. 123. The needle must be kept on the cataract for a few seconds, and then liberated by a slight rotatory motion, raised to the centre of the eye, and

* The direction usually given is, to perform the puncturation farther from the cornea, and at a distance varying from a line and a half to two lines. The ciliary processes extend backwards as far as the eighth of an inch, and could hardly escape injury if the puncture were made nearer than the point last mentioned. It is also commonly recommended to introduce the needle a little above or below the transverse diameter of the eye; but as the long ciliary artery of the temporal side divides a quarter of an inch from the iris at an acute angle into two branches, it is obvious, Mr. Jones remarks, that the vessel itself cannot be wounded, and the surest way to avoid the branches, is to enter the instrument, as Mr. Walton also advises, in the line of the transverse diameter.—Ed.

withdrawn. Each step of the process should be effected very slowly.

Should the cataract rise as soon as the needle is disengaged, the reclination must be repeated till it remain displaced; and if, after several trials, it still reascends, as a last attempt the needle must be passed upwards and downwards, between its posterior part and the vitreous humor, to make a cavity for its reception.* Some operators even think it necessary to lacerate the posterior part of the capsule before commencing the reclination. The reascension of the cataract is owing to the resistance offered by the vitreous humor, which must be in a healthy state to possess this elasticity. Probably the correct practice would be to rupture the vitreous body for the reception of the cataract, as soon as it is perceived that its elasticity offers an impediment to the displacement. If the anterior part of the capsule have not been sufficiently torn in the first instance to allow of a clear pupil, the needle must be applied to it before being withdrawn; the cap-

* To obviate these difficulties, which arise from the resistance of the capsule and the firm adherence of the suspensory ligament of the lens to the ciliary body, and not as stated in the text, to the resiliency of the vitreous humor, Mr. Watson directs a breach to be made, as a preliminary measure, in the posterior part of the capsule and in the vitreous humor, for the escape and reception of the crystalline; and this recommendation, which we have successfully adopted in practice, is sanctioned also by the authority of Dr. Mackenzie. "No attempt," he observes, "should be made to dislocate the lens, till a sufficient opening has been effected in the posterior capsule; the lens should then be reclined; and lastly, if the anterior capsule is opaque, it should be broken up. If it is transparent, as the natural boundary of the aqueous lens, and on the principle of damaging the internal textures of the organ as little as possible, and of inflicting no unnecessary injury, it should be left entire. Tilting away at the entire lenticular body, in repeated attempts at reclination, must often end in tearing the suspensory ligament from the choroid, and lead to destructive inflammation of the eyeball. No wonder that operations for displacement are so generally unsuccessful as we believe them to be, when a plan of operation so utterly regardless of the structure of the parts concerned is adopted!"

Inasmuch as the anterior capsule though transparent at the time, would almost certainly become opaque from the injury necessarily inflicted in the operation, we should prefer its laceration while yet the elasticity of the membrane continued unimpaired.—ED.

sule may, if opaque, accompany the lens. Should the cataract be accidentally projected into the anterior chamber, it must be extracted; the iris being behind the cataract, and necessarily far from the cornea, is not in danger of being wounded during the section of the cornea.

The cataract may fall in pieces under the pressure of the needle; it would be impossible to effect the depression of the fragments, and all that can be done is to leave them alone, unless they enter the anterior chamber and produce irritation, when extraction is the proper course.

Complete pupillary adhesion renders displacement as inapplicable as extraction, for independently of the pupil being so small, that it would be impossible to see that the instrument is in its proper course, the iris must be considerably damaged before the needle could be made to appear in front of the cataract; and if the capsule were opaque and thickened, as in all probability it would be, it is more likely that the iris would separate from its ciliary attachments, than that the pupillary adhesions or the thickened capsule would give way under the pressure. "Drilling," a modification of the operation for solution, is then alone applicable. It does not appear to me, that one or two, or even more slight adhesions contra-indicate reclination, if the capsule of the lens is not much thickened; and I should not attempt to break them down with the needle, as some surgeons have recommended.

The other operation for displacement requires the employment of a straight needle, such as that which I shall figure as a straight solution needle; it is introduced through the sclerotica as far as in reclination, but instead of being carried to the centre of the vitreous humor for the purpose of avoiding the cataract, it is purposely passed by a rotatory motion into the opaque body, the lower part of which is turned backwards, and in that oblique position the cataract is carried downwards just below the edge of the pupil, when the needle is to be most carefully withdrawn.

This is supposed to be a modern operation, and is called the operation of Egerton, who has of late years practised it in Calcutta: I believe that the first notice of it in England was by Mr. Morgan, in the "Guy's Hospital Reports" for April 1842. Whilst I attended the practice of the late Mr. Scott, in 1841, he used to adopt this method, a little modified and improved, and allusion is made to it in his work on Cataract, published in 1843. He thought it better not to transfix the cataract, on account of the danger of accidental dislocation, and the greater difficulty in subsequently detaching the needle, and recommended that it should be pierced only to such a depth as will enable it to be carried backwards. If the needle can be introduced into two-thirds of the cataract, sufficient command will then be obtained for the displacement; when it cannot be so used, the operation is not admissible.

The reputed advantages of Egerton's plan are the less amount of injury to the hyaloid membrane, the greater facility with which the cataract can be placed in any position, the less probability of its rising, owing to the upper surface being covered by an unbroken part of the vitreous body, and the less chance of injury to the retina from any accidental malposition of the cataract. It is better to lacerate the anterior part of the capsule on an after occasion, through the cornea; for the risk there might be of the cataract being touched and returned to its place is thus removed.

These operations are likely to be followed by vomiting, and it is well to forewarn the patient of the probability of the occurrence.

Blood may be effused within the eye, but it is usually readily absorbed; a coagulum deposited under the conjunctiva at the spot where the needle entered the eye, need not excite any fear, for it also readily disappears. Should a fungus be thrown out at the wound, and remain after sufficient time has been allowed for its spontaneous disappearance, an escharotic should be applied.

It is a grave objection to displacement, that in performing it the interior of a healthy eye must necessarily be considerably damaged. No condition of the vitreous humor can be said to be favorable to the operation. When from morbid change it yields readily to pressure, there is danger of the cataract gravitating, and resting on the retina; or floating about, and producing constant annoyance by temporarily interrupting vision, besides it is then peculiarly liable to be dislocated through the pupil.

It is not surprising that acute inflammation of some or of all the textures of the globe, with its destructive consequences, should sometimes immediately follow displacement, and be as baneful as the most acute attack after extraction; but what is most to be dreaded is a low, but certainly destructive, inflammation coming on at a later period, from pressure of the cataract on the iris, ciliary processes, or retina; from violence done to the structure of the vitreous humor; or from irritation occasioned by the unnatural position of the displaced body, in which case there will be all the symptoms that would occur if a foreign body were driven into the eye. The cataract may, in its new place, undergo partial or even entire absorption, and for this it must have been stripped of its capsule. So long, therefore, as it is undissolved, and many years may pass with scarcely any change being effected, there is danger of this low inflammation. Of the treatment, Dr. Mackenzie writes, "if the practitioner who has performed depression or reclamation, sees reason to suspect that the very means which he had adopted for restoring vision, threaten to destroy it, he ought not to hesitate about withdrawing the displaced lens from the eye entirely. Introducing a bent needle through the sclerotica, the cataract is to be raised to its former situation, pressed forward through the pupil and kept in contact with the cornea till a section is made, a hook introduced, and the lens laid hold of, so that it may be extracted." Moreover, from falls, blows on the head, or even without an apparent cause, the cataract may reascend in the track by which it was displaced, or pass into the anterior chamber, and require again to be thrust

back, or extracted; therefore, with all these contingencies, success can never be counted on. Neither repetition of the displacement nor extraction, should, in my opinion, be hastily done when a cataract reascends, except in the very aged—in whom, from the greater density of the lens at that period of life, its solution does not readily take place—or unless much irritation ensues, but the case should merely be watched, as experience justifies our giving a trial to the process of disintegration in an emergency like this.

The after-treatment is the same as that for extraction; quietude in bed is essential, for it is within the first week that there is the greatest likelihood of the cataract resuming its former place; and then it is that there is the most imminent danger of inflammation from its presence in either of the chambers of the eye, in consequence of the violence the operation has inflicted.

OPERATIONS FOR SOLUTION.

NEEDLES FOR SOLUTION.

STRAIGHT NEEDLE.

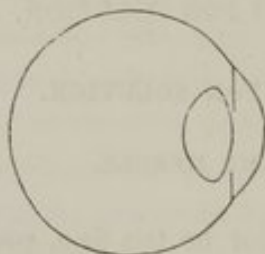
Solution needles cannot be too fine, provided they are strong enough to be guided with precision. The advantage of their delicacy was first strongly pointed out by Dr. Jacob, who, at an early period of his professional career, became strongly impressed with the injurious size of the needles in common use, and, being unable to procure what he desired, produced his well-known instrument, made out of an ordinary fine sewing needle. Dr. Jacob's views on this subject, first published, I believe, in vol. iv. of the "Dublin Hospital Reports," have been made known through many channels. The latest account, however, is contained in a

Fig. 126.



monograph on the operation for cataract with a fine sewing needle through the cornea, printed last year at the office of the "Dublin Medical Press." In this publication the difficulty of introducing the needle from its roundness—and it is round throughout even to the point—and the risk of wounding or transfixing the iris, owing to the force necessary for its introduction, are fully described. These are certainly serious objections, but they are overcome by our present instrument makers, who can produce a needle equalling Dr. Jacob's in size and strength, surpassing it in sharpness, and superior to it in shape. Such is the kind of needle shown at Fig. 126: the body is conical, the largest part about the fortieth of an inch in thickness, the extremity is wedge-shaped, and the point angular. The length, five-eighths of an inch, is as great as is consistent with sufficient stiffness, and ample for the use to which it is to be applied, as may be seen by reference to figure 127, which is intended to show the size and position of the lens, and the distance required to be traversed by a needle to reach the centre of that body.

Fig. 127.



It is supposed that a cataract needle may be made with cutting surfaces above its shoulders. Such an instrument would, however, be useless; but it is impossible to put a keen knife-edge on the sides of a small needle. I speak on the authority of Mr. Weiss when I say that the needle which is sold and used under the impression of its being sharp above the shoulders, is merely thinned, or rolled off, but not sharp.

CURVED NEEDLE.

A curved needle, although neither so readily introduced, nor used with such precision as a straight one, is sometimes required, and should differ from the straight only in shape, and in the absence of shoulders, as in figure 128; it is scarcely practicable, so say the instrument-makers, to make it with an angular point like the straight one.

I find that many surgeons suppose the bent sewing needle of Jacob to possess peculiar appropriateness of temper: the idea is drawn from the circumstance that out of many papers of needles, each of which generally contains twenty-five, not one may take the bend when cold. I have known nearly two hundred broken before the curve could be obtained. This temper, only an accidental result in a few among masses prepared at a time, is just above what the needle-manufacturer desires, what in fact he avoids, but which can always be secured by the surgical instrument-maker. Jacob's needle is not, in reality, the best, for it does not take the keenest edge; nor is it less liable to break, than an instrument forged by a good maker.

A cataract exhibiting the characteristics of softness is effectually removed through the process of absorption, by opening its capsule, and allowing the aqueous humor to come in contact with it.

There are two methods of operating, one through the cornea, another through the sclerotica; these are respectively designated anterior and posterior operations.

The anterior operation is more definite and simple, is less painful, inflicts less injury on the eye, for only one of its coats

Fig. 128.

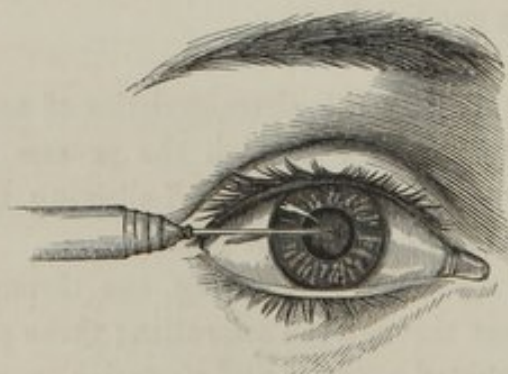


is punctured, can be done as effectually, and quicker than the other, the instrument never being out of view, and is also followed by less inflammation. It is moreover the easiest and safest of all operations for cataract, and is very generally applicable; I shall speak of it first.

The pupil should always be well dilated, not only to expose the cataract, but to place the iris out of the way of the needle. Whether the one or the other kind of needle shall be used, seems to be generally determined by the fancy of the operator: that either may do, is proved by the fact that each is exclusively used by different surgeons. There is, notwithstanding, a certain difference in their power which may be turned to decided advantage in particular cases; with the curved one a cataract can be more comminuted, and with less tearing of the capsule and less chance of dislocation of its nucleus, should there be one, than with the straight. The straight instrument is preferable, principally from being much easier to use.

The eye being steadied, and all the preliminaries arranged as for the other operations on cataract, the needle (the straight one) is introduced through the cornea near its circumference, the point carried through the pupil to the cataract, as in the following sketch, and used according to the circumstances of the case.

Fig. 129.



The curved needle should be introduced with the concavity upwards, that the stem may pass parallel to the iris, so as to avoid

injuring it, and when the pupil is reached, by a slight turn of the handle the point is brought on the cataract.

If the needle is kept well adapted to the wound in the cornea, the aqueous humor will not escape till the cataract has been pierced and the withdrawal is commenced. Should the humor have come away prematurely, the needle must be removed, and the operation delayed. Again, if the iris be wounded, and blood obscure the cataract, the operation must be deferred.

At a first operation, all that seems desirable is to make a small slit in the centre of the capsule, and to penetrate the lens by a rotatory movement of the needle, sufficiently deeply to admit the aqueous humor to its texture without displacing any portion of it, because of the irritation which the fragments might produce. This will most likely cause opacity of the capsule, if it be not already opaque, and render the cataract still more cloudy. When the cataract has become very soft in its superficies, some of the degenerated matter may fall into the chambers of the eye, especially the anterior, and becoming flocculent, will soon be absorbed.

Should the degeneration have gone a stage further, and passed into fluidity, the part so altered will inevitably escape when the capsule is punctured, and render the aqueous fluid more or less turbid. Vomiting, attended with great pain in the eye and sometimes around the orbit, is very frequently attendant on the escape of the fluid contents of the capsule, but it may occur merely from the use of the needle, without lenticular matter of any kind having fallen into either of the chambers. The vomiting may be severe and last even for days, and opium is the only drug to which I have seen it yield. Mr. Dalrymple notices this distressing consequence, but he seems to speak of it in connexion only with an operation on a fluid, or partially fluid, cataract. I quote his own words on the subject:—

“There are some peculiarities which belong to this variety, which it is necessary to mention. If an opening be made into the capsule, as in the operation of keratonyxis, we see the opaque fluid escape, and render turbid that of the anterior chamber. In a few

hours after the operation, the patient is seized with nausea and violent vomiting, and with intense ocular or frontal neuralgia. This is so constant an accompaniment of this form of operation, that it is necessary to forewarn the patient of the probability of its occurrence. Opium and ammonia, in full doses, will sometimes relieve the patient; and if the suffering be considerable we may even evacuate the fluid of the anterior chamber by a puncture with a broad needle. In one case I remember to have seen the vomiting and neuralgia continue almost unremittingly for three days. At the end of a week, however, the whole anterior chamber became clear by absorption of the opaque fluid, and vision was beautifully restored. Upon what circumstance these phenomena depend, is wholly unknown to us; that it must, however, be closely connected with the poisonous presence of the contents of the capsule in a cavity, in which absorption and reproduction are always going on, does not admit of a doubt; for if such a cataract be removed by extraction, in which case the capsule generally escapes entire, no such state follows."

The occupation of the anterior chamber by a part of, or an entire cataract, is of little moment, compared with the disturbance that may ensue when the posterior chamber is the site, principally, it would seem, from pressure on the iris; a cataract or its nucleus, when so situated, and producing irritation likely to destroy the eye, must, if possible, be depressed, or brought into the anterior chamber by a needle, and extracted—alternatives, I am happy to say, that have never been forced on me.

The danger of exciting inflammation from dislocation of the lens, or even any portion of the lenticular tissue that has not become fluid, was constantly insisted on by Mr. Saunders, and is frequently reiterated by Dr. Farre, who edited his method of treating congenital cataract, and who lays down the axiom that solution and absorption are best accomplished when the lens is in its natural position. Were this truth generally received, taught, and acted on, a mere notice of it here would be sufficient; but I know that it is disregarded by many who operate for cata-

ract. The following passage from Dr. Jacob's writings, while it confirms Mr. Saunders' views, shows also that they are not generally received.

"The surgeon who would succeed in restoring vision, by exposing the lens to the contact of the aqueous humor, should never forget that the most formidable impediment to his success is the inflammation which follows the operation; and that his aim should therefore be to accomplish his object with the least possible injury to the organ. He must also recollect that the lens displaced, whether whole or in fragments, is equivalent to a foreign body in the eye, and must therefore be so disposed that it shall not press on the iris. A notion very generally prevails, which I cannot but call a very mistaken one, that it is necessary to place the fragments of the lens in the anterior chamber to accomplish their solution and absorption. The inexperienced operator may rest assured that if he adopts such practice indiscriminately he will have reason to repent of it.

"I have frequently had an opportunity of witnessing the solution of cataract *in situ* after the capsule had been opened, and I could with a magnifying glass observe from day to day the change in form which occurred from the removal of particles of cataract, until at last a portion had disappeared, and left a passage for the light. In such a case I observed three several times, that when a small fragment fell out of the capsule into the anterior chamber, pain and slight inflammation supervened, and continued until the particle was absorbed."

I suspect that the only condition under which a cataract can be absorbed without coexisting inflammation to some degree, however slight, is when it remains in its capsule, and is there exposed to the action of the aqueous humor. Our present knowledge of the pathology of cataract tends to show, that the lens will be doubly acted on when in its place, the opaque capsule, as well as the aqueous humor, effecting its reduction; for we have abundant evidence that a lens may be removed from an unbroken capsule.

Dislocation of the lens during the operation is very readily effected, and is almost sure to ensue unless certain precautions are observed; the most important of these is not to make a large aperture in the capsule so long as it retains its elasticity, for unless the breach be minute, there is great danger of an accidental increase in the opening by rupture, which will most likely allow the lens or a portion of it, to escape. When the capsule is opaque, and consequently has lost much or all of its elasticity and liability to rupture, a large aperture will have the advantage of giving freer entrance to the aqueous humor, and, I may say, is necessary, to obviate the tendency of a wound in a capsule so altered to unite. Not to carry the needle too deeply, nor to move it about too freely on the cataract, are further precautions against dislocation, to which must be added general delicacy of manipulation, in every step of the operation.

A reason commonly assigned for free laceration of the capsule in the first instance, is that the pupil is better cleared from this membrane, after the cataract is absorbed; but the theory is unsound, and even if it were correct, the evils attendant on dislocation of the cataract would more than counterbalance any such little advantage; however, now a-days, from our superior appliances for the removal of capsule when in the way, that question need not be entertained.

The softness of cataract in infancy, owing to which there is so much less danger of the effects of inflammation from the lenticular substance being in the chambers of the eye, as well as the little likelihood of inflammation consequent upon the operation itself, have induced some surgeons to recommend that the needle be very freely used to break up the cataract, and at the same time to eject the fragments from the capsule; but even here the safer plan, and I am not sure of its not being the quicker also, is to endeavor to procure absorption with the cataract in its place.

The posterior operation for solution is performed precisely like that for displacement, except that when the needle is brought

in front of the cataract, it is used for laceration instead of re-clination. This method is generally advocated solely on the score of affording greater facility for breaking up the cataract ; hence it is recommended for infants, and some surgeons always practise it upon them. Mr. Tyrrell told me, shortly before his death, that he had operated on eight infants with congenital lenticular cataract, performing the posterior operation in one eye of each, and the anterior in the other ; the result was that all did well, but those in which the posterior was performed, and the lens broken up and displaced, were cured the soonest. From this it is apparent that time only was saved by the posterior operation ; a matter not of much importance, and the value of which cannot for a moment be insisted on in the present case, from the want of precise evidence as to the subsequent power of vision in the respective eyes. From Mr. Tyrrell's writings his own opinion of the merits of the two operations cannot be arrived at, for the passages relating to them are contradictory.

I give a very decided preference to the anterior operation for the reasons already stated ; by it the lens can be broken up to any extent that is necessary, if the curved needle be used, and with greater ease, I believe, than in the posterior operation. Mr. Saunders preferred it. The only reason why he ever used the posterior, was from the supposed greater facility with which the lens could be comminuted. We are informed by Dr. Farre that "he finally attempted to diminish inflammation by performing his anterior instead of his posterior operation."

There is not, perhaps, any surgeon living who has paid so much attention to needle operations, as Dr. Jacob of Dublin ; the following quotation from his little work on the operation for cataract, before spoken of, expresses his opinion on the comparative value of these operations.

"No anatomist, aware of the nature and number of the structures injured in the posterior operation, can for a moment assume that such injury does not cause more risk of destructive

inflammation than the injury inflicted on the cornea in the anterior one; and no surgeon who has compared the effects and consequences of the two operations can for a moment maintain that the results of the puncture through the sclerotic are not more injurious than those following the puncture of the cornea. No man who knows what the penetrated structures are, could venture to maintain that the conjunctiva, sclerotica, ciliary ligament and ciliary processes, could be traversed by an instrument with the same or less injury than is inflicted in traversing the cornea; and no man who has compared the dimensions and relations of the anterior and posterior chambers of the aqueous humor, could venture to maintain that the narrow space behind the iris affords a more accessible passage for the needle than the comparatively capacious chamber anterior to it. Neither can any man who has witnessed the sufferings caused by this posterior operation, or the destructive consequences of the inflammation which it produces, venture to assert that such mischief follows the anterior one. The truth in fact is, that this most valuable of all the methods devised for the removal of an opaque lens has been brought into discredit and almost into disuse by this bigoted preference of a method handed down to us from a remote antiquity, when surgery was in its infancy and anatomy not yet cultivated. I have every day to listen with wonder and no small vexation to the expressions of want of confidence in the operation for cataract, uttered, not only by patients, but by practitioners; and this I find is to be attributed to the experience people have had of the consequences of this bad method."*

* Without maintaining any of the heresies set forth in the quotation from Dr. Jacob, and without detracting aught from what is unquestionably a very valuable mode of operating, we have been induced, together with our colleagues at Wills Hospital, to perform, as a general rule, sclerotic puncturation; and though failure from inflammation has unhappily occurred in some instances, the degree of success has been such as fully to justify our practice. The greater power of acting upon the lens and its capsule, and the facility with which some of the accidents that may attend either method can be re-

I understand that many Continental surgeons abstain from the anterior operation from the supposed liability of the cornea to inflammation, a dread participated in by many of our countrymen. On this question the testimony of Dr. Jacob, recorded in the above work, is very valuable.

“With respect to the objection made to this operation on the score of its endangering the cornea, and causing opacity of that structure, I can with safety state that there is nothing in it. I never yet saw vision impaired by any opacity caused by the wound of the needle, and very seldom indeed have I seen any

mediated without inflicting a double injury on the organ, are its chief recommendations. Keratonyxis, however, is well adapted to the removal of the softer varieties of the disease, whether congenital or occurring in later life; indeed we have repeatedly witnessed in traumatic cataract, the gradual disintegration and absorption of the lens without any operative interference whatever,—the cause which produced the mischief having simultaneously opened the capsule, and thus prepared the way for its reparation. Whether it would not be advisable in some cases to combine both modes,—lacerating the capsule only by puncturation through the cornea, and subsequently, when the crystalline has become softened by contact with the aqueous humor, completing the operation by division of its substance through the sclerotica—is a question which may deserve consideration. A wider range is given to the operation by solution in this country than in England, and instances of its successful performance in advanced age are not uncommon.

From a statement of the operations by sclerotic puncturation, carefully prepared from the Register, by Drs. Green and Parvin, late House Surgeons of Wills Hospital, it appears that the cures constitute about four-fifths of the whole number of cases operated upon in that Institution;—a result partly owing to the smallness of our instruments, and the cautious avoidance of all unnecessary injury to the eye, and partly also to the attention which is given, both in the preparatory and subsequent management, to the prevention of inflammation. The remarks of the author respecting the size of ophthalmic instruments are very judicious; they have hitherto been made unnecessarily large, and the greater delicacy of those now manufactured, is a principal element of modern superiority in the treatment of several diseases. The needle which we have long been accustomed to use, is not essentially different from that delineated in the text, being about six-tenths of an inch in length, flattened and a little widened towards its extremity, with an angular point, and as sharp an edge as it can be made to receive;—the object being the laceration of the capsule and the division of the lens with as little disturbance as possible of their relations with surrounding parts.—Ed.

opacity at all remain. In fact, as I have said elsewhere, I know no structure in the body which bears simple injury, such as a clean cut or puncture, better than the cornea. In the course of a long practice, I have met but one case in which suppurative inflammation took place in the puncture, and in that case the suppuration and subsequent ulceration were confined to a circle not an eighth of an inch in diameter, and left behind an opacity not larger than the head of a pin, at a distance from the pupil, and consequently not impairing sight. I have also met with cases, but very rarely indeed, in which the whole cornea suppurated, and the entire eye participated in the destructive inflammation, as sometimes happens from any operation for cataract; this, however, I have never considered a consequence of the peculiar nature of the puncture in this peculiar structure, but the result of constitutional derangement operating on local inflammation following injury. In fact, I looked upon it as of the same nature as the abscess of the cornea which follows very slight injury or irritable ulcer, and which takes place, not from the mere injury or ulcer, but from that state of the animal economy, whatever it may be, which is attended by these local destructive processes. But as I have said, this is a very unusual consequence of this operation; so much so, that I have often wondered that it does not occur more frequently, seeing that it so often follows slight wounds of the cornea by particles of stone or steel in stone-cutting or metal turning. I repeat therefore emphatically that the surgeon need never be deterred from operating through the cornea by any apprehension of the effects of injury on this more than any other structure in the body he may be called upon to divide."

The dilatation of the pupil should be maintained till the capsule recedes, from the reduction in the bulk of the cataract; or till adhesion between its margin and the torn capsule may ensue.

It has been supposed that expansion of the pupil may be the cause of dislocating some of the contents of the capsule or the

entire cataract, but this is erroneous, as slight reflection will show; on the contrary, dilatation may, besides keeping the iris away from the capsule, be advantageous in causing any portion of the cataract that might otherwise escape into the posterior chamber, to fall into the anterior, where it is by far less likely to be injurious.

Permanent dilatation of the pupil after discontinuing the use of the sulphate of atropia, has occurred twice in my own practice; yet I am not certain that the fault was entirely due to the atropia, for the dilatation might have been owing to adhesion of the iris to the capsule of the lens, an occurrence not at all unusual, although not perceptible in the cases in question. In the first case, I operated on fluid cataract for solution, in a man forty-three years old; the aqueous humor became immediately turbid; the iris could not be seen, and remained invisible for a week. Neither pain, sickness, nor inflammation ensued, and finding at the end of ten weeks that the capsule had not contracted sufficiently to clear the pupil, and from its density, was not likely to contract more, I extracted it. The atropia drops, which had been used all the while, were discontinued, and then only was it seen that the pupil was permanently dilated; the circular form was somewhat lost, there being a little irregularity at the lower part. The iris seemed healthy, and there was not any discernible cause of the dilatation. With cataract-glasses, this patient could read small print. I operated a few months after, for solution, on the other eye; the lens had not degenerated, and the atropia was used as with the first; in this also I extracted the opaque capsule; however, the iris was not affected.

The second case was also one of soft cataract in a private patient, a man thirty-eight years old. The day after the operation, the cataract was found dislocated into the anterior chamber. Active inflammation ensued, but subsided sufficiently soon to prevent the necessity of extraction. The pupil, contrary to the usual law, remained dilated during the inflammation. After the cataract had been quite absorbed, and the atropia left off, the di-

latation remained as before, and here, too, there was a little irregularity. The capsule contracted and left a wide central aperture, and was not, so far as I could see, adherent to the iris. Now, after the respective intervals of two and three years, the dilatation in these cases is not at all diminished.

Very slight irritation follows a well-executed operation on an eye in which cataract is not complicated with some other disease, and there is not the necessity for that strict observance of quiet, so essential in the operations for extraction and displacement. However, the patient should remain in the house for several days, during which time the other eye should not be used, bright light should be excluded, and the diet carefully regulated.

The pain which always follows the operation must not be mistaken for the commencement of an attack of acute inflammation; so long as the symptoms of active inflammation spoken of at page 432 are absent, narcotics and the application of cold lotions alone need be employed.

The time required for absorption depends on circumstances connected with the nature of the cataract, as well as upon individual peculiarities; under apparently the same conditions a cataract will resist the process of disintegration longer in some persons than in others. The presence of inflammation is said to suspend absorption. This is in a measure, but not altogether correct; it is only during intense inflammation that the absorption seems at a stand-still, and not always even then.

A single operation may suffice in many instances; and it certainly will when the lens has degenerated to fluidity. A repetition is generally made on the grounds that absorption has ceased, or is deviating in its rate, which is more frequently assumed than indicated; indeed there is no positive proof of its cessation, and evidence goes rather to show that absorption, once begun, does not stop. However, it might perhaps be hastened; and if, after the lapse of six or eight weeks, there is not evidence in the flattening of the capsule and the concavity of the iris, that absorption is proceeding, the operation may be repeated. Quite as

much care is necessary in using the needle subsequently as at first ; for, according to my observations, there is in after-operations a greater tendency to inflammatory action, and hence the necessity for the greatest precautions to prevent dislocation of the nucleus of the cataract. On no account should there be a repetition when inflammation is present, nor do I think that anything can be gained by the renewed use of the needle when the capsule is much opened, and the aqueous fluid is in free contact with the lenticular tissue.

If a sufficient interval be allowed, there are few cases that will not yield to two or three operations ; however, some surgeons think it necessary to repeat the use of the needle every third or fourth week : others, again, at even shorter intervals.

By the mere contraction of the capsule, and its greater or lesser separation from the suspensory ligament and hyaloid membrane, or by retraction of its divided parts consequent on absorption of the cataract, the pupil may be, and very often is, sufficiently cleared ; should the aperture not be ample enough, a special operation must be resorted to, which I shall describe under the head of capsular cataract.

Unless ill health forbid, congenital cataract should be operated on before the eyeball oscillates ; and, as a rule, a child may be safely submitted to operation after the first month of life.

Dr. Jacob has achieved great celebrity by his operation with his peculiar needle, and he operates by solution in many cases in which most surgeons would extract ; yet, in justice to this talented man, who has contributed so largely to our knowledge of the structure of the eye and the treatment of its diseases, I must not allow it to be supposed that he would use his needle in every case ; he assigns to extraction a place, restricting its performance to hard cataract in aged persons, and stating that under fifty years of age, the crystalline lens once broken in pieces, must be sooner or later dissolved and absorbed, there being no question as to result, but only as to time.

The late Mr. Gibson, dissatisfied with the result of solution,

used to extract soft cataracts. Having lacerated the capsule, some weeks later he opened the cornea and removed the cataract piece-meal with the curette. Mr. Travers also at one period advocated extraction, and has recorded his opinions concerning it in vol. v. of the "Medico-Chirurgical Transactions." Should a cataract be softer than a healthy lens in early life, it would be difficult, if not impossible, with safety to the eye, to remove it by extraction; a considerable portion of it must be left behind, thus incurring the immediate risk that belongs to extraction, while absorption must be relied on for the removal of that portion of the cataract which is necessarily left.

The operation for solution is certainly the safest of all for the removal of cataract, as regards any immediate danger to the eye, and in particular instances may equal in its results that of extraction, which, according to what I have witnessed, is generally much superior. It would seem from the united testimony of surgeons, that congenital cataract, when operated on in infancy, or even rather later, during childhood, is that in which this operation is most eminently successful, and this is readily accounted for, since the soft cataract of later years often results from general disease in the eyeball, and is frequently merely a degeneration of the lens from an inflammatory affection of the globe. Failure or imperfect recovery after the use of the needle very frequently arises from the partial amaurotic state consequent on inflammation of a chronic form, that continues for a long while, in spite of all treatment.

The very process of absorption may of itself damage the eye, a fact which has not escaped the observation of Dr. Mackenzie, who asks, "Has the process of solution and absorption of the lens no exhausting effect upon the internal parts of the eye? Are these parts left as sound, after this process has been accomplished, as after extraction, in neither case inflammation having occurred? To these questions, I must answer, that after the process of solution and absorption is completed, we frequently observe undeniable signs of the internal textures of the eye

having suffered, not from inflammation apparently nor from irritation, but rather from exhaustion. The nutritive, or regenerative power of the eye, appears to be weakened. The iris becomes paler and more flaccid than natural, the pupil smaller, and its motions less vivid; while, in some cases, the wasting of the eye extends more deeply, the vitreous humor shrinks, and the retina loses its sensibility."

OPERATION FOR CAPSULAR CATARACT.

CAPSULE FORCEPS.

This modern instrument, for which we are indebted to the stimulus given to the surgical instrument makers by the Great Exhibition, combines delicacy of manufacture, simplicity, and remarkable ingenuity. The blades are brought into play by a canula, which encloses them; shutting when the canula is pushed forwards, and opening when it is withdrawn. The degree of their expansion may be graduated by allowing more or less length of blades for the canula to work over, an alteration which is provided for by the screw at the shoulder of the instrument that secures the stem of the blades. Much delicacy of workmanship is required in order that inequality shall not exist between the canula and the blades when the instrument is shut. Fig. 130 represents those forceps which possess tenaculum points; the larger illustration showing them when closed, the smaller when open. Fig. 131 portrays the sharp capsule forceps, the mechanism of which is very beautiful, shut and open. The larger and sharp blade is perforated about the centre to receive the hooked end of the lesser, and the surfaces where the two come in contact, are cross-cut like common forceps. The object of these ar-

Fig. 130.




Fig. 131.



rangements for taking secure hold of the capsule is at once apparent. This, the more delicate instrument of the two, requires great excellence of workmanship to perfect it. The sharp blade should be sufficiently keen to enter the cornea readily, and the lesser should have its edges so bevelled that there shall not be any projecting angles, or any obtuseness to impede penetration. It is considered by some surgeons an improvement for the canula to be worked with what the instrument-makers call a "trigger spring," which is arranged like that of the canula scissors figured amongst the iris instruments, but with a spring the instrument is very likely to get disarranged. To the same handle different sized blades may be applied; I find it requisite to have many. Each time it is used, the canula should be removed, carefully wiped out with threads drawn through by finely-twisted wire, and the other parts wiped and oiled.

When larger and more powerful forceps are required for removing substances from within the eyeball, those with a cross-spring answer the purpose best. I introduce a very powerful and effectual pair with an excellent arrangement, Fig. 132, made according to my order by Messrs. Weiss. One blade passes through the other, as a security against any lateral movement, and this adjustment enables a check to be placed against too great a separation of them. The extremities remain parallel at any degree of separation, and their points are toothed. The lesser figure shows the points magnified.

Fig. 133 represents a coarser and less expensive instrument on the cross-spring principle, but one better adapted for seizing a large body, and for penetrating deeper than the others. The lesser cut shows the actual size of the teeth.

After the lens has been removed by extraction, solution, or

displacement, the capsule may not roll up and contract out of the field of the pupil, in consequence either of the loss of its elas-

Fig. 132.



Fig. 133.



ticity from thickening, from not having been sufficiently divided, or, because it is more or less adherent to the iris from inflammation; so far it is, surgically speaking, a secondary affection, and requires certain treatment to be directed specially to it.

Till within a very recent date, a safe and effectual operation was a great desideratum. An eye requiring this after-operation was, if treated at all, submitted to attempts, generally ineffectual, at tearing or depressing the capsule, for the complicated mode of extraction then in use was fraught with such danger to the organ, that few surgeons undertook it, and the process of boring an aperture in the capsule with a needle is most uncertain. With the improvement in our instruments the great difficulty has been overcome; with the canula capsule forceps we are enabled to execute an operation which, while efficient, possesses the very peculiar advantages of being applicable to an eye that may have been already severely tried by previous operative proceedings, and of being unattended with the risk of collapse from opening the cornea when there is a degenerated state of the vitreous humor. We can now, in most instances, seize the capsule and withdraw it through an aperture only just sufficient for its transit, yet scarcely large enough to allow of the escape of the vitreous humor or prolapse of the iris.*

The opaque capsule is nearly always so disposed, that the sharp forceps alone will suffice for its extraction, no other instrument being required. Circumstances, however, may call for the employment of the blunt pair, as, for instance, when an unusually large aperture is required for the extraction of an entire capsule that has become thickened, or cretaceous, or a very large portion

* The retention of the aqueous humor is desirable inasmuch as the prehension of the opaque capsule is facilitated thereby, and the escape of any portion of the vitreous humor also effectually prevented; but this advantage may be purchased at the risk of too great injury to the organ. Dr. Mackenzie states that he has not yet been fortunate enough to meet with any sharp-pointed canular forceps, which could be made to penetrate the cornea without excessive force; and we should make the same inference from those that have fallen under our observation. Greater perfection, therefore, in the manufacture of instruments, must be attained, before it can be determined how far this mode of operating is preferable to that of extraction through a small section of the cornea. In performing the latter, the authority just cited speaks favorably of the guarded iris hook of Schlagintweit, as requiring only a mere puncture of the membrane, and, while equally manageable, being, from the greater simplicity of its construction, less liable to derangement than Charriere's canular forceps.—Ed.

of one so altered, and in either of which cases the incision made by the sharp ones will be inadequate; or when a pupil that is diminished from any cause so restricts the space in which the forceps are to play, that the employment of a sharp pair would be dangerous. Under these conditions, the cornea must be opened to the required extent with an iris or cataract knife, and the blunt forceps applied; here, too, the cross-spring forceps may be of essential service. On some occasions, both kinds of forceps may be used; the blunt ones, when more than one attempt is requisite to clear the pupil. After the aqueous humor has escaped, the sharp ones ought not to be applied, lest serious injury be inflicted.

The following representation conveys a very good idea of bands of capsule across the pupil. In this instance, a soft

Fig. 134.



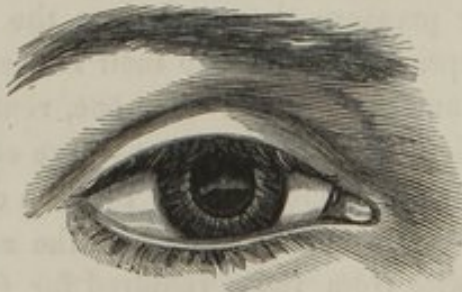cataract had been removed by the operation of solution; several attempts had been made to break through the bands, without success, for under pressure they sank into the vitreous humor, from which they sprang unaltered to their former place, and the eye, which unfortunately was the only one, remained with this impediment to vision, till capsule forceps were employed.

All the preliminaries, including the position of the operator, the steadying of the eye, the placing of the assistant, and so forth, differ in nowise from those required for the extraction of a cataract, and need not be repeated. The pupil should always be dilated to its utmost. If the sharp forceps are to be used, the instrument, held with the short limb anterior, is carried

through the cornea near its circumference, into the pupil; when it has arrived at the edge of the capsule, it is opened, the sharp blade passed behind, the short one in front, the opaque body seized, all pressure on the globe remitted, and the withdrawal commenced; a slightly twisting movement will facilitate its detachment, and make it clear the cornea more readily. It is essential that the aqueous humor be retained till the forceps are closed over the capsule—hence the necessity of the patient lying down—and should it have escaped prematurely, the forceps must be withdrawn and the operation delayed. When possible, the blades should be made to pass on each side of the capsule, that effectual hold may be got by seizing both the surfaces; but this cannot be done except the capsule be partially free, or has in some degree receded from its circumferential attachment, otherwise the sharp blade must be carried through a part of it. When the blunt forceps are used, there is almost of necessity an escape of some aqueous fluid, but then their blunt ends enable them to be opened and used to a certain extent in a flaccid eye with impunity.

This second representation of capsular cataract is from the eye of an adult who had undergone the operation for solution, under the hands of a late distinguished surgeon. When the iris was in a natural state, the eye was nearly useless from the obscurity of the pupil.

Fig. 135.



The great thickness of the central part of the capsule constituted an important difference between this and the above case,

and it was a question whether the sharp forceps were applicable ; however, they were used, and successfully ; the body of the mass came away, and the ring that remained was quite out of the way, when the pupil was undilated. Should there be opacity of the cornea from previous operations for lenticular cataract, it is desirable, if possible, to enter the forceps through an opaque spot, to prevent the risk of rendering more of it opaque.

The only obstacle I know of to the use of the forceps for extracting capsule, is extreme narrowness of the anterior chamber from adhesion of the iris to the cornea, which is usually conjoined with such close adaptation of these parts, as to prevent the instrument being used except directly in front of the contracted pupil, where opacity of the cornea, which is so likely to ensue on a puncture from any large instrument, would be fatal to vision. Other attempts therefore must be made to dispose of the capsule ; or other methods resorted to for restoring sight—artificial pupil for instance.

When an unbroken capsule demands operation, the lens having been absorbed by the unaided effort of nature, there is great probability that there has been congenital cataract, and that both hemispheres of the capsule are opaque.

The densest capsules that I have seen have been in cases of congenital capsulo-lenticular cataract, in which affection there may even be a deposit of earthy matter, as the following paragraph from Mr. Dalrymple's work testifies :—"In some cases of congenital cataract, the capsule is covered by dense opaque patches, which more rarely present a hard, bony, or earthy surface. In figure 1, plate xxviii., a case is given of one eye of a boy, aged nineteen, born with imperfect cataract, and in whom a dense earthy spot surrounded by a circle or ring of earthy deposit existed ; while in the other eye, and in those of a brother two years younger, were scattered several similar deposits, of irregular shape and size. The lens in each case was but semi-opaque."

Adhesion of the capsule to the iris is a serious complication, and is, now-a-days, the only obstacle to clearing the pupil of

secondary cataract. When the adhesion is very limited, a preliminary operation with the curved needle may detach it; even in very extensive or general adhesion, detachment in this manner is not impossible, although the occurrence must be looked on as being very fortunate. More than once the capsule has separated in a mass, at the first endeavor to form a central aperture; therefore with partial or entire adhesion, it is legitimate to attempt separation, which, however, should be abandoned after a well-directed but inefficient trial. The iris, especially if altered in structure, will sometimes give way at the ciliary attachment, or tear at some part, rather than separate from what seems a slight connexion, and any attempt at disengaging it from the capsule may be followed by paralysis, or tremulousness. Sometimes by detaching the capsule at its circumference, it rolls up against the iris, and a sufficiently clear space is left for the passage of the rays of light.

When the above means fail, the alternative is, to make a central division of the capsule, and whether it shall be better to attempt to cut through it with an iris knife or with a pair of iris scissors, or to attempt the same by the repeated use of the needle, must depend on the thickness of the capsule, and the firmness with which it is connected to the iris; whichever mode be adopted, success will mainly depend on the absence of inflammation, which is so frequent a cause of failure by uniting the divided surfaces and on the divided capsule rolling up.*

In January, 1846, I was consulted by a lady who had been operated on by Mr. Saunders for cataract, in whom, in each eye, the capsule was united to the entire pupillary edge; one eye had been submitted to nine, and the other to eleven needle operations

* If the capsule has lost its elasticity the parts will not separate how completely soever it may be divided; but this division having been effected, the iris may be subsequently prolapsed at its circumference, and will draw after it that portion of the capsule to which it is adherent, leaving between the edges of the membrane an opening, though narrow sufficient for useful vision;—what is usually regarded as an unfortunate complication may thus be sometimes made instrumental in accomplishing the object of the surgeon. Mr. Bowman's proposition is not likely to be regarded with much favor.—Ed.

to remove the cataract, and to make apertures in the capsule; and in one only was there a sufficient opening to admit of useful vision.

In the "Medical Times and Gazette" for Oct. 30th, 1852, there is a short notice of Mr. Bowman's method for clearing the pupil. Two cataract needles are introduced through different parts of the cornea, and made to enter the capsule or false membrane, at the same spot, or as near as possible, and the mass is torn by the separation of their points.

When all the resources enumerated fail, recourse must be had to an operation on the iris, for the formation of an artificial pupil.

OPERATION FOR DRILLING.

I have reserved till now the consideration of the complication of capsulo-lenticular cataract with entire pupillary adhesion, which is, in many cases, combined also with a deposit of lymph on the capsule. Prior to Mr. Tyrrell's time, this was almost beyond the reach of surgery, that is, as far as success was concerned. The practice then was to divide the lens, the capsule, and the iris, at the same time, after the manner of Maunoir; but frequent failures induced Mr. Tyrrell to seek for a surer plan, and he ultimately adopted the operation for solution, with such modifications as might serve the additional purpose of effecting an efficient aperture in the capsule, and to this he applied the term "Drilling." The following is his description of the operation:—

"The patient being placed as if to undergo the anterior operation for solution, I have passed a very fine straight needle through the cornea at the outer part; and then, directing the point to the anterior capsule of the lens close to the inner margin of the pupil (taking care not to injure the iris), and causing the instrument to penetrate the capsule, and enter the substance of the lens to the extent of about one-sixteenth of an inch, I have rotated the handle of the needle between the forefinger and thumb, so as to make the point act as a drill; and have thus secured an opening more free than could be effected by a simple puncture; then I have withdrawn the needle.

"By using a very fine straight needle, of uniform thickness, and by introducing it a little obliquely through the cornea, I have frequently performed this operation without the loss of a single drop of aqueous humor; and I have rarely found it produce any inflammation.

"According to the degree of absorption or solution, I have usually repeated this operation every three, four, or five weeks; and have been careful to puncture the opaque capsule in a fresh place, at each operation; and this has generally enabled me so far to weaken or detach the portion of the capsule, occupying the site of the pupil, that it has been easily displaced, when the lens has become dissolved."

Solution and absorption must be facilitated by admitting the aqueous fluid to several portions of the lens, an advantage that renders drilling applicable when the lenticular cataract is hard. The capsule being unyielding, from its thickness, and the puncture in it being small, fragments of the lens cannot escape and do mischief. Mr. Tyrrell usually repeated the operation every three, four, or five weeks, and on an average from seven to eight times, before he was satisfied that the lens was removed. I believe such frequent repetition to be useless, if not dangerous; in the young it can never be required, and it is at variance with Mr. Tyrrell's accustomed practice in operations on soft cataract; in the middle aged, it is unnecessary, especially if what Mr. Tyrrell conjectured be true, as I admit it is, that in such cases the lens has not generally, even in elderly persons, the hard character of ordinary cataract; the absence of hardness at the period of life at which the lens is naturally densest, can arise only from degeneration of the lenticular structure, and it must further be borne in mind that such instances of cataract ensue from inflammation of the eye. By allowing longer intervals, fewer operations will suffice. I prefer, therefore, to operate less often; and when I think that the lens is absorbed, I endeavor, with a broad needle, or the smallest iris knife, to effect at one operation a central aperture in the capsule. The only positive proofs of the removal of the lens when the pupil is adherent, are concavity of the iris, and consequently increased size of the anterior cham-

ber, but these are not always present, for the iris may be too much damaged to admit of such changes; nor is it possible, as Mr. Tyrrell supposed, to gain the required knowledge either from the resistance which a degenerated lens offers to a fine sharp needle, or from the absence of color in any aperture that has been made. It is only by the performance of a sufficient number of operations to expose the lens to the action of the aqueous humor, and the allowance of sufficient intervals of time for absorption, that there can be any certainty of the emptiness of the capsule.

SPECTACLES NECESSARY AFTER LOSS OF THE CRYSTALLINE LENS.

It is a point of the greatest importance, that spectacles be not used until the eye has recovered from the inflammation and intolerance of light consequent on the operation.

A choice of lenses must not be made, till after a careful trial with many whose foci are closely graduated. A power of two and a half inches' focus generally suffices for minute purposes, and one of four inches for long ranges.

Should it be found by experiment after the interval of a few months, that the eye will take lower powers, a change must at once be effected.

As the spectacles which are required after the crystalline lens is lost must necessarily be heavy, the frames should be made as light as is consistent with strength; and the weight may be farther reduced by using crystal instead of glass, for as its refractive power is greater, the lenses need not be so thick. Another, and indeed the only other advantage of pebble, which applies especially to cataract lenses, owing to their convexity, is the less liability from its hardness to become scratched or broken, an advantage compensating for the increase of price. The rims of tortoise-shell, which the opticians usually place between the frame and the lens, are totally useless, very disfiguring to the wearer, and publish to the world that he has had cataract. The frames should be nicely adjusted to the face and nose, and be sufficiently

wide, that the centres of the lenses may be brought in correspondence with the optic axes.

A degree of intolerance of light may remain for months after the operation, and may be obviated by having a tinted lens; glass must then be used, as pebble will not admit of being colored.

Mistakes in distances, especially in ascending or descending the stairs, are common when spectacles are first worn, and the patient must be particularly warned that this may occur. He should also be admonished not to use them unless actually required, and when distant objects can be viewed without them, especially out of doors, to employ the eye alone.

From the power the eye, unaided by spectacles, has sometimes acquired after the operation, particularly in children, it has been supposed that the crystalline lens may have been wholly or partially reproduced. Its reproduction in some of the lower animals has been often proved, and there seems to be a possibility of it in man. It is said by Mr. W. Jones that Textor has observed it in the human subject, and Valentin has discovered by the microscope that the regenerated substance possesses the same intimate structure as the lens. In a publication of Mr. Guthrie's, in 1834, on the certainty and safety with which the operation of extraction of cataract from the human eye may be performed, &c., p. 43, an instance is given of what the author considers to be regeneration of the lens. "Anne Wholly, aged twenty-three, came under my care nine years ago, when fourteen years old, having congenital cataracts of both eyes, on which I operated with success. Some circumstance induced her mother to go out of town suddenly, before the eyes were quite clear, and I did not see her again until the 11th of March last, when a small portion of capsule appeared to impede vision at the lower part of the pupil of the right eye, the left being quite free. Supposing that the removal of this portion of capsule would improve her sight, I proposed it to her, and on doing it, I found to my great surprise that the lens had been reproduced, and was quite transparent. It became, of course, opaque, and is now dissolving in the usual manner."

CHAPTER XVII.

ENTOZOA WITHIN THE EYEBALL, AND ABOUT THE OCULAR APPENDAGES.—CYSTS WITHIN THE CHAMBERS OF THE EYEBALL.

ENTOZOA WITHIN THE EYEBALL, AND ABOUT THE OCULAR APPENDAGES.

THE *cysticercus cellulosæ*, well known as the so-called measles in pigs, has been found in many parts of the human frame, especially in the cellular tissue of muscles, generally of the glutei, iliaci interni, psoas muscles, and extensors of the thigh, and it sometimes also takes its habitat about the eye.

It may not be uninteresting to delineate this parasite, and I

Fig. 136.

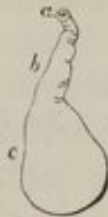
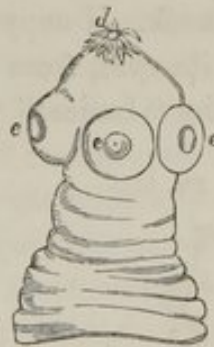
Fig. 137.



have for this purpose borrowed the annexed illustration from the article "Entozoa," by Professor Owen, in the "Cyclopædia of Anatomy and Physiology."*

* The head of the cysticercus, being the heavier part, should have been represented downwards, but the mistake, which is one commonly made, was not noticed in time for correction in the present edition.—Ed.

The smaller figure shows a full-sized entozoon in its cyst; *a* indicates the head, *b* the neck or body, and *c* the dilated vesicular tail. The larger one exhibits the head sufficiently magnified to display the uncinated rostellum, or proboscis *d*, for irritation and adhesion, and the suctorious discs, *e e e*, for imbibing the surrounding nutriment.

While it is confined to the eyelids, or to the external part of the eyeball, danger does not impend, but should it exist in the interior of the globe, the organ is endangered, and, as far as records allow me to speak, would be sacrificed, unless the cysticercus were removed.

A child, two years and seven months old, whose vision was perfect, was brought to Mr. Canton at the Westminster Ophthalmic Hospital, with a small yellowish tumor of the consistence of soft jelly, near the inner canthus of the eye, lying between the conjunctiva and the sclerotica. A snip of the conjunctiva gave exit to serum and a cysticercus. At the end of two or three days the edges of the wound were united.

The entozoon was about the size of a garden-pea, and presented at one part of its circumference a circular opaque body, projecting into the interior of the vesicle; this was the retracted head and neck. I copy these illustrations of the animalcule deprived of its cyst, from Mr. Canton's account of the case, published in the "Lancet" for July, 1848.

Fig. 138.

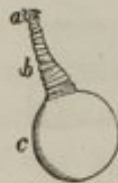
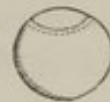
Fig. 139.



The natural size is observed. In the first sketch, *a* shows the head, *b* the neck or body, *c* the tail vesicle. In the second, the head and body are retracted within the tail vesicle.

A very analogous case occurred in the practice of M. Baum of Dantzic, and is reported in the "Annales d'Oculistique," t. 11,

p. 69. The patient, a female, was twenty-three years old; the tumor, which had been noticed for six months, was at the internal angle of the eye, in the sclerotica; the conjunctiva covering it was thickened. A depression remained in the sclerotica after its removal. Vision was unimpaired.

In the same journal is the record of another case by Hoering, in a girl seven years old; the cyst adhered to the sclerotica, towards the external angle of the eye. Sight was saved.

Mr. Estlin of Bristol, published in vol. xxii. of the "London Medical Gazette," another similar instance that occurred in a girl six years old.

It has also been found in the subcutaneous cellular tissue of the upper lid, as recorded by Sichel, in the "Revue Medico-Chirurgicale," April, 1847; as well as in the neighborhood of the palpebræ.

Great interest attaches to the internal implication of the eye, from the attendant risk, and till lately, the forlorn hope of recovery. A man, forty-five years old, applied at the Central London Ophthalmic Hospital, in 1849, in consequence of frequent pain that had existed in his right eye for six weeks; the sight had been quite lost a year previously from a sudden attack of inflammation. The conjunctiva was much inflamed, the cornea vascular and semi-opaque. At his next attendance I saw in the anterior chamber what I took for an opaque capsule, which slipped into the posterior chamber when I commenced to examine it, and could not be got to its former place by any change of position or shaking of the head. The man, who was quite aware of this shifting, which he said occurred many times in the day, was directed to apply when the body was visible. The following sketch of it expresses all that a woodcut can convey. The cornea is supposed to be semi-opaque. In the original the pupil was not by any means so visible.

To relieve the pain the body was extracted, and proved to be a cysticercus. The cornea healed readily, and cleared very considerably; the pain was removed, but of course vision was not restored. The crystalline lens must have been absorbed, or the

cysticercus could not have passed so readily into the posterior chamber. The opacity of the cornea obscured the only means

Fig. 140.



of diagnosis—the alteration in the form of the vesicle by the protrusion and retraction of the tail.

Mr. Logan's remarkable case, originally published by him in a pamphlet, and afterwards recorded in the "Medical Gazette," vol. xii. p. 110, by Dr. Mackenzie, possesses many points of value. A girl seven years old was the subject of it. From August to January there had been several inflammatory attacks in the left eye, producing slight opacity of the lower part of the cornea. Then a semi-transparent body, from which hung a slender process, with a slightly bulbous extremity like the proboscis of the common house-fly, sometimes retracted, sometimes protruded, was seen loose in the anterior chamber. Objects placed above the level of the eye could be distinctly seen, but not when placed below, or directly in front, showing that in the latter positions, the rays of light were merely obstructed, and that the eye was not damaged. Increase of size was not observed by Mr. Logan, and he trusted that its natural period of existence coming to a close, would free the eye from the danger of disorganization. Various means were suggested for killing the insect in its situation, that it might be afterwards removed or left, according to circumstances; such as electric or galvanic shocks passed through the eye, oil of turpentine rubbed round the orbital region, and given internally, or the administration of some vegetable bitter known to be inimical to the life of para-

sitical animals. The sequel is given in Dr. Mackenzie's work. Several weeks afterwards, extraction was attempted by Dr. Robertson of Edinburgh. From the struggling of the child after the cornea was opened, the lens was forced out, and the hydatid ruptured. After a long interval the girl was induced to open the eye, and the cysticercus was brought away in shreds. A portion of the iris remained in the wound, but nothing would induce the girl to allow Dr. Robertson to attempt to return it. The eye healed, and the cornea remained clear, except at the cicatrix; there it was only semi-transparent. The pupil, in consequence of adhesion of the iris to the cicatrix, was elliptical, and was occupied by opaque capsule. The patient readily recognised the presence of light.

There cannot be a doubt as to the propriety of extracting any entozoon from the eye that can be readily got at, on the earliest recognition of its existence. The cornea should be opened to an extent equal to the size of the mass which is to be removed.

Directly that the knife is withdrawn, the blunt canula or cross-spring forceps, should be used, without first letting the lids free. In other respects the operation is to be conducted as for the extraction of a cataract. In Mr. Logan's operation, the unfortunate issue arose from the perversity of the patient; chloroform should therefore be given whenever a cysticercus is to be removed from within the eye of a child, or any irresolute individual.

In Dr. W. Sæmmerring's case, which has been often quoted by writers, from having been one of the earliest, if not the earliest ever recorded, the parasite was extracted alive; it moved about in lukewarm water for half an hour, and then gradually turned opaque and white. In the original, given in the "*Isis Von Oken*" for 1830, the result of the operation is not mentioned; the record seems more with a view of illustrating a point in natural history, than for the advancement of medicine. As in Mr. Logan's case, the cysticercus was observed after active inflammation, which subsequently subsided, and it scarcely produced inconvenience, except when moving about.

In seven months it had doubled its volume, and when extracted was as big as a pea. The subject was a girl aged eighteen.

In a case which Rosas quotes of a lad fourteen years old, who was under Neumann, the eye was otherwise healthy, and dilatation of the pupil caused the cysticercus to quit the anterior chamber and lie across the pupil, from which the further use of belladonna could not free it; the new position caused much pain. The animalcule was depressed and the pain was comparatively removed, but suppuration of the eyeball ensued.

The most satisfactory case of extraction of a cysticercus from within the eye, on record, is to be found in a communication to the Medico-Chirurgical Society by Dr. Mackenzie, and is published in vol. xxxii. of the "Transactions." The girl, who was sixteen years old, applied at the Glasgow Eye Infirmary in 1848. The vesicle was uppermost, the usual position in the eye, and the head was occasionally drawn up into the vesicle. Inflammation preceded its appearance. Vision would have been perfect but for the partial obstruction by the cysticercus to the rays of light. The girl was unconscious of its presence. Eighteen days after its recognition, the cornea was opened to the extent of three-twentieths of an inch, the body removed, and received into a teaspoonful of warm blood-serum; but its movements were not so lively as when transferred to tepid water. Next day the patient felt quite well, the eye appeared natural, and she said she saw as well with it as with the other. No reaction followed. The author thinks that the attack of ophthalmia immediately preceding the appearance of the hydatid, was owing to the development of its ovum in one of the blood-vessels of the iris or choroid; and that the inflammation ceased suddenly as soon as it dropped into the anterior chamber, where it lived at its ease, amply furnished with sustenance from the aqueous humor, and unrestrained by any external cyst, such as that which surrounds the same entozoon when lodged among the muscles. The truth of this theory would seem to be confirmed by the presence of inflammation in the majority of other cases prior to the full deve-

lopment of the insect, and it might have existed in each instance for any proof that we have to the contrary.

After a *cysticercus cellulosæ* has destroyed the eye, mischief is not certainly over, even though its extraction has been accomplished, as the morbid action excited by its presence may continue. Mr. Canton watched one for several months previous to its removal; the symptoms were gradual diminution of vision, consequent upon an increasing nebulous state of the cornea, with slight inflammation of the conjunctiva and the sclerotica. By degrees the central part of the cornea became more opaque than the circumference. Almost constant darting pain in and around the eye was unrelieved by the various modes of treatment that were resorted to. An opening was made by Mr. Guthrie, through the most prominent part of the cornea, and a *cysticercus* in a perfect state escaped. Relief ensued. The circumstances of the case, six or seven months after, appearing to require a similar procedure, the cornea was again opened, and what was supposed to be a *cysticercus* removed, but this most likely was the crystalline lens, a close examination of it not having been made. Three years afterwards there was constant pain about the eye, and such symptoms as induced Mr. Guthrie to suspect the presence of another *cysticercus*. The cornea was again divided, and vitreous humor alone escaped: the operation removed the pain.

Mr. Gulliver has given a good general account of the *cysticercus cellulosæ*, with illustrations, in vol. xxiv. of the "Medico-Chirurgical Transactions." Dr. Knox has also written on it in the "Lancet" for June 16th, 1838.

Other entozoa have been discovered in the human eye, but from their rarity and diminutiveness, being mostly microscopic, few persons have detected them, and they possess scarcely any surgical interest.

The *filaria oculi humani*, was so called by Dr. Nordmann of Odessa, who discovered two of them in the fluid of a degenerated cataract which was extracted from an elderly woman. With a microscope their true nature was determined, and in one which

was uninjured, its organization was clearly discernible. Specimens of the genus *monostoma* and *distoma* have also been discovered in the lens by the same observer, and by Drs. Gescheidt and Ammon.

The *filaria medinensis*, or Guinea worm, may infest the eye. According to Rhind, this worm was known at a very early period, the first mention of it having been by Agatharchides, four or five hundred years before Christ. He mentions also that Plutarch described it very accurately. It has been extracted from under the conjunctiva of a negress, and from its frequently infesting the inhabitants of the tropics, and occurring in numbers in the same individual, it is not unlikely that it takes its resting-place more frequently about the eye than the rare mention of it by authors would lead us to infer. About four years ago I saw an example in King's College Hospital, in the leg of a lad who had just returned from the coast of Africa. It generally lies in a coil, producing much itching, and afterwards the formation of an abscess. When the head protrudes, it should be secured with strong thread, and the process of extraction should be commenced by coiling the worm around some small substance by gentle turns daily, and continued till the whole is removed. Without great care it will be broken. When the head does not protrude, the worm must be reached by incision, secured, and wound out.

Many other observers have verified the existence of these and of other living bodies in the eye, some even between the layers of the cornea. The *echinococcus oculi humani* has been discovered between the choroid and the retina. "Notes sur les Helminthes des Yeux, dans les Archives de Médecine comparée," par P. Rayer, Paris, 1843, p. 67-154.

Under the head of tumors in the orbit, an instance has been given of the occurrence of hydatids in that situation.

An entozoon that infests the Meibomian glands remains to be mentioned; but its presence, like that of some just described, is not of any surgical interest, and I allude to it merely to complete the number of those that have been found about the eye. It is the "*steatozoon folliculorum*" of Mr. Erasmus Wilson,—an

animalcule formed in the oil-tubes whenever there exists any disposition to the unnatural accumulation of their contents. It is very minute, being the forty-fifth of an inch in length. In form and shape, in the perfect state, it is like a caterpillar, having a distinct head with feelers, a chest with four pairs of legs, and a long tail. In Mr. Wilson's work on the "Healthy Skin," from which these particulars are taken, all relating to the history of this little insect is narrated. It appears that Dr. Simon discovered it; but his descriptions and figures were imperfect, and several points of entomological importance were overlooked, and Mr. Wilson has completed our knowledge of the subject, and changed the name of the insect to that it now bears.

CYSTS WITHIN THE CHAMBERS OF THE EYEBALL.

A cyst in these situations is liable to be mistaken for a dislocated lens, or for the cysticercus cellulosæ, both of which it much resembles, the chief characteristic distinction being that the cyst is attached. Should there be slight opacity of the cornea, it might not be possible to distinguish between them, except from the history of the case.

Unless when existing at birth, a cyst generally has a traumatic origin, a wound or a blow on the eye inducing it. Either chamber of the eye may be the seat of the growth, the iris being generally the part to which it adheres. Mr. Dalrymple alludes to one that was produced at the point of puncture of the cornea, after the use of the needle for cataract.

Its increase although slow is, I believe, almost certain, and as it enlarges, the disorganization of the eye from pressure or irritation is inevitable, unless it be destroyed. We have abundant evidence that the mere evacuation of the cyst with a needle will suffice; the disease will disappear, and the eye will recover its integrity. When the cyst is too large or too dense to admit of this treatment, the eye is in the greatest danger; for extraction, then the only resource, is fraught with the greatest peril.

The following very instructive case is recorded in the "Mir-

ror" of the "Lancet" for June 12th, 1852. A child, five years old, thrust the point of a fork into his eye, from which accident he speedily recovered. About a year and a half after, uneasiness and inflammation in the eye induced the parents to apply for advice; there was now in the anterior chamber a large transparent body, at first supposed to be a dislocated lens, but ultimately recognised as a very delicate, watery cyst, protruding from the posterior into the anterior chamber, the lower part of the iris having been detached from its ciliary connexion, and pressed upwards. The cyst was punctured, discharged a considerable quantity of fluid, and collapsed. The pupil lost much of its irregularity, and the interval of separation of the iris became less. Soon afterwards the cyst refilled, and in two months it was repunctured through the cornea by Mr. Jones, who had not seen the case before. After a few days inflammation followed, and according to the report, "There was, at the bottom of the collapsed cyst, a small quantity of yellow matter or lymph, with a minute vascular ramification upon its anterior wall." The eye became worse from some indiscretion on the part of the child's mother. Leeches were applied, and calomel and Dover's powder were given. Some of "the matter of the cyst worked its way outwards at the junction of the cornea and sclerotica by a narrow passage." The mercury was discontinued after all the matter was absorbed. The cyst shrank in a manner that left little trace of it, and sight was quite restored.

A somewhat similar case is recorded by Dr. Mackenzie:—A lady was affected with considerable pain in one of her eyes, which presented the appearance of a small vesicle pushing into the anterior chamber from under the ciliary margin of the iris, behind the lower edge of the cornea. The vesicle gradually increased, separating the iris more and more from the choroid, and as it caused severe pain he punctured it through the cornea, with an iris knife. A minute quantity of fluid was discharged from the cyst, which immediately contracted so much that it was no longer visible, and the pain was removed. The cyst refilled and appeared in its former situation, but was larger than before.

He punctured it a second and a third time, at the respective intervals of six and eight weeks. After the third puncture, it did not fill again, the iris returned to its natural place, and vision was preserved.

Mr. Dalrymple gives the following particulars of one in a girl twenty-five years old. The pupil was partially hidden by a semi-transparent cyst attached to the iris and to the posterior surface of the cornea. The cyst was punctured and evacuated of its pellucid fluid, without the aqueous humor being lost. In a few days it refilled, was again punctured, and now collapsed completely. Its walls were very thin, and through them could be seen an apparent aperture in the iris, which led Mr. Dalrymple to believe that the cyst originated in the iris, or from behind it, and elevated its serous covering into a watery cyst. "I am aware," he writes, "a serous covering to the iris is denied by modern anatomists, but in that opinion I cannot yet acquiesce." To admit this explanation we must suppose that two cysts were present.

Mr. Tyrrell gives an example of a cyst growing in the anterior chamber from the eye having been injured by the beard of an ear of corn, that well illustrates the danger of inflammation from extraction. The patient was a girl; the cyst was about the size of a pea, glistening, and attached near the margin of the pupil, with the motions of which it somewhat interfered, but vision was good. As it increased and excited inflammation, Mr. Tyrrell was induced to operate; the cornea was opened, the cyst drawn out, and the portion of iris to which it was attached cut off. The wound in the cornea healed readily. Active inflammation of the eyeball ensued, in consequence, it is said, of imprudent exposure; the other eye sympathized, and was similarly affected, but to a slighter degree, "exhibiting inflammation of the iris and aqueous membrane." After many weeks passed in treatment, the left eye, that not operated on, perfectly recovered; in the other the pupil became very much contracted, and the iris adhered to the capsule of the lens; however, large bodies could be discerned.

The great objection to extraction arises from the immediate danger to the eye, for unless a cyst be small, and attached by a small base to the iris near the pupil, it is almost impossible to remove it by excision without separating the iris from its ciliary connexion, besides inflicting other serious damage on the eye, and endangering the loss of the vitreous humor. Again, it is hardly possible to extract it without rendering the lens and its capsule opaque.

During the last summer I saw an eye destroyed in an attempt to remove a cyst that in all probability could have been destroyed by puncturing. Indeed in every instance such treatment should be fairly tried, often repeated, and not prematurely abandoned; and I think that the cyst should be opened by a large aperture, in order to afford entrance to the aqueous fluid. I should use such an instrument as the smallest iris knife, and make the puncture near the base.

Mr. Dalrymple mentions that the late Mr. Scott removed from the anterior chamber, a cyst from which was growing a hair that resembled an abortive eyelash.

CHAPTER XVIII.

ARTIFICIAL EYES.

THE improvements which have of late been effected by the principal artists of London and of Paris, in the composition of, and method of coloring the enamels for artificial eyes, render the imitation so perfect that not only is the casual observer deceived, but even the professional man who is conversant with ophthalmic practice may not detect the substitute.

I find that patients always couple the idea of pain with the wearing of the artificial eye, and this arises from its supposed size, and the belief that the sensitiveness which belongs to the eye only in its integrity, is retained after its loss. With the destruction of the cornea the greater portion of the sensibility of the front of the globe is destroyed.

An artificial eye, as seen by this sketch, is but a very light

Fig. 141.



shell of enamel, made to represent the front of the living feature. The shape and size must vary to suit different cases, almost each requiring a different model, and this adaptation, and the correspondence in size with the other eye, demand much more nicety than is necessary to match the color.

It is the duty of the surgeon to see that the entire surface, including the edges, is enamelled, since it is a common practice

for workmen, or rather agents for the sale of artificial eyes, who are not makers, to grind the shell to the required size without afterwards restoring the desired smoothness, for which the action of fire is required.

Judging from the generally miserable workmanship of the artificial eyes forwarded to the Great Exhibition from several nations, one must conclude that there are not more than three or four houses in the world that have obtained high proficiency in the manufacture; of these, that of Messrs. Grossmith and Desjardins obtained the prize medal. Mr. Gray, of No. 7 Goswell Road, Clerkenwell, has supplied several of my patients with admirable artificial eyes; and so has M. Boissonneau of London. All, however, does not rest with the mechanic; the best mechanism will fail in full effect, unless the globe retains sufficient fulness to be moved by its muscles, and so to act in concert with its fellow. Those globes are best adapted to receive the enamel that are just a little below the natural size; an enlarged eye must therefore be reduced, and staphylomatous projections must be excised. Very slight reduction will suffice. On the other hand, with very little more than a mere button of collapsed tunics, I have seen an artificial eye that few persons would have detected, except from its imperfectly following the other. Some degree of movement in these cases is acquired by the conjunctiva, which, in its reflections from the lids to the shrunken globe, is influenced by the recti muscles, and the lids also directly impart some vertical motion. Even an eye that is motionless, however, is certainly very much less objectionable than the distressing vacancy of an empty orbit, or the disfiguring patch that is worn to conceal it.

When an eye is lost before the orbit has attained its destined growth, this cavity is never fully developed; and the earlier in life that the accident has occurred, the less will be its size, and the case will be proportionally less adapted for the assistance of art.

Besides the removal of deformity, the presence of the false eye may be of essential service in keeping the lids in their natural position, and preventing the cilia from irritating the

shrunk globe; in placing the puncta in a more natural position for conveying away the tears; in acting as a defence against intruding bodies, which are apt to be retained within the lids and to produce irritation; and as a means of keeping the cavity free from collections of lachrymal secretions.

The lids may require some slight surgical operation, such as the removal of adhesions, or of thickened conjunctiva, or of ectropium.

The eye is to be inserted in the following manner: it is to be wetted, and the broad or outer end first passed under the upper lid, slid as far as it will readily go, and kept there with the forefinger of the one hand, while with that of the other, the under lid is drawn down till the lower part slips in. For removal, the lower lid must be depressed, and the finger-nail, the edge of a tooth-pick, the head of a pin, a little hook, or any small and blunt instrument, passed under the edge and made to lift it forwards, when it will slip out; and care should be taken to receive it in the hand, or on a handkerchief, for a fall would be attended with fracture. A person soon learns to do this for himself. Occasionally it is necessary to accustom the lids to its presence by wearing it at first for a few hours only at a time, and it may even be requisite to begin with one of a smaller size than that to be eventually worn. All active disease should have passed away before one is used.

An artificial eye requires great cleanliness in order to preserve it, and it should be removed every night. This cessation of use it farther necessary to prevent ulceration of those parts on which its edges rest. If the globe be much reduced, the interior of the lids should be syringed with tepid water every morning. Should there be an habitual unnatural conjunctival secretion, or should that be excited by the presence of the enamel, an astringent lotion used night and morning may remove or lessen it.

Instances are met with in which the false eye causes too much uneasiness to be worn.

After the gloss is lost, a new eye is needed; for if the damaged one be still used, irritation of the lids is set up. The average period of wear is about twelve months.

CHAPTER XIX.

MALIGNANT AFFECTIONS OF THE EYE.

GENERAL CONSIDERATIONS, INCLUDING DEFINITION OF CANCER; MICROSCOPIC CHARACTER OF CANCER; ORIGIN AND PHYSIOLOGY OF CANCER IN CONNEXION WITH TREATMENT; QUESTION OF LIABILITY OF THE EYE TO CANCER. ENCEPHALOID CANCER OF THE EYEBALL. MELANOSIS. SCIRRHUS. CANCER OF THE ORBIT. CANCER OF THE EYELIDS. CANCER OF THE LACHRYMAL GLAND. QUESTION OF THE PROPRIETY OF OPERATING IN THE SEVERAL VARIETIES OF CANCER ABOUT THE EYE.

GENERAL CONSIDERATIONS.

It is only within a comparatively recent period that the mode of investigating cancerous disease has made any advances towards accuracy or precision. The loose manner in which the term "malignancy" was formerly applied to tumors and to ulcerations of every description which proved intractable under the ordinary modes of treatment, and the reliance which was placed upon the coarser external characters for their classification, led to the grouping together of diseases of the most opposite characters, and proved a barrier alike to the progress of sound pathology, and of correct treatment. The labors of Abernethy, Wardrop, Travers, Carswell, Hodgkin, and a host of other distinguished pathologists of this country, as well as of France and Germany, cleared up much of this confusion, and paved the way for the rapid progress which has been made since the general introduction of the microscope as a means of pathological research; by the aid of this invaluable instrument, much of the obscurity surrounding the subject has been cleared away.

We are now enabled to distinguish between various morbid products, which, however similar in their external characters, are totally distinct in their pathological signification; and the knowledge thus gained has enabled us to undertake the treatment on more rational principles, and with better prospect of ultimate success. Much, doubtless, still remains to be done before we can be said to have mastered the subject in all its bearings. The most eminent pathologists still differ in opinion upon points of great importance in the classification and diagnosis of several of the varieties of cancerous disease; while the momentous question as to the true principles on which the treatment should be conducted, has yet to be answered.

In the following observations I shall make a free use of the labors of those who have directed especial attention to malignant affections, and while I avoid disputed points of pure pathology, I shall endeavor to extract what practical lessons I can from those upon which all are agreed. I shall devote more space to the physiology and pathology of these diseases than may at first sight appear to be consonant with the plan of a work which is intended to be solely practicable; but a little consideration will show that such a course is not only expedient but necessary. The immense importance of an accurate diagnosis, and the necessity of having clear views of the nature of the disease, have induced me to bring forward all the information which appears calculated to elucidate the subject.

In consequence of the confusion, which has arisen from the careless manner in which the word "malignant" has been employed, Dr. Walshe has proposed its total abandonment. I shall use it as synonymous with cancerous. I shall avoid the use of the term "canceroid," though proposed by such authorities as Lebert and Bennett, for it appears to serve merely as a cover for our ignorance, and tends to give rise to erroneous views of the nature of the growths to which it is applied.

DEFINITION OF CANCER.

It is impossible to give a concise definition of cancer, which

shall not be open to objection, as in many of its more prominent characteristics it presents points of resemblance to disease of a non-malignant nature ; but I shall endeavor to give a brief summary of some of the more striking peculiarities by which it is distinguished.

Cancer is a heterologous growth ; that is, its histological elements, or rather the peculiar manner in which those elements are arranged and associated, differ from what is seen in the normal tissues. It has the inherent faculty of reproduction, and a tendency to degeneration and decay ; it can extend to the adjacent structures by infiltration, causing the delusive appearance of having converted them into its own proper tissue ; and it sooner or later produces a peculiar effect on the constitution, which is known as the cancerous cachexia.

Probably the most striking peculiarity of cancer is its power of infiltration ; the cancerous matter is deposited among the elements of the tissue, causing their absorption, and preventing their evolution, so that on a section being made, no trace of the original structure can be perceived. This takes place more readily and rapidly in the cellular membrane, but all tissues are liable to it, though they possess different powers of resistance ; the fibrous structures are those which control its advance the longest, as is well seen in fungus of the eyeball, where the sclerotica may be surrounded on both sides by the cancerous matter, without undergoing change.

DIVISION OF CANCER.

Cancer is generally divided into three varieties, encephaloid, scirrhus, and colloid ; to these, a fourth, namely, epithelial cancer has recently been added. This is one of the varieties described by Lebert and Bennett as a cancrroid disease, but its truly cancerous nature has been fully established by more recent and extended observation.

Melanosis, which was formerly described as a distinct variety of cancer, is now generally referred to an incidental association of pigmentary matter with other morbid growths ; in the great majority of cases of a malignant character.

As colloid cancer has never been found in connexion with the eye or its appendages, I shall at once dismiss it from farther consideration, and shall go on to describe the characters of the other three species, which in their external appearance and in the course which they run, present numerous and striking differences.

Encephaloid, which derives its name from the close resemblance which its section frequently bears to the human brain, occurs most frequently in infants and young persons below the age of puberty; no period of life, however, is exempt from its attacks, and it is seen occasionally, though comparatively rarely, in those far advanced in years. It attains a greater size, runs a more rapid course, and appears to indicate a greater degree of malignancy, than any of the other varieties of cancer. In some situations in the body, it frequently attains the bulk of a man's head, or may even be larger; it is not unusual to see a mass in connexion with the eye, as large as half of the head on which it rests.

Though it may occasionally lie dormant for a considerable period, it more usually runs its course with great rapidity; a few months, or even a few weeks, may carry the case from the commencement to a fatal termination. Like the other varieties of cancer, encephaloid consists of a stromal or containing, and an intrastromal, or contained substance; the former a fibrous structure, and the latter being chiefly cells of various shapes and sizes.

According to the preponderance of the one or the other element, the tumor varies in consistence; in the harder and more slowly developed species, the fibrous structure being in excess, and in the softer and more rapidly developed, the cellular. The intrastromal substance may, in many instances, be separated from the stroma, by gentle washing, the latter being left in the form of a delicate filamentous web; but in the harder varieties considerable manipulation and pressure may be necessary to effect the separation. The section of encephaloid generally presents a striking resemblance in many parts to brain, being white and soft, mottled here and there with spots of gray or pink, the latter color depending on the presence of blood-vessels, with

which this variety of cancer is largely supplied. The coats of these blood-vessels are of great delicacy, and from the small degree of support they receive from the structure in which they ramify, they are very liable to rupture, giving rise to hemorrhage, more or less copious, into the substance of the tumor. To this is due the dark and bloody appearance which was formerly thought to indicate a distinct variety of cancer, distinguished by the name of fungus hæmatodes. Hemorrhage is peculiarly liable to occur as the tumor begins to soften and decay, and numerous shades of color are then seen, partly from the presence of blood in different stages of disintegration, and partly from the changes which the cancerous matter itself undergoes. The tumor varies in consistence in different parts, and in the different stages of its development. Here and there the fibrous structure will be found collected in masses, little inferior in density and hardness to what is seen in scirrhus, into which in fact it frequently merges; while at other parts, where the cellular element predominates, it is soft and almost diffuent. Encephaloid occurs either infiltrated into the structure of organs, or in separate masses enclosed in an investing membrane, which was formerly described as a true cyst, secreting from its walls the contained matter. This opinion, however, is not now generally adopted; most pathologists agreeing with Dr. Walshe, that the investing capsule is formed by the condensation of the surrounding cellular membrane. When encephaloid tumors approach the surface, as invariably happens with those with which we are more immediately concerned, they involve the investing skin or conjunctiva, which undergo changes, not merely from distension, but also from becoming infiltrated with the cancerous matter; the skin assumes a dusky and livid color, and large blue veins ramify over its surface. In either case, but more speedily when the disease is subconjunctival, ulceration finally takes place, and the tumor, released from pressure, bursts into luxuriant fungous growths, which rapidly increase in bulk, and by their profuse discharge, and frequent hemorrhage, bring the case to a fatal termination.

It may here be advisable to say a few words regarding melanosis, which is considered by Müller, and by several other distinguished pathologists, to constitute a distinct variety of cancer. The accuracy of this opinion, however, is now disputed, and, I think, upon good grounds. The black color is dependent solely upon the presence of pigmentary matter, different in no respect from that of the choroid, and, like it, enclosed for the most part in irregularly spherical cells; or when associated with a morbid growth, partly infiltrated into the peculiar cells, or among the elementary structures, of which it is composed. The black matter cannot of itself be considered as cancerous; it is never met with in the human subject associated with any stroma peculiar to itself; it has been found coloring tumors not of a malignant character, and it is asserted that it in no way modifies the growth or progress of the structure in which it occurs, though I am inclined to think that this latter assertion has been made on insufficient grounds, and that the subject has not as yet met with that careful consideration which its importance deserves. I shall revert to this question when describing the progress of the disease as it appears in the eyeball, and shall state my reasons for adopting the above opinion.

Scirrhus is so called from the stony hardness which forms one of its most striking physical characteristics, and which has procured for it the popular designation of "stone cancer." This property is more conspicuous while the tumor is still connected with the body than after its removal; a fact pointed out by Dr. Walshe, and attributed by him to the loss of blood and the absence of turgor vitalis produced by excision. The hardness also varies slightly in degree according to the age, stage of development, and complications of the tumor, but is always well marked, and constitutes a prominent symptom for diagnosis. Scirrhus occurs in distinct masses, or infiltrated into the tissue of organs; in either case, it seldom attains a large size; in fact, from the absorption which it occasions in the surrounding structures, the affected organ, notwithstanding the addition of the new matter,

may actually appear to be diminished in bulk; as is frequently well seen in scirrhus of the mamma. From its hardness and toughness, a scirrhous tumor cuts like ligament, frequently creaking under the knife. The section presents a smooth, semi-transparent surface, of a bluish white tinge, occasionally mottled with spots of pink or buff color, if the disease be in an advanced stage and disintegration is commencing. In some instances the surface is perfectly uniform and homogeneous, nearly resembling cartilage; in others, a fibrous arrangement is very perceptible. The radiating white bands, upon which much stress was formerly laid as a diagnostic mark of scirrhus, are due to thickening and infiltration of lymphatics, lacteals, or other vessels which naturally exist in the organ; they are most plainly seen in the scirrhous mamma, and the fact of this organ having been more frequently examined than any other of the body, has led to the mistaken idea that these bands are essential and diagnostic. When the cut surface of a scirrhous growth is firmly pressed, it yields a semi-transparent or milky fluid, in greater or less abundance, according to its density and stage of development or disintegration; this cancer-juice, as it is termed, is loaded with cells of various sizes and shapes, and is considered as highly diagnostic. In the dense cartilaginous-looking tumors, it is small in quantity, and almost resembles lymph; when softening has commenced, it is more abundant, and of a milky or yellowish hue. But few blood-vessels can be traced into scirrhus, and those are small in size and irregular in distribution; nor is it ever enveloped in a cyst, but appears to be intimately blended with the surrounding structures, sending out long shoots and prolongations in various directions, a fact of much practical import, and one which should never be forgotten in operating. Scirrhus seldom appears before the middle period of life, though to this rule some exceptions have been recorded. Müller has, in several instances, seen deposits of *carcinoma reticulare*, one of the varieties into which he divides scirrhus, in the cellular tissue of the orbit of infants, and it has also been observed in young adults, but in the vast majority of cases, its subjects have reached the middle period of

life. The development of scirrhus takes place very slowly, and it is not at all unusual to observe its growth altogether suspended for a number of years; the rough calculation made by Vogel is probably near the truth, that it usually requires, to run its course, as many years as encephaloid does months.

Of epithelial cancer, no very perfect description has as yet been published. It is described by Lebert and Bennett as a cancrioid growth, or one, which to the naked eye and in its progress closely resembles cancer, but which, on more minute examination, presents marked structural differences. More extended and recent observations, however, appear to have established its nosological position as a variety of cancer. It is not a mere hypertrophy of the normal tissues; for though its histological elements individually may be undistinguishable from those of the normal textures, yet they are so abnormally arranged and associated, as to constitute a true heterologous growth. In its progress, it is the slowest of all the varieties of cancer, frequently remaining perfectly stationary for many years; in an unhealthy state of the constitution, however, or when injudiciously interfered with by irritating applications, it advances much more rapidly, and ultimately effects the most extensive destruction of the parts involved.

MICROSCOPIC CHARACTERS.

I now proceed to consider the microscopical characters of cancer, and in each of the varieties above described, it will be found that the essential elements are the same, and that the striking differences which they present to the unassisted vision, are dependent mainly upon the various proportions in which those elements are combined.

Cancers, then, consist essentially of molecules and granules, nucleated cells of various sizes and shapes, free nuclei, and fibres, associated with a semi-transparent fluid or amorphous solid, which is rendered transparent by acetic acid, and which

is regarded as the blastema from which the other elements are developed.

The granules and molecules are minute bodies, generally spherical in shape, but frequently amorphous; according to Dr. Walshe, they average one-thousandth of an inch in diameter; they consist partly of a modified protein-compound, and partly of fat; they are found infiltrated in the blastema, in the interior of the cells, and in some instances attached to the fibres; they exhibit molecular motion; they are found in every variety of cancer, excessively numerous in some, and sparingly in others.

The cells present great variations in size and form, and occur in very variable proportions, constituting in some growths the great bulk of the tumor, whilst in others, masses of considerable size may be found in which they are nearly or altogether wanting. In those growths which, like encephaloid, are rapid in their progress, of large size, and of soft consistence, they form the principal ingredient, whilst in small, dense, and slowly-forming tumors, as in scirrhus, they are comparatively few in number. Much discussion has arisen as to the existence of a true, diagnostic cancer-cell; one, namely, which is invariably to be found in every genuine specimen of cancer, and the detection of which, is of itself sufficient proof of the malignant nature of the disease. Great importance was at one time attached to the caudate and fusiform cells, and opinions were stated as to their diagnostic value, with a degree of confidence which more extended observation has not justified; they have been satisfactorily ascertained to exist in various non-malignant tumors, and have been found by Dr. Bennett even in recent inflammatory exudation. The following description of the various forms of cancer-cells, condensed from the work of Dr. Bennett, agrees in the main with those of Dr. Walshe, Hannover, and Lebert.

Cancer-cells are of various shapes, round, oval, caudate, heart-shaped, spindle shaped, &c.; they are of variable size, ranging from one-hundredth to one-tenth of a millimetre in diameter; nucleated singly, doubly, trebly, or more generally, nucleolated; colorless, or with melanic deposit. They increase commonly on

an endogenous plan, thus often presenting the phenomenon of parent-cells containing two or more generations of younger cells; occasionally they increase by the division of the nucleus, but never by the division of the cell-wall, or by splitting up into segments of the mother cell. The cell-wall, when young, is readily dissolved in acetic acid; as it increases in age, it becomes thicker, and is merely rendered more transparent by acid; by the same reagent the nuclei are corrugated and thickened at their margins, or remain unaffected; they may throw out pointed prolongations, but never pass into fibres; the cause of their various shapes is the arrest of their development at various stages.

Dr. Walshe found the average diameter to be 1-1900th of an inch, the extremes being 1-900th and 1-3500th of an inch; Vogel states the range of from 1-300th to 1-100th of a line. The most characteristic is probably the large oval cell, with thick walls, containing one, or several nucleolated nuclei. Lebert considers that they cannot be confounded with any others, but this is denied by some pathologists of equal eminence, who maintain the impossibility, in numerous instances, of distinguishing them from epithelial, cartilage, or embryonal cells in certain stages of their growth. With regard to the constancy of their occurrence Lebert affirms that "the principal element of cancer, its proper cell, is found in all truly cancerous formations." The same opinion is held with equal confidence by Hannover, but is disputed by most other pathologists. Thus, Dr. Walshe asserts, "we have known growths which have destroyed life with the cachexia of cancerous disease, and clearly exhibited the local progress and naked-eye characteristics of encephaloid; growths which, nevertheless, were composed of non-nucleated cells, undistinguishable from those of common exudation matter." In the same article, that upon *Adventitious Growths*, in the "*Cyclopædia of Anatomy and Physiology*," he gives numerous other illustrations of the impossibility of considering any single element, or even, in some cases, the association of several elements, as absolutely diagnostic, and concludes by saying, "a constant

and unfailing microscopical characteristic of cancer has hitherto been vainly sought for." Similar opinions are held by Müller, Bennett, and others, who maintain that there is no single element of cancer which can be considered as diagnostic; but that proof of its existence must be sought for in the association and peculiar arrangement of several. A growth composed of cells such as are above described, infiltrated through a fibrous stroma, and surrounded by a viscous fluid, may be considered as almost certainly cancerous; and the probability is further increased, though, in the opinion of Dr. Walshe, still not absolute, if fat be associated in large quantity with the cellular and fibrous structures. In short, the microscopical appearances alone, cannot be absolutely depended on; invaluable as the microscope is in assisting our diagnosis, we have the united testimony of those who are most familiar with its use, that it must not be considered as an infallible guide, but merely as one of the most important aids to other and more ordinary modes of observation.

Nuclei are found in cancerous growths, either in the interior of cells, or free; those contained in cells, are in general relatively large, averaging, according to Dr. Walshe, 1-3200th of an inch in diameter; they contain a variable number of nucleoli.

Fibres occur in different conditions; as very delicate filaments, rendered more transparent by acetic acid, and exhibiting an elongated nucleus; as fibrils studded with granules, and resembling those of the buffy coat of the blood; or thicker and stronger, resembling elastic tissue in appearance, branching or dichotomous, and rendered more clear by the addition of acetic acid. In encephaloid, the fibres are delicate, widely set, and with a general tendency to a curvilinear arrangement: in parts of the tumor, they may be collected together in great abundance, forming masses which are hard in proportion to their number and the closeness of their arrangement. In scirrhus, the fibres interlace closely, forming a plexus, of which the minute loculi have a tendency to a rectangular form, from the general straight disposition of the fibres. A section of epithelial cancer, examined

under the microscope, presents the appearance of fine fibres, which are in reality attenuated epithelial scales, closely matted together in a concentric arrangement, enclosing smaller spheroids of various sizes, in rounded clusters, each containing some material different from themselves, as more transparent. I borrow the above description of this latter variety of cancer from the lectures of Mr. Simon, in the "*Lancet*" for May 1822, which contain the only recent account of the microscopical structure that I have been able to discover, with the exception of Dr. Bennett's, which refers exclusively to individual cases.

Such is a brief summary of the coarse and microscopical anatomy of the three species of cancer with which, as occurring in the eyeball or its appendages, we are more immediately concerned; numerous varieties of encephaloid and scirrhus have been described in pathological works, but I consider it unnecessary to pursue the subject more at length; my object being merely to place before my readers the more prominent facts, and those which have a direct practical bearing, leaving the minutiae to be studied in other works where they are more appropriately introduced. I shall therefore pass on to consider the origin and physiology of cancer, a subject of paramount importance in connexion with the question as to the propriety of surgical interference.

ORIGIN AND PHYSIOLOGY OF CANCER.

It is the opinion of some pathologists that cancer-cells are formed primarily in the blood, and thence exude through the walls of the capillaries into the substance of the organ where the deposit occurs: and the detection of cancerous matter within the veins, as well as within the coats of the blood-vessels, has been thought to confirm the accuracy of this view. The rarity of the cases, however, in which the deposit has been found in these situations, is of itself sufficient proof that this is not the usual mode of its development; and a still stronger, and apparently insuperable objection, is drawn from the fact, that the size of the fully-developed cancer-cell renders it a physical impossi-

bility that it should escape through the unruptured capillary walls. A sufficient explanation, moreover, of these cases is afforded by supposing the existence of some undiscovered deposit, whence the absorption of cancerous matter might readily take place through the open mouths of the vessels which are ruptured during the process of softening; and when we recollect the great difficulty of discovering cancerous infiltration when in small quantity, and in certain situations, as within the cavities of the bones, such an explanation appears by no means improbable. The great mass of evidence hitherto has gone to prove, that cancer is usually developed from a blastema or exudation, exactly similar in appearance to that from which the normal structures are formed, namely, from a transparent, slightly viscous fluid, which generally coagulates shortly after its exudation, and which contains numerous molecules and granules. Such a fluid invariably accompanies and surrounds cancer-cells in the earliest stages of development in which they have been observed; and therefore, as all attempts to prove their primary formation in the blood have failed, and as their escape through the walls of the blood-vessels, even if so formed, would be a physical impossibility, we are warranted in concluding that their primary formation is extravascular, and that the exudation of a fluid blastema forms the first step towards their development. Why this exudation, whose physical properties appear always to be identical, should at one time be converted into healthy structure, and again, under other circumstances, into cancerous matter, is a problem hitherto unsolved; neither can we with any amount of certainty refer to the conditions under which it acquires the peculiar properties which determine its future mode of development. It is supposed by Dr. Walshe that these properties are impressed upon it chiefly while it is still mingled with the general circulation, and to a certain extent also, during its transudation through the vascular parietes. Dr. Bennett endeavors to trace its history still farther, and argues, that as the peculiar properties of the blood are the results of the primary and secondary digestions, those of the exudation matter are in all probability derived from the same

source. However this may be, every fact in the physiology and pathology of the disease indicates its constitutional origin, and proves, that though it may long be confined to one spot, though for years it may remain stationary and unchanged, still that it depends upon a taint in the system, and only requires favoring circumstances to be urged into rapid development. "A cancerous tumor under all circumstances, even should it remain single and stationary for years, is but the local evidence of a general vitiation of the system." Such is the proposition for which Dr. Walshe claims almost the certainty of a mathematical demonstration, and in this opinion he is supported by the great majority of modern pathologists; even those who maintain that under certain circumstances it may be considered as a local disease, express their views with such limitations as to render them almost identical. No amount of local irritation can induce the formation of a cancer, unless the peculiar and inexplicable property have been acquired by the constitution, of converting liquor sanguinis into cancer-cells instead of into the normal tissues; but this property being present, any irritation or injury which causes an unnatural influx of blood to a part, which induces exudation of liquor sanguinis, or depresses locally the vital energy, affording as it does the pabulum required, and the conditions under which the healthy tendency of nutrition can afford the least resistance, is likely to be followed by the deposition of cancerous matter.

The deposit once having taken place, its growth may proceed in two ways. In one, each cell has within itself the elements of a second, which, in its turn, possesses similar powers of propagation; this, which is known as the endogenous method, occurs in colloid, and occasionally also in encephaloid. In the other, granular matter is precipitated from the blastema, forming a nucleus around which the cell-wall is formed; this, the non-endogenous mode, is usually seen in encephaloid and scirrhus. In whichever of these modes the development proceeds, a constant supply of the exudation from which the cells are formed, is necessary for its continuance, and in proportion to the abundance with which this material is supplied, will be the rapidity

of the growth; when sparing, or altogether withheld, the tumor will be stationary; when, either from local irritation, or from intensity of the constitutional cachexia, the supply is abundant, it will increase rapidly in bulk, and the termination of the case will be accelerated.

The natural tendency of cancerous growths is to decay. After a longer or shorter period of existence, the cells become disintegrated, sometimes in groups, and sometimes generally throughout the tumor, which thus becomes softened and converted, more or less, into a pulpy or almost fluid mass; ulcerated openings then form in the skin, and the effete matter is discharged. While decay is thus proceeding in one part of the tumor, rapid growth may be taking place in another direction; and thus notwithstanding the profuse discharge, and the separation of large masses by sloughing, the bulk of the whole may be increased. Such cases prove rapidly fatal. The abundant discharge, and the perversion of the material which ought to supply the waste of the healthy tissues, completely exhaust the vital energy; and these depressing influences are still further increased in many instances, especially in encephaloid, by the copious hemorrhage which takes place from rupture of the blood-vessels, to whose delicate walls the softened mass no longer affords sufficient support. These ruptured vessels also form direct channels through which cancerous germs are absorbed into the circulation, whence they are deposited in various situations, there to vegetate and form secondary growths, which, if they affect the brain, heart, or any of the more essential organs, may prove the direct cause of death. These changes take place with varying degrees of rapidity. In encephaloid, the greater abundance of blood-vessels occasions more profuse hemorrhage, and affords greater facilities for absorption; while in scirrhus and epithelial cancer, the progress is in general more gradual; and death is, perhaps, more frequently caused by the exhausting influence of pain than by hemorrhage or profuse discharge.

Having thus taken a brief survey of the anatomy and histology of cancerous disease, as well as of its origin, mode of progress,

and termination, I shall proceed to consider the various ways in which it attacks the eyeball and the orbital appendages; premising a few remarks as to the frequency of its occurrence in these situations, a point upon which very erroneous ideas are prevalent among those who have not devoted particular attention to the subject. These misconceptions I believe to arise, in part, from the frequency with which specimens of the disease are to be found in pathological museums; a fact which merely illustrates the interest with which they are regarded, and which would not be so strongly felt were they more commonly met with. The only conclusive method of proving what I believe to be the fact, that cancerous disease of the eye is of rare occurrence, would be by accurate and extensive statistics, a desideratum which unfortunately cannot at present be supplied, owing to the imperfect manner in which the pathological records of many of our large hospitals are kept. I draw my conclusions, partly from the results of my own experience, and partly from the unanimous answers to inquiries on the subject with which I have been favored by several gentlemen who have had extensive opportunities of witnessing Ophthalmic disease. Out of 18,544 patients, seen at the Central London Ophthalmic Hospital by myself and my colleagues, there have been only two unequivocal cases of malignant disease; in both instances in the lids. Out of 14,343, seen by Dr. Hibbert Taylor, at the Liverpool Eye Dispensary, there has been but one, a case of encephaloid of the eyeball in an infant; and one only, an encephaloid tumor of the orbit, has been seen by Mr. Walker during five years' experience at the Edinburgh Eye Dispensary. Numerous other replies which I have also received, though not expressed numerically, tend to the same result, which is still farther confirmed by all that has been hitherto made out with regard to the statistics of cancerous disease generally.* It is unnecessary to pursue the

* Our own experience accords with that of the author and his correspondents. A few examples of the several varieties have been seen at Wills Hospital, but we cannot recall more than five or six unequivocal cases during a period of nearly twenty years that we have been connected with the Institution.—Ed.

subject farther, as enough has been said to show that the affection is not one of common occurrence; while much more extensive investigations than have as yet been made would be required, before we could with any certainty state its relative frequency compared with that of the other morbid changes to which the eye is liable. I shall, therefore, proceed at once to the next branch of my subject, which refers to the phenomena presented by cancerous disease when it attacks the eyeball.

ENCEPHALOID CANCER OF THE EYEBALL.

Encephaloid cancer of the eyeball has been occasionally met with in elderly persons, though so rarely that the fact has been questioned by some writers. Several instances, however, are on record, which prove the possibility of its occurrence: one in particular is mentioned by Mr. Saunders, where the examination of the eye after extirpation, and still more, the formation of secondary tumors in various parts of the body, leave no room for doubt as to the nature of the disease. The patient in this case was a lady thirty-five years of age. Several other cases are given by the older as well as more modern writers; but it is to be regretted that in most of the records there is an absence of detail which deprives them of much of the value which they might otherwise possess. The existence of several specimens of the disease in the Museum of the College of Surgeons, renders unquestionable the fact that the disease sometimes occurs in adult life; though it is equally certain that in the vast majority of instances it makes its appearance in early childhood, generally before the fifth, and rarely after the tenth year. Mr. Travers gives a drawing of a child eight months old, in whom the disease was congenital, the tumor having acquired the bulk of a walnut at the time of birth; and Dr. Mackenzie has seen it in an infant of nine weeks, in whom, as it had been observed six weeks previously, it also was probably congenital. Instances are not unfrequent in which it has been seen in an advanced stage of development before the completion of the first year; but the mass of

cases will be found to have occurred in children from two to four years of age. It is usually confined to one eye, but occasionally attacks both, either consecutively or simultaneously. I shall, to facilitate the description of the disease, divide it into three stages, an arrangement which presents considerable advantages.

The first includes the period between the discovery of the disease and its advance to the front of the eye, when its pressure first causes alteration in the size and form of the globe; in the second, the eyeball is enlarged and undergoes various changes in figure and appearance; in the third, the tunics of the eye give way, and the tumor appears externally.

First Stage.—The earliest symptom that generally attracts attention, is a shining, yellowish, and deep-seated reflection from the bottom of the child's eye, as if it contained a piece of metal; this is best seen in particular lights, and somewhat resembles the peculiar appearance of a cat's eye when seen in the dark. At the same time the iris will be found to have changed in color, being rather darker than that of the other eye; the pupil is dilated and sluggish, and vision, even at this early stage, is nearly or altogether lost. Slight external inflammation, lachrymation, and intolerance of light, occur in some instances; but these are by no means necessarily, or even frequently, present in the early stages; more usually, the child shows no indications of pain, and has every appearance of perfect health. As the disease advances, the cause of the metallic reflection becomes evident. It is now seen to be owing to a tumor springing up apparently from the fundus of the eye, of an irregularly rounded form, generally divided superficially into two or three lobes, and traversed by one or two small blood-vessels, which ramify on its surface; in color it varies from a deep orange hue to nearly white, the most usual being, perhaps, a bright canary yellow. This growth gradually increases in size, approaches the front of the eye, causing absorption of the vitreous humor, and presses upon the lens, which becomes opaque, and in most instances is ultimately absorbed; previous to this, however, it is pressed forward against the iris, which loses whatever brilliancy it may have retained,

changes to a grayish brown color, and is thrust forwards against the cornea, both the anterior and posterior chambers of the eye being completely abolished. Towards the conclusion of this stage, the eye is undergoing considerable tension from the internal pressure; it feels hard, its motions are limited, there are frequent attacks of external inflammation with epiphora, and the child evidently suffers frequent and severe paroxysms of pain, becoming restless, feverish, and emaciated.

Second Stage.—The external parts of the eye now undergo a change; the cornea expands and becomes opaque, the sclerotica thinned by absorption, allows the dark-colored choroid to shine through it, and is irregular in outline, rising into small dark-colored knobs where the pressure has been most severe, or the absorption most rapid. In many instances it is so densely covered with large varicose vessels, that no alteration in color is perceptible. The eyelids now become œdematous, and the eyeball prominent, and, apparently, greatly enlarged in size; I say apparently, for though I admit that enlargement takes place to a considerable extent, I cannot conceive the possibility of the dense fibrous structure of the sclerotica expanding to two or three times its normal dimensions, as some authors have asserted. I agree rather with Dr. Argyll Robertson, that "it is probable that, in most instances, these writers have been deceived by an unnatural prominence being given to the eye by the infiltration of the cellular tissue of the orbit projecting the eyeball forward, thus giving it the appearance of being augmented in bulk." This stage terminates in the escape of the fungus from the interior of the eye; and this may take place either through the cornea or the sclerotica. In the former, the cornea becomes more and more attenuated, pus or lymph is effused into its structure, and ulceration or sloughing ensues. These changes are not witnessed in the sclerotica, the fibres of which, previously thinned and opened up by a long-continued distension, finally give way in a small rent, through which the morbid mass, still covered by the conjunctiva, protrudes. During the latter part of this stage, when the eye is subjected to great distension, the sufferings of the patient are

acute; the pain generally comes on in paroxysms, extends over the whole side of the head, and even down the neck, and is accompanied with the usual symptoms of febrile excitement. Great relief is experienced when the fungus escapes and the distension is removed.

Third Stage.—The tumor, now released from pressure, rapidly increases in bulk, so as in a short time to distend the orbit and eyelids, and efface all appearance of the eye. When it has escaped through the sclerotica, at some little distance from the cornea, it is at first covered by the conjunctiva, and this may remain entire until the tumor has attained a considerable bulk, when it is finally destroyed by ulceration and sloughing. In other cases of less frequent occurrence, the sclerotica gives way at the back part of the eye, so that the fungus escapes directly into the orbit. Under such circumstances the eyeball will be displaced in various directions according to the position of the protruded mass, until finally this latter has acquired sufficient bulk to extend beyond the margin of the orbit, when it overlaps and conceals any remains of the eyeball that may have been visible.

The fungus, on its first escape, is soft, and generally of a light red or yellowish color; this appearance, however, is rapidly changed as it increases in bulk; the surface becomes irregular and covered with ulcerations which discharge profusely; large, livid, and fungoid granulations form, which bleed freely on the slightest touch; interstitial hemorrhage takes place, forming clots in the interior of the growth, while large masses are detached from its surface by sloughing, giving rise to fresh bleeding, in some instances so profuse as to prove the immediate cause of death. No diminution of the size of the tumor ensues from the separation of the sloughs; on the contrary, the growth seems to take place with increased vigor, and is limited only by the length of time that the patient survives. I have already spoken of the enormous magnitude to which encephaloid sometimes attains; while masses of the size of a large orange, or of a man's fist, are not unfrequent. The skin of the distended eye-

lids, and of the adjoining parts of the face, assumes a dark livid hue, and is traversed by large varicose veins ; and the glands of the neck, and under the lower jaw are enlarged, and, in exceptional cases, proceed to ulceration. Death finally ensues, in some instances from extension of the disease to the brain, when it is preceded by coma or convulsions : in others from constitutional irritation, and the exhausting effects of pain, hemorrhage, and discharge.

A post-mortem examination discloses that the contents of the orbit have undergone great changes. In cases of long standing, all means of distinction between the various textures is lost by their disorganization ; the bony structures are softened and expanded, and frequently partially removed by absorption, so that the diseased mass is in direct contact with the brain. In many, I believe in most instances, the optic nerve will be found to be involved in the disease ; thickened by the deposit of cancerous matter, except where it is constricted by the foramen opticum during its passage to the brain, and frequently again expanded so as to form a tumor, immediately on its entrance within the skull. This change may take place at the earliest as well as at the most advanced stages of the disease ; a pathological fact of much importance, and one to which I shall again refer, as bearing strongly on the question as to the propriety of operating in these cases. In pursuing our examination to the other regions of the body, we may find secondary cancerous deposits in various situations ; for in this respect, encephaloid obeys the same laws as when it commences primarily in any other organ. The brain seems to be very liable to these deposits, but in many instances, when in this situation, they can scarcely be called secondary, as they are the consequence rather of direct extension along the tract of the optic nerve. The uterus and the testicles, and the various thoracic and abdominal viscera, are the seats of what is strictly called secondary deposit, and will be found to be attacked in the usual order of their liability.

Much discussion has arisen as to the particular tissue of the eye which is the primary seat of the cancerous deposit ; and this

is a question which it is very difficult to determine by post-mortem examination, as we seldom have an opportunity of making a dissection until the disease has so progressed as to involve all the tunics, and in an especial manner the retina, which, owing to the delicacy and great vascularity of its structure, is peculiarly unfitted to withstand either the extension of the disease, or the effects of pressure. The uniform manner in which the tumor appears to spring from the fundus of the eye, and the constancy with which the nervous structures have been found on dissection to be to a greater or less extent involved, have led to the opinion now almost universally held, that the disease has its origin in the optic nerve, just as it begins to expand into the retina, or in the latter tunic, close to the nerve. While I admit that in most of the instances in which any conclusions can be drawn from dissection, this opinion will be found to be correct, still exceptional cases occur, which show that exclusive views on the subject are inadmissible, and that the opinion held by Mr. Travers, "that this is not a disease of this or that texture, as writers would insinuate, but of all the textures, the crystalline and cornea excepted, which yield to its progress, but never exhibit a specific change of texture," is more in accordance with fact. A careful examination of the preparations in the Museum of the College of Surgeons, has led me to the conclusion that the disease may originate in any of the tissues of which the eye is composed, but that in the majority of cases the retina is its primary seat, and that this tunic never eventually escapes contamination, to a greater or less extent.

From the striking appearances exhibited by encephaloid from the very commencement, its diagnosis might be thought to be an easy matter. Such, however, is not the case. There is not any disease, as to the nature of which mistakes are more constantly made; and I shall endeavor to show that a positive diagnosis, until the fungus has protruded through the external coats of the eye, is in the present state of our knowledge totally impracticable. I shall first mention one or two of the complaints with which it may be confounded by a superficial or unpractised ob-

server, but from which it may be readily distinguished by a little attention.

The opacity of the lens occasioned by the pressure of the tumor, has been mistaken for idiopathic cataract, and attempts have even been made to perform the operation for depression. I need scarcely say that such an error ought not to occur. The condition of the lens may for a time conceal the true nature of the affection, but the history of the case, the discolored and bulging iris, and the general symptoms of internal disorganization, which are invariably present, will be sufficient to deter any surgeon of ordinary intelligence from operative interference.

The color of the vitreous humor may be altered in various ways, giving a dull red or yellowish appearance to the pupil, which might at first sight cause some embarrassment. The most ordinary cause of this discoloration is effusion of blood into the hyaloid cells; this may be almost invariably traced to the effect of a blow, or of some violent muscular exertion; it occurs suddenly, the blood is readily absorbed, and it seldom produces any very serious symptoms. A deposit of lymph on the surface of the retina from idiopathic or traumatic inflammation, occasions a yellowish reflection through the pupil; but the history of the case will sufficiently indicate the nature of the disease, while the indefinite and unchanging appearance of the discoloration, and the absence of anything like a tumor gradually advancing to the front of the eye, will assist still farther in forming a correct diagnosis. Attentive observation of the progress of the affections, and careful inquiry into their history, will seldom leave much doubt as to their real nature. It is far otherwise, however, with deposit of inflammatory exudation or scrofulous matter in the interior of the eye, occurring either spontaneously, or as the result of injury, which may assume an appearance so exactly similar to that which was formerly considered as peculiar to malignant disease, as to render the diagnosis, in most instances of its occurrence, absolutely impracticable.

The true nature of these cases seems to have been first clearly pointed out by Mr. Travers. In several instances of what ap-

peared to be malignant disease, as indicated by permanently dilated pupil, with a deep-seated opacity of a splendid yellow tint, the healthy appearance of the children induced him to abstain from operating, when he found, to his surprise, that the disease remained stationary for years, unaccompanied by any disorder of the health. Subsequent observation induced him to express the opinion that the "peculiar tint and splendor of the opaque substance, is not to be depended on as a sign of malignity;" and he remarks further, in a paper read before the Medico-Chirurgical Society, "that the appearance I allude to is very analogous to that of the medullary tumor, will be inferred, when I inform the Society that (in the case of a lady who several years since recovered with the loss of sight, but is still in perfect health), at a consultation, including some eminent members of the profession, the extirpation of the organ was overruled by one dissentient, although I had sat down to perform it on two several occasions." Another instance came under his observation, in which a wound of the eyeball with a fine-pointed pair of scissors, was followed by a deep-seated fawn-colored, resplendent surface, with red vessels branching over it, presenting exactly the appearance of malignant disease. In this case vision was lost, and the eye gradually shrank. The accuracy of these views has since been confirmed by numerous observers. Mr. Lawrence has frequently witnessed similar instances at the London Ophthalmic Infirmary, and details the case of a boy, ten years of age, in whom a wound of the cornea was succeeded by a bright yellow deposit, which gradually extended over the whole fundus of the eye, was accompanied by change of color in the iris and extinction of vision, and led to softening and atrophy of the globe. Dr. Mackenzie, in illustrating the same subject, details an interesting case, in which the same appearances were produced by suppuration of the globe. The patient, a boy eleven years of age, was admitted into the Glasgow Eye Infirmary on account of an attack of inflammation of the eye, which had followed exposure to a thunder-storm, by which he had been much frightened. Vision was extinct, the pupil was dilated and fixed, the iris changed in color, and symp-

toms of general inflammation of the globe were present. "On examining the bottom of the eye, a tawny appearance presented itself, exactly similar to that which attends the incipient stage of medullary fungus." These changes were considered by Dr. Mackenzie and his colleagues to indicate the presence of malignant disease, and extirpation was proposed, but as the friends would not consent, calomel and opium were administered. The eye continued to enlarge, the tawny appearance became still more distinct, the lens was forced forwards in contact with the cornea, and the sclerotica finally yielded towards the inner canthus, giving exit to a quantity of thick purulent matter, after which the globe shrank and became atrophic.

Mr. Tyrrell relates cases which he has witnessed, both in children and in adults, in which prominent yellow tumors with red vessels ramifying over their surface, have gradually disappeared under a steady and well-directed course of treatment. In one of these cases, extirpation had been determined on, and postponed only on account of the condition of the patient's general health. Mr. Dalrymple, in his "Illustrations of the Pathology of the Human Eye," observes: "The metallic lustrous appearance of the pupil may be caused by a deposit of simple exudation-cells, in fibrinous dropsy of the eye, in acute or chronic choroiditis, or in scrofulous inflammation;" and he concludes that the diagnosis in the early stages is therefore impossible. It is unnecessary farther to multiply authorities. The frequent occurrence of such cases is now admitted by all ophthalmic surgeons, and the difficulty of diagnosis is acknowledged. It has been asserted that in the non-malignant disease, the metallic lustre is not so brilliant, and the color not so deep; that the iris and lens remain unchanged; that the globe becomes atrophic without previous enlargement; that the tumor never proceeds so far as to rupture the coats of the eye and escape externally. These, and all other attempts which have hitherto been made to establish diagnostic marks, have failed; their accuracy having been disproved by an appeal to recorded cases. The occurrence, in a scrofulous subject, of the peculiar symptoms soon

after the receipt of an injury, or, on the other hand, an hereditary predisposition to cancer, would be sufficient reason for forming a strong opinion as to the scrofulous or malignant nature of the disease; but in the present state of our knowledge the only sure grounds upon which we can pronounce authoritatively as to its character, are, the atrophy of the globe, or the progress of the growth after it has escaped from the interior of the eye.

I may just allude to the proposal of Mr. Travers to make a deep incision across the globe in doubtful cases. This proposal was made at a period when the pathology of these affections was very imperfectly understood; and the advances that have been made since that time, render such a proceeding inadmissible. When the deposit is scrofulous, any operative interference is unnecessary; when it is malignant, an incision would only hasten the fatal termination.

I am not convinced that encephaloid cancer attacks the surface of the globe primarily. In the "Northern Journal of Medicine," for December, 1844, Dr. Argyll Robertson relates a case in which he believes this to have taken place. The patient, a woman sixty-two years of age, had been subject from childhood to attacks of inflammation of the left eye. Three years before she came under Dr. Robertson's notice, one of these was followed by the formation of a fleshy, elevated ring round the cornea, which after remaining stationary for a year and a half, began to increase, and was accompanied by severe lancinating pain, darting through the temple and head; the growth appeared to proceed from before backwards, projecting the eyeball from the socket till it could no longer be covered by the lids. Excision was followed by rapid recovery, and the patient survived the operation for twelve years, when she died from general decay, without any marked disease. The coats and the contents of the eyeball were perfectly healthy; "exterior to the sclerotic, and under the conjunctiva, it was surrounded by a dense mass of medullary sarcoma, which, when subjected to the microscope, presented spherical cells." While I do not mean to deny

that this may have been a genuine case of encephaloid disease commencing on the surface of the eye, I think that the proof adduced is far from sufficient. We can draw no conclusion from the bare announcement of the presence of spherical cells; the cure of encephaloid cancer by operation is extremely rare; and all the appearances above described are produced by chronic inflammatory deposit in the orbital tissues.

Fungus-looking growths of various kinds occasionally spring from the conjunctiva, near the margin of the cornea; these, when neglected, may attain a very large size, completely concealing the eye, and projecting between the lids in the form of a livid tumor, which bleeds readily when handled. There can be little difficulty, in most cases, in ascertaining the external origin of such growths; and this, so far as we yet know, must be taken as sufficient proof of their non-malignant nature; where they have proceeded so far as to destroy the eyeball and to fill up the orbit, as we are informed by Dr. Mackenzie that they occasionally do, the diagnosis will be difficult, and must depend chiefly upon the history and progress of the case, and the absence or presence of the cancerous cachexia.

MELANOSIS.

I have stated that it is the general opinion of modern pathologists, that deposits of melanic pigment do not occur in the human subject, except in association with some other structure; that no growth contains it so frequently as cancer; that encephaloid is the variety of cancer with which it is most frequently combined; and that, as it occurs in the eye, it is invariably associated with this growth, which, moreover, is not modified in any respect by its presence. That these opinions are, in the main, correct, I readily admit, but I have seen reason to doubt their universal applicability; and I think it can be shown, that in some respects the peculiarities of encephaloid do undergo modification, or, what is equally probable, that these melanotic growths are more frequently of a non-malignant nature than is commonly supposed.

I have shown that encephaloid is a disease almost peculiar to early life, and that instances of its occurrence after the age of puberty are comparatively rare. Such is not the case with melanosis, which is unknown in infancy. The earliest age at which I have seen it occur, has been twenty-three; the patient, a female, was under the care of Mr. Lawrence, at St. Bartholomew's Hospital, during my house-surgeoncy. Mr. Lawrence met with it, in one instance, at the age of twenty-two, but confirms the general statement, that it rarely occurs before the middle period of life.

In other respects, it does not differ materially in its progress from uncomplicated encephaloid. At the commencement, extinction of vision is the only objective symptom; the shining reflection from the fundus of the eye is wanting, and there is seldom any way of distinguishing it from amaurosis, though, in exceptional cases, a dusky, slate-colored tumor may be seen deep in the eye. As the disease advances, however, the symptoms of distension become evident; the eyeball is gradually enlarged; the lens becomes opaque, and, with the iris, is thrust forward against the cornea; the sclerotica assumes a dusky hue, is traversed by numerous large, tortuous vessels, and is elevated into dark-colored prominences, which eventually give way, and permit the escape of the dark-colored tumor. This increases in size; there is occasional bleeding and sloughing, and copious discharges of thin, inky fluid: death takes place, either from the exhaustion produced by the local disease, or from the formation of secondary deposits, of a similar nature, in various parts of the body. When the eye is examined, after death or after extirpation, the tumor is found to be soft in consistence, and of a deep sooty-black color, streaked here and there with various shades of brown or gray. This appearance is well illustrated by a preparation in the Museum of the Royal College of Surgeons. In Mr. Lawrence's experience, melanosis has always appeared to originate in the choroid. He states that where it is deposited, the choroid cannot be distinguished, while in those

parts of the eye to which the disease has not extended, this tunic has not undergone any alteration.

At the period of its growth, before the sclerotica is ruptured, it is liable to be confounded with sub-choroid dropsy. Dr. Robertson has witnessed two instances of the latter disease, in which the mistake had been made, and in which he saved the eyes from excision; he agrees with Mr. Lawrence in considering the state of the iris as the best means of diagnosis. In melanosis, the iris is thrust forwards by the opaque lens, in contact with the cornea; and though the pupil is generally dilated, it is not irregular, or only to a very slight degree; in sub-choroid dropsy, there is no protrusion of the iris, but it is dragged in the direction of the tumor of the sclerotica, so as frequently to be altogether invisible on that side of the eye.

Melanotic growths occasionally take their origin from the outer surface of the globe. In his "Illustrations of the Pathology of the Human Eye," Mr. Dalrymple relates and figures a case of this nature which occurred in the practice of Mr. Cooper, and which exactly resembled another that had been under his own care. The patient was a lady sixty-two years of age. After many attacks of superficial inflammation, a tumor, pyriform in shape, and of a dark bluish brown color, sprang from the junction of the sclerotica and cornea, and gradually increased till it covered half of the latter tunic. It was dissected off without opening the anterior chamber, and seven years after the operation, the cornea still remained clear, and there had been no return of the disease. The tumor was examined microscopically immediately after its removal, and the following description is given of its appearance. "Its structure was soft, dark brown, and made up of nucleated cells, of a discoid elliptical figure; flattened and varying in size, some transparent, others filled with dark-brown sepia-like material. In some of the cells the nuclei were numerous, in others, few; in certain points there appeared congeries of minute cells aggregated together, while in others a few large cells were connected one to the other; the long diameter of the largest measuring 1-2200th of an inch. The parietes

of the cavities in which the cells were contained were composed of fibres, which here and there were also collected into bundles. The tumor seems to have had its origin in the development of these cells in the interspaces of the fibrous tissue at the junction of the sclerotica and cornea."

A growth apparently of a similar nature, was removed from the eye of a gentleman aged sixty, by Dr. Hibbert Taylor, of Liverpool. It had commenced four years previously with vascularity and a dark appearance of the outer part of the sclerotica, and increased slowly and without pain till the time of its removal, when it had attained the size of a sewing-thimble. It was attached by a narrow neck to the outer part of the right cornea at its junction with the sclerotica: was of a dark bluish black color, and soft consistence, and bled when handled; the pupil, and the eye generally, retained their natural appearance, and the patient could distinguish one person from another with this eye. The tumor was removed by ligature in June 1849: it soon reappeared, and in January 1850, it had attained nearly its original bulk; the pupil was sluggish, and vision was limited to the perception of light and shadow, but the eyeball retained its natural size and form. It was on this occasion excised with scissors, and has not again returned. Mr. Travers describes a tumor which he removed from the eye of an elderly lady, and which was in his experience unique; a careful examination of the illustrations which accompany his description induces me to think that it was a case of melanotic deposit in the structure of the cornea. It was of a dark-purple color, lobulated, so as somewhat to resemble a bunch of currants, and of sufficient size to project between the lids, and cause great inconvenience. When examined, after removal, it was found to have its origin in the cornea, and to a certain extent also in the sclerotica; its section was of a dark color and varied consistence, being soft and pulpy in some places, firm in others.

SCIRRHUS.

Scirrhus of the eyeball, as a primary affection, is a very rare

occurrence.* Doubts as to its existence are expressed by Mr. Wardrop, who had never witnessed nor obtained a correct account of a single case; Mr. Tyrrell does not even allude to it, and Mr. Lawrence, in the last edition of his work on diseases of the eye, expresses himself nearly to the same effect as Mr. Wardrop; since then, however, a case has come under his observation, of which he has given a brief description in the "Medical Gazette," July 2d, 1847. Mr. Middlemore appears to have seen more of the disease than any other English author, and his description of its origin and progress is the fullest that we possess, though, unfortunately, he does not illustrate his general statements by any detailed cases. Little reliance can be placed upon what is said on this subject by the French authors, on account of the indiscriminate manner in which they apply the term "squirrhe" to every affection of which pain and hardness are prominent symptoms. As I have not myself witnessed a genuine instance of the disease, my description must be entirely borrowed.

Just as in other parts of the body, scirrhus does not attack the eyeball until middle or advanced life; the most common age is between forty and fifty, and it has been more frequently observed in females than in males. It has been seen to follow a blow or other injury, but more commonly is preceded by numerous attacks of inflammation, generally of an intractable nature, and is attended with more or less pain. After one of these attacks, there is dimness of vision, and this gradually increases until the sight is totally lost; the cornea becomes flattened and hazy; the sclerotica assumes a dirty yellow hue, is traversed by enlarged vessels, and losing its regular rounded shape, becomes puckered, contracted and nodulated. As the disease advances, the eyeball generally shrinks, though in some instances it is said

* A case of scirrhus degeneration occurring primarily in the eyeball, and ultimately involving the whole contents of the orbit, came under our care a few years ago, but at a period too late for extirpation, and opportunity was not permitted of determining its precise nature by an operation. The patient, who was nearly fifty years of age, and the mother of ten or twelve children, died eventually of constitutional irritation, with symptoms also indicating implication of the brain.—Ed.

to enlarge slightly; the different tunics are gradually invaded, and all distinction of texture is lost; there is constant severe, lancinating, or burning pain, generally with nocturnal exacerbations; profuse lachrymation and spasmodic closure of the lids are also common, as well as extension of the pain to the whole side of the head. The disease is usually long in passing the limits of the eyeball, but eventually extends to the surrounding parts; the eye becomes fixed and immovable, and the whole contents of the orbit are converted into a scirrhus mass, firmly adherent to the bone, which, in some instances, is also involved in the disease. This condition of parts may continue for a long period, and the patient may succumb, worn out by pain, constitutional irritation, and want of rest, without the appearance of ulceration; in fact, Mr. Middlemore asserts that he has never witnessed this termination of the disease; ulceration has been observed, however, by other authors, who describe it as commencing in the conjunctiva, and gradually extending to the whole diseased mass, involving the lymphatic glands, and producing frightful destruction of the face.

In the case which was observed by Mr. Lawrence, the patient was a middle-aged man; "the tissues of the anterior and inferior third of the right eye were occupied by an irregular growth of firm and very vascular substance, with a granular, warty, and very vascular surface. The posterior segment of the eye, and the lachrymal appendages were sound." The eye was extirpated by Mr. Wormald, and the patient died two years afterwards, with medullary tumors in the heart and various other organs. There was no return of the disease in the orbit. This is the only case of primary scirrhus of the eyeball which I can find recorded; further details are very much wanted.*

* A farmer, fifty years of age, applied to the editor in the summer of 1850, with a fungous growth of an irregular surface, vascular texture, and firm, granular appearance, occupying the inner angle of the left eye. The excrecence, which was intimately connected with the sclerotica, and with the cornea also, where it had encroached upon that membrane, was attended with severe pain; and the health of the patient being much impaired by suffering and anxiety, he left the city on leave of temporary absence, for his home in a distant part of the country, and did not afterwards return.

I may perhaps mention here a curious case which is given by Mr. Lawrence in the same paper, and considered by him to be unique. By a less experienced observer it might readily have been mistaken for scirrhus. A soldier of the Guards, twenty-four years of age, was seized suddenly with pain and inflammation of the eye, and vision was soon afterwards lost; notwithstanding a variety of treatment, no improvement was effected, and the patient was brought to Mr. Lawrence four months after the first attack. The globe was unnaturally prominent, distending and protruding the lids; the conjunctiva was uniformly red and thickened, and there was under it an undefined dark prominence behind the edge of the cornea, on the nasal side of the globe. The crystalline lens was opaque, and pushed forwards against the cornea. The patient had all along suffered severe pain, and his general health was impaired. Some time afterwards the globe was still further protruded, so that the lids could not be closed, and it formed a red, fleshy mass, in the centre of which there was an ulcer the size of a sixpence, in the situation of the cornea, which it evidently penetrated. The eye was now extirpated—I was present at the operation; the patient made a rapid recovery, and in a few weeks was again fit for duty. “The globe was filled with a diseased growth, moderately firm, partly yellowish, partly reddish, of considerable vascularity, without any trace of the normal structures; it was very much like what is frequently observed in a scrofulous testicle. If it had been seen detached, no one would have supposed that it had formed part of an eye. Upon careful examination, it was found that this diseased mass was choroid and iris, both of them much thickened, entirely altered in structure, and in great part deprived of their normal coating of pigment cells. In the middle of the eye there was a small cavity, with smooth and darkish surface, containing a little dark fluid. This cavity was filled with a mass consisting of the reflected iris; it had pushed forwards against the posterior surface of the cornea, and had been from thence reflected towards the centre of the globe. The sclerotica was much thickened, in some parts to the extent of a quarter of an

inch, its texture being softer than usual. The cornea was extended and thin. At the extremity of the optic nerve, there was a small shred of the retina. The ulcerated spot upon the anterior surface of the globe, penetrated the cornea, and opened into the anterior chamber. There was no trace of crystalline lens or ciliary processes." It was also examined microscopically. "The sclerotic coat, 4-5 lines in thickness, was composed as usual of white fibrous tissue. The choroid was thickened by the deposit of numerous small granular corpuscles (cytoblasts), and a few nucleated cells, in a dense fibrous stroma. The pigment cells of the choroid were in a great measure deprived of their coloring matter."

MALIGNANT TUMORS OF THE ORBIT.

Malignant tumors exhibit no peculiarity in the physical changes they produce in the orbit or in the orbital appendages, by which they can be distinguished, till they have approached close to the surface, or have produced their peculiar deteriorating effect upon the constitution; and until then, the same remarks apply to them as to non-malignant growths, on which I have fully dwelt in my chapter on Tumors.

I shall therefore merely make brief mention of the different forms in which malignant disease has been observed to occur in this situation, illustrating my remarks by a few cases which have either come under my observation, or have been supplied to me by the kindness of friends.*

ENCEPHALOID AND MELANOSIS.

Encephaloid and Melanosis occasionally have their primary seat in the orbital tissues, forming tumors which protrude or dis-

* Medullary formations within the orbit, when they first make their appearance at its margin, sometimes impart to the finger a deceptive feeling of fluctuation; and in other respects simulate so closely an encysted tumor containing fluid, that a correct diagnosis is not always practicable. The age, appearance, and general condition of the patient may throw some light on the subject, and if doubt still exist, it will be dispelled by an exploratory puncture.—ED.

place the eye in various ways, according to their situation and the direction of their growth. Cases are recorded by Mr. Lawrence, Dr. Mackenzie, and others, in which these diseases appear to have been consecutive to local violence, and there is no doubt that injury occasionally produces them, though in perhaps the majority of cases, no directly exciting cause can be assigned. The seat of the deposit may be either the cellular or the adipose tissue; in some instances, growths of considerable size have been found to spring from the optic nerve, while the eye was still sound. It is important to recollect that when these growths attain a large size, their pressure is very liable to cause absorption of the bony walls of the orbit; hence, should any attempt be made to remove them, the greatest caution will be necessary to avoid injuring the brain. That this is not an imaginary danger, we have the authority of Dr. Argyll Robertson, who, on one occasion, while extirpating an enlarged eyeball, had his finger in contact with the membranes of the brain, the greater part of the orbital plate of the frontal bone having been removed by absorption.

Malignant growths, originating in the immediate neighborhood of the eye, as for instance in the frontal cells, the Antrum Highmorianum, &c., frequently make their first appearance in the orbit, after having given rise to symptoms the nature of which was, for the time, misunderstood. I am indebted to Mr. Solly for the details of the case to which the annexed illustration refers.

The first symptom that called for surgical interference, was epiphora, caused apparently by obliteration of the ductus ad nasum; at this time there could have been no external indication of the true nature of the disease, as Mr. Travers, under whose care the patient then was, introduced a silk seton through the lachrymal tube, and allowed it to remain for two months. The tumor subsequently appeared at the inner angle of the eye, and its true nature was recognised. When it had increased to about the size of a walnut, an attempt was made to remove it, which was only partially successful, owing to its soft and friable consistence.

During the operation, the finger passed freely into the nostril, the bones having been absorbed. The fungous mass was repressed by pure nitric acid, and the man left the hospital considerably

Fig. 142.



relieved, but returned in about a year with active disease in both orbits. The growth pressed downwards into the nostrils, and at the same time upwards so as to cause absorption of the orbital parietes, and death by pressure on the brain.

EPITHELIAL CANCER.

Epithelial cancer occasionally appears in the orbit in the form of a subcutaneous or subconjunctival tumor, which may acquire considerable bulk before it ulcerates, or shows any indication of

malignity. I have lately witnessed two cases of this description, which, as they present several points of great interest, I shall give in detail.

A man, sixty years of age, applied to my colleague, Dr. Taylor, at the Central London Ophthalmic Hospital, on account of a tumor at the upper and inner angle of the orbit, which he had

Fig. 143.



first observed several months previously, and which was gradually increasing and displacing the eye downwards and outwards. It was about the size of a nutmeg, smooth and regular on the surface, firm and elastic, and immovable, but apparently not attached to the skin (Fig. 143). There was occasional slight pain in the situation of the frontal nerve, which was pressed upon by the growth. Vision was not impaired, though the eye was considerably displaced, and as this was gradually increasing, he was anxious to have the tumor removed. As there appeared to be nothing to contra-indicate the operation, his wish was complied with. The tumor, which was found to be pretty firmly adherent at one point to the bone, was removed, apparently entire, partly by evulsion, and partly by dissection, and the spot to which it had adhered was carefully scraped. The wound healed by the first intention, but the eye only partially recovered its proper position. A few weeks afterwards it was evident that the disease was again growing; the same situation was reoccupied by a firm, elastic growth, and the displacement of the eye became greater

and greater. A second attempt was therefore made to effect its complete removal, and the operation on this occasion was attended with considerable difficulties, as the morbid growth had extended deep into the orbit, adhered firmly to the bone and the upper tarsal cartilage, and was thoroughly matted between the muscles and other surrounding textures. The wound was carefully washed, every portion that presented a suspicious appearance dissected out, and the edges brought together by sutures. The relief afforded by the operation was only temporary, as the disease soon reappeared. At present, after an interval of six months, the eye is much displaced and compressed. The tumor has increased to the size of a hen's egg, and has involved the skin, which is of a dark purple color, studded here and there with small tubercular elevations. An ulcer, the size of a sixpence, occupies the seat of the wound; the discharge is scanty, but contains numerous characteristic cells. The patient suffers occasional severe pain, and his general health is much impaired.

Immediately after the last operation, the tumor was submitted to microscopical examination by Mr. Quekett, who pronounced it to be a well-marked specimen of epithelial cancer. While making the examination he received for inspection another tumor which had just been removed from the orbit of a young man, aged twenty-two, by Mr. Guthrie, and which proved to be of an exactly similar nature. The patient had been for some time annoyed by lachrymation and irritation of the left eye, when he discovered a small swelling along the lower margin of the orbit. This was treated by leeches, poultices, and lotions, but continued to increase in size, and produced partial exophthalmia. Mr. Guthrie being now consulted, recommended and effected the removal of the growth. The operation was succeeded by severe inflammation and rapid extension of the cancer. I had an opportunity of seeing the patient about four months after the first appearance of the disease, and six weeks after the operation. Both lids were then involved, forming a tumor about the size of an orange, which completely concealed the eyeball, was of a dark livid color, traversed by large veins, ulcerated in many places, and bled pro-

fusely when touched. He was worn out with pain, discharge, and hemorrhage, and was evidently fast sinking under their exhausting influence.

ENCANTHIS.

The caruncula lachrymalis is said to be the occasional seat of scirrhus enlargement. It must be a disease of very rare occurrence, as it has never been observed by Messrs. Wardrop, Travers, Lawrence, or Guthrie; it is described, however, by Dr. Mackenzie, and Mr. Middlemore has removed a tumor which he believes to have been of this nature.

Authors speak of it as forming a hard, irregular swelling, mottled with spots of a pale color, traversed by varicose vessels, and liable to bleed when touched. If left to run its course, it eventually ulcerates; the discharge is acrid and excoriating, and the ulceration extends to the surrounding textures, after the manner of scirrhus sores generally.

EYELIDS.

Encephaloid and melanosis occasionally, though rarely, have their primary seat in the eyelids. In this situation, they present no peculiarities which merit separate consideration.

Scirrhous and epithelial cancer are the varieties of malignant disease to which the lids are especially liable, and in the great majority of cases, the under lid is the one that is attacked; a fact of which no satisfactory explanation has hitherto been given.

Occurring here, these two varieties of cancer present in many respects, a close resemblance to each other; so close, indeed, that it is to their history and mode of progress, rather than to their external appearance, that we must look for marks by which to distinguish the one from the other. Dr. Jacob, and after him Mr. Middlemore, were the first to draw attention to the fact that malignant ulceration of the lids occurs under two forms; and the general accuracy of the distinctions which they drew, has been confirmed by subsequent observers, who have placed it beyond a doubt that the "Peculiar Ulcer," which they described, was that

which is now known as epithelial cancer. Both forms of the disease are unknown in childhood; they occasionally attack young adults, but are much more common in those somewhat advanced in years.

In scirrhus, the attention of the patient is generally first attracted by a feeling of stiffness in the lid, by which its free motion is impeded, and on farther examination, this is found to be due to an undefined thickening and hardening of the subcutaneous cellular tissue. As the disease advances, adhesions are contracted to the bone, and the lid may appear as if somewhat retracted within the orbit; the skin also gradually becomes involved, and assumes a dusky, livid hue, from the presence of numerous small veins which ramify upon its surface. In some instances, severe lancinating pain is an early and prominent symptom: in others, there is merely a sense of uneasiness or itching, which induces the patient to rub, or scratch the part, and thus, by breaking the skin, leads to the commencement of ulceration.

This process having once begun, follows the same destructive course as in other parts of the body, and produces the most frightful deformity. The bones as well as the soft parts are destroyed by ulceration, and the nose, mouth, and orbit have been seen to be thrown into one large cavity. As is the case with fibrous structures generally, the sclerotica long resists the attacks of the disease, and though all the other contents of the orbit should be destroyed, the eyeball may be seen lying in the cavity, almost as completely detached as if it had been dissected; in other cases, the irritation to which it is exposed, leads to inflammation and sloughing of the cornea, the humors escape, and the globe collapses. Death takes place from the contamination of the system, and the formation of secondary deposits, or from the exhausting influence of pain and constitutional irritation. Epithelial cancer commences by the formation of small white elevations or tubercles, towards the inner canthus; they are hard to the feel, and appear to be situated in the texture of the skin. They slowly enlarge and increase in number, producing, as Mr. Middlemore says, the appearance that would be

caused "by introducing a knotted thread, or a minute white bead, or a series of them, beneath the skin of the eyelid." In process of time, these tubercles coalesce into a mass; itching or uneasiness is felt; the surface is irritated or scratched, and ulceration commences. This proceeds gradually, but irregularly; at one part of its circumference it may be extending, while at another, cicatrization may be going on. Ultimately, the destruction of the face which takes place is equal to that which is seen in scirrhus; the soft parts of the orbit and cheeks being destroyed, and the cavities of the mouth, nose, and orbit, thrown into one, by the ulceration of their bony parietes. One of the most striking peculiarities of this form of cancer is the slowness with which it progresses. If the general health of the patient be unimpaired, and the local affection shielded from irritation, six or seven years may elapse before ulceration supervenes. Its progress after the commencement of ulceration may be equally slow; ten, fifteen, or even twenty years may elapse, without much advance having been made; in other instances, however, and in especial, when by any means the general health of the patient is depressed, or the sore is injudiciously treated by irritating applications, the disease may advance with the most destructive rapidity. Another striking peculiarity is the tendency to partial reparation in one part of the sore, while ulceration is in active progress in others; smooth, shining cicatrices of a pale-bluish color are formed, but are seldom of long duration; they are again involved in ulceration, while the same process is repeated in another part of the sore. Pain is not a prominent symptom of epithelial cancer; in some cases, even where the disease has committed the most extensive ravages, it may be almost entirely absent. At other times acute pain is felt, but this seems to be owing rather to incidental complications, such as the exposure of the nerves by ulceration, &c., than to be an essential feature of the disease. Ultimately, the cancerous cachexia is induced, and the patient dies, most frequently from the exhausting irritation of the disease.

In those in whom the constitutional conditions necessary for

the development of cancer are present, the spot at which the epithelial growth makes its appearance, is frequently determined by local irritation; in the neighborhood of the eye, for instance, it may be induced by the repeated friction of optical instruments, as has been witnessed more than once by Mr. Simon.

From the above description it will be seen that the distinction between scirrhus and epithelial cancer is to be drawn rather from their history than from their appearance. In the early stage, when alone the diagnosis is of any practical importance, it will be found that in scirrhus, the skin is movable over the indurated mass, whereas the epithelial growth appears to be deposited in its texture. The tubercles of scirrhus are less prominent, more speedily become adherent to the subjacent textures, are of a more decided color, and are more frequently attended with pain, than those which usher in epithelial cancer. The progress of the former, too, is in general rapid; the constitutional cachexia is more speedily and decidedly developed, and the lymphatic glands are in general implicated; a complication which is rarely seen in epithelial cancer. Such are some of the distinguishing features by which it is stated that the two forms of the disease may be recognised in their early stages; in many cases they are so slightly marked as to be scarcely perceptible, and the diagnosis becomes exceedingly difficult; it should, however, be always attempted, and every effort should be made to add to the number of diagnostic marks upon which dependence can be placed, as experience has shown that a correct appreciation of the nature of the disease may materially influence our prognosis.

Malignant ulceration of the lids may be confounded with lupus, or with ulceration of a syphilitic character. Lupus may be distinguished by the large size, soft texture, scaly surface, and red color of its tubercles, and by the sharp margin of its ulceration, as contrasted with the knotted and irregular edge of the cancerous sore. According to Mr. Lawrence, lupus does not attack the eyelids: in this respect he is at variance with Mr.

Dalrymple, who gives a drawing of a case which he believes to be lupus, attacking the eyelids and inner canthus. Syphilitic ulceration may be recognised by its history, by the diffuse swelling and inflammation by which it is accompanied, by its rapid progress, and by the effect of treatment.

LACHRYMAL GLAND.

Were we to place implicit confidence in the statements generally repeated in books, we should arrive at the conclusion that scirrhus of the lachrymal gland was a disease of by no means unfrequent occurrence. I have already (p. 337) expressed my dissent from this opinion, and my belief that the term "scirrhus" has been indiscriminately applied to affections of this organ, which possess no single character of malignancy. Everything in the history of these growths appears to me to prove the accuracy of this opinion. The large size to which they attain; the absence of ulceration; of adhesion to or implication of the surrounding parts; of disease of the neighboring lymphatics, and of constitutional cachexia; and, finally, the invariable success which attends their extirpation; are characters which are unknown in connexion with scirrhus in any other situation, but which are universally recognised as features in the chronic inflammatory induration and hypertrophy of other glandular organs. I by no means intend to assert that the disease never occurs, or that there is anything in the structure of the lachrymal gland which should exempt it from liability to scirrhous infiltration; we have the authority of Dr. Mackenzie, Mr. Dalrymple, and other competent observers for believing in its existence; and their descriptions lead us to suppose that the stage of induration is, as in other situations, succeeded by softening and ulceration which involve the surrounding textures. This, however, is certain, that it is an affection of very rare occurrence; Mr. Lawrence doubts the correctness of the opinion that the enlargement and induration of the gland, which are occasionally observed, are due to scirrhus, "never having seen any

evidences of malignity in such cases," and I have failed in discovering a detailed account of any case at all resembling the general descriptions of the disease which are given by some authors.

The symptoms are represented as being the same as those which indicate enlargement of the gland of a non-malignant nature, but the pain is said to be much more severe, and of a lancinating character. I am not aware of any means by which its cancerous nature could be ascertained, previous to the occurrence of softening and ulceration.

QUESTION AS TO THE PROPRIETY OF OPERATING.

There is, probably, not any subject in the whole range of surgery, upon which more discordant opinions have been expressed than upon the question as to the propriety of extirpating malignant growths. This is attributable to various causes, one of the chief of which I believe to be, the careless and indiscriminate way in which the term cancer is applied. In a Lecture, published in the "Medical Gazette" for February 1844, Sir Benjamin Brodie relates, that having been requested by a surgeon to examine a scirrhus mamma which he was about to amputate, he found the so-called scirrhus to be a chronic abscess; the same surgeon informed him that he had excised ten cancers with success. For the credit of the profession, I should be disposed to consider this as an extreme case; but there can be no question that fibrous and other non-malignant growths are constantly confounded with cancerous affections, and, next to the mamma, this mistake probably occurs more frequently in the eye than in any other organ, from the exact similarity which exists between scrofulous and encephaloid diseases of the globe in their early stages. Although the researches of modern pathologists have made us acquainted with many distinguishing marks by which the recognition of malignant growths may be facilitated, yet in numerous instances the diagnosis is still extremely difficult; and the most careful and well-informed observers are liable to be mistaken,

until they have an opportunity of examining the disease after its removal from the body. Another, and very common source of fallacy in examining this important question, is the prevalent custom of reporting cases as cured within a very short period after the operation. Were recovery from the immediate consequences of the operation to be considered as a true test of success, we might look upon cancer as equally amenable to surgical treatment with almost any other form of disease: to do so, however, would be to overlook one of its most distinctive and deadly characteristics, its liability to return as well in its original seat, as in the form of secondary deposits in the internal organs. If instead of losing sight of patients as soon as the wound is healed, their future history could be carefully traced, it would be found, I believe, in the great majority of instances, that a recurrence of the disease had proved fatal within two years. Such a result cannot be termed a cure; I shall inquire presently whether it can be regarded as a prolongation of life.

All that we have hitherto ascertained as to the origin and nature of cancer, leads us to the conclusion that it is a constitutional, not a local disease; that the tumor or sore is merely the evidence of the poison that is at work within; the outlet, so to speak, at which the *materies morbi* endeavors to escape from the system. If this be true, it is evident that any attempt to arrest the disease by the removal of its local manifestation, can be attended only with disappointment; and that the illustration adduced by Mr. Simon, that we might as well attempt the cure of gout by the amputation of the offending toe, is, in many respects, strictly applicable. I do not mean to assert that cancer, when left to run its course, is inevitably fatal; or that an operation for its removal is invariably followed by its recurrence: cases occur, from time to time, in which it disappears spontaneously from the system, by processes which it is not necessary here to describe; and several well-authenticated instances are on record, in which the extirpation of malignant growths, even under the most discouraging circumstances, have been followed by complete and permanent recovery. Such exceptional

cases, however, are so rare, and the conditions under which they occur are so little understood, that it would not be safe to make them the basis of any practical conclusion. It is but fair, however, to mention, that one of our most eminent authorities, Dr. Bennett, has drawn a different inference from the same facts. At page 242 of his work on "Cancer and Cancroid Growths," he remarks:—"It seems to me that a cancerous may supervene upon a cancroid growth, and that both for a time may be local;" a statement which I am at a loss to reconcile with his observations upon the origin of cancer, in which he endeavors to trace it still farther than has been done by other pathologists, to disorder of the primary and secondary digestions; and at page 245, he proceeds to say:—"So long as a cancer remains fixed in a part which is capable of being removed, and the strength of the patient is not too much reduced, so long is the surgeon warranted in operating." To this proposition I can by no means agree; and therefore, while I concur with him in thinking that these exceptional cases of recovery should prompt us to increased diligence in investigating the conditions under which they occur, I am of opinion, that in the present state of our knowledge, the unfavorable views expressed by Dr. Walshe, as to the results of surgical interference, are more in consonance with sound pathological reasoning. Dr. Walshe's conclusions are founded partly upon physiological grounds, and partly upon an extensive statistical survey, from which every source of fallacy has been carefully excluded. My space will not permit me to do more than to state the results at which he arrives; for details, I must refer to his admirable monograph upon Cancer, a work which contains more valuable information upon the subject than any other with which I am acquainted. At page 236, he thus sums up his argument as to the operation as a means of cure:—"First, inasmuch as the number of permanent recoveries is infinitely small, and as no combination of circumstances, however favorable, protects the patient from relapse, the operation cannot, in any individual case, be recommended as likely to cure the disease. Secondly, inasmuch as no operation by excision

is performed without the chance of some of the diseased structure being left behind, an accident which hastens the progress of the malady;—inasmuch as absolute certainty of the freedom of internal organs from the disease is unattainable;—inasmuch as the dormant cancerous diathesis is sometimes roused into activity by the removal of a tumor;—inasmuch as cancers in a state of active growth acquire increased energy of vegetation, if reproduced after extirpation;—and lastly, inasmuch as the operation itself has not very unfrequently proved both the occasion and the cause of death; excision cannot be undertaken without imminent risk of placing the patient in a worse condition than he or she was previously to the use of the knife.”

Dr. Walshe next examines into the truth of two opinions, which are almost universally prevalent among the profession; namely, that the best chance of success is afforded by operating at an early stage of the disease; and again, that though not curative, the operation may be undertaken as a means of prolonging life. Upon both those questions, he arrives at the most unexpected conclusions; upon the first he asserts, “Of a given number of cancerous individuals, a considerably larger proportion will be saved from untimely death under the influence of well devised and judiciously sustained treatment, aided, if this become necessary, by extirpation, performed at a comparatively late period, than will recover under the influence of the operation (unprecedented by methodized treatment), effected at the very earliest stage of local development:” and, upon the second, his researches lead him to infer that “the use of the knife decreases by more than half the chances of surviving the sixth year of a cancerous affection.”

Mr. Paget, in his admirable Lectures upon Cancer, delivered at the Royal College of Surgeons, has added the weight of his testimony to the conclusions of Dr. Walshe; as these Lectures are not yet published, I cannot refer to them more particularly; I may, however, remark that his opinions are founded upon extensive and independent research, and appear to be amply established by the evidence which he has adduced.

The above observations are intended to apply to the operation as undertaken with a view to the *cure* of cancer, and especially of the two varieties, encephaloid and scirrhus. In certain cases of melanosis and epithelial cancer, I believe that an operation may be performed with a very fair prospect of permanent success; and even in encephaloid and scirrhus, circumstances may occur which will render their removal not only permissible, but even necessary. I shall be better able to state my views upon this subject, by passing under brief review the different forms of malignant disease of the eye, with which we have to contend.

ENCEPHALOID.

In the encephaloid disease of the eyeball which occurs in children, I can scarcely conceive any combination of circumstances that would warrant us in extirpating the organ. In support of this opinion it is needless to cite authorities; every author of experience coincides in denouncing surgical interference in terms more or less strong; even the older writers, who may fairly be supposed to have frequently removed eyes affected merely with scrofulous disease, found the general results of the operation so unfavorable, as to have almost abandoned it. I should scarcely consider it necessary to do more than allude to this subject, did we not from time to time see cases recorded in the journals, in which, in defiance of the lessons of ample experience, this operation has been repeated. The invariable result of such attempts has been recurrence of the disease, as well locally, as in the form of secondary tumors of the brain or other vital organs; and there is every reason to believe that in the great majority of instances the fatal event has occurred sooner than if the disease had been left to run its course. I am not aware that there is a single unequivocal case of success on record; while numerous instances that might be quoted in which death has taken place within a few months or even weeks after the operation. The impossibility of forming a correct diagnosis of the nature of the deposit during the early stage of the disease,

appears to be of itself sufficient ground against interference; "but so far," says Mr. Dalrymple, "from that circumstance being to the disadvantage of the patient, I am inclined to rejoice that it offers another bar to the performance of the operation of extirpation of the eyeball." He further shows that even at the earliest stage of the ocular disease, and while to external appearance the eye may be in a favorable state for operation, there may be extensive latent disease of the brain; and illustrates his remarks by drawings from preparations taken from children dying of extensive fungoid tumors within the cranium, while as yet the ocular deposit was confined to the back of the eye, and the globe had undergone no alteration in form or size.* In short, every fact, practical as well as pathological, with which we are acquainted, tends to show that, in the words of Mr. Syme, "it would be better both for the interest of humanity and the credit of surgery, if the operation were entirely abandoned." Mr. Liston, in speaking of excision of the cancerous mamma, while the neighboring glands are involved in the disease, expresses himself as follows:—"The practitioner who would advise interference with the original tumor, must be grossly ignorant, atrociously unprincipled, or of unsound mind." I consider, that this language, though strongly expressed, would be equally applicable to the

* A case of this kind came under our care a few years ago, and may not be unworthy of brief record in this place. The left eye of the patient, a fine healthy looking boy, was occupied by a trilobate deposit of a bright yellow color, the convexities of which, traversed by one or two reddish streaks or stains, approached each other so as to leave a small triangular channel extending along the axis of vision to the bottom of the globe. The nature of the disease was at once recognised, and an unfavorable prognosis given. Iodine was prescribed internally, occasional attacks of inflammation abated by leeches and mild aperients, and such hygienic measures employed as seemed best adapted to improve and sustain the general health. Under this treatment the morbid growth lost its rounded form, was reduced apparently to a thin expansion lining the interior of the eye, and in some parts disappeared altogether. During this arrest of development, however, the organ assumed an unhealthy aspect externally, vision in the other eye was gradually lost, and the patient dying after the lapse of a year, a medullary tumor as large as a walnut was found lying on the chiasm of the optic nerves.—ED.

surgeon, who, in the present state of our knowledge, would indiscriminately sanction or perform extirpation of the eyeball for the encephaloid cancer of childhood.

The same observations apply to the rarer instances in which the disease appears in the adult; for though it may not always be so rapid in its progress, it has hitherto been found to be equally fatal in its results, and beyond the control of operative surgery. In either case, careful and well-regulated treatment has frequently been found to effect much towards the alleviation of the more distressing symptoms, and the prolongation of life; and instances have occurred to Mr. Dalrymple, in which it has even appeared to induce a pause in the progress of the malady; on the other hand, it cannot be too carefully kept in mind, that irritating applications by which the afflux of blood to the part is increased, as well as every debilitating cause which tends to impair the general health of the patient, adds renewed energy to the vegetative force of the morbid mass, and accelerates death.

SCIRRHUS.

With regard to scirrhus of the eyeball, our experience is as yet too limited to warrant us in forming any opinion as to the propriety of extirpation, except from our observation of its results when applied to other organs similarly affected. I have already stated that these results have hitherto proved highly unfavorable.

MELANOSIS.

Whatever be the true nature of melanosis, whether, when it occurs in the eye, it invariably presents the characters of encephaloid, as is supposed by some, or whether it be occasionally associated with tumors of a non-malignant character, it is the opinion of some of the most experienced surgeons that it differs materially from uncomplicated cancer, in the result of operations for its removal. Mr. Dalrymple says, "there seems, if one may use the term, less malignancy in it, and its extirpation by operation

is unquestionably less liable to be followed by reappearance of the disease, than that of either medullary sarcoma or carcinoma." In support of this view, he details a case, to which I have already referred, in which the removal of a melanotic tumor from the exterior of the eyeball of an elderly lady, was followed by what may be considered a permanent cure, as there had been no return of the disease seven years after the operation. In the "Medical Gazette" for October, 1845, and again for July, 1847, Mr. Lawrence reports several cases in which the operation was followed by various results. One of these cases I had an opportunity of witnessing during my residence in St. Bartholomew's Hospital. It occurred in the young woman, twenty-three years of age, already alluded to, who was admitted into the hospital on account of some trifling venereal affection, during recovery from which she called attention to the state of her eye, which was the seat of great pain. There was considerable conjunctival and sclerotic injection; the pupil was dilated and motionless, and the lens, dull and dingy in appearance, was, with the iris, thrust forward in contact with the cornea; there were also three dark staphylo-matous projections of the sclerotica, close to the margin of the cornea. The eye was extirpated in 1841. Towards the end of 1844, having previously enjoyed good health, she began to complain of pain and swelling of the abdomen; her symptoms rapidly increased in severity, and the case terminated fatally nearly four years after the extirpation. On post-mortem examination, melanotic tumors were found in nearly every organ of the body. In this instance, judging from what we know of the usual progress of the disease, I think we are warranted in asserting that life was prolonged and much suffering averted, by the performance of the operation.

Another case, reported in the same paper, is worthy of notice, and not the less on account of the eccentric means adopted by a surgeon who was consulted, in order to stop the progress of the tumor. The patient was a robust man, forty-four years of age, who had lost one of his eyes, twelve years previously, from inflammation. When he applied to Mr. Lawrence, the mela-

notic growth was of eight months' duration; it had sprung from the shrunken eyeball, and had rapidly increased in size, so as to fill the orbit and partly project from it. To check this growth, the surgeon sewed the lids firmly together, by strong sutures, which, in spite of the distension occasioned by the increasing bulk of the mass, still performed their office when the patient presented himself to Mr. Lawrence. The disease was removed at the man's urgent request, with the effect of affording immediate relief; and there had been no return of it a considerable time after the operation. The conclusion at which Mr. Lawrence arrives, as well from his own experience as from that of others, is, that though it is probable that melanosis will always be found to terminate fatally, sooner or later, yet that life may be prolonged by the early performance of an operation; and that surgical interference should be limited to those cases in which protrusion and ulceration of the melanotic growth has not yet taken place.

Dr. Argyll Robinson, in an interesting paper in the "Northern Journal of Medicine," for November, 1844, relates six cases in which he had extirpated the eyeball on account of melanotic growths, and the results of which lead him to form a very favorable opinion of the operation. One of his patients, a man fifty-two years of age, was in good health two years afterwards, and a small melanotic deposit above the cornea of the other eye, had existed for nine years unchanged.

Less favorable views are entertained by some other surgeons, whose operations have been succeeded by a rapid development of the disease in various parts of the body, and, consequently, speedy death. The question is as yet far from being decided. Much more satisfactory evidence and accurate statistical research is necessary, before any trustworthy conclusion can be arrived at, either for or against the propriety of operating; but I think, that as the matter at present stands, we are warranted in hoping that an early operation will be followed by prolonged life, and relief from suffering. When protrusion and ulceration of the tumor have taken place, and, still more, when there is any

reason to suspect that the internal organs are affected, surgical interference will almost certainly precipitate the fatal termination.

MALIGNANT TUMORS OF THE ORBIT.

When we have satisfied ourselves as to the malignant nature of a tumor of the orbit, experience shows, that as in the case of the disease in other situations, surgical interference is, as a general rule, injudicious. I have already mentioned two cases which have recently fallen under my own observation, in which the removal of epithelial tumors pressing upon the eye, was followed by unfavorable results; and we have abundant evidence that there is nothing in their position which exempts them from the laws by which our treatment of malignant disease in general should be regulated.*

Under certain circumstances, however, an operation may be not only permissible, but necessary. When, either from their original position, or from the direction of their growth, such tumors are in close contact with the roof of the orbit, they are liable, as they increase in size, to cause absorption of the bone, and death from pressure on the brain. In such cases, after having made the patient fully aware of the danger of his position, and having explained that our interference is not with the hope of effecting a permanent cure, but merely with the view of averting impending death, it will be proper to deviate from the general principle, and to excise the tumor, removing at the same time the whole of the contents of the orbit, should it be judged expedient to do so. In the "Dublin Hospital Gazette," for February, 1846, Dr. O'Ferrall relates a case in which he removed an encephaloid tumor from the orbit of a girl twelve

* In a case of encephaloid tumor of the orbit, occurring in a patient whom we admitted into Wills Hospital, and which ultimately attained an enormous magnitude, the morbid growth was found, on making the autopsy, to be so closely connected with the dura mater at the bottom of that cavity, as to have rendered its complete extirpation impracticable, had such operation been attempted.—ED.

years of age, with this object in view. The immediate result was satisfactory, but the child's subsequent history is unknown.

Should the lachrymal gland be affected with malignant disease, it must be treated, in all respects, according to the same rules as apply to tumors in the same situation, but originating in some other tissue.

MALIGNANT ULCERATION OF THE EYELIDS.

The same unfavorable results have been found to follow the excision of scirrhus growths and ulcerations from the eyelids, as from other parts of the body; in such cases, therefore, reliance should be placed rather upon judicious and well-sustained general treatment than upon operative interference.

In epithelial cancer, however, we have more encouragement to hope for success. "It is in this form of cancer," says Mr. Simon, "that the development of true cancer-growth appears to be at its minimum; it is in this form that the bulk of the morbid mass consists of elements seemingly not foreign to the normal structure of the part; it is in this form that cancer most nearly ceases to be what is called heteromorphous, and is least remote from the signification of a simple hypertrophy." On these grounds he advocates, under certain circumstances, the removal of epithelial ulcerations, even of considerable magnitude; and supports his views by the details of several cases in which such operations were followed by success. In remarking on these cases he observes, "I considered, from the pathological affinities of each case, that the constitutional tendency to cancer could not be of extreme strength, and that accordingly, if I removed the existing masses of disease, a long period, perhaps even the remaining years of life might elapse without the cachexia having sufficient intensity to reproduce them anew."

I believe that by acting upon the views thus expressed, by excluding cases of scirrhus, and by limiting our operations to those of epithelial cancer in which there is no suspicion of secondary deposit, and in which every particle of the diseased structure can

be removed, we would find that in many instances the operation was followed by a permanent cure, or at all events by prolonged life, and relief from present suffering. Too much care cannot be taken, however, in forming a correct diagnosis, a matter, in many cases of extreme difficulty; sores, even of a non-malignant nature, occasionally assume an appearance which it is impossible to discriminate by their naked-eye characteristics from genuine cancer; it is a wise precaution, therefore, never to operate without previously submitting our patient to treatment, which will in some instances clear up the real nature of the case, and will in all, increase the chances of a successful result.

It will frequently happen that the disease to be removed is of such an extent as to render it necessary to sacrifice the whole lid in order to effect its complete extirpation. In such cases the eye will almost inevitably be lost, from the irritation produced by exposure, and the contact of dust and other extraneous matters; it will, therefore, be well, in every instance in which it is practicable, to conclude the operation by the formation of a new lid, which must be taken from any of the healthy skin in the neighborhood, that may be available. This proceeding, the filling up of the wound by a piece of healthy skin, was at one time thought to exert a powerful influence in preventing the reproduction of the disease; more extended experience, however, has shown that this opinion is erroneous, and that plastic operations need not be resorted to, except with the view of obviating such a result as that to which I have alluded.

There is one rule which applies with equal force to every case in which the removal of cancer is attempted; a rule of such importance, that, at the risk of repetition, I must again endeavor to impress it on the minds of my readers; it is this, that every particle of the diseased structure must be thoroughly eradicated, and that the healthy parts in the neighborhood be freely included in the incisions. Every stroke of the knife through the diseased part opens up channels by which the cancerous germs are conveyed directly into the circulation, and the condition of the patient,

from whom the disease has been only in part extirpated, is thus rendered infinitely worse than if no operation had been attempted. When circumstances permit, the edges of the incised part should be carefully examined by the microscope; and that this is no useless precaution, we learn from a case related by Dr. Bennett, in which the apparently healthy structures thus examined, were found to be loaded with cancerous germs. Under such circumstances the knife should be resumed, and the operation should not be considered as complete till every trace of the disease has been eradicated.

In the above observations, I have made no mention of the use of escharotics, which are strongly advocated by some for the removal of superficial cancerous sores; and I have avoided speaking of them, because I believe that the instances are rare indeed in which the knife is not to be preferred, as at once more rapid and effectual, and much less painful. Escharotics undoubtedly sometimes effect the removal of the disease, but they frequently require to be several times repeated; their use is attended with intense pain, and in the event of their not succeeding, the irritation which they produce cannot fail to be followed by the most injurious effects.

In concluding this chapter, I shall briefly allude to those melancholy cases in which excessive and incessant pain induces the sufferer to implore the removal of his disease, at any hazard. For such cases it is impossible to lay down any general rule; each must be investigated on its own merits, and the surgeon must form his own judgment on the expedience of operating. For my own part, if after having had all the circumstances fully explained, the patient should still persist in his request, I should feel disposed to comply with his wish. Certain rare instances are recorded in which an operation, performed under apparently the most desperate circumstances, has been followed by complete and permanent recovery; nor should we forget that severe and protracted agony, besides incapacitating the sufferer from de-

voting his attention to those subjects which his situation so urgently demands, may of itself, from the exhausting nature of its influence, prove the immediate cause of death. In such cases we might be justified in performing an operation, which, under other circumstances, would be altogether inadmissible; the result of even partial removal of the disease would be, not only great relief from present suffering, but, in all probability, prolongation of life.*

* The chapter on Malignant Affections of the Eye, deserves especial commendation for the sound principles of pathology which it contains. A few years ago operations for the removal of reputed growths of this nature, were not uncommon in this country; and when we consider the comparative infrequency of true cancer, and the constitutional origin of the disease, it is evident, not only that many eyes were needlessly sacrificed to a mistaken diagnosis, but that much mischief was caused by unwarrantable interference where there was no error in this respect. Modern surgery, with better means of discrimination, and the deductions from a more enlarged experience, inculcates authoritatively a more rational and conservative treatment; but the same lesson, less confidently propounded, might have been gathered also from the works of some of the older writers;—the consentient testimony of the more judicious among them witnessing to the truth of the proposition enunciated by Dr. Walshe, that a cancerous tumor is merely the local evidence of a general depravation of the system. Regarding the question as thus definitively settled by the judgment of the profession, we have from the beginning of our practice, discouraged the use of the knife in all cases of unequivocal character, and have had abundant reason to be satisfied with the propriety of our conduct; for in every instance which has fallen under our observation where opportunity was afforded of examining the condition of the parts after death, there has been found such implication of important organs as plainly showed that an operation must of necessity have precipitated the fatal event.—ED.

CHAPTER XX.

ARTIFICIAL PUPIL.

CONDITIONS UNDER WHICH AN OPERATION MAY BE UNDERTAKEN, AND THOSE WHICH CONTRA-INDICATE IT. RELATIVE ADVANTAGES OF THE SEVERAL POSITIONS IN THE IRIS FOR A PUPIL. SIZE OF THE PUPIL. SHAPE OF THE PUPIL. CLASSIFICATION OF THE PRINCIPAL MORBID STATES OF THE EYE REQUIRING A PUPIL, WITH THE MOST APPROPRIATE OPERATIONS. CONCLUDING GENERAL REMARKS.

By artificial pupil is meant a passage opened for the admission of rays of light to the retina, when disease or accident has rendered the natural pupil inefficient.

When there is complete closure of the pupil by lymph, by the adhesion of its margin to an opaque capsule, or by prolapse of the iris; or when it is eclipsed by an opacity of the cornea, too extensive to admit of relief by artificial dilatation of the pupil, there cannot be any doubt, abstractly, of the propriety of operating. When, however, there is but partial interruption of vision from any of these causes, it must frequently be a very nice practical question whether an operation should be undertaken, and the answer must be based on the degree of sight that exists, and the probability of being able to increase it by the means at our disposal.

The admissibility of making an artificial pupil when one eye is sound, or at least affords sufficient sight for the ordinary purposes of life, has been much discussed, and different conclusions have been arrived at. My own opinion is against operating, as a rule, so long as one eye is efficient, for in all probability the vision that may be restored to the faulty eye will not be equal to that of the other, which will continue to be used alone. A more forcible objection however is, that as a new pupil cannot be made to correspond with the natural one, there will most probably be confusion of sight, double vision, or squint; and the same objection applies to making two artificial pupils, as I shall presently

illustrate by an example. Why a dissimilarity in the pupils should not always be followed by disturbance of vision, I am not able to say; I only know the fact, that under apparently the same circumstances, when the pupils disagree, sometimes there will be this derangement, sometimes not any.

The only exception that I know of to the above rule is, when the pupil is merely a little deranged by a small part of its edge being adherent to the cornea in consequence of a wound, or a penetrating ulcer, and when the adhesion may be readily detached. In such cases the pupil may be advantageously re-established; I am informed by Mr. Browne of Belfast, that in four instances of defective pupil from the latter cause, one eye being quite sound, he operated with the effect of very nearly restoring the pupils to their natural state, and considerably adding to his patients' powers of vision. Desmarres states that the parallelism of the optic axes of the sound eye and the one with an artificial pupil may be preserved, by forming the pupil at the inner side of the eye, provided that the natural pupil is rendered useless by opacity of the cornea, or only partially destroyed by adhesion of the iris to the cornea or to the capsule of the lens, and that the internal portion of the cornea remains transparent. I shall point out as I proceed, the great imperfection of a pupil made at the margin of the cornea.

The morbid states of an eyeball that forbid an operation, are generally very palpable, and are declared in altered states of the cornea, the iris, and the retina.

When the true tissue of the cornea has been lost and its place supplied by a cicatrix, an operation is contra-indicated, although there may be a part of the cicatrix nearly transparent, for the iris is necessarily incorporated with the new material. An operation is also contra-indicated when the iris is adherent to the corneal tissue, as an aperture could not be made in the portion so adhering, for it is an indispensable condition that these parts be distinct; however closely they may lie, an operation is not impossible, although actual apposition renders it very difficult. It is not therefore essential, as I shall show that an anterior chamber should exist.

An iris that has lost its characteristic fibrous appearance and lustre, and bulges forwards, affords but a doubtful prospect of success, from the tendency there is for the breach that is made in it to close by adhesive inflammation, and, moreover, the eye in general is almost certainly so disorganized, as to render the success of an operation questionable; still no structural change in the iris, taken alone, imperatively forbids a trial.

To determine whether the retina has entirely lost its function, is certainly not difficult. Perhaps it is just possible for a moderate light to be intercepted by closure of the pupil, combined with capsulo-lenticular cataract; but rays of bright light would, I think, always reach it. I do not think that the sclerotica and the choroid are impenetrable to light. When, however, the retina is feeble, and it frequently is in the class of cases under consideration, the propriety of operating cannot always be readily decided; but the rule of affording every chance for restoring some vision, and recovering a person from total blindness, assists us out of the difficulty, justifying an attempt under the most discouraging conditions.

The several morbid states of the ocular appendages mentioned at page 401, as being more or less obnoxious to the operations for cataract, apply also here, although less forcibly, and should be, as far as possible, removed or reduced, prior to operating.

There are certain conditions, local and general, that are essential to insure the success of an operation.

The local condition is freedom of the eyeball from active or chronic inflammation. A long interval should be allowed to elapse after the cessation of the disease which has occasioned the loss of the pupil; when inflammation of the entire globe has been the cause, the disappearance of increased vascularity about the eye proves the cessation of the more active state, and the absence of the subjective symptoms of flashes, corruscations; and intolerance of light, and the decrease in the size, the number, or the blackness of *muscæ*, are the criteria of the more chronic condition having subsided.

In certain traumatic cases, closure of the pupil is the only trace of the mischief which the eye has sustained; but when the

closure results from inflammatory causes, especially of long duration, the globe rarely becomes freed from an unnatural vascularity, which, in most cases, must be regarded as an irrecoverable state of the blood-vessels, rather than as evidence of the persistence of the morbid condition. If the original disease has long passed away, and a fair trial has been given to means calculated to subdue inflammation; if the health is good, and the eye is free from irritability, and if there is much encouragement from the soundness of the retina, I consider such varicose condition of no importance, and do not hesitate to operate.

The general condition includes the absence of any virus or taint that may have induced the ophthalmic affection. When syphilis, gout, rheumatism, or struma, yet contaminate the system, it is dangerous to operate, owing to the great probability of re-establishing severe local disease; and it seems to be generally admitted, that when loss of the pupil in childhood has arisen from any scrofulous affection, an operation should not be performed under puberty.

An eye that has seemed to be in an almost hopeless condition directly after the subsidence of the disease that has rendered its pupil useless, may on the restoration of the general health improve considerably, and be brought into a proper state for a successful operation. Thus it is, that an iris which may have been for months in a morbid state, apparently permanent, will lose much of its dulness, and even recover some of its color, and a cornea that has been densely opaque, will clear to an extent incredible to those unaccustomed to observe eye-diseases; indeed so great may be its restoration that an operation for an artificial pupil should never be attempted on account of such opacity, until every suitable means have been tried for its removal, and a considerable time allowed for their operation, as well as for that of the restorative power of nature. The importunity of patients to be relieved from blindness, and the anxiety of surgeons lest they should appear to be negligent, are not unfrequent causes of premature, consequently of unsuccessful operations; and much judgment is at times required, not to allow oneself to be misled.

That a central position for an artificial pupil is superior to a lateral one, is most obvious, and is indicated by the natural arrangement of the eye, and the configuration of the cornea, the lens, the vitreous body, and even the retina, the most sensitive part of which is opposite the pupil. This has no doubt been recognised ever since the general introduction of the operation for artificial pupil; though, perhaps, it has not always been acted upon. The imperfections of a lateral aperture, arising from the interception of the light by the intervention of the ciliary processes, have been long pointed out, especially by Scarpa; the indistinctness of the image formed by the circumference of the lens, and the disadvantage of its falling on a part of the retina not the most sensitive, are facts which the elements of physiology teach us, and the details of practice confirm. As a natural effort to obviate these defects, when the pupil is external, the eye generally squints inwards. It has often been a matter of surprise to me, how slightly vision has been interfered with by central opacities of the cornea, so long as the pupil was natural, and its margin extended a little beyond the opaque part; and also, where there has been general, although slight loss of corneal transparency, with a perfect state of pupil. As a rule, therefore, I have ever preferred forming a pupil centrally, even though it should be by the side of a dense opacity of the cornea, or be somewhat shaded, to choosing the circumference of the iris, though there the cornea may be transparent.

There is much diversity of opinion regarding the most advantageous spot to be selected when a pupil cannot be made centrally, though all parts of its circumference may be available. This discrepancy arises from the real difficulty that invests the subject, inasmuch as we are almost without the assistance of practical deductions; for it is seldom that the results of lateral pupils can be compared with each other, owing to the very different states of the eye, and the variation in the sizes and in the shapes of the pupils in different individuals. I will state the opinions of some of our most distinguished ophthalmic surgeons on the matter; and, first, that of Mr. Guthrie:—

“When an artificial pupil cannot be made in the centre of the iris (from whatever cause), the other parts of it are eligible in the following order: 1st, the inferior part of the iris inclining inwards; 2d, the internal, a little below the transverse diameter of the eye; 3d, the inferior and external; the upper part being the least eligible, from the eyelid covering that portion of the cornea in the natural state of the eye. The lower and inferior parts of the iris are to be preferred, for the following reasons: because the line of vision being through that part, the eye is less removed from its natural axis, and consequently less squinting is occasioned than when vision is acquired in any other direction; and, if both eyes are operated upon, the axes of vision are made more nearly parallel. A decided preference of a position, not higher than the centre of the iris, is founded upon the natural position of by far the greater number of objects of vision, which it is essential for a person to see, being viewed forwards or downwards.”

Mr. Lawrence writes, “When a lateral opening is to be made, in consequence of the circumference of the cornea only remaining transparent, the nasal side of the iris should be chosen on the level of the natural pupil; then comes the temporal side. The normal place of the opening is nearer to the nasal than to the temporal edge of the cornea; the axis of vision, therefore, with a pupil in the former situation, coincides more nearly with that of the perfect eye, than when it occupies the latter place. The next best situation is the lower and outer part of the iris, after which comes the lower; but the optic axis then deviates widely from its natural direction. The least favorable position is above; for a pupil is not of much use here, as the upper eyelid interferes with it, so that the eye must be turned downwards, and even then sight is imperfect.”

Dr. Mackenzie prefers the nasal edge of the cornea, and gives as one of his reasons, the deformity which is caused by a pupil at the temporal edge; a consideration that I think ought scarcely to have any weight in the question. He thinks, besides, that when the pupil is behind the temporal edge of the

cornea, a person finds it difficult to turn the eye, so as to bring the pupil into the necessary direction to embrace the usual range of objects.

Mr. Tyrrell directs, that when the position and extent of opacity of the cornea does not forbid, the pupil should always be brought downwards and outwards, and when that cannot be effected, it should be directed downwards, and never, unless compelled by circumstances, should it be drawn upwards. He does not make any mention of an internal position.

M. Desmarres, the most recent French writer on Ophthalmic Surgery, advises a choice in the following order; first the internal side, then the lower, next the external inferior.

My own opinion is in favor of a pupil at the inferior margin of the iris, as I think that position possesses the greatest advantages, and it is that which I should adopt whenever the prominence of the eye allowed of its easy execution; but where retraction of the globe, or a prominent cheek, at all interfered with the ready use of instruments, I would make it downwards and outwards.

When circumstances oblige us to place the pupil laterally, we should endeavor, if opacity of the cornea do not interfere, to make it ample enough, without extending the aperture to the very margin of the iris, for the reasons above stated.

It is well to have some principle by which we may regulate the size of an artificial pupil, when the physical peculiarities of the case do not limit its dimensions. The multiplicity of the conditions to be taken into account, especially when the crystalline lens has been lost, renders it difficult to solve the problem on purely theoretical grounds, and experience must be our guide. When the aperture is to be central, we should endeavor to make it of a size corresponding to the pupil in a state between dilatation and contraction; in the middle of the iris, however, although all pupillary movements are necessarily lost, size seems of less importance than when the aperture is lateral, for then, except it be of a certain size, sufficient light will not enter, and if very large, too much will be admitted, and confusion of

vision must ensue. The following appropriate remarks of Mr. Bowman, are taken from the "Medical Times and Gazette" for 1852.

"For the finer purposes of vision, supposing the surgeon has the option of making a pupil near the axis of the eye, it is important that the opening be *not too large*. A small pupil near the axis of the crystalline will be much more efficacious than a larger one which extends so far from the axis as to admit a part of the rays through the edge of the lens; and this will be more the case, if, as usually happens, the base or wider part of the new pupil be outwards, towards the border of the lens, and its narrower part inwards, towards its axis. If the pupil be unavoidably narrower at one part, that part should be, if possible, towards the margin of the lens. If the central part of the cornea be only nebulous, and *so allow of some, though imperfect vision*, it will be of trifling avail to enlarge the pupil up to the margin where the cornea may be clearer. For the largeness of its size and its partial mal-position will counteract any benefit derivable from the arrival of the light through a clearer medium."

"A large orifice, if narrow and much elongated, and if it take the direction of a radius in front of the lens, allows of better sight than a circular pupil of the same area. In fact, I have found a long, narrow, elliptical slit, extending from the situation of the natural pupil to the very border of the lens, sufficient to permit almost perfect vision."

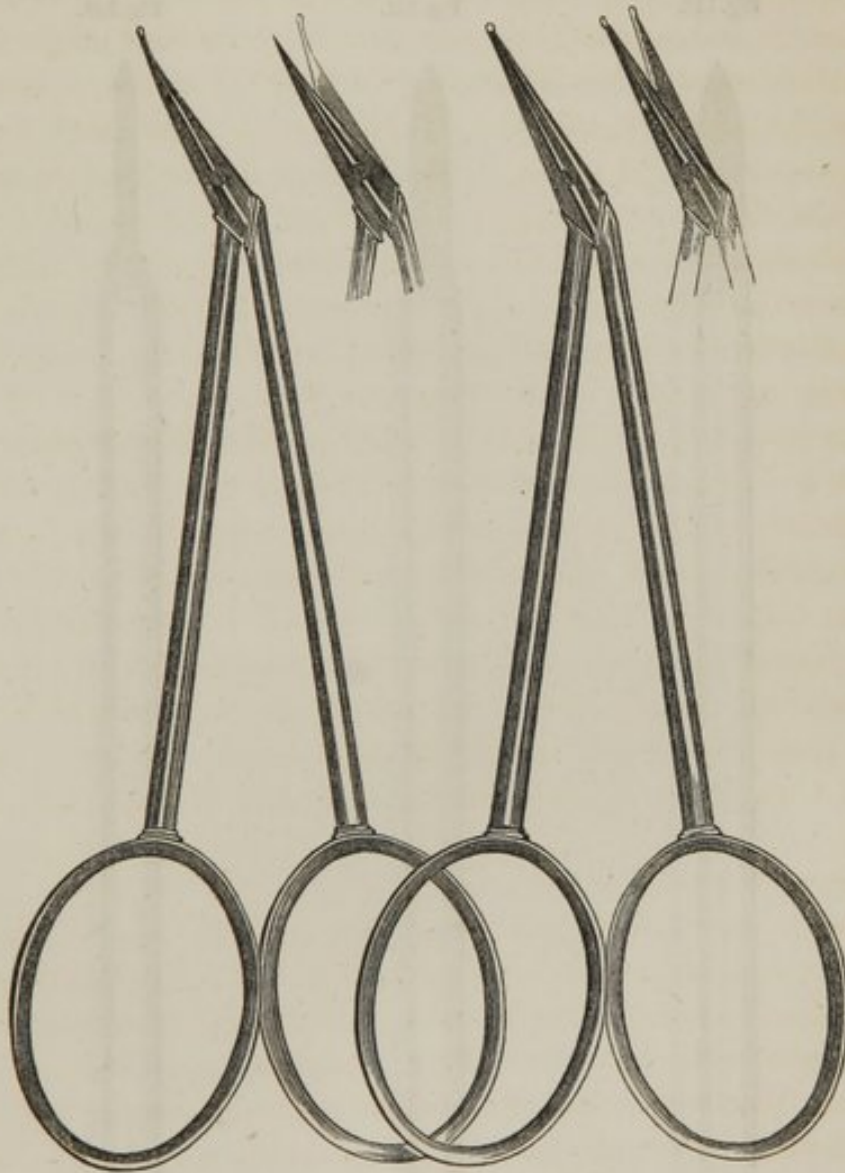
The form of the new pupil is scarcely under our control; practical surgeons well know the impossibility of insuring any predetermined shape even in the most favorable cases, and an operator should not be dissatisfied if he can effect an aperture of any figure at the spot he desires, provided it be ample; for the outline matters little. At the time of operating it is for the most part impossible to say what will be the form, or even the size of the future pupil; a small slit in a flaccid iris may, when the chambers of the eye are filled with the aqueous fluid, expand beyond expectation, and the excision of an apparently insufficient portion, may form an opening well shaped, and equal to that required.

IRIS SCISSORS.

In the scissors represented at Fig. 144, one blade is probe-pointed, and longer and broader than its fellow, which is sharp.

Fig. 144.

Fig. 145.



When the two are closed, the lesser blade is completely shielded by the greater, the instrument being then blunt, as is shown in the larger wood-cut. Great nicety of workmanship is required for the sharp limb to be fine enough to penetrate the iris readily, and to leave also a cutting edge to the very extremity.

The scissors, Fig. 145, are merely blunt pointed.

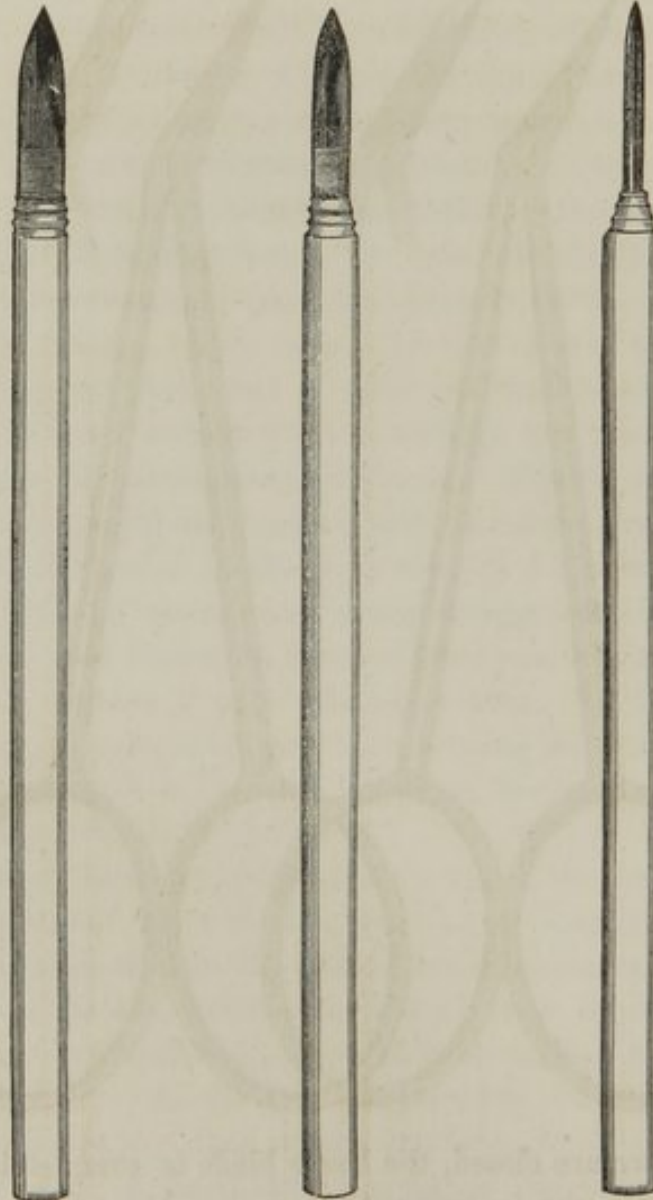
IRIS KNIVES.

These instruments should be sufficiently thin to penetrate the cornea and the iris readily. They need not be sharp beyond the

Fig. 146.

Fig. 147.

Fig. 148.



shoulder. The different sizes are necessary in order that the incision of the cornea may not in any instance exceed that which is required to be made in the iris.

IRIS HOOKS.

The first hook, Fig. 149, known as Tyrrell's, owes its efficiency to its long and narrow recess, within which the iris can be securely retained. As a precaution against the capsule of the

Fig. 149.



Fig. 150.



Fig. 151.



lens being injured, the point is blunt, smooth, and inclined a little inwards.

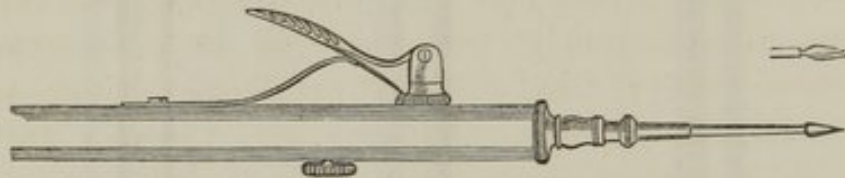That represented by Fig. 150, is like a lady's crochet needle,

but has a blunter and more prominent barb. I have found it useful on certain occasions when it has been necessary to disengage the instrument readily from the iris. Fig. 151 illustrates a hook that I have often employed in the necessarily varied manipulations required in the formation of an artificial pupil.

IRIS CANULA SCISSORS.

The mechanism of this beautiful instrument resembles, in all respects, that of the capsule forceps described at page 465, ex-

Fig. 152.



cept that the canula is here worked by a spring, and this is necessary because it is required to be moved backwards and forwards repeatedly.

The lesser figure representing the instrument partly open, shows the form of the blades, one of which is blunt. It is well to have several blades of different sizes, some with both extremities sharp, others, for particular occasions, with both dull.

The chief value of these scissors is that they can be used without previously incising the cornea, which allows the aqueous humor to escape; but unless the blades be thin enough, and so wrought, that they may penetrate readily, the instrument will not only be ineffectual, but is very likely to inflict severe injury on the cornea and the iris. So great is the difficulty of producing scissors thoroughly efficient in all their parts, that I know but of one house in London, that of Messrs. Weiss, which accomplishes it.

To Mr. Wilde, of Dublin, is due the credit of this valuable addition to our ophthalmic instrument case. His announcement of the invention is in the "Medical Times" for December 1850.

Perhaps the simplest, and at the same time the most practical and concise manner of treating the operative part of this subject, is to classify the principal states of the eye admitting of an artificial pupil, and to annex to each its generally appropriate operation.

1. Closure of the pupil from inflammation, or prolapse of the iris; the crystalline lens absent, the cornea clear, or if partially opaque, the opacity not interfering with the formation of a central aperture in the iris.

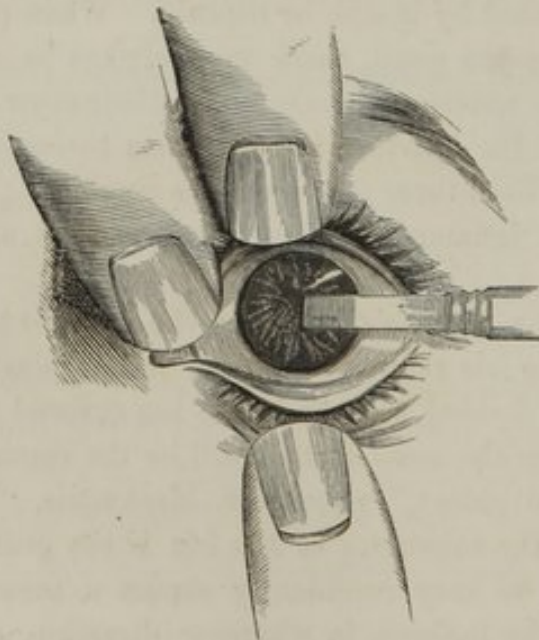
When inflammation has destroyed the pupil, the iris is not necessarily altered in its position; it does not bulge by the loss of communication between the chambers of the eye, provided its tonicity is preserved; and the size of the anterior chamber is not only undiminished, a matter of importance in operating, but may be actually increased by the falling back of the iris, in consequence of the loss of the lens. There may be but a mere trace of the remains of the pupil, or the aperture, very much contracted, may be closed by lymph or capsule. When prolapse of the iris has shut up the pupil, there must always be a reduction in the size of the anterior chamber, the diminution depending on the position of the aperture in the cornea through which the iris has escaped. Both these states may be combined; the pupil may be closed from inflammation, and the iris may afterwards prolapse.

The operation of "incision," with the knife, is the most appropriate when the iris retains enough of its physical properties to gape on being divided, and the less it has suffered from the effect of inflammation the more certain will be the result. "We need not hesitate to assert," writes Dr. Mackenzie, "that in every case in which the substance of the iris is not greatly altered by inflammation, we may confidently expect a successful issue to the operation by incision, in whatever direction, or in whatever part of the iris the incision is made, above or below, or in the line of the natural pupil, and whether it is a mere pin-hole or extends to two-thirds of the diameter of the iris."

Independently of the superiority of a central pupil, it must certainly be an advantage, as tending to produce a more perfectly formed aperture, to divide the iris in its centre, that the circumference or dilating portion may act equally on the divided part. Perhaps, too, there may be some practical advantage in cutting through those fibres in the centre of the iris, by the interlacing of which a sort of sphincter muscle is provided: besides, it is in these pupillary fibres, if I may so call them, that there is generally the greatest agglutination from inflammation.

I invariably operate through the cornea, after the following manner:—An assistant draws down the lower lid, resting his finger on the malar bone, so that the globe may not be pressed on; I raise the upper lid with my forefinger, and with the tip of it and that of the middle finger, steady the globe after the manner indicated by this diagram, which represents the operation on the left eye.

Fig. 153.



With the first or second sized iris knife, according to the circumstances of the case, I divide the cornea at the outer part,

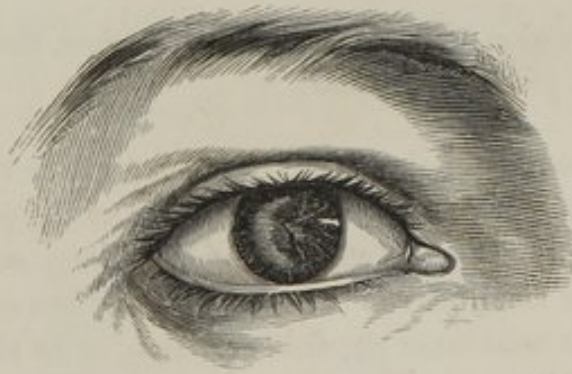carry the knife across the anterior chamber, and penetrate the centre of the iris, thrusting the blade up to the shoulder. In the above figure, the second knife is introduced, but, for most cases, the largest is required.

The aperture thus made, is about the third of the diameter of the iris, elliptical and vertical.

A great deal of stress is usually laid on the fitness of "incision" in cases where the iris is on the stretch from prolapsus. Without going into the question of the greater elasticity or contractility of the iris, under such circumstances, but giving it as my opinion, that this property is much overrated, I would suggest that the choice of the operation, so far as the state of the iris can be taken as a guide, should be made to depend on its actual structural condition; because any advantage that the mere stretching might afford, may be lost by slight structural change, and inflammation of the eyeball is often a cause of the prolapse.

The annexed sketch of a pupil closed by prolapse of the iris, is from a man seventy years of age, who applied to me after

Fig. 154:

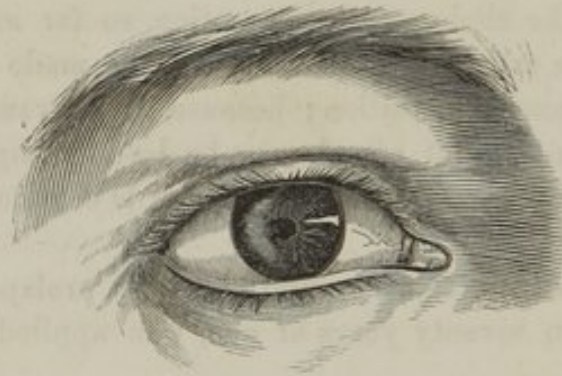


having undergone the operation for extraction. The broad white line on the outer side of the cornea indicates the cicatrix of the incision, to the entire extent of which the iris was adherent. The pupil, reduced to a minute aperture, was nearly useless. I suspect that a large portion of the iris, including a part of the pupillary margin, had been cut off in making the

section of the cornea. The other eye was quite lost in the attempt to extract. With the second-sized knife I divided the iris obliquely upwards and inwards, endeavoring to make the incision divaricate from the upper end of the narrow slit that existed; my object was accomplished, and good vision was obtained. Not the slightest untoward symptom ensued, and in a week he was able to leave the hospital.

This second sketch of the eye was taken several months afterwards, and exhibits the form of the new pupil. The artist has

Fig. 155.



shown the reduction in the opacity of the cornea, the consequence of the natural process of repair.

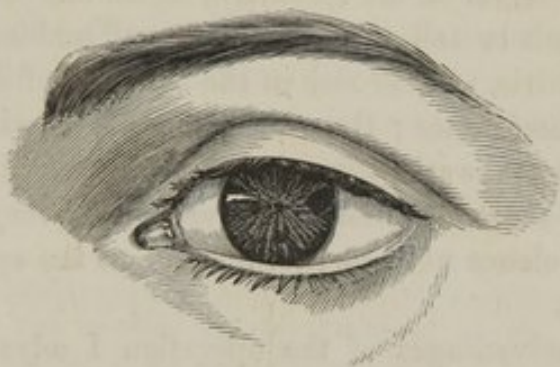Perhaps this may be the most appropriate place to describe the operations requisite in that inefficient state of the pupil which so frequently exists after the operation for drilling, and which may be due to the smallness of the aperture in the capsule, or the lymph that yet remains in the field of vision, or to the diminutiveness of the pupil, even although it may be quite clear.

J. Browne, twenty-one years old, an inmate of the St. Pancras Work-house, had been operated on, by drilling, at some institution in London. When he came to me, at the Ophthalmic Hospital, I found that the lenticular cataract had been absorbed, and that the capsule, though partly detached, yet blocked up the pupil, which was too much contracted to be of much use if cleared,

and I therefore determined to make an artificial pupil. The figure 156 represents the state of the eye.

The operation of "incision" with the knife was performed, and an ample pupil resulted. The capsule separated from the iris during the operation, but retained a part of its natural attachment, and moving backwards and forwards, occasionally produced much inconvenience by temporarily interrupting vision.

Fig. 156.



After the lapse of a few months I attempted to remove it; the cornea was opened with the second-sized iris knife, the blunt canula capsule forceps used, and the greater part was withdrawn. The portion that remained, being behind the iris at the inner side of the eye, did not interfere with vision, which was excellent. Fig. 157 shows the present state of the pupil.

Fig. 157.



It was by incision performed through the sclerotica that Che-

selden, the well-known originator of artificial pupil, used to operate; his method fell into disrepute and was almost abandoned, when Sir W. Adams revived it. From Adams's own account he was very successful, and he attributed this to making a more free incision in the iris than his predecessor, and using a long and very narrow scalpel, known as Adams's iris knife, which is still to be found among most sets of ophthalmic instruments. While this author, in his last book, "Adams on the Eye," speaks in the most laudatory terms of his operation, as he was wont to call it, he does not omit to tell of the difficulty of making a sufficient aperture in the iris, and the risk in the attempt, of detaching the iris at its circumference; the cause of both of which, namely, operating through the sclerotica, seems to have escaped his notice. Irrespective of these objections, however, is the very serious one of the great violence necessarily inflicted on the eye by operating posteriorly.

The great advantages of the operation I advocate are, its being executed through the cornea, the certainty of being able to make the pupil at the desired spot, and the division of the iris before the aqueous humor is lost, and therefore while it is tense, by an incision, which, owing to the form of the knife, is effected with such slight pressure that there is no risk of detachment from its natural connexions.

The arguments that I have advanced in my chapter on Cataract for the superiority of the anterior operation for "solution" over the posterior, as respects injuring fewer textures of the eye, apply here also, and with greater force, because of the larger wound inflicted; but, more than this, in the posterior operation, there is generally much bleeding within the eye, and the blood may proceed from many sources, whereas in the anterior, the iris is the only part from which it can issue, and very frequently it does not bleed when wounded. The only argument which might be raised against the anterior operation is, that an opacity of the cornea may ensue. All that need be said in answer on this head, and in the way of precaution is, that when the cornea is clear there can be no objection to it, when

partially opaque, and circumstances would oblige a transparent part of it to be incised, and that part is over the pupil, some of the several other modes of operating must be adopted, and I am sure that many may be chosen in preference to that of Cheselden.* To whom the anterior operation is due I cannot say, but it appears that Beer used to perform it.

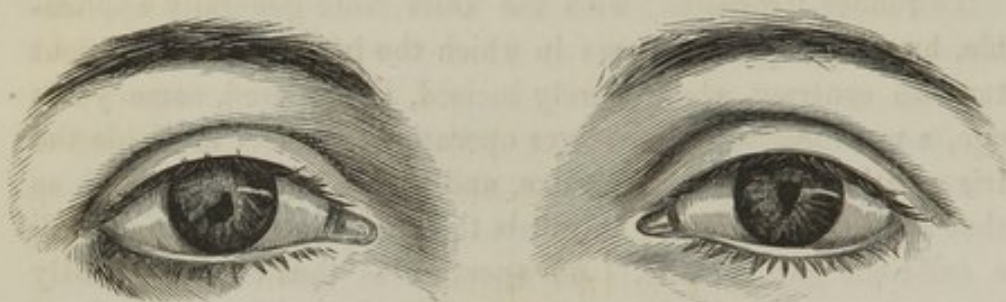To render "incision" with the knife more generally applicable, by adapting it to cases in which the iris has not sufficient tone to contract when merely incised, I proposed, some years ago, a modification of the above operation; namely to divide the iris a little internal to its centre, and with a blunt hook, such as that at Fig. 151, to draw outwards the outer lip of the wound, till a sufficient gap is made. An aperture is thus effected, partly by tearing, partly by stretching, and by the folding inwards of

* Some of the best examples of artificial pupil that we have seen, have been formed by us in this manner, but the division of the iris is effected with more difficulty than might be supposed, and only by an instrument of the keenest edge; which, in combination with the requisite narrowness of form, it is often difficult to procure. The operation is performed by introducing the knife with its back towards the cornea, through the sclerotica at the same spot as in puncturation for cataract, and when the point has fairly entered the eye, directing it forwards so as to penetrate the iris near its temporal margin. The instrument is then carried across the anterior chamber to the nasal side, and the membrane incised by gentle pressure with the edge as it is partially withdrawn. If an aperture of sufficient size be not made by the first movement, the blade should be again pushed forward and retracted, and the manœuvre repeated until the object is either accomplished, or found to be unattainable. Considerable injury is necessarily inflicted on the organ, but a degree of force that would separate the iris from its ciliary connexions, would be quite excusable. If the membrane have lost its contractility,—a circumstance which may be pretty certainly inferred from its general appearance,—its fibres would not separate, how completely soever, they might be divided, and some mode of operation other than that of simple incision should be chosen. The difficulty of severing a texture so intricately woven, and so delicately supported as the iris, constitutes, independently of other considerations, a strong objection to operating through the sclerotica; but this difficulty is not insuperable, and there are cases—those, for example, in which closure of the pupil is complicated with an opaque lens and an adherent capsule—that may be most successfully treated in this way. The crystalline being divided at the same time, is left to be absorbed in situ.—ED.

the flap of iris. This may be denominated "incision with extension."

The following sketch shows two pupils made after this method, in a patient whose natural pupils were closed from inflammation

Fig. 158.



after the operation for extraction. Mr. Tyrrell had operated on one of the cataracts, and I on the other.

The irides were discolored, puckered, and bulging.

In this instance I yielded to the tempting opportunity of making two artificial pupils; yet although they correspond, as nearly as it is possible to make false pupils agree, and the focal range of each eye is the same, and though the globes are parallel when both eyes are directed to an object, the patient sees double. With either eye he can see to tell the hour by his watch without glasses. More than a year after the operations double vision remained, but it was lessening, owing to his using only one eye. In the right eye, the remains of the natural pupil, displaced by prolapse of the iris, and closed by lymph, is seen above the artificial one.

A central pupil cannot be made with the knife, when the iris bulges at the circumference, unless the instrument be introduced much more towards the anterior part of the cornea than is shown in the sketch of the operation, Fig. 153.

When the iris is so altered, that neither simple "incision," nor "incision with extension," is applicable, Janin's operation, improved by Maunoir, may be available. The principle of it is,

to form a flap of a portion of the iris, by the shrivelling of which an aperture may result.

The cornea is divided towards its margin, to about a fourth of its circumference, and the scissors (Fig. 144) introduced sideways till they reach the desired spot, then turned, opened, the iris pierced with the sharp limb, and the instrument carried on till sufficiently advanced, as indicated by the blunt limb that traverses the anterior chamber, when the iris should be divided; a second incision should then be made, at an acute angle with the first. The two should be as nearly as possible in correspondence with the diverging lines in the following diagram:—

Fig. 159.



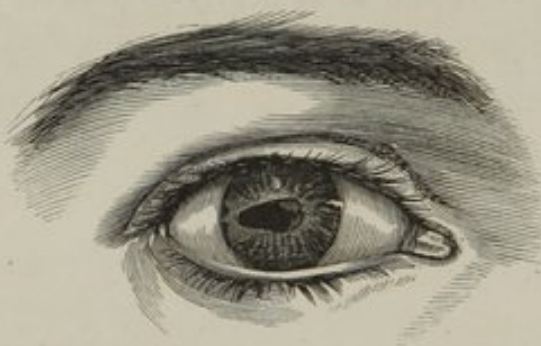The line at the margin represents the incision of the cornea. Mr. Tyrrell advised, that on account of its liability to unite, the flap of the iris should be depressed towards the vitreous body by the scissors. He writes:—"I formerly used to take out a piece of the iris, but I afterwards found the above modification of the operation to answer exceedingly well."

This being a complicated operation, and requiring for its execution that the cornea be opened as extensively as for "incision" with the knife, should not be adopted when either of the others will suffice. Perhaps, by employing the canula scissors, the corneal incision may be reduced, but, as I have not used them in such a case, I can only suggest their applicability.

It not unfrequently happens, that a dense layer of lymph or thickened capsule blocks up the pupil, and forms an impediment to "incision" with the knife, at least to the formation of a central aperture by it, but with the aid of another mode of operating, "excision," the details of which will be given in Section 2, we are enabled to make the pupil more towards the

centre of the iris, and to secure for it a better shape than by any other means. The following case will explain this. I performed the operation for "drilling," on a youth eighteen years of age, but could not, by any endeavor, make a patent opening in the capsule, nor detach it from the pupil: having divided the iris close to the capsule, with the largest iris-knife, I seized the outer portion with the hook (Fig. 150), drew it without the cornea, and cut off a piece. Fig. 160 represents the eye after

Fig. 160.



the operation. A portion of the capsule is seen at the inner side of the pupil, the remainder of it lies rolled up behind. The two black dots at the margin of the cornea indicate two very minute portions of the iris that prolapsed. This patient recovered sufficient vision to enable him to get his living as an errand lad.

2. Partial opacity of the cornea obscuring the pupil, the iris unadherent, the lens and its capsule transparent.

"Excision," which is of very old date, is the operation that is generally adapted for this condition.

The operator prepares the eye as in Fig. 153. The cornea is incised to about a fourth of its circumference, close to its margin, and in that direction which may seem most desirable for a lateral pupil. Should the iris prolapse, an occurrence not unusual, it is seized with a pair of forceps, drawn out sufficiently, and the required portion cut off by an assistant. Some surgeons prefer to

intrust the retracting of the lids and the steadying of the eyeball entirely to the assistant, while they execute the rest of the operation, but I prefer the other method.

When the iris does not prolapse, the blunt hook (Fig. 149) is introduced, the pupillary margin caught, and the iris pulled out.

There may be some embarrassment in withdrawing the hook on account of its catching the edge of the cornea, to avoid which it should be half rotated when it arrives at that part. It is a fact now fully established, that the capsule of the lens may be touched with impunity by a blunt and smooth instrument.

The opacity of the cornea may so obscure the pupil that the hook cannot be readily applied to its margin; in such a case the iris must be withdrawn with a pair of forceps. I object to an attempt to cause its protrusion by pressing on the eye, from the attendant danger of dislocating the lens.

Those who have practised this operation most frequently, lay great stress on the importance of cutting off a part of the edge of the pupil; this has reference to the liability of the new pupil to close when the iris is unhealthy, and does not apply here. It is a matter of nicety to decide how much of the iris should be excised, and nothing but actual practice can ever teach this; however, I may state that too much is more likely to be removed, than too little. The operation is finished by endeavoring to return within the eye, any part of the iris that yet protrudes.

Mr. Tyrrell endeavored to improve on this operation by employing the hook that I have just alluded to, and retaining the iris in the wound of the cornea; strangulating it, as it is generally called. A pupil so made is pear-shaped, the apex at the margin of the cornea; and this is the best shape a lateral pupil can have. The hook is undoubtedly a valuable addition to our instruments, its form enabling the iris to be readily seized and securely held; but the process of strangulation is so uncertain, from the frequent spontaneous extrication of the iris from the wound, an occurrence of great likelihood when it is healthy and has not any adhesions, that few operators trust to it in these cases, but perform the older operation. However, Mr. Tyrrell's practice has not been with-

out benefit, for it has taught us at once to apply the hook and seize the iris.*

3. Closure of the pupil by lymph, the lens and its capsule remaining transparent.

Until within a very recent period, in England at least, it was generally supposed that the lens and capsule become entirely opaque when a deposit of lymph completely closes the pupil; a condition in which the iris is necessarily adherent to the capsule of the lens. Dr. Mackenzie, certainly, alludes to transparency of the lens and capsule in connexion with closure of the pupil by lymph, but then he does not admit that the lymph is adherent to the capsule of the lens. "Closure of the pupil from inflammation of the iris, without any opacity of the capsule, or any adhesion between it and the iris, is certainly a very rare occurrence, and from the appearance presented, is exceedingly liable to be taken for a case of closure of the pupil with adhesion to an opaque capsule." With due deference to such authority, I must record my disbelief that such a state can exist: I think that the lymph must bind the iris to the capsule of the lens. Even so great a pathologist as the late Mr. Dalrymple maintained the prevalent opinion that the lens and capsule are always rendered opaque, as I had an opportunity of knowing from himself, in a consultation very shortly before his death. I understand that the German

* Prolapsus without excision was successfully performed by Professor Himly also. He made for this purpose a small opening in the cornea, introduced a blunt hook, drew out the pupillary margin of the iris, and entangling the membrane between the edges of the wound, left it there to contract adhesions with the cicatrix. Another mode of accomplishing the same object without the use of the hook, consists in making a rapid incision of the cornea to the extent of a sixth or more of its circumference; the aqueous humor suddenly escapes, carrying with it the iris, which is strangulated in the opening. This method of operating is preferred by our colleague Dr. Hays, and will, no doubt, often succeed,—the tendency of the iris to protrude when its support is removed at any point of the cornea near its ciliary margin, being matter of daily observation; but, as stated in the text, the permanency of the prolapsus, especially in a healthy condition of the membrane, cannot certainly be relied on, and it is safer, as a general rule, to excise a portion with the scissors.—Ed.

surgeons first showed the fallacy of the opinion, and taught, that while the centre of the capsule just under a deposit of lymph may be opaque, the rest of it, and the whole lens may be transparent. With this knowledge we now avoid the destruction of the lens, and proceed to make a pupil in a manner that shall not injure it or the capsule. Of course we cannot determine beforehand, with certainty, whether they are transparent; the history of the case and the perception of light which the patient may possess, will afford us some guide; but we ought, whenever there is a probability of the absence of opacity of these parts, to proceed on the assumption of their integrity. Prior to Mr. Tyrrell's time, when the formation of an artificial pupil was undertaken, this state of the eye was a sad puzzle to surgeons, the chief difficulty being how to dispose of the lens. Mr. Tyrrell, by introducing drilling, was supposed to have overcome this.

There seem to be only two operations appropriate to such a condition, for in any by which the iris is transfixed, the capsule and the lens can hardly escape injury. One of these is very modern and very simple. The cornea is punctured, the blunt canula forceps introduced, a portion of the iris close to the pupil is seized, and a piece gradually torn away. An instance of its execution by Mr. W. Cooper, my colleague at St. Mary's Hospital, came under my notice in the early part of the year. The particulars, with the diagram of the operation, are taken from the paper of Mr. Bowman on artificial pupil in the "*Medical Times*," already alluded to. "Samuel Hill, of Derby, aged forty-five, a stout, florid man, by occupation a porter, was attacked in February, 1850, with iritis of both eyes, which ultimately led to the closure of the pupils by deposit of lymph. They were contracted to the size of pins' heads, and the iris was much stretched in each. In the lower part of the left pupil there was a clear point, but so small as to be scarcely perceptible.

"The right eye was selected as being the worst, and the operation performed was as follows:—A small incision was made with Jäger's double-edged knife through the outer margin of the cornea, a little below the median line; the aqueous humor escaped,

but the iris did not bulge into the wound. A pair of extremely fine forceps (made by Luer after the pattern of Charrière) were then introduced, with the blades closed; when in front of the pupil the blades were opened by means of a spring, and a few fibres of the iris at the external border of the pupil, seized, and very gently drawn out of the wound. The rent thus made in the tense membrane, immediately dilated, forming a good-sized oval pupil, Fig. 161. Nothing more was required; not a drop of blood appeared, and the eye was closed and bound up.

Fig. 161.



“The patient recovered without a bad symptom, and returned home to Derby on the twelfth day after the operation, having regained good vision.”

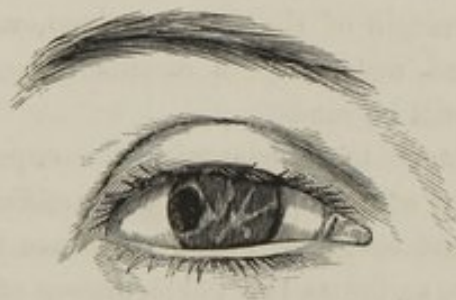I saw the man just before he left town, and can corroborate the accuracy of the statement respecting the form and size of the pupil, and the degree of vision that was restored.

The other operation, “excision,” has been already sufficiently described in Section 2, and all that need be said here is, that if the iris do not prolapse when the cornea is opened, as in such a case it probably will not, a part of it must be seized with a pair of forceps, withdrawn, and excised. It does not appear in any of the cases related by Gibson, who was a great authority on “excision,” that he executed it when the iris was adherent to the capsule of the lens by means of lymph; he restricted it, as most operators have, since his time, to those cases in which the pupil was lost by the iris adhering to the cornea, or was obscured by corneal opacity, or in which both of these states existed. Indeed, the operation has by some been deemed impracticable, unless the pupil be in part free, so as to admit of a portion of the iris being readily drawn out. That such is not absolutely necessary, although its existence affords great facility in operating, I con-

clude from a case that I have lately seen, in which the operation has been done in spite of entire pupillary adhesion, and it is from this instance, that I have ventured to describe the means as appropriate. I will relate the case.

A young woman, twenty-one years old, applied at the Central London Ophthalmic Hospital, with trichiasis. An artificial pupil in that eye quickly attracted my notice. It was the most efficient I had ever seen at the side of the iris, for, with the naked eye, small print could be read. She was, to my astonishment, short-sighted, seeing better through a concave glass. I examined the eye more narrowly, and discovered, by the catoptric test, that the lens was present. The accompanying figure is a representation of the eye, after the trichiasis was removed.

Fig. 162.



The iris had lost its fibrous appearance, and the remains of the pupil in its centre, closed by lymph, was just perceptible. The girl could not tell who was the operator; she knew only from her mother's account, that, when a child, she was taken to a gentleman in London, who operated, and restored sight, which had been lost in infancy, from a severe attack of inflammation.

When a portion of the circumference of the iris cannot be withdrawn, excision is inapplicable, and a piece must be torn away.

4. Partial closure of the pupil by lymph, the lens and its capsule transparent.

This state differs from the last described merely in the pupil

not being entirely lost. The cornea should be punctured near the margin, with the smallest iris-knife, the hook (Fig. 149) introduced, the point carefully inserted into the opening of the pupil, and an endeavor made to tear out a piece of the iris. Sometimes a thin strip is brought away, which may or may not be snipped off, according to the length of the piece: sometimes only a fissure is made; the result depends very much on the condition of the iris, whether it be considerably altered in structure or not; if much damaged, the hook readily tears out. It may, therefore, be necessary to enlarge the fissure. Of course this should not be attempted, till it has been well ascertained that the pupil so made is insufficient, for a linear pupil, apparently too narrow, may afford good sight. After it has been determined in which direction the enlargement shall be made, the cornea is punctured on the corresponding side, the hook introduced, the margin of the fissure seized, withdrawn, and cut off or strangulated, according to circumstances. A triangular-shaped opening will be made.

The hook is more in contact with the capsule of the lens in this, than in any other operation for artificial pupil; yet, if properly made, and carefully used, it will not inflict any injury.

It matters not, as far as the performance of the operation is concerned, at which side of the eye the free portion of the pupil be situated, for the stem of the hook may be bent, so as to allow the instrument to be used in any direction; but I would suggest that it might be better, when the iris is partially free in a direction not the best suited for extension of the pupil, to employ the canula forceps, and make an aperture in the most advantageous situation.

To obviate the inconvenience arising from the loss of the aqueous humor, when the knife is withdrawn, and which consists chiefly in the alteration that takes place in the position of the iris and the lens, Mr. Bowman has introduced a hook that cuts its own way into the cornea. The following description of it is taken from his lecture in the "Medical Times and Gazette."

"It is sharp and flattened at the point, and the stem is cylin-

drical, and of such a size as exactly to occupy the corneal wound, and effectually prevent the escape of the aqueous humor during the operation. There is a slit on one margin, near the point, running up towards the point, and making the terminal part of the instrument a hook as well as a needle. The cutting edge extends from the point as far as the shoulder, on the side opposite the slit; while, on the other side, or that which must be turned towards the lens in seizing the pupillary border, the edge is cutting only close to the point, and the convex part of the hook, that might touch the capsule, is blunt. The slit may be made of different depths in different instruments, so as to entangle more or less of the iris, as desired."

This is a sketch of the instrument :—

Fig. 163.



It may be mentioned, that the author speaks of having the recess of the slit sufficiently sharp, for "those cases in which it is desirable to slit up the iris from the pupillary border rather than to withdraw or remove a portion with the scissors. In the latter cases, when the iris has been slit up as far as necessary, say one-half of the distance from the pupillary to the ciliary margin, the hook may be disengaged and withdrawn leaving the pupil much limited in the direction of the ciliary margin." I fear that this is impracticable,—that a cutting edge could not be obtained; perhaps, however, the edge might be made sufficiently thin to tear the iris readily. This hook may suffice when a first attempt to withdraw a portion of the iris is effectual; but for obvious reasons, it could not be re-introduced when the eye is flaccid, so that it does not actually supersede any instrument already in use. Tyrrel's hook is yet required on many occasions, and it may too be used in connexion with the needle-hook, supplementary to it, as the inventor of the new hook expresses it.

5. Diminution or closure of the pupil from prolapse of the iris,

or adhesion of it to the cornea in consequence of a wound, a penetrating ulcer, a slough, or suppuration of the cornea ; the cornea more or less opaque, the lens and its capsule transparent or opaque, or the lens lost.

Under this head occur the greater number of cases requiring an artificial pupil, and of these, the majority arise from ulceration of the cornea and prolapse of a part of the iris ; but as, in a surgical point of view, it is the same whether the pupil be lost by prolapse, or by mere adhesion of the iris to the cornea, I shall not practically recognise any difference.

When a part of the margin of the pupil is implicated, the aperture being merely diminished, and the opacity of the cornea is limited, or if extensive, not so dense as to obstruct light, the practice should be to detach the iris from the cornea, without injuring the capsule of the lens, and thus to make the pupil central. A slight tag of the iris may be readily divided with the smallest iris knife, and the operation is extremely simple. The cornea is punctured at the spot from which the adhesion can be most readily reached, subject only to the rule of avoiding that part under which the pupil will fall, the knife is directed between the iris and the cornea with great care, as the anterior chamber is necessarily small, and applied at once to the part to be severed. If it be carried too far, and then withdrawn, the aqueous humor will escape, and the operation probably fail.

When a large portion of the pupil is adherent, in which case no inconsiderable part of the body of the iris is generally tied to the cornea, it is scarcely possible, even with a large knife, to operate in the above manner, for in attempting to divide the iris the aqueous humor is apt to escape, and then the operation must be abandoned, or the capsule of the lens will be wounded and rendered opaque. I recently witnessed a very marked failure of this kind ; Adams's iris knife was used, only a part of the adhering band of the iris could be divided, and when the knife was withdrawn, a portion of the circumference of the iris prolapsed, and reduced the pupil that existed, which was by no means an inadequate one, to a mere pin-hole.

In these cases, therefore, I have incised the cornea, and divided the connexions with the blunt iris scissors, and where the scissors could not readily reach every adhering part, I have torn the remainder through with one or other of the blunt hooks.

It is supposed that the canula scissors are well adapted to this class of cases, but I find that they are not generally applicable, and when they may be used with impunity, the iris knife may also be employed, and I think with greater safety. There is not generally space enough for them to be worked in, without their inflicting injury on the cornea, or the capsule of the lens.

When the above methods are forbidden from the extent of the iris that adheres, and from the presence of a broad opacity, perhaps an actual cicatrix of the cornea, a central aperture may yet be secured, and the capsule of the lens avoided, provided the part of the pupil that is free be visible, and can be readily got at to be incised. Here the canula scissors may be brought into play with advantage; indeed they are of especial value, because they enable the iris to be cut while the chambers of the eye are yet filled with their aqueous secretion. A more favorable example of their applicability, than one which is taken from Mr. Bowman's writing already alluded to, could scarcely be given. The patient, thirty-six years old, had lost the left eye by a blow. The right was rendered useless by a severe inflammation, which ended in sloughing of the cornea. A dense leucoma occupied the greater part of the cornea, nearly concealing the lower portion of the iris, and obscuring the pupil. When the eye was shaded so as to dilate the pupil, it rose a little above the leucoma, and his sight was considerably improved. Still, the cornea was slightly hazy above the leucoma, to nearly its upper margin. The lens appeared to be *in situ*, and perfectly clear. The lower edge of the pupil adhered to the leucoma.


The patient being placed on his back, the scissors were introduced at the outer side of the cornea, where it was very nebulous, and pushed on as far as the existing pupil, where it lay almost, but not quite, obscured by the leucoma, for atropine had been applied. The shorter, blunt-pointed blade of the scissors was then passed behind the upper border of the pupil, and the

long sharp-pointed blade in front of the iris, and the upper margin of the pupil cut to the extent of about 1-16th of an inch. No blood flowed to discolor the aqueous humor, and the man, sitting up, could at once see the trees and distant houses through the window. No inflammation ensued, and he returned to the country.

Early in November he came back for inspection, and his sight continued much improved; but as he stated that he saw more distinctly when the eye was shaded, and as it was found that the pupil enlarged slightly upwards when that took place, the operation was repeated, and the iris incised at the same point, but to a greater extent, so as to place the pupil permanently in the condition in which it was found to serve most efficiently the purposes of vision. A minute strip of iris remained between the two cuts.

No inflammation followed; nor did the capsule of the lens become opaque, although it was evidently touched with the scissors, and that too not slightly.

Fig. 164.



The first diagram shows the size of the pupil before operation. The oblique line indicates the course of incision by the scissors. The line at the margin points out the position at which the cornea was divided. The second diagram represents the pupil after the first operation.

Instances may occur in which the canula scissors are inapplicable, and the common ones suitable, but with the latter, there must ever be the disadvantages attendant on operating when the eye is flaccid.

When a slight portion of the pupil is free, but from its position the scissors cannot be used, it may be possible, perhaps, to operate with the hook, after the manner described in Section 2,

and make a linear pupil, a proceeding that should, if practicable, be adopted.

When the pupil is quite closed, the choice of an operation must depend chiefly on the extent of the corneal opacity, and the supposed state of the lens. A girl, nine years old, whose right eye had been quite destroyed by an attack of purulent ophthalmia in infancy, was placed under my care by Mr. Harding, of Percy Street, for the purpose of having an artificial pupil made in the left. The central and lower part of the cornea was occupied by a dense cicatrix (Fig. 165), to the entire extent of which the iris was adherent, the pupil being of course lost, and the rest of the

Fig. 165.



cornea was more or less opaque. Acting on the supposition that the lens had escaped, or having become opaque, was most probably absorbed, my opinion being founded on what I had observed in parallel cases, I incised the iris at the outer and upper part with the second-sized iris knife, but its texture was too much damaged for a gap to ensue. However, the incision did not close, and a few weeks afterwards, I divided the cornea on the outer side, near its margin, and with the iris scissors (Fig. 144) cut the iris transversely at each extremity of the incision, and a good-sized, well-shaped, and well-placed pupil resulted, as the preceding sketch shows.

Scarcely any inflammation followed either operation. I was disappointed in the little benefit that ensued, for the retina was, it appeared, too much damaged to admit of useful sight.

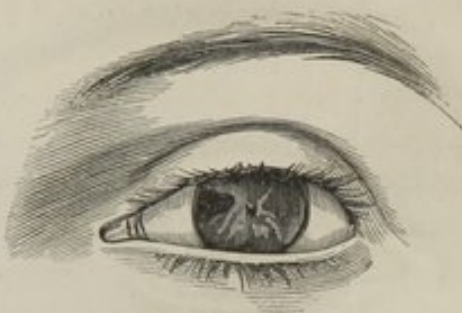Different modes of operating may be adopted in this class of

cases. When the lens is absent or opaque, it must be left to the judgment of the operator, whether incision with the knife, incision combined with excision, as described in Section 1, or double incision with the scissors, page 569, should first be tried, and when the lens is present and not opaque, whether a portion of the iris should be torn away with the capsule forceps, as described at page 573, or an old method, a little modified by Mr. Tyrrell, adopted, namely, that of incising the iris close to the cornea, with the smallest iris knife, and with the blunt hook tearing away a portion of it, as in the operation for enlarging a pupil, page 570; this is the more hazardous of the two to the capsule of the lens. When, however, only just the circumference of the cornea is transparent, "separation," or the tearing away of the iris from its natural attachment, is the only resource, for then, it would be most imprudent to incise that part of the cornea for the execution of any of the other operations, lest opacity of it should ensue. When the transparent portion is at the upper or the inner side, even although it be not very limited, "separation" may be required, from the impediments to the performance of other operations in such situations. To execute this, the cornea is divided obliquely with the second-sized iris knife, opposite, or as nearly as possible opposite, the portion of the iris to be detached, and so far only from its margin that, when enough of the iris is torn away, it shall readily reach the incision, so to allow of a part of it being cut off or strangulated. If the incision be very far, too much will be separated, and too large a pupil formed; therefore, it should not be further from the margin of the cornea than half of its diameter, and this distance will allow the knife to be thrust up to its shoulder, thereby effecting an ample cut.

The hook—and I find that shown at page 417 superior to any that I have used—is carried in front of the iris to its margin, where it is implanted, separation effected, and a portion of the iris withdrawn and cut off. The instrument must be kept close to the cornea while it is being withdrawn, lest the capsule of the lens be injured. The circumference of the iris being a little behind the sclerotica, the extremity of the hook must pass out of sight to seize it. When the operation is suc-

cessful, the form of pupil that usually results resembles that shown in the annexed sketch, which was taken from a patient

Fig. 166.



whom I was attending for an affection of the lids. I may observe, that in this instance, the operation had been badly chosen, and the pupil badly placed, and that vision was very defective.

There is, I believe, greater uncertainty in the execution of "separation," than any of the foregoing operations; it is, moreover, attended with great pain. Instead of a portion of iris of the required size separating, a mere strip of it may give way, or, what is more common in a diseased state, the hook may tear out without effecting any separation. Sometimes, directly that the separation is commenced, blood is poured out, and the subsequent steps of the operation obscured. The withdrawal of the hook through the opening in the cornea requires adroitness, and unless the aperture be ample, the iris will probably be shaken off: the size should bear some relation to that of the hook, being of course always much larger.

A man, twenty-two years of age, applied to me at the Central London Ophthalmic Hospital, to know if his right eye could be submitted to an operation similar to one which had been performed on his left, by Mr. Wilde, of Dublin—namely, "separation." An instance to which this form of operation was more adapted, or a better example of its execution, I have never seen. I subjoin a sketch of the eye. A severe attack of purulent ophthalmia, which had completely destroyed the right eye, had

also rendered leucomatous the cornea of the left, with the exception of a strip at the outer and upper part, which was hazy.

Fig. 167.

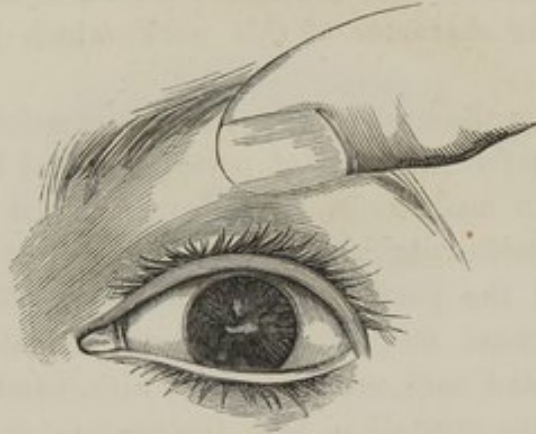


The new pupil was made opposite to the most external part, in order to afford a greater range of sight. The corresponding portion of iris had lost its fibrous appearance, and was, as far as I could judge, in actual contact with the cornea; this being the instance of such apposition that I alluded to at page 550. The remainder of it was adherent to the leucoma. He had sufficient sight to read very large print, such as the titles of books, without glasses; to do which, however, he almost closed the lids, to diminish the aperture and reduce the rays of light. I did not examine the eye catoptrically, and cannot tell if the lens was present. In an answer from Mr. Wilde, to whom I wrote about this person, I learn that in the majority of cases in Ireland, requiring artificial pupil, purulent ophthalmia has damaged the eye; that "separation" is the operation most suitable, and that, for the most part, he strangulates the iris in the wound in the cornea, though he sometimes cuts it off, and then the pupil is less triangular. In the case in question, he thinks that the latter must have been practised.

Although the hook is more likely to tear out of a diseased iris than a healthy one, and, as a rule, "separation" is less suited when this is likely to happen, we may be obliged, by the very unhealthiness of an iris, to resort to it, because, in such a state, it is less likely than any other method, to be followed by

closure of the pupil. The accompanying figure represents an eye in which the pupil had been lost for some years, by prolapse of its margin, through an ulcer of the cornea. The state of the

Fig 168.



entire eyeball proved that the strumous inflammation, the cause of the ulceration, had damaged all of its tunics, yet the sensibility of the retina showed the feasibility of an operation. I incised the cornea, and, with the blunt canula-forceps, tore away a large piece of the iris from its adhesion, detaching it still farther with a blunt hook, but to no effect; for, although but slight inflammation ensued, the aperture closed.

Following out the practice I have adopted with success in a somewhat analogous case, I shall make a second attempt, with the same forceps, to seize the iris at its circumference, and to separate and excise a portion of it.

It may be stated in general, respecting "separation," that eyes requiring it are most unfavorable for an operation, as they are usually the wrecks of disease, and fall only just within the compass of operative surgery. The cornea, besides having dense opacities from slough or penetrating ulceration, is frequently staphylomatous, and adhesion of the iris to it has diminished, or even destroyed, the anterior chamber, whereby the operation is rendered very difficult.

The above sections include all the individual alterations in the eye, that admit of the formation of an artificial pupil; and

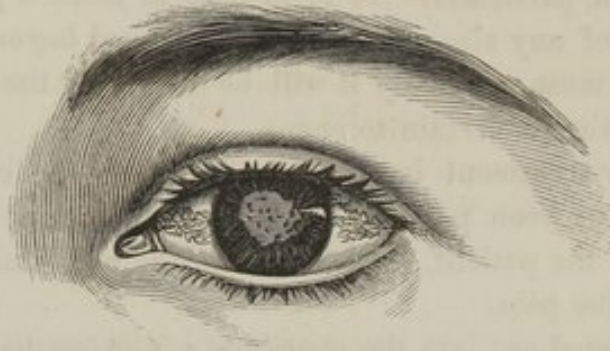the operations described, comprise all that are practised at the present day. Some other methods have been suggested by a recent Continental writer, but their inapplicability is so self-evident, that I shall not speak of them. To describe those that have been superseded and are now obsolete, would not be compatible with the character of this work, which is professedly practical.

I must caution the student, that the classification I have made has been solely for the sake of perspicuity and brevity, and I hope it has been made sufficiently clear, that the choice of any particular operation must be based on a careful examination and analysis of all the particulars of the case. Should this be neglected, he must frequently fall into difficulties when instances occur, and such are often met with, combining morbid alterations in the crystalline lens, the capsule, the iris, and the cornea. A single example of this complication I shall adduce. Mr. E. A. Lloyd, of Bedford Row, submitted to my treatment a patient who had been injured by an explosion of gunpowder. The right eye was quite lost. The cornea of the other was densely opaque in the central portion, and some black dots showed where grains of the powder had entered. The pupil, so far as could be seen, was adherent to an opaque capsule, or to a deposit of lymph, from which a narrow band of adhesion, apparently of lymph, passed to the opaque part of the cornea, thus resembling a case mentioned at page 36. The iris was discolored, but not bulging. Here the choice was in favor of "incision" with the knife. I inserted the instrument through the cornea, at the lower and outer edge of the cicatrix, and divided the iris, but an attack of inflammation frustrated my operation. Some months afterwards, I divided the cornea nearer the circumference, and at the same time attempted to draw out the external portion of the iris with a blunt hook, but as this was not readily effected, I desisted, lest there should be an escape of the vitreous humor, which it was supposed had degenerated. When the eye was opened, a week after, a small and irregular, but useful pupil was discovered, and in a few days the man was able to walk

alone in the streets. My colleague, Dr. Taylor, took the following sketch of the eye for me.

The pupil will be observed at the outer and lower part of the corneal opacity; the vessels at each corner of the eye were the

Fig. 169.



remains of the active inflammation the eye had undergone; such probably will be always present. The lens was absorbed and the capsule had contracted towards the centre, and was quite away from the position of the pupil; very likely the iris knife had torn it from its external attachments.

I have postponed till now, speaking of the manner of dealing with lenticular cataract, when combined with closed pupil. When the pupil is adherent to a capsulo-lenticular cataract, and the cornea is sufficiently clear in the centre to allow it to be seen, the cataract must be first attended to. This has been fully dwelt on under the head of "drilling," page 473. When the opacity of the cornea precludes the application of instruments to the centre of the iris, or when adhesion of the iris to the cornea renders it impossible that the cataract can be operated on without transfixing the iris, the pupil should first be made, and the opaque lens disposed of afterwards; that is, by a subsequent operation for solution or displacement. It would be almost certain destruction to an eye which is already much damaged, to make an artificial pupil and to operate on the cataract at the same time; except that it be much reduced, and while making the pupil, its nucleus admits of easy removal. With respect to capsular cataract the same principles hold good.

If, at the time of operating, it admits of ready extraction, it is better at once to take it away. If otherwise, any operation on it should be delayed.

The immediate and permanent success of an operation for artificial pupil, is in a ratio to the healthiness of the eye, and of the iris in particular. It is in vain to make a pupil by any method, or of any size, if the iris is diseased beyond a certain degree, for most assuredly it will be closed by the general inflammation that is certain to ensue.

The after-treatment is the same as when the operation for extraction has been performed, the most important points being the quiet of the patient, perfect rest to the eye, and opiates and cold to subdue pain.

Blood poured out into the chambers of the eye need not cause any apprehension. I am not aware that it is attended with any disadvantage, it is soon absorbed, and does not require any special treatment; but I have considered this subject in detail in connexion with injuries, at page 49.

It is possible that atropine may be beneficial after operating, by keeping the edges of the pupil more apart; it should always be used, except when a part of the iris has been left strangulated.

The advantage of having a patient narcotized during these operations is very great, and should never be foregone, except for cogent reasons.

When the crystalline lens has been lost, cataract spectacles will of course be requisite; for rules respecting their use I beg to refer to page 475. When the pupil is away from the centre of the iris, it may be requisite to adapt the glass accordingly. Here much ingenuity is required, but an optician who has had practice in such cases, readily sees what is needed. Similar contrivances are necessary, when, without loss of the lens, glasses are wanted.

Certain mechanical appliances may be of advantage when the pupil is too large, such as a diaphragm in a spectacle frame, with a hole or a slit to look through, and I have found that several patients with lateral pupils have seen better when the side light has been shut out by a sort of goggle.

CHAPTER XXI.

EXTIRPATION OF THE EYEBALL.

REMOVAL OF THE ENTIRE CONTENTS OF THE ORBIT. REMOVAL
OF THE EYEBALL ALONE.

WHEN extirpation of the eyeball is undertaken on account of malignant disease, the whole of the contents of the orbit should be removed. Unless this be done, the important rule—always to endeavor to eradicate every part of the diseased structure by cutting beyond it, or by removing along with it the healthy tissues immediately around—could not be carried out. As this topic has been particularly dwelt on in my chapter on Malignant Affections of the Eye, page 546, to which I beg to refer, more need not be said here.

Should the eyeball require extirpation from disorganization arising out of a scrofulous affection, in which exhausting pain or profuse discharge are the urgent symptoms, the other parts of the orbit may be so diseased, that their removal would be advisable.

It is very seldom, however, that a case is met with, not of a malignant nature, that demands removal of the eyeball, and rarer still, that the ocular appendages require to be taken away. In the scrofulous affection of the eye mentioned at page 524, it was considered necessary to clear out the orbit.

In the Museum of the Royal College of Surgeons, an eyeball is preserved that was removed by Mr. Liston under the following circumstances; whether the other parts in the orbit were taken away is not said.

A man received a kick from a horse on the supra-orbital region, destroying vision in the corresponding eye. From that time he had frequent attacks of pain in the eye, and twelve years afterwards, fistulous openings formed in several places around the eyeball, from which a constant discharge issued. After this had continued for ten years, and his health had begun to fail through the irritation, discharge, and occasional hemorrhage, the eye was extirpated. The whole of the orbital plate of the frontal bone had been destroyed, so that the finger could rest on the dura mater beneath the anterior cerebral lobe. The patient completely recovered, and lived long after the operation. The preparation is referred to in the catalogue, from which the above is taken, as an eye extirpated after twenty-two years' disease, from a man sixty-five years old. The coats of the eye are thickened, indurated, and consolidated. The place of the vitreous humor is occupied by a whitish substance.

REMOVAL OF THE ENTIRE CONTENTS OF THE ORBIT.

It is a prevalent custom to place the patient on his back, but I prefer that he should lie on his side, to allow of the escape of the blood from the orbit, whereby the operator sees what he is about, and is enabled to proceed safely and quickly.

The external commissure of the lids, including the conjunctiva, should be divided to the extent of half an inch, or more, according to the size of the eyeball, and it may even be required to dissect up the divided integuments to afford room. The eyelids are to be retracted by an assistant, either with small bent copper spatulas or wire retractors. When the eyeball cannot be laid hold of with the fingers, and it is seldom, when there is enlargement, that it may not, a large pair of tenaculum forceps is the best substitute, because they can be readily shifted from place to place, and quickly laid aside when the fingers may be applied.

Some operators use a hook to the eyeball, others pass a few threads through it by a curved needle in order to hold it. With a small scalpel the reflections of the conjunctiva are cut through,

whether first above or first below, or in any other direction, should depend on circumstances; the operator should proceed in the manner most likely to facilitate the subsequent steps of the operation. While dissecting at the upper edge of the orbit the levator palpebræ should be divided as close to the tarsus as possible. The division of the other muscles, and of the vessels and nerves, now occupies attention. The inferior oblique muscle must be severed close to its bony attachment; the trochlea of the superior oblique cut from the bone, and the eyeball turned from side to side, while the knife is swept around the orbital walls to divide the cellular connexions and the small vessels and nerves.

The muscles, the optic and other nerves, and the ophthalmic vessels, are now to be divided at the apex of the orbit, to effect which the eyeball should be pulled forwards and inwards, and the scalpel or scissors used on the outer side, the slant of the outer wall of the orbit affording more room for the instruments in that direction. Lastly, the lachrymal gland is to be dissected away, together with whatever fat and cellular tissue may have been left.

I have not found that crooked instruments at all facilitate any steps of the operation, but that they rather constitute an impediment. Their introduction must have arisen from the assumption that they were superior, and never from a comparative trial between them and straight ones, on the dead or the living body. Besides the use of sponges, syringing the orbit may be advantageous in cleaning away the blood and exposing surfaces.

The parts around the eye in cases of melanosis are sometimes so altered from condensation, that the several structures can scarcely be recognised, and a tedious dissection with the scalpel and a pair of forceps may be required to clear the orbit. The bleeding from the ophthalmic and other arteries, although very smart at first, readily ceases. Should it continue rather long, or after the application of cold water, a compress must be used.

It would be difficult, though not altogether impossible, to apply a ligature to the ophthalmic artery. A tendency to oozing of blood from the cavity, may be checked by applying cotton-wool or lint wetted with a solution of alum. Some surgeons

invariably fill the orbit with lint: this is, I think, objectionable, and very likely to keep up suppuration. The divided commissure must be united by suture, and water-dressing applied over the orbit.

REMOVAL OF THE EYEBALL ALONE.

The removal of the eyeball alone, by dissecting it from its cellular sheath, was proposed almost simultaneously by Dr. O'Ferrall and M. Bonnet. Dr. O'Ferrall's suggestion is published in the "Dublin Journal of Medical Science," for July, 1841.

When this may be done, it is certainly an advantage; for, as its proposers have pointed out, hemorrhage is avoided, and the parietes of the orbit not being stripped, there is less chance of dangerous inflammation.

After the commissure of the lids is divided, and the conjunctiva cut through, the attachments of the recti and oblique muscles are separated from the eyeball, which is then to be dissected from the sheath, turned aside, and the optic nerve severed.

A description of the ocular sheath, accompanied by a sketch of a dissection of it, will be found in my chapter on Tumors, page 303.

There can be very few cases to which this operation is applicable; in malignant affections it is evidently inadmissible, and I do not know an instance in which it has yet been done except in melanosis.

A patient demands much attention after the eyeball has been extirpated. The operation has several times proved fatal; in one instance, I nearly lost a case from a consecutive attack of phlegmonous inflammation of the face and head.

INDEX.

- Abscess of eyelid, 89.
of edge of orbit, 206.
- Acids and alkalies, injuries from, 66.
- Adhesion of eyelids to eyeball, 90.
of the edges of eyelids to one another, 97.
- Affections of the eyelids, 89.
of the puncta and canaliculi, 177.
malignant, of the eye, 492.
- Amaurosis from injury to frontal nerve, 63.
distinction between it and cataract, 403.
- Aneurism by anastomosis, 228.
treatment of, by extirpation, 229.
by ligature of common carotid artery, 230.
- Aneurism in the orbit, 235.
treatment of by ligature of the common carotid artery, 236.
- Aqua Morgagnii, 392.
- Aqueous humor, evacuation of, in inflammation of eyeball, 44.
- Artificial eyes, 489.
pupil, 549.
formation of, at centre of iris, 553.
at other parts of iris, 553.
by staphyloma, 358.
operation for "incision" with knife, 562, 586.
for "incision with extension," 567.
of Maunoir for "incision," 569.
of Tyrrell, for "incision," 569.
for "incision," with "excision," 569.
for "excision," 570.
for tearing away a central piece of iris with canula forceps, 573.
for tearing away a central piece of iris with hook, 576.
- Artificial pupil, operation for dividing a portion of adherent iris, 578.
operation for incising the pupillary margin with scissors, 579.
for "incision" with scissors and knife, 581.
for "separation," 583.
- Atrophy of eyeball from a blow, 35.
from tumors, 295.
- Atropia causing permanent dilatation of pupil, 460.
formula for, 43.
use of, in prolapse of iris, 57.
- Belladonna, effects on iris when diseased and when healthy, 400.
use of, 57.
- Beer's knife, 415.
- Blisters, use of, in ophthalmic diseases, 48.
- Blood, absorption of, from chambers of eye, 49.
effusion of, into chambers of eye, 49.
from wound of iris, 423.
after extraction, 425.
after needle operations, 447.
- Blows on the eye, 35.
- Blunt hook (squint), 248.
- Burns on the eye, 32.
- Calculi in the conjunctiva, 175.
in the caruncle, 176.
- Canaliculi, accidental division of, 61.
affections and injuries of, 177.
obstruction of, 178.
by polypi, 182.
- Cancer, 492.
colloid, 494.
definition of, 493.
division of, 494.
encephaloid, 495.
epithelial, 499.
microscopic characters of, 499.
origin and physiology of, 503.
scirrhus, 497.

- Cancer, infrequency of, 507.
 Capsular cataract, 394.
 Capsulo-lenticular cataract, 473.
 Capsule-forceps, 465, 466, 467.
 Capsule of lens, opacity of, from blows, 56.
 Caries of the orbit, 201.
 diagnosis of, by chemistry and the microscope, 205.
 treatment of, 203.
 Carotid artery, ligature of, for nævus, 255.
 for aneurism by anastomosis, 231.
 aneurism in orbit, 236.
 Caruncle, calculus in, 176.
 enlargement of, 288.
 scirrhus of, 530.
 warts of, 288.
 Cataract, 383.
 absorption of, after operating for solution, 464.
 acute inflammation after extraction, 432.
 adhesion of iris to capsule of lens, 426.
 adjustment of corneal flap, 428.
 Bowman's method of lacerating opaque capsule, 473.
 capsular, 394.
 capsulo-lenticular, 473.
 catoptrical test for, 405.
 cause of, 384.
 circumstances regulating choice of operations, 408.
 circumstances contra-indicating operations, 413.
 coloration of lens, 388.
 combined with amaurosis, 403.
 complications of, 398.
 congenital, 396.
 curette for lacerating capsule, 416.
 danger of wounding iris, 423.
 dilatation of pupil in, 460.
 disintegration of, during extraction, 426.
 distinction from amaurosis, 403.
 distinction from glaucoma, 405.
 effusion of blood while extracting, 425.
 after extraction, 426.
 after needle operations, 447.
 evacuation of vitreous humor to reduce prolapse of iris, 427.
 loss of vitreous humour while operating, 427.
 fluid, 391.
 hard, 388.
 imperfect union of cornea after extraction, 437.
 inadequate section of cornea, 424.
 infiltration of cornea with pus after extraction, 432.
 irregularity of pupil after extraction, 437.
 knife for extraction, 414.
 secondary, 417.
 laceration of capsule, 424.
 lenticular, 387.
 Morgagnian, 392.
 necessity for spectacles after loss of the crystalline lens, 475.
 operations for, 407.
 for extraction, 420.
 for extracting a dislocated lens, 439.
 for extraction of soft cataract, 463.
 for extraction of capsule, 469.
 for displacement, 442.
 for displacement by depression, 442.
 for displacement by reclination, 443, 445.
 for displacement by Egerton's plan, 447.
 for solution (anterior operation), 452.
 for solution (posterior operation), 456, 459.
 for drilling, 473.
 preparatory measures before operating, 410.
 prolapse of iris after extraction, 435.
 removal of, by hook, 425.
 soft, 390.
 subacute inflammation following extraction, 431.
 suppuration following extraction, 432.
 thickening and adhesion of capsule, 432.
 treatment after operation for extraction, 428.
 after needle operation, 448.
 varieties of, 383.
 vomiting following needle operations, 447, 453.
 Catoptrical test, 405.
 Chemical injuries to eyeball, 65.
 Chemosis, 64.
 division of, in gonorrhœal ophthalmia, 238.
 in inflammation of the orbital cellular membrane, 342.
 Chloroform, use of, 17.
 precautions to be observed in its administration, 18.
 tests for its purity, 20.
 Choroid membrane, ossification of, 87.
 prolapse of, from a blow, 49.
 Cicatrices, causing ectropium, 158.
 removal of, 61.
 Cilia, excision of, in trichiasis, 120.
 in entropium, 139.
 forceps, 109.
 Colloid cancer, 495.
 Congenital cataract, 396.
 Conjunctiva, calculi on, 175.

- Conjunctiva, incision of, in chemosis from purulent ophthalmia, 238.
 injuries of, 90.
 penetration of, by foreign body, 77.
 polypi and warts of, 289.
 wounds of, 64.
 Copper caps, impactment of, in the eye, 85.
 Cornea, conical, 366.
 division of, 419.
 imperfect union of, 437.
 infiltration of, with pus, 432.
 opacity of, from heated substances, 66.
 opacities of, removed by operation, 373.
 opening of, for evacuation of pus, 46.
 ossification of, 87.
 stain on, from metallic particles, carbonized substances, &c., 76.
 staphyloma of, 350.
 transplantation of, 379.
 tumors of, 295.
 warty, opacity of, 297.
 wounds of, 55.
 hypertrophy of the epithelial scales of, 297.
 Curette, 416.
 Cysticercus cellulosæ, 477.
 Cysts within eyeball, 485.
 Dacryolites, 176.
 Dilated and tortuous veins, 226.
 Dislocated lens, removal of, from chambers of eye, 51.
 from beneath conjunctiva, 52.
 Distichiasis, 111.
 Distinction between cataract and amaurosis, 403.
 cataract and glaucoma, 405.
 Division of supra and infra-orbital nerves, 64.
 Drum for testing the points of instruments, 25.
 Ecchymosis, 33.
 Echinococcus oculi humani, 484.
 Ectropium, 152.
 causes of, 152.
 from strumous inflammation, 168.
 from purulent ophthalmia, 173.
 from paralysis, 173.
 from mechanical and chemical injuries, 157, 158.
 operation for, 153.
 plastic operation for, 159.
 proper time for operating, 165.
 producing displacement of the puncta, 180.
 Encanthus, 530.
 Encephaloid cancer, 495.
 diagnosis of, within eyeball, 513.
 of eyeball, 508.
 Encephaloid cancer of eyelids, 530.
 of orbit, 525.
 Entozoa, within eyeball, 477.
 within Meibomian gland, 484.
 Entropium, 127, 130.
 action of orbicularis and tensor tarsi muscles in producing it, 132.
 congenital, 152.
 influence of skin causing the inversion, 128.
 of palpebral conjunctiva, 128.
 of tarsal cartilages, 129.
 opinion respecting its causes, 128, 135.
 operation for, 136.
 operation for, by excision of cilia, 139.
 by amputation of edge of eyelid, 141.
 by subcutaneous incision, 143.
 with trichiasis, 149.
 Epicanthus, 100.
 Epiphora, from displacement of puncta, 180.
 Epithelial cancer, 499.
 of eyelids, 531.
 of orbit, 527.
 Exostosis of orbit, 318.
 Extirpation of lachrymal gland, 328.
 of eyeball, 589.
 Eye, blows on, 35.
 burns on, 32.
 malignant affections of, 492.
 Eyes, artificial, 489.
 Eyeball, acute inflammation of, 432.
 atrophy of, 35, 295.
 congenital enlargement of, 346.
 cysts within, 485.
 diagnosis between protrusion and enlargement of, 346.
 diminution of, 400.
 encephaloid cancer of, 508.
 enlargement of, 361.
 entozoa within, 477.
 eversion of, 269.
 extirpation of, 589.
 foreign bodies within, 80.
 malignant affections of, 508.
 melanosis of, 518.
 protrusion of, 269, 331.
 rupture of, 48.
 scirrhus of, 521.
 subacute inflammation of, 433.
 suppuration of, 46.
 traumatic lesion of, 53.
 tunic of, 303.
 warty growths about, 296.
 Eyelids, adhesion of, from lead solder, 67.
 to one another, 97.
 to the eyeball, 90.
 affections of, 89.
 amputation of, for bite of rabid animals, 62.

- Eyelids, horns on, 276.
 glandiform tumor of, 277.
 malignant affections of, 530.
 operations on, 62.
 tumors of, 275.
 wounds of, 60.
- Fibrine, organization of, 39.
- Filaria medinensis, 484.
 oculi humani, 483.
- Fistula lachrymalis, 193, 194.
 spontaneous cure of, 185.
 congenital, 199.
- Focal range subservient to diagnosis of tumors, 346.
- Forceps, capsule, 465, 466, 467.
 cilia, 109.
 dissecting and tenaculum, 28.
- Foreign bodies on surface of eye, 69.
 encasement of, on surface of eyeball, 80.
 within eyeball, 80.
 encysting of, 82.
 extraction of, 80.
 means of detecting, 70.
 producing sympathetic inflammation, 85.
 removal of, from surface of eyeball, 70.
 when embedded in eyeball, 74.
 by chemical action, 77.
 by operation for "extraction," 440.
- Frontal nerve, injury of, 63.
- Fungus hæmatodes, 496.
- Glandiform tumor of eyelids, 277.
- Glaucoma, 404.
- Granular conjunctiva, 243.
- Gonorrhœal ophthalmia, 239.
 treatment of, by division of chemosis, 242.
 by local applications, 243.
- Grooved needle-knife, 440.
- Guarded curette, 416.
- Gunpowder, injury from, 65.
- Hair, growth and development of, 112.
 growing from tumor of eyeball, 298.
 transplantation of, to form cilia, 126.
- Hard cataract, 388.
- Heat, application of, to eye, 66.
- Hook, blunt, for squint, 248.
 sharp, 418.
- Hyaloid membrane, ossification of, 117.
- Hydrophobia, from bite on eyelid, 62.
- Hypertrophy of skin and cellular tissue, causing ptosis, 106.
- Incisions, course of, about the eyelids, 62.
 of conjunctiva for gonorrhœal ophthalmia, 241.
- Inflammation of eyeball, 37.
 Dr. Jacob's views, 37.
 sympathetic, 85.
 acute, 432.
 subacute, 433.
- Infra-orbital nerve, division of, 64.
- Injuries of canaliculi, 61, 177.
 conjunctiva, 90.
 cornea, 50.
 eyeball, 53.
 eyelids, 60.
 frontal nerve, 63.
 iris, 50.
 lachrymal tube, 61.
 optic nerve, 63.
 puncta, 177.
 sclerotica, 77.
- Instruments, 23.
- Iris, adhesions of, 426.
 detachment of, 50.
 escape of, from ruptured globe, 50.
 prolapse of, 55, 436.
 reduction of, 56.
 tremulous, 35, 401.
 scissors, 557.
 canular scissors, 560.
 hooks, 559.
 knives, 558.
- Iron, removal of particles, by chemical action, 76.
- Knife for lachrymal tube, 182.
 for dividing chemosis, 238.
 cataract, 415, 417.
 for artificial pupil, 558.
- Lachrymal gland, cysts in, 330.
 dilatation of its ducts, 330.
 enlargement of, 324.
 extirpation of, 325.
 malignant affections of, 534.
 tumors of, 324.
 tube, absence of, 195.
 bony deposit obstructing, 194.
 congenital fistula of, 194.
 dilatation of, by probe, 197.
 fistula of, 193.
 hemorrhage from, 193.
 laceration of, 61.
 obstruction of, 182.
 operation when obstructed, 185.
 polypi in, 194.
 probe for, 177.
 rupture of, 61.
 style for, 186.
 syringe for, 190.
- Larvæ of insects under eyelid, 79.
 within eyeball, 79.

- Lens, absorption of, 51, 397, 464.
 degeneration of, 391.
 discoloration of, in age, 388.
 dislocation of, 52, 456.
 displacement of, 51.
 effects of, as a foreign body, 86.
 escape of, through rupture of globe, 50.
 opacity of, from blow, 56.
 ossification of, 351, 87.
 Lenticular cataract, 387.
 with closed pupil, 587.
 Lid retractor, 29.
 Lime in the eye, 66.
 causing adhesion of eyelids, 91.
 Lippitudo causing ectropium, 168.
 Lymph, organization of, 39.
- Magnets for removal of iron particles, 78.
 Malignant affections of the eye, 492.
 colloid cancer, 495.
 definition of cancer, 493.
 division of cancer, 494.
 encanthis, 530.
 encephaloid cancer, 495.
 of eyeball, 508.
 of eyelids, 530.
 of orbit, 526.
 epithelial cancer, 499.
 of eyelids, 530.
 of orbit, 526.
 escharotics, effects of, 547.
 fungus hæmatodes, 496.
 general considerations, 492.
 melanosis, 494, 497.
 of eyeball, 518.
 of eyelids, 530.
 of orbit, 525.
 malignant affections of eyelids, 530.
 of caruncle, 530.
 of eyeball, 508.
 of lachrymal gland, 534.
 of orbit, 525.
 origin and physiology of cancer, 503.
 propriety of operating in, 535.
 in scirrhus of eyeball, 541.
 in scirrhus of eyelids, 545.
 in scirrhus of lachrymal gland, 545.
 in encephaloid of eyeball, 539.
 in melanosis of eyeball, 541.
 in malignant tumors of orbit, 544.
 in malignant ulceration of eyelids, 545.
 scirrhus, 497.
 of eyeball, 521.
 of eyelids, 530.
 of lachrymal gland, 534.
 Meibomian ducts, obstruction of, 174.
 glands, entozoa within, 484.
- Meibomian glands, injury of, from ectropium, 168.
 Melanosis, 494, 497.
 of eyeball, 518.
 of eyelid, 530.
 of orbit, 525.
 Morgagnian cataract, 392.
 Muscles of the eyeball, insertion of, 303.
- Nævi, 208.
 cutaneous, 209.
 subcutaneous, 208.
 structure of, 209.
 development of, 210.
 mixed, 224.
 treatment of, 212.
 by pressure, 212.
 by intense cold, 213.
 by heated platinum wire, 213.
 by extirpation, 214.
 by red hot pins, 213.
 by vaccination, 215.
 by escharotics, 215.
 by irritating injections, 216.
 by ligature, 217.
 by seton, 222.
 by twisted suture, 222.
 by ligature of common carotid artery, 225.
- Necrosis accompanying caries of orbit, 203.
 Needles, 30.
 grooved, 440.
 for reclamation, 441.
 curved, 451.
 straight, 449.
- Obstruction of canaliculi, 178.
 by polypi, 182.
 of lachrymal tube, 182.
- Opacity of cornea from entropium, 144.
 from heated substances, 67.
 from trichiasis, 119.
 removed by operation, 373.
- Optic nerve, impaction of grain of shot in, 87.
 rupture of, 64.
- Orbicularis palpebrarum, action of, in entropium, 132.
- Orbit, abscess of edge, 206.
 aneurism in, 235.
 caries of, 201.
 exostosis of, 318.
 hairy tumor on, 298.
 hypertrophy of bony walls, 320.
 malignant tumors of, 544.
 tuberculous deposit around, 313.
 tumors of, 299.
 acephalocysts, 311.
 echinococci, 311.
 encysted, external to orbit, 301.
 encysted, within orbit, 308.


- Orbit, tumors of, fatty, 312.
 fibrous, 303.
 fibro-cystic, 305.
 hydatids, 311.
 oily encysted, 312.
 osteo-sarcoma, 321.
 steatomatous, 301.
- Ossification of choroid membrane, 87.
 of cornea, 87.
 of hyaloid membrane, 87.
 of lens, 86.
 of retina, 87.
 of sclerotica, 87.
 of vitreous humor, 87.
 ocular fascia, 303.
- Polypi in canaliculi, 182.
 on conjunctiva, 284.
 in lachrymal tube, 194.
 in nasal cavities, 344.
- Probe for puncta and canaliculi, 177.
 for lachrymal tube, 196.
- Prolapse of iris, 56, 435.
 reduction of, 56, 57.
 of choroid and retina from a blow, 49.
- Protrusion of eyeball, 321.
 from abscess within ocular sheath, 339.
 from abscess within orbit, 340.
 from anæmia, 332.
 from causes within orbit, 331.
 from causes external to orbit, 342.
 from chronic hydrocephalus, 343.
 from disease of optic nerve, 342.
 from disease of antrum of Highmore, 343.
 from exostosis in temporal fossa, 343.
 from nasal polypi, 344.
 from obstruction of nasal duct, 344.
 from periostitis of orbit, 336.
 from pus within frontal sinus, 343.
 from rheumatic inflammation of ocular sheath, 336.
 from unknown causes, 347.
- Pterygium, 288.
 congenital, 290.
 operation for, 291.
 pingue, 293.
- Ptosis, 102.
 congenital, 104.
 from want of power in levator palpebræ, 105.
 from hypertrophy of skin and cellular tissue, 106.
 from falling of the brow, 108.
 from a surgical operation, 62.
 operation for, 105.
- Puncta, affections of, 177.
 congenital defect of, 181.
 contraction and obstruction of, 178.
 destruction of, 181.
- Puncta, displacement of, by ectropium, 180.
 artificial dilatation of, 198.
- Pupil, artificial, 358, 549.
 closure of, 433.
 from inflammation, or prolapse of iris, 561, 563.
 by lymph, 572.
 partial, by lymph, 575.
 in combination with lenticular cataract, 587.
 diminution of, from prolapse of iris, or other causes, 577.
 obscurity of, caused by partial opacity of cornea, 570.
 size of, 555.
 coloration of, 402.
 dilatation and contraction of, 399.
 dilatation of, 461.
 permanent, 461.
 dilated and motionless, 400.
 effects on, from prolapse of iris, 56.
 irregularity of, after extraction, 437.
 natural size of, 399.
- Pus, evacuation of, from anterior chamber of eye, 46.
 from cornea, 46.
 in anterior chambers of eye, 46.
 in frontal sinuses, 343.
 infiltration of cornea with, 432.
- Retina, concussion of, 35.
 discoloration of, 514.
 idiopathic inflammation of, 37.
 ossification of, 87.
 prolapse of, from blow, 49.
- Rupture of eyeball, 48.
- Scalds, 32.
- Scalpel, 27.
- Scirrhus, 497.
 of eyeball, 521, 523.
 of eyelids, 531.
 of lachrymal glands, 534.
- Scissors, curved, 31.
 iris, 557.
 iris canula, 560.
 straight, 247.
- Sclerotica, discoloration and vascularity of, 401.
 ossification of, 87.
 penetration of, by foreign body, 77.
 staphyloma of, 358.
 tumors of, 275.
 rupture of, 48.
- Soft cataract, 390.
- Spectacles, 475.
- Squint, 247.
 external, 271.
 internal, 249.
 double, 251.

- Squint, evacuation of vitreous humor after subconjunctival operation for, 267.
 operation for, 259.
 protrusion of eyeball following operation, 269.
 subconjunctival operation, 267.
 permanency of operation for, 273.
- Staphyloma of the cornea, 350.
 of the cornea and sclerotica, 361.
 of the sclerotica, 358.
 operation for, 353.
 partial, 357.
 sympathetic inflammation resulting from, 355.
- Steatomatous tumor, 278.
- Steatozoon folliculorum, 484.
- Strabismus, 247.
- Stye, 275.
- Style for obstructed lachrymal tube, 186.
- Supra-orbital nerve, division of, 64.
- Suppuration of eyeball, 47.
- Symblepharon, 90.
 congenital, 90.
 from action of quick lime, 91.
 operation for, 94.
 by M. Amussat, 95.
 by M. Ammon, 95.
 by M. Petrequin, 95.
 by M. Dieffenbach, 96.
- Syringe for obstructed lachrymal tube, 190.
- Tarsal tumors, 280.
 treatment of, 282.
- Transplantation of cornea, 372.
 of hair, 126.
- Traumatic injuries of eye, 35.
 treatment of, 35.
 by bloodletting, 38.
 by counter-irritation, 48.
 by dilatation of pupil, 43.
 by evacuation of aqueous humor, 44.
 by local applications, 48.
 by mercury, 41.
- Tremulous iris, 401.
- Trichiasis, 110.
 causes of, 112.
 congenital, 119.
- Trichiasis, idiopathic, 113.
 operation for, 117.
 operations for, 119.
 by partial excision of cilia, 121.
 by entire excision of cilia, 123.
 by an improved method, 125.
 by removal of portion of eyelid, 120.
 treatment by cauterization, 125.
 transplantation of hair to form new cilia, 126.
- Tuberculous deposit around orbits, 313.
- Tumors, 275.
 of the conjunctiva, 284.
 of the cornea, 295.
 of the eyelids, 275.
 of the lachrymal gland, 324.
 of the orbit, 299.
 of the sclerotica, 293.
 hairy, 298.
 osteo-sarcoma, 321.
 steatomatous, 278.
 tarsal, 280.
 vesicular, 279.
- Vesicular tumor, 279.
- Vitreous humor, alterations in, affecting condition of eyeball, 401.
 discoloration of, 514.
 escape of, from injury to eyeball, 49.
 evacuation of, after operation for squint, 267.
 during operation for "extraction," 427.
 for the reduction of prolapsed iris, 427.
 ossification of, 87.
- Vomiting consequent on operations for "solution," 447-453.
- Warts, 276.
 of caruncle, 288.
 of conjunctiva, 284.
- Warty opacity of cornea, 297.
- Wounds, 55.
 of cornea, 55.
 of canaliculi, 61.
 of conjunctiva, 64.
 of eyelids, 60.

ERRATA.

Page 415, note, for "the space of an inch," read, the space of a line.
 Page 522, note, for, "by an operation," read, by an autopsy.





MAR 4 1954

NATIONAL LIBRARY OF MEDICINE



NLM 03206860 2