

**The dissector's guide, or, Student's companion : illustrated by numerous wood cuts, clearly exhibiting and explaining the dissection of every part of the human body / by Edward William Tuson.**

### **Contributors**

Tuson, Edward William, 1802-1865.  
Lewis, Winslow, 1799-1875.  
Lovejoy, J. W. H.  
National Library of Medicine (U.S.)

### **Publication/Creation**

Boston : Allen and Ticknor, 1833.

### **Persistent URL**

<https://wellcomecollection.org/works/rm6med3r>

### **License and attribution**

This material has been provided by This material has been provided by the National Library of Medicine (U.S.), through the Medical Heritage Library. The original may be consulted at the National Library of Medicine (U.S.) where the originals may be consulted.

This work has been identified as being free of known restrictions under copyright law, including all related and neighbouring rights and is being made available under the Creative Commons, Public Domain Mark.

You can copy, modify, distribute and perform the work, even for commercial purposes, without asking permission.

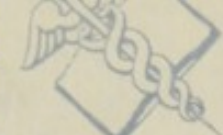**wellcome  
collection**

Wellcome Collection  
183 Euston Road  
London NW1 2BE UK  
T +44 (0)20 7611 8722  
E [library@wellcomecollection.org](mailto:library@wellcomecollection.org)  
<https://wellcomecollection.org>

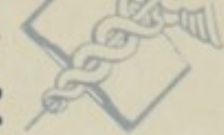QS  
T964d  
1833a



U.S. Department of



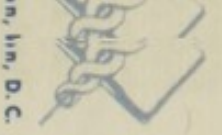Washington, D.C.



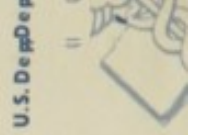U.S. Department of



Washington, D.C.



U.S. Department of

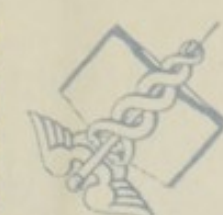

NATIONAL LIBRARY OF MEDICINE

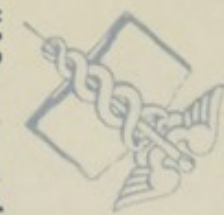NATIONAL LIBRARY OF MEDICINE

NATIONAL LIBRARY OF MEDICINE

Washington, D.C.



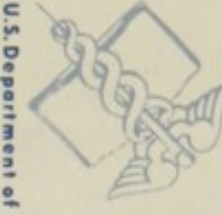U.S. Department of



Washington, D.C.



U.S. Department of



Washington, D.C.

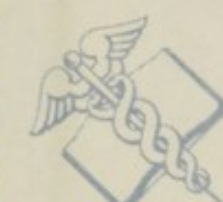

NATIONAL LIBRARY OF MEDICINE

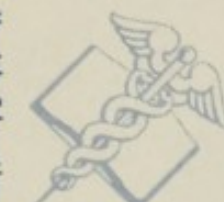NATIONAL LIBRARY OF MEDICINE

NATIONAL LIBRARY OF MEDICINE

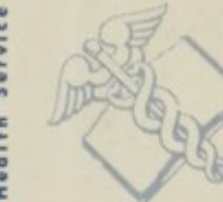Health Service



Health, Education,



Health Service



Health, Education,



Health Service

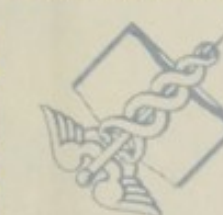

NATIONAL LIBRARY OF MEDICINE

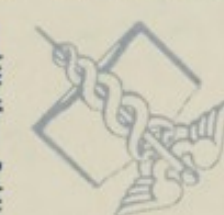NATIONAL LIBRARY OF MEDICINE

NATIONAL LIBRARY OF MEDICINE

and Welfare, Public



and Welfare, Public



and Welfare, Public



and Welfare, Public



and Welfare, Public

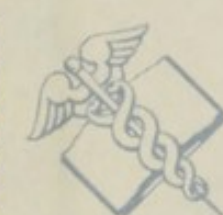

NATIONAL LIBRARY OF MEDICINE

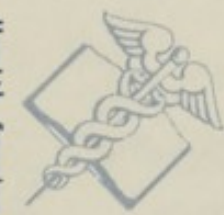NATIONAL LIBRARY OF MEDICINE

NATIONAL LIBRARY OF MEDICINE

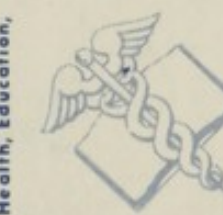Health, Education,



Health Service



Health, Education,



Health Service



Health, Education,

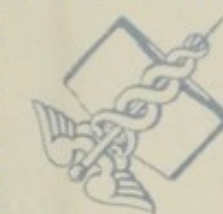

NATIONAL LIBRARY OF MEDICINE

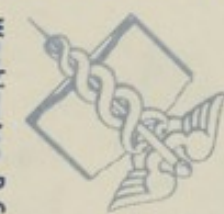NATIONAL LIBRARY OF MEDICINE

NATIONAL LIBRARY OF MEDICINE

U.S. Department of



Washington, D.C.



U.S. Department of



Washington, D.C.



U.S. Department of

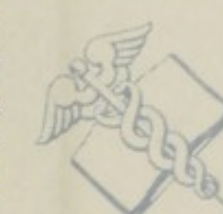

NATIONAL LIBRARY OF MEDICINE

NATIONAL LIBRARY OF MEDICINE

NATIONAL LIBRARY OF MEDICINE

Washington, D.C.



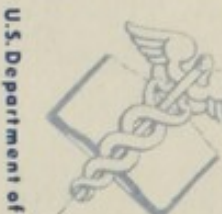U.S. Department of



Washington, D.C.



U.S. Department of



Washington, D.C.

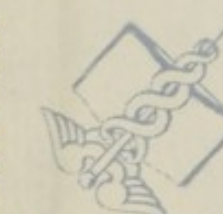

NATIONAL LIBRARY OF MEDICINE

NATIONAL LIBRARY OF MEDICINE

NATIONAL LIBRARY OF MEDICINE

Health Service



Health, Education,



Health Service



Health, Education,



Health Service



NATIONAL LIBRARY OF MEDICINE

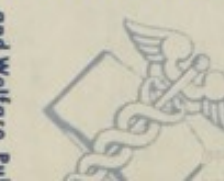NATIONAL LIBRARY OF MEDICINE

NATIONAL LIBRARY OF MEDICINE

and Welfare, Public



and Welfare, Public



and Welfare, Public



and Welfare, Public



and Welfare, Public



NATIONAL LIBRARY OF MEDICINE

NATIONAL LIBRARY OF MEDICINE

NATIONAL LIBRARY OF MEDICINE



U.S. Depa

en, D. C.

U.S. Depa

en, D. C.

MEDICINE NATIONAL LIBRARY OF MEDICINE NATIONAL LIBRARY OF MEDICINE

Washington, D. C.

U.S. Department of

Washington, D. C.

U.S. Department of

NATIONAL LIBRARY OF MEDICINE NATIONAL LIBRARY OF MEDICINE NATIONAL LIBRARY OF MEDICINE

Health Service

Health, Education,

Health Service

Health, Education,

MEDICINE NATIONAL LIBRARY OF MEDICINE NATIONAL LIBRARY OF MEDICINE

and Welfare, Public

and Welfare, Public

and Welfare, Public

and Welfare, Public

NATIONAL LIBRARY OF MEDICINE NATIONAL LIBRARY OF MEDICINE NATIONAL LIBRARY OF MEDICINE

Health, Education,

Health Service

Health, Education,

Health Service

MEDICINE NATIONAL LIBRARY OF MEDICINE NATIONAL LIBRARY OF MEDICINE

U.S. Department of

Washington, D. C.

U.S. Department of

Washington, D. C.

NATIONAL LIBRARY OF MEDICINE NATIONAL LIBRARY OF MEDICINE NATIONAL LIBRARY OF MEDICINE

Washington, D. C.

U.S. Department of

Washington, D. C.

U.S. Department of

MEDICINE NATIONAL LIBRARY OF MEDICINE NATIONAL LIBRARY OF MEDICINE

Health Service

Health, Education,

Health Service

Health, Education,


NATIONAL LIBRARY OF MEDICINE NATIONAL LIBRARY OF MEDICINE NATIONAL LIBRARY OF MEDICINE

and Welfare, Public

and Welfare, Pu

and Welfare, Public

and Welfare, Public



THE

DISSECTOR'S GUIDE;

OR

*W. H. Lovejoy*  
STUDENT'S COMPANION.

ILLUSTRATED BY NUMEROUS WOOD CUTS,

CLEARLY EXHIBITING AND EXPLAINING

THE DISSECTION

OF

EVERY PART OF THE HUMAN BODY.

By EDWARD WILLIAM TUSON, F. L. S.

MEMBER OF THE ROYAL COLLEGE OF SURGEONS IN LONDON, LECTURER OF ANATOMY  
AND PHYSIOLOGY AT THE LITTLE-WINDMILL-STREET SCHOOL.

FIRST AMERICAN EDITION, WITH ADDITIONS,

By WINSLOW LEWIS, JR. M. D.

DEMONSTRATOR OF ANATOMY TO THE MEDICAL SCHOOL AT HARVARD UNIVERSITY.


BOSTON:  
ALLEN AND TICKNOR.  
1833.

MAY 4 - 1901  
172799

QS  
T964L  
1833a

Entered according to Act of Congress, in the year 1833,  
By ALLEN AND TICKNOR,  
In the Clerk's Office of the District Court of Massachusetts.

PRINTED BY TUTTLE AND WEEKS,  
No. 8, School Street.



## DEDICATION.

TO THE

STUDENTS ATTENDING THE MEDICAL SCHOOLS.

GENTLEMEN, —

As the following pages have been compiled for the purpose of facilitating the study of Anatomy, and as they are more particularly calculated to come under your notice, during the period of your attendance at the Medical Schools, permit me to dedicate this work to you. I do so, not only to return you my public thanks for the very flattering manner in which you have been pleased to receive my former publications, but also as a public mark of esteem, which, believe me, I shall ever feel; and should I be able, at any time, to lessen your labors, and accelerate or assist your studies, by making the intricate path of Anatomy more clear, be assured that I shall ever be ready and willing to use my exertions in your behalf.



To the gentlemen who attend the School in Little Windmill Street, I wish to say, in addition, that I cannot allow this opportunity to pass, without expressing my most sincere and grateful acknowledgments for the very kind approbation that they have at all times evinced towards me ; and should my present exertions tend in any way to promote their studies, and prove useful to the Students attending the other Schools, the object I have in view will be fully accomplished.

I am, Gentlemen,

Your most obedient and humble servant,

EDWARD WILLIAM TUSON.

RUSSELL PLACE, FITZROY SQUARE,  
March 26th, 1832.

## PREFACE OF THE AMERICAN EDITION.

IN presenting the work of Mr TUSON to those commencing the labors of practical Anatomy, the Editor has thought that the way would be rendered less intricate by the simplified descriptions, accompanied by the diagrams, which are given in this publication.— Mr TUSON is reputably known as a skilful teacher of Anatomy, and as the Author of a work on Myology, the most ingenious ever given to the public. He is a competent judge of what is wanted in the dissecting rooms, and has endeavored to supply the deficiency by this work. The diagrams do not profess to show the exact appearance of the several parts, but are done in a rough outline, to convey to the mind of the student their relative positions and connexions.

W. L., JR.

PREFACE TO THE AMERICAN EDITION

In presenting the work of the French to their countrymen the Editor of the French Edition, M. Lacroix, has thought that the work would be rendered less interesting by the addition of a preface, and has accordingly omitted it. The Editor of the American Edition, however, has thought it necessary to add a preface, and has endeavored to supply the deficiencies of the work. The diagrams are not printed in the original, but are drawn by the Editor, to convey to the mind of the student their relative positions and connections.

W. L. G.

## INTRODUCTION.

THE study of Anatomy presents almost insurmountable difficulties to those who attempt it without method. And in the practical part, how many soon quit this most necessary attainment, from an ignorance of a few simple rules, which when attained, the investigation is satisfactory, profitable, and easy. Some of these which are considered to be of value to the beginner, will be given in this place. The manner of using the scalpel and forceps, and of dissecting the various structures of the body, cannot be *well* conveyed by books. These are *best* explained in the anatomical room by the demonstrator.

### DISSECTING INSTRUMENTS,

Should consist of *scalpels* of different forms, and varied according to the textures which are to be demonstrated. A knife for Myology should be rounded at the extremity and large, but for the dissection of the blood-vessels and nerves, it should be delicate and more pointed. — The *forceps* should be rather larger than those usually manufactured here. There is no necessity for a small pair in dissection. They should be long enough for the head to rest on the metacarpal bone of the first finger. — The *scissors* should

cut well at the point, and be of a medium size. The *hooks* usually found in dissecting cases are not so good as those connected by chains, which are very serviceable.—The *blow-pipe* usually completes the case, but it is well to have a few *curved needles*, which are to be used after each dissection to bring the integuments over the part, and probes of various sizes. Each student should be provided with a sponge and towel, and a drawer or box, to contain the articles to be used: All instruments should be well cleaned and put in good order after use. Cleanliness is necessary in order to a neat dissection, and the strictest regard should be had to this, among those who combine together for anatomical practice.

#### SELECTION OF SUBJECTS.

For the dissection of the muscles, a body is to be preferred which is fully developed in this particular; not corpulent, lean or œdematous; of one who has died suddenly is best, and of an adult age, and a male. For making preparations, lean, emaciated subjects are preferable. Dropsical bodies show the lymphatic system more fully and distinctly. The young are the proper subjects for the investigation of the nerves.

As but a *portion* of the same subject can be *well* dissected by one individual, it is customary in Anatomical Schools, to divide it into five parts, viz. 1st. The head and neck. 2d and 3d. The superior extremities, which include the thorax, its contents, and the diaphragm. 4th and 5th. The inferior extremities to which belong the pelvic and abdominal viscera. Those viscera which cannot be advantageously divided, as the heart, stomach, bladder, organs of generation, &c. are usually appropriated by lot, as also the aorta and such parts.

## DISSECTION OF MUSCLES, WITH GENERAL RULES.

The muscles are the parts which are first dissected by those commencing practical Anatomy, and to do this well, requires considerable adroitness and practice. There are some which are very intimately connected with the skin, as those of the lips, nose, &c. To expose these is difficult, as their fibres are very indistinct and confounded with the integuments. — The student should, therefore, not be disappointed if he fails in his first attempts. But the large, long and thick muscles are more easily shown. — Muscles, being composed of nearly parallel fibres, the manner of displaying them is naturally indicated. The integuments are to be divided until the muscular fibres are exposed, the knife always following the direction of these fibres, detaching all the cellular tissue with the skin. Without this precaution, shreds would remain on various points of the surface of the muscle, and the difference between the color of the fleshy fibres and the cellular membrane, would give a very disagreeable, and rough aspect to the preparation. The evil cannot be remedied when once committed, for by removing these portions of membrane, the muscle has a mangled appearance, and its regularity is destroyed.

The skin being divided, the hand is to be used in preference to the forceps. By doing this, the skin, and with it the cellular membrane, can be drawn from the muscle in a more uniform manner, and to a greater extent. The thumb is then used with advantage in pinching up the membrane.

The part on which a muscle is to be dissected, should always be placed in such a situation as to produce a forcible extension of that muscle. This not only much facilitates the dissection, but impresses on the mind its direction and use.

No more of the skin should be raised than is necessary to exhibit the part to be shown, and after each dissection, it should be covered again with the integuments, to prevent the drying, which soon takes place, if left exposed to the air. It is best to defer shaving the head and other parts, where there is hair, until it is wished to dissect the subjacent muscles, as the cuticle on doing this immediately dries, becomes almost of a horny hardness, which renders the dissection unpleasant and almost impracticable.

After having exposed an external layer of muscles, the deeper seated should be demonstrated in the same manner, always raising the fat and cellular substance from them with the muscle already studied and dissected.

A muscle being dissected, and having no further use for it in its original situation, it is better, if a long one, to divide it in its middle, and thus to preserve the two points of its origin and insertion. The large muscles of the trunk it is advisable to detach from their insertion. But general rules cannot be given which will extend to such varieties as occur in the removing of muscles. But it may be well to observe that in removing muscles, they are not to be divided according to the direction of their fibres, but following the course of the fibres of those muscles which are beneath.

The manner of holding the scalpel when dissecting muscles or aponeuroses, is only to be learnt in the dissecting room to advantage. Finally, in the dissection of the muscles, use the scalpel in a free and prompt manner. Make the strokes long and bold, using the little finger as a *point d'appui* to steady the movement of the hand. By practice this is soon acquired, and it is a necessary acquisition not only to the dissector but to the surgeon.

To acquire a dexterity in the application of surgical

instruments, students should accustom themselves to practice those operations which may be done upon the body without mutilating it, or spoiling it for injection, as the introduction of the male and female catheters, the use of the probang, manner of plugging the nostrils, cutting off small portions of the conjunctiva, passing a probe into the ductus ad nasum, both from without through the puncta lacrymalia, and from within through the nostrils, &c. &c.

As Anatomy is the only basis of Surgery, the *relation of parts* should be strictly attended to during every dissection, and each region should be studied and examined in reference to surgical operations connected with it. The student of practical Anatomy should always bear in mind that the end and aim of his labors, is to deduce from them just practical conclusions.

The study of practical Anatomy, is not necessarily so pernicious to health, as has been commonly imagined;\* but there are precautions which must be taken to obviate the bad tendency which the air of a dissecting room would have upon the body.

There should never be more fire in anatomical rooms, than is necessary to preserve the subjects from being frozen. The windows should be open during the dissection. The student should be dressed warm, and the best garment is one made of baize fitting close to the body. The sleeves may be made of India rubber cloth, tight around the wrist. The garments ordinarily worn should never be brought

\* Dr Warren has published in the Boston Medical and Surgical Journal, Volume II. some very interesting observations on the influence of decomposing animal matter, and cites his personal experience on the subject of the foul air of the dissecting room, in 1829. The Editor can also vouch for the statement, suffering no deviation from health, although exposed to its *immediate* influence for a long time.



into a dissecting room. Parts which have been dissected should be immediately removed. Attention must be paid to the diet: the food should be nutritious and generous, and it is proper to take a small quantity of wine, at a time when the body and mind is debilitated by long sitting at lectures and dissections; but avoid all excess of fluids or solids. Temperance is strictly necessary. Wounds received during dissection should not be neglected. If a simple abrasion, it should be immediately covered. If pricked, the liquid muriate of ammonia, or caustic potass are recommended to be applied as cauteries. These are the early measures to be pursued, but after absorption has taken place, a different course must be practised, for a knowledge of which, the student is referred to "Parsons's Anatomical Preparations," where it is fully stated.

As works proper for the dissecting room, "Edwards's Manual of Surgical Anatomy," "Shaw's Manual," "Maygrier's Manual of the Anatomist," "Velpeau's Anatomy of Regions," and "Parsons on making Anatomical Preparations," are among the best, and are those which will be found the most useful in facilitating the exertions of the young Anatomist.

WINSLOW LEWIS, JR.

*August, 1833.*

# THE DISSECTOR'S GUIDE;

OR

## STUDENT'S COMPANION.

---

THE human body is divided into the head and neck; the two superior extremities; the trunk, comprising the thorax and the abdomen; and the two inferior extremities. In speaking of the relative position of any part, the dissector should bear in mind that he is to suppose a line (called the median line) drawn down the body, from the centre of the frontal bone, in a perpendicular direction. Every part that is placed nearer (than another) to this line, is termed internal, and if farther from the line, external; parts placed nearer the skin are called anterior or superficial, and if farther from the skin, deep-seated or posterior.\* By bearing this in his recollection, little difficulty will be experienced by the student in ascertaining the proper seat or position of each part. As I have been in the habit of recommending the tyro to commence his labor in the dissecting-room upon the inferior extremity, conceiving it easier than the other parts, I have been induced to begin the following pages by describing the anatomy of the thigh and leg, which has been subdivided into five dissections, besides that of the joints.

### DISSECTION OF THE ANTERIOR PART OF THE THIGH.

In the dissection of the thigh, the limb may be slightly bent, and the foot turned outwards. An incision is to be

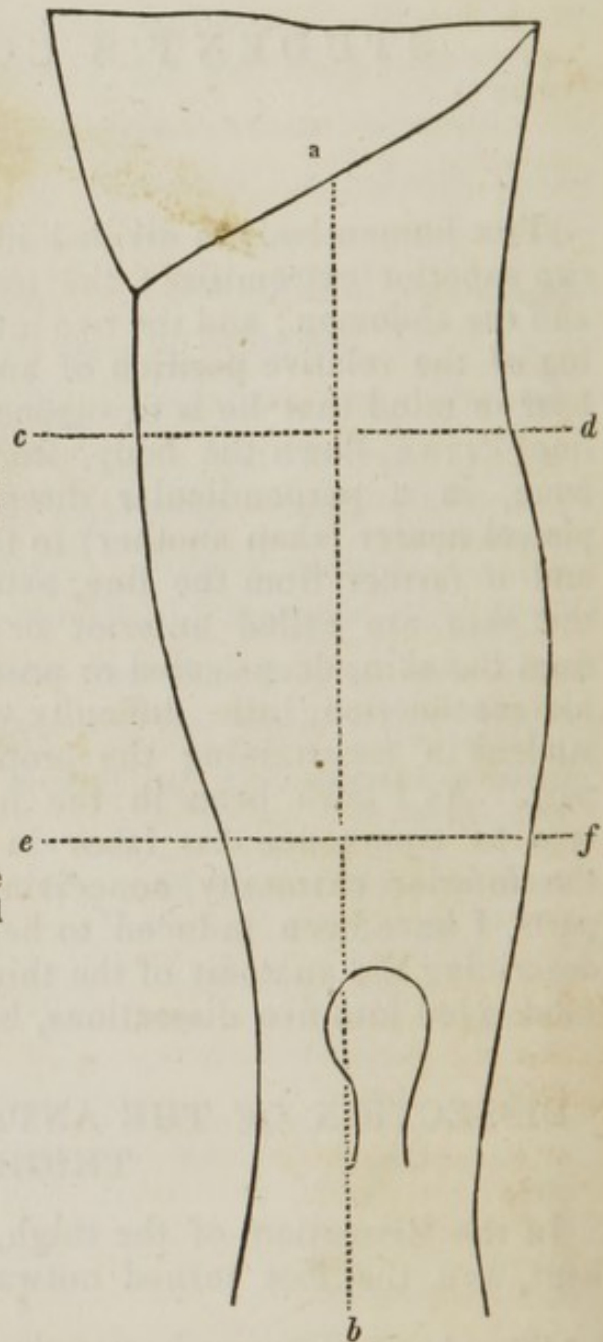
\* When describing the superior extremities, the palm of the hand is supposed to present forwards, and the thumb outwards. It is also necessary to add that the terms *superior* and *inferior* refer to the body in an erect position. Barclay has introduced the better terms *atlantal* and *sacral* instead of the above; *sternal* and *dorsal* for *anterior* and *posterior*, and *dermal* and *central* for *superficial* and *deep seated*.

made, from the centre of Poupart's ligament to the under part of the patella; a second incision may be made about the under part of the upper third of the thigh, in a transverse direction; and to facilitate the reflection of the skin, a third may be made at the upper part of the lower third of the thigh. These incisions should be made through the skin only. The incisions are pointed out in the following diagram.

*ab.* The first incision, extending from the centre of Poupart's ligament to the under part of the patella.

*cd.* The second incision, at the under part of the upper third of the thigh.

*ef.* The third incision, at the lower part of the middle third of the thigh.



The dissection will be greatly facilitated by reflecting only a small portion of the skin at a time, when the cellular substance beneath may be removed, and the parts brought into

sight. By following this rule, the dissector will find the parts keep moist, and consequently easier to dissect.

The integuments being reflected, the present dissection will be brought into view. The superficial fascia is removed, as it will be more particularly shown and described in the anatomy of femoral hernia.

*a.* The external cutaneous nerve.

*b.* The cutaneous branches of the anterior crural nerve.

*c.* One of the inguinal lymphatic glands.

*d.* The vena saphæna major.

*e.* The iliac portion of the fascia lata, forming

*f.* The falciform process, under which the saphæna vein is seen to pass.

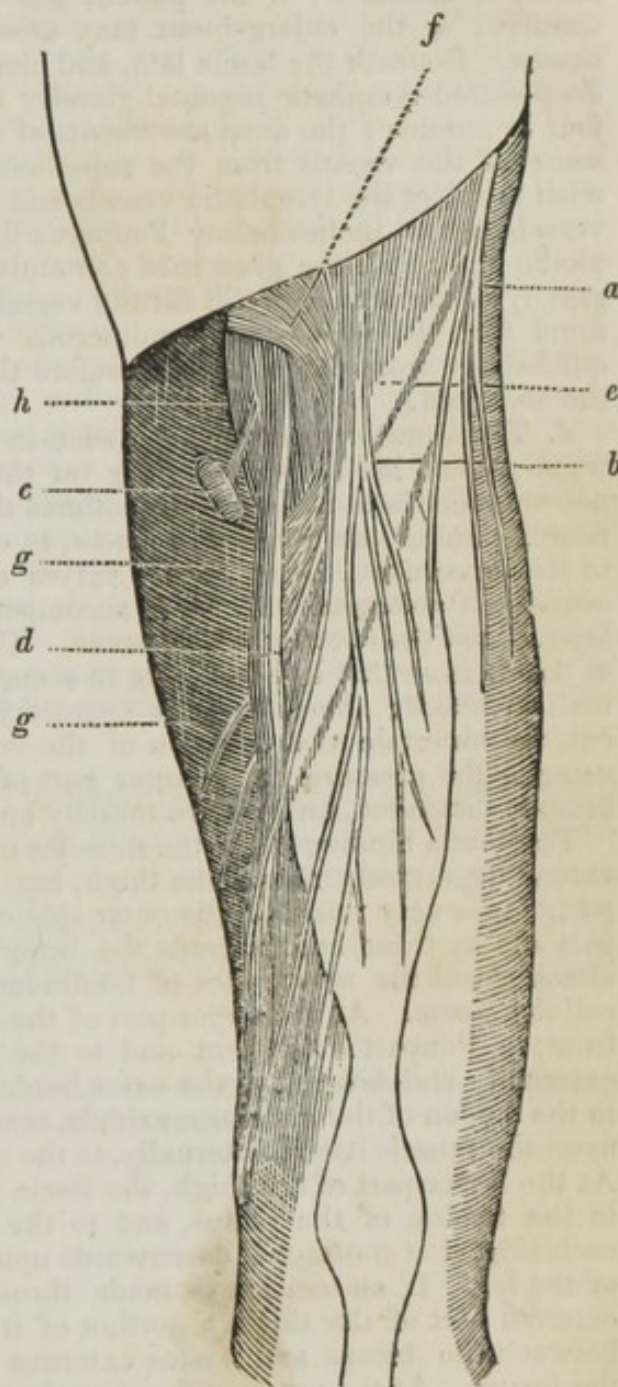
*gg.* The public part of the fascia lata, forming

*h.* A small semilunar fold, opposed to the falciform process.

*a.* The external cutaneous nerve is formed by branches of the last dorsal and first lumbar nerves, which unite between the psoas magnus and quadratus lumborum. The nerve then descends, running under Poupart's ligament (sometimes over it) near the anterior superior spinous process of the ilium, and is distributed upon the skin and fascia on the outer part of the thigh.

*b.* The cutaneous branches of the anterior crural nerve pierce the fascia, and are distributed upon the integuments and fascia, as low as the patella.

*c.* The superficial lymphatic glands are brought into view in this dissection, (one, however, is only seen in the drawing). They are from eight to ten in number. Five or six of them are placed parallel to Poupart's ligament, some above, others below it, embedded in the superficial fascia; two or three are situated lower



down in the groin, near the termination of the saphæna vein; they are larger than the former; through the conglobate inguinal glands the superficial absorbent vessels of the lower extremity pass, also those from the external parts of generation, parities of the abdomen, nates, and verge of the anus. Therefore, should one of these glands be enlarged, we are to inquire the cause, before we attempt to apply our remedy. We are to ascertain if there be an ulcer, wound, or scratch upon the leg, nates, or abdomen; if the patient has piles, or if there is or has been chancre; as the enlargement may arise from these several and other causes. Beneath the fascia lata, and close to the femoral vessels, are the deep-seated lymphatic inguinal glands; they are small, and only three or four in number; the deep absorbents of the limb pass through these, also some of the vessels from the superficial glands. Should the dissector wish to inject the lymphatic vessels and glands, let him pierce one of the vessels, a few inches below Poupart's ligament, and introduce the lymphatic pipe, with the glass tube containing quicksilver, when the specific gravity of the mercury will fill the vessels and glands. He must bear in mind that the vessels have numerous valves, which will prevent the quicksilver from descending, therefore the tube must be pointed towards the abdomen.

*d.* The vena saphæna major is seen in this dissection passing up at the inner part of the knee, ascending on the fascia, receiving several cutaneous branches in its course, sometimes the vena saphæna minor; finally, running under the falciform process, to enter the femoral vein, irregular in its appearance, owing to the valves at its inner surface, which form occasional enlargements: it is accompanied by some of the cutaneous branches of the anterior crural nerve. The vein often runs in the course of the incision that is to be made in securing the femoral artery for popliteal aneurism; therefore it is necessary that, before we make our first cut, we ascertain the situation of the vein, by applying our hand, and using slight pressure at the inner part of the thigh, when the vein will become distended, and we are thereby enabled to avoid wounding it.

The fascia binding down the muscles of the thigh is termed fascia lata, extending entirely round the thigh, but not of equal thickness in every part. It is very thick on the outer side of the thigh, less so at the back part and in front, and towards the inner side it becomes so thin that it almost loses the appearance of tendinous structure, resembling common cellular tissue. At the upper part of the thigh, the fascia is attached; in front, to Poupart's ligament and to the anterior edge of the os pubis; externally and behind, to the outer border of the crista of the ilium, and to the tendon of the glutæus maximus, some of the fibres gradually arising upon the muscle itself; internally, to the ramus of the ischium and pubes. At the lower part of the thigh, the fascia has, in front, a firm attachment to the tendon of the rectus, and to the vasti muscles; behind and on each side, it is continued downwards upon the knee joint into the fascia of the leg. If an incision is made through the fascia at the lower and external part of the thigh, a portion of it will be discovered penetrating between the biceps and vastus externus muscles to the external line of the femur. At the upper and external part of the thigh, a portion of the fascia penetrates beneath the tensor vaginæ muscle, and is continued to the capsular ligament of the hip joint. A portion of the fascia also penetrates beneath the sartorius muscle.

There are small apertures in the fascia lata, for the passage of vessels and nerves; and just below Poupart's ligament, there is a considerable

interval in the fascia, where the vena saphæna major joins the femoral vein. This interval is formed by the division of the fascia into two portions, which have distinct attachments; one to Poupart's ligament, the other to the anterior edge of the os pubis, *g g*. That portion of the fascia attached to Poupart's ligament is termed the iliac portion, and presents a crescent-shaped edge, the concavity of which is towards the opposite limb; this is denominated the falciform process of the fascia, *f*. This semilunar edge may be traced downwards, into a second semilunar edge, *h*, the concavity of which is upwards. The vena saphæna ascends over this second semilunar edge of the fascia, just before its termination in the femoral vein. These semilunar edges of the fascia are occasionally distinct, separated into two layers, with fat interposed. The internal part of the fascia lata, termed the pubic portion, is attached to the transverse ramus of the pubis, and the pubic portion of Poupart's ligament. It descends obliquely outwards, crossing the adductor muscles and pectinalis, passes under the femoral vessels, to be attached to the inner part of the linea aspera, as low as the insertion of the adductor magnus.

Between the margin of the falciform process and the pubic part of the fascia lata, there is a thin membrane, perforated by numerous small nerves and vessels, termed the cribriform fascia; it is connected on either side to the iliac and pubic portions of the fascia lata, and extends from the saphæna vein to Poupart's ligament. The cribriform fascia must be removed before the falciform process can be rendered distinct.

Observe the great degree of density of the fascia lata, and the several processes that it forms or sends off between the muscles; \* should inflammatory action be set up beneath it, and suppuration take place, there can be no exit for the matter; therefore we must make a free incision through the fascia, to allow the escape of the suppuration, or otherwise the matter will burrow between the muscles, and even pass down as low as the bone itself.

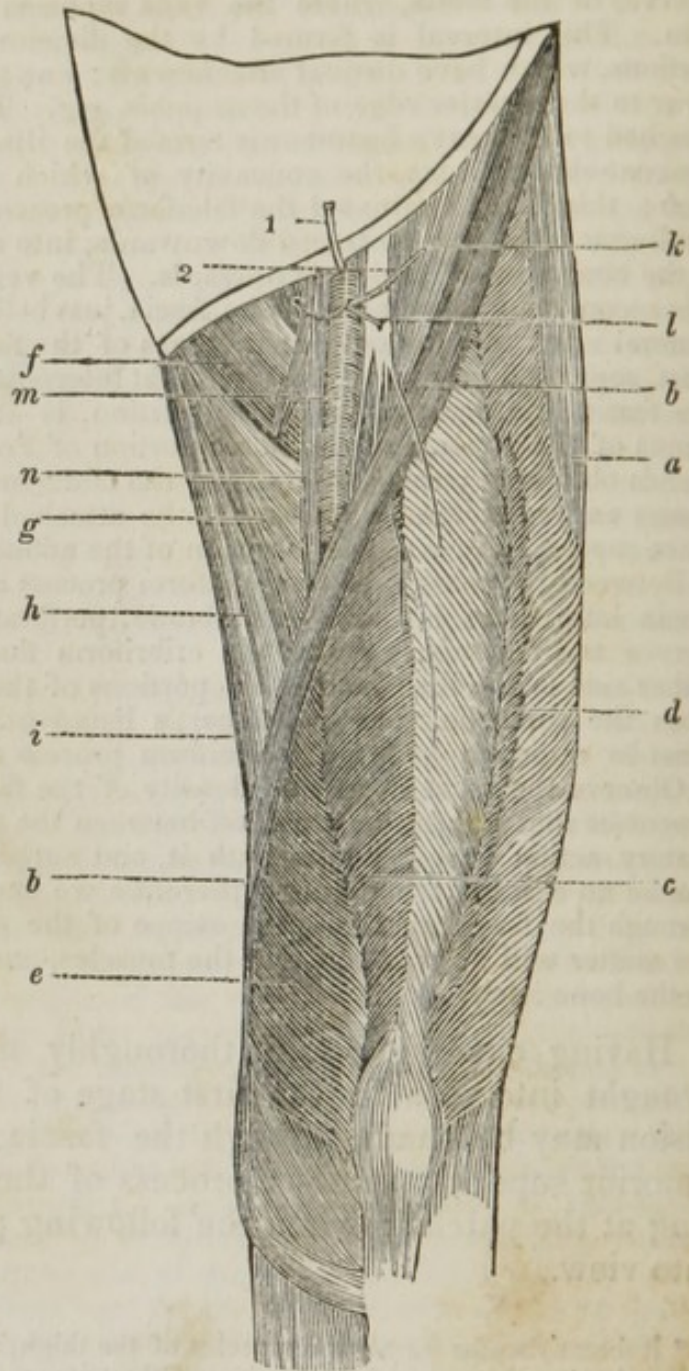
Having examined and thoroughly understood the parts brought into view in the first stage of the dissection, an incision may be made through the fascia, commencing at the anterior superior spinous process of the ilium, and terminating at the patella; when the following parts will be brought into view.

\* It forms sheaths for all the muscles of the thigh, and for the vessels after the femoral artery has passed the tendon of the triceps.

- a.* The tensor vaginae femoris.  
*b.* The sartorius.  
*c.* The rectus femoris.  
*d.* The vastus externus.  
*e.* The vastus internus.  
*f.* The pectinalis.  
*g.* The adductor longus.  
*h.* The adductor magnus.  
*i.* The gracilis.  
*k.* Iliacus internus.  
*l.* The anterior crural nerve.  
*m.* The femoral artery.  
*n.* The femoral vein.  
 1. The external epigastric artery.  
 2. The external circumflexa ilii; also the external pudic, and inguinal branches to the inguinal glands are seen to be given off from the inguinal or femoral artery.

*a.* The tensor vaginae femoris *arises* by a narrow, tendinous, and fleshy beginning, from the external part of the anterior spinous process of the ilium; passes downwards, and a little backwards, forming a thick fleshy belly, inclosed in a doubling of the aponeurosis or vagina of the thigh, to be *inserted* a little below the trochanter major, into the inner surface of the aponeurosis, covering the outside of the thigh. *Action*,—to stretch the aponeurosis, and to assist in the abduction of the thigh, and in its rotation inwards.\*

*b.* The sartorius *arises* tendinous, from the anterior superior spinous process of the ilium; soon becomes fleshy, runs obliquely downwards over the muscles situated upon the fore and inner side of the thigh, and is the longest muscle of the body, to be *inserted*, by a broad and thin tendon, into the inner side of the tibia, near the inferior part of its tubercle. *Action*,—to bend the knee, and bring one leg obliquely inwards across the other.



\* When dissecting off the fascia of the thigh, it is better to leave a strip of it as wide as the tensor vaginae femoris connected with this, its peculiar muscle.

c. The rectus femoris *arises* fleshy, from the anterior inferior spinous process of the ilium, and tendinous from the dorsum of that bone, a little above the acetabulum, by a triangular origin: runs down over the anterior part of the neck of the femur, in its passage along the fore part of the thigh, becomes gradually larger as far down as its middle, after which it decreases towards its lower extremity. In the middle of the muscle there is a longitudinal tendinous line, from which the muscular fibres run off like the plumage of a feather; the tendon itself being more conspicuous behind, where it passes over the cruralis, *inserted*, tendinous, into the upper part of the patella. There are several bursæ mucosæ between this muscle and the cruralis. *Action*,—to extend the leg.

d. The vastus externus *arises* broad, tendinous, and fleshy, from the outer part of the roof of the trochanter major. Its origin is continued from the trochanter, along the whole outer side of the linea aspera, to near the external condyle of the femur, by fleshy fibres, which run obliquely forwards to a middle tendon, where they terminate, to be *inserted* into the upper and outer part of the patella, at the edge of the tendon of the rectus, with which it is connected. Part of it ends in an aponeurosis, which is fixed to the head of the tibia, and afterwards is continued to the leg. *Action*,—to extend the leg.

e. The vastus internus *arises* tendinous and fleshy, from between the fore part of the femur and root of the trochanter minor. The origin is also continued along the whole inside of the linea aspera, by fibres running obliquely forwards and downwards, to be *inserted*, tendinous, at the side of the cruralis with which it is connected, into the upper and inner edge of the patella, continuing fleshy, lower than the vastus externus. Part of it likewise ends in an aponeurosis, which is fixed to the upper part of the tibia, and afterwards is continued to the leg. *Action*,—to assist the former muscle in extending the leg; when the patella, fixed to the tubercle of the tibia by a strong ligament, supplies the office of a pulley.

f. The pectinalis *arises* broad and fleshy, from the upper and fore part of the os pubis, immediately above the foramen thyroideum. It runs downwards and outwards at the inner side of the psoas magnus, to be *inserted*, by a flat and short tendon, into the linea aspera of the femur, a little below the trochanter minor. *Action*,—to pull the thigh upwards and inwards, and to give it, and of course the foot, a degree of rotation outwards.

g. The adductor longus *arises* by a strong roundish tendon, from the upper and fore part of the os pubis, and ligament of the synchondrosis, at the inner side of the pectinalis; it runs downwards and outwards, to be *inserted* by a broad flat tendon into the middle of the linea aspera.

h. The adductor magnus *arises* from the side of the symphysis pubis, a little lower than the former. The origin is continued downwards from the crus and tuberosity of the os ischium. The fibres run outwards and downwards, spreading out wide, and forming a large muscle, to be *inserted* into the whole length of the linea aspera; the under part of the muscle, extending along the ridge which leads to the inner condyle of the femur. It is also fixed, by a roundish tendon, into the upper part of the condyle, a little above which the femoral artery, taking a spiral turn towards the ham, passes between the tendon of this muscle and the bone. *Action*,—to bring the thigh inwards and upwards, according to the different directions of the fibres, and to assist a little in rolling it outwards.



*i.* The *gracilis* arises by a thin tendon, from the os pubis, near the symphysis; soon becoming fleshy, and descending at the inside of the thigh, to be inserted, tendinous, into the tibia, under the sartorius. *Action*,—to assist the sartorius in making the full flexion of the knee, after it has been bent to a certain degree by the flexors on the back part of the thigh.

*k.* The *iliacus internus* (this muscle occupies the whole of the cavity of the ilium,) arises from the inner margin of the crista ilii, nearly in its whole length from the anterior superior spinous process, and from the concave surface of the bone, descends under Poupart's ligament, unites with the tendon of the *psoas magnus*, which is common to the two muscles, and descends upon the anterior part of the capsular ligaments of the hip joint, to be inserted into the trochanter minor of the femur. *Action*,—to assist the *psoas magnus*. An aponeurosis, termed the *fascia iliaca*, covers the *iliacus internus* and adjacent parts of the *psoas magnus*.

Observe the relative position of the anterior crural nerve, in respect to the femoral artery; on its outer side, nearer the anterior superior spinous process, deeper seated, being embedded in the muscular fibres of the *iliacus internus*, and about half an inch from the artery; the femoral artery between the nerve and vein lying upon the common union of the *iliacus internus* and *psoas magnus*. This artery, as soon as it passes beneath Poupart's ligament, sends off the external epigastric artery, the external circumflexa ilii, the external pudic, and the inguinal branches to the glands. The femoral vein, or continuation of the popliteal, is seen to ascend first upon the posterior part of the artery, then on the inner side, and in its course up the thigh, receiving the deep-seated veins accompanying the arteries, and the *vena saphæna major*. Beneath Poupart's ligament the vein and artery are contained in the same sheath, which is formed anteriorly by the *fascia transversalis*, and behind by the *fascia iliaca*; the union of these two fasciæ being in the shape of a funnel, is therefore termed *fascia infundibuliformis*, or crural sheath, which is more particularly described in the anatomy of femoral hernia.

The dissection may be continued by reflecting the *sartorius*, *rectus*, *adductor longus*, and *pectinalis*, when the whole course of the femoral artery will be brought into view, by drawing the *vastus internus* a little outwards, as the accompanying plate points out.

a. The tensor vaginæ femoris.

b. The sartorius reflected.

c. The rectus reflected.

d. The vastus externus.

e. The vastus internus, pulled outwards.

f. The pectinalis reflected.

g. The adductor longus reflected.

h. The adductor magnus.

i. The gracilis.

k. The iliacus internus.

l. The anterior crural nerve, sending off several muscular branches, and two branches to accompany the femoral artery, one to be distributed upon the adductor muscles, and one termed nervus saphænus major.

m. The femoral artery seen passing down the whole length of its course, situated at first upon the common union of the iliacus internus and psoas magnus, then running over the pectinalis, adductor brevis, longus, and magnus, on the inner edge of the vastus internus, and under the sartorius.

5. The arteria profunda, sending off

6. The external circumflex artery.

7. The internal circumflex artery; the profunda then terminates in three or four branches termed perforantes.

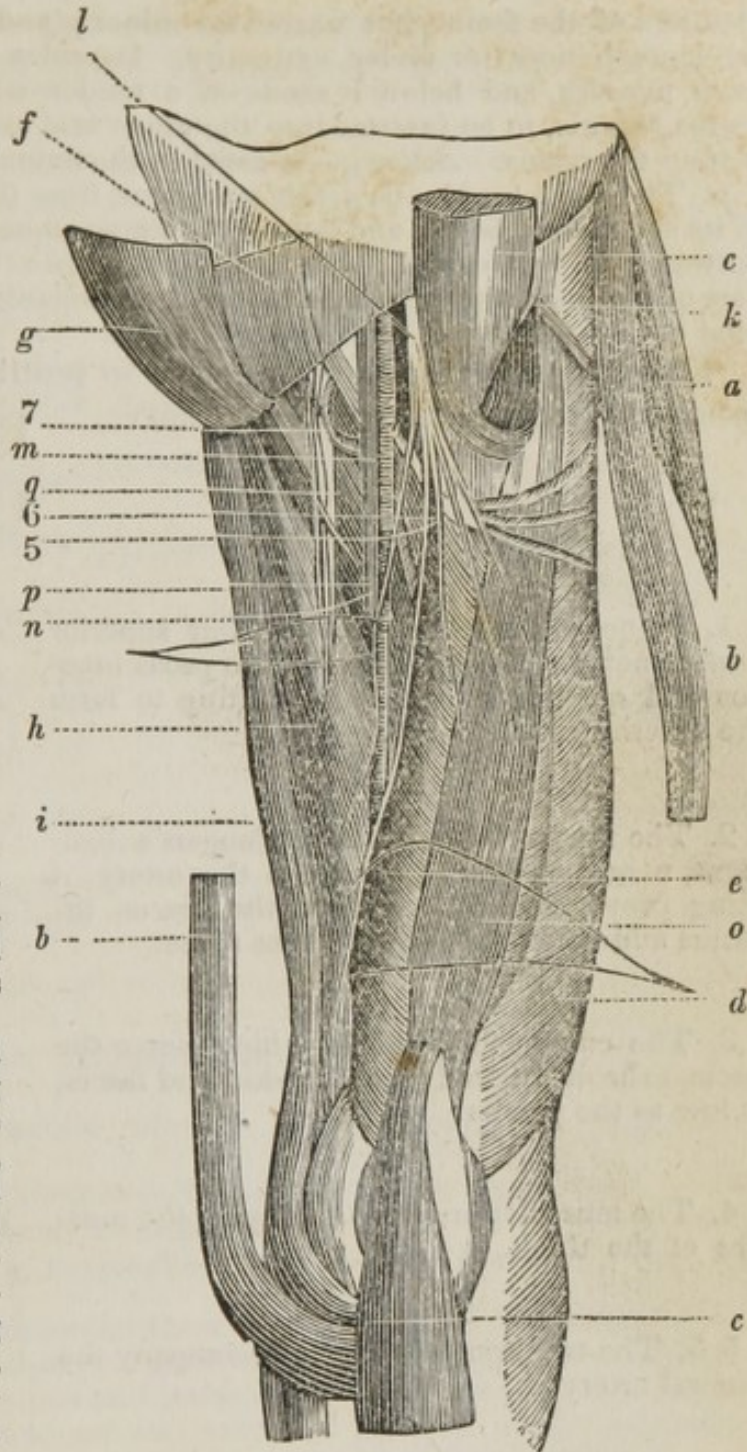
n. The femoral vein.

o. The cruralis.

p. The adductor brevis.

q. The obturator artery and nerve, descending upon the adductor brevis and magnus, beneath the pectinalis and adductor longus.

r. The cruralis, vel *crureus*, arises fleshy, from between the two tro-



chanters of the femur, but nearer the minor; and from the fore part of the bone to near its under extremity. Its sides are connected to both vasti muscles, and below it sends off a tendon which joins that of the rectus femoris, to be *inserted* into the upper and back part of the patella, behind the rectus. *Action*,— to assist in the extension of the leg.

*p.* The adductor brevis, *arises* tendinous, from the os pubis, at the side of its symphysis, below and behind the former muscle. It runs obliquely outwards, to be *inserted* by a flat tendon into the inner and upper part of the linea aspera, a little below the trochanter minor, to the beginning of the insertion of the adductor longus.

The present diagram is intended to point out the origin and branches of the anterior crural nerve.

1. Branches from the three or four superior lumbar nerves passing between the psoas magnus and quadratus lumborum, uniting to form the anterior crural nerve.

2. The nerve running under Poupart's ligament, near the ilium and next to the artery, it being previously situated upon the iliacus internus and under the fascia of that name.

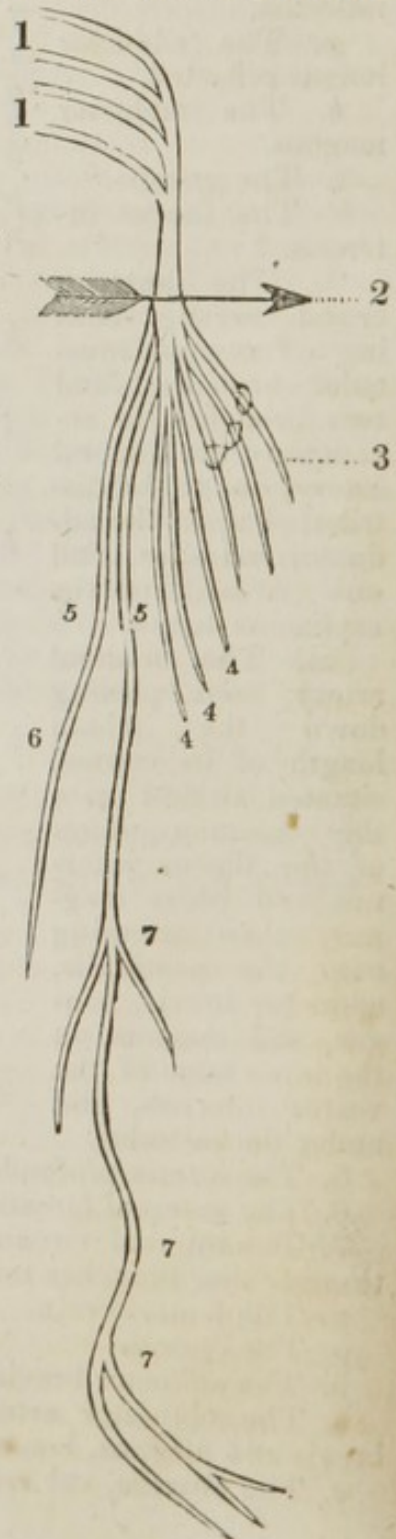
3. The cutaneous branches which pierce the fascia, to be distributed upon the skin and fascia, as low as the patella.

4. The muscular branches supplying the muscles of the thigh.

5.5. The two branches which accompany the femoral artery.

6. The branch which leaves the artery, to supply the adductor muscles.

7. The nervus saphænus major accompanying the femoral artery, until that vessel runs through the adductor magnus, when the nerve runs under the gracilis, pierces the fascia, and becoming cutaneous, accompanies the saphæna vein, and is distributed upon the anterior part of the leg and foot.



The course of the femoral artery having been described, the accompanying diagram is intended to point out its branches.

1. The femoral artery passing under Poupart's ligament.

2. The external or superficial epigastric artery.

3. The superficial circumflexa ili.

4. The external pudic artery, occasionally a superior and inferior branch.

5. One of the inguinal branches.

6. The arteria profunda femoris, sending off

7. The external circumflex artery, dividing into

8. An ascending set of branches.

9. A descending set of branches.

10. A transverse set of branches.

11. The internal circumflex artery, a branch of the profunda, sending off

12. An ascending set of branches.

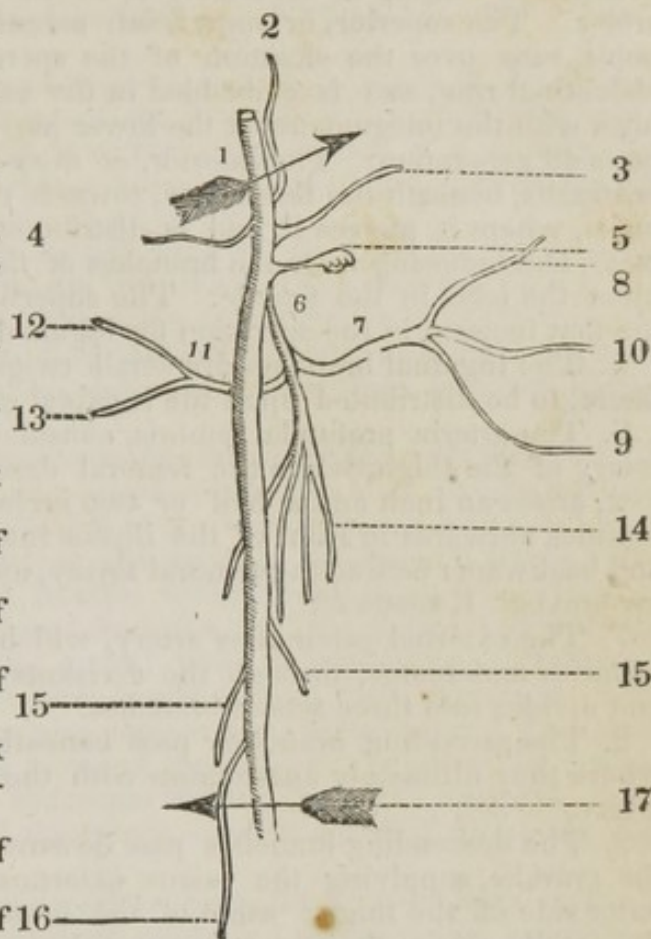
13. A posterior set of branches.

14. The arteriæ perforantes, three or four branches, the continued trunks of the profunda.

15. Muscular and nutritious branches of the femoral artery.

16. The ramus anastomoticus magnus.

17. The femoral artery, terminating in the popliteal artery.



1. The femoral, the continued trunk of the external iliac artery, after having passed under Poupart's ligament, is situated upon the common union of the iliacus internus and psoas magnus, and continues its course until it perforates the tendinous and muscular portions of the adductor magnus, to enter the popliteal cavity. In its course it sends off

2. The external epigastric artery, which arises occasionally half an inch below Poupart's ligament, runs through the saphænous opening of the fascia lata, perforating the fascia cribrosa, then ascends perpendicularly between the laminæ of the fascia superficialis, ramifying as high as the umbilicus, anastomosing with the proper epigastric artery, its principal branches being distributed upon the skin and superficial fascia in its course. This vessel is divided in making the transverse section in the operation for strangulated femoral hernia.

3. The superficial circumflexia ili artery, passes outwards and upwards towards the spine of the ilium, parallel with Poupart's ligament; crossing the psoas magnus and iliacus internus, it divides into small

twigs, which pierce the fascia and anastomose with branches of the internal circumflexa ilii artery, with the gluteal, and external circumflex.

4. The external pudic artery, superior and inferior, arises either by a common origin, or separately from the inner side of the femoral artery. The superior, or superficial, ascends towards the spine of the pubis, runs over the situation of the spermatic cord, near the external abdominal ring, and is embedded in the superficial fascia, which it supplies with the integuments at the lower part of the abdomen and external parts of generation. The inferior, or deep-seated branch, runs upon the pectinalis, beneath the fascia lata, towards the descending ramus of the pubis, where it pierces it, and is distributed upon the scrotum; in the male, anastomosing with the branches of the external pudic artery, and upon the labia in the female. The superficial artery is cut in making the first incision in the operation for inguinal hernia.

5. The inguinal branches are small twigs which pierce the cribriform fascia, to be distributed upon the inguinal glands.

6. The arteria profunda femoris, considered as the proper nutritious artery of the thigh, while the femoral descends to supply the leg and foot, arises an inch and a half or two inches below Poupart's ligament, inclines outwards in front of the iliacus internus, then runs downwards and backwards behind the femoral artery, upon the pectinalis and adductor brevis. It sends off

7. The external circumflex artery, which passes outwards under the sartorius and rectus, through the divisions of the anterior crural nerve, and divides into three sets of branches.

8. The ascending branches pass beneath the tensor vaginae femoris, where they ultimately anastomose with the ramifications of the gluteal artery.

9. The descending branches pass downwards, under the rectus, upon the cruralis, supplying the vastus externus and other muscles on the outer side of the thigh; some of the branches can be traced as low as the patella, where they anastomose with the articular arteries of the popliteal.

10. The transverse branches pass over the cruralis, pierce the vastus externus so as to get near the femur, just below the trochanter major, then pass at the back part of the thigh to anastomose with the gluteal and ischiatic arteries.

11. The internal circumflex artery arises from the inner and back part of the profunda artery, turns backwards between the pectinalis and adductor brevis, towards the inner part of the tendon of the psoas magnus, runs in a sort of cavity of a triangular figure, bounded externally by the capsular ligament, neck of the femur, and psoas magnus: superiorly, by the obturator externus, and internally by the adductor muscles; it then divides into two sets of branches.

12. The ascending branches pass upwards, supplying the obturator externus, and anastomosing with the obturator artery.

13. The posterior branch passes backwards, above the trochanter minor, gains the back part of the thigh, running between the adductor magnus and quadrator femoris, where it anastomoses with the superior perforating branches, the ischiatic, and deep-seated gluteal branches; when this artery arrives opposite the cotyloid ligament, it sends a branch into the hip joint, to supply it with nourishment, then passes along the ligamentum teres to the head of the femur, which it also supplies.

14. The arteriæ perforantes, three or four in number, are the terminating branches of the profunda artery; they pierce the adductor muscles, anastomosing with the ischiatic, obturator, and articular branches. The femoral artery also sends off

15. The muscular branches, to supply the muscles, and afford nutriment to the bone.

16. The ramus anastomoticus magnus, sent off previous to the passage of the artery through the tendon of the triceps; it descends with many ramifications upon the vastus internus, upon which it is chiefly dispersed; inosculating with the descending branch of the circumflexa externa, and below, with branches about the knee.

The vena femoralis, the continued trunk of the popliteal, receives the veins which correspond with the branches of the femoral artery, and passes in through the triceps, where the artery comes out. In the middle of the thigh, it lies deeper than the artery, afterwards turning gradually to its inner side; and at the upper part of the thigh is joined by the vena profunda.

The vena profunda receives the veins corresponding with the branches of the artery of that name, and is sometimes of a large size, being then in a great measure the continuation of the vena poplitea, — a small vein only in such cases accompanying the trunk of the femoral artery. Besides the vena profunda, the femoral vein takes in small veins from the external parts of generation, and from the inguinal glands, and from the other superficial parts of the groin; and, in particular, it receives a branch of considerable size, which descends from the integuments of the fore side of the abdomen, as also the vena saphæna major. The trunk of the femoral vein, having received the different veins of the inferior extremity, passes into the abdomen, behind Poupart's ligament, being situated at the inner side of the artery, — after which it forms the vena iliaca externa.

The obturator artery usually arises from the internal iliac, or one of its branches, either the gluteal or ischiatic; occasionally, however, it takes its origin from the epigastric. When it arises from the iliac, it passes forwards close to the obturator internus, between it and the levator ani, it pierces the pelvis fascia, passes through the foramen of the obturator ligament to the inner part of the thigh, where it divides into two branches, an external and internal. The external inclines downwards and outwards to the tuber ischii, supplying the obturator and quadrator muscles, as also the hip joint. The internal descends below the pectinalis and adductor longus, and upon the adductor brevis and magnus, supplying these muscles, and anastomosing with the arteriæ perforantes and ischiaticæ. The obturator nerve is formed by branches of the second, third, and fourth lumbar nerves. It emerges from behind the inner edge of the psoas magnus, descends on the inner border of that muscle into the pelvis, and passes obliquely downwards, to accompany the obturator artery through the thyroid foramen, dividing into branches, which are distributed upon the muscles on the inner part of the thigh.

The dissector having duly considered the parts already described, the muscles of the thigh may be reflected or cut off; and if the abdomen has been previously dissected, the two following muscles will be thoroughly understood.

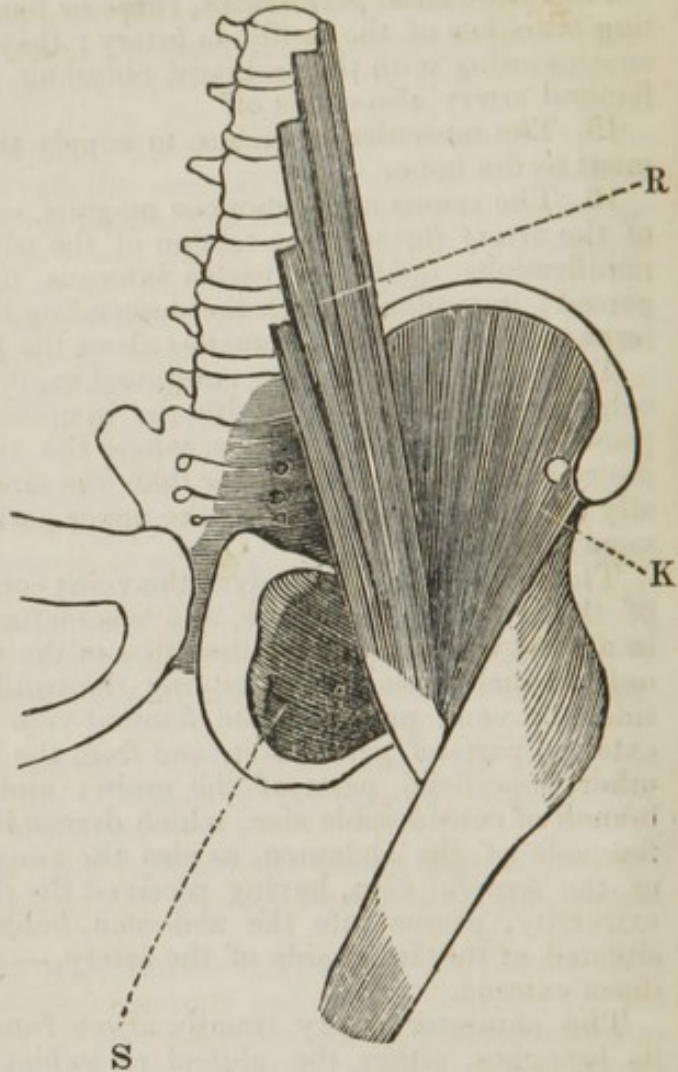
- K. The iliacus internus.  
 R. The psoas magnus.  
 S. The obturator externus.

The iliacus internus has already been described.

R. The psoas magnus *arises* by distinct tendinous and fleshy portions from the transverse processes, and from the sides of the bodies of the last dorsal and four superior lumbar vertebræ, descends on the lateral part of the brim of the pelvis, passing under Poupart's ligament, unites with the iliacus internus, and runs to be *inserted* into the trochanter minor. As it passes over the pubis, there is a large bursa mucosa. *Action*, — to bend the thigh upon the pelvis, at the same time to turn the whole extremity a little outwards, and to bend the spine and pelvis upon the thigh. In progression it raises the extremity from the ground. In standing, the two muscles maintain the spine and pelvis steadily.

S. The obturator externus *arises*, by a semicircular margin, from the anterior parts of the pubis and ischium, which form the anterior half of the foramen thyroideum, and from the membrane which fills up that foramen. The fibres are collected like rays towards a centre, and pass outwards over the back part of the cervix of the femur, to be *inserted*, by a strong round tendon, into the cavity at the inner and back part of the root of the trochanter major, adhering in its course to the capsular ligament of the thigh bone. *Action*, — to roll the thigh bone obliquely outwards, and to prevent the capsular ligament from being pinched.

From the dissection of the thigh, as also by this description, we are to bear in mind the course and situation of the femoral artery, so as to be enabled to secure it, whenever we are called upon to do so. If a line be drawn from the centre of Poupart's ligament to the middle of the patella, it will nearly indicate the course of the artery, but not precisely; the situation of the vessel being downwards along the anterior and inner part of the thigh, as has been already seen. At first it passes beneath Poupart's ligament, between the vein and nerve, the former on its inner side, contained in



the same sheath, the latter on its outer part, about a quarter of an inch from it. The vessel is situated upon the *psaos magnus*, which separates it from the brim of the *acetabulum* and *os pubis*; it is here only covered, first by its sheath, then by one or two of the inguinal glands and *fascia superficialis*, and can be easily compressed by making pressure upon the *pubis* or brim of the *acetabulum*. The artery also, in this stage of its course, can easily be secured in case of a wound of the vessel, or for an aneurism. The method of taking this vessel up, is to make a semilunar incision with its concavity upwards, the centre of the incision being in the middle of *Poupart's ligament*; the skin is divided by this cut, and the *fascia superficialis* brought into view; care being taken to avoid the inguinal glands. When the *fascia* is divided, the sheath of the vessels is brought into sight; sometimes, when the incision is rather large, the falciform process of the *fascia lata* may be divided. The sheath being then divided, we arrive at the femoral artery, which I have been in the habit of calling inguinal. An aneurismal needle may now be passed, armed with a ligature, from the inner to the outer part of the thigh, and the vessel may be secured; the nerve cannot be included, as it is full a quarter of an inch from the artery. Care must be taken, in opening the sheath, not to wound the artery, by taking a small part of the sheath up with the forceps, and opening it by cutting upwards towards the point of the forceps. The anastomosing branches that will carry on the circulation after this operation, are the *gluteal*, the *obturator*, and *ischiatric* arteries, by uniting with branches of the *internal* and *external circumflex*, as also with the *arteriæ perforantes*. The femoral artery then runs over the *pectinalis* muscles, being covered by its sheath, *fascia lata*, *fascia superficialis*, and skin; the vessel then runs over the *adductor brevis* and *magnus*, under the *sartorius*, at the inner edge of the *vastus internus*; it is here deeper seated, being covered by the *sartorius*, and in some degree by the *vastus internus*; next the vessel runs between the tendinous and muscular part of the *adductor magnus*, when it terminates by becoming the *popliteal* artery. In the upper third of the thigh it is usually secured for the cure of *popliteal aneurism*, as in the middle third the artery is much deeper seated. The method of securing this artery in the upper third of its course is the following:—The knee being



slightly bent, and the limb rotated outwards, an incision is to be made through the skin, beginning about two inches below the middle of Poupart's ligament, and carried downwards for about three inches; the fascia lata being exposed, a small part of it may be pinched up with the forceps and cut across, so as to form a small opening, into which a director may be introduced, and the fascia divided by a scalpel upon the director; the inner edge of the sartorius is then brought into view, and by separating it a little with the handle of the knife, we arrive at the sheath of the vessels; then a small part should be raised with the forceps and divided, the knife being held in the horizontal position; the vein will be found behind the artery and a little on its inner side; the needle must be passed from the inner to the outer part, being cautiously insinuated between them, its surface being drawn close to the artery. Should the artery be disturbed in its course, two ligatures must be placed around it, the one at the upper part of the disturbed portion, the other at the lower; or if this be not done, the vessel is in danger of sloughing, as its coats derive their nourishment from the surrounding sheath, by small branches which form the vasa vasorum. The artery being secured, the ligature may be passed through the incision, the edges of which may be brought together by adhesive plaster.

---

#### DISSECTION OF THE ANTERIOR AND OUTER PART OF THE LEG AND THIGH.

IN this dissection the student must rotate the leg inwards, making the point of the great toe turn inwards. The leg must be kept in this position by two hooks fixed in the inner part of the foot or great toe, the third hook being fixed into the dissecting-table. The leg being placed in this position, an incision may be made from the upper part of the leg, commencing midway between the tibia and fibula, and carried downwards to the second or third toe. To facilitate the removal of the integuments, a transverse incision can be made at about the upper third of the leg, and another transverse incision may also be made near the ankle. The dissector should bear in mind that it is the outer

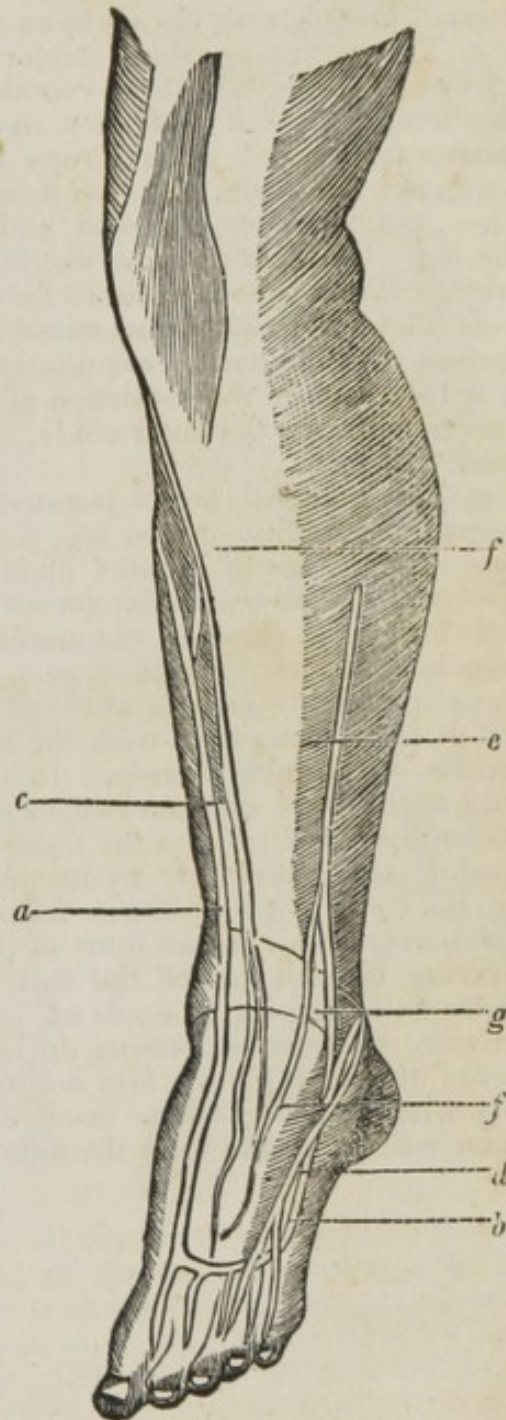
and anterior part of the leg that he is exposing, and that the skin must not be removed from the inner part of the leg, or the dissection at the back part will become dry. The integuments being removed, the following parts will be brought into sight.

- a.* The vena saphæna major.
  - b.* The vena saphæna minor.
- These two veins forming an arch at the anterior part of the foot.
- c.* The nervus saphænus major.
  - d.* The nervus saphænus minor.
  - e.* The peroneal nerve.
  - f.* The fascia of the leg.
  - g.* The situation of the annular ligaments pointed out.

In this stage of our dissection we have to bring into view two principal veins and the three cutaneous nerves, as also the fascia. We shall also find, by a careful removal of the integuments near the inner ankle, a lymphatic gland, which will receive the absorbents from the anterior part of the foot. Lymphatic vessels will pass up the inner part of the leg, accompanying the vena saphæna major, and terminating in a gland near the inner condyle of the femur. In anasarcarous subjects these absorbents can be distinctly seen, and may be injected with quicksilver, by perforating one, and introducing the mouth of the lymphatic injecting tube.

*a.* The vena saphæna major, or interna, is situated on the inner side of the leg. It is formed by the union of many veins, which, commencing near the great toe, (forming an arch,) proceed over the foot to the inner side of the leg. Here they unite into a single trunk, which is continued straight upwards between the skin and the fascia to the knee, and then ascends obliquely to the inner side of the thigh.

*b.* The saphæna minor arises upon the outer side of the foot, and afterwards passes behind the malleolus externus. From this it ascends, on the back part of the leg, between the integuments and fascia. It then perforates the fascia, running on the surface of the gastrocnemius,



and enters the ham, terminating in the popliteal vein. It is formed by the veins of the upper and outer part of the foot, and is joined to the saphæna major, over the metatarsal bones, by one or more arches, which receive a plexus of branches into their lower or convex part. It is joined by the superficial veins of the outer and back part of the leg, which form frequent anastomoses with each other, and with the branches of the saphæna major. A little above the knee, it communicates constantly by a small branch with the saphæna major.

*c.* The nervus saphænus major descends between the sartorius and triceps, perforates the theca containing the femoral artery, and runs with the artery, until it perforates the adductor magnus, where the nerve crosses the artery; it next runs under the gracilis and sartorius, then perforates the fascia, proceeds from the thigh down the inner side of the knee, near the vena saphæna, and is continued down the inner side of the leg. Its filaments are distributed superficially, and some of them may be traced over the foot as far as the great toe.

*d.* The nervus saphænus minor is formed by a branch of the popliteal uniting with the nervus communicans, sent off from the peroneal nerve. It will be seen in the dissection of the back part of the leg; it passes, in this view, round the outer ankle, and is distributed upon the three small toes.

*e.* The peroneal nerve penetrates the fascia on the outer side and towards the middle of the leg, and thence descending, divides into filaments, which are distributed upon the upper surface of the foot, where they communicate with the nervus saphænus.

*f.* The fascia covering the muscles of the leg is much thicker in front than behind. At the upper part of the leg, it is continuous with the fascia lata, and is besides attached to the heads of the tibia and fibula, and is firmly connected with the tendons of the rectus, vasti, sartorius, gracilis, and semitendinosus. In its course down the leg, the fascia is fixed to the outer and inner edges of the tibia, where it terminates without being continued over the front of the bone, so that the latter is separated from the skin only by its periosteum. At the lower part of the leg, the fascia is continued in front, into the anterior annular ligament, which extends across the front of the ankle joint. The fascia descends, covering the dorsum of the foot, gradually becoming thinner. In its course down the leg, it sends off prolongations or processes, which sink between the muscles, forming the intermuscular ligament. At the upper part of the leg it gives a firm origin to the muscles, and can be separated only with difficulty. The fascia may next be removed, when the dissector will bring into view the following parts.

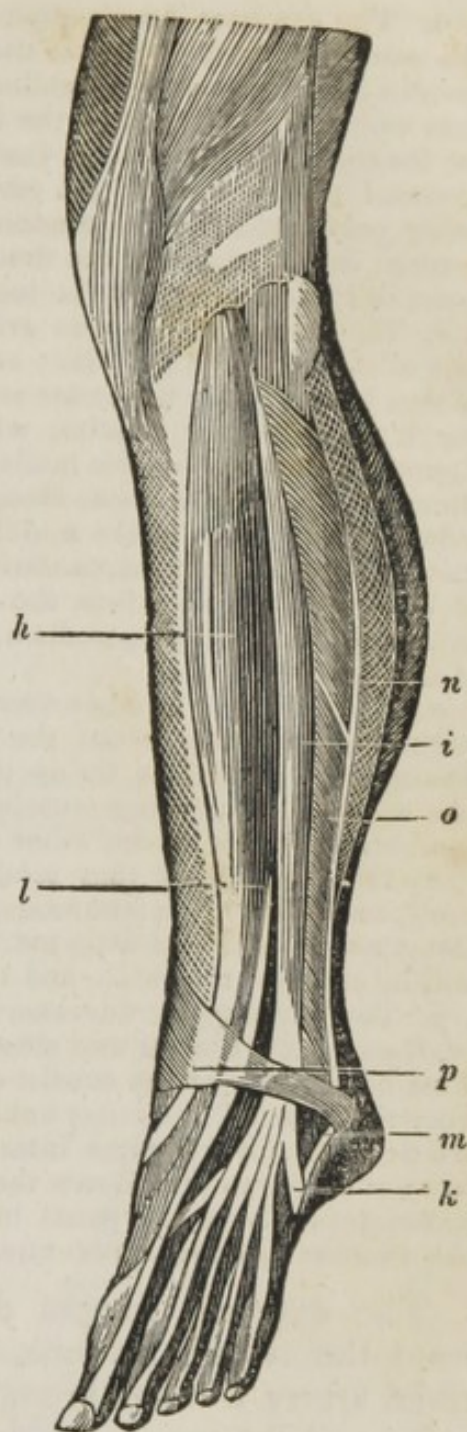
- h.* The tibialis anticus.  
*i.* The extensor longus digitorum.  
*k.* The peroneus tertius.  
*l.* The extensor longus, or proprius pollicis.  
*m.* The extensor digitorum brevis.  
*n.* The peroneus longus.  
*o.* The peroneus brevis.  
*p.* The annular ligament.

*h.* The tibialis anticus *arises* tendinous, from the upper part of the tibia, between its tubercle and articulation with the fibula. It then runs down, fleshy, on the outside of the tibia, adhering to it and to the upper part of the interosseous ligament. Towards the under part of the leg, it sends off a strong round tendon, which passes under the annular ligament, near the inner ankle, to be *inserted*, tendinous, into the middle of the os cuneiforme internum, and base of the metatarsal bone of the great toe. *Action*,— to bend the foot.

*i.* The extensor longus digitorum *arises* tendinous and fleshy, from the upper and outer part of the head of the tibia, and from the head and almost the whole length of the anterior spine of the fibula. It arises, also, fleshy, from the aponeurosis which covers the upper and outer part of the leg, and from the interosseous ligament, passes under the annular ligament, and splits into four round tendons, which pass along the upper part of the foot, to be *inserted* into the base of the first phalanges of the four small toes, by flat tendons which are expanded over the upper side of the toes as far as the root of the second phalanges. *Action*,— to extend all the joints of the four small toes.

*k.* The peroneus tertius, a portion of the former muscle, *arises* from the middle of the fibula, in common with the extensor longus digitorum, and passes under the annular ligament, to be *inserted* into the base of the metatarsal bone of the little toe. *Action*,— to assist in bending the foot.

*l.* The extensor proprius pollicis *arises* by an acute, tendinous, and fleshy beginning, from the fore part of the fibula, about the two inferior thirds of the bone, continuing its origin to near the outer ankle, by fleshy fibres, which descend obliquely, to be *inserted*, tendinous, into the base of the extreme phalanx of the great toe. *Action*,— to extend the great toe.



*m.* The extensor brevis digitorum *arises* fleshy and tendinous, from the outer and anterior part of the os calcis, forming a fleshy belly, which divides into four portions, sending off an equal number of tendons, which pass over the upper part of the foot, and under the tendons of the extensor longus digitorum, to be *inserted*, by four slender tendons, the three external into the base of the second phalanges of the three middle toes, being perforated by the tendons of the extensor longus; the internal tendon, into the base of the first phalanx of the great toe. *Action*,— to assist in the extension of the toes.

*n.* The peroneus longus *arises* tendinous and fleshy, from the fore part of the head of the fibula; and fleshy, from the outer part of the head of that bone to near the inner ankle. The fibres run in a penniform manner towards a long tendon, which becomes round, and, inclosed in a sheath, passes behind the malleolus externus; it is then reflected to the sinuosity of the calcis, runs along a groove in the os cuboides, and crosses obliquely the bones in the middle of the sole, under the long ligament of the calcis, to be *inserted*, tendinous, into the base of the metatarsal bone of the great toe, and into the internal cuneiforme bone. *Action*,— to extend the foot a little, to draw it outwards, and to turn the inner edge of it downwards.

*o.* The peroneus brevis *arises* fleshy, from the outer part of the fibula, beginning some way about the two inferior thirds of the bone, and continuing its adhesion as far as the malleolus externus. The fibres run, like those of the former muscle, to an external tendon, which becomes round, passes behind the outer ankle, included in the same sheath, and there crossing behind that tendon, runs forward in a sheath proper to itself, to be *inserted*, tendinous, into the root and external part of the metatarsal bone of the little toe. *Action*,— to assist the former muscle in pulling the foot outwards, and to extend it in a small degree.

*p.* The annular or transverse ligament binds down the tendons, and is evidently but a thicker and stronger part of the general fascia of the leg. This ligament seems to consist of two distinct cross bands, which, going from the point of the outer ankle and neighboring part of the os calcis, are fixed to the malleolus internus, and to the inside of the os naviculare; it serves to bind down the tendons, keeping them in their proper situations. There are small bursæ mucosæ between each tendon and the annular ligament, preventing the tendons from adhering to it.

The extensor longus digitorum may now be separated from the tibialis anticus, when the course of the anterior tibial artery will be brought into view, accompanied by two veins and the anterior tibial nerve.

*h.* The tibialis anticus.

*i.* The extensor longus digitorum.

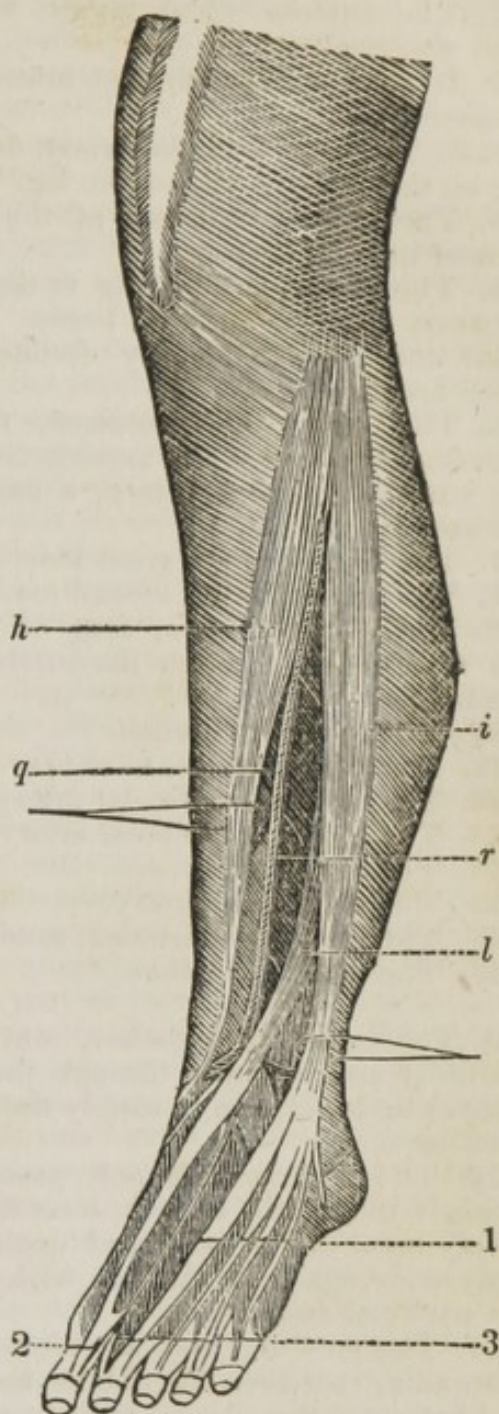
*l.* The extensor longus pollicis.

*q.* The anterior tibial artery, passing at first between the tibialis anticus and extensor longus digitorum, then between the tibialis anticus and exterior longus pollicis, running under the annular ligament, crosses under the tendon of the extensor longus pollicis, running over the astragalus naviculare and middle cuneiforme bones, to gain the space between the great and second toe, where it divides into three branches: 1. The ramus anastomoticus; 2. A branch to the great toe; 3. A branch to the second toe.

*r.* The anterior tibial nerve.

*q.* The anterior tibial artery passes from the ham betwixt the inferior edge of the popliteus, and the superior fibres of the soleus, and then through a large perforation in the interosseous ligament, to reach the fore part of the leg; this perforation is much larger than the size of the artery, and is filled up by the fibres of the tibialis posticus. The artery may be said to pass between the head or origin of this muscle. The artery then runs down close upon the middle of the interosseous ligament, between the tibialis anticus and extensor proprius pollicis; below the middle of the leg, it leaves the interosseous ligament, and passes gradually more forwards; it crosses under the tendon of the extensor proprius pollicis, and is then situated between that tendon and the tendon of the extensor longus digitorum. At the ankle it runs over the fore part of the tibia, being now situated more superficially; then over the astragalus and os naviculare, and over the junction of the os cuneiforme internum and medium, crossing under that tendon of the extensor brevis digitorum which goes to the great toe. Arriving at the space between the bases of the two first metatarsal bones, it divides into three branches, one of which plunges into the sole of the foot, and immediately joins the plantar arch.

The following diagram is intended to facilitate the knowledge of the branches of this vessel.



The following diagram is intended to facilitate the knowledge of the branches of this vessel.

1. The anterior tibial artery, sent off from the popliteal.

2. It passing through the interosseous ligament.

3. 3. The anterior tibial artery, descending on the anterior part of the leg.

4. The continued trunk of the artery termed the dorsal artery.

5. The vessel terminating at the space between the metatarsal bones of the great and second toe, by dividing into three branches.

6. The ramus anastomoticus, running between the bones, to anastomose with the external plantar artery, a branch of the posterior tibial.

7. The branch to the great toe.

8. The branch to the second toe.

9. Muscular branches, sent off before the vessels pass through the interosseous ligament.

10. The recurrent branch.

11. Muscular and nutritious branches.

12. The external malleolar artery.

13. The internal malleolar artery.

14. The tarsal artery.

15. The metatarsal artery.

16. The interosseal arteries, sending off

17. The digital branches.

9. The muscular branches, sent off as the tibial artery passes through the interosseous ligament, run to supply the tibialis posticus muscle.

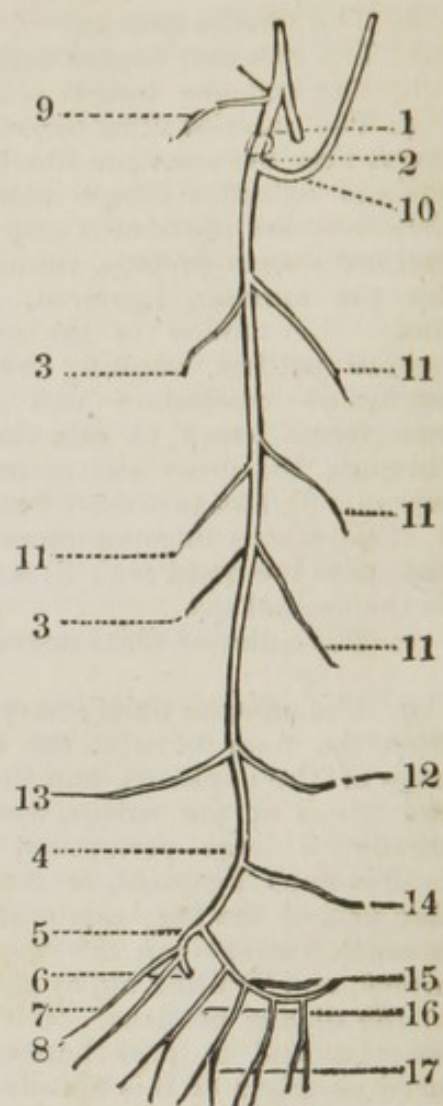
10. The recurrent branch passes upwards and outwards, running through the tibialis anticus, soon dividing into several branches, which ramify upon the anterior and outer part of the knee. These branches form numerous inosculation with the articular branches sent off from the popliteal artery.

11. The muscular and nutritious arteries are sent off as the vessel is descending between the tibialis anticus and extensor longus digitorum, and between the tibialis anticus and extensor longus pollicis. These branches supply the muscles on the anterior part of the leg.

12. The external malleolar artery passes under the tendons of the extensor longus digitorum to the outer ankle, and forms anastomoses with the fibular and tarsal arteries.

13. The internal malleolar artery runs under the tendon of the tibialis anticus to the inner ankle, to be distributed upon the surrounding capsule of the joint anastomosing with branches of the posterior tibial artery.

14. The tarsal artery runs outwards close to the tarsal bones, beneath the extensor brevis digitorum; it communicates with the fibular and external malleolar arteries; its continued trunk sinks under the tendon of the peroneus brevis, and terminates in supplying the outer border of the foot.



15. The metatarsal branch is sent off just as the dorsal artery is about to divide into its three branches; it passes outwards to the little toe, running upon the metatarsal bones, forming an arch, from the convexity of which arise the interosseal branches, which ramify upon the interosseal muscles, and ultimately terminate by dividing into branches to supply the toes, termed digital arteries.

The branch sent off to the great toe is termed the *dorsalis hallucis*, and terminates in supplying it. The branch to the second toe is sometimes a branch of the former, and supplies the inner part of the second toe.

The two veins which accompany the anterior tibial artery are formed by the small veins which accompany the minute branches of the artery, and which unite to form the two *venæ comites*; they ascend, pass through the interosseous ligament, and unite with the two veins, which accompany the posterior tibial artery, to form the popliteal vein.

r. The anterior tibial nerve is a branch of the peroneal; it penetrates the *peroneus longus* at the head of the fibula; it here divides into two branches, one cutaneous, the other the anterior tibial. The cutaneous branch, or fibular nerve, has already been seen in the first dissection. The anterior tibial nerve penetrates the *peroneus longus* and *extensor longus digitorum* to the front of the leg, and here continues its course downwards, between the *tibialis anticus*, the *extensor longus digitorum*, and the *extensor proprius pollicis*, and in front of the anterior tibial artery. It then passes beneath the annular ligament to the upper surface of the foot, and here divides into filaments, which extend to the toes.

The course of the anterior tibial artery may be ascertained by drawing a line from the inner part of the head of the fibula to between the great and second toe. This vessel may be secured almost at any part of its course. At the upper part it is deep-seated, and rests upon the interosseous ligament; to secure it at this part of its course, an incision may be made at the outer border of the *tibialis anticus*. When the skin is divided, and the fascia is brought into view, divide the fascia, and then take the inner part of the *extensor longus digitorum* as your guide, separating it from the *tibialis anticus* with the handle of the scalpel, when the vessel will be found, at some depth, upon the interosseous ligament. At the lower third of the leg, the vessel is more superficial, between the *extensor longus pollicis* and *tibialis anticus*; we may therefore take the tendon of the *tibialis anticus* as our guide, and make an incision upon the outer part of this tendon; when the skin is cut, divide the fascia, and the vessel will soon be brought into view.\* Upon the upper part of the foot, the vessel is situated between the *extensor longus pollicis* and *extensor longus digitorum*, being partly covered by the *extensor brevis digitorum*; the artery can be easily secured in this situation, or compressed in case of hemorrhage. We must bear in mind that the artery anastomoses with the posterior tibial.

\* Encircle the leg with a piece of tape, and thus get its circumference; divide this into eight parts, and you have the distance of the artery from the spine of the tibia, at the part where the circumference is taken; for the vessel, all along the leg, is distant one eighth of its circumference from the spine of the tibia.  
— *Smith on the Surg. Anat. of the Arteries.*



## THE DISSECTION OF THE POSTERIOR PART OF THE THIGH.

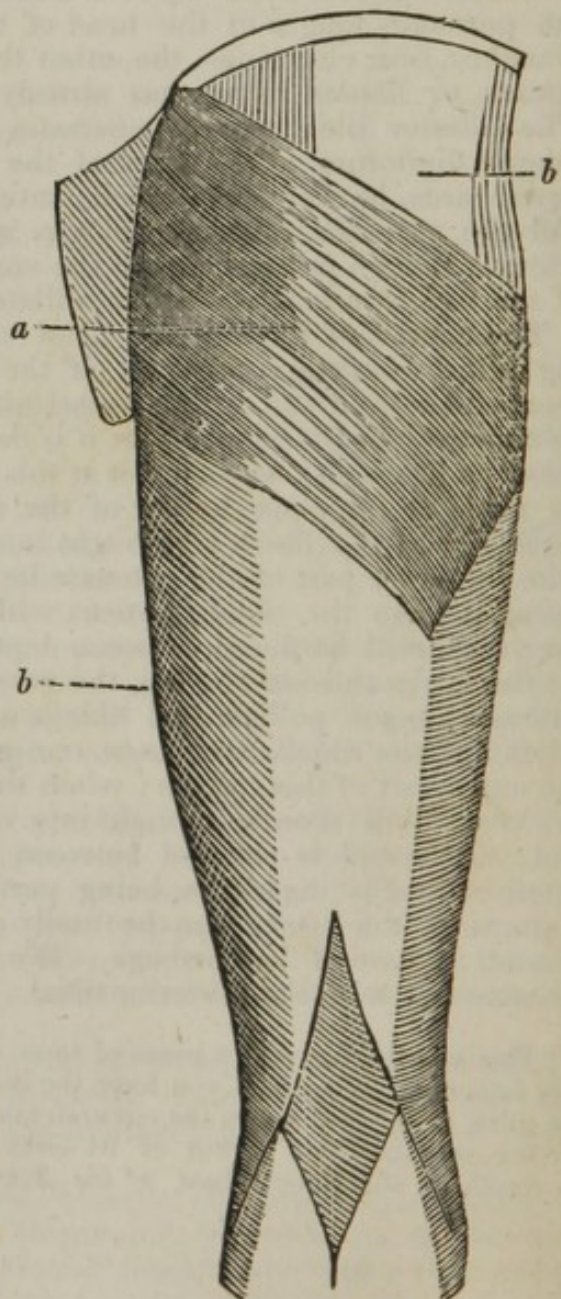
WHEN the subject or limb is turned, an incision may be made in the centre of the thigh, commencing from the middle of the crista of the ilium, and terminating below the popliteal cavity. Two transverse incisions may be made, similar to those on the anterior part of the thigh; one at the union of the first with the middle third, the second between the second and third division of the thigh.\* - When the integuments are removed, the following parts will be brought into sight.

- a.* The gluteus maximus.  
*b. b.* The fascia.

*a.* The gluteus maximus arises fleshy, from the back part of the spine of the ilium, from the under and outer part of the sacrum, from the os coccygis, and from the posterior sacro-ischiatic ligament. The fibres run obliquely forwards, and a little downwards, to form a thick broad muscle, composed of distinct coarse fasciculi. The upper part of it covers almost the whole trochanter major, and it is connected with the broad tendon of the tensor vaginae femoris, to be inserted, by a strong, thick, and broad tendon, into the upper and outer part of the linea aspera, along which it is continued for some way down. *Action*,—to extend the thigh, and pull it backwards and a little outwards.

The fascia at the back part of the thigh is a continuation of the fascia that serves to bind down all the muscles except the gluteus maximus, keeping them in their proper place, preventing the one muscle from starting over the other, thereby increasing their action.

Above the fascia which invests the thigh behind, we meet with several cutaneous nerves; these



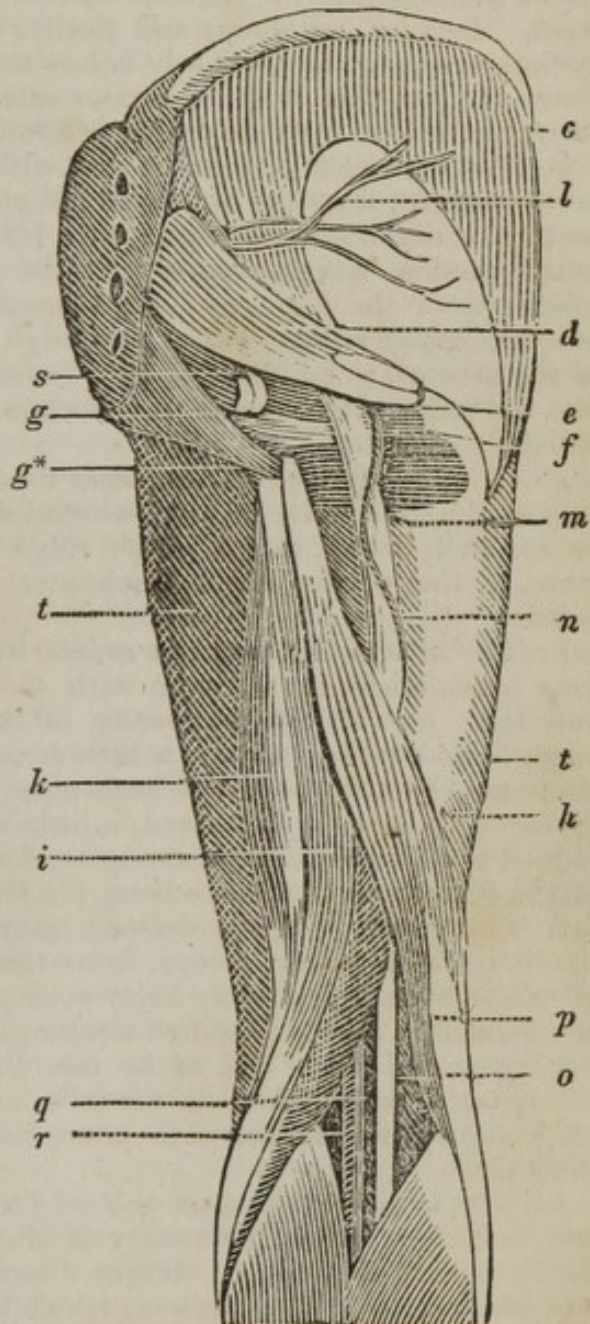
\* The following incisions are better calculated to develop the glutei. One

are of little importance ; — they have their origin either from the lumbar nerves, and come over the spine of the os ilium, or from the great sciatic nerve, and emerge under the lower margin of the gluteus maximus. Other twigs come from the sacral nerves, and from the sciatic in its course down the thigh.

The gluteus maximus is now to be lifted from its origin, and left hanging by its tendon ; remark the large bursa mucosa formed between the tendon and the trochanter major ; and another between its insertion into the fascia and the tendon of the vastus externus. The fascia can also be reflected, when the following parts will be brought into sight.

- c. The gluteus medius.
- d. The pyriformis.
- e. The geminus superior.
- f. The geminus inferior.
- g. The obturator internus.
- g\*. The quadrator femoris.
- h. The biceps flexor cruris.
- i. The semitendinosus.
- k. The semimembranosus.
- l. The superficial gluteal artery and nerve.
- m. The great ischiatic nerve.
- n. The ischiatic artery.
- o. The popliteal nerve.
- p. The fibular or peroneal nerve.
- q. The popliteal vein.
- r. The popliteal artery.
- s. The internal pudic artery, vein, and nerve.
- t. t. The muscles on the anterior part of the thigh.

c. The gluteus medius arises fleshy, from all that part of the spine of the ilium which is unoccupied by the gluteus maximus, from the upper part of the dorsum of the bone, and from an aponeurosis which covers the muscle, and joins the fascia of the thigh. It sends off a broad tendon, to be inserted into the outer and back part of the trochanter major. *Action*, — to pull the thigh outwards and a little backwards. The fore part of the muscle assists in rolling it inwards.



around the spine of the ilium, and a second from the middle of the spine of the sacrum to opposite the great trochanter. The last should be semicircular, the concavity towards the anus.

*d.* The pyriformis *arises* within the pelvis, by three tendinous and fleshy heads, from the second, third, and fourth bones of the sacrum; and, becoming round and tapering, it passes out of the pelvis through the sacro-iliac notch, along with the sciatic nerve, to be *inserted*, by a roundish tendon, into the upper part of the cavity between the trochanters. *Action*, — to assist in the abduction of the thigh, and in its rotation outwards.

*e.* The geminus superior *arises* from the back part of the spinous process of the ischium, and is inserted with the following muscle.

*f.* The geminus inferior *arises* from the upper part of the tuberosity of the os ischium, and the anterior surface of the posterior sacro-sciatic ligament. *Inserted*, tendinous and fleshy, into the cavity at the root of the trochanter major, immediately below the insertion of the pyriformis, and above the insertion of the obturator externus. *Action*, — to roll the thigh outwards, and to bind down the tendon of the obturator internus.

*g.* The obturator internus *arises* within the pelvis, by a semicircular fleshy margin, from the anterior half of the foramen thyroideum, and in part from the obturator ligament. Its fibres converge, and send off a round tendon, which passes over the ischium, between the spine and tuberosity of the bone, as a rope passes over a pulley; where it goes over the capsular ligament of the thigh bone, it is inclosed in the sheath of the gemini, to be *inserted*, by a round tendon, along with the gemini, into the large pit between the trochanters. *Action*, — to roll the thigh obliquely outwards.

*g*\*. The quadrator femoris *arises* tendinous and fleshy, from the outer side of the tuberosity of the ischium, running transversely outwards, to be *inserted*, fleshy, into a rough ridge continued from the root of the great to that of the small trochanter. *Action*, — to roll the thigh outwards.

*h.* The biceps flexor cruris *arises* by two distinct heads: the first, or long head, *arises* in common with the semitendinosus, from the upper and back part of the tuberosity of the ischium; the second, or short head, from the linea aspera, a little below the termination of the gluteus maximus, by a fleshy acute beginning, which soon grows broader, as it descends to join the first head, a little above the external condyle of the femur, to be *inserted*, by a strong tendon, into the upper part of the head of the fibula. *Action*, — to bend the leg.

*i.* The semitendinosus *arises* tendinous and fleshy, in common with the long head of the biceps, from the posterior part of the tuberosity of the ischium. Its fleshy belly runs down the back part of the thigh, and sends off a long roundish tendon, which passes by the inner side of the knee, and ends flat, to be *inserted* into the inside of the ridge of the tibia, a little below its tubercle, and connected to the under edge of the gracilis. *Action*, — to bend the leg, and, when bent, to roll it inwards.

*k.* The semimembranosus *arises* by a broad flat tendon, from the upper and back part of the tuberosity of the ischium. The fibres composing the fleshy belly run in an oblique direction towards a tendon at the inner and under part of the muscle, which is situated behind the semitendinosus, to be *inserted* into the inner and back part of the head of the tibia. *Action*, — to bend the leg, and bring it directly backwards.

The semitendinosus and semimembranosus form the inner ham-string, and the biceps the outer ham-string; between the ham-strings, the great vessels and nerves are situated which run to the leg.

l. The superficial gluteal artery is a branch of the gluteal, which divides as it is passing above the pyriformis muscle through the sacro-iliac foramen, into the superficial and deep-seated; the superficial ramifies between the gluteus maximus and medius, supplying these muscles and the adjacent parts; and the deep-seated is distributed between the gluteus medius and minimus, supplying the hip joint. The nerves are branches from the last lumbar and first sacral, which pass to be distributed to the same parts as the artery.

m. The ischiatic, or great sciatic nerve, is formed within the pelvis, from branches from the two last lumbar and first sacral nerves; it passes out of the pelvis, along with the sciatic artery, below the pyriformis, descends over the gemini and quadrator femoris in the hollow betwixt the great trochanter and the tuberosity of the ischium, — runs down the back part of the thigh, anterior to the long head of the biceps, nearer the bone than the ham-string muscles; being situated between the anterior surface of the semimembranosus, and the posterior surface of the triceps adductor longus. After sending off the peroneal nerve, it arrives in the ham, and becomes the popliteal nerve. In this course it gives off several branches to the muscles and integuments. It sometimes perforates the belly of the pyriformis by distinct trunks, which afterwards unite.

n. The ischiatic artery, a branch of the internal iliac, passing out of the pelvis through the lower part of the great sacro-iliac hole, below the pyriformis, descends beneath the gluteus maximus, between the tuber ischii and trochanter major, to the back part of the thigh. Its branches, distributed to the surrounding muscles, communicate with the internal circumflex artery, and with the upper perforating branches of the profunda.

o. The popliteal nerve, the continued trunk of the great sciatic, is situated superficially in the popliteal cavity, nearer the integuments than the vessels it sends off.

p. The peroneal, or fibular nerve, passing outwards and obliquely downwards, runs between the external head of the gastrocnemius and the tendon of the biceps flexor cruris, and sinks among the muscles which surround the head of the fibula,

q. The popliteal vein is formed by the union of the anterior and posterior tibial veins; it ascends from the leg through the ham into the thigh. Just above the knee-joint, the popliteal vein receives the large branch, the saphæna externa, which ascends from the back part of the leg.

r. The popliteal artery, the continued trunk of the femoral, situated anteriorly to the vein contained in the same sheath; it is placed more internally than the vein, and sends off several branches, which will be described in the dissection of the posterior part of the leg.

s. The internal pudic artery passes out of the pelvis, above the superior ischiatic ligament, twists round it, and returning into the pelvis above the inferior ischiatic ligament, descends on the inside of the tuber ischii; then ascends on the inner surface of the ramus of the ischium, and the ramus of the pubis; in its course, it gives off the external hæmorrhoidal artery as it passes by the anus; the arteria transversa perinea, following the course of the transversus perinei muscle, on which it ramifies; a branch also to the prostate gland; the pudic artery then ends in sending branches to the corpus spongiosum urethræ, and to the corpora cavernosa, and the arteria dorsalis penis, which passes under the arch of the pubis, and runs along the dorsum penis, to be distributed upon the membrane of the penis.

The internal pudic artery is accompanied by a vein which enters the internal iliac.

The *nervi pudici* arise in two fasciculi, a superior and inferior, which are formed by fibrillæ from all the cords entering the composition of the sciatic nerve. The superior fasciculus is formed, more particularly, by filaments from the two under lumbar and two upper sacral nerves; the inferior is composed of a small cord from the second, and a large one from the third sacral. The fasciculi pass through the under part of the notch of the os ilium, afterwards between the sacro-sciatic ligaments, and follow the pudic blood vessels, anastomosing in some places with each other by oblique branches. They send many branches to the muscles and other parts about the anus and perineum, and then pass forwards to supply the different parts of the penis. On the penis, the nerves follow the course of the arteries; the superior fasciculus constituting the *nervus dorsalis*, and the inferior giving branches to the under part of the penis.

The *nervus dorsalis*, which is the most considerable nerve of the penis, runs forward between the corresponding artery and vena magna, expanding into many branches, which, after supplying the *corpus cavernosum* and integuments of the corresponding side, terminate in the substance of the glands.

In the dissection of the back part of the thigh, after these parts have been duly considered, the *gluteus medius* may be separated from its origin, when the *gluteus minimus* will be brought into view, together with the deep-seated gluteal artery and nerve.

The *gluteus minimus* arises from the whole surface of the ilium between the semicircular ridge and the acetabulum. Its fibres descending, converge and terminate in a broad and thick tendon, inserted into the upper and front part of the trochanter major. The internal surface of the *gluteus minimus* in part covers the capsule of the hip-joint. A bursa mucosa is found beneath the tendon, just before its insertion. *Action*, — to draw the thigh outwards and backwards.

The gluteal artery is the largest branch of the internal iliac. It passes through the sacro-iliac foramen above the *pyriformis*, then divides into a superficial and deep-seated branch; the former has already been described; the latter ramifies between the *gluteus medius* and *minimus*, sending off small branches which assist in supplying the hip-joint. The ramifications of this artery anastomose with the internal circumflex and sciatic arteries; it is accompanied by a nerve from the last lumbar and first sacral, which has the same distribution as the artery.

It is sometimes necessary to secure the gluteal artery, to stop hemorrhage, or for an aneurism. To take this vessel up, an incision may be made perpendicularly from the centre of the spine of the ilium, commencing about an inch below it, and extending two inches in length. The skin and *gluteus maximus* must be cut through, when we take the upper part of the *pyriformis* for our guide, and find the artery between it and the ilium, as it is passing through the sacro-iliac foramen.

## DISSECTION OF THE POSTERIOR PART OF THE LEG.

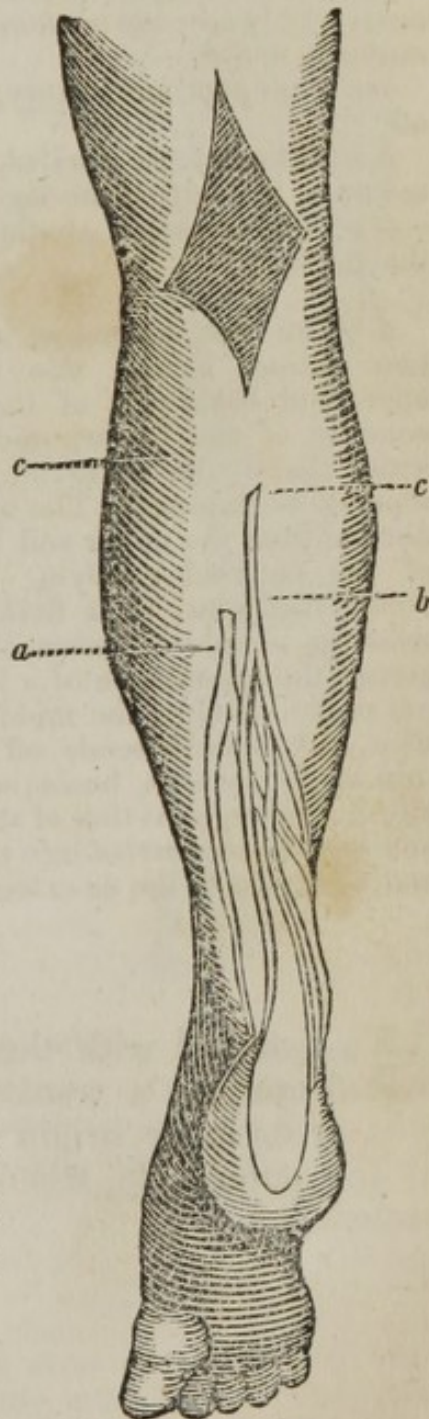
AN incision may be made in the centre of the leg, commencing from the popliteal cavity, and terminating at the os calcis; and the reflection of the integuments will expose the following parts.

- a.* The vena saphæna minor.
- b.* The nervus saphænus minor.
- c c.* The fascia.

*a.* The vena saphæna minor is formed by branches from the small toes and dorsum of the foot, forming an arch, which is seen in the dissection of the anterior part of the foot; the vein then passes round the outer ankle, and ascends at the back of the leg between the skin and fascia; near the middle of the calf it perforates the fascia, and ultimately enters the popliteal vein.

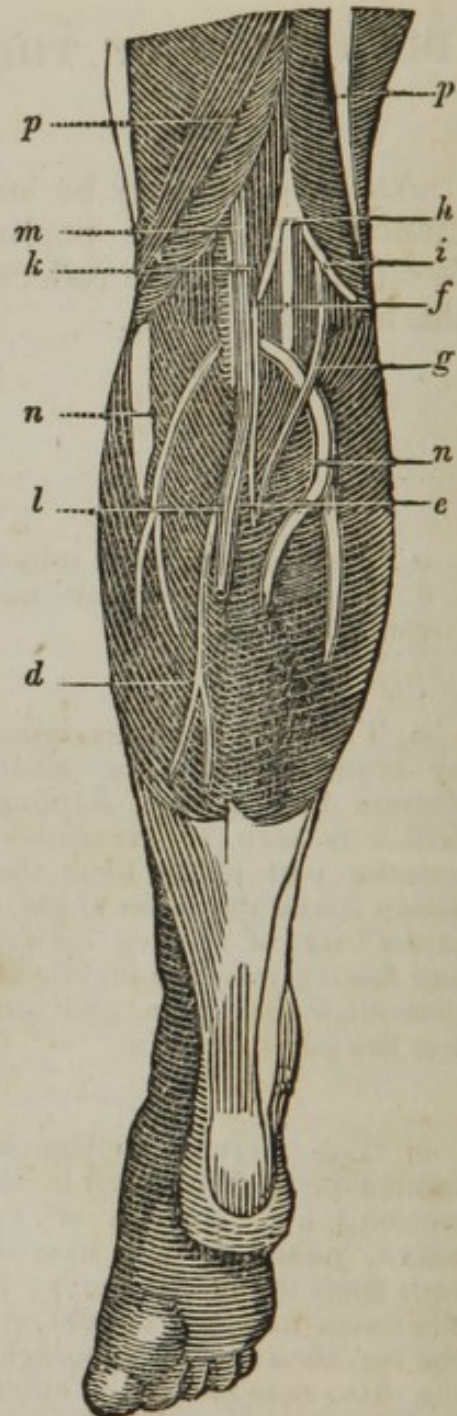
*b.* The nervus saphænus minor is formed (as will be seen in the next dissection,) by a branch of the popliteal nerve, joined by the nervus communicans from the fibular nerve; it perforates the fascia near the middle of the calf of the leg, then passes superficially beneath the skin, runs round the outer ankle, and is distributed upon the three small toes.

*c.* The fascia covering the muscles on the back part of the leg, a continuation of the fascia lata; it is much thinner than that on the anterior part. When it is reflected, the following view will be seen.



- d.* The gastrocnemius.  
*e.* The nervus saphænus minor, formed by  
*f.* The branch arising from the popliteal, and  
*g.* The nervus communicans, arising from the peroneal or fibular nerve.  
*h.* The popliteal nerve.  
*i.* The fibular or peroneal nerve.  
*k.* The popliteal vein, receiving  
*l.* The vena saphæna minor, which occasionally ascends to enter the vena saphæna major.  
*m.* The popliteal artery, sending off  
*n n.* The arteriæ surales, distributed upon the calf of the leg.  
*p p.* The muscles on the back of the thigh.

*d.* The gastrocnemius arises by two distinct heads; one from the upper and back part of the internal condyle of the femur, and from a little above the condyle, by two separate beginnings. The other, tendinous, from the upper and back part of the external condyle. A little below the joint, their fleshy bellies meet in a middle tendon, the union giving the appearance of a longitudinal raphè. Below the middle of the tibia, the muscle sends off a broad thin tendon, which, becoming gradually narrower, joins that of the soleus, and runs to be inserted into the upper and back part of the os calcis.



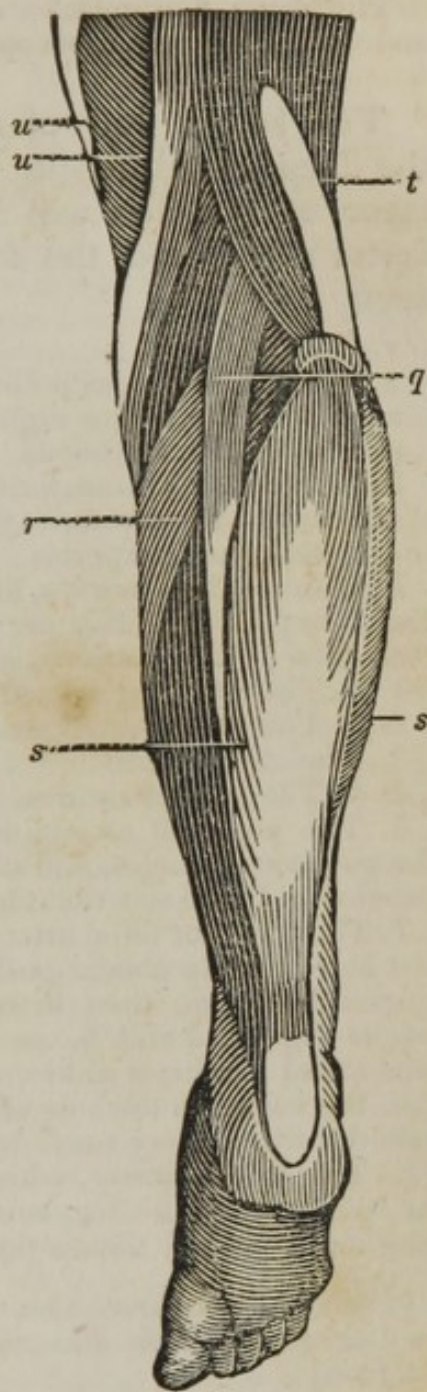
To proceed with the dissection, the gastrocnemius may be reflected by a transverse incision made through its middle; or its inner origin may be cut, and the muscle turned to the outer side, when the following muscles can be dissected.

- q.* The plantaris.  
*r.* The popliteus.  
*s.* The soleus.  
*t.* The biceps, forming the outer ham-string.  
*u u.* The semitendinosus and semi-branosus, forming the inner ham-string.

*q.* The plantaris *arises* thin and fleshy, from the upper and back part of the external condyle of the femur, and from the capsular ligament of the joint. A little below the head of the fibula, it sends off a long slender tendon, which descends obliquely inwards, between the inner part of the gastrocnemius and soleus, and afterwards runs along the inner edge of the tendo Achillis, to be *inserted* into the inside of the posterior part of the os calcis, below the tendo Achillis. *Action*,—to assist the gastrocnemius, and to pull the capsular ligament of the knee from between the bones. This muscle is sometimes, though very seldom, wanting.

*r.* The popliteus *arises* by a small round tendon, from the outer and under part of the external condyle of the femur, and from the back part of the capsular ligament of the joint. In passing the joint, it becomes fleshy, and spreads out, the fibres running obliquely inwards and downwards, covered with a tendinous membrane, to be *inserted*, thin and fleshy, into a ridge at the upper and inner edge of the tibia, a little below its head. *Action*,—to assist in bending the leg, and, when bent, to roll it inwards. The muscle also prevents the capsular ligament from being pinched.

*s.* The soleus *arises* by two heads. The first from the back part of the head, and upper and posterior part of the fibula. The other from the back part of the tibia, running inwards along the under edge of the popliteus, towards the inner part of the bone, from which it receives fleshy fibres for some way down. The flesh of this muscle, covered by the tendon of the gastrocnemius, descends nearly as far as the extremity of the tibia, a little above which the tendons unite, and form a strong round cord, called tendo Achillis, to be *inserted* into the upper and back part of the os calcis, by the projection of which the tendo Achillis is at a considerable distance from the tibia. *Action*,—the gastrocnemius and soleus elevate the heel, and draw the whole foot backwards, thus producing the extension of the ankle joint. They bend the leg upon the thigh. The plantaris co-operates with the gastrocnemius.





The above four muscles are sometimes considered as the first layer; and the following, the second layer.

The soleus and plantaris may now be reflected, when the deep-seated fascia separating the first from the second layer of muscles will be brought into view. When this fascia is removed, the following muscles and vessels will be seen.

*r.* The popliteus.

*v.* The flexor longus pollicis.

*w.* The flexor longus digitorum.

*x x.* The tibialis posticus.

*k.* The popliteal vein, formed by the union of the two veins accompanying the anterior and posterior tibial arteries.

*h.* The popliteal nerves, descending to become the posterior tibial nerve.

*m.* The popliteal artery, sending off

1. 1. The two internal articular arteries.

2. 2. The two external articular arteries.

3. 3. The azygos branch.

4. 4. The arteriæ surales.

5. The popliteal artery, descending upon the popliteus muscles, and dividing into the anterior and posterior tibial arteries.

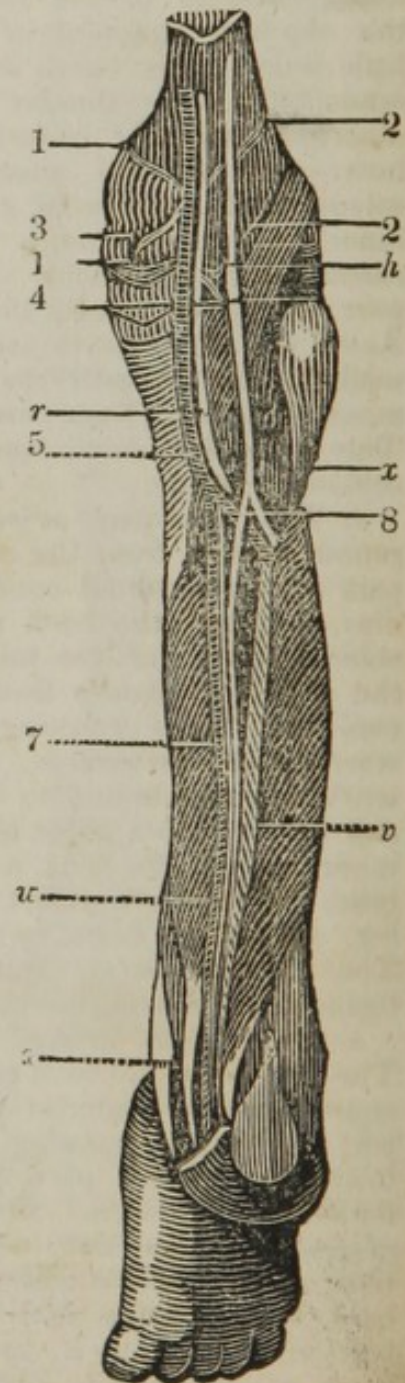
7. The posterior tibial artery, descending at first between the tibialis posticus and flexor longus digitorum, then between the flexor longus digitorum and flexor longus pollicis, runs round the inner ankle, nearer the tibia than the nerve, to the sole of the foot. The posterior tibial artery sends off

8. The fibular artery, which passes down the back part of the leg, between the flexor longus pollicis and tibialis posticus.

[For a further description of these vessels, see diagrams after the dissection of the sole of the foot.]

*h.* The popliteal nerve (continued trunk of the ischiatic nerve) is situated between the ham-strings, and between the skin and popliteal blood-vessels. A little above the bending of the knee, it is divided into a small external and a large internal branch; the former named fibular, and the latter tibial nerve. The tibial and fibular nerves adhere for some way, by cellular substance; and even the trunk of the sciatic may be split into these two nerves, for a considerable way up the thigh.

The fibular, termed also peroneal nerve, sends off at its beginning the cutaneous externus, which is a small branch giving twigs to the



under end of the biceps, and which, after running down on the outer head of the gastrocnemius, disappears in the integuments of the same side of the leg. Over the outer condyle of the os femoris, it gives off another cutaneous branch, to unite with the saphænus minor, which goes over the gastrocnemius, anastomosing with a branch of the tibial, passes round the outer ankle, and terminates in the integuments of that side of the foot. The fibular nerve afterwards passes over the head of the fibula, and perforating the peroneus longus, divides into a superficial and a deep-seated branch, which supply the muscles and integuments of the outer and fore part of the leg. The superficial crosses the fibula, immediately under its articulation; perforating the peroneus longus, and going over the brevis, it gives branches to both, and afterwards becomes subcutaneous, about the middle of the outer part of the leg. It sends branches to the metatarsus, and to the extensor digitorum brevis; and others, which, after anastomosing upon the upper part of the foot, furnish dorsal branches to the larger toes. The deep-seated nerve divides into several branches: — a reflected branch to the soft parts of the joint; branches to the muscles; the continued trunk; the anterior tibial nerve; passes under the extensor longus digitorum, to gain the anterior tibial artery which it accompanies, and divides upon the foot into branches, which have some connexion with each other, and supply the extensor digitorum brevis. Some filaments, continued from these branches, run to the interossei muscles, while others of more considerable size go to some of the innermost toes; one twig sinking with a branch of the anterior tibial artery to the deep muscles of the sole.

The tibial nerve passes between the heads of the gastrocnemius, and, perforating the origin of the soleus, descends between it and the flexor longus digitorum, upon the posterior tibial artery, to the under part of the leg; in which course it sends off the following nerves. The nervus saphænus minor, which accompanies the vena saphæna minor in the back part of the leg, and to the outer part of the foot. Behind the belly of the gastrocnemius, it sends a branch to be consumed in the fat; and a little lower it anastomoses with the communicating branch of the fibular nerve. The under part of this nerve is dispersed upon the integuments of the outer ankle and adjacent side of the foot, some branches passing as far as the dorsal side of two or three of the smaller toes. Branches to both heads of the gastrocnemius, to the plantaris, and to the soleus. Near the middle of the leg, the tibial nerve sends branches to the tibialis posticus, to the flexor digitorum, and flexor longus pollicis. One or two cutaneous branches dispersed upon the skin at the under and inner part of the leg. Near the ankle, a branch passes behind the tendo Achillis, principally to the integuments of the outer and back part of the foot and os calcis. The tibial nerve passes afterwards round the inner ankle, between the artery and the tendon of the flexor longus pollicis. After detaching branches to the parts adjacent, it divides into internal and external plantar nerves, which are nearly of equal size.

The internal plantar nerve runs near the inner side of the sole, sends filaments to the abductor pollicis, flexor digitorum brevis and flexor digitorum accessorius, and twigs to the lumbricales. It afterwards gives out four large branches, splitting into others, which run with the arteries along the plantar sides of the three first toes, and inner side of the fourth toe, in the manner the radial nerve runs along the corresponding fingers.

The external plantar nerve sends branches to the heel, and passes

with the artery of the same name to near the outer edge of the sole, where it splits into three principal branches. The two first run to the adjacent sides of the fourth and fifth toes, and outer side of the little toe: the inner one often anastomosing with a corresponding branch of the internal plantar. The third forms an arch corresponding with that of the external plantar artery; it furnishes branches to the short muscles of the little toe, to the interossei, lumbricales, and transversalis, and terminates in the short muscles of the great toe.

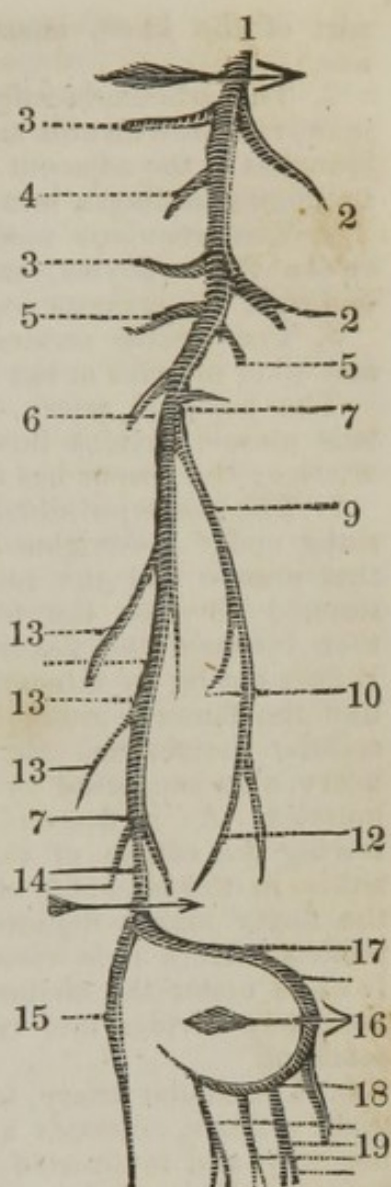
v. The flexor longus pollicis *arises* tendinous and fleshy, from the back part of the fibula, some way below its head; being continued down the same bone, almost to its under end, by a double order of oblique fleshy fibres. Its tendon passes under an annular ligament at the inner ankle, to be *inserted* into the last joint of the great toe. *Action*,—to bend the great toe, particularly the last joint.

w. The flexor longus digitorum *arises* by an acute tendon, which soon becomes fleshy, from the back part of the tibia, at the under edge of the popliteus; and this beginning is continued down the inner edge of the bone, by short fleshy fibres ending in its tendon. It arises also by tendinous and fleshy fibres, from the outer edge of the tibia; and between this double order of fibres the tibialis posticus lies inclosed in a sheath. Having gone under an annular ligament, it passes through a sinuosity at the inside of the os calcis; and about the middle of the sole of the foot, receives a tendon from the flexor longus pollicis, and the massa carnea Jacobi Sylvii. It then divides into four tendons, which run through the slits of the perforatus, and are *inserted* into the base of the third phalanges of the four smaller toes; the tendons of this, as well as of the flexor brevis, being inclosed by annular ligaments. *Action*,—to bend the different joints of the toes, particularly the last one.

x. The tibialis posticus *arises* fleshy, from the upper and posterior part of the tibia, from the back part of the fibula, next the tibia, and from near one half of the upper part of the last-named bone, as also from the interosseous ligament; the fibres running towards a middle tendon, which, in its descent, becomes round, and passes in a groove behind the malleolus internus, to be *inserted* tendinous, chiefly into the internal cuneiform bone, and partly into the inner surface of the metatarsal bone of the great toe. *Action*,—to extend the foot, and, with the assistance of the tibialis anticus, to turn the toes inwards, and the outer edge of the foot downwards.

The accompanying diagram is intended to illustrate the branches of the popliteal and posterior tibial arteries.

1. The popliteal artery.
2. 2. The external superior and inferior articular arteries.
3. 3. The internal superior and inferior articular arteries.
4. The azygos articular artery.
5. 5. The arteriæ surales.
6. The anterior tibial artery.
7. 7. The posterior tibial artery.
9. The fibular artery, sending off
10. The nutritious artery of the fibula.
12. The anterior and posterior fibular arteries, or continued trunk of the fibular.
13. 13. The muscular and nutritious branches.
14. 14. The branches to be distributed about the adjacent parts of the os calcis.
15. The internal plantar artery.
16. The external plantar artery, which may be divided into two stages of its course.
17. The first, or superficial part of the course of the artery, where it passes between the flexor brevis digitorum and massa carnea Jacobi Sylvii.
18. The deep-seated portion or arcus plantaris, situated between the interossei muscles and flexor longus digitorum tendons, sending off
19. The digital arteries, to supply the under surface of the toes.



1. The popliteal artery is the continued trunk of the femoral, and is situated in the popliteal cavity anteriorly, and internally to the vein and nerves placed at the back of the knee; it is lodged deep in the hollow between the ham-strings, the condyles of the femur, and heads of the gastrocnemius; as it passes over the joint, it adheres to the capsular ligament; it is afterwards placed upon the popliteus muscle, and is covered generally by a quantity of fat. It adheres to the popliteal vein, which is situated behind, and to its outer side; it sends off the following branches.

2. The articularis superior externa arises nearly opposite the internal superior branch, runs outwards under the tendon of the biceps, to be distributed upon the vastus externus, and outer and upper part of the knee.

2. The articularis inferior externa passes off opposite the internal inferior artery, and runs downwards and outwards, between the external lateral and capsular ligaments.

3. The articularis superior interna passes round the inner condyle of the femur, runs under the semimembranosus and semitendinosus, perforates the tendon of the triceps, to be dispersed upon the upper

part of the knee, anastomosing with the ramus anastomoticus magnus.

3. The articularis inferior interna arises opposite the bending of the joint, runs downwards and inwards round the head of the tibia, sending branches to the adjacent parts of the joint; some of these passing by the semilunar cartilages into the inner part of the joint.

4. The articularis media *vel* azygos is irregular in its origin, runs between the condyles, and is distributed upon the fat, ligaments, and bones, at the posterior part of the joint.

5. The arteriæ surales descend to supply the gastrocnemius, soleus, and other muscles at the back of the leg.

The popliteal artery, having gained the inferior border of the popliteus muscle, divides into two branches, the anterior and posterior tibial arteries; the former has already been described.

7. The posterior tibial artery, the continued trunk of the popliteal, sinks under the origins of the soleus, and runs down the leg between that muscle and the more deeply-seated flexors of the toes; at first situated between the tibialis posticus and flexor longus digitorum, then between the flexor longus digitorum and flexor longus pollicis. It does not lie in immediate contact with the fibres of the flexors, but, like the femoral artery, is invested by a strong sheath of condensed cellular membrane. It is, together with its veins and accompanying nerve, also supported by the fascia which binds down the deep-seated muscles. As it descends, it gradually advances more forwards, following the course of the flexor tendons: it passes behind the inner ankle, in the sinuosity of the os calcis, lying external to the tendon of the flexor longus digitorum, and internal to that of the flexor longus pollicis. Here it is close upon the bone, and its pulsation may be felt. It sinks under the abductor pollicis, arising from the os calcis, and immediately divides into two branches. In its course down the leg, it sends off

9. The fibular artery, termed also peroneal, smaller than either of the tibial arteries, descends at the inner side of the fibula, for a considerable way, and is situated, first between the tibialis posticus and flexor longus pollicis, and is afterwards covered by the last-named muscle. Its branches are distributed to the muscles at the outer part of the leg in the neighborhood of the fibula, a small medullary branch penetrating the substance of that bone. About the inferior third of the tibia and fibula, it sends a branch forwards, termed fibularis, or peronea anterior, which perforates the interosseous ligament, and is dispersed upon the fore part of the ankle, where it anastomoses with the external branch of the tibialis antica. The continuation of the trunk descends behind the malleolus externus, to the outer and back part of the foot, anastomosing with the external malleolar and tarsal branches of the tibialis antica.

The posterior tibial artery sends off numerous branches to the muscles. The arteria nutritia tibiæ, which begins a little below the upper end of the trunk, descends for some way in the leg, and gives branches to the deep muscles and membranes near it; and one branch, termed arteria medullaris, which enters the hole near the middle of the bone. Several branches to the parts behind, and at the inner side of the ankle and heel, which communicate with others of the anterior tibial artery.

The posterior tibial artery, having passed round the inner ankle, divides into the two plantar arteries.

15. The plantaris interna passes near the inner side of the sole, between the aponeurosis plantaris and abductor pollicis; it gives branches which run in a retrograde direction to the back part of the ankle and adjacent parts of the heel: several branches from each side, which go forwards to the muscles and integuments, and other parts at the concave edge of the sole. At the root of the great toe, it sends a principal branch to its inner side; it then passes under the flexor longus pollicis, and, after anastomosing with the arcus plantaris, gives off a large branch which splits into two,—one to the outer side of the great toe, and the other to the adjacent side of the toe next it.

16. The plantaris externa, which may be considered as the continuation of the trunk of the posterior tibial artery, being in general much larger than the internal, passes obliquely outwards between the flexor brevis digitorum and flexor accessorius, till it reaches the base of the metatarsal bone of the little toe. It is afterwards arched forwards, between the flexor muscles and metatarsal bones of the small toes, the trunk being continued to the root of the great toe, under the name of arcus plantaris. The external plantar artery sends off a considerable branch, first to the under, then to the outer part of the heel, which communicates externally with branches of the anterior tibial and the fibular arteries; and several branches to the flexor muscles of the toes, and to other parts in the outer portion of the sole, which communicate, on the other side, with the branches of the plantaris interna, and at the outer with those of the anterior tibial artery.

The arcus plantaris gives off several branches to the deep muscles of the sole; rami interossei to the muscles between the metatarsal bones; a branch to the outer side of the little toe; and three large digital arteries, which are forked at the roots of the toes, and run along the edges of these, in the manner the digital arteries do along the fingers.

Having considered the course and distribution of the arteries, let us now remark how those vessels can be secured in case of being wounded, or for aneurism.

*Method of securing the popliteal artery at the upper part of its course.*—The body being placed upon the fore part, and the leg extended, an incision may be made through the skin, along the external and posterior part of the semimembranosus; the fascia can be divided to the same extent, and the semimembranosus is to be drawn inwards; when the sheath containing the vein and artery is to be observed, the vein is to be cautiously separated from the artery, and the aneurism needle may be carefully insinuated between it and the artery, being carried from the outer to the inner part. The popliteal nerve is to the outer part of the incision, and therefore cannot be injured, as it is some little distance from it.

*Of securing the posterior tibial artery at the middle of the leg.*—There are two methods; the original is the following:

The leg being bent, and the foot extended, both lying on their outer side, an incision may be made, three or four inches in length, at the inner and posterior border of the tibia, avoiding the vena saphæna major; the edge of the gastrocnemius muscle will then be exposed; this may be raised and drawn to the outer side. A director may now be introduced beneath the inner origin of the soleus, which is to be divided, cutting upon the director. The deep-seated fascia is now arrived at, which is very dense and strong, binding down the deep-seated muscles and vessels; this must be cautiously divided on a director passed beneath it, the artery may now be felt, about an inch from the edge of the tibia; the veins are to be separated from it by a blunt instrument, and the aneurism needle passed round the artery, from the outer to the inner part, so as to avoid the nerve.

The second, or new method of securing this vessel, is by making an incision in the centre of the calf of the leg, cutting through the skin, fascia, gastrocnemius, and soleus; then dividing the fascia upon a director, and securing the vessel by passing the aneurism needle round the artery, in the same manner as in the former operation.

---

### THE DISSECTION OF THE SOLE OF THE FOOT.

BENEATH the integuments covering the sole of the foot, (the cuticle of which is much thicker from the constant pressure,) there is a considerable depth of firm and granulated fat, with threads of fibrous tissue extending irregularly through it. When this fat is dissected away, the plantar fascia is exposed, binding down the muscles, vessels, and nerves of the foot, which, besides serving the general purpose of an aponeurosis, performs the office of a ligament, by firmly connecting the two ends of the arch of the foot together.

The fascia is seen in the accompanying view.

*a a.* The fascia plantaris.

*b b.* The nerves supplying the toes, perforating the fascia to ramify superficially; branches of the plantar nerves, they are accompanied by small branches of the plantar arteries.

The plantar fascia is very thick and firm. It commences behind, at the under and back part of the os calcis, and thence advancing forwards, divides into three portions, which are expanded over the parts in the sole. The two lateral portions of the fascia are attached to the outer and inner edges of the foot. The middle portion, diverging as it advances forwards, terminates in front, by dividing into five distinct slips, which again divide into smaller slips. These slips penetrate inwards, and become united to the digital ends of the metatarsal bones. Through the spaces left between these slips, the tendons pass forwards to the toes.

The plantar fascia is firmly attached on its inner surface to the muscles beneath. Two processes of the fascia extend inwards between the muscles, so as to form partitions, separating them into distinct masses.

The plantar fascia being removed, the muscles beneath will be brought into view, consisting of three, which form the first layer.

*c.* The adductor pollicis.

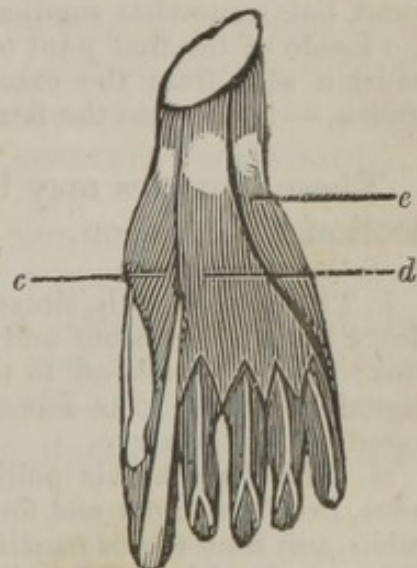
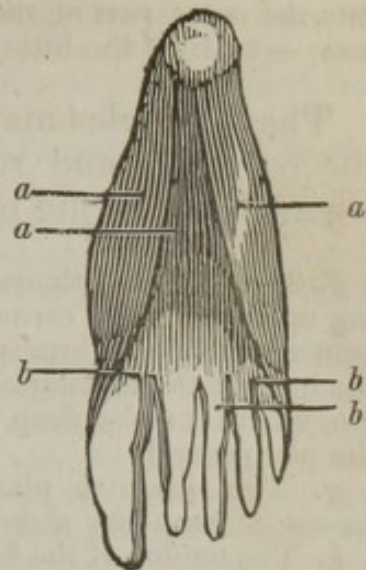
*d.* The flexor brevis digitorum.

*e.* The abductor minimi digiti.

*c.* The abductor pollicis *arises* fleshy, from the anterior and inner part of the protuberance of the os calcis, and tendinous from the same bone, where it joins with the naviculare, to be *inserted*, tendinous, into the internal sesamoid bone, and root of the first bone of the great toe. *Action*,—to pull the great toe from the rest.

*d.* The flexor ~~longus~~ <sup>*Brevis*</sup> digitorum *arises* narrow and fleshy, from the anterior inferior part of the tuberosity of the calcis, and from the aponeurosis plantaris; forms a thick fleshy belly, which sends off four small tendons, and these split for the passage of the tendons of the flexor longus, to be *inserted* into the second phalanges of the four small toes. *Action*,—to bend the first and second joints of the toes, but particularly the second. The tendon of the little toe is frequently wanting.

*e.* The abductor minimi digiti *arises* tendinous and fleshy, from the edge of a cavity on the under part of the protuberance of the os calcis, and from the root of the metatarsal bone of the little toe, to be *inserted*





into the outer part of the base of the first bone of the little toe. *Action*, — to draw the little toe outwards.

These muscles may be dissected from their attachment to the os calcis, and reflected, left hanging by their tendons, when the following part can be seen.

*f.* The external plantar artery, seen passing upon the massa carnea Jacobi Sylvii and beneath the flexor brevis digitorum, towards the base of the metatarsal bones of the little toe, where it sinks deep in the sole, to form the plantar arch.

*g.* The internal plantar artery, which passes beneath the abductor pollicis.

*h.* The tendon of the flexor longus pollicis, passing to be inserted into the base of the extreme phalanx of the great toe.

*i.* The tendons of the flexor longus digitorum, receiving

*j j.* The massa carnea Jacobi Sylvii, or the musculus accessorius, arising by two portions; the inner fleshy, from the sinusity of the os calcis: the outer tendinous, but soon becoming fleshy, from the fore and outer part of that bone.

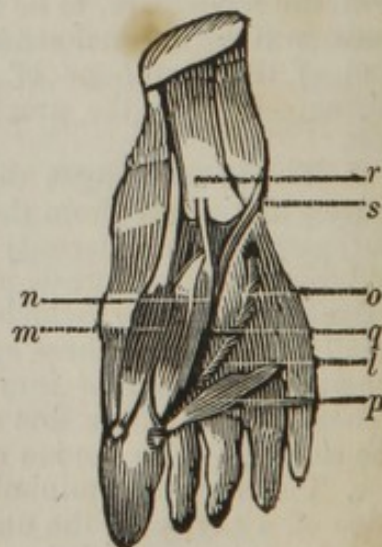
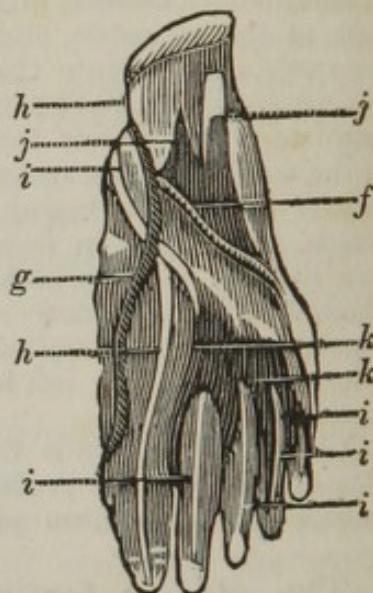
*k k k.* The lumbricales arising by four tendinous and fleshy beginnings, from the tendon of the flexor profundus, just before its division, running forwards, under the same general appearance with those in the hand, but somewhat smaller, to be inserted, by four slender tendons, at the inside of the first joint of the four small toes, into the tendinous expansion sent from the extensors to cover the upper part of the toes. *Action*, — to increase the flexion of the toes, and to draw them inwards.

These muscles may be reflected, when the following dissection will be seen.

*l.* The plantar arch, situated between the flexor longus digitorum and interossei muscles; the arch sends off in this situation the digital arteries. It is accompanied by the external plantar nerve.

*m.* The flexor brevis pollicis arises tendinous, from the under and fore part of the os calcis, and from the os cuneiforme externum. It is united with the abductor and adductor pollicis, to be inserted into the external sesamoid bones, and root of the first bone of the great toe. *Action*, — to bend the first joint of the great toe.

*n.* The adductor pollicis arises by a long thin tendon from the under part of the os calcis, from the os cuboides, from the ex-



ternal cuneiforme bones, and from the root of the metatarsal bone of the second toe, to be *inserted* into the external sesamoid bone, and root of the metatarsal bone of the great toe. *Action*,— to pull the great toe towards the rest.

*o.* The flexor brevis minimi digiti *arises* tendinous from the os cuboides, near the groove for lodging the tendon of the peroneus longus, and fleshy from the outer and back part of the metatarsal bone of the little toe, to be *inserted* into the anterior extremity of the metatarsal bone, and root of the first bone of the little toe. *Action*,— to bend this toe.

*p.* The transversalis pedis *arises* tendinous, from the under and fore part of the metatarsal bone of the great toe, and from the internal sesamoid bone. It forms a fleshy belly, which runs transversely between the metatarsal bones and flexor muscles of the toes, to be *inserted*, tendinous, into the under and outer part of the anterior extremity of the metatarsal bone of the little toe, and ligament of the next toe. *Action*,— to contract the foot, by bringing the roots of the outer and inner toes towards each other.

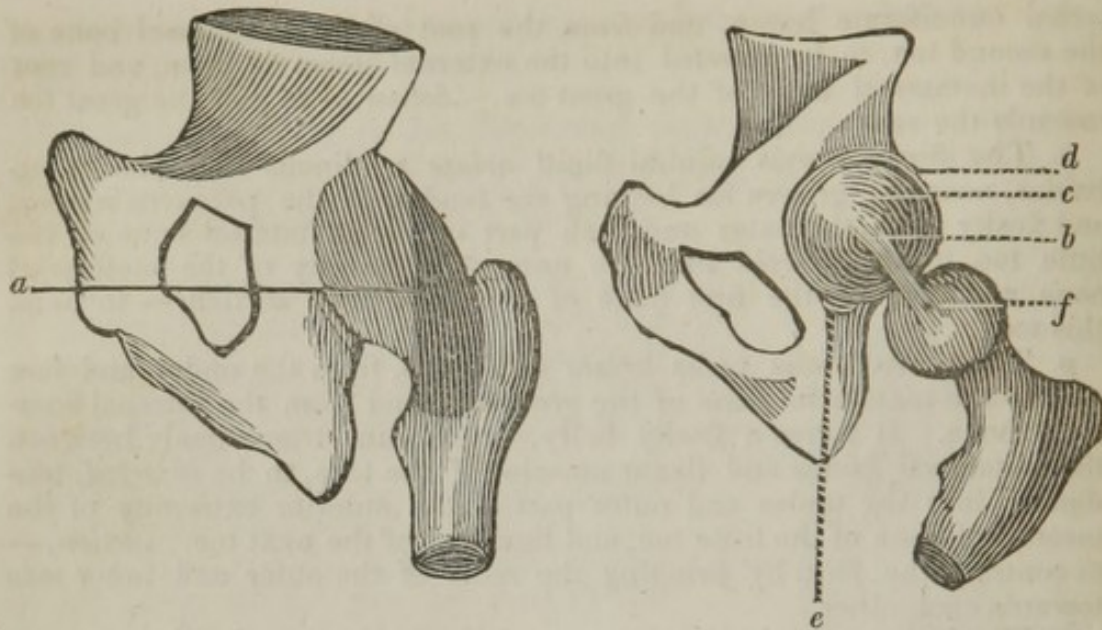
*q.* The interossei arise tendinous and fleshy from, and fill the spaces between, the metatarsal bones. Three, called interni, arise with single heads, and are placed in the sole; and four, termed externi or bicipites, arise with double heads, and appear on both sides of the foot. The insertions of the interossei are by slender tendons, into the expansion sent off from the tendons of the lumbricales and of the extensor muscles of the toes.

*r.* The long ligament of the calcis, taking its attachment from the projection of the os calcis, and attached to the under part of the os cuneiforme and os cuboides.

*s.* The tendon of the peroneus longus.

The posterior part of the leg and the sole of the foot having been described, and the relative position of the several parts considered, I have added the dissection of the ligaments, and given a description of the several dislocations.

When the dissector has removed the muscles and other soft parts of the inferior extremity, he may next proceed to dissect the ligaments, and examine the interior of the joints. The hip, probably, may be the first, and the external ligament to be dissected will be capsular. The following sketch, however, is intended to illustrate the ligaments of the hip-joint.



- a. The capsular ligament of the head of the femur.
- b. The ligamentum teres.
- c. The acetabulum.
- d. The cotyloid cartilage.
- e. The cotyloid ligament.

a. The capsular ligament, the largest and strongest of the articular ligaments, arises round the outside of the brim of the acetabulum, embraces the head of the thigh-bone, and incloses the whole of its cervix, as far as the root or outer extremity, round which it is firmly connected. The outer part of the capsular ligament is extended farther down than the inner, is reflected back upon the neck of the bone, and, in certain parts, forms folds: it is not everywhere of the same strength; it is thickest at its anterior and outer part, thinner where it is covered by the iliacus internus, and thinnest posteriorly, where the adjacent quadratus is opposed to it. It is strengthened on its outer surface by various additional slips, which run down from the fascia lata and surrounding muscles; but the strongest of these slips arises, with diverging fibres, from the anterior inferior spinous process of the os ilium.

The capsular ligament allows the thigh-bone to be moved to every side, and when its body is moved forwards or backwards, a small degree of rotation is performed round the cervix of the bone.

b. The ligamentum teres, or internal ligament, arises by a broad flat beginning from the under and inner part of the cavity of the acetabulum, and is connected with the substance termed gland of the joint; it runs backwards and a little upwards, becoming gradually narrower and rounder, to be fixed to the pit upon the inner surface of the ball of the femur: it prevents the bone from being so easily dislocated upwards or inwards, and assists in agitating the mucous substance within the joint.

d. The cotyloid cartilage is of a circular form, thickest at its posterior part or base, and thinnest externally, or at that part which is nearest the neck of the femur; it serves to increase the depth of the acetabulum, making its whole depth nearly two thirds of a complete globular cavity. It is firmly connected to the os innominatum, so as to be only removed with some degree of difficulty, and gives a firm origin at its external surface to the capsular ligament.

e. The cotyloid ligament extends from the inner and inferior part of the cotyloid cartilage, and is inserted into the inner part of the acetabulum. This ligament serves to fill up the space that otherwise would exist, where the vessels of the joint enter to supply its structure.

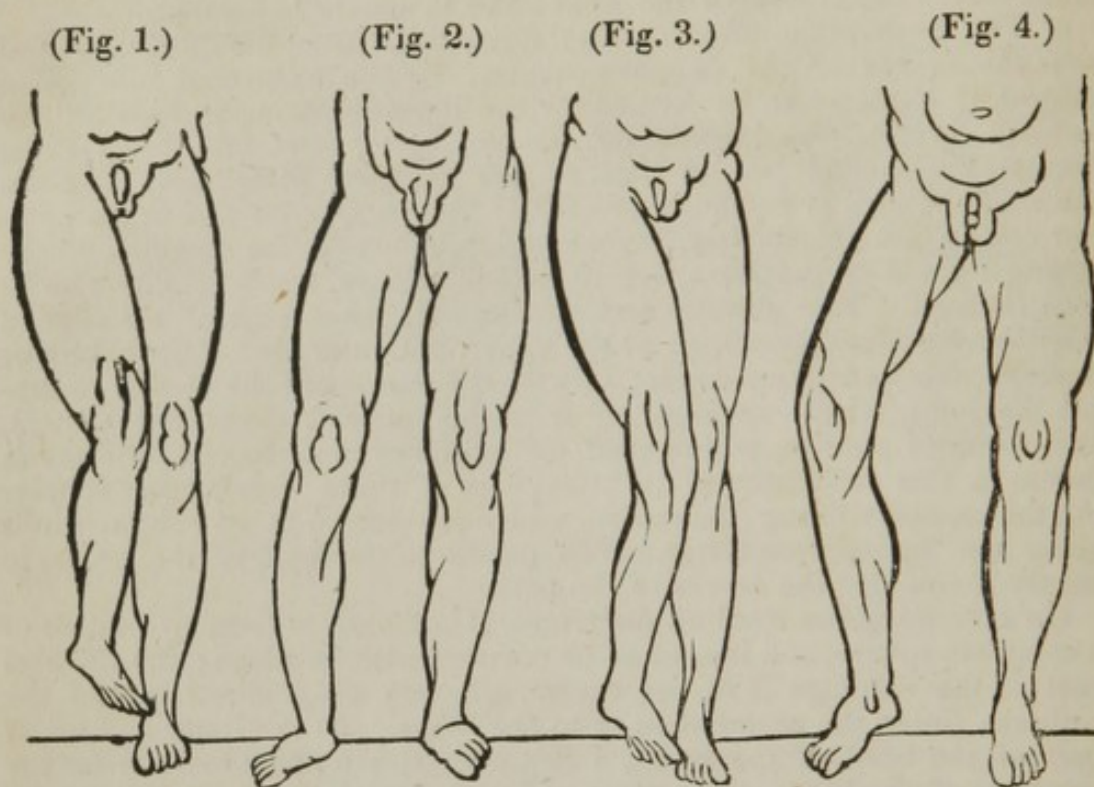
c. The acetabulum, of a cup-like form, situated at the outer part and near the centre of the os innominatum. When examined in a young subject, it is found to be formed by the ilium, ischium, and pubis; the ischium forming the largest part, or not quite three fifths; the ilium forming the second longest part, or less than two fifths; and the pubis the smallest part, or not quite one fifth. At the inferior and to the anterior part of the acetabulum, there is a depression for the situation of the synovial gland of the joint, which, when held up to the light, is to be seen through. The anterior and near to the lower part of the edge of this cavity is found wanting; at the upper and outer part of the obturator foramen, this deficiency exists; it is for the passage of the vessels to supply the joint, which are sent off from the internal circumflex, gluteal, and obturator arteries, which send off branches that pass into the acetabulum at this deficiency of its brim; one of these vessels, after supplying the cartilage lining the cavity, which is thinnest at its centre, winds along the ligamentum teres, and so passes to the head of the femur, to supply it and also the cervix of the bone.

On examining the head of the femur, it is found to form two thirds of a complete sphere, and is seen to be covered with cartilage; the thickest part of the cartilage is in the centre, whereas the thickest part of the cartilage lining the acetabulum is at the edges. At the inner and lower part of the head of the femur, a depression is to be observed for the insertion of the ligamentum teres, which is attached to this point, so as to prevent this ligament from getting between the femur and acetabulum, which would have caused considerable pain. There is also a contrivance in the acetabulum for the reception of this ligament, which is an irregular depression or hollow, so that it can be placed in it, which completely prevents any pressure on the ligament, even in the recumbent posture.

The muscles surrounding this joint in actual contact, are, at the anterior part, the rectus, psoas magnus, iliacus internus, a few fibres of the pectinalis, and the obturator externus; on the posterior part, the gluteus minimus, pyriformis, two gemini, obturator internus, and quadrator femoris. The additional muscles which surround the joint, not in contact with the capsular ligament, are the sartorius, tensor vaginæ femoris, adductor longus, brevis, and magnus, the gluteus maximus and medius, the biceps flexor cruris, the semitendinosus, semimembranosus, and gracilis.

Having considered the formation of the structure of the joint, the dissector may next bear in mind the several dislocations that are liable to happen to this articulation. They are four in number:—1. On the dorsum of the ilium, or upwards; 2. Into the foramen ovale, or downwards and inwards; 3. Into the ischiatic notch, or upwards and backwards, when the head of the femur is beneath the pyriformis muscle; 4. Upon the pubis, or upwards and inwards. The accompanying diagram is intended to accelerate the

knowledge of the position of the foot in these several displacements.



1. Dislocation upwards, upon the dorsum of the ilium.
2. Dislocation downwards, into the foramen ovale.
3. Dislocation upwards and backwards, into the ischiatic notch.
4. Dislocation forwards and upwards, upon the os pubis.

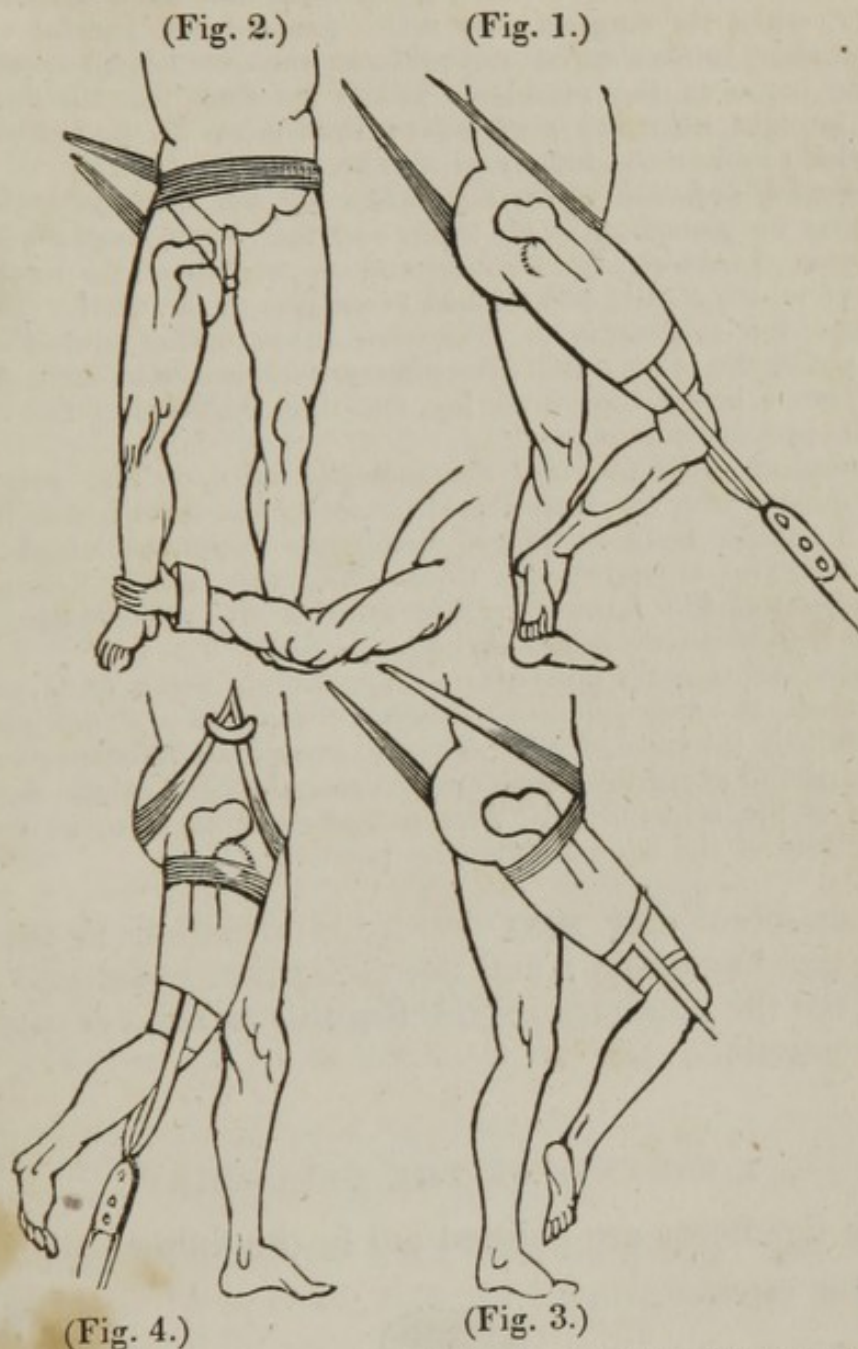1. Dislocation of the head of the femur upon the dorsum of the ilium. — The affected limb is from two to three inches shorter than the sound one; the knee is a little bent, and carried towards the other; the knee and foot are turned inwards, the knee being higher than the other; the great toe rests upon the dorsum of the opposite foot, and abduction of the limb is prevented.

2. Downwards and inwards into the foramen ovale. — The affected limb is from one to two inches longer than the other; when the patient stands erect, the knee projects, and is advanced and drawn from the other, and cannot be made to touch the sound knee without great violence. When the thigh is attempted to be straightened, the body is bent, owing to the psoas magnus and iliacus internus being in action, and the head of the femur being lower than the acetabulum.

3. Dislocation backwards into the ischiatic notch. — The limb is an inch, or an inch and a half shorter than the sound one; the knee and foot are turned inwards, and the toe rests upon the ball of the great toe of the sound limb.

4. Dislocation upon the pubis. — The limb is shorter; the great trochanter is raised, and the bullock is sunk; the knee, leg, and foot turn outwards, and the head of the bone may be felt a little above the level of Poupart's ligament, upon the pubis. It forms a round hard swelling, which moves when the limb is rotated and bent.

The modes of reducing these dislocations are pointed out in the accompanying diagram.



1. *Reduction of the dislocation of the head of the femur upon the dorsum of the ilium.*—Should the patient be a strong-muscled man, it may be necessary to have recourse to venesection, for the purpose of producing relaxation, as well as to prevent the subsequent inflammation. The man may then be placed in the warm bath at about  $100^{\circ}$ , gradually increasing it to  $110^{\circ}$ , until fainting is nearly produced. While in the bath, doses of tartrate of antimony with ipecacuanha may be administered, until nausea is excited. The patient may then be placed upon a table situated between two staples; a strong girt may then be placed between the thighs, the ends of which may be fastened to the staple at the head of the table; this girt is intended to fix the pelvis, which must be ascertained prior to the commencement of employing the extension. A wetted roller is to be placed round the thigh, just above

the knee, and upon this a leathern belt, with straps and rings attached to it, should be tightly buckled; the pulleys may now be fixed to the straps, when the knee is to be slightly bent, and then directed across the other, when the surgeon may make gradual and careful extension, resting at short intervals, (but not relaxing the extension,) so as to counteract the action of the muscles. When he finds that the head of the bone is brought near the acetabulum, the limb is to be rotated gently, under which motion the reduction will be accomplished.

2. *Method of reduction of the dislocation into the foramen ovale.*—The patient may be placed upon his back, and the pelvis should be fixed by the girt passed between the scrotum and upper part of the injured limb, the end of which should be attached to a staple in the wall. The pelvis being fixed, the surgeon is to grasp the ankle of the injured limb, and bring it across the other; or if the patient be a powerful man, the ankle may be drawn below the sound leg, and thus the head of the bone will resume its proper situation.

3. *Method of reduction into the ischiatic notch.*—The pelvis being fixed, extension may be commenced, drawing the limb across the other thigh. A napkin is to be placed under the dislocated thigh, that the surgeon may (by elevating the thigh while extension is being made,) raise the head of the femur over the brim of the acetabulum, and the reduction is in this way accomplished.

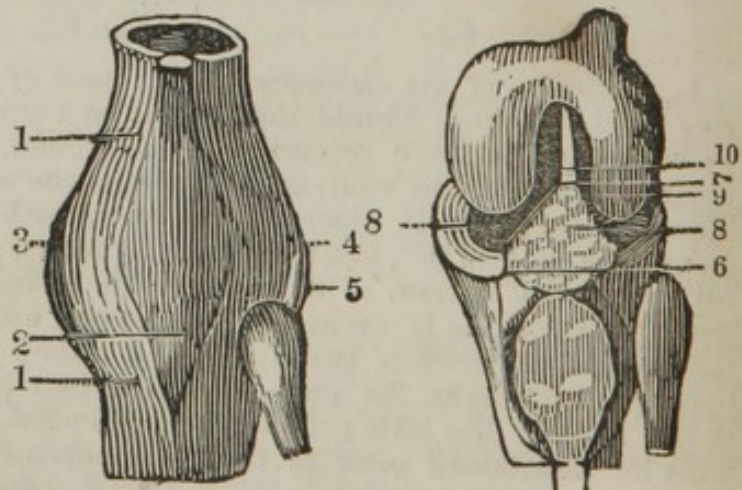
4. *Method when upon the pubis.*—The pelvis being fixed, extension may be made upwards and backwards, a towel having been previously passed beneath the injured thigh, so as to enable an assistant to raise the thigh during the extension, which will draw the head of the femur over the brim of the acetabulum. The extension is then to be continued until the head of the bone assumes its position.

The dissector may next direct his attention to the structure of the knee-joint; and the bones that enter into its formation are the condyles of the femur, the head of the tibia, and the patella.

#### LIGAMENTS OF THE KNEE-JOINT.

These ligaments are pointed out in the following plate.

1. 1. The capsular ligaments.
2. The ligamentum patellæ.
3. The internal lateral ligament.
4. The long external lateral ligament.
5. The short external lateral ligament.
6. The ligamenta alaria.
7. The ligamentum mucosum.



8. The semilunar cartilages.
9. The anterior crucial ligament.
10. The posterior crucial ligament.

1. A capsular ligament, or synovial capsule, arises from the whole circumference of the under end of the thigh-bone, some way above the margin of the articulating surfaces, and above the posterior part of the great notch between the condyles; it descends to be fixed round the head of the tibia, and into the whole margin of the articulating surface of the patella, in such a manner that the patella forms part of the capsule of the joint. The capsular ligament is of itself remarkably thin, but is covered by the general aponeurosis of the limb, and by the tendons of muscles surrounding the joint, so as to acquire a considerable degree of strength. At the back part of this ligament there are some fibres, termed the *ligamentum posticum*, as also the *ligamentum posticum Winslowii*, a broad expansion, extended obliquely across the back part of the joint, between the external condyle and the head of the tibia, where it is connected with the tendon of the *semimembranosus* muscle. Other smaller ligamentous bands extend irregularly upon the back part of the capsule.

2. The ligament of the patella arises from a depression behind the apex of that bone, and is fixed to the tuberosity of the upper and fore part of the tibia. By the intervention of this ligament, the muscles inserted into the patella are enabled to extend the leg. A *bursa mucosa* is placed between the ligament and the front of the tibia, just above the tuberosity. Above the bursa, a large quantity of fat occupies the space between the posterior surface of the ligament and the synovial membrane of the joint.

3. The internal lateral ligament is broad and flattened. It is attached to the internal condyle of the femur, whence it descends, increasing in breadth, and is fixed to the upper part and inside of the tibia.

4. The long external lateral ligament is narrower, but thicker and stronger than the former, arising from the tubercle above the external condyle of the *os femoris*, and fixed to the fibula, a little below its head.

5. The short external lateral ligament arises from the external condyle, lower than the long, and is inserted into the tibia, some fibres also passing to be attached to the head of the fibula.

When these ligaments have been examined, the synovial membrane may be opened, and the interior of the joint examined. The first ligaments seen are

6. The *ligamenta alaria*, divided into major and minor, two folds of the capsular ligament, situated between the under part of the condyles of the femur and the sides of the patella. Its appearance is of a fatty kind, or of a species of synovial gland. From these ligaments

7. The *ligamentum mucosum* takes its origin, which ascends to attach itself between the condyles of the femur. This ligament serves to support the alar ligaments, and also allows the synovia to flow up it, to lubricate the under part of the femur.

8. The semilunar cartilages placed upon the articular surfaces of the tibia. The external margin of each cartilage is convex and thick, its internal margin has a sharp delicate edge. Each cartilage presents



above, an excavated surface, adapted to the convexities of the condyles, and below, a flattened surface adapted to the head of the tibia. Externally, the cartilages are connected with the lateral ligaments, while their internal thin edges are loose in the cavity of the joint. The anterior and posterior extremities of each cartilage are fixed to the head of the tibia, in front of, and behind its middle protuberance, as also to the femur, by ligamentous expansions, which have received the name of oblique ligaments. The two cartilages are united in front by a transverse ligament extended between their convex borders, and also behind, by a similar transverse ligament. The cartilage covering the condyles of the femur is thicker in the middle than in the circumference. The cartilage covering the head of the tibia is the reverse. The cartilage covering the posterior surface of the patella is thicker than that upon the tibia.

The crucial ligaments. — The anterior runs downwards from the inner part of the external condyle, to be fixed to a pit before the rough protuberance in the middle of the articulating surface of the head of the tibia: the posterior descends from the inner part of the inner condyle, to be fixed to a pit behind the rough protuberance.

These ligaments, in the extended state of the leg, prevent it from going forwards beyond a straight line with the thigh. When the knee is bent, they allow the foot to be turned outwards, but not in the contrary direction.

When the formation and structure of the joint have been considered, we are to bear in mind that the muscles surrounding it are, the rectus, the two vasti, cruralis, sartorius, gracilis, biceps, semitendinosus, semimembranosus, gastrocnemius, plantaris, and popliteus. The dislocations that usually occur at this articulation are divided into those peculiar to articulation between the condyles and the tibia, and those of the patella. The former, or those, more properly speaking, of the knee itself, are four in number; two complete, and two partial. The two complete are

1. *The dislocation of the tibia backwards.* — The limb is shorter; the condyles of the femur project; a depression may be observed in the situation of the ligamentum patella; the leg is bent forward, and a projection may be felt in the ham, which is the head of the tibia.

2. *Forwards.* — The tibia projects forwards; the thigh bone is thrown backwards. The patella and tibia are drawn forwards by the action of the quadriceps muscle.

The two partial dislocations are laterally, either internally or externally. In the first, the external condyle rests upon the internal articular surface, on the inner part of the tibia, and the internal condyle projects and forms a tumor at the inner side of the knee; the contrary takes place in the other situation. In regard to the treatment of these dislocations, they require gentle extension, and the head of the tibia may be pushed towards its proper situation; and when the reduction is accomplished, the usual means should be had recourse to, to avert the inflammation.

The patella may be dislocated in three directions: inwards, outwards, and upwards. These dislocations are easily recognised. Should they be either inwards or outwards, the limb may be extended, and the thigh bent towards the body, so as to relax the rectus, two vasti, and cruralis; pressure may then be made upon the patella, so as to raise it over the edge of the condyle. If dislocated internally, the pressure should be on the inner part of the patella, so as to lift the outer part over the inner condyle; and in the opposite manner, in the other accident. Dislocation cannot occur upwards, without a rupture of the ligamentum patella, in which case the leg should be left straight, and the thigh bent towards the body; and the limb should be kept in this situation until the two divided parts unite, which they will do in the course of six weeks or two months, when the limb should have a splint placed at its back part, so as to prevent the knee from being too suddenly bent, which might occasion a displacement, or, rather, a disunion of the ligament.

The dissector may now direct his attention to the rest of the ligaments of the inferior extremity.

The upper part of the fibula is connected to the tibia by an anterior and posterior ligament, which have been termed anterior superior and anterior inferior, or, occasionally, these ligaments have been called the capsular.

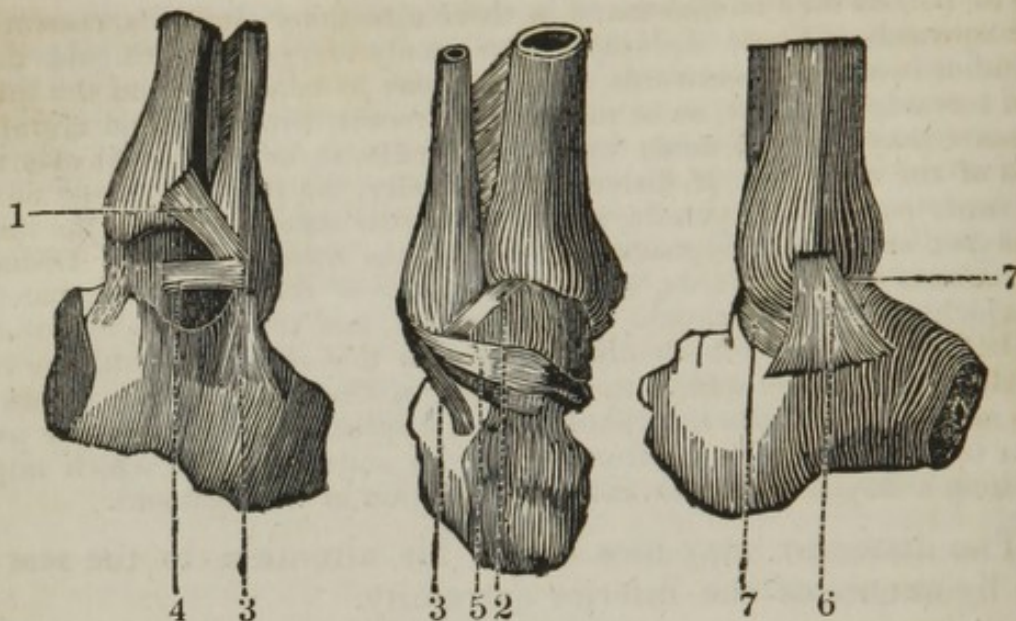
The interosseous ligament connects the fibula to the tibia, one edge of which is fixed to the ridge or angle at the outer and back part of the tibia, the other to the corresponding ridge at the inner side of the fibula: it fills the space between the tibia and fibula, like the interosseous ligament of the fore arm, and is of a similar structure, being formed of oblique fibres, and perforated in various places, for the passage of vessels and nerves.

At its upper part there is a large opening, where the muscles of the opposite sides are in contact, and where blood-vessels pass to the fore part of the leg.

The ligaments of the inferior extremity of the fibula are called anterior inferior and posterior inferior, according to their situations, arising from the edges of the semilunar cavity of the tibia, and fixed to the malleolus externus of the fibula.

The ligaments between the ends of the tibia and fibula join the two bones so firmly together, as to admit of no sensible motion.

These ligaments are seen in the following plan, as also those entering into the formation of the ankle-joint.



1. The anterior inferior ligament, connecting the anterior part of the fibula to the tibia.
2. The posterior inferior ligament, connecting the back part of the fibula to the tibia.
3. The perpendicular ligament of the ankle, or middle external lateral.
4. The anterior external lateral ligament.
5. The posterior external lateral ligament.
6. The internal lateral, or deltoid ligament.
7. The capsular ligament.

The ankle-joint is formed by the tibia superiorly and internally, externally by the fibula, and inferiorly by the astragalus. These bones are connected together by five ligaments.

3. The perpendicular ligament takes its origin from the under part of the fibula, and descends to be inserted into a small projection peculiar to the inner part of the os calcis.

4. The anterior external lateral ligament arises from the anterior part of the inferior part of the fibula, and crosses to be inserted into the anterior and outer part of the astragalus.

5. The posterior external lateral ligament arises from the posterior part of the inferior portion of the fibula, and is inserted into the back part of the astragalus.

6. The deltoid ligament, or internal lateral, arises from a small projection peculiar to the under part of the malleolus internus of the tibia, and descends in a radiated manner to be inserted into the astragalus, os calcis, and os naviculare.

7. The capsular ligament, or sinovial capsule, connects the three bones together which form this joint, and sends off a continuation of its structure, which enters the joint to be reflected over the articulating surfaces of the tibia, fibula, and astragalus. The anterior part of the capsular ligament is the most lax part, and when it is opened at this point, there is a species of fatty substance, which fills up a slight depression between the tibia and astragalus. On opening this joint, the anterior

part of the astragalus may be observed to be the broadest part of the articulating surface.

The tendons that surround this joint are, the peroneus longus and brevis externally, or round the outer ankle; the tibialis anticus, flexor longus digitorum, and flexor longus pollicis (together with the posterior tibial artery and nerve, the nerve being nearer the os calcis) internally, or round the inner ankle; the tibialis anticus, extensor longus, or proprius pollicis, the extensor longus digitorum, sending off the peroneus tertius, anteriorly.

Having observed the construction and surrounding parts of the ankle, we may next consider what are the accidents that generally occur to it.

The end of the tibia, where it articulates with the astragalus, may be dislocated inwards, outwards, forwards and backwards.

*Of the dislocation inwards, or the foot outwards, termed "Potts's fracture"* — In this accident the inner part of the tibia, or malleolus internus, is thrown more inwards, and forcibly projects against the skin, so as occasionally to rupture it, producing a compound dislocation; the foot is thrown outwards, and its inner edge rests upon the ground. The anatomical derangement that takes place in this accident is, that the fibula is fractured about two inches above the malleolus externus; it is either separated from its articulation with the tibia, or else a small slip of the tibia is fractured, the external lateral ligaments are relaxed, and the deltoid ligament is ruptured, or the end of the tibia giving origin to this ligament is broken off, which I have seen in two or three cases; this small fractured portion feeling somewhat like a small horse-bean, after the reduction was accomplished. The method to be pursued for the treatment of this accident is, that the leg should be bent, so as to relax the gastrocnemius; slight extension may be then made, when the parts will resume their proper situation; the limb may be kept upon its outer side, placing the leg previously on Sharp's splint, and the usual means may be had recourse to, so as to prevent inflammation. If a compound dislocation, the wound will be at the inner ankle, the edges of which should be brought carefully together, so as to reduce it, if possible, to a simple dislocation.

*Of the dislocation outwards, or the foot inwards.* — The ends of the tibia are thrown outwards, the foot is turned inwards, the sole facing the opposite limb, and its outer edge resting upon the ground; the outer ankle projects, forming a considerable prominence; the foot and toes point downwards. The derangements that take place in this accident are, a fracture of the malleolus internus, which allows the tibia to pass from off the articulating surface of the astragalus; by which means the foot turns inwards, the deltoid ligament is relaxed, the three external laterals are ruptured, or else the end of the fibula is fractured, in which case they are entire. Should it be a compound dislocation, the wound is at the outer ankle.

*Of the dislocation forwards.* — In this accident the foot is shortened and fixed; the heel is proportionably lengthened as the foot is shortened; the tibia rests upon the naviculare; the toes point downwards. The derangements that take place are, that the under part of the fibula is fractured, and this portion advances with the tibia, and is placed by its side; the malleolus externus remains in its natural situation, but the

fibula is broken about three inches above it.\* The capsular ligament is partially ruptured, the deltoid somewhat lacerated, but the external ligaments remain entire.

*Dislocation of the tibia backwards, or the foot forwards.* — In this accident the foot is lengthened, and the heel consequently shortened; the fibula is fractured, and the deltoid ligament ruptured. The occurrence of this accident is extremely rare.

The remaining ligaments of the foot consist of

A capsular ligament, which joins the articular surface of the os calcis to that of the astragalus.

A number of short ligaments, lying in the fossa of the astragalus and of the os calcis, and forming the ligamentous apparatus of the sinuous cavity, which assists in fixing the two bones strongly together.

A capsular, connecting the astragalus to the os naviculare, and admitting of the lateral and rotatory motions of the foot.

Capsular ligaments, connecting the whole tarsal bones together. First anterior ligament, connecting the fibula to the astragalus. Second anterior ligament, connecting the astragalus to the naviculare. Third anterior, connecting the anterior part of the calcis to the os cuboides.

Plantar ligaments, running on the under part of the tarsal bones upon the capsular ligaments.

The dorsal ligaments, running on the upper part of the capsular ligaments of the tarsus already mentioned.

The long ligament of the calcis, arising from the projection of the os calcis, and attached to the under part of the os cuneiforme and os cuboides, allowing the tendon of the peroneus longus to run under it.

From the strength of the ligaments which unite the tarsal bones to each other, and from the plainness of their articulating surfaces, little motion is allowed.

The bones of the metatarsus are fixed to those of the tarsus by capsular ligaments, strengthened by the dorsal, plantar, and lateral, the nature of this joint being the same as that between the carpus and metacarpus.

Capsular and lateral ligaments, uniting the metatarsal to the first phalanges.

The transverse ligaments join the extremities of these bones together.

Capsular and lateral ligaments connect the phalanges to each other, and vaginal ligaments confine the tendons to the phalanges.

## DISSECTION OF THE SUPERIOR EXTREMITY.

WHEN the arm has been extended upon a board, and brought at right angles with the body, the skin may be reflected, as is indicated by the accompanying sketch, the first incision commencing at the sternum, and carried in a direct line towards the centre of the bend of the arm,

\* See Sir Astley Cooper on Dislocation, sixth edition, page 227.

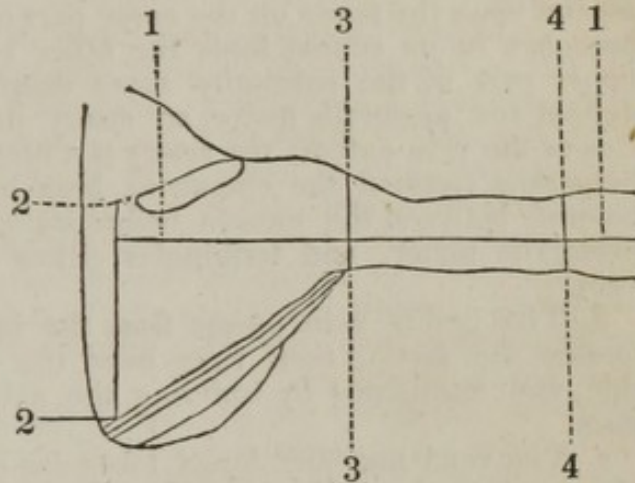
between the condyles of the humerus; an incision may then be made along the centre of the sternum, when the angles formed by these two divisions of the skin may be reflected. A third incision may be made, when the dissector may require to expose the arm to a greater degree, by making a transverse cut across the arm, at about its upper third; and a fourth may afterwards be made at or near the bending of the elbow.

1. 1. First incision, commencing at the sternum, and ending between the condyles of the humerus.

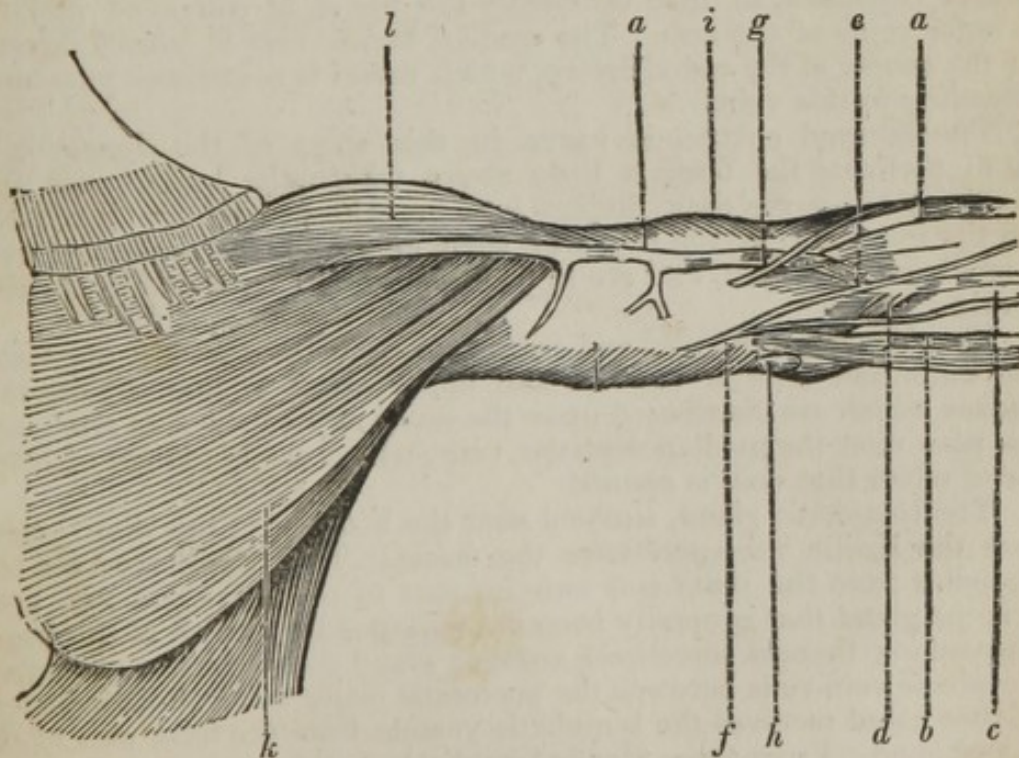
2. 2. Second incision, along the middle of the sternum.

3. 3. Third incision.

4. 4. Fourth incision.



When the skin has been fully reflected, the following parts will be brought into sight.



- a a.* The cephalic vein, seen ascending on the outer part of the arm, and running between the pectoralis major and deltoid muscle.
- b.* The basilic vein.
- c.* The vena mediana longa, sending off

- d.* The median basilic vein.
- e.* The median cephalic vein.
- f.* The internal cutaneous nerve.
- g.* The external muscular cutaneous nerve.
- h.* A lymphatic gland.
- i.* The fascia covering the muscles of the upper arm.
- k.* The pectoralis major.
- l.* The deltoid muscle.

*a a.* The cephalic vein is seen in this stage of the dissection to ascend upon the fascia on the outer part of the arm. It receives several branches in its course from the other cutaneous veins; it runs at the upper part of the extremity more deep seated, sinking between the deltoid and pectoralis major, an artery passing out between these muscles as the vein enters; the artery is a branch of the axis of the thoracica humeralis (termed the cutaneous branch.) The cephalic vein having entered between the muscle before stated, runs over the tendon of the pectoralis minor, and terminates either in the axillary or subclavian vein.

*b.* The basilic vein passes from the inner part of the fore arm, perforates the fascia, then runs over the brachial artery on its inner side, and terminates by entering the axillary vein, which it assists to form.

*c.* The vena mediana longa takes its commencement from a venous plexus about the ball of the thumb and palm of the hand, proceeds up the anterior part of the arm between the cephalic and basilic veins, and near the bending of the elbow divides into the mediana basilica and the mediana cephalica, so that ultimately the blood is conveyed into the two outer veins of the arm. The median basilic vein is placed directly over the course of the radial artery, which vessel is sometimes punctured in bleeding in this vein.

*f.* The internal cutaneous nerve in this stage of the dissection is seen to perforate the fascia a little above where the basilic vein runs beneath it; the nerve then divides into branches, which are distributed upon the inner part of the fore arm, some of which run under and over the median basilic vein, and are in danger of being wounded in opening the vein.

*g.* The external muscular and cutaneous nerve perforating the fascia at the outer and inferior third of the upper arm. It then divides into branches which are distributed upon the outer part of the fore arm; and twigs pass over the median cephalic vein, which are in danger of being divided when that vein is opened.

*h.* The lymphatic gland, situated near the bending of the elbow, close where the basilic vein perforates the fascia. This gland receives the lymphatics from the inner and anterior part of the hand and fore arm, and is the gland that generally becomes enlarged by a prick of the finger in dissection; there is sometimes another gland found higher up, where the cephalic vein runs between the pectoralis major and deltoid muscles; the latter gland receives the lymphatic vessels from the back part of the arm and hand. From these glands lymphatic vessels ascend to terminate in the axillary glands.

*i.* The fascia of the arm covers both the anterior and posterior part of the arm, and is a continuation of the cellular tissue that is placed over the pectoralis major. This fascia serves to bind down the muscles giving them support; the deltoid is uncovered by the fascia.

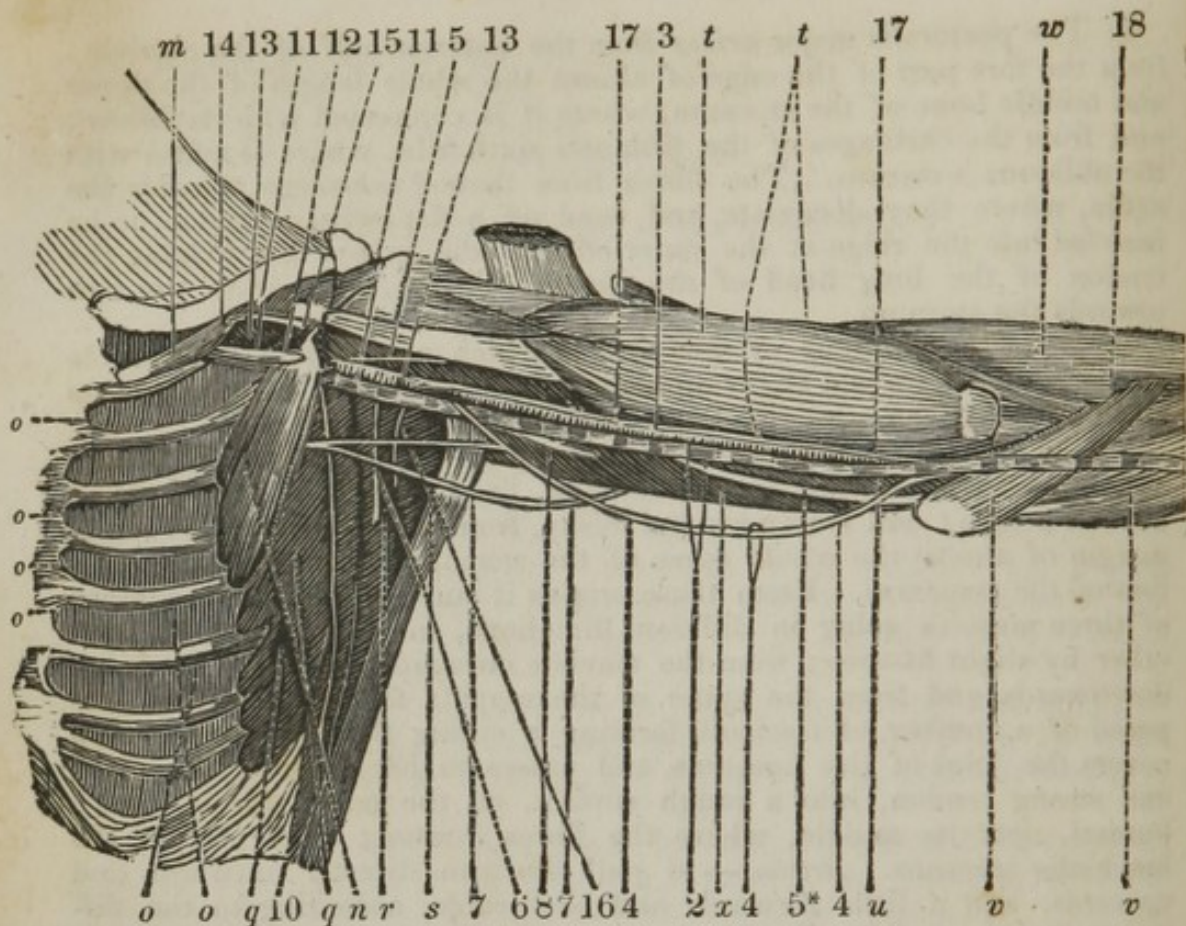
*k.* The pectoralis major *arises* from the anterior half of the clavicle ; from the fore part of the edge of almost the whole length of the upper and middle bone of the sternum, where it is connected with its fellow ; and from the cartilages of the fifth and sixth ribs, where it mixes with the obliquus externus. The fibres from thence converge towards the axilla, where they decussate, and send off a flat twisted tendon, to be *inserted* into the ridge at the outer edge of the groove for lodging the tendon of the long head of the biceps. *Action*,—to draw the arm towards the sternum.

Between the portions of this muscle which arises from the clavicle and sternum, there is a slight separation, in consequence of which these portions have been considered by some as two distinct muscles.

*l.* The deltoid muscle *arises* fleshy, from all the outer part of the clavicle unoccupied by the pectoralis major, from which it is separated by a small fissure ; and tendinous and fleshy, from the acromion, and lower margin of almost the whole spine of the scapula, opposite to the insertion of the trapezius. From these origins it runs, under the appearance of three muscles going in different directions, and separated from each other by slight fissures ; from the clavicle outwards, from the acromion downwards, and from the spine of the scapula forwards ; and is composed of a number of fasciculi, forming a strong fleshy muscle, which covers the joint of the humerus, and passes to be *inserted*, by a short and strong tendon, into a rough surface, on the outer side of the os humeri, near its middle, where the fibres intermix with part of the brachialis internus. *Action*,—to pull the arm directly outwards and upwards, and a little forwards and backwards, according to the different directions of its fibres.

When these parts have been considered, the dissector may make a perpendicular incision in the centre of the pectoralis major, and reflect the two sides of it. He can also make a similar incision across the centre of the deltoid, and it can also be reflected. When this has been done, the fascia may be removed. The following parts are next to be dissected.





- m.* The subclavius.  
*n.* The pectoralis minor.  
*o. o.* The intercostal muscles.  
*q. q.* The serratus magnus anticus.  
*r.* The subscapularis.  
*s.* The teres major and the latissimus dorsi.  
*t.* The biceps flexor cubiti, and on its inner edge the coraco-brachialis.  
*u.* The brachialis internus.  
*v.* The pronator radii teres and flexor muscles of the fore arm.  
*w.* The supinator radii longus.  
*x.* The triceps.  
 2. The basilic vein, ascending to terminate in the axillary vein.  
 3. The median nerve.  
 4. 4. The internal cutaneous nerve.  
 5. The external muscular and cutaneous nerves.  
 5\*. The ulnar nerve.  
 6. The scapular nerve.  
 7. 7. The intercosto humeral nerve and cutaneous nerve of Wrisberg.  
 8. The muscular spiral nerve.  
 10. The external inferior respiratory nerve.  
 11. The axillary vein, situated anteriorly and inferiorly to the artery, receiving  
 12. The cephalic vein, the inferior portion of which has been cut off.  
 13. The axillary artery. The nerves surrounding it have been detached, so as to bring the artery fully into view; sending off  
 14. The arteria thoracica suprema.  
 15. The thoracica humeralis, forming an axis, sending off the acromion, the cutaneous, and muscular branches.

16. The subscapular artery.

17. The brachial artery, seen to be the continued trunk of the axillary, running at first between the coraco-brachialis and tendon of the biceps; then between the coraco-brachialis and triceps; then between the biceps and triceps, upon the brachialis internus. The artery is seen to be crossed above the elbow-joint by the median nerve.

18. The radial artery.

*m.* The subclavius *arises* tendinous, from the cartilage of the first rib. It becomes fleshy, and runs outwards, under the clavicle, increasing in breadth, to be *inserted* into the under surface of the clavicle, from near its head, as far outwards as the coracoid process of the scapula. *Action*,—to pull the clavicle, and with it the scapula, downwards and forwards.

*n.* The pectoralis minor *arises* tendinous and fleshy, in a serrated manner, from the third, fourth, and fifth ribs, near their cartilages. Passing obliquely outwards, it becomes gradually narrower, to be *inserted*, tendinous, into the point of the coracoid process of the scapula. *Action*,—to bring the scapula downwards and forwards, or, in laborious respiration, to raise the ribs.

*o.* The intercostal muscles are divided into the external and internal.

The intercostales externi *arise* from under the edge of each rib, excepting the twelfth. They run obliquely downwards and forwards, from the spine to the joining of the ribs with their cartilages, from which, to the sternum, they are discontinued; (that place being occupied by an aponeurosis,) to be *inserted* into the upper edge of each rib, immediately below that from which they take their respective origin.

The intercostales interni *arise* the same as the externi; but they begin at the sternum, and run downwards and backwards, decussating the former muscles like the strokes of the letter X, and continuing as far as the angle of the ribs, from which to the spine they are wanting. *Inserted* in the same manner as the externi. *Action* of the intercostales interni, as well as of the externi,—to enlarge the cavity of the thorax, by elevating the ribs in the time of inspiration; and the obliquity of the one set balancing that of the other, allows them to be raised more immediately upwards.

From the obliquity of their fibres, they are found to possess a greater power in raising the ribs, than fibres going in a perpendicular direction.

The intercostales externi cease near the sternum, and the interni near the spine, to admit the ready motion of the ribs; for had the former been continued to the sternum, and the latter to the spine, the parts of these muscles supposed to be thus fixed, would of course have become antagonists to the rest.

*q.* The serratus magnus anticus *arises* from the nine superior ribs, by an equal number of fleshy digitations. They run obliquely upwards and backwards, upon the side of the thorax, and between it and the subscapularis, to be *inserted* fleshy, into the whole length of the base of the scapula, and in a manner folded round it, between the insertion of the rhomboideus and the origin of the subscapularis. *Action*,—to move the scapula forwards or downwards, according to the direction of its different digitations, and when the scapula is forcibly raised, as in violent inspiration, to assist in dilating the thorax by elevating the ribs.

r. The subscapularis *arises* fleshy, from the three costæ, and whole inner surface of the scapula. It is composed of a number of tendinous and fleshy portions, which run in a radiated manner, and make prints on the bone; in its passage outwards, adhering to the capsular ligament, to be *inserted*, tendinous, into the upper part of the internal protuberance at the head of the humerus. *Action*, — to roll the arm inwards, to draw it to the side of the body, and to prevent the capsular ligament from being pinched.

s. The teres major and latissimus dorsi are inserted into the inner part of the bicipital groove. A further description is given in the dissection of the back and posterior part of the arm.

t. The biceps flexor cubiti *arises* by two heads; the outer one, called its long head, begins by a slender tendon from the upper edge of the glenoid cavity of the scapula, passes over the ball of the humerus within the joint, and, in its descent, is enclosed in a groove upon the upper and fore part of that bone, by a ligament which proceeds from the capsular ligament and adjacent tendons. The inner one, called its short head, tendinous and fleshy, from the coracoid process of the scapula, in common with the coraco-brachialis. A little below the middle of the fore part of the humerus, the two heads unite, and form a thick fleshy belly, running to be *inserted*, by a strong roundish tendon, into the tubercle at the upper and inner part of the radius, sending a tendinous expansion to the aponeurosis of the fore arm, which it assists in forming. *Action*, — to bend the fore arm, and to assist the supinator muscles in rolling the radius outwards, and, of course, to turn the palm of the hand upwards.

The coraco-brachialis *arises* tendinous and fleshy, from the fore part of the coracoid process of the scapula, in common with the short head of the biceps, to which it adheres the greater part of its length, to be *inserted*, tendinous and fleshy, into the internal part of the humerus, near its middle. *Action*, — to bring the arm obliquely upwards and forwards.

u. The brachialis internus *arises* fleshy, from the middle of the humerus, at each side of the deltoides, attached to the under and fore part of the bone. It runs over the joint, adhering firmly to the capsular ligament, to be *inserted*, by a strong short tendon, into the coronoid process of the ulna. *Action*, — to bend the fore arm, and to prevent the ligament of the joint from being pinched.

v. w. The pronator radii teres and flexor muscle of the fore arm are described in the dissection of the fore arm. The supinator radii longus also, and the triceps, in the dissection of the back of the arm.

2. The basilic vein, having pierced the fascia, ascends on the inner part of the arm, and terminates by entering the axillary vein.

3. The median nerve arises by two branches, one on either side. The nerve descends on the outer side of the artery till within an inch of the elbow, where it crosses the artery, and is placed on the inner side; it then passes between the pronator radii teres, or between its origin, and sinks between the flexor sublimis upon the flexor profundus, to be distributed upon the hand.

4. The internal cutaneous nerve descends upon the basilic vein, generally perforates the fascia above the vein, and is distributed upon the inner part of the fore arm by dividing into two sets of branches, internal and external; these ramify upon the skin, and branches surround and run over the median basilic vein.

5. The external cutaneous nerve, (musculo-cutaneous, or perforans *casserii*,) is the third branch of the axillary plexus. It passes through the belly of the coraco-brachialis muscle. After its passage, it continues its course obliquely across the arm, betwixt the biceps flexor cubiti and the brachialis internus. It gives twigs to these muscles, and appears as a superficial nerve on the edge of the supinator longus. It runs over the outer condyle, and is distributed to the integuments on the outside of the fore arm and back of the hand.

5\*. The ulnar nerve descends along the inner side of the arm upon the triceps, near the line of its union with the brachialis internus. From the lower part of the arm the nerve descends between the inner condyle and olecranon to the fore arm. In its progress down the arm it gives off filaments, some of which are distributed to the triceps, and others to the integuments.

6. The scapular nerve takes its origin from the axillary plexus, and descends upon the subscapular muscle, to be distributed upon it, the *teres minor*, and insertion of the *latissimus dorsi*.

7. The intercosto humeral nerve passes out from the second or third intercostal space, being a branch of one of the dorsal nerves, runs down the axilla superficially, and unites with a small twig from the axillary plexus, termed the cutaneous nerve of *Wrisberg*, when the two descend to be distributed upon the skin at the back of the triceps muscle.

8. The spiral, or muscular spiral nerve, is apparently formed by all the nerves entering into the axillary plexus; and when the sheaths of the nerves are slit open, is found to be composed of fibrillæ from each of the trunks, excepting from that of the first dorsal. It is rather larger than any other nerve of the superior extremity, and is distinguished by its spiral direction. It is at first situated between the axillary artery and the ulnar nerve, and passes obliquely downwards between the two heads of the triceps extensor cubiti, and afterwards behind the humerus to the outside of the elbow. While passing behind the humerus, it gives several branches of considerable size to the different heads of the triceps; some of them accompanying the branches of the *arteria spiralis*, and terminating on the heads of the extensors of the hand. Immediately behind the body of the humerus, it transmits a subcutaneous branch, which is distributed upon the muscles and integuments on the posterior part of the fore arm, anastomosing at last with the nerves on the back part of the hand. The trunk of the nerve, having arrived at the elbow, is lodged in a fissure between the brachialis internus and supinator radii longus, and there gives off branches to the extensors and to the supinators of the hand.

10. The external respiratory nerve is a branch of the inferior cervical; it passes beneath the clavicle, and over the first rib, to be distributed upon the *serratus magnus anticus* muscle.

11. The axillary vein, formed by the union of the two *vena comotes* that accompany the brachial vein. It is situated superficially in the axilla, but in the dissection of this cavity, the lymphatic or axillary glands are nearer the integuments. These glands, in the preceding sketch, have not been exhibited, to render the other parts more clear. The axillary vein receives the basilic vein, then passes under the insertion of the *pectoralis minor*, sometimes receiving, 12. The cephalic vein; it then passes under the clavicle and over the first rib, when it assumes the name of subclavian vein.

13. The axillary artery.

To render the ramifications of this vessel more apparent, I have subjoined the following diagram, with a view to facilitate the knowledge of its various branchings.

1. The axillary artery, the continued trunk of the subclavian, which I have divided in two stages of its course.

2. The first stage of its course, being situated between the clavicle and tendon of the pectoralis minor.

3. Second stage, or from the tendon of the pectoralis minor to where it runs over the tendon of the latissimus dorsi. The axillary artery in the first stage generally sends off two branches, and in its second stage five branches; in the whole seven branches. These branches are

4. The thoracica suprema.

5. The thoracica humeralis, running over the tendon of the pectoralis minor, when it divides into three branches.

6. The acromion branch.

7. The cutaneous branch.

8. The muscular branch.

9. The thoracica longa.

10. The thoracica alaria.

11. The scapularis.

12. The posterior articular, or circumflex.

13. The anterior circumflex, or articular artery.

14. Intended to show where the vessel runs over the tendon of the latissimus dorsi, to become

15. The brachial or humeral artery, which descends at first between the tendon of the latissimus dorsi and coraco-brachialis, then between the coraco-brachialis and triceps, afterwards between the inner edge of the biceps upon the triceps, then upon the brachialis internus at the inner border of the biceps to the bend of the elbow, where it generally divides into

16. The radial artery.

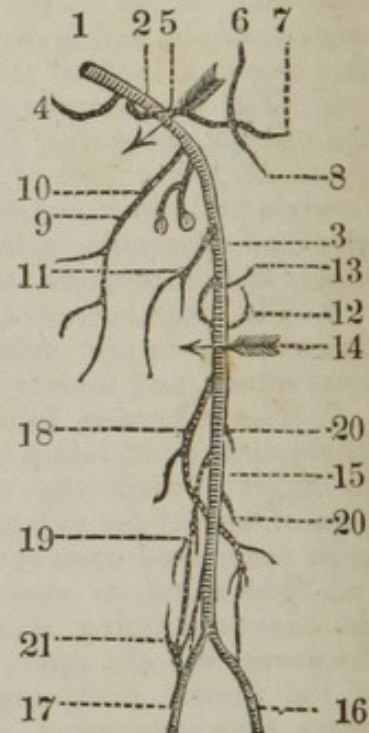
17. The ulnar artery. The brachial artery sends off

18. The profunda superior, to accompany the muscular spiral nerve, and ultimately anastomosing with the recurrent branch of the radial artery.

19. The profunda inferior, which descends upon the triceps in company with the ulnar nerve, and anastomoses with the recurrent branch of the ulnar artery.

20. Muscular and nutritious branches.

21. The ramus anastomoticus magnus.



1. The axillary artery, placed in the axilla, between the subscapularis and serratus magnus anticus, surrounded by the lymphatic glands and fat, by the veins, and also by the large nerves which form the brachial plexus; it gives some small branches to the adjacent muscles and

nerves;—but its principal branches are the *thoracica vel mammaria externæ*, three or four branches, which are described under particular names; as

4. The *thoracica suprema*, which arises opposite the first or second rib, gives branches to the *serratus* and *intercostales*, and to the pectoral muscles and skin.

5. The *thoracica humeralis vel acromialis*, which goes off opposite the *thoracica suprema*, runs over the tendon of the *pectoralis minor*, and forms an axis, from which three branches take their origin.

6. The *acromion* passes under the *deltoid* muscle to supply it, the *acromion* process, adjacent parts, and anastomoses with the *articular arteries*, as also with the *supra scapular* and *dorsalis scapulæ inferior*.

7. The *cutaneous* branch, which passes between the *deltoid* and *pectoralis major*, where the *cephalic vein* enters. It is distributed upon the superficial parts about the shoulder.

8. The *muscular* branch, or branches that supply the *pectoralis major*, *deltoid*, and *coraco-brachialis*.

9. The *thoracica longa vel mammaria externa*, sends twigs to the *axillary glands*; but goes chiefly to the *serratus*, *pectoralis*, *mamma*, and *integuments*, and inosculates with branches of the *thoracica superior*.

10. The *thoracica axillaris vel alaria* goes off from or near the *thoracica humeralis*, and is lost upon the *axillary glands* and *fat*, frequently dispersing branches upon the under edge of the *scapularis*, and upon the *pectoralis* and *serratus*.

11. The *scapularis* arises at the under edge of the *subscapularis*, and soon divides into the *scapularis interna*, and the *dorsalis scapulæ inferior*. The *scapularis interna* runs near the inferior edge of the *scapula*, and sends off many large branches, the principal part of which are dispersed upon the *latissimus dorsi*, *teres major*, and *subscapularis*; branches to the muscles arising from the *coracoid process*, to the *capsular ligament*, and to the *axillary glands*, which have large anastomoses with each other.

The *dorsalis scapulæ inferior*, immediately after leaving the *internal scapular artery*, turns round near the *cervix* of the *scapula*, between the *inferior costa* of the bone and *teres major*, to the *fossa infra-spinata*. Upon the posterior surface of the *scapula* it spreads out into branches of considerable size, which are dispersed upon the muscles covering the under and back part of the bone, and extend also to the *capsular ligament*; while the trunk, ascending, inosculates with that of the *dorsal artery* of the *scapula*.

12. The *circumflexa vel articularis posterior* arises directly opposite to the former, or by a common root with it, and is by much the larger of the two. It passes first between the *subscapularis* and *teres major*, and then turns round between the back part of the *humerus* and long head of the *triceps*, and the *deltoides*. It sends branches to the *periosteum* and joint, to the short head of the *biceps* and *coraco-brachialis*, to the *triceps* and *subscapularis*, and runs in a circular manner to the *deltoides*. Its extreme branches anastomose with those of the *anterior circumflex artery*. After giving off these different branches, the *axillary artery* emerges from behind the edge of the *pectoralis major*, passing over the insertion of the *latissimus dorsi*, and then descends to the fore arm, where it is termed the *humeral*, or *brachial artery*.

13. The *circumflexa vel articularis anterior*, sent off between the

subscapularis and teres major, passes in a transverse direction between the heads of the coraco-brachialis and biceps, immediately below the joint of the humerus. It is dispersed upon the muscles which cover it, and upon the periosteum and capsular ligament of the joint.

15. The humeral artery descends behind the inner edge of the coraco-brachialis, covered by the tendinous aponeurosis of the arm, and having the triceps extensor cubiti at the back part of it, then on the inner edge of the biceps upon the brachialis internus. In its course, it gives branches to the muscles, integuments, periosteum, and bone; also branches under the coraco-brachialis to the capsule of the joint and parts adjacent to it; branches to the triceps and coraco-brachialis; various branches to the biceps and brachialis internus. Besides the following:—

18. The profunda superior *vel* spiralis, arises near the upper part of the arm, at the insertion of the latissimus dorsi and teres major, taking a spiral direction downwards and outwards, between the triceps and bone, terminating at the outer condyle of the humerus, by a large communicating radial, or profunda-radial branch. The arteria profunda sends branches upwards, which inosculate with others from the humeral and scapular arteries. The principal branches run to the coraco-brachialis and triceps, and to the muscles at the outer part of the elbow.

19. The profunda inferior, or minor. This artery is frequently a branch of the profunda superior, but more commonly an original branch sent off from the trunk of the artery, near the middle of the arm. It gives branches to the muscles and other parts at the inside of the arm, and terminates about the inner part of the humerus.

21. The ramus anastomoticus magnus comes off a little above the elbow, and bestows branches to the brachialis internus, to the under end of the triceps, and to the muscles, ligaments, and parts in general about the elbow-joint. Besides these, there are several other branches (mentioned above) sent in succession from the trunk of the humeral artery into the muscles and parts adjacent, which are shorter than the rest, and run in a transverse direction, especially those to the biceps. One small branch, termed nutritia, or medullaris, goes into the substance of the bone, through the foramen near its middle, to supply the bone. The trunk of the humeral artery, having sent off the different branches which belong to the arm, passes to the middle of the bending of the elbow, between the aponeurosis and tendon of the biceps upon the brachialis internus. About an inch below the elbow, it commonly divides into two principal arteries, the radial and ulnar. It happens, sometimes, that this division takes place about the middle of the arm; and, in certain instances, as high as the axilla, and occasionally the interosseal artery will be given off at the bifurcation of the humeral.

The dissector should pay great attention to the following parts, first observing the boundaries of the axilla. It is bounded superiorly by the subscapularis and humerus; anteriorly, by the pectoralis major; posteriorly, by the latissimus dorsi; internally, by the subclavius, clavicle and upper part of the serratus magnus anticus. Secondly, he should consider that when the axilla is dissected, beneath the skin

some fat of a red color is seen ; that fascia is situated beneath it ; that the axillary glands are beneath the fascia ; the vein is situated beneath or more superficially ; that the artery, and the artery at the middle of its course, is surrounded by the axillary plexus of nerves ; therefore, that vessel is only enabled to be secured at the upper and lower part of its course. The first situation is where the artery is beneath the clavicle, and before it has passed under the tendon of the pectoralis major.

*The method of securing the axillary artery at the first stage of its course.*— The arm being elevated, an incision may be made of a semilunar form, having the concavity of the incision upwards ; the skin is divided, together with a few fibres of the platysma myoides. The clavicular origin of the pectoralis major is then to be cut through ; this being divided, care must be taken not to wound the cephalic vein, which should be depressed, when the axillary vein is to be sought for and also depressed, and the axillary artery will be found behind it ; the aneurism needle should then be passed from below upwards, taking care not to wound the vein. The artery is situated here in a triangular border, formed, superiorly, by the clavicle and subclavian muscle ; inferiorly and internally, by the first rib ; and externally, by the pectoralis minor. The axillary artery, at the inferior part of its course, can be secured with much greater ease. The arm should be separated from the side, the hand brought supine ; the head of the humerus is then to be felt in the axilla, and an incision made parallel to and between the pectoralis major and latissimus dorsi, the skin, cellular substance, and fascia being cut through ; the axillary vein and median nerve are next observed ; the vein may be drawn on the tricipital, the nerve on the bicipital side ; then, by bending the fore arm, the nerves are relaxed and may be separated from the artery, and the aneurism needle may be passed round the artery, from the ulnar to the radial side.

The dissector must consider the position of the brachial artery, that it is accompanied by the two vena comotes, also by the median nerve, which is placed at the upper three fourths of the artery on the radial side, but at the under fourth on the ulnar side, the nerve having crossed



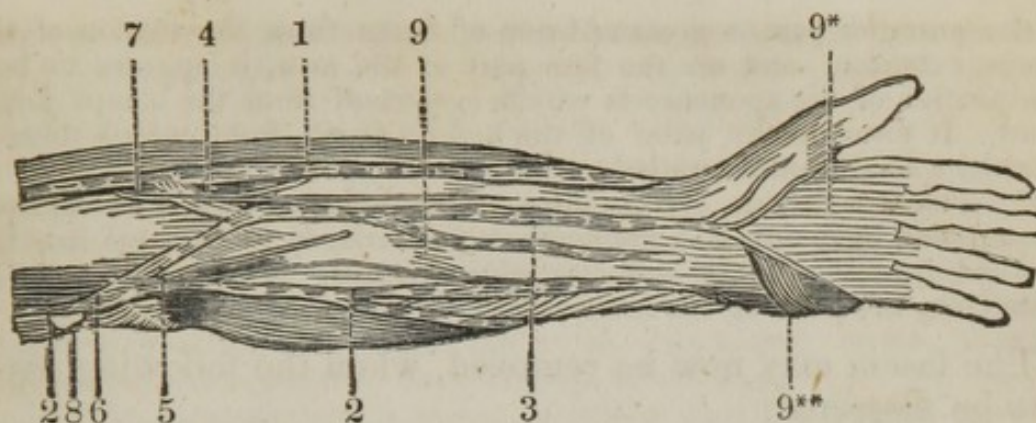
the artery. This vessel can be readily secured in any part of its course; and, by attending to the relative situation of these parts, little danger will ensue from wounding other parts. Attention should be particularly directed to the various and numerous anastomoses that the branches of the axillary and brachial arteries make, by which we become acquainted how the circulation is carried on, in case the primary vessel be tied. Should the axillary require to be taken up, the supra scapular artery will principally carry on the circulation, by anastomosing with the articular, the acromion, and scapular branches, also by the anastomosing branches of the two profunda arteries. Should the brachial be secured, the circulation will be carried on by the profunda artery anastomosing with the recurrent of the ulnar and radial; and should the brachial artery be secured above the origin of the profunda, then the circulation will be carried on by the anastomosing branches of the profunda, which unite with the articular and scapular arteries of the shoulder-joint.

The dissector, after having completely understood the upper arm, may next direct his attention to the anterior part of the fore arm, which is pointed out in the following dissection.

---

#### DISSECTION OF THE ANTERIOR PART OF THE FORE ARM.

A PERPENDICULAR incision may be made along the arm, commencing from between the condyles of the humerus, and carried to the palm of the hand; two other incisions may then be made, the first at the upper third of the fore arm, the other a little above the wrist-joint. When the integuments have been reflected, the following parts will be brought into view.



1. The cephalic vein.
2. The basilic vein.
3. The vena mediana longa, dividing into
4. The vena mediana cephalica, entering the cephalic vein.
5. The vena mediana basilica, entering the basilic vein.
6. The internal cutaneous nerve.
7. The external muscular cutaneous nerve.
8. A lymphatic gland.
9. The fascia.
- 9\*. The fascia palmaris.
- 9\*\*. The palmaris brevis.

1. The cephalic vein commences by the union of several branches from the back of the hand ; it ascends on the outer part of the fore arm, receiving several veins in its course, and then passes up the arm to enter either the subclavian or axillary vein. Near the bending of the elbow it receives the median cephalic vein.

2. The basilic vein commences from a small branch at the inner side of the little finger, called *salvatella*, passes up the fore arm at its ulnar side, pierces the fascia a little above the elbow-joint, and ultimately terminates in the axillary vein. Near the elbow it receives the median basilic vein.

3. The *mediana longa* is formed by a plexus at the ball of the thumb and palm of the hand ; it ascends between the two other cutaneous veins, and just below the elbow divides into the median cephalic and median basilic veins ; the latter passes in the course of the upper part of the radial artery, but superficial to the fascia.

6. The internal cutaneous nerve divides in the lower part of the arm into filaments, which, descending over the front and inner side of the elbow-joint, continue their course along the front, inner side, and back part of the fore arm to the hand. They are distributed principally to the skin, and some of them communicate with the filaments of the external cutaneous nerve.

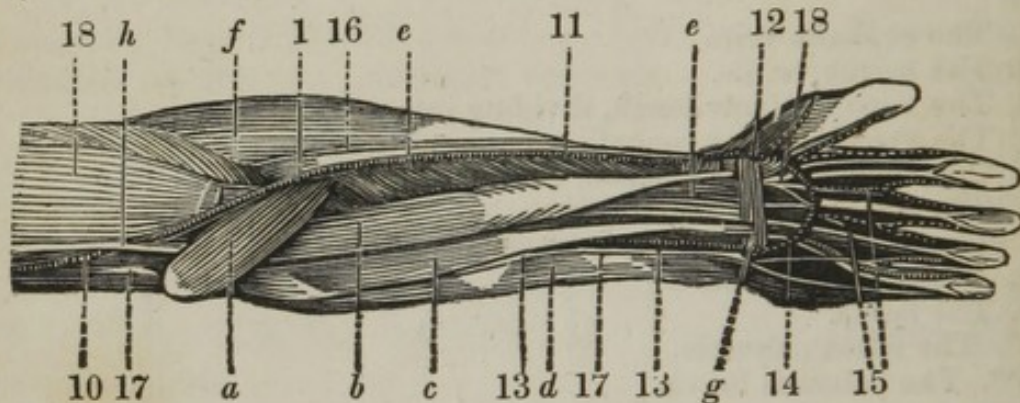
7. The external cutaneous nerve, descending over the front of the elbow-joint, continues its course along the front and outer side of the fore arm to the wrist. In its progress, it distributes many filaments to the skin, and it terminates in filaments, some of which are distributed to the back of the hand, and others extend into the palm.

9. The fascia is continued from the intermuscular ligaments which pass down to the condyles of the *os humeri*. It is attached to the condyles, and it adheres firmly to the olecranon of the *ulna*. It receives,

on the posterior part, a great addition of fibres from the tendon of the triceps extensor; and on the fore part of the arm, it appears to be a continuation of the aponeurosis which is sent off from the biceps flexor cubiti. It forms in the palm of the hand a fascia, from which there is attached a small muscle, called

9\*\*. *Palmaris brevis*, arising by small bundles of fleshy fibres, from the annular ligament, and aponeurosis palmaris, to be inserted into the skin and fat covering the abductor minimi digiti. *Action*, — to assist in contracting the palm of the hand.

The fascia may now be removed, when the following parts may be dissected.



- a. The pronator radii teres.
  - b. The flexor carpi radialis.
  - c. The palmaris longus.
  - d. The flexor carpi ulnaris.
  - e. The flexor sublimis digitorum.
  - f. The supinator radii longus.
  - g. The annular ligament.
  - h. Biceps and muscles of the arm.
  10. The brachial artery, sending off
  11. The radial artery, which at first descends between the tendon of the biceps and pronator radii teres, then between the supinator radii longus and pronator radii teres over the tendon of that muscle, being then placed between the supinator radii longus and flexor carpi radialis; first on the flexor sublimis, then on the flexor longus pollicis, and afterwards on the pronator radii quadratus, running then round to the back of the hand, towards the space between the metacarpal bone of the thumb and fore finger, where it dips down to the palm of the hand to form the deep-seated palmar arch.
  12. Superficialis volæ, anastomosing with the superficial palmar arch.
  13. The ulnar artery, seen only at the under half of the fore arm, and placed between the flexor carpi ulnaris and sublimis upon the flexor profundus, runs over the annular ligament, to form
  14. The superficial palmar arch, sending off
  15. The digital arteries.
  16. The radial nerve.
  17. The ulnar nerve.
  18. The median nerve seen in the palm, to send off digital branches to supply the thumb and fingers, except the little and half of the ring finger.
- a. The pronator radii teres arises fleshy, from the internal condyle of the humerus; passes obliquely across the upper end of the flexor mus-

cles of the wrist, and is of a tapering form, to be *inserted* thin, tendinous, and fleshy, into the middle of the posterior part of the radius. *Action*,— to roll the radius inwards, by which it brings the palm of the hand backwards, or into a state of pronation.

*b.* The flexor carpi radialis *arises* tendinous and fleshy, from the inner condyle of the humerus, between the pronator radii teres and flexor sublimis, to which it firmly adheres. It forms a long tendon, which passes down near the radius, goes through a fossa in the os trapezium, and becomes flat at its inferior extremity, to be *inserted* into the fore and upper part of the metacarpal bone of the fore finger. *Action*,— to bend the wrist, and to assist in the pronation of the hand.

*c.* The palmaris longus *arises* tendinous from the internal condyle of the humerus, soon becoming fleshy, and sending off a long slender tendon, to be *inserted* into the annular ligament, and into the aponeurosis palmaris. *Action*,— to bend the hand, and stretch the aponeurosis palmaris.

This muscle is frequently wanting, but the aponeurosis is always to be found.

*d.* The flexor carpi ulnaris *arises* tendinous, from the internal condyle of the humerus, and, by a small fleshy beginning, from the corresponding side of the olecranon. It passes along the inner side of the ulna, adhering to it, for a considerable way down. A number of its fleshy fibres likewise arise from the aponeurosis of the fore arm, to be *inserted*, by a strong tendon, into the os pisiforme. *Action*,— to assist the flexor carpi radialis in bending the wrist.

*e.* The flexor digitorum sublimis *vel* perforatus, *arises* tendinous and fleshy, from the internal condyle of the humerus, tendinous from the root of the coronoid process of the ulna, and membranous and fleshy from the middle of the fore part of the radius. Its fleshy belly sends off four round tendons before it passes under the annular ligament. In their course, they are connected to those of the following muscle, by fine membranous webs, and upon the fingers are inclosed in strong tendinous sheaths, to be *inserted* into the anterior and upper part of the second phalanges of the fingers, split and twisted, to form a passage or kind of sheath for the tendons of the flexor profundus. *Action*,— to bend the second, and then the first phalanx of the fingers.

*f.* The supinator radii longus will be described in the dissection of the back part of the fore arm.

*g.* The annular ligament *arises* from the os naviculare and trapezium, and crosses the wrist to be *inserted* into the os pisiforme and cuneiforme. It serves to bind down the tendons, preventing them from starting out of their place.

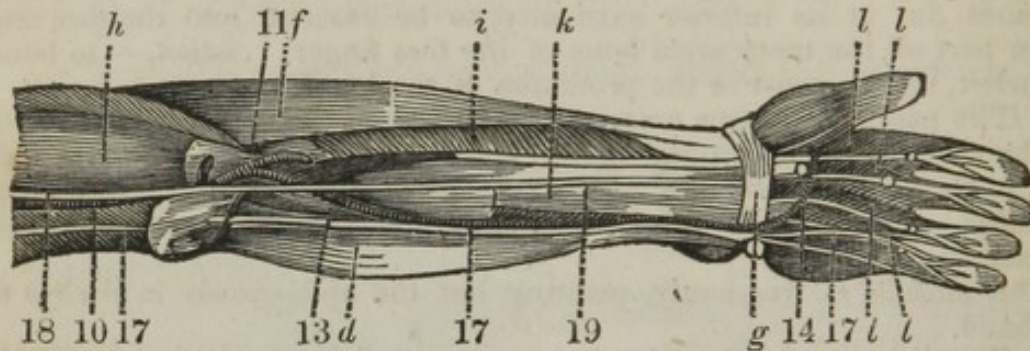
*h.* The biceps, and other muscles of the arm, have already been described.

10. The arteries will be considered after the dissection is completed.

16. The radial nerve, or superficial branch of the muscular spiral, which makes its appearance at the outer part of the arm, between the supinator radii longus and brachialis internus, here divides into two sets of branches; a deep-seated set, which perforate the supinator radii brevis, to supply the muscles on the back of the fore arm; the superficial branches, or radial nerve, accompanies the radial artery until near the insertion of the supinator radii longus, when the nerve runs under that tendon to the back of the hand, to be distributed upon the thumb, index, middle, and half the ring fingers.

The remaining parts will be hereafter described, as they are again seen in the following plate.

The dissector can now reflect the pronator radii teres, flexor carpi radialis, palmaris longus, flexor carpi ulnaris and sublimis, and making a transverse incision through the centre and turning them back, the following parts can be dissected.



- d. The flexor carpi ulnaris.
- f. The supinator radii longus.
- g. The annular ligament.
- h. Biceps and muscles of the arm.
- i. The flexor longus pollicis.
- k. The flexor profundus digitorum.
- l. The four lumbricales.
- 10. The brachial artery, seen bifurcating into
- 11. The radial artery.
- 13. The ulnar artery.
- 14. The superficial palmar arch.
- 17. 17. 17. The ulnar nerve.
- 19. The median nerve.

*i.* The flexor longus pollicis manus *arises* by an acute fleshy beginning, from the fore part of the radius and interosseous ligament, the origin extending from the tubercle of the bone, as far as the pronator quadratus, by a distinct fleshy slip, from the internal condyle of the humerus. This muscle is situated between the flexor sublimis and profundus, to be *inserted* into the last joint of the thumb, after its tendon has passed under the annular ligament. *Action*, — to bend the last joint of the thumb.

*k.* The flexor digitorum profundus *vel perforans arises* fleshy, from the external side and upper part of the ulna, for some way down, and from a large share of the interosseous ligament, also from the radius, descends behind the flexor sublimis, and splits into four tendons, a little before it passes under the annular ligament, and these pass through the slits in the tendons of the flexor sublimis, to be *inserted* into the anterior and upper part of the third phalanges of the fingers. *Action*, — to bend the last joint of the fingers.

The tendons send off

*l.* The four lumbricales, which are *inserted* with the tendons of the interossei muscles, into about the middle of the first phalanges. *Action*, — to bend the first phalanx, and increase the flexion of the fingers, while the long flexors are in full action.

13. The ulnar artery is here seen to arise from the brachial; it is considered as the continued trunk of that artery. It passes under the pronator radii teres, flexor carpi radialis, palmaris longus, and flexor sublimis digitorum, and is placed upon the flexor profundus, being crossed by the median nerve. It runs over the annular ligament to form the superficial palmar arch.

17. The ulnar nerve comes off from the axillary plexus. It extends along the inside of the triceps, frequently perforating some of its fleshy fibres, and, near the elbow, slants a little backwards, to get in a groove between the inner condyle of the humerus and olecranon of the ulna. From thence it passes to the fore arm, perforating the heads of the flexor carpi ulnaris, joins the ulnar artery a little below its origin, and accompanies that vessel, lying on the ulnar side of it. Under the axilla, it sometimes receives a branch from the spiral nerve; and from this connexion, or from the trunk of the ulnar nerve itself, a subcutaneous branch is sent off, which runs between the triceps and integuments, furnishing branches to the latter for a considerable way along the fore arm. Near the under end of the humerus, a twig or two commonly go to the inner edge of the triceps. Under the bending of the elbow, a branch is given off to be distributed upon the belly of the flexor carpi ulnaris. About the middle of the fore arm, a filament is transmitted, which adheres to the ulnar artery, furnishing small twigs to the coats and sheath of the artery, and terminating in the corresponding parts of the wrist, and integuments of the palm. Near the end of the ulna, a considerable branch, termed dorsalis, is sent off, which, turning between the flexor ulnaris and ulna, is directed to the back part of the hand.

The dorsal nerve sends branches to the integuments of the wrist and metacarpus, which have various anastomoses with others of the spiral nerve. It sends off a branch, which proceeds along the ulnar side of the little finger; and at the heads of the metacarpal bones, another, splitting into two branches, which run along the adjacent sides of the auricular and ring fingers. The trunk of the nerve passes with the corresponding artery over the annular ligament into the palm, where it is covered by the aponeurosis palmaris. In the palm it divides into superficial and deep branches; the former destined chiefly for the fingers, the latter for the deep region of the hand.

The superficial palmar nerve sends branches to the short muscles of the little finger: a branch to the ulnar side of the little finger: and another, which is soon split into two smaller branches: one to the radial side of the little finger, the other to the ulnar side of the ring finger.

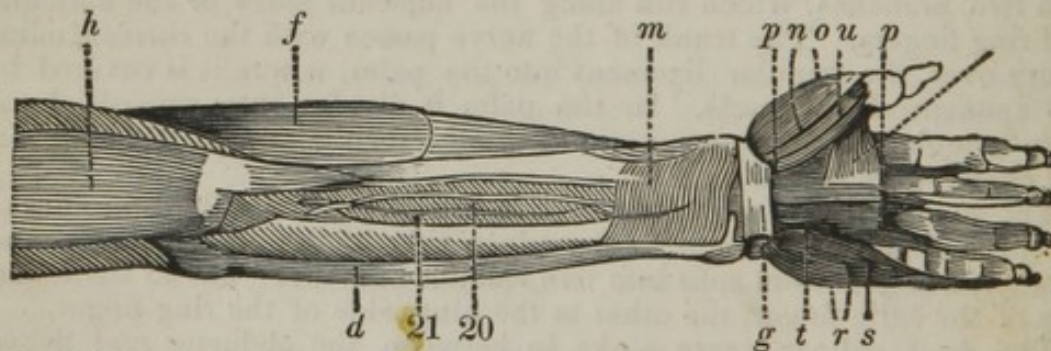
The deep palmar nerve sinks in between the abductor and flexor brevis minimi digiti, or perforates the head of the latter, and forms an arch which accompanies the deep arch of the arteries, under the tendons of the flexors, and the lumbricales.

19. The median, or radial nerve, comes from the middle and lower part of the plexus; it is formed by fasciculi from all the nerves which enter the plexus, and is nearly of a similar size with the spiral nerve. It descends in the arm, along the anterior surface of the humeral artery, to which, and to the deep veins, it adheres closely by cellular substance. In this course it does not give off any considerable branches: twigs, however, are sent from it to the coats of the adjacent vessels. At the bending of the elbow, it crosses over the humeral artery, and the tendon of the brachialis internus, perforating the back part of the pronator radii teres. It afterwards descends between the flexor sublimis and pro-

fundus, lying in the middle of the interval of the radial and ulnar artery in its way to the hand. When it approaches the fore arm, it transmits branches to the pronator radii teres and integuments near that muscle. In the flexure of the arm, it furnishes branches to the pronator radii teres, flexor carpi radialis, and flexor sublimis, and an interosseous branch, which, in some subjects, receives an addition from the spiral nerve.

The interosseous nerve gives branches to the flexor longus pollicis, and to the flexor profundus digitorum, descends upon the interosseous ligament with the vessels of that name, and terminates in the pronator radii quadratus. Near the hand, it sends a branch, dividing into others which supply the muscles and integuments forming the ball of the thumb. The trunk of the median nerve, having given branches to the fore arm, passes under the annular ligament of the wrist, where it divides into branches which are situated behind the aponeurosis palmaris and superficial arch of the arteries. The principal branches in the palm come off in three divisions, from which seven nerves of considerable size are distributed to the thumb and fingers. Of these, two go to the thumb, and one to the radial side of the fore finger; the rest come off from two forked trunks, near the heads of the metacarpal bones, and supply the adjacent sides of the fore and middle, and of the middle and radial side of the ring finger. These branches send twigs through the aponeurosis to the integuments of the palm, and others to the muscoli lumbricales; after which they accompany the arteries sent off from the superficial palmar arch, bestowing twigs to the adjacent parts of the fingers, at the points of which they terminate, by numerous fibres.

The flexor longus pollicis and profundus may now be reflected in a similar manner as the other muscles, when the following dissection can be made.



- d.* The flexor carpi ulnaris.
- f.* The supinator radii longus.
- g.* The annular ligament.
- h.* Biceps and muscles of the arm.
- m.* The pronator radii quadratus.
- 20.* The interosseal artery, a branch of the ulnar, descending upon the interosseous ligament, beneath the flexor profundus.
- 21.* The interosseal nerve, a branch of the median, accompanying the artery.
- n.* The abductor pollicis.
- o.* The opponens pollicis.
- p.* The flexor brevis pollicis.
- q.* The adductor pollicis.

- r. The abductor minimi digiti.
- s. The flexor brevis minimi digiti.
- t. The adductor ossis metacarpi minimi digiti.
- u. The lumbricales.

m. The pronator radii quadratus *arises* broad, tendinous, and fleshy, from the under and inner part of the ulna. The fibres run transversely, to be *inserted* into the under and fore part of the radius. *Action*,— to assist the pronator radii teres.

n. The abductor pollicis *arises* broad, tendinous, and fleshy, from the annular ligament, and from the os trapezium. It lies immediately under the skin, and over the opponens pollicis, to be *inserted*, tendinous, into the outer side of the root of the first bone of the thumb. *Action*,— to draw the thumb from the fingers.

o. The opponens pollicis *arises* fleshy, from the os trapezium and annular ligament; it lies immediately under the abductor pollicis, to be *inserted*, tendinous and fleshy, into the under and fore part of the metacarpal bone of the thumb. *Action*,— to bring the thumb inwards, so as to make it oppose the fingers,— from which circumstance it derives its name.

p. The flexor brevis pollicis *arises* from the ossa trapezoides, magnum, et unciforme, and annular ligament. It is divided into two portions, which form a groove for the tendon of the flexor longus pollicis. *Inserted* into the ossa sesamoidea, and base of the first bone of the thumb. *Action*,— to bend the first joint of the thumb.

q. The adductor pollicis *arises* fleshy, from almost the whole length of the metacarpal bone of the middle finger; going across the metacarpal bone of the fore finger, its fibres converge, and send off a short tendon. *Inserted* into the inner part of the root of the first bone of the thumb. *Action*,— to pull the thumb towards the finger.

r. The abductor minimi digiti *arises* fleshy, from the os pisiforme, and from that part of the annular ligament next it, to be *inserted*, tendinous, into the inner side of the base of the first bone of the little finger. *Action*,— to draw the little finger from the rest.

s. The flexor brevis minimi digiti *arises* from the os unciforme, and adjacent part of the annular ligament; passes obliquely over the under end of the former muscle, to be *inserted*, by a roundish tendon, into the inner part of the base of the first bone of this finger. *Action*,— to bend the little finger, and to assist the adductor.

t. The adductor ossis metacarpi minimi digiti *arises* fleshy, from the edge of the os unciforme, and from that part of the annular ligament next it, to be *inserted*, tendinous, into the inner side, and anterior or under extremity of the metacarpal bone of the little finger. *Action*,— to bend the metacarpal bone, and bring the little finger towards the rest.

Besides these muscles, there are

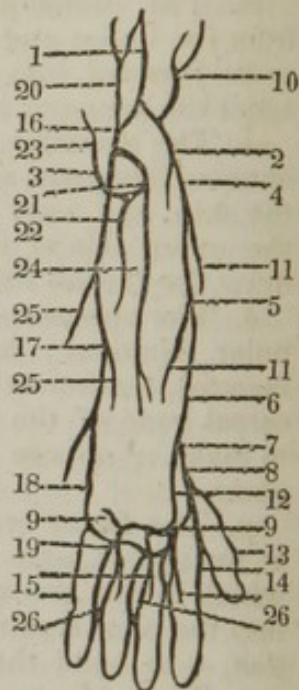
The interossei which *arise* from the sides of the metacarpal bones. They fill up the spaces between them, and are something similar to the lumbricales, but larger. *Inserted*, by slender tendons, along with those of the lumbricales, into the sides of the tendinous expansions of the extensor digitorum communis. *Action*,— to give the fingers their lateral motions, and to assist a little, according to their situations, in bending or extending the first phalanx of the fingers. Three are to be seen in the palm of the hand, arising by single heads, and are called interni; and four on the back of the hand, with double heads, termed externi, or



bicipetes. Part of the externi, however, are also seen in the palm of the hand.

The accompanying diagram is intended to point out the branches of the radial and ulnar arteries.

1. The brachial artery, bifurcating into
2. The radial.
3. The ulnar.
4. The radial artery, situated between the pronator radii teres and supinator radii longus.
5. Situated between the supinator radii longus and flexor carpi radialis, upon the flexor sublimis.
6. On the flexor longus pollicis.
7. Upon the pronator radii quadratus.
8. Where the artery turns round the radius, runs over the os naviculare, between the os trapezium and trapezoides, then passes between the metacarpal bones of the thumb and index finger deep into the palm, where the artery forms
9. The deep-seated palmar arch. The branches sent off in the course of the artery, are
10. The recurrent branch, which anastomoses with the profunda inferior sent off from the humeral.
11. Muscular and nutritious branches.
12. The superficialis volæ, running over the ball of the thumb, to anastomose with the superficial palmar arch.
13. The hallucis pollicis.
14. The dorsalis indices.
15. The interosseal arteries, arising from the deep-seated arch.
16. The ulnar artery, where it sinks deep under the pronator radii teres, flexor carpi radialis, palmaris longus, and flexor sublimis digitorum, upon the flexor profundus.
17. Where the artery becomes superficial, being placed beneath the fascia upon the flexor profundus, between the flexor carpi ulnaris and flexor sublimis.
18. Where the vessel passes over the annular ligament, to form
19. The superficial palmar arch. The branches sent off from the ulnar artery, are
20. The recurrent ulnaris, which anastomoses with the profunda inferior.
21. The interosseal artery, which sinks beneath the flexor profundus to gain the interosseous ligament, then sends off
22. The dorsal branch, to perforate the ligament, and to supply the muscles on the back part of the fore arm.
23. A recurrent branch of the posterior interosseal, running up to supply the elbow-joint.
24. The continued trunk of the interosseous artery, passing upon the interosseous ligament. This branch ultimately passes beneath the annular ligament, to supply the wrist joint.
25. Muscular and nutritious branches.
26. The digital branches, which pass towards the fingers, and then divide into branches, which pass at the sides of the fingers, anastomosing with their fellows at the apex of the fingers.



The brachial artery, in its passage over the elbow-joint, is situated close to the inner side of the tendon of the biceps, and upon the brachialis internus beneath the portion of fascia, continued from the tendon of the biceps into the fascia of the fore arm, it enters the triangular space just below the elbow-joint; and divides into two, the radial and the ulnar arteries, which, separating from each other, proceed, one to the radial, and the other to the ulnar side of the fore arm.

The arteries of the fore arm are subject to many varieties in the mode of their origin.

The radial, ulnar, and interosseal arteries may arise together at the elbow. The most frequent arrangement is, that the radial is the first branch, the brachial then terminating in the ulnar and interosseal; but it often happens that the ulnar is the first branch, the brachial then terminating in the radial and interosseal. The least frequent arrangement is, that the interosseal is the first branch, the brachial then terminating in the radial and ulnar arteries. Sometimes there is a fourth artery of the fore arm, termed the median; if so, it accompanies the median nerve, runs under the annular ligament, and anastomoses with the superficial palmar arch.

Either of the three arteries of the fore arm may arise from the brachial in any part of its course, even as high as the axilla.\* Whatever may be the variety in the origin of the branches, the brachial trunk constantly preserves its regular course down the inside of the arm, and whichever may be the branch having the high origin, it always passes down the inside of the arm with the brachial trunk. Occasionally, when the ulnar is the branch having the high origin, it descends superficially upon the fascia of the fore arm. When the radial is the branch having the high origin, it may descend on the inner or outer side of the brachial trunk. When it descends on the inner side of the brachial trunk, it will afterwards cross over it to the radial side of the fore arm. A large artery is sometimes given off high up from the brachial, and after running some way down the arm, it enters either the brachial trunk again, or one of its branches.

The radial artery follows the course of the radius through its whole length. It descends first between the supinator radii longus and pronator radii teres, then passes over the tendon of the latter muscle, running between the supinator radii longus and flexor carpi radialis, resting at first on the flexor sublimis, then on the flexor longus pollicis. At the upper part of the fore arm, it is covered by the supinator radii longus; in its descent, it becomes more superficial; and, at the under part of the fore arm, it lies close upon the radius, and immediately under the skin. Its principal branches are, the recurrens radialis, or anastomosing branch, reflected to the muscles and parts of the joints near, and anastomosing freely with the profundo-radial at the outer part of the elbow. Numerous lateral branches are sent off in the descent of the artery, to the muscles and integuments, and parts in general situated about the radius, termed muscular and nutritious. The superficialis volæ is sent off at the wrist, passes over or through the abductor pollicis to the palm. It is sometimes so small as scarcely to reach the palm; more frequently, it is a considerable artery, sending branches to the ball of the thumb and superficial parts of the palm

\* The American Editor has a preparation where the radial is given off by the subclavian.

near it,—a branch along the outer side of the thumb,—and an anastomosing branch, which unites with the arch of the ulnar artery. Small branches to the ligaments, bones, and parts about the wrist. At the under end of the fore arm, the radial artery runs under the tendons of the extensors of the thumb, to gain the space between the roots of the metacarpal bones of the thumb and fore finger, perforating the abductor indicis. It divides into three principal branches, *viz.* the arteria magna pollicis, which runs along the side of the thumb next the fingers, and sometimes divides at its root into two branches, which supply both sides of it; the radialis indicis, which runs along the side of the fore finger next the thumb; and the palmaris profunda, which crosses the hand between the roots of the metacarpal bones and flexors of the fingers, and forms the arcus profundus, from which branches go off to the interossei muscles, and other deep parts of the palm.

The ulnar artery is somewhat larger than the radial, and appears at first as the continuation of the trunk of the humeral artery. At its upper part, it sinks deep behind the flexor muscles of the hand, and passes afterwards, for some way, between the flexor sublimis and profundus digitorum. Near the wrist, it becomes more superficial, and runs between the tendons of the flexor carpi ulnaris and flexor digitorum profundus, to the hand. In its course, it sends off many branches to the fore arm; the following are the most considerable. The recurrens ulnaris, which runs deep among the flexor muscles and soon divides into branches, which ascend and supply the parts about the posterior and inner sides of the elbow and capsule of the joint. In the groove behind the inner condyle of the os humeri, it communicates by distinct anastomoses with the profunda inferior, and with the ramus anastomoticus, sent down from the humeral artery. The interosseal comes off at the upper end of the interosseous ligament, and divides into an anterior and posterior interosseal artery; the posterior, perforating the ligament immediately at its origin, and going to the back part of the fore arm, sends upwards a recurrent branch, which communicates, upon the back part of the elbow, with the recurrent arteries, and with the other branches sent down from the humeral artery, and forms along with these a plexus of vessels upon the back part of the joint. The posterior interosseal is afterwards continued downwards, and is chiefly dispersed upon the bellies of the extensor muscles of the hand and fingers, being commonly lost before it reaches the wrist. The anterior interosseal is considerably the larger of the two, but only about half the size of the ulnar artery, from which it springs; it runs close upon the interosseous ligament, and furnishes branches to the muscles and deep parts upon the anterior side of the fore arm, and the nutritious arteries of the radius and ulna; near the wrist, the principal part of the artery perforates the ligament, and goes to the posterior side of the carpus and back of the hand, dividing into branches which inosculate with others of the posterior interosseal and radial arteries. The other part of the artery is lost about the ligaments on the fore side of the wrist.

The ulnar artery, having given off its recurrent branch, and the interosseal, with many lateral branches to the other side of the fore arm, passes by the radial side of the os pisiforme, and then over or through the fibres of the annular ligament into the palm, where it forms the arcus volaris superficialis. At the under end of the fore arm, it sends off a dorsal branch, which passes behind the tendon of the flexor carpi

ulnaris to the back of the hand, where, joining with branches of the anterior interosseal and radial arteries, it assists in forming a plexus, which supplies the back part of the wrist, hand, and fingers. The *arcus volaris sublimis, vel superficialis*, is placed with its convex side downwards, and extends obliquely from the root of the metacarpal bone of the little finger towards that of the first bone of the thumb; being covered by the expansion termed *aponeurosis palmaris*. From the *arcus volaris*, branches are sent off to the integuments and superficial parts of the palm: a branch, which sinks near the root of the metacarpal bone of the little finger, inosculating with the palmar branch of the radial artery, assisting in forming the *arcus profundus*; a branch to the inner side of the little finger; three large digital branches, which run opposite to the interstices of the metacarpal bones, to the roots of the fingers; here each digital artery is divided into two branches, one branch of each division runs along the anterior radial margin of one finger, and the other along the anterior ulnar margin of the finger next it — the digital arteries thus supplying the margins of all the fingers; each artery receives a small branch from the *arcus profundus*. At the roots and joints, but more particularly at the points of the fingers, the arteries communicate by cross arches. The superficial arch of the palm commonly sends off one of the arteries of the thumb, and ultimately communicates by a large anastomosis with the root of the *arteria magna pollicis*.

Having duly considered the course and relative position of every part of the anterior portion of the fore arm, we may next reflect upon the best situation to secure the vessels in case of accident or aneurism.

The radial artery may be secured in any part of its course, only carry in mind the relative position of the vessel. At the upper stage of its course, it is more deeply seated, and placed between the *supinator radii longus* and *pronator radii teres*. Make, therefore, an incision on the outer part of the fore arm, between these muscles, first dividing the skin, the fascia afterwards, taking as your guide the inner border of the *supinator radii longus*, and separate this muscle from the *pronator radii teres* with the handle of the scalpel, when the artery will be seen and may be secured. In the lower part of its course it is more superficial, and, consequently, easier to pass a ligature around it. No difficulty can arise, provided the course of the artery be carried in the recollection. Take as the guide the inner portion of the tendon of the *supinator radii longus*, and the vessel will be found between it and the *flexor carpi radialis*. This artery may also be secured as it is passing between the *os trapezium* and *trapezoides*, without the slightest difficulty.

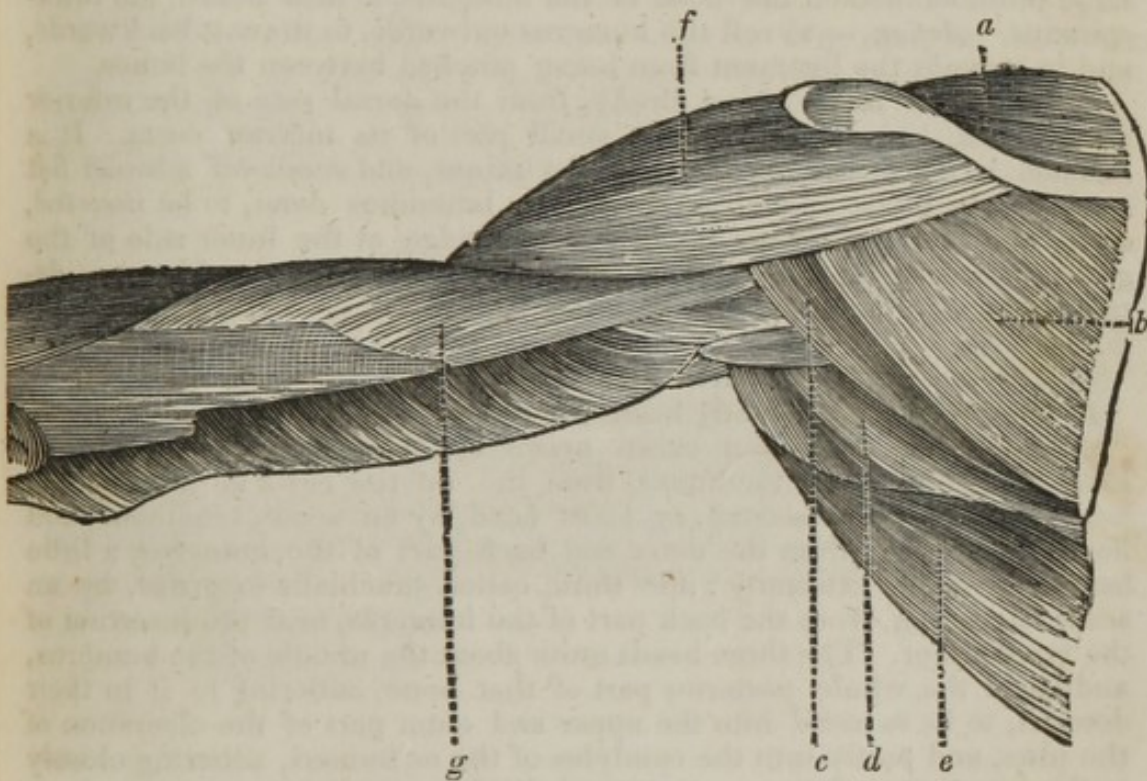
The ulnar artery may be secured in any part of its course. To pass a ligature round the upper part of the vessel, as it sinks beneath the pronator radii teres and flexor muscles, an incision must be made through them, when the artery is to be observed, situated beneath the flexor sublimis and profundus; it is here crossed by the median nerve, and may be secured.

At the lower part of the arm the artery is more superficial, being placed between the tendon of the flexor carpi ulnaris and flexor sublimis, upon the flexor profundus; therefore take as the guide the inner border of the tendon of the flexor carpi radialis, divide the skin and fascia, and the artery will be discovered on the inner part of the tendon; the nerve, however, is situated between the tendon and artery, therefore the aneurism needle may be passed from the inner to the outer part, which will prevent the possibility of including the nerve in the ligature.

The free anastomoses that are formed between the radial and ulnar arteries, must be considered in all accidents to the hand or arm. The superficial palmar arch being placed immediately beneath the palmar fascia, freely anastomoses with the deep-seated palmar arch, the two arches embracing the tendons of the flexor sublimis and profundus, the lumbricales, and the branches of the median and ulnar nerves. By these free inosculation, the blood is enabled to circulate in every part of the hand or arm, by the free union of the vessels, in case any of the arteries become obliterated; and should any of the arteries be divided by accidental causes, it is necessary to secure both ends of the divided vessel, as the lower part bleeds as freely as the upper.

## DISSECTION OF THE POSTERIOR PART OF THE UPPER ARM.

THE skin may be removed by similar incisions to those made at the anterior part of the arm. When this has been done, and the insertion of the trapezius dissected off, the following muscles will be brought into view. These muscles, or most part of them, are covered by a fascia, which is a continuation of the same aponeurotic expansion as is situated on the anterior part of the arm.



- a. The supra-spinatus.
- b. The infra-spinatus.
- c. The teres minor.
- d. The teres major.
- e. The latissimus dorsi.
- f. The deltoid.
- g. The triceps extensor cubiti.

a. The supra-spinatus *arises* fleshy, from the whole fossa supra-spinata, and from the spine and superior costa of the scapula; passes under the acromion, adheres to the capsular ligament of the joint, and runs over the head of the humerus, to be *inserted*, tendinous, into the upper part of the large tubercle on the head of the humerus. *Action*,—to raise the arm, and at the same time to pull the capsular ligament from between the bones, so as to prevent it from being pinched.

*b.* The *infra-spinatus arises* fleshy, from all that part of the *dorsum scapulæ* below its spine; and from the spine itself, as far as the *cervix scapulæ*. The fibres pass obliquely towards a tendon in the middle of the muscle, which runs forwards, and adheres to the capsular ligament, to be *inserted*, by a flat thick tendon, into the upper and outer part of the large protuberance on the head of the humerus. *Action*,—to roll the head of the humerus outwards; to assist in raising, and in supporting it when raised; and to pull the ligament from between the bones.

These two muscles are covered by an aponeurosis, which extends between the *costæ* and edges of the spine of the scapula, and gives rise to many of the muscular fibres.

*c.* The *teres minor arises* fleshy, from the inferior costa of the scapula. It ascends along the under edge of the *infra-spinatus*, and adheres to the capsular ligament, to be *inserted*, tendinous, into the back part of the large protuberance on the head of the humerus, a little below the *infra-spinatus*. *Action*,—to roll the humerus outwards, to draw it backwards, and to prevent the ligament from being pinched between the bones.

*d.* The *teres major arises* fleshy, from the dorsal side of the inferior angle of the scapula, and from a small part of its inferior costa. It is situated at the under part of the *teres minor*, and sends off a broad flat tendon, which accompanies that of the *latissimus dorsi*, to be *inserted*, along with the *latissimus dorsi*, into the ridge at the inner side of the groove for lodging the tendon of the long head of the biceps. *Action*,—to roll the humerus inwards, and to draw it backwards and downwards.

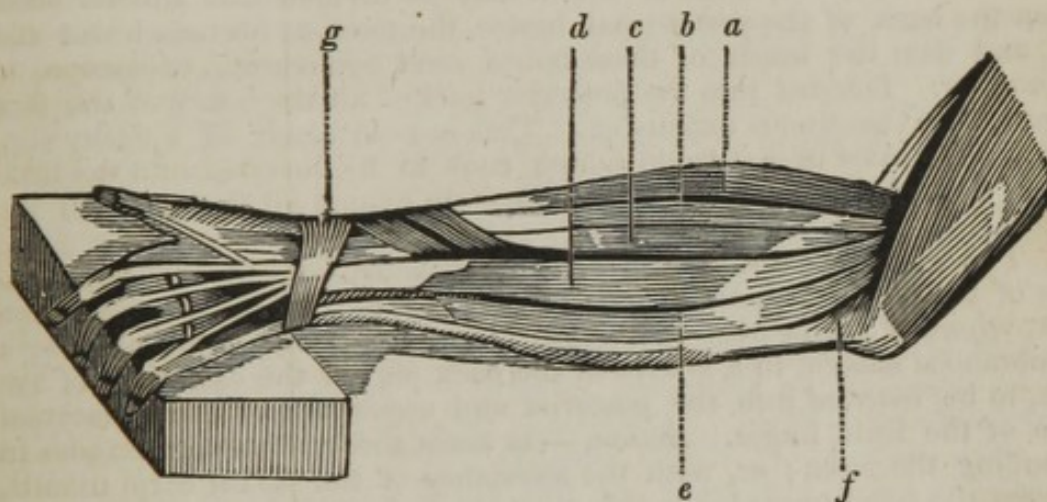
*e.* The *latissimus dorsi* will be given in the dissection of the back.

*f.* The deltoid has already been described.

*g.* The *triceps extensor cubiti arises* by three heads; the first, or long head, broad and tendinous, from the inferior costa of the scapula, near its *cervix*; the second, or short head, by an acute, tendinous, and fleshy beginning, from the outer and back part of the humerus, a little below its upper extremity; the third, called *brachialis externus*, by an acute beginning, from the back part of the humerus, near the insertion of the *teres minor*. The three heads unite about the middle of the humerus, and cover the whole posterior part of that bone, adhering to it in their descent, to be *inserted* into the upper and outer part of the olecranon of the ulna, and partly into the condyles of the *os humeri*, adhering closely to the ligament. *Action*,—to extend the fore arm.

## DISSECTION OF THE POSTERIOR PART OF THE FORE ARM.

THE integuments may be removed in the same manner as on the anterior part of the arm, when the fascia will be observed to be similar, and a continuation of the same that serves to bring down the muscles on the fore part. The fascia on the back part of the arm, however, receives additional strength by an expansion sent off from the triceps. The fascia sinks between the muscles, forming a separation between them, which has received the name of inter-muscular ligament. The muscles take a firm origin from the fascia, and it can only be removed at the upper part with some difficulty. When reflected, the following muscles, forming the first layer, are brought into view.



- a. The supinator radii longus.
- b. The extensor carpi radialis longior.
- c. The extensor carpi radialis brevior.
- d. The extensor digitorum communis, sending off the auricularis.
- e. The extensor carpi ulnaris.
- f. The anconeus.
- g. The annular ligament.

a. The supinator radii longus *arises* by an acute fleshy beginning, from the ridge of the os humeri, above the external condyle, nearly as high as the middle of the bone; it forms a thick fleshy belly, which covers the upper part of the extensor carpi radialis longior; and about the middle of the fore arm sends a tendon along the edge of the radius, to be *inserted* into the outer side of the under end of the radius. *Action*, — to roll the radius outwards, and to turn the hand into a supine situation, or with the palm outwards.

b. The extensor carpi radialis longior *arises* broad, thin, and fleshy,



directly below the supinator radii longus, from the lower part of the ridge of the humerus, above its external condyle. It sends off a long flat tendon, which passes down, first upon the outer edge, and then upon the back of the radius, descending in a groove, and going under the external annular ligament, to be *inserted* into the upper, back, and outer part of the metacarpal bone of the fore finger. *Action*,— to extend the wrist, and bring the hand backwards.

*mid. fingers*  
*c.* The extensor carpi radialis brevior *arises* tendinous, in common with the extensor longior, but farther down, from the external condyle of the humerus, and from the ligament which connects the radius to it. Passing down upon the back part of the radius, its tendon goes under the annular ligament, in the same channel with the tendon of the extensor longior, to be *inserted* into the upper and back part of the metacarpal bone of the little finger. *Action*,— to assist the former muscle in extending the wrist; or, with it and the flexor carpi radialis, to draw the hand to the side next the thumb.

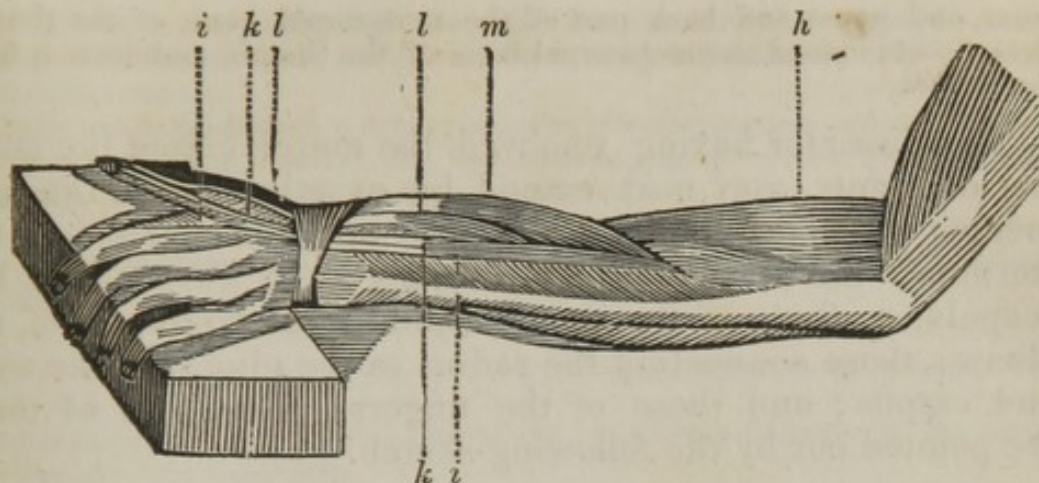
*d.* The extensor digitorum communis *arises* tendinous and fleshy, from the external condyle of the humerus, where it adheres to the supinator radii brevis. It passes down upon the back part of the fore arm, and before it goes under the posterior annular ligament, it splits into three or four tendons, some of which may be divided into smaller ones. Upon the back of the metacarpal bones, the tendons become broad and flat, and near the heads of these bones send aponeurotic expansions to each other. *Inserted* into the posterior part of all the bones of the four fingers, by a tendinous expansion. This muscle sends off a fleshy slip, which terminates in a tendon which runs to be inserted into the little finger, termed the auricularis. *Action*,— to extend all the joints of the fingers.

*e.* The extensor carpi ulnaris *arises* tendinous, from the external condyle of the humerus, and in its progress fleshy, from the middle of the ulna, where it passes over that bone. Its round tendon is inclosed by a membranous sheath, in a groove at the back part of the extremity of the ulna, to be *inserted* into the posterior and upper part of the metacarpal bone of the little finger. *Action*,— to assist the two former muscles in extending the wrist; or, with the assistance of the flexor carpi ulnaris, to draw the hand towards the side next the little finger.

*f.* The anconeus *arises* tendinous, from the posterior part of the external condyle of the humerus. It descends, being of a triangular form, soon becomes fleshy, and part of its flesh is likewise continued from the third head of the triceps, to be *inserted*, fleshy and thin, into a ridge on the outer and back edge of the ulna, a little below the olecranon. *Action*,— to assist the triceps in extending the fore arm.

*g.* The posterior annular ligament is formed by a thickening of the fascia at the back part of the wrist. It is connected to the lower part of the radius, and stretches across towards the inner part, where it is connected to the unciforme bone and base of the metacarpal bone of the little finger. It serves to confine the tendons of the muscles of the back in their proper situation.

The muscles may now be reflected, or separated from the lower attachment, when the deep-seated ones will be brought into sight.



- h.* The supinator radii brevis.  
*i.* The indicator.  
*k.* The extensor secundi internodii pollicis.  
*l.* The extensor primi internodii pollicis.  
*m.* The extensor ossis metacarpi pollicis.

*h.* The supinator radii brevis *arises* tendinous, from the external condyle of the humerus, and tendinous and fleshy from the outer and upper part of the ulna, and from the interosseous ligament. It passes over the external edge of the radius, to be *inserted* into the upper and fore part of the radius. *Action*, — to assist the supinator longus.

*i.* The indicator *arises* by an acute fleshy beginning, from the middle of the posterior part of the ulna, at the inner side of the extensor secundi internodii pollicis. Its tendon passes under the same ligament with the extensor digitorum communis, to be *inserted* along with part of the extensor digitorum communis, into the posterior part of the fore finger. *Action*, — to assist the extensor communis in extending all the joints of this finger, as in pointing at anything. There is a small muscle at the back of the hand, termed abductor indicis, which *arises* from the os trapezium, and from the upper part and inner side of the metacarpal bone of the thumb, to be *inserted*, by a short tendon, into the outer and back part of the first bone of the fore finger. *Action*, — to bring the fore finger towards the thumb.

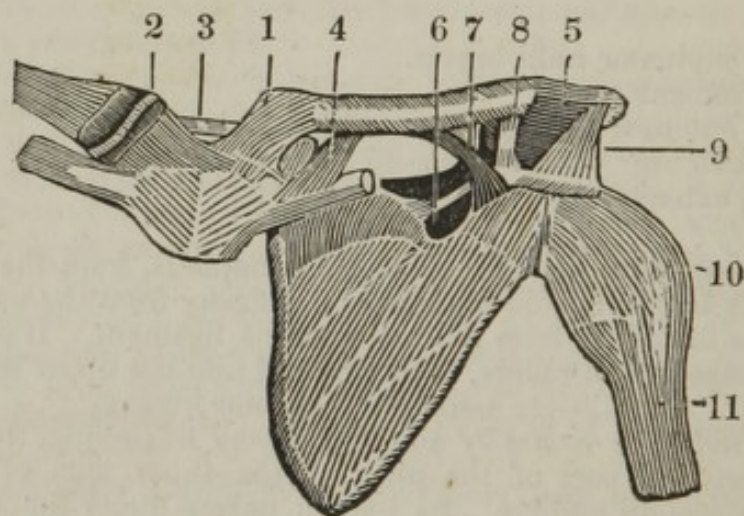
*k.* The extensor secundi internodii pollicis *arises* by an acute, tendinous, and fleshy beginning, from the middle of the back part of the ulna, and from the interosseous ligament. Its tendon runs through a small groove at the inner and back part of the radius, to be *inserted* into the last bone of the thumb. *Action*, — to extend the last joint of the thumb.

*l.* The extensor primi internodii pollicis *arises* fleshy, from the back part of the ulna, and from the interosseous ligament, near the following muscle, by the side of which it runs, to be *inserted*, tendinous, into the posterior part of the first bone of the thumb; a portion of it may be traced as far as the second bone. *Action*, — to extend the first joint of the thumb.

*m.* The extensor ossis metacarpi pollicis *arises* fleshy, from the middle of the posterior parts of the ulna, radius, and interosseous ligament. It runs obliquely over the radius, sending one, or, more frequently, two tendons, through an annular sheath, to be *inserted* into the os trape-

zium, and upper and back part of the metacarpal bone of the thumb. *Action*,—to extend the metacarpal bone of the thumb, and draw it from the fingers.

The dissector having removed the muscles from the superior extremity, may next extend his examination to the ligaments; they consist of those connecting the clavicle to the sternum; the clavicle to the scapula; the humerus to the scapula, or those of the shoulder-joint; the ligaments of the elbow; those connecting the radius to the ulna; of the wrist and carpus; and those of the fingers. The first of these are pointed out by the following sketch.



1. The capsular ligament, connecting the clavicle to the sternum; attached also to the edges of
2. The second inter-articular cartilage (seen in this diagram on the outer side.)
3. The inter-clavicular ligament.
4. The sub-clavicular, or rhomboid ligament.
5. The capsular ligament, connecting the clavicle to the acromion process.
6. The ligament of the semilunar notch.
7. The conoid ligament.
8. The trapezoid ligament.
9. The triangular, or deltoid ligament.
10. The capsular ligament of the shoulder-joint.
11. The long head of the biceps.

#### OF THE STERNO-CLAVICULAR ARTICULATION.

The capsular ligament arises from the outer surface of the inner end of the clavicle, and is fixed round the edge of the corresponding articular cavity of the sternum. Upon this ligament are radiated fibres, sometimes termed radiated ligaments.

An inter-articular cartilage divides the joint into two distinct cavities, and accommodates the articulating surfaces of the clavicle and sternum.

The inter-clavicular ligament, joining the clavicles together behind the top of the sternum, and partly formed by a continuation of the radiated ligaments.

The sub-clavicular, or *ligamentum rhomboideum*, arises from the inferior rough surface at the anterior extremity of the clavicle, and is fixed to the cartilage of the first rib.

By the ligaments of this joint, with the assistance of the intervening cartilage, the shoulder is allowed to move in different directions, as upon a centre.

#### OF THE ACROMIC-CLAVICULAR ARTICULATION.

The capsular ligament connects the posterior extremity of the clavicle to the acromion process.

The conoid, or posterior ligament, connects the clavicle to the coracoid process; of a conical form, with its base upwards, which takes its origin from a tubercle at the under part of the clavicle, and descends to be inserted into the base of the coracoid process of the scapula.

The trapezoid ligament descends from the extremity of the clavicle close to its connexion with the acromion process, to be inserted into the base of the coracoid process. The connexions of those ligaments are strong, but sufficiently loose to allow the scapula to perform its several motions without the clavicle.

#### OF THE LIGAMENTS PROPER TO THE SCAPULA.

The triangular, or anterior ligament, is a firm band of ligamentous structure, connecting the acromion to the coracoid process. It is broader at its superficial, or that part nearest the skin, and narrow at the posterior portion.

The ligament of the semilunar notch, or posterior ligament, arises from the base of the coracoid process and outer edge of the semilunar notch, and passes to be inserted into the back part of the semilunar notch. This ligament forms a foramen, at least completes the upper part of a foramen, which allows the supra-scapular artery to pass through it.

#### OF THE SHOULDER-JOINT.

The capsular ligament arises from the edge of the cartilage lining the glenoid cavity, then descends to attach itself to the lower part of the cervix of the humerus, at the base of the two tuberosities. It is of unequal thickness, being thinner at the posterior and inferior portion, where, however, it is strengthened by the *infra-spinatus* and *teres minor*; at its inner part it is lined by a synovial membrane, which is reflected over the head of the humerus; also lines the glenoid cavity, and covers that portion of the long head of the biceps that is within the joint, so as to prevent the tendon from adhering to the membrane, when inflammation occurs.

The long head of the biceps takes its origin from the upper part of the glenoid cavity, and passes over the head of the humerus, through a perforation of the capsular ligament, to the bicipital groove; it serves to strengthen the upper part of the joint.

The glenoid cavity of the scapula in a dried bone, is of an oval form, but when viewed covered by its cartilage, it is of a circular form, the

upper part giving attachment to the long head of the biceps. The cartilage serves to increase the depth of the cavity, and gives attachment to the capsular ligament.

The muscles which pass round the shoulder-joint, and which adhere or are attached to the capsular ligament, are the deltoid, coraco-brachialis, biceps, sub-scapularis, supra-spinatus, infra-spinatus, teres minor, and long head of the triceps.

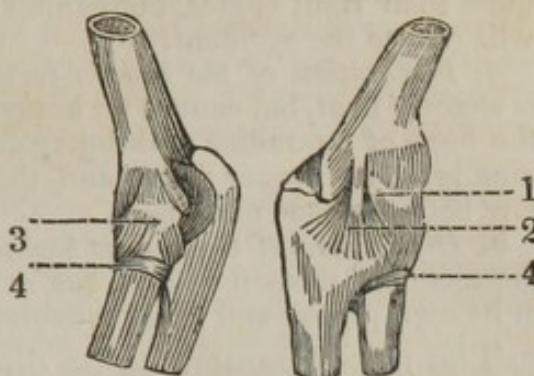
The sterno-clavicular articulation may be dislocated in two directions, forwards and backwards; the former is the most common, the latter the most severe accident, on account of the bone pressing upon the nerves and vessels of the arm, as also upon the œsophagus. In either of these accidents the ligaments are more or less lacerated, according to the violence producing the displacement; the methods of treatment are similar. The scapula should be brought backwards as much as possible, the arm supported at the same time by elevating the elbow, and when the end of the bone resumes its proper cavity, it should be kept in its situation by the application of the stelite roller, a pad having been put into each axilla. The arm also should be bound to the side, to prevent its motion, as it otherwise would cause the bone to start from its situation. The parts must be kept in this position until the union of the ligament be completed.

The acromic-clavicular joint can be only dislocated in one direction, upwards, and is more frequent than the dislocation at the sternal end. Its mode of treatment is the same, by bringing the scapula backwards, and confining the arm until the union of the ligament be accomplished.

The shoulder-joint may be dislocated in four directions. *Downwards* into the axilla, when the head of the humerus rests upon the inferior costa of the scapula. *Forwards*, under the pectoral muscle, when the head of the bone is placed upon the second rib on the sternal side of the coracoid process. *Backwards*, when the head of the bone is situated upon the dorsum of the scapula, upon the outer part of the inferior costa, forming a protuberance. And *partial*, when the capsular ligament is torn through, and the head of the bone rests against the coracoid process. In these dislocations care must be taken, prior to the attempt of reduction, to fix the scapula; otherwise it never can be accomplished. This bone may be kept in its place by means of a jack-towel passed round the upper part of the shoulder and given to an assistant to hold, when extension may be made until the head of the bone gains the articulating surface. When displaced forwards, care must be taken to reduce the dislocation into the axilla, when it will slide into its place, as in this dislocation the coracoid process is between the glenoid cavity and the head of the bone.

The dissector may now direct his attention to the elbow-joint. It will be found to be of an irregular ginglymoid form, composed at its upper part by the articulating surfaces between the condyles of the humerus; and inferiorly, by the head of the radius and greater sigmoid cavity of the ulna; these parts are connected together by the following ligaments.

1. The capsular ligament.
2. The internal lateral ligament.
3. The external lateral ligament.
4. The coronary, or annular ligament.



1. The capsular ligament arises round the margin of the articular surface, at the lower end of the humerus, and is fixed above the edge of the articular surface of the ulna, and also to the coronary ligament of the radius.

The sides of the elbow-joint are strengthened by two ligamentous bands, which adhere so firmly to the outer surface of the capsular ligament, that they appear to be part of its substance, *viz.*

2. The internal lateral ligament arises from the fore part of the inner condyle of the humerus, and spreads out, in a radiated manner, to be fixed to the inside of the coronoid process of the ulna.

3. The external lateral ligament is like the former, but larger; it arises from the external condyle of the humerus, and is expanded upon the coronary ligament into which it is inserted.

4. The coronary ligament of the radius, approaching to the firmness of a cartilage, arises from one side of the small semilunar cavity of the ulna, and, after surrounding the neck of the radius, is fixed to the other side of that cavity. The upper edge of it is incorporated with, and may be considered as a part of the capsular ligament, while its under edge is fixed round the neck of the radius, allowing that bone to move freely round its own axis, upon the articular surface of the humerus, and in the small semilunar cavity of the ulna. Below the elbow-joint there is a ligamentous band, which descends in an oblique direction from the rough surface below the coronoid process of the ulna, to be inserted into the radius below its tubercle. This band has been called the oblique ligament, which serves to bind the bones firmer to each other.

The elbow-joint may be dislocated in five directions. 1. Both bones may be dislocated backwards, when the radius and ulna are thrown upwards behind the condyle of the humerus, the coronoid process of the ulna occupying the fossa behind and between the condyles; the anterior part of the capsular ligament is lacerated, and the olecranon projects at the back of the elbow, above its usual situation an inch and a half.

2. *Laterally.* — In this case the coronoid process is situated at the back part of the external condyle of the humerus, the projection of the ulna backwards is consequently greater; the radius also forms a prominence behind and on the outer part of the external condyle. Sometimes the dislocation occurs internally instead of externally, when the ulna is thrown on the inner condyle, and the head of the radius occupies the deep fossa at the back part of the humerus; the external condyle projects very much outwards.

3. *Dislocation of the ulna backwards.* — The radius in this accident keeps its proper situation; the olecranon projects behind the humerus; the hand and arm are turned inwards, and the elbow can be bent to

more than right angles, but cannot be extended, except by force, which will reduce the accident.

4. *Dislocation of the radius forwards.*—In this accident the fore arm is slightly bent, but cannot be brought to a right angle with the upper, by the head of the radius striking against the fore part of the humerus; the ulna is in its proper place, and the head of the radius occupies the hollow between the condyles.

5. *Dislocation of the radius backwards.*—In this accident the head of the radius is thrown behind the external condyle, and the ulna remains in its own proper and usual articulating surface.

The next ligament to be dissected may be

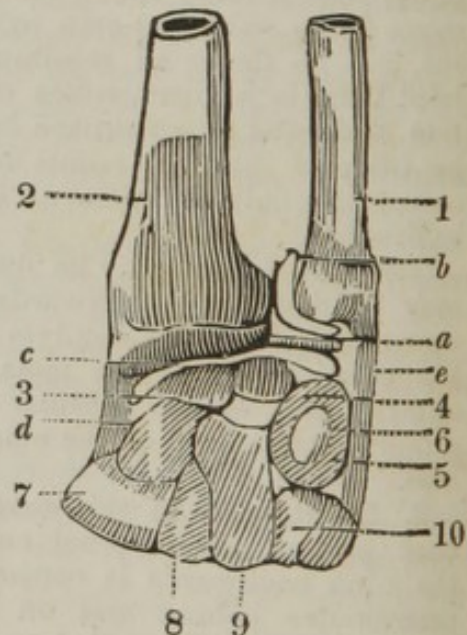
The interosseous, which extends between the sharp ridges of the radius and ulna, filling up the greater part of the space between these two bones. It is broadest in the middle, and is composed of small fasciculi, which run obliquely downwards and inwards. Two or three of these slips go in the opposite direction.

In different parts of the interosseous ligament there are perforations for the passage of blood-vessels from the fore to the back part of the fore arm, and a large opening is found at the upper edge of it, which is occupied by muscles.

This ligament assists in binding the ulna and radius together, prevents the radius from rolling too much outwards, and furnishes a commodious attachment for the muscles.

Of the remaining ligaments of the superior extremity, the accompanying diagram is intended to point out the inferior radio-ulnar articulation, as also the wrist-joint.

1. The ulna.
2. The radius.
3. The os scaphoides.
4. The os lunare.
5. The os cuneiforme.
6. The os pisiforme.
7. The os trapezium.
8. The os trapezoides.
9. The os magnum.
10. The os unciforme.
- a. The third inter-articular cartilage.
- b. The ligamentum capsulare saciforme.
- c. The capsular ligament of the wrist-joint.
- d. The external lateral ligament.
- e. The internal lateral ligament.



The third inter-articular cartilage is of a triangular shape, situated between the button-like extremity of the ulna and the cuneiforme bone; the base of the triangle is placed next the radius, and the apex consequently near the styloid process of the ulna. It forms the upper and inner part of the wrist-joint, and tends to increase the motion of that joint.

The ligamentum capsulare sacciforme takes its origin from the articular surface on the inner part of the radius; from thence it passes to the under part of the ulna, and then to the upper surface of the inter-articular cartilage. It forms a distinct joint between the ulna and radius, and has nothing to do with the wrist; from its looseness it receives its name.

The wrist-joint is composed superiorly of the under surface of the radius and the inter-articular cartilage, and inferiorly by the os scaphoides, lunare, and cuneiforme; the two former bones being connected to the radius, and the latter to the under surface of the inter-articular cartilage. The ligaments of this joint are three in number.

The capsular ligament arises from the edges of the articular surface of the radius and inter-articular cartilage, and descends to be reflected over the scaphoides, lunare, and cuneiforme. This ligament is said to be strengthened by an anterior and posterior ligament, a thickening, or mere division of the capsular ligament.

The external lateral ligament arises from the styloid process of the radius, and descends to be inserted into the scaphoides and trapezium. It is occasionally termed the radio-carpal ligament.

The internal lateral ligament arises from the styloid process of the ulna, and is inserted into the cuneiforme and unciforme bones.

The wrist-joint may be dislocated either forwards or backwards, which displacement is termed complete. It can also be dislocated laterally, which is only partial. If the wrist is dislocated forwards, the radius and ulna are thrown backwards; and if the accident occurs backwards, the reverse takes place. The ligaments, particularly the capsular, are more or less lacerated; and, therefore, when the accident is reduced, the parts will not remain in their proper place. It is necessary to apply a splint, both at the anterior and posterior part, and to keep them on until the parts are united.

The following ligaments finish those of the superior extremity.

A capsular ligament arises from the cartilaginous edge of the upper row of the carpus, and is fixed in a similar manner to that of the under row, chiefly admitting of flexion and extension, and that in a smaller degree than in the former joint.

The anterior annular ligament stretches across from the projecting points of the ossa pisiforme and unciforme, to the scaphoides and trapezium, and forms an arch, which covers and keeps in place the tendons of the flexor muscles of the fingers.

Short palmar ligaments, small ligamentous slips, running in various directions, joining the different bones of the carpus, — first of the same row, then of the two rows together.

A capsular ligament arises from the margins of the second row of the carpal bones, and is fixed to the margins of the adjoining bones of the metacarpus. Other ligaments run in a radiated manner from the carpal to the metacarpal bones.

From the flatness of the articular surfaces, and strength of the con-



necting ligaments, very little motion is allowed between the carpus and metacarpus.

A capsular ligament enclosing each joint of the metacarpal bones with the first phalanx.

A transverse ligament connecting each of the extremities of the metacarpal bones with each other, preventing them from being separated.

The lateral ligaments placed at the sides of the joints, and adhering to the capsular ligaments, confining the motion to flexion and extension.

The vaginal ligaments of the flexor tendons are fine membranous webs connecting the tendons of the sublimis, first to each other, then to those of the profundus, and forming, at the same time, bursæ mucosæ, which surround the tendons.

The vaginal or crucial ligaments of the phalanges arise from the ridges on the concave side of the phalanges, and run over the tendons of the flexor muscles of the fingers. Upon the body of the phalanges, they are thick and strong, to bind down the tendons, while their muscles are in action; but over the joints they are thin, and have, in some parts, a crucial appearance, to allow the ready motion of the joints.

Capsular ligaments connect each joint of the phalanges to each other. These ligaments are thicker on each side, termed lateral ligaments.

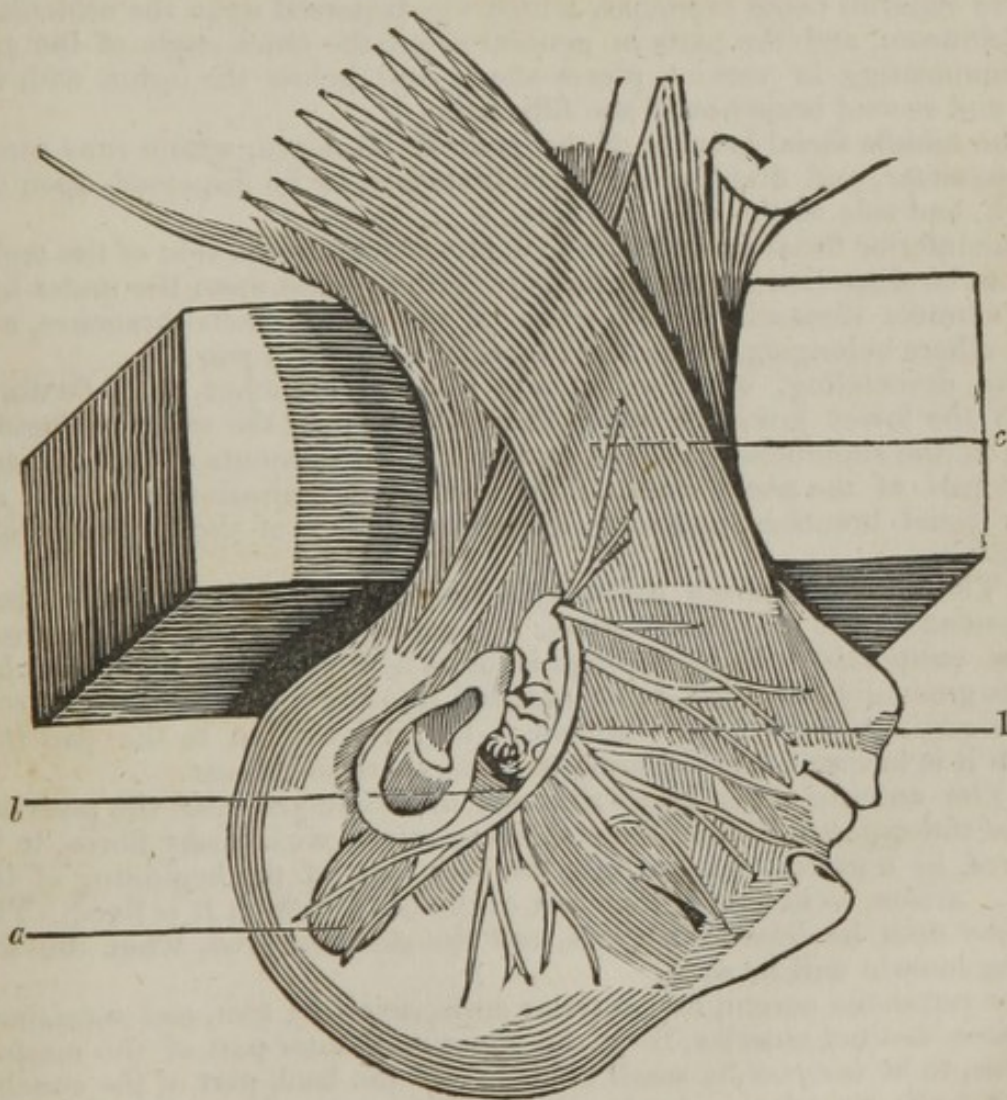
Capsular ligaments connect the sesamoid bones to the joint of the thumb and little finger.

---

## DISSECTION OF THE HEAD AND NECK.

THE dissection of this division of the body is divided into the dissection of the head and face, also that of the neck. The head having been properly shaved, the mouth may be stuffed with tow or horse-hair, when the lips can be sown together. The neck can then be placed upon a block, so that the muscles should become tense, and an incision may be made, commencing at the occipital bone, and carried in the course of the sagittal suture to the upper part of the nose, when the same cut can be carried round the tarsal edges of the cartilages, and along the centre of the nose towards the mouth; it can then be carried around the mouth, from thence to the chin, along the ridge of the inferior maxillary bone to the angle of the jaw. A transverse incision may be made near the middle of the frontal bone, and another similar transverse incision near the superior transverse ridge of the occipital bone. Great care must be taken, in making these incisions, not to cut too deep, as the muscles and other parts are extremely superficial. Should the student intend to complete a dissection of the neck at the same time, (which I should not recommend, but it has

been given here, to prevent the necessity of having two plates,) the incision may be carried from the chin to the upper border of the sternum; this may be continued along the clavicle. When the skin has been carefully reflected, the parts seen in the following plate may be dissected. In removing the skin covering the cranium, observe the formation of the scalp; it is composed of the cuticle, which is delicate, the rete mucosum, and the cutis vera, being very thick, the subjacent cellular membrane contains granulated fat, and the bulbs of the hair, which may be seen to perforate the skin in an oblique course; the cellular tissue here has partly a ligamentous structure, and adheres intimately with the muscular and tendinous expansion, beneath which the occipito frontalis is placed, the under parts of this muscle being but loosely connected to the pericranium.



1. The pes anserinus.  
a. The attollens aurem.

b. The anterior auris.  
c. The platysma myoides.

1. The portio dura of the seventh pair of nerves passes from the aqueduct of Fallopius by the foramen stylo-mastoideum, and is at first lodged deep, being situated in a hollow behind the parotid gland. Here it gives a small occipital branch, which sends twigs to the back part of the ear, and terminates in the oblique muscles of the head. It sends a branch to the digastricus, and another to the stylo-hyoideus; gives off a filament, which joins the auricular branch of the inferior maxillary nerve, and goes to the fore part of the ear; and is connected by another small filament at the under part of the ear, with branches of the sympathetic nerve which run along the external carotid artery. It also furnishes filaments to the parotid gland, and perforates it; dividing into large branches, which join, separate, and rejoin, different times, on the side of the face. This plexus is expanded in such a manner as to constitute what has been called the pes anserinus, and is divided into the following sets of branches:—

The temporal branches, which ascend upon the side of the head, to be distributed upon the temple; some running over, others under the branches of the temporal artery, and forming several joinings with the frontal branches of the first part of the fifth pair of nerves.

The superior facial branches, which are dispersed upon the orbicularis palpebrarum, and the parts in general about the outer angle of the eye, communicating in various places above and below the orbit, with the first and second branches of the fifth pair.

The middle facial branch, or the great facial nerve, which runs across the masseter, and divides into many branches, to be dispersed upon the cheek, and side of the nose and lips.

The inferior facial branches, which proceed along the side of the under jaw, to be dispersed upon the parts covering it, and upon the under lip; and connect themselves with some of the middle facial branches, and with others belonging to the third branch of the fifth pair.

The descending, or subcutaneous cervical branches, run forwards under the lower jaw, and others downwards, near the external jugular vein, to the superficial muscles, and to the integuments at the side and upper part of the neck, where they form communications with the inferior facial branches, and with different branches of the upper cervical nerves.

*a.* The attollens aurem *arises* by a broad tendinous expansion, from the tendon of the occipito-frontalis. It goes down over the aponeurosis of the temporalis. In its passage it forms a thin fleshy slip, which becomes gradually narrower, to be *inserted* into the upper part of the root of the cartilage of the ear. *Action*,—to give tension to the part into which it is inserted, and, in some persons, to raise the ear.

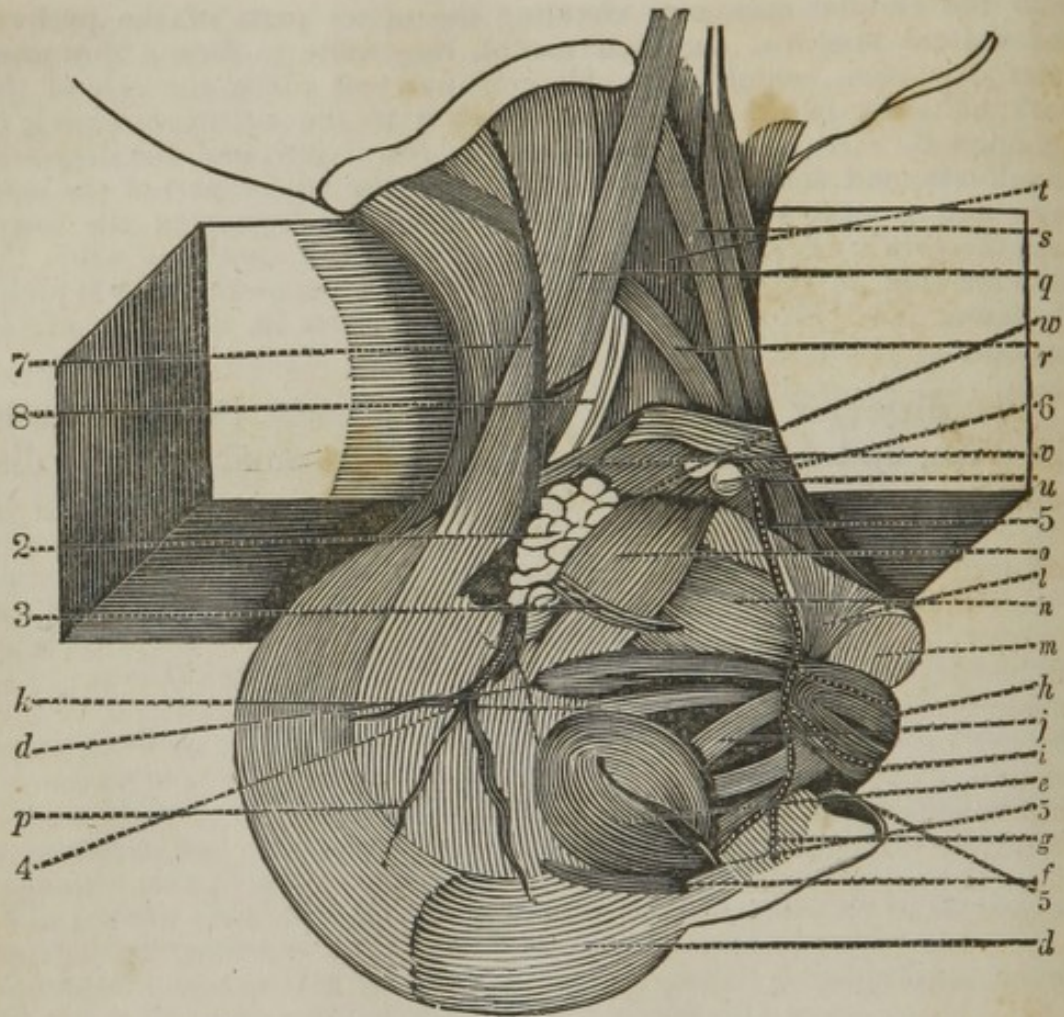
*b.* The anterior auris *arises* thin and membranous, near the posterior part of the zygoma, the middle part being mixed with fleshy fibres, to be *inserted*, by a narrow tendon, into the back part of the beginning of the helix. *Action*,—to stretch that part of the ear to which it is fixed. The ear may then be drawn forwards and the skin removed, when the following muscle will be seen.

The retrahens aurem, *vel* posterior auris, *arises* by two, and sometimes by three distinct muscles, from the upper and outer part of the mastoid process, to be *inserted* by small tendons into the back part of the concha. *Action*,—to stretch the concha, and, in some persons, to draw back the ear.

*c.* The platysma myoides *arises* by a number of separate fleshy slips,

from the cellular substance covering the upper parts of the pectoral and deltoid muscles. In their ascent, they unite to form a thin muscular expansion, which runs obliquely upwards along the side of the neck, adhering to the skin, and is similar to the cutaneous muscle of quadrupeds, *inserted* into the side of the lower jaw, and the depressor anguli oris, and into the skin which covers the under part of the masseter and parotid gland. *Action*,—to assist in depressing the lower jaw, the corner of the mouth, and the skin of the cheek;—when the jaws are shut, to raise all that part of the skin connected with it under the lower jaw. This muscle forms the wrinkles in the neck of old persons.

The dissector may next carefully dissect the muscles of the face, and by reflecting the platysma myoides, the dissection of the neck may be continued.



- d.* The occipito-frontalis.  
*e.* The orbicularis palpebrarum.  
*f.* The corrugator supercilii.  
*g.* The compressor naris.  
*h.* The orbicularis oris.  
*i.* The levator labii superioris alæque nasi.  
*j.* The levator anguli oris.  
*k.* The zygomaticus major and minor.  
*l.* The depressor anguli oris.  
*m.* The depressor labii inferioris.  
*n.* The buccinator.  
*o.* The masseter.  
*p.* The temporal fascia, or aponeurosis.  
 2. The parotid gland.  
 3. Steno's duct.  
 4. The temporal artery.  
 5. The facial artery, passing up to gain the inner angle of the orbit.

*Parts seen in the Dissection of the Neck.*

- q.* The sterno-cleido mastoideus, being perforated by the nervus accessorius.  
*r.* The omo-hyoideus.  
*s.* The sterno-hyoideus.  
*t.* The sterno-thyroideus.  
*u.* The digastricus.

- v. The stylo-hyoideus.
- w. The mylo-hyoideus.
- 6. The submaxillary gland.
- 7. The external jugular vein.
- 8. The sheath containing the carotid artery, with the descendens noni passing down upon it.

d. The occipito-frontalis *arises* fleshy, from near the middle of the upper arched ridge of the occipital bone, and tendinous from the extremity of that ridge, where it joins the temporal bone. It arises after the same manner on the other side. From the fleshy origins, and also from between them, a tendinous expansion is extended along the upper part of the cranium, adhering firmly to the skin, and but loosely to the pericranium. At the upper part of the forehead it becomes fleshy, and descends with straight fibres, to be *inserted* into the skin and parts under it belonging to the eyebrows, and to the frontal bone at the inner part of the orbit. *Action*,—to move all that part of the skin which covers it, and particularly the skin of the eyebrows.

e. The orbicularis palpebrarum *arises* from the orbital process of the superior maxillary bone, from the internal angular process of the frontal bone, and, by a small round tendon, from the nasal process of the superior maxillary bone; the muscle passes outwards, under the skin of the eyelids, surrounding the orbit in a circular manner, extending somewhat beyond it, and covering the upper part of the cheek. The outer surface adheres to the skin of the eyelids; its upper and inner edge is intimately connected with the occipito frontalis and corrugator muscles. *Action*,—to close the eye by bringing the eyelids together, to press the ball of the eye inwards, and act upon the lachrymal organs, so as to assist them in the production and direction of the tears.\* That part of the orbicularis palpebrarum which covers the cartilages of the eyelids, and is remarkably thin, is the musculus ciliaris of some authors. A fleshy slip sometimes passes down from the under and outer part of the orbicularis, to join the levator labii superioris alæque nasi. When present, it may draw a little towards each other those parts to which it is attached.

f. The corrugator supercilii *arises* from the internal angular process of the frontal bone, above its union with the os nasi. It runs upwards and outwards, in the direction of the superciliary ridge, and behind the inferior part of the occipito-frontalis, to be *inserted* into the inner part of the occipito-frontalis and orbicularis palpebrarum, where those two muscles join each other, as far out as the middle of the superciliary ridge. *Action*,—to assist its fellow in drawing the eyebrows downwards and inwards, and corrugating or wrinkling the skin between them into longitudinal folds.

g. The compressor naris *arises* by a narrow beginning from the root of the ala nasi, where it is connected with the levator labii superioris alæque nasi. It spreads into a number of thin scattered fibres, which

\* Horner has discovered a muscle whose use is to serve to adapt the lids to the globe of the eye, and to direct the tears into the lachrymal sac. It arises from the posterior superior part of the os unguis, just in advance of the vertical suture between the os planum and the os unguis. Having advanced three lines, it bifurcates: one bifurcation is inserted along the upper lachrymal duct, and terminates at its punctum, or near it, and the lower has the same relation to the lower duct.

cross the ala nasi, and run towards the dorsum nasi, where it joins its fellow, to be *inserted* into the anterior extremity of the nasal bones, and to the slip which descends from the frontal muscle. *Action*,— to press the ala towards the septum, as in smelling; or, if the fibres of the frontal muscle, which are connected to it, act, they pull the ala outwards. It also corrugates the skin of the nose, and assists in expressing certain passions.

*h.* The orbicularis oris, *vel* labialis. This is a complete sphincter surrounding the mouth, and composing the principal part of the lips, and is in a great measure formed by the muscles which terminate in it. At the corners of the mouth, the fibres decussate each other, so as to make it resemble two semicircular muscles. *Action*,— to shut the mouth, and to counteract the different muscles inserted into it. Part of the muscle, running up to be connected to the septum nasi, and serving as a levator of the upper lip, or a depressor of the under part of the nose, termed by Albinus, *nasalis labii superioris*.

*i.* The levator labii superioris *alæque nasi arises* by two thin fleshy slips, the first from the external part of the orbital process, the second from the upper part of the nasal process of the superior maxillary bone; they run to be *inserted* (the first part of the muscle) into the upper lip, and (the second) into the upper lip and outer part of the wing of the nose. *Action*,— to raise the upper lip in opening the mouth, and to dilate the nostril.

*j.* The levator anguli oris *arises* thin and fleshy, from the superior maxillary bone, immediately under the foramen infra-orbitarium; running deeper down and farther out than the levator labii superioris, to be *inserted* into the angle of the mouth and the cheek, where it joins its antagonist. *Action*,— to raise the corner of the mouth, as in expressing joy.

*k.* The zygomaticus major *arises* fleshy from the os malæ, near the zygomatic suture; descending obliquely forwards, to be *inserted* into the angle of the mouth; its fibres intermixing with those of the depressor anguli oris and orbicularis oris. *Action*,— to raise the angle of the mouth in the direction of its fibres, and to make the cheek prominent, as in laughing.

The zygomaticus minor *arises* higher on the os malæ than the former muscle. It is situated before it, and takes the same course, (but is much more slender,) to be *inserted* into the upper lip, along with the levator anguli oris. *Action*,— to raise the corner of the mouth, and draw it obliquely outwards.

*l.* The depressor anguli oris *arises* broad and fleshy, from the under edge of the lower jaw, at the side of the chin. It runs over the origin of the depressor labii inferioris, becoming gradually narrower, to be *inserted* into the angle of the mouth, where it intermixes with the levator anguli oris. *Action*,— to depress the corner of the mouth, as in expressing anger.

*m.* The depressor labii inferioris *arises* broad and fleshy, from the under part of the lower jaw, at the side of the chin; from thence it runs obliquely upwards and inwards, till it becomes contiguous to its fellow in the middle of the lip, to be *inserted* into one half of the edge of the under lip. *Action*,— to assist in opening the mouth, by depressing the under lip, and pulling it a little outwards.

*n.* The buccinator *arises* from a ridge extending between the last dens molaris and coronoid process of the lower jaw, from the upper

jaw, between the last dens molaris and pterygoid process of the sphenoid bone; from the extremity of which it has also part of its origin. Thence going forwards with straight fibres, it adheres closely to the membrane which lines the mouth, and runs to be *inserted* into the corner of the mouth. *Action*,— to draw the angle of the mouth backwards and outwards, and to contract its cavity by pressing the cheek inwards, by which the food is thrust between the teeth in mastication. It is likewise active in blowing wind instruments, as a trumpet— hence its name.

*o.* The masseter *arises* by strong tendinous and fleshy fibres from the superior maxillary bone, where it joins the os malæ, and from the whole length of the under and inner edge of the zygoma; the outer part of the muscle slanting backwards, the inner part forwards, and in some measure decussating the other. In its descent, it covers the coronoid process, and under end of the temporal muscle, to be *inserted* into the angle of the lower jaw, and from that upwards to the outside of the coronoid process. *Action*,— to raise the lower jaw, and to pull it a little forwards or backwards, according to the direction of the fibres of the muscles.

*p.* The temporal fascia, or aponeurosis, covers the temporal muscle. It is strong and tense, of a semicircular form at its upper part, where it takes its origin from the semicircular ridge that extends from the external angular processes of the frontal bone to near the mastoid process of the temporal bone. At its inferior part it is attached to the upper part of the zygoma. This fascia serves to give an additional strength to the temporal muscle, by binding it in its situation, giving origin to the outer part of the fibres, so that the muscle has a double source of origin. On elevating this fascia, the temporalis will be seen to *arise* semicircular and fleshy, from the lower half of the parietal bone, and temporal fossa of the frontal bone, and from the squamous part of the temporal, and temporal plate of the sphenoid bones, likewise from the aponeurosis covering it; from these origins the fibres descend like radii, and the muscle sends off a strong tendon, which passes under the zygoma, to be *inserted* into the whole of the coronoid process of the lower jaw, which it incloses as in a sheath, and is continued to near the last dens molaris. *Action*,— to pull the lower jaw upwards, and a little backwards against the upper jaw.

2. The parotid gland is the largest of the salivary glands, of an irregular square figure, of a pale color, filling the space between the ramus of the lower jaw and the ear; it overlaps the posterior third of the masseter muscle. Its external surface is rather flat, but the internal is very irregular. It sinks in behind the jaw, fills the deep excavation between this bone and the ear, rests against the styloid process of the temporal bone, the internal carotid artery, jugular vein, and the nerves. In this situation it fills the posterior part of the glenoid cavity of the temporal bone, and adheres to the capsular ligament of the articulation. From the anterior and superior part of this gland, the parotid, or Steno's duct, arises, from the union of numerous small tubes, which issue each from one of the granulations of the gland. Between the duct and zygoma a small glandular mass is frequently found, named *socia parotidis*. The duct crosses the masseter muscle, parallel to a line drawn from the opening of the ear to the tip of the nose; it winds round the anterior edge of the masseter muscle, through a quantity of soft fat, and pierces the buccinator muscle to open through the mucous membrane of



the mouth, by a small opening opposite the second or third molar tooth of the upper jaw. The transversalis faciei artery generally accompanies this duct at its upper part.

4. The temporal artery, the continued trunk of the external carotid, ascends behind the articulation of the under jaw, and divides into branches, which are distributed upon the temporal fascia muscle and integuments. Two of these branches are more regular and conspicuous than the others, an anterior and posterior branch; the anterior passing forward over the forehead, to be distributed upon the muscles and integuments, and anastomoses with the continued trunk of the ophthalmic artery; the posterior passes towards the occiput in a tortuous direction, and forms numerous ramifications, which are distributed upon the adjacent parts, and anastomoses with the occipital artery.

This vessel is the only one that can be opened for the purpose of abstracting blood from the system, which operation is termed arteriotomy; the dissector should, therefore, pay particular attention to this artery. The method that I have usually followed to open this vessel, has been to mark the course of one of its branches, by tracing it with the finger, and marking it on the skin with dots made by a pen and ink. This being done, I have pinched up the integuments, and divided them with a lancet, when the artery has been brought into view. I have then made a puncture into it, and taken the quantity of blood required; then the vessel has been divided, and the hemorrhage has stopped. I have found this plan never to fail, and therefore can safely recommend it. On account of this vessel rolling so much in the cellular tissue, it is difficult to cut into it at once; I have always opened one of the branches, and never the trunk itself.

5. The facial, or external maxillary artery, is sent off from the external carotid, ascends upwards and inwards, running under the digastricus and stylo-hyoideus, then upon the mylo-hyoideus, under or through the submaxillary gland, passes over the middle of the lateral part of the inferior maxillary bone, runs up to the angle of the mouth to gain the inner canthus of the eye, where the artery terminates by dividing into two or three branches, which anastomose with the angular branches of the ophthalmic artery, forming a communication between the internal and external carotids. The branches sent off from this artery, are the mylo-hyoideal branch, to supply the parts beneath the lower jaw; the inferior coronary branch, to the under lip; the superior coronary artery, to the upper lip; the arteria nasalis, to the ala of the nose; and the angular branches, to anastomose with the branches of the ophthalmic artery.

When the dissector has duly considered the muscles of the face, the lips may be unsewn and drawn out by the hook, when the mucous membrane lining both the upper and under

lip may be removed, and a few fibres will be seen. Those from the upper lip are termed,

The depressor labii superioris alæque nasi, *arising* thin and fleshy, from the alveoli of the dentes incisivi and caninus of the upper jaw, running upwards, at the side of the furrow of the lip, to be *inserted* into the upper lip, and root of the ala nasi. *Action*,— to draw the upper lip and ala nasi downwards.

Those from the under lip,

The levator labii inferioris, *vel* levator menti, *arising* from the roots of the alveoli of the dentes incisores and dens caninus of the lower jaw, to be *inserted* into the under lip and skin of the chin. *Action*,— to raise the parts into which it is inserted.

*Description of the Parts seen in the Dissection of the Neck.*

*q.* The sterno-cleido-mastoideus *arises* by two distinct heads; the first, round, tendinous, and a little fleshy, from the top and anterior part of the sternum; the other, broad and fleshy, from the anterior third of the clavicle. A little above the clavicle, the two heads unite to form a strong muscle, which runs obliquely upwards and outwards; the greater part of it being covered by the platysma myoides, to be *inserted* by a strong tendon into the mastoid process, which it surrounds; and becoming thinner, the insertion extends as far back as the lambdoid suture. *Action*,— to turn the head to one side, and assist in rolling it. When both muscles act, they bow the head.

The nervus accessorius *arises* by small filaments from the lateral parts of the medulla oblongata and upper portion of the spinal marrow. The filaments from the spinal marrow come off between the anterior and posterior bundles of the cervical nerves,— the first of them frequently extending as far as the space between the sixth and seventh pairs. The different filaments unite by degrees into their respective trunks, and often have connexion, while within the dura mater, with one or two of the bundles of the uppermost spinal nerves; it runs through the foramen magnum occipitale. The trunk of the nerve then passes out, on each side of the cranium, in company with the nerve of the eighth pair, through the foramen lacerum in basi cranii, being included in its own peculiar sheath received from the dura mater. After perforating the cranium, it separates from the eighth pair, and descends obliquely outwards through the sterno-cleido-mastoideus to the trapezius muscle, upon which it is lost. At the fore part of the sterno-cleido-mastoideus it is joined by an arch to the sub-occipital, and frequently by another to the first cervical nerve.

*r.* The omo-hyoideus *arises* from the superior costa of the scapula, near the semilunar notch. It passes obliquely upwards and forwards, and is of a very slender form. Under the sterno-cleido-mastoideus, where it passes over the jugular veins and carotid artery, it becomes tendinous, and again grows fleshy, running to be *inserted* into the base of the os hyoides, at the side of the sterno-hyoideus. *Action*,— to depress the os hyoides, and pull it to one side; or, when both act, to draw it directly down.

*s.* The sterno-hyoideus *arises* from the upper part of the sternum internally, and from the adjacent parts of the clavicle and cartilage of the first rib;— ascending upon the fore part of the trachea, converging

towards its fellow, as it runs to be *inserted* into the base of the os hyoides. *Action*, — to depress the os hyoides.

*t.* The sterno-thyroideus *arises* from the upper and inner part of the sternum, and partly from the cartilage of the first rib; running along the fore part and side of the trachea and thyroid gland, diverging from its fellow, as it runs to be *inserted* into the under and lateral part of the thyroid cartilage. *Action*, — to depress the larynx.

*u.* The digastricus *arises* by a fleshy belly from the groove behind the mastoid process of the temporal bone; it runs downwards and forwards, and forms a strong round tendon, which passes through the stylo-hyoideus; it is then attached to the os hyoides, and having received an addition of tendinous and muscular fibres, it runs obliquely upwards and forwards, forming another fleshy belly, to be *inserted* into a rough sinuosity at the under part of the middle of the lower jaw. *Action*, — to open the mouth by pulling the lower jaw downwards and backwards; and when the jaws are shut, to raise the os hyoides, and, of course, the throat, — as in swallowing. The submaxillary gland is situated in a triangular space formed by this muscle and the lower jaw, superficially to the mylo-hyoideus.

*v.* The stylo-hyoideus *arises* from the under half of the styloid process. It goes downwards and forwards, splitting for the passage of the digastricus, to be *inserted* into the os hyoides, at the junction of the base and cornu. *Action*, — to pull the os hyoides to one side, and a little upwards.

*w.* The mylo-hyoideus *arises* fleshy, broad, and thin, from the inside of the lower jaw, between the last dens molaris and the middle of the chin, where it joins its fellow, running down behind the digastricus, to be *inserted* into the lower edge of the body of the os hyoides, and joined to its fellow by the intervention of a white tendinous line. *Action*, — to pull the os hyoides forwards, upwards, and to one side. Under this muscle the sub-lingual gland is situated, between it and the muscles of the tongue. Beneath this muscle the genio-hyoideus is situated, which *arises* from a tubercle on the under and inner part of the symphysis of the lower jaw, by a slender beginning, which descends and gradually becomes broader, to be *inserted* into the body of the os hyoides, under the former muscle. *Action*, — to draw the os hyoides towards the chin, when the jaws are shut; or the chin towards the os hyoides, when the latter is fixed by the muscles which come from the sternum.

6. The submaxillary gland is situated in a triangular boundary, which is formed internally by the digastricus, externally by the lower jaw. The gland is placed between the platysma myoides, and mylo-hyoideus; it is a salivary gland of the conglomerative kind. Its excretory duct, called the Whartonian duct, arises by numerous fine tubes from the various lobules of the gland, leaves it at its outer end, winds round the mylo-hyoideal muscle, and runs forwards and inwards towards the frænum linguæ, by the sides of which it opens into the mouth. The gustatory nerve accompanies this duct, at first superior, afterwards inferior to it. The orifice of the duct can be viewed by elevating the tongue, when a prominent papilla is seen, which is the opening of the duct.

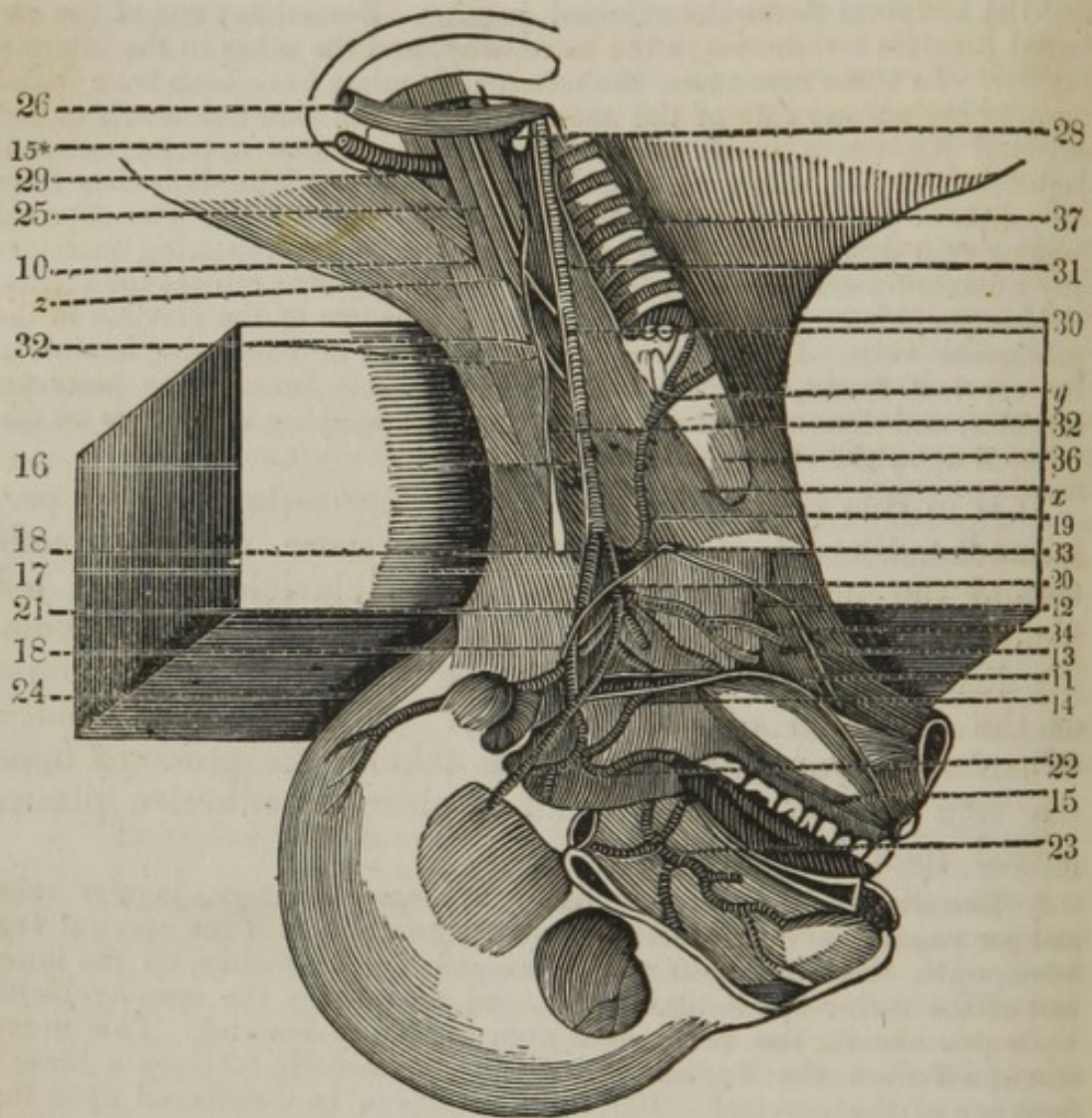
7. The external jugular vein, the continuation of the temporal vein. However, in the origin and termination of this vein, there is great variety in different subjects. It frequently happens that most of the ramifications, which commonly run from the face and throat into this vein, go to the internal jugular. Often the facial vein enters the internal jugular,

and the temporal forms the external jugular. Sometimes one of the external jugulars terminates in the usual way, and the other in the internal jugular. In some rare cases, the external jugulars have both been found terminating on one side of the neck. Besides the vein commonly called external jugular, a small subcutaneous vein, termed anterior external jugular, descends in the fore part of the neck, receiving branches from the adjacent parts, and terminating in the subclavian vein. The external jugular vein descends beneath the platysma myoides, receiving occasionally a communicating branch from the internal jugular, crosses the sternocleido-mastoideus, to terminate opposite the centre of the clavicle in the subclavian vein. In this course, it is situated between the laminae of the cervical fascia, which is placed immediately beneath the platysma myoides, and has several cutaneous nerves ramifying upon it, to be distributed upon the superficial parts.

It is in this vein the operation of venesection is often performed. Should it be required, pressure may be made behind the upper, and centre of the clavicle by the left hand, which will expose the course of the vein by its becoming distended; a lancet may then be introduced in the course of the direction of the fibres of the platysma myoides. When sufficient blood has been taken, the pressure upon the vein may be removed, and a piece of adhesive plaster placed upon the incision.

8. The sheath, or theca, containing the carotid artery, jugular vein, and par vagum nerve, is situated upon the lateral part of the cervical vertebræ, upon the outer part of the œsophagus and trachea, on the inner part of the sternocleido-mastoideus, and crossed by the omo-hyoideus. Upon this sheath, the descendens noni is seen to descend. This nerve is sent off from the lingual nerve, and occasionally receives a branch from one of the cervical. The trunk passes to be distributed upon the muscles situated between the sternum and os hyoides.

The dissector may next divide the sternocleido-mastoideus and the other muscles of the neck. Open the sheath containing the vessels, so as to be able to trace their course. To accomplish this, the under jaw may be sawn through at its symphysis; the zygoma can then be cut through with a saw, and a transverse section may be made from the end of the nasal bones to the lateral part of the inferior maxillary; and the superior maxillary bone may be taken away, so as to show the interior of the nose. By this section the dissector will have little difficulty in tracing the ramifications of the carotid artery and the nerves. The tongue may remain, and can be pulled tense by the use of the hooks. The accompanying plan will, no doubt, assist the dissector in his labor.



- x.* The situation of the thyro-hyoideus.  
*y.* The situation of the crico-thyroideus.  
*z.* The scalenus anticus.  
 10. The scalenus medius.  
 11. The lingualis.  
 12. The hyo-glossus.  
 13. The genio-hyo-glossus.  
 14. The stylo-glossus.  
 15. The tongue.  
 15.\* The subclavian artery.  
 16. The common carotid artery.  
 17. The internal carotid artery.  
 18. The external carotid artery.  
 19. The superior thyroid artery.  
 20. The lingual artery.  
 21. The external maxillary, or facial artery.  
 22. The internal maxillary artery.  
 23. The spheno-palatine artery.  
 24. The occipital artery.  
 25. The phrenic nerve.  
 26. The subclavian vein.  
 28. The termination of the internal jugular vein.

29. The nerves, passing to form the axillary plexus.
30. The par vagum.
31. The recurrent branch of the par vagum.
32. The great sympathetic nerve.
33. The lingual nerve.
34. The glosso-pharyngeal nerve.
35. The gustatory nerve.
36. The larynx.
37. The trachea.

*x.* The thyro-hyoideus *arises* from the sides of the thyroid cartilage, and ascends to be *inserted* into part of the base, and into almost all the cornu of the os hyoides. *Action*, — to depress the os hyoides, or to raise the thyroid cartilage.

*y.* The crico-thyroides *arises* from the side and fore part of the cricoid cartilage; runs obliquely upwards, to be *inserted*, by two portions, the one into the under part of the thyroid cartilage, the other into its inferior cornu. *Action*, — to depress and pull forwards the thyroid cartilage, or to raise and draw backwards the cricoid cartilage.

*z.* The scalenus anticus *arises* from the transverse processes of the third, fourth, and fifth cervical vertebræ, to be *inserted*, tendinous and fleshy, into the first rib, near its cartilage. The subclavian vein passes over this muscle.

10. The scalenus medius *arises* from the transverse processes of all the cervical vertebræ by tendinous slips, to be *inserted* into the outer and upper part of the first rib, from its root to near its cartilage. The subclavian artery and the nerves, which form the axillary plexus, pass between this and the former muscle. Behind this muscle there is the following :

The scalenus posticus, *arising* from the transverse processes of the fifth and sixth cervical vertebræ, to be *inserted* into the upper edge of the second rib, near the spine. *Action* of the three scaleni, — to bend the neck to one side, or when it is fixed, to raise the ribs and dilate the thorax, as in violent inspiration.

11. The lingualis *arises* from the root of the tongue, laterally. It advances between the genio-hyo-glossus and hyo-glossus, to be *inserted* into the tip of the tongue. *Action*, — to raise the point of the tongue, to contract its substance, and bring it backwards.

12. The hyo-glossus *arises* from the whole length of one half of the os hyoides; running upwards, and a little outwards, to be *inserted* into the side of the tongue, near the stylo-glossus. *Action*, — to depress the edge of the tongue, and thereby render its upper surface convex.

13. The genio-hyo-glossus *arises* from the same tubercle as the genio-hyoideus; its fibres spreading out like a fan, to be *inserted* into the whole length of the tongue, and base of the os hyoides. *Action*, — according to the direction of its fibres, — to draw the tongue forwards or backwards, — to pull it downwards, and render its dorsum concave, — and to make the os hyoides advance towards the chin.

14. The stylo-glossus *arises* from the styloid process of the temporal bone, and from a ligament which connects that process to the angle of the lower jaw. It goes downwards and forwards, and is of a slender form, to be *inserted* into the root of the tongue, near the hyo-glossus; and running along its side is insensibly lost near the apex. *Action*, — to draw the tongue backwards, and to one side.

15. The tongue is of an oval form, divided into base, body, and apex. The base, or posterior part of the tongue, is connected to the os hyoides, and, by the medium of this, to the adjacent bones and muscles. The body, or middle part of the tongue, terminates anteriorly in the loose movable point. On the dorsum or upper surface, there is a *linea mediana*, or middle groove, running longitudinally, and dividing it into two lateral convexities. The inferior surface, which reaches only from the middle of the tongue to the point, is connected to the parts below by the sublingual ligament, or *frænum linguæ*, which is a doubling of the skin or lining of the mouth. The sides of the tongue are fixed to the lower jaw and styloid processes, and parts adjacent, by membranous ligaments. The tongue is chiefly composed of the fibres of the muscles which serve for its motions. These fibres are disposed in various directions, and intermixed with medullary fat. The muscles have already been described.

The tongue is covered by a continuation of the common integuments, which are preserved soft and moist by the saliva. The cuticle forms *vaginæ* for receiving the substances called *papillæ*. The *papillæ* are divided into three kinds, the *maximæ*, *mediæ*, and *minimæ*.

The first class, the lenticular *papillæ*, are by much the largest; of a lenticular form, placed at the base of the tongue, in superficial *fossulæ*, and the whole are arranged in such a manner as to form an angle with its point backwards: they are glands of the salivary kind, and have each of them a small perforation in the middle of its convex surface at the root of the tongue. Besides these *papillæ*, there are numerous mucous follicles, which cover the greater part of the surface of the root of the tongue. At the root of the tongue, and behind the angle formed by the *papillæ maximæ*, there is a hole called *foramen cæcum*.

The second class, the semi-lenticular *papillæ*, are much smaller than the former, and are scattered over the upper surface of the tongue, at some distance from each other. They are of a cylindrical form, and terminate by a round extremity.

The third class, called *papillæ minimæ*, *vel villosæ*, are the most numerous, but very minute. They occupy almost the whole upper surface of the tongue, and are most abundant towards the apex, where the sensation of taste is more acute. The two latter classes are formed chiefly of the extremities of nerves, and constitute the real organ of taste.

The accompanying diagram has been added, to convey an idea of the various ramifications of the several arteries that are to be seen in the dissection of the neck.

1. The arch of the aorta, sending off three branches.

2. The arteria innominata, dividing into

3. The right subclavian.

4. The right carotid.

5. The left carotid.

6. The left subclavian. This vessel passes obliquely upwards and outwards, and sends off five branches.

7. The vertebral artery.

8. The inferior thyroid artery forming an axis, sending off

9. The inferior thyroid, which passes under the carotid artery to supply the thyroid gland, and anastomoses with the superior thyroid artery. This vessel is the artery which would become enlarged, and carry on the circulation, if the carotid artery were tied.

10. The cervicalis ascendens.

11. The transversalis colli.

12. The supra scapular.

13. The cervicalis profundus.

14. The superior intercostal artery, which passes down on the heads of the ribs, and divides into branches, which supply the three superior intercostal spaces.

15. The internal mammary artery, which sends off

16. The pericardiac artery.

17. The arteria comes nervi phrenici.

18. The superior diaphragmal artery.

19. The left common carotid artery, dividing into

20. The internal carotid.

21. The external carotid, sending off

22. The superior thyroid artery.

23. The lingual artery.

24. The external maxillary, or facial artery.

25. The internal maxillary artery.

26. The arteria transversalis faciei.

27. The temporal artery.

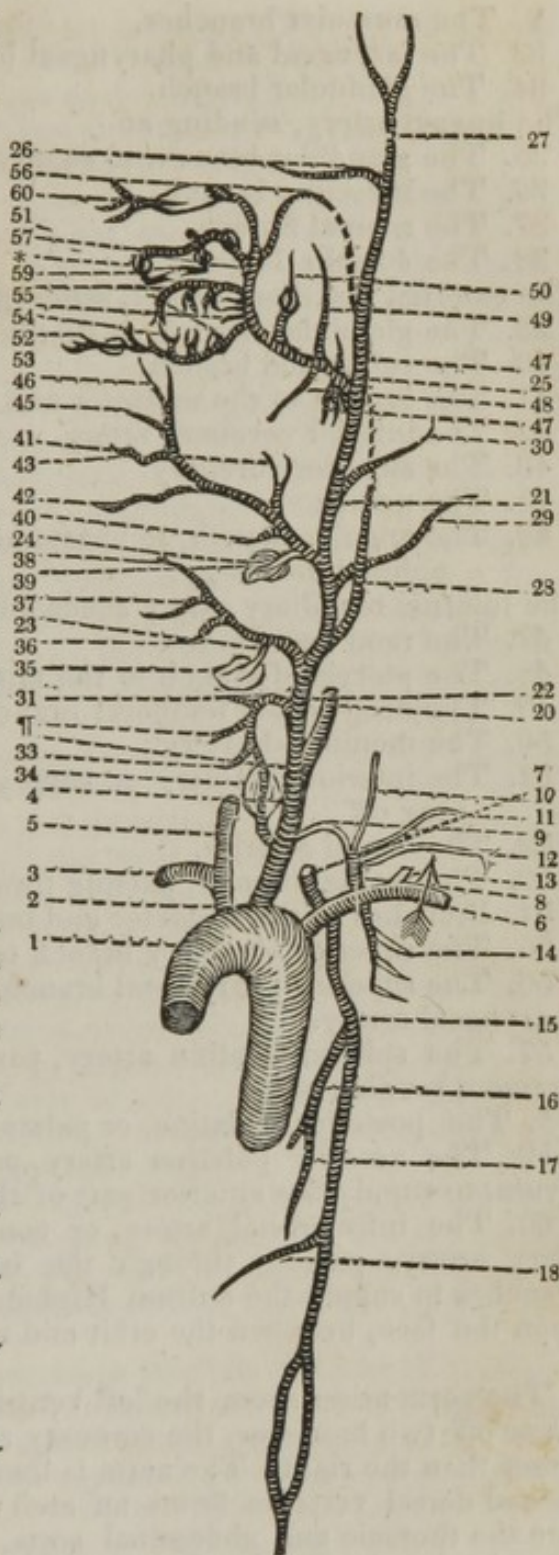
28. The inferior, or ascending pharyngeal artery.

29. The occipital artery.

30. The posterior auricular artery.

The superior thyroid artery descends, and sends off

31. The hyoideal branch.





- ¶. The muscular branches.
33. The laryngeal and pharyngeal branch.
34. The glandular branch.
- The lingual artery, sending off
35. The glandular branch, to supply the sublingual artery.
36. The muscular branch.
37. The reuinal branch.
38. The dorsalis linguæ.
- The external maxillary artery, sending off
39. The glandular branch, to supply the submaxillary gland.
40. The submental branch.
41. The branch to the masseter and buccinator muscles.
42. The inferior coronary artery.
43. The superior coronary.
45. The nasalis.
46. The angular branch, to anastomose with the angular branch of the ophthalmic artery.
- The internal maxillary artery sends off
47. The rami parotidea.
48. The pterygoid branch to the muscles of that name.
49. The deep-seated temporal branch.
50. The meningeal artery.
51. The inferior alveolar, to supply the teeth of the under jaw, sending off
52. The dental arteries.
53. The mental branch, passing through the foramen mentale.
54. Branches to the masseter and buccinator.
55. The superior alveolar branch to the teeth of the upper jaw.
56. The superior pharyngeal branch, anastomosing with the ascending pharyngeal artery.
57. The spheno-palatine artery, passing through the spheno-palatine foramen, sending off
- \*. The posterior palatine, or palato-maxillary artery.
59. The anterior palatine artery, passing through the foramen incisivum, to supply the anterior part of the hard palate.
60. The infra-orbital artery, or continued trunk of the internal maxillary artery, passing through the infra-orbital foramen, sending off branches to supply the antrum Highmoranium, and ultimately ramifying upon the face, between the orbit and upper lip.

The aorta arises from the left ventricle of the heart, and immediately sends off two branches, the coronary arteries, to the heart, the left being larger than the right. The aorta is then termed ascending, and about the second dorsal vertebra forms an arch; it then descends, and is divided into the thoracic and abdominal aorta. The arch of the aorta sends off three branches; the arteria innominata, the left carotid, and left subclavian. The left carotid is found to be generally sent off from the arch, close to the arteria innominata, and the subclavian at about twice the distance; but they are seldom sent off alike. The arteria innominata soon divides into the right common carotid and right subclavian, the left subclavian taking its origin from the arch of the aorta. The two subclavians ascend obliquely, the left more than the right, pass between the anterior and middle scaleni muscles over the first rib, under the clavicle and subclavian muscle, to become axillary. In their course they send off

the following branches, five generally in number. The vertebral, running upon the longus colli, enters the foramina in the transverse processes of the cervical vertebræ: then passes through the foramen magnum occipitale, having made contortions similar to the internal carotid. — The further distribution of this artery is hereafter given.

2dly. The inferior thyroid arises at the inner edge of the scalenus anticus, inclining forwards and upwards, but soon divides into branches, when it is termed axis thyroidea. The continued trunk of the inferior thyroid ascends obliquely upwards and inwards, passing in a winding manner under the common carotid artery, taking a turn downwards under the sterno-hyoideus and sterno-thyroideus, it forms an arch; its convexity being downwards, supplies the thyroid gland, inosculates with its fellow, and superior thyroid artery, and gives branches to the trachea, which descend in the thorax, anastomosing with the bronchial arteries, and twigs to the larynx, pharynx, and œsophagus. The axis thyroidea gives off also the following branches, viz. — The arteria cervicalis ascendens, sometimes arising from the last-mentioned branch, and not from the axis: it is a small artery which ascends on the scalenus anticus, near the phrenic nerve, to be distributed to the deep-seated muscles on the front and sides of the vertebræ. Twigs passing through the intervertebral foramina to anastomose with the vertebral and spinal arteries. The arteria supra-scapularis, or transversalis humeri, passes across the scaleni muscles, subclavian artery, and phrenic nerve, runs along the base of the triangular space, where the subclavian vessels lie; formed at its inner edge, by the sterno-cleido-mastoideus and scalenus anticus; on the outer and upper side, by the omo-hyoideus; and below, by the clavicle. The artery passes through the notch at the superior costa of the scapula, to enter the supra-spinal fossa, sometimes above the ligament, which fills up the notch, but generally below, forming it into a foramen. The artery then divides into an acromion branch, to supply the acromion process, trapezius, and deltoid; a branch to the supra-spinal fossa, to supply that muscle inosculating with the articular arteries; a branch to the infra-spinal fossa, creeping under the acromion to supply the teres major and minor, which anastomose with the posterior scapular. The arteria transversalis colli is the largest branch of the axis thyroidea; like the former artery, it passes obliquely across the scalenus anticus, and brachial plexus of nerves, to supply the muscles of the neck, a branch running to the upper angle of the scapula, to the muscles arising from the upper part of that bone.

The cervicalis anterior sometimes comes off from the root of the inferior thyroid, or from the subclavian. It ascends in the neck, furnishing superficial branches to the muscles which go from the trunk of the body to the neck, and deep branches to the glands, nerves, &c. lying on the fore and lateral parts of the cervical vertebræ. The deep branches anastomose with the vertebral and occipital arteries, and some, passing through the intervertebral holes where the nerves come out, communicate with the spinal arteries.

3dly. The cervicalis posterior arises in common with the anterior cervical, or with the inferior thyroid. This is larger than the former, lies farther out, and runs in a winding direction outwards and upwards; it supplies the skin and muscles at the lateral and back part of the neck, communicates with branches of the occipital and vertebral arteries, and sends a principal branch downwards to the parts about the top of the shoulder, and the upper and lateral parts of the thorax.

4thly. The *mammaria interna* arises from the subclavian, opposite the vertebral artery, and descends between the pleura and cartilages of the true ribs, and between the *intercostales interni* and *sterno-costalis*, at the edge of the sternum; sending off a small reflected branch to the integuments and muscles adjacent to the clavicle, one or two small branches to the thymus gland, which, like the gland itself, are more considerable in the young subject, and a minute branch, termed *comes nervi phrenici*, to accompany the phrenic nerve; it gives twigs to the neighboring membranes, and is distributed upon the diaphragm; sends some small branches, called *mediastinæ* and *pericardiacæ*, to the mediastinum and pericardium: several branches, outwards, to the *intercostales*, and others between the cartilages of the true ribs at the edge of the sternum, to the pectoral muscles, *mamma*, and integuments, which communicate with those of the *thoracicæ externæ*; and a large branch, at the under end of the thorax, termed *musculo-phrenica*, which is dispersed upon the diaphragm. The mammary artery afterwards emerges from the thorax, commonly under the cartilage of the seventh true rib, and forms an epigastric branch, which runs upon the back part of the *rectus abdominis*, between that muscle and the posterior part of its sheath, upon the upper end of which it is dispersed, after sending a branch to the oblique muscles, and anastomoses with the epigastric artery.

The superior intercostal artery is given off from the subclavian, opposite the *cervicalis posterior*. It descends in front of the neck of the first rib, external, to the first thoracic ganglion of the sympathetic nerve, and sends off a branch to the first intercostal space; in like manner to the second intercostal space, and a branch sometimes to the third. The subclavian artery, having given off these branches, passes under the clavicle and over the first rib to become the axillary artery.

The carotid arteries,\* after emerging from the thorax, ascend upon the *longus colli*, and *rectus capitis anticus major*, on each side the neck, between the trachea and internal jugular veins, behind the *sterno-cleido-mastoideus*, crossed by the *omo-hyoideus*, they gradually recede from each other, and do not send off any branches till they reach the top of the larynx, opposite the *os hyoides*, where they divide into external and internal carotids, the latter entering the *canalis caroticus* to the brain; and the former, the external carotid, being placed more anteriorly, and nearer the larynx than the internal, which lies deeper, and is, at its root, the larger of the two.

\* Tying the common carotid artery can be done in two places, either above or below the *omo-hyoideus* muscle, — which last crosses the *sterno-cleido-mastoideus* posteriorly. These generally decussate nearly opposite to the upper margin of the cricoid cartilage. By laying a thread from the anterior part of the mastoid process to the centre of the upper bone of the sternum, and by extending another from the side of the body of the *os hyoides* to a little nearer the sternum than the central part of the clavicle, we can form an idea of the course of these muscles. Just beneath the point of intersection of these two lines, the common carotid may ordinarily be found. Above this spot the course of the vessel may be discovered, by laying a thread from the point of decussation up to the angle of the jaw. The incision should be two inches in length, terminating just below the *omo-hyoideus* muscle. The *descendens noni* nerve will be seen upon the sheath of the artery. This nerve is to be turned aside. In cutting for the artery beneath, make the incision from a little above the intersection of the *omo-hyoideus* with the *sterno-cleido-mastoideus* on the internal edge of this last muscle, to near the sternum. Divide the *platysma* and the strong cervical fascia. This must be done with caution, on account of the number of veins in this region.

The external, though smaller than the other, appears as a continuation of the common trunk.

It runs up behind the angle of the lower jaw, towards the temple, under the digastricus and stylo-hyoideus muscles, and in its passage before the ear is sunk deep in the substance of the parotid gland, which it supplies; it then runs over the zygomatic process, and in its course sends off the following principal branches.

The arteria thyroidea superior comes off from the root of the external carotid, and sometimes from the top of the common carotid. It passes downwards and forwards in a winding direction under the omo-hyoideus, sterno-hyoideus, and sterno-thyroideus; sends branches to the muscles under the os hyoides, branches to the sterno-cleido-mastoideus, platysma myoides, and skin near the larynx; and a laryngeal branch to the small muscles and other parts peculiar to the larynx.

The thyroid branch, or glandular branch, is the continuation of the trunk, dispersed upon the substance of the thyroid gland: it anastomoses with its fellow, and with branches of the inferior thyroid.

The carotid, immediately above the former, sends off the arteria lingualis. It passes forwards and upwards over the cornu of the os hyoides, under the digastricus, stylo-hyoideus, mylo-hyoideus, and hyo-glossus, towards the under and fore part of the tongue. It sends off a branch to supply the sublingual gland and adjacent muscles; the dorsalis linguæ, to the fauces, amygdalæ, epiglottis, and pharynx; the ramus raninus; the continued trunk of the lingual artery runs at the under and lateral parts of the tongue, and terminates near its point. The artery sends off also branches to supply the muscles of the tongue.

The external carotid sends off the arteria facialis, *vel* maxillaris externa, which runs forward, and goes under the stylo-hyoideus, and tendon of the digastricus, over the mylo-hyoideus; it perforates the submaxillary gland, mounts suddenly over the angle of the lower jaw, at the under and fore part of the masseter, under the zygomatic muscles, from whence it proceeds in a tortuous manner by the side of the nose, towards the inner canthus of the eye.

In its course, the following branches are sent off to the adjacent parts:

1st. To the submaxillary gland. 2d. The submental branch, which is distributed upon the muscles situated between the os hyoides and lower jaw. 3d. Small branches to the buccinator. 4th. The coronaria inferior, given off at the corner of the mouth, running in a tortuous manner on the under lip, and communicating with the branch of the opposite side. 5th. The coronaria superior, larger than the former, to the upper lip, uniting with its fellow, supplying the point of the nose. 6th. Nasal branches to the ala nasi; and 7th. The artery terminates in the angular branches which run at the inner angle of the eye, to supply this part, anastomosing with the angular branch of the ophthalmic artery, and forming a communication between the internal and external carotids.

The carotid sends off next, the arteria maxillaris interna, which goes off from that part of the trunk which is covered by the parotid gland, and at its origin lies behind the middle of the upright plate, between the condyloid and coronoid processes of the lower jaw.

It passes first between the jaw and pterygoideus externus, and afterwards ascends, in a tortuous manner, towards the back part of the antrum maxillare, sending numerous branches to the parts belonging to both jaws.

At its origin, it furnishes twigs to the fore and adjacent parts of the outer ear and parotid gland, and sends off—A deep-seated temporal branch, to ramify upon the bones forming the temples, under the temporalis muscle; a branch to the pterygoideal muscles; the arteria duræ matris media maxima, *vel* meningea, which runs between the external and internal carotids, passes through the foramen spinale of the sphenoid bone, and spreads, like the branches of a tree, over the surface of the dura mater and inside of the parietal bone: before entering the foramen spinale, it sometimes gives twigs to the muscles and other parts near it, and within the cranium, besides the branches mentioned, it furnishes twigs to the substance of the bones, and to the internal ear. The inferior alveolar branch runs in the inferior maxillary canal, sending branches to the substance of the bone, and to the teeth: the remainder of it passes out at the foramen mentale, communicating upon the chin with branches of the facial artery, and with its fellow. The arteria alveolaris superior, sends branches to the soft parts surrounding the superior maxillary bone, and branches enter the foramina in the bone, to supply the teeth and antrum. Branches are sent off to supply the masseter and buccinator muscles, which pass between the joints, to ramify over the cheek.

The large lateral nasal, or spheno-palatine branch, enters the foramen spheno-palatinum, and divides, at the upper and back part of the nose, into many branches, which supply the greater part of the inside of the nose, a branch to the posterior ethmoid cells, a large branch to the septum narium, a conspicuous branch passing through the spongy bones to the bottom of the nose, furnishing twigs to the membrana schneideriana and antrum maxillare. The palato maxillary branch, sometimes given off from the latter, and at other times from the internal maxillary itself, runs through the posterior palatine foramen to supply the under part of the nose and palate, sending off a branch which passes through the foramen incisivum. The superior pharyngeal, supplying and terminating at the upper part of the pharynx. The infra orbiter branch passing in the canal, at the lower part of the orbit, supplying the soft parts and antrum, then making its exit at the foramen infra orbitarium, and ending in small branches which anastomose with the facial artery.

The trunk of the external carotid, having given off the arteries already mentioned, passes up between the meatus auditorius externus and root of the zygoma, and forms the temporal artery, from the root of which are sent off several branches of unequal size to the parotid gland, and

The transversalis faciei, arising nearly opposite to the internal maxillary, proceeds transversely under the zygoma, over the masseter, and, near the parotid duct, after giving branches to the parotid gland, it supplies a large portion of the cheek, communicating with the facial and internal maxillary arteries; the temporal artery then divides into branches, which are distributed on the temporal muscles, superficially, and deeper seated, and freely anastomose with the occipital, and the branches of the opposite side.

The branches from the outer side of the carotid artery, are the pharyngeal inferior, *vel* ascendens, which is a small artery, sometimes arising near the lingual, and frequently from the root of the occipital. After ascending some way, it divides into branches, which are dispersed upon the pharynx and fauces.

The arteria occipitalis arises from the back part of the external carotid,

nearly opposite the external maxillary branch. It runs over the beginning of the internal jugular vein, and afterwards passes between the atlas, mastoid process, and posterior belly of the digastricus. It goes under the upper ends of the trachelo-mastoideus, splenius, and complexus; after which it becomes more superficial, where it runs near the middle of the occipital bone, supplying the muscles, &c.

The carotid also sends off the auricularis posterior, which runs under the digastricus, and twigs, which run behind the ear, giving off branches to the integuments, muscles, and bone, and terminating on the side of the head.

25. The phrenic, or diaphragmatic nerve, receives a small filament from the third cervical; but is chiefly formed by a branch from the fourth, and by one, and sometimes by two, from the fifth cervical nerve. It descends in the neck, along the outer and fore part of the scalenus anticus, and enters the thorax behind the anterior extremity of the first rib, between the subclavian artery and corresponding vein. In the thorax, it passes over the root of the lungs, and then proceeds along the pericardium, to which it adheres closely in its way to the diaphragm. The right phrenic has nearly a straight direction, while the left makes a considerable curve near its under end, corresponding with that part of the pericardium which covers the point of the heart. Upon the surface of the diaphragm, the trunk is divided into several branches, which are distributed in a radiated form upon the sides of that muscle.

The internal jugular vein is a continuation of the lateral sinus, which receives the blood from the other sinuses sent to the brain from the carotid and vertebral arteries; it passes out of the cranium through the foramen lacerum in basi cranii, and forms the internal jugular vein, each of which, at its origin, is bulged back in form of a varix, which is lodged in a fossa at the root of the pars petrosa of the temporal bone.

The internal jugular vein descends behind the sterno-cleido-mastoideus, upon the fore and outer part of the common carotid artery, with which it is included in a sheath of cellular substance, and is frequently a good deal dilated, towards its under extremity. In its course in the neck, it receives branches from the pharynx and muscles adjacent to it; the internal maxillary veins; one or more branches from the occiput; the lingual vein, which sometimes terminates in the external jugular; the superior laryngeal, and now and then the inferior laryngeal, which more frequently goes into the subclavian, or to the top of the vena cava. The internal jugular also receives branches from the muscles of the neck, and at length terminates in the subclavian vein.

The four inferior cervical and first dorsal nerves, pass between the scalenus anticus and medius, under the clavicle and over the first rib, to form the axillary plexus of nerves.

The accompanying diagram of the par vagum and glosso-pharyngeal nerve has been added, to enable the dissector to have a better idea of their course and distribution; also to enable him to trace the ramifications of the branch with greater facility.

1. The common origin of the par vagum, and glosso-pharyngeal nerve, from between the corpora olivaria and restiforma.

2. Passing out of the cranium through the foramen lacerum in basi cranii.

3. Filaments passing to be connected to the cervical, great sympathetic, and lingual nerves.

4. The glosso-pharyngeal nerve quitting the par vagum, running between the external and internal carotid arteries, to be distributed upon the tongue and pharynx.

5. The par vagum descending in the theca, containing the jugular vein and carotid artery behind and between the two.

6. The superior laryngeal nerve. It passes beneath the carotid artery towards the thyro-hyoideal membrane, when it divides into three branches.

7. The superior branch.

8. The inferior.

9. The internal.

10. The par vagum entering the thorax, between the subclavian artery and vein, sending off

11. The recurrent branch, which on the right side passes from before, backwards round the arteria innominata, but on the left side, round the arch of the aorta.

12. The par vagum surrounding the œsophagus, forming the œsophageal plexus, which sends off, assisted by branches of the great sympathetic :

13. The pulmonary plexus to the lungs.

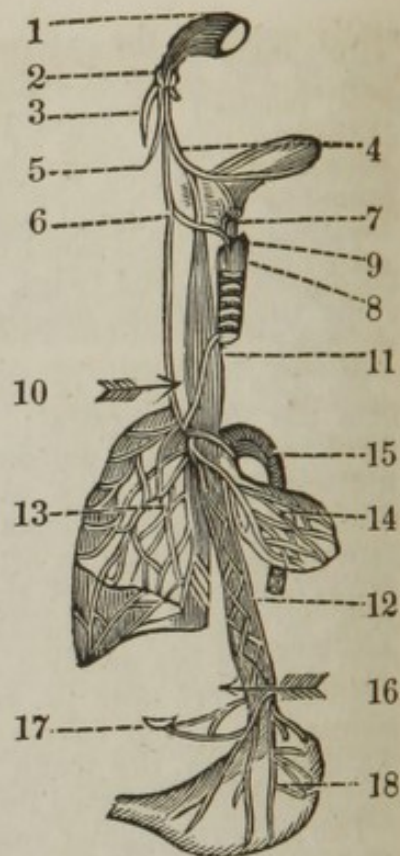
14. The cardiac and pericardiac plexus.

15. The aortic plexus.

16. The par vagum entering the abdomen, through the left foramen of the diaphragm.

17. The par vagum sending off some small filaments to the semilunar ganglion.

18. The par vagum terminating upon the stomach, forming the stomachic plexus.



The eighth pair of nerves arise from the sides of the corpora olivaria, and consist, on each side, of the nervus glosso-pharyngeus, and par vagum, — the former is the smaller of the two.

The par vagum comes off immediately under the glosso-pharyngeus, and is composed of several separated fasciculi, which soon collect into a single cord. The two nerves pass outwards, go through the base of the cranium, immediately before the end of the lateral sinus, by the foramen lacerum in basi cranii. The glosso-pharyngeus, upon its exit from the cranium, sends a branch backwards, which joins the digastric branch of the portio dura. A little lower, it gives off branches, which, with others from the pharyngeal branch of the eighth pair, and from the great sympathetic nerve, form a plexus which embraces the internal carotid artery, and afterwards sends branches along the common

carotid to the heart. Still lower, it gives branches which communicate with others belonging to the pharyngeal nerve, and go to the upper part of the pharynx, and to the stylo-pharyngeus. The glosso-pharyngeal, after sending a twig or two to the upper part of the pharynx, tonsil, and membrane of the epiglottis, divides into many branches, which run partly to the margin and partly to the middle of the root of the tongue, supplying, especially, the *papillæ majores*, and the parts in their neighborhood.

The *par vagum*, upon emerging from the cranium, descends in the neck at the outer and back part of the common carotid artery, to which it is closely united, being included in the same common sheath of cellular substance, between the artery and vein, in a triangular space. At the upper part of the neck, it transmits a branch, called pharyngeal, to the pharynx; and immediately afterwards, a larger one, termed laryngeus superior, to the larynx. The pharyngeal is afterwards joined by branches from the glosso-pharyngeus, and descends obliquely over the internal carotid artery: and near the origin of this artery, it sends filaments which join others from the upper part of the great sympathetic, which creep along the common carotid. Upon the middle of the pharynx, it expands into a gangliform plexus, from which many small branches are sent out to be distributed upon the three constrictors of the corresponding side of the pharynx.

The laryngeus superior descends obliquely forwards between the carotid arteries and pharynx; and behind the origin of the carotids is divided into an internal, a superior, and an inferior branch. The internal passes forwards between the *os hyoides* and superior cornu of the thyroid cartilage, dividing into numerous branches, some of which go to the arytenoid gland, and to the *arytenoideus obliquus et transversus*, and others to the glandular membrane of the epiglottis; while the greater number and the largest of these branches are dispersed upon the glandular membrane lining the upper portion of the larynx and parts adjacent. The superior branch runs to the adjacent parts about the *os hyoides*. The inferior branch, which is more properly termed pharyngo-laryngeus, is originally composed of a branch from the internal laryngeal, and another from the great sympathetic; and is connected by a filament to the pharyngeal, and sometimes also by one to the internal laryngeal nerve. It imparts twigs to the middle and lower constrictors of the pharynx, and afterwards terminates in the thyroid gland and inner part of the larynx. The *par vagum* having given off these branches, descends still between the carotid artery and internal jugular vein, enters the thorax between the subclavian artery and vein, and sends a reflected twig, from before, backwards, on the right side, round the *arteria innominata*, and on the left, round the arch of the aorta; the reflected twigs pass upwards between the *œsophagus* and trachea, and are distributed upon the muscles of the posterior part of the larynx, being the nerve of speech. The *par vagum* then enters the posterior mediastinum, and forms a plexus round the *œsophagus*, the right being before, and the left behind it. This pair of nerves, assisted by the great sympathetic, then form—the pulmonic plexus, to supply the lungs; the cardiac to the heart; the pericardiac to the pericardium; the aortic to the aorta; and then pass, still surrounding the *œsophagus*, through the foramen sinistrum of the diaphragm, and end in forming the stomachic plexus, sending a few twigs to the semilunar ganglion on the *cœliac artery*.



The following diagram has been added, to assist the dissector in the knowledge of the course and distribution of the great sympathetic nerve.

1. The formation of the nerve in the canalis caroticus, by branches of the fifth and sixth pair.

2. Passing through the canalis caroticus.

3. Sending off branches to unite with the cervical, the par vagum, and ninth pair.

4. The superior cervical ganglion, situated opposite the second cervical vertebra, sending off branches which pass to supply adjacent parts of the neck.

5. The second or middle cervical ganglion, situated opposite the fourth dorsal vertebra.

6. The inferior cervical ganglion, placed upon the sixth cervical vertebra. These two ganglia send branches to adjacent parts of the neck, and some filaments which enter the thorax over the subclavian vein, to assist the par vagum to form the cardiac and pericardiac plexus.

7. The sympathetic, entering the thorax behind the subclavian vein, giving off a small recurrent branch which runs from the anterior to the posterior part, to supply the adjacent parts.

8. The sympathetic, forming ganglia with all the dorsal nerves, twelve in number, below the heads of each rib.

9. The situation where the nerve perforates the diaphragm, running through its muscular portion.

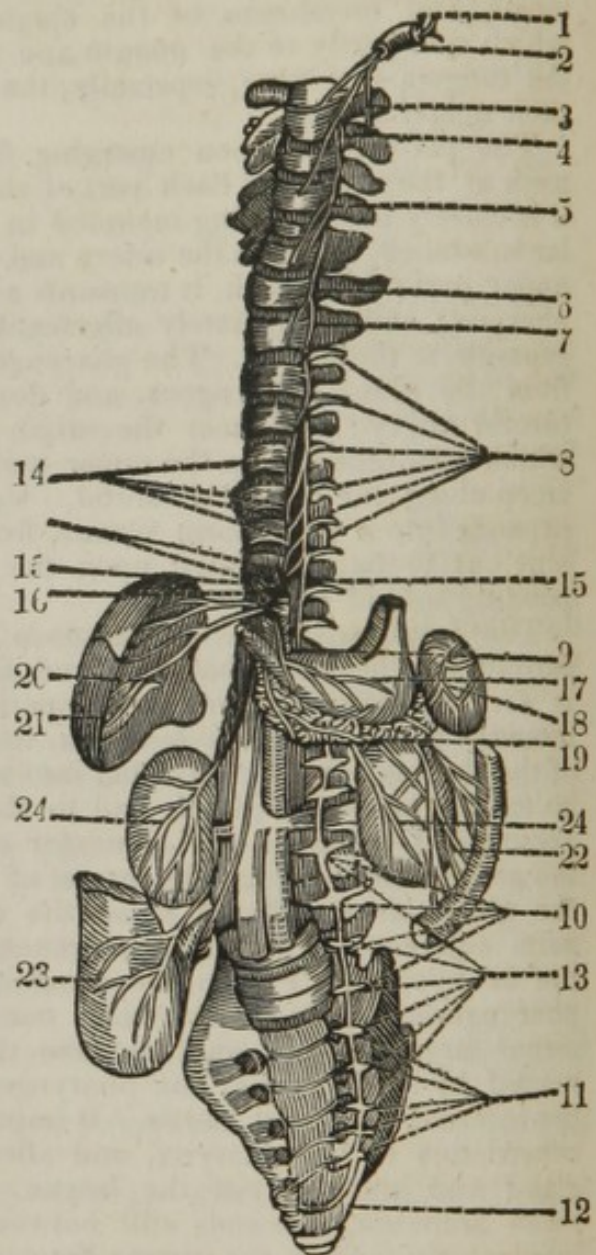
10. The nerve forming ganglia with the lumbar nerves.

11. The nerve descending upon the anterior surface of the sacrum, forming ganglia with the sacral nerves.

12. The nerve uniting with its fellow, forming the ganglia imparia.

13. The two last lumbar and three superior sacral, forming the hypogastric plexus, which sends off several branches to supply the pelvic viscera.

14. The third, fourth, fifth, sixth and seventh dorsal ganglia, sending off branches to unite together, to form the ramus splanchnicus, which passes between the long and short crura of the diaphragm to the cœliac artery, where it forms



15. The semilunar ganglion. The two semilunar ganglia are united together by numerous filaments, forming
16. The solar plexus, which plexus gives off
  17. The inferior stomachic plexus, to the stomach.
  18. The splenic, to the spleen.
  19. The pancreatic, to the pancreas.
  20. The hepatic, to the liver.
  21. The cystic, to the gall bladder.
  22. The superior mesenteric, to the small intestines.
  23. The inferior mesenteric, to supply the large intestines, and
  24. The emulgent plexus, to supply the kidneys.

22. The great sympathetic nerve obtains its name from its numerous connexions with the other parts of the body; it is formed by the reflected branch from the second of the fifth pair, and by one or two, and sometimes three small filaments sent down from the sixth pair, while in the cavernous sinus. Upon the surface of the internal carotid artery, while in the carotid canal, the branches of the fifth and sixth nerves form the great sympathetic; they are pulpy and tender, and form a plexus which surrounds the carotid artery; from which the trunk of the sympathetic is most frequently considered as being sent out. After escaping from the carotid canal, the trunk is closely connected, for a short space, with the trunks of the eighth and ninth nerves; and, separating from these, it expands into a large ganglion, termed ganglion cervicale superius, of a long oval form, and situated opposite the second cervical vertebra. From this ganglion the nerve comes out, and descends on the rectus capitis anticus major, behind the sheath containing the carotid artery, jugular vein, and par vagum. At the under part of the neck, and nearly where the inferior laryngeal artery turns towards the larynx, the sympathetic forms another ganglion, termed by some authors cervicale medium, and by others cervicale inferius. The ganglion medium is somewhat similar in shape and size to the ganglion superius; though it varies considerably in these respects in different subjects. From this ganglion, branches are sent down, one of which, larger than the rest, and considered as the continuation of the trunk, turns outwards between the inferior laryngeal and vertebral arteries to another ganglion. The third ganglion is placed at the head of the first rib, and is termed ganglion cervicale inferius.

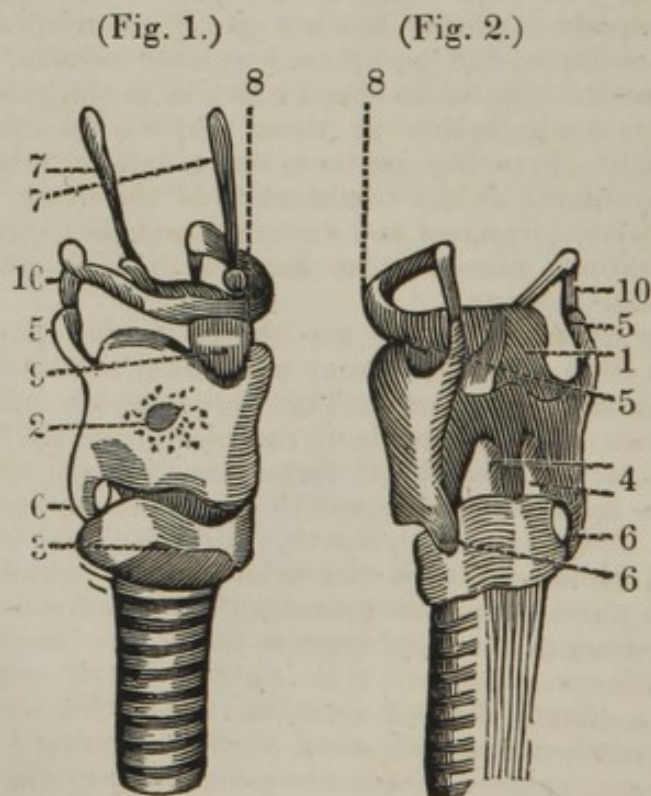
The great sympathetic enters the thorax behind the subclavian artery, and sends off a small recurrent twig from behind, forwards round the artery to the adjacent parts. The nerve having passed behind the pleura, runs down upon the heads of the ribs, not in the posterior mediastinum, but externally to it; it forms ganglia between the head of the ribs at the intercostal spaces with the dorsal nerves; branches are given off from about the third, fourth, fifth, sixth, and seventh ganglia, which descend obliquely upon the sides of the vertebræ and unite, forming a trunk; and the nervus splanchnicus, which passes between the long and short crura of the diaphragm to the cœliac iliac artery, where it forms the semilunar ganglion. The right and left semilunar ganglia are united by a plexus termed solar, and from this plexus the several nerves are given off to the abdominal viscera, forming a plexus to each, viz. — The splenic, to the spleen; the pancreatic, to the pancreas; the hepatic, to the liver; the superior mesenteric, to the small intestines; the inferior mesenteric, to the large intestines; the renal, to the kid-

neys; the spermatic to the testicle, consisting of a superior and inferior set of capillary branches, the former derived from the renal, the latter from the lumbar. The great sympathetic still continuing to form ganglia with the remaining dorsal nerves, perforates the diaphragm at its posterior part, and is termed the posterior great sympathetic, the anterior being the ramus splanchnicus.

The posterior sympathetic nerve, after reaching the abdomen, makes a sweep forwards upon the anterior and lateral part of the lumbar vertebræ, between the tendinous crura of the diaphragm and the psoas magnus. It afterwards descends into the pelvis, nearly of the same size as at the superior parts of the body, and passes over the anterior surface of the os sacrum, at the inner side of the great sacral foramina; towards the lower part of the pelvis, it becomes considerably smaller, and at last finishes its course upon the surface of the os coccygis, where it unites into an arch with its fellow of the opposite side. In the loins, it forms ganglia similar to those in the thorax, each of which is connected behind by two or three long slender branches to the roots of the lumbar nerves, and before, by other slender nerves, to the aortic plexus. In the pelvis also it forms ganglia, which are connected to the sacral nerves on one side, and to the great sympathetic on the other, by cross branches. Filaments are sent off, in the pelvis, from the sympathetic to the muscles and membranes about the os coccygis, and to the intestinum rectum.

35. The gustatory nerve is a branch of the third division of the fifth pair; it passes to be distributed upon the tongue, forming the villi, being the nerve of taste.

36 and 37. The trachea at its superior part is called the larynx, which is composed of five cartilages. Fig. 1, represents an anterior and lateral view, Fig. 2, a posterior view of the larynx.



The five cartilages are

1. The epiglottis.
2. The thyroid cartilage.
3. The cricoid auxiliary, and
4. The two arytenoid cartilages.
5. The two superior cornua of the thyroid cartilage.
6. The two inferior cornua.
7. The suspensory ligament of the os hyoides.
8. The os hyoides.
9. The azygos ligament, connecting the os hyoides to the thyroid cartilage.
10. The two lateral ligaments, connecting the cornua of the os hyoides to the superior cornua of the thyroid cartilage.

The larynx is situated at the upper and fore part of the neck, immediately under the os hyoides, which is placed at the root of the tongue. It is composed of cartilages, muscles, ligaments, membranes, and mucous glands; and is connected above to the tongue and os hyoides, and behind to the pharynx. The cartilages of the larynx are generally considered as being five, though, besides these, some enumerate small projections which are connected with them. The five cartilages are,—the epiglottis, the thyroid, the cricoid, and the two arytenoid.

The epiglottis, obtaining its name from its situation above the glottis, is of an oval form when surrounded by its ligaments and membranes; but when divested of these, it is found to be narrow below, broad above, and rounded at its upper extremity. It is convex towards the tongue, and concave towards the glottis, with its point reflected a little forwards. It is placed behind the upper part of the thyroid cartilage, is situated obliquely over the glottis, and may be seen and examined in the living body, by pressing down the root of the tongue. Its under end is fixed by a broad and short ligament to the middle notch of the thyroid cartilage, and by two lateral ligaments to the whole length of the arytenoid cartilages. It is fixed to the roots of the os hyoides and tongue by another ligament, which is a doubling of the inner membrane running along the middle of its anterior surface, and forming the frænum epiglottidis. It is very elastic, and is much more pliable than the other cartilages. It is found to have a number of fissures, in which lacunæ are placed, perforated by numerous foramina, which are the mouths of so many mucous follicles, in a great measure concealed by the membrane which covers it. It breaks the current of the air coming from the mouth and nose, and prevents it from rushing too forcibly into the cavity of the lungs. Pressed and drawn down by the tongue and by small muscles, it defends the glottis, and shuts it completely in the time of swallowing. After the action of swallowing, it is raised by its own elasticity, and by the root of the tongue, to which it is fixed, returning to its former position.

The thyroid, scutiform, or shield-like cartilage, is placed at the upper and fore part of the larynx, and is the largest of the whole; it is broad anteriorly, and wanting behind. When spread out, it is of an oblong shape; but, in the natural position, consists of two lateral wings or portions, of a quadrangular form, uniting before in a longitudinal angle, which can be readily felt in the fore part of the throat, termed *pomum Adami*. The upper part of the angle is formed into a notch, from which, and from the upper edge of the cartilage in general, a broad ligament ascends, to fix it to the under part of the os hyoides. From the posterior

corners, four processes project, called cornua, two of which, termed superior, are long, and ascend to be joined by round ligaments to the extremities of the cornua of the os hyoides. In the middle of these ligaments, one or two small cartilaginous, or even osseous substances, of an oval form, are frequently found. The other cornua, called inferior, are shorter than the superior, and curved backwards, to be fixed by smooth articulating surfaces to the sides of the cricoid cartilage. The thyroid cartilage serves for the protection of the other cartilages, and, along with the os hyoides, preserves the passage open, for the transmission of food to the stomach. This cartilage in old age is frequently ossified.

The cricoid, annular, or ring-like cartilage, is placed below, and also behind the thyroid, and, like it, may be readily felt in the fore part of the throat. It is narrow before, where it lies under the thyroid cartilage, and thick, broad, and strong posteriorly, where it is placed behind that cartilage. Its posterior surface is divided by a ridge into two lateral cavities, for the reception of the posterior crico-arytenoid muscles. Its under edge is horizontal, and fixed to the whole circumference of the beginning of the trachea. The upper edge slants considerably, and has its anterior narrow part fixed to the under edge of the thyroid cartilage. It has four small articular surfaces, with distinct capsular ligaments, of which two are placed above, for the articulation of the arytenoid cartilages, and two at the under and lateral parts, for the connexion of the inferior cornua of the thyroid cartilage. The cricoid cartilage forms part of the general tube of the trachea, constitutes the base of the larynx, and supports the arytenoid cartilages.

The two arytenoid cartilages are much smaller than the other cartilages, and are placed upon the upper, posterior, and lateral parts of the cricoid cartilage, at a small distance from each other. They are of a triangular form, and a little twisted, and are bent back, so as to have a broad concave surface behind. Their upper extremities, or cornua, are turned towards each other. They are now and then found loose in the form of appendices. Their bases are broad and hollow, where they are articulated by capsular ligaments with the cricoid cartilage, upon which they are moved in different directions, by the action of various muscles. They are connected to each other, and to the adjacent cartilages, by muscles and ligaments. The arytenoid cartilages form a part of the opening called glottis, and give attachment to its ligaments.

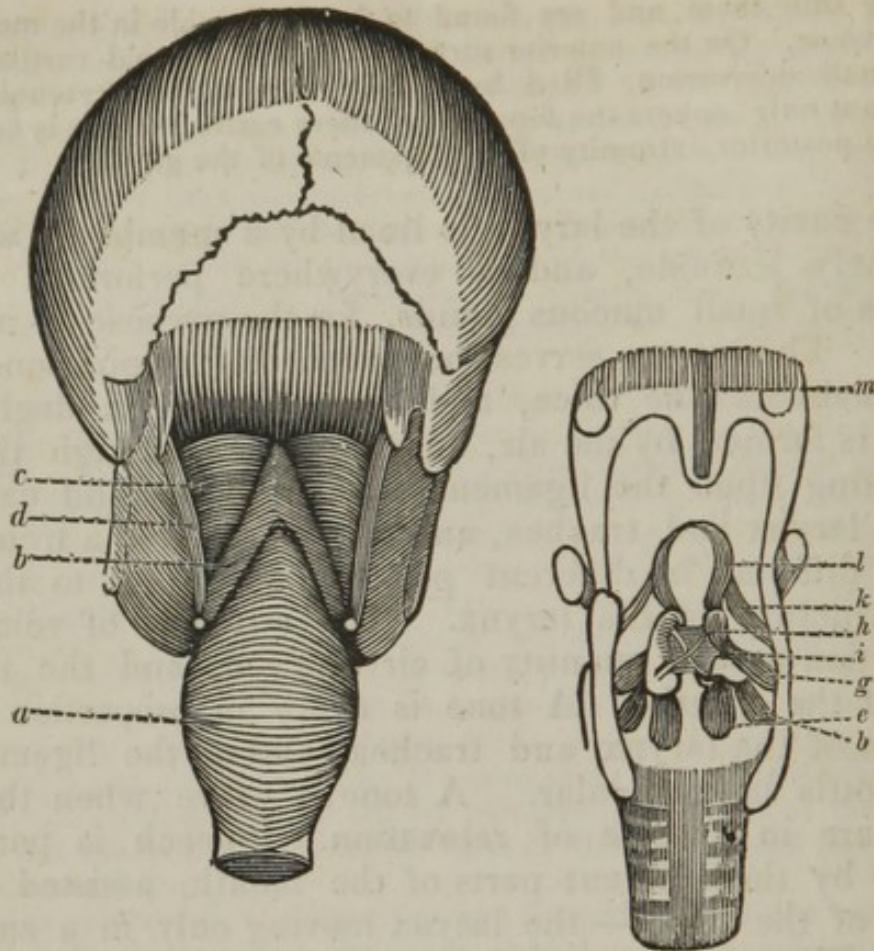
*Ligaments of the glottis.*—From the fore part of the body of each of the arytenoid cartilages, a ligamentous cord passes horizontally forwards, to be fixed by its other extremity to the inside of the anterior angle of the thyroid cartilage. The opening formed between these ligaments is called the glottis, or rima glottidis, and is of a triangular figure, the ligaments being in contact before, but at a considerable distance from each other at their posterior extremities. Under these two ligaments there are two others, larger and more distinct than the former, and which are commonly considered as the proper ligaments of the glottis. They arise from the base of the arytenoid cartilages, and run in the same direction with the former, to be fixed to the thyroid cartilage. In the interstice of the superior and inferior ligaments, on each side there is a fissure, leading to a small membranous cavity or depression, termed

The ventricles of Galen, which are chiefly formed by the inner membrane of the larynx. They differ in size, have mucous follicles

opening into them, and are found to be serviceable in the modulation of the voice. On the anterior surface of each arytenoid cartilage there is a small depression, filled by a body termed the arytenoid gland, which not only covers the fore part of these cartilages, but is continued over the posterior extremity of the ligaments of the glottis.

The cavity of the larynx is lined by a membrane which is extremely irritable, and is everywhere perforated by the mouths of small mucous glands, for the purpose of moistening it. The larynx serves the purpose of respiration, forms and modulates the voice, and is also useful in deglutition. Voice is formed by the air, in its passage through the glottis, acting upon the ligaments of the glottis and cartilages of the larynx and trachea, and thus producing a tremor; — and is different in different persons, according to the form and structure of the larynx. The strength of voice is in proportion to the quantity of air expired, and the narrowness of the glottis. A tone is acute in proportion to the tension of the larynx and trachea, and of the ligaments of the glottis in particular. A tone is grave when the same parts are in a state of relaxation. Speech is performed chiefly by the different parts of the mouth, assisted by the cavity of the nose, — the larynx moving only in a small degree. When the air passes through the larynx without producing a tremor, it occasions a whisper. When a person speaks during inspiration, the voice is thereby very materially altered, and may be made to appear as coming from other places than the mouth of the speaker; as is the case with those who call themselves ventriloquists.

When the dissector has duly considered these parts, he may make an incision through the trachea and œsophagus near the sternum, and they may be pulled forwards so as to dissect the back of the pharynx; or the dissector may defer it until the muscles of the back of the neck have been examined, when the cervical vertebræ may be removed, which will expose the posterior part of the pharynx much better; the cellular substance may then be dissected off, when the following muscles will be brought into view.



- a.* The constrictor pharyngis inferior.  
*b.* The constrictor pharyngis medium.  
*c.* The constrictor pharyngis superior.  
*d.* The stylo-pharyngeus.

Beneath the three constrictors the palato-pharyngeus may be seen, and upon removing the mucous membrane of the pharynx, the muscles situated upon the back of the larynx may be dissected, which the diagram is intended to illustrate.

- e.* The crico-arytenoideus posticus.  
*f.* The crico-arytenoideus lateralis.  
*g.* The thyro-arytenoideus.  
*h.* The arytenoideus obliquus.  
*i.* The arytenoideus transversus.  
*k.* The thyro-epiglottideus.  
*l.* The aryteno-epiglottideus.  
*m.* The azygos uvula.

*a.* The constrictor pharyngis inferior *arises* from the sides of the thyroid and cricoid cartilages. The superior fibres, running obliquely upwards, cover the under part of the following muscle, and terminate in a point; the inferior fibres run more transversely, and cover the

beginning of the œsophagus, to be *inserted* into its fellow, by the medium of a longitudinal tendinous line in the middle of the back part of the pharynx. *Action*,— to compress the lower part of the pharynx, and to draw it and the larynx a little upwards.

*b.* The constrictor pharyngis medius *arises* from the appendix and cornu of the os hyoides, and also from the ligament which connects the cornu to the thyroid cartilage. In its passage, it spreads out, and terminates in a point above and below; the upper part covering the following muscle, to be *inserted* into the cuneiform process of the occipital bone, before the foramen magnum, and to its fellow on the opposite side by a tendinous line, in a similar manner as the former muscle. *Action*,— to compress the middle and upper part of the pharynx.

*c.* The constrictor pharyngis superior *arises* from the internal plate of the pterygoid process; from an aponeurosis which extends between the pterygoid process and the alveolar process of the lower jaw; and from the lateral part of the base of the tongue. The fibres proceed transversely over the pharynx, to be *inserted* into the tendinous line in the centre of the pharynx, and the basilar process of the occipital bone. *Action*,— each constrictor muscle diminishes the capacity of that part of the pharynx upon which it is situated, and presses the sides of the bag against its contents. By the successive action of these muscles, the food is forced downwards into the œsophagus.

*d.* The stylo-pharyngeus *arises* from the root of the styloid process; it passes downwards and forwards, to be *inserted* into the side of the pharynx, expanding over it, and attaching itself to the thyroid cartilage. *Action*,— to dilate and raise the pharynx, and thereby prepare it to receive the food. It at the same time elevates the thyroid cartilage.

The palato-pharyngeus *arises* from the middle of the velum palati, at the root of the uvula, and from the insertion of the constrictor isthmi faucium, and circumflexus palati. The fibres proceed downwards, forming the posterior arch of the palate, and run to the upper and lateral parts of the pharynx, where they spread, and mix with those of the stylo-pharyngeus, to be *inserted* into the ala of the thyroid cartilage; some of its fibres being lost between the membrane and inferior constrictor of the pharynx. *Action*,— to draw the velum and uvula downwards; the larynx and pharynx being at the same time raised; assisted by the constrictor superior and muscles of the tongue, to shut the passage into the nostrils; and in swallowing, to convey the food from the fauces into the pharynx.

*e.* The crico-arytenoideus posticus *arises* broad and fleshy, from the back part of the cricoid cartilage, to be *inserted* by a narrow extremity into the back part of the base of the arytenoid cartilage. *Action*,— to pull back the arytenoid cartilage, by which the ligament of the glottis is made tense, and the glottis itself longer.

*f.* The crico-arytenoideus lateralis *arises* from the side of the cricoid cartilage, where it is covered by the thyroid, to be *inserted* into the side of the base of the arytenoid cartilage. *Action*,— to open the glottis, by separating the arytenoid cartilages, and, with them, the ligaments of the glottis.

*g.* The thyro-arytenoideus *arises* from the under and back part of the middle of the thyroid cartilage, from which it runs backwards and a little upwards, in a double order of fibres, upon the side of the glottis



and ventricle of the larynx, to be *inserted* into the fore part of the arytenoid cartilage. *Action*,— to pull the arytenoid cartilage outwards and forwards, and thereby to widen the glottis, and relax its ligaments.

*h.* The arytenoideus obliquus *arises* from the root of one of the arytenoid cartilages : crosses its fellow obliquely, to be *inserted* near the point of the other arytenoid cartilage. *Action*,— to draw the arytenoid cartilages towards each other, and assist in closing the aperture of the glottis.

*i.* The arytenoideus transversus *arises* from almost the whole length of the posterior part of one of the arytenoid cartilages, and runs transversely, to be *inserted* in a similar manner into the arytenoid cartilage on the opposite side. *Action*,— to close the glottis, by drawing together the two arytenoid cartilages and the ligaments of the glottis.

*k.* The thyro-epiglottideus *arises* by a few scattered fibres from the thyroid cartilage to be *inserted* into the side of the epiglottis. *Action*,— to assist its fellow in drawing the epiglottis towards the glottis, thus shutting the rima glottidis.

*l.* The arytenoid-epiglottideus *arises* from the side and base of the arytenoid cartilage by a number of small fibres ; they run along the outer side of the opening of the glottis, to be *inserted* into the epiglottis. *Action*,— to assist its fellow in drawing the epiglottis immediately down upon the glottis. The action of this, as also of the former muscle, is counteracted by the elasticity of the epiglottis.

The pharynx, so called from its conveying food to the stomach, is a large muscular bag, in form of an irregular funnel, with the tube termed œsophagus descending from it, and forming the inferior end of the funnel. It is bounded above by the cuneiform process of the occipital bone, the pterygoid processes of the sphenoid bone, and back part of the jaws ; with all of which it is intimately connected. The anterior margins of its fleshy parts are connected to the edges of the larynx, and its sides are covered by the great blood vessels of the neck. The fore part of the pharynx is formed by a membrane common to it and to the back part of the larynx. Behind it lies flat upon the cervical vertebræ, and upon the muscles which cover the fore parts of the sides of these vertebræ. The pharynx is surrounded by a loose cellular substance, and consists of different layers of muscles, called constrictores pharyngis, which have been already described. On the inner side, it is lined by the continuation of the membrane of the mouth, which is perforated by the ducts of numerous glands, for the secretion of mucus. The lower end of the pharynx, opposite to the under edge of the cricoid cartilage, describes a complete circle, which forms the beginning of the œsophagus. It receives the aliments from the mouth, and, by the action of its muscles, conveys them to the œsophagus. It may likewise assist in the modification of the voice.

The mouth may now be opened, when the velum pendulum palati will be seen, hanging down from the back part of the palatine bones ; its use is to close the posterior nares in deglutition. Two arches may be observed on either side, the anterior one formed by the constrictor isthmi faucium, the posterior by the palato-pharyngeus ; between

the two arches, the amygdalæ, or tonsils, are situated. The uvula is the small projection in the centre of the soft palate, and it has a few muscular fibres in it, serving to shorten its length.

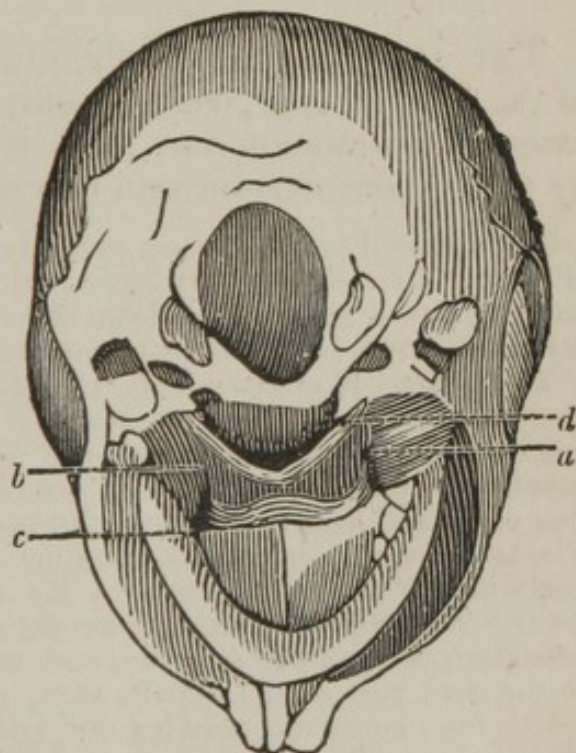
The constrictor isthmi faucium *arises* from the side of the root of the tongue. It runs in the doubling of the membrane, which forms the anterior arch of the palate, to be *inserted* into the middle of the velum palati, at the root of the uvula, where it is connected with its fellow. *Action*,—to draw the palate and root of the tongue towards each other, and thereby to shut the opening into the fauces.

The constrictor pharyngeus has already been described.

The azygos uvulæ *arises* from the posterior extremity of the azygos process of the palatine bones. It runs in the middle of the velum palati, and goes through the whole length of the uvula, adhering in its passage to the circumflexi, to be *inserted* into the point of the uvula. *Action*,—to shorten the uvula.

When the muscles of the tongue, larynx, and pharynx have been removed, the muscles may be dissected that are placed at the base of the cranium, which serve to move the under jaw upon the upper; as also those that draw the soft palate up. The following diagram exhibits these muscles.

- a. The pterygoideus externus.
- b. The pterygoideus internus.
- c. The circumflexus palati.
- d. The levator palati.



The pterygoideus externus *arises* from the outer side of the pterygoid process of the sphenoid bone; from the tuberosity of the superior maxillary bone; and from the root of the temporal process of the sphenoid bone. From these origins it passes outwards, and a little backwards, to be *inserted* into the cervix of the inferior maxillary bone and capsular ligament of the joint. *Action*,—to pull the lower jaw to the opposite side; and when both muscles act, to bring it forwards, so as to make the under fore teeth project beyond those of the upper jaw.

The pterygoideus internus *arises* from the fossa pterygoidea of the sphenoid bone, passes downwards and outwards, to be *inserted* into the inner side of the angle of the inferior maxillary bone. *Action*,—to raise the jaw, and draw it obliquely towards the opposite side.

The *circumflexus palati arises* from the spinous process of the sphenoid bone, from the osseous and cartilaginous parts of the Eustachian tube, and from the root of the internal pterygoid process. It runs along the pterygoideus internus, passes over the hook of the internal plate of the pterygoid process, and playing on it by a round tendon, as on a pulley, it spreads out into a broad membrane, to be *inserted* into the velum palati, and semilunar edge of the os palati, extending as far as the suture which joins the two bones. Generally, some of its posterior fibres join the constrictor pharyngis superior and palato-pharyngeus. *Action*,—to depress and stretch the velum.

The levator palati *arises* from the point of the pars petrosa of the temporal bone, and also from the membranous portion of the Eustachian tube. From these parts it descends to be *inserted*, by a broad expansion, into the velum palati, extending as far as the root of the uvula, and uniting with its fellow. *Action*,—to raise the velum in the time of swallowing, and prevent the food or drink from passing into the nose, by pressing the velum against the back part of the nostrils.

From the soft palate and arches, to the larynx and pharynx, the space is termed the fauces, which has the following openings:—the mouth, the two posterior nares, the two Eustachian tubes, the larynx, and pharynx.

The dissector may now proceed to

## THE DISSECTION OF THE NOSE.

THE nose constitutes the organ of smell, and contributes to the general purpose of respiration; it is divided into the external prominent part, and the internal cavity, separated by the septum narium into two smaller cavities.

The external part, or nose, properly so called, is composed superiorly of bones, inferiorly of cartilages, and has a partial covering from the muscles, and a general one from the common integuments. The inner part of the nose is divided into hard and soft parts.

The upper and anterior part being formed by the nasal, superior maxillary, frontal, and ethmoidal bones. The lateral parts, by the superior maxillary, palatine, and turbinated bones. The inferior part, by the superior maxillary and palatine bones. The septum, by the nasal process of the ethmoid bone above, the vomer below, and cartilage between. The two cavities, or nostrils, terminate anteriorly in the face, and posteriorly in the fauces, enlarged by the sinuses which communicate with them. The internal nares or cavities of the nose extend upwards to the cribriform plate of the ethmoid, and to the body of the sphenoid bone. In the fore part of the nostrils there are stiff hairs, which prevent the mucus from constantly flowing out, and insects, or other extraneous matter, from entering.

The inside of the nose is lined with a thick spongy substance, termed *membrana mucosa*, or *membrana pituitaria* of Schneider, or *membrana schneideriana*, which is also continued to the different sinuses, to the lachrymal sacs and palatine ducts, to the pharynx, palate, and Eustachian tubes. This membrane is very vascular and nervous, and is the primary organ of smelling. It is constantly lubricated and preserved

in a proper degree of moisture by the mucus of the nose, which is discharged from numerous small follicles, everywhere dispersed over the surface of that membrane.

The frontal sinuses send passages downwards into the anterior ethmoid cells, which terminate in the upper part of the nose, below the superior turbinated bone. Besides the passages common to the frontal sinuses and anterior ethmoid cells, there are others proper to the posterior ethmoid cells, which terminate in the upper and back part of the nose, near the openings of the sphenoid sinuses. The sphenoid sinuses open, behind the cells of the ethmoid bone, into the upper and back part of the nose. The maxillary sinuses, or antra maxillaria, open at their upper and inner sides, each by one, and sometimes by two passages, into the middle of the space between the superior and inferior spongy bones, nearly opposite to the under edge of the orbit. The different sinuses are lined with a continuation of the membrana schneideriana; but in these it is thinner, and less vascular and nervous, than that part of it which lines the general cavity of the nose. They are constantly moistened, but not filled with a fluid. The sinuses increase and modulate the voice: their hollow structure renders the bones lighter; but they do not appear to constitute part of the organ of smell. Their passages being directed backwards, prevent extraneous matter from getting into them.

The lachrymal duct is formed by the superior maxillary, lachrymal, and inferior spongy bones. In its descent, it runs a little obliquely backwards to the lower and lateral part of the cavity of the nose, where it terminates at its fore part, under the os spongiosum inferius, a little behind the anterior extremity of that bone, and in a direct line upwards from the second dens molaris. The upper part of the groove forms only a semi-canal, the under end a complete one.\*

---

## DISSECTION OF THE ORBIT.

THE upper part of the orbit should be removed with a saw, in such a manner as to bring into view the contents. When the lining membrane has been removed, the muscles and vessels will be brought into view; first, the supra orbital nerve will be seen, a branch of the ophthalmic twig of the trigemini; then the levator palpebræ superioris, together with the other muscles and nerves. The muscles consist of the four recti and the two oblique; the nerves are the second, third, fourth, first division of the fifth, and the sixth; the vessels are the ophthalmic artery and vein. There is also

\* It will be of practical utility to the student to pass a probe from within the cavity of the nostrils, through the lachrymal duct; as also into the maxillary sinus; and backwards into the fauces; operations which are called for in surgical practice.

in the orbit a considerable quantity of fat, and the lenticular ganglion.

The levator palpebræ superioris *arises* from the upper margin of the foramen opticum of the sphenoid bone. It runs forwards within the orbit over the levator oculi, where it becomes gradually broader, its anterior extremity passing under the orbicularis palpebrarum, to be *inserted* by a broad thin tendon, into nearly the whole length of the cartilage of the upper eye-lid. *Action*,—to open the eye, by raising the upper eye-lid.

The levator oculi, *vel* rectus attollens, *arises* from the upper part of the foramen opticum, below the levator palpebræ superioris, to be *inserted* into the upper and fore part of the tunica sclerotica. *Action*,—to raise the fore part of the ball of the eye.

The depressor oculi, *vel* rectus deprimens, *arises* from the inferior part of the foramen opticum, to be *inserted* opposite to the former, in the tunica sclerotica. *Action*,—to pull the fore part of the eye downwards.

The adductor oculi, *vel* rectus adducens, *arises* from the foramen opticum, between the obliquus superior and depressor, to be *inserted* opposite to the inner angle of the eye. *Action*,—to turn the fore part of the eye towards the nose.

The abductor oculi, *vel* rectus abducens, *arises* from the bony partition between the foramen opticum and lacerum, to be *inserted* into the ball of the eye, opposite to the outer angle. *Action*,—to turn the fore part of the eye towards the temple. When two of the opposite recti, or all of them, act together, they draw the eye into the orbit. When two of the adjacent recti act, they turn the fore part of the eye obliquely, in a direction towards their origins.

The obliquus superior, *vel* trochlearis, *arises* like the straight muscles, from the edge of the foramen opticum; from thence it runs directly forwards, sends off a long round tendon, which passes through a cartilaginous pulley fixed behind the internal angular process of the os frontis, and is here inclosed in a bursa mucosa. From this it goes a little downwards, and returns backwards and outwards, passing under the levator oculi, to be *inserted*, by a broad thin tendon, into the tunica sclerotica, about half way between the insertion of the levator oculi, and entrance of the optic nerve. *Action*,—to roll the ball of the eye, by turning the pupil downwards and outwards.

The obliquus inferior *arises* by a narrow beginning, from the anterior edge of the orbital process of the superior maxillary bone, near the lachrymal groove, from which it passes obliquely outwards, backwards, and upwards, round the ball of the eye. *Inserted*, by a broad thin tendon, into the sclerotic coat, between the entrance of the optic nerve, and insertion of the abductor oculi, and opposite the insertion of the obliquus superior. *Action*,—to roll the ball of the eye, by turning the pupil upwards and inwards.

The optic nerve, entering the orbit through the foramen opticum, proceeds forwards, and rather obliquely outwards, to the back part of the eye, which it penetrates on the inner or nasal side of its axis. In this course the nerve is surrounded by a dense fibrous sheath.

The motor oculi, or third nerve, passing through the foramen lacerum into the orbit, divides into several branches, which are distributed to the levator palpebræ superioris, rectus superior, rectus internus, rectus inferior, and obliquus inferior.

From that branch of the third pair distributed to the obliquus inferior muscle, a filament proceeds to the lenticular ganglion.

The first branch of the fifth pair enters the orbit through the foramen lacerum of the sphenoid bone, and is there divided into three branches: the supra orbital, the nasal, and the lachrymal. The supra orbital, the largest of the whole, being a continuation of the ophthalmic nerve; it passes immediately under the membrane which lines the upper part of the orbit, and splits into two branches of unequal size. The smaller branch runs under the superciliary ridge to the upper eye-lid and forehead. The larger passes through the foramen supra-orbitarium, or over the superciliary ridge when the foramen is wanting, — sends branches to the upper eye-lid, and divides into several others, which run back under the occipito frontalis, to supply the fore and upper part of the head in general. The nasal branch runs obliquely over the optic nerve, where it detaches a filament or two to the eye, then under the levator palpebræ and levator oculi, and getting between the abductor oculi and trochlearis, passes to the inside of the orbit. It sends two branches, which enter the foramen orbitarium internum anterius et posterius. The anterior re-enters the cavity of the cranium, and gets upon the cribriform plate of the ethmoid bone; from thence it passes down through one of the anterior holes of this plate, and sends twigs to the membrane at the anterior part of the nostril, while the nerve, descending at the fore part of the septum narium, is dispersed upon the point and wing of the nose. The posterior goes direct to the nose. These branches are sometimes sent off by the lenticular ganglion. The nasal branch then passes forwards to the inner corner of the eye, and is distributed upon the lachrymal sac and parts adjacent. The lachrymal branch runs along the abductor oculi, sends twigs to the membranes and fat near it, likewise one or two through the substance of the cheek-bone, and one in particular to the substance of the lachrymal gland, while another passes over the gland, and vanishes in the neighboring parts. A branch to the lenticular ganglion is sometimes sent off from the nasal, at other times from the ophthalmic trunk.

The lenticular ganglion is situated in the back part of the orbit, close to the outer side of the optic nerve. Very careful dissection is required to discover it, on account of its small size. To the back part of the ganglion two nerves are attached, one from the third pair, and the other from the nasal branch of the ophthalmic nerve, which is the first division of the fifth pair. From the front part of the ganglion, eight or ten slender filaments arise, which are the ciliary nerves. These proceed forwards in the orbit, some above, others below the optic nerve. Then penetrating the sclerotica, they are continued forwards between the sclerotic and choroid coats to the iris, in which they are wholly distributed.

The nerve of the sixth pair, the abductor, passing through the foramen lacerum into the orbit, proceeds to the outer side of the cavity, and is distributed wholly to the rectus externus muscle.

The internal carotid transmits, near the posterior clinoid process, the arteria ophthalmia, or ocular artery, which enters the foramen opticum, and passing under the optic nerve to the outer part of the orbit, it traverses its cavity, running in a spiral direction towards the nose; between the optic nerve and depressor oculi it sends off twigs to the nerve and the origin of the muscles, supplying also the dura mater lining the orbit, and then gives off the following branches: — 1st, The arteria centralis retinae, perforating the optic nerve a little behind the sclerotic coat, runs into the

centre of the nerve, and divides into many branches upon the inside of the retina. When the optic nerve is cut across, the orifice of the divided artery is seen, and known by the name of *porus opticus*. A small filament also perforates the vitreous humor to the back part of the capsule of the crystalline lens. This artery, in the fœtus, forms the *membrana pupillaris*. 2d, The *arteriæ ciliares*, three, or sometimes more, in number, dividing into many branches, running in a serpentine direction, and separating into the *ciliares longæ*, and *ciliares breves*. The *ciliares longæ* consist generally of two trunks, which perforate the sclerotic coat a little farther forwards than the *breves*, pass along the choroid coat to its anterior part, and then each separates into two branches, and these into others, which inosculate round the outer edge of the iris. The *ciliares breves*, formed not only of branches from the original ciliary trunks, but also of twigs from the muscular branches, are numerous. They perforate the sclerotic coat, near the insertion of the optic nerve, give twigs to that coat, and dividing into still smaller branches, creep forwards upon the choroid; but forming many communications with each other as they advance, and retiring gradually from the convex to the concave surface of this coat, to supply the iris and ciliary processes. 3d, A lachrymal branch to the gland. 4th, An angular branch, to supply the inner canthus of the eye, which anastomoses with the angular branch of the external maxillary. 5th, The *muscularis superior*, et *muscularis inferior*, dispersed upon the muscles, membranes, and fat of the eye; giving twigs also to the sclerotic coat. 6th, The *ethmoidalis anterior* et *posterior*, two extremely small twigs, especially the latter, which pass through the *foramina orbitaria interna*, *anterior* et *posterior*, to the bones and membranes of the nose, particularly to the frontal, ethmoid, and sphenoid sinuses, where they communicate with the nasal branches of the internal maxillary artery. 7th, The *supra-orbitalis*, *vel frontalis*, which, after giving branches to the muscles and periosteum at the upper and fore part of the orbit, emerges from the socket, passes through the *foramen supra-orbitarium*, and is divided into two parts; — one dispersed upon the periosteum of the forehead, the other running to the skin and muscles on the forehead and upper eye-lid, communicating with the anterior branch of the temporal.

The blood sent to the contents of the orbit is returned partly to the facial vein at the inner corner of the eye, but chiefly to the proper ocular vein, which passes through the *foramen lacerum in orbitarium*, to terminate in the cavernous sinus. The ocular vein is formed by the *vena centralis retinæ*, which accompanies the artery in the optic nerve; and the long and short ciliary veins which pass through the sclerotic coat. The *venæ vorticossæ* obtain their name from the whirls they make; they form four trunks, perforating the sclerotic coat, to terminate in the ocular vein, which receives also the lachrymal, ethmoidal, and muscular veins.

## DISSECTION OF THE EYE.

THE eyes constitute the organ of vision ; they are situated in the cavities of the orbits, and surrounded by several parts to protect them from injury, and assist in the performance of their various motions.

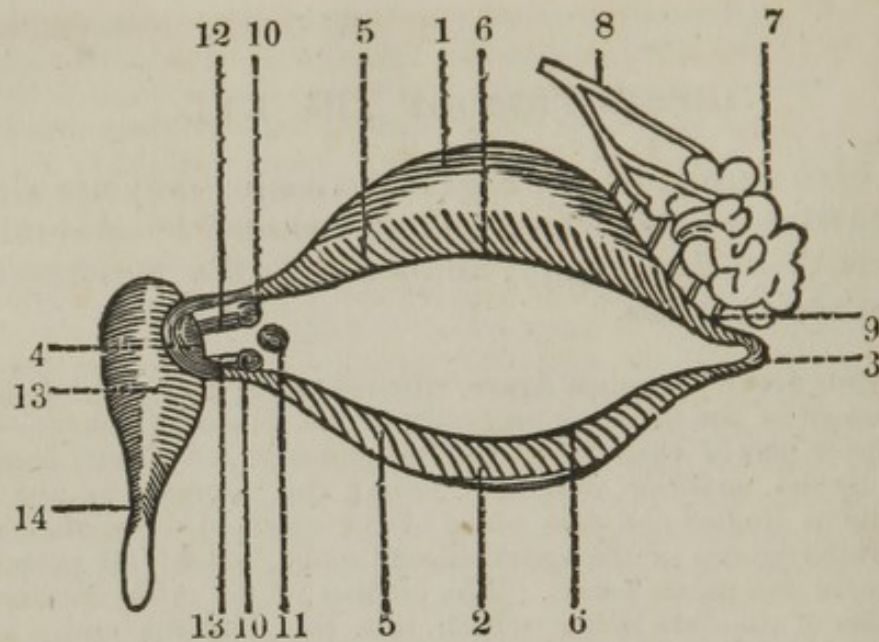
The orbits are of a conical figure, situated in the fore part of the cranium, formed of the different processes of the following bones : —

The upper part of each, by the orbital plates of the frontal bone ; the inferior, by the superior maxillary bone ; the internal, by the orbital part of the os unguis and pars plana of the ethmoid bone ; the external, by the orbital plates of the sphenoid and malar bones ; the posterior, by the sphenoid and palate bones. The cavities of the orbits are lined with productions of the dura mater, which pass the foramina optica and lacerata ; and, at the anterior edges of the orbits, join the periosteum of the face, where they supply the place of ligaments to the palpebræ.

The eye consists of the globe, or ball, and its appendages. The latter consist of the muscles, nerves, arteries, and lachrymal apparatus. The eye is protected by the superior and inferior palpebræ ; the superior consists of the skin, fibres of the orbicularis palpebrarum, tarsal cartilage, fibres of the levator palpebræ superioris, and the tunica conjunctiva ; the inferior, of the same parts, with the exception of the levator palpebræ superioris.

The following diagram is intended to point out the lachrymal apparatus.





1. The superior tarsus.
2. The inferior tarsus.
3. The external canthus.
4. The internal canthus.
5. The cilia, or eye-lashes.
6. The situation of the Meibomian glands.
7. The lachrymal gland.
8. The lachrymal artery ramifying upon it.
9. The lachrymal ducts.
10. The two puncta lachrymalia.
11. The caruncula lachrymalis.
12. The lachrymal ducts.
13. The lachrymal sac.
14. The ductus ad nasum.

The tarsi, a thin cartilaginous arch, situated in the edge of each eye-lid, the upper one being considerably broader than the lower, and each broader at its middle than towards its extremities. They terminate at a little distance from the inner angle of the eye; their edges are so placed, that when the eye-lids are shut, a groove is left near the eye, by which the tears are conveyed towards the nose. The tarsi serve to keep the eye-lids extended, allow them to be accurately applied to each other, and prevent them from being collected into folds.

The canthi are the union of the two tarsi; by some they are called the tarsal ligaments. The internal one is much larger than the external, and contains the two puncta lachrymalia and caruncula lachrymalis.

The cilia, or eye-lashes, are small stiff hairs placed on each side of the eye-lids. Those of the upper lid are bent upwards, and are considerably longer than those of the under lid, which are bent in the opposite direction; — they are wanting near the inner angle. The cilia prevent dust, insects, &c. from getting into the eye, assist in moderating the quantity of light sent into it, and add to the beauty of the face.

The Meibomian glands are placed between the tarsi and lining of the eye-lids, forming a series of white lines or follicles, and running in a serpentine direction; when viewed through a magnifier, they appear

like rows of pearls. From their substance, an oily or sebaceous matter may be squeezed out through the foramina or puncta ciliaria, placed upon the edges of the eye-lids. The matter of these glands facilitates the motions of the eye-lids, and prevents their accretion during sleep.

The lachrymal gland is situated upon the upper and outer part of the eye, in a hollow behind the outer part of the superciliary ridge of the frontal bone. It is of the conglomerate kind, of a yellowish color, oblong form, and a little flattened, with one end pointing to the nose, the other to the outer angle of the eye. The excretory ducts of this gland, (seven or eight in number,) on account of their smallness, are not often seen; they terminate on the inner side of the upper eye-lid, near the outer angle of the eye, and upper edge of the tarsus. The use of the lachrymal gland is to secrete the tears, which are spread over the surface of the eye by their own weight, and by the motion of the eye-lids, for the purpose of preserving the delicacy of the eye, and particularly the transparency of the cornea.

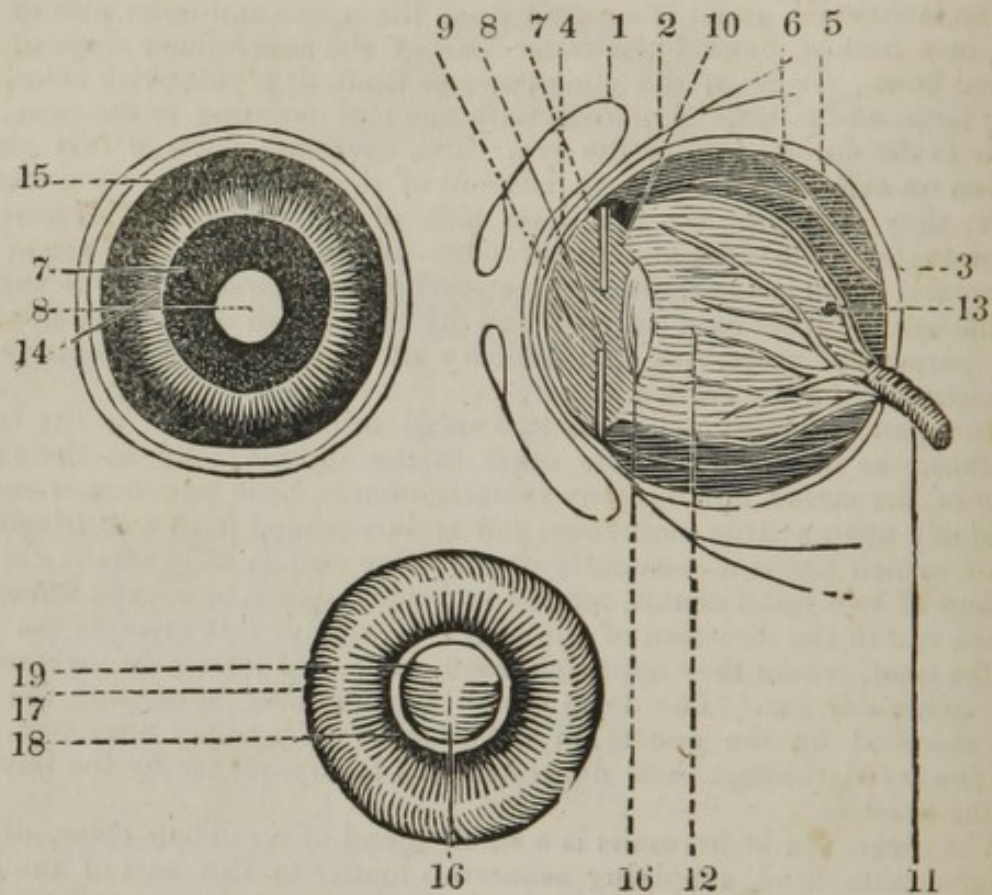
The puncta lachrymalia are two small orifices situated at the inner canthus, one in the upper, the other in the under eye-lid, at the extremity of the tarsus, and opposite to each other. Each punctum is seated obliquely upon a little eminence, and is surrounded with a cartilaginous circle, which keeps it constantly open. The puncta lachrymalia are the orifices of two small canals, termed lachrymal ducts, or cornua limacum, which run in the direction of the edges of the eye-lids towards the side of the nose, where they approach each other, and terminate together in the lachrymal sac. The tears which remain after moistening the eye are absorbed by the puncta, in the manner of capillary attraction, and are conveyed through their ducts into the lachrymal sac by the impulse of the eye-lids.\*

The caruncula lachrymalis is a small gland of a reddish color, of the conglomerate kind, supplying sebaceous matter to this part of the eye-lids; and serving in particular to separate the puncta lachrymalia, and to direct the tears to them while the eye-lids are shut. Minute hairs are found upon the surface of this body, serving to entangle small objects which get into the eye.

The lachrymal sac is a receptacle for the tears, and is placed in a fissure formed by the os unguis and superior maxillary bone; the ductus ad nasum is a continuation of the sac, and conveys the superfluous tears into the nose.

\* From the diagram on the opposite page, the student may learn how a probe should be inserted into the ductus ad nasum, viz. by introducing it first in an horizontal, then in a perpendicular direction.

The ball, or globe of the eye, is composed of common and true coats, which the accompanying diagram is intended to point out.



1. The tunica conjunctiva.
2. The tunica albuginea.
3. The tunica sclerotica.
4. The cornea.
5. The tunica choroides.
6. The ciliary nerves passing between the choroid and sclerotic coat.
7. The iris, which is connected to the choroid membrane by the ciliary ligament or circle.
8. The pupil.
9. The anterior chamber, } containing the aqueous humor.
10. The posterior chamber, }
11. The optic nerve, seen perforating the sclerotic and choroid membranes, to be expanded into the retina, and the arteria centralis retinae piercing the optic nerve.
12. The retina, with its artery ramifying upon its surface.
13. The foramen of Soemmering.
14. The ciliary ligament, seen connecting the iris to the choroid membrane.
15. The ciliary processes.
16. The crystalline lens surrounded by its capsule.
17. The vitreous humor surrounded by its capsule.
18. The zonula ciliaris.
19. The canalis Petitianus.

1. The *tunica conjunctiva*, or *tunica adnata*, named from its connecting the eye to the orbit, is a reflection of the skin continued from tarsus to tarsus, and canthus to canthus, over the whole fore part of the ball of the eye. It forms a small fold at the inferior tarsus, between it and the *caruncula lachrymalis*, termed *valvula semilunaris*. It is in form of a crescent, the horns of which are turned towards the *puncta lachrymalia*, to assist the *caruncula* in conducting the tears to the *puncta*. It is larger in the ape, and other quadrupeds, than in the human species, and still larger in birds; in which, as well as in quadrupeds, it is called *membrana nictitans*.

The *tunica conjunctiva* adheres slightly by means of cellular substance to the white of the eye, but so firmly to the cornea, as to be separated from it with difficulty. It is so remarkably thin, that the color of the subjacent parts appears readily through it; it supports the ball of the eye, prevents extraneous bodies from getting to the back part of it, and forms a smooth covering to lessen the friction between the eye and eyelids, and it is said to be a mucous membrane.

Between this coat and the white part of the eye, a quantity of loose cellular substance is found, which is very vascular, and is the common seat of ophthalmia. Under the *tunica conjunctiva* the *recti* muscles are said to send off a tendinous expansion, which passes over the cornea, termed the *tunica albuginea*; these constitute the common coats of the eye.

The *tunica sclerotica*, named from its hardness, is the largest and strongest coat of the eye, covering the whole ball, excepting the parts occupied by the entrance of the optic nerve behind, and by the cornea before. It is so firmly fixed to the edge of the cornea, that it has been considered as a continuation of the same substance; but it differs from the cornea, being of a pure white color, formed of fibres running in every direction, and closely interwoven with each other, and not divisible into layers. It is thickest posteriorly, and receives a little tinge on the inner surface, from the choroid coat, with which it is in contact.

The cornea, so called from its resemblance to horn, is termed by many authors *cornea lucida*, to distinguish it from the *sclerotica*, which these authors call *cornea opaca*. It forms the anterior pellucid covering of the eye, is more convex than the rest of the ball, and is joined to the *tunica sclerotica*, like the segment of a small sphere to that of a large one. The convexity, however, varies in different persons, so as to form a short or long-sighted eye, according as the cornea is more or less prominent. In a recent subject, it is hard, dense, and transparent; but after maceration in water, it becomes soft and opaque, and may be readily separated, especially in young animals, into different lamellæ, the anterior of which is the continuation of the *tunica adnata*. By a slight degree of putrefaction, it may also be separated from the *tunica sclerotica*, and is found attached to it as a watch-glass is to a watch. It collects the rays of light, and transmits them to the eye, protects the tender parts within it, and contains the aqueous humor.

The *tunica choroides* lies under the *sclerotica*, and is connected to it by the trunks of vessels and nerves which pass from the one coat to the other, and also by a tender cellular substance, of a brown color, which tinges the inner surface of the *sclerotica*. It begins at the entrance of the optic nerve into the eye, runs between the *sclerotica* and retina, nearly to the crystalline lens, where it is more firmly connected to the *sclerotic* coat than it is elsewhere, by means of the ciliary circle.

Many veins are observed on the choroid coat, running in various directions, making frequent anastomoses, termed *venæ vorticosæ*.

The ciliary nerves are also to be observed passing between the choroid and sclerotic coats; they are sent off from the lenticular ganglion, and run to be distributed upon the iris, ciliary ligament, and processes.

In the human eye, the choroid coat is of a dusky brown color, both externally and internally; but the color varies considerably in the eyes of different animals.

Upon the inner side of the choroid coat there is a mucus, the color of which, in different animals, is found to correspond somewhat with the general color of the hair and skin, though commonly, in the human body, it is of a blackish brown, termed *pigmentum nigrum*; the darkness of the shade, however, still corresponding with that of the hair. It is supposed to be produced from the vessels of this coat, and is blackest and thickest at the fore part of the eye, where it adheres so firmly as to be removed with difficulty; but behind it is thinner, more fluid, and more easily removed; becoming gradually less evident towards the optic nerve, round which it almost disappears. In advanced age, the *pigmentum nigrum* becomes more diluted, and of a lighter color, so that the vessels of the choroid coat may be seen shining through the vitreous humor.

The choroid coat, with its dark paint, serves to intercept the rays of light which pass through the retina, thereby allowing a distinct image to be formed upon the bottom of the eye, and preventing the rays from being reflected, so as to form a second image. In those animals in which this coat, or its paint, is of a brighter color, it acts as a mirror to reflect light, and make the impression stronger.

The iris, so named from being in some persons of different colors, is the only coat of the eye which possesses motion. It was considered as a continuation of the choroid coat, until described by Zinn, who shows that it is only connected to this coat by the medium of the ciliary ligament. It is placed at a little distance from the cornea, begins a small way behind the junction of that coat with the sclerotica, and, running across, it forms a septum, a little convex anteriorly, and perforated in the middle by a hole, called the pupil, or sight of the eye. In the *fœtus*, the pupil is occupied by a vascular membrane, termed *membrana pupillaris*, which generally disappears between the seventh and ninth month of gestation. Upon the back part of the iris there is a dark-colored pigment, which has been considered as a posterior layer of the iris, called *uvea*, from its resemblance in color to the grape. When the paint is washed off, the iris exhibits two sets of fibres, concerning which, various opinions have been entertained; one set in the form of radii, the different colors of which give the diversity of color to the eye; the other circular, surrounding the inner edge of the iris, and considered as the sphincter muscle of the pupil. The iris floats in the aqueous humor, and is of such a nature, that upon exposure to a strong light, or when the eye looks upon a near object, the diameter of the pupil is diminished, and *vice versa*. The different motions of the iris are supposed to be excited by the sensibility of the retina, and by the quantity of light which falls upon that nerve. The iris serves to regulate the quantity of light sent to the bottom of the eye.

The space between the cornea and crystalline lens is divided into two cavities, called chambers; the anterior, situated between the cornea and iris, is the larger of the two; and the posterior placed between the iris

and crystalline lens, is so much smaller than the former, that its existence has been denied, though it is a distinct cavity, demonstrable in the adult where the pupil is open, and in the fœtus before the pupil is formed. The chambers contain the aqueous humor, clear as the purest water, but somewhat heavier, possessing a small degree of viscosity, and containing a little salt. In the fœtus, and for the first month after birth, it is reddish and turbid. When evacuated, it is quickly renewed; for within fortyeight hours after it has been discharged by puncture, the cornea is observed to be again perfectly distended. It is supposed to be secreted from the neighboring arteries, particularly from those on the fore part of the iris and ciliary processes. It serves to keep the cornea distended, and, by its roundish form and pellucidity, it collects and transmits the rays of light to the inner parts of the eye. It likewise guards the iris and lens, and admits of the motions of the former.

*The optic nerve and retina.* — The optic nerve, in its passage through the orbit, is covered by a continuation of the membranes which surround the brain. At the foramen opticum, the dura mater is divided into two laminæ, one of which assists in forming the periosteum of the orbit; the other, which is again divided into two laminæ, furnishes a sheath to the nerve, and accompanies it to the tunica sclerotica, to which it is firmly connected by cellular substance. At the back part of the ball of the eye, and a little removed from the axis, towards the nose, the fasciculi of the optic nerve pass through a cribriform part of the sclerotic and choroid coats. The nerve is contracted at its entrance through the sclerotic coat, but immediately after its ingress it expands to form the retina, — so called from its supposed reticular appearance.

In the centre of the optic nerve, the artery of the retina is seen dividing into branches, which are dispersed upon its inner surface. The retina advances between the choroid coat and capsule of the vitreous humor, to the fore part of the eye, and terminates or disappears upon the anterior part of the edge, or greatest diameter of the capsule of the crystalline lens. The retina is contiguous to the choroid coat and capsule of the vitreous humor, but does not, by blood-vessels or otherwise, adhere to either, till it reaches the ciliary ligament, under which the retina is so covered externally with the pigmentum nigrum, and adheres internally so closely to the capsule of the vitreous humor, as to be prevented from being seen till the black paint be washed off, or till all the coats be removed posteriorly, and the eye viewed through the medium of the vitreous humor. In the back part of the retina, directly in the axis of the eye, there is a central hole, of a dark color, surrounded with a yellow border, which becomes paler towards the circumference, the foramen of Soemmering. The retina is composed of a tender and pulpy-like substance, is semi-transparent, and of a light grey color, resembling that of ground glass, and may be divided into two layers. The retina is the seat of vision, and therefore the primary part of the eye, to which all the other parts within the orbit are subservient.

The ciliary circle, or ciliary ligament, as it is called, is composed of a quantity of condensed shining cellular substance, which forms a white ring connecting the fore part of the choroides, and the root or outer margin of the iris, to the sclerotica. The choroid coat is much thinner and more tender than the sclerotic, and is one of the most vascular parts of the body, seeming, at first sight, to be entirely composed of vessels. The greater number of those on the outside run in whirls; while those on the inside, taking a direction nearly parallel to each other, are termed the *membrana ruyschiana*.

At the posterior part of the ciliary ligament there are numerous pale radiated ciliary striæ, but so covered with the pigmentum nigrum, as not to be distinctly seen till the paint is removed. These striæ become gradually broader and more elevated, and form white plicæ or folds, termed processus ciliares, the intervals of which are also covered with the pigmentum nigrum.

The processus ciliares are commonly formed each of two or more striæ. They are not all of an equal size, and many of them are forked at their extremities.

The crystalline lens has its name from its resemblance to crystal, and from its lenticular form; though a solid body, which may be moulded into various shapes, it has always been classed among the humors of the eye. It is situated behind the aqueous humor, opposite to the pupil, and the whole of its posterior part is received into a depression on the fore part of the vitreous humor. Like a common lens, or magnifying glass, it has two convex surfaces, the anterior of which is less convex than the posterior, the two being formed of segments of spheres of unequal size. It has been observed, that the figure of the lens varies at different periods, being in the fœtus almost of a spherical form, but becoming gradually flatter on the anterior and posterior surfaces, till about the age of thirty, after which its form does not appear to vary. As the figure, so also the color and consistency are found to change at different times of life. In the fœtus, not only the capsule, but the lens also, is of a reddish color; but, immediately after birth, they become perfectly transparent. In a person considerably advanced in years, the lens is observed to acquire a yellow tinge, which appears first in the centre, and afterwards extends gradually to the circumference; and in extreme old age, this yellow tinge becomes so deep as to resemble amber. The lens becomes opaque soon after death, and acquires an additional opacity when put into spirits of wine. It is composed of concentric lamellæ, laid over each other like the coats of an onion. These lamellæ are connected by a fine cellular substance, and are more closely compacted the nearer they are to the centre. The substance of the lens somewhat resembles half-melted gum, is very soft and tender on the outside, but becomes gradually firmer and tougher towards the centre, where it forms a nucleus.

The lens is surrounded by a very pellucid proper capsule, called tunica aranea, or crystallina, which is much thicker and more elastic than the capsule of the vitreous humor, but adheres so slightly, and is so easily lacerated, that after a small puncture has been made in it, the lens starts out, upon applying gentle pressure to the capsule. The posterior part of the capsule is much thinner, softer, and weaker than the anterior; but is quite a distinct membrane from the tunica vitrea; yet so firmly connected to it by cellular substance, that it is difficult to separate them without lacerating both the vitreous coat and its humor. Some describe an aqueous humor as seated between the lens and its capsule, the aqua Morgani.

The vitreous humor is situated in the back part of the cavity of the eye, from the insertion of the optic nerve to the surface of the crystalline lens. It is round at the back part and sides, where it is covered by the retina, but is concave before, where it forms a bed for the crystalline lens. It is by much the largest of the three humors, occupying upwards of nine tenths of the whole eye, and has a gelatinous appearance, — or is somewhat like the glaire of an egg. In an adult, it is always very

transparent, and in an old person it does not, like the lens, degenerate into a yellow, or any other color. In the fœtus, like the aqueous humor, it is of a reddish color. The liquor with which the vitreous humor is filled, is similar to the aqueous, — very fluid, transpires readily through the capsule, though that coat be entire, and, like the aqueous humor, is somewhat thicker, heavier, and more viscid than water. When this humor is evacuated by puncture, in the living body, it is seldom, though sometimes renewed. Upon the surface of this humor there is a coat, termed *tunica vitrea*, or *hyaloidea*, from its resemblance to glass, as transparent as the humor itself.

The *tunica vitrea* is remarkably smooth on its outer surface; but within, it sends processes into the body of the humor. The structure of the inner part of the coat consists of a set of delicate cells, which contain the liquor within them, as may be seen by the assistance of acids, or by boiling water. The cells of the tunic communicate freely with each other, as appears from the liquor oozing out by the smallest puncture made in the general capsule.

Under the ciliary ligament, the capsule of the vitreous humor sends off an external lamina, which accompanies the retina, and is inserted with it into the fore part of the capsule of the lens, a little before its anterior edge. It is termed *zonula ciliaris*, from its striated appearance and circular form, and assists in fixing the lens to the vitreous humor. After sending off the ciliary zone, the coat of the vitreous humor goes behind the capsule of the lens, with which it is intimately connected.

Between the ciliary zone and the part where the capsule of the vitreous humor adheres to that of the lens, — a passage is formed, named *canalis Petitianus*, after Petit, who discovered it. The membranes forming this passage are pervaded by transverse fibres in such a manner, that when air is introduced, it goes freely round the edge of the lens; but the passage has a cellular appearance, being contracted and dilated alternately. The canal of Petit is nearly of the same breadth with the ciliary ligament; it is always empty, and has no communication with the capsules of the vitreous or crystalline humors. The vitreous humor serves to give shape to the eye, to keep the coats properly expanded, to preserve the due distance of the lens, and direct the rays of light to the retina.

The eye receives and collects the rays of light, in such a manner as to form upon the retina the image or picture of the object which the eye looks at; and the point where these different rays meet is called the focus. The object is painted upon the retina in an inverted manner, the rays from above falling upon its under, and those from below upon its upper part; it is supposed to be by habit, or rather by instinct, that we judge of the real situation of the object. That the rays of light may terminate distinctly on the retina, it is necessary that both the cornea and crystalline lens should have a certain degree of convexity. If either the one or the other be too prominent, the focus will be formed before it reaches the retina, as is the case in short-



sighted people, who require concave glasses to enable them to see objects distinctly, at the proper and ordinary distance. If, on the contrary, the cornea or lens be too flat, or the refractive power of the humors be in any way diminished, the focus will then be imperfectly formed, till the object is viewed at a greater distance than ordinary, as is the case with persons advanced in life, to whom the assistance of convex glasses becomes necessary. The eye is enabled to judge and accommodate itself to objects at different distances, by the action of its muscles increasing or diminishing the length of its axis, and by the motions of the iris allowing a greater or smaller quantity of light to be thrown into the eye.

---

### DISSECTION OF THE ANTERIOR PART OF THE BODY.

THIS dissection may be subdivided into that of the thorax and abdomen, which I have combined. Some of the muscles upon the anterior part of the thorax have been already described in the dissection of the superior extremity. Prior to the removal of the skin, the dissector should make himself acquainted with the regions of the abdomen, which are the following. Draw two transverse lines across the abdomen, the upper from the ninth rib on the right to the left side, the lower line from the anterior superior spinous process, to the same part on the opposite side: the space above the first line is the epigastric region; the space between the two, the umbilical; and the space between the lower line, the hypogastric region. These three regions are again divided into others, by two perpendicular lines, each drawn from the union of the cartilage of the ninth rib to the union of the os pubis with the ilium. These two lines divide each of the regions into three: the epigastric, into the right and left hypochondric region; between these, the scrobiculus cordis. The umbilical region has on either side the two lumbar regions, and the hypogastric is divided into the two iliac regions, and the part above the pubis, into the regio pubis, or mons veneris, in the female. These regions are better explained by the following diagram.

*a. b.* First transverse line, from the ninth rib on the right side to that on the left side.

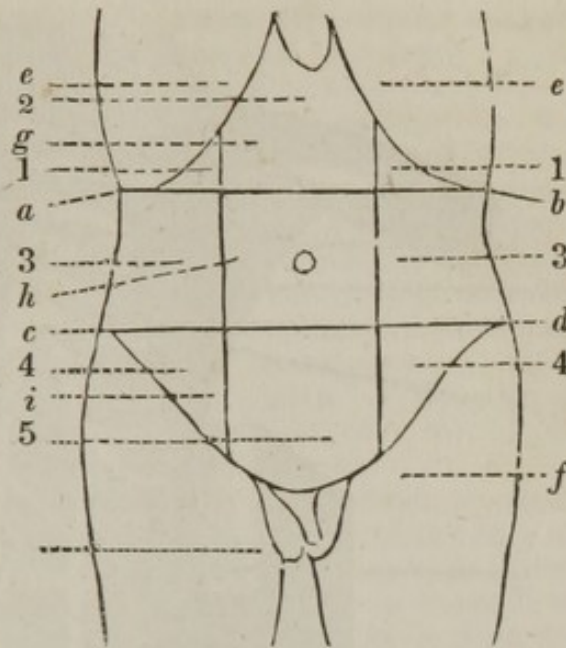
*c. d.* Second line, from the anterior superior spinous process to the same parts on the opposite side.

*e. f. e. f.* The two perpendicular lines, from the ninth rib to the union of the pubis to the ilium.

*g.* The epigastric region, dividing into 1. 1. The two hypochondric regions; and 2. The scrobiculus cordis.

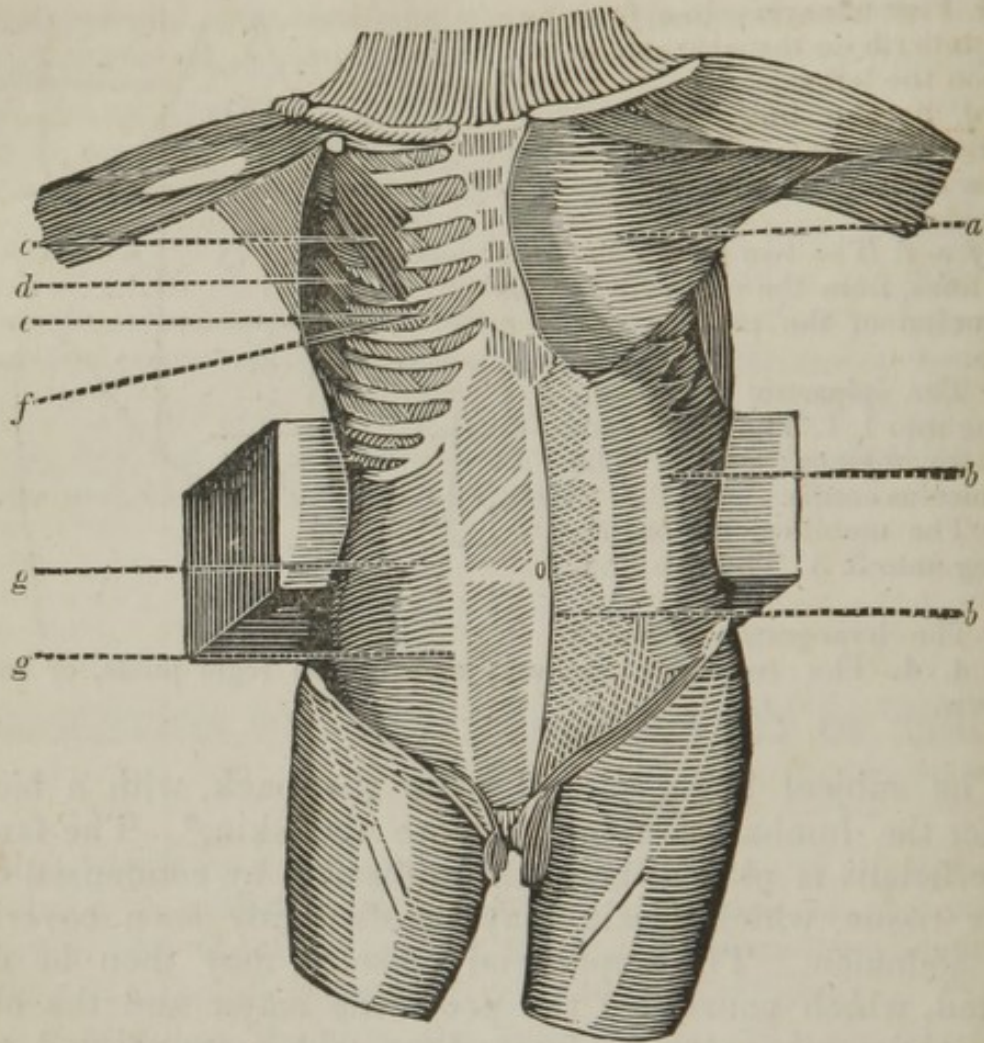
*h.* The umbilical region, dividing into 3. 3. The two lumbar.

*i.* The hypogastric, divided into 4. 4. The two iliac regions; and 5. The regio pubis, or mons veneris.



The subject being placed upon the back, with a block under the lumbar vertebræ, remove the skin.\* The fascia superficialis is placed beneath it, formed by condensed cellular tissue, which fascia may be distinctly seen covering the abdomen. The superficial muscles may then be dissected, which consist of the pectoralis major and the obliquus abdominis externus descendens, which are pointed out, as also the muscles beneath them, in the following plate.

\* As it is necessary to remove the abdominal viscera, which soon decompose, the muscles of this region are usually the first to be dissected, and there are none which are more difficult to the student. A large block should be placed under the back, the legs should hang over the table, and the arms thrown over the head, the hands being tied together. If the right external oblique is to be dissected, bend the body towards the left, and vice versa. From about an inch above the ensiform cartilage, commence an incision which is to be carried in a semicircular direction to the posterior superior spinous process of the ilium. The exact line of this incision will be determined, by recollecting the origin of this muscle from the edge of the eight inferior ribs. Make another incision down to the muscle, from the place marked 1 in the above view, to the spinous process of the pubis. From this last incision dissect towards the linea alba upwards, and towards the crest of the ilium in the opposite direction.



- a.* The pectoralis major.  
*b. b.* The obliquus abdominis externus descendens; beneath these muscles the following:—  
*c.* The pectoralis minor.  
*d.* The serratus magnus anticus.  
*e.* The external intercostal muscles.  
*f.* The internal intercostal muscles.  
*g.* The obliquus abdominis internus ascendens.

The pectoralis major has already been described.

*b.* The obliquus abdominis externus descendens *arises* in a serrated manner, from the lower edge of the eight inferior ribs, near their cartilage. The five superior serræ intermix with the indentations of the serratus magnus anticus, the three inferior between the latissimus dorsi; the last of them covering a portion of it, extending from the twelfth rib to the spine of the ilium, having part of its origin from the anterior half of the crista, and anterior superior spinous process of that bone. From these attachments the fibres run obliquely downwards and forwards, and terminate by a tendinous aponeurosis, which, near its margin, is firmly connected with the tendons of the internal oblique and transversalis abdominis, where it forms a curved line, called *linea semilunaris*. From this the tendinous fibres are continued, in the same direction as the fleshy fibres, to the middle of the abdomen, to be *inserted* into its fellow

of the opposite side, by the medium of the linea alba, which extends from the ensiform cartilage to the pubis; this line is formed by the union of the tendons of the oblique and transverse muscles, and is perforated in the middle by the umbilicus, originally a passage for the umbilical cord, and now formed into a cicatrix. The tendon of this muscle is strengthened by the internal oblique and transversalis tendons, being of a more delicate nature, which decussate it in a curved direction, upwards and inwards. The under part of the tendon is thicker and stronger than the rest of it, and extends from the anterior superior spinous process of the os ilium, over the flexor muscles and great vessels and nerves of the thigh, to the upper part of the os pubis, to which it is fixed. This part of the tendon, known by the name of Poupart's, or Fallopius's, or inguinal ligament, forms a curve behind, over the blood-vessels, and therefore receives the name of the crural arch.

Somewhat higher, and farther out than the symphysis pubis, or about an inch and a half in a full-sized adult, the crural arch divides into an upper and under column. The upper is fixed to the symphysis pubis, and to the os pubis of the opposite side. The under is twisted or doubled in, and inserted into the upper part of the os pubis, from the femoral vessels, as far as the crest or tuberosity of the bone, and forms a firm sharp line towards the abdomen, which constitutes the posterior edge of the crural arch, or the third insertion of the external oblique. The under column is looser and more slender in the female than in the male; and the space between the femoral vessels and the insertion of this part of the ligament is larger; in consequence of which, protusions of the bowels happen here more frequently in women.

Where the columns separate, a space of a triangular form is left, about an inch in length in the male, but less in the female; the direction running upwards and outwards, or somewhat in a line between the pubis and spine of the ilium. This is the external abdominal ring, formed by the tendon of the external oblique muscle, for the transmission of the spermatic cord in the male, and the round ligament of the uterus in the female.

Surrounding the exit of the cord, or the round ligament, from the ring, there is a quantity of cellular substance, and some tendinous fibres, which assist in filling that passage, and in preventing any communication between the outer and inner parts. The place where the columns separate to form the ring varies in different subjects; in some, the separation is considerably farther out than already described, though more generally the division is at the outer end of the ring. The columns are joined by tendinous fibres, which arise from the os ilium, and from the inguinal ligament, and are part of the fibres before mentioned as decussating the tendon of the external oblique muscle. From the under end of the inguinal ligament, and from the pubis, an aponeurosis descends and forms part of the general fascia of the thigh. This expansion stretches the ligament in the extended state of the thigh, but allows it to be relaxed when the limb is bent, or when the aponeurosis, by being cut across, loses hold of the thigh.

Besides the aponeurosis, there is a thin expansion which descends upon the abdominal muscles, adheres firmly to the crural arch, and vanishes in the fat of the thigh, and over the inguinal glands. Part of it also descends over the cords, as far as the scrotum. At the upper and fore part of the thigh, the aponeurosis forms a falciform edge, which leaves a large opening in that sheath, where the vena saphena major terminates

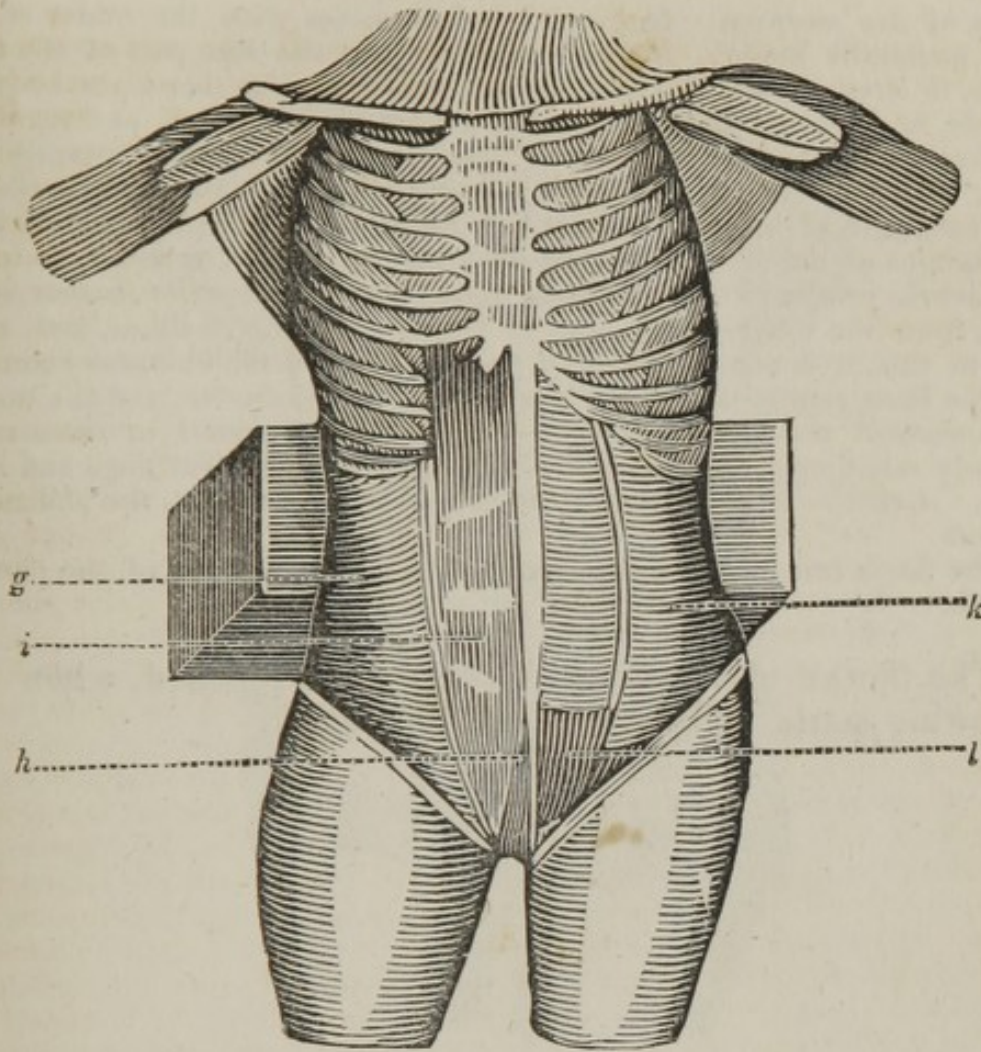
in the femoral vein. Farther in than this curved edge, the aponeurosis descends over the pectineus and other muscles, to unite with the former portion behind the great saphena. Through the abdominal ring, there is no direct opening into the cavity of the abdomen; the passage being shut by the obliquus internus, and transversalis abdominis. *Action*,—to draw the lower ribs downwards and backwards, thus diminishing the cavity of the thorax,—to draw the chest and upper part of the trunk obliquely downwards and forwards, and towards the opposite side,—to draw the pelvis towards the chest when the latter is fixed. Both muscles acting, bend the upper part of the trunk directly forwards, at the same time compressing the viscera.

The pectoralis minor, serratus magnus anticus, and intercostal muscles, have been already described, see page 57.

*g.* The obliquus abdominis internus ascendens *arises* from the fascia lumborum, which is attached to the back part of the os sacrum, and spinous processes of the three inferior lumbar vertebræ, from the whole length of the spine of the os ilium, from its anterior superior spinous process, and from the inside of Poupart's ligament, at the middle of which it sends off the cremaster muscle. From these origins the fibres are disposed in a radiated manner; but the greater part of them run in a slanting direction upwards. At the linea semilunaris, the muscle becomes tendinous, and adheres firmly to the tendon of the obliquus externus. Here its tendon divides into two layers. The anterior layer, with the greater part of the inferior portion of the posterior layer, joins the tendon of the external oblique, and goes over the rectus, to be inserted into the whole length of the linea alba. The posterior layer joins the tendon of the transversalis, and goes behind the rectus; and this union is continued down, till it reaches about half way between the umbilicus and pubis. Lower than this, only a few scattered fibres of the posterior layer are to be found behind the rectus; the principal part of it passing before that muscle, with the tendon of the transversalis, to be *inserted* into the cartilages of all the false ribs, into the ensiform cartilage, and whole length of the linea alba. *Action*,—to assist the former muscle. It bends the body, however, in the same direction with the obliquus externus of the opposite side.

The cremaster, *vel* musculus testis, *arises* from the inferior edge of the obliquus internus abdominis; passing through the ring of the obliquus externus, it surrounds the spermatic cord as far as the testicle, where the fibres separate and expand, to be *inserted* into the tunica vaginalis testis, and cellular substance of the scrotum. *Action*,—to suspend, elevate, compress, and evacuate the testicle.

The sheath of the internal oblique may now be reflected on one side, and the muscular fibres on the opposite side, which will bring into view the remaining muscles.



- g.* The obliquus internus, with its tendon divided, to show  
*h.* The pyramidalis.  
*i.* The rectus abdominis. Beneath the internal oblique there is situated  
*k.* The transversalis abdominalis, and  
*l.* The fascia transversalis.

*h.* The pyramidalis *arises* by a broad base, from the upper part of the symphysis pubis. It runs upwards within the same sheath with the rectus, tapering to a point in its ascent, to be *inserted* near half way between the pubis and umbilicus, in the linea alba and inner edge of the rectus. *Action*, — to assist the under part of the rectus in drawing down the ribs, or to compress the under part of the abdomen. It is frequently wanting in both sides, and then the under end of the rectus is larger, thus in some measure supplying its place.

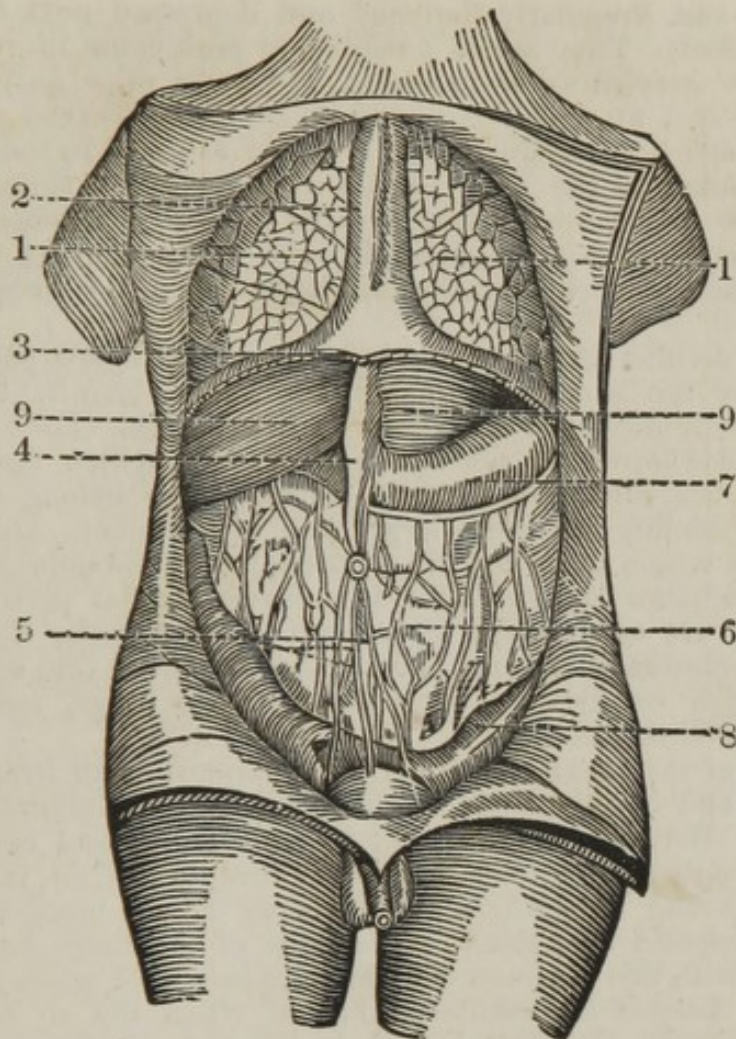
*i.* The rectus abdominis *arises* from the fore and upper part of the symphysis pubis by two small tendons; it soon becomes fleshy, and runs upwards in form of a flat band, the whole length of, and parallel to, the linea alba. In its course it is divided by three transverse tendinous intersections, at and above the umbilicus; and there is generally a half intersection below it; these seldom penetrate through the whole thickness of its substance, they adhere firmly to the anterior part of the sheath which incloses the muscle, and but slightly to the posterior layer. *Inserted* into the cartilages of the fifth, sixth, and seventh ribs, and extre-

mity of the sternum. It frequently intermixes with the under edge of the pectoralis major. *Action*,— to compress the fore part of the abdomen, to draw down the ribs, in expiration, and to bend the body forwards, or to raise the pelvis. By means of its sheath and tendinous intersections it is kept in its place, and allowed to act more equally.

*k.* The transversalis abdominis *arises* fleshy, from the inner surface of the cartilages of the six or seven lower ribs, where it intermixes with the digitations of the diaphragm and with the intercostal muscles, from the transverse processes of the twelfth dorsal and four superior lumbar vertebræ, from the whole inner edge of the spine of the os ilium, and, anterior to this, it is connected to the under edge of the obliquus externus. At the linea semilunaris, the muscle becomes tendinous, and the tendon is continued across, adhering to the obliquus internus in the manner already mentioned, to be *inserted* into the ensiform cartilage and linea alba. *Action*,— to support, and immediately to compress, the abdominal viscera.

The fascia transversalis is described in the dissection of the parts of hernia.

The thorax and abdomen may now be opened, when the following parts will be brought into sight.

*Thorax.*

1. 1. The lungs.
2. The pleura, forming the anterior mediastinum and pericardium.
3. The diaphragm, cut all round its anterior part.

*Abdomen.*

4. The suspensory ligament of the liver, containing the ligamentum teres.
5. The suspensory ligament of the bladder, formed by the uracus and the two obliterated hypogastric arteries.
6. The omentum magnum, divided into the omentum gastro colicum and omentum colicum.
7. The stomach.
8. The intestines, situated behind the omentum.
9. 9. The liver.

1. The lungs are two soft spongy bodies, which occupy the far greater part of the cavity of the thorax. They completely fill the two bags of the pleura, and are everywhere in contact with the parts adjacent; no air intervening between them and the thorax. In figure they have been compared to that of the foot of an ox, with the back part turned forwards;—or, their shape corresponds exactly with the inside of the thorax; being rounded next the ribs, hollow towards the



diaphragm, and irregularly flattened and depressed next the mediastinum and heart. They are of a reddish or pink color in children, of a light blue or greyish color in adults, and more of a purple and livid color in old age, at which period they are also observed to be tinged with black spots, proceeding from a matter secreted in their substance. They are joined to the neck by the trachea; to the spine by the two layers of the mediastinum, which serve them as ligaments; and to the heart, by the pulmonary vessels; the rest of them being free and unconnected, unless when an adhesion takes place in consequence of inflammation.

They are divided into right and left lungs, which are separated from each other by the heart and mediastinum, and which have no communication except through the medium of the trachea. Each of the lungs is again divided into large portions, called lobes, which facilitates their motion and the dilatation of their cells. Three belong to the right lung, corresponding with the larger bag of the pleura, and two to the left, between which there is a sinus, occupied by the point of the heart. Each of the lobes is subdivided into many smaller parts, termed lobules, which are of different sizes, and of an irregular angular form. The lobules diminish in size, and degenerate at last into small vesicles or cells, which constitute a large share of the lungs, and which are nearly visible to the naked eye.

The cells of the lungs are purely membranous, of an irregular figure, compressed and closely connected, and have a free communication with each other. Between the different lobes, lobules, and cells, a large quantity of common cellular substance, destitute of fat, is interposed; which unites and strengthens them, and allows the blood-vessels to be minutely dispersed over them. The cells of the lungs have no communication with this common cellular substance; for when air is blown into it, the lobules are compressed; but when the air is blown in through a branch of the trachea, the cells are again distended, and the lobules recover their former dimensions. In the fœtus, the cells are empty and in a collapsed state; — but, as soon as respiration begins, they become distended, and continue so during life.

The lungs are covered by two coats; an external or common, and an internal or proper one. The external or common coat is a continuation or reflection of the pleura; it is extremely thin, but dense, and, like the other parts of the pleura, is found to possess little sensibility. It forms a general covering to the lungs, but does not enter between their different lobules. The internal or proper coat adheres so firmly to the former, as to appear to constitute part of its substance. It not only covers the lungs, but insinuates itself between the lobules, and is intimately connected with their cellular substance.

The trachea, *vel* *aspera arteria*, so called from the inequality of its surface, and from its conveying air, begins at the under part of the cricoid cartilage, and descends in the fore part of the neck; it passes into the thorax, where it is situated between the layers of the upper part of the posterior mediastinum. Behind the curvature of the aorta, and opposite to the third dorsal vertebra, the trachea divides into two lateral branches, termed bronchi; one of which goes to the right, and the other, which is the smaller of the two, to the left lung.

The bronchi are divided into branches, which by degrees become smaller, and at last terminate in the cells of the lungs, which communicate so freely with each other, that, upon introducing air into any of these branches, a large portion of the lungs may be inflated.

The trachea consists of cartilaginous rings, about sixteen or eighteen in number, which give strength and firmness to it, and preserve it constantly open for the transmission of air. They are incomplete, however, behind, where the trachea is formed of a soft fleshy substance, which yields to the œsophagus in the time of deglutition. Each cartilage forms a large segment of a circle, about a line or one twelfth of an inch in breadth, and one fourth of a line in thickness. The cartilages are situated horizontally, with their edges opposed to each other, small spaces intervening between them. They are united to each other by a musculo-ligamentous substance, which is so elastic, that when the lungs are taken out of the body, it draws the cartilages close together.

The bronchi, at their beginnings, have the same kind of cartilage with the trachea; but after they enter the lungs, each cartilaginous ring is divided into two or three pieces, which, however, are so connected to each other, as to go completely round the bronchi, and keep the passage open and free from compression.

A very vascular and irritable membrane, continued from the mouth, lines the inner side of the trachea, and terminates in the cells of the lungs. The inner membrane of the trachea is everywhere perforated by the ducts of mucous glands, and by the mouths of the exhalent arteries, the former pouring out mucus to lubricate the lungs, the latter the vapor, which is thrown off in expiration.

In the cellular substance round the under end of the trachea and roots of the bronchi, where these penetrate into the substance of the lungs, there is placed a chain of glands, termed bronchial. They are of various sizes, from that of the point of the little finger to that of a millet-seed, and have a bluish or dark color, corresponding in a great measure with the color of the darkest part of the lungs. They are of the lymphatic kind, — the absorbents of the lungs passing through them in their way to the thoracic duct. The trachea serves to convey air into, or out from, the cells of the lungs, during respiration, and to carry off the perspirable matter from the arteries in the time of expiration.

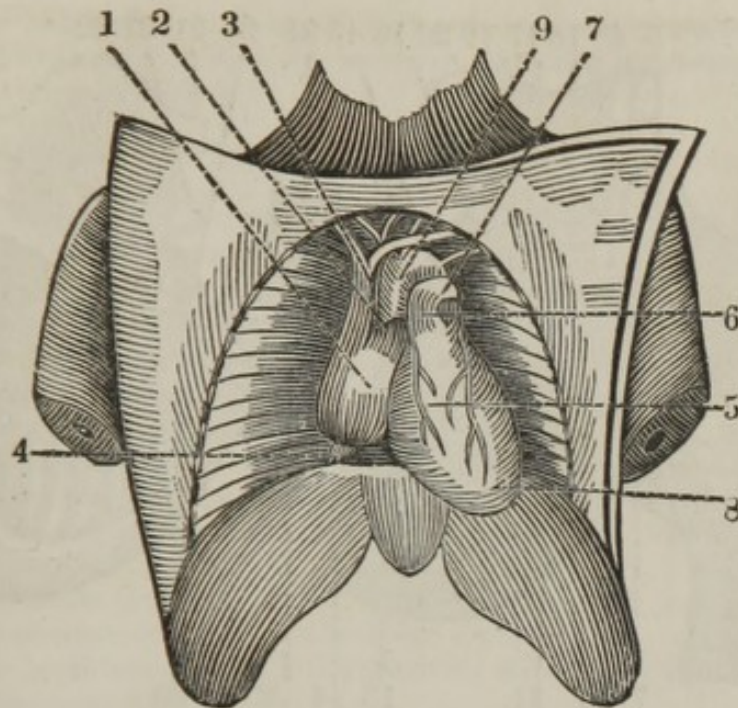
The lungs serve the general purpose of respiration, which consists of inspiration and expiration, or the passage of the air into, or out from, the lungs, by the alternate dilation and contraction of the thorax. Inspiration is performed in consequence of the thorax being dilated by the action chiefly of the diaphragm and intercostal muscles; the lungs, which are passive, and in contact with the thorax, following it and the air rushing into the trachea by its own gravity. Expiration is performed in consequence of a relaxation of the muscles which dilate the thorax, — of the action of the abdominal and a few other muscles, — of the elasticity of the cartilages of the ribs, and likewise of the lungs, by which the cavity of the thorax is diminished, and the air is expelled from the lungs. Upon the alternate states of inspiration and expiration depend the formation of the voice, the sensation of smell, and all the other functions of the body: — but the great and principal office of the lungs is, during inspiration to receive from the atmosphere pure air, upon which the principle of heat and life depends; and, during expiration, to carry off an impure air, which is noxious to our existence.

According to experiments, the venous blood passing to the lungs, of a dark red or purple color, is charged with carbon and hydrogen; — that, while circulating upon the bronchial cells, one part of the oxygen, contained in the common air which has been inspired, unites with the carbon and hydrogen, and forms fixed air and a watery halitus, which are

carried off by expiration ; — that another part of the oxygen is imbibed by the blood, which, in consequence of these changes, returns from the lungs of a florid red color, and full of heat in a latent state, which becomes sensible in the course of the general circulation, and is diffused over the different parts of the body ; — and that the blood thus charged also affords a stimulus to the arteries, and promotes the different secretions.

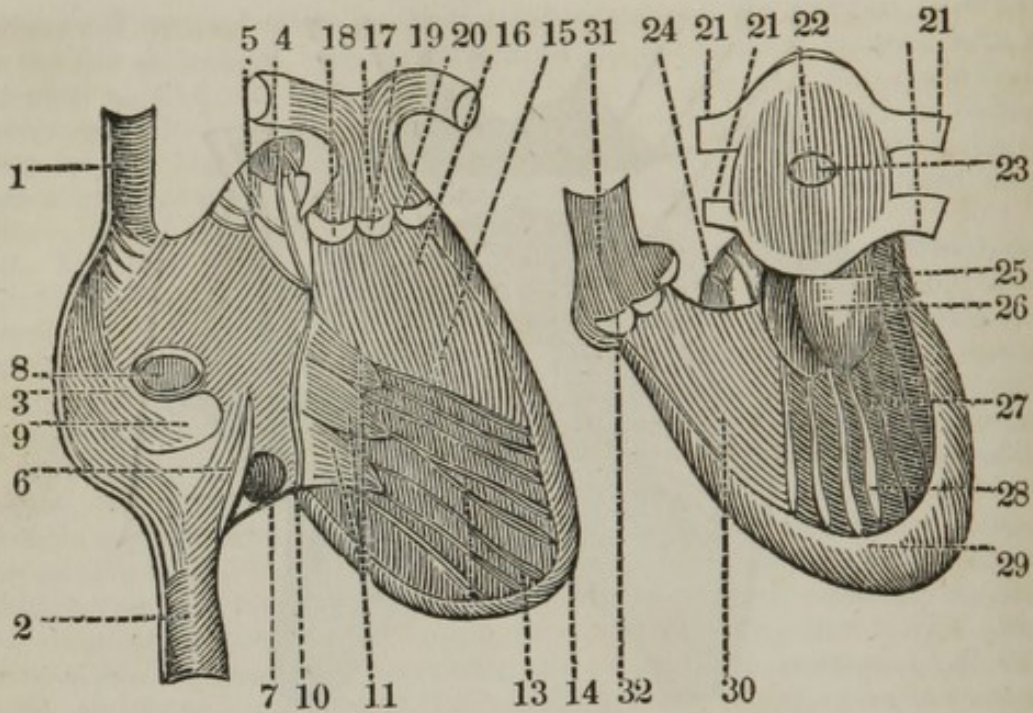
2. The pleura lines the thorax, dividing it into cavities, which contain the several vessels, nerves, and viscera between its layers ; it is a membrane of considerable strength ; its external surface cellular, and adheres closely to the parts which surround it ; its internal surface smooth and polished, being moistened by a serous fluid, which exudes from its arteries. It is divided into two lateral sacs or pleuræ, the form of which corresponds exactly with that of the surrounding bones of the thorax. The pleuræ adhere to the periosteum of the ribs, line the intercostales and sternocostales, the sternum, the dorsal vertebræ, and cover the pericardium, lungs, and lateral or fleshy parts of the diaphragm. This membrane, covering the ribs, is termed pleura costalis ; covering the diaphragm, pleura diaphragmatis : and covering the lungs, pleura pulmonalis. Behind the sternum, the pleuræ are contiguous to each other, and form a partition called mediastinum, which extends from the sternum to the vertebræ, in the centre of which the pericardium, or capsule of the heart, is situated, one of the strongest membranes of the body, and its size such as to be properly adapted to that of the heart, which it contains. It is formed of two layers ; the external of which is a continuation of the anterior mediastinum, which afterwards passes to the lungs and lateral parts of the diaphragm. The external layer is stronger than the other ; it adheres so firmly to the tendinous part of the diaphragm, as not to be separated from it without much difficulty. The pericardium extends a considerable way beyond the base of the heart, and includes the large blood-vessels, as far as the roots of their first principal branches, in consequence of which it forms several angles, which have been termed cornua of the pericardium. While the external layer is reflected to cover the parts which surround it, the internal is also reflected, first over the roots of the large blood-vessels, and then over the heart, to form its proper covering ; in the same manner as the tunica conjunctiva is reflected from the eye-lids to cover the fore part of the eye. From the ends of the extreme arteries upon its surface, a fluid, called liquor pericardii, is discharged, by which it is lubricated, and the effects of friction diminished. The pericardium preserves the heart *in situ*, defends it from being injured by the parts which surround it, and restrains its inordinate motion.

The membrane may now be opened, when the heart will be seen in its proper position, and the vessels which arise and run to terminate in it may be observed ; the first that presents itself is the pulmonary artery. The following plan shews the proper position of the heart.



1. The right auricle of the heart.
2. The auricular portion.
3. The superior vena cava, terminating in this cavity.
4. The inferior vena cava, entering also the right auricle.
5. The right ventricle.
6. The pulmonary artery.
7. The left pulmonary artery; the right passes behind the ascending aorta.
8. The left ventricle, forming the apex of the heart.
9. The aorta, arising from the left ventricle.

The heart can now be removed, and its anterior portion examined. The dissector may introduce a blow-pipe into the superior and inferior vena cava, and the part between those two vessels must be cut through, when the inner part of the auricle is to be observed. I have added the accompanying diagram, to accelerate the knowledge of the anatomy of this important organ.



*Right side of the heart.*

1. The superior vena cava
2. The inferior vena cava
3. The sinus of the right auricle.
4. The auricular portion, containing
5. The musculi pectinati.
6. The Eustachian valve ; a fold of the lining membrane of the auricle, which in the fœtus is supposed to conduct the blood in its two different courses, and in the adult it may prevent to a slight degree the reflux of the blood from the vena cava superior, and from the right auricle generally into the vena cava inferior.
7. The coronary valve, closing in a great measure the entrance of the coronary vein.
8. The fossa ovalis, or obliterated foramen ovale.
9. The tuberculum Loweri.
10. The opening from the auricle to the ventricle, termed ostium venosum, giving attachment to the tricuspid valve.
11. The tricuspid valve. The apex of this valve is situated in the right ventricle, and has occasionally received the name of the curtena tendina.
12. The cordæ tendinæ attached to the tricuspid valve, and passing to be connected to
13. The carneæ columnæ, which pass to be attached to
14. The parieties of the right ventricle.
15. The situation of the foramina Thebesii.\*
16. The pars plana, leading to
17. The pulmonary artery, which is seen to bifurcate into the right and left pulmonary artery. At the orifice of this artery there are placed
18. The semilunar valves, three in number ; and in the centre of each a small projection, termed

\* This is an error. The foramina of Thebesius which are the openings of the cardiac veins, are in the right auricle.

19. The sesamoid processes.\* They serve to complete the valves when the blood passes from the ventricle into the pulmonary artery.
20. The sinus Valsalvæ.

*Left side of the Heart.*

21. The four pulmonary veins, returning the blood from the lungs into
22. The sinus of the left auricle.
23. The fossa ovalis, seen on the left side.
24. The auricular portion, containing the muscoli pectinati, but less on this side of the heart than on the right side.
25. The ostium arteriarum, or entrance from the auricle to the ventricle.
26. The mitral or bicuspid valve, situated in the left ventricle. The apex of this valve has received the term of the *curtina tendina*, and is thicker than the other part of the valve. This valve gives attachment to
27. The *cordæ tendinæ*, which are attached to
28. The *carneæ columnæ*, which are attached to
29. The parieties of the left ventricle, which are much thicker than those on the right side.
30. The *pars plana*, leading to
31. The aorta; at the origin of which are
32. The three semilunar valves, with the sesamoid processes, in the centre of each; and behind the valves, the sinus Valsalvæ.

The action of the heart consists in its contraction and dilatation; the former termed systole, the latter diastole. The auricles contract and dilate together, and the ventricles also. The heart may be said to be an involuntary muscular organ; the fibres are stated to arise from a central tendon situated at its base.

The pleura forms the mediastinum, so named from its situation in the middle of the thorax. It extends between the sternum and vertebræ; but is intercepted by the heart and root of the lungs, and divides the thorax into two distinct cavities, which have no communication with each other. It is formed by a reflection of the pleura, and is of course double, and contains between its layers a considerable quantity of cellular substance, by which they are united. It is divided into anterior and posterior mediastinum, the former of which is situated at the fore, and the latter at the back part of the thorax.

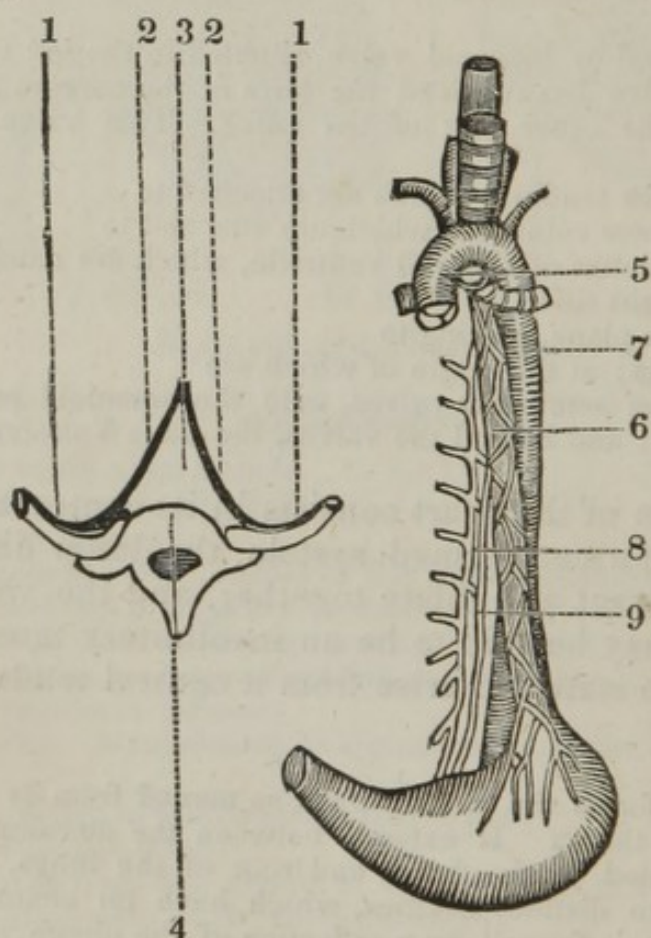
The anterior mediastinum is connected before to the sternum; and behind, to the pericardium and large vessels of the heart. The two layers of the anterior mediastinum are closely applied to each other, excepting at the upper part of the thorax, where they are separated by the remains of the thymus gland. At the upper part of the thorax, it lies exactly behind the middle of the sternum; but in its descent it inclines gradually towards the left side of that bone.

The posterior mediastinum reaches from the root of the lungs and back part of the heart, to the dorsal vertebræ. It is a triangular cav-

\* Or *Noduli Morgagnii*.

ity, formed laterally by the pleura, which, after lining the inner part of the ribs, is reflected towards the membrane of the opposite side, when the two membranes unite together to form the apex of the cavity, while the base is formed by the dorsal vertebræ. This cavity contains the bifurcation of the trachea; the œsophagus, surrounded by the par vagum; behind this, the thoracic aorta, the vena azygos on its right side, and the thoracic duct behind and between the two.

The following diagram is intended to illustrate the relative position of these vessels, and the formation of the posterior mediastinum.



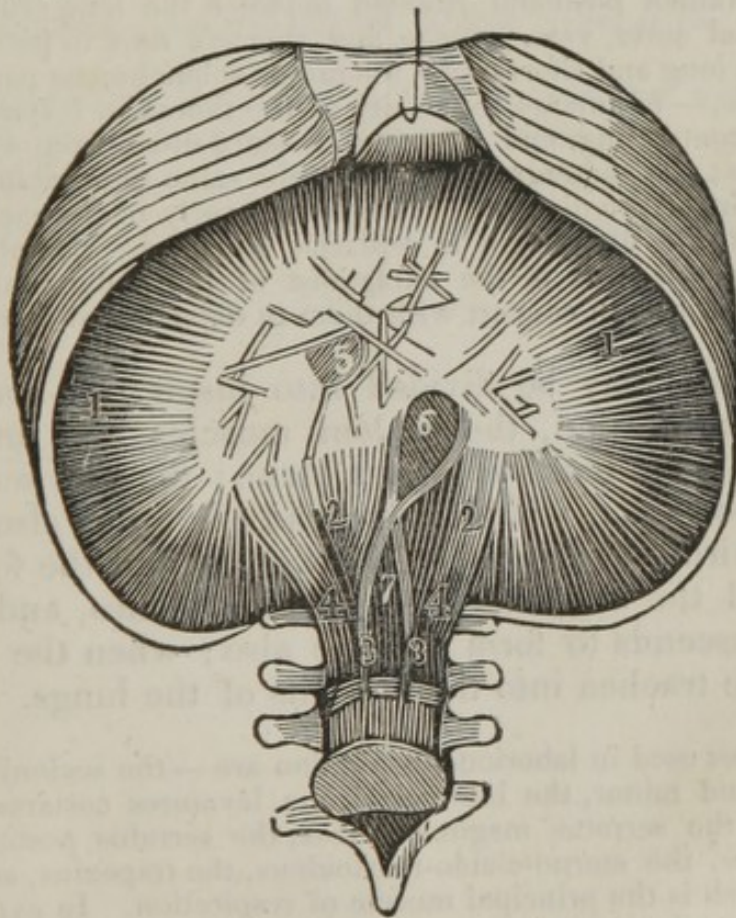
1. The pleura, lining the ribs.
2. The two membranes, passing towards each other to unite and form
3. The posterior mediastinum, which is bounded posteriorly by
4. The anterior part of the bodies of the dorsal vertebræ.
5. The trachea, seen passing behind the arch of the aorta, where it bifurcates into the two bronchial tubes; at the bifurcation, there are several bronchial glands, which receive the lymphatic vessels from the lungs. These glands are of the color of the lungs, and contain carbon.
6. The œsophagus, passing behind the arch of the aorta, posterior to the trachea; it then descends, crossing gradually towards the left side, when it passes through the left opening of the diaphragm to terminate in the stomach. The œsophagus is surrounded by the par vagum, which forms the œsophageal plexus. This tube is supplied by small branches of arteries which arise from the thoracic aorta; the blood is returned back by small trunks which terminate in the vena azygos.

7. The thoracic aorta, descending on the left side of the cavity, and gradually crossing towards the right side.

8. The vena azygos, situated at the right side of the posterior mediastinum. This vein is formed by the union of the two first lumbar veins, which, after uniting, pass through the posterior opening of the diaphragm to enter the mediastinum; here it receives the right intercostal veins by twelve distinct trunks, and on the left side it receives the intercostal veins by three or four branches, which pass under the aorta. The vena azygos then forms an arch, the concavity of which is downwards, and enters the central and posterior part of the superior vena cava.

9. The thoracic duct, situated behind and between the aorta and vena azygos, the continued trunk of the receptaculum chyli, which passes through the posterior opening of the diaphragm, and ascends as high as the fourth dorsal vertebra, where it crosses behind the aorta, ascending as high as the sixth cervical vertebra, when the duct descends to enter the outer part of the junction of the left jugular and subclavian vein.

The diaphragm is divided into a large and small muscle. It cannot be dissected until the abdominal viscera have been removed, when it is only necessary to keep the muscle tense, by drawing up the ribs and removing the peritoneum.



1. 1. 1. The large muscle, arising from the cartilages of all the inferior ribs, serrating with the transversalis abdominis; from the ligamentum arcuatum; and from the ensiform cartilage. From these origins the muscular fibres all converge, running as it were to a centre, where they are inserted, or form the cordiforme central tendon.



2. 2. 2. The small muscle, arising by four crura; two long, or internal, and two short, or external.

3. 3. The long crura, taking their origin from the second and third lumbar vertebræ, and from an aponeurotic expansion situated over those bones. The right crus is longer than the left, and has beneath it the receptaculum chyli. Between the long crura there is an opening formed, termed the foramen posticum.

4. 4. The short crura, taking their origin from the first and second lumbar vertebræ, also from the tendinous expansion, covering the lumbar vertebræ: the four crura ascend to be inserted into the cordiform tendon; the two long crura unite, then decussate to form the left foramen of the diaphragm.

5. The right opening of the diaphragm, or, as it is occasionally called, the foramen dextrum triangulare. It is formed by a decussation of the tendinous fibres of the cordiform tendon, and allows the vena cava inferior to pass through it; the angles of the opening being filled by condensed cellular substance. This opening is tendinous, to prevent the circulation of the blood being impeded in its passage to the heart.

6. The left opening, or foramen dextrum ovale, formed by a decussation of the long crura; the opening is muscular, but the upper part is slightly tendinous. This opening allows the œsophagus and par vagum to pass through it.

7. The foramen posticum, situated between the long crura, allowing the abdominal aorta, vena azygos, and thoracic duct to pass through it. Between the long and short crura, the ramus splanchnicus passes. *Action* of the muscle,—to enlarge the cavity of the thorax in inspiration, by its fleshy part contracting, and bringing its sides down from a convex to a plane surface; the abdominal muscles at the same time yielding, but the tendinous part of the diaphragm remaining nearly in the same situation. In expiration, the diaphragm is replaced chiefly by the action of the abdominal muscles; it is the antagonist of the abdominal muscles in inspiration, but acts in concert with them in dejection and vomiting.

Respiration may be divided into inspiration and expiration. In inspiration, the scaleni muscles act, and fix the first rib, so as to make it form a plane; the first set of intercostal muscles act, when the second rib forms also a plane; then the third set of intercostal muscles, and the fourth, and so on, until the whole of the ribs form planes, and the diaphragm descends to form a plane also; when the air passes through the trachea into the air cells of the lungs.

The muscles used in laborious inspiration are—the scaleni, the pectoralis major and minor, the intercostal, the levatores costarum longiores et breviores, the serratus magnus anticus, the serratus posticus inferior, the subclavius, the sterno-cleido-mastoideus, the trapezius, and the diaphragm, which is the principal muscle of respiration. In expiration, the abdominal muscles press against the viscera, which (by the pressure) causes the diaphragm to become convex at its upper surface, and at the same time the abdominal muscles draw down the ribs, with the assistance of the triangularis sterni and serratus posticus inferior, when the air is expelled from the air cells of the lungs.

The muscles used in laborious expiration are — the abdominal muscles, the triangularis sterni, the serratus posticus inferior, the quadratus lumborum, spinalis, and longissimus dorsi.

*The Abdomen.*

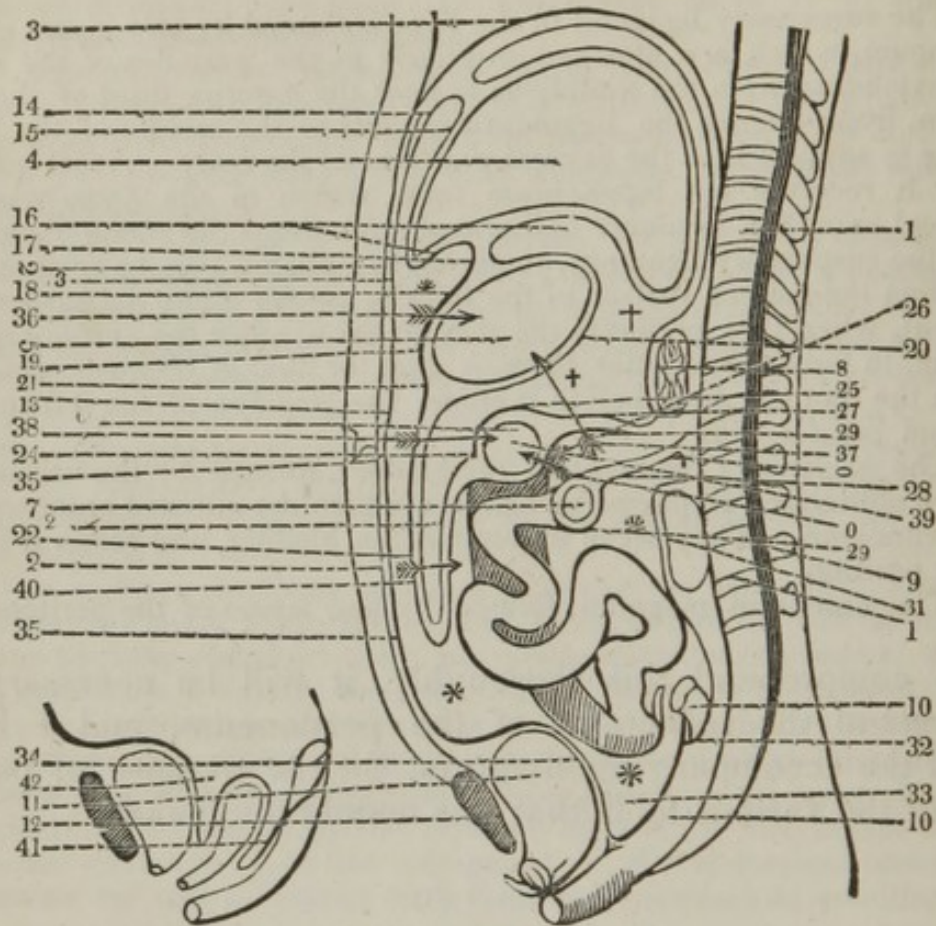
4. The suspensory ligament of the liver is formed by two layers of the peritoneum, which are attached anteriorly to the parieties of the abdomen, extending from the umbilicus to near the anterior third of the diaphragm, from whence the ligament descends to the middle of the liver, serving to support it in the several positions of the body. At its inferior border it receives the ligamentum teres, which in the fœtus was the umbilical vein, but becomes obliterated, and forms the round ligament. Upon the suspensory ligament, numerous lymphatics may be seen, which arise from the convex surface of the liver to ascend along the suspensory ligament, when they perforate the diaphragm to enter the anterior mediastinum, to form the anterior thoracic duct, or duct of Hewson, terminating in the thoracic duct, before it enters the junction of the left subclavian and jugular vein.

5. The suspensory ligament of the bladder, formed by the uricus and the two obliterated hypogastric arteries, which are situated anteriorly to the peritoneum. They serve to support the bladder, and retain it in its proper position.

6. The omentum magnum, formed by four layers of the peritoneum.

To comprehend this thoroughly, it will be necessary to understand the reflections of the peritoneum, and I have added the accompanying diagram, for the purpose of pointing out the various folds that this membrane makes.

The diagram shows a section of the body, and the peritoneum may be traced from any point round the viscera, back again to the same point.



1. 1. A section of the spinal column.
2. 2. A section of the parieties of the abdomen.
3. 3. A section of the diaphragm.
4. 4. The section of the liver.
5. 5. Section of the stomach.
6. 6. Section of the colon.
7. 7. Section of the intestines.
8. 8. Section of the pancreas.
9. 9. Section of the kidney.
10. 10. The rectum.
11. 11. Section of the bladder.
12. 12. Section of the pubis.
13. 13. The peritoneum, lining the upper part of the parieties of the abdomen traced from the umbilicus,
14. 14. Passing upon the under or concave part of the diaphragm, from thence to
15. 15. The convex surface of the liver, (forming the suspensory, the two lateral, and coronary ligaments, which are not shown;) from the convex surface of the liver, it passes to
16. 16. The concave surface; from thence it descends, forming

17. The lesser omentum, or hypogastricum of Winslow,\* which consists of two layers, which pass to

18. The lesser curvature of the stomach. Here the two layers divide :

19. The one layer passing on the anterior part of the stomach ;

20. The other layer on the posterior part of the stomach ; so that the two layers embrace that viscus, meeting at

21. The greater curvature, when the two layers again unite ; and at

22. They descend to form the anterior part of the omentum magnum. At

23. The two layers are reflected upon themselves, completing the formation of the omentum magnum.

24. The two layers meet the transverse arch of the colon, where they again divide : one layer at

25. Passing above, or anterior to the colon, and the other at

26. Behind, or below the colon ; the two layers again meet at

27. To form the mesocolon, connecting the colon to the spine, when one layer passes up to cover the anterior part of the pancreas and spleen, the other layer passes at

28. To form the anterior part of the mesentery, which passes at

29. Over the intestines, then is reflected at

30. To form the posterior part of the mesentery, the mesentery serving to contain the vessels and support the intestines. The peritoneum then, at

31. Is reflected over the kidney, then descends at

32. Forming the mesorectum, connecting that intestine to the sacrum, at

33. Forms a cul de sac between the rectum and bladder, at

34. Is reflected over the posterior and superior part of the bladder.

35. Ascends at the inner part of the parieties of the abdomen to the umbilicus, to the point where it was first begun to be traced, forming an anterior and posterior shut sac.

\* \* \*. The anterior shut sac, the seat of ascites.

† † †. The posterior shut sac.

This diagram points out, that when the abdomen is opened, that at

36. The anterior part of the stomach, one layer of the peritoneum covers it ; at

37. The posterior part of the stomach, three layers are situated ; two layers of the mesocolon, and one layer at the back of the stomach.

38. Three layers, situated at the anterior part of the colon.

39. One layer, at the back part of the colon.

40. Four layers, forming the omentum magnum ; which is divided into the omentum colicum, that part situated on the right side of the abdomen attached alone to the colon, and into the omentum gastrocolicum, that part attached to the stomach and colon.

\* The opening termed the *Foramen of Winslow* is a communication of the cavity of the small epiploon with the cavity of the peritoneum. This opening is rounded and oblong, on the right side of the abdomen. It has on the right the fissure of the vena-portæ, anteriorly the hepatic artery and the biliary ducts, on the left the commencement of the duodenum, and below the posterior parieties of the peritoneum.

- In the female, two cul de sacs are formed, one at  
41. Between the rectum and uterus, and one at  
42. Between the uterus and bladder.

The peritoneum, named from its being stretched or spread around the intestines, is a firm but simple membrane, by which the abdominal viscera are surrounded, and partly supported. Its external surface is rough and cellular, and closely connected with the parts to which it belongs. The internal surface is remarkably smooth, and lubricated by a liquor which is exhaled from its own vessels. It is very elastic, and admits of great extension, as happens in gestation, corpulency, ascites, and hernia; but, upon the causes of extension being removed, it returns to its former dimensions. It lines the diaphragm, and passes downwards, adhering firmly to the abdominal muscles. It also lines and covers the contained parts of the pelvis, from which it is reflected in the back part of the abdomen, lining the muscles there, and, by its reduplications, covers the intestines and great blood-vessels of that cavity. However, the abdominal viscera may be said to lie on the outside of the peritoneum. In its passage from one intestine to another, it forms doublings, which serve as ligaments to fix them to each other, and likewise to the body. It forms a large sac, the posterior part of which adheres firmly to the different viscera, and the anterior to the abdominal muscles, the part lining the abdomen being merely in contact with its contents, and allowing a small degree of motion.

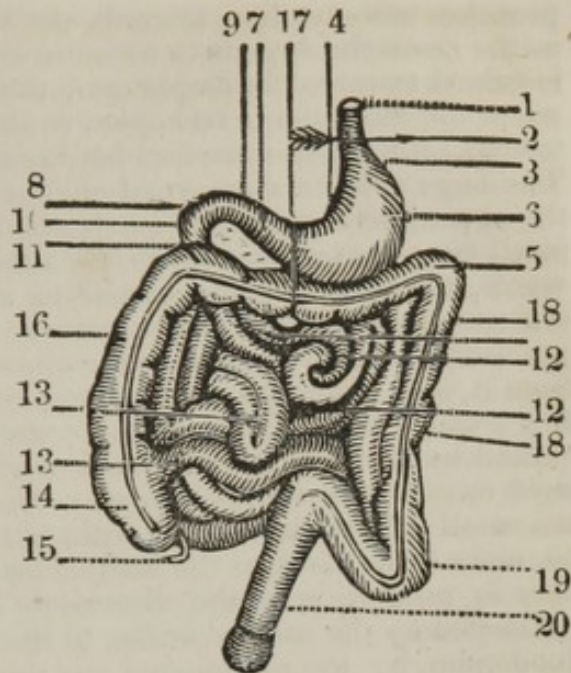
The cellular substance, on the external surface of this membrane, is not everywhere of equal thickness, being in some parts, as upon the intestines, remarkably thin; in others, as over the kidneys, filled with a considerable quantity of fat.

The peritoneum lines and strengthens the cavity of the abdomen; incloses and assists in supporting its different viscera, furnishes most of them with an external coat, connects them to the body, and by its smoothness prevents the effects of friction.

#### 7. 8. The stomach and intestines.

I have added the accompanying diagram, to point out the division of the stomach and intestines, which, speaking of them collectively, have been termed chylopoietic viscera.

1. The œsophagus, perforating
2. The left opening of the diaphragm.
3. The cardiac orifice of the stomach.
4. The small curvature of the stomach.
5. The great curvature of the stomach.
6. The fundus of the stomach.
7. The pyloric orifice.
8. The duodenum, divided into three portions.
9. The ascending.
10. The transverse, and
11. The descending portion.
12. The jejunum, forming three fifths of the small intestines, distinguished from the ilium in being thicker, more vascular, larger, and having more valvulæ conniventes.
13. The ilium, forming less than two fifths of the small intestines, and terminating in the cæcum, having two valves at the entrance.
14. The cæcum, the first of the large intestines; a blind oval gut, situated in the right iliac region, having attached to it
15. The appendix cæci vermiformis. The cæcum terminating in
16. The ascending portion of the colon, which directs its course from the cæcum towards the stomach, connected to the right kidney by a fold of the peritoneum.
17. The arch of the colon, traversing the abdomen beneath the stomach.
18. 18. The descending portion of the colon, directing its course towards the left iliac region, connected to the left kidney by a fold of the peritoneum.
19. The sigmoid flexure of the colon, situated in the left iliac region, and terminating in
20. The rectum.



The stomach is a large bag or reservoir, situated obliquely across the upper and back part of the abdomen, in the left hypochondric and epigastric regions; it is turned downwards and forwards, so as to form an angle with the œsophagus, the angle becoming more conspicuous in proportion as the stomach is more distended. The right part of the stomach is situated under the left part of the liver, the rest of it is placed immediately under the diaphragm; and in the upright position of the body, the stomach rests upon the intestines; the stomach is long, round, and tapering, and has been compared in shape to the bag of a bag-pipe; the size is in proportion to the quantity of aliment it has been accustomed to receive. It has a large and small extremity, an upper and under surface, a great and small curvature, a left and right orifice, and consists of several layers or coats. The large, called also the left extremity, is situated in the left hypochondric region; it is in contact with the spleen; is considerably higher than the small or right extremity, which is placed in the epigastric region, and ap-

proaches more or less towards the right hypochondrium, in proportion as the stomach happens to be more or less distended. The upper surface is turned towards the diaphragm, the under towards the intestines; but when the abdomen is laid open, (unless the stomach be considerably distended,) the superior surface becomes anterior, and the inferior posterior. The large curvature is turned obliquely forwards and backwards towards the abdominal muscles, and extends from one orifice to the other. The small curvature is opposed to the other, and turned backwards and upwards, towards the spine, extending also between the two orifices. The orifices are next the small curvature. The left is termed cardiac, or upper orifice of the stomach. It is opposed to the spine, at a little distance from it, and is formed by the termination of the œsophagus. It allows a free passage for the food into the stomach, the return of which is prevented by the angle formed between the stomach and œsophagus. The right or inferior orifice, commonly termed the pylorus, is situated under the small lobe of the liver, a little to the right side of the spine, is turned more forwards than the cardiac orifice, and is considerably lower, but rises in proportion to the distension of the stomach. The stomach is connected by the cardiac orifice to the œsophagus, by the pylorus to the duodenum, by the peritoneum and blood-vessels to the spleen, and by the omentum minus to the root of the liver.

The structure of the stomach is in general similar to that of the œsophagus, of which it is a kind of expansion. The coats of the stomach are four in number: — the first or external coat, called also peritoneai, is a reflection of that part of the peritoneum which comes from the root of the liver. It strengthens the stomach; by its smoothness it diminishes the effects of friction; and possessing few nerves or blood-vessels, it is not very susceptible of pain or inflammation. The cellular substance under the peritoneal covering is described by some authors as a distinct coat, called *tunica cellulosa ruyschiana*; but should not be numbered among the coats of the stomach. The second or muscular coat is composed chiefly of two planes of fibres variously disposed. The external plane is longitudinal; it extends from the longitudinal fibres of the œsophagus, and follows the same general course with that of the stomach, from the great to the small extremity. Upon each side of the small curvature, the longitudinal fibres form a thick, strong, muscular band. The second plane is chiefly transverse, or circular, and considerably thicker and stronger than the other. The muscular coat assists in the digestion of the food, by giving a gentle motion to the stomach, according to the direction of its fibres: the one set shortening it, the other rendering it narrower. The pylorus is formed by a doubling of the two inner coats, which project into the passage between the stomach and intestines, and contain a fold of muscular fibres, which form a kind of sphincter. The substance, by contracting, prevents the grosser and indigested parts of the aliment from escaping, and, by dilating, allows the pulpy digested part to pass to the intestines. The third coat, commonly called nervous, but properly cellular, consists of a large quantity of fine cellular substance without fat, and is intermixed with, and supported by, small aponeurotic-like filaments, which cross each other obliquely; the filaments being also of a cellular nature. This coat strengthens the stomach, and allows the vessels to be distributed to the inner coat, with which it is intimately connected. The fourth or inner coat, called villous, is continued from the inner coat of the œsophagus, but has much more of the velvet appearance than it. It is formed of fine, short, prominent villi, which are crowded

with small vessels, some for furnishing a mucous liquor to the stomach, others for absorbing a portion of the thinner part of the food. The two last coats are more extensive than the rest, and form, upon the inner part of the stomach, many doublings, termed *rugæ*, the greater number of which run in a waving transverse direction, and are afterwards divided into a sort of net-work. Near the orifices, especially towards the upper one, they run more in a longitudinal direction, and have a radiated appearance. The *rugæ* of the stomach are most distinct when the stomach is empty; when it is full, they are much less evident. They admit of distension without endangering the vessels and nerves dispersed in them, and assist a little in detaining the aliment till properly digested. From the inner surface of the stomach a liquor issues, which is found to approach to the nature of saliva, termed gastric juice; a secretion from the arteries of the stomach, no glands being evident there, in the sound state of the viscus. The stomach receives the food from the œsophagus, and afterwards prepares it, by digestion, for the intestines. The digestion of the food in the stomach is found to be effected by the motions of the stomach and surrounding muscles, by dilution, and by a partial fermentation, but chiefly by the action of the gastric juice serving as a menstruum.

The duodenum begins at the pyloric orifice of the stomach, and makes a short turn upwards and backwards, by the neck of the gall-bladder, to which it is contiguous. It then passes obliquely downwards and to the right side, before the great vessels which go into the liver, and likewise before the renal artery and vein; it being included in the cellular substance of the mesocolon. Opposite to the under part of the kidney, it makes a turn to the left side, where it is lodged in the common root of the mesocolon and mesentery, receiving into its back part the ends of the biliary and pancreatic ducts, and going over the aorta and vena cava, at the upper part of the lumbar vertebræ. In passing across these vessels, it is involved in the root of the mesentery, and ascends a little till it gets to the left side of the spine; then perforating the common root of the mesentery and mesocolon, it makes a turn forwards, and obtains the name of jejunum.

The jejunum, so named from its being commonly more empty than the other intestines, in consequence of the thinner parts of its contents being sooner absorbed, begins at the last turn of the duodenum, and forms numerous convolutions, which run in all directions, and are situated in the upper part of the umbilical region. Like the stomach, it is formed of four coats, the inner of which makes numerous folds, which do not go quite round the gut, termed *valvulæ conniventes*.

The ilium, so named from its numerous turns, begins where the jejunum terminates, and is distinguished externally from that gut, by being smaller, thinner in its coats and paler, and from its forming about three fifths of the length of the two intestines. The ilium forms many convolutions, which are situated on the under part of the umbilical region, and extend as far as the hypogastric and iliac regions. It surrounds the lateral parts of the jejunum, and is supported by the *ossa ilia*; and, the last turn of the gut passing across towards the upper edge of the right *os ilium*, terminates by a valve\* in the left side of the beginning of the colon. Through the whole of this course, the jejunum and ilium are fixed to the spine by a continuation of the mesentery.

\* This ileo-colic valve is called the *valve of Bauhin*.



The structure of the small intestines is nearly similar to that of the stomach, and the number of their coats the same. The external coat, excepting in a portion of the duodenum, is a continuation of that part of the peritoneum which forms the mesentery. It closely surrounds the intestines, adhering to them by fine cellular substance. The second or muscular coat, as in the stomach, is composed of two planes of fibres; of which the external or longitudinal are more minute than the internal. The circular fibres are distinct and numerous: they consist of segments of circles, which unite at different distances, so as to surround the canal. The longitudinal fibres shorten, and the circular contract the intestines; and upon the alternate relaxation and contraction of these fibres depends that vermicular motion called peristaltic, by which the contents are pushed through the canal. The third, commonly called the nervous coat, like that in the stomach, is white and firm, and composed of cellular substance without fat; its firmness giving strength to the intestines. The fourth, or villous coat, differs from that of the stomach, in forming, with the cellular coat, numerous transverse folds, termed *valvulæ conniventes*, from their serving as valves, to retard the motion of the food.

One edge of these valves is fixed to the intestines, the other is loose. They are much deeper than the *rugæ* of the stomach, and placed opposite to the interstices of each other, and are of different lengths, not forming entire circles. The villi of the inner coat are much more conspicuous than in the stomach, being composed not only of the extremities of arteries, veins, and nerves, but particularly of the mouths of lacteal vessels, the origins of which are extremely small. Numerous ducts of simple and compound glands terminate on this coat, for the secretion of mucus. The former are called solitary, and the latter congregate; and, from their describers, *glandulæ Peyeri*, and *glandulæ Brunneri*. They are in the form of papillæ, but so minute as seldom to be seen, excepting in the diseased state;—though they are supposed to be dispersed over the whole of the canal.

The duodenum is the most lax, and the straightest of the small intestines, and so large as to have been considered as a secondary stomach. It is of a redder color than the rest, has a thicker muscular coat, receives only a partial covering from the peritoneum, and is fixed more closely to the body, without floating like the other intestines. It is perforated at the distance of three or four fingers-breadth from the pylorus, by the ends of the biliary and pancreatic ducts, for the reception of bile and pancreatic juice. On the duodenum, the lacteal vessels begin to make their appearance, and numerous mucous glands are found in it, especially near the pylorus. The duodenum receives the food from the stomach, and detains it until mixed with the bile and pancreatic juice.

The jejunum differs from the duodenum in deriving its common coat wholly from the peritoneum,—in being smaller—in having a weaker muscular coat, the external fibres of which are extremely minute,—in the *valvulæ conniventes*, villi, and lacteals, which proceed from them, being much more conspicuous and numerous.

The ilium differs from the former in being less in diameter, and its coats thinner and of a pale color, and in having fewer and smaller lacteal vessels. In this intestine the *valvulæ conniventes* gradually decrease in size and number, and at length entirely disappear.—At its under end, the mucous glands are distinct and frequent. The small intestines in general promote the formation of the chyle, allow it to be

absorbed, and propel the remains of the food into the large intestines.

The great intestines, like the small, form one continued canal, which tapers from its upper to near its under extremity; but they differ from them in being considerably wider, shorter, and straighter, in being irregular in their outer surface, and tacked up into cells, and in having many processes pending from them, termed *appendiculæ epiploicæ*. Like the small intestines, also, they are divided into three parts, termed *cæcum*, *colon*, and *rectum*.

The *intestinum cæcum* forms a round short bag, only about three or four fingers-breadth in length, and nearly the same in diameter. The *cæcum*, properly so called, is that part of the intestine which lies upon the right *iliacus internus*, though frequently the dilated beginning of the *colon* is distinguished by the same name. It rests on the cavity of the *os ilium*, at the under end of the right kidney, and is concealed by the last convolutions of the *ilium*. The bottom of it is turned downwards, and forms a shut sac, the mouth of which is directed towards the *colon*, and may be considered as forming the *cæcum caput coli*. At the posterior and left side of the *cæcum* there is a small process, about the same length with the *cæcum* itself, but the diameter not larger than that of a goose-quill, — termed *appendix cæci vermiformis*, from its resemblance to an earth-worm. It is convoluted, and fixed by its sides to the *cæcum*. It has two extremities, one of which is impervious, the other opens obliquely into the back part of the *cæcum*.

The *colon* is the largest of the great intestines; it encircles the smaller ones, and is contiguous to most of the abdominal viscera; it is a continuation of the *cæcum*, which ascends in the right lumbar region, over the kidney of that side, to which it is connected. From the kidney it passes forwards, and crosses the abdomen in the epigastric and hypochondric regions connected to the stomach, under the name of the great arch of the *colon*. The right portion of the great arch is situated under the liver and gall-bladder; the latter commonly tinges part of it and the duodenum with bile. The left portion of the arch is situated under the stomach; and immediately below the arch are the convolutions of the jejunum. In the left hypochondrium, it turns backwards under the spleen, and descends in the left lumbar region, on the fore side of the kidney, to which also it is closely connected. In the left iliac region it forms two convolutions, compared in shape to the Greek letter *s*, and hence called the sigmoid flexure of the *colon*, which afterwards constitutes the *rectum*. The sigmoid flexure varies considerably in length in different persons, extending frequently into the hypogastric region, and in some instances as far as the *intestinum cæcum*. The *colon*, through its whole extent, is fixed to the body by means of the *mesocolon*.

The *rectum* begins at the last lumbar vertebra, descends upon the fore side of the *sacrum* and *os coccygis*, and terminates in the anus, a little beyond the extremity of the last-named bone. In its course, it follows the direction of the bones over which it passes; turning first downwards, then a little backwards, then forwards, and is fixed to them by the *mesorectum*. The *rectum* differs from the other intestines, in becoming wider in its progress downwards, and forming below a reservoir for the *fæces*. At the anus it contracts into a narrow orifice, the sides of which are disposed in close longitudinal folds. Upon the outer surface of the great intestines, but more especially upon the *colon*, are the *appendiculæ epiploicæ*, situated at different distances

from each other; thin at their roots, becoming thicker in their bodies, and projecting from the intestines, like so many pendulous papillæ. They are covered by the peritoneum, and are of the same structure and use with the omentum. Besides the appendiculæ, there are, on both sides of the adhesions of the mesocolon, adipose strata, which are of the same nature with the others. The colon is divided longitudinally into three parts, by as many ligamentous-like bands, which run upon its surface. One of them goes along each side of the colon, and that most exposed to view, when the omentum is turned up, is the largest. The third, which is the smallest, is concealed by the attachment of the mesocolon. They begin at the root of the appendix vermiformis, and, after running along the cæcum and colon, they gradually unite, form two, and then terminate on the rectum.

The great have the same number of coats with the small intestines, but differ from them in being thicker and stronger. The valvulæ conniventes are deep, and placed opposite to each other, forming cells. The villous appearance is much less distinct. The mucous glands are larger, but simpler than those of the small intestines.

The liver is a large solid mass, of a dusky red color, situated immediately under the diaphragm, extending downwards to the margin of the thorax. It is placed partly in the right hypochondrium, which it in a great measure fills, and partly in the epigastrium, reaching over a little way into the left hypochondrium. It is convex, and very smooth on the upper surface, where it is opposed to the diaphragm, though a little flattened on the upper part of its left side, where it is placed opposite to the heart. It is irregularly concave on the under side, where it rests upon the stomach and intestines, and is perforated by several large blood vessels. It is thick on its right and posterior part, and becomes gradually thinner towards the left side; is obtuse or blunt on its posterior, and acute or sharp on its anterior edge, and considerably broader from one side to the other, than from before backwards. It is divided into prominences or lobes, two of which, called great and small, or right and left lobes, are so considerable as to form the body and whole upper part of the liver. The other lobes, which are very inferior in size, are placed upon the under side of the former. The great lobe is situated obliquely in the right hypochondric region, following the curve of the diaphragm, and rests upon the pylorus, colon, and top of the right kidney. The small lobe, distinguished from the great one by a broad ligament, is placed almost horizontally, chiefly in the epigastric, only a small portion of it lying in the left hypochondric region. The other lobes are the lobulus Spigelii, which is small when compared with the two former lobes, but is the principal one below; is situated near the spine, upon the left side of the great lobe, and is of a pyramidal form, projecting like a nipple, at the small curvature of the stomach. The lobulus caudatus is merely the root, or one of the angles of the lobulus Spigelii, advancing towards the middle of the lower side of the great lobe. The lobulus anonymus, or quadratus, is placed between the passage of the round ligament and the gall-bladder, and is less prominent but broader than the former lobule. From the lobulus quadratus a bridge runs across the passage, for the round ligament to be joined to the left lobe.

Upon the under side of the liver there are several fissures. The great fissure, called fossa umbilicalis, between the right and left lobes, at the under and fore part of the liver. This is terminated by a notch at the fore part of the liver; and behind, it is commonly covered by

the pons. The principal fissure, termed *sulcus transversus*, or *sinus portarum*, extending from right to left, between the great and small lobes, and bounded by these lobes at its extremities, and by the lobulus anonymous before, and the lobulus Spigelii behind; the two latter forming parts compared by the ancients to a gate, and therefore called *porta*. The depression between the great lobe and lobulus Spigelii, for the passage of the inferior vena cava, which has frequently a bridge over it, forming it into a canal. A small depression, called *fossa ductus venosi*, between the left lobe and lobulus Spigelii, running a little obliquely from right to left side, and receiving a ligament, formerly a branch of the umbilical vein in the fœtus.

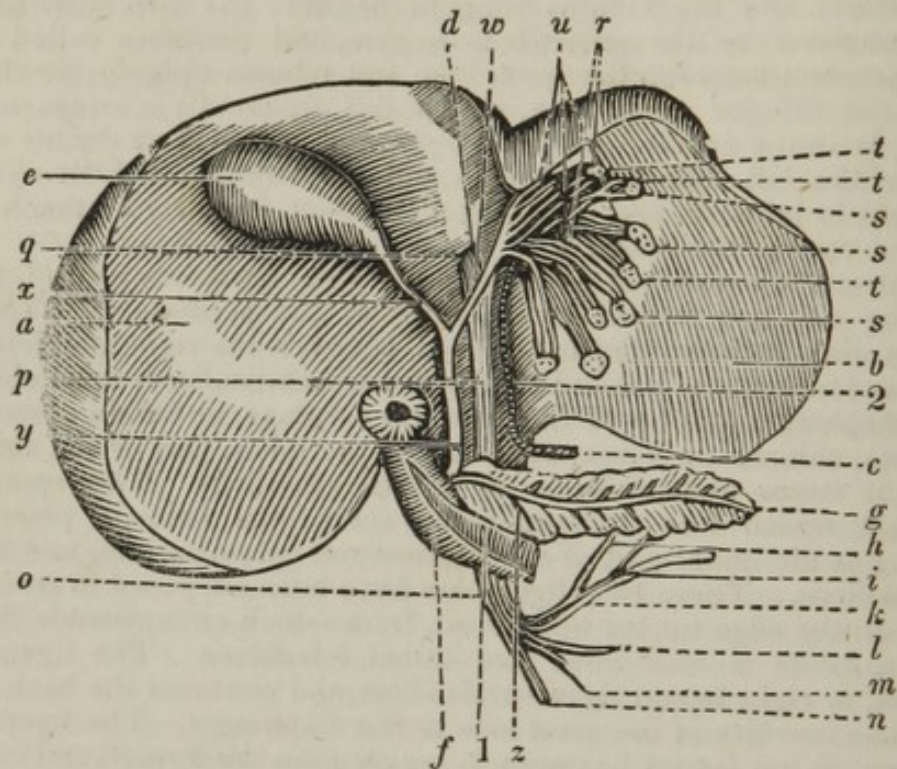
The liver is connected to the body by its ligaments; all of which, excepting one, are formed by doublings of the peritoneum. The *ligamentum suspensorium hepatis*, placed between the right and left lobes above, and extending below into the *fossa umbilicalis*, is fixed obliquely to the diaphragm and tip of the ensiform cartilage, and then descends in the same oblique direction, adhering to the inner part of the sheath of the right rectus abdominis, as far as the umbilicus. The *ligamentum rotundum*, which was the umbilical vein in the fœtus, is placed in a doubling at the under part of the *ligamentum suspensorium*, and fixed to the umbilicus. These two ligaments have been supposed to resemble a falx, with the edge turned uppermost, from which circumstance the *ligamentum latum* is sometimes also called *falciforme*. The *ligamentum dextrum*, or right lateral ligament, is short, and connects the back part of the right extremity of the great lobe to the diaphragm. The *ligamentum sinistrum*, or left lateral ligament, is longer than the former, and connects the left extremity of the small lobe to the diaphragm. The *ligamentum coronarium*, considered by some as merely cellular substance, and by others as a reflection of the peritoneum, unites the root of the liver to the tendinous portion of the diaphragm. The ligaments of the liver preserve it in its proper situation, and of course prevent it from inclining too much in any direction. The stomach and intestines support it when the body is upright, and the diaphragm when the body is inverted.

The liver has a simple coat adhering closely to it, which it derives from the peritoneum, and is everywhere covered by this membrane, excepting behind, where it adheres to the diaphragm by cellular substance. The substance of the liver is composed of several kinds of vessels, the extreme branches of which are intermixed in such a manner, as to form numberless corpuscles, named *acini*, which, when minutely examined, are observed to be composed of vessels in the form of radiated villi.

The vessels of the liver are the hepatic artery, *vena porta*, *venæ hepaticæ*, absorbents, and biliary ducts. It has likewise numerous nerves.

The vessels and nerves are intermixed with much cellular substance, and covered externally by a reflection of the peritoneum, which has obtained the name of capsule of Glisson. The artery is situated on the left side of the capsule; the biliary ducts, on the right; and the *vena porta*, behind and between the two. The branches of vessels and nerves accompany each other through the substance of the liver, forming small fasciculi. In their course through the liver, the branches of the different vessels and nerves, but particularly those of the *vena porta*, are inclosed in a portion of cellular substance.

The accompanying diagram is introduced for the purpose of illustrating and pointing out the secretion of the bile.



- a. The right lobe of the liver.
  - b. The left lobe.
  - c. The lobulus Spigelii.
  - d. The porta of the liver.
  - e. The gall-bladder.
  - f. The duodenum cut open.
  - g. The pancreas.
- The veins forming the vena porta are
- h. The stomachic vein.
  - i. The pancreatic.
  - k. The splenic.
  - l. The superior mesenteric.
  - m. The inferior mesenteric, receiving
  - n. The hemorrhoidal veins.
  - o. The several veins uniting, and forming an arch opposed to that of the aorta.
  - p. The vena porta, ascending in the capsule of Glisson, behind and between the hepatic artery and biliary ducts.
  - q. The vein entering the porta of the liver, ramifying over the structure of the liver, forming
  - r. The vena porta hepaticæ, and terminating by conveying the blood into
  - s. The acini of the liver. The bile is there separated from the blood by
  - t. The pori biliarii, and conveyed into
  - u. The hepatic ducts, which unite to form
  - w. The hepatic duct, which conveys the bile out of the porta of the liver; and receives

x. The cystic duct ; the two ducts together forming  
 y. The ductus communis cholidocus, which is situated on the left side of the capsule of Glisson. This duct receives the ductus pancreaticus, and

1. Terminates at the middle portion of the duodenum.
2. The hepatic artery, placed on the left side of the capsule of Glisson.

The gall-bladder is a small, oblong, pyriform bag, consisting of a fundus, body, and cervix, situated upon the concave side of the great lobe of the liver, and placed in a transverse direction from behind forwards. It extends from the sinus portarum, where the cervix is situated, to the anterior edge of the liver, and, when full, advances beyond the edge of the liver, so as sometimes to have its fundus opposed to the soft parts of the abdomen, under the edge of the false ribs. The fundus is a little lower than the cervix, when the person is in an erect posture. It then also inclines a little to the right side, and rests upon the colon at the beginning of the duodenum. It is composed of several coats, the external of which is a continuation of the membrane of the liver. This, however, is only a partial coat, covering that part of the gall-bladder which projects beyond the surface of the liver. It serves to give strength to the gall-bladder, and to fix it to the liver.

Under the former coat, a few pale scattered fibres, running in various directions, are sometimes observed, which have been considered as a muscular coat ; and under this there is some cellular substance, which has obtained the name of nervous coat. The inner coat, sometimes called villous, is full of reticular rugæ or folds, which become extremely minute towards the cervix, where they run in a longitudinal direction. The surface of this coat is everywhere perforated by the ducts of small follicles, which discharge a viscid mucus, to defend the surface of the inner coat from the stimulant nature of the bile. The gall-bladder is connected through its whole length to the liver by cellular substance, blood-vessels, and absorbents. The cervix, or neck of the gall-bladder, is twisted and folded against itself, and afterwards contracts and sends out a duct called cysticus, which runs near the ductus hepaticus, and then joins it, to form the ductus communis cholidochus.

The veins which return the blood from the chylopoietic and assistant chylopoietic viscera, accompany their respective arteries, the hepatic veins excepted. They have frequent communications with each other, are larger, and are destitute of valves. These veins unite and form one large trunk, termed the vena porta, or vena portarum. The principal branches forming this vein are the gastric, the splenic, pancreatic, superior mesenteric, and inferior mesenteric, which receive the hemorrhoidal veins ; these veins form the commencement of the vena porta, running under the head of the pancreas to enter the capsula Glissonii ; the veins forming the vena porta, are termed the vena porta ventralis. The vena porta then passes at the posterior part of the capsule of Glisson, behind, and rather between the hepatic artery and biliary duct, to enter the porta of the liver, where it divides into numerous branches, which are termed vena porta hepaticæ.

The biliary ducts arise by extremely minute branches, termed pori biliarii, or tubuli biliferi, chiefly from the extremities of the vena porta,

in the substance of the corpuscles, through the whole of the liver. The *pori biliarii* run in company with the branches of the artery and veins, and unite into larger and larger branches, which afterwards go into two, and these again into a single trunk in the *sinus portarum*, called *ductus hepaticus*. The *ductus hepaticus* serves to carry the gall or bile, which is of a yellow green color, from the liver, and to convey it, by the power of the heart, hepatic artery, and *vena porta*, assisted by the pressure of the surrounding muscles, to the duodenum, and partly to the gall-bladder.

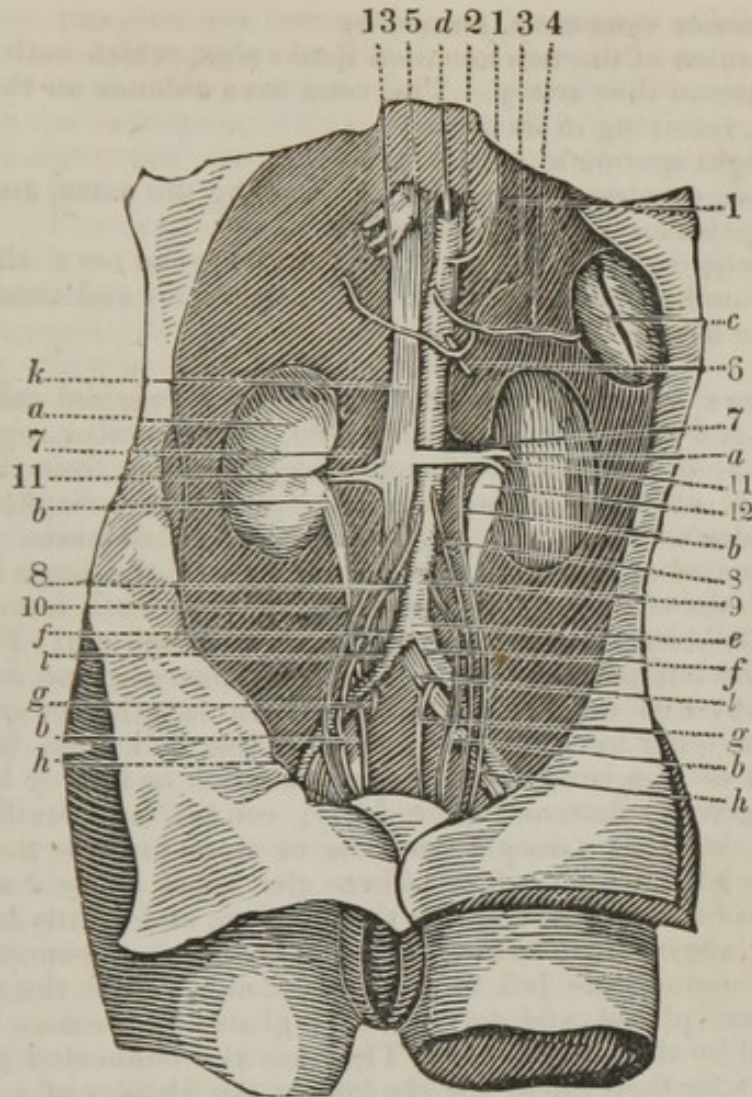
The *ductus cysticus* is smaller than the *ductus hepaticus*, and differs from it also in having a number of imperfect partitions or *plicæ*,\* running in a somewhat spiral direction, and forming it into cells which retard the flow of the bile. The gall-bladder serves as a receptacle for the bile, when the stomach and intestines are empty and have no need of it, and retains it till wanted for the purpose of digestion. It is afterwards discharged from the gall-bladder, when the stomach is full, into the *ductus communis*, and from that to the duodenum, chiefly by the pressure of the surrounding viscera. The whole of the bile contained in the gall-bladder is found, by experiment, to pass from the liver through the hepatic duct to the *ductus communis*, and from that by the cystic duct into the gall-bladder. The bile returning from the gall-bladder is observed, from the thinner parts being absorbed, to be thicker, more acrid and bitter, and of a deeper color, than that which flows from the liver.

The *ductus communis cholidochus* is about the size of a goose-quill, and is considerably larger than either of the ducts which open into it. It descends at the posterior and left side of the duodenum, and passes for some way obliquely between the muscular and inner coats of the gut, — the obliquity answering the purpose of a valve. It terminates in the left, posterior, and nearly in the under part of the second turn of the intestine, by a projecting orifice, which is rounded above, and pointed below. The structure of the *ductus cholidochus*, and of the biliary ducts, is of the same nature, being entirely membranous. The inner surface of the ducts is perforated by numberless pores, which are the mouths of mucous follicles, similar to those upon the inside of the gall-bladder.

The bile serves to mix the different parts of the food properly together, for the formation of the chyle, — to correct too great a disposition to acidity, and to excite the peristaltic motion of the intestines.

The dissector may now remove the intestines and liver, when the parts seen in the following plate may be carefully dissected.

\* The spiral valves of the cystic duct may be shown by inflating the gall-bladder with air, and when dried, making a section of the duct in the direction of its length.



- a. a.* The kidneys.  
*b. b.* The ureters, seen crossing the iliac vessels, and being crossed by the spermatic vessels.  
*c.* The spleen.  
*d.* The aorta, having passed through the diaphragm, becomes the abdominal aorta, and descends upon the left side of the spine, and at *e.* Opposite the fourth lumbar vertebra, bifurcates into  
*f. f.* The two common iliac arteries; at the bifurcating sending off the middle sacral artery. The aorta in its course sends off  
 1. The inferior phrenic artery.  
 2. The cœliac artery, forming an axis from which three branches arise.  
 3. The coronaria ventriculi.  
 4. The splenic artery.  
 5. The hepatic artery.  
 6. The superior mesenteric artery.  
 7. 7. The two emulgent arteries; the right running under the vena cava.  
 8. 8. The two spermatic arteries.  
 9. The inferior mesenteric artery, arising midway between the emulgent arteries and the bifurcation of the aorta into the common iliac arteries.



*k.* The inferior vena cava, formed by

*l. l.* The union of the two common iliac veins, which both pass under the right common iliac artery. The vena cava ascends on the right side of the spine, receiving in its course

10. The right spermatic vein.

11. The two emulgent veins, the left crossing the aorta, and receiving

12. The spermatic vein on the left side.

13. The vena cava hepatica. The inferior vena cava also receives four pair of lumbar veins, perforates the diaphragm, and enters the right auricle of the heart.

The kidneys are two glandular bodies, of a pale red color, situated in the upper and back part of the abdomen, in the lumbar region. They are placed one on each side of the spine, extending from the eleventh pair of ribs to near the ilium, each resting upon the diaphragm, *psoas magnus*, *quadratus lumborum*, and *transversalis abdominis*. The right kidney is situated at the under and back part of the large lobe of the liver, behind the colon, and is commonly a very little lower than the left. The left kidney is placed at the under and back part of the spleen, and behind the left portions of the stomach, pancreas, and colon. The kidney is about five or six fingers-breadth in length, but considerably less from the outer to the inner side, and less still from before backwards; or, it is compared in shape to a French or kidney bean. It is rounded anteriorly, flattened posteriorly, convex and uniform at its outer margin, and has a deep depression or sinus towards the vertebræ, surrounded with unequal edges, where the renal vessels and nerves enter. It is a little broader behind than before, and a little broader and more curved above than below. The right kidney is connected to the liver and duodenum, the left to the spleen, and both to the muscles on which they are placed, and to the renal glands and colon, by cellular substance and by the peritoneum. They are also connected to the aorta and vena cava by their blood vessels, and to the bladder of urine by the ureters. They accompany the motions of the liver and spleen, in the different states of respiration. Each kidney is surrounded by loose cellular substance, which commonly contains a considerable quantity of fat, from which it is termed *tunica adiposa*.

The *tunica adiposa* covers not only the kidney, but the large vessels, and defends them from the pressure of the surrounding viscera. Under the *tunica adiposa*, there is a membrane composed of the original proper coat and cellular substance incorporated, which adheres closely to the kidney, and is reflected over the edges of the sinus, to be joined to the pelvis and large vessels. The substance of the kidney is commonly smooth and uniform, though sometimes it is irregular, in consequence of the lobes which originally form it not being completely incorporated. It consists of an outer part called cortical, and an inner termed medullary.

The cortical substance surrounds the kidney, and forms about a third of its breadth. It likewise sends in partitions, which separate the medullary parts from each other.

The medullary, termed also uriniferous substance, is of a redder color than the former, and is divided into a number of distinct columns, each of which terminates in a projection called *papilla*, or *processus mammillaris*. The *papillæ* are merely the continuation of the uriniferous part, though frequently considered as a third division of the substance of the kidney.

Each kidney has one, and sometimes more arteries, which run transversely from the aorta, and a vein still larger than the artery, which terminates in the cava. They enter at the sinus of the kidney, and are included in cellular substance, which accompanies them throughout their course. The right renal artery is longer than the left, in consequence of the vena cava, behind which it passes, being placed upon the right side of the aorta. The artery, as it approaches the kidney, is divided into branches, which are afterwards minutely distributed through the cortical substance, forming arches and anastomoses; but these are found to be much less frequent than are commonly described. The small branches, after turning and winding in various directions, pass partly towards the surface of the kidney, where they form irregular stars, some of which supply the proper membrane. Others turn inwards in a waving direction, and form corpuscles, disposed somewhat after the manner of clusters of small berries, which can only be seen distinctly by the assistance of glasses, after a minute inspection. The veins running from the extremities of the arteries unite in the cortical substance of the kidney. The branches of the renal vein are much larger than those of the artery, but correspond with them in their course. They form a large trunk on each side, which lies anterior to the corresponding artery, and runs transversely to the cava; the left, which is the longer of the two, passing across the fore part of the aorta. From the minute extremities of the renal artery, in the corpuscles seated in the cortical substance, the uriniferous tubes arise. They are mixed with some extremely small blood-vessels, and constitute the medullary substance of the kidney. By degrees they unite into larger tubes, which run in a radiated manner, the direction being from the outer edge or circumference, towards the inner part or cavity of the kidney. The radiated tubes, becoming still larger in their passage, terminate in the papillæ, which are of a compressed conical form, and at a little distance from each other. The papillæ are twelve or more in each kidney, the number varying according to that of the original lobes of which the kidney is composed, and likewise from some of the papillæ being incorporated with each other. Upon the points of the papillæ are the terminations of the uriniferous tubes, large enough to be distinguished by the naked eye, through which the urine distils from the substance of the kidney. Round the root of each papilla, a membranous tube arises, termed infundibulum or calix, which receives the urine from the papillæ. They are commonly the same in number with the papillæ; the number, however, varying in different subjects, two or more of the papillæ sometimes opening into the same infundibulum. They join into two or three larger trunks, which afterwards form a dilatation of considerable size, of the shape of an inverted cone, which is termed the pelvis of the kidney.

The pelvis is placed partly within, but the greater part of it without, the body of the kidney, and contracts into a long tube, about the size of a writing-pen, called the ureter; it descends, crossing the iliac vessels, and terminates by entering the coats of the bladder obliquely, at its posterior, inferior, and lateral parts.\*

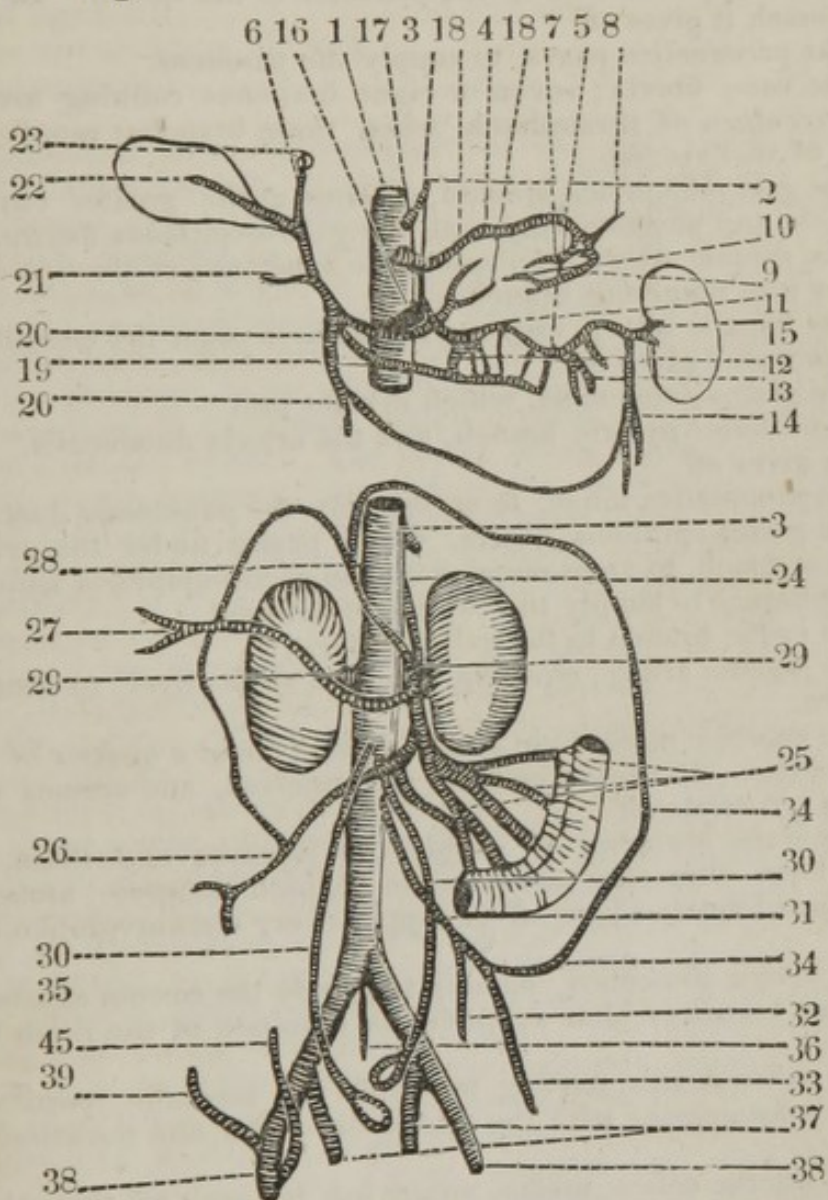
\*The *renal capsules* are bodies of a somewhat triangular form, and of a glandular appearance, which are situated directly above the kidneys, to which they are united by cellular membrane. Their use is unknown. They are large in the foetal state. Meckel thinks, that like the liver, the spleen, the thyroid, and thymus glands, they contribute directly to the perfection of the blood. Their arteries are derived from the abdominal aorta.

The spleen is a soft and very vascular substance, and of a purple color. It is somewhat depressed, is of a long oval form, and of a considerable size, but varying in this respect in different subjects. It is situated in the left hypochondric region, between the large extremity of the stomach and corresponding false ribs; — its under end lying behind the colon, and over the top of the left kidney. The situation of the spleen varies a little, according to the state of respiration, and to the fullness or emptiness of the stomach; rising or falling as the lungs are more or less dilated, and becoming more oblique in its situation, — with its inferior extremity turned more forwards, — in proportion as the stomach becomes more distended. Its external surface is convex and uniform, like that of the ribs, to which it is opposed. Its internal surface, or that next the spine, is irregularly concave; and it is divided into an anterior and a posterior plane, by a longitudinal groove or fissure, where the vessels and nerves enter. The anterior plane is more concave than the posterior, corresponding to the contiguous convexity of the stomach. The spleen has frequently deep fissures upon its edges; — sometimes it has small appendages attached to it, and not unfrequently there is one or more small spleens connected with it. At the inner side, it is fixed to the omentum, and, by means of that and blood-vessels, to the stomach and pancreas. Behind, it is connected to the diaphragm; and below to the left kidney and colon, by reflections of the peritoneum, and by cellular substance. It is covered by a double membrane, one layer of which is a production of the peritoneum, the other proper to the spleen itself, but so closely connected to the common coat, that they appear to be one and the same membrane. The substance of the spleen is remarkably soft, and it is by much the most tender of the abdominal viscera. It consists of a congeries of blood-vessels, lymphatics, and nerves, joined together and supported by a large quantity of cellular substance. The extreme branches of the blood-vessels put on the appearance of penicilli, which have been mistaken for glands. These vessels are so tender, that when an injection is forcibly thrown into either artery or vein, particularly the latter, it bursts into the common cellular substance, and gives the appearance of follicles or cells. The blood-vessels of the spleen are among the largest of the body, in proportion to the size of the viscus on which they are dispersed. No excretory duct has been found to proceed from the spleen, in consequence of which very various opinions have been entertained with respect to the use of this organ. Many of the ancients were of opinion, — that, besides the bile of the liver, there was an *atra bilis*, or black bile, and that the spleen was the receptacle of it. Others have thought a particular menstruum was secreted in it, and conveyed to the stomach for the purpose of digestion. Others again, that the blood of the spleen promotes the sluggish circulation of the blood of the *vena porta*. It has been also supposed, — that as the stomach becomes full, the spleen is compressed by it, in consequence of which a greater quantity of blood is sent to the pancreas, for the secretion of the pancreatic juice. But the present opinion is, — that the blood undergoes some change in it, which renders it useful in the secretion of the bile; and this opinion derives support from the great quantity of blood with which this organ is known to be supplied, and from its vein passing to the *vena porta*.

I have added the following diagram, to point out the branches which take their origin from the descending aorta.

It was necessary to make a division in the diagram, to prevent the numerous branches becoming complicated.

The thoracic aorta, in the posterior mediastinum, sends off ten pair of intercostal arteries, œsophageal branches to the œsophagus, and bronchial branches to supply the structure of the lungs.



1. The abdominal aorta, immediately after having passed between the crura of the diaphragm, sends off
  2. The inferior phrenic artery. Occasionally, this vessel arises from the cœliac, and sometimes there are two trunks arising from the aorta.
  3. The cœlic artery, arising from the left side of the aorta; it forms an axis, which gives off three branches.
  4. The coronaria ventriculi.
  5. The splenic artery.
  6. The hepatic artery.
- The coronaria ventriculi passes forwards to the cardiac orifice of the stomach, where it divides into

7. The posterior coronary, which supplies the posterior surface of the stomach, sending off

8. The cardiac branch, to supply the cardiac orifice.

9. The anterior coronary, supplying the anterior part of the stomach. This branch sends off

10. A branch to supply the pyloric orifice.

11. The splenic artery, which runs in a tortuous direction between the stomach and upper surface of the pancreas to the spleen. In the course of this vessel, it gives off

12. The pancreatica parva, to supply the pancreas.

13. The vasæ brevia; seven or eight branches running towards the greater curvature of the stomach, when these branches ramify to supply the coats of this viscus.

14. The gastro-epiploica sinistra, passing at the greater curvature of the stomach, and anastomosing with the gastro-epiploica dextra.

15. The splenic artery then enters the substance of the spleen, where it ramifies into numerous branches.

16. The hepatic artery, crossing the aorta to enter the capsule of Glisson. This vessel gives off

17. The gastro-duodenalis, which divides into

18. The inferior pyloric branch, and the arteria duodenalis. The hepatic then gives off

19. The pancreatica longa, to accompany the pancreatic duct.

20. The gastro-epiploica dextra, which passes under the pyloric orifice of the stomach, to anastomose with the gastro-epiploica sinistra.

21. The branch to supply the capsule of Glisson.

22. The cystic branch to the gall-bladder.

23. The hepatic artery, entering the porta of the liver, to ramify over its structure.

24. The superior mesenteric artery, arising about a quarter of an inch from the cœliac. It passes beneath the pancreas, and crosses over the duodenum; it sends off

25. Numerous branches to supply the jejunum and ilium. These branches form numerous anastomoses, which compose arches, from which various branches pass off to supply every circumvolution of these intestines.

26. The arteria ilio-colica, passing to supply the cæcum anastomosing with the last branch, which supplies the entrance of the ilium into the cæcum.

27. The colica dextra, passing to supply the ascending portion of the colon, and anastomosing with the arteria ilio-colica, and the arteria colica media.

28. The arteria colica media, supplying the arch of the colon, and anastomosing with the colica sinistra, sent off from the inferior mesenteric artery.

29. The emulgent arteries, arising at right angles from the aorta; the right passes beneath the vena cava.

30. The spermatic arteries, passing to the testes in the male, and the ovaria in the female.

31. The inferior mesenteric artery, arising midway between the emulgent and the bifurcation of the aorta into the two common iliacs; this vessel sends off

32. The middle hemorrhoidal artery, to supply the rectum.

33. The artery to the sigmoid flexure of the colon, and

34. The arteria colica sinistra, to supply the descending portion of the colon.
35. The aorta, bifurcating into the two common iliacs, and at the bifurcation sending off
36. The middle sacral artery. The common iliacs bifurcate into
37. The internal iliacs, and
38. The external iliac, which directs its course towards the centre of Poupart's ligament, but sends off two branches before it passes beneath that ligament.
39. The circumflexus illi, and
40. The epigastric.

The abdominal aorta descends on the fore part of the spine, till it reaches the fourth lumbar vertebra, where it bifurcates into two primitive or common iliacs, sending off at the bifurcation the middle sacral artery, which descends on the anterior part of the sacrum, and twigs enter the foramina of this bone to supply the inferior part of the spine. The aorta in its course sends off the following branches:—The inferior phrenic; sometimes two branches are sent off before it has fairly entered the abdomen, to be distributed over the diaphragm; they sometimes are sent off in one trunk, which divides, and sometimes arise in one trunk from the cœliac. The cœliac artery is given off from the left side of the aorta, between the crura of the diaphragm; it is a single, large, but short trunk, and is situated between the inferior surface of the liver, and the lesser curvature of the stomach, surrounded by the semilunar ganglion; it divides into three branches, dispersing into different directions from one point; before this division it is termed the axis arteriæ cœliacæ; the three branches are the gastric, the splenic, and the hepatic. The gastric artery sends off the anterior and posterior coronaries to the stomach, which give off the branches supplying the cardiac and pyloric orifices. The splenic artery, leaving the trunk of the cœliac, goes directly to the left side, under the stomach, and upon the upper part of the pancreas, running in a serpentine direction, enters the left side of the spleen in several branches, previous to which it sends off the short pancreatic twigs, where it passes along the upper part of that viscus; the vasæ brevia, seven or eight branches, about two or three inches in length, to the greater curvature of the stomach; the gastro-epiploica sinistra, passing along the great curvature of the stomach, anastomosing with the gastro-epiploica dextra. The hepatic artery runs in a direction opposite to the splenic, to the right side, sending off the pyloric branch to the pyloric orifice of the stomach, ending in its lesser curvature; the long pancreatic to the pancreas; the duodenalis to the duodenum; the gastro-epiploica dextra, anastomosing with the gastro-epiploica sinistra, running at the greater curvature of the stomach. The hepatic then sends a branch to the gall-bladder, a branch to the capsule of Glisson, and then divides into the right and left hepatic; the right supplying the right lobe of the liver; the left the left lobe, and the lobulus Spigelii, and a portion of the right lobe.

The superior mesenteric artery is a single branch; leaving the aorta about half an inch lower than the cœliac, it passes under the mesocolon, crosses the duodenum, then enters the fold of the peritoneum, forming the mesentery; gradually incurvating from the left to the right side, it supplies the small intestines, (the jejunum and ilium,) and then sends off the ilio-colica, which runs down to the last turn of the ilium and

the caput coli ; its branches inosculating with the branches supplying the small intestines, given off before this branch ; the ilio-colica anastomoses with the next branch.

The colica dextra, which passes to the right side of the colon, where that intestine arises over the right kidney, supplies the ascending portion of the colon, and anastomoses with the last branch of the superior mesenteric. The colica media is then sent off, supplying the arch of the colon, and anastomosing on the right side with the colica dextra and on the left with the colica sinistra, which is a branch of the inferior mesenteric artery.

The aorta sends off next the emulgent, or renal arteries, two in number ; arising one on each side, a little below the superior mesenteric, they proceed transversely to the kidneys. The right renal artery passes behind the vena cava, and is larger than the left. At the concave edge of the kidney, the artery divides into three or four branches, which sometimes send twigs to the glandula renalis and tunica adiposa of the kidney. The renal branches then plunge into the substance of the kidney, surround its pelvis, and afterwards ramify chiefly in its cortical substance, forming arches with each other, at the roots of the papillæ.

The spermatic artery, the diameter of which is small when compared with its great length, arises opposite to its fellow, from the fore part of the aorta, a little below the renal arteries. It descends in a waving direction on the surface of the psoas, behind the peritoneum, the right passing obliquely over the cava, and both before the ureters, to the under part of the abdomen. After this, it perforates the ring of the obliquus externus, and runs in the spermatic cord, where it divides into branches which are dispersed, some upon the epididymis, while others run across the surface of the testicle, plunge into its substance, and are distributed upon the seminal ducts. These arteries in the female have the same kind of origin, and the same course through the abdomen, as in the male, but are frequently more tortuous ; and, in place of perforating the abdominal ring, as they do in the latter, they descend into the pelvis, each artery passing between the lamina of the ligamentum latum, to be dispersed first upon the ovarium and uterine tube, and then upon the body of the uterus itself, and communicating with the artery of the opposite side.

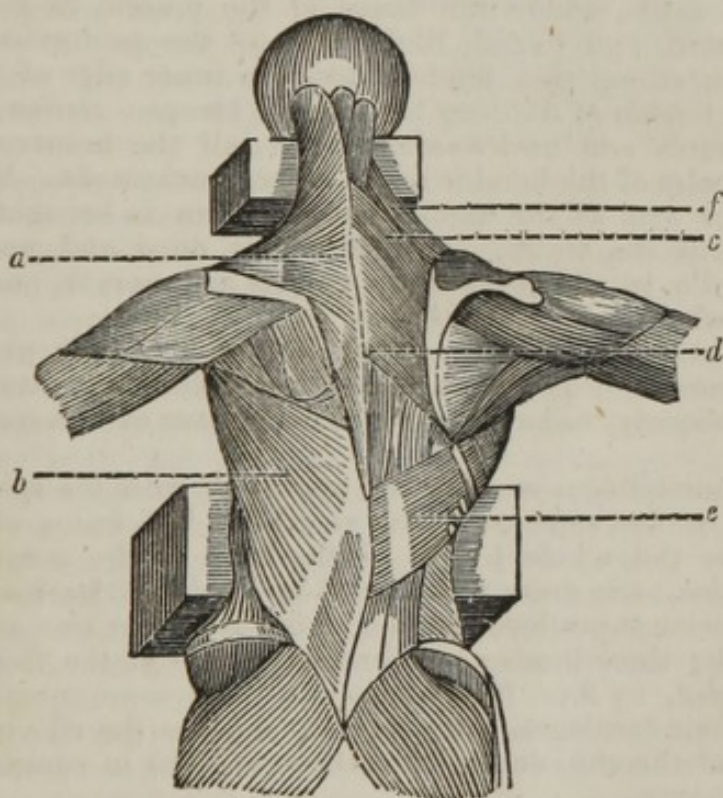
The aorta then sends off the inferior mesenteric artery, which arises somewhat lower than half way between the superior mesenteric and the bifurcation of the aorta. It descends upon the left psoas muscle, and soon divides into the colica sinistra, which rises in the mesocolon, and anastomoses with the colica media, given off from the superior mesenteric artery, and also with the branch sent off to supply the sigmoid flexure of the colon.

The hemorrhoidalis interna is of great size, being the continued trunk of the inferior mesenteric. It anastomoses with the colica sinistra, and afterwards descends upon the back part of the rectum to its under extremity.

The abdominal aorta, besides the above branches, sends off five on each side, termed lumbar, to supply the muscles, &c. of the loins ; the aorta then bifurcates, as before stated, in two common or primitive iliacs.

## DISSECTION OF THE BACK.

PLACE the subject on the fore part, raise the lumbar vertebræ by a block, and put another block under the anterior part of the neck; let the head hang over the table, also the two superior extremities. Make an incision from the occipital bone to the sacrum, over the spinous processes of the vertebræ; then a second incision, from the spinous process of the last cervical vertebra to the acromion process of the scapula; and a third incision, from the last dorsal vertebra towards the ribs. Reflect the integuments, and dissect the superficial muscles, which consist of the trapezius and latissimus dorsi; these constitute the first layer, which are seen, as also some of the other muscles of the back, in the following plate.



- a.* The trapezius.
- b.* The latissimus dorsi.
- c.* The rhomboideus minor.
- d.* The rhomboideus major.
- e.* The serratus posticus inferior.
- f.* The levator anguli scapulæ.



*a.* The trapezius, *vel* cucullaris, *arises* from the middle of the great arched ridge of the occipital bone, from its fellow, over the spinous processes of the cervical vertebræ, by the intervention of a strong tendon, called ligamentum muchæ, from the spinous processes of the two inferior vertebræ of the neck, and from all those of the back, adhering tendinous to its fellow the whole length of its origin, to be *inserted*, fleshy, into the scapular half of the clavicle; tendinous and fleshy, into the acromion, and into the spine of the scapula. *Action*,— to move the clavicle and scapula, according to the directions of its different fibres. The superior fibres, descending, raise the shoulders; the middle, running transversely, pull it backwards; and the inferior fibres, ascending, depress it. The whole acting together, bring it immediately back. When the scapula is fixed, the muscle assists in moving the head backwards.

*b.* The latissimus dorsi *arises* by a broad tendinous expansion from the posterior part of the spine of the os ilium, from all the spinous processes of the vertebræ extending between the under end of the os sacrum and sixth dorsal vertebra, and, by three or four tendinous or fleshy slips, from an equal number of inferior ribs. The tendon by degrees changes into a muscle of great breadth, the inferior fibres of which run upwards and outwards, and the superior transversely over the inferior angle of the scapula, receiving a small slip from it in their way to the axilla, where the fibres of the muscle in general are collected, twisted, and folded, like those of the pectoralis major, to be *inserted* by a strong thin tendon, into the inner edge of the groove for lodging the tendon of the long head of the biceps. *Action*,— to pull the arm downwards and backwards, and to roll the humerus inwards, by which the palm of the hand is made to face backwards. When the pectoralis major acts at the same time, the arm is brought immediately down towards the trunk. The latissimus dorsi and pectoralis major form the axilla, in which the great vessels and nerves, and likewise the glands, lie which belong to the arm.

*c.* The rhomboideus minor *arises* from the spinous processes of the three inferior cervical vertebræ, and from the ligamentum nuchæ, descending obliquely, to be *inserted* into the base of the scapula above its spine.

*d.* The rhomboideus major *arises* tendinous, from the spinous processes of the four or five superior dorsal vertebræ, descending obliquely, to be *inserted* into the whole length of the base of the scapula, below its spine. *Action*,— to draw the scapula upwards and backwards.

*e.* The serratus posticus inferior *arises* from the two inferior dorsal, and from the three lumbar vertebræ, by means of the fascia lumborum, to be *inserted*, by four fleshy slips, into the same number of inferior ribs, near their cartilages. *Action*,— to depress the ribs into which it is inserted, and thereby, during expiration, to assist in contracting the cavity of the thorax.

*f.* The levator scapulæ *arises* from the transverse processes of the five superior cervical vertebræ, by the same number of distinct heads, which soon unite to form a flat muscle, running downwards and outwards, to be *inserted* into the superior angle of the scapula. *Action*,— to pull the scapula upwards and a little forwards, as in shrugging the shoulder; and when the scapula is fixed, to pull the neck a little to one side.

These muscles may be reflected, when the following will be brought into view.

*g.* The serratus posticus superior.

*h.* The splenius capitis.

*i.* The splenius colli.

*k.* The spinalis dorsi.

*l.* The longissimus dorsi.

*m.* The sacro-lumbalis.

*n.* The complexus.

*o.* The cervicalis descendens.

*p.* The transversalis colli.

*q.* The trachelo-mastoideus.

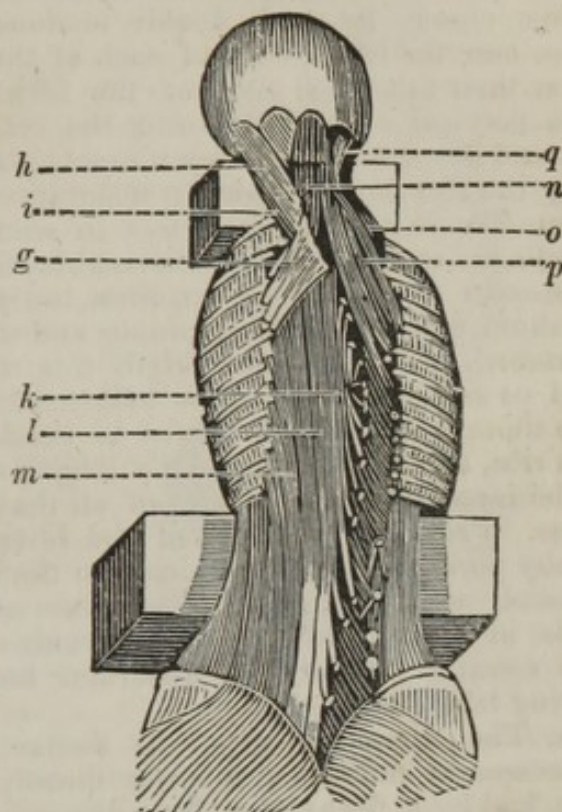
*g.* The serratus posticus superior *arises* by a broad thin tendon, from the ligamentum nuchæ, over the spinous processes of the three last cervical, and two uppermost dorsal vertebræ; going obliquely downwards, to be *inserted*, by four fleshy slips, into the second, third, fourth, and fifth ribs, under the upper and back part of the scapula. *Action*,—to elevate the ribs, and thus to dilate the thorax in violent inspiration.

*h.* The splenius capitis *arises* tendinous, from the two superior spinous processes of the dorsal, and tendinous and fleshy, from the five inferior of the cervical vertebræ; it adheres firmly to the ligamentum nuchæ, and at the third cervical vertebra it recedes from its fellow, so that part of the complexus is seen, to be *inserted*, tendinous and fleshy, into the posterior part of the mastoid process, and into the os occipitis, where it joins with that process. *Action*,—to antagonise the sternocleido mastoideus, by bringing the head and upper cervical vertebræ obliquely backwards and to one side. When the splenii act together, they draw the head directly backwards. This muscle is divided by Albinus into splenius capitis, or that which arises from the neck and goes to the head, and splenius colli, or that which arises from the back and is fixed to the neck. These two portions are the cervico-mastoideus and dorso-cervicalis of Chaussier.

*i.* The splenius colli *arises* from the spinous processes of the third and fourth dorsal vertebræ, and runs to be *inserted* into the four or five transverse processes of the superior cervical vertebræ. *Action*,—to assist the former muscle to bend the neck backwards.

*k.* The spinalis dorsi *arises* by five tendinous slips, from the spinous processes of the two upper lumbar, and the three lower dorsal vertebræ. In its ascent it is incorporated with the longissimus dorsi. *Inserted* into the spinous processes of the eight or nine uppermost dorsal vertebræ, excepting the first, by as many tendons. *Action*,—to fix the vertebræ, and to assist in extending the trunk, and keeping it erect.

*l.* The longissimus dorsi *arises* in common with the sacro-lumbalis.



It forms a large, thick, and strong muscle, which fills the hollow between the spine and angles of the ribs, becoming gradually smaller in its ascent, to be *inserted* into the transverse processes of all the dorsal vertebræ, chiefly by small double tendons, and, by a tendinous and fleshy slip, into the lower edge of each of the ribs, excepting the two inferior near their tubercles, and into the fifth and sixth transverse processes of the cervical vertebræ, joining the cervicalis descendens. *Action*,—to extend the trunk, and keep it erect; the outer part may assist in depressing the ribs during laborious inspiration.

*m.* The sacro-lumbalis *arises* in common with the longissimus dorsi, tendinous without, and fleshy within, from the side, and all the spinous processes of the os sacrum, from the posterior part of the spine of the os ilium, and from all the spinous and transverse processes of the lumbar vertebræ. The common origin fills up the space between the os ilium and os sacrum, and also the hollow of the loins. At the under part of the thorax, the muscle begins to send off tendons, which lie flat upon the ribs, and become gradually longer, the nearer they are to the spine, to be *inserted* into the angles of all the ribs, by an equal number of tendons. From six or eight of the lower ribs arise an equal number of fleshy portions, which terminate in the inner side of this muscle, termed musculi accessorii, *vel* additamentum ad sacro-lumbalem. *Action*,—to assist in raising and keeping the trunk of the body erect; it also assists the serratus inferior, and quadratus lumborum, in depressing the ribs during laborious expiration.

*n.* The complexus *arises* by distinct tendons, from the transverse processes of the seven superior dorsal, and four inferior cervical vertebræ, and by a fleshy slip, from the spinous process of the first dorsal vertebræ. In its passage upwards, it is intermixed with tendinous and fleshy fibres, to be *inserted* into a depression, under the large arched ridge of the occipital bone. *Action*,—to draw the head backwards, and to one side; and, when both act, to draw the head directly backwards. The long portion of this muscle which lies next the spinous process is more loose than the rest, and has a roundish tendon in the middle of it, with a fleshy belly at each end, termed biventer cervicis.

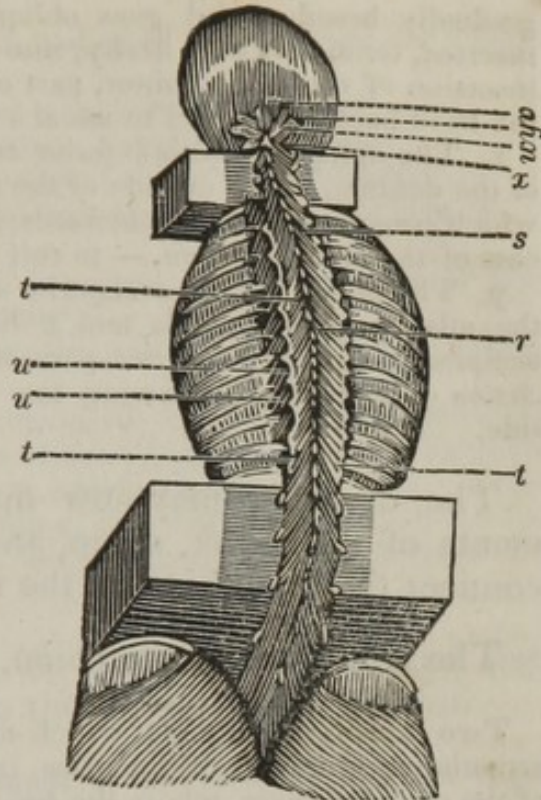
*o.* The cervicalis descendens *arises* from the upper part of the four superior ribs, and passes upwards to be *inserted* into the fourth, fifth, and sixth cervical vertebræ. *Action*,—to assist in bending the neck backwards.

*p.* The transversalis colli *arises* from the transverse processes of the five uppermost dorsal vertebræ, by the same number of tendinous and fleshy slips. It runs between the trachelo-mastoideus, and cervicalis descendens, to be *inserted* into the transverse processes of all the cervical vertebræ, except the first and last. *Action*,—to turn the neck obliquely backwards, and a little to one side.

*q.* The trachelo-mastoideus *arises* from the transverse processes of the three uppermost dorsal, and five lowest cervical vertebræ, by as many thin tendons, which unite into a slender belly, and run up under the splenius, to be *inserted* into the posterior margin of the mastoid process, by a thin tendon. *Action*,—to assist the complexus; but pulling the head more laterally.

These muscles may now be reflected, when the deeper seated will be seen, which the following plate exhibits.

- r.* The semi-spinalis dorsi.  
*s.* The semi-spinalis colli.  
*t.* The multifidus spinæ.  
*u. u.* The levatores costarum longiores et breviores.  
*v.* The rectus capitis posticus superior.  
*w.* The rectus capitis posticus inferior.  
*x.* The obliquus capitis inferior.  
*y.* The obliquus capitis superior.



*r.* The semi-spinalis dorsi *arises* from the transverse processes of the seventh, eighth, ninth, and tenth dorsal vertebræ, by as many distinct tendons, which soon grow fleshy, and then again become tendinous, to be *inserted* into the spinous processes of the six or seven uppermost dorsal, and two lowest cervical vertebræ, by as many tendons. *Action*,—to extend the spine obliquely backwards.

*s.* The semi-spinalis colli *arises* from the transverse processes of the six uppermost dorsal vertebræ, by an equal number of distinct tendons, which run obliquely under the complexus, to be *inserted* into the spinous processes of all the cervical vertebræ, except the first and last. *Action*,—to extend the neck obliquely backwards, and to one side.

*t.* The multifidus spinæ *arises* from the side and spinous processes of the os sacrum, and from that part of the os ilium which joins with the sacrum; from all the oblique and transverse processes of the lumbar vertebræ; and from all the transverse processes of the dorsal, and of the four inferior cervical vertebræ, by as many distinct tendons, which soon become fleshy, and run obliquely upwards and inwards, to be *inserted*, by distinct tendons, into all the spinous processes of the lumbar, dorsal, and cervical vertebræ, excepting the first. *Action*,—to extend the spine obliquely, and pull it to one side. When both the muscles act, they draw the spine directly backwards.

*u. u.* The levatores costarum longiores et breviores *arise* from the transverse process of each dorsal vertebra, except the last; to be *inserted*, the breviores into the upper part of each rib, below the transverse process from which it arises; the longiores into the upper part of the second rib, below each transverse process. *Action*,—to elevate the ribs.

*v.* The rectus capitis posticus superior, *vel* minor, *arises* tendinous, close to its fellow, from a small protuberance which is instead of the spinous process of the atlas, spreading out in its ascent, to be *inserted*, fleshy, into a depression between the smaller arch and foramen magnum of the occipital bone. *Action*,—to assist the rectus inferior in drawing the head backwards.

*w.* The rectus capitis posticus inferior, *vel* major, *arises* fleshy, from the external part of the spinous process of the dentata. It becomes

gradually broader, and goes obliquely upwards and outwards, to be *inserted*, tendinous and fleshy, into the os occipitis, at the outside of the insertion of the rectus minor, part of which it covers. *Action*, — to pull the head backwards, and to assist a little in its rotation.

*x.* The obliquus capitis inferior *arises* fleshy, from the spinous process of the dentata, at the outside of the rectus major. It forms a thick belly, which runs upwards and outwards, to be *inserted* into the transverse process of the atlas. *Action*, — to roll the head.

*y.* The obliquus capitis superior *arises* from the transverse process of the atlas, passes upwards and a little inwards, to be *inserted* into the occipital bone, at the outer part of the insertion of the rectus major. *Action*, — to assist in drawing the head backwards, and a little to one side.

The dissector may now direct his attention to the ligaments of the trunk, spine, and pelvis, as also to those that connect the under jaw to the temporal bone.

The ligaments of the spine, or vertebræ, consist of

Two capsular ligaments, which arise from the margin of the superior articulating processes of the atlas, inserted into the base of the condyles of the occipital bone, where the head has its flexion and extension without rotation.

Two capsular ligaments, which fix the inferior oblique processes of the atlas to the superior oblique of the dentata, and admit of the rotation of the head, with a small degree of flexion.

The perpendicular ligament, which fixes the odontoid process of the dentata to the edge of the anterior part of the foramen magnum, and is twisted in the rotation of the head.

The two lateral, or moderator ligaments, arise each from the side of the odontoid process, and run outwards and upwards, to be fixed to the inner part of the side of the atlas, and to the inner edge of the foramen magnum. They are of great strength, and prevent the head from turning too far round.

The transverse ligament arises from the inner side of the atlas, and, going across behind the processus dentatus, is fixed to the opposite side of the atlas.

The edges of this ligament extend upwards and downwards, and form two processes, called its appendices, which are fixed to the foramen magnum and odontoid process. The middle of the ligament is remarkably firm where that process plays upon it: it keeps it in its place, and prevents it from injuring the spinal marrow in the different motions of the head.

The anterior common ligament of the vertebræ, a strong tendinous band, extending along the convex or outer part of the vertebræ, from the upper to the under region of the spine. It begins at the second cervical vertebra, and descends as far as the os sacrum, where it spreads out, becomes thinner, and ends about the under part of this bone. It is much thicker upon the fore part than on the sides of the vertebræ, by which the bones are more firmly united; and is thinnest in the neck and loins, where the motion of the spine is greatest. Internally, it is blended with the periosteum, and, through its whole course, it sends

off small processes to be fixed to the bodies of the vertebræ, by which their connexion is made more secure.

The crucial intervertebral ligaments are numerous and short, but strong, situated behind the ligamentum commune anterius; crossing each other obliquely, they join the bodies of the vertebræ together, upon the outer edges of the intervertebral substances, to which also they firmly adhere.

Ligaments between the transverse processes of the vertebræ of the back, fixing these processes to each other.

The capsular ligaments, which join the articulating processes to each other.

The posterior or internal common ligament of the vertebræ, somewhat similar to the anterior one. It begins at the anterior edge of the foramen magnum, and passes along the inner or concave part of the bodies of the vertebræ, becoming broader over each of the intervertebral substances. It adheres firmly to their upper and under edges, and terminates at the lower part of the os sacrum.

The ligaments that connect the ribs to the spine, and also those which connect the ribs to the cartilages, consist of

The capsular ligaments of the heads of the ribs, arising from their heads, to be fixed to the circumference of the pits in the sides of the bodies of the vertebræ and intervertebral cartilages. The outer part of each ligament sends off, or is connected with, radiated fibres, which are spread out upon the sides of the vertebræ.

The capsular ligaments of the tubercles of the ribs arise round the articular pits on the points of the transverse processes of the vertebræ of the back, and are fixed round the tubercles of the ribs.

The transverse ligament, connecting the transverse process to the rib; the anterior ligament of the cervix of the rib, arising from the transverse process of the vertebra above, to be inserted into the anterior part of the cervix of the rib.

The posterior ligament of the cervix of the rib, arising from the inferior oblique fourth of the vertebra above, to be inserted into the posterior part of the cervix of the rib.

The ligaments at this end of the ribs, together with the situation of the transverse processes, admit of their motion upwards and downwards, but prevent them from moving in any other direction.

Short ligamentous fibres run from the margins of the anterior extremities of the ribs to the margins of their corresponding cartilages; the cartilages and ribs being joined by a union of substance.

Radiated ligaments pass from the anterior surfaces of the capsular ligaments upon the external surface of the sternum.

Many of the fibres of these ligaments intermix with their fellows on the opposite side.

The capsular ligaments of the cartilages of the ribs arise from the margins of the articular cavities of the sternum, and are fixed round the extremities of the seven true ribs.

The membrane proper to the sternum, is a firm expansion, composed of tendinous fibres, running in different directions, but chiefly in a longitudinal one, and covering the anterior and posterior surfaces of the bone.

Ligaments of the cartilago ensiformis, which are part of the proper membrane of the sternum, divided into strong bands running obliquely

from the under and fore part of the second bone of the sternum, and from the cartilages of the seventh pair of ribs, to be fixed to the cartilago ensiformis. The ligaments covering the sternum serve considerably to strengthen it.

The ligaments of the pelvis may next be dissected, which consist of

A capsular ligament, connecting the last lumbar vertebra to the sacrum.

The two transverse ligaments of the pelvis, from the posterior part of the spine of the os ilium, running transversely; the one superior, fixed to the transverse process of the last vertebra of the loins; the other inferior, connected to the first transverse process of the os sacrum.

The anterior and posterior sacro-iliac ligaments arise from the anterior and posterior portion of the ilium, and descend obliquely, the anterior to the fore part of the sacrum, while the posterior is attached to the spurious spinous processes of the sacrum. These, with the transverse ligaments, assist in binding the bones together.

The capsular ligament of the symphysis of the os ilium and sacrum surrounds the joint, and assists in connecting the two bones to each other.

A very thin cartilage within this joint, connecting the two bones strongly together, and which constantly adheres to the os sacrum, when the joint is opened.

The two sacro-ischiatic ligaments, situated in the under and back part of the pelvis. They arise in common from the transverse processes of the os sacrum, from the under and lateral part of that bone, and from the upper part of the os coccygis. One, called the large, external, or posterior sacro-ischiatic ligament, descends obliquely, to be fixed to the tuberosity of the os ischium. The other, the small, internal, or anterior sacro-ischiatic ligament, runs transversely, to be fixed to the spinous process of the ischium. These two ligaments assist in binding the bones of the pelvis, in supporting its contents, and in giving origin to part of its muscles. By these ligaments the ischiatic notch is formed for the passage of the obturator internus and the internal pudic vessels; they also assist to form the sacro-iliac foramen for the passage of the pyriformis, gluteal vessels, and great ischiatic nerve.

Besides the sacro-iliac and sacro-ischiatic ligaments, several other slips are observed upon the back of the os sacrum, which descend in an irregular manner, and strengthen the connexion between that bone and the ossa illi.

The large holes upon the back part of the os sacrum are also surrounded with various ligamentous expansions projecting from one tubercle to another, and giving origin to muscular fibres, and protection to small vessels and nerves which creep under them.

A general covering is sent down from the ligaments of the os sacrum, which spreads over and connects the different pieces of the os coccygis together, allowing considerable motion.

Longitudinal ligaments of the os coccygis, which descend from those upon the dorsum of the os sacrum, to be fixed to the back part of the os coccygis. The ligaments of this bone prevent it from being pulled too much forwards by the action of the coccygeus, and they restore the bone to its natural situation, after that muscle has ceased to act. A

ligamentous expansion hanging from the os coccygis, to support the rectum, the *ligamentum cutaneum ossis coccygis*.

Poupart's, or Fallopius's ligament, running transversely from the anterior superior spinous process of the ilium to the tubercle and symphysis of the os pubis, sending off a crescentic layer backwards, under the name of Gimbernat's ligament or duplicature, to be attached to that portion of the *linea ileo-pectinea* called the crest of the pubis.

The capsular ligament of the symphysis of the ossa pubis, which joins the two bones to each other externally and internally.

The ligamentous cartilage, which unites the two ossa pubis so firmly together as to admit of little or no motion.

A ligament situated at the arch of the pubis, allowing the *vena magna ipsius penis* to pass through it, the *ligamentum pubis interosseum*, or *ligamentum pubis triangulare*.

The obturator membrane, or ligament of the foramen thyroideum, adheres to the margin of the foramen thyroideum, and fills the whole of that opening, excepting the oblique notch at its upper part, for the passage of the obturator vessels and nerve. It assists in supporting the contents of the pelvis, and in giving origin to the obturator muscles.

### The ligaments of the lower jaw consist of

The capsular ligament, which arises from the edges of the glenoid cavity of the temporal bone; attaches itself to the edges of the interarticular cartilage, and is inserted into the neck or base of the condyloid process of the under jaw; so that it, by being attached to the movable cartilage, forms two synovial cavities. At the outer and inner part of this ligament, there is placed a perpendicular ligamentous expansion, termed the lateral ligament, which connects the bones firmer to each other.

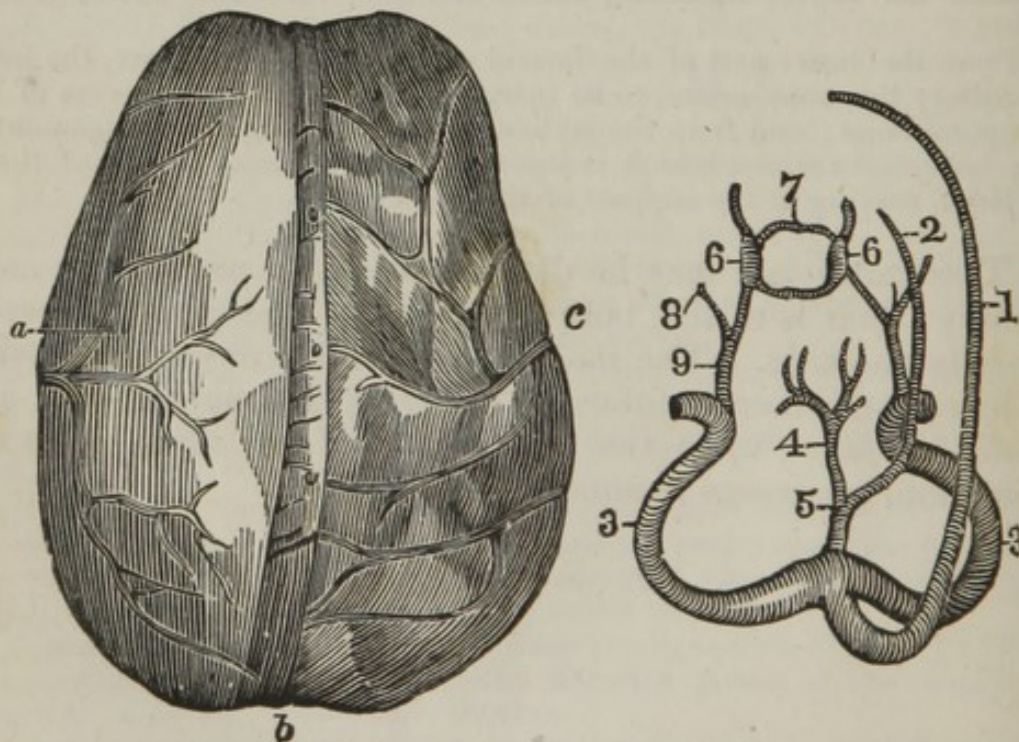
From the inner part of the lateral ramus of the under jaw, the intermaxillary ligament arises, to be inserted into the styloid process of the temporal bone; and from the styloid process the suspensory ligament of the os hyoides arises, which is inserted into the lesser cornua of the os hyoides, serving as the support of that bone.

The under jaw may be dislocated either partially or completely; that is to say, both sides may be dislocated forwards, or only one side. The mode of reduction consists of placing a lever, or rather a fulcrum, between the molar teeth, and using pressure upon the under part of the chin, when the condyloid processes resume their situation.



## DISSECTION OF THE BRAIN.\*

THE head being properly placed and fixed, an incision is to be made from the upper part of the right ear, and terminating at the upper part of the left. The scalp is now to be reflected, by dissecting it from the upper part of the skull, the anterior part being turned over the face, and the posterior over the back of the neck. When the upper part of the cranium has been sufficiently brought into view, a piece of string may be tied round it, to mark the course that the saw is to take. When the upper part of the calvarium has been removed, the dura mater is brought into sight. There is some difficulty in removing the skull-cap from this membrane, owing to the strong adhesions which exist between the two by the capillary vessels. When it is removed, a slight quantity of red coagulum may be observed, as also the external Pacchionian glands. The coverings of the brain are three in number, called the meninges; they consist of the dura mater, tunica arachnoidea, and pia mater. The following plate is intended to illustrate these membranes, as also the sinus formed by the dura mater.



\* The manner of exposing the various parts of the brain, is best explained in "Shaw's Manual of Anatomy," a work to which we refer the anatomical student, and one which all such should have by them in the dissecting room.

- a. Dura mater, with the meningeal artery ramifying upon it.
- b. The superior longitudinal sinus opened, showing the cross-bands and the open mouths of the veins.
- c. The pia mater, with its veins.

*Diagram of the Sinuses of the Dura Mater.*

1. The superior longitudinal sinus.
2. The inferior longitudinal sinus.
3. The two lateral sinuses.
4. The vena magna Galeni.
5. The torcular Herophili.\*
6. The two cavernous sinuses.
7. The circular sinus of Ridley.
8. The superior petrosal sinus.
9. The inferior petrosal sinus.

The dura mater, so named from its being of a firmer texture than the other two membranes, incloses the brain, and lines the different parts of the cranium. This membrane, in several parts, is divisible by maceration into two, or even more layers of fibres. The texture of the dura mater is very dense; it is the thickest and strongest membrane of the body, composed of tendinous-like fibres, which have a shining appearance, particularly on its inner surface; in many parts running in a variety of directions, decussating each other at different angles. The dura mater adheres everywhere to the surface of the cranium, in the same manner as the periosteum adheres to the bones in the other parts of the body; it is more firmly connected at the sutures and foramina than elsewhere; and so much more firmly in children than in adults, that, in separating it from the cranium, it is apt to bring along with it some of the fibres of the bone to which it is attached. In the adult, the separation of the bone from the membrane is less difficult, in consequence of many of the fibres being obliterated. The inner surface of the dura mater is remarkably smooth, and is lubricated by a fluid discharged through its vessels, which guards the brain from danger. The dura mater serves as a defence to the brain, and supplies the place of a periosteum to the inside of the bones of the cranium; giving nourishment to them, as is evident from the numerous drops of blood which appear after removing the skull-cap. From the inner side of the dura mater, processes are sent off, which divide the brain into certain parts, and serve to keep it steady.

The falx major, *vel* septum cerebri, formed by a doubling of the dura mater, and running between the hemispheres of the cerebrum, commences at the middle of the sphenoid bone, and crista galli of the ethmoid bone, and runs along the upper and middle part of the head, adhering to the frontal bone and foramen cæcum, then to the union of the parietal bones, and afterwards to the middle of the occipital bone. It becomes gradually broader at its posterior part, extends from the cranium to near the corpus callosum, and terminates in the middle of the tentorium. At the upper part of the falx a triangular space is formed, termed the superior longitudinal sinus, and at its inferior part, the inferior longitudinal sinus. The falx supports the tentorium, and prevents the two sides of the brain from pressing upon each other.

\* The Torcular Herophili is the general union of the longitudinal, the fourth, and the lateral sinuses.

The falx minor, or septum cerebelli, is placed between the lobes of the cerebellum. It descends from the under and back part of the falx and middle of the tentorium, adheres to the inferior longitudinal spine of the occipital bone, and terminates insensibly at the edge of the foramen magnum.

The tentorium cerebelli, or transverse septum of the dura mater, is continued laterally from the falx, connected behind to the inner transverse ridges of the occipital bone, and at the fore and outer edges to the ridges and great angles of the temporal bones, and terminates at the posterior clinoid process of the sphenoid bone. The tentorium keeps the falx tense, and forms a floor or vault over the cerebellum, which prevents the cerebrum from pressing upon it.

The dura mater forms sinuses, which differ from veins only in this, that their transverse sections are of a triangular figure, and that they are enclosed in a doubling of the dura mater, which is so tense over them, as to be little affected by the pressure of the surrounding parts. The sinuses serve to carry the blood from the brain, and convey it to the veins of the neck; for which purpose they are properly fitted, their covering from the dura mater giving them strength, and their frequent communications preventing congestion.

The superior longitudinal sinus begins at the under part of the spine of the frontal bone, runs along the upper edge of the falx major, and, becoming gradually wider, terminates upon the middle of the occipital bone, in the two lateral sinuses; it receives the blood from the upper part of the brain, by several large venous trunks, which enter it obliquely.

The inferior longitudinal sinus, remarkably small, situated in the under edge of the falx, receives branches from the corpus callosum and parts of the brain near it, and terminates in the fourth sinus.

Two lateral sinuses, or second and third sinuses of the ancients, formed by the longitudinal and fourth sinuses. They run at the posterior edge of the tentorium, along the lateral ridges of the occipital bone, as far as the base of the petrous portion of the temporal bones, from whence they wind downwards, pass through the foramina lacera, common to the occipital and temporal bones, and terminate in the internal jugular veins. Frequently, one of the lateral sinuses is formed by the longitudinal, and the other by the torcular sinus; in which case the one is found larger than the other. The lateral sinuses receive veins from the cerebellum, and from the under and back part of the cerebrum. They likewise receive the following small sinuses.

The fourth sinus of the ancients, chiefly formed by the vena magna Galeni, returns the blood from the choroid plexus, corpora striata, septum lucidum, and other internal parts of the brain; it passes back in the joining of the falx and tentorium, and terminates, with the superior longitudinal sinus, in the beginning of the lateral sinuses.

The cavernous sinuses, situated at the sides of the sella turcica, receive blood from veins lying near the lateral branches of the internal carotid arteries, from the ocular veins, and from the circular sinus of Ridley. The cavernous sinuses surround the carotid arteries, and have a cavernous structure within.

The circular sinus of Ridley is placed about the glandula pituitaria, and frequently surrounds it completely, receiving the blood from it, and from the adjacent bones and membranes, terminating in the cavernous sinuses.

The superior petrosal sinuses, situated upon the ridges of the partes petrosæ; they receive some small veins from the dura mater and base

of the brain, and communicate backwards with the lateral, and forwards with the cavernous sinuses.

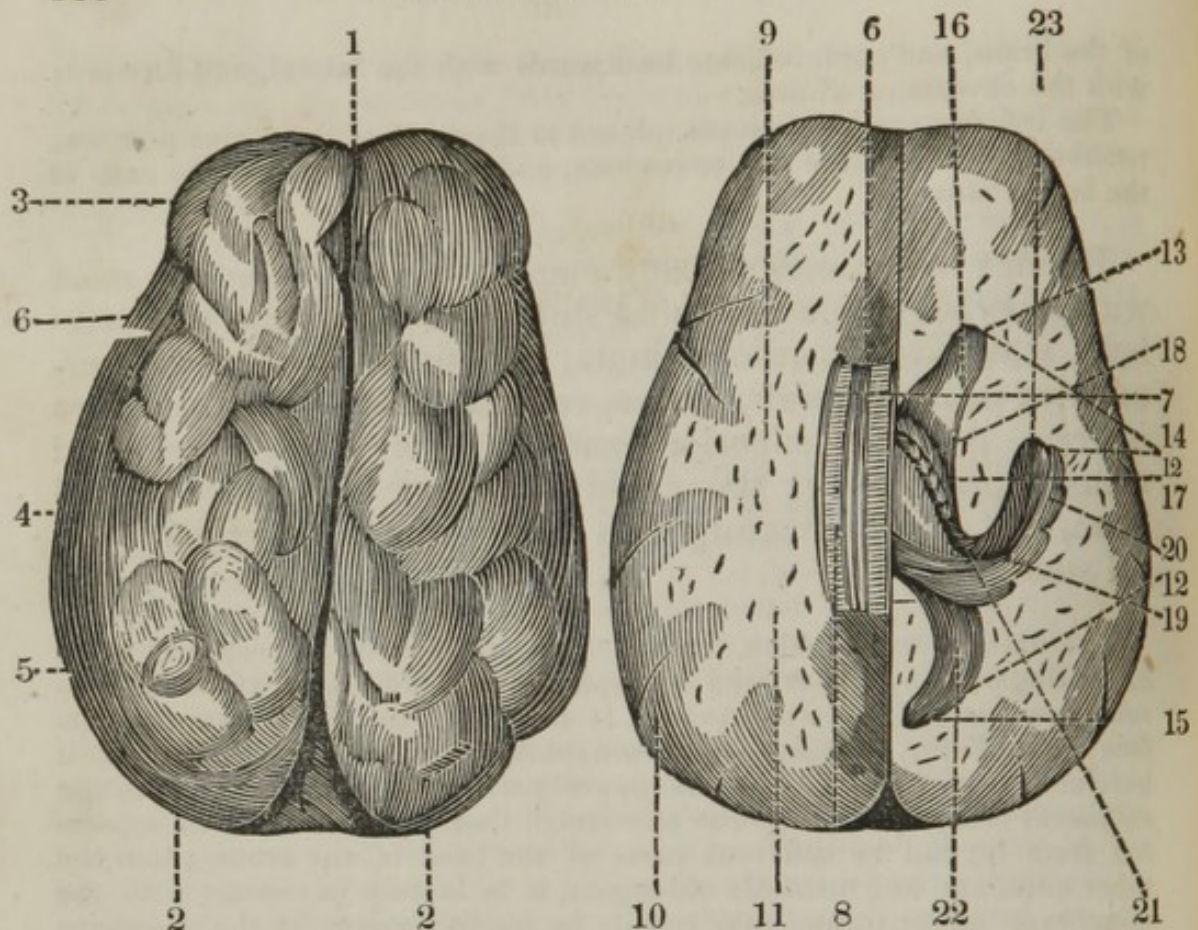
The inferior petrosal sinuses, placed at the roots of the partes petrosæ, receive the blood from the cavernous, and discharge it into the ends of the lateral sinuses.

Besides the sinuses already mentioned, we frequently meet with a perpendicular occipital sinus, situated in the falx cerebelli, which is sometimes single, sometimes double, and terminates in the lateral sinuses, receiving veins from the dura mater. Anterior superior, and anterior inferior occipital sinuses, placed over the cuneiform process of the occipital bone, and communicating with the inferior petrosal and lateral sinuses.

The tunica arachnoidea, named from its cobweb appearance, is an exceedingly thin, tender, and transparent membrane, in which no vessels have been hitherto observed. It is spread uniformly over the surface of the brain, inclosing all its convolutions, without insinuating itself between any of them. At the upper part, it adheres so closely to the subjacent coat, by fine cellular substance, that it can scarcely be separated from it; but in different parts of the base of the brain, about the tuber annulare and medulla oblongata, it is merely in contact with the membrane under it, and may readily be raised from it by the assistance of the blow-pipe. The tunica arachnoidea, like the cuticle, covers and defends the parts under it.

The pia mater, named from its tenderness, is somewhat of the nature of the former covering, but extremely vascular. It envelopes the brain, entering double between all its convolutions, and lines the different cavities called ventricles. It serves to contain and support the vessels, and allows them to divide into such minute parts, as to prevent the blood from entering the tender substance of this viscus with too much force. It has numerous veins ramifying over it, which terminate in the sinuses, those at the superior parts in the longitudinal sinus.

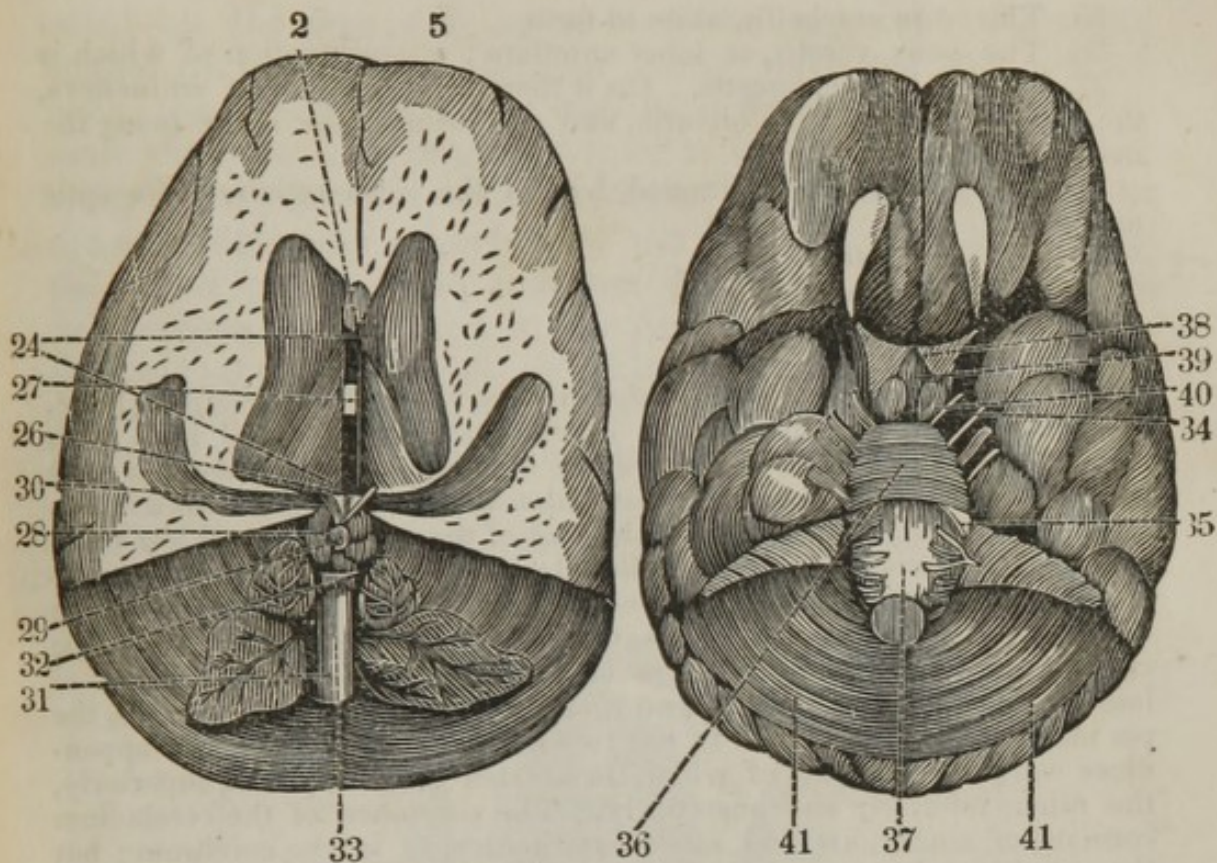
The brain is divided into cerebrum and cerebellum; the former constituting the upper and fore part; the latter, the lower and inferior part.



1. The cerebrum, divided into
2. The two hemispheres, each divided into three lobes.
3. The anterior.
4. The middle.
5. The posterior.
6. The fissura magna Sylvii, situated between the anterior and middle lobes; better seen at the base of the brain.

On separating the two hemispheres, we bring into view

6. The corpus callosum, with
7. The raphe in the centre, formed by the depressions of the arteries of the corpus callosum.
8. The linea transversæ, fibres passing laterally from the raphe. On making a section, and cutting away the upper part of the hemisphere,
9. The centrum ovale of Vieussiens is brought into view. It forms the ceiling of the lateral ventricle.
10. The cortical structure of the cerebrum.
11. The medullary structure of the cerebrum, upon which the cut vessels are seen.
12. The third ventricle opened, showing its division into the three cornua.
13. The anterior.
14. The middle, or inferior.
15. The posterior.
16. The corpus striatum.
17. The thalami nervi optici. The small eminences upon this body are called the corpora geniculata.
18. The linia semicircularis, separating the two former bodies.
19. The hippocampus major, terminating in



20. The pedes hippocampi.  
 21. The tænia hippocampi, the continuation of the posterior crura of the fornix.  
 22. The hippocampus minor.  
 23. The plexus choroides. Beneath the corpus callosum the septum lucidum is situated, and beneath that, the fornix, which sends off two anterior and two posterior crura; the anterior plunge into the anterior lobes of the cerebrum.  
 Between the two lateral ventricles  
 24. The third, or middle ventricle is situated. It is bounded laterally by the thalami, superiorly by the fornix and velum interpositum, and inferiorly by the pons varolii and pars cribrosa.  
 25. The anterior commissure; under it the iter ad infundibulum.  
 26. The posterior commissure; under it, the iter a tertia ad quartum ventriculum.  
 27. The commissura mollis, connecting the two thalami. Behind and above the posterior commissure there is situated  
 28. The corpora quadrigemini; upon these eminences  
 29. The pineal gland, sending off  
 30. The two peduncles, running to the thalami. Below and behind the corpora quadrigemini, there is situated  
 31. The fourth ventricle, bounded superiorly by the valvula Vieussensii, laterally by the crura cerebelli, and inferiorly by the upper part of the medulla oblongata.  
 32. The valvula Vieussensii.  
 33. The situation of the calamus scriptorius.  
 At the base of the brain —  
 34. The crura cereberii, and

35. The crura cerebellii, unite to form
36. The pons varolii, or tuber annulare; a continuation of which is
37. The medulla oblongata. On it there are three pair of eminences, the corpora pyramidalia, olivaria, and restiformia; the latter being the most external.
38. The infundibulum, situated behind the decussation of the optic nerves.
39. The pons Varolii.
40. The corpora albicantia.
41. The cerebellum.

The cerebellum is situated in the inferior fossæ of the occipital bone, under the posterior lobes of the cranium, and is separated from them by the tentorium. It is somewhat of a roundish form, though a little broader from one side to the other than from before backwards. It is only about a fifth or sixth part of the size of the cerebrum, and less complex. It is divided behind by the falx minor into two lobes or hemispheres. Its surface is divided into numerous circumvolutions, which form arches in many parts, decussating each other at sharp angles. The circumvolutions run chiefly in a lateral direction, and are formed of laminae, with deep sulci between them, into which, as in the brain, the pia mater insinuates itself. It has two middle eminences, called appendices vermiformes, one of which is situated anteriorly and superiorly, the other inferiorly and posteriorly. The substance of the cerebellum consists of cineritious and medullary matter, as in the cerebrum; but the cineritious bears a greater proportion to the medullary in the former than in the latter. When the cerebellum is cut in a vertical direction, the medullary part is then found to bear a striking resemblance to the branching of the shrub called arbor vitæ; from which circumstance it has obtained that name.\*

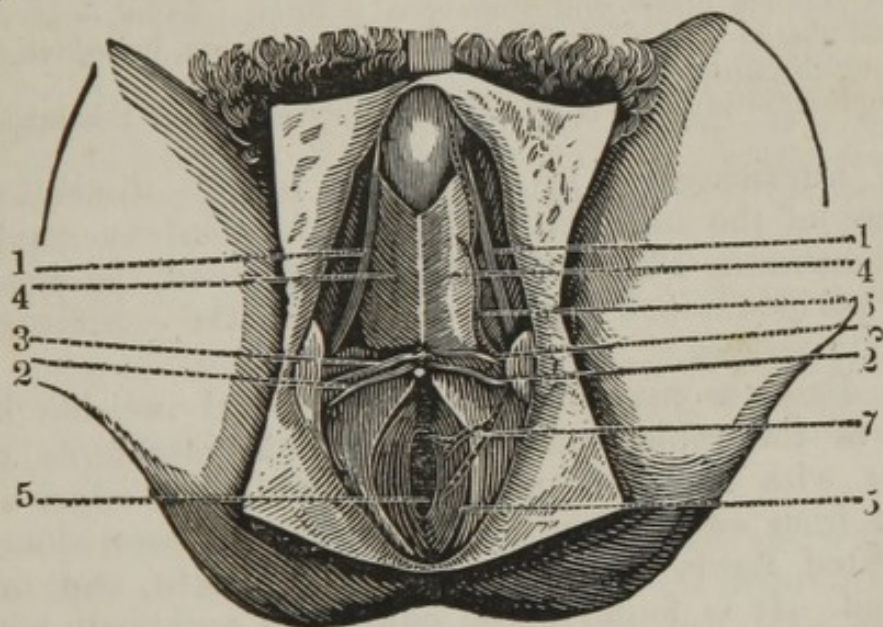
---

### DISSECTION OF THE PERINEUM.

THE body must be placed in the same position as when the operation of lithotomy is performed; a staff should be introduced into the urethra, the anus ought to be stuffed with tow, and the edges sewn together. The dissector may observe the divisions of the perineum into anterior and posterior, the former being placed between the arch of the pubis and anus, and the latter between the anus and os coccygis. An incision is to be made from the arch of the pubis to the os coccygis; a second incision is to be made from the tuber

\*To show the *organization* of the brain in a more satisfactory and rational manner, than that as practised until the discoveries of Gall and Spurzheim, the student should examine the "Anatomy of the Brain," as demonstrated by the latter, in his work on that subject.

ischii on the one side to that on the opposite; when, the angles of the crucial incision being reflected and pinned back, the superficial fascia may be dissected. It is nothing more than the sub-cutaneous cellular tissue. It is connected laterally to the rami of the ischium and pubis, anteriorly to the sub-cutaneous covering of the scrotum, and posteriorly the fascia passes back, and just below the transversus perinei, becomes connected to the deep-seated fascia. By considering the attachment of this fascia, the dissector will readily perceive that when extravasation of urine takes place, the fluid passes towards the scrotum, as it cannot pass backwards or laterally, on account of its firm attachments. This fascia may be reflected, when the following parts may be dissected.



1. The erector penis.
2. The transversus perinei.
3. The transversus perinei alter.
4. The accelerator urinæ.
5. The sphincter ani.
6. The artery of the perineum, sending off the transverse artery of the perineum.
7. The external hemorrhoidal artery to the verge of the anus.

1. The erector penis *arises* from the inner side of the tuber ischii, and its ascending ramus, continuing upwards upon the crus penis, to be *inserted* into the corpus cavernosum. *Action*,— to draw the crus penis downwards and backwards.

2. The transversus perinei *arises* from the inside of the tuberosity of the ischium, close to the erector penis; running transversely to be *inserted* into the back part of the accelerator urinæ, and adjoining part of the sphincter ani. *Action*,— to dilate the bulb for the reception of the semen or urine, and to assist the levator ani in retaining the anus, after the discharge of the fæces.



3. The transversus perinei alter runs along the former, and has nearly the same origin, insertion, and action, but goes more obliquely upwards.

4. The accelerator urinæ arises fleshy from the sphincter ani, and membranous part of the urethra; and tendinous from the crus and beginning of the corpus cavernosum penis; also from the inner part of the tuber ischii and its ascending ramus. In its course it forms a thin fleshy layer, the inferior fibres of which run more transversely than the superior, and descend in an oblique direction, with the muscles on the opposite sides completely inclosing the bulb of the urethra, to be inserted into its fellow by a tendinous line, running longitudinally on the middle of the bulb. *Action*,— to propel the urine or semen forwards, and, by compressing the bulb, to push the blood into, and thereby distend the corpus cavernosum urethræ and glans penis.

5. The sphincter ani arises from the extremity of the os coccygis, runs forward within the skin and fat which cover the verge of the anus, and in its passage forming a broad, flat, oval muscle, which surrounds the extremity of the intestinum rectum, to be inserted, by a narrow point, into the acceleratores urinæ and transversus perinei. *Action*,— to shut the anus, and also to pull down the bulb of the urethra, by which it assists in ejecting the urine and semen.

The sphincter internus is merely the superior part of this muscle.

The arteries seen in this stage of the dissection are branches of the internal pudic, accompanied by small nervous filaments. They will be described when the dissection of the perineum is completed, and after the examination of the pelvic viscera.

The dissector may make a longitudinal incision in the course of the raphe, and reflect the acceleratores urinæ, together with the other muscles, drawing the edges of this incision from each other. When this has been done, the deep-seated fascia will be brought into sight, and may be examined. It is found to be connected anteriorly with the ligamentum pubis interosseum and descending rami of the pubis; laterally, to the ascending rami and tuber ischii; and posteriorly, to the os coccygis and posterior sacro-schiatic ligament; this attachment is occasionally very indistinct. The fascia is a thin firm membrane, forming the floor of the pelvis, and consequently must be of a triangular figure, as the pelvis, when viewed at its inferior portion, presents a triangular space. This fascia has been by some anatomists termed the ligamentum triangulare.\* If this fascia be examined, beneath the arch of the

\* "About half an inch below the base of the sub-pubic ligament, and, therefore, an inch below the arch, the membrane presents a foramen peculiarly formed for the transmission of the urethra. If the latter be drawn forwards, it will be found to be invested by a tubular prolongation, derived from the margin of the foramen, and continuous with the perineal or external lamellæ of the fascia. A

pubis, it will be found to be composed of two lamellæ, which separate at the base of the sub-pubic, or triangular ligament; one lamina passing on the outer, and the other on the inner part of the pubis, upon which they terminate.

The dissector may next divide the deep-seated fascia by making a longitudinal incision, and reflect the fascia to either side. This will bring into view the two deep-seated muscles of the perineum, the levator ani, and the coccygeus.

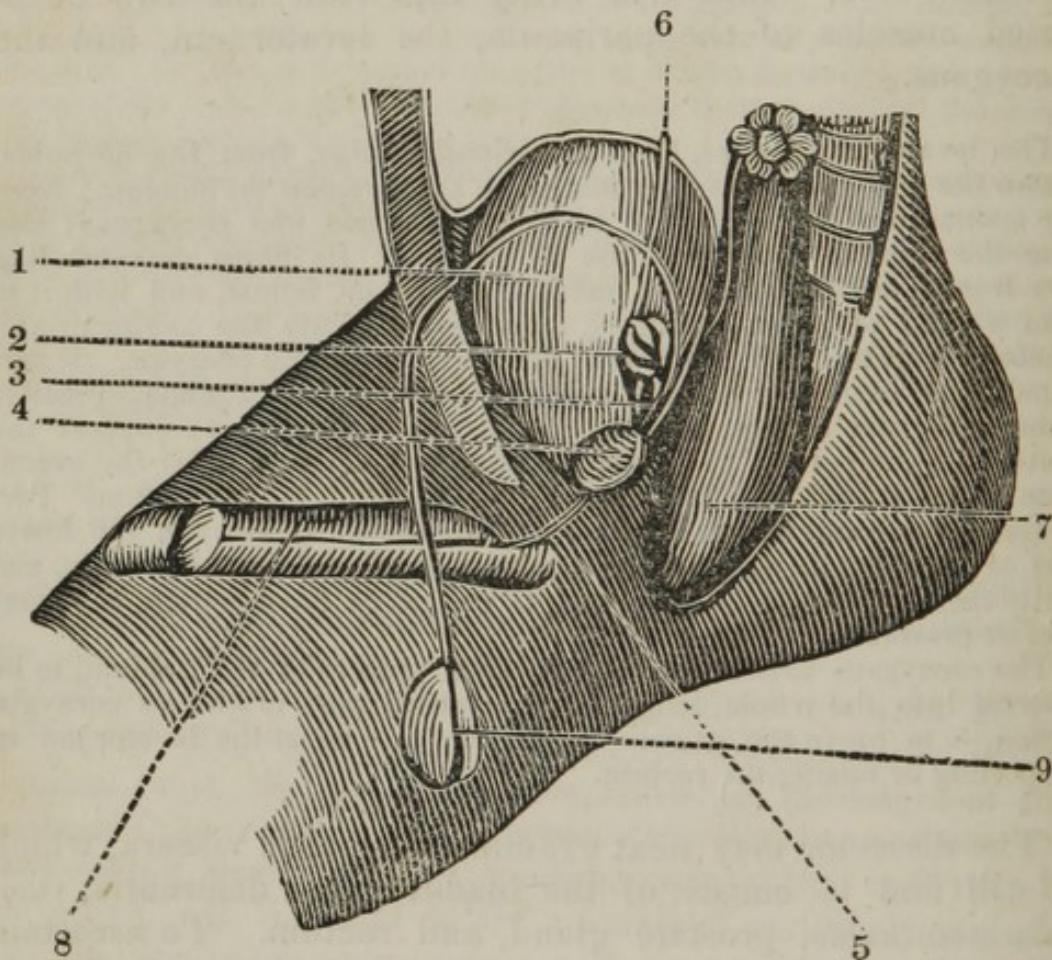
The levator ani *arises*, by a semicircular edge, from the os pubis, within the pelvis, at the upper margin of the foramen thyroideum; from the aponeurosis, covering the obturator internus and coccygeus; and from the spinous process of the os ischium. Its fibres descend like rays from a circumference, to meet those of its fellow, and with it to form a kind of inverted funnel, to be *inserted* into the sphincter ani, accelerator urinæ, and under and fore part of the os coccygis. It surrounds the extremity of the rectum, neck of the bladder, prostate gland, and part of the vesiculæ seminales. *Action*,—to support the contents of the pelvis; to retract the end of the rectum, after the evacuation of the fæces; and to assist in the evacuation of the rectum. Part of the levator ani, which arises from the os pubis, between the lower part of the symphysis and the upper part of the foramen ovale, and partly inclosing the prostate gland, is called, by Soemmering, the compressor prostatæ.

The coccygeus *arises* from the spinous process of the ischium, to be *inserted* into the whole length of the lateral part of the os coccygis. *Action*,—to move the os coccygis forward; to assist the levator ani in supporting or raising the rectum.

The dissector may next examine the pelvic viscera, which he will find to consist of the bladder, vasa deferentia, vesiculæ seminales, prostate gland, and rectum. To ascertain a correct idea of the relative situation and connexion of these parts, the bony walls of the pelvis on the one side may be removed. To accomplish this, the symphysis pubis can be carefully divided, the crus penis attached to the tuber ischii cut, and the os innominatum separated from its

similar prolongation is reflected backwards from the posterior or pelvic lamella, which invests the membranous and prostatic portion of the canal, and extends as far as the neck of the bladder. When the parts remain undisturbed, the surface of the fascia is quite flat; and if the urethra be cut across close to it, the aperture will be found barely sufficient to transmit it. But if the penis be drawn obliquely upwards, the fascia is rendered tense and convex forwards, by means of the traction exerted on it through the medium of its tubular prolongation. Should the experiment be then made of cutting off the urethra close to the fascia, the foramen will be found much wider, for the tube had been previously rendered, as it were, trumpet-shaped, and so it will be when the urethra is rendered tense, during the introduction of the catheter." — *Quain's Elements of Anatomy*, p. 556.

union with the sacrum. The dissector may now moderately inflate the bladder by a blow-pipe introduced into the urethra, preventing its escape by tying a ligature around the penis; and the rectum may be sufficiently distended with tow. The accompanying diagram points out the parts that will be brought into view by making this section.



1. The bladder.
2. The left vesicular seminalis.
3. The vas deferens entering into it, and taking its origin from the testicle.
4. The prostate gland.
5. The membranous part of the urethra.
6. The left ureter, terminating at the posterior, inferior, and lateral portion of the bladder.
7. The rectum.
8. The penis.
9. The testicle.

The vesica urinaria, or bladder of urine, is a large sac, situated in the pelvis, in the bottom of the hypogastric region. It is placed in the fore part of the pelvis, behind the pubis, and before the upper, and above the under portion of the rectum. When empty, it is contracted into a small size, which occupies the under and fore part of the pelvis;

but, when fully distended, it rises above the brim of that cavity, and sometimes ascends to within a little distance of the umbilicus. When moderately dilated, it is of a roundish or irregular oblong form, but a little flattened before, more convex behind, and broader at its anterior and posterior than towards its lateral parts. It is divided into the fundus, body, and cervix; the first of which is placed upwards and a little forwards, and the last at the under and fore part. It is connected below to the rectum, and at the sides to the pelvis, by the reflected peritoneum and cellular substance. It is attached, at the fore part of its body, by cellular substance, to the pubis, without the intervention of the peritoneum; and also to the parieties of the abdomen, just above the pubis, by the same intervention of cellular membrane. It is also fixed to the umbilicus by three ligaments, situated between the peritoneum and abdominal muscles. They are formed of the urachus running upwards from the fundus, and of the obliterated umbilical arteries passing obliquely from the sides of the bladder. The firmest connexion is by means of a ligamentous expansion, which runs from each side of the neck of the bladder and prostate gland, to be fixed to the inside of the arch of the ossa pubis. It is connected also to the penis by the urethra. It consists of different coats joined together by cellular tissue; the first being only a partial one, continued from the peritoneum.

The peritoneal, or common coat, passes over the superior, and down upon the posterior and lateral parts of the bladder, to near the termination of the ureters, where it is about a finger's-length from the anus, and is there reflected upon the rectum and back part of the pelvis. When the bladder is much distended, it carries the peritoneum with it, and leaves a space between that membrane and the pubes.

The second coat, the muscular, consists of distinct fleshy fibres, interwoven with each other. The external fibres running in a longitudinal direction, and connected at the under and fore part of the bladder with the pubis; internally, the fibres run in all directions, and are intermixed with each other in the form of net-work. The fibres are contracted about the neck of the bladder, and form the sphincter vesicæ, which are but the continuation of the other fibres. The muscular coat has been called the detrusor urinæ. The coat beneath the muscular has been termed the nervous coat, which consists principally of cellular tissue.

The inner, or villous coat, is smooth, thin, and dense, to prevent the exudation of the urine; it is rendered unequal by the projecting of the fasciculi of the muscular fibres; and, when the bladder is empty, forms rugæ.

The under part of the bladder is perforated by three openings; of which one is placed anteriorly, and two posteriorly. The anterior opening is the beginning of the passage called the urethra, and is surrounded by the neck of the bladder. It comes off almost at a right angle from the lower part of the bladder, without any tapering of that viscus. The other two openings are formed by the termination of the ureters, which run obliquely forwards and inwards.

At the posterior part of the bladder, the two vesiculæ seminales are placed, and more internally still, the two vasa deferentia. Each vas deferens unites with one of the vesiculæ seminales to form one common duct, which passes at the posterior part of the neck of the bladder, and runs for a short distance within the prostate gland, in company with the urethra, which it ultimately perforates, forming the eye of the caput gallinaginis. At the posterior and inner part of the bladder, at its inner portion, just below and between the termination of the ureters, there is

a triangular thickening, with the apex facing towards the urethra, which has received the name of the vesical *trigon*.

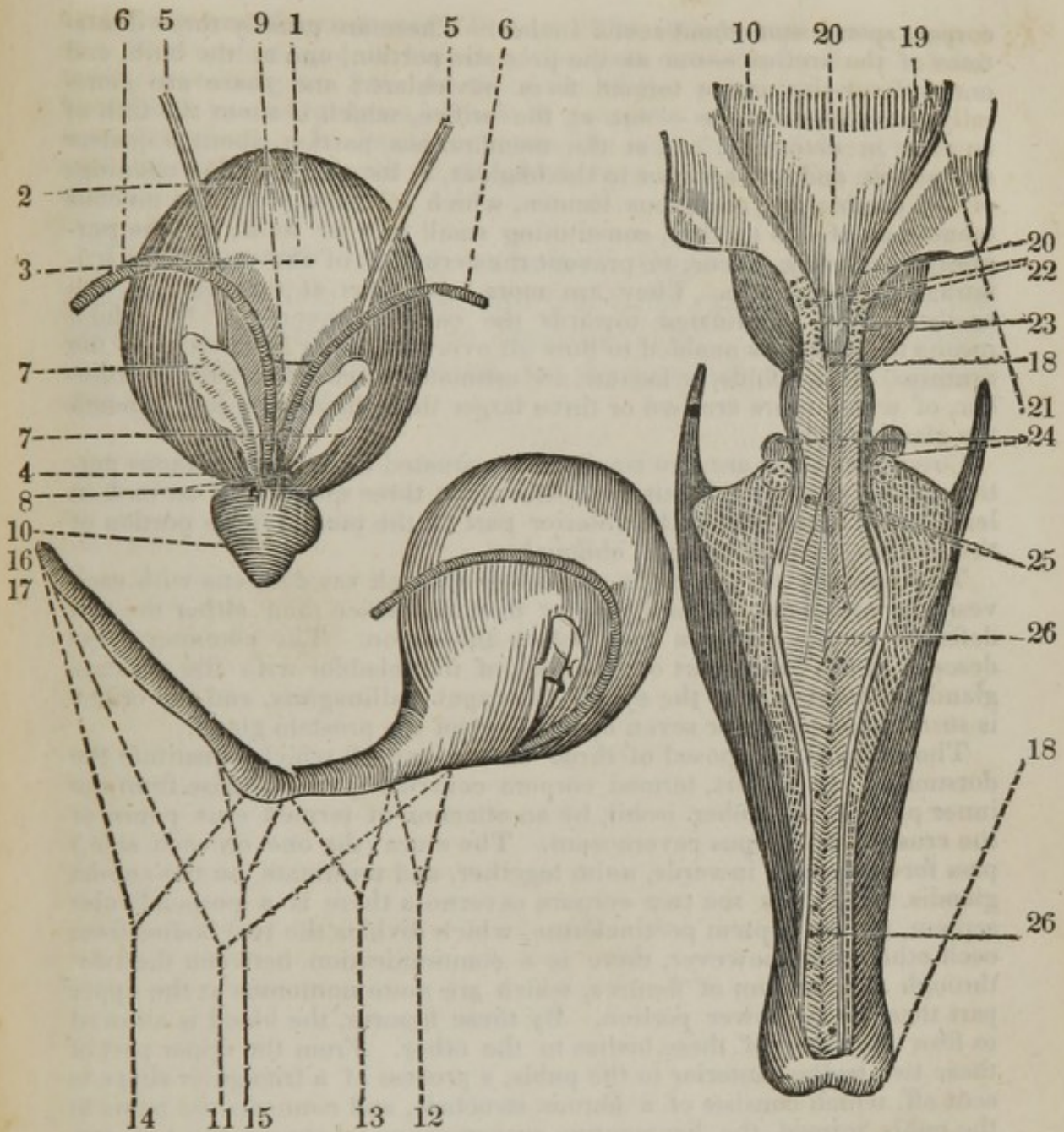
The vesiculæ seminales are two sacculated irregular bodies, placed at the posterior and inferior part of the bladder, between it and the lateral parts of the rectum. They serve to receive the semen, and retain it in the several sacs, which are formed by septæ running from the one side of the parieties of the receptacle to that of the other; so that it becomes impossible for the whole contents of that vesicular to be ejaculated at once.

The vasa deferentia are the excretory ducts of the testicle, and take their origin from the upper part of the epididymis of that body, by the termination of the coni vasculosi. Each vas deferens proceeds up the posterior part of the spermatic cord, runs through the abdominal rings to the pelvis, when it directs its course to the posterior part of the bladder, to enter or unite with the duct of the vascular seminales, conveying its contents into that body. This tube is of a firm consistence, and resembles a common smoking-pipe, being remarkable for the thickness of its coats and the smallness of the perforation. At the termination of the vas deferens, between it and its fellow, the bladder is firmly connected to the rectum, without the intervention of the peritoneum; and it is in this situation that the bladder may be punctured, which part is pointed out in the next plate; but care must be taken not to make the perforation too high, as the peritoneum then would be wounded.

The prostate gland is about the size of a walnut, and of the shape of a Spanish chesnut, or as the heart painted on playing cards; its base towards the bladder, and its apex towards the penis. It consists of three lobes; two lateral, and a posterior one termed lobulus Morgani, or third lobe. The gland completely surrounds the neck of the bladder, and sends off twelve or fourteen small ducts, which perforate the urethra, that the mucus, or fluid secreted by it, may facilitate the passage of the semen through the urethra.

The urethra is the long elastic canal which conveys the urine from the bladder, and is divided into the parts described in the following diagrams, which have been added to point out the relative positions of some of the parts described in the preceding page.

1. A posterior view of the bladder.
2. The fundus.
3. The body.
4. The cervix.
5. The ureters, descending to terminate at the posterior, inferior, and lateral parts of the bladder.
6. The vasa deferentia, terminating in
7. The vesiculæ seminales.
8. The common union of each vas deferens and vesiculæ seminales.
9. The situation of puncturing the bladder, where it is connected to the rectum by cellular substance.
10. The prostate gland.
11. The urethra; its average length being about nine inches; dividing into
12. The prostatic portion.
13. The membranous portion.
14. The portion situated in the corpus spongiosum.
15. The bulb.
16. The orifice.



- 17. The fossa navicularis.
- 18. The bladder and penis opened.
- 19. The termination of the ureters.
- 20. The trigon.
- 21. The caput gallinaginis.
- 22. The opening of the common union of the vesicular seminalis and vas deferens into the prostatic portion of the urethra.
- 23. The opening of the ducts of the prostate gland.
- 24. Cowper's glands.
- 25. The opening of Cowper's ducts into the urethra.
- 26. The openings of the lacunæ.

The average length of the urethra is about nine inches, the prostatic portion occupying about three quarters of an inch, the membranous portion about an inch and a quarter, and the portion contained in the

corpus spongiosum about seven inches. There are usually three dilations of the urethra — one at the prostatic portion, one at the bulb, and one behind the orifice termed fossa navicularis; and there are generally three contractions — one at the orifice, which is about the fifth of an inch in diameter; one at the membranous portion, about a quarter of an inch, and one anterior to the bladder, at its orifice. The openings of the urethra are numerous lacunæ, which are formed by the mucous membrane of the urethra, constituting small sacs or folds, for the purpose of secreting mucus, to prevent the acrimony of the urine from irritating this membrane. They are more numerous at that part of the urethra which is situated towards the corpora cavernosa, by which means the mucus is enabled to flow all over the lining membrane of the urethra. These folds, or lacunæ, are estimated at about seventy in number, of which there are two or three larger than the others, just beneath the glands penis.

Cowper's glands are two small bodies situated at the membranous portion of the urethra. Their ducts are about three quarters of an inch in length, and enter just at the anterior part of the membranous portion of the urethra, by perforating it obliquely.


The opening of the common union of each vas deferens with each vesiculæ seminales forms a smaller duct or orifice than either the vas deferens or the vesiculæ had, before the union. The common ducts descend at the back part of the neck of the bladder with the prostate glands, to terminate at the eye of the caput gallinaginis, and the orifice is surrounded by six or seven openings from the prostate gland.

The penis is composed of three bodies, two of which constitute the dorsum or upper part, termed corpora cavernosa, which arise from the inner part of the tuber ischii, by an attachment termed crus penis, or the crus of the corpus cavernosum. The crura (the one on each side,) pass forwards and inwards, unite together, and terminate on the corona glandis. Between the two corpora cavernosa there is a perpendicular septum, termed septum pectineforme, which divides the two bodies from each other; but, however, there is a communication between the two, through the medium of fissures, which are more numerous at the upper part than at the lower portion. By these fissures, the blood is allowed to flow from one of these bodies to the other. From the upper part of these two bodies, anterior to the pubis, a process of a triangular shape is sent off, which consists of a fibrous structure, and connects the penis to the pubis, termed the ligamentum suspensorium; between the two corpora cavernosa there is a groove at their upper part, and in this groove the vena magna penis is situated, having an artery on either side, the arteria dorsalis penis.

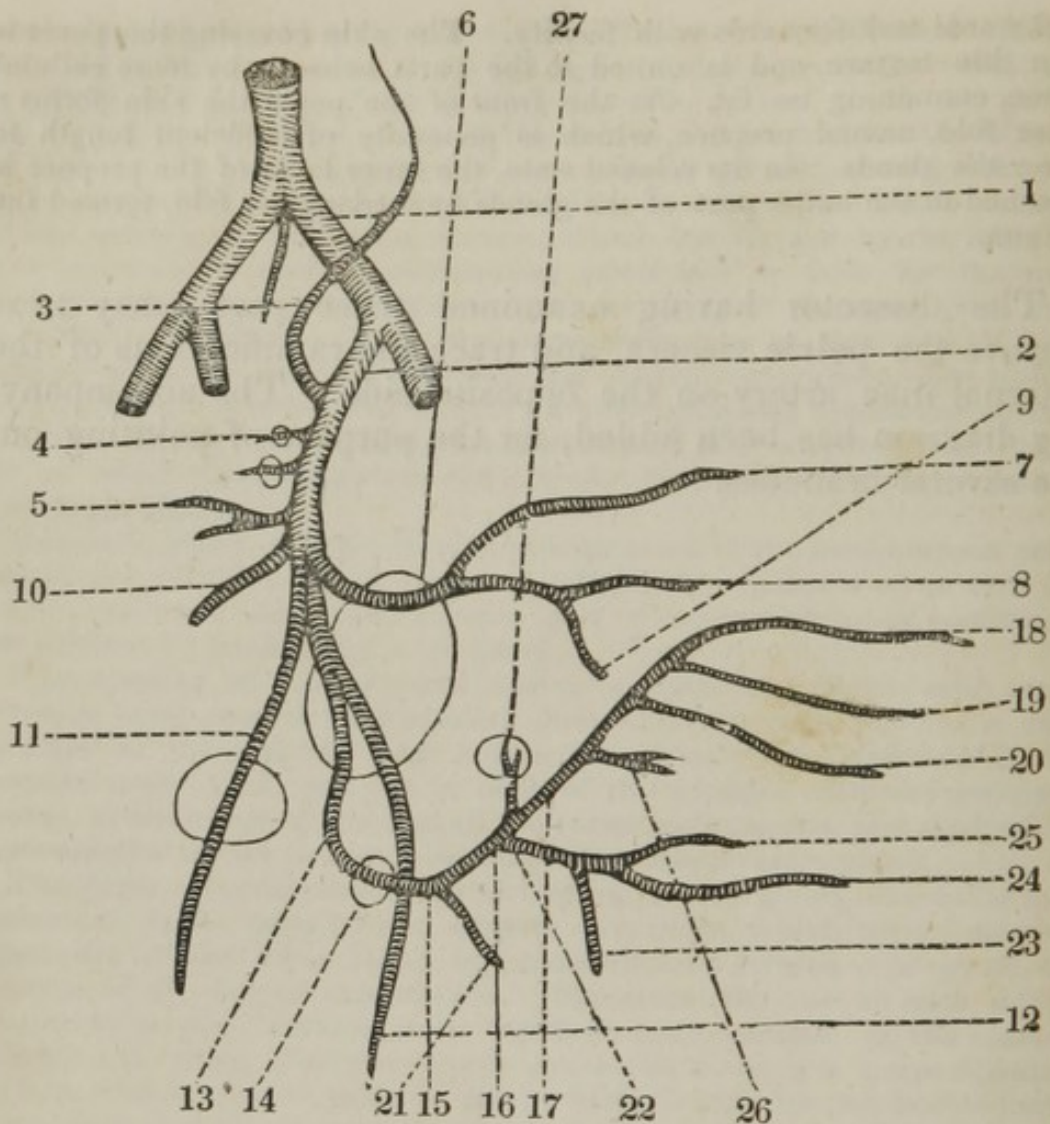
The corpus spongiosum urethræ is situated immediately beneath the two former bodies, commencing from the bulb of the urethra, and advancing forwards to terminate by forming the glans penis, which covers and incloses the ends of the corpora cavernosa, but separated from them by a continuation of the same membranous sheath which inclosed those two bodies. The corpus spongiosum is covered by a sheath similar to that investing the corpus cavernosum, but it is of a more delicate texture. The internal structure of the corpus spongiosum is nearly similar to the corpus cavernosum, but some anatomists consider it as merely a plexus of veins. About the cervix of the corona glandis there are many follicles, termed glandulæ odoriferæ, which discharge a sebaceous matter to preserve the sensibility of the glands, and allow the prepuce to move

backwards and forwards with facility. The skin covering the penis is of a thin texture, and is united to the parts beneath by loose cellular tissue, containing no fat. At the front of the penis the skin forms a loose fold, named prepuce, which is generally of sufficient length to cover the glands. In its relaxed state, the inner layer of the prepuce is attached to the under part of the glands by a triangular fold, termed the frænum.

The dissector having examined these parts, may next remove the pelvic viscera, and trace the ramifications of the internal iliac artery on the opposite side. The accompanying diagram has been added, for the purpose of pointing out the several branches.







1. The common iliac artery, sending off
2. The internal iliac, opposite the sacro-iliac synchondrosis. It descends into the pelvis, and gives off the following branches.
3. The ilio-lumbalis, to anastomose with the circumflexus ilii.
4. The lateral sacral arteries, to enter the foramina in the sacrum.
5. The lateral hemorrhoidal.
6. The gluteal, to pass through the sacro-iliac foramen, and dividing into
7. The superficial branch, to ramify between the gluteus maximus and medius.
8. The deep-seated branch, to ramify between the gluteus medius and minimus, sending off
9. A branch to anastomose with the internal circumflex, to supply the hip-joint.
10. The situation of the origin of the hypogastric artery, which becomes the artery to supply the bladder.
11. The obturator artery, passing out of the obturator foramen to supply the inner part of the thigh.
12. The ischiatic artery, passing through the ischiatic notch to accompany the ischiatic nerve.

13. The continued trunk of the iliac artery becoming the internal pudic, passing out of the pelvis at the sacro-iliac foramen, and into the pelvis again at

14. The ischiatic notch. At

15. It is situated at the inner part of the tuber ischii.

16. At the inner portion of the ascending ramus of the same bone, and

17. At the inner part of the descending ramus of the pubis, ultimately gaining the arch of the pubis, where it divides into three branches.

18. The arteria dorsalis penis.

19. The artery of the corpus cavernosum, and

20. The artery of the corpus spongiosum. The pudic artery in its course sends off

21. The external hemorrhoidal artery to the verge of the anus.

22. The artery to the perineum, which gives off

23. The transverse artery of the perineum, and then divides into

24. A superficial, and

25. A deep-seated branch; the former running between the erector penis and accelerator urinæ, to be distributed upon these parts and the back of the scrotum; the deep-seated branch supplying the deep-seated fascia.

26. The branches to the bulb of the urethra.

27. The branch to supply the prostate gland.

The internal iliac artery, having left the trunk of the common iliac, runs immediately into the pelvis, where it gives off the following branches. The ilio lumbalis, supplying the iliacus internus and psoas muscles. The lateral sacral, one or two small vessels supplying the sacrum, descending on that bone to the os coccygis, where it inosculates with the ramifications of the middle sacral artery. The lateral hemorrhoidal,—several small branches to the rectum. The gluteal, termed also posterior iliac; a large branch running out of the pelvis, through the superior part of the ischiatic notch, above the pyriformis, passing upwards to the posterior part of the pelvis, under the gluteus maximus dividing into two branches, the external branch passing between the gluteus maximus and medius, supplying these muscles and the sacro-ischiatic ligaments; the deep-seated branch passing between the gluteus medius and minimus to the anterior superior spinous processes of the ilium, sending off branches to the muscles of this part and the capsular ligament of the hip-joint; before the gluteal artery divides into the two branches above enumerated, it sends off ramifications to the sacrum, os coccygis, rectum, and the muscles situated within the pelvis. The hypogastric, which, in the fœtus, is the artery that conveys the blood back to the placenta; in the adult, this artery passes to the side of the bladder; it gives branches, in the female, to the neck of the uterus, sending branches to the vagina. The ischiatic, passing out of the pelvis by the ischiatic notch; below the pyriformis it divides into many branches, supplying the gluteus maximus, levator ani, and ischiatic nerve. The obturator artery is sometimes given off from the gluteal,\* passes forwards to the obturator foramen, the superior part of which it traverses: at its exit from the pelvis it divides into an anterior and posterior branch; the former descends between the adductor muscles which it supplies; also, the obturator externus, pectinalis, vastus internus, and the integuments on the

\* This artery, (the obturator) as to its origin, presents many anomalies, being given off at least once in ten times from other branches than the hypogastric.

inner part of the thigh, and anastomoses with a branch of the posterior; the latter passes beneath the quadratus femoris, supplying the back part of the thigh.

The internal pudic artery passes out of the pelvis, above the superior ischiatic ligament, twists round it, and returns within the pelvis above the inferior ischiatic ligament, descends on the inside of the tuber ischii, then ascends on the inner surface of the ramus of the ischium, and the ramus of the pubis; in its course it gives off the external hæmorrhoidal, as it passes by the anus.

The artery to the perineum, dividing into the transverse artery of the perineum. The superficial artery, to be distributed upon the muscles, and passing in a hollow or depression between the erector penis and accelerator urinæ, to ramify ultimately upon the back part of the scrotum, and the deep-seated branch to the deep-seated fascia, bulb, and adjacent parts. The pudic artery then sends a branch to the prostate gland, and, having gained the arch of the pubis, divides into three arteries,—the dorsalis penis, the branch to the corpus cavernosum, and the branch to the corpus spongiosum. The dorsalis penis runs upon the dorsum of the penis, and is placed at the side of the vena magna penis, so that the vein is situated between the two arteries of the dorsum of the penis.

The branch to the corpus cavernosum enters the crus of that body, and ramifies into numerous branches, which terminate in its cellular structure, which receives the blood from the open mouth of the artery; the branch to the corpus spongiosum enters it, and is distributed upon it.

---

## ORGANS OF GENERATION IN THE FEMALE, AND DISSECTION OF THE PERINEUM.

THE organs of generation in the female are divided into the external and the internal; the former consisting of the following:—the mons veneris, an eminence situated in the front of the pubis, between the groins, being covered with hair; this eminence is formed by adipose tissue, deposited immediately beneath the skin. From the centre of the inferior portion of the mons veneris, there is a thick elongated fold of the skin, containing adipose and cellular substance on each side, which extend towards the anus; these are the labia, which are united behind by a line of a crescentic shape, termed frænum, or commissure. Between the two labia, a longitudinal fissure is to be observed, named vulva, or pudendum, which extends to within an inch of the anus; and the space behind to the anus is termed the perineum. By separating the labia, the clitoris will be seen, which arises by two crura resembling the origin of the penis; they

are attached to the inner part of the tuber ischii and pubis, ascend towards the pubis, unite, and constitute this cylindrical body, terminating in front by forming the glands clitoridis, which is covered above and laterally by a loose fold of membrane, termed prepuce; under which sebaceous glands are deposited, similar to the glandulæ odoriferæ of the penis. From the prepuce, two membranous folds (termed nymphæ) descend to about the middle of the opening of the vagina. In the same perpendicular line as the clitoris, but about an inch below it, the opening of the urethra is placed, termed meatus urinarius; its margin being thick and prominent, and of a roundish form. Immediately below this opening, is the one to the vagina, which, in the virgin, has a membranous duplicature attached to its sides, denominated the hymen, placed just within the orifice of the vagina; it is generally of a crescentic shape, the concavity being upwards. When this is broken down, several fleshy eminences are left, of a reddish color (the carunculæ myrtiformis.)

For the purpose of dissecting the perineum in the female, the subject should be placed in the same position as that described for the male, and the skin may be removed from the tuber ischia, and also between the arch of the pubis to the os coccygis. The muscles may be then dissected, consisting of

1st. The erector clitoridis, arising from the inner border of the tuber ischii, which proceeds upwards to be inserted into the crus clitoridis.

*Action*,— to draw the clitoris downwards and backwards

2dly. The transversi perinei, which extend across the perineum, in the same manner as in the male.

3dly. The sphincter vaginæ, arising from the body of the clitoris, descends on each side the vagina, immediately behind the labia, to the outer part of the perineum, to be inserted and intermixed with the sphincter ani and transversi perinei. *Action*,— to contract the orifice of the vagina.

4thly. The sphincter ani,	} Origin, insertion, and use, the same as in the male.
5thly. The levator ani,	
6thly. The coccygeus.	

The internal parts of generation may next be examined; and, for this purpose, it will be necessary to remove one of the ossa innominata, in the same manner as for the examination of the male pelvis. When this has been accomplished, the bladder and rectum will be found to hold the same situation as they do in the male. The urethra will be seen to be of about three inches in length, having several lacunæ opening into it and the orifice of Cowper's ducts; the blad-

der and rectum will be found to be covered in the same manner with peritoneum as in the male, and between them the vagina, uterus, Fallopian tubes, and ovaria, are placed.

The vagina is a membranous canal, situated in the middle of the pelvis, between the bladder and rectum, about six inches in length, and extends from the *caruncula myrtiformis* to the neck of the uterus; the upper end is attached to the whole external part of the cervix of the uterus, so that the orifice of the uterus hangs, as it were, pendulous in the vagina. The external orifice of the vagina is surrounded by the sphincter, and when these fibres are removed, a spongy substance, of a dark blue color, is exposed, which also surrounds the vagina, named the *plexus retiformis*. The anterior surface of the vagina is united to the bladder by cellular substance, and to the urethra also by cellular substance, which is of a much firmer texture. The posterior surface of the vagina is attached to the rectum at its two inferior thirds, and to the peritoneum at its upper third.

The uterus is a triangular body, the greatest breadth being in the transverse direction, situated obliquely in the pelvis, between the bladder and rectum; its superior part termed *fundus*, its middle portion the body, and its lower or contracted part *cervix*, which is principally seated in the vagina, although it may be observed externally. In the lower end of the cervix there is an oval opening, the longest diameter being in the transverse direction, termed *os internum*, or *os tinæ*.

The Fallopian tubes are two small and tortuous canals, between four and five inches long; each tube arises from the upper and outer border of the uterus, passes transversely outwards in the upper portion of the broad ligament, to terminate in a loose margin, which has a fringed-like appearance, hence termed *fimbriated extremity*. The tube is of a trumpet shape, the broadest part being the *fimbriated extremity*, which pierces the peritoneum, forming a communication between the inferior of the tube and cavity of the abdomen. The portions which constitute the *fimbriæ* are not of equal length, and the longest extends backwards to the ovary.

The ovaries are two oblong and flattened bodies, being inclosed in the broad ligament; they contain from twelve to fourteen ova, and, after conception, a space is left which was previously occupied by one of these ova, which space is called *corpus luteum*.

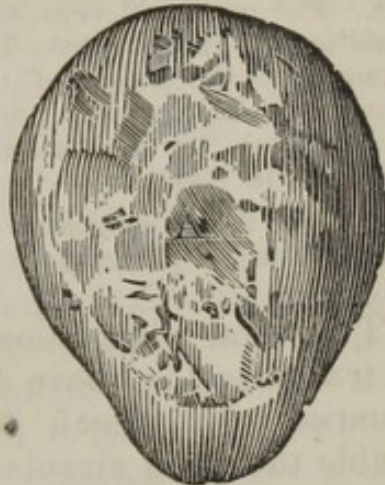The peritoneum, after being reflected over the rectum, forms a *cul de sac* between that intestine and the uterus and vagina. It is then reflected over the *fundus* of the uterus, also over the Fallopian tubes and ovaries, so as to form the lateral ligaments, which connect the uterus to the sides of the pelvis, containing the Fallopian tubes and ovaries. The peritoneum is then reflected over the anterior part of the uterus, and forms another *cul de sac* between the uterus and bladder. (See reflection of the peritoneum, page 154.)

Besides these ligaments of the uterus, there are two others, termed round ligaments, tendinous cords arising from the upper angle of the uterus, in front of, and below the Fallopian tubes. Each ligament proceeds outwards, upwards, and forwards, within the lateral ligament, to the inner opening of the inguinal canal, through which it passes, and terminates by becoming expanded, and being intimately connected to the upper part of the cellular and adipose substance composing the labia.

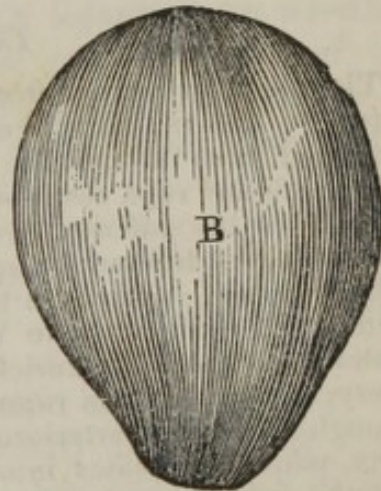
*Of the Gravid Uterus.*

When an ovum has been conveyed into the cavity of the uterus, through the Fallopian tube, impregnation is said to have taken place. The ovum when first visible has a smooth surface, but in a short time it sends off flocculent branches, the greater part being converted into or forming the placenta. The ovum consists of a capsule, inclosing the embryo or fœtus, the umbilical cord, and the waters; the capsule consists of an external layer, the spongy or false chorion, the true chorion, and the amnion.

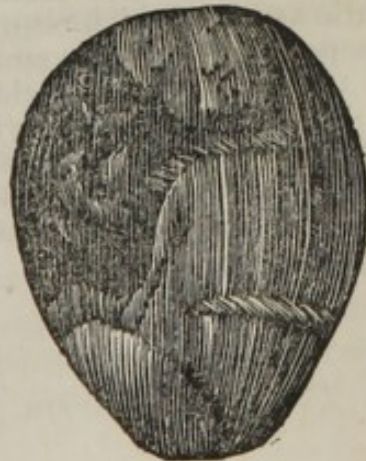A. The spongy chorion; a thick opaque membrane which adheres to the uterus, and forms the outer layer of the ovum or embryo. Between the uterus and placenta it is less distinct, being perforated and in part concealed by the vessels proceeding from the uterus. This membrane has a spongy and villous appearance, and is full of small blood-vessels, which can be injected from those of the uterus.



B. The true chorion; a thin, smooth, dense membrane, connected to the spongy chorion, as far as the edge of the placenta, where it separates from it to be reflected over the surface of the placenta nearest the fœtus, and also over the whole of the cord. This membrane is uniform in its texture, has somewhat of a transparent appearance, and adheres to the spongy chorion and surface of the placenta by delicate cellular substance.



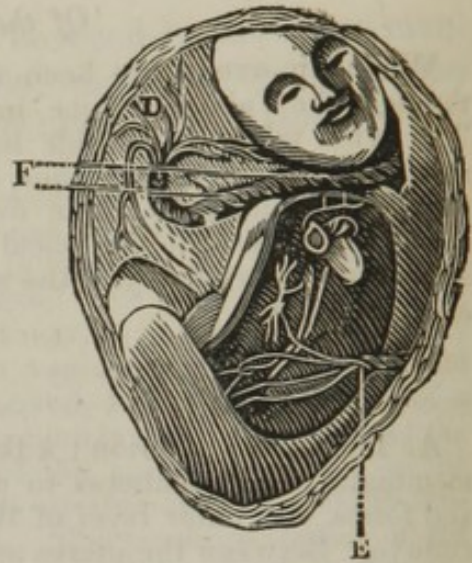
C. The amnion; a thin, transparent, and a more dense membrane than the chorion, adhering to it everywhere by a kind of serum resembling jelly; it is reflected over the placenta and cord, forming its outer covering. This membrane is smooth and polished on the side next the fœtus, and gives origin to the fluid or liquor amnii, in which the child floats.



D. The placenta; a spongy mass of an irregular round form, occupying nearly the fourth part of the ovum. It is connected to the uterus by the vessels and spongy chorion, and this surface is divided into deep fissures, while the internal, or that next the fœtus, forms an irregular mass, which has numerous large branches of the umbilical vessels dispersed upon it.

E. The umbilical vein, entering the umbilicus of the fœtus. This vein is formed by the union of the several branches which ramify upon the placenta, being the continuation of the cells of the placenta.

F. The two hypogastric arteries, which return the blood back from the child to the placenta.



The fœtal circulation has been here delineated, and may be traced in the above diagram. The fœtus is placed in the situation of a breech presentation, which has been done to enable the fœtal circulation to be better understood.

#### *The Fœtal Circulation.*

The blood is carried from the placenta, through the umbilicus of the fœtus, by the umbilical vein, to the sinus of the vena porta; a part of the blood runs through the liver, and a part through the ductus venosus to the inferior vena cava, or to one of the venæ cavæ hepaticæ; it then passes into the inferior cava, to the right auricle of the heart, where it passes by two different passages; one part of the blood runs through the foramen ovale, situated in the septum auriculorum, into the left auricle, then in the left ventricle to the aorta; the other portion of the blood passes from the right auricle to the right ventricle, into the pulmonary artery, a small portion running to the lungs, but the major part passing through the ductus arteriosus into the aorta; the blood passes down the aorta, which bifurcates into the common iliacs, which again bifurcate into the internal and external iliacs, the internal sending off the hypogastric arteries, which return a portion of the blood back to the placenta. The peculiarities of the circulation are, 1st. The umbilical vein conveying the blood to the child, afterwards forming the ligamentum teres. 2d. The ductus venosus, which becomes obliterated. 3d. The foramen ovale, which becomes closed. 4th. The ductus arteriosus, forming afterwards the ligamentum arteriosum. 5th. The two hypogastric arteries, conveying the blood back to the placenta.

## DISSECTION OF THE PARTS CONNECTED WITH INGUINAL HERNIA.

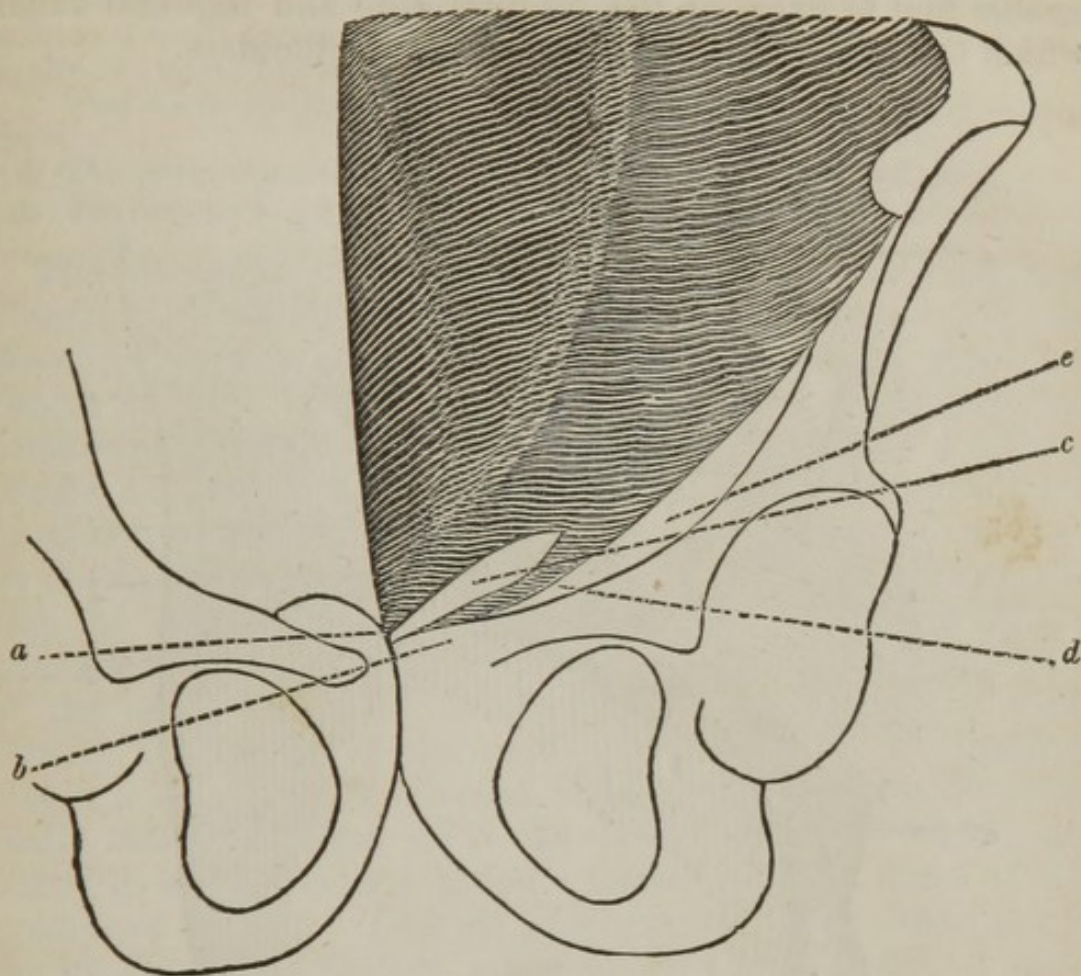
THE subject being placed upon the back, the pelvis is to be raised by a block put beneath it, or the thigh and leg may be left hanging over the edge of the table. The dissector must now make an incision, commencing an inch above the anterior superior spinous process of the ilium, to the linea alba; the incision is then to be carried along the linea alba to the os pubis, and the skin may be reflected towards Poupart's ligament. This will bring into sight adipose and cellular tissue, varying in quantity and density in different subjects, and denominated fascia superficialis. It is placed upon the external oblique muscle, and contains between its laminæ the external epigastric artery; as it passes over the spermatic cord, when it makes its exit from the external ring, it contains the external pudic artery. The fascia is reflected over Poupart's ligament, to which it is attached, and from thence to the anterior part of the thigh. It also passes over the cord, forming a lining to the scrotum, to which it is firmly connected; and at the raphé of the scrotum, the fascia is reflected upwards, towards the pubis, to which it is attached; so that between the two testes there is a doubling of the fascia, which constitutes the septum between the two, and by which means the fascia also forms a bag, for the reception of each of these two glands. The two layers of the septum are but loosely connected, as may be easily demonstrated by holding them between the finger and thumb, when they can be felt to slide over one another. The superficial fascia may now be reflected, by an incision similar to the first, when the obliquus abdominis externus will be exposed; but, superficial to its tendon, several lines are to be observed running in a semicircular manner, the convexity of which are placed upwards and outwards. This is the intercolumnar fascia, or aponeurosis of the external oblique; it serves to unite the tendinous fibres of the oblique more firmly together. It descends, being reflected, over the cord, constitutes one of its coverings, and, by being placed over the cremaster muscle, has



been nominated fascia cremasterica,\* and completely encircles the cord. Without this fascia is removed by dissection, or reflected, the external ring cannot be exposed, as it passes directly before it, and in some way fills up the slight space that would otherwise exist between the cord and the two pillars of the external oblique. This fascia being removed, the external ring may be examined. It is found to be composed or formed by a decussation of the tendinous fibres of the external oblique, or by two pillars or columns; the upper one runs over the spermatic cord, to be inserted into the pubis of the opposite side, that on the right side generally running over the one on the left; the lower pillar passes beneath the cord, to be inserted into the crista of the pubis: thus, between the pillars or columns a triangular opening is formed, the base of which corresponds with the crista of the pubis, and the sides with the two columns above named. This opening is the external abdominal ring, being for the passage of the spermatic cord and cremaster muscle in the male, and the round ligament in the female. The two pillars or columns are nothing more than the two pubic insertions of the external oblique muscle; and the third insertion of this muscle forms the crescentic arch.

The following diagram points out the three insertions of the external oblique.

\* Fascia spermatic, or fascia of the cord. — "This thin fascia may be detached from the cord, so as to exhibit clearly the margins of the pillars, by holding the cord forward; and lightly drawing the edge of the scalpel all round it, so as to divide the fascia, after which it can be readily pushed upwards." — *Quain's Elements of Anatomy*, page 324.



*a.* The first insertion of the external oblique, or superior column or pillar, which passes over the cord, and is inserted into the symphysis pubis and pubis on the opposite side.

*b.* The second insertion, or inferior column or pillar, running beneath the cord, to be inserted into the spine of the pubis.

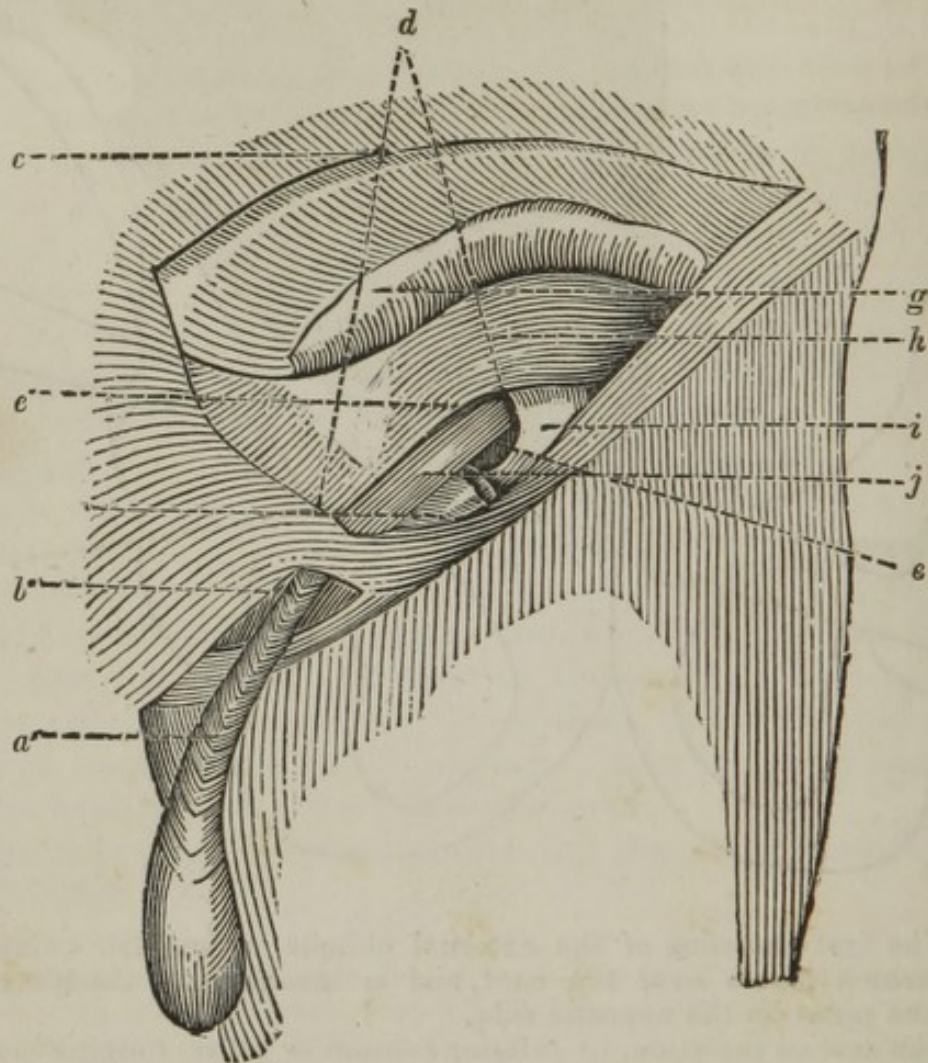
*c.* The external abdominal ring, formed between the two insertions or columns.

*d.* The third insertion of the external oblique passes backwards to be attached to the crest of the pubis forming a crescentic arch. This insertion is more particular to the seat of femoral hernia, and is the same which is called Gimbernat's ligament.

*e.* The crural arch for the passage of the femoral vessels.

The dissector having examined the formation of the external ring, may now endeavor to trace the fibres of the cremaster muscle, which pass out through it, being sent from the under edge of the internal oblique. These fibres generally pass down in a semicircular form, having one portion occasionally attached to the pubis. He may now make an incision in the course of Poupart's ligament, commencing above the external ring, almost in a semicircular manner; this will

enable him to examine the internal ring and inguinal canal, which the following diagram purposes to elucidate.



*a.* The spermatic cord\* passing through the external abdominal ring, with fibres of the cremaster muscle seen upon it.

*b.* The external abdominal ring.

*c.* The tendon of the external oblique, reflected by an incision made in the course of Poupart's ligament, carried above the ring toward the linea alba, for the purpose of showing the inguinal canal and internal ring.

*d.* The inguinal canal, situated between the two rings. The boundaries of this canal consist of the tendon of the external oblique on the anterior part or towards the skin, the internal oblique at the upper part, Poupart's ligament at the lower part, and the transversalis muscle and fascia at the posterior part, or towards the abdomen.

*e.* The internal ring, formed by the fascia transversalis, and the epigastric artery, seen passing round the inner part of the internal ring.

\* The spermatic cord consists of the spermatic artery, arising from the aorta; the spermatic vein, entering into the vena cava on the right side, and the emulgent vein on the left side; the artery of the cord, a branch of the epigastric, the vas deferens and its artery, a branch of the internal iliac, the spermatic plexus of veins, lymphatic, and the cremaster muscle.

*g.* The internal oblique partially reflected, to show the internal ring. It forms a small portion of the anterior boundary of the canal, but principally the upper boundary.

*h.* The transversalis muscle, forming the posterior boundary of the canal.

*i.* The fascia transversalis, forming the internal abdominal ring.

*j.* The spermatic cord, situated in the inguinal canal.

The dissector, by reflecting the parts as described, will observe that the internal ring is placed about two inches on the outer part of the external ring, and that the space between the two is an oblique passage, termed the inguinal canal, containing the spermatic cord. Particular attention should be paid to the boundaries of the passage, also to the formation of the internal ring, which is composed or formed by the fascia transversalis, and that at the inner part of the ring the epigastric artery is situated, being a branch of the external iliac; and as this artery runs round the inner part of the cord, that it sends a small branch along the cord, termed the artery of the cord. Anteriorly to the internal ring, the transversalis muscles occasionally encircle the spermatic cord, and send off a circular set of fibres, which surround it, and ultimately become mixed with the fibres of the cremaster muscle. This set of fibres was first pointed out to me by Sir Astley Cooper, since which I have observed them on several occasions.

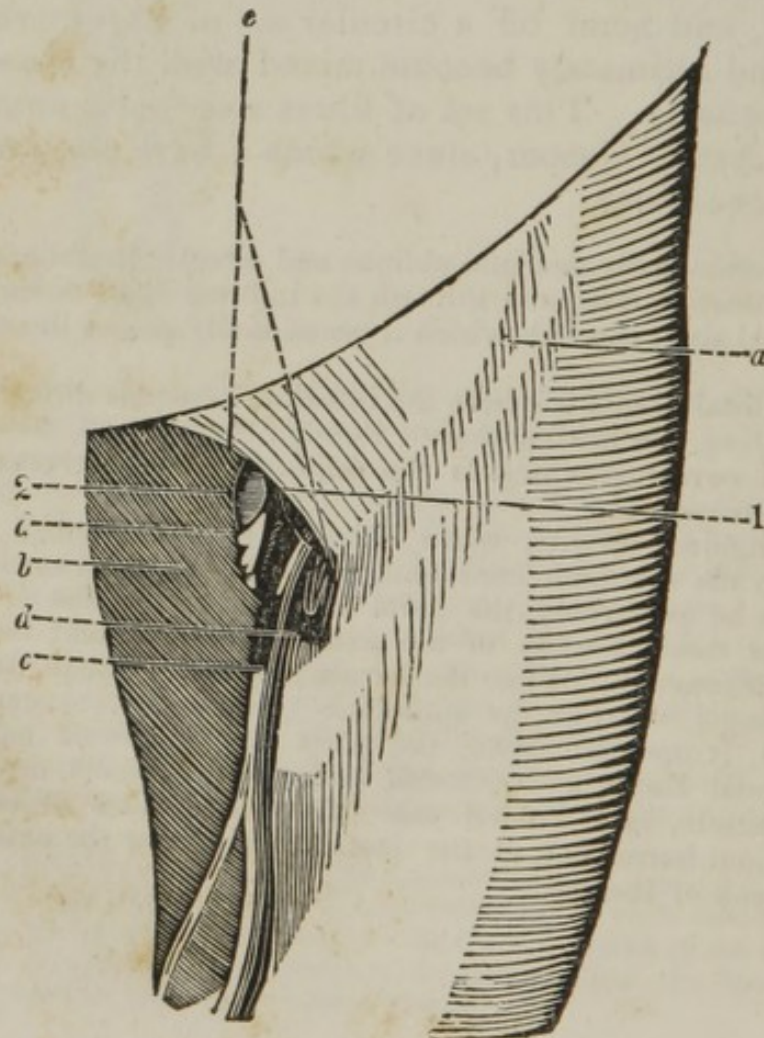
Inguinal hernia is divided into oblique and direct. In oblique inguinal hernia, the intestine descends through the internal ring, down the canal to the external ring, through which it occasionally passes down as far as the scrotum.

Direct inguinal hernia is where the intestine descends directly through the external ring, not having passed through the internal, taking with it an additional covering, which is the union of the transversalis tendon and fascia transversalis.

Oblique inguinal hernia, when situated in the inguinal canal, is directly upon the spermatic cord, and, consequently, if strangulated, and the operation be performed, the parts cut through consist of the skin, intercolumnar fascia, tendon of the external oblique, and hernial sac, formed by peritoneum. When the hernia descends through the external ring, it is placed between the spermatic cord and cremaster muscle; consequently, if operated upon, the parts divided would be, first the skin, superficial fascia, and external pudic artery, fascia cremasterica, cremaster muscle, and hernial sac. The three seats of stricture of oblique inguinal hernia are, at the internal ring, near the external ring, and at the neck of the sac.

### DISSECTION OF THE PARTS CONNECTED WITH FEMORAL HERNIA.

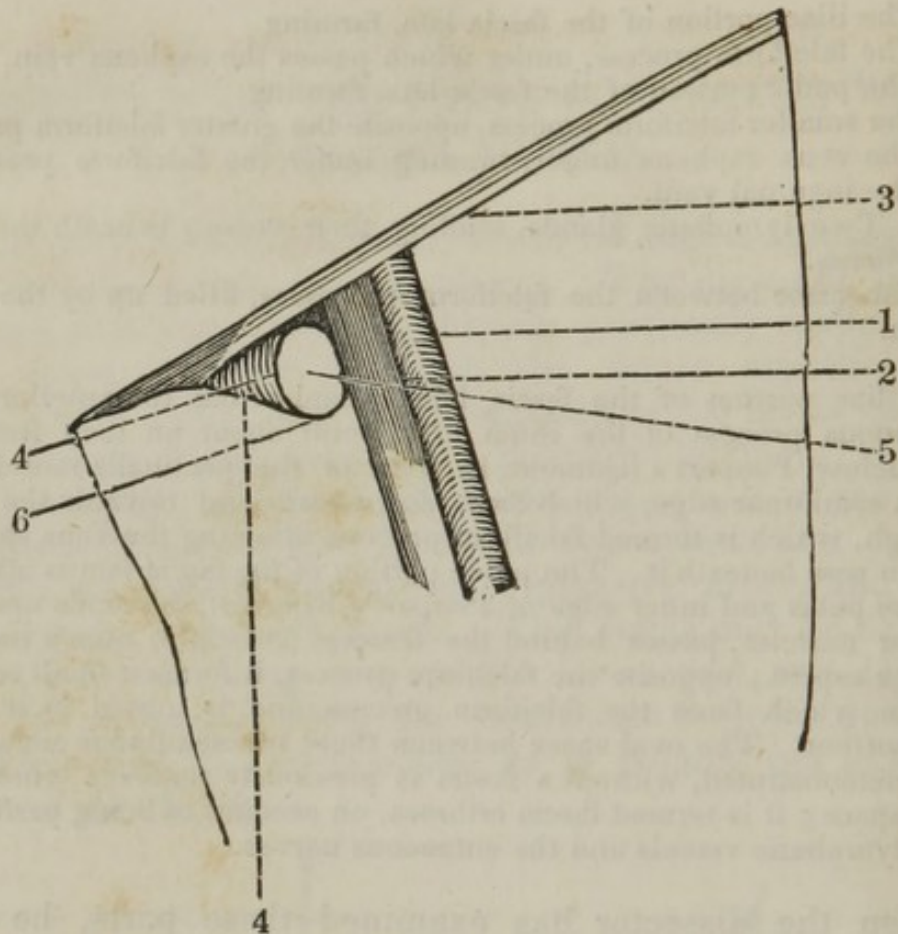
THE parts of femoral hernia are to be more advantageously examined in a thin female subject. The dissector is to reflect the skin very carefully, having previously rendered the parts tense. When removed, the fascia superficialis is brought into sight; it is a prolongation of the fascia covering the abdomen, which passes over Poupart's ligament, to which it is connected, and descends on the upper half of the thigh. It adheres firmly to the skin and fascia lata, and contains between its laminæ the external epigastric artery and absorbent vessels, with their glands. This fascia may be carefully reflected, by elevating it from the lower part and laying it over the abdomen, when the fascia lata is to be dissected, which consists of two portions, as is pointed out in the accompanying diagram.



- a.* The iliac portion of the fascia lata, forming
  1. The falciform process, under which passes the saphena vein.
- b.* The pubic portion of the fascia lata, forming
  2. The smaller falciform process, opposite the greater falciform process.
- c.* The vena saphena major, running under the falciform process to enter the inguinal vein.
- d. d.* Two lymphatic glands, sending their vessels beneath the falciform process.
- e.* The space between the falciform processes, filled up by the fascia cribrosa.

The iliac portion of the fascia lata extends from the anterior superior spinous process of the ilium to a point about an inch from the pubis, below Poupart's ligament, in front of the pectinalis muscle. It forms a semilunar edge, which faces downwards and towards the opposite thigh, which is termed falciform process, allowing the vena saphena major to pass beneath it. The pubic portion of the fascia lata is attached to the os pubis and inner edge of Poupart's ligament, descends upon the adductor muscles, passes behind the femoral vessels to attach itself to the linea aspera; opposite the falciform process, it forms a small semilunar edge, which faces the falciform process, and is united to it at its lower portion. The oval space between these two semilunar edges cannot be demonstrated, without a fascia is previously removed which fills up the space; it is termed fascia cribrosa, on account of being perforated by the lymphatic vessels and the cutaneous nerves.

When the dissector has examined these parts, he may make a transverse incision, about three inches below the falciform process, and reflect it towards the abdomen, which, when done, will expose the sheath containing the inguinal or femoral artery and vein. This sheath being formed, at its anterior part, by the prolongation of the fascia transversalis, and at its posterior part by the fascia iliaca, which two fasciæ unite both at the outer and inner part, it is somewhat of the shape of a funnel, and consequently called fascia infundibuliformis, or crural sheath. Internally, between the inguinal artery and vein, the sheath sends off a process which separates the artery and vein. The dissector may now carefully divide this sheath at the lower part, and reflect its upper portion towards the abdomen, when he will observe the femoral vein on the inner side of the artery, or nearer the pubis; and between the vein and third insertion of the external oblique, a lymphatic gland will be seen. This must be removed, when the aperture through which femoral hernia passes is to be examined, and for the purpose of conveying a knowledge of its boundaries, I have added the following diagram.



1. The femoral artery, passing beneath Poupart's ligament.
2. The femoral vein, passing under Poupart's ligament on the pubic side of the artery.
3. Poupart's ligament.
4. The crescentic arch, third insertion of the external oblique, or Gimbernat's ligament.
5. The aperture through which the intestine descends in femoral hernia, which is filled up by a lymphatic gland. This aperture, or crural ring, is seen to be bounded anteriorly by Poupart's ligament, posteriorly or inferiorly by the pubis, internally by the crescentic arch, or third insertion of the external oblique muscle, and externally by the inguinal vein.
6. The posterior boundary, consisting of the pubis.

The crural ring, or aperture, cannot be distinctly seen until the pectinalis has been in some way removed, and it is found to be closed or filled by a lymphatic gland. Femoral hernia descends beneath Poupart's ligament, upon the pubis, externally to the crescentic arch, or third insertion of the external oblique, and internally to the femoral vein, situated within the sheath of the artery and vein, but separated from the vein by a septum formed by the sheath of the vessels, occupying the same situation as a lymphatic vessel does in

the healthy subject. Owing to the strong connexion of the sheath and adjacent parts below, the tumor cannot descend far down the thigh, but as the anterior part is the weakest, it consequently protrudes beneath the falciform process, and if of a large size, the tumor passes upwards over Poupart's ligament; therefore, the hernial tumor may truly be said to embrace Poupart's ligament. Now, should it be of a small size, and require to be operated upon, the parts to be divided consist of the skin, the fascia superficialis which contains the external epigastric artery, the falciform process, fascia propria, and hernial sac. Should the tumor be of a larger size, the parts consist of the skin, fascia superficialis, with the external epigastric artery; when the back of the tumor is seen reflected over Poupart's ligament, which must be turned down; the fascia propria is to be divided, and then the hernial sac. The three usual seats of stricture, are at the falciform process, crescentic arch, or third insertion of the external oblique muscle, and at the neck of the sac.

The fascia transversalis is a thin, smooth membrane, placed between the transversalis muscle and peritoneum. It may be traced upwards as far as the margin of the ribs, gradually becoming thinner; at its lower part it is connected to Poupart's ligament, to every portion, except where the artery and vein pass beneath it, at which place it sends off a process over these vessels. At the outer portion of Poupart's ligament, it is connected to the fascia iliaca. If traced behind the rectus, the fascia is reflected over the inner part of the pubis to the floor of the pelvis. About, or near the centre of Poupart's ligament, a quarter of an inch above it, it forms the internal abdominal ring, and sends off a thin expansion to accompany the spermatic cord towards the external abdominal ring.



# I N D E X .


	Page.		Page.
Abdomen, dissection of . . . . .	136	Arytenoideus obliquus . . . . .	118
region of . . . . .	ib.	transversus . . . . .	ib.
Abdominal aorta . . . . .	171	Aryteno-epiglottideus . . . . .	ib.
Abductor pollicis pedis . . . . .	39	Azygos uvulæ . . . . .	121
— manus . . . . .	71	Back, dissection of . . . . .	175
minimi digiti pedis . . . . .	39	Basilic vein . . . . .	54, 56
oculi . . . . .	124	Biceps flexor cruris . . . . .	26
Accelerator urinæ . . . . .	191	— cubiti . . . . .	58
Accessorius nervus . . . . .	97	Bile, secretion of . . . . .	164
Acetabulum . . . . .	43	Bladder . . . . .	194
Acromic-clavicular articulation . . . . .	83	Brachialis internus . . . . .	58
— dislocation of . . . . .	84	Brain, dissection of . . . . .	184
Adductor longus . . . . .	7	Buccinator . . . . .	94
magnus . . . . .	ib.	Cæcum intestinum . . . . .	161
brevis . . . . .	10	Calcis, long ligament of . . . . .	41
pollicis pedis . . . . .	40	Capsule of Glisson . . . . .	164
— manus . . . . .	71	Carotid artery, common . . . . .	103
oculi . . . . .	124	external . . . . .	106
ossis metacarpi min- imi digiti . . . . .	71	Cartilage, semilunar . . . . .	47
Alaria ligamenta . . . . .	47	Cephalic vein, . . . . .	54, 65
Anconeus . . . . .	80	Cervicalis descendens . . . . .	178
Ankle, ligament of . . . . .	50	Chylopoietic viscera . . . . .	156
tendons surrounding dislocations of . . . . .	51 ib.	Coccygeus . . . . .	193
Annular ligament of the foot . . . . .	20	Colon . . . . .	161
— the fore arm . . . . .	67	Complexus . . . . .	178
— posterior . . . . .	80	Compressor nares . . . . .	93
Anterior auris . . . . .	90	Constrictor pharyngeus inferior . . . . .	118
Arm, dissection of posterior part of . . . . .	77	— medius . . . . .	119
— anterior part of . . . . .	52	— superior . . . . .	ib.
— anterior part of the fore . . . . .	64	isthmi faucium . . . . .	121
— the posterior . . . . .	79	Coraco-brachialis . . . . .	58
Arytenoid cartilages . . . . .	116	Corrugator supercillii . . . . .	93
		Cotyloid cartilage . . . . .	42
		ligament . . . . .	43
		Cremaster muscle . . . . .	140
		Cricoid cartilage . . . . .	116

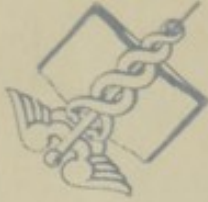- Crico-thyroideus . . . . . 101  
 Crico-arytenoideus posticus . . . . . 119  
     — lateralis . . . . . ib.  
 Crucial ligaments . . . . . 48  
 Crural nerve, anterior . . . . . 10  
 Cutaneous nerve, internal . . . . . 58, 65  
     — external muscular, . . . . . 59, 65  
 Deltoid ligament . . . . . 50  
     muscle . . . . . 55  
 Depressor labii inferioris . . . . . 94  
     — superioris alæ-  
         que nasi . . . . . 96  
         oculi . . . . . 124  
 Diaphragm . . . . . 151  
 Digastricus . . . . . 97  
 Digiti flexor brevis minimi . . . . . 41  
 Digitorum extensor longus pedis . . . . . 19  
     — brevis . . . . . 20  
     flexor longus . . . . . 34  
     flexor brevis . . . . . 39  
     flexor sublimis . . . . . 67  
     — profundus . . . . . 68  
 Ductus cysticus . . . . . 166  
     hepaticus . . . . . 165  
 Duodenum . . . . . 159  
 Elbow joint . . . . . 84  
     ligaments of . . . . . 85  
     dislocations of . . . . . ib.  
 Epiglottis . . . . . 115  
 Erector penis . . . . . 191  
     clitoridis . . . . . 203  
 Extensor carpi radialis longior  
     et brevior . . . . . 80  
     digitorum communis . . . . . ib.  
     carpi ulnaris . . . . . ib.  
     secundi internodii pol-  
         licis . . . . . 81  
     primi . . . . . ib.  
     ossis metacarpi . . . . . ib.  
 Extremity, dissection of superior . . . . . 52  
 Eye . . . . . 127  
 Facial artery . . . . . 96  
 Fallopian tubes . . . . . 204  
 Fascia of the arm . . . . . 54  
     fore-arm . . . . . 65  
     anterior part of the leg . . . . . 18  
     — the thigh . . . . . 4  
     posterior part of the thigh . . . . . 24  
     — of the leg . . . . . 29  
     plantar . . . . . 39  
     temporal . . . . . 95  
     transversalis . . . . . 215  
 Femoral artery . . . . . 11  
 F. artery, method of securing . . . . . 15  
     hernia, anatomy of . . . . . 212  
 Fibular artery . . . . . 32, 36  
     — ligaments of . . . . . 49  
 Flexor brevis pollicis manus . . . . . 71  
     — minimi digiti . . . . . ib.  
     carpi radialis . . . . . 76  
     — ulnaris . . . . . ib.  
     — sublimis . . . . . 68  
     digitorum profundus . . . . . ib.  
     longus pollicis . . . . . ib.  
 Fœtal circulation . . . . . 206  
 Foot, ligaments of . . . . . 52  
 Foramen of Winslow . . . . . 155  
 Fore-arm, dissection of ante-  
     rior part of . . . . . 64  
     — posterior part of . . . . . 79  
 Gastrocnemius . . . . . 30  
 Geminus superior and inferior . . . . . 26  
 Generation, female organs of . . . . . 202  
 Genio-hyo-glossus . . . . . 101  
 Glosso-pharyngeal nerve . . . . . 110  
 Gluteal artery . . . . . 26  
 Gluteal artery, securing of . . . . . 28  
 Gluteus maximus . . . . . 24  
     medius . . . . . 25  
 Gracilis . . . . . 7  
 Gravid uterus . . . . . 205  
 Hand, ligaments of . . . . . 87  
 Head, dissection of . . . . . 88  
 Heart, dissection of . . . . . 148  
 Hip, capsular ligament of . . . . . 42  
     round ligament of . . . . . ib.  
     muscles surrounding . . . . . 43  
     dislocations of . . . . . 44  
     — method of reducing . . . . . 45  
 Horner's muscle . . . . . 93  
 Humeral artery, and its branches . . . . . 62  
     — remark: upon  
         securing . . . . . 63  
 Hyo-glossus . . . . . 101  
 Iliac artery, internal . . . . . 201  
 Iliacus internus . . . . . 8  
 Ilium intestinum . . . . . 159  
 Indicator . . . . . 81  
 Infra-spinatus . . . . . 78  
 Inguinal hernia, anatomy of . . . . . 207  
 Intercostal muscles . . . . . 57  
 Intercosto-humeral nerve . . . . . 59  
 Interosseal nerve . . . . . 70  
 Interossei muscles of the foot . . . . . 41  
     — of the hand . . . . . 71  
 Interosseous ligament of the leg . . . . . 49

Ischiatic nerve . . . . .	27	Lumbricales of the foot . . . . .	40
artery . . . . .	ib.	band . . . . .	68
Jejunum . . . . .	159	Lungs . . . . .	143
Jugular vein, external . . . . .	98	Lymphatic gland of the fore	
— method of bleed-		arm . . . . .	54
ing in . . . . .	99	Massa cornea Jacobi Sylvii . . . . .	40
Kidney . . . . .	168	Masseter . . . . .	95
Knee-joint, ligaments of . . . . .	46	Mediana longa vena . . . . .	54, 65
capsular ligaments of . . . . .	47	Median nerve . . . . .	58, 69
internal lateral of . . . . .	ib.	Mediastinum, the anterior . . . . .	149
external lateral of . . . . .	ib.	the posterior . . . . .	ib.
semilunar cartilages of . . . . .	ib.	Motor oculi . . . . .	124
alar ligament of . . . . .	ib.	Mucosum ligamentum . . . . .	47
mucous ligament of . . . . .	ib.	Multifidus spinæ . . . . .	179
crucial ligament of . . . . .	48	Musculo-spiral nerve . . . . .	59
muscles surrounding . . . . .	ib.	Mylo-hyoideus . . . . .	98
dislocations of . . . . .	48, 49	Neck, dissection of . . . . .	88
Lachrymal apparatus . . . . .	128	Nervus accessorius . . . . .	97
Larynx . . . . .	114	Nose, dissection of . . . . .	122
Lata, fascia . . . . .	4	Obliquus abdominis externus	
Latissimus dorsi . . . . .	175	descendens . . . . .	138
Leg, dissection of anterior part		internus ascendens . . . . .	140
of . . . . .	16	capitis inferior . . . . .	180
— posterior part of . . . . .	29	— superior . . . . .	ib.
Lenticular ganglion . . . . .	125	superior oculi . . . . .	124
Levator labii superioris alæque		inferior oculi . . . . .	ib.
nasi . . . . .	94	Obturator externus . . . . .	14
Levator anguli oris . . . . .	94	internus . . . . .	26
labii inferioris . . . . .	96	artery . . . . .	9
palati . . . . .	122	nerve . . . . .	ib.
palpebræ superioris . . . . .	124	Occipito frontalis . . . . .	93
oculi . . . . .	ib.	Omo-hyoideus . . . . .	97
scapulæ . . . . .	176	Ophthalmic nerve . . . . .	125
ani . . . . .	193	artery . . . . .	ib.
Levatores costarum longiores		Opponens pollicis . . . . .	71
et breviores . . . . .	179	Optic nerve . . . . .	133
Ligamenta alaria . . . . .	47	Orbicularis palpebrarum . . . . .	93
Ligamentum mucosum . . . . .	ib.	oris . . . . .	ib.
Ligaments of the knee-joint . . . . .	46	Orbit, dissection of . . . . .	123
clavicle . . . . .	82	Palato-pharyngeus . . . . .	119
pelvis . . . . .	182	Palmaris brevis . . . . .	66
scapula . . . . .	83	longus . . . . .	67
shoulder-joint . . . . .	ib.	Par vagum . . . . .	110
lower jaw . . . . .	183	Parotid gland . . . . .	95
wrist-joint . . . . .	86	Patella ligamenta . . . . .	47
hand . . . . .	87	dislocations of . . . . .	49
glottis . . . . .	116	Pectinalis . . . . .	7
spine . . . . .	180	Pectoralis major . . . . .	54
ribs . . . . .	181	minor . . . . .	57
Ligamentum teres of the hip . . . . .	42	Pelvic viscera . . . . .	193
patella . . . . .	47	Penis . . . . .	198
Lingualis . . . . .	101	Peritoneum, reflection of . . . . .	190
Liver . . . . .	162	fascia of . . . . .	192, 193
Longissimus dorsi . . . . .	177	Perineum, dissection of . . . . .	154

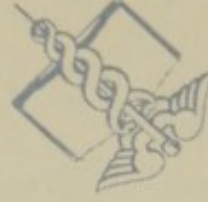- |                                      |            |   |        |
|--------------------------------------|------------|---|--------|
| Peroneal nerve . . . . .             | 18, 32, 35 | Saphena major nerve . . . . .             | 18     |
| Peroneus tertius . . . . .           | 19         | minor vein . . . . .                      | 17, 29 |
| Peroneus longus . . . . .            | 20         | — nerve . . . . .                         | 18, 29 |
| brevis . . . . .                     | ib.        | Sartorius . . . . .                       | 6      |
| Perpendicular ligament of the        |            | Scalenus anticus . . . . .                | 101    |
| ankle . . . . .                      | 50         | medius . . . . .                          | ib.    |
| Pes anserinus . . . . .              | 90         | posterior . . . . .                       | ib.    |
| Pharynx . . . . .                    | 120        | Scapula, ligaments of . . . . .           | 83     |
| Pia-mater . . . . .                  | 187        | Scapular nerve . . . . .                  | 59     |
| Pleura . . . . .                     | 146        | Semilunar cartilages . . . . .            | 47     |
| Plantar nerve, internal . . . . .    | 33         | Semi-spinalis dorsi . . . . .             | 179    |
| — external . . . . .                 | 34         | colli . . . . .                           | ib.    |
| artery . . . . .                     | 40         | Semi-membranosus . . . . .                | 26     |
| — internal . . . . .                 | ib.        | tendinosus . . . . .                      | ib.    |
| arch . . . . .                       | ib.        | Serratus magnus anticus . . . . .         | 57     |
| Plantaris . . . . .                  | 31         | posticus inferior . . . . .               | 176    |
| Platysma myoides . . . . .           | 90         | — superior . . . . .                      | 177    |
| Pollicis extensor proprius . . . . . | 34         | Shoulder-joint, ligaments of . . . . .    | 83     |
| flexor longus pedis . . . . .        | ib.        | dislocation of . . . . .                  | 84     |
| flexor brevis pedis . . . . .        | 40         | Sinus of the dura mater . . . . .         | 185    |
| — longus manus . . . . .             | 68         | Sole of the foot, dissection of . . . . . | 38     |
| Popliteal nerve . . . . .            | 27, 32     | Soleus . . . . .                          | 31     |
| vein . . . . .                       | ib.        | Sphincter ani . . . . .                   | 191    |
| artery . . . . .                     | 27         | vaginæ . . . . .                          | 203    |
| — method of secu-                    |            | Spinalis dorsi . . . . .                  | 177    |
| ring . . . . .                       | 37         | Spine, ligaments of . . . . .             | 180    |
| Popliteus . . . . .                  | 31         | Spiral muscular nerve . . . . .           | 59     |
| Pronator radii teres . . . . .       | 66         | Spleen . . . . .                          | 169    |
| — quadratus . . . . .                | 71         | Splenius capitis . . . . .                | 177    |
| Prostate gland . . . . .             | 196        | colli . . . . .                           | ib.    |
| Psoas magnus . . . . .               | 14         | Sterno-clavicular articulation . . . . .  | 82     |
| Pterygoideus externus . . . . .      | 121        | — dislocation . . . . .                   | 84     |
| internus . . . . .                   | ib.        | cleido-mastoideus . . . . .               | 97     |
| Pyramidalis . . . . .                | 141        | hyoideus . . . . .                        | ib.    |
| Pyriformis . . . . .                 | 25         | thyroideus . . . . .                      | ib.    |
| Quadrator femoris . . . . .          | 26         | Stylo-glossus . . . . .                   | 101    |
| Radial nerve . . . . .               | 67         | hyoideus . . . . .                        | 98     |
| artery . . . . .                     | 66, 72, 74 | pharyngeus . . . . .                      | 119    |
| — method of securing . . . . .       | 75         | Stomach . . . . .                         | 157    |
| Rectum . . . . .                     | 161        | Subclavius . . . . .                      | 57     |
| Rectus femoris . . . . .             | 6          | Subscapularis . . . . .                   | 58     |
| capitis posticus superior . . . . .  | 179        | Supinator radii longus . . . . .          | 79     |
| — inferior . . . . .                 | ib.        | — brevis . . . . .                        | 81     |
| abdominis . . . . .                  | 141        | Supra spinatus . . . . .                  | 77     |
| Renal capsules . . . . .             | 169        | Sympathetic nerve, great . . . . .        | 112    |
| Respiration . . . . .                | 152        | Temporal fascia . . . . .                 | 95     |
| Respiratory nerve external . . . . . | 59         | artery . . . . .                          | ib.    |
| Retina . . . . .                     | 133        | — method of open-                         |        |
| Retrahens aurem . . . . .            | 90         | ing . . . . .                             | 96     |
| Rhomboideus major . . . . .          | 175        | Tensor vaginæ femoris . . . . .           | 6      |
| minor . . . . .                      | ib.        | Teres major . . . . .                     | 78     |
| Sacro-lumbalis . . . . .             | 178        | minor . . . . .                           | ib.    |
| Saphena major vein . . . . .         | 4, 17      | Theca of carotid artery . . . . .         | 99     |

Thigh, dissection of anterior		Transversus perinei alter . . .	191
part of . . . . .	1	Trapezius . . . . .	175
— posterior . . . . .	24	Triceps extensor cubiti . . . . .	78
Thigh, external cutaneous		Tunica arachnoidea . . . . .	187
nerve of . . . . .	3	choroides . . . . .	131
Thyro-arytenoideus . . . . .	119	sclerotica . . . . .	ib.
epiglottideus . . . . .	120	Ulnar artery . . . . .	66, 68, 74
hyoideus . . . . .	101	— method of securing . . . . .	76
Thyroid cartilage . . . . .	115	nerve . . . . .	59, 69
Tibial artery, anterior . . . . .	21	Urethra . . . . .	198
— method of securing . . . . .	23	Uterus . . . . .	204
nerve, posterior . . . . .	34, 35	Vagina . . . . .	ib.
— method of securing . . . . .	37	Valve of Bauhin . . . . .	159
Tibialis anticus . . . . .	19	Vasa deferentia . . . . .	196
posticus . . . . .	34	Vastus externus . . . . .	7
Tongue . . . . .	102	internus . . . . .	ib.
Trachea . . . . .	114	Ventricles of Galen . . . . .	116
Trachelo-mastoideus . . . . .	178	Vesiculæ seminalis . . . . .	196
Transversalis abdominis . . . . .	142	Wrist-joint . . . . .	86
colli . . . . .	178	dislocations of . . . . .	87
pedis . . . . .	41	Zygomaticus major . . . . .	94
Transversus perinei . . . . .	191	minor . . . . .	ib.

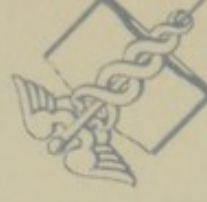



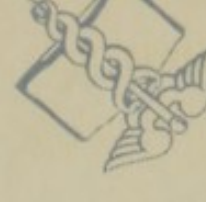Washington, D.C.



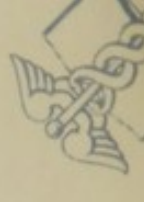U.S. Department of



Washington, D.C.



U.S. Department of



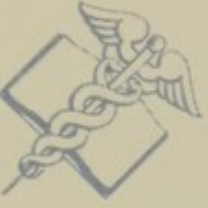NATIONAL LIBRARY OF MEDICINE

NATIONAL LIBRARY OF MEDICINE

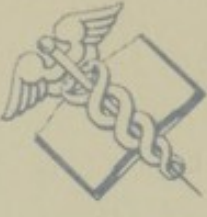NATIONAL



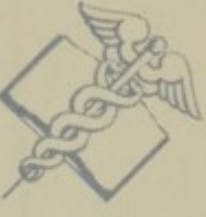Health Service



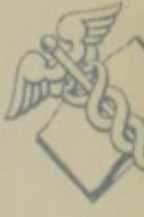Health, Education,



Health Service



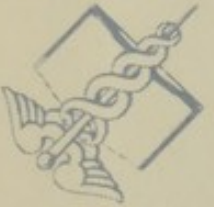Health, Education,



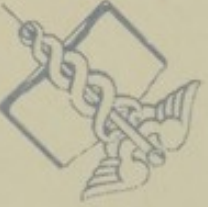NATIONAL LIBRARY OF MEDICINE

NATIONAL LIBRARY OF MEDICINE

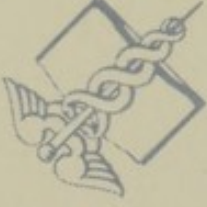MEDICINE



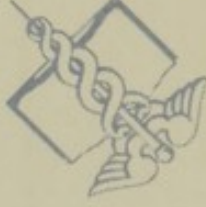and Welfare, Public



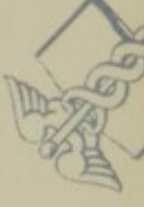and Welfare, Public



and Welfare, Public



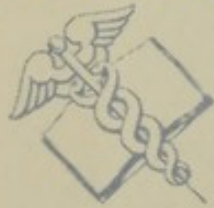and Welfare, Public



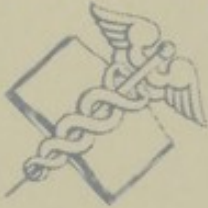NATIONAL LIBRARY OF MEDICINE

NATIONAL LIBRARY OF MEDICINE

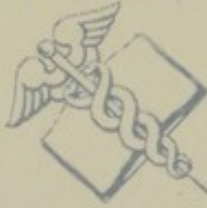NATIONAL



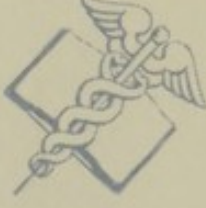Health, Education,



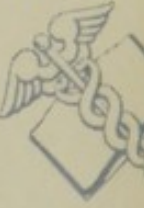Health Service



Health, Education,



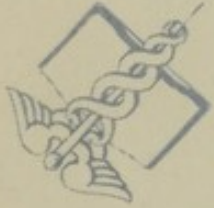Health Service



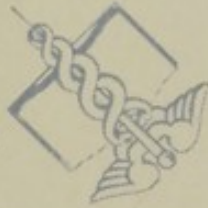NATIONAL LIBRARY OF MEDICINE

NATIONAL LIBRARY OF MEDICINE

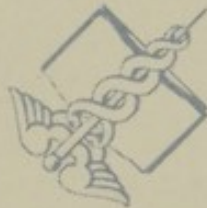MEDICINE



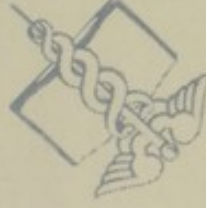U.S. Department of



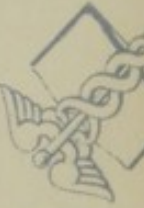Washington, D.C.



U.S. Department of



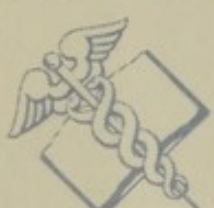Washington, D.C.



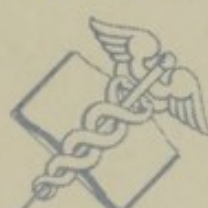NATIONAL LIBRARY OF MEDICINE

NATIONAL LIBRARY OF MEDICINE

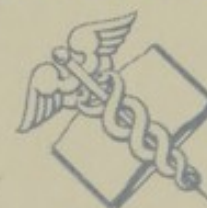NATIONAL



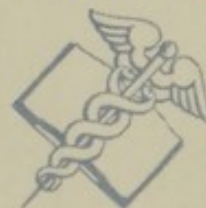Washington, D.C.



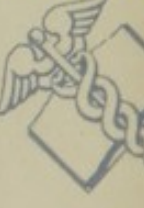U.S. Department of



Washington, D.C.



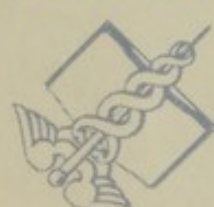U.S. Department of



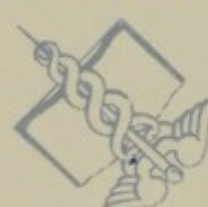NATIONAL LIBRARY OF MEDICINE

NATIONAL LIBRARY OF MEDICINE

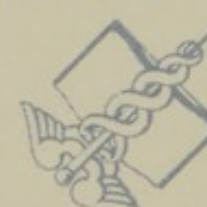MEDICINE



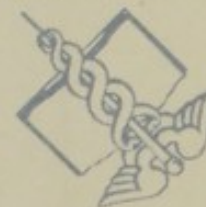
Health Service



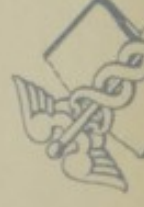Health, Education,



Health Service



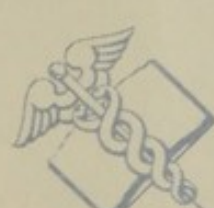Health, Education,



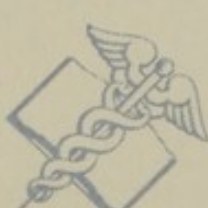NATIONAL LIBRARY OF MEDICINE

NATIONAL LIBRARY OF MEDICINE

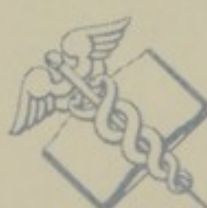NATIONAL



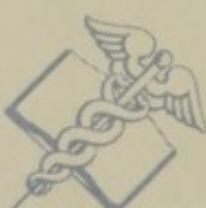and Welfare, Public



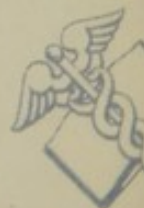and Welfare, Public



and Welfare, Public



and Welfare, Public



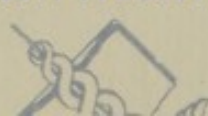NATIONAL LIBRARY OF MEDICINE

NATIONAL LIBRARY OF MEDICINE

MEDICINE



Education,




Health



Education,



Health





JUL 27 1961

Health  
Education,  
and Welfare, Public

Health  
Education,  
and Welfare, Public

Health, Education,  
and Welfare, Public

Health, Education,  
and Welfare, Public

U.S. Department of  
Washington, D. C.

U.S. Department of  
Washington, D. C.

Health Service

and Welfare, Public

Health, Education,  
and Welfare, Public

U.S. Department of  
Washington, D. C.



NATIONAL LIBRARY OF MEDICINE



NLM 01001522 7