

# **Treatment of fractures of long bones by simple extension / by John Swinburne.**

## **Contributors**

Swinburne, John, 1820-1889.  
National Library of Medicine (U.S.)

## **Publication/Creation**

Albany : Van Benthuyssen, printer, 1861.

## **Persistent URL**

<https://wellcomecollection.org/works/a52x85bx>

## **License and attribution**

This material has been provided by This material has been provided by the National Library of Medicine (U.S.), through the Medical Heritage Library. The original may be consulted at the National Library of Medicine (U.S.) where the originals may be consulted.

This work has been identified as being free of known restrictions under copyright law, including all related and neighbouring rights and is being made available under the Creative Commons, Public Domain Mark.

You can copy, modify, distribute and perform the work, even for commercial purposes, without asking permission.



Wellcome Collection  
183 Euston Road  
London NW1 2BE UK  
T +44 (0)20 7611 8722  
E [library@wellcomecollection.org](mailto:library@wellcomecollection.org)  
<https://wellcomecollection.org>

WE  
5978t  
1861



Surgeon General's Office

LIBRARY

Section, *Preventive*

No. *24036*

3  
TREATMENT


OF

FRACTURES OF LONG BONES,

BY SIMPLE EXTENSION.

By JOHN SWINBURNE, M. D.,

One of the Surgeons of the Albany City Hospital.



ALBANY:

CHARLES VAN BENTHUYSEN, PRINTER.

1861.

WE  
5978t  
1861

Film 7891. Item 6

## FRACTURES OF LONG BONES.

---

At the annual meeting of the Medical Society of the State of New York, for the year 1859, I gave my experience in the treatment of fractures of the femur by simple extension, and related the histories of twenty-five cases, which, in my hands, had resulted better, with more rapid recoveries, and more comfort to the patient, than I had been able to attain by any other means. I now propose to show that the same method can be applied to the treatment of fractures of all the long bones with equal success; and also that splints *per se* are useless, and in many instances worse than useless, if not absolutely injurious, except they are used as a medium by which the muscles are kept on the stretch.

I will endeavor to show from actual experience, first, that the practical surgeon requires no appliances for the treatment of fractures of any of the long bones, except such as are extemporaneously made; second, that the same can be said of the treatment of fractures occurring in, or in close proximity to any joint, such as intra-capsular fracture of the neck of the femur, Colles' fracture of the radius, those involving the elbow-joint, the surgical neck of the humerus, compound dislocation and fracture of the ankle-joint, compound fracture of the tibia and fibula, etc.; thirdly, that the same is true of diseased hip-joint, morbus coxarius, also incipient knee-joint disease. These several points I shall discuss separately, as well as the principles involved in the procedure. To the young surgeon I conceive this to be the most important part of surgical practice, for this reason: that in fracturing a limb, the first or most convenient physician is called in, who is surely expected to know all about this class of cases, and also the true principle involved in its treatment. On the other hand, if he should be deficient in knowledge, and the case result badly, his ultimate success as a surgeon is destroyed.

A physician will seldom be called to any important surgical case, except it be one of emergency, such as fractures, injury by

fire-arms, accidents by machinery, railroad, &c. In such instances, accident furnishes the material, while the young man must have the proper knowledge to profit by it; for it is purely accident, and not intention, that gives the surgeon employment, thereby giving the public an opportunity to distinguish between the really scientific surgeon and the charlatan.

If the surgeon has all the knowledge, and not the means, to purchase the complicated and increasing complications of surgical appliances, he is like a ship without ballast, or like a carpenter without his tools. And here I would enquire how many young practitioners have the means to purchase mechanical appliances for the treatment of fractures indiscriminately, in order that they may be able to compete with old practitioners, or be prepared for any emergency?

It has been said that *accident makes the man*. Would *accident* make the *man* if he had not the knowledge to take advantage of circumstances? I can conceive how *accident* might give us wealth; but *accident*, developing *wealth* or *social* position, and accident developing one's *mental* and scientific *resources*, are two things quite separate and distinct.

I would ask of what service are splints? What office do they perform in the treatment of fractures? Authors say they support the bone while union is being effected. I would ask, how many fractures of the long bones can be placed in apposition without the *use of extension*, particularly in oblique fractures, or where there has been great injury to soft parts, and overlapping of the bones? I know of few exceptions. The true use of splints *should* be to keep the fractured ends of the bone in apposition, by placing the muscles on the stretch, and thereby making them (the muscles) the true splints. The experiments of Reid and others show that muscles are not susceptible of being stretched beyond their normal capacity; that when so stretched, they are capable of bearing great lateral pressure without much deflection; and any attempt at undue lateral pressure results in rupture of the muscular substance.

The supporting power of the muscles may be pretty well illustrated by the following experiment: Take a strip of wood, and encircle it lengthwise with a number of cords or catgut or other strong fibre. Fasten these cords to two pieces of board, and then, by drawing these boards strongly apart, render the cords tense. The cords represent muscles; the strip of wood, bone;

and the tightening of the cords, extension and counter-extension. While the investing cords are in this tense condition, endeavor to bend the strip of wood, when it will be found that the deflection is very slight, and that fracture of the stick is impossible. Replace this strip of wood with one broken through the centre, endeavor to bend it while the cords are tense, and the deflection in this case will also be very slight. To carry out the analogy still further, let the cords be attached to the ends of the strip of wood, as the muscles are virtually at the ends of a bone. Now, if the fractured ends happen to be square (representing a transverse fracture of bone), they will be in apposition while the cords are made tense; but when the tension is relaxed the stick is no longer straight, and it bends to one side or the other as the case may be. Now, represent an oblique fracture of bone, by cutting the fractured ends of the stick to any angle, oblique or acute; while the cords are stretched by extension the ends lie in juxtaposition, but when the extension is relaxed, the ends slide past each other, and lie at rest, side by side, in the only position possible for them. Suppose this broken stick, instead of being enveloped by simple threads, was covered with muscles put upon the stretch, and bound laterally by strong investing fascial and cellular tissue, the interstices of which are filled up with fat and invested by the skin, so as to combine the separate parts in one whole, you would have then, I apprehend, splints more permanent, unyielding and enduring than any artificial appliances. How is it, for instance, where nature is left to herself, without any mechanical appliances? The bone unites, and that too without any bandages or lateral pressure, though with more or less deformity. But it unites, notwithstanding the motion which takes place almost hourly.

All that nature requires for perfect union of bone is rest and a moderate degree of excited action, while all pressure by splints, bandages, etc., only impedes the process of reparation; and this pressure, in my humble opinion, is a prolific cause of non-union, as I will endeavor to demonstrate hereafter. While nature requires rest for bony union, she requires also "perfect apposition" for union without deformity. How is apposition to be effected? We start with the knowledge that a muscle cannot be extended beyond its normal capacity, and that any attempt to go beyond this not only provokes resistance, but a tearing of the muscle. Take, for instance, a fractured thigh; extension on the extremity

by a strong man, will stretch the muscles to their normal length only, which fact can be shown by the most careful measurement, thus proving that the danger of too much extension is only imaginary. With the muscles drawn out to their natural state, what becomes of the bone? Where can it go, if not to its normal position, with the fractured ends in contact?

Let any one take the cadaver, dissect out cleanly and carefully all the muscles of any long bone, leaving all their attachments entire, and after fracturing the bone at any part, make extension. He will find that the fractured ends assume their normal position. Would they not equally do so in the living subject, where muscles are invested with skin, fat, fasciæ, cellular tissue, and vessels?

Again, assuming the position that the extended muscles act as permanent adjusters of broken bones, and are in reality the only means by which the fracture is maintained in apposition, I ask of what use are all the mechanical appliances and apparatus called "surgical splints," if not to effect the above named results? The splint beyond this possesses no practical worth; on the contrary, it is apt, by its too careful adjustment, to impede the reparative process, by interfering with the proper circulation of the part. It is for this reason that some surgeons make it a point to apply emollient dressings until the inflammation and the swelling subside. Even this delay is far preferable to the immediate application of carefully adjusted splints, bandages, etc., particularly where there is much contusion of the soft tissue, either from the bone within, or externally from the forces by which it was broken. Take, for example, two limbs equally contused, the sharp edges of the broken bone goring the muscles and nerves, the cellular tissue filled to repletion with blood, and the slightest movement causing the most excruciating pain. Subject one of these to simple extension, without any incumbrance to the broken member, such as splints or bandages, apply simple warm water dressings, and in a few minutes the patient is easy and comfortable, and remains so as long as the extension is kept up. Let the other limb be adjusted by the most careful and approved surgical appliances (unless these are such as keep up the extension without bandages or compression), and there will be a marked difference between the two in the degree of comfort experienced.

Then we may say that in extension the muscles and other in-

vestments of the bone are the true splints, and that there is but little exception to this principle being universally applicable. Surgeons situated in remote parts of the country have to act and not originate. They see comparatively few cases of surgery, and are the possessors of fewer instruments and surgical appliances. They may be called a number of miles to see a patient, and find, when they arrive at the house, that the appliances which they are in possession of do not answer the purpose. What are they to do? Send for some one at any distance, thereby wasting much time and entailing much unnecessary suffering? If we can treat any fracture occurring in the leg or thigh, from the hip to the foot, simply by a perineal belt and extension from the foot, without any splints, and make better results, with more comfort to the patient, and with more speedy recovery of the use of the limb, we have surely arrived at the grand desideratum; and when the treatment of fracture of the arm or forearm is rendered equally as simple, we have, I apprehend, arrived at the "ultima Thule." As for myself, I employ this treatment indiscriminately, and I only ask my professional brethren who have the opportunity to try it, to do the same, and I am sure they will be able and willing cheerfully to bear witness to its entire efficiency, as have my friends Drs. Thorn, of Troy; McLean, of the Marshall Infirmary; Whitbeck, of West Troy; and Willard, of this city. I am positive that the method will withstand the most searching tests, and that it challenges comparison with the results of the most complex machinery of splints and bandages.

I have now treated over forty fractures of the femur and tibia, and in no instance have I seen over half an inch shortening (and that was the result of inattention), while in the larger majority there was no shortening at all (this, of course, does not include inter-capsular fractures, where there is always more or less deformity), nor were there any of these that resulted in a non-union. The only case of non-union of the femur that has occurred in this city, to my knowledge, was that of a boy of about eighteen years, of good habits and enjoying good health. By some accident he broke the humerus and femur. The former was treated with the ordinary splint, and recovered in a reasonable period, while the latter was fastened to the bed by the perineal belt and kept upon extension for some days. After this (the surgeon not having full confidence in simple extension), thinking to make the treatment doubly sure, made use of a Lis-

ton splint in addition. Thus while "trying to serve two masters," he failed in effecting union of the limb, and, though nearly two years have elapsed, it still remains ununited.

In fractures of the tibia I have seen no patients suffering from non-union, where extension was applied. But I have had three that failed to unite for three to five months, and they united only by giving support to the bones and allowing the patient to move about on crutches and use his limb moderately, thereby creating some excited action. Of the humerus, radius, and ulna, I have seen no cases of non-union occurring in this city.

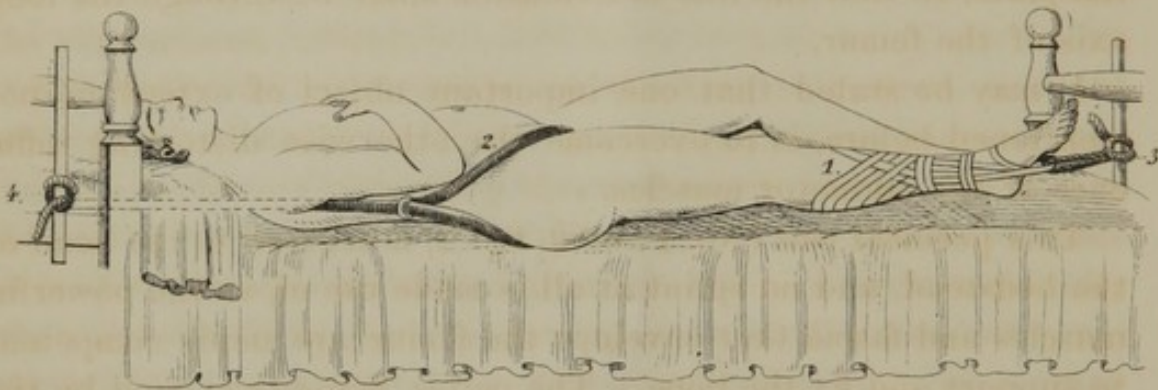
In my opinion, one of the prolific sources of non-union is the action of the muscles (spasmodic or otherwise) in causing the overlapping of the ends of the bone. I do not agree with the suggestion lately advanced, that non-union of the humerus might be due to a separation of its broken fragments. Is it true that the bone separates after hanging some time? I answer no! Instead of separating, it overlaps, and extension is absolutely requisite in order that it may be placed in apposition. The biceps and triceps are too powerful to relax in that way, particularly when under the influence of excited and inflammatory action. Overlapping of the bone has been suggested as a cause of non-union. Let us see a little what takes place when a bone is broken. 1st. You have the muscles gored and irritated; and the result is contraction of the muscles to their fullest extent. 2d. More or less overlapping of the bone. 3d. Infiltration of blood in the tissues. 4th. Muscles inflamed and hardened. This is the first stage. Now if this condition is left alone, ossific matter is thrown out, and union takes place, but with a shortened bone. If, on the other hand, you bandage and splint this limb, the parts are compressed; absorption goes on, and with it the ossific deposit is either prevented from forming, or is slowly taken up; the muscles are agglutinated to the surrounding tissues; and union is thereby needlessly impeded or wholly prevented, making the process of restoration exceedingly tedious. This also constitutes another of the causes of non-union in healthy subjects. In my experience, extension without splints, has never resulted in non-union, notwithstanding over one hundred cases of fractures of the various long bones have been treated by that method, while out of only twenty or thirty cases treated by splints, I have seen temporary non-union result in three instances.

In fractures of the inferior extremities, the patient, of necessity,

THE HISTORY OF THE  
CITY OF BOSTON  
FROM THE FIRST SETTLEMENT  
TO THE PRESENT TIME  
BY  
JOSEPH NEALE  
OF THE BOSTON BAR  
IN TWO VOLUMES  
VOL. II.  
BOSTON: PUBLISHED BY  
J. NEALE, AT THE  
PRINTING OFFICE OF  
J. NEALE, NO. 10, NASSAU ST.  
1846.

# PLATE N<sup>o</sup> 1.

*Fig. 1.*



*Fig. 2.*



*1. Adhesive Plaster.*

*2. Padded Strap.*

*3. Extension.*

*4. Counter Extension.*

is obliged to keep his bed, and hence there is less demand for comely appliances than in cases of fracture of the arm or forearm. In fracture of the femur, I use simply extension and *counter-extension without splints*, and in the leg I sometimes do the same, making use of the following plan by which the extension and counter-extension is effected. The patient is placed in bed, and a broad, well-padded perineal belt, made from  $1\frac{1}{2}$  to  $2\frac{1}{2}$  inches in diameter where it comes in contact with the perineum, (in order more fully to equalize the pressure) is adjusted as indicated in the plate, so that the line of extension shall be through the long axis of the femur.

It may be stated that one important object of extension, not mentioned before, is to overcome the otherwise distorting influence of the adductor muscles.

This perineal belt (No. 1 and 2, fig. 2) is secured to the head of the bedstead, and no splint at all is made use of, as the powerful muscles and fascia that envelope the femur are amply competent to support and fix the bone. The pelvis being thus fixed by the perineal belt, extension is obtained by means of adhesive strips secured to the leg. The plasters are cut proportionally to the size of the limb, from one-half to one inch in breadth, and of sufficient length to be applied along the outside of the leg, descending spirally, protruding so as to form a strong loop under the sole of the foot, and then extending up on the inside of the leg. These strips are not applied one directly over the other, but at small distances apart, so as to embrace a larger surface of the leg, thus equalizing the tension upon the integument. Then a number of shorter strips are applied in a manner similar to the many tailed bandage, surrounding and securing the long plasters against possible detachment. The shorter strips are not indispensable, as the same end may be attained by a simple roller.

Fig. 1 and 2. All that is now necessary is to pass a strong cord through the loop of plasters, and secure it to the foot of the bedstead. The simplicity of this method is a strong recommendation. There are many occasions when a Liston splint, or any other, can be obtained only with difficulty; for the treatment by this method nothing is required but ordinary adhesive plaster, which can be obtained very readily; and an old sheet or rope will furnish the remaining complement of apparatus.

The patient can move about in the bed as much as is necessary with greater freedom than when embarrassed by a long splint,

and with really less danger of displacement. The seat of fracture can be examined at any moment without having a long bandage to unroll, and wet cloths or other local applications can be used, with as great facility as if the limb were well. The advantages of this method of extension are best manifested in the case of compound fractures; the wound of the muscles and integument is as perfectly accessible as if it were not complicated with a fracture. Perfect cleanliness may be preserved, which is an important consideration, and which it is impossible to obtain when the splint and bandage are used, without much trouble both to the surgeon and patient.

The limb can be measured as often as is desired, and the amount of extension regulated accordingly, with scarcely any trouble, by merely tightening the cord which secures the foot to the end of the bedstead. The circulation is not interfered with, as is often the case when the splint and roller is used; especially when not rightly applied; and, what is to be considered of great importance, the patient is far more comfortable than when trammelled by the usual dressings.

There is no danger of sloughing of the heel or malleolus, a complication by no means seldom met with under the usual treatment, because here there need be no pressure upon the prominent bony projections, either from the bed or the dressings; and with regard to the perineal belt, the chances of excoriation are not greater than when the long splint is applied. In fact, the line of traction in the latter case being more oblique, has greater tendency to press the upper part of the thigh outward, and is consequently more painful than when the force is applied more directly to the pelvis, which effect may always be obtained by a proper adjustment of the perineal belt.

I have lately treated a patient having delirium tremens which lasted several days, for fracture of the femur. Union was not interfered with or materially retarded. After a few days the patient can set up in bed or lift his hips for the calls of nature, with impunity and without apparent injury. He can roll from side to side, or even sit up, and thereby relieve the tedium of confinement.

One other, and not the least advantage, is, that in this form of treatment there is no agglutination of the muscles to the bone, or each other, and consequently no stiffening of the limb from that source; and as soon as the bone is strong enough to bear

the weight of the patient, the muscles are ready to do their part in the locomotion.

One objection, and by the way the only one which possesses a show of validity, has been made, that the foot is liable to evert or invert; but a single moment's reflection will satisfy any one that no great ingenuity is required to avoid this—a bag of sand or bran on either side of the foot, or a strip of plaster, or of cloth, any of these simple means can be so employed as to maintain the foot in a proper position.

The fact to be dwelt upon is, that but little extension is necessary during the first stage of treatment. In order to prevent perineal excoriations, and accustom the patient to the necessary pressure when union is taking place, little more is essential, at first, than what is required to overcome spasmodic muscular contraction, and displacement of the fractured ends. When the process of reparation has been thoroughly begun, even after the provisional callus has been thrown out, or at all events has begun to form, say a period of fifteen days, there is time enough to use extension for the purpose of acquiring the necessary length of the limb. In this way the patient has an opportunity of becoming accustomed to the confinement, and the parts where the pressure falls become inured and hardened, and thus better prepared for the necessary extending force.

The efficacy of this treatment, like that of many and all others, is to be tested by its practical results. So far as an experience of about thirteen years, which, it is granted, is only a limited time, can be depended upon, there is no method more reliable than this. There is none under which more favorable results have proceeded, none in which there have been fewer failures (in this there have been no unfavorable results), considering the different varieties of fractures to which it is applicable, and in which it has been used; and also considering the circumstances which have often attended, and of course complicated this as all other methods, it has been eminently successful, and has been exclusively used in private practice with uniform satisfaction. No written histories have been kept of the majority of these cases, except facts obtained from note-books, but the results have been such as to warrant its indiscriminate use.

By this method there have been treated forty cases, twelve of which were hospital, and twenty-eight private patients. Of the latter twelve were intra-capsular.

In the case of hospital patients records have been kept, more or less full and perfect, and from these records the following cases have been quoted, as illustrating fairly the results of this practice.

*Case 400.*—Nov. 7, 1857, admitted Wm. Devine, aged 30, Ireland, with fracture of femur near its middle. Extension and counter-extension by perineal belt and adhesive strips. Dec. 25, seven weeks after injury, extension was discontinued. Jan. 9, nine weeks, walked with crutches, and Jan. 14, discharged cured, with no perceptible difference between the sound and injured limb, as regards shape or length, having been under treatment nine weeks and five days. (No splints used.)

*Case 457.*—June 24, 1858, admitted James Linan, U. S., aged 13, with fracture of right femur through its middle. Extension and counter-extension by perineal belt and adhesive strips. Aug. 23, nine weeks lacking three days from the date of injury, patient was discharged cured, with a perfect limb. (No splints used.)

*Case 135.*—January 5, 1854, admitted John A. Pitcher, aged 21, Germany. Patient met with a fall of thirty feet, fracturing the femur at its middle; also the left tibia and fibula at their lower third; extension by perineal belt and adhesive strips at the lower part of the thigh, just below the patella. Strips were also applied to the lower part of the leg, forming a loop under the sole of the foot, upon which extension was made, merely sufficient to maintain the fractured ends of the tibia and fibula *in situ*, the principal extension being between the perineal belt, and the lower end of the thigh. Feb. 14, six weeks lacking two days from the date of the accident, the extension was discontinued Feb. 23, patient was discharged cured, having been under treatment seven weeks. This limb is now (1861), so perfect that a most skillful surgeon would be unable to detect the broken leg or thigh. (Treated without splints.)

*Case 250.*—July 19, 1855, admitted Wm. Malloy, aged 18, Ireland, with fracture of left femur at its upper third. Extension and counter-extension made by perineal belt and adhesive strips, to foot. September 10, eight weeks lacking two days from time of injury, extension was discontinued. September 22, nine weeks and two days, patient discharged cured. Injured limb perfect, and splints used.

*Case 340.*—Feb. 3, 1857, admitted John Levine, aged 19, Ireland, with fracture of femur through its middle. Extension and

counter-extension by perineal belt and adhesive plaster. March 7, five weeks lacking three days, extension discontinued, and leg firm and perfect. (Treated without splints.)

*Case 139.*—February 22, 1854, admitted James McKenzie, aged 16, Scotland, with *compound* fracture of the left femur, through its middle. Extension and counter-extension by perineal belt, and adhesive strips to leg. In consequence of the fact that the other thigh had been fractured previously, and was three-quarters of an inch short, the extension in this case was only made sufficiently to accommodate the length of this leg to the other. April 3, after six weeks lacking two days, extension was discontinued, and May 1st patient was discharged cured, with legs of equal length, having been under treatment ten weeks, lacking two days. (Treated without splints.)

*Case 206.*—February 13, 1855, admitted Mary Pettit, aged 24, Ireland, with fracture of the left femur, at its lower third, by a fall upon the side-walk. The bone had for a long time been diseased, fistulous opening having appeared from time, leaving cicatrices, some of which still remain. Near the site of the fracture was a fistulous opening, through which was detected carious bone. Extension made by perineal belt, and adhesive strips. April 17, nine weeks from date of fracture, extension was discontinued, and union found pretty firm; the fistula remaining open, and necrosed bone escaping occasionally, patient was not discharged until June 17, two months after. Limb as perfect as before the injury, and not more than one-fourth inch shortened. (Treated without splints.)

*Hospital record. Case 97.*—William Graham, aged 26, Ireland, was admitted June 15, 1853, with fracture of the right femur, by the falling of a pile of lumber. Extension and counter-extension made by perineal belt and adhesive strips to leg. August 5, after a period of seven weeks and two days, extension discontinued; on the fifteenth, patient walked with crutches, and on the 25th was discharged with a sound limb, less than half an inch short, after a treatment of not quite nine weeks. (No splints used.)

*Case 106.*—Martin Connor, aged 35, Ireland, was admitted Aug. 3, 1853, with fracture of the right femur, a trifle below its middle, and also fracture of the fibula, two or three inches above the malleolus. Extension and counter-extension by perineal belt, and adhesive strips to the leg; on the first of September the case passed into the hands of a surgeon to whom this method of

treatment was distasteful. Sept. 17, after a period of six weeks and three days, extension was discontinued, and the leg found to be half an inch short. On the 26th patient was discharged, cured, after having been under treatment seven weeks and five days. It is probable that in this case the extension might have been made sufficiently to have prevented the half inch shortening. (No splints used.)

Case 108.—August 12, 1853, admitted Stephen M. Wiggins, aged 21, with fracture of the left femur at its lower third. On the first of September this patient, like the last, passed into other hands. Extension was discontinued, and the limb found to be less than half an inch short, otherwise perfect. October 3d, after a period of seven weeks and three days, patient walked with crutches. (No splints used.)

Richard Hathaway, aged 48, weighing 185 lbs., admitted to hospital July 20, 1859, with compound comminuted fracture, with great contusion of the femur at its upper third, received by the fall of a derrick while rearing a monument. Treated by extension and counter-extension, without splints. Limb firm in four weeks and patient walked with crutches in eight weeks.

This man presented himself before the State Medical Society for examination, and the best surgeons present could not say which had been the broken limb. The same thing can be said of the other private and hospital cases.

The record of the remaining one has been lost or removed from the hospital, but the results are as perfect as the above. The above patients, some of them, passed through different hands, some of which were not familiar with this mode of treatment; some *sceptical*, and under such circumstances, some degree of vigilance would be necessary to secure a favorable result in all cases. The utmost extent of shortening mentioned above did not exceed half an inch, and the question is left for candid minds to decide whether that half inch might not have been avoided by extension made sufficiently at the proper time.

Without further comment upon these cases treated in the hospital, the following are alluded to, which all occurred in private practice. As was said before, no daily record was kept, but facts were noted down of the result as they occurred.

J. Foster, aged 30, contusion of soft parts and fracture of upper third of femur; railroad accident; extension discontinued in six weeks. Patient walked to office with crutch and cane from Green-

bush, in eight weeks from the date of accident. No distortion or shortening. (Without splints.)

O. H., aged 14, fracture of lower third of femur; extension discontinued in four weeks; pretty firm; union in three weeks; walking with cane and crutch in six weeks; no distortion or shortening. (Treated without splints.)

P. R., aged 9 years, fracture of upper third of femur; union firm in three weeks; extension discontinued in four weeks; walked with cane and crutch in six weeks; no distortion or shortening. (Treated without splints.)

Hon. John Evers, aged 42 years, oblique fracture of femur at upper third, from being thrown violently against the curb-stone by a run-away horse. Extension continued for six weeks; discharged in ten weeks, with limb less than half an inch short, while he maintains that there is *no* difference.

For this case I am indebted to Dr. S. O. Vanderpoel, of this city.

F. Mc., aged 18, fractures of femur, tibia and fibula; treated as described in hospital patient, with like accident; union firm in four weeks; extension discontinued in six weeks; walked with cane and crutch in eight weeks; no distortion or shortening. (Treated without splints.)

J. C., aged 40, compound fracture of upper third of femur; union firm in six weeks; walked in nine weeks; no distortion or shortening. (Treated without splints.)

P. F., aged 32, fracture of middle third of femur; union firm in five weeks; walked in eight weeks, with crutch and cane.

McW., aged 9 years, fracture of lower third of femur; union firm at three weeks; extension discontinued in four weeks and three days; no distortion or shortening. (Treated without splints.)

D. W. Wilson, aged nine years, received Oct. 20, 1859; comminuted fracture of the femur through the middle third, by being crushed by the wheel of a truck, which with its load of three tons passed over his thigh. Extension and counter-extension applied, without splints, and continued for six week. Union in twenty-five days; walked in seven weeks. Owing to the splintering of the bone he was confined to the bed longer than would be necessary under ordinary circumstances. Now (12 weeks) he is as well as ever, and the limb as perfect as before the injury.

Master Warren, aged ten years, received Nov. 28, 1860; comminuted fracture of the femur through the middle third, by the

fall of a bale of hops from the second story of a store. The muscles were much bruised, and the ends of the bones overlapped, Extension and counter-extension applied, without splints, and continued for four weeks. Confined to bed six weeks, walked in seven weeks. Here union took place in twenty days, was firm in twenty-five days, but owing to the contusion, he was confined longer than would have been otherwise necessary. At the 12th week Dr. Lewis A. Sayre, of Bellevue Hospital, saw it, and pronounced it as perfect as its fellow.

Through the politeness of Dr. L. G. Warren of this city, I was allowed to attend this case.

Infant of J. T. had its thigh broken, in 1858, through its upper third. The attending physician tried all the appliances commonly used, but without success. He was unable to keep the parts in apposition. Accordingly, on the 5th day, extension and counter-extension were applied by means of a perineal belt fastened to a piece of board which extended from the crest of the ilium to about two inches below the knee, to which it was fastened by means of adhesive plaster. This apparatus was applied to the infant's thigh, as represented in the following cut for fractures of the humerus, and for the same reason, i. e., that it would be impossible to fasten the infant to the bed, rendering the board necessary to furnish the extending and counter-extending points.

For this case I am indebted to Dr. Craig, of this city.

F. M., aged 9 years, fell off from a stoop, in 1859, upon a pavement below, a distance of five feet, contusing the soft parts greatly, and fracturing the femur through its upper third. This boy had morbus coxarius for nearly five years, and had passed into the stage of extensive suppuration, with four fistulas discharging pus and debris of bone. This profuse discharge and constitutional derangement had reduced him to a mere skeleton. Nevertheless, extension and counter-extension without splints removed the pain and lessened the discharge, and in 18 days considerable union was effected. In four weeks the fracture was firmly united, and without shortening. The measurement was made, on account of the altered position of the joint by disease, from the trocanter major to the malleolar process. The interest of this case is two-fold. The previous disease of the joint, and the excessive constitutional disturbance caused thereby, together with the contusion and distortion from the injury, made the case very unpromising, so that I almost

doubted the propriety of any but palliative measures. Knowing, however, the little discomfort caused by simple extension, I applied it, and was much surprised to find my patient, on the following day, not only comfortable but cheerful, and without pain. He thus continued happy and cheerful, and gaining daily in flesh during the 12 weeks' confinement. The extension gave him not only a perfect thigh, but also cured his diseased hip. Now, April, 1861, the fistulas are all headed, the limb is sound, and his general health completely restored.

In 1859, J. McG., aged 70, fell from a stoop a distance of six feet, fracturing the thigh through its upper third, and producing great distortion and contusion. Treated as above, without splints; considerable union in 25 days, firm union in five weeks. Owing to infirmity from age and chronic rheumatism, her recovery was necessarily protracted. The limb is now perfect, though treated under disadvantages; the bed being a common straw bed, and the ropes giving way at points and settling in the centre.

F. E., aged 21. 1860. Fracture of femur through the trochanters, by a fall of eight feet from a scaffold. Much contusion, swelling and soreness. Treated as above, without splints. Considerable union in 18 days; firm union in five weeks; walked on crutches in six weeks; no deformity.

P. Y., aged 46. 1860. Thigh fractured at lower third by the fall of a clay bank. Treated as above, without splints. Firm union in 35 days; walked with crutches in six weeks; no distortion or shortening.

O. W., aged 60. 1860. Fractured femur through middle third by falling down stairs. Treated as above, without splints. Walked with crutches in seven weeks; no distortion or shortening.

All of these cases were treated as above described. In but one of them was there visible shortening, nor was there any distortion of the thigh; no eversion or inversion of the foot. The average period of time during which extension was maintained was five weeks; and in the majority of cases, union was tolerably firm at the expiration of from fifteen to thirty days, according to the age of the patient and the nature of the injury. Here are, in all, forty cases of fractured thighs, occurring at all parts of the shaft and neck. Some were oblique, some compound, some comminuted, (in one case four inches of the bone being crushed in fragments.) Two were cases where the thigh and leg were *both* fractured, and in *all* the results may be considered *perfect*; for

where shortening only amounts to half an inch, it can be ascertained only by actual measurement. Of these forty cases, twelve were fractures within the capsular ligament, occurring in patients, most of them over sixty years of age, and all treated by this method of extension, with results much better than could be expected, and which it would have been vain to expect under the usual treatment.

One suggestion may be made in reference to intra-capsular fractures. As they occur generally in the aged, and for the most part enfeebled, and those who endure treatment and confinement badly, and the pain incident to overlapping of fragments still worse, the grand object is to place the ends of the bone as nearly in apposition as possible, with the least degree of pain, and as little constriction and confinement of the patient's movements as possible. This can be obtained by dispensing with the perineal belt, elevating the foot of the bed slightly and making extension by weights, and cord and pulley. Thus the body impinges upon an inclined plane, and becomes the counter-extending force, and then by keeping the limb drawn to its normal length, we remove all sources of irritation and allow perfect freedom of motion, without any constriction from splints, bandages, or even a perineal belt. From my limited experience, I think this treatment far better than allowing the limb to unite at any angle and shorten unchecked, or even attempting the use of Liston's long splint to obtain the requisite length and position of the limb. It seems that, in nearly all of these cases, the bone unites, but whether by bony or cartilaginous union it matters but little, otherwise than as a matter of scientific research.

I think extension in this way (in intra-capsular fractures) is not only devoid of objections, but is absolutely more comfortable for the patient than where the case is left to nature without any mechanical appliances, for the reason that when the bone is drawn down to its normal condition the pricking and goring of the tissues, by the broken bone, is dispensed with, and the patient is allowed to move about the bed with more absolute freedom, than when every movement of the body rotates the bone at the seat of fracture, instead of at the joint, as it does where the extension is used.

If the extension were used in every case, I trust we should find less impacted intra-capsular fractures than we now do.

In three of these cases, the perineal belt was dispensed with,

and the result equalled my most sanguine expectations, and warrants its continuance. The treatment consisted of weights and pulleys, and elevating the foot of the bed. Patients thus treated were even more comfortable than when lying in bed without any dressings at all, and certainly, the results are more favorable, and some of my cases having resulted so well that the gait does not discover any faulty condition of the limb, nor does measurement reveal more than from three-quarters to an inch of shortening, while the patient says there is no difference in the two limbs.

Although this method is so applicable to the aged and enfeebled, it would be presuming too much to seek to apply it to fractures generally, and particularly those occurring in younger persons. From my own experience, it appears insufficient for the treatment of *any* but intra-capsular fractures.

As to the treatment lately proposed, of *elastic* extending and counter-extending bands with weights and pulleys, it has many objections; among which are:

1. It admits of spasmodic contraction of the muscles.
2. It presumes that all muscular tissues are equal in tone and strength, which is by no means the fact.
3. Were there to be applied a trifle too much weight, the object would be defeated by absolute separation of the bone.

There is much difficulty in ascertaining the exact degree of weight necessary, and this difficulty is increased by the elastic band for counter-extension and that for extending. Should you apply a weight apparently sufficient, you may find at your next visit that the muscles have relaxed more than sufficient. If you reduce the weight, you may find at your next visit that the limb is too short. Again, if your patient stretches his extending band by drawing himself down in bed, so that his foot rests on the foot-board, the weight only expends its force upon the foot-board or else rests on the floor. In *permanent* extension, however, it is obvious that none of these inconveniences can, by any possibility, occur. Both methods possess in common this advantage, that if the limb happens to be too short from overlapping, in no instance can there be any deformity, as the straight line will always be maintained.

The method of extension is extremely simple, and can be carried out by any surgeon who can measure from the anterior spinous process to either maleolus. As I am daily asked many questions concerning it, I give here a brief resumé:

1. I have the perineal belt, made *large* and easy, to draw in the line of the axis of the bone. Moderate extension is made sufficiently to maintain the muscles firmly on the stretch, until the soreness of the bruised limb has abated and the patient become accustomed to the confinement; when firm extension is made, until the limb is drawn out so as, by absolute measurement, to equal the length of its fellow.

2. I maintain this extension until union is moderately strong. In cases where time is of no importance, I keep the patient in this condition until there is no danger of any refracture. In those where time is of much importance, I apply a roller, and some split deal or pieces of cigar box, around the limb, moderately tight, so as to keep the bones firm, but not sufficient to constrict the limb. The patient can then sit up or walk with crutches. This is removed as soon as I feel assured of the firmness of the bone, and generally from seven to eight weeks is sufficient for this. In this condition (where union is firm enough to prevent any shortening), I find the starched bandage of special service, particularly where *time* is the grand desideratum.

In concluding this article, I make no apology for adding the valuable experience of Drs. Thorn and others. It speaks for itself, and requires no comments from me.

In conclusion, I have merely to say, that after about thirteen years of experience, I feel that this is the true method of treating fractures. All who have tried it bear testimony to its full efficacy.

If the reader has been surprised at the frequent repetition of the words "*no splints*," he will readily understand my design, when he knows that a physician, who heard this paper read before the society, and afterwards read the article in the American Medical Times, actually supposed that the leg apparatus was used for the thigh, and hence accused me of using splints in contradiction to my own theory. For this reason, therefore, and that no one else may fall into the same error, I have been thus explicit in annexing to each case separately the positive declaration, "*no splints used*." Dr. Thorn writes me on the subject as follows:

TROY, N. Y., *January 8, 1861.*

Dr. SWINBURNE, My Dear Sir: Having had an opportunity of testing, both in private and public practice, your mode of treatment in fractures of the femur, and of the tibia and fibula by simple extension, I take the opportunity of giving the particu-

lars of some cases which have fallen under my care, and my especial views of the same.

1st. Since I have adopted the plan of treating fractures of the femur by extension without splints, I have found no difficulty in maintaining reduction and apposition of the fractured end of the bone. When I used splints I frequently found great difficulty.

2d. I have found that simple extension answers all the requirements in treatment of this form of fractures.

3d. My experience is that the chances of distortion or shortening are very little by the extension treatment, as compared with the use of splints.

4th. I have found the extension treatment applicable to all fractures of the thigh, within the capsular ligament or not.

5th. I have found that the muscles recover their use much sooner, under the extension treatment, than they do when splints are used.

6th. I feel much more easy as to the results, while the limb is under treatment with simple extension than with the use of splints.

7th. As regards the ease and comfort of the patient, it is very much in favor of simple extension.

8th. I have treated and seen the treatment of fifteen cases of fracture of the femur by simple extension, and they compare very favorably indeed with treatment by splints.

9th. I have never seen a case of non-union of the femur.

10th. My experience, in fracture of the tibia and fibula, is favorable for extension, when it is required. I have lately had under treatment, a case of compound and comminuted fracture of leg, where the extension came up to the most sanguine expectation, and the result was good.

*Case 1.* M. R., ætatis 9 years, fell on the ice, fractured the thigh at the upper third portion. Reduced the fracture, having applied strips of adhesive plaster from the knee downwards, and with a perineal bandage, extension was kept up between three and four weeks, with little or no inconvenience to the patient, and with only small side splints, perfect union without shortening took place.

*Case 2.* M. C., ætatis 34. Fracture of femur, lower third, just above the condyles. Extension kept up, in the same way, for 34 days, good union, no shortening.

*Case 3.* J. F., ætatis 29. Fracture of tibia and fibula near the ankle joint, requiring considerable extension to effect reduction,

after which permanent extension was kept by adhesive straps for five weeks. The case terminated in every way favorable.

The following cases were treated at the Marshall Infirmary :

John McGreacor, aged 60, admitted March 18, 1858. Fracture of the thigh just above the condyles. Extension was kept up in the same way for 40 days, good union, with one inch shortening.

Prosper Hankin, aged 18, admitted August 28, 1856. Fracture of the middle third of the thigh. The same treatment; recovery without any deformity.

Charles Smelser, aged 25, admitted Sept. 3, 1856. Fracture of the lower third of the femur, recovery without any deformity, by the same mode of treatment.

The above cases I have singled out as a fair specimen of the superiority of the mode of treatment by extension, without the aid of long splints, the first adaptation of which, I believe, you are justly entitled to the credit of, and I venture to predict, from the simplicity of the application, and from the great power which can be easily *kept up* without injury to the soft parts, that your plan of treatment by simple extension, will be considered as one of the "modern improvements."

With high respect and esteem,

Believe me, my dear sir,

Yours truly,

JAMES THORN,

*Surgeon, Marshall Infirmary, Troy, N. Y.*

To DR. J. SWINBURNE, *Albany.*

WEST TROY, *January 1, 1861.*

DR. SWINBURNE:

Dear Sir,—I send you the report of three cases treated by your method of extension and counter-extension, together with the results and my views of this mode of treatment, in which I fully agree with Dr. Thorn.

Case No. 1. P. R——, aged 35, Irish; fracture of the lower third of femur just above the condyles and extending into the joint; placed the leg on inclined plane without angle; was unable to retain the bone in apposition, from the great pain, swelling, inflammation, and consequent restlessness of the patient. At the suggestion of Dr. McLean, (who was familiar with your method of treatment of fractures,) I used the perineal belt for counter-extension, and the adhesive plaster and rope fastened to the foot of the bed for extension. The knee was slightly elevated by

means of a box and pillow in the popliteal region, but no splint of any kind was used. Under this mode of dressing, our patient was easy, and remained so for one month, when all dressings were removed. About ten weeks after the accident, he resumed his labor as a teamster as usual, and with a good limb.

Case No. 2. October 6, 1859. J. M——, aged 22, Irish; middle third of femur broken by fall from railroad bridge; treated it by perineal belt to the head of the bed, and by the adhesive plaster and rope to the foot of the bed. Had no trouble from displacement or otherwise, notwithstanding there were no splints used. In four weeks from accident, removed dressings and commenced passive motion; in a few days was moving about on crutches, and in seven weeks from the accident, was able to be about on his limb and attend business.

Case 3. Sept., 25, 1860. J. W——, aged 40; laborer. Was caught under a pile of falling lumber in such a manner as to crush the tibia and fibula, producing a compound fracture displacing the bones. Placed on him an ordinary splint; found that the bones could not be kept in place by this means. Accordingly, on the third day (in consultation with Dr. Thorn), we applied extension to the foot by the above named means, and counter-extension by the perineal belt, which constituted the entire dressing, except a straight splint for the contused limb to rest upon. After eight weeks, the limb united with but little shortening; there was excessive suppuration, which increased the natural nervous and irritable temperament, and hence the patient required constant watching and attention to prevent his displacing the parts.

Dr. Thorn and myself agree, that no other mode of dressing could have effected the same results with so much comfort to the patient, in the same period of time.

Respectfully yours,

JOHN P. WHITBECK.

DR. SWINBURNE:

Dear Sir,—While resident surgeon in the Albany City Hospital, I had an excellent opportunity of studying fractures of the femur as treated by extension and counter-extension. It cannot be denied that it is the simplest style of dressing conceivable, requiring only extemporaneous appliances, and such as are always at hand. Besides, after the limb is once dressed, there is no more labor required during the whole time occupied in reparation, beyond maintaining extension by occasionally tightening the ex-

tending cords. But, what is of more importance than the time of the surgeon or attendant, the results, in every case which I have seen, were perfect, and the time necessary for recovering much more brief than one would believe possible. Add to all these considerations the fact that the greatest possible comfort is secured to the patient, and I do not believe that any one who has faithfully made trial of this method, will ever have recourse to a long splint and bandages, unless his patient is so unfortunate as not to possess that most comfortable of all long splints, a bed.

O. H. YOUNG, M. D., *House Surgeon.*

Dear Doctor : The case of intra capsular fracture, an account of which I promised to furnish you, occurred in an old lady of 65 years, of feeble health and greatly impaired constitution. The dressing was most simple, consisting of a large, soft, perineal belt, attached to the head of the bed, and counter-extension made from the foot. She suffered but little pain, and scarcely no inconvenience from the dressing, although her skin was remarkably tender and easily chafed. The old lady, after a few days, rather *luxuriated*, while the bone was uniting. She was not able to leave her bed for eight weeks—when at first she was able to get about, there appeared little shortening. I think (without having measured it) that it is greater now, at the expiration of one year, than it was when she first began to walk.

The great comfort of this simple appliance to an old and infirm patient,—the avoidance of excoriations and sloughs, and the successful result, would lead me to forego the use of splints in all similar cases.

In haste, truly yours,

ALBANY, Feb. 1, 1861.

SYLVESTER D. WILLARD.

*Treatment of Fractures of Leg by extension and counter-extension.*

In fractures of the inferior extremities, the patient, of necessity, is obliged to keep his bed, and hence there is less demand for comely appliances than in cases of fracture of the arm or forearm. In fracture of the femur, I use simply extension and counter-extension without splints, and in the leg I sometimes do the same.

Two cases are reported in this paper, one in the hospital and one in private practice, where the fractures were double, i. e. both thigh and leg. By referring to these cases, it will be seen that I dispensed with splints entirely, by making extension and counter-extension by means of the perineal belt, while the exten-

sion for the broken leg is made from the foot, and for the fractured thigh, from the knee.

During the past year, I have treated three cases of fractured leg, (tibia and fibula, one compound) by simple extension and without splints. Inasmuch as these cases may be of considerable professional interest, and since, moreover, it has been asserted by high authority that this method cannot be used with any degree of safety or success, I subjoin the following history of some cases thus treated.

1861 (1.) P. Van Wie, aged 13, while sliding down hill, was run over by a team, producing a compound fracture of the middle third of the tibia and simple fracture of the fibula. Treated by extension without splints, as in fractured thigh. On the sixteenth day, Drs. James R. Wood, Lewis A. Sayres, attending surgeons to Bellevue Hospital, and Prof. Charles A. Lee, saw this fracture and pronounced it perfect and quite firmly united. Dr. Wood seeing a bag of sand placed by the family on either side of the leg, contended that it acted effectually as a side splint. This I deny. It may be considered as lateral support, but not as a splint in the common acceptation of the word *splint*. Two months after the accident the limb was as perfect as ever, and there was but very little callus.

1860 (2.) J. Van Dusen, aged 21: fracture of the tibia and fibula, about four inches from the ankle, and oblique.

Treated as above, without splints or sand-bags; union firm in three weeks, and extension discontinued; lateral support given, and patient allowed to walk with crutches. In this case there was no distortion or shortening.

James Eagen, aged 39, fractured tibia and fibula, by the fall of a clay bank; much contusion. Treated as above, without splints or lateral support, excepting a sand-bag on either side of the foot to prevent eversion or inversion. Extension discontinued in four weeks and union found firm. Starched bandage applied and patient allowed to walk with crutches. No distortion or shortening in this case.

Though I firmly believe that all fractures of the leg can be treated without splints as successfully as with them, and that the same treatment is as applicable to them as to those of the thigh, still, as a matter of comfort, where the fracture is transverse, and there is no over-lapping of the bones, lateral support is admissible, if it can be applied without causing constriction of

the parts, because it does not render rigid confinement to the bed necessary.

But in oblique fracture of these bones I know of no mode of treatment which effects all the required indications so perfectly, as extension and counter-extension, with or without lateral support. Like fracture of the thigh, this form of fracture (oblique) cannot be successfully treated without proper extension and maintenance of the same. But if the requisite extension is once effected, the practitioner seeks to maintain it by compression with co-acting splints and bandages, the result will not, in my opinion, be so favorable, or to the patient so comfortable, as without any such mechanical appliances, and with simple extension, free from all constriction.


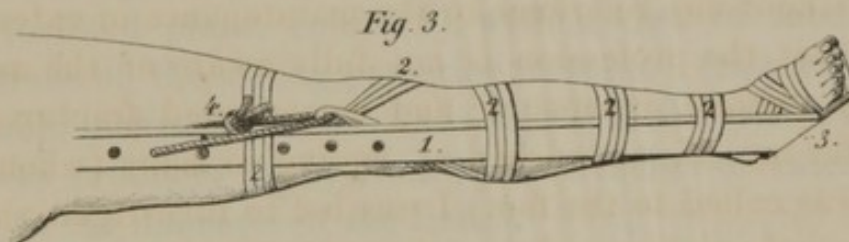
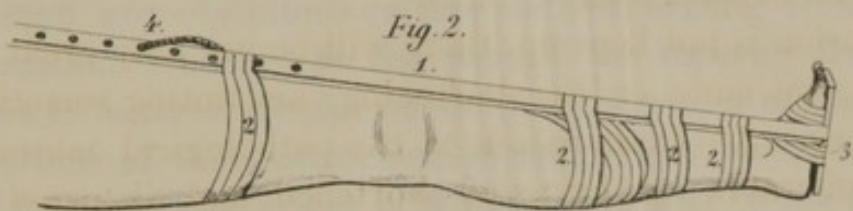
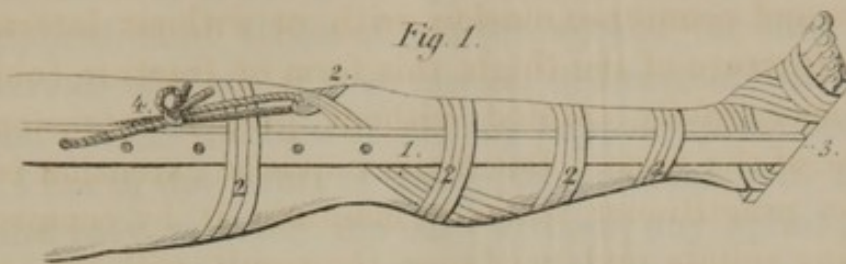
If extension is not kept up, there will be not only great lateral distortion, but more or less shortening, amounting sometimes to three inches. An examination of the pathological museums affords innumerable specimens of shortened and distorted tibias. If their histories were accessible we should find that they had been treated with the fracture-box, two side splints, inclined plane, or some similar contrivance for keeping the parts in apposition, without any reference to the maintenance of extension.

I feel that the profession is not fully aware of the many bad results of oblique, compound and comminuted fractures of the leg; as for myself, astonished at finding so many (when my attention was called to the fact) I was led to investigate the cause. I examined the museum of the Albany Medical College, and found, I should judge, at least one hundred, more or less, distorted and shortened tibias.

Since this time I have not lost sight of the subject, and have treated all my cases of oblique and compound fractures of the tibia and fibula, and in fine, all those where any distortion is anticipated, by extension and counter-extension, with what success I leave for the reader to judge, after perusing my reported cases, together with those of Doctors Thorn and Whitbeck.

Instead of using the method above detailed, I generally effect extension and counter-extension through the medium of a delicate splint, (plate 2, fig. 1, 2, 5, 4) and an equally delicate foot piece fastened to the foot by means of strips of adhesive plaster, while the counter-extension is made from the knee by adhesive plaster looped about the limb below the joint. (See plate No. 2, figs. 1, 2, 3.) Then by means of a strong cord passed through this loop,

PLATE N<sup>o</sup> 2.



- 1. Splint.
- 2. Adhesive Plaster.
- 3. Extending Foot Piece.
- 4. Counter extending Point or String.

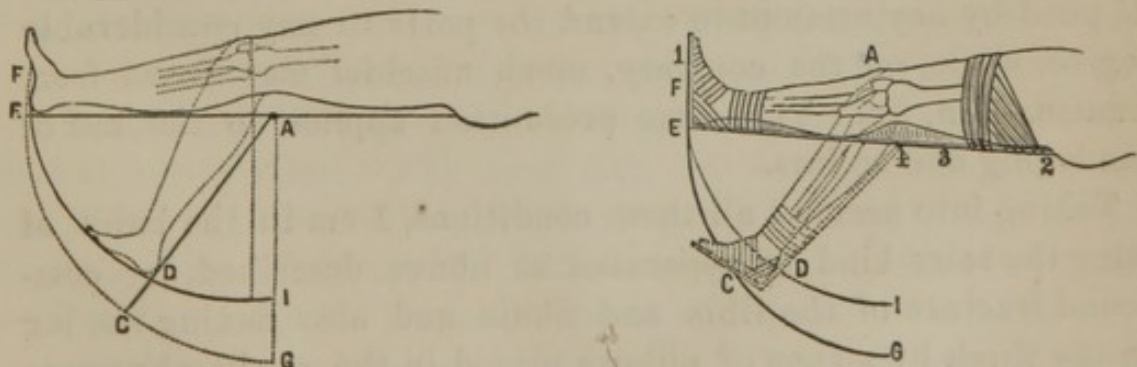
*Lith. of C. Van Benthuysen, Albany, N. Y.*



and thence through a hole in the side splint some distance above the knee, the requisite extension can easily be made to any desired degree. If, after full extension is effected, it should appear that the limb is not sufficiently steady at the seat of the fracture, the application of strips of plaster around the limb and splint, at intervals of three or four inches, will accomplish all the indications. If the fracture of the leg happens to be near the knee-joint, I am in the habit of using the perineal belt, made large, full, and easy, treating the case without any splint and by the same means as if it were a fractured thigh.

In compound fractures of the tibia and fibula, extension is especially applicable, and I may say indispensable. And here, to forestall any objections to this method, arising from the fact of a constant tendency on the part of the superior fragment of the tibia to anterior displacement, in consequence of the powerful contractions of the gastrocnemius and soleus muscles, I remind you of four artifices, either of which, according to the preference of the surgeon, or the particular exigencies of the case, will be certainly effectual in conjunction with extension and counter-extension, in preventing this deformity. 1. The use of the double inclined plane, (plate 3), with a view of subduing the contractions of the strong posterior muscles. (See wood cut of said double inclined plane. As is shown in the plate, flexion to 45 degrees produces about from  $1\frac{1}{2}$  to 3 inches of extension, according to the diameter of the limb.)

The following diagrams, showing the principle of the double inclined plane, illustrate the principle of extension by means of the apparatus:



*a*, plate 3, is the joint of the apparatus; *b*, is the knee joint: *a*, is about one or two inches above *b*, and from two to three in front of it.

No. 1, Extension. No. 2, Counter-extension. No. 3, Splint. No. 4, Hinge.

The end of the instrument and the sole of the foot extend to the same point. Now semiflex the leg upon the thigh, and the splint will extend farther than the foot, by the distance *c d*, fig.

2, and when the flexion extends to a right angle, the difference is  $g i$ . It is plain, therefore, that if the foot be made fast to the end of the foot-piece, while extended, then when it is flexed, the foot and the end of the instrument will describe the same arc, and both extend to the point  $C$ , fig. 2, the leg being extended to an amount proportional to the diameter of the leg.

In other words, the vertical distance between the joints of the knee and instrument is, respectively, increased; and also the horizontal distance between them, so that by means of this simple arrangement, sufficient extension is made.

Suppose we have an oblique fracture of the leg, with one, two or three inches of overlapping of its ends. Apply the extended splint to the extended leg; let the hinge of the splint be a little lower than the knee joint, then secure the splint to the foot and thigh, flex the leg on the thigh, and when the leg and splint are at an obtuse angle, the leg will be extended to its normal length, and so vice versa for fractures of the thigh.

2. The judicious application of adhesive strips around the extending splint, (plate 2) and limb, after inflammation has subsided. 3. The insertion of stout silver-wire through small holes drilled into the fragments, and bringing these into apposition by twisting. 4. Malgaigne's steel point apparatus.

In compound fracture of the ankle joint, with dislocation, there is, from the same cause, more or less disposition to displacement, and consequent shortening. Here we are obliged to pursue a different course of treatment. The injury to the bone and soft parts is, in such cases, in so close proximity to the dressing used for extension, that for some few days we can do but little good by any attempt to extend the parts to any considerable degree, while, on the contrary, much mischief may ensue from inflammation, &c. The same precaution applies to the use of bandaging and splints.

Taking into account all these conditions, I am in the habit of using the same kind of apparatus as above described, for compound fracture of the tibia and fibula, and also flexing the leg on the thigh by means of pillows placed in the popliteal region. At other times, I elevate the whole limb, keeping it in the extended position, while ordinarily a common pillow under the lower portion of the leg and heel, is sufficient to effect apposition of the distorted fragments. By this means, we create a single or double inclined plane, and hence can effec-

tually relax or stretch the gastrocnemii and solei muscles, the contractions of which constitute an essential element in this form of displacement. I have endeavored to demonstrate that it is not the *kind* of splint used by the surgeon, so much as the *principle* involved and the faithfulness with which it is carried out, that renders the treatment successful, and I think it matters little whether we make the bed the means by which extension and counter-extension is effected, or use a stick round, flat, or of any other form, so long as the requisite length of the limb is maintained. When it is so maintained, the limb will always be straight and perfect. I do not consider the apparatus as necessary for side support or co-aptation at all, but it is more convenient, is easily made, is light, and does not constrict the limb in the slightest degree.

The first case in which I was induced to try the apparatus was that of McD., in 1858, aged 50; hospital case No. 416, whose tibia and fibula received a compound comminuted fracture from the fall of a stone weighing 20,000 lbs. I applied a side splint for a few days, but found it impossible to keep the fragments from overriding, so that the upper one jutted outside of the skin. On the eighth day patient left the hospital, and I applied, at his house, the extension by the apparatus above described, when the pain soon subsided, and the bones assumed their normal position. At six weeks extension was discontinued, union being firm, and without distortion or shortening.

Michael Dregan, hospital case 590, aged 15, admitted July 23, 1859. Compound oblique fracture of tibia and fibula at lower third. The upper fragment protruded nearly three inches, and was returned only by great efforts. Limb was drawn down to proper length, and lateral splints, &c., applied to maintain it. Great pain followed, notwithstanding warm lotions and other topical applications. The next day, on dressing the limb, it was found to be two inches short. Applied extension and counter-extension, by apparatus, and without side splints, the limb being of full length. Upper fragment still overrides a little, but not sufficient to be a source of deformity. These fragments were fastened by silver wire passed through holes drilled in the ends, and twisted. From this time the suffering of the patient was entirely diminished. Extension was continued for six weeks. In eight weeks and three days he was discharged well, with a perfect limb.

John Silversmith, aged 24, hospital case No. 495, admitted

August 6, 1859. He fell about 20 feet, producing oblique fracture of tibia near the ankle joint, dislocating the fibula. Great contusion and distortion. Treated as above, and discharged well in 30 days, with a perfect limb.

Giles Dockstater, aged 29, hospital case 621, admitted Oct. 5, 1859. Was thrown violently from his carriage, producing compound comminuted fracture of the tibia and fibula, with great contusion and shortening. Treated as above, the limb being easily extended to proper length. On the third day was removed to his home in the country, since which I have not heard from him. Doubtless, if the same treatment was continued, his case resulted favorably.

Wm. Hogle, aged 35, hospital case 671, admitted April 16, 1860, with compound comminuted fracture of tibia and fibula, with much distortion and about three inches of shortening. Treated by Prof. James McNaughton by fracture box; and, in fact, all the ordinary appliances were used by that distinguished surgeon, for maintaining apposition. Notwithstanding his vigilance, the fragments continued to overlap, causing great uneasiness. Eight days after the accident extensive suppuration followed, with great constitutional disturbance. Fifteen days after the accident, no union, over  $2\frac{1}{2}$  inches of overlapping, and a small shell of bone in process of exfoliation. Extension and counter-extension applied, so as gradually to extend the limb and reduce overlapping. Thirty days after extension was begun, union was firm, although delayed by presence of necrosed bone (afterwards removed by the trephine. Forty-five days after extension, patient was dismissed well, with limb a little less than one inch short.

Patrick Carr, aged 21, hospital case 697, admitted July 14, 1860, with compound comminuted fracture of the lower third of tibia and fibula, with much contusion and shortening. Extension and counter-extension applied, and patient made comfortable, and remained so until dismissed 45 days after admission, with no shortening or distortion.

I quote these as fair samples of this mode of treatment as they were all bad cases and all resulted in perfect limbs. The advantage of this method is, that after the swelling subsides, and the dressings are readjusted, nothing is necessary except occasionally to tighten the cord by which extension is made, and also to add a strip or two of adhesive plaster to keep the line of extension perfect, inasmuch as the plasters sometimes slip upward on the

leg, from the natural heat and the depending position of the latter. The plasters are applied pretty firmly at first, and the patient visited soon after, when, if there be pain or swelling, the plasters are cut here and there until the feelings of the patient assure us that there is no danger of constriction. These little attentions are of vital importance at first, because negligence or carelessness is very likely to result in constriction of the limb with its attendant evils, often endangering the value of the limb, and sometimes life itself.

I make it a point either to visit the patient within six hours after the first dressing, or to leave directions with some intelligent member of the family how and where to cut the plasters if they become too tight by the swelling of the limb. Daily visits rarely have to be continued for more than a week; but it is always safest to watch broken limbs more closely than almost any other malady, for here the reputation of a surgeon is either secured or lost, to say nothing of legal responsibilities, which are more likely to accrue here than in any other branch of surgery.

Prior to the adoption of this method, I was constantly pained at results following compound fractures of the tibia, and much puzzled as to what course to pursue in order to avoid unfavorable results.

I well remember one which occurred as early as 1847, a case of compound fracture of the tibia and fibula with the bone, greatly protruding. I reduced it, but it would not remain reduced, and with all the appliances of art then at command, the case resulted unfavorably.

There was overlapping to the extent of  $2\frac{1}{2}$  inches, and great distortion. I do not doubt that this case would have resulted in a perfect leg, had extension and counter-extension been used, even without any splints.

This is not the only case where I have failed to make good limbs by following the old method, and using fracture boxes and such other appliances, while I hold that with extension properly made, there can be no distortion, and there ought to be but little shortening.

In addition to the cases already detailed, I offer three more, which were examined by Prof. Charles A. Lee, Dr. James R. Wood, and Lewis A. Sayres, while under treatment.

Case 1. A. C——, a boy of 16; oblique fracture of tibia and fibula at lower third. Dressed by extension and counter-extension; continued three weeks, when limb was found as perfect as the other.

Case 2. James Y——, aged 22; fracture of tibia and fibula; same treatment during five weeks. At the end of this time the limb was perfect.

Case 3. J. R——, aged 45, and weighing 300 lbs, and six feet six inches high, had oblique fracture of tibia and fibula; treated as above. Owing to the great contusion, the whole leg was covered with blood-blisters when these gentlemen saw the case; whereas, in the other two cases, fracture occurred on the same day, but this blistering did not appear. On the twelfth day he was moved three miles without displacing the dressings. Owing to his extreme length, the foot piece was crowded against the foot of the bedstead, thus somewhat retarding the reparative process. Six weeks from the accident, the dressings were removed and the limb found as perfect as its fellow. Inasmuch as the bones were not very strong, I applied some split deal for temporary support. Eight weeks after the injury, the bone being not strong enough to support his great weight, I applied a starched bandage and allowed him to walk about on crutches.

An inspection of all of these broken limbs, would leave the examiner in doubt as to whether they had ever been fractured; in fact, they were equally perfect with the sound and uninjured limbs.

*Treatment of fractures of arm by extension and counter-extension.*

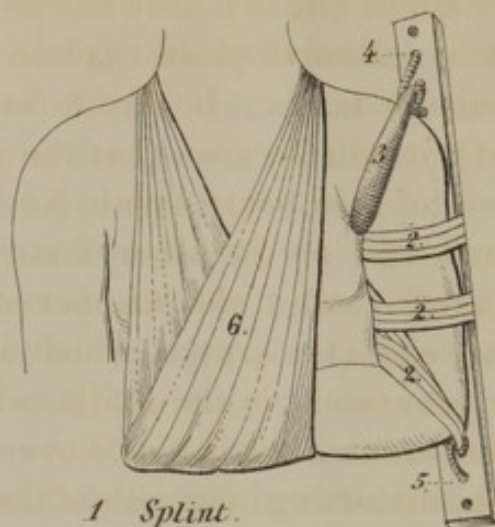
The fractures of the superior extremities are subject to the same laws, and hence require the application of the same principles. But, owing to the fact that the patient is not confined to the bed, the extension and counter-extension are necessarily made through the *medium* of a *splint*, while, in the lower extremities, the *bed* is the splint, the *foot* of the bedstead the point of *extension*, and the *headpiece* the *counter-extending point*.

In fracture of the humerus through any portion of the shaft, simple extension can be made by having a splint extending three inches below the elbow and the same distance above the shoulder. The elbow is secured to the lower part of the strip of board by means of adhesive plaster passed through a fenestrum, while to its upper extremity it has fastened the extremities of an axillary belt. We are thus enabled to obtain full extension and counter-extension with comparative ease and comfort to the patient, the muscles making the only true splints. The arm is kept in a sling, and if the surgeon feels any uneasiness as to the disposition of the bone, he can place a strip of adhesive plaster loosely at short



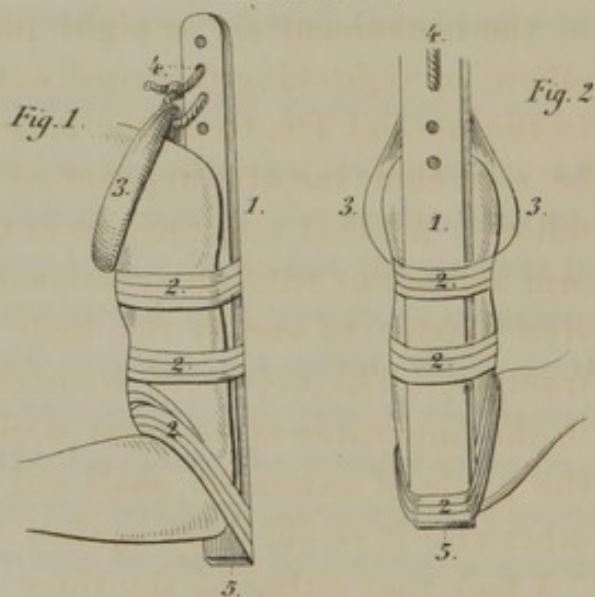
# PLATE N<sup>o</sup> 4.

*Fig. 1.*



- 1 Splint.
- 2 Adhesive Plaster.
- 3 Wadded Strap.
- 4 Counter Extension.
- 5 Extension.
- 6 Slings.


# PLATE N<sup>o</sup> 5.



*Fig. 3.*



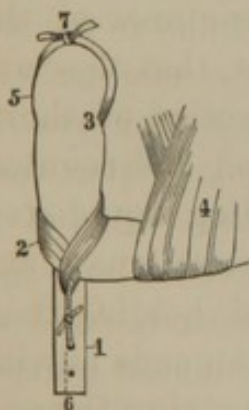
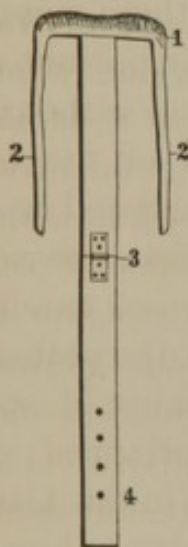
- 1 Splint.
- 2 Adhesive Plaster.
- 3 Wadded Strap.
- 4 Counter Extension.
- 5 Extension.



*Fig. 4.*

intervals about the arm and splint, so as to prevent any kind of lateral motion in the parts. (See figure No. 1.)

In plate No. 5, the splint (fig. 4), does not go below the elbow, but is fastened to it by adhesive plaster (plate No. 5, figs. 1 and 2), after full extension is made. In No. 3 (my almost uniform method of treatment), it will be seen that the splint is made by taking a delicate piece of thin board (plate No. 4) or lath, boring some holes in one end, and on the other fasten an axillary belt (plate 5, fig. 3), somewhat after the manner of a perineal belt, the counter-extending end (the crutch, which is heavily padded with this belt), fits accurately in the axilla, while the two ends of the belt are carried around and fastened over the shoulder, the better to dispose of the distorting influences of the pectoral muscles.



This crutch apparatus (plate No. 6), extends from the axilla along the inside of the humerus to about six or eight inches below the elbow. Strips of adhesive plaster are placed longitudinally about the lower end of the humerus, so as to form a loop, through which is passed a cord, and thence through a hole in the lower end of the instrument six or eight inches below the elbow, by tightening this cord, extension is made to the normal length of the bone; when it will be seen that the arm appears as natural as its fellow. All that now remains is to surround the arm and splint with an occasional strip of adhesive plaster to steady the limb at the seat of fracture. The object of connecting the elbow to the apparatus at so great a distance, is that the angle of extension shall not be too obtuse, otherwise it would draw against the splint.

I find that either of the three forms of apparatus fulfills all the indications of an axillary

of apparatus have succeeded most admirably, and are well adapted to the treatment of fractures occurring in any portion of the humerus, from the surgical neck down to within two inches of the elbow joint. In fractures occurring immediately below the insertion of the pectoralis major and latis-

Plate 6.—1, apparatus; compress, also extension and counter-extension, 2, plaster; 3, crutch; 4, sling; 5 counter-extension; 6, extension; 7, strings.

simus dorsi, there exists the necessity of overcoming the distorting influence of these muscles; it would have its broken end carried directly toward the body in a line with the muscles and at right angles with the shaft of the bone. The *crutch* or axillary *belt* will fulfill this important indication, first, of crowding the fragment of bone outward; second, the pressure upon the tendons of the pectoralis major and latissimus dorsi prevents the direct action of these muscles upon the broken fragment of the bone (the same as a perineal belt in a fractured thigh in disposing of the adductors), while extension and counter-extension fulfill all the indications of caliptation.

These are important considerations in treatment of fractures occurring through the surgical neck of the humerus, whether it occur above or immediately below the insertion of these muscles, the indications are the same, while the crutch is important and so indispensable that even extension is of little value without it; many say that there is more danger of separation of the fragments of bone than there is of overlapping. In answer I would say that I have yet to see the first case of oblique fracture without overlapping of the fragments. Examine your cases carefully and you will find that this assertion is true. Visit the pathological museums of the country and see the great number of specimens (fractures of the humerus) which are overlapped very considerably and some very much distorted. I find in the Albany Medical College museum eighteen cases that are more or less distorted and shortened. Examine all standing fractures of the arm, and you will find by absolute measurement that they are short  $\frac{1}{2}$  inch to  $2\frac{1}{2}$  inches. It is not for the objection of shortening alone by any means that I propose extension and counter-extension, but for the double purpose of preventing any distortion, and more particularly of keeping the muscles tense, and bringing the bones into their normal position and holding them there, so that there is no possibility of the broken ends moving and rubbing against each other and thereby destroying the provisional callus, and also stretching the muscles that they may act as splints. No one can appreciate this tenseness of muscular fibre until he has tried the experiment upon a broken limb. Take, for instance, a limb dressed with the most approved surgical appliances, note the degree of suffering, remove all these, gently extend the limb to its normal condition, fasten it there until the spasm has subsided, and you will find a marked differ-

ence in the patient's comfort. Now if this extension is made through the medium of an apparatus which is fastened to the limb, it will be found that the motions and rotations of the limb are made with ease and little discomfort, the broken limb moving as a whole and rotating at the joint and not at the seat of fracture, while, on the contrary, move the broken limb while encircled by splints applied in the ordinary way, and the motion at the seat of the fracture is made manifest by the severe pain from the bones rotating at the seat of fracture, while motion in the joint is very limited. These experiments have only to be tried to be appreciated. I have had the privilege of testing this upon a very intelligent gentleman of this city who had the misfortune to break his arm, and who fully appreciated my motives. The reader is also referred to the case of L., hereinafter reported, as being quite appropos of extension, muscular splints, crutch, &c.

I wish to call attention to the two following cases, the first of which (through the politeness of the resident surgeon of the New York City Hospital) I was permitted to examine. I found it in as good condition as a fracture could be, treated without extension, and simply by the ordinary appliances of axillary compress bandages, splints, &c. The superior fragment was dragged or twisted around and on a line with the tendon of the pectoralis major, the sharp point of which seemed as if it would ulcerate through the skin. The shaft of the bone overlapped the side of the upper fragment, producing about  $1\frac{1}{2}$  inches of shortening, and presenting the same kind of deformity as is found in the following case, and which would not have resulted as well as this by any treatment except the one practiced, i. e., extension, counter-extension, and axillary belt or crutch.

July 29, 1859, admitted to Albany Hospital, James Keating, aged 18. Fracture of surgical neck of humerus, very oblique, and being much distorted. Fracture occurred some days before, during which time a good surgeon and physician had been treating it with splints, bandages, axillary compress, etc., but with obvious bad results; since, at the time of his admission, there existed about two inches of overlapping and great distortion in the direction of the pectoralis major, &c. The application of the crutch apparatus with extension and counter-extension restored the natural position of the parts; and this was continued for three weeks, when the arm was found firmly united; and though considerable bony callus was present, the arm was progressing

finely. Oct. 26th, eight weeks and three days, discharged with a perfect arm.

Oct. 20, 1860, D. W. Wilson, aged 9, (same boy whose case is reported among the broken femurs produced by being run over by a heavy truck), comminuted fracture of the arm, (about four inches broken into fragments); great contusion and inflammation of soft parts. Dressed with crutch apparatus, the inferior portion of which did not extend below the elbow; drew the arm down to its normal position, and retained it there by strips of adhesive plaster passed about the arm and splint and elbow; this was done as a matter of convenience, (since he was confined to the bed with his broken and crushed thigh, besides several severe flesh bruises.) Twenty-five days after the injury the fragments seemed quite firmly united together; at forty days all dressings discontinued; arm perfect, very little callus, and absolutely no shortening or distortion. This fracture extended from within two inches of the joint downwards, three to four inches comminuted so that I could feel at least four distinct fragments. The question may be asked, how is it that a fracture like this can unite so as to have so little deformity? I answer, that by making tension upon the arm or limb, the soft parts become so tense that the bone is absolutely forced into its natural relations, and if examined while thus on the stretch, that no deflection, distortion or change of bony relations can be discovered without again relaxing the tension or bending the broken bone. Admitting this fact, it only remains to fix the limb without state of extension, to obtain union with perfect results. I have only reported the more important cases, and such as will demonstrate fully the results of this mode of practice. I will quote one more only, and as it occurred, in the practice of Dr. S. O. Vanderpoel, of this city, who kindly furnished me the facts, I will give them in full, for the reason that the accident occurred in one who can appreciate the difference between comfort and discomfort, having worn the ordinary dressings, and being confined mostly to his bed for some days, when they were replaced by permanent extension by the crutch apparatus. As will be seen in the report, the transition from pain and confinement to ease and freedom, was immediate and marked:

"Mr. L., aged about 30 years, fleshy and rather muscular, slipped on the evening of the 13th of March, and, on falling, received the force upon the ball of the thumb and inner condyle of the humerus; the humerus fractured at the junction of the middle

and upper third, the lower part overriding very prominently, and causing about three inches shortening. From the contusion of the forearm, and the knowledge that erysipelatous inflammation supervened with him from slight causes, the arm was merely reduced, placed in simple splints, and upon a pillow. On the sixth day the inflammation had so far subsided, that it was deemed prudent to apply permanent extension, on account of the distortion of the bones, to overlap. On removing the plain splints, shortening was found to have occurred from the spasmodic action of the muscles. This arm was now dressed with the crutch apparatus, with extension and counter-extension, when the arm was firmly drawn down to its proper position. The relief was immediate and very great, for he could freely move both the shoulder and elbow joints, while the shaft of the bone was immovable. He moved about at once with the greatest ease, and was materially relieved from the laminating pains in the arm. After two weeks' application the splint was removed; the limb was handsomely united, so that a starch bandage will be sufficient to protect and steady the arm.

*Treatment of fractures in or near the elbow joint, with or without dislocation.*

The most important forms of fractures are those situated near and involving the elbow joint, either of the bones of the forearm or arm. In this position, extension by direct means would be inadmissible for several reasons; the least important one being the awkward position of the arm for comfort to the patient. The plan I propose is simple, the apparatus easy of manufacture, while the extension and counter-extension is effected by simply flexing the forearm at right angles with the arm, and maintaining it in this position, thus effecting all the required conditions for a perfect apposition. The instrument is made by taking two pieces of thin board, one quarter inch thick, fastened at the bend of the elbow by a hinge one or two inches wide, the lower portion extending from the elbow to the ends of the fingers, or even two inches below; the short portion extending from the elbow to the shoulder, terminating in a crutch for counter-extension; or the same end can be attained by fastening the upper end of the splint to the arm by means of adhesive plaster with the arm in an extended position. The lower end of the splint is fixed to the hand and fingers with adhesive plaster, the other to the arm by the same means, or to the axilla by a crutch. Now, flex the

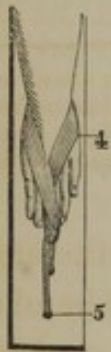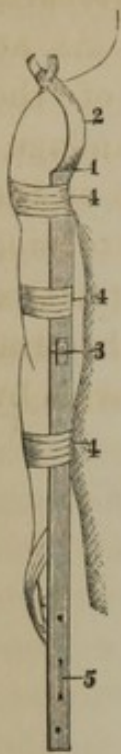


Plate 7.—1, counter-extension; 2 strings; 3 hinge; 4 strips of adhesive plaster; 5 extension.

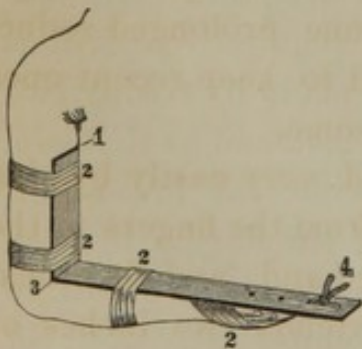


Plate 8.—1, counter-extension; 2 adhesive plaster; 3 hinge; 4 extension.

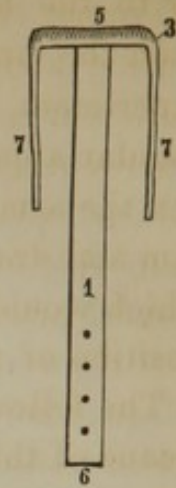


Plate 7.—1, axillary crutch; 2, strings; 3, hinge; 4, extension.

forearm upon the arm, and you will produce from one to two inches of extension, depending upon the diameter of the arm. (Plate No. 7, fig. 1, 2, 3.) This form of dressing is especially applicable to fracture of the ulna and dislocation of the humeral portion of the radius fracture of the humerus through the olecranon and coronoid processes, and where the fragment is displaced with the ulna. The complication of displacement of the head of the radius, or even fracture of this bone, will not alter this mode of procedure.

The material fault of ordinary dressings for the elbow joint, is the want of proper extending influences. There is usually much distortion from overlapping of the broken bones caused by irritation of the muscular fibre. This has to be overcome, else there is distortion, and at best there is always too much deformity for the credit of surgery.

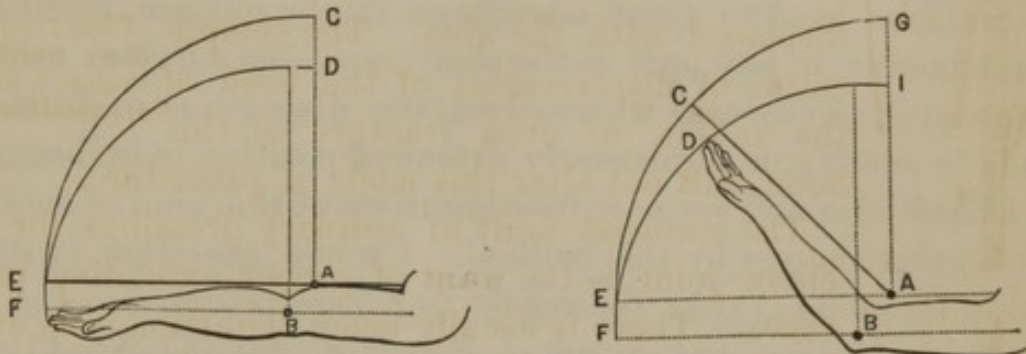
I fully believe that the application of this principle will almost, if not entirely, obviate the deformity consequent upon this fracture; and surely the profession want something for this, more than simple angular splints, since more bad results follow this fracture than any other in the body except intra-capsular fracture of the femur. It matters little what kind

of a hinge is at the elbow, whether it is made encircling the angle of the splint with adhesive plaster, cloth, leather, or a common table hinge, so long as it fulfils the indications and keeps the fragments in position. The important point is, to present the two points, i. e., extension and counter-extension, and this I sometimes

effect by a hinge (plate No. 8) apparatus that only extends a few inches above and below the joint. Apply the apparatus in the extended position of the arm by fastening the two ends with strips of adhesive plas-

ter to the arm and forearm respectively; then flex the forearm upon the arm and the requisite extension will be made. As an experiment, apply the same without fixing the ends of the angular apparatus, (Day's, or the Rose splint), with a bandage; flex the arm, and it will be found the ends are moved up on the arm and drawn on the forearm, thereby losing all the extension which would otherwise be obtained by the change in the relative position of the hinge in the apparatus and the bones of the arm.

The following diagrams illustrate the principle of extension by means of this apparatus :



*a*, Fig. 1, is the joint of the instrument, *b* is the elbow joint. The joint *a* is about one or one and a half inches above the joint *b*, and from one and a quarter to three inches in front of it. The end of the instrument and the forearm extend to the same point. Now, semiflex the forearm, and the splint will extend farther than the fingers by the distance *c d*, fig. 2, and when the flexion extends to a right angle, the difference is *g i*.

It is plain, therefore, that if the hand be made fast to the end of the instrument while extended, then, when it is flexed, the hand and the end of the instrument will describe the same circle, and both extend to the point *g*, the forearm being forcibly extended, the amount of extension being proportional to the diameter of the arm—in other words, the vertical distance between the joints of the arm and instrument respectively, and also the horizontal distance between them, so that, by means of this simple arrangement, sufficient extension is made to continue prolonged reductive efforts in old standing dislocations, and to keep recent ones reduced, which might otherwise be troublesome.

The principle involved may be illustrated very easily by simply placing a bit of board on the forearm, from the fingers to the elbow, fixing it at the joint with the other hand, and then flexing, when it will be seen that the splint extends two inches or more beyond the fingers, as is seen in fig. 2, compared with fig. 1.

Suppose we have an oblique fracture of the humerus, with an inch of overlapping of its ends. Apply the extended splint to the extended arm; let the hinge of the splint be an inch lower

down than the elbow joint; secure the splint to the arm, and flex: then when the arm and splint are at right angles, the humerus will be extended to the amount of one inch, and thus of normal length; vice versa, to obtain extension upon the bones of the forearm, it is only necessary to place the extended splint in such a position that its hinge shall fall above the elbow, when, by flexing, the action is reversed, and the extension produced between the elbow and hand, or lower forearm.

From the description of the apparatus, its applicability to all fractures, both of the arm and forearm, will be readily inferred. It could be used to great advantage in any oblique fracture of the humerus, in any part of the shaft, or of the surgical neck, or in general, in any case where, from the disposition of fractured ends to overlap, a permanently extended position is indicated.

I have been and am now treating cases of this kind of accident with great success by this method. I would, therefore, (without going into detail) refer the reader to a case reported in the Philadelphia Medical and Surgical Reporter, vol. 3d, No. 11, new series, where there had been a fracture of the ulna eight weeks previous and dislocation of the radius. The ulna was united, but overlapped about two inches and very much distorted one fragment, nearly pricking through the skin. The radius was dislocated anteriorly upon the anterior face of the humerus, so as to effectually prevent any great degree of motion. After breaking up the bony union of the ulna and reducing the radius as far as the fibrinous deposits would allow, I applied this apparatus, and in the course of four weeks effected gradual reduction of the radius and union of the ulna in its normal position, leaving a perfect result, though there remains a slight prominence of the head of the radius. I know of no other means by which this end could be accomplished. Dr. Craig, of this city, has tried this method, and inasmuch as his testimonial is so perfectly in accordance with my experience, I will give it in full:

ALBANY, *April 4*, 1861.

DR. SWINBURNE:

Dear Sir—It affords me pleasure to bear testimony to the satisfactory results attained in the treatment of fractures by your method of extension and counter-extension. The following case of its application came recently under my observation:

J. E., aged 12 years, fractured the radius and ulna near the middle of the arm, in jumping from a sleigh and falling with

great violence upon the ground, producing great distortion, on the afternoon of December 14, 1859. I applied the usual dressing of side splints and compresses; the arm swelled considerably and continued very painful, while the distortion was uncontrollable until the 16th, when you called and recommended the use of a hinged splint, by which the arm was put upon simple extension and counter-extension. The pain and distortion immediately subsided, and the boy experienced no inconvenience from the fracture, except the consequent confinement to the house. On January 7, a period of about three weeks, the dressings were removed, union having taken place perfectly. Two months after the place of fracture could hardly be detected. I have since treated three other cases of fracture by similar appliances with the same result.

Yours, respectfully, WM. H. CRAIG.

*Treatment of Fractures of any portion of the Radius and Ulna, from the carpus to those situate near the elbow-joint, also Colles' and Barton's fracture, by means of a single posterior extending apparatus.*

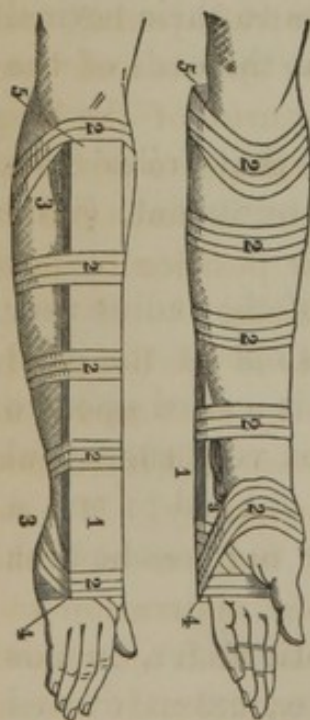
In the treatment of fractures through the shaft of the radius, or radius and ulna, I use a simple splint situated on the posterior part of the forearm, fastened at the bend of the flexed arm by adhesive plaster, and the other end to the wrist by the same method, so that you get extension of the muscles to their normal condition, and also by this means approximate the ends of the bones.

In the preliminary part of this article I stated that Colles' fracture was the only exception to this plan of treatment, (i. e., simple extension.)

(Colles' fracture, which consists in fracture of the radius near the carpus, and dislocation of the ulna. presents one of the most troublesome forms of fracture that the surgeon is called upon to treat. This last appliance has in my hands been very successful in the treatment of this accident, though I am obliged to use a compress in the concavity of the wrist in order to give the ulna sufficient posterior prominence.)

By exception I do not mean absolute exception, for, in this form of fracture, we require the two points, i. e., extension and counter-extension, and, inasmuch as the arm in its normal condition, does not represent a straight line, we require some posterior deflection at the wrist to imitate a normal arm.

This posterior deflection and extension I have successfully obtained by the use of one splint, made of thin material, (a piece of cigar box,) and applied to its posterior aspect, no wider than the arm, extending from the point of the elbow to the metacarpophalangeal articulation, and having two compresses, one of which fills the posterior concavity of the carpus, and the other to supply the deficiency of the straight line at the elbow. Now apply the splint (fig. 1) to the posterior surface of the arm, fasten the upper end of it to the elbow by means of adhesive plaster, enclosing the end of the splint, and applied in a serpentine course about the arm, so that it cannot slide upward. Now, make the proper extension on the hand, and at the same time counter-extend, by pushing up the carpal end of the splint, continuing this effort at extension and counter-extension until full reduction of the fractured radius and dislocated ulna is effected; then the splint is fastened to the hand by the same serpentine application of the plasters. At this period of the dressing it will be seen that the compress (fig. 3) seems to crowd the splint away from the arm, when, in fact, the limb is only straight, which is not its natural condition. All that is now necessary to complete the dressing, is to press the carpal end of the fore-arm gently backward against the splint, and retain it there by the adhesive plaster passed around the arm and splint. (fig. 2-2.)




1. Splint; 2. Adhesive Straps; 3. Compress; 4. Extension; 5. Counter-extension.

By this simple plan I have now treated eight cases of Colles' fracture, and in all of those where this treatment was carried out it resulted in the full restoration of the limb without the splint ever being removed, and with only an occasional addition of a few pieces of adhesive plaster to perpetuate the extension and retain it in position.

These results are so good that in *Case No. 3*, seen by Dr. Lewis A. Sayre, consulting surgeon to Bellevue Hospital, New York, the affected arm was pronounced as perfect as its fellow.

The dressings were removed from this arm on the 22d day of its treatment, and he saw it on the 26th day after the occurrence



of the accident. This was distorted at the time of fracture as much as it could be with fracture of the radius, and complete antero-lateral dislocation of the ulna, giving it the peculiar appearance called the *silver fork* deformity.

A surgeon would naturally think that little more could be said of the treatment of fractures after reading the complete and comprehensive work on Surgery, by Prof. Samuel D. Gross, of Philadelphia, in which this subject is fully and ably discussed; and though I may disagree with him on several points, as regards the treatment of fracture, and especially this one, I hope he will receive it with due kindness by showing me wherein I am wrong. In reference to the band apparatus for the treatment of Barton and Colles' fracture, he says: "Having encircled the thumb and fingers, the better to control the resulting swelling, and the fracture having been adjusted by pressure and extension, a roller is next passed around the limb as high up as the superior part of the fore-arm, special care being taken that it shall not produce the slightest constriction anywhere."

Now, we start with the assertion that there is no need of bandaging in the treatment of fractures at all, and that the treatment is more speedy and comfortable to the patient without bandages than with them. I have now treated, without any bandages whatever, forty fractures of the thigh, in every portion of its shaft, simple, compound, comminuted, and intra-capsular, and with better results than would be obtained by splints and bandages. I have treated over one hundred fractures of the long bones with no bandaging, and only dressing enough to perpetuate the extension, which, in my humble judgment, is much better than trying to force the bones to maintain their position by lateral pressure with bandages, compresses and splints.

If the source of irritation, (the fractured ends of the bones,) is removed by their reduction and maintenance by such means as will not obstruct circulation and cause infiltration and inflammation, the precautions as to bandaging are unnecessary. If bandaging, at the time of its application, does not produce the slightest constriction anywhere, the subsequent infiltration and inflammation of the tissues will soon make the limb an uncomfortable bedfellow, as every day's practice will sufficiently attest.

I think it is not the bandaging at the time that produces all the bad results we occasionally see; it is the subsequent swelling. I regret to say that the profession, sometimes, sacrifice every-

thing to appearance. A beautiful dressing (with them) is synonymous with a good result.

Now, if there is no necessity of bandages in the treatment of fractures, why not dispense with them as much as possible, as they are painful and troublesome in their application, and in all the subsequent dressings still more so.

They constrict the limb, producing more or less mischief—1st, by the extra warmth of the parts; 2d, obstruction to circulation; 3d, difficulty of examining carefully the position of the bones; 4th, the trouble, pain and disturbance of the bones in re-dressings. Per contra, by the plan under discussion the limb is kept cool, is examined at will, and little constriction ensues. Hence, little or no pain is experienced during the process of reparation, and no disturbance caused in re-dressing. From the inspection of the wood cuts in Prof. Gross' work in the treatment of this fracture, the hand is allowed to drop or slope, as he says, "so as to put the extensors of the thumb slightly on the stretch," and, in relation to this form of displacement, he says: "The above dressings, (Bond's,) and a modification of Bond's\* splints, will answer equally well, whatever may be the character of the displacement, whether backward or forward." I think that this simple dropping or flexing of the hand to the ulnar side effects something still more important than simply "to put the extensors of the thumb slightly on the stretch." It forces the dislocated ulna backward in its normal position posterior to instead of anterior to the carpus, and in apposition with the os pisiforme. By this means he makes the hand the lever, the ulna the fulcrum, the distorted radius and extensors of the thumb the resistance, while the ulna is moved or pried into its normal position by this leverage. It cannot pass by the pisiform bone in front, and hence a reduction of necessity is effected, though not as complete as could be desired. The radius is, of necessity, elongated, and hence, by these means, extension is obtained without really appreciating it.

Take, for example, an old unreduced Colles' fracture, where

\* I see, by a reference to the journals, that a splint devised by Dr. Geo. F. Shrady, of New York, is applied with great success in the treatment of this form of fracture, thereby obviating the so-called "silver-fork" deformity. Although the principle of extension and counter-extension by Dr. Shrady's plan is similar to that which Prof. Gross recommends, and the peculiar flexed and adducted position in which he places the hand is sufficient to maintain the fractured ends in apposition, I would, however, say, in relation to the splint, that in the first place it is not always at hand; second, its results *can* be no better than those obtained by the simple method of treatment by a shingle, piece of cigar-box, or any other piece of thin board by which to keep up the extension and counter-extension.

the ulna is resting against the os pisiforme, as it is in a recent case—imitate the movements necessary for replacement by Bond's apparatus—note the difficulty in anterior or lateral ulnar flexion.

Here, then, you have the solution of this problem. Lateral flexion and moderate extension replaces the ulna and radius, while the continued lateral flexion retains the ulna and prevents any subsequent displacement; while the extensors could not displace the wrist as long as the ulna plays the part of a radius, even though it is not absolutely in its normal position. The advantages of the form described in this paper can be summed up in a few words:

1st. The hand and arm are in a straight position and not encumbered by clumsy dressings, so that a business man can dress himself and go about as usual.

2d. It can be examined at pleasure, while any lotions do not disturb the dressings.

3d. From the first, the ulna assumes its natural relations with the pisiform bone, and the whole wrist seems at once restored to its natural symmetry.

4th. The swelling which may ensue does not disarrange the dressings or jeopardize the integrity of the parts.

5th. No re-dressings of the limb become an absolute necessity.

6th. The material is always at hand, easily applied, and with little suffering to the patient, except slight uneasiness for two or three days, after which, I may say, there is almost absolutely none.

7th. Union is effected much sooner by this method when the parts are not constricted and absolutely at rest.

8th. The ultimate restoration of the joint to its normal usefulness is obtained much sooner, for this reason, that there is less infiltration and subsequent inflammation where there is no pressure by splints and bandages, etc., to obstruct circulation than where they are used in the ordinary way, though applied with every precaution.

The simplicity of this dressing recommends its consideration and use, even though it were only *equally* efficient with other modes of treatment.

Six out of eight cases treated by this method were discharged as perfect results at periods varying from twenty-one to twenty-five days, while union was complete at from sixteen to eighteen days. In one instance, it was allowed to remain for thirty-two

days, at the earnest solicitation of the old lady, who had already one silver-fork deformity—which occurred in the “ould counthry”—and did not desire any more. The remaining two passed out of my hands, one (the Scott case, No. 7,) to the western part of the State (Livingston county). I learn, though the dressings were not disturbed after he left this city, that his arm is perfect. This was the Hon. Mr. Scott who kindly consented to present himself before the State Medical Society, that they might see the dressings as applied, and the position of the bones. None of the learned members could take exception to its position.

The second (case No. 5), passed into the hands of a New York doctor, and did not fare so well, as will be seen by the extracts of a report written me by a grandson of the lady. She left here on the fourth day after the accident for New York with all the parts in apposition, and with every prospect of union in twenty-two to twenty-five days. He writes me, under date of February 20th, 1861: “The plasters were all taken off, the wrist bandaged and kept in a paste-board rest. It seemed to mend slowly; but about four weeks after the fracture, the hand swelled very considerably, and the skin appeared very much puffed up. Perhaps this was owing to the bandaging too tightly, as, on being loosened, the swelling subsided slowly. About eight weeks after the fall, the bandages were left off, and then it was found that, besides the fracture, the wrist had been very much sprained. The fingers are yet stiff and very clumsy.”

This case, when collated with the other seven, stands out in bold relief, and would really seem to require no comments, but inasmuch as I am familiar with the details of the treatment, and the character and results, I will venture to indulge in a few remarks.

First. The seven treated without bandaging and constriction from the beginning to the end, resulted in perfect arms, and in from twenty-two to thirty days, and some of them were much more bruised and distorted than hers.

Second. While in this special case, No. 5, the extension was removed I suppose about the fifth or six day; also, the means of keeping the dislocated ulna in its normal position, were dispensed with, and in its place a bandage was “applied around the hand and wrist, and the arm laid in a pasteboard rest. About four weeks after the fracture the hand swelled!” At four weeks there should have been no swelling, nor should there have been any

need of bandages to make the hand swell and puff, and at eight weeks (56 days), only the bandages are removed. Surely, time enough was here consumed to have perfected the cure in three such fractures. After all these fifty-six days are consumed in the treatment of Colles' fracture, they gravely tell us that "the wrist had been very much sprained," as if dislocation and fracture, followed by infiltration and inflammation, and aggravated by tight bandaging for four weeks, and moderate bandaging for four more, with no passive motion, is synonymous with a simple sprained wrist!

I mean not to reflect unjustly on any practitioner, but simply wish to lay these cases, with their treatment and ultimate results, before the profession, as they were all equally fair cases for good results, and this one in particular.

Case No. 1. Mrs. —, aged 40, American, good habits and constitution. December 8, 1861, fell on the ice fracturing the radius and dislocating the ulna. Dressed with splint on the dorsal surface of arm, as delineated in this paper. Applied cloths wrung out of warm water—pain and swelling disappeared on the third day, but no disposition to displacement in any direction—no redressing—well in twenty days, and all dressings removed in twenty-two days; arm as perfect as its fellow.

No. 2. Mrs. J. U—, aged 50 years, Irish, office patient. January 4, 1861, Colles' fracture was produced by a fall on the ice; great distortion. Dressed as above. Called at office every third day, when an occasional plaster was added, but no re-dressing until the twenty-third day after accident, when all dressings were removed, leaving a perfect arm.

No. 3. Mrs. J. R—, aged 38, English. January 10, 1861, produced Colles' fracture by a fall on ice. Great distortion and intense pain, which was instantly relieved by the application of the splint with the extension, warm water dressing, etc. Dressing removed in twenty-two days, leaving a perfect arm. This Dr. Sayre, of New York, saw with me on the twenty-fifth day, and pronounced it perfect.

No. 4. Mrs. J. E—, aged 39, Irish, office patient. January 2, 1861, fell on ice, producing Colles' fracture, with great distortion, pain, and swelling. Dressed as above, and though I did not see this patient for three weeks after the injury, and found that there had been no re-adjustment of the adhesive straps, no re-dressing, the dressings were entirely removed on the fifteenth day

by the patient herself, when she commenced using it in her household duties; and I saw it at twenty-three days after the accident; she complained that it was too weak "for washing heavy things with." Notwithstanding the early removal of these dressings, and the little medical attention bestowed, the result was good.

No. 5. Mrs. W——, aged about 60, American. December 5, 1860, fell on ice, producing Colles' fracture, with dislocation of ulna; great distortion, pain, and swelling. Dressed as above; applied warm water dressings. Pain subsiding gradually on the fourth day, when she left for New York, swelling nearly all subsided, and little pain remaining. Parts in perfect position.

No. 6. Mrs. R——, aged 70, Irish. January 20, 1861, fell down stairs, and produced Colles' fracture. Intense pain, great distortion, and swelling. Dressed by the above method and lotions. Union formed in twenty-two days, but from solicitation of patient left dressing on a few days longer, when it was found perfect.

No. 7. Hon. Mr. Scott, aged 50. February, 1861, slipped on the ice, and produced Colles' fracture, with great distortion and swelling. Through the politeness of Dr. Mason F. Cogswell, of this city, I was permitted to take charge of the case, as also the following one, No. 8. Applied the above dressings and lotions, and on the fourth day he was well enough to present himself to the State Medical Society then in session in this city, with his arm passed through his coat sleeve as usual, and supported by a sling. On the fifth day he returned to his friends, since which I learn that the arm will be perfect, and that no change was made in the dressings after he left the city.

No. 8. Mr. J. O——, aged 50. February 10, 1861, fell on ice, producing Colles' fracture, with moderate distortion. Dressed as above; same treatment. Dressings removed in twenty-two days, leaving a perfect arm.

In all of the above cases there is more or less stiffening of the wrist and fingers for a time, but much less than there is when any considerable constrictive power is used, and particularly when the relative position of the dislocated joint and fractured ends are fully restored to their original condition.

There is a second and even more important consideration to be fulfilled, and that is to separate, so as to prevent friction of the dislocated ends of the bone, (without constricting them,) thereby

imitating the now received notions for the treatment of recently inflamed joints.

I have now treated eight cases of this form of fracture, seven of them with the best possible results by my method, and they will bear comparison with those treated by any other. In fact, they are as perfect as they were before the accident. The fractures managed thus are nearly painless; and none of them have required re-dressing during three weeks of treatment except an occasional addition of a new adhesive strip to perpetuate the extension. There is so little incumbrance about the limb that it can be examined without disturbing the dressings, while there is no swelling from tight bandaging, and the application of warm or cold water does not disarrange the dressings.

*Treatment of fracture of the clavicle by simple extension.*

In treatment of fractured clavicle through any portion of it, or in fracture of the coracoid process of the scapula, the common treatment has always been to draw the shoulders backwards, and thereby apply this principle to its fullest extent without any appliances of adjustive splints, and who ever failed to obtain union of the clavicle?

The plan I have adopted with success, and particularly in children, is to overlap their clothes in the back and pin them firmly in that position. I have found a strong waistcoat closed in front answer a very good purpose for the adult, pinned or laced up behind, thereby effecting all the requisite ends without the annoyance of wearing all mechanical appliances made and applied "secundem artem." In this way patients go about with all their clothes in position, as if nothing serious had happened. If a portion of the bone should become prominent, I am in the habit of using strips of adhesive plaster drawn tightly over the projecting fragment, and thereby keeping it in its proper place.

The following diagram, (plate 9) fully illustrates the principle upon which lateral support is based. By reference to fig. 1 it will be seen that the line of extension is from *a* to *b*, and directly through the center of the shaft, while the bone assumes the natural position. Contrast this with fig. 2, where the extension is made through the apparatus *a*, *b*, and distorts the shaft of the bone. (See line *e*, *f*, fig. 2.)

Fig. 1 represents a humerus, femur, or tibia, treated by simple extension without splints.

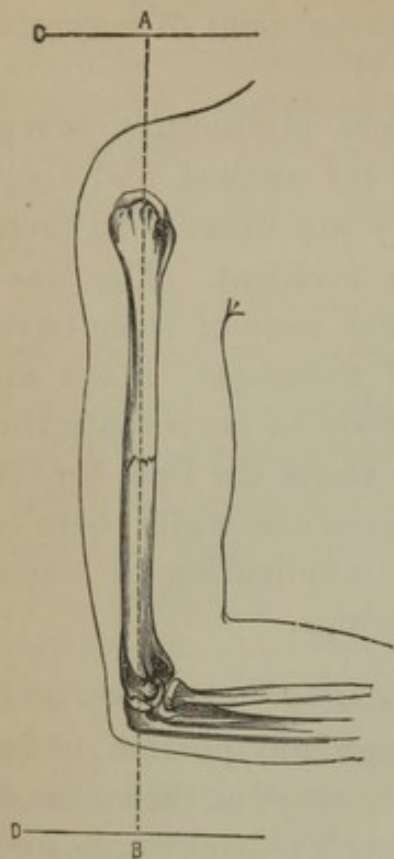


Fig. 1.—*a, b*, Line of extension; *a*, counter-extension; *b*, extension; *c*, head of bed; *d*, foot of bed.

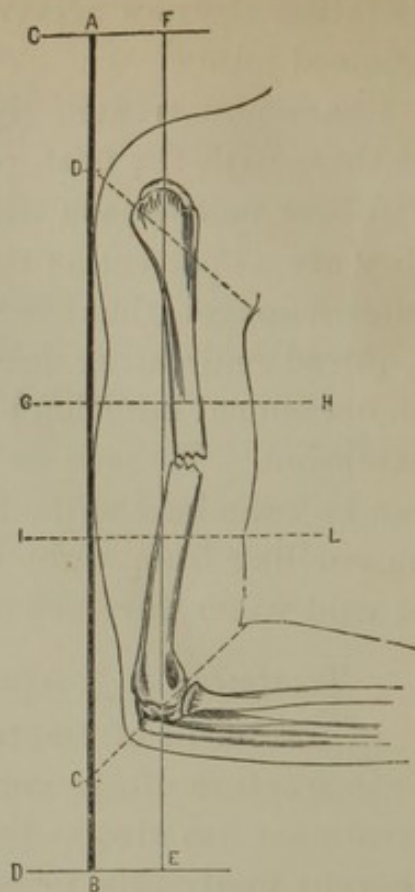



Fig. 2.—*a, b*, Splint through which extension is made; *a*, counter-extension; *b*, extension; *c*, hole in splint through which extension is made; *d*, same for counter-extension; *g, h, i, j*, represent the position for plaster in this fracture.


Fig. 2 represents the principle of the treatment of a femur by a Liston splint; a tibia treated by my apparatus; a humerus treated by any of the above named appliances; also the appliance for Colles' fracture.

I think this fully demonstrates where the necessity for the support by adhesive plaster exists.

While in simple extension, without splints, the limb requires no lateral support; per contra, when the extension is made outside of the long axis of the bone, and by the side of the limb, that the limb must be fastened to that line.

ERRATA.—The cut of a Crutch, *with* hinge, on page 33, should go on page 38; and cut of Crutch, *without* hinge, on page 38, should go on page 33.—DR. SWINBURNE.





82

---

DR. SWINBURNE

ON THE

TREATMENT OF FRACTURES OF THE LONG BONES.

---

REPRINTED FROM TRANSACTIONS OF THE MEDICAL SOCIETY OF THE STATE OF NEW YORK, 186

