CLINICAL RESEARCHES

IN

ELECTRO-SURGERY.

ROCKWELL—BEARD.

CLINICAL RESEARCHES

IN

ELECTRO-SURGERY.

BY

A. D. ROCKWELL, A.M., M.D.,

FELLOW OF THE N. Y. ACADEMY OF MEDICINE; MEMBER OF THE N. Y. COUNTY MEDICAL SOCIETY; ELECTRO-THERAPEUTIST TO THE N. Y. STATE WOMAN'S HOSPITAL,

AND

GEO. M. BEARD, A.M., M.D.,

FELLOW OF THE N. Y. ACADEMY OF MEDICINE; MEMBER OF THE N. Y. COUNTY MEDICAL SOCIETY; ELECTRO-THERAPEUTIST TO DEMILT DISPENSARY.

NEW YORK:
WILLIAM WOOD & COMPANY,
27 GREAT JONES STREET.
1873.

PREFACE.

ELECTRO-SURGERY is a department of science that has been so little studied that any contribution to it, however fragmentary and imperfect, becomes of value.

The pathway that leads to truth on this subject is at best tortuous and obscure; but every advance of the pioneers, every removal of obstructions, makes the journey shorter, clearer and easier for those who are setting out upon it. An early publication of experience and experiments, provided it be candid and thorough, will secure the aid of many collaborators who may perhaps be induced to carefully study the subject.

Through a variety of laborers there will be brought out a variety of results which will reciprocally supplement and correct each other. Therapeutics in all its branches, and certainly electro-therapeutics is a subject so wide and so complex that only by comparing the studies of many observers can we arrive at the full truth.

Although a long time must elapse before some of the questions that may be raised in connection with

the following clinical cases can be fully answered, yet strong and important points are in the way of settlement. The objection that is often and very properly brought against the early publication of clinical experience, that it is apt to teach either absolute error or but half-truths, need not apply, provided the reports are fairly and impartially made, without any attempt to conceal or distort or in any way warp the evidence to sustain a theory, and no inferences are drawn beyond the requirements of the demonstrated facts. We have not attempted to exhaust our experiments, but to fairly represent them in all their aspects. Cases of absolute or approximate success have been placed side by side with cases of absolute or approximate failure. Cases where every opportunity was afforded for treatment, and cases that failed for lack of opportunity, have been accorded equal prominence. Cases in which the ordinary and accepted methods of treatment would have been sufficient have been mingled with those cases which under the ordinary and accepted methods would have been utterly hopeless.

Many inquiries of great importance have been left wholly or partially unanswered; to other problems a merely provisional solution has been given; while in some departments we have been able to draw generalizations that have been at once legitimate and satisfactory.

Those who on the one hand believe that electro-

therapeutics is the one great problem of the future, and those who on the other hand suspect that it is all a delusion, will be equally disappointed. The cases are taken from both public and private practice, and many of them were treated in the presence and with the assistance of able and recognized surgical authorities.

The method of *central* galvanization and electrolization by *working up the base*, which we have recently devised and employed, will in the future be more widely tested, and on the principles here indicated. The striking and suggestive results obtained in certain diseases of the skin, and especially under central galvanization, will probably excite surprise. Some of the results, we are happy to state, have now been confirmed by a number of observers.

A. D. R. AND G. M. B.

CLINICAL RESEARCHES IN ELECTRO-SURGERY.

CHAPTER I.

Erectile or vascular tumors.

Erectile or vascular tumors include both cutaneous and subcutaneous nævi. The terms—cutaneous and subcutaneous—however, simply indicate a difference in seat but not in kind. The two forms are often associated, and the wide-spread dilatation of cutaneous vessels attended with little swelling, that are commonly called mother spots, are evidently similar in character to the subcutaneous variety to which Bell gave the name of aneurism by anastomosis.

In the treatment of the various forms of subcutaneous erectile tumors, both arterial and venous, it is evident that electrolysis must bear an important part if it does not altogether supersede the knife. Its advantages over other methods are various and decided. 1st. There is not the slightest hemorrhage; no more blood need be lost then after any fracture. 2d. No scar is left. By proper insulation and care in the introduction of

the needles and management of the current, chemical effects will be confined to the blood alone. 3d. During the operation the pain is slight, and subsequently the patient experiences no inconvenience. 4th. The operation is easily performed, and produces no such disagreeable reflections to either patients or friends as the knife or actual cautery. The number of needles to be introduced into the tumor depends very much on its size. When the enlargement is slight, not exceeding in size a small filbert, one needle is sufficient, while a nævus an inch or more in breadth and depth will require three or four.

Subcutaneous erectile tumor of the right cheek; complete recovery follows electrolytic treatment.

Case I.—In April, 1871, Dr. D. F. Reynolds consulted us in regard to the case of a little child aged eight months, who was afflicted by an erectile tumor in the right cheek. It appeared shortly after birth, and had gradually enlarged until the date mentioned, when it measured one and a-half inches in width and from one half to three-quarters of an inch in depth. Upon firm pressure the enlargement would almost entirely disappear. The patient having been placed under the influence of chloroform, we operated at Bellevue Hospital in the presence of Dr. Frank Hamilton and his class, by introducing into the four quarters of the tumor four

small gilded steel needles insulated to within one-quarter of an inch of the points.

During the passage of a current of very moderate tension the enlargement gradually grew harder and more prominent as the blood coagulated, and at the expiration of eight minutes, when the needles were withdrawn, the part was quite firm. The child suffered no inconvenience during or after the operation, and when seen the next morning was as well and playful as usual. The process of absorption soon became manifest, and in two months three-quarters of the clot had disappeared.

From this time there was a most marked decrease in the rapidity of absorption, since but two months more were required before the clot had entirely disappeared.*

A large arterial tumor in a weak, ill-nourished child; the result of electrolytic treatment unsatisfactorg.

Case II.—Annie ——, a child aged one year, was directed to us by Dr. H. P. Farnham. On her back over the upper dorsal vertebræ we found a large fluctuating arterial tumor, nearly two inches in diameter at its base.

The child was markedly anæmic, and her general condition was much below par.

---

* This case was briefly mentioned in the *New York Medical Journal* before complete absorption had rendered the operation a success.

It was thought best, however, to operate, and in the presence of Drs. Farnham, Pinkney, Grant, and others, the needles were used in the same manner as in the previous case. Coagulation was readily produced, but owing to some unpleasant symptoms in the respiration of the child the needles were withdrawn (as the progress of the case subsequently attested) a little prematurely.

Absorption set in very slowly indeed, and after a few weeks its effects were barely perceptible. After a couple of months it was evident that the circulation in one portion was beginning to be re-established, but the mother refused to allow anything more to be done for the little patient. It should be stated that on the night following the operation, the child was allowed to lie upon its back with the hard enlargement of coagulated blood entirely unprotected. Subsequently a soft circular ring was prepared and placed around the tumor, but the irritation already caused by the pressure was followed by slight ulceration and discharge.

This, however, healed in the course of two weeks, but it undoubtedly contributed towards the general unsatisfactory result. The slowness with which the absorbing process was carried on is to be attributed undoubtedly to impaired nutrition, and the re-establishment of the circulation mainly to the unfortunate necessity of cutting short the operation.

Arterial erectile tumor from birth in a child fifteen months old; complete recovery under electrolyzation.

Case III.—In a little child fifteen months old, upon whose face near the angle of the lower jaw a small erectile tumor had existed from birth, electrolysis was completely successful. The patient was placed under the influence of chloroform, and two platinum needles, insulated to within one-third of an inch of the points, and connected with the positive pole, were introduced into the two lower quarters of the tumor; while two steel needles, connected with the negative pole and insulated in a similar manner, were thrust into the two upper quarters. The current from twelve medium-sized cells of a zinc-carbon battery was allowed to pass for ten minutes, at the end of which time the coagulation was complete. Absorption of the clot rapidly became manifest, and in four months it had entirely disappeared, leaving no scar.

In subsequent operations we have not hesitated to use steel or gilded needles for the positive pole, since the oxidation which these metals undergo in all probability tends to accelerate coagulation.

Subcutaneous erectile tumor treated by electrolysis; subsequent sloughing.

Case IV.—At the request of Dr. Geo. K. Smith, we operated, Nov. 22, 1871, on a case of subcutaneous

erectile tumor just over the inner angle of the eye in a child sixteen months of age. The tumor, which was about the size of a hazel-nut, could easily be compressed. The child was thoroughly etherized with the assistance of Dr. F. H. Colton, and three insulated needles were inserted into the tumor—two connected with the positive, and one with the negative pole.

The current was from sixteen weak cells; the *séance* twenty minutes. The color of the tumor changed during the operation and became hard through the coagulation. Subsequently the tumor sloughed at certain points, and the result was not satisfactory, since a deformity was left that may be permanent. The mistake we made was in using too strong a current and unduly prolonging the operation. In our desire to avoid repeating the operation as had been found necessary in other cases, we went to the other extreme.

The delicate skin of the child was so affected by the action of the current that sloughing ensued in spite of the insulation of the needles.

This mistake is one that can be easily avoided.

Nævus in a child cured by electrolysis.

Case V.—April 1, 1872, we were requested by Dr. E. Bunker, of Brooklyn, to operate on a small nævus on the neck of a child eight weeks old. The tumor was situated just below the chin, and was one-third of an inch in diameter.

A current from eight zinc-carbon cells was applied into the tumor by means of a small needle (uninsulated) connected with the negative pole, while a sponge electrode attached to the positive was applied to the surface of the body.

Immediately the diseased spot began to decompose and to change in color, and ultimately disappeared. The sitting was continued but four minutes. No anæsthetic was employed.

Dr. Bunker informs us (June 15) that there are signs of reappearance of the growth.

Bronchocele (goitre).

In the treatment of goitre etherization is not necessary, provided a needle is used that can be introduced with ease. The ordinary glover's needle (small size) of the fancy stores, we find enters the skin easier than any other shape that we have tried. It is not necessary to insulate the needles for goitre; but hard rubber can be melted on and allowed to cool, in cases where insulation is required. To introduce the round needles into the skin of the neck is a matter of great difficulty.

Simple or adenoid goitre in a child aged fourteen; steady decrease in size under electrolytic treatment.

Case VI.—L. W., a girl aged 14 years, first observed four years since a slight enlargement of the thyroid gland. It rapidly increased in size, until Dec. 5,

1871; when she presented herself for examination it was 1½ inches in depth and 2 inches in width, reaching to the anterior border of either sterno-cleido mastoideus muscle. The mass was quite movable and did not in any way cause inconvenience, excepting when she attempted to sing. Iodine, both internally and externally, had been used without appreciable benefit. For the first two months localized *external* galvanization repeated twice a week was alone tried, resulting in no diminution in the size of the swelling, but in a very decided alleviation of the distressing sensation of strangling, which invariably occurred whenever she attempted to sing.

Subsequently the needles were introduced, and to this date the tumor has steadily decreased in size, until it is now, June 1, one-quarter its original size, and the indications are that it will entirely disappear. The needle (a small glover's needle), has been introduced some twenty times, but as the pain produced is very slight no chloroform has at any time been used.

Fibrous goitre of four years' standing in a woman aged twenty-nine; considerable diminution in size under external galvanization and electrolyzation.

Case VII.—K. M., an unmarried woman, aged 29, observed some four years ago a slight swelling over the right side of the pomum Adami. The growth was rapid and soon involved both lobes of the thyroid gland.

By accurate measurement the distance from the posterior border of one sterno-cleido-mastoid muscle to the posterior border of its fellow was found to be seven and one-half inches.

Five applications of localized galvanization during the three weeks following reduced the above measurement one-half an inch. From the date of the last external application (March 18, 1872), a needle was introduced and the current allowed to act about fifteen minutes. Six similar applications during the following four weeks reduced the distance from the two given points to six inches. The patient after this came but two or three times until June 23, when ether was administered, and three needles and eighteen zinc-carbon cells were used. The operation was continued fifteen minutes, when two needles were withdrawn and the cells increased to twenty-three, and the current allowed to pass eight minutes longer. The patient recovered rapidly from the effects of ether, but, unfortunately, never returned to report progress.

Large cystic tumor in the right axilla successfully treated by electrolysis.

Case VIII.—Mary M., aged 33, noticed three years ago a swelling in the right axilla, which gradually increased until Feb. 29, 1871, the date of her presentation for treatment, when it was about one-half the size of her clenched fist. The swelling was hard and movable. Alternate localized galvanization and faradization (ex-

ternal applications) were essayed for one month, greatly relieving the pain and slightly reducing the enlargement. April 2d.—The needles were attempted—one being used at each *séance*. The operation was repeated eight times until June 26, when the tumor was no larger than a small chestnut. She returned no more to the Dispensary, for the reason, doubtless, that absorption had completed its work. Another result of treatment is worthy of notice. The patient had borne four children, and while nursing the first had suffered from a fissured nipple on the side where the tumor was seated, and in consequence was, during the whole period of nursing, unable to give nourishment to the child from the affected side. With subsequent children the quantity of milk secreted by this breast was hardly one-half of that given by the other.

At the time of our first operations she was nursing a child twelve months old, and thus gave us an opportunity to demonstrate the value of electrization in increasing the lacteal secretion. The quantity of milk secreted rapidly increased until it quite equalled the amount produced by the healthy side.

Cystic tumor of forehead of forty years' standing; immediate and permanent cure by electrolysis.

Case IX.—Mrs. H., aged 60, we first saw in consultation with Dr. A. W. Catlin, of Brooklyn, Nov. 9, 1871.

For forty years she had been afflicted with a tumor on the forehead, which, in appearance and size, and

in its feel and compressibility at the time we saw it, exactly resembled a ripe Isabella grape. This appearance had not, however, been constant; its size varied, and at one time after stooping it had considerably enlarged, and a vein connected with it and leading towards the upper part of the nose became swollen and prominent.

Whether the enlargement was erectile or cystic was a matter of doubt. Dr. A. B. Crosby, who saw the case with us, regarded it as cystic. The patient had refused to submit to any operation for the radical cure of the tumor—partly on account of fear of hemorrhage—and consequently, had worn the unpleasant deformity the greater portion of her life. Nov. 11, 1871, with the assistance of Drs. Catlin, Crosby, Cooper, and Wyckoff, local anæsthesia was used, and two small insulated needles were inserted into the tumor near the base, one pole connected with the positive and the other with the negative pole of ten cells of a portable Galvano-Faradic Co. zinc-carbon battery. Immediately the color of the tumor began to lighten, through the change of its fluid contents into oxygen and hydrogen gases, and in five minutes the whole surface was almost colorless, and the tumor was much distended. The needles were now withdrawn; there was no hemorrhage, but the gases began to escape at the places where the needles were inserted. Dr. Crosby now used a little pressure, and the tumor flattened with more escape of gas. Under repeated pressure still

more gas escaped; and in ten minutes from the beginning of the operation the tumor was perfectly flattened. Gradually the residuum of the tumor disappeared, and in a few weeks scarcely a trace of the long-standing deformity existed.

Epithelioma involving one-half the lower lip; recovery under electrolytic treatment.

Case X.—Mrs. J. C., aged 65. In September, 1871, a little hard lump, the size of a pea, appeared on the left side of the under lip. By Jan. 19, 1872, it had extended from the angle of the mouth along the lip to the median line. The surface presented a warty appearance, was exceedingly hard, and bled readily. Localized galvanization (external) dissipated almost completely the excessive pain in the diseased part. On Jan. 26, five uninsulated needles were introduced into the lip, *around and beneath* the tumor, so as to entirely separate the healthy from the unhealthy tissue, and a current of considerable tension from eighteen cells was allowed to pass for twenty-five minutes. Equal parts of chloroform and ether were administered.

Inflammation and suppuration followed, and in two days the entire tumor had sloughed away.

By Feb. 2 the inflammation had subsided, and the surface was covered with healthy granulations. Improvement continued until Feb. 23, when the surface had entirely healed, and the patient was discharged as cured, with a well-formed lip.

Large uterine fibroid; dissipation of pain and some decrease in the size of the tumor under internal faradization and electrolysis.

Case XI.—Isabella McV. came to the Dispensary for examination and treatment, March 7th, 1871.

Some eighteen months previously she first noticed a slight enlargement occupying the right iliac region. It gradually increased in size, and on examination we found a tumor extending from the fundus to the os uteri. The menses and secretions were normal, but the associated pains in the hip and down the right limb were of the severest character. The woman was sleepless, without appetite, and suffered from continual vomiting. The faradic current was first used by applying a large flat electrode connected with the positive pole, directly over the upper portion of the tumor, while the negative electrode, so constructed as to be readily introduced, was held firmly against the right side of the cervix uteri. The above treatment in connection with an occasional general application was repeated twice a week for nearly four months, resulting in great improvement to her general condition and effectually allayed the acute pain from which she had suffered.

No effect was produced on the size of the growth, except that further increase seemed to be checked. In the latter part of June electrolysis was resorted to. A long needle insulated to within one inch of the point was thrust into the tumor as it could be felt at

the right side of the cervex uteri. The current from twenty-five cells was allowed to pass for fifteen minutes, and the operation was repeated twice a week.

After a few applications a thick dark-colored discharge appeared, and when this flow was most abundant the patient's health was correspondingly better.

After two months of this treatment the patient was lost sight of, but the tumor had decreased decidedly in size and become much softer, while her general health remained good and her limbs free from pain to the last visit.

Indolent ulcer of the arm; recovery under local galvanization.

Case XII.—Mary H., aged forty, while moving, May 1, 1871, fell and injured the arm immediately above the external condyle. The pain was excessive and continued to distress her for several weeks, when a small ulcer made its appearance and enlarged until it was two inches in diameter.

The patient applied for treatment, July 18. The ulcer was covered with a dark-colored scab three-fourths of an inch, partly lifted from its resting-place by exuberant and unhealthy granulations.

The scab was removed, and a wet cloth in connection with the positive pole was applied to the diseased part while the negative was placed on an indifferent but approximate part. The galvanic current was used. She suffered no more pain after the second *séance*, and

as the applications were repeated the ulcer rapidly healed, until August 30, when the part was covered by sound healthy skin.

Syphilitic ulcer; recovery follows three operations by electrolysis.

Case XIII.—Catherine McK., aged forty, suffered three years since from a number of syphilitic tubercles and ulcers about her hips, thighs, and vulva. They persisted a long time and gave her much annoyance, but finally healed, with the exception of one on the inside of the thigh. It was elevated nearly one-half an inch above the surrounding surface, was excessively painful, and discharged an offensive secretion. A needle connected with the positive pole was passed through the base of the elevation, and a current of moderate tension allowed to pass for a few moments. This application dissipated all pain, and after the third *séance*, given several weeks after the first, soon healed, and the patient was discharged from the Dispensary.

Recurrent fibroid tumor of years' standing.—Repeated electrolyzations without etherization and attended with trifling pain.—Arrest of Growth.—Gradual decrease in the size of the tumor.

Case XIV.—Mrs. P., a lady of middle age, was directed to us by Dr. F. Winston, in Feburary, 1871.

On examination, we found under the right ear a large tumor, soft and movable, and equal in size to the closed fist. The enlargement was of the recurring fibroid character, entirely painless, but most unsightly in appearance. The patient first observed the growth some ten years since, when its size was barely appreciable. It gradually enlarged until it attained the size of an ordinary hen's egg, and was removed by the late Dr. Cheeseman.

A few months subsequently it made its appearance a second time, and steadily enlarged, until at the expiration of three years its size was somewhat greater than when the first operation was performed.

It was again removed by Dr. Willard Parker, but in course of time returned. The patient was now unwilling to have the operation by the knife repeated, and for seven years the tumor slowly increased to the size above stated.

To avoid any possibility of exciting an action in the

tumor that might render it truly malignant in character, we at first made use only of external galvanization.

After a dozen applications no change could be perceived in its outward conformation ; but that the treatment had not been without some effect was manifested from the fact, that the head could now be turned in any direction without causing the disagreeable and sometimes painful sensations that had formerly followed pressure of the deep portion of the growth on the underlying tissues.

We now decided to try the ordinary method of electrolysis, and accordingly introduced, an inch into the tumor, a needle insulated to within half an inch of its point. The application, alternating with external galvanization, was repeated some twelve times during the course of two months, and resulted in a very decided alteration in the shape, as well as a marked diminution in the size of the growth. After each operation a large quantity of free hydrogen gas escaped through the opening made by the needle, followed by a slight flow of blood.

At this time two needles were used—the second one of platinum, and connected with the positive pole. It should be stated that previously only twelve zinc carbon cells had been used, and the current allowed to pass but ten minutes. We now increased the cells to twenty, and permitted the needles to remain some fifteen minutes ; but when they were withdrawn, neither gas nor blood escaped, and yet it was absolutely certain that

the current had been passing every moment, and with power greater than in previous operations.

In a few hours the tumor and tissues surrounding it became greatly swollen, accompanied by very considerable pain.

The pain and swelling were relieved by a poppy poultice, but a slight discharge continued through the months of July and August, during which time treatment was intermitted. In September, when the patient returned to the city, the discharge, which had ceased two weeks previously, had evidently resulted in a still further reduction of the tumor.

The treatment was resumed, and continued at intervals during the past winter and spring. The effect has been a slow but constant decrease in size, until now it is about one-third its original size.

At one time during an interval in the treatment the patient observed, in a portion of the tumor to which the needles had not been applied, a projection which rapidly enlarged until it was one-third of an inch in diameter, and extended downward into the healthy tissue for more than an inch. A single needle was introduced into this unwelcome addition, and a mild current allowed to pass for ten minutes. The process of absorption was excited, and in two weeks this protuberence completely disappeared. It is interesting to note in this description, that while the growth was slowly but steadily enlarging before the use of needles, it has not, since the treatment by electrolysis was be-

gun, shown the slightest disposition to increase in those parts actually influenced by the current—although at one time several months elapsed between the operations.

While the above case cannot be cited as a brilliant result of electrolytic treatment, it is of exceeding interest, and has afforded many useful hints that have been of value in other cases. The pain of introducing the needles was trivial; and the electrolytic action, even when it was very intense, produced little or no sensation; consequently it was at no time necessary to use chloroform, and the treatment was as readily borne as if the applications were merely external. The impression very generally prevailing, that electrolyzation of morbid growths must be excruciatingly painful, is not confirmed by the test of experience. The above and other cases of like character illustrate that fibroid tumors may be thus treated with but little pain; goitre, and some erectile tumors as well, are not acutely susceptible to the pain of electrolysis.

Cases of scirrhus seem to be more sensitive to the chemical action of the current; and it is frequently necessary to etherize the patient, although in other cases local anæsthesia is sufficient. In several instances the introduction of the needles and the action of the current were borne with but little more fortitude than it is necessary to exercise in some external applications.

If, in the case related, it is found necessary to remove the tumor at once by the process of undermining,

profound anæsthesia will have to be produced; since without it, the consequent disintegration of the underlying sound tissue would cause intense pain.

Cystic tumor of the submaxillary region: three operations; rapid healing with slight disfigurement. Successful result.

Case XV.—Miss ———, a young lady in her teens, was sent to us March 25th, 1872, by Dr. Wm. W. Reese. The patient was of a fragile constitution, and had become debilitated by confinement in the stifling air of a manufactory where she was employed. For one year she had been troubled with a tumor on the submaxillary region of the left side, that was at first supposed to be simply an enlarged gland. It did not, however, yield to the usual treatment that various physicians and surgeons had given her, and at the time we saw it, it was about the size of an English walnut, and was apparently encysted. Lancinating pains of a tolerably severe character were sometimes felt in and near the growth.

Careful examination made it pretty clear that the enlargement was cystic; that soft substance was inside of it, although the walls were quite hard. March 27th, with the assistance of Dr. Reeves and Hyde, we electrolyzed a portion of the growth, and found that it was really cystic and contained a dark cheesy substance. The patient was fully etherized during the operation, which lasted forty minutes. Large and long needles were employed, and 16 zinc-carbon cells.

The operation was followed for two days by irritative fever, but by no other unpleasant result. There was considerable sloughing, but the bulk of the growth remained as a large unsightly mass. April 14th, we again operated by *working up the base* of the tumor, undermining it and separating it from the surrounding healthy tissue. Dr. A. B. Crosby assisted at the operation, and enucleated a portion of the mass before the needles were inserted. The irritative fever was slighter than after the previous operation. An ulcer 1½ inch in length and a half an inch in depth remained—the surface presenting, as usual after electrolytic operations, a charred appearance which at first alarmed the patient. The subsequent healing was, in the judgment of all the surgeons, surprisingly rapid and satisfactory. Dr. Crosby, in proper time, brought the edges together and thus expedited the reparative process, so that at the end of a month only a trifling scar remained. At one of these operations the parenchymatous hemorrhage was excellently controlled by the action of the current, and no other styptic was required. The patient had now positively improved in her general health, and was free from any sign of the disease. It was hoped by all parties that she would hear no more from the tumor. It had been suspected at the close of the operation that a small portion of the growth remained, but it was not deemed advisable to protract the operation.

Very soon, pains of quite a severe character began to be felt just beneath the skin in the region of the sub-

lingual gland: then followed swelling, and in a few weeks a tumor as large as a horse-chestnut, of the same appearance and feel as the previous growth. We decided to operate again, this time with absolute thoroughness; the same surgeons being present, and also Dr. Mann. Dr. Crosby made an incision and enucleated the growth, the operation being completed by electrolyzation with large needles as before.

The work was thoroughly done; the base was thoroughly electrolyzed. During the operation, a branch of the facial artery was severed by the needle; this was tied by Dr. Crosby. The wound was treated as before and with the same result—rapid and satisfactory healing, that has been permanent. The scar disfigures but slightly, while the patient has improved in her general health, and at the date of writing weighs much more than at the time of the operation.

Large and painful epithelioma of the upper lip of several months' standing.—Removal by electrolysis and satisactory healing.

Case XVI.—Miss ———, aged 20, was brought to us by Dr. Corey, Oct. 23, 1871, to be treated for an epithelioma of the upper lip that had distressed her for several months. At this time the growth extended from the median line to the left corner of the lip, being about one inch in diameter and one-half an inch in ength. The pain of the growth was at times very great, especially when exposed to the cold; the disfig-

urement was annoying, and there was an evident tendency to quite rapid increase. At the base, on the inner surface of the lip and especially at the corner, hard nodules were easily detected by the finger. With the assistance of Dr. Corey, and in the presence of a number of physicians, we electrolyzed the upper portion of the growth with five small needles, three connected with the negative and two with the positive pole. Full anæsthesia was used, and the operation lasted twenty minutes. The needles were inserted directly into the body of the tumor and not around the base. The method of working up the base, we had not at that time begun to employ. The soft parts of the tumor in the vicinity of the negative pole decomposed with rapidity. A yellowish foam was developed, which, forcing its way underneath the scab that covered the tumor, gradually lifted it up and completely detached it from the body of the growth.

The parts presented the usual charred appearance after the operation, but there was little or no pain, either in the tumor or in the vicinity. There was, however, considerable irritative fever, and the face was somewhat swollen. In the course of a week, the portion of the diseased part that had been electrolyzed begun to contract, and near the median line healthy tissue appeared. The lower part, that was little affected by the needles, remained as before. Nov. 9, we again operated with four negative and one positive needle with the same number of cells (16 zinc-carbon)

and for about the same time. Dr. Corey administered the anæsthetic, and Drs. Armor, Caldwell, and others were present. This operation was more thoroughly performed than the previous one, but the needles were not inserted into the nodules or the inner surface, but only into the superficial parts of the growth. No bad result followed; and by Nov. 27th the tumor had contracted to one-third of its original size and was healing rapidly. The healing process continued until scarcely any trace of the disease remained. The healing was almost perfect; there was an entirely natural skin in the region where the tumor had formerly existed, and the only cicatrix was at the corner of the mouth. Twitches of pain have been felt in the vicinity of the scar, especially on exposure to cold, giving rise to the suspicion that possibly that portion of the growth was not thoroughly treated.

It is now one year since the patient was treated, and the recovery may be regarded as most satisfactory. In reference to this case it may be remarked:—

1st. If the diseased mass had been thoroughly separated from the surrounding healthy tissues by inserting large needles, one operation would have been sufficient, and the cure would probably have been absolute. This was the first case of the kind that we had treated, and we had not then employed the method of working up the base and had not devised the long, sharp, double-edged needle which we now employ in the electrolyzation of large growths.

2d. There was scarcely any hemorrhage or other unpleasant symptoms during or after the operation, excepting the irritative fever of which we have spoken.

3d. The scar was probably less than if the knife had been employed.

Scirrhus of the left breast in a woman aged 45.—Complete and instant relief from excruciating pain, and in the course of four days, disappearance of one-half the growth from one electrolytic operation.

Case XVII. Mrs. ——, aged about 45, an inmate o Bellevue Hospital, was affected with cancer of the left breast.

The main portion of the scirrhus was the size of an ordinary orange, and extending in to the axilla were a number of cancerous nodules of considerable size.

The surrounding and intervening tissue was as hard and unyielding as the tumor itself. The process of suppuration was beginning to manifest itself, and for several weeks the patient had suffered night and day the most excruciating pain through the diseased parts. The first operation was performed in one of the wards of the hospital, in the presence of Prof. Frank Hamilton (who had requested us to operate by the electrolytic method) and his private class. The patient having been etherized, we introduced deeply into the upper portion of the breast three gilded needles, and with a fourth transfixed the largest of the axillary nod-

ules. The positive pole (a large moist sponge) was applied to the under portion of the gland. No very decided change was manifest in the appearance of the mass during the operation other than some puffing up of the skin, due to the disengaged hydrogen; but very soon after it began to decrease in size, and in one week not only had all the hardness of the surrounding tissue and all the axillary enlargements entirely disappeared, but the mammary tumor had decreased in size at least one-half. The most grateful relief the patient experienced, however, was the complete and seemingly permanent dissipation of pain. In ten days we again operated, and by the same method, in the amphitheatre and before Dr. Hamilton and the regular class of the College. On the following day the patient felt so comfortable that she left the hospital, and in a week's time presented herself for examination, when it was found that there had been a still further decrease in the size of the tumor. She still remained entirely free from pain, and was delighted with the results of treatment. Most unfortunately, we now lost sight of the patient. She never returned, and thus an opportunity of witnessing the final results in this case of scirrhus, in which the immediate effects of electrolysis was so remarkable, was forever lost.

The probabilities are that the patient was satisfied with the result of treatment, and did not feel it necessary to continue it.

Scirrhus of two years' standing involving the whole right breast.—Pain relieved by external treatment, but electrolyzation with a strong current does not appreciably affect the growth.

Case XVIII.—Mrs. D——, a lady of middle age, observed, during the winter of 1869, a very slight enlargement on the right breast.

Its growth was exceedingly slow until June of the following year, when it rapidly increased in size, and in two months it had involved the whole breast.

She first consulted, in this city, Dr. Wm. H. Van Buren, who pronounced it a case of scirrhus and referred her to us for electrolytic treatment.

We found the tumor to be remarkably hard, involving two of the axillary glands.

The patient had for months suffered very great pain, while the arm of the affected side was so lame that it was impossible to lift it more than a little way from the side. External applications relieved the pain very decidedly, and improved the condition of the arm so that she was able to use it quite readily.

On Dec. 4th, 1871, in the presence of Drs. Nott and Metcalfe, we etherized the patient and operated by introducing into the upper portion of the tumor four three-cornered needles, insulated to within one inch o the points. The current was from 36 zinc-carbon cells, and in tension sufficient to deflect the needle of our galvanometer some fifty degrees. The needles remained

n position twenty minutes; and although the current was constantly passing, the effect on the substance of the growth where the needles pierced was barely appreciable, while the skin, covered by the large sponge of the positive pole, was well-nigh blistered.

The needles utterly failed, and we were forced to content ourselves with the relief afforded by external applications, not attempting the undermining or destructive process.

Scirrhus of the breast, in a married lady, of four months' standing; very severe pain; very great relief of pain by external galvanization and electrolyzation by working up the base.—Death from exhaustion.

Case XIX.—Margaret D——, aged 35, was referred to us, October 10, 1871, by Drs. Skene and Corey, of the Female Department of Long Island College Hospital. She was affected with a tumor of the left breast, that was manifestly scirrhus. The entire mamma was hard, quite firm, and presented, in spots, a reddish and angry appearance. It was four months since the attention of the patient had been called to the growth, and probably much longer than that since its first appearance. For several weeks the pain had been terrible and almost constant, and it was this fact more than any apprehension of the nature of the malady that had brought her to the hospital.

The face of the patient was considerably cachectic, and her condition in general was one of debility.

We at once began treatment by localized faradization (external). The applications were made with wet sponges, and the *séances* continued about ten minutes. After the second application the pain diminished, and after further treatments ceased almost entirely.

This relief continued for six weeks or more, varying slightly at intervals. External galvanization, localized in the same manner, was next resorted to, with apparently even greater effect than the faradization.

The tumor, however, did not perceptibly diminish in size, and therefore we begun to try electrolysis, at first with an insulated needle, connected with the negative pole, the positive being applied by a sponge on the surface of the tumor. The comparatively slight pain caused by the operation was borne without an anæsthetic. We may here remark, that the pain of introducing a needle is sometimes greater than that of the subsequent action of the current on the deeper tissues, and for that reason we have sometimes used local anæsthesia by ether spray, and, what is more convenient still, *carbolic acid.* A mixture, first suggested to us by our assistant, Dr. J. H. Sterling, composed of carbolic acid one part and sulphuric ether two parts, applied to the skin, will cause a circumscribed anæsthesia lasting for perhaps about ten minutes. By this extremely simple method anæsthesia may be restricted by a space one-eighth of an inch in diameter. As the skin offers the chief resistance to the introduction of the needle, and is more abundantly supplied with nerves than the deeper

tissues, it is easy to understand that by this local and superficial anæsthesia the pain, and what is oftentimes worse, the *dread* of the introduction of needle, can be reduced to a minimum. The only effect of the electrolyzation several times repeated was to cause a sloughing near the spot where the needle was inserted. The patient remained mostly free from pain, but the body of the growth refused to diminish.

Just before the needle was used, the patient was brought before the Kings Co. Medical Society, and there examined by a large number of physicians and surgeons; the opinion was unanimous that the case was one of scirrhus.

By request of Dr. Geo. K. Smith, of St. Peter's Hospital, where the patient was staying, we now resolved to try more thorough treatment, and on November 14, 1871, the patient was fully anæsthetized by Dr. Corey, and three negative and three positive needles were inserted *around the base* of the upper part of the growth, in such a way as to surround that portion of the tumor and separate it from the healthy tissue.

This was the first time that we employed this method which we subsequenly denominated—*working up the base.*

Drs. Armor, Skene, Bunker, and other physicians and surgeons were present. The operation lasted half an hour. It was followed by some irritative fever and by a sloughing of the parts; the patient rallied, how-

ever, to such an extent that she was able to leave the Hospital of St. Peter's, where she had been confined and to walk to her home.

November 27, hemorrhage appeared from some artery, and the patient lost a number of ounces of blood. She suffered, however, but little pain, and continued her housework. Subsequently, we operated by the same method in the Hospital of St. Peter's. Drs. Spier, Ormiston, Hutton, and others were present, and assisted in the etherization. The usual sloughing followed, until the entire body of the growth was removed; completely detached from the surrounding part. The base of the part first operated on had healed up almost entirely.

The patient went to her home in the city. She suffered little or no pain, but was manifestly growing feeble, and, April 22, she died of exhaustion. Up to the day of her death she suffered very little pain.

The interesting features in the above case—which may be regarded as one of the worst manifestations of scirrhus of the breast—are, that it was so quickly relieved of pain by electricity, however administered, and that this relief was so permanent; that the size of the tumor did not diminish under the treatment; that the working up of the base was followed by a very satisfactory healing; that this method was, however, adopted too late to prevent the constitutional infection and finally, that the patient, even in her debility, bore without the trace of a shock severe and protracted operations.

In their relations to electro-therapeutics there would appear to be two general varieties of tumors of the breast; one variety in which all or nearly all the mamma is involved and is very hard, firm and unyielding, the skin being tense, glossy, and indicating inflammation and induration. The case above described would come under that head. The variety is more obstinate and unyielding; the pain may be relieved, as in the case above cited, but the tumors do not grow smaller under the action of the current; they can be diminished in size or removed only by actual destruction of the tissue.

In the other variety the tumor involves but a limited portion of the breast; the skin is not tense, but is soft and yielding, and of the natural color; the growth is felt as a nodule beneath the skin, and the pain is not usually so severe as in the other variety, and the growth is much slower. This variety is the one that is most disposed to yield to electrical treatment. Not only is the pain relieved, but the tumors grow softer and smaller, and in some instances permanently disappear. In other cases their advance is arrested by the treatment, so that they remain stationary for months or years.

Whether what we call, for convenience sake, and for clinical reasons, only two varieties, are really but different stages of one variety; whether the latter may sometimes come under the head of abscess, or of the atrophying cancer described by Billroth, these questions we resign to the pathologists of the future.

Epithelial cancer in a lady aged 30, *involving the rectum, vagina, and external parts. Eleven electrolytic operations remove the growths, alleviate pain, and modify very greatly the rapidity with which the disease subsequently reappears.*

Case XX.—The wife of a physician, aged about 30, had for eight years of her married life suffered from what was supposed to be scirrhus of the rectum, which had been removed by ligatures at different times and by different surgeons.

About three years before we saw her, an epithelial cancer appeared at the entrance of the vagina; this gradually increased in size and protruded, until by Oct. 1871, it appeared to be about one-half as large as a cauliflower, and much resembled one in appearance. The discharge was very profuse and very offensive; the pain terrible and almost constant. The growth was evidently increasing, and only with difficulty could the patient walk about the house.

A more distressing case of disease of any kind we had never seen. After each removal of the mass by the ligature, it would spring up almost before the sight and become larger than before. There was about it a rankness, a fierceness, a malignity, quite unusual. Like rampant weeds in rich soil, the more it was cut off, the faster it grew. Escharotics of all kinds, as well as condurango, had been tried, the latter remedy seeming to do injury.

The galvano-cautery had been suggested by Dr. E.

R. Peaslee, whom the patient consulted, and Dr. Byrne had intended to give it a trial, but deferred the operation in order to experiment with condurango. We began treatment with external galvanization in order to relieve the pain. The first treatment acomplished nothing; the third treatment, we connected an insulated rectal electrode with one pole, while the positive, by means of a wet cloth, was gently passed over the very sensitive surface of the tumor. The patient was relieved of pain for a whole night. Satisfied with the result, we now resolved to use the needles.

With the assistance of Dr. Rotton and the husband of the patient we operated eleven times, with intervals of two or three weeks between the *séances*. Full etherization has been obtained in each operation.

We used two, three, or four needles, according to circumstances, and both poles were inserted into the base of the growth.

The first operation, Oct. 20, which lasted twenty-five minutes, removed one-third of the growth; and by the end of the third operation, all the growth external to the orifice of the vagina was removed.

Far up in the vagina, the diseased portion could readily be detected, spreading out in all directions like a watermelon vine.

Nov. 15th, there were some evidences of a reappearance of the external growth in those parts that were not thoroughly electrized. Nov. 22d, operated again by electrolysis for half an hour.

Dec. 5th, operated again by electrolysis in connection with Dr. Byrne, who by the aid of his speculum applied the galvano-cautery to the portions of the growth in the vagina. Jan. 17th, again operated by the same method for 30 minutes. The external ulcer caused by the removal of the tumor had hitherto been about four inches long, three inches wide, and one inch in depth, extending from the middle of the labia beyond the anus on the right side.

This ulcer now began to heal at the edges and to contract. Jan. 6th, began the use of nitrate of silver, applied to the ulcer. Jan. 8th, the discharge which had come from the vagina was much diminished and the ulcer had contracted to half the original size. Jan. 21st, operated by electrolysis in the vagina chiefly.

March 24th, repeated the operations with long needles, in the vagina, on some ragged portions of the growth. We were now able to ascertain by digital examination that there was a pretty direct connection between the growth in the rectum and the one in the vagina; they seemed indeed to be extensions from a common centre.

The septum at the base of the tumor in the vagina was so thin that we much feared a recto-vaginal fistula, and great care was necessary in operating, to preserve this delicate and partially disorganized tissue that separated the two canals. April 21, again operated by electrolysis.

Subsequently the actual cautery was once used, in the hope that perhaps it might cause a more thorough drying up of the profusely discharging surface in the vagina; but the results of its use were unsatisfactory. The febrile condition that followed was alarming, and the local pain was terrific for several days after the operation. During the summer, local applications of various kinds have been experimented with; among others, a mixture of iodine, iodide of potassium, and glycerine, which was employed at the suggestion of Dr. Byrne, and with good effect.

During the year the patient had taken cod-liver oil, and except by intervals has had a good appetite. Twice a severe and protracted attack of sciatica has been brought on, apparently by exposure to cold.

At one time the patient was confined to her bed, and was somewhat hysterical. During the summer the external part of the growth gradually reappeared, but there was no difficulty in urination or defecation; and hence we conclude that the portion in the rectum has not greatly enlarged, and at the last examination the condition of the vagina was not seriously altered. We have all along feared that the disease would extend to the uterus, but examinations made at different times gave no evidence of involvement of that organ.

The operations were performed with a zinc-carbon battery of 18 cells, freshly charged.

The constringing power of the current was observed

at both poles, but most decidedly at the positive. After each operation the surface presented a dark and somewhat charred appearance, as though it had been slightly burned. No large artery was severed during the operations, hence it was not necessary to use either the ligature or persulphate of iron. During the past winter (1873) Dr. Byrne has twice operated on the external portion of the growth with the galvano-cautery. The result has been a most satisfactory healing of the external ulcer that has been much more permanent than the healings that followed electrolysis.

We have given the above case in considerable detail, because of its great interest to surgeons, and especially because it illustrates most vividly at once the value and the limitations of electrolysis in malignant tumors. It illustrates:—

1. The power of electrolysis to control hemorrhage. The growth was so vascular that it bled quite profusely on the slightest touch, and yet, under the various and protracted electrolytic treatments to which it was subjected, the amount of blood lost was but a trifle.

2. The fact that the electrolytic treatment does not cause shock, to the extent that similar destruction of tissue by other methods would be likely to do. Twice, when chloroform was employed as an anæsthetic, the pulse acted badly and compelled us to suspend the operation sooner than we desired; but under etherization the needles were used for half an hour and longer without causing any shock. The stimulus of the cur-

rent, with the occasional interruptions that are required, seemed, by reflex influence on the central nervous system, to act as an antidote to shock, as it has appeared to do in other cases.

3. Better healing, and later reappearance of the growth than after the operation by ligature and caustics. When removed by ligature this growth sprang up with great rapidity—in the course of a few days; even before the eyes, as it were, it seemed to enlarge, and to develop an offensive discharge; and the base never began to heal, even on the edges. After thorough electrization of the base, this growth not only did not show signs of recurrence for several weeks, but an external ulcer of large size entirely healed. With the internal ulcer on the feebly organized mucous tissues o the vagina we were not so successful.

4. The severe irritative fever that sometimes follows electrolysis. After all the operations, the patient was confined to her bed for several days, and was more or less distressed by inflammation and swelling, not only on the edges of the ulcer, but at some distance down the nates and through the labia. The swelling of the labia was so great that difficulty and pain were experienced in passing water. It should be noted, however, that after the operations with the galvanic cautery and the actual cautery, the irritative fever and surrounding inflammation were much more decided and distressing, and for that reason we returned to electrolysis.

5. The utter inability of even the most thorough and

repeated electrolyzations of the base, to permanently eradicate the growth in those parts where it was *connected with the mucous membrane.* Although *the base was thoroughly worked up* by inserting the needles into the healthy tissue surrounding it so as to completely cut off all communication between the natural and morbid parts, yet the disease extended *from the vagina*—to all appearances travelled bodily, according to Morgan's theory of cancer—until quite distant parts were attacked and became saturated with cancerous degeneration. The *external* portion of the growth connected with the perinæum and nates was apparently eradicated as thoroughly and as successfully as the cases of epithelioma of the lip, previously reported, and the subsequent reappearance of the growth was due to the extension of the disease from the vagina.

6. The comparative value of electrolysis and galvano-cautery. The healing after electrolysis was incomparably more satisfactory than after the ligation; but in the course of months the growth returned, apparently by extension from the vagina. Since the last operations by galvano-cautery there has been as yet no recurrence. The irritative fever that followed the electrolytic operations was not observed to any very marked degree after the use of the galvano-cautery.

Take the case all in all, its long standing and wide extent, its excessively rapid growth and still more rapid reappearance after operation by ligature, the

requent repetition of long electrolyzations and the temporary benefit resulting therefrom, and the opportunity it afforded for comparing the advantages of electrolysis and galvano-cautery, it may probably be regarded as without a precedent in electro-surgery.

CHAPTER II.

CERTAIN DISEASES OF THE SKIN.

The theoretical arguments in favor of using electricity in diseases of the skin, and the methods to be employed, with the general results, we have elsewhere considered.* Our present purpose is to illustrate by cases what we have previously stated in an abstract form. We present the cases just as they appear in our note-book—the successful, the unsuccessful, and the doubtful.

We may, perhaps, so far repeat what we have previously written on the subject, as to state that in the electrical treatment of diseases of the skin both currents are required in the various forms of electrization, with wet sponges and cloths, with dry metals and the metallic brush. The best results are obtained by the *galvanic* current, and for reasons that will be clear, without argument, to those who are familiar with the differential action of the two currents.

During the past two years we have treated a number of cases of eczema, prurigo, and acne by *central galvanization* alone, *without* making *any application to the diseased surface whatever;* and under this method of

---

* *American Journal of Syphilography and Dermatology*, January, 1872; also *Medical and Surgical Electricity*, pp. 600, 601.

treatment, the results have in some instances been more satisfactory than under any other method of using electricity in these affections.

*In central galvanization the negative pole is applied to the epigastrium (the patient holding it by an insulated electrode), while the positive is applied at the top of the head, over the region of the pneumogastric and the cervical sympathetic, in the neck, and down the entire length of the spine, in such a way as to bring the brain, the pneumogastric, the spinal cord, and all the prominent ganglia and plexuses of the sympathetic—indeed the whole central nervous system—under the influence of the current.**

Not only after medication has failed, but after ordinary *localized electrization* has accomplished but little, central galvanization is sometimes rapidly and quite permanently efficacious. We should judge from our observations up to the present time that under this treatment the more *peripheral* patches of cutaneous disease yielded earlier than those on the trunk and near the centre; for example, eczematous spots on the hands and feet would sooner show signs of improvement than spots of the same disease on the upper arm, leg, and back. The dependence of certain diseases of the skin—as eczema, acne, prurigo—on the nervous system is by the remarkable results of this method of treatment demonstrated in a most interesting and suggestive manner.

---

* This method is described in full detail in the *New York Medical Journal*, October, 1872.

We first used central galvanization in hysteria, hypochondriasis, insanity, and other allied nervous affections, and the excellent results accomplished by it suggested its use in cutaneous affections.

Eczema.

It is an interesting comment on the value of theory in medicine that in eczema, which has not been supposed to be a nervous disease, the effects of central galvanization, according to our present experience, are as decided as in prurigo, and the results here recorded are more satisfactory than in almost any other form of cutaneous disorder.

At first we used localized galvanization in eczema, with sponges, cloths, and the metallic brush, and obtained thereby great relief of the itching, and in time cure; but during the past year we have used central galvanization for this disease, making no application whatever to the diseased surface, and have obtained far more rapid and we believe more permanent results. The following case illustrates the power of central galvanization in a most striking manner:—

Severe and obstinate chronic eczema of leg, eight years' standing; intolerable itching; failure of various remedies; rapid relief and permanent cure under central galvanization.

Case I.—Mrs. S. M——, an Irish servant-girl, aged 51, was admitted to the Long Island College Hospital, February 14, 1872, with chronic eczema of the left

leg about the ankle, and extending one-third of the distance to the knee. The itching and pain were intolerable, and there was much soreness. The patient was in other respects strong and well, but had suffered from this affection by intervals for eight years. Four years before she had been under treatment at the City Hospital, and had been discharged apparently cured, but relapsed.

The case was treated by iodoform, arsenic, bicarbonate of soda, rhubarb, carbolate of zinc, glycerine, cod-liver oil, iodide of potassium, delcamara, acetate of lead, wine of colchicum, and acetate of potash. These remedies were variously used, in various modifications, externally and internally. From some of these agents the patient derived temporary relief of the itching and soreness; but the average and ultimate effect was, that on April 1st the following record of the case was made in the hospital book: "Very painful, red and angry, rapidly extending, and now covering nearly the whole leg below the knee, and most of the dorsal aspect of the foot."

Arsenic and tincture of cinchon. comp. were now ordered, but April 15th, the record was: "Very much the same." At this time, Dr. Davis suggested *localized faradization.* This suggestion was acted on with gratifying result; the intense distress was at once in a measure relieved.

April 16th, the patient was more comfortable than for a long time previous.

April 23d, very much improved and comparatively comfortable.

At this time Prof. A. B. Crosby, the surgeon in charge of the ward, requested us to see the patient, stating that she had been very obstinate under the various remedies that he had tried. The patient was suffering greatly from the severe itching and burning, and the soreness was so great that only with difficulty could she hobble about the ward. The appearance of the diseased part was red and angry, and some portions were more or less covered by scales.

We decided to try on the patient the effect of *central galvanization, making no application whatever to the diseased part.* We were induced to make this trial on the strength of successes in other and milder cases of cutaneous diseases. Our chief hope was, perhaps, to relieve the itching and pain; a permanent cure we had no reason to anticipate. As the patient was a good and willing subject on which to demonstrate electrical applications, she was taken before the class of the Long Island College Hospital, and treated by central galvanization, the statement being made, that we did not hope thereby to cure, but simply to illustrate the method of using electricity.

The details of the applications were entrusted entirely to Dr. Edwin E. Smith, house-surgeon, who carried out the treatment with great faithfulness, and to whom we are indebted for the full history of the case as here presented.

The relief of the itching and pain was very rapid, although on the 25th Dr. Smith made the following record: "A little more irritable." This result was probably due to over-treatment, too strong currents, or too prolonged applications.

April 30th.—Patient "much better."

May 10th.—"Still steadily improving." The appearance of the leg was now much changed for the better. The most obstinate portion was the region about the ankle. The applications were made four and five times a week with a 12-cell zinc-carbon battery of Kidder for about ten minutes at a *séance.*

May 25th.—A lotion of acetate of lead wash was ordered by Dr. Crosby, to contract the enlarged capillaries.

June 5th.—"Patient is walking about out-doors with comparative ease, and is nearly well."

We again presented the case before the class of the College, demonstrated on her our method of central galvanization, and pointed out the extraordinary and unlooked-for improvement. The skin of the whole leg, except around the ankle, was well, and the patient for a long time had been entirely free from itching and pain.

June 15th.—The patient was "discharged cured."

Jan. 13th, 1873.—Dr. Smith informs us that there has been "no recurrence of the difficulty."

The above case, taking all the facts into consideration—its long standing, its inveteracy under manifold

treatment, and the immediate and rapid relief and cure under central galvanization, is certainly most extraordinary, and it will not subtract from the instructiveness and brilliancy of the result, if in future years a fresh attack of the disease should occur. Although the case was not, so far as we know, studied by any recognized specialist in dermatology, yet among the very many surgeons and physicians who watched its progress before and during the electrical treatment, there was, we believe, no difference of opinion in regard to the diagnosis, and there was no question that the cure was wrought entirely by *central galvanization, acting upon the central nervous system*, and thus improving the *peripheral* nutrition.

Eczema of head and face and lower limbs in a child; rapid improvement, with disappearance of the eruption under central galvanization.

Case II.—John B——, aged 3 months, was admitted to the Electro-Therapeutical Department of Demilt Dispensary, March 8, 1872. The child was affected with eczema of the scalp and face, which was most marked between the eyes, and extended down the back, and on the legs from the knees to the feet.

The eruption was very moist, and the diseased part was covered with thick yellow scabs. The child was very restless at night; was very constipated, and could scarcely open its eyes. The case had been treated by various poultices and ointments. At that time we

were experimenting with central galvanization in diseases of the skin, and we resolved to test the method in this case. After the third application the bowels became more free, the child slept well, and the eruption had dried up, and the scabs peeled off. At the end of two weeks the fourth and last application was given; the disease had then nearly disappeared from the back and legs. Since that time we have seen nothing of the patient.

It is proper to remark of the last case that, because of the situation of the disease, it was impossible to use central galvanization without directly acting on some portion of the diseased surface. It is possible, therefore, that the benefit was due in part to the local action of the current, and yet we were not able to trace any more rapid improvement in those portions thus slightly acted on than in the portions not touched by the electrodes.

The effect of merely localized applications is illustrated by the following case:—

Chronic eczema of the legs and feet, one year's standing; relief of pain and itching under localized faradization and galvanization.

Case III.—Michael P——, aged 64, had suffered for twelve months from chronic eczema of the legs and feet, accompanied with terrible itching and burning sensations. The affected parts were but little sensitive to the electric current, either galvanic or faradic.

Localized galvanization and faradization were employed, and some of the time the electric brush with a strong current was not only well borne, but was most grateful to the patient. The applications were made from five to twenty minutes. *In all cases there was relief of the distressing pain.* Symptoms of relief began to appear soon after the beginning of the *séance*, and at the close was sometimes absolute. This relief lasted at first from two to twelve hours.

The patient continued treatment for three weeks—in all six applications were made. The intervals of relief were sensibly lengthened, and the patient abandoned treatment. With the relief in the itching and pain there was corresponding relief in the appearance of the diseased parts.

Eczema of arm and hands; relief of pain and itching under localized galvanization.

Case IV.—Mary C——, aged 46, had been afflicted for some time with eczema of the forearm and hands. In the palm and back of the hand there was considerable disease, and the pain was very intense. She complained of severe itching and scalding. The general condition of the patient was very good. The hands were considerably swollen, and patches of various sizes appeared on the fingers.

Localized galvanization was used, with good results. There was relief of the pain; corresponding with the relief of the pain there was improvement in the appearance of the disease.

The patient abandoned treatment before an exhaustive trial had been made.

The advantage of central galvanization over merely localized applications was shown in the following:—

Chronic eczema of twenty years' standing; localized galvanization and improvement; subsequent relapse, and more rapid and satisfactory improvement under central galvanization.

Case V.—John P——, aged 52, had for twenty years suffered from chronic eczema, that attacked by turns different parts of the body. For four years he had, by intervals, been attending the Skin Department of the Demilt Dispensary, under the treatment of Dr. Woodruff, who had given him various remedies, relying chiefly on arsenic. Under the arsenic treatment the improvement was quite decided, but beyond a certain point he could not be carried.

When brought into the Electro-Therapeutical Department of the Dispensary, there was a small patch of eczema on the back of the left hand, and a little of the disease on the right foot. The history of the disease had been, that it spread over the hand from this one centre.

Treatment by localized galvanization was used for a month, with positive evidences of benefit.

The disease subsequently recurred, and the patient again desired treatment. At that time we were using central galvanization, and we resolved to test it in his

case, making no electrical or other applications to the diseased surface. Under this method of electrization the relief was apparently more satisfactory than under merely localized applications. It is more than probable that the patient will again suffer relapse; but, up to the date of writing, we have heard no more of him.

Chronic eczema of the right foot, of ten years' standing; rapid and complete relief from localized galvanization.

Case VI.—Thomas D——, aged 28, came into the Electro-Therapeutical Department of the Dispensary, Sept. 19, 1871. For ten years chronic eczema of the right foot and ankle had afflicted him, and for two weeks the distress had been so great that he had been obliged to give up his occupation, which was that of waiter. The relief from pain, on galvanization with wet sponges, was immediate, and continued for some time after the *séance* was concluded. Some of the time, dry metallic electrodes were used, and *always with rapid relief to the distressing sensation of heat, by which the disease was marked.* The electric brush was used at times, and even with a strong current was grateful to the patient. The patient apparently recovered in the course of a month's treatment, and we then lost sight of him.

In the above, as in some other cases of painful diseases of the skin, strong currents were not only well borne on the diseased surface, but were exceedingly grateful.

Acne.

Our first experiments in the electrical treatment of acne were failures. These failures were due partly to the neglect of the patients to persevere, and partly to our not using *central* treatment. Under the combined influence of central and peripheral treatment, or under central alone, or peripheral alone, something may be accomplished in this affection, although great perseverance is necessary, and it is not impossible that cases which are relieved, or apparently cured, may relapse.

Our observations in this department are as follows:—

Acne rosacea of long standing; immediate improvement under localized galvanization.

Case VII.—A medical gentleman, aged about 60, in April, 1872, requested us to treat him for acne rosacea that had for some time caused him annoyance. The blood-vessels were considerably enlarged on both sides of the nose, the color was a decided red, and there was the usual thickening. The health of the patient was in other respects pretty good, excepting attacks of indigestion with acidity.

We began treatment with localized galvanization—with wet cloths and sponge, sometimes using pure metal with a sharp edge. When the metal was used, the dilated capillaries were electrolyzed under the negative pole, and gases escaped with a sound that could be easily heard. There was a tendency to reappearance of the dilated vessels, but after a few weeks'

treatment they were entirely destroyed, leaving no scar or trace, and the color of the nose on both sides had disappeared. There appeared to be also a diminution of the hypertrophied tissues.

There has been, since that time, some return of the affection, but he is very much better than formerly. The habits of the patient were never intemperate, but he had always been accustomed to use more or less alcoholic liquors.

A French physician has reported excellent results in the treatment of acne rosacea by electricity.

The following is one of the earliest cases of disease of the skin that ever came under our observation :—

Case VIII.—Mrs. —— was referred to us in 1867, for treatment for acne of very long standing. The limbs and face were affected by the disease. An immense variety of treatment had been employed, and the patient had consulted very many American and European authorities—among others, Hebra, of Vienna—and she was nothing better.

At that time we had not used central galvanization, and had had no experience in the treatment of diseases of the skin by any method of electrization.

As a matter of experiment, we used general faradization, but the patient did not continue the treatment long enough to determine just how much benefit was obtained thereby.

It is by no means impossible that general faradization, by improving the digestion and relieving the con-

stipation, might be of great service in acne, either alone or in connection with central galvanization.

In the above case all the symptoms were aggravated at the monthly period ; it is not unlikely that general faradization or localized faradization of the patient, internal or external, might have been of service in relieving the dysmenorrhœa as well as the digestive disturbance, and this might have relieved the acne.

Acne of several years' standing treated by central galvanization and dry faradization.

Case IX.—In May, 1872, a young man of 26 was brought to us by Dr. Carpenter, complaining of acne of the back especially, that for several years had been his companion. The back was well covered with the eruption. The digestion was not right, and the bowels were constipated.

Central galvanization was at once used three times a week, which a part of the time was varied by *dry* faradization with the hand and metallic electrodes—a method Dr. Piffard had suggested to us as efficacious in acne. There was very soon improvement: the large spots began to dry up, but the patient went away after eight applications.

During the present summer (1873) we have been treating a case of acne indurata of the face—a patient of Dr. Thayer—with the negative pole of the galvanic current connected with metallic disks and points, and electrodes armed with many sharp points,

alternating with central galvanization. This case has improved slowly but decidedly, and is still under treatment.

Our assistant, Dr. J. H. Sterling, informs us that one year ago a case of hereditary acne indurata of the face and back under his care was treated by eighteen applications of central galvanization without any other treatment, and the disease disappeared. The constipation and headache, which had been very distressing, were also relieved. Up to date (July 1873) the patient was well.

Prurigo.

In prurigo it would be consistent to expect benefit from electrical treatment. Experience shows that this expectation is well grounded. All methods of using electricity seem to do good in prurigo. Relief of the itching is obtained by dry faradization and galvanization with wet sponges and cloths, but the most permanent results seem to come from central galvanization.

General prurigo, six years' standing; intense itching; approximate cure after fifteen séances of central galvanization.

Case XI.—W. R——, 9 years of age, came into the Electro-Therapeutical Department of Demilt Dispensary, April 11, 1872. At the age of three the patient had scarlet fever; this was followed by general prurigo that had never been relieved. The disease covered the back, abdomen, and legs. The itching was most severe. Sleep at night had for years been in-

terrupted by this distress, and marks of scratching were everywhere seen. The disease was at its worst on the back.

Acting on the theory that the disease was of a nervous character, Dr. Woodruff referred the case to the Electro-Therapeutical Department, when treatment by central galvanization was begun and continued for two months. Towards the close of the treatment, June 1, little remains of the eruption were seen excepting on the back, and there was very little itching.

June 15.—The patient abandoned treatment; the recovery appeared to be satisfactory. We have no further intelligence of the case.

Dr. Sterling gives us the following case, the diagnosis of which was not fully clear to him :—

Lichen ægrius of long standing; some improvement under localized galvanization, and galvanization of the cervical sympathetic; much greater improvement under central galvanization.

Case X.—Mr. G——, at the age of twelve, was attacked with an eruption all over the body, after sea-bathing. Treatment cured the eruption, but a burning, smarting sensation was left in the fore-eye, that always was increased on any excitement. Drinking a cup of tea or coffee, or entering a heated room, would bring on burning and smarting in the face, with very decided puffiness. Arsenic and various other remedies had been used faithfully.

May 1, 1871.—Treatment by galvanization of the

sympathetic and localized galvanization was begun, and the result was satisfactory; but relapse occurred, and some months subsequently he was treated by central galvanization alone, with very great improvement. He still suffers from slight relapses that are always benefited by electrical treatment.

Psoriasis and pityriasis.

These diseases have not, in our hands, yielded to electrical treatment with great rapidity. They improve slowly, however, up to a certain point, and in some cases an apparent cure, or something approximate to a cure, may be obtained by a long course of treatment. Our first experiments in the treatment of psoriasis by electricity were made with Dr. H. G. Pifford at the Dispensary for Diseases of the Skin.

General pityriasis of four years' standing; slow but decided improvement under galvanization, localized and central; relapse.

Case XII.—Miss O——, aged 19, had for four years been a victim of pityriasis, that attacked first the scalp, causing profuse "dandruff," and extending to the trunk. Treatment of various kinds, external applications and internal medication had been used by good surgeons, and with great perseverance, for many months. The benefit had been slight and transitory. A short interval of disappearance of the patches of the disease would be followed by a rapid reappearance, and at no period had she been even approximately free from the disease.

The patient was brought to us November, 1871, by Dr. Freeman, who, at that time, had the patient under observation. The scalp was then pretty well covered with the disease, and behind the ears were large patches. Dandruff was very abundant. The health of the patient was excellent. Patches of the disease were also on the back, sides, breast, and abdomen.

Treatment by localized galvanization was commenced and continued for three months by intervals. The improvement was quite slow, but after about a month, some of the spots on the breast had entirely disappeared. The patches on the back and sides were most obstinate, and although they changed in their character, had not entirely disappeared when the patient left the city.

The first evidence that the treatment was taking hold was observed on the head; for several weeks before the close of treatment, the amount of "dandruff" had been reduced to a minimum. The patches of disease behind the ears yielded with great slowness. The patient relapsed the next season, and was as bad as ever.

Pityriasis capitis of many years' standing treated by galvanization without immediate effect, but subsequent improvement.

Case XIII.—A physician had for many years been annoyed by "dandruff," that was constant and very profuse. By our request he took a course of galvanization. The hair was thoroughly moistened, and

the applications were made over the head, as well as over the neck and spine; combining localized with central galvanization.

During the course of treatment, which lasted for several weeks, there was no apparent improvement; but since the abandonment of the experiment the disease has diminished. It is not improbable that here, as in other diseases, the *after* effects may be observed even when the effects during treatment are negative.

Psoriasis of the arms and legs of thirty years' standing; some improvement under localized faradization.

CASE XIV.—Mary P——, aged 63, had suffered for thirty years from psoriasis that attacked the arms and legs. She was sent into the Electro-Therapeutical Department of Demilt Dispensary, April 14th, 1871. Treatment was commenced that day by localized galvanization, by means of adjustable* electrodes, covered with flannel. Both poles were employed.

This treatment was combined with central galvanization. The patient discontinued treatment before a fair trial had been given; but some improvement was observed, even during the short time that she was under observation.

Herpes.

More than a century ago herpes zoster was treated by

* Adjustable electrodes is a term that we have applied to flat metallic electrodes of different sizes and shapes; these are provided with flannel or chamois covers. These covers are provided with elastic borders, and may be put on and off at pleasure, and may be washed like towels.

Franklinic electricity, and, it is claimed, with success. A spot of *herpes circinatus* disappeared under galvanization, and up to date has not returned.

In a case of herpes zoster associated with neuralgia, that we treated during the past year, the neuralgia was rapidly and permanently cured by faradization; the herpitic eruption had nearly disappeared before electric treatment was begun.

In another very ugly and obstinate case of herpes zoster of four weeks' standing there was a decided improvement in the condition as soon as the galvanic current was applied. The most remarkable results of the electrical treatment of herpes have been obtained in the variety known as *herpes frontalis seu ophthalmicus.* This disease, besides being very painful, sometimes excites inflammation of the cornea, and destroys the eye. In two cases that were treated at the Brooklyn Eye and Ear Hospital by localized galvanization, the relief of pain was immediate, and the cure was rapid and permanent. Both of these cases we saw, and one we treated. In both cases the eye was saved.

Elephantiasis of the legs, over two years' standing, attended with ulceration and great pain; relief of pain; removal of the elephantine skin and very remarkable reduction in the size of one leg under localized galvanization.

Case XV.—Mr. P——, an Englishman of middle life, a man strong and vigorous beyond the average, a distiller of oils by occupation, returning from his daily

duties on the evening of February 22d, 1870, observed, on removing his socks, a small blister on the inner side of the left ankle. The next day he called on his physician, Dr. Rotton, under whose care he remained for one year and more.

The disease spread over the *left* foot and ankle, and in about two months the right foot was similarly attacked. The blisters as they ruptured left inflamed and angry surfaces in their track. The disease involved the surface of the feet, and both legs up to the knees. The treatment carried out by Dr. R. was mainly of a tonic and alterative character, with local applications of glycerine, carbolic acid, and lead wash. At one time Dr. Johnson saw the case, confirmed the diagnosis of elephantiasis, and rendered a diagnosis positively unfavorable.

We first saw the case by request of Dr. R. in May, 1872. At that time the right leg below the knee measured *twenty-five inches* in circumference, and it was covered all over with elephantine skin, excepting an ulcerating surface below the ankle. This ulcer was treated with charcoal poultice and discharged freely. The *left* leg was not greatly enlarged, but was red, angry, and inflamed, and kept up an incessant discharge from the surface.

The patient *suffered horrible agonies*, so that at night the neighbors were disturbed by his howling. He was unable to move from the sofa on which he sat, and where he worked at his newly-learned trade of cleaning gloves.

By our request Dr. E. Mann, one of our assistants, undertook the experimental treatment of the case by electricity. We had never known of elephantiasis being treated electrically, and gave an unfavorable prognosis, and were indeed inclined not to attempt it; only by the earnest request of the patient and his physician we decided to try and see whether we might give him some relief. Localized *faradization* at first tried by Dr. Mann accomplished nothing, and, so great was the anæsthesia, was not felt by the patient.

Localized *galvanization* by means of wet sponges and both poles with zinc-carbon battery of 16 cells was appreciably felt, and very soon began to relieve the pain.

The applications, from 10 to 30 minutes in length, were made at first by Dr. Mann, and subsequently by the daughter of the patient under our supervision.

After two months' treatment the elephantine skin on the left leg was removed, the pain had ceased, and the leg was reduced in circumference from *twenty-five* to *seventeen inches.* The ulcerated portion below the ankle was also nearly well.

The electrical treatment was then discontinued for several months. During the latter part of this time there were evidences of relapse and reappearance of ulcers and pain. The case has been seen by a large number of the profession.

The features in the cases here recorded most worthy of note are the following:–

1. The rapid relief of the itching and pain of eczema, prurigo, and herpes by local applications.

2. The relieving and curative effects of *central galvanization* not only in prurigo, but also and especially in eczema, which has not generally been supposed to be so closely dependent on the nervous system.

3. The fact that herpes, prurigo, and eczema yield in some instances very rapidly, while psoriasis and pityriasis are quite slow and obstinate.

4. The tendency of some cases to relapse even after they have been greatly benefited, while in other cases —notably in eczema and herpes—the cure is more or less permanent.

Comparative advantages of electrolysis and galvano cautery.

A question of great interest in electro-surgery is the comparative value of electrolysis and galvano cautery. They are both used to accomplish some of the same indications.

We have thus compared the two methods—

(1.) By using them simultaneously on the same case.

(2.) By using them in succession on the same case.

(3). By treating cases more or less similar, exclusively by one or the other.

The conclusions at which we have arrived are these—

1st. The relief of pain of malignant tumors is best accomplished by electrolysis, or by external galvanization.

Cauterization with the galvano cautery burners

modifies the pain to a certain extent, and in some grave cases may have a more permanent relieving influence than electrolysis, or external electrization; but for the great majority of cases of ulcers or tumors, where relief of pain is the leading indication—electrolysis or external galvanization, or both combined, will best accomplish the purpose.

2d. Schirrus of the breast, where there is no ulceration; external fibroids and goitres, are best treated by external electrization and electrolysis.

3d. For the treatment of polypi—some other tumors, with a base of moderate size and accessible, as of the ear, nose, larynx and uterus—the galvano-cautery is preferable to electrolysis.

4th. In cases where large blood-vessels are involved and there is consequently great liability to hemorrhage, the galvano-cautery is preferable to electrolysis. Moderate hemorrhage can be easily controlled by electrolysis, especially by the positive pole.

5th. Erectile tumors, superficial and subcutaneous, epithelial and encephaloid cancers in all accessible locations, may be treated with more or less success by either electrolysis or galvano-cautery, or by both combined. We are inclined to the belief that the results of a combination of the two methods would be more permanent in many cases than when only one is employed. To establish this opinion by clinical experience will require time and careful observation.

The accompanying cuts represent the needles—insulated and non-insulated—and needle-holders that

we have been accustomed to employ in the operations recorded in this series of papers. The large spear-shaped needles, with sharp edges, we devised for the method of working up the base.

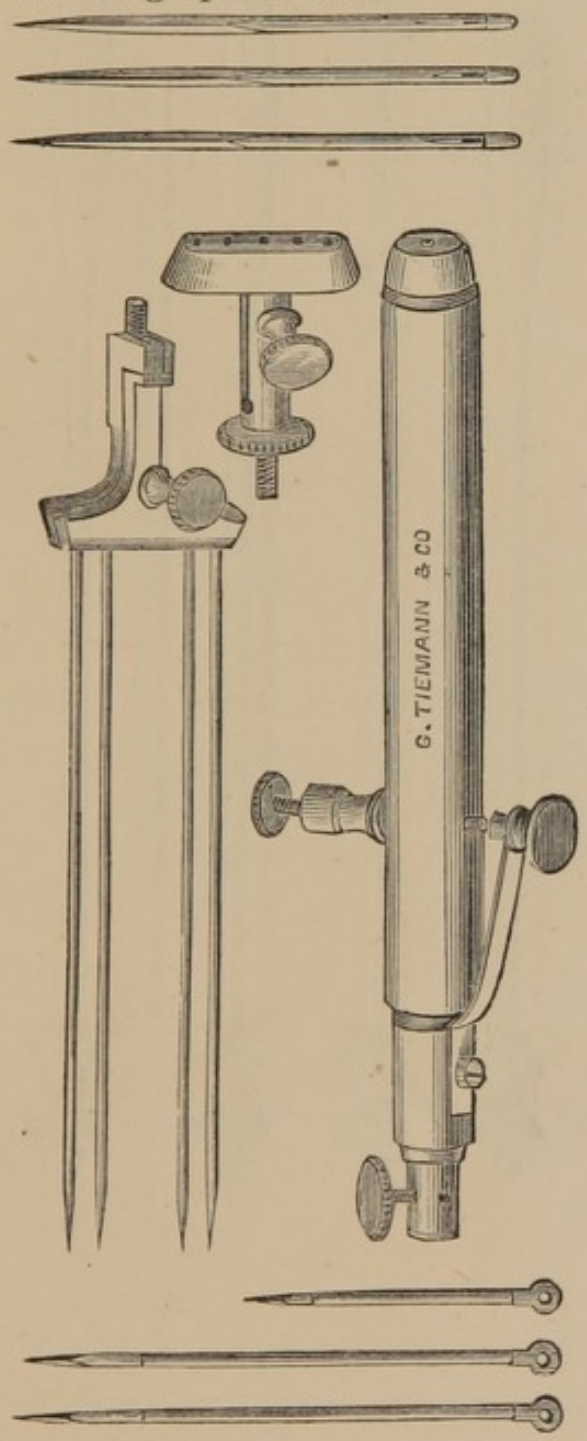

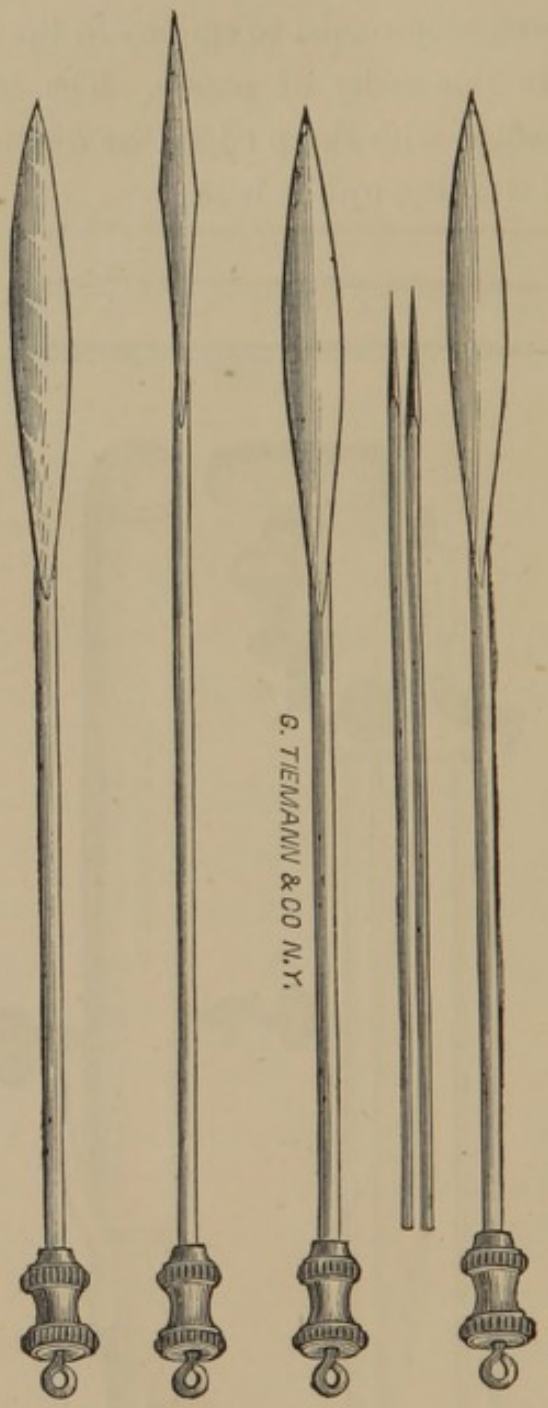
G. TIEMANN & CO N.Y.