

## **Human anatomy (Volume 1).**

### **Contributors**

Quain, Jones, 1796-1865.  
Leidy, Joseph, 1823-1891.  
Quain, Richard, 1800-1887.  
Sharpey, William, 1802-1880.  
National Library of Medicine (U.S.)

### **Publication/Creation**

Philadelphia : Lea and Blanchard, 1849.

### **Persistent URL**

<https://wellcomecollection.org/works/cuypwmtmp>

### **License and attribution**

This material has been provided by This material has been provided by the National Library of Medicine (U.S.), through the Medical Heritage Library. The original may be consulted at the National Library of Medicine (U.S.) where the originals may be consulted.


This work has been identified as being free of known restrictions under copyright law, including all related and neighbouring rights and is being made available under the Creative Commons, Public Domain Mark.


You can copy, modify, distribute and perform the work, even for commercial purposes, without asking permission.



Wellcome Collection  
183 Euston Road  
London NW1 2BE UK  
T +44 (0)20 7611 8722  
E [library@wellcomecollection.org](mailto:library@wellcomecollection.org)  
<https://wellcomecollection.org>







QUAIN AND SHARPEY'S  
QUAIN'S ANATOMY.  
VOL. I.



OF LIN AND SHERBET

QUINN'S AND SHERBET

VOL. I

# HUMAN ANATOMY.

BY

JONES QUAIN, M.D.

EDITED BY

RICHARD QUAIN, F.R.S.

AND

WILLIAM SHARPEY, M.D. F.R.S.

PROFESSORS OF ANATOMY AND PHYSIOLOGY, IN UNIVERSITY COLLEGE, LONDON.

---

FIRST AMERICAN, FROM THE FIFTH LONDON EDITION,

EDITED BY

JOSEPH LEIDY, M.D.

---

IN TWO VOLUMES.

WITH OVER FIVE HUNDRED ILLUSTRATIONS.

VOL. I.



PHILADELPHIA:  
LEA AND BLANCHARD.  
1849.

QS  
Q/c  
1849  
v. 1

Entered, according to Act of Congress, in the year 1849,  
BY LEA AND BLANCHARD,  
In the Clerk's Office of the District Court for the Eastern District of Pennsylvania.

PHILADELPHIA:  
C. SHERMAN, PRINTER.  
19 St. James Street.



## P R E F A C E

BY THE AMERICAN EDITOR.

---

AMONG the many systems of Human Anatomy, which have appeared from the press, in the English language, of late years, none have presented more completely the progress of General and Special Anatomy, than Drs. Quain and Sharpey's present edition of Quain's Anatomy. Indeed, so thoroughly and carefully have the researches of modern anthropotomists and histologists of continental Europe, and others, been examined and incorporated in the work, with the addition of much original matter, that I have been able to add little else than a few observations made in this country.

The department of General Anatomy or Histology, so important to a proper understanding of Physiology, will be found to have been minutely and ably discussed, and brought up to the day.

The book is also the first systematic treatise of Anatomy in the English language, containing the history of the ossification and development of the individual bones of the skeleton, which must render it of peculiar value to the anatomist.

Topographical Anatomy, as also abnormal arrangements of the arteries and veins, have been fully attended to;—and the whole being illustrated by more than five hundred well-executed wood engravings, cannot fail in rendering it a valuable hand-book, and an acceptable offering to the American student.

All matter which I have added is included in brackets, most usually with the initials of my name attached, and in most cases is original. In a number of instances, wood-cuts have been substituted where simi-

lar ones were already in the hands of the publishers, and frequently additional ones will be found to have been introduced, all of which are included in brackets, with the last initial of the authors' names whence they were obtained, or the names in full when I have known them to be original, thus:—[W.], Wilson's Anatomy; [Todd and Bowman], &c.

No expense has been spared in getting up the work in excellent style, and the publishers certainly deserve the thanks of the profession in thus encouraging this fundamental department of Medical Education.

JOSEPH LEIDY.

Philadelphia, June, 1849.



## ADVERTISEMENT.

---

SOON after they had begun to prepare for publication a new edition of Dr. QUAIN'S ANATOMY, the Editors found that in order to place the work on a level with the existing state of anatomical knowledge, and maintain for it the character it has hitherto possessed, their labour must be much more extensive than usually falls to the lot of an editor. They perceived, in fact, that it would be advisable to write a considerable part of the work anew, whilst the rest underwent such alterations as were required in a careful revision. The following changes have accordingly been made in the present edition.

The whole of the Section on General Anatomy is re-written.

The Descriptive Anatomy of the Osseous System has undergone various alterations, and some portions, including those which treat of the Formation and Growth of the several Bones of the Skeleton, belong exclusively to this edition. The description of the Articulations has been subjected to a complete revisal.

Under the head of the Muscular System, many additions have been made; among which may be especially mentioned the account of the variations of form and attachment observed in individual muscles. Several parts have been re-written; but the paragraphs headed "Dissection" and "Action of Muscles" are printed from the preceding edition with scarcely any alteration.

The principal changes to which the section on the Vascular System has been subjected, occur in the description of the Arteries. The history of each of the larger arteries has been recast, and a statement of the varied forms which these vessels present in different cases has



been abridged from a special treatise published by one of the Editors.

In the remainder of the work, including the description of the Brain, Nerves, and Organs of the Senses, the Heart, with the Digestive, Respiratory, Urinary, and Generative Organs, little or nothing remains of the former editions.

The Surgical Anatomy, which has been introduced partly in connexion with the history of the principal arteries and partly at the end of the work, has likewise been written for the present edition.

In editing the work, the different parts have been apportioned in the following manner, viz.: the General Anatomy to Dr. SHARPEY, with the Descriptive Anatomy of the Brain, the Heart, the Organs of Respiration, Voice, Digestion, Urine, and Generation; and to Mr. QUAIN, the remaining portion of the Descriptive Anatomy, comprehending the Bones, Muscles, Articulations, Fasciæ, Vessels, Nerves, and Organs of the Senses, as well as the Surgical Anatomy of the different regions.

In a part of their labours, the Editors have availed themselves of the aid of their Junior Colleagues in the Anatomical Department of University College, viz., Mr. ELLIS, the late Mr. POTTER, and Mr. MARSHALL.

The Description of the Nerves is, in great part, due to Mr. ELLIS, who has devoted much attention to the prosecution of this branch of Anatomy. Mr. POTTER afforded his aid in the account of the Fasciæ and Organs of Sense. By the assistance of Mr. MARSHALL, Dr. SHARPEY has been relieved of much of the labour required for the execution of his share of the Descriptive Anatomy; in the preparation of which, while free use has been made of existing systematic works, the notes of his lectures have, for the most part, served as a basis. But while they willingly concede to their colleagues a full share of any merit which may be found in those portions of the work in which they were respectively engaged, the Editors assume to themselves the whole of the responsibility.

A large number of Engravings on wood have been added to those which appeared in preceding editions. When copied from any other

work, the sources from which the new Illustrations have been derived are in all cases mentioned; when no such acknowledgment is made, the drawing is to be considered original.

Lastly, it may be well to explain, that when statements are made in the first person, they proceed from the Editor of that part of the book in which they occur.

September, 1848.





# CONTENTS OF THE FIRST VOLUME.

	PAGE		PAGE
INTRODUCTION - - - -	37	FIBRO-CARTILAGE - - - -	243
GENERAL CONSIDERATIONS on the		The SYNOVIAL Membranes - -	244
Textures - - - -	39	ARTICULATIONS - - - -	247
Physical properties of the Textures - - - -	40	Classes of Articulations - -	247
Chemical composition of the Textures - - - -	42	Movements of Articulations -	249
Vital Properties of the Textures	49	Articulations of the Vertebral Column - - - -	252
Development of the Textures -	51	Articulation of the lower Jaw -	259
Nutrition and Regeneration of the Textures - - - -	68	Articulations of the Ribs - -	260
OSTEOLOGY - - - -	72	Articulations of the upper Limbs	263
BONE or OSSEOUS tissue - -	72	Articulations of the Pelvis -	274
The Skeleton - - - -	95	Articulations of the lower Limbs	278
The Vertebrae - - - -	96	FASCIAE - - - -	292
The true Vertebrae - - - -	97	Superficial Fascia - - - -	293
The false Vertebrae - - - -	103	Fasciae of the Head and Neck -	294
The Sacrum - - - -	103	Fasciae of the Thorax - - - -	297
The Coccyx - - - -	106	Fasciae of the Upper Limb - -	298
The Vertebral Column - - - -	107	Fasciae of the Abdomen - - -	301
Ossification of the Vertebrae - - - -	109	Fasciae of the Perineum - - -	304
The Bones of the Cranium - -	115	Fasciae of the Pelvis - - - -	304
The Bones of the Face - - - -	139	Fasciae of the Lower Limb - -	307
The Os Hyoides - - - -	151	MYOLOGY - - - -	313
The Sutures of the Skull - -	152	The MUSCULAR tissue - - - -	313
The General Conformation of the Skull - - - -	154	MUSCLES - - - -	331
Analogy between Cranial Bones and Vertebrae - -	163	Muscles of the Epicranial Region - - - -	331
Man adapted to the Erect Posture - - - -	165	Muscles of the Face and side of the Head - - - -	334
The Thorax - - - -	169	Muscles of the Neck - - - -	349
The Bones of the Upper Extremity - - - -	175	Muscles of the Back - - - -	366
The Os Innominatum - - - -	198	Muscles of the Upper Limb - -	384
The Pelvis - - - -	205	Muscles of the Fore-arm, - -	396
The Bones of the Lower Extremity - - - -	208	Muscles of the Hand - - - -	407
The CELLULAR or AREOLAR tissue - - - -	227	Muscles of the Abdomen - - -	413
The FIBROUS Tissue - - - -	232	Muscles of the Ribs - - - -	421
The YELLOW or ELASTIC tissue -	235	Muscles of the Perineum - - -	426
CARTILAGE - - - -	237	Muscles of the Lower Limb - -	426
		Muscles of the Leg - - - -	444
		Muscles of the Foot, - - - -	456
		Table of the Muscles in the order of Dissection - - - -	462
		Table of the Muscles according to their Actions - - - -	465
		ANGIOLOGY - - - -	468

	PAGE		PAGE
ORGANS OF CIRCULATION -	468	THE ABDOMINAL AORTA -	595
The Thorax -	468	The Celiac Artery or Axis -	596
The Pericardium -	469	The Coronary Artery of the	
The Heart -	470	Stomach -	596
Development of the Heart and		The Hepatic Artery -	597
great Blood-vessels -	488	The Splenic Artery -	598
Peculiarities of the Fœtal Heart		The Superior Mesenteric Artery	599
and Circulation -	491	The Inferior Mesenteric Artery	600
ARTERIES -	526	The Capsular or Suprarenal Ar-	
THE AORTA -	526	teries -	601
The Coronary Arteries -	532	The Renal or Emulgent Arte-	
The Innominate Artery -	534	ries -	602
The Common Carotid Arteries -	534	The Spermatic Arteries -	603
Surgical Anatomy of -	538	The Inferior Phrenic Arteries -	603
The External Carotid Artery -	538	The Lumbar Arteries -	604
Branches of -	539	The Middle Sacral Artery -	605
The Internal Carotid Artery -	551	The Common Iliac Arteries -	606
Branches of -	553	Surgical Anatomy of -	607
The Subclavian Arteries -	556	The Internal Iliac Artery -	608
Surgical Anatomy of -	561	Surgical anatomy of -	609
Branches of -	563	Branches of -	610
The Axillary Artery -	573	The External Iliac Artery -	617
The Axillary space -	574	Surgical Anatomy of -	618
Branches of the Axillary		Branches of -	619
Artery -	575	The Femoral Artery -	621
The Brachial Artery -	578	Branches of -	622
Surgical Anatomy of -	580	Surgical Anatomy of -	625
Branches of -	581	The Popliteal Artery -	627
The Ulnar Artery -	583	The Popliteal Space -	628
Branches of -	584	Branches of Popliteal Ar-	
The Interosseous Artery -	585	tery -	629
The Radial Artery -	587	The Posterior Tibial Artery -	630
Branches of -	589	The Peroneal Artery -	631
THE THORACIC AORTA -	593	The Anterior Tibial Artery -	634
		Anastomoses of Arteries in the	
		Lower Limb -	637



# LIST OF ILLUSTRATIONS.

## VOL. I.

FIG.	PAGE.
1. Nucleated cells from a bulbous root, . . . . .	52
2. Section of vegetable textures, . . . . .	53
3. Stellate cells from bull-rush, . . . . .	53
4. Section of ligneous cells, . . . . .	53
5. Section of stone of a fruit, . . . . .	54
6. Section of branchial cartilage of tadpole, . . . . .	54
7, 8, 9. Cartilage of branchial ray of a fish, . . . . .	55
10. Formation of cell, . . . . .	57
11. Production of cells within a parent cell, . . . . .	59
12. Duplication of cells in ova of Ascaris and Cucullanus, . . . . .	59
13. Cells from ovum of Cucullanus, . . . . .	60
14. Cleaving of yolk after fecundation, . . . . .	61
15. Yeast plant, magnified, . . . . .	62
16. Irregular pigment cells, . . . . .	64
17. Cells from cortex of a growing feather, . . . . .	65
18. Development of areolar tissue, . . . . .	66
19. Transverse section of bone, magnified, . . . . .	76
20. Longitudinal section of bone, magnified, . . . . .	77
21. Transverse section of bone, very highly magnified, . . . . .	78
22. Reticular lamella of bone, . . . . .	79
23. Parietal bone of an embryo sheep, . . . . .	83
24. Bony spicula from frontal bone of an embryo dog, . . . . .	85
25. Humerus of a foetus, . . . . .	86
26. Longitudinal section of ossifying cartilage, . . . . .	87
27. Transverse section of ossifying cartilage, . . . . .	87
28. Longitudinal section of ossifying cartilage, highly magnified, . . . . .	88
29, 30. Transverse sections of growing bone, . . . . .	89
31. Ultimate reticular structure of bone, . . . . .	90
32. Formation of Purkinjean corpuscles, . . . . .	91
33. Reticulated structure of bone, . . . . .	92
34. A cervical vertebra, . . . . .	99
35. Dorsal vertebra, . . . . .	100
36. Lumbar vertebra, . . . . .	100
37. Atlas, . . . . .	101

38. Axis, . . . . .	102
39. Sacrum, . . . . .	104
40. Coccyx, . . . . .	106
41. Ossification of a vertebra, . . . . .	110
42. Epiphyses of a vertebra, . . . . .	111
43. Ossification of the atlas, . . . . .	111
44. Ossification of the axis, . . . . .	112
45. Ossification of the sacrum, . . . . .	112
46. Occipital bone, external surface, . . . . .	115
47. Occipital bone, internal surface, . . . . .	117
48. Occipital bone, ossification of, . . . . .	118
49. Parietal bone, external surface, . . . . .	119
50. Parietal bone, internal surface, . . . . .	119
51. Frontal bone, external surface, . . . . .	121
52. Frontal bone, internal surface, . . . . .	121
53. Frontal bone, ossification of, . . . . .	123
54. Temporal bone, external surface, . . . . .	124
55. Temporal bone, internal surface, . . . . .	124
56. Temporal bone, ossification of, . . . . .	127
57. Sphenoid bone, external surface, . . . . .	129
58. Sphenoid bone, internal surface, . . . . .	129
59. Sphenoid bone, ossification of, . . . . .	133
60. Ethmoid bone, . . . . .	135
61. Superior maxillary bone, . . . . .	139
62. Anterior palatine fossa, . . . . .	141
63. Superior maxillary bone, ossification of, . . . . .	142
64. Superior and inter-maxillary bone, . . . . .	143
65. Inter-maxillary bone, . . . . .	143
66. Malar bone, . . . . .	144
67. Nasal bone, . . . . .	145
68. Lachrymal bone, . . . . .	145
69. Palate bone, posterior view, . . . . .	146
70. Palate bone, external surface, . . . . .	147
71. Vomer of fœtus, . . . . .	148
72. Turbinate bone, . . . . .	148
73. Inferior maxillary bone, . . . . .	149
74. Inferior maxillary bone, ossification of, . . . . .	150
75. Hyoid bone, . . . . .	152
76. External surface of the base of the skull, . . . . .	155
77. Nasal fossæ, . . . . .	161
78. Bony septum narium, . . . . .	161
79. Thorax, . . . . .	169
80. Sternum, ossification of the, . . . . .	171
81. Rib, ossification of a, . . . . .	174
82. Scapula, . . . . .	176
83. Scapula, ossification of, . . . . .	179
84. Clavicle, . . . . .	180
85. Clavicle, ossification of, . . . . .	181
86. Humerus, . . . . .	182
87. Humerus, ossification of, . . . . .	184
88. Bones of the forearm, . . . . .	186



89. Radius, ossification of, . . . . .	187
90. Ulna, . . . . .	189
91. Bones of the carpus, . . . . .	190
92. Bones of the hand, . . . . .	193
93. Bones of the carpus, ossification of, . . . . .	196
94. Bones of the hand, ossification of, . . . . .	196
95. Innominate bone, . . . . .	198
96. Innominate bone, ossification of, . . . . .	204
97. Antero-posterior vertical section of female pelvis, . . . . .	206
98. Antero-posterior vertical section of female pelvis in outline, . . . . .	206
99. Femur, . . . . .	209
100. Femur, ossification of, . . . . .	211
101. Patella, . . . . .	212
102. Bones of the leg, . . . . .	213
103. Tibia, ossification of, . . . . .	215
104. Fibula, . . . . .	217
105. Bones of the foot, dorsal surface, . . . . .	218
106. Bones of the foot, plantar surface, . . . . .	218
107, 108. Bones of the foot, ossification of, . . . . .	224, 225
109. Filaments of cellular tissue, magnified, . . . . .	228
110. Two elements of areolar tissue, magnified, . . . . .	229
111. Bundles of cellular tissue, magnified, . . . . .	230
112. Development of areolar tissue, magnified, . . . . .	231
113. Organic cell of developing areolar tissue, . . . . .	231
114. White fibrous tissue, magnified, . . . . .	233
115. Elastic fibres, magnified, . . . . .	236
116. Elastic fibres, development of, . . . . .	237
117. Diagram of vertical section of articular cartilage, . . . . .	239
118. Transverse section from surface of articular cartilage, . . . . .	239
119. Vertical section of articular cartilage, . . . . .	240
120. Filamentous structure of articular cartilage, . . . . .	240
121. Section of fibro-cartilage, . . . . .	241
122. Cell-structures, from an intervertebral disk, . . . . .	244
123. Anterior ligaments of the vertebræ, . . . . .	252
124. Posterior common vertebral ligament, . . . . .	252
125. Horizontal section of an intervertebral disk, . . . . .	253
126. Vertical section of an intervertebral disk, . . . . .	253
127. Fibrous arrangement of exterior layers of the intervertebral disks, . . . . .	254
128. Diagram of an optical illusion caused by the arrangement indicated in fig. 127, . . . . .	254
129. Ligamenta subflava, . . . . .	255
130. Transverse ligament of the atlas, . . . . .	256
131. Ligaments of the atlas, axis, etc., posterior view, . . . . .	256
132. Ligaments of the atlas, axis, etc., anterior view, . . . . .	258
133. Posterior occipito-atloid, and atlo-axoid ligaments, . . . . .	258
134. Occipito-axoid ligament, . . . . .	258
135. Articulation of the lower jaw, external view, . . . . .	259
136. Articulation of the lower jaw, internal view, . . . . .	259
137. Articulation of the lower jaw, interior view, . . . . .	260
138. Posterior ligaments of vertebræ and ribs, . . . . .	261
139. Middle costo-transverse or interosseous ligament, . . . . .	261



140. Ligaments of the sterno-clavicular and costo-sternal articulations,	261
141. Ligaments of scapula and shoulder-joint,	264
142. Ligaments of fore-arm, front view,	267
143. Ligaments of fore-arm, posterior view,	267
144. Orbicular ligament of radius,	268
145. Fibro-cartilage connecting radius and ulna,	269
146. Diagram of disposition of synovial membranes of the wrist-joint,	271
147. Ligaments of pelvis and hip-joint,	275
148. Sacro-sciatic ligaments,	275
149. Ligaments of pelvis and hip-joint,	277
150. Ligaments of knee, anterior view,	280
151. Ligaments of knee, posterior view,	280
152. Knee-joint laid open,	281
153. Longitudinal section of knee-joint,	283
154. Anterior ligaments of the leg,	284
155. Ligaments of ankle-joint, posterior view,	285
156. Ligaments of sole of foot,	287
157. Fasciculi of muscle, magnified five diameters,	314
158, 159. Muscular fibres, magnified,	314, 315
160. Sarcolemma of muscular fibre,	316
161. Muscular fibrils of pig,	316
162. Muscular fibre broken up into disks,	317
163. Muscular fibre after maceration,	318
164, 165. Muscular fibre exhibiting nuclei,	319
166. Capillaries of muscle,	320
167. Loop-like termination of nerves in muscle,	321
168. Plain muscular fibres,	321
169. Development of muscular fibre,	324
170. Muscles of head and face,	332
171. Tensor tarsi muscle,	337
172. Muscles of the nasal region,	338
173. Two pterygoid muscles,	345
174. Muscles of the eyeball,	347
175. Anterior muscles of the neck,	351
176. Styloid muscles and muscles of the tongue,	355
177. Prævertebral group of muscles of the neck,	358
178. Side view of muscles of the pharynx,	362
179. Muscles of the pharynx and fauces,	365
180. Muscles of the back,	368
181. Deep muscles of the back,	375
182. Muscles of anterior aspect of trunk,	385
183. Anterior muscles of the arm,	391
184. Triceps muscle of the arm,	395
185. Superficial layer of muscles of the fore-arm, anterior aspect,	397
186. Tendons of the fingers,	399
187. Deep layer of muscles of the fore-arm, anterior aspect,	400
188. Superficial layer of muscles of the fore-arm, posterior aspect,	402
189. Deep layer of muscles of the fore-arm, posterior aspect,	406
190. Muscles of the hand,	408
191. Muscles of the hand, deep-seated,	410
192. Dorsal interosseous muscles of the hand,	411

193. Palmar interosseous muscles of the hand, . . . . .	411
194. Transversalis muscle of the abdomen, . . . . .	417
195. Diaphragm, . . . . .	423
196. Muscles of posterior femoral and gluteal region, . . . . .	430
197. Deep muscles of the gluteal region, . . . . .	431
198. Muscles of the anterior femoral region, . . . . .	436
199. Muscles of the anterior tibial region, . . . . .	445
200. Superficial muscles of the posterior aspect of the leg, . . . . .	450
201. Deep layers of muscles of the posterior tibial region, . . . . .	453
202. Superficial plantar muscles, . . . . .	457
203. Deep-seated plantar muscles, . . . . .	459
204. Third layer of plantar muscles, . . . . .	459
205. Dorsal interosseous muscles of the foot, . . . . .	461
206. Plantar interosseous muscles of the foot, . . . . .	461
207. Heart and lungs, . . . . .	471
208. Anterior aspect of the heart, . . . . .	472
209. Posterior aspect of the heart, . . . . .	472
210. Right auricle and ventricle of heart, laid open, . . . . .	474
211. Transverse section of the top of the ventricles, . . . . .	476
212. Left auricle and ventricle laid open, . . . . .	480
213. Sigmoid valves of the aorta, . . . . .	480
214. Muscular fasciculi of auricles, anterior view, . . . . .	483
215. Muscular fasciculi of auricles, posterior view, . . . . .	483
216. Muscular fibres of ventricles, . . . . .	484
217. Development of the heart of the chick, . . . . .	489
218. Development of heart of human embryo, . . . . .	489
219. Diagram of transformation of arterial bulb, &c., in mammalia, . . . . .	490
220. Heart of foetus of four months, front view, . . . . .	491
221. Heart of foetus of four months, back view, . . . . .	492
222. Heart of an infant five days old, . . . . .	492
223. Foetal circulation, . . . . .	493
224. Corpuscles of human blood, . . . . .	496
225. Corpuscles of frog's blood, . . . . .	496
226. Red corpuscles collected into rolls, . . . . .	498
227. Pale corpuscles of human blood, . . . . .	498
228. Arterial fenestrated membrane, . . . . .	514
229. Diagrams of valves of veins, . . . . .	519
230. Capillary circulation in frog's foot, . . . . .	520
231. Capillaries of muscular fibres, . . . . .	522
232. Capillaries of skin, . . . . .	522
233. Structure of a minute artery, . . . . .	522
234. Capillary vessels from pia mater, . . . . .	523
235. Capillary vessels of the tail of a young larval frog, . . . . .	525
236. Thoracic and abdominal aorta, . . . . .	527
237. Arch of the aorta, . . . . .	528
238. Carotids and their branches, . . . . .	536
239. Internal maxillary artery, . . . . .	547
240. Internal carotid artery, . . . . .	552
241. Branches of right subclavian artery, . . . . .	563
242. Branches of the axillary artery, . . . . .	575
243. Subscapular artery, . . . . .	576



244. Branches of the ulnar artery,	584
245. Abdominal aorta,	595
246. Cœliac artery or axis,	596
247. Branches of the cœliac axis,	598
248. Superior mesenteric artery,	599
249. Inferior mesenteric artery,	601
250. Internal iliac artery,	608
251. Branches of the pudic artery,	614
252. Course and branches of the femoral artery,	619
253. Popliteal and posterior tibial artery,	627
254. Arteries of the sole of the foot,	632
255. Anterior tibial artery,	634

# LIST OF ILLUSTRATIONS.

## VOL. II.

FIG.	PAGE.
256. Veins of head, face, and neck, . . . . .	6
257. Superficial veins of upper limb, . . . . .	11
258. Veins of thorax and abdomen, . . . . .	14
259, 260. Sinuses of dura mater, . . . . .	22, 24
261. Veins of lower extremity, . . . . .	25
262. Veins on back of leg, . . . . .	26
263. Portal system of veins, . . . . .	30
264. Lymphatic vessels of skin, . . . . .	38
265. Lymphatic gland, . . . . .	41
266. Thoracic duct, . . . . .	46
267. Superficial lymphatics of thigh, . . . . .	48
268. Superficial lymphatics of leg, . . . . .	48
269. Deep lymphatics of thigh, . . . . .	49
270. Deep lymphatics of leg, . . . . .	49
271. Lymphatics of groin, . . . . .	50
272. Lymphatics of abdomen, . . . . .	53
273. Superficial lymphatics of upper limb, . . . . .	56
274. Fragment of epithelium from peritoneum, . . . . .	60
275. Epithelium scales from inside of mouth, . . . . .	61
276. Epithelium from conjunctiva of the calf, . . . . .	62
277. Columns of epithelium from the intestine, . . . . .	62
278. Columns of epithelium from the intestine of rabbit, . . . . .	63
279. Cells from the liver, . . . . .	64
280. Columnar ciliated cells from the nose, . . . . .	66
281. Spheroidal ciliated cells from mouth of frog, . . . . .	66
282. Cells with pigmentum nigrum, . . . . .	69
283. Vertical section of cuticle from scrotum of negro, . . . . .	70
284. Cluster of fat cells, . . . . .	71
285. Blood-vessels of fat, . . . . .	72
286. Under surface of cuticle with depressions for papillæ, &c., . . . . .	84
287. Papillæ of the palm, . . . . .	87
288. Surface of skin of palm, showing ridges, furrows, &c., . . . . .	87
289. Cuticle and nail detached from the cutis and matrix, . . . . .	88



290. Sections of hair, . . . . .	89
291. Magnified view of root of hair and hair-follicle, . . . . .	90
292. Sebaceous glands, magnified, . . . . .	93
293. Sweat-gland and commencement of its duct, magnified, . . . . .	94
294. Vertical section of skin of sole of the foot, magnified, . . . . .	94
295. Plan of a secreting membrane, . . . . .	99
296. Plan to show increase of surface by formation of processes, . . . . .	100
297. Plans of extension of secreting membrane, by inversion, . . . . .	101
298. Groups of air-cells from an emphysematous lung, . . . . .	117
299. Diagrams of simple structure of lungs in reptiles, . . . . .	118
300, 301. Diagrams to show relation of air-cells to bronchioles, . . . . .	119
302. Capillaries of air-cells, . . . . .	120
303. Development of respiratory organs, . . . . .	122
304. Cartilages of larynx, separated, . . . . .	124
305. View of laryngeal pouch, . . . . .	130
306. View of membrana vocalis, . . . . .	131
307. Side view of larynx, . . . . .	133
308. Posterior view of larynx, . . . . .	134
309. Diagram of interior of larynx, . . . . .	135
310. Muscles of larynx, . . . . .	136
311. Tubular nerve-fibres, magnified, . . . . .	149
312. Nerve-tubes of the eel, magnified, . . . . .	151
313. Fibres from root of a spinal nerve . . . . .	152
314. Gelatinous nerve-fibres, . . . . .	152
315. Ganglionic nerve-cells, . . . . .	153
316. Caudated ganglionic cells, . . . . .	154
317. Cells from gray matter of brain, . . . . .	155
318. Vesicular and fibrous nervous matter from corpus dentatum, . . . . .	159
319. Section of gray substance of convolutions of cerebrum, . . . . .	159
320. Section of Gasserian ganglion, . . . . .	161
321. Nerve in its common cellular sheath, . . . . .	163
322. Pacinian corpuscles of finger, . . . . .	170
323, 324. Pacinian corpuscles from mesentery of cat, magnified, . . . . .	171
325. Development of nerve, . . . . .	183
326. Plans of spinal cord, . . . . .	192
327. Sections, transverse, of spinal cord, . . . . .	193
328. Lateral view of encephalon, . . . . .	196
329. Anterior view of medulla oblongata, &c., . . . . .	198
330. Posterior view of medulla oblongata, &c., . . . . .	198
331. Base of encephalon, . . . . .	208
332. Vertical section of encephalon, . . . . .	212
333. Section of cerebrum displaying lateral ventricles, . . . . .	214
334. Section of hippocampus major to show its arrangement of white and gray matter, . . . . .	217
335. Section of cerebrum with velum interpositum, &c., . . . . .	218
336. Section of cerebrum with corpora striata, &c., . . . . .	221
337. Inferior view of cerebellum, . . . . .	225
338. Analytical diagram of encephalon, . . . . .	231
339. Sections of medulla oblongata, . . . . .	232
340. Section of medulla oblongata, magnified, . . . . .	233

341. Fibres of medulla oblongata and pons, &c., . . . . .	234
342. Arrangement of columns of medulla, &c., . . . . .	236
343. Peduncular fibres of cerebrum, &c., . . . . .	237
344. Under surface of left hemisphere of cerebrum dissected, . . . . .	239
345. Dissection of fibres of gyrus fornicatus and of the fornix . . . . .	240
346. Olfactory ganglion and commissure, . . . . .	244
347. Olfactory commissure, . . . . .	244
348. Front view of crura cerebri, pons, medulla, &c., . . . . .	246
349. Early condition of nervous centres in embryo of the fowl, . . . . .	253
350. Development of brain and spinal cord in the human embryo, . . . . .	255
351. Deep nerves of the orbit, . . . . .	261
352. Nerves of the orbit, . . . . .	262
353. Distribution of the fifth nerve, . . . . .	263
354. Side view of nerves of orbit with lenticular ganglion, . . . . .	267
355. View of olfactory nerve and Meckel's ganglion, . . . . .	270
356. Inner view of otic ganglion, . . . . .	277
357. Nerves anastomosing with the facial in the temporal bone, . . . . .	280
358. Distribution of facial nerve and branches of cervical plexus, . . . . .	281
359. Tympanic nerve, . . . . .	284
360. Distribution of eighth pair of nerves of Willis, . . . . .	286
361. Diagram of ganglia and communications of divisions of the eighth pair . . . . .	287
362. Diagram of the trunk of the hypoglossal nerve, . . . . .	293
363. Plan of cutaneous nerves on the front of the arm, . . . . .	309
364. Plan of the nerves of the arm, . . . . .	311
365. Plan of cutaneous nerves of back of arm, . . . . .	315
366. Cutaneous nerves of chest and abdomen, . . . . .	318
367. Intercostal nerves, . . . . .	319
368. Lumbar plexus, . . . . .	321
369. Nerves from lumbar plexus to lower limb, . . . . .	325
370. Cutaneous nerves on front of thigh, . . . . .	326
371. Great and small sciatic nerves, . . . . .	333
372. Cutaneous nerves of back of leg, . . . . .	335
373. Cutaneous nerves of fore part of leg, . . . . .	338
374. Ganglia of sympathetic in the chest, . . . . .	346
375. Meibomian glands, on ocular surface of eyelids, . . . . .	359
376. Anterior view of lachrymal apparatus, . . . . .	361
377. Vasa vorticosa of the choroid . . . . .	364
378. Corpus ciliare, . . . . .	365
379. Arteries of the iris, . . . . .	367
380. Nerves of the iris, . . . . .	368
381. Structure of the retina, . . . . .	369
382. Plan in section of the structures in the fore part of the eye, . . . . .	370
383. Lens split into its constituent lamellæ, . . . . .	372
384. View of the left ear, . . . . .	374
385. Cartilage of ear with some of its muscles, . . . . .	376
386. Muscles on inner surface of pinna, . . . . .	376
387. Horizontal section of external meatus seen from above, . . . . .	377
388. Membrana tympani, . . . . .	378
389. Inner wall of tympanum, . . . . .	379
390. Inner wall of tympanum with Eustachian tube, &c., . . . . .	381



391. Malleus,	382
392. Incus,	382
393. Front view of stapes,	382
394. Base of stapes,	382
395. Ossicles of left ear articulated,	382
396. Contents of tympanum seen from above,	384
397. Labyrinth, magnified,	387
398. Labyrinth in outline, natural size,	387
399. Interior view of osseous labyrinth,	388
400. Osseous labyrinth of barn owl,	388
401. Diagram of form and structure of the dry cochlea,	389
402. Section of the cochlea,	389
403. Labyrinth laid open exposing the membranous labyrinth, &c.,	394
404. Membranous labyrinth with nerves and otoliths,	394
405. Section of cochlea with distribution of arteries and nerves,	395
406. Ampullæ and arrangement of nerves,	395
407. Bones and cartilages of the outer nose,	397
408. Front view of cartilages of nose,	397
409. Inferior view of cartilages of nose,	398
410. Septum of nose,	398
411. Vertical section of nasal fossæ,	400
412. Outer wall of the left nasal fossa with the pituitary membrane,	401
413. Distribution of olfactory nerve on septum,	402
414. Incisors of right side, superior and inferior,	407
415. Superior canine tooth,	407
416. Bicuspid tooth, superior and inferior,	407
417. First molar tooth of upper and lower jaw,	408
418. Temporary teeth,	410
419. Sections of incisor and molar teeth,	410
420. Diagram of section of a bicuspid tooth,	411
421. Section of dentine across the tubules, highly magnified,	411
422. Section of an imperfectly developed incisor,	414
423. Hexagonal structure of the enamel,	414
424. Fibres of enamel viewed sideways,	414
425. Enamel from tooth before its eruption,	415
426. Hexagonal prisms of enamel,	415
427. Enamel cells from an embryo canine tooth,	416
428. Enamel fibres from an embryo molar,	416
429. Enamel membrane,	416
430. Transverse section of enamel from an embryo tooth,	416
431. Diagrams representing the successive development of a tooth,	418
432. Upper jaw and palate of a foetus of fourteen weeks, magnified,	419
433. Mode of formation of a molar tooth with two fangs,	420
434. Section of the crown of a molar tooth, highly magnified,	422
435. Right and left half of lower jaw of a child at birth, exhibiting the tooth-sacs,	423
436. Diagram of left half of lower jaw of embryo of fourteen weeks, exhibiting the tooth follicles, magnified,	425
437. Relation between sac of milk and permanent tooth,	426
438. Position of a milk and permanent tooth in the lower jaw,	426



439. Part of lower maxilla of a child, containing all the milk teeth of the right side, &c., . . . . .	427
440. The tongue, with its papillæ, . . . . .	430
441. Various forms of compound papillæ, . . . . .	430
442. Simple papillæ near the base of the tongue, . . . . .	431
443. Various papillæ of the tongue, . . . . .	432
444. Median section of the nose, mouth, &c., . . . . .	435
445. Development of parotid gland in the sheep, . . . . .	440
446. Lobules of the parotid in the embryo of the sheep, . . . . .	440
447. Surface of the abdomen with regions indicated, . . . . .	444
448. Diagram of course of stomach and intestines, . . . . .	445
449. Diagram outline of stomach, . . . . .	447
450. Cells of the mucous membrane of the stomach, . . . . .	451
451. Perpendicular section of mucous membrane of stomach of pig, . . . . .	451
452. One of the tubuli from the stomach of the pig, . . . . .	451
453. Blood-vessels of intestinal villi, . . . . .	456
454. Epithelium of small intestine, . . . . .	457
455. Peyer's glands, enlarged view, . . . . .	458
456. Solitary gland, magnified, . . . . .	458
457. Solitary follicles, from large intestines, . . . . .	464
458. Tubuli and follicles of large intestine, . . . . .	464
459. Cæcum and ilio-cæcal valve, . . . . .	465
460. Muscles of perineal region, . . . . .	470
461. Under surface of the liver, . . . . .	477
462. Longitudinal section of an hepatic vein and lobules of the liver, . . . . .	480
463. Section of portal canal and portal vein, &c., . . . . .	481
464. Diagram of arrangement of blood-vessels in the lobules of the liver, . . . . .	483
465. Biliary plexus, . . . . .	485
466. Hepatic cells, . . . . .	485
467. Longitudinal section of human liver, &c., . . . . .	486
468. Transverse section of a lobule of the liver, . . . . .	486
469. Portion of biliary plexus, highly magnified, . . . . .	486
470. Portion of a biliary tube, highly magnified, . . . . .	486
471. Development of the liver in the chick, . . . . .	492
472. Under surface of foetal liver at birth, . . . . .	492
473. Liver, stomach, pancreas, &c., . . . . .	493
474. Diagram of the reflections of the peritoneum, . . . . .	504
475. Longitudinal section of the kidney, . . . . .	508
476. Portions of uriniferous tubes, magnified, . . . . .	512
477. Plan of renal circulation, . . . . .	512
478. Lateral view of viscera of male pelvis, . . . . .	518
479. Base of the male bladder, &c., . . . . .	520
480. Root of the penis and attachments, . . . . .	530
481. Transverse section of the penis, . . . . .	530
482. Erectile tissue of corpus cavernosum, . . . . .	532
483. Helicine artery, . . . . .	532
484. Posterior view of pubes, &c., . . . . .	539
485. Testicle, tunica vaginalis laid open, . . . . .	544
486. Transverse section of the testicle, . . . . .	547
487. Plan of a vertical section of the testicle, . . . . .	547
488. Testicle injected with mercury, . . . . .	549

489. Spermatozoa and their development, . . . . .	553
490. Lateral view of erectile structures of female organs of generation, . . . . .	555
491. Front view of erectile structures of female organs of generation, . . . . .	555
492. Anterior view of uterus and appendages, . . . . .	559
493. Posterior view of uterus and appendages, . . . . .	562
494. Graafian vesicle, seated in the ovary, and ovum of the sow, removed from Graafian vesicle, . . . . .	565
495. Genito-urinary organs of an embryo, . . . . .	567
496. Development of genito-urinary organs, . . . . .	570
497. Aponeurosis of external oblique muscle and fascia lata, . . . . .	579
498. View of spermatic cord escaping below the edge of the internal oblique, . . . . .	580
499. Transversalis muscle and fascia exposed to view, . . . . .	581
500. Plans of formations of tunica vaginalis testis, . . . . .	585
501. Posterior aspect of a portion of the wall of the abdomen and pelvis, . . . . .	587
502. Direct inguinal hernia, . . . . .	587
503. Small oblique and a direct inguinal hernia, . . . . .	588
504. Poupart's ligament, . . . . .	591
505. Femoral hernia, . . . . .	593
506. Deep femoral arch displayed, . . . . .	593
507. Dissection of superficial parts of perineum, . . . . .	599
508. Dissection of deeper parts of perineum, . . . . .	600
509. Pubic arch and attachment of perineal fascia, . . . . .	601
510. Pelvic viscera of the male, seen on the left side, . . . . .	602
511. Deep dissection of perineum, . . . . .	603



# ELEMENTS OF ANATOMY.

---

## INTRODUCTION.

THE material objects which exist in nature belong to two great divisions; those which are living or which have lived, and those which neither are nor have ever been endowed with life. The first division comprehends animals and plants, the other mineral substances.

In a living animal or plant changes take place and processes are carried on which are necessary for the maintenance of its living state, or for the fulfilment of the ends of its being; these are termed its functions, and certain of these functions being common to all living beings serve among other characters to distinguish them from inert or mineral substances. Such are the function of *nutrition*, by which living beings take extraneous matter into their bodies and convert it into their own substance, and the function of generation or *reproduction*, by which they give rise to new individuals of the same kind, and thus provide for the continuance of their species after their own limited existence shall have ceased.

But in order that such processes may be carried on, the body of a living being is constructed with a view to their accomplishment, and its several parts are adapted to the performance of determinate offices. Such a constitution of body is termed organization, and those natural objects which possess it are named *organized bodies*. Animals and plants, being so constituted, are organized bodies, while minerals, not possessing such a structure, are *inorganic*.

The object of anatomy, in its most extended sense, is to ascertain and make known the structure of organized bodies. But the science is divided according to its subjects; the investigation of the structure of plants forms a distinct study under the name of Vegetable Anatomy, and the anatomy of the lower animals is distinguished from that of man or human anatomy under the name of Comparative Anatomy.

On examining the structure of an organized body, we find that it is made up of members or organs, through means of which its functions are executed, such as the root, stem, and leaves of a plant, and the heart, brain, stomach, or limbs of an animal; and further, that these organs are themselves made up of certain constituent materials named tissues or textures, as the cellular, woody, and vascular tissues of the vegetable, or the osseous, muscular, filamentous, vascular, and various others, which form the animal organs.

Most of the textures occur in more than one organ, and some of



them indeed, as the cellular and vascular, in nearly all, so that a multitude of organs, and these greatly diversified, are constructed out of a small number of constituent tissues, just as many different words are formed by the varied combinations of a few letters; and parts of the body, differing widely in form, construction, and uses, may agree in the nature of their component materials. Again, as the same texture possesses the same essential characters in whatever organ or region it is found, it is obvious that the structure and properties of each tissue may be made the subject of investigation apart from the organs into whose formation it enters.

These considerations naturally point out to the Anatomist a twofold line of study, and have led to the subdivision of Anatomy into two branches, the one of which treats of the nature and general properties of the component textures of the body; the other treats of its several organs, members, and regions, describing the outward form and internal structure of the parts, their relative situation and mutual connexion, and the successive conditions which they present in the progress of their formation or development. The former is usually named "General" Anatomy, the latter "Special" or "Descriptive" Anatomy.<sup>1</sup>

<sup>1</sup> These names have been objected to, and the terms Histology (*ἵστος*, a web, and *λόγος*, a discourse,) and Morphology (*μορφή*, form, &c.) themselves not free from objection, have been proposed in their stead; there seems no sufficient reason for the substitution; the latter term, indeed, is often used in a different sense.

## GENERAL CONSIDERATIONS

ON THE

## TEXTURES.

---

THE human body consists of solids and fluids. Only the solid parts can be reckoned as textures, properly so called; still there being some of the fluids, viz. the blood, chyle, and lymph, which contain in suspension solid organized corpuscles of determinate form and organic properties, and which are not mere products or secretions of a particular organ, or confined to a particular part, the corpuscles of these fluids, though not coherent textures, are nevertheless to be looked upon as organized constituents of the body, and as such may not improperly be considered along with the solid tissues. In conformity with this view the textures and other organized constituents of the frame may be enumerated as follows:—

The blood, chyle, and lymph.

Epidermic tissue, including epithelium, cuticle, nails, and hairs.

Pigment.

Nervous tissue.

Adipose tissue.

Blood-vessels.

Cellular tissue.

Absorbent vessels and glands.

Fibrous tissue.

Serous and synovial membranes.

Elastic tissue.

Mucous membranes.

Cartilage and its varieties.

Skin.

Bone or osseous tissue.

Secreting glands.

Muscular tissue.

Every texture taken as a whole was viewed by Bichat as constituting a peculiar system in the body, presenting throughout its whole extent characters either the same, or modified only so far as its local connexions and uses rendered necessary; he accordingly used the term "organic systems" to designate the textures taken in this point of view, and the term has been very generally employed by succeeding writers. Of the tissues or organic systems enumerated, some are found in nearly every organ; such is the case with the filamentous, which serves as a connecting material to unite together the other tissues which go to form an organ; the vessels, which convey fluids for the nutrition of the other textures, and the nerves, which establish a mutual dependence among different organs, imparting to them sensibility, and governing their movements. These were named by Bichat the "general systems." Others again, as the cartilaginous and osseous, being confined to a limited number, or to a particular class of



organs, he named "particular systems." Lastly, there are some tissues of such limited occurrence that it has appeared more convenient to leave them out of the general enumeration altogether, and to defer the consideration of them until the particular organs in which they are found come to be treated of. Accordingly the tissues peculiar to the crystalline lens, the spleen, the suprarenal bodies, the enamel of the teeth, and some other parts, though equally independent textures with those above enumerated, are for the reason assigned not to be described in this part of the work.

It is further to be observed, that the tissues above enumerated are by no means to be regarded as simple structural elements; on the contrary, many of them are complex in constitution, being made up of several more simple tissues. The blood-vessels, for instance, are composed of several coats of different structure, and some of these coats consist of more than one tissue. They are, strictly speaking, rather organs than textures; and indeed it may be remarked, that the distinction between textures and organs has not in general been strictly attended to by anatomists. The same remark applies to mucous membrane and the tissue of the glands, which structures, as commonly understood, are highly complex. Were we to separate every tissue into the simplest parts which possessed assignable form, we should resolve the whole into a very few constructive elements, and, having regard to form merely, and not to difference of chemical constitution, we might reduce these elements to the following, viz. 1, *simple fibre*, 2, *homogeneous membrane*, either spread out or forming the walls of *cells*, and 3, *globules* or *granules*, varying in diameter from the  $\frac{1}{2000}$  to the  $\frac{1}{8000}$  of an inch. These, with a quantity of *amorphous matter*, homogeneous or molecular, might be said, by their varied combinations, to make up the different kinds of structure which we recognise in the tissues; and if we take into account that the chemical nature of these formative elements and of the amorphous matter may vary, it will be readily conceived that extremely diversified combinations may be produced.

#### PHYSICAL PROPERTIES.

The physical properties of the tissues, such as consistency, density, colour, and the like, which they possess in common with other forms of matter, require no general explanation. An exception must be made however in regard to the property of imbibing fluids, and of permitting fluids to pass through their substance, which is essentially connected with some of the most important phenomena that occur in the living body, and seems indeed to be indispensable for the maintenance and manifestation of life.

All the soft tissues contain water, some of them more than four-fifths of their weight; this they lose by drying, and with it their softness and flexibility, shrinking up into smaller bulk and becoming hard, brittle, and transparent; but when the dried tissue is placed in contact with water, it greedily imbibes it again, and recovers its former size, weight, and mechanical properties. The imbibed water is no doubt partly contained mechanically in the interstices of the tissue, and retained there by capillary attraction, like water in moist sandstone or other inorganic porous substances; but it has been questioned whether the essential part of the



process of imbibition by an animal tissue is to be ascribed to mere porosity, for the fluid is not merely lodged between the fibres or laminæ, or in the cavities of the texture; a part, probably the chief part, is incorporated with the matter which forms the tissue, and is in a state of union with it, which is supposed to be more intimate than could well be ascribed to the mere inclusion of a fluid in the pores of another substance. Be this as it may, it is clear that the tissues, even in their inmost substance, are permeable to fluids, and this property is indeed necessary, not only to maintain their due softness, pliancy, elasticity, and other mechanical qualities, but also to allow matters to be conveyed into and out of their substance in the process of nutrition.

The tissues being permeable, we may next consider how fluids may be made to pass through them. This may be effected, 1. by the force of pressure, which again may be produced in various ways, easy to be understood. 2. It can be shown by experiment, that water imbibed by a tissue is given out from it again when the tissue is exposed to some substance with which the water has a tendency to mix or to combine, as for example, alcohol or salt, or a strong solution of salt; and if the experiment be so arranged that one surface of the tissue, say a piece of bladder, is kept in contact with water and the other with the alcohol or solution of salt, the water will be imbibed by the tissue at the one surface, and given off to the alcohol or saline solution at the other, and thus pass through in a continued current. In many cases of this kind both fluids pass through the membrane, and, of course, in opposite directions, the water to the salt and the saline solution to the water; and the interchange continues till the two fluids are thoroughly mixed, or until the solution acquires a uniform strength on both sides of the membrane. In such cases, however, it usually happens that one of the fluids is imbibed more readily by the tissue than the other, and is transmitted through it more rapidly, so that a greater quantity of fluid accumulates on one side of the membrane. In the case supposed, the water is imbibed, and transmitted more rapidly, than the saline solution; hence if the solution be contained in a tube closed at the bottom with bladder, and placed in a vessel of water, the level of the fluid within the tube will rise from the water entering more rapidly than the solution issues. Of course, if the relative position of the two fluids were reversed, the bulk of the fluid in the tube would diminish for the same reason as before, and its level sink. The same effect is shown very clearly by inclosing a solution of salt, sugar, or gum in a piece of gut or small bladder, and immersing it in water; the bladder soon becomes distended, but when the water is put inside and the solution without, the bladder becomes flaccid; the water in both cases being more readily imbibed and transmitted by the animal tissue than the solution. The terms *endosmosis* and *exosmosis* have been employed to express these phenomena, the former denoting the greater, the latter the lesser, or weaker current, terms which, though in general use, are unquestionably ill chosen, seeing that their etymological import has led many to apply them to the entering and issuing current respectively, in experiments like the foregoing; a distinction which is quite unessential, for it is plain that the same kind of current may cause the entrance of fluid into a receptacle in one case, and its issue in another.

Water being imbibed by animal textures with more avidity than other fluids, it may be stated, as a general rule, that when water and a fluid of a different kind, with which it tends to combine or mix, are placed on opposite sides of an interposed animal membrane, the preponderating current will be from the water to the other fluid. This is the case, as has been already stated, with water and alcohol, or solutions of salt, or solutions of organic matters, such as gum, sugar, and albumen. Further, when a weaker and a stronger solution of the same substance are exposed to one another, the greater current will be from the weaker solution to the more concentrated. Dutrochet has however observed a remarkable and hitherto unexplained deviation from the above rule in the case of water and acids, especially the oxalic and some other vegetable acids. Lastly, the observer just named has found that solutions of different kinds of matter, though of the same density, differ in their power of producing endosmosis; thus, equally dense solutions of the following substances produced currents of water proportionate to the numbers given, viz., albumen 12, sugar 11, gum 5·17, gelatin 3.<sup>1</sup>

<sup>1</sup> See Cyclopædia of Anat. and Phys., art. Endosmosis.



Phenomena illustrative of the truths now stated present themselves in many of the processes which occur naturally in the animal economy.

The animal tissues are also permeable to aeriform fluids. It is well known that the air in respiration produces changes in the blood, although the membranous coats of the blood-vessels are interposed between the two fluids; and if a bladder distended with carbonic acid be exposed to air, it will become flaccid from the escape of the contained gas. In such cases, however, the aeriform fluid does not pass through the moist membrane in its actual state of gas; it is first liquefied by the water in the soft tissue, and thus penetrates the tissue as a liquid; on reaching the opposite surface, it mixes with the blood in the one case, and in the other rapidly evaporates into the air, the tendency of the carbonic acid and air to diffuse into each other, a property they possess in common with other gases, greatly favouring the result. For further information on this interesting phenomenon, see Graham's Chemistry, p. 76.

#### CHEMICAL COMPOSITION.

The human body is capable of being resolved by ultimate analysis into chemical elements, or simple constituents, not differing in nature from those which compose mineral substances. Of the chemical elements known to exist in nature the following have been discovered in the human body, though it must be remarked that those at the bottom of the list occur only in exceedingly minute quantity: oxygen, hydrogen, carbon, nitrogen, phosphorus, sulphur, chlorine, fluorine, potassium, sodium, calcium, magnesium, iron, silicon, manganese, aluminium, copper.

These ultimate elements do not directly form the textures or fluids of the body; they first combine to form certain compounds, and these appear as the more immediate constituents of the animal substance; at least the animal tissue or fluid yields these compounds, and they in their turn are decomposed into the ultimate elements. Of the immediate constituents some are found also in the mineral kingdom, as for example, water, chloride of sodium or common salt, and carbonate of lime; others, such as albumen, fibrine, and fat are peculiar to organic bodies, and are accordingly named the proximate organic principles.

The animal proximate principles have the following leading characters. They all contain carbon, oxygen, and hydrogen, and the greater number also nitrogen; they are all decomposed by a red heat; and, excepting the fatty and acid principles, they are, for the most part, extremely prone to putrefaction, or spontaneous decomposition, at least, when in a moist state; the chief products to which their putrefaction gives rise being water, carbonic acid, ammonia, and sulphuretted, phosphuretted, and carburetted hydrogen gases. The immediate compounds found in the solids and fluids of the human body are the following:

I. *Azotized substances*, or such as contain nitrogen, viz., albumen, fibrin, casein, gelatin, chondrin, extractive soluble in alcohol, extractive soluble in water, salivin, kreatin, pepsin, globulin, mucus, horny matter or keratin, pigment, hæmatin, pyin, urea, uric acid, azotized biliary compounds.

II. *Substances destitute of nitrogen*, viz., fatty matters, (except cerebri acid,) sugar of milk, lactic acid, certain principles of the bile.

Some of the substances now enumerated require no further notice in a work devoted to anatomy. Of the rest, the greater number will be explained, as far as



may be necessary for our purpose, in treating of the particular solids or fluids in which they principally occur; but there are a few of more general occurrence, which it will be advisable to give some account of here; these are, albumen, fibrin, casein, gelatin, chondrin, extractive, and fatty matters

#### ALBUMINOID OR PROTEIN COMPOUNDS.

Albumen and fibrin, with casein, globulin, and perhaps some others, such as horny matter, belong to a group of compounds, which have been supposed to consist essentially of one and the same fundamental substance united with varying proportions of sulphur, phosphorus, salts, or other inorganic bodies. This common principle has been named Protein. In some of these instances, as albumen and casein, the protein comprehends the whole carbon, hydrogen, nitrogen, and oxygen of the compound; the proportions of these elements are therefore the same in each, and the substances are identical in essential composition, though they may differ in some of their properties. In other compounds, yielding protein, the proportion of the above-mentioned elements is not the same as in that substance; and in such cases it has been supposed, that some other organic substance is associated with protein, or the compound has been represented as consisting of protein with the addition of oxygen, the elements of water, or the elements of ammonia, or with some similar modification calculated to reconcile the supposed protein constitution with the actual analysis. The most general characteristic mark of these protein or albuminoid compounds is, that they are soluble in acids, and precipitated from their acid solutions by the ferro and ferricyanide of potassium (the yellow and the red prussiates of potash).

*Albumen* exists very extensively in the body, forming the chief ingredient of the serum of the blood, chyle, and lymph, and of the serous fluid which penetrates and moistens nearly all the tissues; it enters largely also into the composition of the brain and nerves. The white of eggs consists of liquid albumen.

In the albuminous liquids mentioned, which are all, more or less, alkaline from contained soda, the albumen is dissolved in water, but it may be obtained in a solid state by evaporation at a temperature of  $120^{\circ}$ , and successive washing of the dry residue with ether and alcohol, to remove foreign matters. Solid albumen thus obtained is soluble in water. In the liquid or dissolved state it is coagulated by a heat of  $158^{\circ}$ ; but if its solution is much diluted, a boiling heat is required. Albumen is also coagulated, and its solutions rendered turbid by alcohol, creosote, most acids, the acetic, phosphoric, and pyrophosphoric, being notable exceptions, and by many metallic salts; also by the voltaic pile, which acts by decomposing salt in the albuminous solution. Ether coagulates the white of eggs, but not the serum of the blood.

In its coagulated state albumen is insoluble in water; it is freely dissolved by caustic alkali. When exposed to an acid extremely diluted with water it is dissolved; by increasing the proportion of acid the albumen is precipitated, but this precipitate is again dissolved, if the acid be still more concentrated and heat applied. The solution in strong hydrochloric acid acquires a purple and then a blue colour. When dissolved in diluted acetic acid it is not precipitated by adding that acid in excess, and the tartaric, phosphoric, and pyrophosphoric acids, agree in this respect with the acetic. The acid solutions of albumen are precipitated by the feroprussiates of potash.

Albumen unites with alkalies and metallic oxides, forming albuminates. The albuminates of the alkalies are soluble in water, those of the oxides in an excess of albumen. Metallic salts, as already stated, cause a precipitate in watery solutions of albumen, and none in a more marked manner than corrosive sublimate, which causes a milkiness in a solution containing no more than  $\frac{1}{5000}$ th part of albumen, and serves therefore as one of its most delicate tests. These precipitates appear not to be all of a similar constitution, some of them being compounds of albumen and the metallic salt; while in others the albumen is supposed to combine independently with the acid and with the base, and the precipitate accordingly to consist of albuminate of the acid and albuminate of the oxide. Whatever their constitution, the precipitates in question, not excepting that from corrosive sublimate, are soluble in an excess of albumen. Phosphate of lime is readily dissolved by liquid albumen, and a certain portion of that salt naturally



exists in the albumen of the egg, and in the albuminous fluids of the human body; a fact of no small importance in a physiological point of view.

Albumen consists of *protein*, combined or associated with a small proportion of sulphur and phosphorus. To obtain the protein, albumen is dissolved in a solution of caustic potash, and heated to  $120^{\circ}$ ; by this means the sulphur and phosphorus are converted into sulphuret of potassium and phosphate of potash; the alkaline solution is then to be saturated with acetic acid, and the protein separates as a gelatinous, grayish, semitransparent precipitate, which when washed and dried appears as a yellowish, hard, easily pulverized, and tasteless substance. According to the latest analysis, that of M. Dumas, the following is the composition of protein.

	From actual Analysis.	Calculated by Atoms.
Carbon . . . . .	54.38	54.44 — $C_{48}$
Hydrogen . . . . .	7.14	6.99 — $H_{37}$
Nitrogen . . . . .	15.92	15.88 — $N_6$
Oxygen . . . . .	22.56	22.69 — $O_{15}$
	100.—	100.—

Liebig's formula is  $C_{48}, H_{36}, N_6, O_{14}$ . These numbers will of course also represent the proportions of the respective elements contained in albumen; but the proportion of sulphur differs in the albumen of eggs and that of the serum of the blood. According to Mulder, the albumen of eggs consists of ten atoms of protein with one of sulphur, and half an equivalent of phosphorus, and is accordingly represented by the formula,  $10 \text{ Pr} + \text{SP}_{\frac{1}{2}}$ . The albumen of serum contains twice the amount of sulphur, and its formula is therefore  $10 \text{ Pr} + \text{S}_2 \text{ P}_{\frac{1}{2}}$ . Protein is insoluble in water and in alcohol; its solubility in acids follows the same law as that of albumen, and, like albumen, it is precipitated from its acid solutions by the ferropussiates of potash. With concentrated acids it forms new compound acids.

*Fibrin* exists in two states, liquid and coagulated. In the former condition it is found in the blood, and in its concrete state it may be obtained from muscle, of which it forms the basis.

The most characteristic property of liquid fibrin is its tendency to coagulate spontaneously, or at least independently of any apparent extrinsic cause; the coagulation of the blood itself, in fact, is owing to this property of the fibrin contained in it. Hence the difficulty of procuring fibrin in a liquid state, and indeed it has never been obtained pure in this condition. The fibrin and serum of the blood together constitute its colourless part or liquor sanguinis; this fluid, in certain states of the body, separates from the red particles before coagulation, and may be obtained by itself; or, if blood be diluted with serum the instant it is drawn, it may be filtered before coagulation, and the diluted liquor sanguinis, containing the liquid fibrin, is obtained free from the red particles, which remain on the filter. In both cases, however, the fibrin quickly solidifies and separates in a concrete form from the serum, and the same happens with fibrinous fluids, resembling the liquor sanguinis, occasionally found effused into cavities within the body.

Coagulated fibrin may be procured by stirring fresh-drawn blood with a bundle of twigs, the solidifying fibrin is thus entangled and removed. When well washed, it then appears as a white, soft, stringy, somewhat elastic, substance, without taste or smell, which, by drying, loses about three-fourths of its weight, and becomes hard and brittle. The appearance of coagulated fibrin under the microscope will be afterwards noticed.

Coagulated fibrin is insoluble in water, alcohol, and ether; but by long boiling in water, especially under pressure, it is dissolved, being however at the same time altered in nature. Like albumen, it is soluble in caustic alkalies, and combines with them, neutralizing their alkaline properties. It also combines with acids in different proportions, its neutral combinations being soluble in water, but precipitated by the addition of an excess of acid. Strong acetic acid is rapidly imbibed by it, and causes it to swell up into a transparent colourless jelly, which is soluble in hot water. This solution is precipitated by adding another acid, but not by acetic acid. The acid solutions of fibrin, like those of albumen, are precipitated by the prussiates of potash.



Many neutral salts, when added to the blood, prevent its coagulation by preventing the coagulation of its fibrin; and some of them, as nitre for example, may, with certain precautions, be made to dissolve freshly coagulated fibrin. Corrosive sublimate and the persalts of iron combine with moist fibrin, giving it increased firmness, and obviating its tendency to putrefy.

Moist coagulated fibrin decomposes binoxide of hydrogen, liberating oxygen, and reducing the binoxide to water, without itself undergoing any change. This property belongs to many organic substances which contain no fibrin, but it happens not to be possessed by coagulated albumen, which in most other respects so much resembles coagulated fibrin. The property just mentioned, and that of forming a jelly with acetic acid, are the most striking points of difference between the two substances.

Fibrin was considered by Mulder as identical in composition with albumen of eggs, the formula he assigned for it being accordingly  $10 \text{ Pr} + \text{SP}\frac{1}{2}$ ; and in this view he has been followed by most other chemists. Dumas, however, after a very laborious experimental inquiry by M. Cahours and himself, has assigned to it a different composition; in the fibrin of human blood he found 52.78 of carbon 6.96 of hydrogen, 16.78 of nitrogen, and 23.48 of oxygen; therefore, more nitrogen and less carbon than in protein or albumen. He states that, by long boiling in water, it yields a little ammonia and a peculiar soluble product, while the fibrin that remains undissolved is altered in nature, having become identical in composition with albumen; he therefore supposes that fibrin contains protein along with another substance. Fibrin yields on incineration about  $\frac{2}{3}$  per cent. of ashes, which consist principally of phosphate of lime, with a little phosphate of magnesia, and sometimes traces of silica.

*Casein* is an albuminoid or protein compound, agreeing with albumen in constitution and in most of its properties. It is a well-known ingredient of milk; it exists also in smaller proportion in the pancreatic juice and some other secretions, and in the blood.

The most remarkable property of casein is that of being coagulated by rennet. Its solution is precipitated by acids, not excepting the acetic, and in this last circumstance it differs from albumen. The precipitates may be freed from acid, purified and redissolved in water, by which means pure casein may be obtained. In this condition it is soluble in water, and, to a small extent, in alcohol. Coagulated casein, on the other hand is insoluble, or only very sparingly soluble. The acids combine with it, both in its liquid and coagulated state, its combinations closely resembling those of albumen, and it is precipitated from its acid solutions by ferroprussiate of potash. Like albumen, also, it forms soluble combinations with alkalies, and unites with alkaline earths; and the same earthy and metallic salts which precipitate liquid albumen likewise precipitate casein. Milk, or a concentrated solution of casein, is also precipitated by alcohol. When heated in an open vessel it becomes covered by an insoluble pellicle, which is ascribed to the formation of lactic acid by oxidation, and is said not to occur when milk is heated in carbonic acid.

Casein yields on incineration 6 per cent. of phosphate of lime, and  $\frac{1}{2}$  per cent. of lime or its carbonate. It contains a little sulphur, but no phosphorus in chemical combination. Its basis is protein, and it may be represented as composed of 10 atoms of protein and one atom of sulphur.

#### GELATINOUS COMPOUNDS.

Many of the solid parts of the body are, by long boiling in water, entirely or in great part reduced into a soluble substance, which has the remarkable property of forming a jelly with the water as it cools; and two distinct kinds of this substance have been recognised, which differ in a marked manner in many of their chemical characters, as well as in the sources from which they are derived. The one has been long known under the name of "gelatin," the other, being principally obtained from cartilages, has accordingly been named "chondrin." Neither kind of the gelatinizing substance is found in any of the animal fluids, nor, according to the view entertained by Berzelius, does it exist ready formed in the tissues which yield it; he conceives that these tissues are converted into gelatinous substance by the prolonged action of boiling water, somewhat in the same



manner as starch may be changed into gum and sugar, and the analogy is strengthened by the fact, that in both cases the process is accelerated by the presence of a dilute acid.

*Gelatin*, strictly so called, is obtained from the cellular and fibrous tissue, skin, serous membrane, and the animal basis of bone. The jelly derived from these tissues yields the dry gelatin in form of a hard transparent substance, which, when pure, is without colour, taste, or smell. It softens but does not dissolve in cold water; a gentle heat is, however, sufficient to effect its solution in water, and, as already stated, the solution, unless too much diluted, forms a jelly when cold. It is insoluble in ether, and very nearly insoluble in alcohol. With the aid of heat, it readily dissolves in acetic and diluted mineral acids.

A solution of gelatin in water is precipitated by alcohol, creosote, and corrosive sublimate; but its most effectual precipitant is tannic acid, or a strong infusion of gall-nuts, which throws down gelatin, when dissolved even in 5000 times its weight of water; the precipitate, which has been named *tanno-gelatin*, is dissolved by adding a fresh quantity of gelatin. It is not precipitated by mineral acids, acetic acid, alum, sulphate of alumina, acetate and subacetate of lead, all which occasion a precipitate in a solution of chondrin; nor is gelatin thrown down from any of its solutions by the prussiates of potash, in which respect it differs from the albuminoid compounds. Gelatin combines with several salts; it readily dissolves freshly precipitated phosphate of lime, and it naturally contains about  $\frac{1}{2}$  per cent. of this salt, as appears by incineration.

The composition of gelatin may be represented by the formula,  $C_{48}, H_{11}, N_{7\frac{1}{2}}, O_{18}$ , founded on an analysis of gelatin and of some of the tissues yielding it by Scherer. This formula gives the following proportions per cent.:—viz., carbon, 50.207, hydrogen, 7.001, nitrogen, 18.170, oxygen, 24.622. Hence it appears, that gelatin contains proportionally less carbon and more oxygen and nitrogen than are contained in albumen.

*Chondrin* was first pointed out as a distinct substance by Müller. It is obtained from permanent cartilages, and the cartilage of bone before ossification, and from the cornea of the eye, by boiling these tissues for a long time in water. In its relations to water chondrin resembles gelatin, but the jelly it forms is not so firm. Like gelatin, also, it is thrown down from its solutions by tannic acid, alcohol, ether, creosote, and corrosive sublimate, and not by prussiate of potash. It differs from gelatin in being precipitated by the mineral and other acids, the acetic not excepted, also by alum, sulphate of alumina, persulphate of iron, and acetate of lead; the precipitates being soluble in an excess of the respective precipitants. According to Mulder, 100 parts of chondrin yield 40.96 of carbon, 6.63 of hydrogen, 14.44 of nitrogen, 28.59 of oxygen, and 0.38 of sulphur. Liebig gives the following formula from Scherer's analysis:  $C_{48}, H_{40}, N_6, O_{20}$ .

#### EXTRACTIVE MATTERS.

Serum of blood and several other animal fluids, on being freed from albuminous ingredients by heat or some other suitable means, and evaporated, yield a substance known under the name of animal extractive matter, usually mixed with fatty matters, from which it is to be separated by solution in water and subsequent evaporation. The same kind of substance may be extracted from many of the solid tissues, especially muscle, by macerating them in cold water, boiling the liquid to free it from albumen, and proceeding as before. The matter obtained from these different sources is associated with free lactic acid and several salts, especially the lactates of soda, lime, and magnesia, lactate of ammonia in minute quantity, the chlorides of sodium and potassium, phosphate of soda and phosphate of lime; moreover, the animal substance itself is separable into several different compounds, but even if the characters of these compounds were better defined than they are, it would here be out of place to enter into detail respecting them individually; it will be sufficient to point out the differences between the two principal classes of them.

1. *Extractive matters soluble in water only.*—While all are soluble in water, the substances included under the present head are insoluble in pure alcohol and rectified spirit; they are accordingly left undissolved after treating the mass with spirit of wine of specific gravity .833, and along with them there remain the



phosphates of soda and lime, with a portion of free lactic acid, rendered difficultly soluble in alcohol by its connexion with the animal matter. Of this group of extractive principles, one of the most important is a substance which has been named *zomidin*, from its being supposed to be the cause of the peculiar taste of boiled or roasted meat.

2. *Extractive matters soluble in rectified spirit*.—By evaporating the spirit employed in the preceding operation there is obtained, along with the chlorides of sodium and potassium, and the greater part of the lactic acid and lactates, a yellowish brown matter, which was named *osmazome*, because the characteristic odour of soup seems to be owing to it. Berzelius has, however, shown that this matter may be further subdivided, by means of anhydrous alcohol, into an extractive substance, which is soluble in that menstruum, and another which is not; the lactic acid and lactates being shared between the two; for though the acids and salts in question are naturally soluble in pure alcohol, a certain portion pertinaciously abides by the insoluble organic substance. Finally, the two matters thus separated from each other by pure alcohol, are themselves mixtures of two or more principles, which show different reactions with corrosive sublimate, subacetate of lead, tannin, &c.

The extractive compounds obtained from a tissue are supposed to be contained in the fluids which penetrate the solid substance, and Berzelius has suggested that these matters, as well as the lactic acid, lactates, and other salts, which seem invariably to accompany them, are the product of the continual change or waste of the tissues, especially of the muscular substance, which naturally takes place in the economy, and that they are destined to be separated from the tissue, and afterwards eliminated from the blood by the excretions; a view which, as he states, is strengthened by the fact, that principles of the same kind are found in the urine.

#### FATTY MATTERS.

The substances of this class which are found in the human body, possess the following general characters: They are lighter than water, fusible at a moderate heat, insoluble in water, and soluble in ether and in boiling alcohol. They are divided into the proper fats, or such as are capable of forming a soap with alkalis and oxides, and those which are not saponifiable.

#### SAPONIFIABLE FATS.

The common fat of the human body may be represented as a mixture of a solid fatty substance, named "*margarin*," and a liquid oily substance, "*olein*;" the suet or fat of oxen and sheep, on the other hand, consists chiefly of a second solid principle, "*stearin*," associated with olein. These three substances, *margarin*, *stearin*, and *olein*, are themselves compounds of a base, named "*glycerine*," with three different fatty acids, the *margaric*, *stearic*, and *oleic*. In the saponification of fat these acids combine with the alkali or oxide employed, and the *glycerine* is set free.

*Glycerine*.—The common base of the above-mentioned compounds, is obtained separately as a liquid of syrupy consistence, and remarkably sweet taste, from which circumstance it has received its name. It is supposed to be an oxide of a hypothetical radical "*glyceryl*," which again is composed of  $C_6, H_7$ , this, combined with 5 atoms of oxygen, forms an oxide, and the oxide of *glyceryl*, in separating from the acids with which it is naturally combined in fat, unites with one atom of water to form *glycerine*, so that *glycerine* is, strictly speaking, a hydrated oxide of *glyceryl*, and has the formula,  $C_6, H_7, O_5 + HO$ .

*Margaric and stearic acids*.—These acids are both obtained as solid crystalline substances, soluble in ether and in boiling alcohol, and fusible, the *margaric* being more fusible than the *stearic*. They combine with bases, but, having weak acid properties, are separated from their combinations by most other acids. They are both compounds of a radical "*margaryl*,"  $C_{31}, H_{33}$ , with different proportions of oxygen, and, in their uncombined state, are obtained as hydrates. One atom of *margaryl*, with three of oxygen, and one of water, form *margaric* or "*margaryllic*" acid,  $C_{31}, H_{33}, O_3 + HO$ ; and two atoms of *margaryl*, with five of oxygen, and



two of water,  $2(C_{31}H_{61})O_2 + 2HO$ , form stearic acid, which is, therefore, "hypomargarylic," acid. The combined water quits them when they unite with bases. *Stearin*, or the acid stearate of glycerine, is soluble in alcohol and ether, and separates from its solutions in crystalline plates; but, on being fused and cooled, it appears as a white, waxy-like, pulverisable substance, which is not crystalline. *Margarin*, or margarate of glycerine, in most of its properties, resembles stearin, but it is more fusible and more soluble in ether and alcohol.

*Oleic acid* is an oily liquid, possessing very distinctly acid properties. It solidifies into a crystalline mass a few degrees above the freezing point of water. Its formula is  $C_{18}H_{33}O_2$ . *Olein*, the oleate of glycerine is also a liquid substance at ordinary temperatures, insoluble in water, but easily soluble in ether and in alcohol. It is the chief constituent of the fat oils, and of most solid fats found in nature; with margarin it forms the human fat.

*Cerebric acid*.—From the researches of Fremy, it appears that the chief constituent of the fat found in the brain is a compound of soda, with a peculiar acid, the "cerebric," which also exists in a free state. The cerebric acid differs from other fatty principles as yet known in containing nitrogen; 100 parts of it consist of carbon 66.7, hydrogen 10.6, nitrogen 2.3, oxygen 19.5, and phosphorus 0.9.

#### UNSAPONIFIABLE FATTY MATTERS.

*Cholesterin* is a solid, white, crystalline substance, which may be obtained in small quantity from the blood, the bile, and the substance of the brain and nerves. It is found much more abundantly in many morbid products, dissolved, swimming in fluid in form of crystalline scales, or forming solid concretions, as in biliary calculi, the most common species of which are formed of cholesterin, tinged with the colouring principles of the bile. Cholesterin fuses at  $278^\circ$ ; it is soluble in ether, sparingly soluble in cold, but abundantly so in boiling alcohol. It possesses no acid properties, and is not acted on by alkalies; by nitric acid it is converted into cholesteric acid. The formula of cholesterin is  $C_{27}H_{52}O$ .

*Serolin*.—When blood is dried, deprived of matter soluble in boiling water, and repeatedly treated with boiling alcohol, a small quantity of a fatty substance thus named is obtained, which separates from the alcohol on cooling, as a shining flocculent mass. It possesses neither acid nor alkaline properties, fuses at  $97^\circ$ , is readily soluble in ether, sparingly so in boiling alcohol, and quite insoluble in cold alcohol.

#### SUMMARY OF THE LEADING CHARACTERS OF THE FOREGOING SUBSTANCES.

A. *Albuminoid principles*, albumen, fibrin, and casein. Coagulable, fibrin spontaneously, albumen by heat, casein by rennet. Precipitated by mineral acids, tannic acid, alcohol, corrosive sublimate, subacetate of lead, and several other metallic salts. *When coagulated*, not soluble in water, cold or hot, unless after being altered by long boiling; insoluble in alcohol; soluble in alkalies; soluble in very dilute and also in concentrated acids; the solutions precipitated by red and yellow prussiates of potash.

B. *Gelatinous principles*, gelatin and chondrin. Not dissolved by cold water; easily soluble in hot water, the solution gelatinizing when cold. Precipitated by tannic acid, alcohol, ether, and corrosive sublimate, and not by the prussiates of potash. *Chondrin*, precipitated by acids, alum, sulphate of alumina, and acetate of lead, which do not precipitate gelatin.

C. *Extractive matters*, associated with lactic acid and lactates. All soluble in water, both cold and hot; some in water only, some in water and rectified spirit; some in water, rectified spirit, and pure alcohol.

D. *Fatty matters*. Not soluble in water, cold or hot; soluble in ether and in hot alcohol.



## VITAL PROPERTIES OF THE TEXTURES.

Of the phenomena exhibited by living bodies, there are many which, in the present state of knowledge, cannot be referred to the operation of any of the forces which manifest themselves in inorganic nature; they are therefore ascribed to certain powers, endowments, or properties, which, so far as known, are peculiar to living bodies, and are accordingly named "vital properties." These vital properties are called into play by various stimuli, external and internal, physical, chemical, and mental; and the assemblage of actions thence resulting has been designated by the term "life." The words "life" and "vitality" are often also employed to signify a single principle, force, or agent, which has been regarded as the common source of all vital properties, and the common cause of all vital actions.

1. Of the vital properties, there is one which is universal in its existence among organized beings, namely, the property, with which all such beings are endowed, of converting into their own substance, or "assimilating," alimentary matter. The operation of this power is seen in the continual renovation of the materials of the body by nutrition, and in the increase and extension of the organized substance, which necessarily take place in growth and reproduction; it manifests itself, moreover, in individual textures as well as in the entire organism. It has been called the "assimilative force or property," "organizing force," "plastic force," and is known also by various other names. But in reality the process of assimilation produces two different effects on the matter assimilated: first, the nutrient material, previously in a liquid or amorphous condition, acquires determinate form; and secondly, it may, and commonly does, undergo more or less change in its chemical qualities. Such being the case, it seems reasonable, in the mean time, to refer these two changes to the exercise of two distinct properties, and, with Schwann, to reserve the name of "plastic" property for that which gives to matter a definite organic form; the other, which he proposes to call "metabolic," being already generally named "vital affinity." Respecting the last-named property, however, it has been long since remarked, that, although the products of chemical changes in living bodies for the most part differ from those appearing in the inorganic world, the difference is nevertheless to be ascribed, not to a peculiar or exclusively vital affinity different from ordinary chemical affinity, but to common chemical affinity operating in circumstances or conditions which present themselves in living bodies only; and undoubtedly the progress of chemistry is daily adding to the probability of this view.

2. When a muscle, or a tissue containing muscular fibres, is exposed in an animal during life, or soon after death, and scratched with the point of a knife, it contracts or shortens itself; and the property of thus visibly contracting on the application of a stimulus is named "vital contractility," or "irritability," in the restricted sense of this latter term. The property in question may be called into play by various other stimuli besides that of mechanical irritation, especially by electricity, the sudden application of heat or cold, salt, and various



other chemical agents of an acrid character, and, in a large class of muscles, by the exercise of the will, or by involuntary mental stimuli. The stimulus may be applied either directly to the muscle, or to the nerves entering it, which then communicate the effect to the muscular fibre, and it is in the latter mode that the voluntary or other mental stimuli are transmitted to muscles from the brain. Moreover, a muscle may be excited to contract by irritation of a nerve not directly connected with it. The stimulus, in this case, is first conducted by the nerve irritated to the brain or spinal cord; it is then, without participation of the will, and even without consciousness, transferred to another nerve, by which it is conveyed to the muscle, and thus at length excites muscular contraction. The property of nerves, by which they convey stimuli to muscles, whether directly, as in the case of muscular nerves, or circuitously, as in the case last instanced, is named the "*vis nervosa*."

Besides the obviously muscular textures, there are others which possess a certain amount of vital contractility, although the existence of muscular fibres in them has not been satisfactorily demonstrated. In the present state of knowledge, therefore, we cannot with certainty affirm that vital contractility belongs exclusively to muscular structure. Some physiologists, indeed, have attempted to distinguish the contractility observed in textures not reputed muscular, from the contractility of muscle, and have named it "*non-muscular*" vital contractility; but, except as regards its seat, it cannot be said to have any distinctive character; for the contractility acknowledged to be muscular differs itself in different muscular textures in the rapidity and force with which it is exerted, as well as in the nature of the stimuli by which it is excited.

The evidence that a tissue possesses vital contractility is derived, of course, from the fact of its contracting on the application of a stimulus. Mechanical irritation, as scratching with a sharp point, or slightly pinching with the forceps, electricity obtained from a piece of copper and a piece of zinc, or from a larger apparatus if necessary, and the sudden application of cold, are the stimuli most commonly employed. Heat, when of certain intensity, is apt to cause permanent shrinking of the tissue, or "*crispation*," as it has been called, which, though quite different in nature from vital contraction, might yet be mistaken for it; and the same may happen with acids and some other chemical agents, when employed in a concentrated state: in using such stimulants, therefore, care should be taken to avoid this source of deception.

3. We become conscious of impressions made on various parts of the body, both external and internal, by the faculty of sensation; and the parts or textures, impressions on which are felt, are said to be sensible, or to possess the vital property of "*sensibility*."

This property manifests itself in very different degrees in different parts; from the hairs and nails, which indeed are absolutely insensible, to the skin of the points of the fingers, the exquisite sensibility of which is well known. But sensibility is a property which really depends on the brain and nerves, and the different tissues owe what sensibility they possess to the sentient nerves, which are distributed to them.



Hence it is lost in parts severed from the body, and it may be immediately extinguished in a part, by dividing or tying the nerves so as to cut off its connexion with the brain.

In estimating the degree of sensibility possessed by a tissue, whether in the human subject or by observations made on the lower animals, which for obvious reasons are much less satisfactory, several modifying circumstances must be taken into account, which will be duly adverted to in their proper place.

It thus appears that the nerves serve to conduct impressions to the brain, which give rise to sensation, and also to convey stimuli to the muscles, which excite motion; and it is not improbable that, in both these cases, the conductive property exercised by the nervous cords may be the same, the difference of effect depending on this, that in the one case the impression is carried upwards to the sensorial part of the brain, and in the other downwards to an irritable tissue, which it causes to contract; the stimulus in the latter case either having originated in the brain, as in the instance of voluntary motion, or having been first conducted upwards, by an afferent nerve, to the part of the cerebro-spinal centre devoted to excitation, and then transferred to an efferent or muscular nerve, along which it travels to the muscle. If this view be correct, the power by which nerves conduct sensorial impressions and the before mentioned "*vis nervosa*" are one and the same vital property; the difference of the effects resulting from its exercise being due partly to the different nature of the stimuli applied, but especially to a difference in the susceptibility and mode of reaction of the organs to which the stimuli are conveyed.

#### DEVELOPMENT OF THE TEXTURES.

The tissues of organized bodies, however diversified they may ultimately become, show a wonderful uniformity in their primordial condition. From researches which have been made with the microscope, especially during the last few years, it has been ascertained that the different organized structures found in plants, and, to a certain extent, also those of animals, originate by means of minute vesicles, or cells. These cells, remaining as separate corpuscles in the fluids, and grouped together in the solids, persisting in some cases with but little change, in others undergoing a partial or thorough transformation, produce the varieties of form and structure met with in the animal and vegetable textures. Nay, the germ from which an animal originally springs, so far at least as it has been recognised under a distinct form, appears as a cell; and the embryo, in its earliest stages, is but a cluster of cells produced from that primordial one; no distinction of texture being seen till the process of transformation of the cells has begun.

No branch of knowledge can be said to be complete; but there is, perhaps, none which can, at the present moment, be more emphatically pronounced to be in a state of progress than that which relates to the origin and development of the textures, and much of the current opinion on the subject is uncertain, and must be received with caution. In these circumstances, in order both to facilitate the exposition, and to explain to the reader more fully the groundwork of the doctrines in question, we shall begin with a short account of the development of the tissues of vegetables; for it was in consequence of the discoveries made in the vegetable kingdom that the happy idea arose of applying

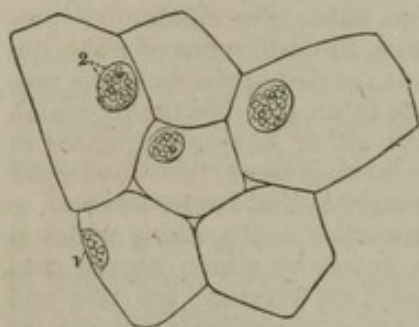


the principle of cellular development to explain the formation of animal structures, and they still afford important aid in the study of that, as yet, more obscure process.

#### OUTLINE OF THE FORMATION OF VEGETABLE STRUCTURE.

When a thin slice from a succulent part of a plant is viewed under the microscope, it is seen to consist chiefly or entirely of a multitude

Fig. 1.



Nucleated cells from a bulbous root; magnified 290 diameters. (Schwann.)

of minute vesicles adhering together, of a rounded or angular form, and containing various coloured or colourless matters in their interior; these are the elementary cells (fig. 1; fig. 2, <sup>1</sup> <sup>2</sup>). Besides such cells, phænogamous or flowering plants contain tubes, vessels, and other forms of tissue (fig. 2, <sup>4</sup> <sup>6</sup>); but a great many plants of the class cryptogamia are composed entirely of cells, variously modified, it is true, to suit their several destinations, but fundamentally the same throughout: nay, there are certain very simple modes of vegetable existence, in which a single cell may constitute an entire plant, as in the well-known green powdery crust which coats over the trunks of trees, damp walls, and other moist surfaces. In this last case, a simple detached cell exercises the functions of an entire independent organism, imbibing and elaborating extraneous matter, extending itself by the process of growth, and continuing its species by generating other cells of the same kind. Even in the aggregated state in which the cells exist in vegetables of a higher order, each cell still, to a certain extent, exercises its functions as a distinct individual; but it is now subject to conditions, arising from its connexion with the other parts of the plant to which it belongs, and is made to act in harmony with the other cells with which it is associated, in ministering to the necessities of the greater organism of which they are joint members. These elementary parts are therefore not simply congregated into a mass, but combined to produce a regularly organized structure; just as men in an army are not gathered promiscuously, as in a mere crowd, but are regularly combined for a joint object, and made to work in concert for the attainment of it; living and acting as individuals, but subject to mutual and general control.

Now the varied forms of tissue found in the higher orders of plants do not exist in them from the beginning; they are derived from cells. The embryo plant, like the embryo animal, is in its early stages entirely formed of cells, and these of a very simple and uniform character; and it is by a transformation of some of these cells in the further progress of development that the other tissues, as well as the several varieties of cellular tissue itself, are produced. The principal modes, as far as yet known, in which vegetable cells are changed, are the following.



1. The cells may increase in size; simply, or along with some of the other changes to be immediately described.

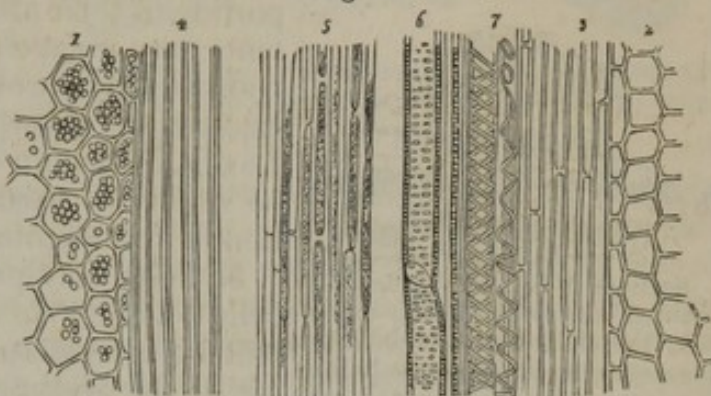
2. They alter in shape. Cells have originally a spheroidal or rounded figure; and when in the progress of growth they increase equally, or nearly so, in every direction, and meet with no obstacle, they retain their rounded form. When they meet with other cells extending themselves in like manner, they acquire a polyhedral figure (fig. 2, <sup>1, 2</sup>) by mutual pressure of their sides.

When the growth takes place more in one direction than in another, they become flattened, or they elongate, and acquire a prismatic, fusiform, or tubular shape (fig. 2, <sup>3, 4, 5</sup>). Sometimes, as in the common rush, they assume a star-like figure, sending out radiating branches, which meet the points of similar rays from adjacent cells (fig. 3).

3. The cells coalesce with adjoining cells, and open into them. In this way a series of elongated cells placed end to end may open into one another by absorption of their cohering membranes, and give rise to a tubular vessel.

4. Changes take place in the substance and in the contents of the cells. These changes may be chemical, as in the conversion of starch into gum, sugar, and jelly, and in the production of various coloured matters, essential oils, and the like. Or they may affect the form and arrangement of the contained substances; thus, the contents of the cell very frequently assume the form of granules, or spherules, of various sizes; at other times the contained matter, suffering at the same time a change in its chemical nature and in consistency, is deposited on the inner surface of the cell-wall, so as to thicken and strengthen it. Such "secondary deposits," as they are termed by botanists, usually occur in successive strata, and the deposition may go on till the cavity of the cell is nearly or completely filled up (fig. 4). It is in this way that the woody fibre and other hard tissues of the plant are formed. It farther appears that the particles of each layer are disposed in lines, running spirally round the cell. In place of forming a continuous layer, these secondary deposits may leave little spots of the cell-wall uncovered, or less thickly covered, and thus give rise to what is named pitted tissue (fig. 2, <sup>6</sup>); [or they may be irregularly deposited, forming the hard

Fig. 2.



Textures seen in a longitudinal section of the leaf-stalk of a flowering plant.

Fig. 3.

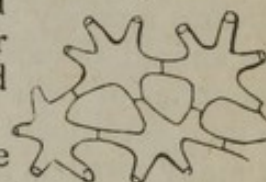Stellate cells from the bull-rush, (*Juncus*.)

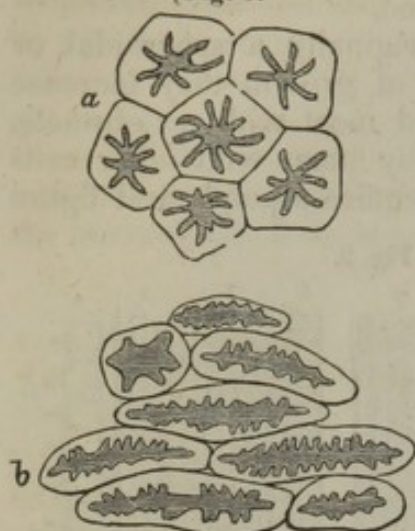
Fig. 4.



Cross section of ligneous cells containing stratified deposit.



[Fig. 5.



Sections of cells strengthened by internal matter irregularly deposited; the shaded portion indicates the remaining cavities: *a*, cells from the gritty centre of the pear; *b*, cells from the stone of the plum.]

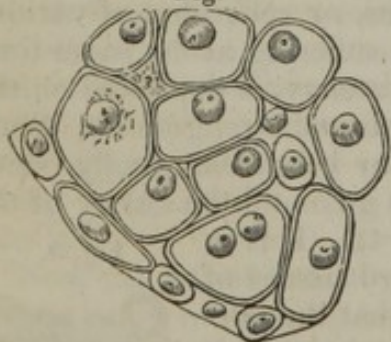
substance of the *stone* or *shell* of most fruits (fig. 5;) or they may assume the form of a slender fibre or band, single, double, or multiple, running in a spiral manner along the inside of the cavity, or forming a series of separate rings or hoops, as in spiral and annular vessels (fig. 2, 7). New matter may be absorbed or imbibed into the cells; or a portion of their altered and elaborated contents may escape as a secretion, either by transudation through the cell-wall, or by rupture or absorption of the membrane. Lastly, in certain circumstances, cells may be wholly or partially removed by absorption of the membrane.

5. Cells may produce or generate new cells. The mode in which this takes place will be immediately considered, in speaking of the origin of animal cells.

#### FORMATION OF THE ANIMAL TEXTURES.

Passing now to the development of the animal tissues, it may first be remarked generally, that in some instances the process exhibits an obvious analogy with that which takes place in vegetables; certain of the animal tissues, in their earlier conditions, appearing in form of a congeries of cells almost entirely resembling the vegetable cells, and, in their subsequent transformations, passing through a series of changes in many respects parallel to some of those which occur in the progress of vegetable development. Cartilage affords a good example of this. Figures 6 and 7, are magnified representations of cartilage in its early condition; and whoever compares them with the appearance of vegetable cells, shown in figures 1 and 2, must at once be struck with

Fig. 6.



Section of a branchial cartilage of a Tadpole, showing the early condition of the cells; magnified 450 diameters. (Schwann.)

the resemblance. Figs. 8 and 9, show the subsequent changes on the primary cells of cartilage; the parietes are seen to have become thickened by deposit of fresh material, the spaces within the cells, are consequently diminished, while the mass between the cavities is increased. Now this change seen to occur in the cartilage cells, though there may be a question as to the precise mode in which it is brought about, may very fairly be compared with the thickening of the sides of the vegetable cells, which takes place when they are converted into the woody and other hard tissues. Again, in most cartilages the cells increase in number as they diminish in size, new ones being formed within the old, as happens in many vegetable structures.



The instance now given, and others to the same effect which will be mentioned as we proceed, tend to show the fundamental resemblance of the process of textural development in the two kingdoms; but, when we come to inquire into the various modifications which that process exhibits in the formation of particular textures, we encounter serious difficulties. The phenomena are sometimes difficult to

observe, and, when recognised, they are perhaps susceptible of more than one interpretation; hence have arisen conflicting statements of fact, and differences of opinion at present irreconcilable, which future inquiry alone can rectify, and which in the mean time offer serious obstacles to an attempt at generalization. In what follows, nothing more is intended than to bring together, under a few heads, the more general facts as yet made known respecting the formation of the animal textures, in so far as this may be done without too much anticipating details, which can only be suitably and intelligibly given in the special history of each texture.

**Structure of Cells.**—A cell, before it has undergone alteration, is a round or oval vesicle, formed of thin, transparent, homogeneous, flexible membrane; varying considerably in size, but never passing beyond the dimensions of a microscopic object. It contains in its interior a fluid or more consistent matter, pellucid or opaque, and in the latter case generally granular. In the greater number of cells there is also to be seen, at some period of their existence, a smaller body, called the “nucleus,” which, as will afterwards appear, performs an important part in their economy. Schleiden attributed to it the function of producing the cell, and accordingly named it the “cytoblast,” an appellation which is synonymous with “cell-germ.” In the nucleus are commonly to be seen one or two, rarely more, minute eccentric spots; these are the nucleoli.

The nucleus (fig. 1, <sup>1</sup>) is of a round or oval shape, and more constant in size than the cell itself: its average diameter in animal cells is from  $\frac{1}{8000}$  to  $\frac{1}{4000}$  of an inch; its aspect is usually granular and dark, often with a yellowish hue, but sometimes quite homogeneous, transparent, and colourless. In some cases it is solid throughout, being then made up of fine molecular matter, or consisting of a cluster of large granules; in other instances, especially in animal cells, its mass appears to be hollow, or at least less consistent in the centre; or it may present itself as a perfect vesicle, inclosing matters of very variable nature. It seems probable, also, that the large granules of which some nuclei appear to be made up, are in reality vesicles, containing peculiar matters in their interior; examples, indeed, of composite vesicular nuclei of this description have been pointed out by Goodsir in various secreting structures.

Fig. 7.

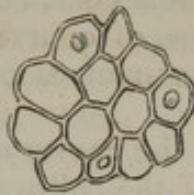


Fig. 8.

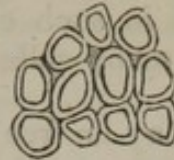


Fig. 9.



Cartilage of the branchial ray of a fish (*Cyprinus erythrophthalmus*) in different stages of advancement; magnified 450 diameters. (Schwann.)



As to the nature of the nucleolus (fig. 1, <sup>a</sup>), little is known; it has even been questioned, whether the little spots termed nucleoli are actually corpuscles or vesicles inclosed in the nucleus, or merely minute cavities in its substance. Schleiden, however, states, that in crushing the nucleus of vegetable cells, he has seen the nucleolus remain entire, and in such cases, of course, it must have been a distinct body. In many cells the nucleus presents no appearance of a nucleolus.

The nucleus may lie free in the cavity of the cell; more commonly it is attached to the inside of the cell-wall, and in some cases it is partially or wholly imbedded in the substance of the membrane. Henlé describes the nucleus of the pigment cells as situated quite on the outside, in a dimple of the cell-wall; but, I must confess, it has to me appeared otherwise: he also assigns an exterior position to the nucleus of the cells of the crystalline lens.

It very generally happens, that, when cells are exposed to the action of certain chemical agents, their different parts are differently acted on. Thus, in many cases acetic acid speedily dissolves the granular or coloured contents of the cell, leaving the nucleus entire, and rendering it more sharply defined and more conspicuous; and the cell membrane itself may be sometimes dissolved by the same agent, and the nucleus liberated. But, notwithstanding this and other aids to investigation, it is not always possible to say whether a given corpuscle is to be reckoned as a cell, or as a vesicular nucleus.

Cells are often seen without nuclei; in vegetable cellular tissues, indeed, this is the general rule: but, doubtless, in most of these instances nuclei have at one time been present, and have subsequently disappeared. Cells occur, however, both in animal and vegetable structures, in which nuclei have never at any time been discovered.

*Origin and Multiplication of Cells.*—The soft or liquid organizable matter out of which cells are immediately produced, is named “blastema,” or “cytoblastema.” This substance may be contained in cells; it may be lodged in their interstices, or in the meshes of a tissue; or it may be deposited on the surface of parts. When the circulation of the blood is once established in the animal system, the clear part of that fluid, “the plasma,” or “liquor sanguinis,” as it is called, may be regarded as a generally diffused blastema, or at least as a general source whence the organizable material or blastema is derived. There is reason to believe that new cells may arise in any of those situations in which the blastema is found; that is to say, they may be formed within previously existing or parent cells, or in the interstitial and free blastema. The included or “endogenous” mode of origin is the most general in the vegetable kingdom; it occurs also in the animal body, as in the ovum, in cartilage, and in some other structures; but Schwann maintains that in animals the free or interstitial mode of origin is the more common.


Now, as to the process by which cells are formed, it appears, from the statements of competent observers, that it may take place in more ways than one; and it must be confessed that, for the present at least, these several modes of production of cells cannot with certainty be referred to one common principle.



1. Formation of a cell on a nucleus.—A nucleus being produced in the first instance, by a process to be afterwards considered, the membrane of the cell is formed on the surface of the nucleus, at first closely surrounding it, but soon separating at one side, and gently rising up like a watch-glass on a watch (fig. 10). The cell-wall, continuing to extend, soon becomes much larger than the nucleus, which at last is left at some point of the circumference of the cell imbedded in the substance of the membrane, where it may either remain, or be removed by liquefaction or absorption.

This is the process, as it has been traced in vegetables by Schleiden, who was the first to discover the important part performed by the nucleus, or "cytoblast," as he accordingly named it. Schwann conceives that animal cells usually originate from nuclei or cytoblasts, in like manner.

Fig. 10.



A layer of matter is deposited and condensed on the surface of the nucleus; it then rises in form of a film or membrane, and separates to a greater or less extent from the nucleus, which remains adherent to its inner surface, or assumes a more central position. The cell membrane becomes firmer and usually thicker as it extends; its expansion being accompanied by actual growth and increase of substance, and not being simply the result of mechanical distension by the fluid which accumulates in its cavity.

Plan representing the formation of a nucleus, and of a cell on the nucleus, according to Schleiden's view.

A layer of matter is deposited and condensed on the surface of the nucleus; it then rises in form of a film or membrane, and separates to a greater or less extent from the nucleus, which remains adherent to its inner surface, or assumes a more central position. The cell membrane becomes firmer and usually thicker as it extends; its expansion being accompanied by actual growth and increase of substance, and not being simply the result of mechanical distension by the fluid which accumulates in its cavity.

Such being the manner in which a cell is formed round a nucleus, we have next to inquire how the nucleus itself originates; and here we meet with a difference of opinion. Schleiden and Schwann conceive that nucleoli first appear in the blastema; that then, round one or sometimes more of these nucleoli, fresh matter is aggregated, and the resulting little mass, becoming defined on the surface, constitutes the nucleus<sup>1</sup> (fig. 10). Schwann, indeed, regards the formation of a cell and the formation of a nucleus as a repetition of the same process; a deposit first taking place round the nucleolus to form the nucleus, and then a second layer being deposited on the nucleus to form the cell. He compares the process to that of crystallization, and ascribes the chief differences between the one and the other to the circumstance, that the permeable organic substance of the cell admits of increase, not only by external apposition of new particles, but by the intussusception of new matter between the particles already deposited; whereas a crystal can grow only in the former way.<sup>2</sup> Henlé suggests

<sup>1</sup> Mr. Addison also describes the formation of cells and their nuclei (in lymph) in this manner. (*Med. Gazette*, 1841-42, p. 146.)

<sup>2</sup> Whatever opinion may be entertained as to the soundness of this and other speculative views of Schwann respecting the economy of cells, there can be no question that his discussion of them is highly instructive; it will be found in his admirable exposition of the whole subject of the cellular origin of the animal tissues. (*Microscopische Untersuchungen*, &c. Berlin, 1839.) To Schwann's celebrated work, as well as to the writings of Schleiden (translated in Taylor's *Scientific Memoirs*), Valentin, Henlé, and Barry, the reader is referred, as original sources of information on all that relates to the development of the textures.



a different view as to the formation of the nucleus, and brings forward arguments to show that it is formed independently of a nucleolus. He supposes that elementary granules of a discoid figure, and from  $\frac{1}{12000}$  to  $\frac{1}{8000}$  of an inch in diameter, first appear in the blastema; that two, three, or four of these group together to form the nucleus; that their union is at first imperfect, and may continue so even some time after the cell is somewhat advanced in formation; but that they ultimately become completely blended into a single mass. It is well known that in many cells, such as the corpuscles of lymph, mucus, and pus, the nucleus, when acted on by weak acetic acid, appears divided, either completely or partially, into two or three segments, and these Henlé conceives to be its constituent granules, as yet imperfectly united.

Nevertheless, he does not deny that a nucleus may be formed by the aggregation of matter round a single elementary granule, and it does not appear in what respect such a mode of formation differs from that proceeding from a nucleolus, as described by Schleiden. Indeed, it is not easy to see how, in any case, a distinction is to be made between the "elementary granules" of a nucleus, especially when they have not coalesced, and Schleiden's nucleoli. It is clear, also, that the nucleus contains, besides the granules, some other matter which surrounds them and binds them together, and which is softened or dissolved by acetic acid. Respecting these elementary granules, Henlé further states, that "they present themselves wherever new formations are about to take place." He supposes that they are, for the most part, minute vesicles filled with fat, but that in forming a nucleus their chemical nature is changed, the nucleus acquiring the characters of a protein compound. Lastly, he thinks it probable that these vesicular bodies are originally merely minute particles of oil which acquire a vesicular envelope of albuminoid matter, on the physical principle pointed out by Ascherson, viz. that globules of oil when brought into contact with liquid albumen, or some similar substance with which oil does not mix, become instantly surrounded with a coherent film or coating of that substance, and thus acquire a vesicular character.

Once the cell-wall is formed, the nucleus may remain without further change; or it may continue to grow larger, but always less rapidly than the envelope; or it may disappear altogether, as already stated: indeed this is the general rule with vegetable cells. Other changes which it undergoes will be afterwards mentioned.

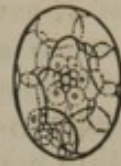2. Resolution of the nucleus of a cell into new cells.—This mode of production has been inferred from the following succession of phenomena: which has not, indeed, been actually seen to occur in the same cell, but has been traced in a series of cells, apparently in different stages of progress. 1. A cell is seen with a nucleus. 2. The nucleus has vanished, and in its place a group of young nucleated cells have appeared, within the original cell. 3. The young progeny, increasing in size, escape by rupture or absorption of the parent cell.

In this case are we to suppose that the nucleus of the original cell becomes resolved into shapeless blastema, from which fresh nucleoli and nuclei arise and produce the new cells? or do the granules of the parent nucleus, or the segments into which it may divide, serve as nucleoli or perhaps as smaller nuclei round which cell membranes are formed, they themselves growing larger all the while? or, lastly, are these granules really minute vesicular bodies which at once expand into perfect cells, subsequently acquiring nuclei, which in turn may go through the same process? The under-mentioned observations of Kölliker agree with the



second, and several facts, stated by Barry and Goodsir, with the last of these suppositions. Dr. Barry, however, represents the nucleus as affording many series of cells in succession; those last formed pushing outwards their older and larger predecessors in concentric ranks, towards the circumference of the parent cell (fig. 11). He conceives, also, that the young cells themselves contain incipient cells of a still younger generation in their interior; in short, that the same process which occurs in the primary cell takes place in each one of its progeny, and that it is impossible to say where the series of new generations terminates. Moreover, he states that only some of the young cells survive, namely, those into which the nucleus in the end divides; the rest having only a temporary existence, and disappearing by liquefaction; and he supposes that the transitory cells serve to elaborate material to be afterwards assimilated by the persistent ones.

Fig. 11.

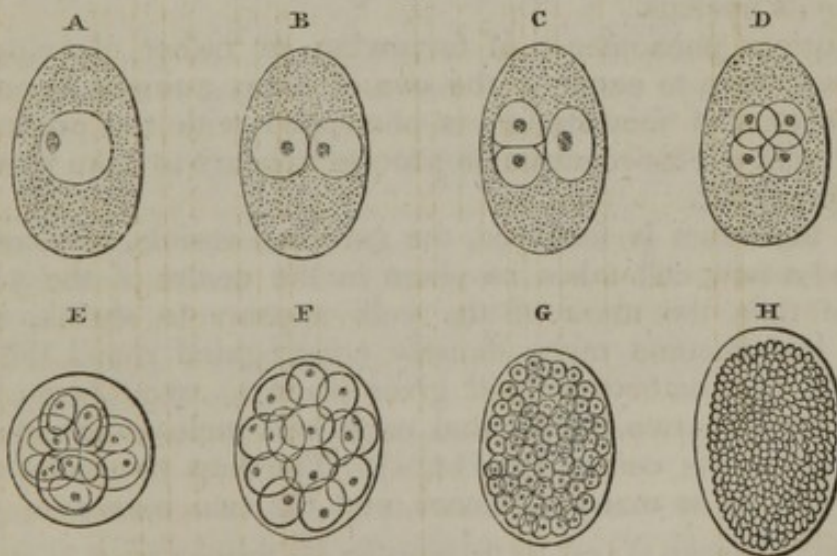


Scheme from Dr. Barry, showing young cells growing within a larger one in concentric series. One of the young cells is represented as filled with a still younger generation.

To this head is to be referred the increase of cells by reduplication, which is seen to take place in the ovum after fecundation, and probably occurs also at after-periods in the growth of some of the textures. The following is an outline of that process, as observed by Kölliker<sup>1</sup> in the ova of certain parasitic worms, in which it presents itself in its least complex form, and from the transparency of the objects can be traced with comparative ease.

Before impregnation there is seen, as usual, within the ovum in the midst of the yolk the vesicular body named the germinal vesicle; this contains a smaller mass within it, the macula germinativa, and has therefore the aspect of a nucleated cell. After the ovum has been fecundated, the germinal vesicle vanishes, all trace of it being lost; but in its place a nucleated cell soon presents itself, which appears to be a new formation (fig. 12, A). This first "embryonic cell" is soon

Fig. 12.



A, B, C, D, successive stages of the ovum of *Ascaris dentata*, showing duplication of cells. E, F, G, H, ovum of *Cucullanus elegans*, showing the advance of the process. (From Kölliker's Memoir.)

succeeded by two others (B), these by four (D), and these again by eight; the number thus doubling, and the cells becoming individually

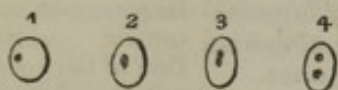
<sup>1</sup> Müller's Archiv., 1843, p. 68.



smaller (F, G), till there results a large mass of cells (H), which assumes the form of the embryo. Now, in this case it is clearly ascertained that at every reduplication a pair of new cells is formed within each of those already existing, the old or parent cells then disappearing, and the new ones becoming free; and stages of the process are observed, in which the parent cells, not having yet disappeared, are seen with a couple of young ones still included within them (c and E).

It seems probable that, when the two young cells are about to be

Fig. 13.



Cells from ovum of *Cucullanus*, showing supposed division of the nucleus. (Kölliker.)

formed, the nucleus of the parent cell divides into two, and that each segment then gives rise to a new cell. In support of this view, Kölliker states that he has occasionally observed cells with the nucleus elongated; others in which it was constricted in the middle, as if about to divide; in others, again, there were two nuclei, of smaller size than the single nucleus of adjoining cells, as if they had just arisen from the division of a larger one<sup>1</sup> (fig. 13, <sup>1, 2, 3, 4</sup>).

3. Matter collects round a nucleated cell, and the whole becomes inclosed in an envelope, thus constituting a larger cell, to which the inclosed one serves as a nucleus. Cells of this kind have been called "complicated," or "complex" cells.<sup>2</sup> The ganglionic globules of the brain and nerves, to be afterwards described, have been looked on as complex cells, and are supposed to be formed in the manner described. The ovum itself is an instance of a complex cell: a small corpuscle, the "germinal spot," appears first; round this, as a nucleus, a cell, the "germinal vesicle," is formed; and then the matter of the yolk collects round the germinal vesicle, and gets inclosed in an exterior membrane; this becomes a second cell, and includes the germinal vesicle as its nucleus.

The curious phenomenon of furrowing, or rather cleaving, of the yolk, now known to occur in the ova of many animals as one of the earliest effects of fecundation, is connected with the production of complex cells. This remarkable process appears to take place in the following manner.

When the ovum is fertilized, the germinal vesicle, as usual, disappears, and a new cell takes its place in the centre of the yolk. At the same time the mass of the yolk appears to shrink, as if its granules had become more densely congregated round the central cell. This first embryonic cell gives place to two others; then the yolk divides into two halves, and each half incloses one of the first pair of cells in its centre (fig. 14, A). The first two cells are succeeded by twice as many new ones, and the two masses of yolk are

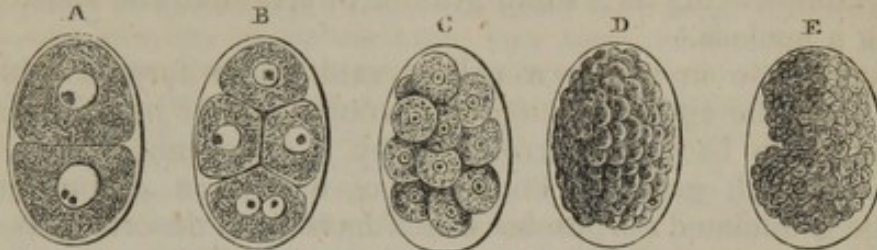<sup>1</sup> The apparent division of a cell, by the formation of a partition across its cavity, which has been supposed to be a common mode of multiplication of cells in vegetables, is in most cases, very probably, as Schleiden explains, merely an instance of the endogenous production of twin cells, the contiguous sides of which form the septum, as in c (fig. 12). But it is doubtful whether the multiplication by partition of a cell may not occur in the algæ, as Mohl has described; Valentin refers to corroborative observations by Shuttleworth, as yet unpublished.

<sup>2</sup> By Henlé: "secondary" cells might perhaps be a more fitting appellation, but that term has already been employed in another sense.



subdivided into four, each new yolk-segment inclosing a cell in its centre, as before (fig. 14, B). The central cells and the inclosing segments of the yolk are again doubled so as to form eight, and this duplication of the cells and concomitant cleaving of the yolk are continued till the masses are greatly increased in number and reduced in size (C, D, E); each of them being then a complex cell containing a

Fig. 14.



Cleaving of the yolk after fecundation.—A, B, C, (from Kölliker,) ovum of *Ascaris nigrovenosa*; D and E, that of *Ascaris acuminata* (from Bagge).

smaller cell within, together with more or less of the matter of the yolk in different instances. Their further changes and ultimate destination it is unnecessary here to pursue.

While it is admitted that the segments of the yolk eventually become inclosed by membranes and form true cells, it has been questioned whether its earlier and larger subdivisions are really surrounded by an enveloping membrane. Acknowledging the difficulty of the question, I should nevertheless be disposed, from what I have seen in the ovum of the ascaris, to answer it in the affirmative, as regards that instance at least. As to the mode of multiplication of the included cells, we can hardly doubt that each pair of young cells is formed within the cell immediately preceding, by subdivision of its nucleus, in the manner previously described (see lower cell in A); the difference in this case being, that each of the young cells, on escaping from the maternal one, becomes wrapt up in the centre of a mass of yolk. The duplication of the cell must of course take place before the division of its including yolk-mass (see lowest segment of B), and is doubtless a necessary condition of it. As to the mechanism of the latter process, we may presume that the cells exercise a sort of attraction on the substance of the yolk, causing it to gather round them as so many separate centres. The shrinking of the granular mass, already noticed, apparently from the more close aggregation of its granules round the central cell, is in harmony with this supposition. I may remark that in the ova of the ascaris nigrovenosa, and asc. acuminata, the granules of the yolk exhibit very lively molecular movements. On one occasion, when one of the large segments, into which the yolk is first cleft, divided itself into two portions while actually under inspection, I first observed a very obvious heaving motion among the granules throughout the whole mass; then ensued a constriction at the circumference, which, proceeding inwards, soon completed the division; but all this time the central cells were quite hidden by the enveloping granular matter.<sup>1</sup>

The process above described, in some animals, affects only a part of the yolk; while in others, again, it has not been discovered.

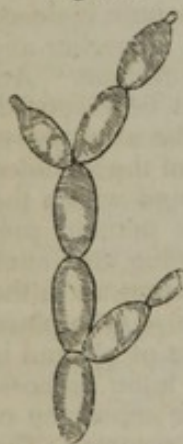<sup>1</sup> Dr. Barry has called attention to the very interesting fact of the resemblance between the spontaneous division of infusorial animalcules, and the process here described. The phenomenon observed in infusoria of the division of a pellucid globule within the animal, which precedes the division of its entire body, is probably owing to the formation of two cells within a central one, and to their subsequent separation from each other, to become the central cells of the respective segments of the body, as happens in the divided yolk. It is worthy of inquiry whether certain phenomena observed in the vegetable kingdom may not be referable to a similar process; as, for instance, the subdivision of a granular mass into separate portions, which occurs in the formation of the sporules of mosses and hepaticæ.



4. A cell may arise without the previous formation of a nucleus. Schwann describes such cells as occurring within larger ones in the "chorda dorsalis" (a transitory cartilaginous structure) of the tadpole and fish. He states that they commence as small spherules, which either from the beginning are, or subsequently become, hollow, and expand into cells. Vogt maintains that they afterwards acquire nuclei, but his description is ambiguous. Other examples are given of a cell commencing as a small granule or spherule, and subsequently acquiring a nucleus.<sup>1</sup>

Another mode in which a cell is said to be formed without a nucleus, is by the agglomeration of granular matter into a considerable mass, which becomes surrounded by a membrane; there results a cell filled with granular contents, but without a proper nucleus. The large granulated corpuscles which have been described as sometimes occurring in inflammatory exudations, and in various morbid growths, under the name of "compound inflammation globules," are said to be examples of this (Henle). The sporules of certain algæ are also described as being formed in the same way.

Fig. 15.



Magnified figure of the yeast-plant, *Saccharomyces cerevisiae*. (After Meyen.)

5. In some of the most simple vegetables multiplication takes place by a sort of sprouting of young cells from the old ones. In the yeast-plant, for example, (fig. 15,) the young cells are seen in various stages of growth, springing from the circumference of older and larger cells. The young cell is usually described as being at first a mere saccular protrusion of the wall of the old cell and becoming afterwards cut off from it; but I must confess that, in this instance, I have never been able to satisfy myself that the cavity of the young cell communicated with that of its parent cell, as represented in the figure, even in its earliest stages; although the lateral protrusion of a cell doubtless occurs in various other algæ.

Finally, as to the nature and origin of the cell-germ. From what has been stated in the preceding paragraphs, it will be apparent that a nucleus and a cell-germ, or cytoblast, are not always the same thing. In many cases the cell is formed round a nucleus, and the latter may be then properly called a cytoblast, though it may itself owe its origin to a nucleolus. In other instances the nucleus seems to be an after-formation in a cell originally without one, serving as a sort of reproductive or generative organ to furnish the germs or rudiments of young cells. It may be a cytoblast, therefore, in two senses,—by generating the cell which contains it, and by resolving itself into the germs of a new cell-family; but it was in the former character that the term was applied to it by Schleiden, and in this sense there are other objects which equally deserve the appellation: we have seen, indeed, that a cell itself may stand in the relation of a cytoblast to a larger cell formed round it. When several cellules arise within a larger cell by resolution of its nucleus, their germs, or first rudiments, are described as minute spherules much resembling nucleoli; and these, perhaps, becoming hollow, may at once expand into cells, or they may become surrounded by a cell-membrane, but without the intermediate step of forming the larger body usually termed a nucleus. The so-called nucleus in the cells of the ovum of the entozoa, already

<sup>1</sup> See, among others, Macleod, in *Lond. and Edin. Journal of Medical Science*, 1842, p. 829.



described (figs. 12, 13, and 14), corresponds more with a nucleolus, if size be regarded as a character, and this body is supposed to divide into two cell-germs. Lastly, minute spheroidal cell-rudiments, which grow into cells, would seem to occur free in the blastema, from whatever source they have been originally derived.

Seeing the successive generations of cells which proceed from a single one in the ovum, and the propagation of cells in a similar manner which in many circumstances occurs at after-periods, physiologists have been naturally led to look to the germinal vesicle of the ovum for the original source to which all succeeding cell-germs in the economy might be traced back; and, that vesicle being itself derived from the parent organism, they have conceived that a peculiar generative matter, probably constituting the substance of the germinal spot, is handed down from parent to offspring, and, receiving an impulse by fecundation, begins in the ovum the series of assimilative and reproductive actions which is afterwards continued throughout life. Dr. Barry has given a formal theory of the origin and multiplication of cells, in which he represents the generative matter as a peculiar pellucid substance, and proposes to call it "hyaline." He conceives that this substance is derived from the germinal spot of the ovum, and, after fecundation by the male, acquires remarkable properties, among others, that of increasing by the assimilation of new matter, and that of propagating itself by division; and he supposes that the globules into which it divides form so many germs of new cells: according to him, therefore, the cell-germ is a globule of hyaline. He is farther of opinion, that many cells which have but a transitory existence, are intended for no other purpose than to reproduce the hyaline; successive generations of them being sometimes employed in elaborating this substance.

It is in the very nature of this subject to excite speculation and engender hypotheses; and, as to those which have been already produced, we may be permitted to remark, that, however plausibly they may harmonize with some of the phenomena, we cannot receive any one of them with confidence until it shall have stood the test of a much more extended comparison, than has yet been made, with the results of observation.

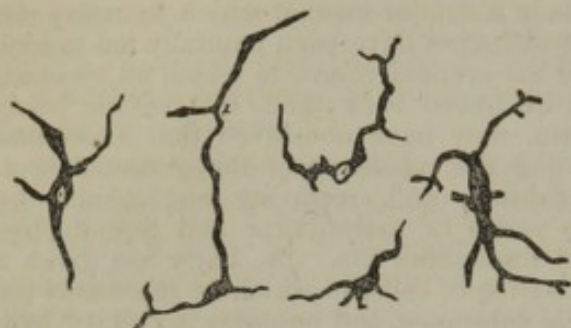*Transformation of Cells and Blastema.*—In the conversion of cells into the several textures, there is, in different instances, a great difference not only in the nature and extent of the change which the cells undergo, but also in the condition which these bodies have attained when the process of change commences. In some cases they have already acquired a distinct cell-wall and cavity; but in others they never attain the condition of cells, strictly so called, and the process of transformation begins whilst they may be said to be but in a nascent state. Indeed, in the development of certain textures, as will afterwards be explained, there is reason to believe that the preliminary process of cell-formation, if in the circumstances we may properly use such a term, goes no farther than the production of nuclei, and that the blastema surrounding or lying between the nuclei, which themselves undergo transformation, is at once converted into the elements of the tissue. The following are the principal modes in which cells or their elements are metamorphosed; it being understood that two or more of the processes, here to be mentioned, may occur in the same cell, and that the nucleus also undergoes changes which will subsequently be explained.

1. Increase in size, and change of figure.—A cell may increase equally, or nearly so, in all its dimensions, in which case it preserves its globular shape; but more commonly the growth is greater in certain dimensions, and then the figure becomes depressed and discoid,



or elongated and oval, fusiform or strap-shaped. When growing cells meet one another, they generally acquire an angular or polyhedral figure; and this may be combined with elongation into the prismatic,

Fig. 16.



Pigment cells from the tail of the tadpole, magnified about two hundred and twenty-five diameters. (Schwann.)

or flattening into the tabular form, as exemplified in the columnar and scaly varieties of epithelium. All these changes correspond with similar transformations already spoken of, which occur in vegetable cells. A more remarkable change of figure occurs in those instances where a cell shoots out into branches at various points of its circumference, as happens with certain varieties of pigment cells (fig. 16); and this, too, may be

aptly compared to the ramified or radiating cells found in the rush and some other plants (fig. 3).

2. Alteration of substance and of contents.—While the above described changes of figure are going on, the cell-wall usually acquires increased density and strength; and in a flattened cell, when much extended, the opposite sides cohere so as to obliterate its cavity. The substance of cells may also be changed in its chemical nature, as in the instance of the cuticle, where the cells, while deep-seated, and recently formed, are soluble in acetic acid, but as they advance to the surface, lose this property and acquire a corneous character.

Granular matter contained within cells may be dissolved and consumed whilst the cell extends itself, as happens with those of the yolk of the bird's egg when they join to form the early rudiments of the embryo. On the other hand, new matters may appear, as fat and pigment within the adipose and pigmentous cells, and the peculiar constituents of certain secretions in the cells of secreting organs; in which last case the cells may eventually burst, and discharge their contents.

As in plants, too, the new substance may be so deposited as to augment the thickness and strength of the cell-wall, of which an example occurs in the thickening of the sides and narrowing of the cavity of cartilage-cells by layers of new matter on their internal surface. Or the process may assume still more of a plastic and organizing character, as in the endogenous production of young cells, already described, and the formation of the spontaneously moving bodies named spermatozoa, or spermatic animalcules, which, in plants as well as in animals, are produced in the cavity of a cell.

These plastic changes are equally unexplained with the other alterations of form and structure which accompany the production and metamorphoses of cells. As regards the changes in the quantity and chemical nature of the contained matter, it may be remarked, that the introduction of new matter into a cell is so far a phenomenon of imbibition, and, as such, must be to a certain extent dependent on the endosmotic effect produced by the substance already within the cell, and on the comparative facility with which the matter to be introduced is im-

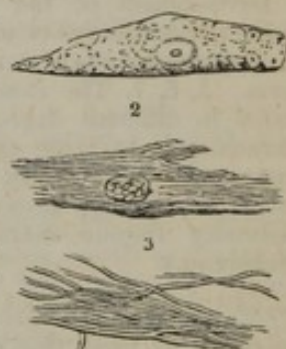


bibed and transmitted by the permeable cell-wall. Some substances, moreover, being more readily imbibed than others of a different nature, the quality as well as the quantity of the imbibed material will be so far determined by the same circumstances. But, while an alteration in the contents of a cell may be thus brought about by the imbibition of one kind of matter in preference to another, the contained substance may be also changed in its qualities by a process of conversion taking place within the cell, and there are two conceivable ways in which this converse or "metabolic" process may possibly occur. 1. Chemical action may be mutually exerted between the matter originally contained in the cell, and that subsequently introduced into it. 2. It has been supposed that the process may be referred to the class of phenomena denominated by chemists "catalytic" actions, or actions by "contact," in which a chemical change is induced in a compound by the presence of a second body, which, as far as appears, does not itself necessarily suffer alteration, and it is conceived that the cell-membrane may exert this species of influence on the matters contiguous to it.

This seems also a fitting place to mention that the well-known tremulous movement which so frequently affects minute particles of matter, is not unfrequently observed in the molecular contents of cells. But in many vegetable cells a motion of a different character, and affecting larger-sized corpuscles, is seen. These corpuscles move in a steady and regular manner along the inside of the cell-wall, and in a constant direction. This motion is named "rotation" by vegetable physiologists; the *Chara* and *Vallisneria* afford beautiful and well-known examples of it.<sup>1</sup>

3. Division into fibrils.—In the formation of certain tissues, cells which have increased in size and altered in shape, generally by elongation and flattening, appear to be resolved into fine fibres. The cells, for example, which form the cortical layers of a growing feather, first become flattened and somewhat oblong, and then divide longitudinally into a number of slender fibres. These fibres at first cohere, but afterwards separate; the nucleus during this change gradually dwindles away, and at last disappears altogether (fig. 17, <sup>1</sup>, <sup>2</sup>, <sup>3</sup>). It is doubtful whether the fibrils are produced by the deposition of new matter in longitudinal lines within or on the flattened cell, in which case the substance of the cell which connects the fibrils together must be removed, or whether the substance of the cell is itself, as it were, cut up into fibres.

Fig. 17.



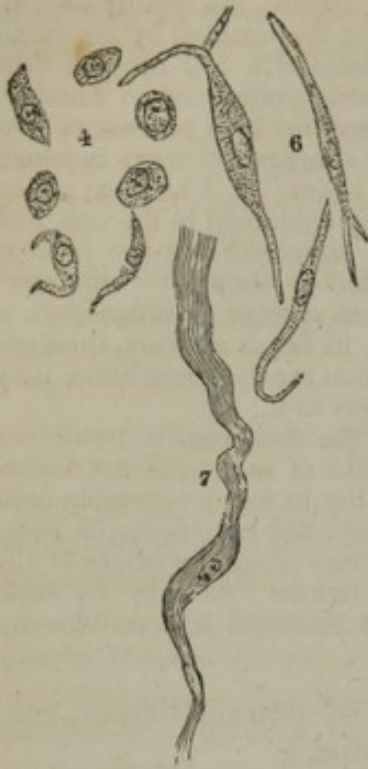
Cells from the cortex of a growing feather, showing their division into fibres.

Schwann supposed that the bundles of fibrils which constitute the chief part of the cellular tissue, were formed by a similar process. He describes the cells as first extending themselves in two opposite directions, into an elongated and usually fusiform figure (fig. 18, <sup>4</sup>, <sup>5</sup>), then dividing at the extremities into fibrils (<sup>6</sup>); the division at length reaching the middle part (<sup>7</sup>), and extending through it, so as to convert the elongated cell into a bundle of parallel fibrils; the nucleus persisting for a time, but at last disappearing.

<sup>1</sup> I once noticed in a spherical epithelium-cell from a very young tadpole (of the toad) a motion of particles which seemed to me almost to go beyond the usual tremulous molecular movements. A little clump of dark granular matter or pigment revolved within the cell, and numerous separated granules coursed round and round it, making the complete circuit of the cavity.



Fig. 18.



Development of the areolar tissue (white fibrous element);—  
4. Nucleated cells, of a rounded form. 5, 6, 7. The same, elongated in different degrees, and branching. At 7, the elongated extremities have joined others, and are already assuming a distinctly fibrous character. — (Schwann.)

Henlé ascribes the formation of cellular tissue to quite a different process, as will be afterwards explained. He admits the occurrence of spindle-shaped cells, split or ramified at their ends, both in healthy tissues and in diseased growths, but he thinks they do not give origin to the fibres of cellular tissue. Though colourless, they seem allied to the system of ramified pigment cells.

4. Changes in the relation of cells to each other.

a. Cells may remain isolated, as in the instance of the corpuscles of blood, chyle, and lymph, and those formed in certain secretions. The first-mentioned corpuscles float freely in fluid, which may be looked on as a sort of liquid blastema.

b. They may be united into a continuous tissue, by means of a sufficiently consistent intercellular substance; their parietes remaining distinct. The epithelium and the cuticle, with its appendages, afford instances of this.

c. The parietes of adjoining cells may be inseparably blended with each other, or with the intercellular substance; the sides of the cells being usually thickened, or their cavities almost filled up, by deposits in the interior. Cartilage is an example.

d. The parietes of adjacent cells coalesce at particular points, and, absorption taking place, their cavities become united. It is supposed that ramified cells may thus open into one another, and Schwann conceives that the networks of capillary vessels originate in that way. In other instances the coalescing cells are placed in a longitudinal series, and by their union form a continuous tube, as happens in the vasiform tissues of vegetables. The tubular ducts of some glands are supposed to grow in this manner. In certain cases, the tube formed by united cells becomes the receptacle of new and peculiar matter, which is deposited in it by an ulterior process of organization; thus, according to Schwann, in the formation of muscular and nervous tissue, a tube is first produced by the coalescence of a series of cells, and within this the muscular fibrillæ are formed in the one case, and the peculiar matter of the nervous fibre in the other.

e. We may here also include the process by which Henlé conceives the hairs and some other structures to be formed. Cells placed in a row are supposed to coalesce into a sort of axis; round this axis fibres are laid on, which are themselves derived from elongated or otherwise altered cells; and outside of all is formed an inclosing sheath. Such a structure he names a "complex fibre," or "complex fasciculus," and he supposes that nervous fibres and the fibres (primitive fasciculi) of muscles are formed on the same principle; the matter surrounding



the axis being fluid in nerves, but in muscle arranged into fibrils: as to the mode in which the homogeneous inclosing tube is produced, he is uncertain. The axis of complex fasciculi may persist, or it may disappear.

5. Formation of membranes and fibres from the blastema, without the intervention of actual cells.—As already mentioned, there are certain cases in which there is reason to suppose that the blastema, in place of forming distinct cells, which thereupon become blended, at once gives rise to continuous membranes or fibres. In such cases nuclei are present in the blastema, and subsequently disappear, or undergo metamorphosis; but how far their presence determines the transformation of the surrounding substance, we have no means of deciding.

*a.* The blastema may in this manner form a simple homogeneous film, from which the nuclei for the most part disappear. The capsule of the lens, and the brittle layer on the posterior part of the cornea, are instances of such simple glass-like membranes, and probably arise in the way mentioned.

*b.* A membrane being produced, as in the last case, fine fibrillæ, uniting together in a reticular manner, may be formed on it, seemingly by the deposition and coalescence of minute granules. Then, frequently, the membrane is itself partially or wholly absorbed, leaving nothing but the network of fibrils. The fibrils withstand the action of acetic acid, and in this respect agree with the nuclear fibres, to be afterwards mentioned. An instance of this structure occurs in one of the coats of the arteries.

*c.* In the formation of the cellular, fibrous, and some other tissues, according to Henlé's view of that process, the blastema is first converted into long flattened bands, which lie between parallel rows of nuclei. Each of these bands, which are not more than  $\frac{1}{1000}$  of an inch broad, is then subdivided into a bundle of fine, parallel fibrils, which soon acquire the waved aspect characteristic of the microscopic filamentous bundles of the cellular and fibrous tissues. While this goes on, the nuclei undergo remarkable changes, to be immediately noticed.

6. Changes in the nuclei of cells.—The nucleus may grow somewhat larger as the cell increases in magnitude, at least at first; thus it enlarges and flattens in epithelium cells. It may then remain without farther change, or it may disappear: it is persistent in most varieties of epithelium, but in the flattened cells of the cuticle and nails it disappears. In other cases, the substance of the nucleus may undergo a chemical change, of which the occasional productions of fat globules in the nuclei of cartilage cells is an example.

We have already spoken of proliferous nuclei, which are resolved into young cells.

In many tissues composed of fibres, as the cellular, the fibrous, the substance of the cornea, and the muscular tissue, the nuclei become lengthened and attenuated, and often crescentic, crooked, or serpentine; in which state they may be seen lying between the fibres of the tissue, on applying acetic acid, in which they are insoluble. Having



reached this condition they may then disappear, being first broken up into rows of little dots. But many of them, instead of vanishing, extend themselves at both ends into a fibre, which meets and joins with similar prolongations from neighbouring nuclei; the little bodies themselves getting gradually thinned down, so that, in some cases, all trace of them in the thread is lost. In this manner a second set of fibres are produced, which have been appropriately named "nuclear fibres." The nuclear fibres lie between the other fibres, or bundles of fibrils, of the tissue in which they occur; sometimes parallel with these, like the rows of nuclei from which they were derived, sometimes winding round them, sometimes alternating with them in layers. They are remarkable for their dark, well-defined outline, and, like the nuclei themselves, are insoluble in acetic acid; so that, by means of that reagent, they may be rendered conspicuous amidst the other elements of the tissue with which they are mixed. It will be afterwards seen that they strongly resemble the fibres of yellow elastic tissue; it is probable, indeed, that the two are identical.

7. *Ultior changes in the Blastema.*—*Intercellular Substance.*—The blastema is usually in great part consumed in the progress of development, but a small portion remains between the cells or other elements of the tissues, generally increasing in consistency, and serving to cement them together; it then constitutes the intercellular or intermediate substance. This substance varies in its condition and aspect; it is represented as being granular in the cellular tissue; in cartilage it is at first pellucid and hyaline, but often undergoes a change, and becomes fibrous; in ossifying cartilage it is hardened and calcified by deposition of earthy salts. In cartilage, moreover, the substance interposed between the cell-cavities increases in quantity as development advances; but, as in this case there is also a thickening of the cell-walls, which are blended with the intervening substance, it is impossible to say how far the increase in question is due to true intercellular deposit.

#### NUTRITION AND REGENERATION OF THE TEXTURES.

*Nutrition.*—The tissues and organs of the animal body, when once employed in the exercise of their functions, are subject to continual loss of material, which is restored by nutrition. This waste or consumption of matter, with which, so to speak, the use of a part is attended, takes place in different modes and degrees in different structures. In the cuticular textures the old substance simply wears away, or is thrown off at the surface whilst fresh material is added from below. In muscular texture, on the other hand, the process is a chemical or chemico-vital one; the functional action of muscle is attended with an expenditure of moving force, and a portion of matter is consumed, whether directly or indirectly in the production of that force; that is, it undergoes a chemical change, and being by this alteration rendered unfit to serve again, is removed by absorption. The amount of matter changed in a given time, or, in other words, the rapidity of the nutri-



tive process, is much greater in those instances where there is a production and expenditure of force, than where the tissue serves merely passive mechanical purposes. Hence, the bones, tendons, and ligaments are much less wasted in exhausting diseases than the muscles, or than the fat, which is consumed in respiration, and generates heat. Up to a certain period, the addition of new matter exceeds the amount of waste, and the whole body, as well as its several parts, augments in size and weight: this is "growth." When maturity is attained, the supply of material merely balances the consumption; and after this, no steady increase takes place, although the quantity of some matters in the body, especially the fat, is subject to considerable fluctuation at all periods of life.

It would be foreign to our purpose to enter on the subject of nutrition in general; we may, however, briefly consider the mode in which the renovation of substance is conceived to be carried on in the tissues.

The material of nutrition is immediately derived from the plasma of the blood, or liquor sanguinis, which is conveyed by the blood-vessels, and transudes through the coats of their capillary branches; and it is in all cases a necessary condition that this matter should be brought within reach of the spot where nutrition goes on, although, as will immediately be explained, it is not essential for this purpose that the vessels should actually pass into the tissue.

In cuticle and epithelium, the nutritive change is effected by a continuance of the process to which these textures owe their origin. The tissues in question being devoid of vessels, nutrient matter, or blastema, is furnished by the vessels of the true skin, or subjacent vascular membrane; cells arise in the blastema, enlarge, alter in figure, often also in chemical nature, and, after serving for a time as part of the tissue, are thrown off at its free surface.

But it cannot in all cases be so clearly shown that nutrition takes place by a continual formation and decay of the structural elements of the tissue; and it must not be forgotten, that there is another conceivable mode in which the renovation of matter might be brought about, namely, by a molecular change which renews the substance, particle by particle, without affecting the form or structure. Still, although conclusive evidence is wanting on the point, it seems probable that something more than a mere molecular change generally takes place, but of what precise nature, is, as yet, only matter of conjecture. Some have supposed that the nuclei seen among the fibres of many tissues may probably minister to their nutrition, and it has been imagined that these nuclei may serve as centres of assimilation and increase, inducing a deposition and organization of matter in their neighbourhood, and propagating themselves by spontaneous division.

In the instance of cuticle and epithelium, no vessels enter the tissue, but the nutrient fluid which the vessels afford, penetrates a certain way into the growing mass, and the cells continue to assimilate this fluid, and pass through their changes at a distance from, and independently of, the blood-vessels. Whether, in such cases, the whole of the residuary blastema remains as intercellular substance, or whether a part is



again absorbed into the vessels, is not known. In other non-vascular tissues, such as articular cartilage, the nutrient fluid is doubtless, in like manner conveyed by imbibition through their mass, where it is then attracted and assimilated. The mode of nutrition of these and other non-vascular masses of tissue may be compared, indeed, to that which takes place throughout the entire organism in cellular plants, as well as in polypes, and some other simple kinds of animals, in which no vessels have been detected. But even in the vascular tissues the case is not absolutely different; in these, it is true, the vessels traverse the tissue, but they do not penetrate into its structural elements. Thus the capillary vessels of muscle pass between and around its fibres, but they do not enter them; still less do they penetrate the fibrillæ within the fibre: these, indeed, are much smaller than the finest vessel. The nutrient fluid, on exuding from the vessels, has here, therefore, as well as in the non-vascular tissues, to permeate the adjoining mass by transudation, in order to reach these elements, and yield new substance at every point where renovation is going on. The vessels of a tissue have, indeed, been not unaptly compared to the artificial channels of irrigation which distribute water over a field; just as the water penetrates and pervades the soil which lies between the intersecting streamlets, and thus reaches the growing plants, so the nutritious fluid, escaping through the coats of the blood-vessels, must permeate the intermediate mass of tissue which lies in the meshes of even the finest vascular network. The quantity of fluid supplied, and the distance it has to penetrate beyond the vessels, will vary according to the proportion which the latter bear to the mass requiring to be nourished.

We have seen that in the cuticle the decayed parts are thrown off at the free surface; in the vascular tissues, on the other hand, the old or effete matter must be first reduced to a liquid state, then find its way into the blood-vessels, or lymphatics along with the residual part of the nutritive plasma, and be by them carried off. But, in certain cases, the mode of removal of the old matter is not clear; as, for example, in the crystalline lens, which is destitute of vessels, and grows by deposition of blastema and formation of cells at its surface: here we should infer that the oldest parts were nearest the centre, and, if we suppose them to be changed in nutrition, it is puzzling to account for their removal.

From what has been said, it is clear that the vessels are not proved to perform any other part in the series of changes above described, beyond that of conveying matter to and from the scene of nutrition; and that this, though a necessary condition, is not the essential part of the process. The several acts of assuming and assimilating new matter, of conferring on it organic structure and form, and of disorganizing again that which is to be removed, which are so many manifestations of the metabolic and plastic properties already spoken of, are performed beyond the blood-vessels. It is plain, also, that a tissue, though devoid of vessels, and the elements of a vascular tissue, though placed at an appreciable distance from the vessels, may still be organized and living structures, and within the dominion of the nutritive process. How far the sphere of nutrition may, in certain cases be limited, is a question that still needs further investigation; in the cuticle, for example, and its appendages, the nails and hairs, which are placed on the surface of the body, we must suppose that the old and dry part, which is about to be thrown off, or worn away, has passed out of the limits of nutritive



influence ; but to what distance beyond the vascular surface of the skin the province of nutrition extends, has not been determined.

*Regeneration.*—When part of a texture has been lost or removed, the loss may be repaired by regeneration of a new portion of tissue of the same kind ; but the extent to which this restoration is possible is very different in different textures. Thus, in muscle, a breach of continuity may be repaired by a new growth of cellular tissue ; but the lost muscular substance is not restored. Regeneration occurs in nerve, but only in a very limited degree : in bone it takes place much more readily and extensively, and still more so in fibrous and cellular tissue. The special circumstances of the regenerative process in each tissue will be considered hereafter ; but we may here state generally, that, as far as is known, the reproduction of a texture is effected in the same manner as its original formation ; lymph or fibrin derived from the liquor sanguinis is deposited as blastema, and in this the elements of the tissue appear in the way already described.

In experimental inquiries respecting regeneration, we must bear in mind, that the extent to which reparation is possible, as well as the readiness with which it occurs, is much greater in many of the lower animals than in man. In newts, and some other cold-blooded vertebrata, indeed, (not to mention still more wonderful instances of regeneration in animals lower in the scale,) an entire organ, a limb, for example, is readily restored, complete in all its parts, and perfect in all its tissues.

In concluding what it has been deemed advisable in the foregoing pages to state respecting the development of the textures, we may remark, that, besides what is due to its intrinsic importance, the study of this subject derives great additional interest from the aid it promises to afford in its application to pathological inquiries. Researches which have been made within the last few years, and which are still zealously carried on, tend to show that the structures which constitute morbid growths, are formed by a process analogous to that by which the natural or sound tissues are developed : some of these morbid productions, indeed, are in no way to be distinguished from cellular, fibrous, cartilaginous, and other natural structures, and have, doubtless, a similar mode of origin ; others, again, as far as yet appears, are peculiar in structure and composition, but still their production is with much probability to be referred to the same general process. The prosecution of this subject, however, does not fall within the scope of the present work.



# OSTEOLOGY.

---

## BONE OR OSSEOUS TISSUE.

THE bones are the principal organs of support, and the passive instruments of locomotion. Connected together in the skeleton, they form a framework of hard material, which affords attachment to the soft parts, maintains them in their due position, and shelters such as are of delicate structure, giving stability to the whole fabric, and preserving its shape; and the different pieces of the skeleton, being jointed moveably together, serve also as levers for executing the movements of the body.

In their outward form the bones present much diversity, but have been reduced by anatomists to the following classes:—1. Long or cylindrical, such as the chief bones of the limbs. These consist of a body or shaft, cylindrical or more frequently angular in shape, and two ends, or heads, as they are often called, which are usually much thicker than the shaft. The heads, or ends, have smooth surfaces for articulation with neighbouring bones. The shaft is hollow and filled with marrow, by which sufficient magnitude and strength are attained without undue increase of weight. 2. Tabular or flat bones, like the scapula, the ilium, the ribs, the lower jaw, and the bones forming the roof and sides of the skull. Many of these contribute to form the walls of cavities. 3. Short bones, often also called round bones, though most of them rather are angular; the wrist and tarsus afford examples of these. 4. Irregular or mixed bones, which would, perhaps, be better named “complex;” such as cannot be entirely referred to any of the foregoing classes. These are mostly situated in the median plane, and have a complex but symmetrical figure; the vertebræ may be taken as instances of them.

The surfaces of bones present various eminences, depressions, and other marks; and, to designate these in descriptive osteology, certain general terms are employed, of which the following are those most commonly in use.

1. Eminences. To any prominent elevation jutting out from the surface of a bone the term “process” or “apophysis” is applied. It often happens that such a process is originally ossified separately from the rest of the bone, and remains long unconnected with the main body (by osseous union at least); in this condition it is named an “epiphysis.” In many bones, considerable portions at the extremities or most prominent parts are originally ossified separately as epiphyses. This is the case with the ends of the long bones, and in this instance the shaft is named the “diaphysis.”

Processes or apophyses are further designated according to their different forms. A slender, sharp, or pointed eminence is named a



"spine" or "spinous process;" a tubercle, on the other hand, is a blunt prominence; a "tuberosity" (tuber) is broader in proportion to its elevation, and has a rough uneven surface. The term "crest" is usually applied to the prominent border of a bone, or to an elevation running some way along its surface; but the latter is more commonly denominated a "line" or "ridge." A "head" (caput, capitulum, or capitellum) is a rounded process, supported on a narrower part named its neck (cervix). A "condyle" has been defined to be an eminence bearing a flattened articular surface; but this term has been very variously applied by anatomists both ancient and modern.

2. Cavities and depressions of bones. An aperture or perforation in the substance of a bone is named a "foramen." A passage or perforation often runs for some way in the bone, and then it is termed a "canal" or "meatus." On the other hand, it may assume the form of a "fissure," and is named accordingly. A "fossa" is an open excavation or depression on the surface of a bone, or of a part of the skeleton formed by several bones. A fossa may form part of a joint, and be adapted to receive the prominent part of a neighbouring bone: it is then said to be "glenoid," when shallow; but a deep excavation, of which the socket for the head of the thigh-bone is an example, is named a "cotyloid" cavity. The meaning of the terms "notch" (incisura) and "groove" or "furrow" (sulcus) is sufficiently plain. "Sinus" and "antrum" are names applied to certain large cavities situated within the bones of the head, and opening into the nose.

In the recent state, bones are covered with periosteum and filled with marrow; they also receive vessels for their nutrition. These soft structures will be noticed in due time, but we shall in the first place consider the proper bony substance.

Bone has a white colour, with a pink and slightly bluish tint in the living body. Its hardness is well known, but it also possesses a certain degree of toughness and elasticity; the last property is peculiarly well marked in the ribs. Its specific gravity is from 1.87 to 1.97.

It consists of an earthy and an animal part, intimately combined together; the former gives hardness and rigidity, the latter tenacity to the osseous tissue.

The earthy part may be obtained separate by calcination. When bones are burned in an open fire, they first become quite black, like a piece of burnt wood, from the charring of their animal matter; but if the fire be continued with free access of air, this matter is entirely consumed, and they are reduced to a white, brittle, chalk-like substance, still preserving their original shape, but with the loss of about a third of their weight. The earthy constituent, therefore, amounts to about two-thirds of the weight of the bone. It consists principally of phosphate of lime, with about a fifth part of carbonate of lime, and much smaller proportions of fluoride of calcium, chloride of sodium, and magnesian salts.

The animal constituent may be freed from the earth, by steeping a bone in diluted nitric or hydrochloric acid. By this process the salts of lime are dissolved out, and a tough, flexible substance remains,



which, like the earthy part, retains the perfect figure of the original bone in its minutest details, so that the two are evidently combined in the most intimate manner. The animal part is often named the cartilage of bone, but improperly, for it differs entirely from cartilage in structure, as well as in physical properties and chemical constitution. It is much softer and much more flexible, and by boiling it is almost wholly resolved into gelatin. It may accordingly be extracted from bones, in form of a jelly, by boiling them for a considerable time, especially under high pressure.

The earthy or saline matter of bone, as already stated, constitutes about two-thirds or 66·7 per cent, and the animal part one-third, or 33·3 per cent; but the bones of children, which are known to be less rigid than those of adults, yield more animal matter, and those of aged persons more earth. A difference, too, has been observed in different bones of the skeleton. Thus, according to Dr. Rees, the bones of the head and of the limbs contain more earth than those of the trunk. It still, however, remains to be determined whether these differences apply to the constitution of the bony matter strictly so called, or whether they may not be occasioned by the different proportions of membranous substance and other soft tissues contained in the minute cavities of bones, and not so perfectly separable from them as to leave a pure material for analysis.

Subjoined are the statements of two analyses. The one, by Berzelius, is well known; the other, which nearly agrees with it, was performed by Mr. Middleton, in the laboratory of University College.<sup>1</sup>

	Berzelius.	Middleton.
Animal matter . . . . .	33·30	— 33·43
Phosphate of lime . . . . .	51·04	— 51·11
Carbonate of lime . . . . .	11·30	— 10·31
Fluoride of calcium . . . . .	2·00	— 1·99
Magnesia, wholly or partially in the state of phosphate . . . . .	1·16	— 1·67
Soda and chloride of sodium . . . . .	1·20	— 1·68

The phosphate of lime is peculiar, and passes in chemistry under the name of the "bone-earth phosphate." It is a tribasic phosphate, consisting probably of 8 equivalents of lime and one of water, with 3 eq. of phosphoric acid. The carbonate is said by Denis to exist in larger proportion in the bones of children. The fluoride of calcium is found in larger quantity in fossil than in recent bones, —indeed, its presence in the latter was lately denied altogether; but since then, the original statements of Morichini and of Berzelius to the effect that it exists in recent as well as fossil bones, have been satisfactorily confirmed.<sup>2</sup>

On sawing up a bone, it will be seen that it is in some parts dense and close in texture, appearing like ivory; in others, open and reticular; and anatomists accordingly distinguish two forms of osseous tissue, viz., the *compact*, and the *spongy* or *cancellated*. On closer examination, however, especially with the aid of a magnifying glass, it will be found that the bony matter is everywhere porous in a greater or less degree, and that the difference between the two varieties of tissue depends on the different amount of solid matter compared with the size and number of the open spaces in each; the cavities being very small in the compact parts of the bone with much dense matter between them: whilst in the cancellated texture the spaces are large, and the intervening bony partitions thin and slender. There is, accordingly, no abrupt limit between the two,—they pass into one another by degrees, the cavities of the compact tissue widening out,

<sup>1</sup> Philosophical Magazine, vol. xxv. p. 18.

<sup>2</sup> By Dr. Daubeny, Phil. Mag. vol. xxv. p. 122; and Mr. Middleton, loc. cit.



and the reticulations of the cancellated becoming closer as they approach the parts where the transition takes place.

In all bones, the part next the surface consists of compact substance, which forms an outer shell or crust, whilst the spongy texture is contained within. In a long bone, the large rounded ends are made up of spongy tissue, with only a thin coating of compact substance; in the hollow shaft, on the other hand, the spongy texture is scanty, and the sides are chiefly formed of compact bone, which increases in thickness from the extremities towards the middle, at which point usually the girth of the bone is least, whilst the strain on it is there greatest. In tabular bones, such as those of the skull, the compact tissue forms two plates, or tables as they are called, inclosing between them the spongy texture, which in such bones is usually named *diploe*. The short bones, like the ends of the long, are spongy throughout, save at their surface, where there is a thin crust of compact substance. In the irregular or mixed bones, the two substances have the same general relation to each other; but the relative amount of each in different parts, as well as their special arrangement in particular instances, is very various.

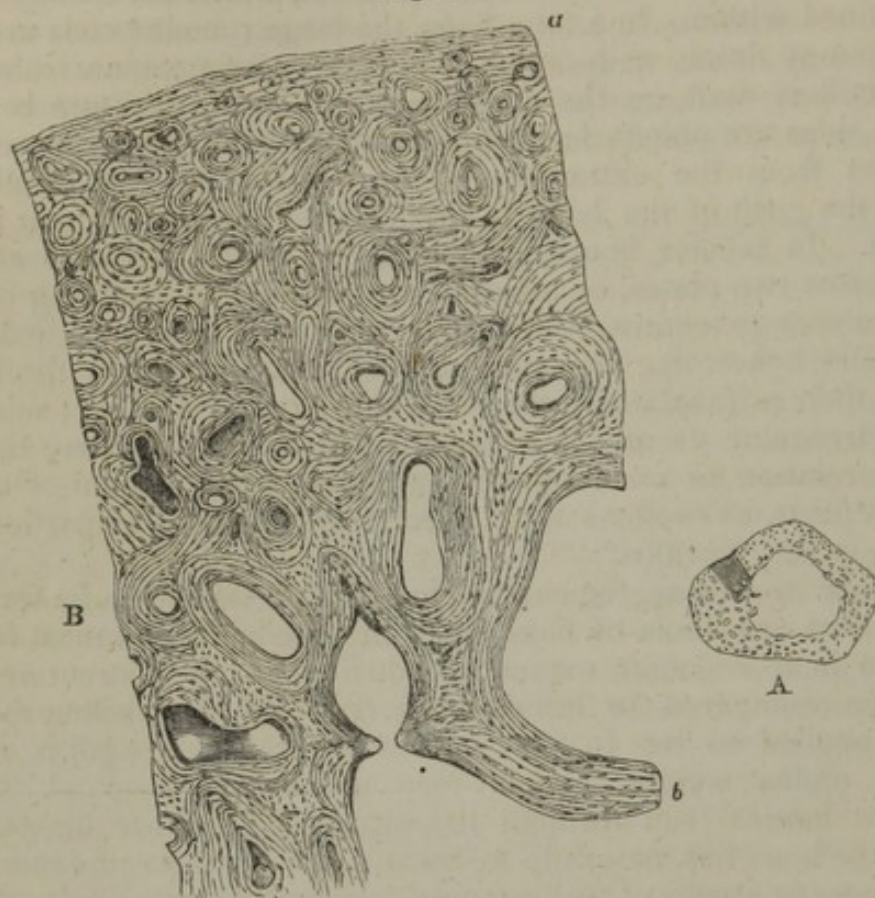
On close inspection, the cancellated texture is seen to be formed of slender bars or spicula of bone and thin lamellæ, which meet together and join in a reticular manner, producing an open structure which has been compared to lattice-work (*cancelli*), and hence the name usually applied to it. In this way considerable strength is attained without undue weight, and it may usually be observed that the strongest laminæ run through the structure in those directions in which the bone has naturally to sustain the greatest pressure. The open spaces or areolæ of the bony network communicate freely together; in the fresh state they contain marrow or blood-vessels, and give support to these tender structures.

The compact tissue is also full of holes; these, which are very small, are best seen by breaking across the shaft of a long bone near its middle, and examining it with a common magnifying glass. Numerous little round apertures (fig. 19, A) may then be seen on the broken surface, which are the openings of short longitudinal passages running in the compact substance, and named the Haversian canals, after Clopton Havers, an English physician and writer of the seventeenth century, who more especially called attention to them. Blood-vessels run in these canals, and the widest of them also contain marrow. They are from  $\frac{1}{1000}$  to  $\frac{1}{200}$  of an inch in diameter: I have measured some which were no more than  $\frac{1}{2000}$ , but these are rare; the medium size is about  $\frac{1}{300}$ . The widest are those nearest the medullary cavity, and they are much smaller towards the circumference of the bone. They are quite short, as may be seen in a longitudinal section, and somewhat crooked or oblique at their ends, where they freely open into one another, their oblique communications connecting them both longitudinally and laterally. Those also which are next the circumference of the bone open by minute pores on its external surface, and the innermost ones open widely into the medullary cavity; so that these short channels collectively form a sort of irregular network of tubes running through the compact tissue, in which the ves-



sels of that tissue are lodged, and through the medium of which these vessels communicate together, not only along the length of the

Fig. 19.



A. Transverse section of a bone (ulna) deprived of its earth by acid. The openings of the Haversian canals seen. Natural size. A small portion is shaded to indicate the part magnified in fig. B.

B. Part of the section A magnified 20 diameters. The lines indicating the concentric lamellæ are seen, and among them the corpuscles or lacunæ appear as little dark specks.

bone, but from its surface to the interior, through the thickness of the shaft. The canals of the compact tissue in the other classes of bones have the same general characters, and for the most part run parallel to the surface.

On viewing a thin transverse section of a long bone with a microscope of moderate power, especially after the earthy part has been removed by acid (fig. 19, B), the opening of each Haversian canal appears to be surrounded by a series of concentric rings. This appearance is occasioned by the transverse sections of concentric lamellæ which surround the canals. The rings are not all complete, for here and there one may be seen ending between two others. In some of the sets the rings are nearly circular, in others oval,—differences which seem mostly to depend on the direction in which the canal happens to be cut; the aperture, too, may be in the centre, or more or less to one side, and in the latter case the rings are usually narrower and closer together on the side towards which the aperture deviates. Again, some of the apertures are much lengthened or angular in shape, and the lamellæ surrounding them have a corresponding disposition.

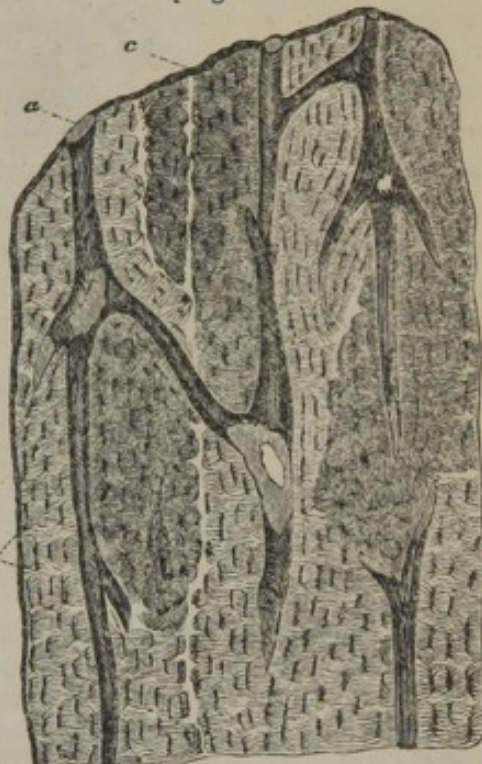

Besides the lamellæ surrounding the Haversian canals, there are others disposed conformably with the circumference of the bone (fig. 19, B a), and which may therefore be said to be concentric with the medullary canal; some of these are near the surface of the bone, others run between the Haversian sets, by which they are interrupted in many places. Lastly, in various parts of the section, lines are seen which indicate lamellæ, differing in direction from both of the above-mentioned orders.

The appearance in a longitudinal section of the bone is in harmony with the account just given (fig. 20); the sections of the lamellæ are seen as straight and parallel lines, running in the longitudinal direction of the bone, except when the section happens to have passed directly or slantingly across a canal; for wherever this occurs there is seen, as in a transverse section, a series of rings, generally oval and much lengthened on account of the obliquity of the section.

The cancellated texture has essentially the same lamellar structure. The slender bony walls of its little cavities or areolæ are made up of superimposed lamellæ, like those of the Haversian canals (fig. 19, B, b), only they have fewer lamellæ in proportion to the width of the cavities which they surround; and, indeed, the relative amount of solid matter and open space constitutes, as already said, the only difference between the two forms of bony tissue; the intimate structure of the solid

[Fig. 20.]



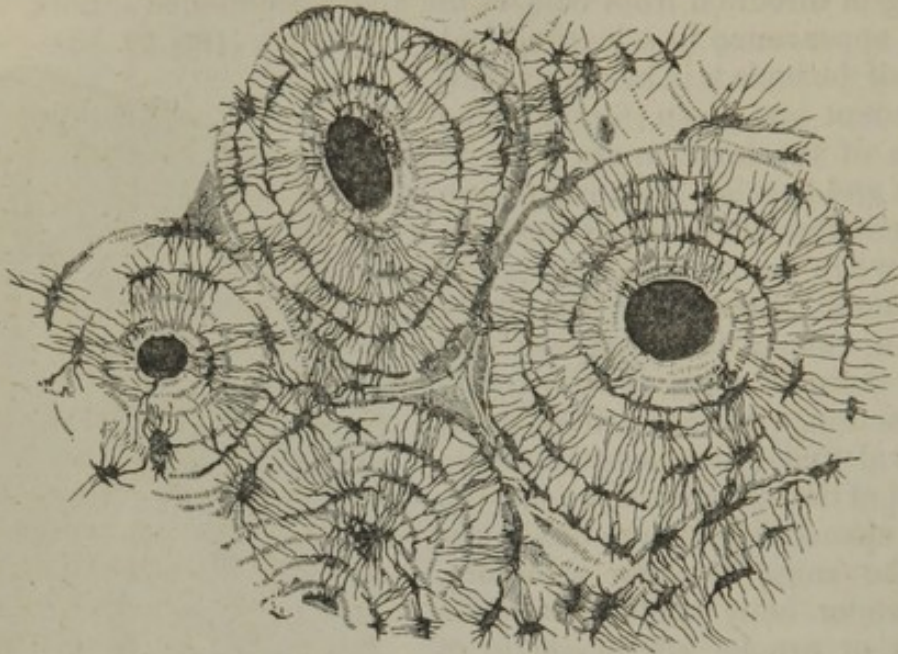
Longitudinal section of bone, from the os femoris, highly magnified. a. Haversian canals; b. osseous lacunæ, or Purkinjean corpuscles; c. clearer interspaces, separating the Haversian columns, and indicating the primary or earliest ossification. From nature, by J. L.] substance and the manner of its disposition round the cavities being essentially the same in both.

All over the section numerous little dark specks are seen among the lamellæ. These were named the "osseous corpuscles;" [or the "corpuscles of Purkinje," after their discoverer;] but as it is now known that they are in reality minute cavities existing in the bony substance, the name of "lacunæ" has since been more fittingly applied to them. To see the lacunæ properly, however, sections of unsoftened bone must be prepared and ground very thin, and a magnifying power of from 200 to 300 must be employed. Such a section viewed with transmitted light, has the appearance represented in fig. 21. The openings of the Haversian canals are seen with their encircling lamellæ, and among these the corpuscles or lacunæ, which are mostly ranged in a corresponding order, appear as black or very dark brown and nearly opaque, oblong spots, with fine dark lines extending from them, and causing them to look not unlike little black insects; but when the



same section is seen against a dark ground, with the light falling on it (as we usually view an opaque object), the little bodies and lines appear quite white, like figures drawn with chalk on a slate, and the intermediate substance, being transparent, now appears dark.

Fig. 21.



Transverse section of compact tissue (of humerus) magnified about 150 diameters. Three of the Haversian canals are seen, with their concentric rings; also the corpuscles or lacunæ, with the canaliculi extending from them across the direction of the lamellæ. The Haversian apertures had got filled with debris in grinding down the section, and therefore appear black in the figure, which represents the object as viewed with transmitted light.

The lacunæ, as already said, are minute recesses in the bone, and the lines extending from them are fine pores or tubes named "canaliculi," which issue from their cavity. The true nature of the canaliculi, as well as of the lacunæ, may be seen by watching the passage of fluids along them.

The lacunæ present some variety of figure, but in such a section as that represented (fig. 21), they for the most part appear irregularly fusiform, and lie nearly in the same direction as the lamellæ between which they are situated; or, to speak more correctly, the little cavities are flattened and extended conformably with the lamellæ; for when the bone is cut longitudinally, their sections still appear fusiform, and are lengthened out in the direction of the lamellæ (fig. 20). The canaliculi, on the other hand, pass across the lamellæ, and they communicate with those proceeding from the next range of lacunæ, so as to connect the little cavities with each other; and thus, since the canaliculi of the most central range open into the Haversian canal, a system of continuous passages is established by these minute tubes and their lacunæ, along which fluids may be conducted from the Haversian canal through its series of surrounding lamellæ; indeed it seems probable that the chief purpose of these minute passages is to convey nutrient fluid from the vascular Haversian canals through the mass of hard bone which lies around and between them. In like manner the canaliculi open



into the great medullary canal, and into the cavities of the cancellated texture; for the thin bony parietes of these cavities contain lacunæ, as indeed all parts of the bony tissue. Mr. Tomes has remarked that the lacunæ belonging to one system of Haversian lamellæ do not often communicate with those of another; the outermost of the series, it is true, send off canaliculi from their further side; but these canaliculi, for the most part, turn or "droop back" again towards the centre. The opaque whiteness of the lacunæ and canaliculi may be removed by an acid; it seems to be owing to some peculiarity in the osseous matter which immediately adjoins these cavities and forms their surface or parietes, and which may differ perhaps in its state of aggregation: there is no sufficient reason for believing that this opaque bone contains more earth than the surrounding transparent part, as was at one time supposed.

To return to the lamellæ. With a little pains thin films may be peeled off in a longitudinal direction from a piece of bone that has been softened in acid. These for the most part consist of several laminæ, as may be seen at the edge, where the different layers are usually torn unequally and some extend farther than others. Examined in this way, under the microscope, the lamellæ are seen to be perforated with fine apertures placed at very short distances apart. These apertures were described by Deutsch,<sup>1</sup> but they have not much attracted the notice of succeeding observers: they appear to me to be the transverse sections of the canaliculi already described, and their relative distance and position accord sufficiently with this explanation. According to this view, therefore, the canaliculi might (in a certain sense) be conceived to result from the apposition of a series of perforated plates, the apertures of each plate corresponding to those of the plates contiguous with it; in short, they might be compared to holes bored to some depth in a straight or crooked direction through the leaves of a book, in which case it is plain that the perforations of the adjoining leaves would correspond.

But the lamellæ have a further structure. To see this the thinnest part of a detached shred or film must be examined, as shown in fig. 22; it will then appear plainly that they are made up of transparent fibres, decussating each other in form of an exceedingly fine network, and that the perforations correspond to the intervals or openings between the reticulated fibres. The fibres intersect obliquely, and they seem to coalesce at the points of intersection, for they cannot be teased out from one another; but at the torn edge of the lamella they may often be seen separate for a little way, standing out like the threads of a fringe.

Fig. 22.



Thin layer peeled off from a softened bone, as it appears under a magnifying power of 400. The figure, which is intended to represent the reticular structure of a lamella, gives a better idea of the object when held rather farther off than usual from the eye.

<sup>1</sup> Not having been able to see Deutsch's work (*De Penitiori Ossium Structura*), I refer to the account of his observations given by Müller in his *Physiology*, 1st. edit., page 377 of translation.



Most generally they are straight, as represented in the figure; but they are not always so, for in some parts they assume a curvilinear direction. Acetic acid causes these fibres to swell up and become indistinct, like the white fibres of cellular and fibrous tissue.

It thus appears that the animal tissue of bone is made up of superimposed laminæ, and that these laminæ are composed of fine reticular fibres. This is unquestionably the general structure; but it may be asked, Is it universal? I am not prepared to answer this question in the affirmative, for, besides what may be inferred from the development of bone, I have seen here and there in the softened adult bone an appearance as if of flattened cells connected together by their edges. I am disposed to think that this apparently cellular structure, which is not general, occurs chiefly at the circumference of a series of Haversian lamellæ,—that is, beyond the outermost of the series.

Another question refers to the mode in which the earthy particles are connected with the animal texture. We know that the combination is very intimate, but the manner in which it is effected is not clear. Mr. Tomes has pointed out, that, by calcination, or by prolonged boiling in a Papin's digester, the osseous substance may be obtained in form of minute granules, varying in size from  $\frac{1}{80000}$  to  $\frac{1}{14000}$  of an inch. He states that they cohere firmly together, and in some few instances he has met with a very minute network, which seemed adapted to receive them in its interstices.<sup>1</sup> Fine spicula of growing bone have often a very decidedly granular aspect.

The periosteum, as already stated, is a fibrous membrane which covers the bones externally. It adheres to them very firmly, and invests every part of their surface, except where they are covered with cartilage or connected to other bones by fibro-cartilage. Numerous blood-vessels, destined for the bone, ramify in the periosteum, and at length send their minute branches into the Haversian canals of the compact substance, accompanied by processes of filamentous tissue derived from, or at least continuous with, the periosteum. Pappenheim<sup>2</sup> has recently stated that he has seen numerous fine nervous filaments in the periosteum, chiefly associated with the arteries; but the statement stands in need of confirmation.

The chief use of this membrane is evidently to support the vessels going to the bone, and afford them a bed in which they may subdivide into fine branches, and so enter the dense tissue at numerous points. Hence, when the periosteum is stripped off at any part, there is great risk that the denuded portion of the bone will die and exfoliate. The periosteum also contributes to give firmer hold to the tendons, and ligaments where they are fixed to bones; indeed, these fibrous structures become continuous and incorporated with it at their attachment.

The marrow (medulla ossium) is lodged in the interior of the bones; it fills up the hollow shaft of long bones and occupies the cavities of the cancellated structure; it extends also into the Haversian canals—at least, into the larger ones—along with the vessels. Like ordinary adipose tissue, it consists of vesicles containing fat, with blood-vessels distributed to them. A fine layer of a highly vascular cellular tissue, lines the medullary canal, as well as the smaller cavities which contain marrow; this is named the medullary membrane, or internal periosteum;<sup>3</sup> its vessels partly supply the contiguous osseous substance,

<sup>1</sup> Todd and Bowman, *Physiological Anatomy*, p. 108.

<sup>2</sup> Müller's *Archiv.* 1843, p. 443.

<sup>3</sup> Dr. Walshe suggests the term *endosteum*, which seems a very suitable one.



and partly proceed to the clusters of adipose vesicles, among which there is but very little cellular tissue, in consequence perhaps of their being contained and supported by bone.

The marrow serves the same general purposes in the economy as ordinary fat. Placed within the bones, which, are made hollow for the sake of lightness, it serves as a light and soft material to fill up their cavities and support their vessels. In birds, for the sake of still further lightening their skeleton, the larger bones, in place of being filled with marrow, contain air, which passes into them from the lungs by openings at their extremities. Even in man there are certain hollow bones of the cranium and face which are naturally filled with air. The cavities of these bones are named sinuses; they open into the adjoining air passages, and are lined with a prolongation of the mucous membrane, underneath which is a thin periosteum.

The bones do not at first contain marrow; in the fœtus their cavities are filled with a transparent reddish fluid, like bloody serum, only more consistent and tenacious. In dropsical subjects also, the marrow, like the rest of the fat, is consumed to a greater or less extent, its place being occupied by a serous fluid.

The bones are well supplied with blood-vessels. A network of periosteal vessels covers their outward surface, others penetrate to the cavities of the spongy part and the medullary canal, on the sides of which they ramify, and fine vessels run through all parts of the compact tissue in the Haversian canals. The sides of these internal cavities and canals make up together a large extent of inward surface on which vessels are spread. The nutritious fluid conveyed by these vessels no doubt escapes through their coats and permeates the surrounding dense bone interposed between the vascular canals; and it seems highly probable that the system of lacunæ and communicating canaliculi, already described, is a provision for conducting the fluid through the hard mass. When a bone is macerated, its vessels and membranes are destroyed, whilst the intermediate true bony matter being of an incorruptible and persistent nature, remains; a process which, for obvious reasons, cannot be effected with the soft tissues of the body.

The vessels of bone may be recognised while it is yet fresh by the colour of the blood contained in them; but they are rendered much more conspicuous by injecting a limb with size and vermilion, depriving the bones of their earth by means of an acid, then drying them and putting them into oil of turpentine, by which process the osseous tissue is rendered transparent, whilst the injected matter in the vessels retains its red colour and opacity. Numberless small vessels derived from the periosteum, as already mentioned, pass along the Haversian canals in the compact substance. These are both arterial and venous, but, according to Todd and Bowman, the two kinds of vessels occupy distinct passages; and the veins, which are the larger, present at irregular intervals, pouchlike dilatations calculated to serve as reservoirs for the blood, and to delay its escape from the tissue. Arteries, of larger size but fewer in number, proceed to the cancellated texture. In the long bones numerous apertures may be seen at the ends, near the articular surfaces; some of these give passage to the arteries referred to, but the greater number, as well as the largest of them, are for the veins of the cancellated texture, which run separately from the arteries. Lastly, a considerable artery goes to the



marrow in the central part of the bone; in the long bones this medullary artery, often, but improperly called the "nutritious artery," passes into the medullary canal, near the middle of the shaft, by a hole running obliquely through the compact substance. The vessel, which is accompanied by one or two veins, then sends branches upwards and downwards to the marrow and medullary membrane in the central cavity and adjoining the Haversian canals. Its ramifications anastomose with the arteries of the compact and cancellated structure: indeed, there is a free communication between the finest branches of all the vessels which proceed to the bone, and there is no strictly defined limit between the parts supplied by each. In the thigh-bone there are two medullary arteries entering at different points.

The veins of the cancellated texture are peculiar and deserve special notice. They are large and numerous, and run separately from the arteries. Their arrangement is best known in the bones of the skull, where, being lodged in the diploe or spongy texture between the outer and inner compact tables, they have received the name of the diploic veins. They run in tortuous canals in the cancellated structure; the sides of which are constructed of a thin lamella of bone, perforated here and there for the admission of branches from the adjoining cancelli. The veins, being thus inclosed and supported by the hard structure, have exceedingly thin coats. They issue from the bone by special apertures of large size. A similar arrangement is seen in the bodies of the vertebræ, from whence the veins come out by large openings on the posterior surface.

The lymphatics of the bones are but little known; still, there is evidence of their existence, for, independently of the authority of Mascagni, (which is of less value in this particular instance, inasmuch as he does not state expressly that he injected the vessels which he took for the lymphatics of bone,) we have the testimony of Cruikshank, who injected lymphatics coming out of the body of one of the dorsal vertebræ, in the substance of which he also saw them ramifying.<sup>1</sup>

Fine filaments of nerves have been seen passing into the medullary canal of some of the long bones along with the artery, but their further distribution is doubtful; and, as far as can be judged from observations on man and experiments on the lower animals, the bones, as well as their investing periosteum, are scarcely if at all sensible in the healthy condition, although they are painfully so when inflamed.

Some hold that the same is true of the marrow, or rather the medullary membrane; others, among whom are Duverney and Bichat, affirm, on the contrary, that the medullary tissue is sensible. They state that, on sawing through the bone of a living animal, and irritating the medullary membrane by passing a probe up the cavity or by injecting an acrid fluid, very unequivocal signs of pain will be manifested. Beclard, who affirms the same fact, points out a circumstance which may so far account for the result occasionally turning out differently,—namely, that when the bone happens to be sawn through above the entrance of the medullary artery, the nerves going along with that vessel are divided, and the marrow consequently rendered insensible, as happens with any other sensible part when its nerves are cut.

<sup>1</sup> *Anatomy of the Absorbing Vessels*, 1790, p. 198.

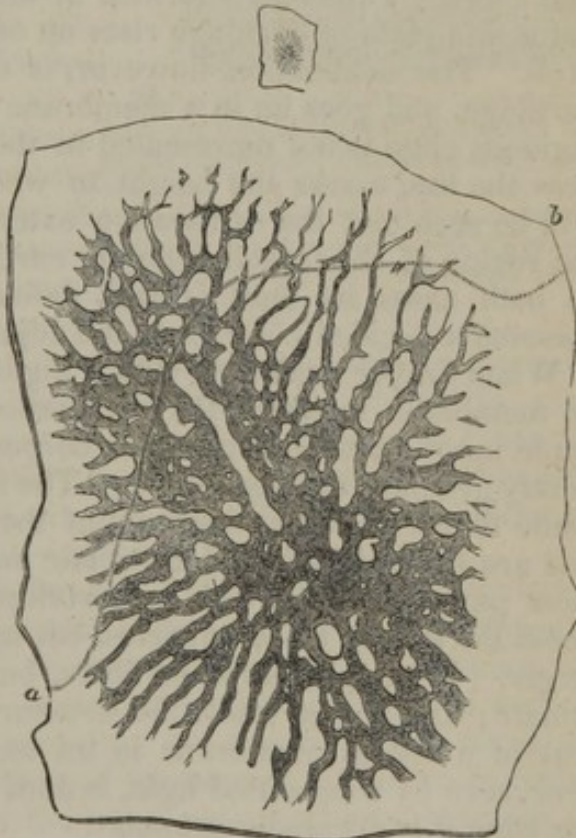


*Formation and growth of bone.*—The foundation of the skeleton is laid at a very early period, for among the parts that appear soonest in the embryo, we distinguish the rudiments of the vertebræ and base of the skull, which afterwards form the great median column to which the other parts of the bony fabric are appended. But it is by their outward form and situation only, that the parts representing the future bones are then to be recognised; for at that early period they do not differ materially in substance from the other structures of the embryo, being, like these, made up of granular corpuscles or elementary cells united together by a soft amorphous matter or blastema. Very soon, however, they become cartilaginous, and ossification in due time beginning in the cartilage and continuing to spread from one or from several points, the bone is at length completed.

But while it is true with respect to the bones generally, that their ossification commences in cartilage, it is not so in every instance. The tabular bones, forming the roof of the skull, may be adduced as a decided example to the contrary; in these the ossification goes on in a membranous tissue quite different in its nature from cartilage;<sup>1</sup> and even in the long bones, in which ossification undoubtedly commences, and to a certain extent proceeds in cartilage, it will be afterwards shown that there is much less of the increment of the bone really owing to that mode of ossification than is generally believed. It is necessary, therefore, to distinguish two species or modes of ossification, which for the sake of brevity may be called the *intramembranous* and the *intracartilaginous*.

*Ossification in membrane.*—The tabular bones of the cranium, as already stated, afford an example of this mode of ossification. The base of the skull in the embryo is cartilaginous; but in the roof, that is to say, the part comprehending the parietal, the upper and greater part of the frontal, and a certain portion of the occi-

Fig. 23.



Parietal bone of an embryo sheep. Size of the embryo,  $2\frac{1}{2}$  inches. The small upper figure represents the bone of the natural size, the larger figure is magnified about 12 diameters. The curved line, *a, b*, marks the height to which the subjacent cartilaginous lamella extended. A few insulated particles of bone are seen near the circumference, an appearance which is quite common at this stage.

<sup>1</sup> This fact was pointed out and insisted on by Dr. Nesbitt, who distinguishes the two different modes of ossification, and so far his views are quite correct.—See his *Human Osteogeny*, Lond. 1736.



pital bones, we find (except where there happen to be commencing muscular fibres) only the integuments, the dura mater, and an intermediate membranous layer, which differs from cartilage in its intimate structure as well as in its more obvious characters, and in which the ossification proceeds.

The commencing ossification of the parietal bone, which may be selected as an example, appears to the naked eye in form of a network, the little bars or spicula of bone running in various directions, and meeting each other at short distances. By and by the ossified part, becoming extended, gets thicker and closer in texture, especially towards the centre, and the larger bony spicula which now appear, run out in radiating lines to the circumference; the ossification continuing thus to spread and consolidate until the parietal meets the neighbouring bones, with which it is at length united by suture.

The adjoining figure (23,) represents the parietal bone of an embryo sheep, about two inches and a half long, and shows the character of the ossification as it appears when the object is magnified about twelve diameters. The bone is formed in membrane as in the human fœtus, but a thin plate of cartilage rises up on its inside from the base of the skull. The ossification, however, is decidedly unconnected with the cartilage, and goes on in a membrane lying outside of it. The cartilaginous plate is not represented in the figure, but a dotted line, *a, b*, near the top, marks the height to which it reached, and from this it will be seen that the ossification extended beyond the cartilage. In the region of the frontal bone the cartilage does not even rise so high. In both cases its limit is well defined, and under the microscope it presents a decided contrast to the adjacent membrane.

When further examined with a higher magnifying power, the tissue or membrane in which the ossification is proceeding, appears to be made up of fibres and granular corpuscles, with a soft, amorphous or faintly granular uniting matter. The fibres have the characters of the white fibres, or rather fasciculi, of the cellular and the fibrous tissue, and are similarly affected by acetic acid. The corpuscles are for the most part true cells, with an envelope and granular contents; some about the size of blood-particles, but many of them two or three times larger. In certain parts the fibres, but in most the corpuscles, predominate; and on the whole the structure might be said to be not unlike that of a fibrous membrane in an early stage of development. The bone, seen by transmitted light, is dark and opaque, and near the growing edge it is decidedly granular.

On now observing more closely the bony processes or spicula at the circumference, where they shoot into the membrane (as in fig. 24), it will be seen, as you trace them into the soft tissue, that they gradually lose their opaque and granular character, indicative of earthy impregnation, and are prolonged a little way into the membrane, in form of bundles of transparent fibres, having all the characters of those of fibrous tissue. These fibres are in some parts closely gathered into thick bundles, but more generally the fasciculi are smaller, and irregularly interlaced or reticulated, with corpuscles lying between



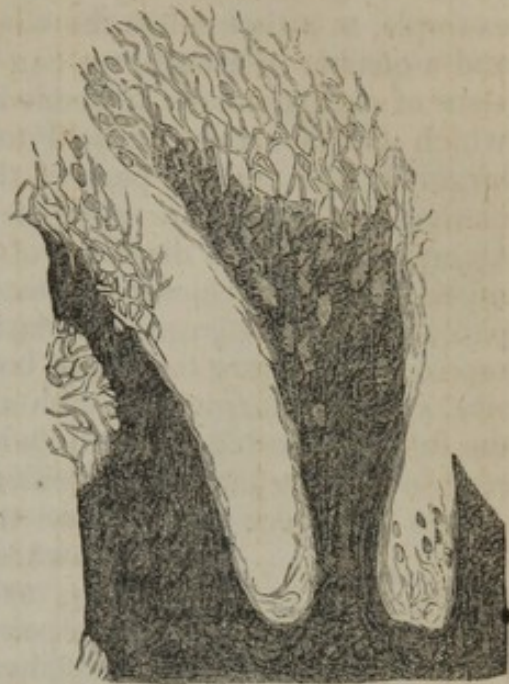them; and we may often observe that where the earthy deposit is advancing to invade the fibres, the recently and as yet imperfectly calcified bone with which they are continuous, presents a similar open and coarsely reticular structure; though the older, harder, and more opaque part is comparatively solid and compact. The appearance referred to is especially well seen at those places where a cross bridge of bone is being formed between two long spicula; we may there distinguish the clear soft fibres which have already stretched across the interval, and the dark granular opacity indicating the earthy deposit may be perceived advancing into them and shading off gradually into their pellucid substance without a precise limit.

It thus appears that in the intramembranous ossification the growing bone shoots into the soft tissue, in form of transparent fibres, resembling those of fibrous texture, more or less intermixed with granular corpuscles, and that these fibres become charged with earthy salts. As to the cells or corpuscles, they certainly seem to be in some way involved in the ossification along with the fibres, but I am not able to say what precise share they have in the process. It has been supposed that they eventually form the lacunæ of the bone; but we shall enter upon this question afterwards.

As the bone extends in circumference it also increases in thickness, the vacuities between the bony spicula become narrowed or disappear, and at a more advanced period the tabular bones of the cranium are tolerably compact towards the centre, although their edges are still formed of slender radiating processes. At this time also numerous furrows are grooved on the surface of the bone in a similar radiating manner, and towards the centre these are continued into canals in the older and denser part, which run in the same direction. The canals, as well as the grooves, which become converted into canals, contain blood-vessels supported by processes of the investing membrane, which deposit concentric layers of bone within; and when thus surrounded with concentric laminæ, these tubular cavities are in fact the Haversian canals.

*Ossification in cartilage.*—It has already been stated that in by far the greater number of bones, the primitive soft cellular matter of which they originally consist is very quickly succeeded by cartilage, in which the ossification begins. One of the long bones taken from a

Fig. 24.



The growing ends of two bony spicula from the frontal bone of an embryo dog, highly magnified. The surrounding membrane has been removed, and most of the corpuscles are washed away, to show more evidently the transparent soft fibres prolonged from the bone, with the dark earthy deposit advancing into them.



very small embryo, just before ossification has commenced in it, is observed to be distinctly cartilaginous. In the tibia of a sheep, for example, at a time when the whole embryo is not more than an inch and a quarter in length, we can plainly see that the substance consists of cartilage-cells imbedded in a pellucid matrix. These cells, which can scarcely be said to be collected into groups, are much larger in the middle part of the shaft where ossification afterwards commences, and there also they are mostly placed with their long diameter across the direction of the bone; towards the ends they are much smaller and closer together, and the cartilage there is less transparent. As it enlarges, the cartilage acquires firmer consistence; it represents in figure the future bone, though of course much smaller in size, and it is surrounded with a fibrous membrane or perichondrium, the future periosteum. Vessels ramify in this membrane, but none are seen in the cartilage until ossification begins.

In a long bone the ossification commences in the middle and proceeds towards the ends, which remain long cartilaginous, as represented in fig. 25. At length, separate points of ossification appear in them, and form epiphyses, which at last are joined to the body of the bone.



Humerus of a fœtus, natural size. The upper half is divided longitudinally. *a*, Cartilage. *b*, Bone, which terminates towards the cartilage by a slightly convex surface.

The new-formed osseous tissue is red and obviously vascular, and blood-vessels extend a little way beyond it into the adjoining part of the cartilage. In a long bone these precursory vessels are seen at either end of the ossified portion of the shaft, forming a red zone in that part of the cartilage into which the ossification is advancing. The vessels are lodged in excavations or branching canals in the cartilage, (fig. 25 *a*,) and seem to ramify in these canals, which are much larger than the vessels they contain. Other vascular canals enter the cartilage from its outer surface, and conduct vessels into it directly from the perichondrium; at least, this may be seen when the ossification approaches near to the ends of the bones.

Dr. Baly has observed that in a transverse section of the ossifying cartilage, its cells appear arranged in radiating lines round the sections of the vascular canals;<sup>1</sup> and I may also remark that in many of these radiating groups the cells successively diminish in size towards the centre, that is, as they approach the canal. It might naturally be asked whether these smaller and more central cells are not more recently deposited, and whether the vascular canals do not minister to the increase of the cartilage; but we are not prepared to give a satisfactory answer to the question. In fact, the precise relation of these canals to the process of ossification is not understood; it is certain, however, that the cavities of the future bone are not formed out of them, as some have supposed.

<sup>1</sup> Müller's Physiology, Plate I., fig. 16.



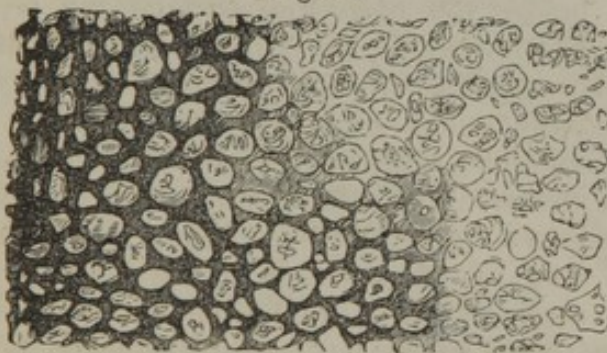
To examine the process more minutely, let an ossifying bone be divided lengthwise, as in fig. 25, and then from the surface of the section (as at *a*, *b*) take off a thin slice of cartilage, including a very little of the ossified part, and examine it with the microscope. Such a view, seen with a low power, is shown in fig. 26.

The cartilage at a distance from the surface of the ossified part has its cells uniformly disseminated in the matrix, (as at *a*, where it appears in the figure as if granular,) but at and near to the limit, where the ossification is encroaching upon it, the cells are gathered into rows or oblong groups, between which the transparent matrix appears in form of clear longitudinal lines obliquely intersecting each other (*b*). Turning now to the newly formed bone (*c*), which from its dark opaque aspect contrasts strongly with the cartilage, and tracing it towards their mutual boundary, you see plainly the dark lines of ossification shooting up into the clear spaces of the cartilage between the groups of corpuscles; it is evident, in short, that the earthy deposit proceeds through the matrix, and that the new osseous substance forms in the first instance oblong areolæ or loculi, which enclose the groups of

Fig. 26.

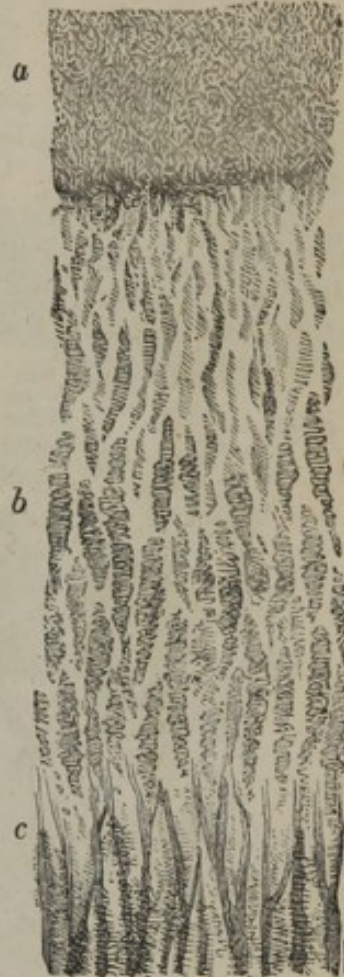

Fig. 27.



Transverse section of the ossifying cartilage represented in fig. 26, made a little above *c*, along the surface of ossification, and including part of the new bone, magnified 70 diameters. The circular sections of the groups of cells and of the osseous areolæ are seen; and the dark bone extending into the clear intercellular matrix.

Thin longitudinal section of ossifying cartilage from the humerus of a foetal sheep, magnified about 70 diameters. *a*, Cartilage cells uniformly diffused; *b*, cells nearer the surface of ossification, collected into piles or oblong groups; *c*, bone shooting up between the groups of cells and forming oblong areolæ.

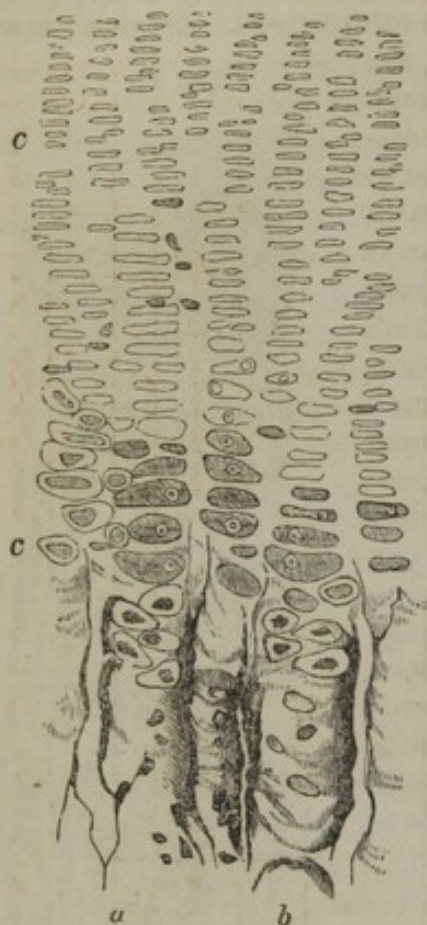
cells. This is further illustrated by a thin transverse section, carried nearly parallel to the ossifying surface, and partly encroaching on it, so as to take off a little of the bone along with the cartilage, as represented in fig. 27. In this view we see at one part the nearly circular sections of the newly formed osseous areolæ; at another, sections of the rows of cartilage cells with the clear matrix between and around them, and into this the dark ossification is advancing.

On using a higher power, as in fig. 28, it will be seen that the cells forming the groups are placed with their long diameter transversely, as if they had been flat-



tened and piled upon one another; but in the immediate vicinity of the bone they become greatly enlarged and more rounded.

Fig. 28.



Small portion of a section similar to that in fig. 26, more highly magnified (about 140 diameters). *a, b*, Two of the new-formed osseous tubes or areolæ, with a few cartilage-cells and granular corpuscles lying in them. *c, c*, Cartilage-cells near the ossifying surface, exhibiting the appearances described in the text.

Most of them have an outline distinct from that of the mass within, indicating the presence of a cell wall. As to the matter they contain, in some it is a pellucid substance, strongly refracting the light, and nearly filling their cavity; in others it is faintly granular and light like ground glass, and has a well-defined outline, and in these there is a very distinct nucleus, varying much in size in different cells, but always most regularly circular, and inclosing one or more nucleoli;<sup>1</sup> lastly, a good many cells may be seen, the mass contained in which does not merely fill the cavity, and is usually coarsely granular or grumous, with an uneven, and in some, a jagged outline. The number of these last appears to increase by exposure, and they probably result from an alteration occurring in those previously described, the contained matter having become coagulated or otherwise changed in condition, and having shrunk away from the sides of the cell.

It thus appears that the bony tissue, as it advances into the cartilage, has at first a sort of alveolar structure, forming oblong areolæ, or short tubular cavities with thin parietes. But this condition, which differs from that of perfect bone, is only transitory, and at a short distance below the ossifying surface we see a change taking place in the newly-formed tissue; the structure becomes more open, the cartilage-cells disappear from its interstices, and the cancelli and Haversian canals, with their concentric lamellæ, begin to be formed. This is the next step of the process to be considered; and the first intelligible account of it

which has, as far as I know, been given, is that by Todd and Bowman, which is founded on the researches of Mr. Tomes, and corresponds in many points with what I have myself seen.

According to Mr. Tomes, the primary osseous areolæ above described (fig. 26, *c*, fig. 27), enlarge, communicate with one another, and become filled with blastema and blood-vessels; and their sides, at first thin and formed of granular bone, become lined and thickened by successive layers of new and more dense osseous deposit, by which the concentric laminæ are produced,—the laminæ last formed pushing outwards the older ones, so that the circumference of the whole series is extended. He supposes that these strata of new bone are produced by the calcification of cells,—partly those originally existing in the cartilage, but chiefly cells newly formed in the blastema,—and that

<sup>1</sup> These circular nuclei were described and figured by Bidder in Müller's Archiv. for 1843.



the cell nuclei, sending out branches, give rise to the lacunæ and canaliculi.

According to my own observations, the primary areolæ of the bone open into one another by absorption of their intermediate walls, both laterally and longitudinally; they possibly expand to a certain extent, but it is mainly to their lateral confluence that the formation of the larger, or what might be termed secondary cavities, which succeed them lower in the bone, is due. This is shown in figure 29, which represents a thin transverse section, made almost immediately below the surface of ossification, and in which the primary cavities are seen to have coalesced into larger ones. A section somewhat lower (fig. 30), shows that they go on enlarging by further coalescence, and that their sides are thickened by layers of new bone; this soon

Fig. 29.

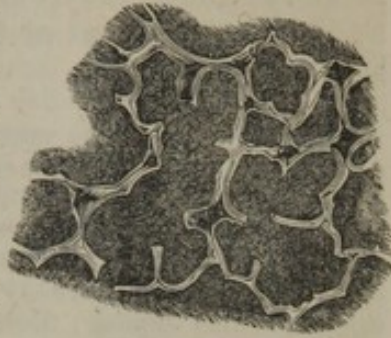
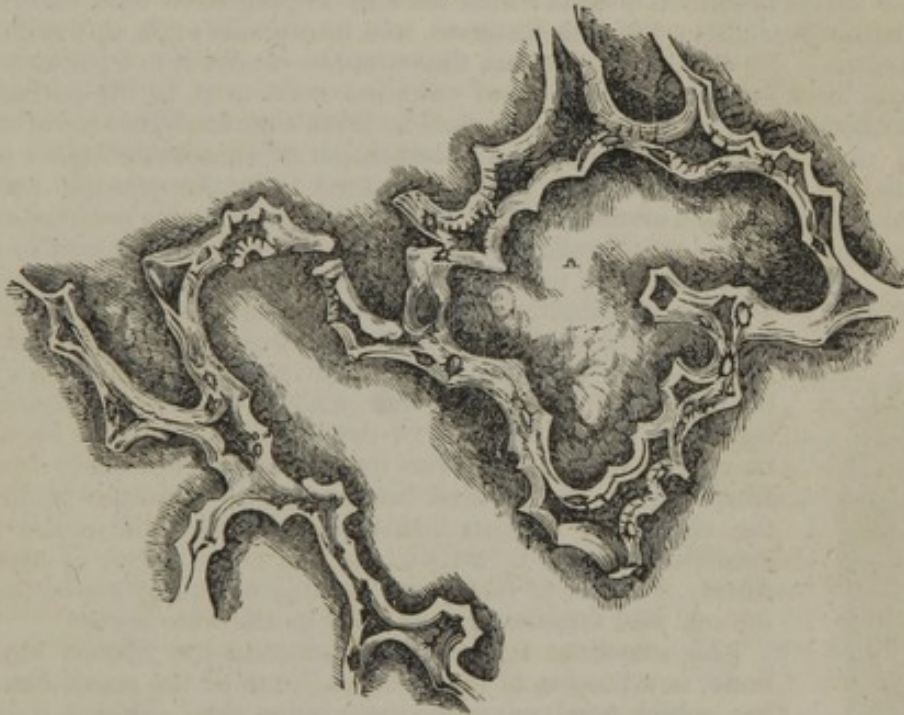


Fig. 30.



29 and 30 represent two transverse sections of growing bone, as in fig. 27, but much more magnified (about 120 diameters). They show the lateral coalescence of the primary bony areolæ and the thickening of the sides of the enlarged cavities by new osseous deposit. The section 29 is made almost immediately below the surface of ossification; 30 is somewhat lower, and shows the cavities still more enlarged and their sides more thickened than in 29. The new osseous lining is transparent and appears light in the figures; the dark ground within the areolæ is owing to opaque debris, which collected there in grinding the sections. It must be further noticed that the letter A within the larger figure marks a place where a bony partition had been accidentally broken away, so that the large space, was naturally divided into two.

begins to be deposited (fig. 29), and goes on increasing (fig. 30). In the mean time the cartilage-cells have disappeared, and the bony cavities, as Mr. Tomes has pointed out, are filled with blastema, in which there are a few fibres and numerous granular corpuscles or cells



resembling those seen in the intramembranous ossification; there are also many blood-vessels. In the end, some of the enlarged cavities remain to form the cancellated structure; while others, getting more and more filled up with concentric lamellæ, become Haversian canals; although the Haversian canals of the compact sides of the bone, it may be remarked, principally arise in another way, as will be afterwards described. In many of these cavities the walls of the coalesced primary areolæ may long be distinguished, like little arches, forming by their union a sort of festooned outline, within which the new bony laminæ are situated.

The primary osseous matter forming the original thin walls of the areolæ is, as Mr. Tomes observes, decidedly granular and has a dark appearance; the subsequent or secondary deposit on the other hand is quite transparent and of a uniform, homogeneous aspect, without obvious granules. This begins to cover the granular bone a very short distance (about  $\frac{1}{80}$ th of an inch) below the surface of ossification, and, as already stated, increases further down. The lacunæ first appear in this deposit; there are none in the primary granular bone. In what further regards the nature and formation of the secondary deposit, my own observations lead me to differ considerably from the views of Mr. Tomes. He supposes that it is formed of cells which become impregnated with earthy matter,—the cartilage cells in the first instance, and afterwards cells newly formed in the blastema. Now, although certain appearances render it not improbable that there may be a layer of flattened and calcified cells next to the surface of the granular bone, I am nevertheless disposed to think that the subsequent and chief part of the deposit results from the calcification of successive layers of fibres, generated in the blastema and possibly derived from the granular cells, some cells being perhaps also involved along with the fibres as in the ossification of the flat bones of the cranium; in short, it appears to me that the deposit in question

[Fig. 31.]



Portion of the base of the stapes rubbed thin and highly magnified; *a*, reticulated fibrous structure; *b*, corpuscles of Purkinje. From nature, by J. L.]

is formed after the manner of the intramembranous ossification already described, (p. 84). I infer that such is the process from the structure of the layers; for they are made up of fine reticulated fibres, like the lamellæ of perfect bone, shown at p. 79. On a careful inspection, and with a certain adjustment of the light, the little apertures of the canaliculi may be seen, and in many parts also fine striæ indicating the obliquely decussating fibres of the new-formed laminæ. The structure reminds us of the secondary deposit inside the oblong cells in the wood of coniferous trees, in which the ligneous matter is arranged in fibres, or rather in fine lines, running obliquely round the wall of the cell and crossing one another in alternate layers.

[An excellent subject for examining the fibrous structure of bone, is a portion of the "stapes," one of the small bones of the ear, which needs no other preparation than rubbing it down thin enough to transmit light. A finely reticulated fibrous structure may be everywhere observed in it, surrounding the Haversian cancelli and Purkinjean corpuscles, (fig. 31.)—J. L.]

The mode of production of the lacunæ, or so-called corpuscles of bone, is still an enigma in osteogeny, and I do not pretend to solve it. They are generally supposed to be derived from the cells of the soft tissue involved in the ossification by some sort of metamorphosis which has been variously conceived. Some suppose that the cell becomes the lacuna, and sends out branches (like the pigment cells, p. 64) to form the canaliculi (Schwann). Others think that it is not the cell but its nucleus that undergoes this change, and that the substance of the nucleus is afterwards absorbed, leaving the lacuna (Todd and Bowman). Henlé thinks that the lacuna is a cavity left in the centre of a cell which has been partially filled up by calcification, and that the canaliculi are branched passages, also left in consequence of the unequal deposition of the hard matter, as in the instance of

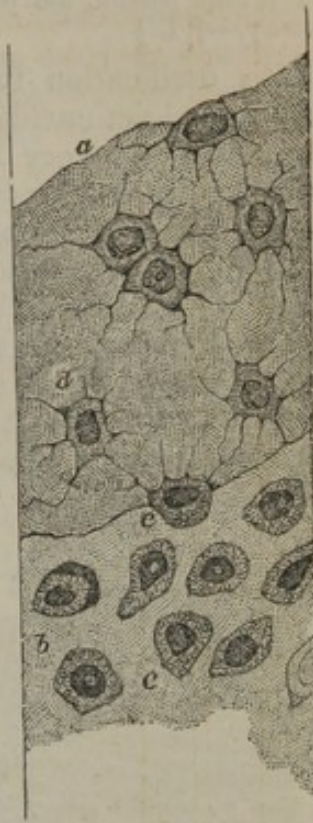


the pore-cells of plants. As to this last opinion, it does not seem reconcilable with the structure of ordinary sound bone, and I am also led greatly to doubt whether the lacunæ and canaliculi are derived from cells or their nuclei in either of the other two ways supposed. It has rather appeared to me as if they were little vacuities left in the tissue during the deposition of the reticular fibres, as open figures are left out in the weaving of some artificial fabrics, (but not within a cell, as Henlé imagined,) and that thus the apposition of the minute apertures existing between the reticulations of the lamellæ gives rise to the canaliculi, in conformity with what has been already stated respecting their structure. At the same time it seems not unlikely that a cell or cell-nucleus may originally lie in the lacuna or central cavity, and may perhaps determine the place of its formation. Such is the view I feel disposed to take of the production of the lacunæ and canaliculi of ordinary bone, although I can by no means speak confidently on the point. In instances of what might be considered a more crude form of ossification, the mode is perhaps somewhat different. In the slow growth of bone which encroaches on the attached surface of articular cartilages, the ossification would almost seem to be produced merely by the impregnation of the cartilaginous matrix with earthy matter, (corresponding with the first step of the ordinary process,) and in this case the cells and clusters of cells being surrounded by the calcified matrix, may remain as little vacuities or lacunæ in the bone; but this, as well as the formation of lacunæ in the crusta petrosa of the teeth and the production of adventitious bony deposits in different textures, requires further investigation.

[From some observations made upon the progress of ossification in the os frontis of a human embryo, measuring two inches from heel to vertex, I am inclined to adopt the views of Schwann relative to the development of the *Purkinjean corpuscle*. Each half of the os frontis at this period presents a network of osseous tissue, which is thickest and most developed along the curve of the supra-orbital ridge, and the frontal and orbital portions are nearly on a plane with each other. When examined by means of the microscope, the interspaces or meshes of the osseous rete are discovered to be filled with cartilage cells contained in a transparent matrix or hyaline substance (fig. 32, *b*). The cells are isolated from each other, granular in structure, and contain a large granular nucleus, within which may be detected a translucent nucleolus. The cell contents are coloured brown by iodine, whilst the translucent intercellular matrix remains unchanged. The average diameter of the cartilage corpuscle is about  $\frac{1}{1888}$  of an inch, the nucleus,  $\frac{1}{3123}$  of an inch.

Upon examining the border of the bone, I noticed a system of reticulated osseous fibres, proceeding from the primitive ossific rete into the intercellular substance of the cartilage cells, apparently by a deposit of earthy salts, in a linear direction. In such positions, I observed the cartilage cells had already protruded, or had connected with them, the canaliculi, and these appear at this time only, because, several cells (fig. 32, *e*), I noticed at the edge of the primitive bony rete, and partly enveloped in the osseous deposit, had the canaliculi passing into the latter, whilst on the unossified or cartilaginous side, none had yet been developed. The cell-wall has until now apparently remained unchanged, but commences to blend or fuse itself with the intercellular substance, and with the secondary osseous fibrillæ. The *Purkinjean corpuscles* (*d*), which are perfectly formed in the osseous structure, at this time have the same diameter, or

[Fig. 32.]



Represents a portion of the border of the os frontis from a human embryo, measuring two inches in length, very highly magnified. *a*. Portion of the ossified rete. *b*. Cartilage of one of the interspaces. *c*. Cartilage cells, with their nuclei. *d*. Newly formed *Purkinjean corpuscles* still containing the nucleus. *e*. A cell partly enveloped in the deposit of the osseous salts. From nature, by J. L.]



nearly so, as the cartilage corpuscle from which they originated, and they still contain a granular nucleus, readily brought into view by iodine, which corresponds to that of the cartilage corpuscle, and has about the same measurement. At a later period, the nucleus of the Purkinjean corpuscles appears to dissolve away.—J. L.]

As ossification thus advances towards the ends of the bone, the portion as yet cartilaginous continues to grow at the same time and increases in every dimension. The part already osseous increases also in circumference; the medullary cavity, of which for some time there is no appearance, begins to be excavated in its interior by absorption, and the sides of the shaft acquire compactness and solidity. The increase in girth is brought about by deposition of bone at the surface underneath the periosteum. It has been sometimes supposed that a formation of cartilage precedes the bone also in this situation; but such is not the case, for the vascular soft tissue in immediate contact with the surface of the growing bone is not cartilage, but consists

Fig. 33.



Subperiosteal layer from the extremity of the bony shaft of the ossifying tibia, as described in the text. The cartilage and more open bony tissue have been scraped off from the inside of the crust, except at *a*, where a dark shade indicates a few vertical osseous areolæ out of focus and indistinctly seen. The part *a b*, of the crust is ossified; between *b* and *c* are the clear reticulated fibres into which the earthy deposit is advancing. Magnified 150 diameters.

of fibres and granular corpuscles; in fact, the increase takes place by intramembranous ossification, and accordingly the Haversian canals of the shaft are formed in the same way as those of the tabular bones of the skull,—that is, the osseous matter is not only laid on in strata parallel to the surface, but is deposited around processes of the vascular membranous tissue which extend from the surface obliquely into the substance of the shaft; and the canals in which these vascular processes lie, becoming narrowed by the deposition of concentric osseous laminæ, eventually remain as the Haversian canals.

That the ossification at the periosteal surface of the bone does not take place in cartilage, may also be made apparent in the following manner. Strip off the periosteum from the bone at the end of the shaft, and from the adjoining cartilage also, taking care not to pull the latter away from the bone. A thin membranous layer will still remain, passing from the bone to the surface of the cartilage; now take a thin slice from the surface, including this membrane with a very thin portion of the bone and of the cartilage, and examine it with the microscope, scraping off the cartilage from the inside if it be too thick. You will then see that the superficial part or shell of the bone, if it may be so called, is prolonged a little way over the surface of the cartilage by means of pellucid, coarsely reticulated fibres of soft tissue, (fig. 33, *b, c*,) into which the earthy deposit is advancing. These fibres are intermixed with granular corpuscles or cells, but form no part of the cartilage, and they are no doubt of the same nature as those seen in the intramembranous ossification of the skull. Their reticulations are in most cases directed transversely, and sometimes they are little, if at all, in advance of the limit between the bone and cartilage. I have observed the structure here described in several bones of the (well-advanced) fœtal sheep,



also in the human scapula, humerus, femur, tibia and fibula, metacarpus and metatarsus, and it probably occurs in all the long bones.

Ossification having thus proceeded for some time in the shaft, at length begins in the extremities of the bone from one or more independent centres, and extends through the cartilage, leaving, however, a thick superficial layer of it unossified, which permanently covers the articular end of the bone. The epiphyses thus formed continue long separated from the shaft or diaphysis by an intervening portion of cartilage, which is at last ossified and the bone is then consolidated. The time of final junction of the epiphyses is different in different bones; in many it does not arrive until the body has reached its full stature. In the mean time the bone increases in length by the ossification continuing to extend into the intervening cartilage, which goes on growing at the same time; and it appears that in the part of the shaft already ossified, little or no elongation takes place by interstitial growth. This is shown by an experiment first made by Dr. Hales and afterwards by Duhamel and by John Hunter, in which two or more holes being bored in the growing bone of a young animal at a certain measured distance from each other, they are found after a time not to be farther asunder, although the bone has in the meanwhile considerably increased in length.<sup>1</sup> In like manner the shaft also increases in circumference by deposition of new bone on its external surface, while at the same time its medullary canal is enlarged by absorption from within. A ring of silver or platinum put round the wing-bone of a growing pigeon, becomes covered with new bone from without, and the original bone included within it gets thinner, or, according to Duhamel, who first made the experiment, is entirely removed, so that the ring comes to lie within the enlarged medullary canal.

Madder given to an animal along with its food, tinges the earth of bone, which, acting as a sort of mordant, unites with and fixes the colouring matter. Now, that part of the bone which is most recently formed, and especially that part which is actually deposited during the administration of the madder, is tinged both more speedily and more deeply than the older part, and, as in this way the new osseous growth can be readily distinguished from the old, advantage was taken of the fact by Duhamel and afterwards by Hunter in their inquiries as to the manner in which bones increase in size. By their experiments it was shown that when madder is given to a young pig for some weeks, the external part of its bones is deeply reddened, proving that the new osseous matter is laid on at the surface of that previously formed; again, it was found that when the madder was discontinued for some time before the animal was killed, an exterior white stratum (the last formed) appeared above the red one, whilst the internal white part, which was situated within the red, and had been formed before any madder was given, had become much thinner; showing that absorption takes place from within. In this last modification of the experiment also, as noted by Hunter, a transverse red mark is observed near the ends of the bone, beyond which they are white; the red part indicating the growth in length during the use of the madder, and the white beyond, that which has taken place subsequently,—thus

<sup>1</sup> Hales. *Veget. Statics*, 4th edit. p. 340. Duhamel, *Mem. de l'Acad. des Sciences*, 1743 et seq. Hunter (reported by Home,) in *Trans. of Soc. for Imp. of Med. and Chir. Knowledge*, vol. ii.: also, *Catalogue of Hunterian Museum*, vol. i., p. 249. Duhamel was led from some of his experiments to infer that an interstitial elongation took place near the ends; but there is some doubt left as to the precise circumstances of the experiments in these cases. Both Hales and Duhamel, in experimenting on the growing tibia of a chicken, observed that the addition of new bone was much greater at the upper end.



showing that the increase in length is caused by the addition of new matter to the extremities.<sup>1</sup> But other changes take place in the bone. The spaces in the cancellated structure become enlarged, as well as the medullary canal, by absorption; whilst in other parts the tissue becomes more compact by farther deposit on the inner surface of the vascular cavities. The sides of the shaft in particular acquire greater solidity by the narrowing of the Haversian canals, within which the vascular membrane goes on depositing fresh layers of bone; and madder administered while this process is going on, colours the interior and recently-formed laminæ, so that in a cross section the Haversian apertures appear surrounded with a red ring (Tomes).

From the foregoing account it is evident that a great portion of a long bone is formed independently of cartilage. Those physiologists, therefore, appear to have reason on their side, who consider the pre-existence of that tissue as not being a necessary condition of the ossific process, and who regard the precursory cartilage of the fetal skeleton chiefly in the light of a temporary substitute for bone, and also as affording as it were a mould of definite figure and of soft but yet sufficiently consistent material, in which the osseous tissue may be at first deposited and assume a suitable form.

The time of commencement of ossification in the different bones, as well as the number and mode of conjunction of their bony nuclei, are subjects that belong to special anatomy. It may, however, be here remarked in general, that the commencement of ossification does not in all cases follow the order in which the bones appear in their soft or cartilaginous state. The vertebræ, for instance, appear as cartilages before there is any trace of the clavicle, yet ossification begins in the latter sooner than in any other bone of the skeleton. The time when it commences in the clavicle, and consequently the date of the first ossification in the skeleton is referred by some to the seventh week of intra-uterine life; others assign a considerably earlier period; but owing to the uncertainty that prevails as to the age of early embryos, the dates of commencing ossification in the earliest bones cannot be given with precision.

In regard to the number and arrangement of the nuclei, the following general facts may be stated. 1. In the long bones there is one centre of ossification in the middle, and the ends are for the most part ossified from separate nuclei; whilst a layer of cartilage remains interposed until the bone has nearly attained its full length. By this means the bone is indurated in the parts where strength is most required, whilst its longitudinal growth is facilitated. 2. The larger foramina and cavities of the skeleton are for the most part formed by the junction of two, but more generally of three or more nuclei round the aperture or included space. The vertebral rings, the acetabulum, the occipital foramen, and the cranium itself, are illustrations of this. It is easy to conceive that in this way the ready and equable enlargement of such cavities and apertures is provided for. 3. Bones of a complex figure, like the vertebræ, have usually many nuclei; but the converse is not always true. 4. We can frequently connect the number of nuclei with the principle of uniformity of type on which the skeleton of vertebrated animals is constructed. Thus the typical form of the sternum seems to be that of a series of distinct bones, one placed between each pair of ribs in front, as the vertebræ are behind, and this is its permanent condition in many quadrupeds. In man it conforms to the archetype in its mode of formation, in so far as it is ossified from several centres and for some time consists of several pieces, but, to suit the fabric of the human thorax, these at last coalesce one with another, and are reduced in number to three.

In the reunion of fractured bones, osseous matter is formed between and around the broken ends, connecting them firmly together; and when a portion of bone dies, as happens in necrosis, a growth of new bone very generally takes place to a greater or less extent, and the dead part is thrown off. The several steps of the process of restoration in these instances are so fully described in works on Surgical Pathology, that it is unnecessary to add to the length of this chapter by introducing an account of them here.

<sup>1</sup> M. Flourens has repeated and varied these experiments, and represented the results in beautiful delineations. *Recherches sur le Developpement des Os et des Dents*. Paris, 1842.



## THE SKELETON.

---

THE osseous structure is peculiarly fitted, by its solidity and hardness, not only to give support to the soft parts, but also to furnish points of attachment to the muscles, by which the different movements are executed. This solid framework of the body is made up of a number of separate pieces, the aggregate of which has been termed "*the skeleton*," (sceletum, σκελλω, *to dry*.) The vertebral column may be considered as the central or fundamental part of the whole, both because it exists in all animals which possess an internal osseous skeleton, and also because the different parts of the osseous system are either immediately or mediately connected with it as a common centre. Thus, on its superior extremity, or apex, it supports the skull; laterally it gives attachment to the ribs, which arch forwards, to form, with the sternum, a bony case for the lodgment of the organs of respiration and circulation, at the same time that they furnish, externally, points of support for the superior extremities: inferiorly the column is immovably connected with the pelvic bones, which are articulated with those of the lower extremity.

When proceeding with the description of the human body, it is usual to consider it as divisible into head, trunk, and extremities, which is sufficient for the purposes of a regional division; but the skeleton must be viewed in a different way, particularly if reference is made to its conformation in the various orders of animals—to its development—and to the subordination of its component parts. The spine being its essential constituent, all the others (viz. the ribs and sternum, clavicle, scapula, and upper extremities, the pelvic bones and lower extremities,) rank as accessories. The sacrum and coccyx are obviously parts of the spine, so likewise are the cranial bones; for though in outward appearance they differ so much in man and the higher animals from the bones of the spine which are placed beneath them, and with which they are articulated, they still are but modifications of similar organic elements—repetitions, in fact, of like parts, differently developed to suit the peculiar relations into which they enter, and the purposes which they are designed to serve.

The number of pieces which compose the osseous system varies in the different ages of life; for some, which in the first instance are divided into two or more portions, become soldered together as the process of ossification goes on. But authors are far from being unanimous as to the number of bones which they recognise even in the adult. Do the sesamoid bones form parts of the skeleton, or are they mere accessory structures developed in tendons? Are the teeth, os hyoides, and ossicula auditûs, to be enumerated as components or accessories? Monro and Scæmmering reckon 260 bones; and Meckel, who takes the number at 253, includes the teeth, patellæ, ossa sesamoidea, os hyoides as five pieces, sternum as three, coccyx as four, and the small



bones of the ear. If, however, we omit those just named, as being either accessories or connected with special organs, the whole number of pieces found in the ordinary skeleton will be 197, as follow:—

The spinal column, properly so called, consists of 24 vertebræ, the sacrum and the coccyx - - - - - 26

The skull is made up of eight cranial bones, viz. the occipital, two parietal, two temporal, the frontal, the ethmoid and sphenoid:—and of fourteen facial, viz. two nasal, two lachrymal, two superior maxillary, two malar, two palatal, two turbinated, one vomer, and the inferior maxillary bone - - - - - 22

The ribs are 24 in number (twelve on each side), with the sternum - - - - - 25

The two superior extremities consist each of a clavicle and scapula, humerus, radius, and ulna, eight carpal bones, five metacarpal, and fourteen in the digital rows - - - - - 64

The two inferior extremities comprise, each, one pelvic bone (innominate), one femur, tibia, and fibula, seven tarsal bones, five metatarsal, and fourteen digital<sup>1</sup> - - - - - 60

In the skeleton we recognise two great cavities (which are again variously subdivided); one anterior and inferior, comprising the thorax and abdomen; the other posterior and superior, formed by the union of the vertebral canal with the cranial cavity.

#### VERTEBRAL COLUMN.

The *vertebral column* (*columna vertebralis*, *rachis*, *spina*,) is situated along the median line, at the posterior part of the trunk, the length of which it determines. Anteriorly it presents the form of an irregular pyramid—posteriorly, a series of elongated processes (*spinæ*), disposed regularly one beneath the other, from which circumstance the term “*spine*” is derived. Viewed as a whole, it resembles at first sight the shape of a long bone, but it is very differently constructed. As it receives the weight of the head and trunk, and transmits it to the base on which it rests, it requires to be firm and resisting, its power of resistance increasing gradually from above downwards. Being the centre of all the movements of the body, it must be as pliant and flexible as a bow, but yet firm, in order to give adequate protection to the spinal cord which it encloses. All these conditions are attained by its being made up of several small pieces united by an elastic substance, the motion permitted between each pair being slight, while the aggregate of all is considerable.

#### VERTEBRÆ.

The *vertebræ*, or separate pieces of which the column is made up, are so named from their mobility (*vertere*, to turn). They are divided into *true* and *false*; the former term being applied to those which remain separate in the adult, and retain their mobility; the latter to such as become united into one mass (viz. the sacrum), or degenerate as it were, and lose all the ordinary characters of vertebræ (viz. the coccyx). The size of the vertebræ increases from above downwards as far as

<sup>1</sup> [In this enumeration the patellæ have been excluded, as belonging to the *ossa sesamoidea*.]



the first pieces of the sacrum, from which it diminishes towards the end of the coccyx, where it terminates by a point; so that the column may be said to consist of two pyramids applied to one another at their bases. The superior, or movable vertebræ, however, do not taper regularly from above downwards; they become somewhat narrowed and constricted as it were at the third dorsal vertebra, after which they gradually enlarge towards the lower end.

#### A. THE TRUE VERTEBRÆ.

The *true vertebræ* are divided into three sets, named from the regions they occupy, *cervical*, *dorsal*, *lumbar*.

They present, 1. certain general characters by which they may at once be distinguished from bones of any other class; 2. those of each region (*cervical*, *dorsal*, *lumbar*,) exhibit peculiar characters by which they are severally distinguished; 3. certain vertebræ present special or individual characters.

##### 1. GENERAL CHARACTERS OF A VERTEBRA.

The objects presented by each vertebra are, a ring, a body, articulating processes, transverse and spinous processes, and notches. Of these, the ring, or foramen, merely to suit the purposes of methodical description, may be considered the central part. As the whole series of vertebræ is intended to form a pillar of support, each, with the exception of the first, presents in front a convex mass (the body), which is a section of a cylinder, and which, by being piled one over the other, form the pillar. As each bone must be securely joined with the one above it and that below it, there exist certain prominences (articulating processes) for articulation with them. The column being flexible, and partaking in the several movements of the body, it is required that there be levers (transverse and spinous processes) for the attachment of the muscles or moving powers. Finally, it is necessary that a free communication should be allowed for the nerves with the nervous centre contained in the canal, and this purpose is served by the notches.

The various parts of a vertebra here named require more detailed notice.

The *ring* (foramen vertebrale, rachidium,) is formed in front by the body, and posteriorly by what is named the *arch* of the vertebræ, from which latter the several processes project. As the vertebræ are piled one over the other, the rings are arranged so as to form, with the aid of the interposed ligamentous structures, a flexible canal for the lodgment and protection of the spinal cord.

The *body* forms the anterior and most considerable part of the bone. Rounded before, and marked in the middle by a transverse groove, which gives it a constricted appearance, it is slightly hollowed posteriorly, where it contributes to the formation of the vertebral canal, and in most instances is flat on the superior and inferior surfaces, by which, through the medium of fibro-cartilage, it is connected with the contiguous bones. Its outer surface all round presents numerous foramina for the passage of blood-vessels, principally veins. One of the



holes situated about the middle of the posterior surface exceeds the others very much in size; it lodges a large vein.

From the body at its lateral margins two processes pass backwards, called "pedicles." The pedicles join with the laminæ, or plates, and these, by inclining inwards, meet at the median line posteriorly, so as to complete the "arch" of the vertebra. From the point of junction of the pedicles with the laminæ at each side, the articulating and transverse processes project; and from the union of the two laminæ the spinous process takes its origin.

*Articulating or oblique processes.*—For maintaining the connexion between the contiguous vertebræ, there are four processes,—two superior, and two inferior,—which project, one on each side, from the junction of the laminæ with the pedicle. Two of these processes project upwards, and two downwards; the smooth surfaces of the upper pair look backwards, those of the lower, forwards; they are coated with cartilage, and articulate with corresponding processes of the next vertebræ. Their margins are rough for the attachment of ligaments.

The *transverse* and *spinous* processes form a series of levers for the attachment of muscles. The transverse processes, two in number (one on each side), and named from their direction, project laterally from the arch near the articulating processes, between which their bases are interposed. The *spinous* process is a single projection, situated posteriorly in the median line; this process, or rather the appearance presented by the aggregation of those of the several vertebræ, has given to the entire column one of its designations (spine).

*Laminæ or plates.*—The parts of the arch which intervene between the bases of the spinous and the transverse processes are thus named.

*Pedicles and notches.*—Lastly, the processes which extend from the plates to the body of the bone, are called "pedicles," as above stated. In each pedicle are seen two excavations, or notches (*incisuræ*), one on the upper, the other on the lower border, the latter being deeper than the former. When the vertebræ are placed in their natural position, the notches in the contiguous margins of each pair of them form rounded apertures, which communicate with the vertebral canal, and give transmission to the spinal nerves and to the entering and emerging vessels. From their position and mode of formation, they are called the *intervertebral foramina*.

## 2. CHARACTERS PECULIAR TO THE VERTEBRÆ OF EACH REGION OR CLASS.

### CERVICAL VERTEBRÆ.

The cervical vertebræ (fig. 34,) are seven in number; they are smaller than those in the other regions, which results from the size of the body and processes being less than that of the corresponding parts in the dorsal and lumbar classes. The vertebral foramen<sup>2</sup> is of a triangular form, and larger proportionally than in the other classes. The body,<sup>1</sup> elongated transversely, is thicker anteriorly than



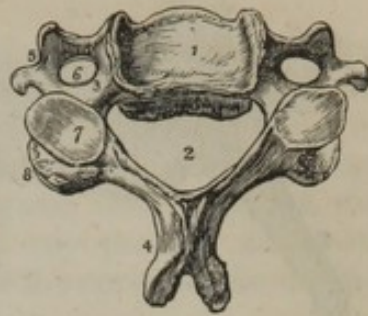
posteriorly; for the under and fore part of each dips down a little. The upper surface is broader than the under one; and is rendered concave from side to side, by two little plates, which project upwards from its lateral margins. The lower surface is slightly convex, and rounded off at the sides. The superior articular processes,<sup>7</sup> are flat and oblique in their direction, so as to look backwards and upwards, whilst the inferior<sup>8</sup> incline downwards and forwards. It is only in the cervical vertebræ that these processes can be

fitly named "oblique." The articular surfaces are supported on rounded and elongated little masses or pillars of bone. The transverse processes,<sup>5</sup> short, and bifid at their extremities, present a deep groove superiorly,<sup>3</sup> for the transmission of the nerves, and at their base a foramen, through which in most of them the vertebral artery passes. It will be observed, that these processes have two roots or points of connexion with the vertebra. The posterior one springs from the junction of the pedicle with the arch, and therein corresponds with the transverse processes in the back and loins. The anterior one is attached to the side of the body of the vertebra, and ranges with the ribs, of which it is a rudiment. The formation of the foramen can, from these facts, be readily indicated. The osseous points, which here represent the ribs, not being required for any special purpose, remain in their rudimentary condition, and merely incline backwards, so as to become ankylosed with the true transverse processes which lie behind them. They thus enclose a space, viz., the foramen, which, however, cannot be said to be intended to lodge the vertebral vessels, as it exists in the seventh cervical vertebra, through which they rarely pass, and in the sixth and fifth in those cases in which the artery enters the fourth. The spinous process<sup>4</sup> is short, projects horizontally backwards, and is bifid at its extremity. The plates, or laminae, are narrower and longer than in the other regions. The notches are deeper and larger in the upper than in the lower border of the pedicles, in all except the second. They lie behind the articular processes in the first, but before them in the rest.

## DORSAL VERTEBRÆ.

The dorsal vertebræ, (fig. 35,) twelve in number, are intermediate in size as well as in situation, between the cervical and the lumbar. The foramen is smaller than in the cervical or lumbar region, and is nearly circular in its form. The lateral notches,<sup>4 5</sup> and consequently the intervertebral foramina which they form, are larger than those in the neck; and those at the lower margin of the pedicles are much

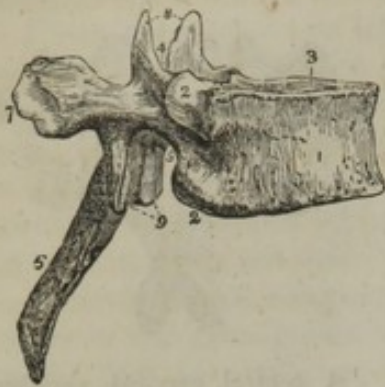[Fig. 34.]



A central cervical vertebra, seen upon its upper surface. 1. The body, concave in the middle, and rising on each side into a sharp ridge. 2. The lamina. 3. The pedicle rendered concave by the superior intervertebral notch. 4. The bifid spinous process. 5. The bifid transverse process. The figure is placed in the concavity between the anterior and posterior tubercles, between the two processes which correspond with the rudimentary rib and the true transverse process. 6. The vertebral foramen. 7. The superior articular process, looking backwards and upwards. 8. The inferior articular process.—W.]



[Fig. 35.]



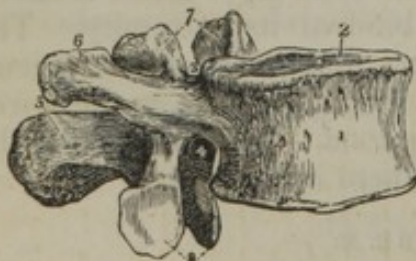A lateral view of a dorsal vertebra. 1. The body. 2. The superior articular process. 3. The superior intervertebral notch. 4. The inferior intervertebral notch. 5. The spinous process. 6. The transverse process. 7. The superior articular process. 8. The inferior articular process. 9. The two superior articular processes looking backwards. 10. The two inferior articular processes looking forwards.—W.]

the tubercle of the rib. The spinous processes,<sup>6</sup> elongated and triangular, are directed downwards, and terminate in a tubercle. The plates are broad and thick, but shorter than those in the neck.

## LUMBAR VERTEBRÆ.

The lumbar vertebræ, (fig. 36,) five in number, are larger than either of the other sets. The foramen of each vertebra in this region is large and triangular. The notches,<sup>3 4</sup> for the formation of the intervertebral foramina are very deep, especially the inferior pair. The body,<sup>1</sup> much broader from side to side than from before backwards, is flat on its superior and inferior surfaces. It is not so convex anteriorly as that of the dorsal vertebræ. The articulating processes are

[Fig. 36.]



A lateral view of a lumbar vertebra. 1. The body. 2. Upper surface. 3. The superior intervertebral notch. 4. The inferior intervertebral notch. 5. The spinous process. 6. The transverse process. 7. The superior articular process. 8. The inferior articular process.—W.]

larger and deeper than those on the upper. The breadth of the body<sup>1</sup> from side to side, exceeds the depth from before backwards much less than in the cervical or lumbar vertebræ. It is convex and prominent on the anterior surface, flat and plain at the upper and lower; at each side of the body may be observed a slight notch,<sup>2 2</sup> in the superior as well as in the inferior border,—these are covered with cartilage, and, when the vertebra is placed in apposition with the adjacent ones, form oval depressions for the reception of the heads of the corresponding ribs. The articulating processes<sup>7 8</sup> are nearly vertical in their direction; the superior looking backwards, the inferior forwards. The transverse processes<sup>6</sup> are long, thick, and inclined backwards, [more in the female than in the male,] and on the anterior surface of each of their tubercular terminations is situated a slight excavation, which in the fresh state is tipped with cartilage, and articulates with

thick, strong, and disposed vertically; the superior pair,<sup>7</sup> concave, look backwards and inwards; the inferior,<sup>8</sup> convex, forwards and outwards; the former are farther apart than the latter, hence they receive and in a manner embrace the lower articulating processes of the vertebra above them. From each of the superior articulating processes a "tubercle" projects backwards. The transverse processes,<sup>6</sup> long, thin, and horizontal, do not project backwards like those of the dorsal vertebræ. The spinous process<sup>5</sup> is broad, flat, and nearly of a square form, so that it terminates not by a pointed extremity, like those in the dorsal region, but presents rather



a compressed and rough border. The plates or laminæ, though shorter, are deeper and thicker than those of the dorsal vertebræ.

If, now, the three vertebræ (cervical, dorsal, and lumbar,) here described separately, are taken together and contrasted, it will be found that the several parts of one differ so much from the same parts in another, and are so characteristic of the region to which they belong, that any one of them would serve to distinguish the classes of the vertebræ. Thus, that the ring, the body, or any process would be sufficient to determine whether a vertebra is of the cervical, the dorsal, or the lumbar part of the column.

### 3. PECULIARITIES OF CERTAIN VERTEBRÆ.

The general characters of vertebræ, and the differences which characterize those of different regions, being considered, it remains to point out certain peculiarities presented by some individual bones in each set. It may be here stated generally, that the vertebræ situated at the extremities of each region assimilate in some degree to the characters of those in whose vicinity they are placed. Thus, for instance, the lower pieces of the cervical region begin to resemble the dorsal vertebræ, and the latter become, by a similar transition, assimilated to the lumbar,—the characters peculiar to each region being best displayed by the bones situated towards its middle point.

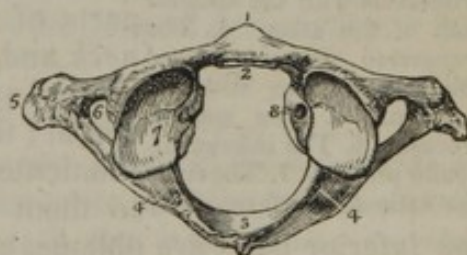
The vertebræ which differ from others of their class so much as to require separate description are the following: the first two and the last cervical; the first and last three dorsal; and the last lumbar.

#### THE FIRST, SECOND, AND SEVENTH CERVICAL VERTEBRÆ.

The first vertebra, or *atlas*, fig. 37, (so called from supporting the

head,) is an irregular ring of bone, which presents nothing analogous either to the bodies or spines of the other vertebræ. The ring, in the fresh state, is divided into two parts by a transverse ligament,—the anterior one being occupied by the odontoid process of the axis, the posterior by the spinal cord;—it presents in front a small arch of bone, the anterior surface of which is marked by a tubercle, the posterior by a smooth depression, adapted to the odontoid process of the axis. The posterior segment of the ring is considerably larger than the anterior; at its middle point<sup>3</sup> it presents a tubercle, which is the analogue of the spinous processes; it is thick and round in the greater part of its extent; but at its junction with the rest of the vertebra there exists on the upper border at each side a smooth groove,<sup>4</sup>

[Fig. 37.

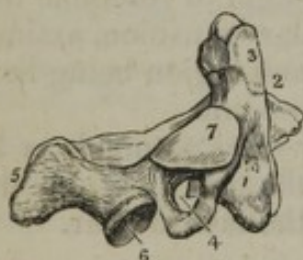

The upper surface of the atlas. 1. The anterior tubercle projecting from the anterior arch. 2. The articular surface for the odontoid process upon the posterior surface of the anterior arch. 3. The posterior arch, with its rudimentary spinous process. 4. The intervertebral notch. 5. The transverse process. 6. The vertebral foramen. 7. Superior articular surface. 8. The tubercle for the attachment of the transverse ligament. The tubercle referred to is just above the head of the figure; the convexity below it is the margin of the inferior articulating process.—W.]



which lies behind the superior articular process, and marks the tortuous course pursued by the vertebral artery previously to entering the cranium. This groove is analogous to the notches in the other vertebræ, for it transmits the first spinal nerve as well as the vertebral artery; it is sometimes converted into a foramen by a spiculum of bone. The articulating surfaces are horizontal and large. The superior pair<sup>7</sup> receive the condyles of the occipital bone; they converge in some sort towards the forepart of the bone; and as their form is oval, and their surface concave from before backwards, they look towards one another; at the inner margin of each is a rough surface,<sup>8</sup> which gives attachment to the transverse ligament. The inferior pair, on the contrary, are flat, and nearly circular in their form. The parts of the vertebra (*lateral masses*) on which these processes are situated are of very considerable thickness, because the weight of the head, which in others is received by the bodies, rests here on the articular surfaces. The transverse processes<sup>5</sup> project considerably on each side, and terminate in a rounded point; at the root of each is situated the foramen,<sup>6</sup> which transmits the vertebral artery.

[Fig. 38.



A lateral view of the axis.  
1. The body. 2. The odontoid process. 3. The smooth facet on the anterior surface of the odontoid process which articulates with the anterior arch of the atlas. 4. The transverse process pierced obliquely by the vertebral foramen. 5. The spinous process. 6. The inferior articular process. 7. The superior articular surface.—W.]

The second vertebra, vertebra dentata, or *axis*, (so called from forming the pivot on which the head rotates,) is somewhat triangular in its form. The body, fig. 38,<sup>1</sup> presents anteriorly a vertical ridge, bounded on each side by a depression for the attachment of the longus colli muscle; superiorly it is surmounted by a process,<sup>2</sup> (*odontoid, p. dentatus*; whence is derived the name *vertebra dentata*.) presenting two smooth surfaces, one for its articulation with the atlas,<sup>3</sup> the other with the transverse ligament, which retains it in its situation; being constricted inferiorly, and somewhat enlarged towards the summit, these parts of the process are called respectively its *neck* and *head*. The superior articulating processes<sup>7</sup> are of considerable size, and nearly horizontal; they are close to the body, so as to communicate to it the weight of the head, transmitted to them by the articular processes of the atlas; the inferior pair<sup>6</sup> are oblique, and of the same size as in the vertebræ beneath them. The transverse processes<sup>4</sup> are neither grooved nor bifurcated, and the foramen at their root is inclined obliquely outwards. The spinous process<sup>5</sup> is very large, and gives attachment to several muscles; it is deeply grooved on its inferior surface; the plates which support it are of proportionate size.

The *seventh*, or prominent vertebra [*vertebra prominens*], approaches in its characters to those of the dorsal region; its spinous process terminates in a tubercle, and is so long as to be, in the natural condition, felt underneath the skin; whilst the other cervical spines lie more deeply, and are covered by muscles; hence the term "prominent," so commonly applied to this vertebra. The transverse process, though pierced by a foramen, [which most usually is too small to



permit the vertebral vessels to pass through it,] presents but a slight appearance of a groove on its upper surface, and seldom more than a trace of a bifurcation at its extremity.

#### THE PECULIARITIES OF SOME DORSAL VERTEBRÆ.

The *first dorsal* vertebra is marked at each side by a complete articular surface for the first rib, and on its inferior border by a slight excavation, which receives half the head of the second: the upper articular processes are oblique, and the spinous more nearly horizontal than those below it.

The *tenth dorsal* vertebra is usually marked by an articular surface, which receives the entire of the head of the corresponding rib.

The *eleventh* has but a single articular surface on the side of its body. Its transverse process is much reduced in size, and does not articulate with the tubercle of the rib. The form of its spinous process, of its laminæ and body, approaches that of the lumbar vertebræ.

The *twelfth dorsal* vertebra, in most of its characters, resembles the eleventh, and is to be distinguished by its greater similarity to the lumbar vertebræ, especially by means of the lower articular processes, which are convex and look outwards, like the same processes in the lumbar region.

#### THE FIFTH LUMBAR VERTEBRÆ.

Amongst the *lumbar* vertebræ, the fifth only is distinguishable by any peculiarity deserving of notice, its body being thicker anteriorly than posteriorly, and its transverse process short, thick, and rounded.

#### B. THE FALSE VERTEBRÆ.

Some of the vertebræ at the lower part of the column lose by their union into a single mass (the sacrum) that character of mobility from which the term vertebra is derived, and others, (the coccygeal,) dwindled to mere tubercles, have none of those important uses to which the true vertebræ serve. Hence the general designation, "false vertebræ," applied to them.

#### THE SACRUM.—OS SACRUM.

The sacrum, fig. 39, much the largest piece of the vertebral column, is placed, when the body is in the erect position, at the superior and posterior part of the pelvis, beneath the last lumbar vertebra, above the coccyx, and between the ossa innominata, between which it is inserted, in some measure like a keystone into an arch.

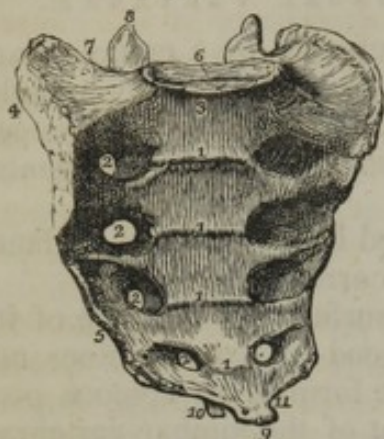
The sacrum is placed very obliquely. It projects backwards from the upper margin, receding to give capacity to the pelvis, and it therefore forms, with the body of the last lumbar vertebra, a projection named the sacro-vertebral angle, or promontory. Its figure is triangular in its general outline,—the base being upwards; concave anteriorly, convex posteriorly. We consider successively its surfaces, borders, and extremities.

The anterior or pelvic surface, which is shown in the figure, is concave from above downwards, slightly so from side to side, and marked by four transverse lines,<sup>1</sup> indicating its original division into five



pieces; laterally it presents four foramina,<sup>2</sup> (anterior sacral,) for the transmission of the anterior branches of the sacral nerves. These are

[Fig. 39.]



The sacrum seen upon its anterior surface. 1, 1. The transverse lines marking the original constitution of the bone of four pieces. 2, 2. The anterior sacral foramina. 3. The promontory of the sacrum. 4. The ear-shaped surface which articulates with the ilium. 5. The sharp edge to which the sacro-ischiatic ligaments are attached. 6. The vertebral articular surface. 7. The broad triangular surface which supports the psoas muscle and lumbo-sacral nerve. 8. The articular process of the right side. 9. The inferior extremity, or apex of the sacrum. 10. One of the sacral cornua. 11. The notch which is converted into a foramen by the coccyx.—W.]

directed outwards into grooves which lead from them, and diminish gradually in size from above downwards; external to the foramina the surface gives attachment to the pyramidalis muscle.

The posterior or spinal surface is narrower than the anterior, for the bone is somewhat wedge-shaped from before backwards as well as from above down. This surface is convex, and presents along the median line four small eminences, usually connected so as to form a ridge; these are rudiments of the spinous processes; and beneath them is a triangular groove, or rather an opening, marking the termination of the sacral canal. The margins of the opening present two tubercles, which give attachment to the ligament that closes in the canal, and the inferior pair (sacral cornua)<sup>10</sup> articulate with the horns of the coccyx. At each side of the median line are two sets of tubercles, and between these is the groove, pierced by the posterior sacral foramina, which are much smaller than the anterior, and transmit the posterior branches of the sacral nerves. The groove represents that situated over the plates of the vertebræ above the sacrum, and one row of the tubercles corresponds to the lumbar articular tubercles, the other ranges with transverse processes.

Each pair of foramina (anterior and posterior) lead from a single foramen situated within the bone, and this is analogous to the intervertebral foramen in other parts of the column.

The borders, or lateral surfaces of the sacrum, present two distinct parts,—one superior, the other inferior. The superior (iliac) is large and irregular,<sup>4</sup> and in front is, in the fresh state, covered with cartilage, and articulated with the ilium; whilst posteriorly it is concave and rough for the attachment of strong ligaments. The anterior cartilaginous part is often named “the *auricular surface*.” The inferior part of the lateral surface<sup>5</sup> is thin and sinuous, and gives attachment to the sacro-sciatic ligaments. A small indentation<sup>11</sup> terminates this border, which, with the corresponding extremity of the coccyx, forms a notch for the transmission of the fifth sacral nerve.

The *base*, or superior extremity, broad, and expanded, presents, towards the middle line, an oval surface,<sup>6</sup> cut off obliquely, which articulates with the likewise oblique body of the last lumbar vertebra; behind this a triangular aperture marking the orifice of the sacral



canal; on each side a smooth convex surface, inclined forwards, and continuous with the iliac fossa; an articular process,<sup>8</sup> concave from side to side, which looks backwards and inwards, and receives the inferior articular process of the last lumbar vertebra. Before each articular process is a groove, forming part of the last lumbar intervertebral foramen, and behind them is a curved, sharp, and depressed border which bounds the sacral canal, and therefore corresponds with the laminæ of the vertebræ, and gives attachment to the last ligamentum subflavum.

The *apex*, or inferior extremity,<sup>9</sup> directed downwards and forwards, presents an oval convex surface, which articulates with the coccyx.

The sacrum in its interior contains much loose spongy substance, and its exterior layer is but moderately compact. Its central part is also hollowed into a canal (sacral), which curves from above downwards as the bone does; it is of a triangular form, and gradually narrows as it descends. The canal ends on the posterior surface of the bone between the sacral cornua.

*Attachments of muscles.*—The sacrum gives attachment, by the lateral parts of its anterior surface, to the pyriformis muscles; by its posterior surface at each side to the gluteus maximus, sacro-lumbalis, longissimus dorsi, and multifidus spinæ; by the inferior part of each border to part of the coccygeus; and by the outer parts of its base to the iliacus muscle of each side.

*Articulations.*—The sacrum articulates with the last lumbar vertebra, the two iliac bones, and the coccyx.

#### PECULIARITIES OF THE SACRUM.

The peculiarities of the sacrum are very numerous. 1. In some cases this bone consists of six instead of five pieces, and it has been found—but much more rarely—reduced to four.<sup>1</sup>

2. Occasionally the bodies of the first and second sacral vertebræ are not joined, although complete union has taken place in every other part.

3. The lower end of the sacral canal may be open for some extent, in consequence of the vertebral laminæ not having grown together, [and occasionally it remains open the whole length of the sacrum.]

4. In no respect does the sacrum vary more in different skeletons than in the degree of its curve. It is difficult to submit the peculiarities in this respect to a precise and sufficiently comprehensive arrangement; still, after examining a considerable number of skeletons, the majority appeared to admit of being grouped into three sets, as follows:—

*a.* In one series the anterior surface was comparatively straight, and the slight bend which existed was situated near the lower end.

*b.* Another group contrasted strongly with the preceding,—the bone

<sup>1</sup> Sæmmering "Lehre von den Knochen und Bandern, &c., herausgegeben von Rudolph Wagner."—1839.



being much curved in its whole length, but especially about its middle.

c. A considerable number may be described as holding an intermediate place between the two foregoing classes. The degree of curve was moderate, and chiefly affected the lower third of the bone.

*Difference in the sexes.*—Besides possessing the ordinary distinctive character of all parts of the skeleton,—viz., more regularity and smoothness of surface,—the sacrum of the female body is, proportionally to the size of the pelvis or of the skeleton, broader than that of the male.

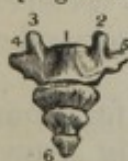The degree in which the bone is bent has been relied on by anatomical writers to distinguish between the sexes; but, on comparing their statements, it will be found that they are contradictory—some assigning the greater curve to the female, others, on the contrary, to the male. The measurement of a considerable number of those bones taken from both sexes, has shown me that the curvature cannot be relied on as a distinctive character. I find that the general remarks made in the preceding paragraphs on the varieties presented by the sacrum, with reference to the point in question, are applicable either to the female or the male taken singly, with only this reservation, that those bones which were most curved, and which constitute the second series in the classification there ventured on, commonly belong to the male body.

It is said by many good observers, that the sacrum usually inclines backwards from the direction of the lumbar vertebræ to a greater extent in the skeleton of the female than of the male,—thus retiring more from the cavity of the pelvis, and forming a more prominent sacro-vertebral angle.<sup>1</sup>

#### THE COCCYX.—OSSA COCCYGIS.

These bones, when united together, which is usually the case in advanced life, are supposed to resemble a cuckoo's bill, and are therefore called coccygeal (κοκκυζ, a cuckoo). Most commonly there are four of them, sometimes but three; in a few instances five have been found. They diminish gradually in size from above downwards, which gives them, when taken together, a pyramidal form. As they are placed in a continuous line with the inferior third of the sacrum, they form a slightly concave surface anteriorly, a convex one posteriorly.

[Fig. 40.



The posterior surface of the coccyx.  
1. First bone.  
2, 3. Cornua.  
4, 5. Shoulders.  
6. Last bone.]

The first of these bones<sup>1</sup> resembles, in some measure, the last false vertebra of the sacrum. Its body is small and concave at its upper aspect, which articulates with the extremity of the sacrum; posteriorly, two small processes, termed cornua,<sup>2, 3</sup> project, which rest upon the sacral cornua. The second bone of the coccyx is somewhat square, the third oblong, and the fourth is a small rounded nodule.<sup>6</sup>

<sup>1</sup> This observation is stated by Blumenbach ("Geschichte und Beschreibung der Knochen," S. 314,) to have been first made by Bonaccioli, a Professor at Ferrara, in the fifteenth century.



The margins (shoulders, as this part has been named,) <sup>4, 5</sup>, of the first piece, in some cases, project upwards, and, joining with the sacrum, construct a fifth sacral foramen—as exemplified in fig. 45, B.

*Attachments of muscles.*—The coccyx gives attachment to the gluteus maximus, and to the coccygeus of each side, and by its point to the sphincter ani. Its base articulates with the sacrum, and in advanced age becomes united to it.

#### THE VERTEBRAL COLUMN.

The true and false vertebræ, when ranged in their natural position, form a column, the average length of which is equal to about two feet two or three inches. The length of the column does not vary in different persons as much as might be anticipated from a comparison of their stature; the relative height of individuals depending more on the length of their lower limbs than of the vertebral column.

*Form.*—Its form is pyramidal—rather it consists of two pyramids joined by their bases; the upper one being formed by the true vertebræ, the lower one, by the sacrum and coccyx. The upper pyramid, however, instead of tapering regularly from the top to the bottom, becomes narrow in the upper part of the dorsal region. It is most narrowed about the fourth dorsal vertebra, and the column above this point has been held to admit of subdivision into two pyramidal parts, meeting by their bases about the first dorsal vertebra, and the apex of one being the vertebra dentata, that of the other the fourth or fifth dorsal vertebra.

*The curves.*—When viewed in profile, it presents four curves depending, except perhaps the last, on the different degrees of thickness of the anterior and posterior part of the bodies of the vertebræ in the different regions, but still more on that of the intervertebral substance. The curves are directed alternately backwards and forwards; in the neck and loins the convexity looks forwards, in the back and pelvis it is in the opposite direction.

A slight degree of lateral curvature is also observable in most cases in the dorsal region, the convexity of which is directed towards the right side. The older anatomists imagined this to be produced by the action of the aorta beating against the left side of the column; but Bichat attributed it to the effect of muscular action, and explained it in the following way:—As most persons are disposed to use the right arm in preference to the left, the muscles of that side become stronger, and act with more power on the points to which they are attached; when making efforts, as in pulling, the body is curved to the left, which gives an additional advantage to the muscles; and the habitual use of this position gives rise to some degree of permanent curvature. In support of this explanation of the fact, Bécclard has stated that he found in one or two individuals, who were known to have been left-handed, the convexity of the lateral curve directed to the left side. A further confirmation of the correctness of this view is afforded by an observation made by Professor Otto.<sup>1</sup> In a case in which the aorta arched to the right instead of the left side, he found that the curve of the

<sup>1</sup> "Seltene Beobachtungen," Th. 2, S. 61. See also "The Anatomy of the Arteries, with its applications to Pathology and Operative Surgery," by R. Quain, p. 19.



vertebral column had the usual direction; so that the great vessel was connected to its convexity. It is stated, too, that the right arm was more muscular than the left. [I have seen several instances of lateral curvature depending upon one side of one or two vertebral bodies being thicker or more developed than upon the other side.—J. L.]

For a detailed examination of its parts, the column will be considered as presenting an anterior and a posterior surface, two lateral surfaces, a base, and a summit, each deserving a particular notice. The part formed by the sacrum and coccyx having been already sufficiently referred to, may be excluded from consideration in this place.

The *anterior surface* is broad in the cervical, narrow in the dorsal, and again expanded in the lumbar region; it is marked by a series of transverse grooves corresponding with the centre of the bodies of the vertebræ, and in the fresh state is covered by the anterior common ligament.

The *posterior surface* presents along the median line the spinous processes, varying in form and direction, as has been already stated, being horizontal in the cervical and lumbar regions, and nearly vertical in the dorsal. Those in the cervical and dorsal regions correspond pretty exactly with the middle line, but in the back the spines will be observed in many instances to incline, some to one side, some to the other. On each side of these are the vertebral grooves, extending from the base of the skull to the sacrum; their breadth corresponds with that of the laminæ; they are broad but shallow in the neck, and become deep and narrow lower down. Along the grooves are seen the spaces between the laminæ, which in the natural condition are filled up by the yellow ligaments. The breadth of these intervals is very trifling in the neck and in the greater part of the back; it increases in the lower third of the dorsal, and still more in the lumbar region. The interval between the occipital bone and the atlas is considerable, and so is that between the last lumbar vertebra and the sacrum.

The *lateral surfaces* present the transverse processes, varying in form and character in the different regions; before these are situated the intervertebral foramina, and more anteriorly still, in the dorsal region, the articular surfaces which receive the heads of the ribs.

The *summit* of the column is surmounted by a sort of capital, (the atlas,) which is articulated with the occipital bone, and supports the head. The *base* rests on the sacrum, and by this bone the weight of the trunk is communicated to the lower extremities through the medium of the innominate bones.

Along the entire extent of the column runs the *vertebral canal*, which is broad and triangular in the cervical and lumbar regions, circular and contracted in the dorsal. The canal may be said to expand at its upper extremity into the cranial cavity; its lower end is prolonged into the narrowing canal of the sacrum.

The *arrangement of the osseous structure* is not the same in the different parts of a vertebra. The arch and the processes projecting from it have a thick covering of compact tissue. The body, on the contrary, is composed nearly altogether of spongy substance. This part of the bone, when sawed through, will be found to consist of cells



bounded by thin plates of bone; and it contains large canals for the lodgment of veins. The canals differ somewhat in disposition in different cases, but they will be found to have the same general direction from behind forward, radiating with more or less regularity from the large foramen on the posterior aspect of the body.

#### OSSIFICATION OF THE VERTEBRÆ.

*General observations on the time when ossification begins.*—The process of ossification begins at different periods in the several parts of the skeleton, and it becomes an object to assign to each centre of bony deposit the time at which it appears. This is a subject of considerable difficulty, and a few general remarks with reference to it are necessary before describing the ossification of individual bones.

The accuracy with which the date of ossification may be determined must depend on the exactness with which the age of the embryo is ascertained. But much uncertainty exists with respect to this point, for the evidence as to the period of conception is not to be fully relied on; and, moreover, the embryo submitted to examination is most commonly in a morbid state, and may have ceased to live some time previous to its separation from the parent. To these sources of uncertainty another may be added: the difference, namely, which actually occurs in the growth of bone in different cases. It seems reasonable that the time of ossification should be influenced by the quality of nutrition; the opinion, however, that there is some variety among the stages of ossification in different individuals, is not founded on such general grounds, but on a comparison one with another of cases which have fallen under my notice, and on the result afforded by contrasting observations accurately made by myself with some which bear the appearance of having been carefully made by others. It is, doubtless, in a measure at least, in consequence of circumstances such as those referred to, that so great a difference prevails between the statements of various observers on the point in question. These considerations lead us to the conclusion, that the period of the commencement of the ossification in a given bone does not admit of being set forth with absolute certainty, especially as regards those bones in which the process begins at very early periods. As to this part of the subject, therefore, we must be content with an approximation to exactness.

But the relation which the time of the appearance of bony matter in one piece of the skeleton has to the time of its appearance in another, admits of being stated with more accuracy; and it will, in our progress, be referred to whenever it shall appear material. To exemplify what has been said, it may be added, that we may not be able to state with rigid accuracy when bone makes its appearance in the several divisions of the vertebral column, or in the clavicle; but we can with confidence determine which of them precedes the other in its ossification.

The observations on the growth of bone in the vertebræ will be arranged under three heads, as follows:—*a.* The first will contain an account of the common characters of the ossification of a vertebra.



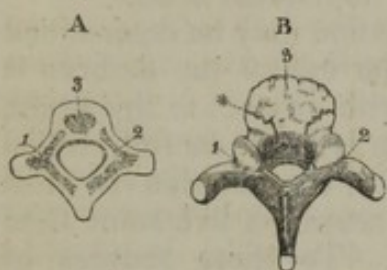
- b. Under the second head will be placed the peculiarities that occur in the growth of certain vertebræ or parts of the vertebral column.  
c. Lastly, the progress of ossification in the column generally will be reviewed.

### a. OSSIFICATION OF A VERTEBRA.

#### COMMON CHARACTERS.

Exclusive of certain exceptional cases, to be afterwards noticed, each vertebra is formed of three principal pieces, to which five small epiphyses are added at an advanced period, and as if for the completion of the bone.

Fig. 41.



A. The three principal pieces of the vertebræ are seen to be distinct one from the other. B. The lateral pieces have joined behind. The spinous and transverse processes remain cartilaginous at their ends. The arch is still separable from the middle anterior piece, and the cartilage having been removed from the body, the surface of this is rounded, rough, and fissured.

1. 2. The lateral pieces. 3. The anterior part for the body. \* Line of separation between the lateral pieces and the anterior.

Of the principal pieces two are destined for the formation of the arch and the processes which project from it (fig. 41,<sup>1 2</sup>). The body of the vertebra is produced from the third (fig. 41,<sup>3</sup>).

Osseous substance is first observable in the vertebræ about the seventh or eighth week from the time of conception, and it commences in the arch (but not invariably) a little before the body.

The osseous granules for the arches make their appearance on each side at the situation from which the transverse processes project; and from this place the formation of bone extends in different directions,—forwards to the body, inwards to the spine, and outwards to the transverse process, as well as into the articular processes; and thus two irregular-shaped angular pieces of bone are produced.

The single nodule from which the greater part of the body of the vertebra is formed appears in the middle of the cartilage.

At the usual period of birth the three primary pieces are still separate. The process of union commences in the first year after birth. It commences with the lateral pieces, which, at the period mentioned, begin to join behind—in the situation of the spinous process; and by this junction the arch of the vertebra is constructed.

In the course of the third year the central anterior part joins the arch on each side in a few of the vertebræ, and the junction is effected in such manner that the body is formed from the three original centres of ossification. Each end of the arch contributes a small angular portion (fig. 41, B).

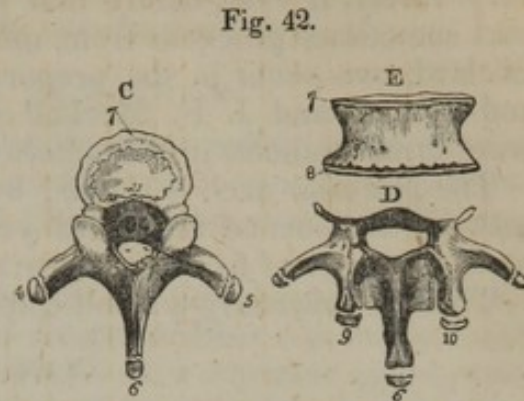
*Epiphyses.*—The spinous process projects backwards from the point at which the lateral pieces have joined, and no further change occurs except the general increase of the different parts of the vertebra and the extension of ossification from the primary pieces, till about the age of puberty. If the bone is examined before that period it will be found, on stripping the cartilaginous ends from the transverse and spinous



processes, that the cells of the osseous structure are exposed; and on separating the bodies of the vertebræ one from the other, the cartilages, which still belong to their upper and lower surfaces, remain adherent to the intervertebral substance, and the osseous part is rough, fissured, and wanting at its circumference the angular shape and dense external covering which belongs to the perfect bone (fig. 41, B).

At the age of about sixteen years, separate osseous points begin to be observable in the cartilaginous ends of the transverse and spinous processes, and they ultimately cover and complete the processes (fig. 42, c, <sup>4 5 6</sup>). At a later period, soon after twenty years, two thin circular plates begin to be formed, one on the upper, the other on the lower surface of the body, at its circumference (fig. 42, c, E, <sup>7 8</sup>).

All the secondary or accessory pieces having joined, the bone is completed before the thirtieth year.—The epiphyses of the transverse and spinous processes usually join before those which belong to the bodies of the vertebra.



These figures are intended to show the epiphyses of a vertebra. That marked c represents a dorsal vertebra. The epiphyses of the processes are drawn slightly away from the rest of the bone. D. The arch and processes of a lumbar vertebra, with the epiphyses. These are somewhat elongated, corresponding to the processes which they cover, but the bone having been viewed from above, their ends only came under the artist's eye; and this circumstance will account for their small size in the drawing. E. A front view of the body of a vertebra to exhibit the thin epiphyses which belong to its upper and lower surfaces. 4, 5. The ends of the transverse processes. These processes are not numbered in figure D. 6. Spinous process. 7, 8. The two epiphyses of the body; the flat surface of one is seen in figure c; the edges of both are marked in figure E. 9, 10. Epiphyses of the articular tubercles of a lumbar vertebra.

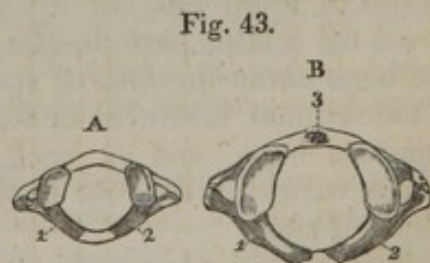
#### b. PECULIARITIES IN THE GROWTH OF CERTAIN VERTEBRÆ.

The vertebræ which require separate notice, by reason of some peculiarities in their manner of growth, are the first, second, and last cervical; those of the lumbar region; together with the sacrum and coccyx.

#### THE ATLAS.

The *atlas* is usually formed from three principal osseous nuclei. The ossification of the lateral parts of the vertebra (fig. 43, <sup>1 2</sup>) commences at a very early period.

At birth the interval between the articular processes of the vertebra (the anterior arch) is altogether cartilaginous, and there is a smaller space posteriorly between the two lateral pieces (fig. 43, A).



The atlas is seen from above in both figures. A. The lateral pieces are separated by a cartilaginous interval in front and behind. B. This figure is intended to show a nucleus in the anterior arch. It has been modified from one given by Kerckringius in his 37th plate.



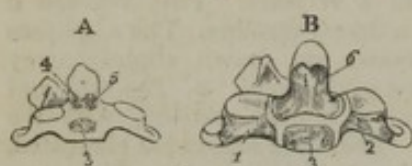The nucleus for the anterior arch (fig. 43,<sup>3</sup>) appears soon after birth, very rarely, if ever, before that period. But the ossification in this part sometimes proceeds from more than one centre. According to Béclard, two occur in the proportion of one instance in four or five; and Albinus<sup>1</sup> and J. F. Meckel<sup>2</sup> observed each a case in which there were three granules in the anterior arch.

The posterior arch is formed by the junction of the lateral pieces, between the second and third years, and the arch joins the anterior part at the age of five or six years.

There is frequently a small epiphysis on the posterior tubercle.

#### THE AXIS.

Fig. 44.



The anterior surface of the axis is represented in both drawings. A. The three nuclei for the anterior part are here shown. In B, four pieces are seen connected by cartilage.—1, 2. The lateral pieces. 3. The nucleus for the lower part of the body. 4, 5. Those for the odontoid process and the upper part of the body. 6. The single piece resulting from the junction of 4 and 5. The formation of the arch of the axis corresponds with other vertebræ. The peculiarities occur in the anterior part, which is developed from three points or centres—one being destined for the lower part of the body, the two others for the odontoid process and the upper part of the body (fig. 44,<sup>3 4 5</sup>). These nuclei appear about the sixth month of fœtal life, the lower single one preceding the others by a short space of time. The two superior lying on the same horizontal plane, enlarge and join before birth. At this period the axis consists of four pieces—the two lateral and two anterior (B,<sup>1 2 3 6</sup>). The body and odontoid process form a single mass about the fourth year (second or third, Béclard).

#### THE SEVENTH CERVICAL VERTEBRA.

The anterior part of the transverse process of this vertebra is frequently, if not constantly, formed from a separate osseous nucleus, which unites on the one hand to the body, and on the other to the posterior division of the transverse process. The time of the appearance of this point of ossification is stated by Béclard to be the second month of fœtal life, but my own observation would lead me to set it down for a later period—the sixth month. It is united to the rest of the bone about the fifth or sixth year.

Occasional instances occur of the continuance of this process as a separate bone, and in such cases,—being lengthened to an extent which varies in different instances,—it forms what has been termed a cervical rib.<sup>3</sup>

Meckel<sup>4</sup> also observed separate centres of ossification in the trans-

<sup>1</sup> "Icones Ossium Fœtus," p. 68.

<sup>2</sup> "Archiv." &c. Band 1, S. 648, and Taf. vi. 1815.—Meckel's case had the additional peculiarity of a separate nucleus interposed between the lateral pieces posteriorly.

<sup>3</sup> Two examples of a cervical rib are described in "The Anatomy of the Arteries, with its applications," &c. by R. Quain, pp. 149 and 187, and plate 25. J. F. Meckel ("Archiv." &c. B. 1, Taf. vi. 1815,) has figured a case resembling one of those in the circumstance of the end of the cervical rib being connected to a prominence on the first proper rib.

<sup>4</sup> Loc. citat.; and "Journal Complement. du Dict. des Sciences Med." vol. ii. p. 218.



verse processes of the second, the fifth, and sixth cervical vertebræ. These were, however, of small size, and in some instances did not form any part of the foramen for the vertebral artery.

#### THE LUMBAR VERTEBRÆ.

In addition to the centres of ossification which belong to the vertebræ generally, those of the lumbar region have each two small epiphyses for the tubercles that project from their superior articular processes (fig. 42, D, <sup>9</sup> <sup>10</sup>).

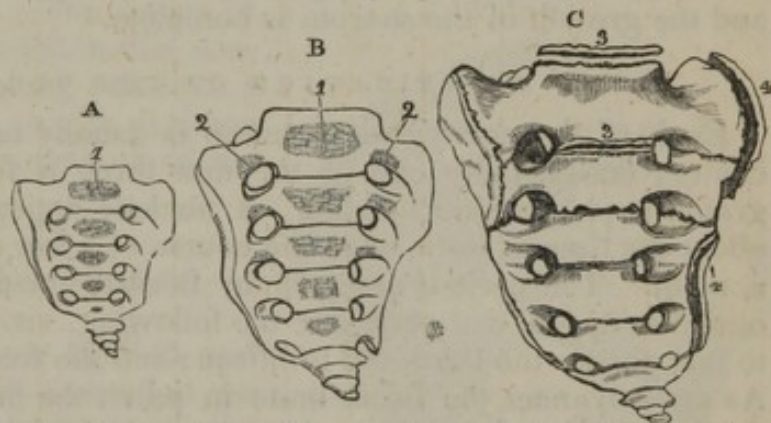
The so-named transverse process of the first lumbar vertebra is sometimes observed to be developed altogether from a separate centre. The persistence of a process so formed, as a separate piece, would account for the existence of a lumbar rib,—examples of which have occasionally been met with.

#### THE SACRUM.

The *sacrum* results from the union of five vertebræ. In the manner of their ossification these do not at an early period differ from the vertebræ in other parts of the column.

About the sixth month characteristic osseous tubercles, three in number on each side, begin to appear, close to the sacral foramina; between them, except the first (B <sup>2</sup> <sup>2</sup>). They belong to the first three vertebræ, and are successively deposited from the sixth to the eighth or ninth month—the highest appearing first and the lowest last. Each of the first three pieces of the sacrum has thus two

Fig. 45.



These figures display different stages of the ossification of the sacrum. Fig. A. taken from a fœtus which had not reached the sixth month, contains in front only the nuclei for the bodies. In fig. B. (from a child at the usual period of birth) three additional nuclei are deposited on each side, close to the sacral foramina. The coccyx has no ossific point. Fig. C. is from a body aged about twenty-five years. Epiphyses are visible on the sides of the bone, and are still apparent on the body of the first vertebra. The lower vertebræ have completely joined, whilst the first two are but partially united.—1. The body. 2. Nuclei peculiar to the sacrum. 3, 3. Epiphyses for the body of a sacral vertebra. 4, 4. Lateral epiphyses.

centres of ossification added to those which belong to other vertebræ.

The lateral pieces join behind to constitute the arch, and subsequently become united to the body in the manner of other vertebræ; but the order in which this junction occurs in the different pieces is deserving of notice. The process of union commences in the lowest vertebra, and progressively extends upwards. The parts of the fifth are joined about the second year, while the first does not appear as a single piece before the fifth or sixth year.

The sacral vertebræ remain separate one from the other, being



united only by cartilage and the intervertebral substance, till about the sixteenth year. At this period they begin to unite one to another, and epiphyses begin to form.

*Epiphyses.*—On the middle part or body of each sacral vertebra the epiphyses are similar to those on the same part in other vertebræ. (c, <sup>3 3</sup>.)

On each side of the sacrum there are formed two thin flat plates, one of which embraces the first three vertebræ, and the other connects the last two (c, <sup>4 4</sup>). The ossification of these lateral epiphyses begins about the eighteenth or twentieth year, by several irregular granules, which increase and coalesce. As the sides of the sacrum may be considered in part to result from the enlargement and union of the transverse processes, or parts analogous to them, so may the lateral epiphyses be taken to represent the epiphyses of those processes,—altered, indeed, and, as it were, fused together.

*The consolidation of the sacrum.*—About the time last mentioned (the eighteenth year) the fourth and fifth vertebræ are joined one to the other, and the process of union gradually proceeding upwards (fig. 45, c), reaches the first two from the twenty-fifth to the thirtieth year; at which period the lateral epiphyses become part of the general mass, and the growth of the sacrum is complete.

#### OSSIFICATION OF THE COCCYX.

Each of the coccygeal vertebræ is usually ossified from a single centre; occasionally one of the first three is found to contain two granules, placed side by side. A nucleus appears in the first piece about the time of birth, or in the course of a few months after (fig. 45, b, note). The periods assigned by Béclard for the ossification of the other coccygeal vertebræ are the following, viz. for the second, five to ten years; the third, ten to fifteen; and the fourth fifteen to twenty. As age advances the bones unite in pairs, the first to the second, the third to the fourth; and at a later period of life, they are formed into a single piece by the union of the third and fourth. Lastly, the coccyx becomes joined to the end of the sacrum in old age, and this is said to occur most frequently in the female.

#### c. THE PROGRESS OF OSSIFICATION IN THE VERTEBRAL COLUMN GENERALLY.

In the observations on the growth of a single vertebra the date at which the osseous points appear for the first time in the column has been mentioned; but inasmuch as the same parts do not begin to ossify simultaneously throughout the spine, it becomes necessary to review the progress of ossification in the vertebral column as a whole, for the purpose of indicating the differences that exist in these respects.

The ossification of the lateral pieces begins at the upper end of the column, and gradually proceeds downwards to its opposite end.

In the bodies of the vertebræ the deposit of bone first occurs in the lower part of the dorsal region (about the ninth dorsal vertebra), and from this the process is extended upwards and downwards, reaching



last of all the atlas at one extremity, and the coccyx at the other; both of which, as has been previously stated, do not ossify till after birth. But it is to be borne in mind, that though the nuclei of the lower dorsal vertebræ appear first, they do not long continue the largest. As growth advances they are surpassed in size by those below them, and in the full-grown fœtus the nuclei are largest in the lower lumbar and the first sacral vertebræ. In fact, their relative size at this period corresponds with that of the vertebræ.

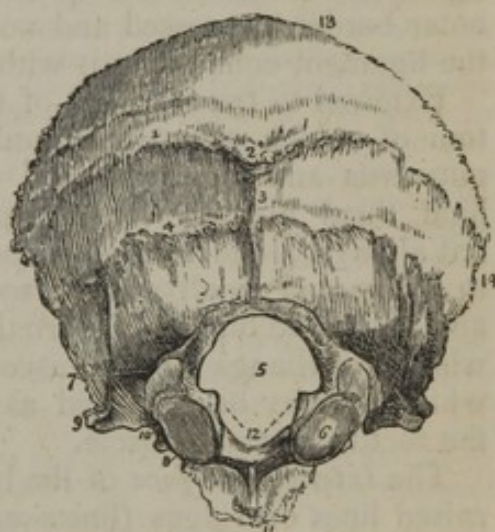### THE BONES OF THE SKULL.

The skull is of a spheroidal figure, compressed on the sides, broader behind than before, and supported by its base on the vertebral column. It is divided by anatomists into two parts, the cranium and the face; the former being composed of eight bones, viz., the *occipital*, two *parietal*, the *frontal*, two *temporal*, the *sphenoid*, and the *ethmoid*; the latter is made up of fourteen bones, viz., two *superior maxillary*, two *malar*, two *ossa nasi*, two *ossa palati*, two *ossa unguis*, two *inferior turbinated* bones, the *vomer*, and *inferior maxilla*; the frontal bone is so situated as to be common to the cranium and face. The bones of the ear are not included in this enumeration, as they belong rather to a special organ than to the skeleton considered as the framework of the body.

#### THE OCCIPITAL BONE.

The occipital bone, figs. 46 and 47, (*os occipitis*), is situated at the posterior part of the base of the skull; broad behind, much narrowed before, of a trapezoid figure, presenting two surfaces, four borders, and four angles. To place the bone in its natural position, hold it so that the great foramen and the articulating processes beside it shall look directly downwards; the thick process in front of the foramen will then project forwards into the base of the skull, whilst the broad expanded part behind it arches upwards and a little forwards, forming the posterior wall of the cavity. *External surface*: this is convex in its general outline, and presents a little above its centre a rough prominence,<sup>2</sup> the *external occipital protuberance*, the part between which

[Fig. 46.



The external surface of the occipital bone. 1. The superior curved line. 2. The external occipital protuberance. 3. The spine. 4. The inferior curved line. 5. The foramen magnum. 6. The condyle of the right side. 7. The posterior condyloid fossa, in which the posterior condyloid foramen is found. 8. The anterior condyloid foramen, concealed by the margin of the condyle. 9. The transverse process; this process upon the internal surface of the bone forms the jugular eminence. 10. The notch in front of the jugular eminence which forms part of the jugular foramen. 11. The basilar process. 12, 12. The rough projections into which the odontoid ligaments are inserted.—W.]

the *external occipital protuberance*, the part between which



and the superior angle is smooth. Extending obliquely outwards at each side from the protuberance is a rough line,<sup>1</sup> called the *superior curved line*, to distinguish it from another, which is lower down between it and the great foramen, called the *inferior curved line*;<sup>4</sup> both are prominent, and give attachment to muscles, as also do the rough depressions between them. These are crossed by a vertical raised line (*external occipital crest or spine*),<sup>3</sup> extending forwards from the protuberance to the foramen magnum.

The *occipital foramen*,<sup>5</sup> (foramen magnum,) which is of an oval figure, (its long diameter extending from before backwards,) gives transmission to the spinal cord, the vertebral arteries, and spinal accessory nerves.

At each side of the foramen, but nearer its anterior part, are situated the articulating processes,<sup>6</sup> (*condyles*), two oblong eminences, which articulate with the first vertebra. These converge from behind forwards; their inferior surface, which in the fresh state is smooth, covered with cartilage, and convex in its general outline, looks downwards and outwards, and is adapted for moving on the concave surface presented by the articulating processes of the atlas. The inner border of each condyle<sup>12</sup> is rough, and receives the insertion of the check ligaments, which extend up from the odontoid process of the axis; the outer border, depressed and not so well marked, gives attachment to the ligament connecting it with the atlas.

External to the fore-part of the condyles are two fossæ, in the bottom of which are two foramina,<sup>8</sup> (*anterior condyloid*), which look outwards and forwards, and transmit the hypoglossal nerves; behind them are also two larger pits,<sup>7</sup> in which are generally, but not always, found foramina, (*posterior condyloid*), which give passage to a vein and small artery: sometimes a foramen exists at one side, and not at the other. External to each condyle is a rough surface,<sup>9</sup> which overhangs the transverse processes of the vertebræ, and of which it may be regarded as the "analogue;" it gives insertion to the rectus lateralis muscle.

The *internal surface* of the bone (fig. 47,) is marked by two crucial raised lines or ridges (*lineæ cruciatæ eminentes*),—one vertical, extending from the upper angle of the bone to the great foramen, and the other transverse from one lateral angle to the other. These intersect towards the central point,<sup>10</sup> (internal occipital protuberance,) and mark off four broad pits, of which the upper pair,<sup>1</sup> (superior occipital fossæ,) receive the posterior lobes of the brain, and the lower,<sup>2</sup> (inferior occipital fossæ) lodge the lateral lobes of the cerebellum; the superior line<sup>3</sup> and the two transverse ones<sup>5</sup> are generally grooved, and correspond with the course of the longitudinal and lateral sinuses. The inferior one,<sup>4</sup> which is commonly named the internal occipital spine or crest, gives attachment to the falx cerebelli. The anterior border of the foramen magnum is slightly excavated, and becomes continuous with the *basilar groove*,<sup>8</sup> a shallow excavation on the surface of the basilar process, which supports the medulla oblongata; close to the margin of the foramen are the anterior condyloid fora-



mina, and a little external to it are two fossæ,<sup>9</sup> marking the terminations of the lateral sinuses.

The thick triangular process<sup>8</sup> which projects forwards into the base of the skull from the foramen, is called the *basilar process*; its margins are rough, and contiguous to the pars petrosa of the temporal bone; its under surface presents slight depressions for the insertion of muscles, and the upper one the shallow groove just noticed. Along the lateral margins of this groove, and close to the edges of the bone, are two linear depressions, which form part of the grooves for the inferior petrosal sinuses.

The *superior borders*<sup>11</sup> of the occipital bone are dentated and converge to a point, but are frequently interrupted by bony islets (*ossa triquetra*—Wormiana); the inferior border at each side is divided into two parts by a prominent piece of bone,<sup>9</sup> the *jugular eminence*, which surmounts an excavation<sup>10</sup> (jugular notch or fossa) contributing with the temporal bone to form the foramen lacerum.

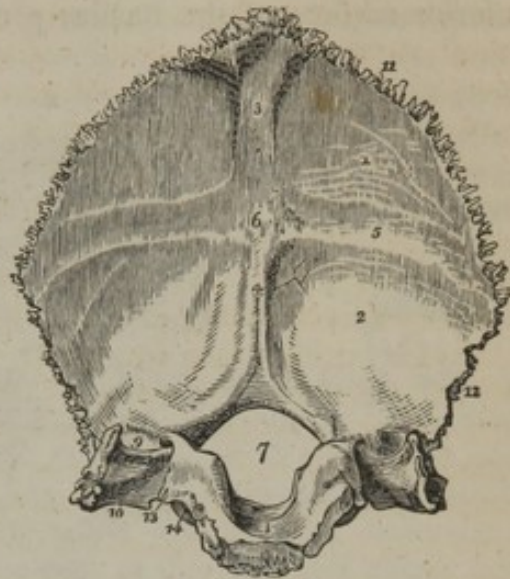
The *superior angle* is acute, and received into the retiring angle formed by the posterior border of the parietal bones; the anterior is represented by the extremity of the basilar process, which is thick, and in the adult shows the internal structure of the bone, because of being sawed from the sphenoid; the lateral angles, not very prominent, correspond with the line at which the postero-inferior angle of the parietal bone joins with the mastoid part of the temporal.

In some parts the occipital bone has considerable thickness, especially at the occipital protuberances and the anterior part of the basilar process. In the lower occipital fossa it is very thin.

*Articulations.*—The occipital articulates with six bones, viz., with the two parietal by its superior borders—the two temporal by the inferior—with the sphenoid by its basilar process—and with the atlas by the condyles.

*Attachments of muscles.*—On each side—the posterior third of the superior curved line gives attachment to the trapezius; its anterior two-thirds to the occipito-frontalis above, and to the sterno-mastoid below: the inner part of the space between the curved lines to the

[Fig. 47.]



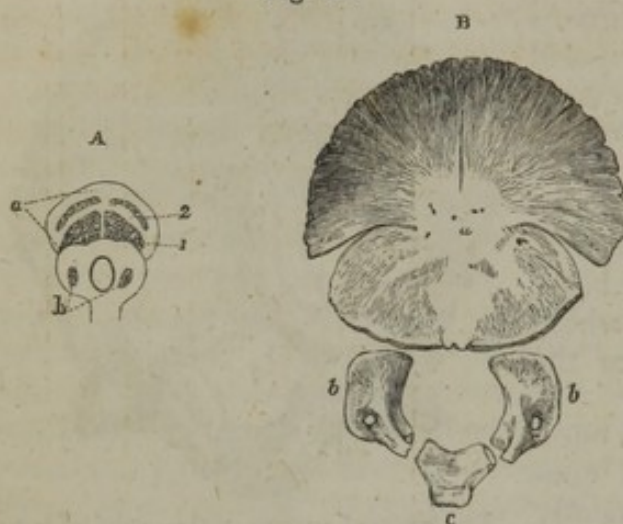The internal surface of the occipital bone.

1. The left cerebral fossa. 2. The left cerebellar fossa. 3. The groove for the posterior part of the superior longitudinal sinus. 4. The spine for the falx cerebelli, and groove for the occipital sinuses. 5. The groove for the left lateral sinus. 6. The internal occipital protuberance. 7. The foramen magnum. 8. The basilar process, grooved for the medulla oblongata. 9. The termination of the groove for the lateral sinus, bounded externally by the jugular eminence. 10. The jugular fossa; this fossa is completed by the petrous portion of the temporal bone. 11. The superior border. 12. The inferior border. 13. The border which articulates with the petrous portion of the temporal bone, and which is grooved by the inferior petrosal sinus. 14. The anterior condyloid foramen.—W.]



complexus: the external part to the splenius capitis: the space between the lower ridge and the great foramen to the recti (major and minor), and more outwardly to the obliquus superior: the under surface of the jugular eminence to the rectus lateralis: the fossa at the inferior surface of the basilar process to the recti antici (major and

Fig. 48.



The occipital bone at different periods of its growth,—namely, about the tenth week and at the ordinary period of birth. The figure marked A. has been copied from one published by Meckel in his "Archiv." (B. 1, Taf. vi.) The four nuclei of the posterior or proral part of the bone are shown,—the two lower being the more advanced. Germs of ossification are observable in the condyloid pieces. There is none apparent in the basilar part.

placed in pairs above and below the occipital protuberance (fig. 48, A<sup>1 2</sup>). The two inferior nuclei appear first, and soon join into a single piece. The superior pair of granules unite one to the other also, and the two pieces thus resulting from the four primitive centres uniting speedily form a single mass.<sup>1</sup>

Soon after the posterior part of the bone, the two condyloid pieces begin to ossify (A, b), and they are followed by the basilar portion. Each is formed from a single central point. It is to be observed that the condyles of the occipital bone are not supported altogether on the pieces named condyloid;—a small portion of each is borne by the basilar part.

<sup>1</sup> J. F. Meckel ("Handbuch der Menschlich. Anat." B. 2, § 543,) assigns eight primitive granules to this part. Four he makes to correspond with those described in the text. Of the other four he places two close together at the upper angle of the bone; and the remaining two in its lateral angles, one at each side.

Judging from the usual appearance or texture of the upper and lateral parts of the occipital bone at early periods of its growth, it seems to me to be most probable that the four points found by Meckel in its angles do not occur constantly, or even generally; and if so, may they not be regarded as the centres of some of those separate pieces which are often to be met with in the neighbourhood of this bone? I would add, as facts bearing on the question, that an independent lateral nucleus existed only on one side of the preparation by which Meckel seems to have been influenced in forming his judgment on the number of the centres of ossification, (see the figure in his "Archiv. für die Physiolog." B. 1, Taf. vi.—1815); and that the upper part of the bone is occasionally altogether detached.

minor), and still more anteriorly to the superior constrictor of the pharynx.

*Ossification of the occipital bone.*—During a considerable time before and after birth this bone consists of four pieces,—namely, the posterior, proper occipital or proral part: the anterior or basilar: and the two lateral or condyloid (fig. 48, B.) These pieces meet around the foramen magnum. Each of them requires separate notice.

The ossification of the occipital bone precedes that of the vertebræ in the time of its appearance. It begins with the proper occipital part. For this division there are four nuclei, which are



At birth the four pieces are distinct, (fig. 48, B, *a, b, c,*) and the posterior one is partially divided by deep fissures, (two being horizontal and one vertical,) extending from the circumference towards its middle.

About the fourth year of age the process of union begins by the junction of the posterior and the two condyloid pieces, and the bone is a single piece about one or two years later. Subsequently the occipital unites with the sphenoid bone, so that, in the adult, the basilar process must be sawed across in order to separate them. And it was in consequence of this circumstance that Sæmmering described them as a single bone under the name *spheno-occipital* or *basilar*.

#### THE PARIETAL BONE.

The parietal bones (*ossa parietalia, verticis, bregmatis*) form a principal part of the roof of the skull; they are of a square form, convex externally, concave internally, and present each two surfaces and four borders. The external surface, fig. 49, rises towards its middle, where it presents a slight elevation, called the *parietal eminence*,<sup>5</sup> below which is a curved line, forming part of the temporal ridge, and bounding a flat surface (*planum semicirculare*), which forms a part of the temporal fossa. At the upper and back part of the bone, usually about two lines from the sagittal suture, is a small hole,<sup>6</sup> (*foramen parietale*,) which transmits a communicating vein; its position is exceedingly variable; even its existence is not constant.

[Fig. 49.

Fig. 50.

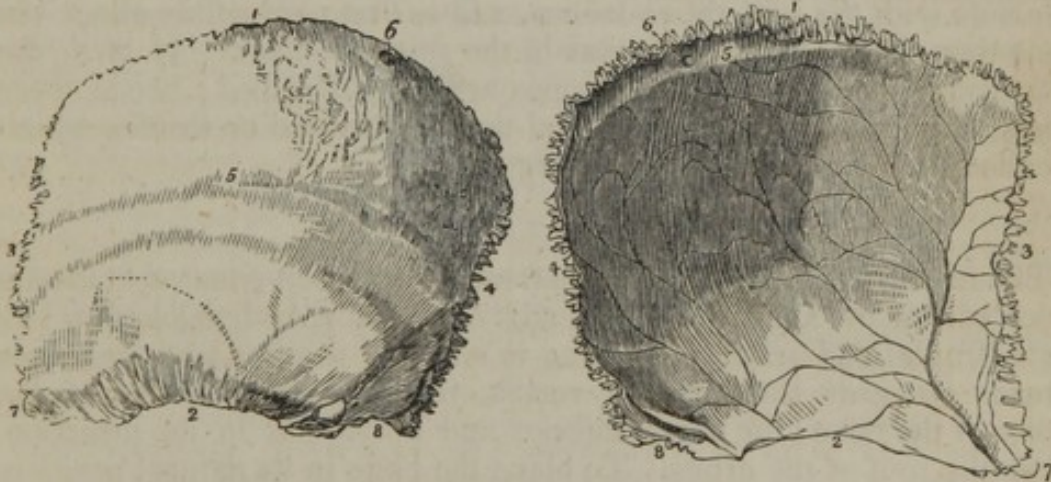

Fig. 49. The external surface of the left parietal bone. 1. The superior or sagittal border. 2. The inferior or squamous border. 3. The anterior or coronal border. 4. The posterior or lambdoidal border. 5. The temporal ridge: the figure is situated immediately in front of the parietal eminence. 6. The parietal foramen, unusually large in the bone from which this figure was drawn. 7. The anterior inferior angle. 8. The posterior inferior angle.

Fig. 50. The internal surface of the left parietal bone. 1. The superior or sagittal border. 2. The inferior, or squamous border. 3. The anterior, or coronal border. 4. The posterior, or lambdoidal border. 5. Part of the groove for the superior longitudinal sinus. 6. The internal termination of the parietal foramen. 7. The anterior inferior angle of the bone, on which is seen the groove for the trunk of the arteria meningeae media. 8. The posterior inferior angle, upon which is seen a portion of the groove for the lateral sinus.—W.]



The internal surface of the bone, fig. 50, is marked by branching lines (sulci meningei), corresponding with the course of the middle meningeal artery, and by depressions (impressiones digitatæ) for the convolutions of the brain. Towards its middle is a depression, "parietal fossa," corresponding with the eminence (parietal) on the outside. Along the superior border is a slight depression,<sup>5</sup> which with a similar one in the corresponding bone forms a groove adapted to the course of the longitudinal sinus; and in the same situation (in most skulls, particularly those of old persons) are some small pits (fovæ glandulares), corresponding with the so-named glandulæ Pacchioni.

The superior border is straight, and articulated with its fellow by a series of dentations; the inferior border, concave and bevelled off at its outer margin, is overlapped by the squamous portion of the temporal bone; the anterior unites with the frontal bone, and the posterior with the occipital.

The anterior inferior angle,<sup>7</sup> dips down to the great wing of the sphenoid bone, and presents a groove,<sup>7</sup> internally for the middle meningeal artery: the posterior inferior angle,<sup>8</sup> articulates with the mastoid part of the temporal bone, and presents internally a small part of the groove which lodges the lateral sinus.

Each parietal bone gives attachment to the temporal muscle by that part of its surface which lies beneath the temporal ridge (planum semicirculare): the remainder of its outer surface is covered by the aponeurosis of the occipito-frontalis.

*Articulations.*—It articulates with its fellow of the opposite side, and with the frontal, the sphenoid, the temporal, and the occipital bones.

*Ossification.*—Its growth proceeds from one ossific centre, which corresponds with the parietal eminence, and is first perceptible about the same time that ossification begins in the spinal column. At birth the antero-superior angles of these bones are not developed; hence there exists an interval between them and the still divided os frontis, which is called the "fontanelle" (fons, bregma).

#### THE FRONTAL BONE.

The frontal bone, figs. 51, 52, (os frontis, coronale,) situated at the anterior part of the skull, and upper part of the face, is divisible into two parts (frontal and orbital), differing in size and position: of these, one extends upwards towards the vertex, forming three-fourths of the extent of the bone; the other, inferior and horizontal in its direction, forms the roof of the orbits. To place the bone in its natural position, hold it so that the orbital plates shall look downwards, and the smooth convex surface forwards.

*The frontal part.*—Its *external surface* is smooth, and presents on each side a slight elevation,<sup>1</sup> named *frontal eminence*, which corresponds with the most prominent part of the forehead: beneath this is an arched depression, bounded below by a prominent curved line,<sup>2</sup> called the *superciliary ridge*, or arch, which is more or less prominent in different individuals. Immediately beneath this is the margin of the orbit (*orbital arch*),<sup>3</sup> which is better defined towards its outer part,



where it curves down to the malar bone, and forms the external angular process,<sup>4</sup> than at its inner portion,<sup>5</sup> where it gradually subsides towards the root of the nose. Towards the inner third of the orbital arch is a small foramen,<sup>6</sup> (*supra-orbital*), or sometimes a notch, crossed by a ligament, which transmits the supra-orbital nerve and artery.

Between the superciliary ridges is the *nasal eminence*,<sup>7</sup> or glabella, which is prominent in proportion to the size of the frontal sinuses: it is bounded inferiorly by a rough surface which articulates with the

[Fig. 51.

Fig. 52.

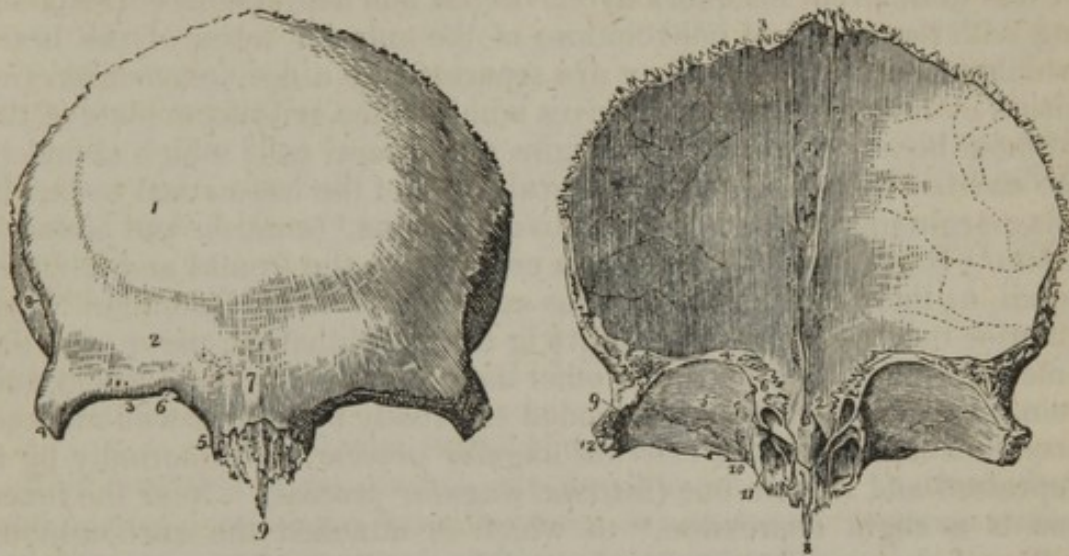


Fig. 51. The external surface of the frontal bone. 1. The situation of the frontal eminence of the right side. 2. The superciliary ridge. 3. The supra-orbital ridge. 4. The external angular process. 5. The internal angular process. 6. The supra-orbital notch for the transmission of the supra-orbital nerve and artery; in the figure it is almost converted into a foramen by a small spiculum of bone. 7. The nasal tuberosity; the swelling around this point denotes the situation of the frontal sinuses. 8. The temporal ridge, commencing from the external angular process (4). The depression in which the figure 8 is situated is a part of the temporal fossa. 9. The nasal spine.

Fig. 52. The internal surface of the frontal bone; the bone is raised in such a manner as to show the orbito-nasal portion. 1. The grooved ridge for the lodgment of the superior longitudinal sinus and attachment of the falx. 2. The foramen cæcum. 3. The superior or coronal border of the bone; the figure is situated near that part which is bevelled at the expense of the internal table. 4. The inferior border of the bone. 5. The orbital plate of the left side. 6. The cellular border of the ethmoidal fissure. The foramen cæcum (2) is seen through the ethmoidal fissure. 7. The anterior and posterior ethmoidal foramina; the anterior is seen leading into its canal. 8. The nasal spine. 9. The depression within the external angular process (12) for the lachrymal gland. 10. The depression for the pulley of the superior oblique muscle of the eye; immediately to the left of this number is the supra-orbital notch, and to its right the internal angular process. 11. The opening leading into the frontal sinuses: the leading line crosses the internal angular process. 12. The external angular process. The corresponding parts are seen on the other side of the figure.—W.]

nasal bones and the ascending processes of the superior maxilla. From this surface projects downwards in the median line a flat thin process<sup>9</sup> called the *nasal spine*; it articulates in front with the nasal bones, and behind with the perpendicular lamella of the ethmoid.

The *internal surface* of this part of the bone is concave, and presents along the median line a groove (*sulcus frontalis*), fig. 52,<sup>1</sup> corresponding with the longitudinal sinus. The margins of the groove



gradually approach towards the fore part of the bone, and in some cases unite so as to form a ridge (*crista frontalis*); but in others the groove, narrowed almost to a line, continues apparent down to the foramen cæcum. In either case it gives attachment to the falx; this ridge terminates in a minute foramen,<sup>2</sup> called *foramen cæcum*, from its having been supposed to be merely a cul-de-sac, but it is in reality pervious, and lodges a small spur-like process of the dura mater, and transmits a vein which enters the sinus from the nasal fossæ.

The *orbital plates*<sup>5</sup> or processes are smooth and concave at their inferior surface; the superior or cerebral is convex, and marked more or less in different instances by elevations and depressions corresponding with the sulci and convolutions of the anterior lobes of the brain which rest upon them. They are separated by a deep excavation (*incisura ethmoidalis*), which receives within it the cribriform plate of the ethmoid bone, and round its margins are several cells which complete the cavities lodged within the lateral parts of the last-named bone. In this margin may also be observed two foramina,<sup>7</sup> (*anterior* and *posterior orbital*,) [*or ethmoidal*,] which are common to the frontal and ethmoid bones, as their contiguous margins contribute to their formation. The anterior one transmits the nasal twig of the ophthalmic nerve, and the anterior ethmoidal artery; the other the posterior ethmoidal artery and vein. Each orbital plate is bounded externally by a thick well-marked prominence,<sup>12</sup> called the *external angular process*; and internally by a depressed and smooth one (*internal angular process*). Near the inner one is a slight depression,<sup>10</sup> to which is attached the cartilaginous pulley of the trochlearis muscle, and hence sometimes named *fovea trochlearis*; near the outer process and within the orbit, is a depression<sup>9</sup> for the lodgment of the lachrymal gland; the external side of this process is slightly hollowed, fig. 51, and forms part of the temporal fossa.

The thickness of the frontal bone varies considerably in different parts of it. The orbital plates are thin and translucent; the nasal and external angular processes are thick and prominent. The upper or broad part is thinner at the frontal eminences than elsewhere, if these are well marked so as to indicate a full development of the corresponding cerebral parts. In childhood the two tables are separated only by the diploe, as in other bones; but, in adult age, an interval exists between them at the middle line over the nasal process, and extending outwards for some way under the superciliary ridges. This interval, the extent of which varies in different individuals, is divided by a ridge of bone into two parts or cavities,<sup>11</sup> called the *frontal sinuses*; they are lined by mucous membrane, and communicate with the anterior ethmoidal cells. [In some rare instances these sinuses are never developed.]

*Articulations.*—The frontal articulates with twelve bones; superiorly with the two parietal; laterally and behind with the sphenoid; inferiorly with the ethmoid, with the nasal bones, with the ossa unguis, with the ascending processes of the superior maxillary bones, and with the malar bones. The mode of articulation differs in different parts of its circumference. Thus, the superior border is found to overlap and rest



on the parietal bones, whilst towards the lateral and inferior parts the exterior table of the bone is bevelled off, and is covered in by the parietal. The posterior border of the orbital plates, straight and squamous, is in a manner inserted between the margins of the two alæ of the sphenoid bone, with each of which it articulates.

*Attachments of muscles.*—It gives attachment to the corrugator supercilii—to a small part of the temporal and of the orbicularis palpebrarum.

*Ossification.*—This bone begins to ossify before the vertebræ, from two osseous points, which appear at the orbital arches.\*

The lateral pieces formed by the spreading of the ossification are quite distinct at birth (fig. 53, *a b*). They afterwards be-

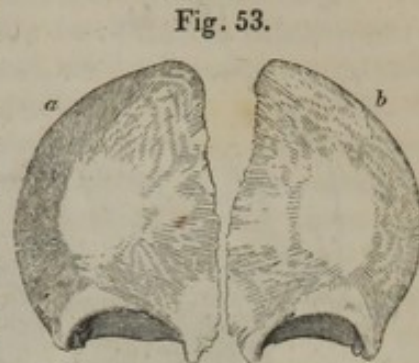


Fig. 53.  
From the frontal bone of a fetus born a short time before the usual period of birth.

come united along the middle by a straight suture, which runs from the vertex, where it is continuous with the sagittal suture, down to the nose. The suture is obliterated within a few years after birth, but the period varies in different cases, and in some instances it is found to remain during life.

#### THE TEMPORAL BONE.

The temporal bones, two in number, are so named because they occupy that part of the head on which the hair first becomes white, and thus indicates the ravages of time (*ossa temporis*).

The *temporal* bone, figs. 54 and 55, (*os temporis*), is placed at the side and base of the skull. When viewed in its natural position, it presents two portions, one at the side of the skull towards its middle and lower part, which is flat and vertical in its direction; whilst the other is horizontal and projects inwards so as to be wedged between the occipital and sphenoid bones. But to facilitate its description, it may be divided into three parts, of which one is superior, flat, scale-like, and named the squamous portion (*squama*, a scale); another posterior, thick at its base, but tapering downward like a nipple, the mastoid part; the third, called petrous from its hardness, is internal and intermediate, projecting into the base of the skull.

A. The *squamous* portion,<sup>1</sup> (*pars squamosa*), by its external surface which is smooth, forms part of the temporal fossa, and is bounded above by an arched border, below by a horizontal process called “zygoma.” The inner surface, fig. 55,<sup>1</sup> of the squamous part of the bone, slightly concave in its general outline, is marked by cerebral impressions like the other bones of the head, and by slight linear grooves for branches of the middle meningeal artery. Its upper edge is bevelled off so as to form a thin scale which overlays the parietal bone.

The *zygoma*,<sup>2</sup> or zygomatic process, (*ζευγνυμι*, to connect or yoke together,) forms a yoke connecting the temporal with the malar bone, and under which the temporal muscle passes; it is broad posteriorly at

[\* For a short period the orbital and frontal portions are almost on a plane with each other.—J. L.]



its base, where it projects outward from the squamous part of the bone, but soon narrows, and turns forward; its outer surface, fig. 54,<sup>4</sup> is convex and subcutaneous, the inner surface is concave and bounds the tem-

[Fig. 54.

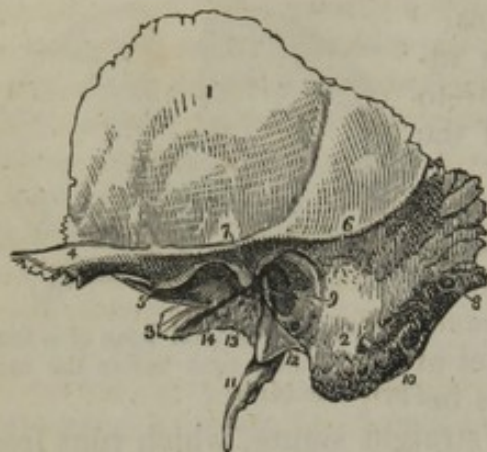

Fig. 55.

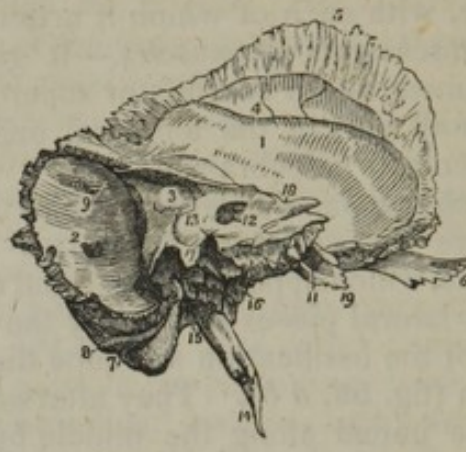

Fig. 54. The external surface of the temporal bone of the left side. 1. The squamous portion. 2. The mastoid portion. 3. The extremity of the petrous portion. 4. The zygoma. 5. Indicates the tubercle of the zygoma, and at the same time its anterior root turning inwards to form the eminentia articularis. 6. The superior root of the zygoma, forming the posterior part of the temporal ridge. 7. The middle root of the zygoma, terminating abruptly at the glenoid fissure. 8. The mastoid foramen. 9. The meatus auditorius externus, surrounded by the processus auditorius. 10. The digastric fossa, situated immediately to the inner side of (2) the mastoid process. 11. The styloid process. 12. The vaginal process. 13. The glenoid or Glaserian fissure; the leading line from this number crosses the rough posterior portion of the glenoid fossa. 14. The opening and part of the groove for the Eustachian tube.

Fig. 55. The left temporal bone, seen from within. 1. The squamous portion. 2. The mastoid portion. The number is placed immediately above the inner opening of the mastoid foramen. 3. The petrous portion. 4. The groove for the posterior branch of the arteria meningea media. 5. The bevelled edge of the squamous border of the bone. 6. The zygoma. 7. The digastric fossa immediately internal to the mastoid process. 8. The occipital groove. 9. The groove for the lateral sinus. 10. The elevation upon the anterior surface of the petrous bone marking the situation of the perpendicular semicircular canal. 11. The opening of termination of the carotid canal. 12. The meatus auditorius internus. 13. A dotted line leads upwards from this number to the narrow fissure which lodges a process of the dura mater. Another line leads downwards to the sharp edge which conceals the opening of the aquæductus cochleæ, while the number itself is situated on the bony lamina which overlies the opening of the aquæductus vestibuli. 14. The styloid process. 15. The stylo-mastoid foramen. 16. The carotid foramen. 17. The jugular process. The deep excavation to the left of this process forms part of the jugular fossa, and that to the right is the groove for the eighth pair of nerves. 18. The notch for the fifth nerve upon the upper border of the petrous bone, near its apex. 19. The extremity of the petrous bone which gives origin to the levator palati and tensor tympani muscles.—W.]

poral fossa; the superior margin, very thin, gives attachment to the temporal fascia; the inferior one is thicker and shorter, owing to the end of the process being bevelled off so as to rest on the malar bone, with which it articulates. At its base the upper surface is concave and supports the posterior border of the temporal muscle. The under surface forms the border of the glenoid cavity; here it presents two roots, of which one runs horizontally backwards, forming the outer margin of the glenoid cavity, whilst the other turns inwards and forms the anterior border of that cavity. At the point of division is a slight tubercle, which gives attachment to the external lateral ligament of



the lower jaw. Now the anterior root widens and subsides, becoming concave from without inwards, and convex from before backwards, as it forms part of the articular surface upon which the lower jaw-bone moves; in its natural condition it is covered with cartilage. The other root, which is continued horizontally backwards, bifurcates;—one part turns inwards to the fissura Glaseri, whilst the other gradually subsides as it passes backwards over the auditory tube, yet marks the separation between the squamous and mastoid portions of the bone. The *glenoid fossa*, (γληνη, a shallow pit,) marked off as here indicated, is elongated from without inwards, and divided into two parts by a fissure,<sup>13</sup> (*fissura Glaseri*), which transmits the chorda tympani nerve and laxator tympani muscle, and gives attachment to the processus gracilis of the malleus. The part before the fissure is smooth, and articulates with the lower jaw; the remainder lodges a process of the parotid gland.

B. The *mastoid* part<sup>2</sup> of the bone externally is rough, for the attachment of muscles, and prolonged downwards, forming the mastoid, or nipple-shaped process, (μαστος, a nipple or teat,) from which this division of the bone is named. This process overhangs a groove, fig. 55,<sup>7</sup> (*digastric fossa*), for the attachment of the digastricus muscle; close to this is a slight groove,<sup>8</sup> (the occipital groove.) When viewed at its inner surface, the mastoid part presents a broad and generally a deep groove, (sulcus sinus lateralis,<sup>9</sup>) which curves forwards and downwards; it here supports part of the lateral sinus. It is usually pierced by a foramen,<sup>2</sup> (f. mastoideum,) which opens into the sinus from the outer surface, commencing near the posterior border of the bone. The size and position of this hole vary in different instances; it sometimes exists in one temporal bone and not in the other.

c. The *petrous* part,<sup>3</sup> pars petrosa, named from its hardness, (πετρος, a stone,) forms a triangular pyramid, (pyramis trigona,) which projects into the base of the skull forwards and inwards. It contains the organ of hearing, and presents for examination a base, an apex, (truncated,) three surfaces, and three borders. In the base is situated the orifice of the auditory canal, which is bounded above by the posterior root of the zygoma; inferiorly, and in the greatest part of its circumference, by a curved, uneven lamella, (*auditory process*), to which the cartilage of the ear is attached: this process is in the fœtus a separate piece. The canal itself, fig. 54,<sup>9</sup> (*meatus auditorius externus*), narrower in the middle than at its extremities, is directed obliquely forwards and inwards, and leads into the tympanum. The *apex* or inner end of the pars petrosa, rough, irregular, and, as it were, truncated, forms part of the foramen lacerum medium, and is pierced by the termination of the carotid canal, fig. 55,<sup>11</sup> (canalis caroticus:)—this canal commences in the inferior surface of the bone anterior and internal to the jugular fossa, ascends at first perpendicularly, but soon turns horizontally forwards and inwards to the apex, where it ends.

The *anterior* or *upper surface* of the petrous portion forms part of the middle fossa in the base of the skull, where it looks obliquely upwards and forwards. Towards the apex it is slightly depressed, where it corresponds with the ganglion of the fifth pair of nerves



(Gasserian). A narrow groove is seen to run obliquely backwards and outwards to a foramen; it lodges a nerve ("the large superficial petrosal," a branch of the Vidian); the foramen is named the *hiatus Fallopii*, and leads to the aqueduct of Fallopius. More externally is a small aperture, which gives passage to a nerve named "the small superficial petrosal." Farther back is a rounded eminence indicating the situation of the superior semicircular canal. The *aqueduct* of Fallopius just alluded to, commences at the internal auditory meatus; it is a small osseous tube lodged in the interior of the bone, and passing at first in an arched direction, outwards and upwards, then backwards and downwards towards the base of the skull, where it ends in the stylo-mastoid foramen; it transmits the portio dura, and receives, through the hiatus Fallopii, the Vidian nerve.

The *posterior surface* looks obliquely backwards, and forms part of the third or posterior fossa at the base of the skull. In it will be observed a large orifice,<sup>12</sup> leading to a short canal (*meatus auditorius internus*). The canal is oblique in its direction, having an inclination outwards and forwards. It conveys the auditory and facial nerves. Its fundus is formed by a lamella of bone (*lamina cribrosa*), divided into two parts by a crest or ridge; the upper or smaller part is pierced by a foramen which transmits the facial nerve, whilst the lower presents several very small apertures through which the fibrils of the auditory nerve pass. About three lines further back than the orifice of the meatus is a narrow fissure, oblique in its direction. It is the termination of the aquæductus vestibuli. Between the aperture of the aqueduct and that of the meatus is an irregular depression, into which a small process of the dura mater is fixed.

On the *inferior surface* of the pars petrosa, which is exceedingly irregular, we observe, proceeding from within outwards and backwards, a rough surface giving attachment to the levator palati and tensor tympani muscles, the carotid foramen, the jugular fossa, the vaginal and styloid processes; lastly, the stylo-mastoid foramen. The carotid foramen leads into the curved canal (*canalis caroticus*) already noticed. The *jugular fossa*, (*fossa bulbi venæ jugularis internæ*, "the thimble-like cavity,") with a larger depression in the margin of the occipital bone, forms the "foramen lacerum posterius." This large foramen is in some cases divided into two parts, but unequally, by a spiculum of bone;<sup>17</sup> the anterior and inner portion gives passage to the glosso-pharyngeal, vagus, and spinal accessory nerves, whilst the posterior and larger one transmits the jugular vein. In the plate of bone which separates this fossa from the carotid canal is the opening of a small canal, through which the nerve of Jacobson passes to the tympanum. External to the margin of the jugular fossa is the styloid or pencil-like process,<sup>14</sup> long and tapering, with an inclination downwards and forwards. Its length varies from an inch to an inch and a half; it gives attachment to three muscles and two ligaments. Close before the base of the styloid process is a compressed bony plate, (fig. 54,<sup>12</sup>) the *vaginal process* (*vagina processus styloidei*), the free surface of which looks obliquely forwards. Between the root of the styloid process and the mastoid (and named from its position with regard to them) is the *stylo-mastoid foramen*, fig. 55,<sup>15</sup> (f. *stylo-mastoideum*.) It



forms the outlet or termination of the aqueduct of Fallopius, and gives exit to the facial nerve. Near this foramen and at the back part of the jugular fossa is another, by which the auricular branch of the vagus nerve enters the bone.

The *superior border* of the pars petrosa is grooved for the petrosal sinus; the *anterior*, which is very short, forms, with the squamous part, an angle at their point of junction, in which is situated the orifice of the Eustachian tube, a canal which leads from the pharynx to the tympanum: above this, and separated from it by a thin horizontal lamella (*processus cochleariformis*), is another osseous tube, that gives passage to the tensor tympani muscle. The *posterior border* articulates with the basilar process of the occipital bone, and forms with it the foramen lacerum. About the middle of this edge or border is a minute foramen,<sup>13</sup> the opening of a small canal leading from the cochlea (*aquæductus cochleæ*).

*Articulations.*—The temporal bone articulates with the parietal, malar, inferior maxillary, sphenoid, and occipital bones.

*Attachments of muscles.*—To the zygoma is attached the masseter; to the squamous portion, the temporal; to the mastoid process, the retrahens aurem, the sterno-mastoid, splenius capitis, and behind the process the trachelo-mastoideus; to the digastric fossa, the digastricus; to the styloid process, the stylo-glossus, stylo-hyoideus, and stylo-pharyngeus; to the apex of the petrous portion, the levator palati and tensor tympani.

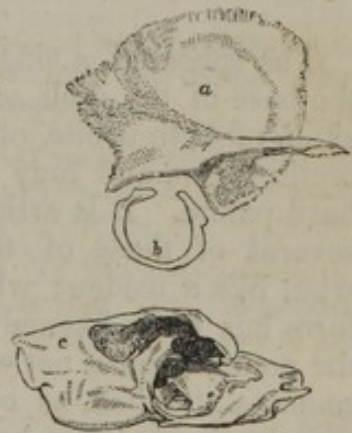The *ossification* of the temporal bone begins at an early period,—about the time that osseous matter begins to form in the vertebræ.

It proceeds from several nuclei. These belong to—1. the zygoma; 2. the squamous part; 3. the tympanic bone; 4. the petrous and mastoid part; 5. the styloid process. The centres of ossification here mentioned are exclusive of those for the internal ear, and the small bones of the tympanum, which will not be referred to in this place.

The formation of bone begins with the *zygoma* and the *squamous* part (fig. 56,<sup>a</sup>); and it is not ascertained with certainty if they are formed from separate nuclei. Béclard speaks of them as seeming to be distinct; but, if they are so, they very speedily coalesce.

The growth of the *tympanic* bone soon succeeds the preceding. This little bone forms about three-fourths of a circle; the deficiency being at the upper part (fig. 56,<sup>b</sup>). The shape is rather elliptical than completely circular. It is grooved along the concave surface for the membrane of the tympanum (annulus membranæ tympani); and it remains distinct from the rest of the temporal bone till about the full period of intra-uterine existence, when it becomes joined by the two extremities beneath the roots of the zygoma.

Fig. 56.



A temporal bone of the right side, consisting of three separate pieces. *a.* The squamous part and zygoma. *b.* The tympanic bone. *c.* The petrous and mastoid part. The letter (*c*) is placed on the mastoid end. The remainder of this piece is, in the natural state, covered by the other divisions of the bone; part of it is the inner wall of the tympanum.



The *petrous* and *mastoid* parts (fig. 56,<sup>e</sup>) are formed from the same centre, and the ossification of the latter is to be regarded as a continuation backwards from that of the former. The mastoid process is also in some instances found to have one or even more independent nuclei.\*

The part of the temporal bone which is latest in its ossification is the *styloid process*, which remains a separate piece for a considerable time ;—in some cases it is never united to the rest of the bone. This process varies very much in the length to which it grows ; in a few instances it has been found to reach even to the os hyoides, instead of being connected to that bone by a ligament of some length.

At birth the temporal bone consists of three pieces, viz. the squamous and zygomatic ; the petrous and mastoid ; and the tympanic. These pieces soon unite, and the place of junction between the petrous and squamous parts is, for some extent, permanently marked by a sort of suture. (Partial union is sometimes found to have taken place at the usual period of birth.) Afterwards the bone undergoes several changes. The most considerable are the following :—The tympanic piece extends outwards, so that it forms a canal, at the bottom of which the membrane of the tympanum is placed, instead of being on a level with the surface of the skull, as it is before that change has taken place in the bone ; the glenoid fossa becomes much deeper ; the surface of the petrous part, previously irregular, is filled up, so to say, and becomes more uniform ; and the mastoid part enlarges, and is rendered prominent by the formation of cells in its interior.

#### THE SPHENOID BONE.

The sphenoid, a single bone, (figs. 57, 58,) placed transversely at the base of the skull, enters into the formation of the cavity of the skull, of both orbits, of the nasal fossæ, of the temporal and the zygomatic fossæ, and may be said to contribute in a small degree to the hard palate. It is articulated with all the bones of the cranium and several of those of the face, between which it is inserted somewhat like a wedge ; whence its name (*σφην*, a wedge ; *εἶδος*, like). The form has been likened to that of a bat with its wings extended, and the comparison is not very far-fetched, particularly if the ethmoid bone remains attached, as often happens. Like other irregular bones, it may be divided into body and processes.

To place this bone in its proper position so as to perceive clearly the relations of its different parts, observe that it has two thick processes somewhat like legs. Hold it so that these shall project downwards, as if from beneath the body and wings, and let those edges of the processes which are channeled into vertical grooves look backwards.

*Of the body*, or central part of the bone.—To give precision to its description we say that it presents six aspects or surfaces, each of which looks in a different direction and has distinct relations. The

\* Kerckringius, "Ostogenia Fœtuum," Tab. 35, 36.



*superior surface*, which forms part of the basis of the skull, is of limited extent, yet is hollowed into a deep pit,<sup>10</sup> which lodges the pituitary gland: hence this excavation is called *pituitary fossa*, and sometimes "*sella Turcica*," from some resemblance to a Turkish saddle

[Fig. 57.]

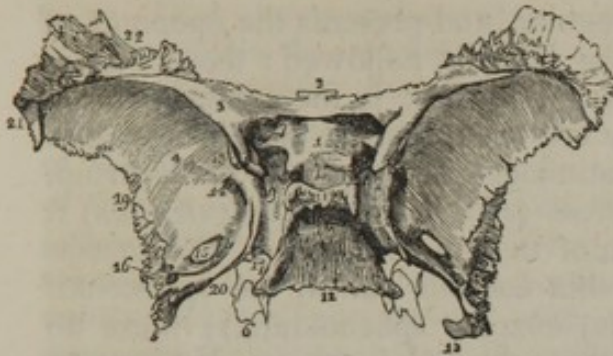


Fig. 58.]

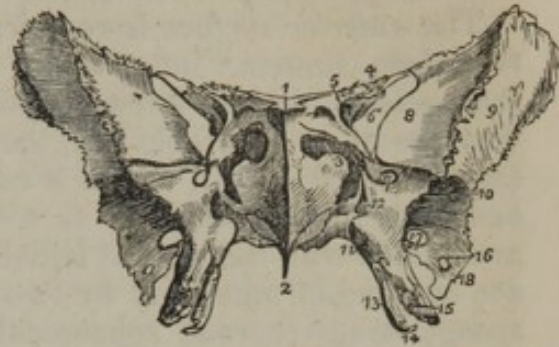

Fig. 57. The superior or cerebral surface of the sphenoid bone. 1. The processus olivaris. 2. The ethmoidal spine. 3. The lesser wing of the left side. 4. The cerebral surface of the greater wing of the same side. 5. The spinous process. 6. The extremity of the pterygoid process of the same side, projecting downwards from the under surface of the body of the bone. 7. The foramen opticum. 8. The anterior clinoid process. 9. The groove by the side of the sella turcica; for lodging the internal carotid artery, cavernous plexus, cavernous sinus, and orbital nerves. 10. The sella turcica; the two tubercles in front of the figure are the middle clinoid processes. 11. The posterior boundary of the sella turcica; its projecting angles are the posterior clinoid processes. 12. The basilar portion of the bone. 13. Part of the sphenoidal fissure. 14. The foramen rotundum. 15. The foramen ovale. 16. The foramen spinosum. 17. The angular interval which receives the apex of the petrous portion of the temporal bone. The posterior extremity of the Vidian canal terminates at this angle. 18. The spine of the spinous process; it affords attachment to the internal lateral ligaments of the lower jaw. 19. The border of the greater wing and spinous process which articulates with the anterior part of the squamous portion of the temporal bone. 20. The internal border of the spinous process, which assists in the formation of the foramen lacerum basis cranii. 21. That portion of the greater ala which articulates with the anterior inferior angle of the parietal bone. 22. The portion of the greater ala which articulates with the orbital process of the frontal bone.

Fig. 58. The antero-inferior view of the sphenoid bone. 1. The ethmoid spine. 2. The rostrum. 3. The sphenoidal spongy bone, partly closing the left opening of the sphenoidal cells. 4. The lesser wing. 5. The foramen opticum, piercing the base of the lesser wing. 6. The sphenoidal fissure. 7. The foramen rotundum. 8. The orbital surface of the greater wing. 9. Its temporal surface. 10. The pterygoid ridge. 11. The pterygo-palatine canal. 12. The foramen of entrance to the Vidian canal. 13. The internal pterygoid plate. 14. The hamular process. 15. The external pterygoid plate. 16. The foramen spinosum. 17. The foramen ovale. 18. The extremity of the spinous process of the sphenoid.—W.]

(ephippium). On each side of the fossa the surface is depressed, and corresponds with the cavernous sinus; farther back are two superficial grooves,<sup>9</sup> directed from behind forwards, which correspond with the internal carotid arteries. Before the fossa, is a slightly depressed portion of the bone (processus olivaris),<sup>1</sup> on a level with the optic foramina, on which rests the commissure of the optic nerves;—behind it, is a prominent ascending lamella, of a square form, and sloping backwards, so as to be continuous with the basilar groove of the occipital bone: the corners of this lamella project over the fossa, and are called the *posterior clinoid processes*,<sup>11</sup> (κλίση, a bed.)

The *inferior surface* of the body is the narrow interval between the pterygoid processes; it is intersected by a prominent spine, (fig. 58,<sup>2</sup>)



called the *rostrum* or azygos process, which dips downwards and forwards to join the vomer. At each side are two small and slightly everted lamellæ (projecting from the base of the pterygoid processes), which articulate with the margins of the vomer. Farther out is a small groove,<sup>11</sup> which contributes with the head of the palate bone to form the *pterygo-palatine canal*.

The *anterior surface* is very irregular, and presents the openings of two deep sinuses,<sup>3</sup> into which the bone is hollowed: these *sinuses* (*sphenoidal*) do not exist in young children; in the adult, in whom they are of considerable size, they are separated by a thin partition (*septum sphenoidale*), which is continuous inferiorly with the rostrum, and in the front projecting as a crest (*crista s. spina sphenoidalis*) it articulates with the central lamella of the ethmoid bone. The sinuses are covered in anteriorly by two thin osseous plates, the *sphenoidal spongy bones* (*cornua sphenoidalia*, *cornets sphenoidaux*); these do not, however, altogether seal up the sphenoidal sinuses, but leave a circular aperture, by which they communicate with the posterior ethmoidal cells. In early life they are distinct, and easily separable; but in the adult they become united either with the margins of the sinuses or with the ethmoid or the palate bone. [Usually before the tenth year these cornets belong to the ethmoid bone, and at this period present the appearance of two hollow cones, the open bases of which are planted upon the posterior part of the ethmoid bone, while, with the apices directed backwards, they are received upon each side of the azygos process of the sphenoid. They afterwards generally become detached from the ethmoid, and by the fifteenth year fuse with the body of the sphenoid, and in this manner become the sphenoidal cells of the adult bone.]

The *posterior surface*, (fig. 57,<sup>12</sup>) is flat, and united with the basilar process of the occipital bone,—in early life by cartilage, but in adult age by osseous matter.

The lateral surfaces are continuous with the great wings, which branch out from them on either side.

*Of the processes.*—The principal processes are the great wings, the small wings, and the pterygoid processes; the minor ones are the ethmoid spine, *processus olivaris*, clinoid processes, the rostrum, the hamular and spinous processes.

The *great wings*, (*alæ majores*), project outwards, forwards and upwards from the sides of the body of the bone, and are so formed as to present each three surfaces, looking in different directions. One, *anterior*, (*orbital*), fig. 58,<sup>8</sup> is square, smooth, inclined obliquely forwards, and forms part of the outer wall of the orbit. The second, fig. 57,<sup>4</sup> (*superior* or *cerebral*), of much greater extent, is elongated from behind forwards, and concave, so as to form part of the middle fossa of the base of the skull, which supports the middle lobe of the brain. The third, fig. 58,<sup>9</sup> (*external* or *temporo-zygomatic*), looking outwards and forming part of the side of the cranium, is elongated from above downwards and slightly hollowed. But it will be observed, that this surface, taken as a whole from the top of the wing down to the root of the pterygoid process, presents two parts divided by a ridge or



crest of varying size. The upper and longer division forms part of the temporal fossa, and the inferior or smaller one enters into the zygomatic fossa.

The *small wings*, fig. 57,<sup>3</sup> (*alæ minores*), called also wings of Ingrassias, are triangular in form, horizontal in direction, and extended forwards and outwards, on a level with the upper surface of the body—its fore part. Their upper surface, plain and flat, supports part of the anterior cerebral lobes, the inferior one overhangs the back part of the orbit and its sphenoidal fissure. The anterior border, sharp, thin, and rough, articulates in the greater part of its extent with the orbital plate of the frontal bone, and internally, at the middle line, where the bases of the two processes are united, there is a slight angular process,<sup>2</sup> (*ethmoidal spine*), which articulates with the cribriform lamella of the ethmoid bone. The posterior border, rounded and smooth, is free and unattached, and corresponds with the fissure (*fissura Sylvii*) which separates the anterior from the middle lobe of the brain. The external and anterior ends of these processes are sharp and pointed, whilst posteriorly they terminate in two blunt tapering productions (the anterior clinoid processes)<sup>8</sup> which incline obliquely backwards, towards the pituitary fossa, and overlay the cavernous sinuses and the carotid artery. They are perforated at the base by a round foramen (*optic*), which transmits the optic nerve and ophthalmic artery.

The *pterygoid processes* are seen at the inferior surface of the bone, from which they project down like legs rather than wings, though the name given to them would indicate the reverse (*πτέρυξ*, a wing). Each of these consists of two narrow plates (*pterygoid lamellæ*), united at an angle in front, and diverging behind, so as to form an angular groove (*pterygoid fossa*). The internal plate, fig. 58,<sup>13</sup> longer and narrower than the external, is prolonged into a slight round process,<sup>14</sup> named, from its crooked form, the hook-like or *hamular process*, round which plays the tendon of the tensor palati muscle. The external lamella<sup>15</sup> looks outwards, and somewhat forwards, bounds the zygomatic fossa, and gives attachment to the external pterygoid muscle. At the root of the internal lamella is situated a slight depression (*fossa navicularis*), which gives attachment to the tensor palati muscle; in the groove or fossa, between the two plates, arises the internal pterygoid muscle. The groove is incomplete at its lower part when the sphenoid bone is examined by itself; for an angular interstice exists between the pterygoid lamellæ. This, however, is filled up by a part of the pyramidal process of the palate bone, which is inserted between the margins of the lamellæ.

The *ethmoid spine*, already noticed, is a very small angular plate<sup>1</sup> which projects forward on a level with the upper surface of the lesser wings in the middle line, and articulates with the cribriform lamella of the ethmoid bone.

The *processus olivaris*, fig. 57,<sup>1</sup> is a minute elevation, seen on that depressed piece of bone on a level with the optic foramina, and which supports the commissure of the optic nerves.

The *clinoid processes* are two pair, one<sup>8</sup> before, the other<sup>11</sup> behind the pituitary fossa; therefore called anterior and posterior. A spiculum of bone often passes from the anterior to the posterior clinoid process



at one or both sides. And occasionally one dips down from this to the body of the bone; it is called the *middle clinoid process*.

The *rostrum*, fig. 58,<sup>2</sup> is the prominent angular ridge, which projects downwards from the under or guttural surface of the bone, dividing it into two parts.

The *hamular process*<sup>14</sup> projects from the termination of the internal pterygoid plate, is thin, constricted, and curved in the greater part of its extent, but ends in a small blunted tubercle.

The *spinous processes*, fig. 57,<sup>5</sup> are placed at the posterior and inner terminations of the great wings, from which they project downwards about two lines.

*Fissures and foramina*.—Each lateral half of the bone presents a fissure, four foramina, and a canal. The fissure, fig. 58,<sup>6</sup> (*fissura sphenoidalis*,) triangular and elongated, is placed between the lesser and greater wings, opens into the orbit, (hence sometimes named foramen lacerum orbitale,) and transmits the third, the fourth, and the sixth nerves, the ophthalmic branch of the fifth and the ophthalmic vein. This fissure is separated at its base from the foramen opticum by a narrow plate of bone which passes from the under surface of the anterior clinoid process (at its root) obliquely down to the body of the sphenoid bone; to this is attached a small tendon, common to the inferior, internal, and external recti muscles of the eye. Of the foramina,—the *optic foramen*, fig. 57,<sup>7</sup> inclines outwards and forwards on a level with the fore part of the body of the bone: it transmits the optic nerve and the ophthalmic artery. Farther back and on a lower plane, inasmuch as it is situated in the great wing, is a round aperture,<sup>14</sup> leading forwards; it is the *foramen rotundum*, which transmits the superior maxillary branch of the fifth pair of nerves. A little farther back and more external is a large foramen<sup>15</sup> of an oval form, hence called *foramen ovale*; it gives passage to the inferior maxillary branch. Near the posterior angle of the ala is the *foramen spinosum*;<sup>16</sup> it is very small, and transmits the middle meningeal artery. The root, or base, of each internal pterygoid process is pierced by a circular foramen, fig. 58,<sup>12</sup> more properly a canal (*pterygoid, Vidian*,) extending horizontally from before backwards, slightly expanded before, narrowed behind, and giving passage to the posterior branch (Vidian) from Meckel's ganglion.

*Articulations*.—The body of the sphenoid bone articulates posteriorly with the basilar process of the occipital; anteriorly with the ethmoid; with the orbital processes of the frontal by the lesser and greater alæ; with the anterior inferior angles of both parietal, and the squamous portion of the two temporal by the great alæ; and by the spinous processes with the angles between the petrous and squamous portions of that bone: with the vomer it articulates by the rostrum; with the malar bones by means of the external border of the orbital plates, and with the palate bones by the pterygoid processes;—in all, twelve bones.

*Attachments of muscles*.—Round the optic foramen in each orbit are attached the four recti, the obliquus superior, and levator palpebræ muscles; to the external surface of the great ala at each side, the temporal muscle; to the external pterygoid process, the external



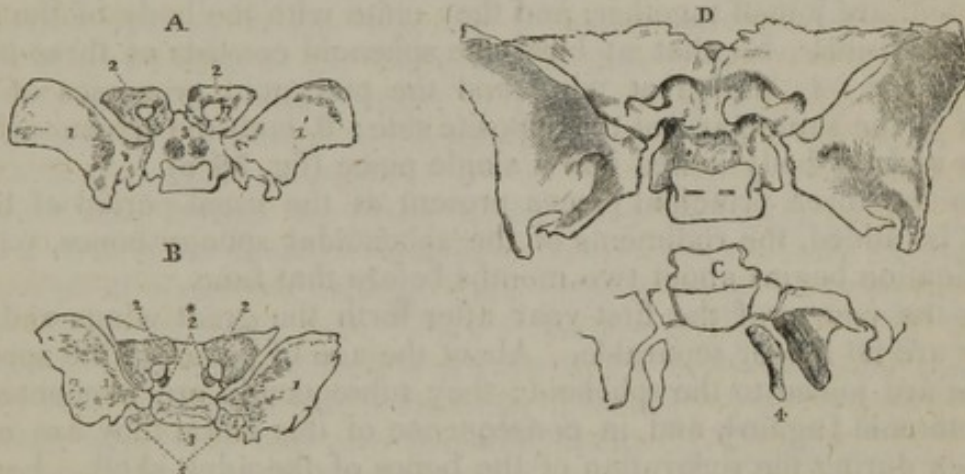pterygoid muscle; to the pterygoid fossa, the internal pterygoid; to the inferior half of the internal pterygoid plate, the superior constrictor of the pharynx; to the fossa navicularis, the circumflexus palati; and to the spinous process, the laxator tympani.

The ossification of the sphenoid bone begins soon after it has commenced in the occipital. As this bone is developed from many centres, and some arrangement is necessary for the sake of clearness, it will be considered as divisible into a posterior and an anterior part, which, with Bécclard, we may name sphenotemporal and sphenoorbital. Each will be noticed separately.

1. The posterior or sphenotemporal division includes the great wings, the pterygoid processes of both sides, and the interposed body. The first nuclei for this part (they are the first that appear in the bone) are deposited one on each side close to the foramen rotundum, and from this point the ossification spreads outwards into the great wing, and downwards into the external pterygoid process (fig. 59, A, B, 1').

The internal pterygoid processes are formed separately, each from a distinct centre (c<sup>4</sup>), and they unite with the external plate soon after the middle of fetal life.

Fig. 59.



A. The sphenoid bone of a fetus, aged about three months, is seen from above. The great wings are ossified; the body has two round granules of bone beneath the sella Turcica, and the rest of it is cartilaginous. In the small wings, which are formed from a single centre, the ossification has encircled the optic foramen, and a small suture is distinguishable at its posterior and inner side. The internal pterygoid processes are still separate (c<sup>4</sup>) in the preparation from which the drawing was made. B. This figure is copied from Meckel ("Archiv." B. 1, Taf. vi. F. 23). It is stated to be from a fetus at the middle of the sixth month. The two granules for the body are united, and a trace of their union is observable in the notch in front. The lateral projections of the body (5) are separate pieces. C. is a sketch of the back part of the preparation drawn in A. The internal pterygoid process, which was united only by cartilage to the rest of the bone, has been drawn aside. D. This figure represents the sphenoid at the usual period of birth. The great wings are separate. The anterior sphenoid is joined to the body.

1. The great wings. 2. The small wings. 2\*. Additional nuclei for the small wing. 3. The body. 4. The internal pterygoid process. 5. The lateral processes of the body.

For the formation of the body two rounded granules are placed side by side in the cartilage beneath the sella Turcica (A<sup>3</sup>). These enlarging, unite about the fourth month into a single piece, which is elongated transversely and notched in the middle (B<sup>3</sup>). This piece sub-



sequently presents on each side a projection, which Meckel describes and figures as an independent formation (B<sup>5</sup>).

The parts here described remain separate one from the other during the whole of foetal life, with the exception of the internal pterygoid processes, the time of whose junction has been mentioned.

2. The growth of the anterior or speno-orbital part commences at an early period, soon after ossification has first showed itself in the bone.

Its first nucleus appears at the outer margin of the optic foramen, and from this point the deposit of bone extends outwards in the small wing and around the foramen (A<sup>2</sup>). There is frequently another granule placed on the inner side of the foramen (B<sup>2\*</sup>).

The middle of this division of the bone either results from the union of the lateral pieces just referred to, or is the product of an independent growth.

The sphenoidal crest is perhaps generally produced by extension of the ossification of the middle of the speno-orbital part, and therefore—according to the manner in which the middle is formed—proceeds either from the lateral pieces or from the central one. It is, however, not unfrequently altogether independent in its formation.

Some time before the end of foetal life, the parts of the anterior sphenoid are joined together, and they unite with the body of the posterior division. So that at birth the sphenoid consists of three large pieces, viz.: 1. the great wing and the pterygoid processes of one side; 2. the same parts of the opposite side; 3. both the speno-orbital parts and the body united into a single piece (fig. 59 D).

To the three principal pieces present at the usual period of birth must be added, the rudiments of the sphenoidal spongy bones, whose ossification begins about two months before that time.

In the course of the first year after birth the great wings and the body are no longer separable. About the age of puberty\* the spongy bones are joined to the sphenoid; they subsequently are connected to the ethmoid [again], and in consequence of this union they are often broken during the separation of the bones of the adult skull. Lastly, the sphenoid unites with the occipital bone.

#### ETHMOID BONE.

The *ethmoid*, or sieve-shaped bone, fig. 60, (*ἠθμός*, a sieve; *εἶδος*, form; *os ethmoides*.) is common to the cranium, the orbits, and the nasal fossæ; it is placed at the fore part of the base of the skull, from which it projects downwards, and is inserted between the orbital plates of the frontal bone, lying behind the nasal and superior maxillary bones, before the sphenoid and above the vomer. It is exceedingly light and thin, considering its size, and seems at first, but a collection of irregular cells, enclosed between plates of bone as thin as paper. It is of a cuboid figure, symmetrical, and composed of two lateral masses, between which is interposed a central vertical plate. This points out a mode of dividing the bone for the purpose of description, but it is more convenient to consider it as a whole, and examine separately each of its six surfaces.

\* [Before this period they are joined to the ethmoid.]

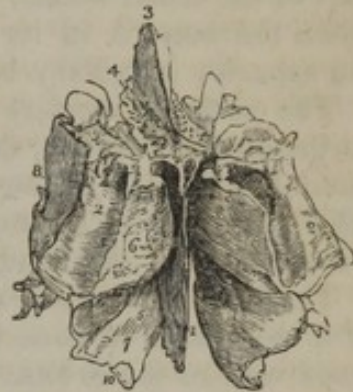


To place the bone in its proper position, observe that its upper surface is the one from which arises a smooth angular process like a cock's comb. The short border of this looks forward, and the long sloping one backwards.

The *superior* or *cerebral* surface of the bone is at once recognised by its presenting a triangular process, which projects upwards from it, in the middle line; this process,<sup>2</sup> from some resemblance to a cock's comb, is called *crista galli*. The surface of the crista is smooth and compact, its form triangular, the base being horizontal, and on a level with the cribriform plate, below which it is continuous with the perpendicular lamella forming the septum narium; the posterior border of this process is long, and slopes backwards, but the anterior is short, and nearly perpendicular; at its junction with the base two small bony masses sometimes project forwards, leaving between them a fissure which forms part of the "foramen cæcum," placed in the middle line at the junction of this bone with the frontal. The crista galli is usually perpendicular, but occasionally inclines to one side; it is sometimes bulged a little at the sides, and is then found to enclose a small sinus; it gives attachment to the falx cerebri, the two layers of which in a manner embrace it.

Beside and behind the crista is the sieve-like or *cribriform lamella*<sup>4</sup> (*lamella cribrosa*). It consists of a narrow plate of bone, pierced by a number of holes, from which it derives its name; posteriorly this plate of bone is, for a very little way, even and horizontal; it then becomes depressed into two grooves beside the crista, which lodge the ganglia of the olfactory nerves. This part of the surface is narrow, elongated from behind forwards, and pierced by numerous foramina, for the transmission of the filaments of the olfactory nerves. The *foramina* in it are of three sorts: those which lie along the middle of the groove are mere holes or perforations which permit the filaments of the nerves, with their membranous investments, to pass down to the roof of the nares; the external and internal rows are larger, and form the orifices of small canals, which are grooved in the bone, and subdivide as they descend into the septum and spongy bones. In the anterior border of the cribriform lamella, and close to the crista galli, is a fissure at each side of its base, which transmits the nasal filament of the ophthalmic nerve; [it is the most anterior and external fissure or foramen, and has a groove leading to it from the anterior ethmoidal foramen.] Along the outer margin of the cribriform plate

[Fig. 60.]



The ethmoid bone seen from above and behind. 1. The central lamella. 2, 2. The lateral masses; the numbers are placed on the posterior border of the lateral mass at each side. 3. The crista galli. 4. The cribriform plate of the left side, pierced by its foramina. 5. The hollow space immediately above and to the left of this number is the superior meatus. 6. The superior turbinated bone. 7. The middle turbinated bone; the numbers 5, 6, 7, are situated upon the internal surface of the left lateral mass, near its posterior part. The interval between these parts is the superior meatus. 8. The external surface of the lateral mass, or *os planum*. 9. The superior or frontal border of the lateral mass, grooved by the anterior and posterior ethmoidal canals. 10. Refers to the concavity of the middle turbinated bone, which is the upper boundary of the middle meatus.—W.]



we observe several small cellules, which are open, and, as it were, incomplete when the bone is detached from its natural situation, but are closed in by the orbital plates of the frontal bone, and completed by a junction with the cells observed in their border. At the posterior margin of this surface, and in the middle line, is a slight notch, which receives the ethmoid spine of the sphenoid bone.

The *anterior surface* of the bone presents in the middle the edge of the perpendicular or nasal lamella;<sup>1</sup> at the sides of this are narrow grooves which separate it from the lateral masses, and form the upper part of the nasal fossæ; still farther out are some open cellules, which when the bone is in its place are closed by the ascending process of the superior maxillary bone.

The *posterior surface* presents also in the middle the edge of the perpendicular lamella, then the grooved posterior margins of the ethmoidal turbinate bones, and still more externally large open cellules which are closed by the sphenoid bone and its turbinate bones, and lower down by the head of the palate bones.

The *lateral or orbital surfaces* are smooth and plain;<sup>2</sup> each is formed of a thin plate of bone (lamella plana; os planum,) which lies in the inner wall of the orbits.

The *inferior or nasal surface* of the bone is of considerable extent, and presents in the middle line a flat plate of bone, and two lateral masses separated from it by a narrow interval; these lateral parts are formed of thin plates, enclosing cellules, which appear so complex as to be likened by some persons to a labyrinth.

Thus far we can proceed with our description of the bone as if it were a single piece, which presented several aspects, each requiring to be noticed; but when we look at it from below, we find it expedient to consider it as divisible into a central or median plate, and two lateral parts or masses.

The descending or *nasal plate*<sup>1</sup> (lamella nasalis), called also the perpendicular or central plate, though it frequently inclines to one side, forms a considerable part of the septum nasi (fig. 78,<sup>2</sup>); it is continuous above with the base of the crista galli, as already stated; below, it articulates with the vomer and the triangular cartilage of the nose; its anterior margin joins by its upper part with the nasal process of the frontal bone, and lower down supports the ossa nasi; the posterior margin articulates with the septum sphenoidale. This plate presents a number of grooves and minute canals, leading from the foramina of the cribriform lamella, for the transmission of the olfactory nerves: in the natural condition it is covered by the pituitary membrane.

*Lateral masses.*—The external surface of each of these consists of a thin, smooth, and nearly vertical plate of bone, fig. 60,<sup>3</sup> (lamella plana, os planum,) which closes in the ethmoidal cells and forms a considerable part of the inner wall of the orbit: it articulates above with the orbital plate of the frontal bone; below, with the superior maxilla and palate bone; in front, with the os unguis; and behind, with the sphenoid. At its anterior and posterior margins the ethmoidal cells are open when the bone is detached from its connexions; in the former situation they are closed by the os unguis; in the latter, by the



sphenoid spongy bones. In its upper margin are two grooves, which are formed into foramina by similar indentations in the frontal bones, and so form the internal orbital foramina (*foramen orbitarium internum, anterius et posterius*).

The inner surface of each lateral mass forms part of the external wall of the corresponding nasal fossa, and consists of a thin osseous plate, connected above with the cribriform lamella, from which it hangs down, and below ends in a free margin, which is convoluted a little, and represents the middle spongy bone. At its upper and fore part is a square, flat, but rough surface, which is pierced by a number of grooves, leading from the foramina of the cribriform lamella; posteriorly are placed two thin and also rough osseous plates, curved a little, so as to represent small bivalve shells, from which circumstance they are called *ethmoidal turbinate* bones; but from their texture, being cellular and porous on the surface, they are named *spongy* bones. Of these, the first or upper one (fig. 77'), (concha superior,) which is also placed farther back, is very small; by the curve or coil which it makes, it arches over, and forms a groove or channel (*meatus naris superior*); this is of small extent from before backwards, not being more than half that of the ethmoid bone; it communicates with the posterior ethmoidal cells, and the sphenoidal sinuses. Still lower down is another osseous lamella (fig. 77'), thin, rough, and convoluted, which is the second ethmoidal spongy, or turbinate bone. Its lower margin is more rough and prominent than that of the upper one, and its extent from before backwards nearly double. Beneath this is a groove or channel which it overhangs so as to form the second *meatus naris*, which communicates with the anterior ethmoidal cells, the frontal sinuses, and the antrum of Highmore.

The surface of these spongy bones is studded over with holes, which are the orifices of canals lodged in the substance of this slender structure. These (the canals) lead from the foramina in the cribriform plate, and they vary in length, some reaching only a very short way, while others extend to the lower margin of the bone. Their direction is nearly vertical, with, in most instances, a slight inclination backwards, and they conduct the branches of the olfactory nerve to the lining membrane of the nasal fossa at different points.

There are also generally, if not always, to be found on the second spongy bone—on the posterior margin, and for a short space in front of it—one or two slight horizontal grooves marking the course of small nervous filaments, which enter through the sphenopalatine foramen.

The osseous plate here described gives attachment by its outer surface to a number of osseous lamellæ, thin and delicate, which pass across the space between it and the lamella plana, dividing it into a number of *cells* (*ethmoidal*). These do not all communicate; they are separated into two sets by a sort of transverse partition, the posterior being small and few in number—from four to five,—whilst the anterior, larger and more numerous, communicate with the frontal sinus. The cellule, which directly communicates with the middle meatus, is prolonged, in a curved direction, upwards and forwards, opening by



a small aperture into the anterior ethmoidal cells, and by another, farther on, into the frontal sinus; and, as it is broad below, and tapering above, it assumes somewhat the form of a funnel, and hence is named *infundibulum*.

The superior border of each lateral mass presents some incomplete cells, before noticed when describing the cribriform plate; the inferior gives off some irregular lamellæ, which articulate with the side of the maxillary sinus and the inferior turbinate bone; the anterior also exhibits some incomplete cells, which are closed in by the os unguis and the nasal process of the superior maxillary bone.

*Articulations.*—The ethmoid articulates with thirteen bones—the frontal, the sphenoid and vomer, two nasal, two ossa unguis, two superior maxillary, two palatal, and two inferior spongy bones.

*Ossification.*—In the ethmoid bone this process begins about the middle of foetal life—from the fourth to the fifth month—a later period than belongs to its commencement in any other bone of the cranium. Bone is first visible in the outer sides—the ossa plana,—and soon after becomes apparent in the spongy bones, but the middle plate remains cartilaginous till after birth.

At the usual period of birth the ethmoid consists of two parts—the lateral masses,—and these are small and narrow. Subsequently, (in the course of the first year,) the middle plate and the lamina cribrosa begin to ossify, and the bone becomes a single piece by the union of the latter to the lateral masses.

The peculiar character of the ethmoid is afterwards gradually developed by the unfolding, as it were, of its substance, and the increase in the size of its cells.

#### OSSA TRIQUETRA.

Accidental, or supernumerary bones, are not unfrequently found in skulls. From their form, which is very variable, they are sometimes called triquetra, at others, triangularia, or ossa Wormii, from Wormius, a learned Danish professor, who is said to have given the first detailed description of them. They are osseous plates, with serrated margins, inserted, as it were, between two cranial bones (ossa intercalaria, epactalia), and appearing like islets placed in the sutures. Their most ordinary position is in the lambdoid suture, next in the sagittal, seldom if ever in the coronal, [there is a cranium in the Wistar Museum in which a triquetral bone exists in the coronal suture,] never in the squamous. The superior angle of the occipital bone sometimes occurs as an accessory piece; so does the anterior inferior angle of the parietal. They are not found before the sixth or eighth month after birth: and whatever varieties of size and appearance they may present, the principle of their formation is the same in all cases. As the broad bones grow by successive deposits, extending from their central points towards the margins, whenever the natural process is retarded or interrupted, the mode of osseous deposition takes a new direction, a new centre is established in the layer of cartilage between the margins of the bones, and therefore in the situation of the suture, from which it extends outwards, until it comes into contact with the margins of the contiguous bones, with which it becomes united in the usual way by suture.



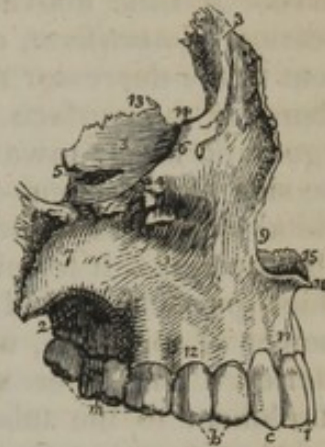## BONES OF THE FACE.

These, as before stated, page 115, are fourteen in number.

## THE SUPERIOR MAXILLARY BONE.

This bone, fig. 61, (maxilla superior,) is very irregular. It presents an external convex surface, corresponding with the anterior and lateral parts of the face; another, internal, of considerable extent, corresponding with the nasal cavity; one, superior, smooth, and inclined inwards, forming the floor of the orbit, and surmounted internally by a triangular process, forming the side of the nose; lastly, a surface which projects horizontally inwards, to form the arch of the palate. The external surface is bounded inferiorly by a thick, dependent border (alveolar), for the lodgment of the teeth; to this as to a common point of union, all the other parts of the bone may be referred.

[Fig. 61.]



The *alveolar border*,<sup>12</sup> thick, semicircular, convex externally, concave internally, is pierced along its margin by a number of deep pits (*alveoli*), into which the teeth are inserted. The pits or sockets vary in form and depth, conforming in these particulars to the roots of the teeth which they receive. From this border the external side ascends to the margin of the orbit, presenting some depressions and elevations; but at its fore part it is interrupted and excavated so as to present a deeply concave margin,<sup>9</sup> which, with a similar one in the corresponding bone, forms the anterior nares. This excavation is surmounted by a process,<sup>8</sup> (*ascending* or *nasal*), prolonged as far as the frontal bone, with which it articulates.

The external surface of the nasal process, slightly grooved, gives attachment to the orbicularis palpebrarum muscle and the levator labii superioris alæque nasi. The internal, or nasal surface, somewhat concave, presents a rough line, running from before backwards, which articulates with the inferior spongy bone; above this is a depression corresponding with the middle meatus of the nose, and, towards the summit, a rough surface, which closes in the anterior ethmoidal cells. The anterior border is rough, for its attachment to the nasal bone; the posterior presents a well-marked groove,<sup>14</sup> running from above downwards, and a little back-

The superior maxillary bone of the right side, as seen from the lateral aspect. 1. The external or facial surface; the depression in which the figure is placed is the canine fossa. 2. The posterior, or zygomatic surface. 3. The superior or orbital surface. 4. The infra-orbital foramen; it is situated immediately below the number. 5. The infra-orbital canal, leading to the infra-orbital foramen. 6. The inferior border of the orbit. 7. The malar process. 8. The nasal process. 9. The concavity forming the lateral boundary of the anterior nares. 10. The nasal spine. 11. The incisive, or myrtiform fossa. 12. The alveolar process. 13. The internal border of the orbital surface, which articulates with the ethmoid and palate bone. 14. The concavity which articulates with the lacrimal bone, and forms the commencement of the nasal duct. 15. The crista nasalis of the palate process. i. The two incisor teeth. c. The canine. b. The two bicuspidati. m. The three molares.—W.]



wards with a slight curve, and which is completed into a canal by a similar one in the os unguis, for the lachrymal sac.

The part of the external surface a little above the molar teeth, is elevated into a rough projection,<sup>7</sup> (*malar process, eminence, tuberosity*), for its articulation with the malar bone. Anterior and inferior to this is observed a fossa, (*fossa canina*), which gives attachment to the levator anguli oris. Between this fossa and the margin of the orbit is the *infra-orbital foramen*,<sup>8</sup> which transmits the superior maxillary nerve. A little above the sockets of the incisor teeth is a slight depression,<sup>11</sup> (*myrtiform, or superior incisor fossa*), which gives attachment to the depressor muscle of the ala of the nose. Behind the malar tuberosity the surface is slightly excavated, and forms part of the zygomatic fossa; towards the posterior border it is plain, and forms one side of the sphenomaxillary fissure; and, at its junction with the orbital plate, it is rounded off and leads to the entrance of the infra-orbital canal. It terminates by a slight *tuberosity*, (*tuber maxillare*,<sup>9</sup>) which projects behind the last molar tooth, and is perforated by a number of foramina, which transmit the superior dental nerves and arteries. The inner surface of its posterior border is rough, for its attachment to the tuberosity of the palate bone, and presents also a slight groove, contributing to the formation of the *posterior palatine canal*, which transmits the descending palatine branches from Meckel's ganglion.

From the upper border of the external surface, the *orbital plate*<sup>3</sup> projects inwards, forming the floor of the orbit; its surface is smooth, being merely interrupted by the groove which leads to the infra-orbital canal; and at its inner and fore part, near the lachrymal groove, is a minute depression, which gives origin to the inferior oblique muscle of the eye. The *infra-orbital canal* commences behind on the surface of the orbital plate as a groove; becoming deeper in front and being changed into a complete canal, it opens on the anterior surface of the bone at the infra-orbital foramen, some distance below the margin of the orbit. It gives passage to a large nerve and an artery. In the interior of the bone a small canal leads downwards from the larger one, and conducts a nerve (anterior dental) to the front teeth.

The horizontal or *palate plate* of the bone projects inwards, forming the roof of the mouth and the floor of the nares. Its nasal surface is concave from side to side, and smooth; externally it is continuous with the body of the bone; internally it presents a rough surface, which is articulated with the corresponding bone, and surmounted by a ridge,<sup>15</sup> which completes the septum narium by articulating with the vomer and nasal cartilage; in front it is prolonged a little, so as to form a small process,<sup>10</sup> (*anterior nasal spine*); beside it is the *incisor foramen*, leading into the *anterior palatine canal*. The inferior surface of the palate plate which overhangs the mouth is arched and rough, and among the prominences of the surface it is slightly grooved for a large nerve which reaches the palate through the posterior palatine canal.

On examining with attention the large canal or fossa, named the



anterior palatine, fig. 62, (in the skull,) it will be found that it contains four openings—two placed laterally,<sup>1 2</sup> and two in the middle, one<sup>3</sup> before the other.<sup>3</sup> The two former are described as the foramina of Steno\* (of Stenon's more properly) in many of the older anatomical works.

They are mentioned above as the "incisor" foramina. The others, which were first brought under notice by Scarpa, are placed in the intermaxillary suture, so that both maxillary bones contribute to form each of them. They are smaller than the preceding pair, from which they are separated by a very thin partition, and the lower orifice of the posterior one is larger than that of the anterior. It is through these median smaller canals (of Scarpa) that the naso-palatine nerves pass,—the nerve of the right side occupying the posterior one, and the nerve of the left side, the anterior.†

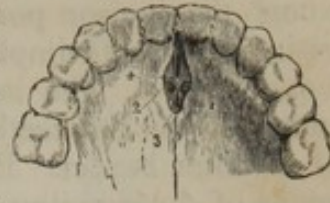

Fig. 62.

The body of the bone is hollowed into a large cavity, *antrum Highmori*, or *maxillare*, which in the fresh state is lined by mucous membrane and communicates with the middle meatus of the nose. Its orifice appears of great size in the dried bone when detached from its connexions, but it is considerably diminished when the contiguous bones are in their natural position, viz., the ethmoid, the inferior turbinate, and the palatal.

*Articulations.*—With the corresponding bone; with the frontal, by its nasal process; also with the ethmoid and os nasi; with the palate bone; with the malar, by the malar eminence; with the os unguis, the vomer, the inferior spongy bone, and the nasal cartilage.

*Attachments of muscles.*—Proceeding from below upwards;—above the border of the alveolar arch, the buccinator, and the depressor labii superioris *alæque nasi*; to the canine fossa, the levator anguli oris and the compressor nasi; to the margin of the orbit, part of the levator labii superioris; to the nasal process, the orbicularis palpebrarum, and the common elevator of the lip and ala of the nose; and just within the orbit, the inferior oblique muscle of the eye.

The *ossification* of the upper maxillary bone begins at a very early period,—immediately after the lower maxilla and the clavicle, and before the vertebræ. The facts hitherto ascertained with respect to its earliest condition are not adequate to determine the number of nuclei from which this bone is formed, or the manner of its growth. If it is produced from several centres—and to this the balance of evidence inclines—the very early period at which the osseous deposit begins, and the rapidity of its progress over the bone, will account for the difficulty of marking the phases of change.

Béclard, whose opportunities of observing the growth of this and

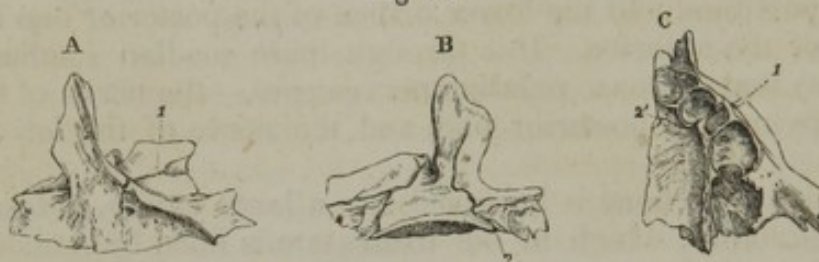\* The name is usually thus written in English books; but it should be mentioned, that the real name was "Stenson," and of this the ordinary Latin version was "Stenon's."—See, among others, Haller, "Elem. Physiol." t. i. p. 353.—Blumenbach, "Introduct. in Histor. Medicinæ Litt." p. 253.

† The median canals have not unfrequently a different disposition. Thus, *a.* They may join one with the other, and open inferiorly by a single common orifice. *b.* Either may be wanting. *c.* One may be found to open into a lateral (incisor) canal. See Scarpa, "Annotat. Anatom." lib. ii. cap. 5.



most other bones were considerable, states that he had found it to consist of four pieces, viz. 1. A palatal part, including all the palate except the incisor portion. 2. An orbital and malar division, comprising the parts implied by these names. 3. The nasal and facial connected. 4. The incisor piece,—being a small part of the palate behind the incisor teeth, and including in front the posterior margin of the alveolar border. But this anatomist adds, that he had not had the means of determining where the several pieces unite one to the other, and he admits that further observations of the bone at very early periods are necessary to determine the manner of its ossification.

Fig. 63.



The superior maxillary bone at early periods:—On the outer side, A, a fissure extends through the orbit and ends at the infra-orbital foramen. B. is a view of the inner side of the bone. The incisor fissure reaches upwards through the horizontal plate and some way on the nasal process. C. The alveolar border and palate plate are displayed from below, and the incisor fissure is seen to cross those parts. At the outer side a small portion of the orbital fissure was noticeable in this view of the bone, and it has been represented. 1. The orbital fissure. 2. The incisor groove or fissure.

Taking this bone when a single piece, it presents two fissures, one along the floor of the orbit (fig. 63, A<sup>1</sup>); the other (the incisor groove) marking off a small portion of the palate behind the incisor teeth (B, C<sup>2</sup>). Now, the question arises, are these the limits of ossification proceeding from different centres? There does not appear to be evidence that the first is so, for its presence may be owing solely to the construction of the canal over which it is placed. But with regard to the second, there are circumstances which would incline us to expect that the portion of bone it circumscribes should prove to be a distinct growth. The circumstances alluded to are the following: 1. The existence, in some cases of hare-lip, of a detached piece corresponding in its extent on the palate to the line of this fissure, and including the entire thickness of the alveolus with the incisor teeth. 2. The strictly defined extent of this piece: it never reaches beyond the line of the fissure—never includes a canine tooth. 3. No similar portion is ever found detached from another part of the upper or from the lower maxillary bone. 4. Lastly, may be added the existence of an inter-maxillary bone in animals with which an incisor piece in man would be analogous.

The foregoing facts render it probable that the incisor part is formed separately from the rest of the bone. Still, seeing that, except in cases of malformation, a distinct piece has not hitherto been clearly observed by any anatomist, and that the trace of separation which exists on the palate has never been found to extend to the anterior surface of the alveolus, it cannot be concluded that the part of the bone defined below by the incisor groove is ordinarily formed from a distinct centre of ossification. In the present state of knowledge, there-



fore, the existence of an incisor bone in the human body at any period cannot be admitted.

[Fig. 64.]

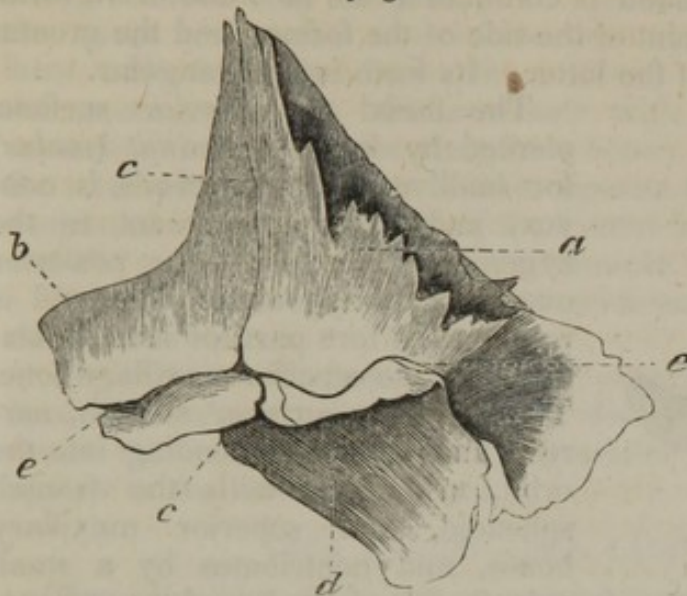


Fig. 65.

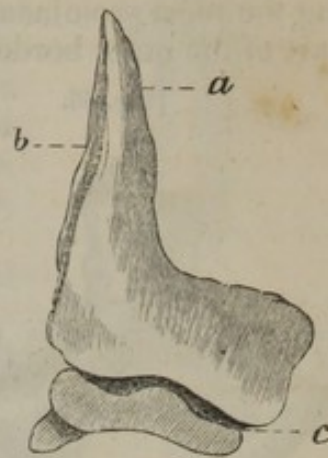


Fig. 64 represents the superior maxillary and intermaxillary bones, much magnified, of a human embryo. The drawing was taken from the right side by means of the camera lucida, which reverses its position. *a*. Superior maxillary bone. *b*. Intermaxillary bone. *c*. Line of articulation between the two bones. *d*. Palatine process. *e*. Alveolar groove.

Fig. 65 represents the antero-inferior surface of the separate intermaxillary bone, much magnified. From the left side, but reversed by the camera. *a*. Ascending or nasal process. *b*. Articulating surface for the superior maxillary bone. *c*. Incisor alveoli. From nature, by J. L.]

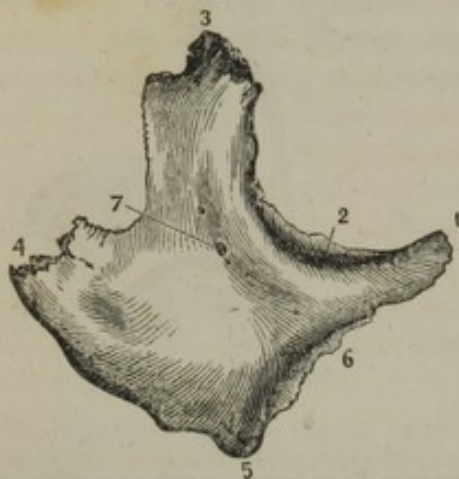[The intermaxillary bone as a distinct piece in man, I have detected existing in the embryo of about the ninth or tenth week (a good deal of uncertainty existing relative to the age of embryos, I will further add that it measures 1 inch 11 lines from heel to vertex, the lower extremities being stretched out). At this period ossification has already advanced in the superior maxillary and intermaxillary bones sufficiently to give them a determinate form, and have the appearance, when magnified, as represented in figures 64 and 65, which were taken from the specimens by means of the camera lucida. The greatest breadth of the two bones in apposition is one line and two-thirds, the greatest height, being at the ascending or nasal process, is one line. They present a facial portion, consisting of the ascending or nasal process, and part of the body of the bones; an alveolar ridge and groove, and a palatine process projecting backward from the superior maxillary bone. The two are easily separable at this period, and the articulation passes through the alveolar ridge, at a point corresponding to the separation between the incisor alveoli and the canine alveolus, and extends transversely inwards behind the incisor alveoli, and vertically upwards, dividing the nasal process into two nearly equal portions. On the posterior surface of the nasal process, the articulation is at the bottom of a comparatively deep and wide groove. The preparations exhibiting these points, which have been the subject of so much discussion, I have carefully preserved, and upon exhibiting them to the Academy of Natural Sciences, the members were fully convinced that the facts are such as I have just stated.—J. L.]



## THE MALAR BONES.

There are two bones named malar, fig. 66, (*os malæ*, *malare*, *jugale*, *zygomaticum*.) Each is common to the face and orbit, forming the most prominent point of the side of the former, and the greater part of the outer border of the latter. Its form is quadrangular.

[Fig. 66.]



Anterior view of the right malar bone. 1, 3, 4, 5. The four angles. 2. Superior or orbital surface. 6. Articulating surface for the maxilla. 7. Malar foramen.—Smith and Horner.]

The facial or anterior surface, pierced by some *foramina*<sup>7</sup> (*malar*) for small nerves and vessels, is convex, and gives attachment to the zygomatic muscles;—the posterior overlays the zygomatic fossa, and is rough at its fore part for its articulation with the superior maxillary bone. The superior surface,<sup>2</sup> smooth, narrow, and lunated, extending into the orbit, articulates with the frontal, sphenoid, and superior maxillary bones, and contributes by a small smooth margin to bound the sphenomaxillary fissure. It is pierced by two or three foramina, and gives passage to a small nerve, which passes backwards through it.

The superior border forms the outer margin of the orbit; the inferior is on a line with the zygomatic arch, which it contributes to form, supporting the zygomatic process of the temporal bone; the anterior articulates with the maxillary bone; the posterior, curved, gives attachment to the temporal aponeurosis.

The angles, <sup>1</sup>, <sup>3</sup>, <sup>4</sup>, <sup>5</sup>, of the bone are readily distinguished one from the other. They are four in number. The anterior is slender and pointed, and rests on the superior maxillary bone. The posterior is thin, and supports the zygomatic process of the temporal; the suture between the two bones is often vertical at the lower end. The superior angle, which is very thick, supports the external angular process of the frontal bone; and the lower one is less prominent than the others.

*Articulations.*—It articulates with the frontal, superior maxillary, temporal, and sphenoid bones.

*Attachments of muscles.*—The *zygomatici*, to its anterior surface; the *masseter* to its inferior border; to its anterior angle, part of the *levator labii superioris*.

*The ossification.*—It extends from a single ossific point, which appears about the time that the ossification of the *vertebræ* commences.

## THE NASAL BONES.

The nasal bones, (fig. 67,) (*ossa nasi*), situated beneath the frontal bone, and between the ascending processes of the superior maxillary, are small and irregularly quadrilateral, and form what is called the “bridge” of the nose. They are thick and narrow in their upper part, but gradually become wider and thinner lower down. The anterior

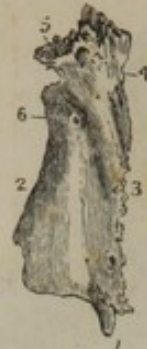

surface of each, concave from above downwards, convex from side to side, presents a minute vascular foramen;<sup>6</sup> the posterior, or nasal, is marked by the passage of a branch of the nasal nerve; the superior border<sup>5</sup> articulates with the frontal bone; the inferior<sup>1</sup> with the nasal cartilage; the external<sup>3</sup> with the ascending process of the maxillary bone; and the internal<sup>2</sup> with its fellow of the opposite side, supported by the nasal spine of the frontal bone, and the perpendicular plate of the ethmoid.

They give attachment to the pyramidales and compressores nasi.

*Ossification.*—They are developed each from a single osseous centre, which is discernible about the same time with those which first appear in the vertebral column.

[Fig. 67.]

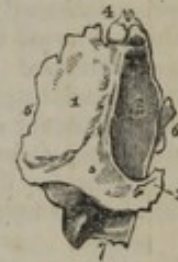

Anterior surface of the right os nasi. 1. Inferior extremity. 2, 3, 4, 5. Articulating surfaces. 6. Nasal foramen.—Smith and Horner.]

#### OSSA UNGUIS—OSSA LACHRYMALIA.

These small bones (fig. 68) are named “ungual” from a resemblance, if not in form, at least in thinness and size, to a finger-nail (unguis); they are also called the “lachrymal” bones, from their presenting each a groove,<sup>2</sup> which, with a similar excavation in the nasal process of the superior maxilla, forms the lachrymal canal. Placed at the inner and anterior part of the orbit, the os unguis presents two surfaces and four borders; its external or orbital surface,<sup>1</sup> plain in the greater part of its extent, is hollowed anteriorly by a groove which runs from above downwards, and contributes, as above stated, to lodge the lachrymal sac. Part of the internal surface, which is rough, corresponds with the anterior ethmoidal cells, the rest with the middle meatus narium. The superior border<sup>4</sup> is articulated with the orbital process of the frontal bone; the inferior with the superior maxillary bone; and where it dips down,<sup>7</sup> to form a part of the lachrymal canal, it joins the inferior spongy bone; anteriorly,<sup>6</sup> it rests on the nasal process of the superior maxillary bone, and posteriorly<sup>5</sup> on the os planum of the ethmoid.

[Fig. 68.]



The lachrymal bone of the right side, viewed upon its external or orbital surface. 1. The orbital portion of the bone. 2. The lachrymal portion. 3. The lower termination of the ridge between the lachrymal and orbital portions. 4. The superior border which articulates with the frontal bone. 5. The posterior border, which articulates with the ethmoid bone. 6. The anterior border, which articulates with the superior maxillary bone. 7. The border which articulates with the inferior turbinated bone.—W.]

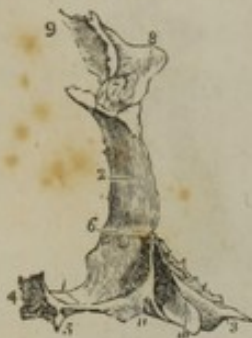*Ossification.*—Each os unguis is developed from one osseous centre, which is apparent shortly after the ossification of the vertebræ is begun.

#### THE PALATE BONES.

Each palate bone, figs. 69 and 70, (os palati,) wedged in between the superior maxillary and sphenoid bones, is common to the cavity of the mouth, nares, and orbit. In its form, this bone somewhat resembles that of the letter L, one part being horizontal, the other vertical.



[Fig. 69.]



A posterior view of the right palate bone in its natural position; it is slightly turned on one side, to obtain a sight of the internal surface of the perpendicular plate (2). 1. The horizontal plate of the bone; its upper or nasal surface. 2. The perpendicular plate; its internal or nasal surface. 3, 10, 11. The pterygoid process or tuberosity. 4. The thick internal border of the horizontal plate, which, articulating with the similar border of the opposite bone, forms the crista nasalis for the reception of the vomer. 5. The pointed process, which, with a similar process of the opposite bone, forms the palate spine. 6. The horizontal ridge which gives attachment to the inferior turbinated bone; the concavity below this ridge enters into the formation of the inferior meatus, and the concavity (2) above the ridge into that of the middle meatus. 7. The sphenopalatine notch. 8. The orbital portion. 9. Articulating surface for ethmoid. 10. The middle facet of the tuberosity, which enters into the formation of the pterygoid fossa. The facets 11 and 3 articulate with the two pterygoid plates, 11 with the internal, and 3 with the external — W.]

lary bone; and the antrum.

The horizontal or *palate plate*<sup>1</sup> of the bone, which is nearly square, and forms the back part of the roof of the mouth and of the floor of the nares, articulates anteriorly with the palate plate of the maxillary bone; internally it presents a rough thick border which rises up into a ridge,<sup>4</sup> which joins with its fellow of the opposite side, and with it forms a groove which receives the lower border of the vomer; externally it unites at right angles with the vertical portion of the bone; posteriorly it presents a thin free border, forming the limit of the hard palate, and giving attachment to the velum or soft palate which projects downwards from it; it is slightly concave, and has at the inner angle a pointed process,<sup>5</sup> (*the palate spine*.) The superior surface of this plate or process is smooth, and forms the back part of the floor of the nasal cavity: the inferior, which forms part of the roof of the mouth, is unequal, and marked by a transverse ridge, into which the tendinous fibres of the circumflexus palati muscle are inserted; it presents also an oval foramen, being the inferior termination of the posterior palatine canal, which transmits the large descending palatine nerve and accompanying vessels; and farther back, another of smaller size, which transmits the middle palatine nerve.

At the junction of the horizontal and vertical portions is situated a thick rough tubercle<sup>3</sup> (*tuberosity, pyramidal process*,) projecting downwards and backwards. This is marked by three vertical grooves; the two lateral ones are rough, and receive the inferior borders of the pterygoid plates of the sphenoid bone; the middle one,<sup>10</sup> smooth, corresponds with and completes the fossa between the pterygoid plates.

The vertical portion of the bone is flat and thin; it presents two surfaces; the internal one (*nasal*) is divided into two parts by a transverse ridge (*crista transversa*),<sup>6</sup> which articulates with the inferior spongy bone; the space below the ridge forms part of the inferior meatus, that above it of the middle meatus. The external surface, rough and unequal, fig. 70, is divided by a vertical groove,<sup>2</sup> which is completed into a canal (*posterior palatine canal*) by the maxillary bone. The posterior part of this surface articulates with the rough border and nasal surface of the maxillary bone; and the anterior, thin and scale-like, with the side of the



The superior border of the vertical portion of the palate bone presents a notch,<sup>3</sup> forming the greater part of a foramen, which is completed by the sphenoid bone when the parts are in their natural position. This is called the *spheno-palatine* foramen; and outside of it is placed the nervous ganglion of the same name (Meckel's ganglion). This notch divides the border of the bone into two processes or heads, the sphenoidal and the orbital.

The *sphenoidal* process,<sup>7</sup> smaller and not so prominent, presents three surfaces, of which one, internal, looks to the nasal fossa; another, external, forms a small part of the zygomatic fossa; and the third, superior, grooved on its upper surface, articulates with the under surface of the sphenoid bone, and with it forms part of the *pterygo-palatine canal*.

The *orbital* process<sup>5</sup> inclines outwards and forwards, and has five surfaces, two of which are free, and three articulated; of the latter, the internal one rests against the ethmoid bone, and covers some of its cellules; the anterior articulates with the superior maxillary bone; and the posterior (which is hollow) with the sphenoid. Of the non-articular surfaces, one superior, smooth and oblique, forms a small part of the floor of the orbit; the other, external, looks into the zygomatic fossa.

*Articulations.*—With the corresponding palate bone; with the superior maxillary, ethmoid, sphenoid, vomer, and inferior spongy bone.

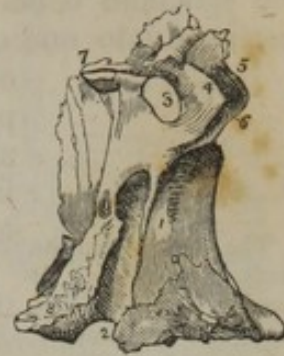*Muscular attachments.*—To its spine, the *azygos uvulæ*; to the centre groove on its tuberosity, a small part of the internal pterygoid; and to the transverse ridge on the palate plate, the aponeurosis of the *circumflexus palati*.

*Ossification.*—The palate bone is formed from a single centre, which is deposited at the angle formed between its parts. From this the ossification spreads in different directions—upwards into the vertical plate, inwards to the horizontal one, and backwards to the pyramidal process. For a considerable time after it has been fully ossified this bone is remarkable for its shortness; the horizontal plate exceeds in length the vertical one in the fœtal skull.

#### THE VOMER.

The vomer, (fig. 78,<sup>3</sup>) [*os vomeris*,] so called from its resemblance to a ploughshare, is flat, irregularly quadrilateral, and placed vertically between the nasal fossæ, presenting two surfaces and four borders. The lateral surfaces form part of the inner wall of the nasal fossæ; the superior border, thick and deeply grooved, receives the rostrum of

Fig. 70.



The perpendicular plate of the palate bone seen upon its external or sphenomaxillary surface. 1. The rough surface of this plate, which articulates with the superior maxillary bone and bounds the antrum. 2. The posterior palatine canal, completed by the tuberosity of the superior maxillary bone and pterygoid process. The rough surface to the left of the canal (2) articulates with the internal pterygoid plate. 3. The spheno-palatine notch. 4, 5, 6. The orbital portion of the perpendicular plate. 4. The spheno-maxillary facet of this portion; 5, its orbital facet; 6, its maxillary facet, to articulate with the superior maxillary bone. 7. The sphenoidal portion of the perpendicular plate. 8. The pterygoid process or tuberosity of the bone.



the sphenoid bone; the margins of the groove expand and are articulated with two small lamellæ at the roots of the pterygoid processes of the sphenoid bone. The anterior border, also grooved, presents two portions, into one of which is implanted the descending plate of the

Fig. 71.



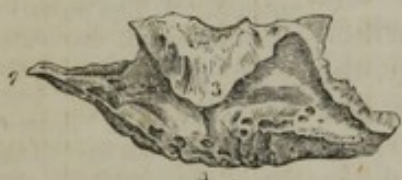The vomer from the skull of a fœtus. It consists of two plates, (1, 2,) united below.

*Ossification* begins in the vomer about the same time as in the vertebræ. In the early periods it consists of two laminæ separated by a considerable interval, except at the lower border, where they are joined (fig. 71).

#### THE INFERIOR TURBINATE BONES.

Each *inferior turbinate*, or *spongy bone*, fig. 72, (so called from its

[Fig. 72.



External view of the right inferior turbinate bone. 1. Anterior extremity. 2. Posterior extremity. 3. Uncinate process. 4. Inferior border. —Smith and Horner.]

texture in the latter case, in the former from some resemblance to the lateral half of an elongated bivalve shell,) extends from before backwards, along the side of the nasal fossa:—it appears as if appended to the side of the superior maxillary and palate bones. It is slightly convoluted, and presents an external concave surface, which arches over the inferior meatus, and an internal convex surface, projecting into the nasal fossa. This bone has not canals or foramina for the olfactory nerve, like the spongy bones of the ethmoid, but it is marked by two horizontal, branching grooves (in part canals) for other nerves. Its superior border articulates with the ascending process of the maxillary bone before, with the palate bone behind, and in the centre with the os unguis; it presents also a hooked process,<sup>3</sup> which curves downwards and articulates with the side of the antrum; the inferior border<sup>4</sup> is free, slightly twisted, and dependent.

The *ossification* commences about the middle of fœtal life, and from a single point.

#### THE INFERIOR MAXILLARY BONE.

The inferior maxilla, fig. 73, (*os maxillæ inferius: mandibula*,) of considerable size, is the thickest and strongest bone of the face, of which it forms a large portion of the sides and fore part. It is convex in its general outline, and shaped somewhat like a horseshoe. It is usually considered as divisible into a middle larger portion—its body, and two branches or rami.

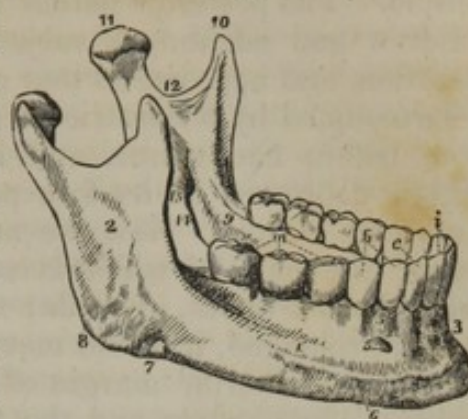
The *body*<sup>1</sup> is placed horizontally; its external surface is convex, and marked at the middle by a vertical line<sup>3</sup> indicating the original division of the bone into two lateral parts, and thence named its *symphysis*. On each side of the symphysis, and just below the incisor teeth, is a superficial depression, (the *incisor fossa*,) which gives origin to the



levator menti muscle; and, more externally, a foramen,<sup>5</sup> (*foramen mentale*), which transmits the terminal branches of the dental nerve and artery. A raised line may be observed to extend obliquely upwards and outwards from near the symphysis to the anterior border of the ramus; it is named the *external oblique line*,<sup>6</sup> and is intended to give attachment to muscles. The *internal surface* of the body of the bone is concave in its general outline, and marked at its centre by a depression corresponding with the symphysis; at each side of which are two prominent tubercles (*spinæ mentales*), placed in pairs one above the other, and affording attachment,—the upper pair, to the *genio-hyoglossi*, and the lower to the *genio-hyoidei* muscles; beneath these are two slight depressions for the *diaphragmatic* muscles. An oblique prominent line,<sup>9</sup> (the *mylo-hyoidean ridge*), will be observed leading from the lower margin upwards and outwards to the ramus; above the line is a smooth depression for the *sublingual gland*, and beneath it, but situated more externally, is another for the *submaxillary gland*. The superior (*alveolar*) border of the body is horizontal, and marked by notches corresponding with the *alveoli*, or sockets of the teeth. The inferior border (*the base*), thicker at its anterior than at its posterior part, is slightly everted in front, so as to project somewhat forwards, constituting the *chin* (*mentum*, γένσιον). The vertical direction of the bone below the incisor teeth, and the projection of the lower border forward in front, are peculiar to man. In other animals the maxillary bone at its anterior part retires or inclines backwards more or less below the alveolar border, leaving this the most prominent point.

The *branches*,<sup>2</sup> (*rami*), project upwards from the posterior extremity of the body of the bone, with which they form nearly a right angle in the adult, an obtuse one in infancy,—the “angle”<sup>8</sup> of the jaw. They are thinner somewhat, and appear as if compressed. The external surface of each ramus is flat, and marked by slight inequalities; the internal surface presents at its middle a *foramen*,<sup>13</sup> (*inferior dental*), leading into a *canal* (*dental*) contained within the bone, and lodging the dental nerve and vessels. Beneath the foramen a slight groove,<sup>14</sup> (occasionally and for a short space, a canal,) marks the passage of the *mylo-hyoid nerve* with an accompanying artery and vein; the rest of the surface being rough, for the insertion of the *pterygoideus internus*. The anterior border of each ramus is nearly vertical in its direction, and terminates in a pointed extremity, named the *coronoid process*;<sup>10</sup> it

[Fig. 73.]



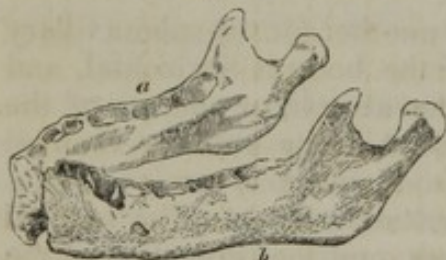The lower jaw. 1. The body. 2. The ramus. 3. The symphysis. 4. The fossa for the depressor labii inferioris muscle. 5. The mental foramen. 6. The external oblique line. 7. The groove for the facial artery; the situation of the groove is marked by a notch in the bone a little in front of the number. 8. The angle. 9. The extremity of the mylo-hyoidean ridge. 10. The coronoid process. 11. The condyle. 12. The sigmoid notch. 13. The inferior dental foramen. 14. The mylo-hyoidean groove. 15. The alveolar process. i. The middle and lateral incisor tooth of one side. t. The canine tooth. b. The two bicuspides. m. The three molares.—W.]



is grooved at its commencement, for the attachment of the buccinator muscle. The posterior border is also almost vertical in adults; but in children and edentulous subjects it departs considerably from this direction, and approaches that of the base of the bone. This border is surmounted by a constricted part, which appears as if compressed from before backwards, and is called the *neck* of the bone. It is slightly depressed at its fore part, and gives insertion to the external pterygoid muscle. Now the neck supports the articular head of the bone,<sup>11</sup> (the *condyle*,) which is convex and oblong, its greatest diameter being from without, inwards; the direction of its axis is oblique, so that, if prolonged, it would meet with that of its fellow of the opposite side at the anterior margin of the foramen magnum. The interval between the condyle and the coronoid process, deeply excavated, is called the *sigmoid notch* (*incisura sigmoidea*),<sup>12</sup> and if viewed when the bones are *in situ*, it will be found to form a complete circle with the arch of the zygoma.

*Attachments of muscles.*—To the incisor fossa, the levator menti; to the external oblique line, the depressor labii inferioris, depressor anguli oris, and a small part of the platysma myoides. To the upper tubercles on the inner surface of the symphysis, the genio-hyo-glossi; to the inferior ones, the genio-hyoidei; to the depression beneath these, the digastricus; to the internal oblique line, the mylo-hyoideus, the buccinator, and posteriorly a small part of the superior constrictor of the pharynx. To the external surface of the ramus, the masseter; to the lower part of the inner surface, the pterygoideus internus; to the neck of the condyle, the pterygoideus externus; to the coronoid process, the temporal.

Fig. 74.



The inferior maxilla of a fœtus at about the full period of intra-uterine life. The two sides are separate.

*Ossification.*—The earliest conditions of this bone have not hitherto been determined in a satisfactory manner, as has been stated of the superior maxilla, and for the same reasons, namely, the earliness of the period at which the ossification begins, and the rapidity of its progress.

The inferior maxilla begins to ossify before any other bone, except the clavicle. It consists of two equal lateral parts, (fig. 74, *a b*,) which are separate at the time of birth. They join in the first year after, but a trace of separation may be found at the upper part in the beginning of the second year.

Some observers admit no other than a single ossific centre for each side,—two for the entire bone;\* while others describe more, without however, agreeing as to the number. Thus,—besides one large piece for the body,—the coronoid process, the condyle, the angle, and the thin plate forming the inner side of the alveolus, and reaching from the dental foramen onwards, have been stated to possess each a distinct ossific point.† The question of the number of nuclei from which

\* *e. g.* Nesbitt, *Lect. ii.* p. 96; and J. F. Meckel, *Op. citat.* B. ii. § 615.

† Kerckringius describes the coronoid process as a separate piece, (*cap. ix.* p. 234,) and gives a representation of it connected by a suture to the rest of the bone (*Tab. 33, fig. 6*).



each side of the bone is produced we must consider to be still undetermined, especially since those anatomists who have described a plurality of them do not agree in their statements. It should, however, at the same time be added, that the observations which have been referred to render it more than probable that there are commonly several nuclei; and the probability is increased by a consideration of the state of the same bone in some animals, as the crocodile, in which it is made up of several permanently separate pieces.

The body of the bone undergoes much change as its growth advances; but as the changes are connected with the evolution of the teeth, the detail of them will more fitly accompany the description of those parts. In this place it will be sufficient to say of the dried bone, that being at first little more than a groove or case lodging the dental sacs with the nerves and blood-vessels, it is afterwards divided by partitions; and that osseous matter having been largely added, we find it in the adult covered with a thick coating of compact substance, with cancellated structure in the interior; and in this the dental canal, from which small offsets lead to the sockets of the teeth.

In old age the alveolar border disappears with the teeth; and the dental canal, with the mental foramen opening from it, is close to the upper margin of the bone. At the same time the prominence of the chin becomes more marked in consequence of the removal of the teeth and the upper part of the bone.

The differences in the relative direction of the rami and the body have already been noticed.

#### OS HYOIDES.—OS LINGUÆ.

This is the v-shaped bone, (fig. 75,) so named from some resemblance to the Greek letter  $\upsilon$ . It is occasionally called the lingual bone, from its important relations with the tongue; it is situated at the base of the tongue, and may be felt between the chin and the thyroid cartilage. It consists of a body, two cornua, and two cornicula.

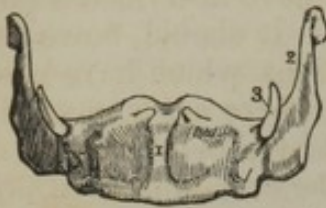The *body* or central piece<sup>1</sup> is small, quadrilateral in its form, and appearing as if compressed from before backwards; hence the

Autenrieth (Wiedemann's "Archiv." &c. B. 1,) confirms the observations of Kerckringius, and mentions two other parts as growing separately: viz., the condyle and the angle. (Not having access to the original Essay, I have borrowed this statement from Spix and Meckel.) Spix ("Cephalogenesis," sect. i. p. 20, and tab. 3, fig. 5,<sup>a</sup>) states, that he had observed the pieces described by Autenrieth, and he adds another from his own observation,—namely, the inner margin of the alveolus; of this a representation is contained in the figure referred to. Béclard found the coronoid process distinct; and in the same preparation the condyle, the angle, and the inner margin of the alveolus were in such a state (the two first being joined by a very thin layer of bone, and the last separated largely by a fissure) that he inclined to regard them likewise as separate formations. M. Cruveilhier ("Anat. Descript.") t. i. admits the existence of but a single secondary piece,—the alveolar plate (of Spix). But Meckel says of this part, that it is only an extension backwards of the general ossification of the bone; and the appearance of separation he attributes to the depth of the groove of the mylo-hyoid nerve, which (according to this anatomist) is rather a fissure than a groove, in consequence of the comparatively large size of the nerve at an early period of life.

From this diversity, and even conflict of statement, it is manifest that the subject requires further investigation.



[Fig. 75.]



The os hyoides seen from before. 1. The antero-superior, or convex side of the body. 2. The great cornu of the left side. 3. The lesser cornu of the same side. The cornua were ossified to the body of the bone in the specimen from which this figure was drawn. —W.]

direction of its plane is nearly vertical; but the great cornua seem as if compressed from above downwards, so that their plane appears horizontal. The anterior surface of the body is convex, and marked at the middle by a vertical line,<sup>1</sup> on each side of which are depressions for the attachment of muscles; its posterior surface is concave, and corresponds with the epiglottis.

The *cornua*<sup>2</sup> project backwards, and end in a rounded point. The *cornicula*,<sup>3</sup> short, irregularly conical in their form, and oblique in their direction, are placed at the junction of the body with the cornua, and give attachment to the stylo-hyoid ligament; they continue for a long time movable, as the carti-

lage which connects them remains unossified to an advanced period of life.

*Attachments of muscles and ligaments.*—The stylo-hyoid ligaments, to the cornicula; the thyro-hyoid, to the cornua. The anterior surface gives attachment to the stylo-hyoid, sterno-hyoid, and digastric muscles; the superior border, to the mylo-hyoid, genio-hyoid, genio-hyo-glossus, lingualis, hyo-glossus, and the middle constrictor of the pharynx; its lower border, to the omo-hyoid and thyro-hyoid muscles, and more internally to the thyro-hyoid membrane.

*Ossification.*—There are five points of ossification for the os hyoides—one for each of its parts. Nuclei appear in the body and the great cornua towards the close of fetal life. Those which belong to the small cornua make their appearance some time after birth.

## THE CONNEXION OF THE BONES OF THE SKULL ONE WITH ANOTHER.

### THE SUTURES.

The bones of the skull, and those of the face, are joined together by seams or sutures. The cranial sutures are commonly said to be five in number, of which three are termed true, as the margins of the bones are, in a manner, dovetailed one into another; and two are called false or squamous, as they merely overlap one another, like the scales of fishes. The true sutures are, the coronal, the lambdoidal, and the sagittal. These names are obviously ill-chosen; they convey no notion of the position which the sutures occupy in the skull, or of the bones which they connect.

The *coronal* suture (*sutura coronalis*) has been so named from being situated where the ancients wore their garlands (*coronæ*). It connects the frontal with the two parietal bones, and hence it may with more propriety be called “fronto-parietal.” It commences at each side about an inch behind the external orbital process of the frontal bone, where the anterior inferior angle of the parietal articulates with the



great wing of the sphenoid bone. From this point it mounts rather obliquely up towards the vertex, having an inclination backwards. The dentations are better marked at the sides than at the summit of the head, for in the latter situation the suture approaches somewhat the squamous character, to allow the frontal bone to overlay the parietal. A similar change takes place at its lower part or commencement, with this difference, that there the parietal bones are made to overlay the frontal.

The *lambdoid* suture (*sutura lambdoidalis*) is situated between the occipital and the parietal bones, its form resembling somewhat that of the Greek letter  $\Lambda$ , whence its name has been taken. It begins at each side on a line with the posterior inferior angle of the parietal bone, and thence inclines upwards and forwards to the point at which the two parietal bones are joined by the sagittal suture. It thus represents two sides of a triangle. It is often interrupted by accessory osseous deposits (*ossa Wormiana*). From its position and relation this suture may be named "occipito-parietal."

The *sagittal* suture (*s. sagittalis*—*sagitta*, an arrow) extends directly backwards, from the middle of the coronal to that of the lambdoid suture, and connects the two parietal bones, from which circumstance it may be called the "inter-parietal" suture: in children, and occasionally in adults, it is prolonged through the frontal bone, even to the root of the nose. The serrated appearance of the sutures is perceptible only on the external surface of the bones; the internal surface, or table of each, as it is called, being merely in apposition with the contiguous bone.

The line of union between the occipital and the temporal bone at each side used to be considered as a continuation of the lambdoid suture, or as an appendix to it, and was accordingly named *additamentum suturæ lambdoidalis*. It may, however, be named *temporo-occipital*, as it connects the mastoid and petrous parts of the temporal bone with the occipital—principally its basilar and condyloid portions. In this suture there are no regular dentations; in a great part of its extent the margins of the bones are merely in apposition.

The *squamous* sutures (*suturæ squamosæ*) are arched and mark the junction of the lower borders of the parietal bones with the squamous parts of the temporal, their edges being so bevelled off as to allow the latter to overlay the former. At the point of junction between the squamous and mastoid parts of the temporal bone, the true squamous suture ceases; but from thence a short suture runs backwards to the lambdoid, connecting the mastoid part of the temporal with the postero-inferior angle of the parietal. This is termed *additamentum suturæ squamosæ*:—both together form the "temporo-parietal" suture.

The line of direction of the sutures (particularly the lambdoid and sagittal) is not unfrequently interrupted by additional bones, inserted between those hitherto enumerated. These, from being sometimes of a triangular form, are called *ossa triquetra*, and also *ossa Wormiana*.

The cranial bones are joined to those of the face by sutures, which are common to both sets of bones. The *transverse* suture, observable at the root of the nose, extends across the orbits, and connects the



frontal with the nasal, superior maxillary, ossa unguis, ethmoid, sphenoid, and malar bones. The *zygomatic* sutures are very short; they are directed obliquely downwards and backwards, and join the zygomatic processes of the temporal with the malar bones. The *ethmoid* suture surrounds the bone of the same name; so does the *sphenoid*; they are necessarily complex in consequence of the many relations of these bones. The lines of connexion between the nasal and maxillary bones, though sufficiently marked, have not received particular names; but those observable between the horizontal lamellæ of the latter, and those of the palate bones, may be termed the palato-maxillary sutures.

#### THE GENERAL CONFORMATION OF THE SKULL.

After having described, in detail, the separate bones of the head and face, it becomes necessary to review them collectively. The description of these bones forms the most difficult part of human, as well as of comparative osteology, as they are the most complex in the whole skeleton; but a correct knowledge of them is indispensable, in consequence of the many important parts which they serve to contain and enclose; viz. the cerebral mass, with its nerves and vessels; the organs of sight, hearing, smell, and taste; and part of those of mastication, of deglutition, and of the voice. To facilitate the description of the numerous eminences, depressions, cavities, and foramina of the skull, anatomists examine successively its external and internal surfaces.

#### THE EXTERNAL SURFACE OF THE SKULL.

This surface may be considered as divisible into five regions, three being somewhat of an oval figure, and situated, one superiorly, another at the base, the third in front, including the face; the others comprise the lateral parts, and are somewhat flat and triangular.

A. The *superior region* extends from the frontal eminences to the occipital protuberance, and, transversely, from one temporal ridge to the other; it thus includes the upper broad part of the frontal, almost all the parietal, and the superior third of the occipital bone, which together form the vaulted arch of the skull. It is divided into two symmetrical parts by the sagittal suture and its continuation when it exists; it presents no aperture or other inequality deserving of particular notice; it is covered by the common integument and occipito-frontalis muscle, on which ramify branches of the temporal, occipital, and auricular arteries, as well as filaments of nerves from the frontal branches of the fifth and portio dura, and also from the occipital nerve.

B. The *inferior region*, fig. 76, also oval in its outline, is the most complex of all, as it includes the entire base of the skull, extending from the incisor teeth to the occipital protuberance, and transversely, from the mastoid process and dental arch on one side, to the corresponding points on the other. It may be considered as divisible into three parts—anterior, middle, and posterior.

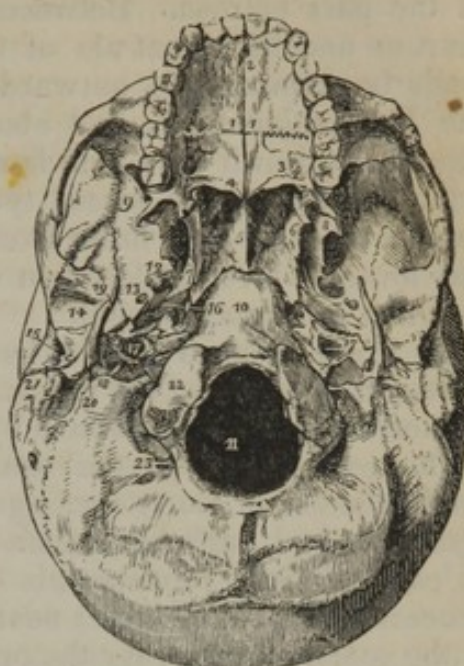
1. The *anterior part* of the base corresponds with the extent of the arch of the palate; it is divided into two parts by a line,<sup>1</sup> extending



from before backwards, and marking the junction of the palate processes of the superior maxillary and palate bones; this is intersected by another, running transversely between each palate bone and the corresponding maxillary bone. Anteriorly, and in the middle line, is a foramen,<sup>2</sup> (the *anterior palatine*), which communicates with the nasal fossæ by four foramina or short canals (for a description of these see page 141). Posteriorly, on each side, and at the base of the alveolar border, is another foramen,<sup>3</sup> (*posterior palatine*), for the posterior palatine nerves and artery.

2. The middle, or guttural part, is bounded on each side by a line extended from the pterygoid process,<sup>6</sup> as far as the mastoid process,<sup>21</sup> thus including the posterior aperture of the nares, and the central part of the base of the skull. In the centre is situated the basilar process<sup>10</sup> of the occipital bone, marked by slight inequalities, for the attachment of muscles, and towards its posterior extremity the anterior condyloid foramina, which transmit the ninth pair of nerves. On each side is the pars petrosa of the temporal bone, in which may be observed the styloid and vaginal processes; more posteriorly is the jugular fossa, which is completed into a foramen<sup>18</sup> (*foramen lacerum posterius basis cranii*) by the border of the occipital bone. This is divided into two parts by a spiculum of bone, or a fibrous band, the internal and anterior one serving to transmit the glossopharyngeal, par vagum, and spinal accessory nerves; the other the jugular vein. Between the apex of the pars petrosa and the side of the basilar process, and the body of the sphenoid bone, is the *foramen lacerum anterius basis cranii*,<sup>16</sup> which is closed inferiorly by a thin plate of cartilage: across its area, as viewed at its upper or cerebral aspect, runs the internal carotid artery in its passage from the carotid canal in the temporal bone to the side of the sphenoid, and also the Vidian nerve, after it has passed backwards through the pterygoid

[Fig. 76.]



The external or basilar surface of the base of the skull. 1, 1. The hard palate. The figures are placed upon the palate processes of the superior maxillary bones. 2. The incisive, or anterior palatine foramen. 3. The palate process of the palate bone. The large opening near the figure is the posterior palatine foramen. 4. The palatine spine; the curved line upon which the number rests, is the transverse ridge. 5. The vomer, dividing the openings of the posterior nares. 6. The internal pterygoid plate. 7. The scaphoid fossa. 8. The external pterygoid plate. The interval between 6 and 8 (right side of the figure) is the pterygoid fossa. 9. The zygomatic fossa. 10. The basilar process of the occipital bone. 11. The foramen magnum. 12. The foramen ovale. 13. The foramen spinosum. 14. The glenoid fossa. 15. The meatus auditorius externus. 16. The foramen lacerum anterius basis cranii. 17. The carotid foramen of the left side. 18. The foramen lacerum posterius, or jugular foramen. 19. The styloid process. 20. The stylo-mastoid foramen. 21. The mastoid process. 22. One of the condyles of the occipital bone. 23. The posterior condyloid fossa.—W.]



foramen, and is proceeding to reach the groove in the upper surface of the pars petrosa. Between the contiguous margins of the pars petrosa and the great ala of the sphenoid bone is a groove, which leads backwards and outwards, and lodges the cartilaginous part of the Eustachian tube; and above the osseous part of that tube, and separated from it by a thin lamella of bone, is the orifice of the canal which transmits the tensor tympani muscle. The foramina of this region, taken in their order from within outwards and backwards, are, the foramen ovale,<sup>12</sup> foramen spinosum,<sup>13</sup> foramen caroticum,<sup>17</sup> and foramen stylo-mastoideum.<sup>20</sup>

In front, this part of the base of the skull is continuous with the posterior aperture of the nares, which is divided into two parts by the vomer.<sup>5</sup> It is bounded above by the body of the sphenoid bone, below by the palate plates of the ossa palati, and on the sides by the pterygoid processes. Each opening measures about an inch in the vertical direction, and half that extent transversely. The pterygoid groove, in each of these processes, is completed inferiorly by the pyramidal process of the palate bone; near its junction with the body of the bone is the scaphoid fossa, for the origin of the circumflexus palati; and at its inferior termination is the hamular process, round which the tendon of that muscle is reflected. Between the base of this process and the posterior palatine foramen is situated a smaller foramen, leading down from the posterior palatine canal, and which transmits the middle palatine nerve.

3. The *posterior part* of the inferior region includes all that is situated between the occipital protuberance and a line connecting the mastoid processes. It is divided into two lateral parts by a ridge, extending to the foramen magnum from the occipital protuberance, from which two rough curved lines branch outwards, giving attachment to muscles; so does the space between the lines, and that between the inferior one and the foramen magnum. At the margin of the foramen, but nearer to its anterior part, are the condyles<sup>22</sup> of the occipital bone, which articulate with the first vertebra; behind each is a depression,<sup>23</sup> (*condyloid fossa*), and usually a foramen (*posterior condyloid foramen*), which transmits a small vein and artery. Before and a little to the outer side of each, in a spot also retiring and depressed, is the opening of the *anterior condyloid foramen*, which looks obliquely outwards and forwards, and transmits the hypoglossal nerve.

c. The *anterior region* of the skull is of an oval form, and extends from the frontal eminences to the chin, and from the external border of the orbit and ramus of the jaw, on one side, to the corresponding points on the other, so as to include the whole of the face. The eminences, depressions, fossæ, and foramina observable in this region are as follow: viz., the frontal eminences, more or less prominent in different individuals, bounded inferiorly by two slight depressions, which separate them from the superciliary ridges: these curve outwards, from the nasal process of the frontal bone. Beneath the superciliary ridge, on each side, is the margin of the orbit, marked at its inner third by a groove, or a foramen, which transmits the frontal nerve and supra-orbital artery; and also by a slight depression which gives attachment to the cartilaginous pulley of the trochlearis muscle. At an



interval corresponding with the breadth of the orbit is another ridge, forming its inferior margin; under which is situated the infra-orbital foramen, for the passage of the superior maxillary nerve; and still lower down, the fossa canina, which gives attachment to the levator anguli oris muscle; it is bounded below by the alveolar border of the upper jaw, and surmounted by the malar tuberosity. Towards the middle line, and corresponding with the interval between the orbits, is the nasal eminence of the frontal bone, which is prominent in proportion to the development of the frontal sinuses over which it is situated. This is bounded by the transverse suture, marking the root of the nose. Beneath the nasal, and between the contiguous borders of the superior maxillary bones, is a triangular opening which leads into the nasal fossæ; it is broad below, and there its edge is surmounted by a prominent process, the nasal spine. Laterally it presents two sharp curved borders, which gradually incline inwards as they ascend to the nasal bones, so as to narrow it somewhat. Below the nasal aperture is a slight depression (myrtiform fossa), at each side of the middle line over the alveolus of the second incisor tooth. Farther down is the transverse rima of the mouth, between the alveolar borders of the jaws. In the inferior maxillary bone, besides some muscular impressions, is the mental foramen, which transmits the terminal branches of the dental nerve and artery.

D. and E. The two *lateral* regions of the skull are somewhat of a triangular figure, the apex of the triangle being at the angle of the lower jaw, the base at the temporal ridge, and the sides formed by two lines drawn, one upwards and forwards, over the external orbital process, the other upwards and backwards, over the mastoid process. In consequence of the great irregularity of the surface, it is necessary to subdivide each of these regions into three; the part above the zygoma being called the temporal region or fossa, that beneath it the zygomatic, the remainder being named the mastoid.

1. The *temporal* part, or fossa, being bounded by the temporal ridge above, and by the zygomatic arch below, is of a semicircular form, and extends from the external angular process of the frontal bone to the base of the mastoid process. It is filled up by the temporal muscle, lodges the deep temporal vessels and nerves, and is formed by the temporal, parietal, frontal, sphenoid, and malar bones.

2. The *mastoid* part is bounded before by the transverse root of the zygoma, above by the horizontal one and the additamentum suturæ squamosæ, behind and inferiorly by the additamentum suturæ lambdoidalis. Proceeding from behind forwards, we observe the mastoid foramen, the process of the same name; anterior to which is the aperture of the meatus auditorius externus, which is circular in young subjects, and somewhat oval in adults, the longest diameter being from above downwards. The osseous tube, continuous, externally, with the fibro-cartilage of the ear, and bounded internally by the membrana tympani, is directed obliquely forwards and inwards, and is somewhat broader at its extremities than in the middle. Anterior to the meatus is the glenoid fossa, which is bounded before by the transverse root of the zygoma, behind by the meatus, and internally by the



spinous process of the sphenoid bone. It is divided into two parts by a transverse fissure (*fissura Glaseri*), the anterior portion being smooth, for its articulation with the condyle of the lower jaw; the posterior rough, lodges part of the parotid gland. This fissure gives entrance to the laxator tympani muscle and a small artery, and transmits outwards the chorda tympani nerve.

3. The *zygomatic* part of the lateral region, situated deeply behind and beneath the orbit, is bounded before by the convex part of the superior maxillary bone, and is inclosed between the zygoma and the pterygoid process. The posterior surface of the maxillary bone is pierced by some small foramina, opening into canals, for the transmission of the superior dental nerves. Between the superior border of this bone and the great ala of the sphenoid, is a fissure (*spheno-maxillary*), which is directed forwards and outwards, and communicates with the orbit; and between its posterior border and the pterygoid process is another (*pterygo-maxillary*), whose direction is vertical. The angle formed by the union of these fissures constitutes the *spheno-maxillary fossa*, which is situated before the base of the pterygoid process, behind the summit or posterior termination of the orbit, and immediately external to the nasal fossæ, from which it is separated by the perpendicular plate of the palate bone. Into this narrow spot five foramina open, viz., the foramen rotundum, which gives passage to the second branch of the fifth pair; the foramen pterygoideum, to the Vidian or pterygoid nerve and artery; the pterygo-palatine to a small artery of the same name (sometimes called also the superior pharyngeal); the posterior palatine foramen, leading to the canal of the same name; and the spheno-palatine, which transmits the spheno-palatine nerve and artery.

#### THE INTERNAL SURFACE OF THE SKULL.

The internal surface of the skull may be divided into its arch and its base.

The *arch* extends from the base of the perpendicular part of the frontal bone, as far as the transverse ridge on the inner surface of the occipital bone. Along the middle line, and corresponding with the direction of the sagittal suture, is a shallow groove, marking the course of the superior longitudinal sinus. Several slight, irregular depressions may also be observed, for the cerebral convolutions, and some tortuous lines for the branches of the meningeal artery; and in many cases irregular depressions over the points occupied by glandulæ Pacchioni. The surface is more or less depressed so as to form fossæ at the points corresponding with the frontal and parietal eminences, and also above the internal occipital ridge, where the posterior lobes of the brain are lodged.

The *base* of the skull presents on the inner surface the several eminences, depressions, and foramina, which have been already enumerated in the description of the separate bones. Three fossæ may be observed at each side, differing in size and depth.

1. The *anterior fossa*, formed by the orbital plate of the frontal bone



and the smaller wing of the sphenoid, and the cribriform plate of the ethmoid, serves to support the anterior lobe of the brain: it is marked by eminences and depressions corresponding with the cerebral convolutions and sulci; and posteriorly, by a transverse line, indicating the junction of the bones just mentioned. The foramina in the anterior fossa are those in the ethmoid bone for the transmission of nerves and an artery to the nasal fossæ: viz., the olfactory nerve, the internal nasal branch of the fifth cerebral nerve, and the ethmoidal branch of the ophthalmic artery.

2. The *middle fossa*, formed by the great ala of the sphenoid, the squamous part of the temporal, and the anterior surface of the pars petrosa, lodges the middle lobe of the brain. It is marked by linear impressions for the meningeal artery, and by shallow pits for the cerebral convolutions; anteriorly, it opens into the orbit by the sphenoidal fissure, sometimes called foramen lacerum anterius, to distinguish it from those placed farther back, and already noticed; it transmits the third, the fourth, and the sixth nerves, together with the ophthalmic branch of the fifth and the ophthalmic vein. Behind this is situated the foramen rotundum for the second branch of the fifth, the foramen ovale for the third, and lastly, the foramen spinosum for the middle meningeal artery. Where the summit of the pars petrosa approaches the body of the sphenoid bone, there the internal orifice of the carotid canal opens. On the anterior surface of the pars petrosa, and directed obliquely backwards, there is a slight groove, leading to the hiatus Fallopii, and transmitting the Vidian nerve.

3. The *posterior fossa*, deeper and broader than the others, gives lodgment to the lateral lobes of the cerebellum. In the posterior surface of the pars petrosa, which forms the anterior limit of this fossa, may be observed the internal auditory foramen, and, within a few lines of it, a triangular fissure, which opens into the aquæductus vestibuli, and towards its inferior margin part of the groove for the lateral sinus, which leads down to the foramen lacerum posterius. Along the middle line, and taking the parts situated in the base of the skull from before backwards, we observe the crista galli of the ethmoid bone, and on each side the cribriform lamella of that bone; further back, a slightly depressed surface, which supports the commissure of the optic nerves; and on each side the optic foramina. Behind this is the pituitary fossa, situated on the body of the sphenoid bone, bounded before and behind by the clinoid processes. Leading downwards and backwards from these is the basilar groove, which supports the pons Varolii and medulla oblongata, and terminates at the foramen magnum; at each side of this foramen are the condyloid foramina, and behind it a crista, leading upwards to the occipital ridge, and giving attachment to the falx cerebelli.

## THE ORBITS.

The form of the orbits is that of a quadrilateral pyramid, whose base is directed forwards and outwards, and apex backwards and inwards, so that if their axes were prolonged backwards they would decussate on the body of the sphenoid bone.



The *roof* of each orbit forms part of the floor for the brain; it is concave, and composed of the orbital process of the frontal, and the smaller wing of the sphenoid bone: at its anterior and inner border may be observed a depression for the attachment of the pulley of the trochlearis muscle; externally, and immediately within the margin of the orbit, a shallow depression for the lachrymal gland; at the anterior border, a groove, sometimes a foramen, which transmits the supra-orbital or frontal nerve and artery; and posteriorly, at the apex of the cavity, the optic foramen, transmitting the optic nerve and ophthalmic artery. The *floor* forms the roof of the maxillary sinus: it consists of the orbital processes of the malar and maxillary bones, and of the small portion of the palate bone which rests on the latter; towards the inner and anterior border, near the lachrymal canal, may be observed a slight roughness, for the attachment of the obliquus inferior muscle; posteriorly, a groove, terminating in the infra-orbital canal, which runs nearly horizontally forwards. The *inner side* or wall of the orbit runs directly backwards, being parallel with the corresponding side of the other orbit, and is composed of the ascending process of the maxillary bone, the os unguis, the os planum of the ethmoid, and part of the body of the sphenoid bone. Near the anterior border is situated the *lachrymal canal*, which is formed, for the most part, between the ascending process and body of the maxillary bone, the remainder being made up by the groove in the os unguis, and a small process of the inferior spongy bone; this canal, a little expanded at its extremities, is directed downwards, backwards, and a little outwards. The *outer side* of the orbit, composed of the orbital plates of the malar and sphenoid bones, presents some minute foramina, which transmit small nerves from the orbit to the temporal fossa.

The *superior internal angle*, formed by the junction of the orbital process of the frontal bone with the os unguis and os planum, presents two foramina (*foramen orbitale internum, anterius et posterius*), which give transmission, the anterior to the nasal twig of the ophthalmic nerve, the posterior to the ethmoidal artery. The *internal inferior angle* is rounded off so as to be scarcely recognised: it is formed by the union of the os unguis and os planum with the orbital plates of the superior maxillary and palate bones. In the *external superior angle*, formed by the malar, frontal, and sphenoid bones, is observed the sphenoidal fissure, of a triangular form, situated obliquely, its base being internal and inferior, the apex external and superior. In the *inferior external angle*, formed by the malar, the great ala of the sphenoid, the maxillary, and palate bones, is situated the sphenomaxillary fissure, inclined at an angle with the former, and communicating with it, but of a different form, being broad at its extremities and narrow at the centre.

The *anterior extremity*, or *base* of the orbit, is directed outwards and forwards; and, as if to provide for a free range of lateral vision, the external wall retreats in some degree, and does not extend as far forward as the internal. The inner termination of the cavity, representing the summit of a pyramid, to which it has been likened, corresponds with the optic foramen. In each orbit, parts of seven bones are



observed, viz. the frontal, ethmoid, sphenoid, os unguis, malar, maxillary, and palate bones; but as three of these, viz. the ethmoid, sphenoid, and frontal, are common to both, there are only eleven bones for the two orbits.

## THE NASAL FOSSÆ.

These fossæ, fig. 77, are two cavities, placed one at each side of the

[Fig. 77.]

Fig. 78.

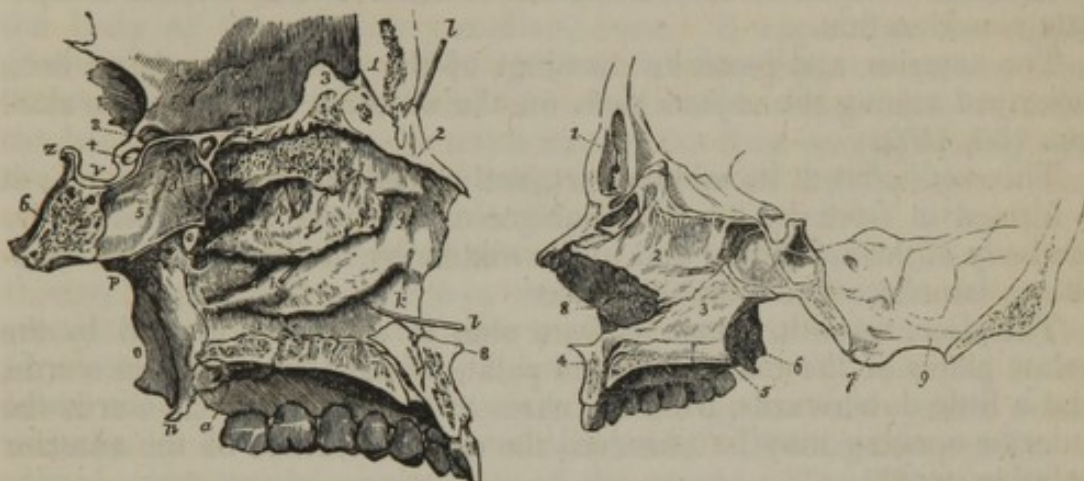


Fig. 77. A longitudinal section of the nasal fossæ made immediately to the right of the middle line, and the bony septum removed in order to show the external wall of the left fossa. 1. The frontal bone. 2. The nasal bone. 3. The crista galli process of the ethmoid. The groove between 1 and 3 is the lateral boundary of the foramen cæcum. 4. The cribriform plate of the ethmoid. 5. Part of the sphenoidal cells. 6. The basilar portion of the sphenoid bone. Bones 2, 4, and 5, form the superior boundary of the nasal fossa. 7, 7. The articulating surface of the palatine process of the superior maxillary bone. The groove between 7, 7, is the lateral half of the incisive canal, and the dark aperture in the groove the inferior termination of the left naso-palatine canal. 8. The nasal spine. 9. The palatine process of the palate bone. *a*. The superior turbinated bone, marked by grooves and apertures for filaments of the olfactory nerve. *b*. The superior meatus. *c*. A probe passed into the posterior ethmoidal cells. *d*. The opening of the sphenoidal cells into the superior meatus. *e*. The spheeno-palatine foramen. *f*. The middle turbinated bone. *g, g*. The middle meatus. *h*. A probe passed into the infundibular canal, leading from the frontal sinuses and anterior ethmoid cells; the triangular aperture immediately above the letter is the opening of the maxillary sinus. *i*. The inferior turbinated bone. *k, k*. The inferior meatus. *l, l*. A probe passed up the nasal duct, showing the direction of that canal. The anterior letters *g, k*, are placed on the superior maxillary bone, the posterior on the palate bone. *m*. The internal pterygoid plate. *n*. Its hamular process. *o*. The external pterygoid plate. *p*. The situation of the opening of the Eustachian tube. *q*. The posterior palatine foramina. *r*. The roof of the left orbit. *s*. The optic foramen. *t*. The groove for the last turn of the internal carotid artery converted into a foramen by the development of an osseous communication between the anterior and middle clinoid processes. *v*. The sella turcica. *z*. The posterior clinoid process.—W.]

Fig. 78. The section of the skull in this case has been made a little to the left of the middle line. The left side of the septum narium (its bony part) is displayed; and beyond it a part of the external wall of the right nasal fossa is shown. The latter is dark, and the figure 8 indicates a portion of the spongy bones which belong to it. 1. A frontal sinus. 2, and 3, are the bones of the septum narium—2 being the middle plate of the ethmoid bone, 3 the vomer. 4, 5. Between these is the hard palate. One is in front of the superior maxillary bone: the other points to the palate bone. Towards the anterior part is seen the anterior palatine canal, or rather about half of it. 6. The pterygoid processes. 7. The right condyle of the occipital bone. 9, is opposite the right half of the foramen magnum.—N. B. Large sphenoidal sinuses are marked above and behind the base of the vomer.

median line, separated by a flat vertical septum. They communicate, by foramina, with the various sinuses lodged in the frontal, the eth-



moid, and superior maxillary bones, and open anteriorly, on the surface, by the nares, and posteriorly into the pharynx.

The depth of the fossa from the upper to the lower part is considerable (most so in its middle): so is the extent from before backwards or between the anterior and the posterior openings. But the breadth, or distance, from the outer to the inner wall is very limited, and it is less at the upper than towards the lower part of the fossa, and in the middle than at the anterior or posterior opening (the nares). The roof, the floor, the inner and the outer walls of these cavities require a separate consideration.

The anterior and posterior openings of the nasal fossæ have been described among the objects seen on the external surface of the skull (pp. 156, 157).

The *roof* is flat at its middle part, and sloped before and behind; it is formed in front by the inner surface of the nasal bones,<sup>2</sup> behind by the body of the sphenoid,<sup>5</sup> and in the middle by the horizontal or cribriform lamella of the ethmoid bone.<sup>4</sup>

The *floor*, smooth, concave from side to side, and formed by the palate plates of the maxillary<sup>7</sup> and palate bones,<sup>9</sup> extends backwards, and a little downwards, from the nares to the pharynx. Towards the anterior opening may be observed the superior orifice of the anterior palatine canal.<sup>7</sup>

The *internal wall*, or septum narium, (fig. 78,) which extends from the roof to the floor of the cavity, is flat, nearly vertical (the deviation, if any, being usually to the left side), and composed of the perpendicular plate of the ethmoid bone,<sup>2</sup> the vomer,<sup>3</sup> and the nasal cartilage.

The *external wall* (fig. 77) is formed by the ethmoid, superior maxillary, os unguis, inferior spongy, and palate bones. The posterior and inferior parts of this surface are marked by a number of inequalities, whilst the superior and anterior are comparatively even. In the latter situation may be observed, first, the smooth surface just mentioned; and, secondly, passing downwards and backwards, three, and frequently four, arched and convoluted bones (spongy bones), beneath which are grooves (*meatus*) leading from before backwards. The superior spongy bone<sup>a</sup> is much shorter than the others; beneath it is the *superior meatus*,<sup>b</sup> into which will be found opening, anteriorly, a foramen from the posterior ethmoidal cells, and, posteriorly, the sphenopalatine foramen. The middle spongy bone<sup>f</sup> overhangs the *middle meatus*,<sup>g</sup> which communicates with the anterior ethmoidal cells; one of these curves forwards and upwards, and is continuous with the frontal sinus; more posteriorly is situated the opening of the maxillary sinus. The *inferior meatus*,<sup>k</sup> situated below the inferior spongy bone,<sup>i</sup> between it and the floor of the nasal cavity, is necessarily longer than the others; it presents anteriorly the orifice of the nasal canal.

#### THE FRONTAL, SPHENOIDAL, AND MAXILLARY SINUSES.

The *frontal sinuses*, fig. 78,<sup>1</sup> correspond with the superciliary eminences of the frontal bone. Of considerable size in the adult, but varying in different individuals, they are not at all developed in the fœtus. They are divided into two, sometimes three, compartments.



They open downwards into the middle meatus narium through the anterior ethmoidal cells.

The *sphenoidal sinuses*, fig. 77,<sup>s</sup> and fig. 78, two in number, are placed within the body of the sphenoid bone; these also cannot be said to exist in infancy. They are separated by a partition. Above, behind, and on each side, they are bounded by the body of the sphenoid bone, and in front by two small spongy bones. They communicate with the posterior ethmoidal sinuses.

The *maxillary sinus* (antrum Highmori) is a large excavation in the body of the superior maxillary bone. It appears at an earlier period than any of the other sinuses, the development commencing about the fourth month of foetal life. Its form is irregularly pyramidal, the base being towards the nasal cavity, the apex corresponding with the malar tuberosity. Superiorly, it is enclosed by the orbital plate of the maxillary bone; and inferiorly by its palate plate: internally, it opens into the middle meatus of the nasal cavity by a foramen, which, though it appears very large in the dry bone when separated from its connexions, is in the natural state small, being little more than sufficient for the admission of a probe; this diminution of size is caused by the lower edge of the ethmoid, the inferior spongy and the palate bones, and also by a fold of the mucous membrane. The narrow opening is placed close to the upper wall of the cavity. The bony plate by which the antrum is separated from the orbit is very slender, so likewise is the partition between it and the nasal fossæ; but in other parts the boundaries of the cavity have considerable thickness—especially the superior maxillary bone at its alveolar border. On the removal of a molar tooth it will, however, be found that its socket is separated from the antrum by a thin partition of bone.

#### ANALOGY BETWEEN CRANIAL BONES AND VERTEBRÆ.

Anatomists have at all times perceived and recognised the analogy between the movable and motionless pieces of the spine—between those of the lumbar and dorsal regions, and those of the sacrum and coccyx; in the one, as well as in the other, similar organic elements are observed to exist, variously modified, in order to suit special purposes; but it is only of late years that any adequate attention has been directed to the points of similitude which exist between vertebræ, properly so called, and the cranial bones. Many persons who adopt, without hesitation, the terms false or pelvic vertebræ, as applied to the sacrum and coccyx, feel a repugnance to use the word false or cranial, as applied to the pieces of the skull; and deny, perhaps, without examination, the analogy upon which it is founded, as being unnatural or far-fetched. We have numerous instances of the harmony that subsists between containing and contained parts throughout the economy; in no case is it more striking than in the relation that obtains between the fundamental part of the osseous structure and the central mass of the nervous system. The spinal canal is accurately adapted in its different parts to the nervous cord which it encloses. In the pelvic region, the canal, at least in the human subject, becomes narrow, as it merely encloses nerves, whilst the body and processes take on a



particular development to meet a special purpose, that of forming a basis of support for the rest of the column. This seems to result from the working of what may be termed a principle of compensation in the growth, as well as in the action of parts; for when one part of a given whole is developed to excess or to a maximum, others will remain at a minimum or atrophied: thus the spinal canal and the arches are at their minimum in the sacrum and coccyx, for the contained parts are there at a low point of development; but at the opposite end of the column the reverse obtains; the contained parts, viz. the central parts of the nervous system, are evolved in the human subject to the greatest extent, and so must the containing parts also be. The portion of the osseous system which corresponds with the bodies of the vertebræ can, therefore, hardly be recognised; whilst that which is analogous to the arches is expanded so much as to retain but a slight similitude to them.

If we take the occipital bone, and examine it attentively, we shall readily perceive in it all the elements of a vertebra. The foramen magnum is the counterpart of the ring of a vertebra, and has a similar relation to the spinal cord; the basilar process represents the body; the condyles are true articulating processes; the rough surfaces external to them, and which give attachment to the recti laterales, correspond to the transverse processes; the vertical ridge extended backwards along the median line, from the foramen to the occipital protuberance, is, in the human subject, merely a rudiment of a spinal process; but in the dog, bear, and badger, it forms a sharp prominence well deserving the name of spine, and the likeness is still more striking in osseous fishes: finally, the broad plates on each side of the spine represent the arches. In this view of the matter, the occipital bone forms the first false vertebra of the cranial region.

In the second cranial piece or vertebra, it must be admitted that the analogies are not so striking; but when we recollect that the cavity of the skull, if examined in the different orders of animals, enlarges in proportion as the brain acquires an increase of development, and that this enlargement attains its maximum in the human subject, we shall at once find sufficient reason to expect that the parts corresponding with the vertebral arches should, in this region, be greatly evolved, while the rest are in a manner atrophied. The parietal bones, with the squamous part of the temporal and the great wings of the sphenoid, taken together, represent the arches, whilst the posterior part of the sphenoid bone, (such as it exists in the human fœtus before its ossification is complete, and such as it continues permanently in several lower animals,) is the counterpart of the body, the mastoid processes of the temporal bones with the glenoid fossæ serve as transverse and articulating processes. These, together, form the middle cranial piece, which may be termed the spheno-temporo-parietal cranial false vertebra.

The frontal bone, the ethmoid, and the anterior division of the sphenoid, (which is that part of the body that sustains the smaller wings,) form the third vertebra; the part of the sphenoid just named, together with the crista galli and the perpendicular plate of the ethmoid



bone, form the body, which is here reduced to a rudimentary state, just as the coccygeal bones are at the opposite end of the column, of which it may be considered a repetition. The lateral and expanded parts of the frontal bone are the arches, and the external orbital processes may be likened to transverse processes.

We have here used the term false vertebra as applied to the cranial pieces; perhaps it would be better to use the word zone, as sanctioned by the authority of Cuvier. The passage in which he recognises the principle of development here indicated, as well as the application of it, (which appears to have been first inculcated by Dumeril, and traced in all its details by Geoffroy Saint-Hilaire,) is as follows:—"Le crâne se subdivise comme en trois ceintures, formées—l'antérieure par les deux frontaux et l'éthmoïde, l'intermédiaire par les pariétaux et le sphénoïde, la postérieure par l'occipital."\*

#### MAN ADAPTED TO THE ERECT POSTURE.

Every part of the conformation of the human subject indicates its adaptation to the erect position. The feet are broader than those of any other animal proportionally to its size; the tarsal and metatarsal bones admit of very little motion; and the great toe is on the same plane with the others, and cannot be brought into opposition with them. The foot is thus fitted to sustain the weight of the body, but not to grasp or seize objects presented to it. The hands, on the contrary, though so well adapted for these purposes, are ill calculated for affording support; so that man is truly "bimanous" and "biped."† The tibia rests perpendicularly on the astragalus, and the os calcis projects backwards for the purpose of increasing the base, and also of lengthening the lever to which the strong muscles of the calf of the leg are attached. The whole extent of the tarsus, metatarsus, and phalanges, in man, rests on the ground, which does not obtain even in apes, the end of whose os calcis is somewhat raised, so as to form an acute angle with the bones of the leg. In dogs and digitated quadrupeds, the carpus and tarsus are considerably elevated from the ground, so that the body rests on the toes; and in the horse, and other solid-hooved animals, the third phalanges only rest on the ground, the os calcis being raised nearly to the perpendicular direction.

The femur, placed securely beneath the pelvis, affords a firm support during progression. The great breadth of the pelvis, serves to enlarge the base on which the trunk rests; and this is farther increased by the length of the cervix femoris. This peculiarity in the neck of the femur renders it necessary that the body of the bone should incline inwards, in order that its axis should approach the central line, and so support the centre of gravity. If its articular head be viewed in profile, it will be observed that the cartilaginous coating is distributed for the most part on its upper and inner aspect, showing its adaptation as a pillar of support in the erect position.

The bones of the pelvis in the human subject are distinguished from those of other animals by some marked peculiarities. The

\* Règne Animal, tom. i. p. 63.

† Ibid. p. 82.



sacrum is remarkably broad and expanded, so as to form a firm support for the spinal column which rests upon it; its lower part is curved and articulated with the coccyx, so that both incline forwards and enclose the pelvic cavity, constituting a support for the viscera when pressed down by muscular action. If a different arrangement of these bones obtained—if they were continued downwards in a straight line, they would project beyond the ischia, and render the sitting posture irksome or impossible.

The spinal column, which is supported on the pelvis, is peculiarly adapted to the erect attitude. Its pyramidal form and enlarged base fit it to sustain the superincumbent weight; and by means of the different curvatures which it presents, a considerable range of motion is allowed to the trunk, the centre of gravity being still supported within the base. The form of the thorax is also peculiar. Shallow and compressed from before backwards, it is broad and expanded from side to side; by which means the preponderance of the trunk forwards is considerably lessened. The sternum, though broad, is very short, so that a considerable space intervenes between it and the pubes, which is occupied solely by muscular parts. But in quadrupeds, the thorax is compressed and flattened laterally, becoming gradually narrower towards the sternum, which is prominent and keel-shaped, so that the breadth from this latter bone to the spine is much greater than that from side to side. This conformation, together with the absence of clavicles in true quadrupeds, enables the anterior extremities to approach closely together, and fall perpendicularly downwards beneath the trunk, so as to give it a steady support. The sternum is elongated in these animals, and the ribs pass from the spine to that bone so directly, without making any angle, that they approach near to the cristæ of the ilia, and thereby increase the extent of firm support necessary to sustain the weight of the viscera. Even with these advantages, the muscles of the abdomen would be inadequate to the support of its contents, were they not assisted by a layer of elastic substance, which is placed over their entire extent, and which of itself marks their destination for the prone position.

Though the upper and lower extremities present several points of similitude, they yet may be contrasted so as to show that they are adapted to totally different purposes. It is quite obvious that the scapula and os innominatum, the humerus and the femur, the bones of the fore-arm and those of the leg, the hand and the foot, are respectively constructed on the same plan; but the differences which they present indicate a difference of function.

The scapulæ, placed on the supero-posterior part of the trunk, are borne off by the clavicles; their glenoid cavities are directed forwards and outwards, so that the arms, which are, as it were, appended to them, are fitted to enjoy a considerable degree of motion in the anterior and lateral directions. But in true quadrupeds the glenoid cavities look downwards, and are approximated closely together, so that the thoracic limbs, which are articulated with them, descend beneath the fore part of the trunk; and, as they are thus calculated to support its weight, they possess little lateral motion. The glenoid cavity in man



is quite shallow, so that the globular head of the humerus is merely applied to its surface; but the acetabulum is a deep cup-like cavity, indicating a quite different destination in the two joints. The breadth of the articular surfaces of the knee-joint, and the peculiar conformation of the ankle-joint, as contrasted with the elbow and wrist, are abundantly sufficient to show that fixity and strength have been designed in the one, mobility in the other. This difference is, if possible, more strongly marked in the conformation of the hand and foot: the latter, as has been already observed, being intended to support the body, is placed at right angles beneath the leg; the former is continuous with the line of direction of the fore-arm, otherwise it could not be guided with sufficient precision to the different objects which it is intended to seize. The tarsal bones are large, firm, and strong; those of the metatarsus are also thick and large, and placed all in a line. That which supports the great toe, being the stoutest of all and almost immovable, ranges with the others. But the metacarpal bones are quite differently disposed; that which supports the thumb admits of considerable motion in every direction, so as to perform a complete circumduction, and is placed so much out of line with the others that it can be opposed to them, as in grasping different objects. The hand and foot may be considered as divisible each into two parts, differing in their degrees of mobility, viz., the digital phalanges, and the row of bones which sustains them. The movable phalanges of the hand are as long as the carpal and metacarpal bones taken together; but in the foot, they are not a third of the length of the tarsal and metatarsal bones.

No part of the osseous system of man affords more striking evidence of his adaptation for the erect posture than the cranium. Resting on the summit of the vertebral column, the line of its base forms a right angle with that of the column itself, which thus affords it a firm support. The condyles, or points of articulation, are situated very near the centre of its base, being, however, a little nearer to the occipital protuberance than to the anterior surface of the jaws; by this arrangement very little active power is required to maintain it *in equilibrio*.\* In other animals the condyles are placed much further back; so that, instead of resting on the column, the skull is, as it were, appended to its extremity, and is sustained by an elastic substance, (ligamentum nuchæ,) which is attached by one extremity to the spinous processes of the vertebræ, and by the other to the occipital protuberance. The head, as has been already observed, is composed of two parts, the cranium and face; the one being intended to contain the brain—the material instrument of the mind; the other to enclose the organs of sight, smell, and taste. The more the organs of smell and taste are developed the greater is the size of the face, and the greater its relative proportion to the cranium. On the contrary, the larger the brain, the greater must be the capacity of the skull, and the greater its proportion to the face. On this principle, a large cranium and a small face indicate a large brain with a restricted development of the sense of smell and taste; but a small cranium and a large face mark an opposite conformation. The character and nature of animals are

\* Lawrence on the Characters of the Human Head, *passim*.



determined by the degree of energy with which their different functions are performed; they are guided and impelled by some leading propensity or disposition; and as the cranium and face bear to the brain and organs of sense the relation of containing and contained parts, the study of their relative proportions is one of great interest to the naturalist, inasmuch as they serve as indices of the faculties, instincts, and capabilities of different individuals as well as of classes.

Several methods have been suggested for determining the proportion of the cranium to the face; the simplest is that of Camper. If a line be drawn upwards from the side of the chin, over the most prominent part of the forehead, it will form an angle with a horizontal line drawn backwards over the external auditory foramen from the margin of the anterior nares; the size of the angle will indicate the degree of development of the cranium and brain, as compared with that of the face and organs of sense. In the crocodile these lines are so nearly coincident that there is scarcely any appreciable angle.

In the Horse it measures*	23°
Ram . . . . .	30
Dog . . . . .	35
Ouran-outang†	56 to 60
European adult . . . . .	85

Thus we find man at the top of the scale of animated beings, distinguished from all the rest, as well by his external conformation as by his internal organization. When the mind has passed in review the many links of the chain which connects the lowest with the highest—the mere animated dot, with man the lord of the creation, it cannot fail to be struck with astonishment at the immense chasm which separates them. Yet, when each link of the chain is compared with that which precedes and follows it, the transition from the one to the other is found to be so gradual as to be almost imperceptible. So easy are the steps of ascent from the organization of the higher orders of the quadrumana, up to the human species, that even Linnæus felt it difficult to assign the specific characters by which man is distinguishable from all others; but any doubt that may have existed on this subject has been long since removed. The physical and moral attributes of man are universally recognised as sufficient to elevate him much further from the higher mammalia than these are from the classes beneath them; and in the opinion of Cuvier,† he should be considered not merely as a distinct species, but even as forming a separate order by himself. Whether, then, with the zoologist, we consider the physical conformation of man as compared with that of other animals, or, with the moralist, reflect on his mental powers and high destination, we can scarcely refrain from saying, with the poet,

Sanctius his animal mentisque capacius altæ  
Deerat adhuc, et quod dominari in cætera possit,  
Natus est homo.

\* Cuvier, *Leçons d'Anatomie Comparée*, tom. ii. p. 8.

† Lawrence on *Nat. Hist. of Man*.

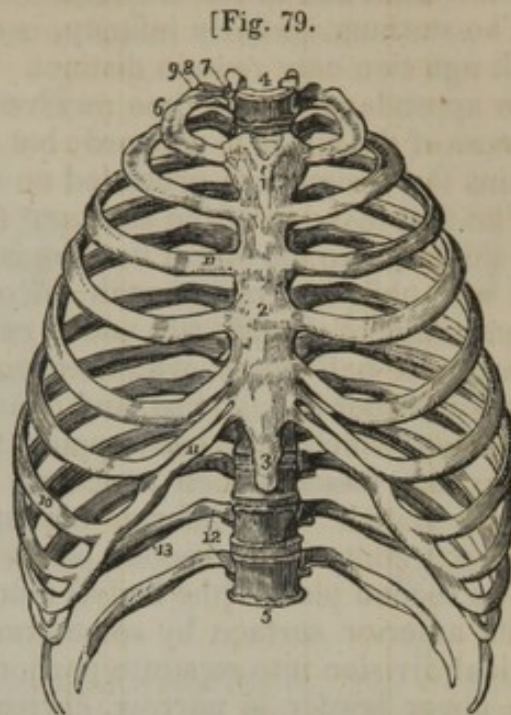
‡ *Règne Animal*, tom. i. p. 81.



## THE THORAX.

Into the composition of the thoracic portion of the skeleton, fig. 79, enter the sternum and ribs, which are proper and peculiar to it, and the vertebræ, which are common to it and other parts. The latter have been already described.

Fig. 79. An anterior view of the thorax. 1. The superior piece of the sternum. 2. The middle piece. 3. The inferior piece, or ensiform cartilage. 4. The first dorsal vertebra. 5. The last dorsal vertebra. 6. The first rib. 7. Its head. 8. Its neck, resting against the transverse process of the first dorsal vertebra. 9. Its tubercle. 10. The seventh or last true rib. 11. The costal cartilages of the true ribs. 12. The last two false ribs or floating ribs. 13. The groove along the lower border of the rib.—W.]



## THE STERNUM AND ENSIFORM CARTILAGE.

The sternum, fig. 79,<sup>2</sup> (os pectoris: xiphoides) is situated in the median line, at the fore part of the thorax: it is flat and narrow, but not of equal width in its entire extent, being broad at its upper part, then narrowed somewhat, after which it widens a little; finally it becomes compressed and narrow where it joins the ensiform cartilage. Its direction is oblique from above downwards and forwards; and the inclination forwards, together with the curve backwards in the dorsal part of the vertebral column, causes a considerable increase in the antero-posterior diameter of the thorax. We have to consider successively its surfaces, extremities, and borders.

The *anterior surface*, slightly convex, and subjacent to the skin, gives attachment to the aponeurosis of the pectoralis major and to the sterno-mastoid muscles, and is marked by four transverse lines, indicating its original division into five pieces. The union between the first and second of these pieces (corresponding with the insertion of the second costal cartilages) is frequently cartilaginous even in adult age.

The *posterior surface*, somewhat concave, looks backwards, towards the cavity of the thorax, and gives attachment, superiorly, to the sterno-hyoideus and sterno-thyroideus muscles; inferiorly, to the triangularis sterni. Along the middle line it corresponds with the interval left by the divergence of the two pleuræ (anterior mediastinum).

The *borders* are thick, and marked on each side by seven angular depressions for the reception of the cartilages of the true ribs, which give them a notched or serrated appearance.

The *superior extremity*, broad and thick, is slightly excavated from



side to side, and presents at each corner a depression for the reception of the sternal end of the clavicle.

The sternum, in early infancy, is divided into several pieces, but in adult age two only remain distinct. These two pieces, with the ensiform appendage, at one time received names derived from an imputed likeness of the whole to a sword; but the last-mentioned part now alone retains the designation grounded on this circumstance.\*

The first division of the sternum<sup>1</sup> (manubrium or handle) is broader and thicker than the other; its form is nearly square; its lateral margins, thin and oblique, present each an oblong depression, which receives the cartilage of the first rib; and at each inferior angle may be observed an articular half notch, which articulates with the second rib. The superior border is hollowed, and hence the names *incisura semilunaris* or *furcula*, which have been applied to it. At the angles which bound it are the fossæ, which articulate with the clavicles, as has been already stated. The inferior border is straight, and united to the upper extremity of the second piece.

The second piece,<sup>2</sup> (the body,) much longer than the first, is marked on its anterior surface by some transverse lines, which indicate its original division into separate portions. Both surfaces are nearly flat. The upper border is narrow, corresponding in breadth with the termination of the first bone, with which it is connected by cartilage. The lateral margins present each five notches for the reception of the cartilages of the five lower true ribs, and a half notch superiorly, which, with a similar depression in the first piece, forms a cavity for the second costal cartilage. The five inferior notches approach one another more closely in proportion as they are situated lower down, and part of the last is occasionally made up by the ensiform cartilage.

If the sternum is examined in several adult skeletons, it will be found to differ in form,—i. e. in the length of its parts, as well as in its breadth at given points;—but these differences are very various, and are not so considerable as to require detailed notice. Other peculiarities, less frequently met with, and of more importance,—such as divisions running through the bone, and perforations of its substance,—will be treated of more conveniently in the account to be given of the ossification; for there the manner of their production can be explained by reference to the process of growth.

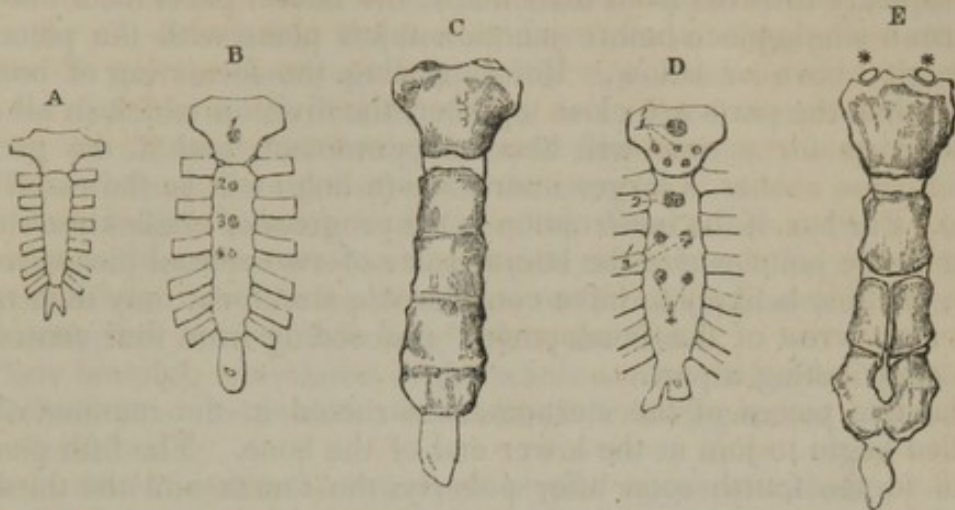
The inferior extremity of the sternum, thin and elongated, gives attachment to a cartilaginous appendix,<sup>3</sup> called the *ensiform* or *xiphoid* (ξίφος, a sword; εἶδος) cartilage, which in most cases remains in the cartilaginous state until an advanced period of life. Its form varies considerably in different individuals: and it is sometimes bent forwards, sometimes in the opposite direction, and sometimes pierced by a hole at its centre (fig. 80, A, B, D). It gives attachment to the aponeurosis of the abdominal muscles.

\* Vesalius, while stating that others regarded the sternum and ensiform cartilage as resembling a sword, prefers to compare the pieces of the sternum to the handle only of that weapon, adding, in support of his view, the curious reason, thus expressed, (Lib. i. p. 115,) "Secundum autem os, illi parti congruit, quam manus tota intus complectitur, in qua sinus costarum cartilaginibus parati, eum præstant usum, quem in gladiis ex manubrij asperitate quærimus, quoties intortis nodosisq' funiculis, aut scabra piscis cute, illud obduci curamus."



*Articulations.*—The sternum articulates by its sides with the cartilages of the true ribs,—by its upper angles with the clavicles, and by the lower end it is connected to the ensiform cartilage.

Fig. 80.



Various conditions of the sternum are represented in these figures. They are described incidentally in the text. 1. The osseous nucleus of the first piece. 1'. Several granules for the same. 2. That of the second piece. 3, 4. Those of the third and fourth. 3', 4'. Double nuclei for the same. \* The epi-sternal granules.

When sawed across, this bone presents a considerable quantity of loose spongy texture in its interior, with a very thin lamella of compact tissue on its outside;—hence it is very light.

*Ossification.*—As far as the middle of foetal life, or a little later, the sternum is altogether cartilage (fig. 80, A). After that time the ossification begins with the formation of osseous granules in the middle of the intervals between the points at which the cartilages of the ribs are connected. There are five of these for the sternum exclusive of the ensiform appendage, and they form as many pieces. The process of ossification makes its appearance in the first piece between the fifth and sixth months, and soon following in the second and the third, it reaches the fourth at the end of foetal life. The osseous centre of the last (fifth) varies considerably in the time of its appearance. It may be found soon after birth, and may not be visible for a considerable time (one or two years) after that period.

In many cases one or more of the divisions of the sternum are formed from more nuclei than one, and there are peculiarities with respect to the number and position of these additional granules which require notice.

The first piece has often two points of ossification, placed usually one above the other; and it has been found to possess three. A number, which I believe to be very unusual (six), is contained in the preparation represented in figure D, 1'. The second has not often more than a single granule (B, D<sup>2</sup>), but the third, fourth, and fifth divisions are frequently formed from two nuclei, which are placed laterally with respect to one another,—not vertically, as occurs in the first piece (D, 3' 4').

The presence of two points of ossification having the relative position



mentioned, accounts for the vertical division sometimes found to run through one or more of the sternal pieces; and the occurrence of a hole, of various size, occasionally met with in the middle of the sternum, is explained by reference to the same peculiarity in the manner of growth. Thus:—in the ordinary course the ossification extending uninterruptedly inwards from their nuclei the lateral parts meet and join to form a single piece before junction takes place with the piece immediately above or below. But supposing the formation of bone to cease when the parts are close together, the division which in all such cases exists for a time will become permanent, and if the growth should cease sooner, a larger interspace (a hole) will be the result (fig. 80, E). Further, if the interruption to the progress of ossification should occur at the point where the lateral parts of two sternal pieces would meet, the hole is likely to have considerable size, for it may then result from an “arrest of the development” proceeding from four centres,—each contributing a part.

The five pieces of the sternum constructed in the manner above detailed begin to join at the lower end of the bone. The fifth piece is joined to the fourth soon after puberty, the fourth and the third are united between twenty and twenty-five years of age, and the body of the sternum is usually not completed by the junction of the third piece to the second before thirty-five or forty years. Lastly, the first division does not in general join with the rest of the sternum at any period; but should its union happen to take place, it is only to be met with in old age.

To the centres of ossification here described M. Brechet\* has added two small epi-sternal granules, whose position is sufficiently shown in the indication of them given in figure E. \* \* They occur only at rather advanced periods of life; but they do not appear to be constant.

The *ensiform* appendage begins to ossify some years after birth,—the time in different cases varying, according to the observation of Béclard, between two years and fifteen or eighteen. The ossification proceeds from a single centre situated at the upper part, and from this it gradually extends downwards; but in most instances a portion remains cartilaginous even in very advanced age.

#### THE RIBS AND THEIR CARTILAGES.

The *ribs* (costæ†) extend from the dorsal portion of the vertebral column to the sternum, forming arches, which enclose the lateral parts of the thorax. They are usually twelve in number at each side, but cases occasionally occur in which the number is augmented by the addition of a cervical or a lumbar rib, to which reference has already been made in describing the vertebræ of those regions. The number may also be diminished to eleven. I have lately seen an instance in which this diminution was accompanied with the absence of a dorsal vertebra. The seven superior pairs, which are united by means of

\* “Recherches sur différentes Pièces du Squelette des Animaux Vertébrés,” &c. in “Annales des Sciences Naturelles,” 2<sup>e</sup> Série, t. 10 (Zoologie), p. 91.

† “As if they were *custodes* of those principal organs of the animal machine, the heart and lungs.”—Monro, “The Anatomy of the Human Bones,” p. 234.—Edinb. 1726.



cartilaginous prolongations to the sternum, are called *sternal* or *true ribs*; the remaining five, which are not prolonged to the sternum, being denominated *asternal* or *false ribs*.

The ribs do not arch uniformly from the vertebral column towards the sternum; the greater number consist of parts of two circles or arches of different diameters, the anterior being much the larger. Thus the rib, directed at first backwards from its connexion with the bodies of the vertebræ, reaches and is supported by the transverse process (which in the dorsal region is inclined backwards); after leaving the extremity of this process, it turns abruptly outwards, and finally is directed forward towards the sternum.

In their length, breadth, and direction, these bones present several varieties. From the first to the eighth their length successively increases, whilst from the ninth to the twelfth they gradually decrease, so that the last is very little longer than the first.

Their breadth, considered in the whole series, diminishes gradually from the first to the twelfth; but in each rib it is greatest towards its sternal extremity.

As to their direction in reference to the vertebral column, the first forms almost a right angle with it, and the succeeding ones gradually incline downwards, so that their anterior extremity is lower than the posterior. The body of all the ribs, except the first, is, as it were, twisted on itself, so that their two extremities cannot be made to rest at the same time on a plane surface.

These bones present two surfaces, two borders, and two extremities.

The external surface is convex and smooth. The internal is concave, and corresponds with the pleura.

The superior border, smooth and rounded, gives attachment to the intercostal muscles; the inferior is marked on its inner aspect by a groove (*sulcus costalis*), fig. 79,<sup>43</sup> which is for the lodgment of the intercostal vessels, and also gives attachment to the intercostal muscles [at its external and internal margin].

The posterior extremity,<sup>7</sup> somewhat rounded and thicker than the other parts of the rib, and hence denominated its *head*, (*capitulum costæ*), presents (except in the instances to be presently stated) two articular faces (separated by a slight ridge) which articulate with the corresponding small surfaces on the bodies of the dorsal vertebræ; the head is supported by a narrow round part,<sup>8</sup> or *neck*, terminated externally by a *tubercle*, (*tuberosity*, *tuberculum costæ*),<sup>9</sup> which is smooth in one part for its articulation with the transverse process of the lower of the two vertebræ to which the head is connected, and rough in the other for the insertion of the posterior costo-transverse ligament.

The anterior extremity is broad, flat, and hollowed at its tip into an oval pit, into which is implanted the costal cartilage.

Between the tuberosity and the most convex part of the body of each rib is a rough line, marking what is termed its *angle*. The distance of the angle from the tuberosity increases gradually from the second to the eleventh inclusive. In the last it is not perceptible: in the first it is not distinguishable from the tuberosity.



The first two and the last two ribs present some peculiarities deserving of notice.

The *first* rib<sup>6</sup> is shorter and broader than either of the succeeding ones; its direction is nearly horizontal; its body not being twisted, as is the case in other ribs, it lies evenly when placed on a plane surface. One surface looks upwards, and is marked by two very slight depressions (over which pass the subclavian vessels), and an intervening roughness, sometimes well marked, which indicates the attachment of the scalenus anticus muscle. The other surface looks downwards, towards the cavity of the thorax. The external border, convex and rounded, is surmounted by the tuberosity;<sup>9</sup> the internal is thin, and forms the margin of the superior aperture of the thorax. The anterior extremity is broad and thick; the *head*, which articulates with the first dorsal vertebra,<sup>4</sup> is small, presents an undivided articular surface, and is supported by a slender neck.

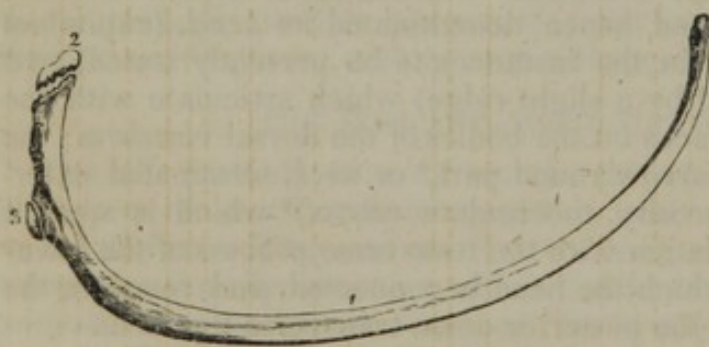
The *second* is longer than the first, and presents externally a prominent line for the attachment of the serratus magnus; its internal surface is somewhat grooved posteriorly.

The *eleventh* has no groove on its inferior border, nor a tubercle, as it is not articulated with the transverse process; its angle is scarcely perceptible, and the head has but one articulating surface. The cartilage by which its anterior extremity ends is unconnected with those of the other ribs.

The *twelfth* differs little from the preceding one, except in being shorter; it has neither angle, tubercle, nor groove, and as its anterior extremity, which is pointed, seems loose and unattached, it is called a floating rib. The same designation has likewise been applied to the eleventh rib.

*Ossification* begins in the ribs at a very early period—somewhat before it has made its appearance in the vertebræ, and the deposit of osseous matter extends rapidly over them. Each rib (with exceptions

Fig. 81.



One of the last true ribs. 1. The principal piece. 2. The epiphysis of the head. 3. The epiphysis for the tubercle. N. B. The epiphyses are represented of somewhat too large size.

to be presently noticed) is formed from one principal piece (fig. 81<sup>1</sup>) and two epiphyses.

The epiphyses are small and thin, and one of them, which in most ribs is slightly angular in shape, belongs to the head,<sup>2</sup> the other, to the tubercle.<sup>3</sup> Their growth commences between the sixteenth and the twentieth year of age, and they are united to the rest of the

bone a few years after,—about the twenty-fifth.

The last two or three ribs want the epiphysis of the tubercle.



## COSTAL CARTILAGES.

These cartilages, fig. 79,<sup>11</sup> [cartilagine costarum,] are twelve in number, like the ribs, of which they form the elastic continuation; their breadth diminishes gradually from the first to the last, whilst the length increases as far as to the seventh, after which it becomes less in each succeeding one. Their line of direction also varies considerably. The first descends a little, the second is horizontal, and all the rest ascend more and more as they are situated lower down. The external or costal extremity, convex and unequal, is implanted into the end of the corresponding rib. The internal extremities of the cartilages of the true ribs, smaller than the external, and somewhat pointed, are articulated with corresponding angular surfaces on the sides of the sternum; each of the cartilages of the first three false ribs, becoming slender towards its extremity, is attached to and blended with the lower border of that which is next above it; in the last two it is pointed and unattached.

The first cartilage usually becomes more or less ossified in adult age, and at this period it is often connected to the sternum by bone. After the middle of life, osseous matter is likewise deposited to a greater or less extent in the other cartilages; and it is more apparent at a later period in those of the false than of the true ribs.

These observations apply to the male body; for in the female the process of ossification does not affect the cartilages until old age has arrived, and it always affects a comparatively small number, if it should happen to extend beyond the first, which commonly is not the case.

*Attachments of muscles to the ribs and their cartilages.*—The two layers of intercostals to the contiguous borders of all the ribs; the scaleni to the first and second; the pectoralis major to the cartilages of the true ribs, except the first; pectoralis minor to the bodies of the third, fourth, and fifth; rectus abdominis to the cartilages of the last three true ribs and ensiform cartilage; obliquus externus to the last three true ribs, and all the false: the internal oblique and transversalis to the cartilages of the four or five false ribs; the diaphragm to the ensiform cartilage, and to those of the last six ribs.

The serratus magnus to the nine superior ribs; latissimus dorsi to the four inferior; serratus posticus superior to the third, fourth, and fifth true ribs; serratus posticus inferior to the last three; sacro-lumbalis to the angles of all the ribs; levatores costarum a little beyond their tuberosities.

## BONES OF THE SUPERIOR EXTREMITY.

The upper extremity consists of the shoulder, the arm, the fore-arm, and the hand. The shoulder consists of the scapula and clavicle: the arm of the humerus; the fore-arm of the radius and ulna; and the hand of the carpus, metacarpus, and fingers.

## SCAPULA.

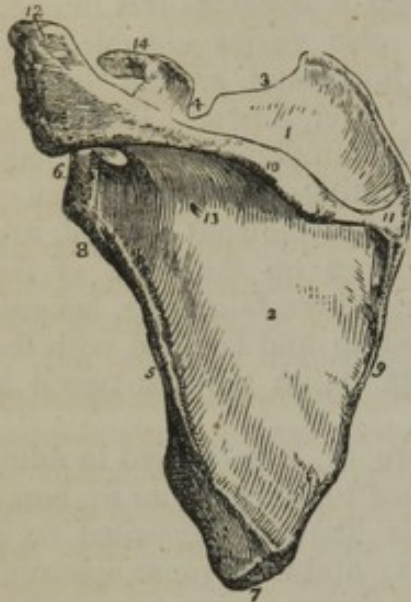
This bone, (fig. 82,) is placed upon the upper and back part of the



thorax, occupies the space from the second to the seventh rib, and forms the posterior part of the shoulder.

Its form is irregularly triangular and flat. It presents for examination two surfaces, three borders, and three angles.

[Fig. 82.]



A posterior view of the scapula. 1. The supra-spinous fossa. 2. The infra-spinous fossa. 3. The superior border. 4. The coracoid notch. 5. The anterior or axillary border. 6. The head of the scapula and glenoid cavity. 7. The inferior angle. 8. The neck of the scapula, the ridge opposite the number gives origin to the long head of the triceps. 9. The posterior border or base of the scapula. 10. The spine. 11. The triangular smooth surface, over which the tendon of the trapezius glides. 12. The acromion process. 13. One of the nutritious foramina. 14. The coracoid process. —W.]

The anterior surface, (*fossa subscapularis, venter*), looks towards the ribs, is triangular, slightly concave, intersected by prominent lines directed from within outwards and upwards, and therefore crossing the direction of the ribs.

The posterior surface (*dorsum scapulae*) is divided into two parts, but unequally, by a prominent ridge,<sup>10</sup> (the spine:) of these the superior one<sup>1</sup> is called fossa supra-spinata; the inferior,<sup>2</sup> fossa infra-spinata.

*Of the spine.*—The spine of the scapula is a prominent ridge of bone, flattened from above downwards, commencing at the posterior border of the scapula, with a smooth flat triangular surface,<sup>11</sup> from which it becomes gradually more elevated as it proceeds forwards, until it terminates in an elongated process,<sup>12</sup> (acromion,) which surmounts the shoulder-joint. The form of the spine, considered by itself apart from the acromion, is triangular; hence we have to notice its two surfaces, and three borders. Its superior surface is concave, and, conjointly with the superior part of the dorsum of the scapula, forms the fossa supra-spinata. The inferior surface is irregularly triangular, constitutes part of the infra-spinous fossa, and in its middle may be observed a small foramen,<sup>13</sup> for a nutritious vessel.

On the projecting border of the spine, which is rough and broad, may be noticed two margins, of which the superior one gives attachment to the trapezius, the inferior to the deltoid muscle: the intervening edge is subcutaneous. The anterior or attached border, or base, is united with the dorsum of the bone. The external border, which is short, round, and somewhat concave, approaches the neck of the bone, and is continuous with the under surface of the acromion.

*Of the acromion process.*—This considerable eminence<sup>12</sup> is flattened in the direction opposite to that of the spine, and, projecting outwards and forwards, forms the summit of the shoulder-joint; hence its designation (*ακρον*, a summit; *ωμος*, the shoulder). Its posterior and upper surface, convex and somewhat rough, is subcutaneous; the anterior and inferior one, concave and smooth, is in relation with the supra-spinatus muscle, and overlays the capsular ligament of the shoulder-



joint; the superior border presents, anteriorly, a narrow oval surface for its articulation with the external extremity of the clavicle, and its summit affords attachment to the coraco-acromial ligament.

The *fossa supra-spinata*,<sup>1</sup> wider towards its vertebral than the other extremity, is filled up by the supra-spinatus muscle. The *fossa infra-spinata*,<sup>2</sup> much larger than the preceding, is convex in the middle, somewhat concave, or rather grooved inferiorly. Between the latter part and the axillary border is a slightly raised and elongated ridge, which extends from the glenoid cavity obliquely downwards to within an inch of the posterior angle of the bone, where it subsides into a flat and nearly quadrilateral surface. This latter part it is that gives origin to the teres major muscle, and over it slides the latissimus dorsi. Along the upper and rounded part arise the fibres of the teres minor; whilst the line of division between them marks the attachment of an aponeurosis, common to these muscles and to the infra-spinatus, which occupies the remainder of the fossa.

Of the three *borders* of the scapula, or *costæ* (as they are sometimes called), the *superior* is the shortest; at its outer part is situated a lunated notch,<sup>4</sup> [coracoid notch,] (lunula; incisura semilunaris,) which is converted into a foramen by a ligament, and is traversed sometimes by the suprascapular vessels and nerve, but usually by the nerve alone. In front and external to this opening is the *coracoid* process,<sup>14</sup> which being thick, elongated, and curved on itself, is named, from some fancied resemblance to a crow's beak (*κροαῖς*, a crow; *εἶδος*, form). This process, superiorly convex and unequal, gives attachment to the coraco-clavicular ligament; anteriorly, to the pectoralis minor muscle; posteriorly, to the coraco-acromial ligament; and by its extremity to the short head of the biceps and coraco-brachialis muscles. The *posterior*, or vertebral border,<sup>9</sup> named also the "base" of the scapula, is the longest of the three; superiorly it approaches to the vertebral column, inferiorly it is more removed from it. The portion of this border which is above the spine will be observed to incline a little outwards. For the purpose of more easily assigning the attachments of the several muscles which are connected with it, we may regard it, though very thin, as divisible into two margins, with an interspace; these are stated in the enumeration of the muscular attachments. The *axillary* border is inclined downwards and backwards from the lower margin of the glenoid cavity to the inferior angle of the bone; hence it is named the *inferior costa* of the scapula. It is of considerable thickness, being surmounted posteriorly by the ridge above noticed as giving origin to the teres minor. The edge itself presents a shallow groove running along the greater part of its extent. It corresponds with the lower border of the subscapular muscle. For about an inch beneath the glenoid fossa there is a well-marked linear impression, which gives origin to the long head of the triceps muscle.

The *postero-superior angle* is formed by the junction of the base with the superior costa of the scapula; it is somewhat inclined outwards. The *inferior angle* is placed at the union of the base with the axillary or inferior border of the bone; upon it may be observed an



elongated flat surface which gives origin to the *teres major*, and over which slides the *latissimus dorsi* muscle. At the convergence of the superior and inferior borders may be observed a narrow constricted part<sup>s</sup> denominated the neck.

The *neck* (*cervix scapulæ*) separates the glenoid fossa and the coracoid process from the rest of the bone. It is bounded below by a slightly raised rim which gives attachment to the fibrous capsule of the shoulder-joint; and finally the rim surrounds the articular surface of the bone which is called the *glenoid cavity*<sup>6</sup> (*γληνη*, a superficial cavity; *εἶδος*). This is a shallow, oval depression, broader below than above, covered with cartilage in the fresh state, and deepened somewhat by a fibro-cartilaginous border, which passes round it from the long tendon of the *biceps* muscle, whose origin is at its upper margin; its longest diameter is perpendicular, its direction outwards and forwards. In this last respect, however, it varies considerably; for during the more extended motions of the humerus, the scapula is made to turn, as it were, on a pivot driven through the centre of its dorsum, by which means the glenoid cavity is kept constantly in apposition with the head of the humerus, which is the chief security against its dislocation.

The scapula *articulates* by its glenoid cavity with the humerus, and by the acromion process with the clavicle.

It affords *attachment to the following muscles*:—The subscapular fossa (the anterior or costal surface of the bone) to the subscapularis muscle. Posterior or dorsal surface,—the spine (by its border and the acromion) superiorly to the trapezius, inferiorly to the deltoid: the fossa supra-spinata, by its posterior two-thirds, to the muscle of the same name; the fossa infra-spinata, in the greater part of its extent, to the infra-spinatus; by a slight oblique line situated near the inferior angle, to the aponeurosis common to the infra-spinatus, *teres minor*, and *teres major*; by a narrow rounded surface, near the axillary border, to the *teres minor*; by the flat surface, at its inferior angle, to the *teres major*.

The superior border, near the margin of its notch, to the *omo-hyoides*; the coracoid process, anteriorly, to the *pectoralis minor*, by its summit to the *biceps* and *coraco-brachialis*. The posterior border or base, anteriorly, to the *serratus magnus*; posteriorly, to the *supra-spinatus* and *infra-spinatus*; in the interspace to the *rhomboidei* and to the *levator anguli scapulæ*. The inferior, or axillary border, at its upper part by a rough ridge to the long portion of the *triceps extensor*; posteriorly, by an unequal surface, to some fibres of the *teres minor*; inferiorly, to the *teres major*.

The inferior angle to the *teres major*, and occasionally to some fibres of the *latissimus dorsi*; the anterior angle (glenoid cavity), by its upper margin, to the long head of the *biceps* muscle.

The scapula has several centres of *ossification*, and the greater part of the bone, as in most other cases, is formed from one of them. This nucleus appears at the time that osseous matter is first deposited in the *vertebræ*, and from it the ossification spreads in different directions, to the spine, the glenoid cavity, and in short over all the bone,

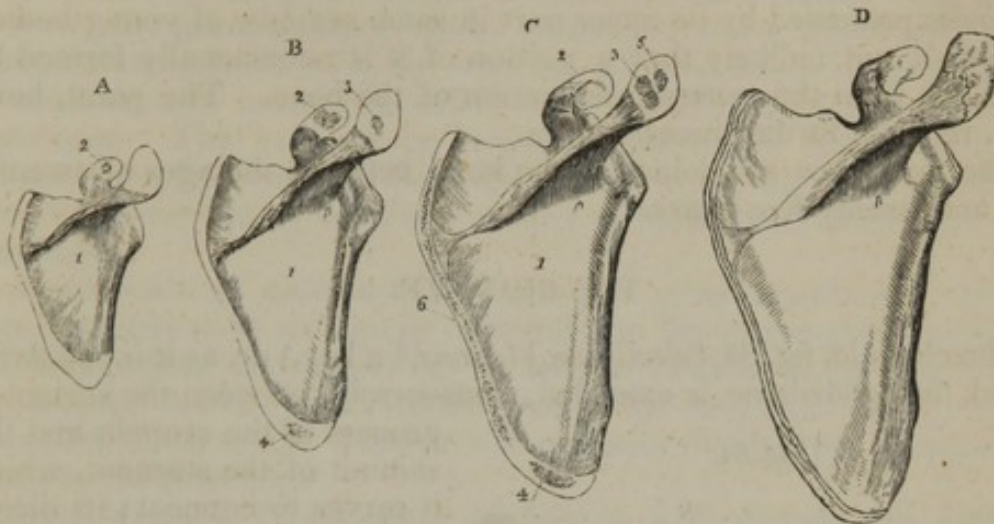


except the coracoid process, the acromion, the lower angle, and the base, each of which is a distinct formation.

At birth the parts last named are cartilaginous.

An osseous granule appears in the middle of the coracoid process (fig. 83, A<sup>2</sup>), usually in the course of the first year after birth, and this

Fig. 83.



The scapula is here represented at various periods of its growth. The figure marked A, shows the condition of the bone at about the end of the first or beginning of the second year of age; ossification is largely extended from the primary centre, and a nucleus has appeared in the coracoid process. B. From a boy aged about fifteen or sixteen years; the coracoid process is partly joined at its base, and nuclei have appeared in the acromion and in the lower angle. C, shows the condition of the bone at seventeen or eighteen years of age. A second point has formed in the acromion, and the ossification of the base is advanced. D. The scapula of a man about twenty-two years of age. The epiphyses of the acromion and the base are still separable. A thin epiphysis, which exists on the coracoid process of the preparation represented in the sketch has been accidentally omitted. N. B. One of those figures (C) is to be regarded as altogether an illustrative plan. I do not possess a preparation showing this stage of the growth of the bone.

part being largely ossified, is joined, or about to join, the rest of the scapula when the remaining pieces begin to form.

The additional centres of ossification succeed one another rapidly, between the fifteenth and seventeenth years, generally showing themselves in the following order:—1. in the acromion near the base; —and in the upper part of the coracoid process; 2. the lower angle; 3. again in the acromion; 4. the base. The several pieces constructed from these nuclei may be regarded as epiphyses. Each of them requires some remark.

The base of the acromion is an extension from the primary centre of ossification through the spine, and the extent to which the ossification from this source reaches varies in different cases (fig. 83). The remainder of the process is produced from two or more irregular nuclei (c<sup>3 5</sup>), which unite one to the other, and form a single piece to be subsequently joined to the spine, or rather to the projection from this (fig. 83, D).

On the convex part of the coracoid process where it turns forward,



a thin scale (an epiphysis) forms after the process has been joined to the general mass of the scapula. I have observed this epiphysis to be in general broad at the upper part, and to taper downwards to the notch on the upper margin of the scapula.

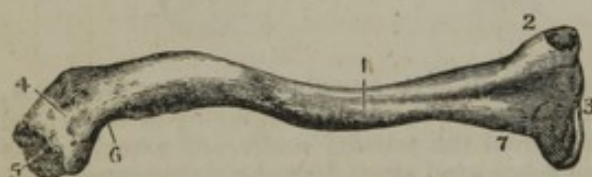The lower angle and the contiguous part of the base are always ossified separately (B, C, D,<sup>4</sup>). The remainder of the base is also to be considered a distinct growth (C, D,<sup>4</sup>); but from the appearance of completeness presented by its upper part in some scapulæ of young bodies, I think it not unlikely that a portion of it is occasionally formed by extension from the general ossification of the bone. The point, however, requires further investigation.

The epiphyses are joined to the bone between the ages of twenty-two and twenty-five years.

### THE CLAVICLE.

The clavicle, fig. 84, [clavicula,] (*clavis*,\* a key,) or, as it is popularly called, the collar-bone, is extended, transversely, between the acromion

[Fig. 84.



Anterior view of right clavicle. 1. Anterior face of the body. 2. Sternal extremity. 3. Articular surface. 4. Scapular extremity. 5. Articular surface. 6. Attachment of coraco-clavicular ligament. 7. Attachment of costo-clavicular ligament.—Smith and Horner.]

process of the scapula and the summit of the sternum, which it serves to connect; its direction, however, is not exactly horizontal, the acromial end being slightly elevated. This bone is curved somewhat like an italic *f*, the degree of the curvature being less in young and female subjects than in male adults; it is rather thick and somewhat triangular towards its sternal end, but broad

and flat towards the scapular extremity; it presents for our consideration a body and two extremities.

The superior surface of the *body* is principally subcutaneous. The inferior surface presents, near the sternal extremity, inequalities for the attachment of the costo-clavicular ligament; in the centre, a longitudinal depression, giving attachment to the subclavius muscle, the foramen for the entrance of the medullary vessels, and, more externally, a rough oblique line, to which the coraco-clavicular ligament is attached; this surface corresponds internally to the first rib, externally to the coracoid process and the shoulder-joint, and in the middle to the

\* Various reasons have been assigned for the name by which this bone is distinguished. It has been said to be taken from the likeness to a peculiar form of key. By most writers the name is considered to have been derived from uses attributed to the bone: such as that, key-like, it closes the chest; or that, as "a stay," it connects the scapula to the trunk. Thus, Riolanus—who is cited because of his character for extensive erudition—says (Comment. de Ossibus, cap. 21), "*Clavis siue clavicula dicitur quod Thoracem claudat. . . . Nam ex Aristotele Clavis, os claudens thoracem et instrumentum quo aliquid clauditur significat. . . . Vel quia clavis modo firmet et stabiliat cum sterno omoplatam. In architectura claves appellantur ligna aliis firmitudinem præstantia.*"



axillary vessels and brachial plexus of nerves. The anterior border is broad and convex towards the sternal, thin and concave towards the scapular extremity; the posterior border presents, of course, the opposite arrangement of curvatures.

The *internal* or *sternal* extremity,<sup>2</sup> is inclined downwards and forwards; it is considerably thicker than the other parts of the bone, and terminates in a triangular unequal surface, which is convex from above downwards, concave from behind forwards; this is tipped with cartilage, and articulates with the sternum, the articular surface of which it much exceeds in size; its entire circumference gives attachment to ligaments. The *external* or *scapular* extremity,<sup>4</sup> compressed and flattened, inclines a little backwards and upwards, and articulates with the acromion by a narrow oblong surface which is covered with cartilage.

*Attachments of muscles.*—The clavicle gives attachment, by the superior surface of its sternal extremity, to the sterno-cleido-mastoid; the longitudinal depression on its inferior surface, to the subclavius; the anterior border, by its sternal half, to the pectoralis major; by its acromial third, to the deltoid; the posterior border, by its acromial third, to the trapezius.

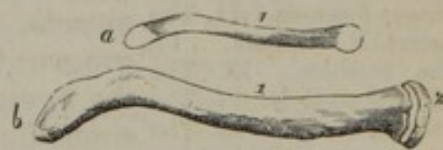*Articulations.*—The clavicle articulates with the sternum and the acromion process of the scapula.

*Peculiarities in the sexes and in individuals.*—The clavicle of the female is more slender and less curved than that of the male. But occasional instances occur which do not conform to this general statement—which are even directly opposed to it. These exceptional cases are in a great measure, if not altogether, referable to circumstances to be noticed in the following paragraph. It is also less bent in young persons than in adults.

The curves of the bone are greatest in persons employed in laborious occupations, and its ends become enlarged under the influence of the same circumstances. It has likewise been found that, from the same cause, a difference may exist between the clavicles of the same person—insomuch that M. Cruveilhier states, he was enabled to predicate correctly of a person that he was left-handed, founding his judgment solely on the relative size of the sternal ends of the clavicles.

*Ossification.*—The clavicle begins to ossify before any other bone. It is formed from one principal piece and a thin epiphysis, which belongs to the inner or sternal end of the bone. The epiphysis begins to form between the eighteenth and twentieth year, and it unites to the rest of the bone a few years after.

Fig. 85.



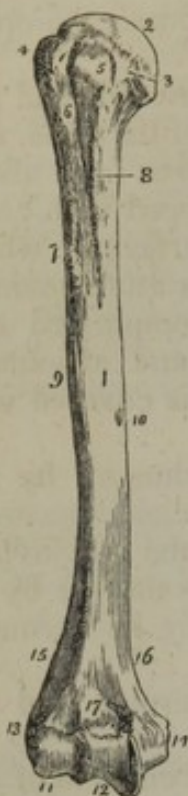
*a.* The clavicle of a fœtus. *b.* This figure is taken from the clavicle of a man who had attained to about twenty-three years of age. N.B. The epiphysis is represented of somewhat greater size (thicker) than it is in nature.

## THE HUMERUS.

The humerus or arm-bone, fig. 86, (os humeri,) the largest bone of



[Fig. 86.]



The humerus of the right side; its anterior surface.

1. The shaft of the bone.
2. The head.
3. The anatomical neck.
4. The greater tuberosity.
5. The lesser tuberosity.
6. The bicipital groove.
7. The anterior bicipital ridge.
8. The posterior bicipital ridge.
9. The rough surface into which the deltoid is inserted.
10. The nutritious foramen.
11. The eminentia capitata.
12. The trochlea.
13. The external condyle.
14. The internal condyle.
15. The external condyloid ridge.
16. The internal condyloid ridge.
17. The fossa for the coronoid process of the ulna.—W.]

the upper extremity, extends from the scapula to the bones of the fore-arm, with each of which it is articulated. Its direction is vertical, with an inclination inwards towards the lower end. Long and irregularly cylindrical in form, the humerus is divisible into a body and two extremities.

The *body* or *shaft* of the bone,<sup>1</sup> thick and rounded superiorly, is somewhat expanded, and triangular inferiorly. It is divided into two nearly equal surfaces by two longitudinal lines, of which one is external and anterior,<sup>15</sup> the other internal and posterior.<sup>16</sup> These lines or ridges may be considered as rising, the former from the external, the latter from the internal condyle, near to which they are well marked, but gradually subside as they proceed upwards on the body of the bone: they afford attachment to the inter-muscular aponeuroses. The external one is interrupted about the middle by an oblique depression, or groove, which runs from above downwards, and marks the course of the musculo-spiral nerve and superior profunda artery; the surfaces separated by these lines are named posterior and anterior.

The *posterior* surface is round superiorly, and inclined a little inwards; in the lower part it is broad, flat, and turned rather outwards; it is covered in the entire of its extent by the triceps extensor muscle, and towards its middle may be observed a small foramen for the medullary vessels. The *anterior* surface is divided superiorly into two unequal portions by a longitudinal groove,<sup>6</sup> directed obliquely downwards and inwards, for about one-fourth of the length of the bone; this lodges the long tendon of the biceps muscle, and is therefore named the *bicipital* groove; its anterior margin,<sup>7</sup> gives attachment to the pectoralis major; the posterior,<sup>8</sup> to the latissimus dorsi and teres major. The portion of the anterior surface which is internal to this groove is smooth in the greater part of its extent, and presents, towards its middle, a linear elevation for the insertion of the coraco-brachialis, and lower

down an oblique medullary foramen;<sup>10</sup> externally to the groove, and a little above the middle of the bone, may be observed a broad, rough eminence,<sup>9</sup> for the insertion of the deltoid muscle, beneath which runs the oblique depression already noticed as corresponding to the course of the musculo-spiral nerve and the accompanying artery.

The *superior extremity* of the bone presents a large hemispherical eminence,<sup>2</sup> covered with cartilage in the fresh state, and directed back-



wards and inwards to the glenoid cavity of the scapula, with which it articulates; this is called the *head* of the humerus. It is bounded by a slightly depressed groove, sufficiently marked on the upper, not on the under aspect, denominated the *neck* of the bone. The axis of this part does not coincide with that of the rest of the bone.—Supposing the humerus in its natural position with respect to the scapula, if the axis of its shaft be vertical, that of the head and neck of the bone is directed backwards and upwards. A little beneath, and to the outside of the head, are two eminences, which project from the end of the shaft of the bone, and, from their relative size, are named the greater and lesser tuberosities (tubercula). The *greater tuberosity*,<sup>4</sup> is external and posterior in its situation, convex in its outline, and marked on its upper border by three flat surfaces for the insertion of the external rotator muscles. The *smaller tuberosity*,<sup>5</sup> rounded and more prominent than the other, gives attachment to the subscapularis muscle. They are separated by the bicipital groove.

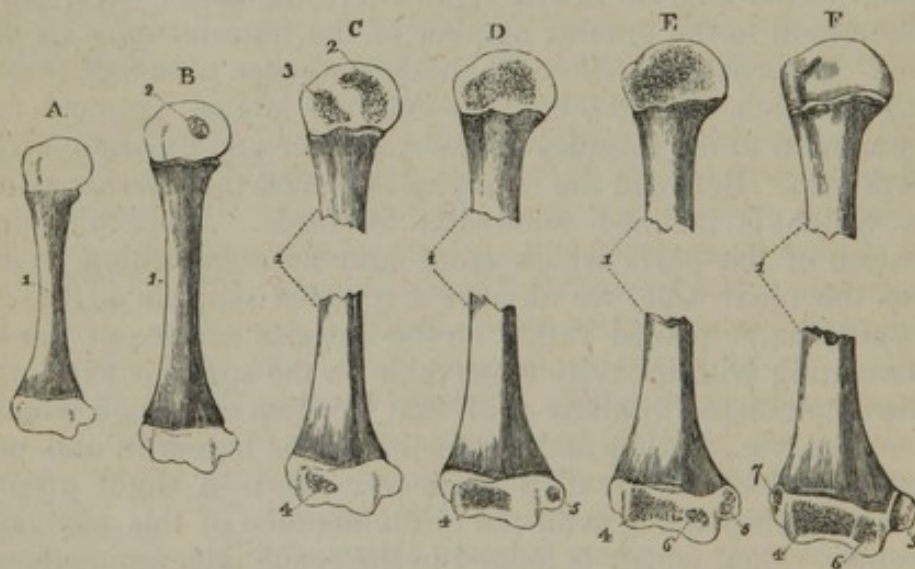
*The lower extremity.*—Towards its lower third the bone widens, and appears compressed and somewhat twisted from behind forward; its longest diameter is transverse; it presents internally a considerable projection,<sup>14</sup> the *inner condyle*, which is inclined backwards, and gives attachment to the internal lateral ligament of the elbow-joint, and to a tendon common to the greater number of the anterior muscles of the fore-arm. Externally is situated another smaller process<sup>13</sup> (*external condyle*,) to which are attached the external lateral ligament and a tendon common to the muscles of the posterior and external surfaces of the fore-arm. Between the condyles is placed the inferior articular surface, which is inclined somewhat forwards. Proceeding in the enumeration of the parts which enter into its composition from the radial to the ulnar side, we observe a rounded eminence, (the *small head, capitellum*,)<sup>11</sup> placed rather on the anterior surface of the bone, and articulating with a cavity observable on the superior extremity of the radius, calculated to allow of all that freedom of motion which the radius enjoys, viz., flexion and extension on the humerus, and pronation and supination by rotation on its own axis;—a slight groove or depression corresponding with the circumference of this eminence, a semicircular ridge, which is lodged in the space intervening between the radius and ulna;—a wide and deep groove which receives the prominent part of the larger sigmoid cavity of the ulna; and, lastly, a prominent ridge, which is received into the internal part of the same cavity. This prominence descends much lower than the external portion of the articular surface, and determines an obliquity in the direction of the humerus, when its lower extremity is made to rest on a plain surface. The groove, with its margins, forms a well-marked pulley-like surface,<sup>12</sup> on which the sigmoid cavity of the ulna moves in flexion and extension; hence it is termed the *trochlea*. At the fore part of the inferior extremity of the bone, and immediately above the trochlea, is a superficial depression,<sup>17</sup> which receives the coronoid process of the ulna during flexion, and posteriorly a more considerable fossa, which lodges the olecranon during the extension of the fore-arm.



A modification of the nomenclature applied to these different eminences has been proposed by Chaussier: retaining the term *trochlea* for the surface of articulation with the ulna, he calls that which articulates with the radius, the *condyle*, and for the two lateral eminences of insertion, now named *condyles*, he substitutes the terms *epi-trochlea* and *epi-condyle*.

*Attachments of muscles.*—The posterior surface gives attachment to the triceps; the anterior (by the posterior margin of the bicipital groove) to the *teres major* and *latissimus dorsi*; in the middle, by a slightly-marked line, to the *coraco-brachialis*; inferiorly, to the *brachialis anticus*;—the external portion of the same surface, superiorly, by a rough eminence, to the *deltoid*; by the anterior margin of the bicipital groove, to the *pectoralis major*. The greater tuberosity gives attachment, by the three flat surfaces on its upper border, to the *supraspinatus*, *infra-spinatus*, and *teres minor* muscles; the lesser tuberosity to the *subscapularis*. The inferior extremity, by its outer border, to the *supinator radii longus* and *extensor carpi radialis longior*; by its external condyle, to the *extensor carpi radialis brevior*, *extensor com-*

Fig. 87.



Several stages in the ossification of the humerus are shown in these figures. That marked A, is the representation of the bone of a full-grown fœtus. B. The condition of the bone at about two years of age. C. The bone in the third year. D. At the beginning of the fifth year. E. The state of the bone about the twelfth year. F. This bone is from a person about the age of puberty.—1. The primary piece. 2. Nucleus for the head. 3. That for the tuberosities. 4. For the outer side of the lower articulating surface. 5. For the inner condyle. 6. The inner part of the lower articulating surface. 7. The external condyle.

N. B. The separated centres of the upper extremity of the bone in figure C, have not been drawn from a preparation.

Some of the bones are represented in two parts, in order to make up in some degree for the absence of the proper proportion in their dimensions.

*munis digitorum*, *extensor carpi ulnaris*, *anconeus* and *supinator radii brevis*; by the internal condyle, to a tendon common to the *pronator*



radii teres, flexor carpi radialis, palmaris longus, flexor carpi ulnaris, and flexor digitorum sublimis.

*Articulations.*—The humerus articulates with the glenoid cavity of the scapula, and with the ulna and radius.

*Ossification.*—The humerus begins to ossify soon after the clavicle, and some time before the vertebræ. From a small cylindrical piece, appearing at the middle, the formation of bone extends towards the extremities, involving the entire shaft.

At the end of fœtal life the shaft of the humerus is ossified nearly in its whole length, and its ends are altogether cartilaginous, (fig. 87, A.)

There is a trace of bony deposit in the head of the bone towards the close of the first year after birth, and in the course of the second year a distinct nucleus has formed in this part (B<sup>2</sup>). Between the second and third years a separate centre is developed for the tuberosities (C<sup>3</sup>). (Béclard mentions two—one for each tuberosity,—the second being very small and appearing after the fourth year.) The osseous nuclei of the head and tuberosities enlarge, join, and form a large epiphysis before the fifth year (fig. 87, D).

The growth of the lower end of the bone is more complicated. It begins, after the expiration of the second year, in the outer part of the articular surface—the small head (C<sup>4</sup>), and from this point the ossification extends inwards and forms much the larger part of the articulating end of the bone (D, E, F<sup>4</sup>).

Before the fifth year an ossific point is deposited in the internal condyle (D<sup>5</sup>).<sup>\*</sup> About twelve years one is apparent in the inner side of the articulating surface; and at thirteen or fourteen years the ossification of the external condyle is begun by a distinct centre (E, F<sup>6 7</sup>).

Soon after the last-mentioned period, or about sixteen or seventeen years, the external condyle and the two parts of the articulating surface (being previously joined) unite with the shaft of the bone. The junction of the internal condyle follows at about the eighteenth year. And thus all the parts of the lower end of the bone have united with the shaft, while the epiphysis of the upper end, whose formation began first, is still separate. Lastly, this too is no longer separable, and the bone is complete about the twentieth year.

#### THE RADIUS.

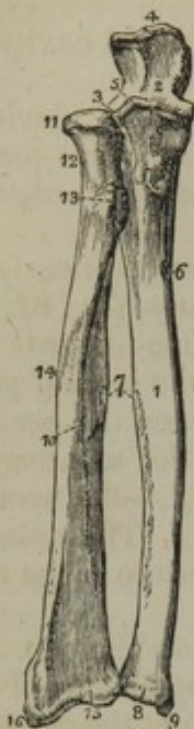The radius, shorter than the ulna by the length of the olecranon process, is placed at the external side of the fore-arm, extending from the humerus to the carpus. It is broader below than above, slightly curved in its form, and divided into a body and two extremities.

As the *body*, or *shaft*, fig. 88,<sup>10</sup> is somewhat triangular, we observe

<sup>\*</sup> As the date mentioned for the appearance of this centre of ossification is much earlier than that assigned by writers who treat of this department of anatomy, it may be well to state, that in one preparation in my collection, which was taken from a boy ascertained to have been a little over six years of age at the time of his death, the ossification of the inner condyle is well advanced;—and that in another—the arm of a female child which I amputated in consequence of an accident on the day after it had attained the fifth year—a small osseous granule is distinctly formed in the same part.



[Fig. 88.]



The two bones of the fore-arm seen from the front. 1. The shaft of the ulna. 2. The greater sigmoid notch. 3. The lesser sigmoid notch, with which the head of the radius is articulated. 4. The olecranon process. 5. The coronoid process. 6. The nutritious foramen. 7. The sharp ridges upon the two bones to which the interosseous membrane is attached. 8. The capitulum ulnæ. 9. The styloid process. 10. The shaft of the radius. 11. Its head surrounded by the smooth border for articulation with the orbicular ligament. 12. The neck of the radius. 13. Its tuberosity. 14. The oblique line. 15. The lower extremity of the bone. 16. Its styloid process.—W.]

on it three surfaces, bounded by three margins, or ridges. The *anterior surface* expands towards the lower part, and is marked along its middle by a longitudinal groove for the flexor pollicis longus; superiorly is situated the foramen for the medullary vessels, its direction being from below upwards; and inferiorly a flat surface, corresponding with the pronator quadratus. The *posterior surface*, convex in the greater part of its extent, is grooved at its central third, for the origin of the extensors of the thumb; the *external surface*, round and convex, is marked towards its middle by a rough impression,<sup>14</sup> which gives insertion to the pronator radii teres. Of the *margins* separating these surfaces, the posterior is distinct only at the middle part; the external is round, and becomes smooth towards the lower extremity; whilst the internal is acute and sharp, for the attachment of the interosseous ligament. The body is terminated superiorly by a rough prominence<sup>13</sup> (tuber radii,) termed the *bicipital tuberosity*, from its giving insertion to the biceps muscle.

Above the tuberosity the bone becomes narrowed and constricted into the form of a *neck*,<sup>12</sup> which is again surmounted by the *head*,<sup>11</sup> intended by its extremity to articulate with the round convex part of the lower extremity of the humerus, its small head, while its margin rolls on the lesser sigmoid cavity of the ulna. The margin is smooth and convex; the upper surface, also smooth, is a shallow cup-like cavity; and both are covered with cartilage in the recent state.

The radius at its lower part becomes broad and thick; the anterior surface is flat and expanded, being covered by the pronator quadratus muscle; it is bounded below by a prominent line, which gives attachment to the anterior ligament of the wrist-joint. The posterior surface is convex, and marked by longitudinal grooves, which transmit the tendons of the extensor muscles; of these, one, which is very narrow and oblique in its direction, and nearly in the middle line, lodges the tendon of the extensor pollicis (secundi internodii). At the inner or ulnar side of this is placed another, much broader, which transmits the tendons of the extensor communis and indicator; and at its outer side a third, divided into two parts by a linear impres-

sion, marks the passage of the flexor carpi radialis, longior and brevior. Corresponding with the external border of the bone is another groove, directed obliquely forwards, and divided into two parts, for the tendons of the extensores—primi internodii and ossis metacarpi pollicis. The outer side of the bone, particularly the part correspond-



ing with the ridge which separates the two latter grooves, is prolonged downwards, and named the *styloid process*;<sup>16</sup> it affords attachment to the external lateral ligament of the wrist-joint. On the inner side of the bone is situated a small cavity, (semilunar,) covered by cartilage, which articulates with the inferior extremity of the ulna. At its inferior extremity the radius presents its carpal articulating surface, scaphoid (navicular), which is included between the base of the styloid process and the oval cavity just mentioned, bounded before and behind by two rough margins for the attachment of the radio-carpal ligaments. It is divided from before backwards, by a line, into two unequal portions, of which the external is triangular, and articulates with the scaphoid bone; the internal is square, and articulates with the semilunar.

*Attachments of muscles.*—The anterior surface of the body, by its grooved part, to the flexor longus pollicis; by the oblique line, leading from the tuberosity to the insertion of the pronator radii teres, to the supinator brevis and flexor sublimis; its inferior fifth to the pronator quadratus; the posterior surface, by a slight concavity in the middle, to the extensores pollicis; the external margin, by a rough surface, to the pronator teres; inferiorly, to the pronator quadratus and the supinator radii longus; whilst the posterior part of the bicipital tuberosity gives attachment to the biceps muscle.

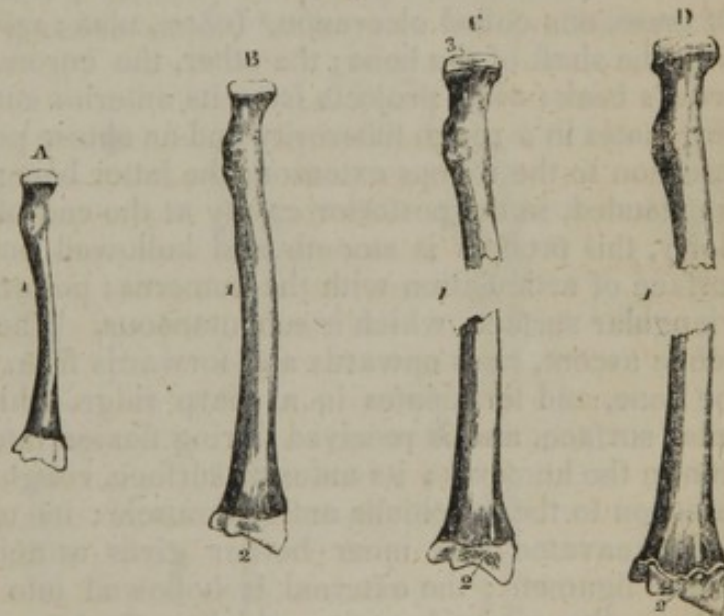
*Articulations.*—The radius articulates with the humerus, the ulna, the scaphoid and semilunar bones.

*Ossification.*—The radius is formed from three points of ossification. In the shaft osseous matter begins to form at its middle immediately after the process has commenced in the humerus, and before the vertebræ. The ossification from this centre extends nearer to the upper than to the lower end of the bone.

At the ordinary time of birth the radius is ossified except the ends, which are both cartilaginous.

A nucleus is deposited in the lower end in the course of the end of the second year, and in the upper one before the fifth year.\* The epiphysis formed from the latter is flat and very thin. It joins the

Fig. 89.



A. The radius of a full-grown fœtus. B. That bone at about two years of age. C. At five years. D. About eighteen years. 1. The primary piece. 2. The ossific point or epiphysis of the lower end. 3. That of the upper end.

\* This statement differs widely from those of Meckel and Béclard. The former mentions seven years, and the latter eight or nine, as the time at which the upper epiphysis begins to ossify. The period stated in the text has been fixed on after repeated observation.



bone about the age of puberty. The lower epiphysis, of greater size, is united about the twentieth year.

#### THE ULNA.

The ulna, fig. 88, (*ωλενη*, cubitus,) is placed at the inner side of the fore-arm; it is a long and rather irregular bone, larger at the upper than at the lower extremity,—a conformation the reverse of that which obtains in the radius.

Its *body* or *shaft*, fig. 88,<sup>1</sup> is marked off into three surfaces by three prominent lines. These are all broader above than below, in consequence of the increasing size of the bone. The *anterior surface*, slightly depressed, is grooved longitudinally for the origin of the flexor profundus, and marked at its upper third by a foramen,<sup>6</sup> directed obliquely upwards for the medullary vessels. The *internal surface*, smooth and somewhat excavated superiorly, is covered in the greater part of its extent by the flexor profundus muscle; it becomes round inferiorly, where it is subcutaneous. The *external surface*, rough and irregular, is divided into two parts, of which one, of small extent, corresponds with the superior extremity of the bone, and forms an elongated depression for the anconeus muscle; the other, reaching to the lower extremity, gives origin to the extensors of the thumb and the supinator radii brevis. Of the three *margins*, the internal and posterior are round, and for the most part, smooth; the external is sharp, and gives attachment to the interosseous ligament.

At the *superior extremity* of the bone are situated two eminences, so placed as to bound the cavity by which it articulates with the humerus. Of these, one called olecranon,<sup>4</sup> (*ωλενη*, ulna; *κρᾶνον*,) is nearly on a line with the shaft of the bone; the other, the coronoid process,<sup>5</sup> (*κορωννη*, a crow's beak; *ειδος*,) projects from its anterior surface. The *olecranon* terminates in a rough tuberosity and an obtuse point; the former giving insertion to the triceps extensor; the latter being lodged, when the arm is extended, in the posterior cavity at the end of the humerus. Anteriorly, this process is smooth and hollowed out, to form part of the surface of articulation with the humerus; posteriorly, it presents a flat triangular surface, which is subcutaneous. The *coronoid process*, by a gentle ascent, rises upwards and forwards from the anterior surface of the bone, and terminates in a sharp ridge, which overhangs the articular surface, and is received during flexion into the anterior depression in the humerus; its anterior surface, rough and triangular, gives insertion to the brachialis anticus muscle; its upper aspect is smooth and excavated: its inner border gives attachment to the internal lateral ligament; the external is hollowed into a smooth depression, the *smaller sigmoid cavity*, which articulates with the head of the radius. The *great sigmoid cavity*,<sup>3</sup> formed by the junction of the smooth surfaces of these two processes, has been so named from some supposed resemblance to the form of the Greek letter Σ (*σιγμα*, *ειδος*, form), as it was originally written. Covered by cartilage in its entire extent, it is divided into two parts (but unequally, the inner one being the larger,) by a smooth ridge running downwards from the peak or point of the olecranon to that of the coronoid process. This ridge and the concavities beside it correspond, the one with the groove, the others



with the lateral parts of the trochlea. At the margins of the sigmoid cavity may be observed two notches which mark off the parts of the surface which belong to the olecranon and the coronoid process respectively.

At the *inferior extremity* of the bone, which is small and rounded, are situated two eminences, of which the external one, named the *head* of the ulna,<sup>8</sup> round and covered with cartilage, presents two aspects, of which one, nearly circular in its form, looks towards the wrist-joint, and corresponds with the triangular fibro-cartilage of that articulation; whilst the external one, narrow and convex, is received into the semi-lunar cavity in the contiguous border of the radius. The internal eminence,<sup>9</sup> named the *styloid process*, projects on a line with the posterior and inner surface of the bone; it is elongated in its form, and gives attachment to the internal lateral ligament of the joint. The head and the styloid process are separated posteriorly by a groove, which is traversed by the tendon of the extensor carpi ulnaris, and inferiorly by a depression at the base of the styloid process, into which the triangular fibro-cartilage is inserted.

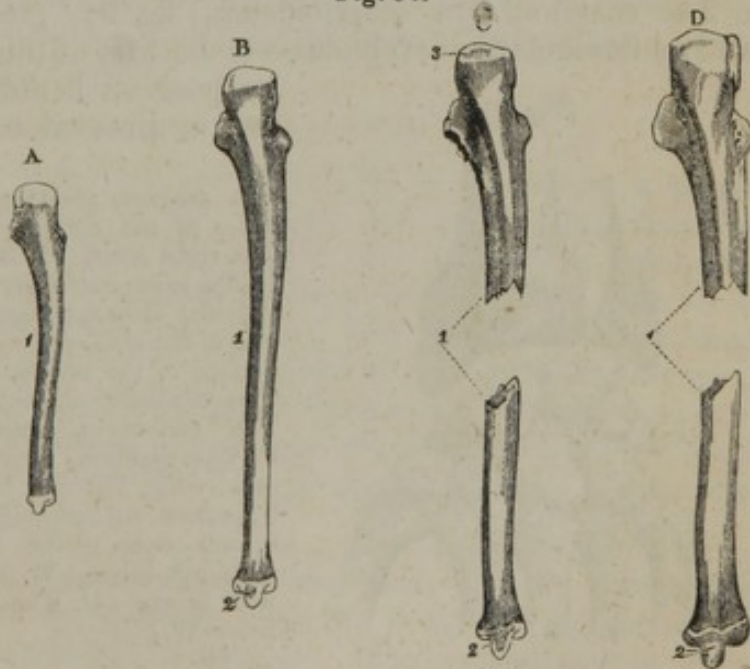
*Attachments of muscles.*—The anterior surface, superiorly, and in the middle, gives attachment to the flexor digitorum profundus; inferiorly, to the pronator quadratus; the posterior surface, to the anconeus, the extensor carpi ulnaris, supinator radii brevis, the extensores pollicis, and the extensor indicis; by the posterior longitudinal line, to an aponeurosis common to the flexor carpi ulnaris, flexor digitorum profundus, and extensor carpi ulnaris. The superior extremity, by the summit of the olecranon to the triceps brachialis; the coronoid process, by its anterior rough surface, to the brachialis anti-

*Articulations.*—The ulna articulates with the humerus and the radius; it has no point of contact with the carpal bones, but it is brought into relation with the cuneiform bone by means of the inter-articular fibro-cartilage.

*Ossification.*—The ulna begins to ossify both in the shaft and the epiphyses a short time after the radius.

The ends are cartilaginous at birth. In the fourth year (sometimes later) a

Fig. 90.



A. The ulna of a fœtus born at the usual period. B. The bone of a child at the end of the fourth year. C. From a boy arrived at about twelve years of age. D. The bone of a male person at nineteen or twenty years of age.

1. The primary piece. 2. The nucleus for the lower end, or epiphysis. 3. The epiphysis of the upper end.



granule of bone forms in the lower end. It appears in the middle of the head, and afterwards extends to the styloid process. The upper epiphysis is very small, the greater part of the olecranon being formed from the original centre of ossification. Ossific matter is perceptible in this part at the tenth year or soon after.

The epiphyses join:—the superior about the sixteenth year of age, and the inferior one about the twentieth year.

## THE HAND.

The hand is composed of the carpus, metacarpus, and fingers.

### CARPUS.

The first or superior part of the hand is named the carpus or wrist, fig. 91; it is placed between the fore-arm and the metacarpus, and composed of eight small bones, which are disposed in two ranges, each consisting of an equal number. Proceeding in the enumeration from the radial to the ulnar side, the bones which constitute the first or superior range are thus named from their shape—scaphoid, semilunar, cuneiform, and pisiform; those of the second or inferior range are the trapezium, trapezoid, os magnum, and unciform.

The dorsal surface of the carpus is convex, the palmar concave and irregular, and marked by four bony prominences, across which is stretched the anterior annular ligament, so as to form a canal for the transmission of the flexor tendons.

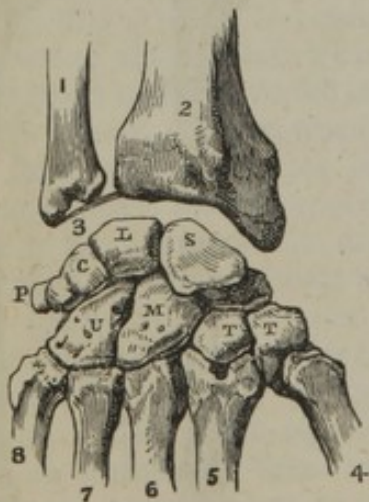
### BONES OF THE FIRST ROW OF THE CARPUS.

#### THE SCAPHOID BONE.

The scaphoid, [os scaphoideum,] fig. 91,<sup>s</sup> (σκαφη, a boat,)—named also os naviculare: cotyloides—is the first of this row and the largest.

[Fig. 91.

Its position is oblique, so that its broad end is directed towards the trapezium



A diagram showing the dorsal surface of the bones of the carpus, with their articulations.—The right hand. 2. The lower end of the radius. 1. The lower extremity of the ulna. 3. The inter-articular fibro-cartilage attached to the styloid process of the ulna, and to the margin of the articular surface of the radius. S. The scaphoid bone. L. The semilunar articulating with five bones. C. The cuneiform, articulating with three bones. P. The pisiform, articulating with the cuneiform only. T. The first bone of the second row,—the trapezium, articulating with four bones. T. The second bone,—the trapezoid, articulating also with four bones. M. The os magnum, articulating with seven. U. The unciform, articulating with five.—W.]

and root of the thumb, whilst the narrow one inclines inwards and upwards to the middle of the articular surface of the radius.

It is convex on one side, concave on the other. The concave or hollowed (scaphoid) surface looks obliquely inwards and forwards,



and is that which determines the form and gives name to the bone. Its upper articular surface, convex and triangular, is applied to the radius; the lower, also convex, articulates with the trapezium and the trapezoid bone. Its concavity receives part of the head of the os magnum; close to this is a narrow articular surface which is in contact with the semilunar bone; on its radial side is a rough surface, to which is attached the external lateral ligament of the wrist-joint; posteriorly is a narrow grooved surface for the attachment of ligaments; and anteriorly is a rough surface, the inner or ulnar half of which is narrow and slightly grooved, whilst the outer is prominent and tuberculated for the attachment of ligaments. It articulates with five bones.

#### THE SEMILUNAR BONE.

The name of this bone (L) [os lunatum] is taken from its being concave or crescentic on its inferior surface. Irregularly triangular in its form, convex superiorly, it articulates with the square part of the articular surface of the radius; inferiorly concave, with the os magnum and the unciform; on the ulnar side with the cuneiform; on the radial side with the scaphoid; anteriorly and posteriorly it gives attachment to ligaments. It articulates with five bones.

#### THE CUNEIFORM BONE.

This is the "wedge-shaped" bone c; sometimes also it is named from its form "pyramidal," as well as "os triquetrum."

Superiorly, it is in relation with the interarticular fibro-cartilage of the wrist-joint; inferiorly, it articulates with the unciform bone; on the ulnar side, gives attachment to ligaments; on the radial side, articulates with the semilunar bone; anteriorly it affords attachment to ligaments, and presents a small articular surface for the pisiform bone. It articulates with three bones.

#### THE PISIFORM BONE.

The "pea-shaped" bone [os pisiforme] (P) is placed on a plane anterior to the other bones of the carpus, and might more fitly be considered as an appendage to the tendon of a muscle—a sesamoid bone—than as a portion of the framework of the carpus.\* The form is indicated by its name (pisum, a pea), and to it is due another designation—os subrotundum. It presents but one articular surface, which is situated on the posterior part, or base, and rests on the anterior surface of the cuneiform bone. It affords attachment to the annular ligament of the carpus, to the flexor carpi ulnaris muscle, and to the abductor of the little finger.

The first three carpal bones form, when in apposition, a rounded convex surface, which corresponds with the concavity presented by the radius and the interarticular cartilage. The greater part of their lower surface constitutes a deep hollow, which receives the head of the os magnum and a small part of the unciform bone; and on the

\* "Carpo extra ordinem appositum est, assidens patellæ in modum, aut sesamoidei."—*B. S. Albini de sceleto hum. liber,* p. 410.



outer side a part of this range (the lower convex surface of the scaphoid) is received into a slight depression of the second row, formed by the trapezium and trapezoid. (See figure 91.)

### BONES OF THE SECOND ROW.

#### THE TRAPEZIUM.

The name of this bone ( $\tau$ ) is taken from its presenting four unequal edges at its posterior aspect, and it has also been known as the "*os multangulum majus*." It is placed at the radial border of the carpus, between the metacarpal bone of the thumb and the scaphoid bone. It is known by the angular appearance of its dorsal surface, and by the tubercle and groove at its palmar aspect.

Superiorly concave, it articulates with the scaphoid bone; inferiorly, concave from behind forward, and convex transversely, with the first metacarpal bone; on the ulnar side, with the trapezoid bone, and, by a small surface situated more inferiorly, with the edge of the second metacarpal bone; on the radial and posterior sides it gives attachment to ligaments; anteriorly it presents a groove traversed by the tendon of the flexor carpi radialis, and a ridge to which the annular ligament of the carpus is attached. It articulates with four bones.

#### THE TRAPEZOID BONE.

This is a small bone ( $\tau$ ) compared with those between which it is placed, viz., the trapezium, scaphoid, and *os magnum*; in form and position it has some resemblance to a wedge, and but little to a trapezium, except that its posterior surface is bounded by four unequal edges. In contradistinction to the preceding bone, this received the name "*os multangulum minus*."

It articulates superiorly with the scaphoid bone; inferiorly, with the second metacarpal bone; on the ulnar side with the *os magnum*; on the radial side, with the trapezium: the anterior and posterior surfaces afford attachment to ligaments. It articulates with four bones.

#### OS MAGNUM.

This ( $m$ ) is the largest of the carpal bones; its form is oblong, round superiorly, cubic inferiorly; the superior surface, named its "*head*," (whence it is sometimes called "*os capitatum*,") is supported by a narrowed portion, named the "*neck*;" its greatest convexity is in the antero-posterior direction, where it is received into a cavity formed by the scaphoid and the semilunar bone; it articulates, inferiorly, by three distinct surfaces, of which the middle is the largest, with the second, third, and fourth metacarpal bones; on the ulnar side, with the unciform bone; on the radial side, with the trapezoid bone: the anterior and posterior aspects are rough (particularly the former) for the attachment of ligaments. It articulates with seven bones.

#### THE UNCIFORM BONE.

The "hook-shaped" bone ( $u$ ) [*os hamatum*] (*uncus*, a hook,) is readily distinguished from the rest by the curved process upon its



palmar surface: it articulates, superiorly, with the semilunar bone; inferiorly, by two distinct surfaces, with the fourth and fifth metacarpal bones; on the ulnar side, with the cuneiform bone; on the radial side, with the os magnum: anteriorly its hooked process affords attachment to the anterior annular ligament of the carpus; posteriorly a rough surface also gives attachment to ligaments. It articulates with five bones.

### THE METACARPUS.

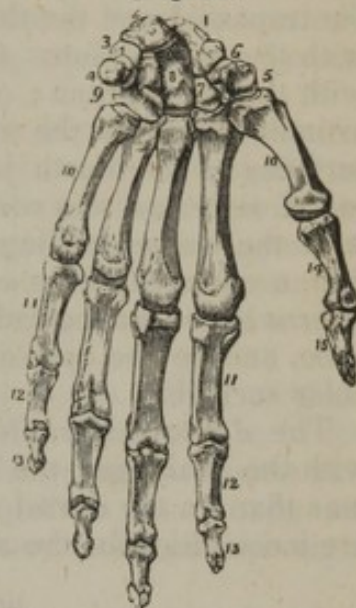
This forms the second or middle portion of the hand, being situated between the carpus and the phalanges; it is composed of five bones, which are named first, second, &c., in their numerical order, the enumeration being commenced at the radial side. These bones are placed parallel one with the other, and nearly on the same plane, with the exception of the first, which is more anterior than the rest, and alters in its relative position to them in its various movements.

The metacarpal bones vary in size. The first is thicker and shorter than the others. The second and third do not differ strikingly one from the other in dimensions, and they are longer than the rest. The fourth exceeds the fifth in size. They are all slightly concave on the palmar surface, convex on the dorsal, larger at their extremities than in the body or middle part, terminated at the carpal extremity by an unequal eminence, and at the digital by a rounded head.

The *bodies* are triangular in shape; each presenting three surfaces, and as many borders. Of the surfaces, two are placed laterally, the third looks backwards; one of the angles is in front, and the others at each side of the dorsal surface. From this shape and position of the sides, it results that the bones become narrow towards the palmar aspect of the hand, and that the spaces between them (*interosseous*) increase from behind forward.

The body of the first metacarpal bone wants the triangular shape of the others; it is more compressed from before backwards, and resembles one of the phalanges in shape. There are some slight peculiarities of the dorsal surface in the several metacarpal bones. It is convex and smooth in the first, and presents in the second, third, and fourth, a longitudinal line, which, bifurcating, forms the sides of a triangular surface, extending over two-thirds of their length; in the fifth, also, is observed a prominent longitudinal line, directed obliquely from the ulnar to the radial side. The lateral surfaces afford attachment to the dorsal interosseous muscles.

[Fig. 92.



The hand viewed upon its anterior or palmar aspect. 1. The scaphoid bone. 2. The semilunare. 3. The cuneiform. 4. The pisiform. 5. The trapezium. 6. The trapezoid. 7. The trapezoides. 8. The os magnum. 9. The unciform. 10, 10. The five metacarpal bones. 11, 11. The first row of phalanges. 12, 12. The second row. 13, 13. The third row, or ungual phalanges. 14. The first phalanx of the thumb. 15. The second and last phalanx of the thumb.—W.]



The *carpal extremity (base)* presents, in each, some peculiarities which render a separate description necessary. By reference to the difference of their carpal extremities, the bones may be distinguished one from the other, and the more readily if their relative size be at the same time taken into account. On the superior extremity of the first is observed a surface, concave in the antero-posterior direction, and convex from side to side, which articulates with the trapezium; this bone has no lateral articulating surface. In the second, an angular depression receives the trapezoid bone, and, on the radial side, a small surface articulates with the trapezium; at the ulnar side, the margin is extended obliquely backwards, so as to become wedged in between the trapezoid and the third metacarpal bone, and articulates by its tip with the os magnum. On the third, a nearly plane surface articulates with the os magnum; on the radial and ulnar sides are surfaces for articulation with the contiguous metacarpal bones. Two articular surfaces of the fourth join with the os magnum and unciform; the radial side has two surfaces, and the ulnar side one, for articulation with the corresponding surfaces of the bone on each side. On the fifth, a concave surface, directed outwards, corresponds with the unciform bone; at the radial side is a surface for the fourth metacarpal bone, and on the opposite side there is a prominence without an articular surface.

The *digital extremities (heads)* of all are convex, and articulated with the phalanges, the smooth surfaces extending farther on the palmar than on the dorsal aspect of the bones; and on the sides of these are inequalities for the attachment of ligaments.

#### BONES OF THE FINGERS.

These are fourteen in number; each, with the exception of the thumb, having three separate pieces (*phalanges, internodia*). Of these the first is longer than the second, and the second than the third. Like other long bones, each is divided into a body and two extremities, of which one represents the base and the other the head. Winslow and some other anatomists reckon three phalanges in the thumb, as they conceive that its posterior, or most movable bone, resembles the first phalanges of the fingers rather than the metacarpal bones. But if its conformation be examined with attention, more especially that of its anterior extremity, and also its mode of articulation with the bone in front of it, its analogy with the metacarpal range will appear more striking than with the first digital phalanges; and so it is considered by Meckel, Portal, H. and J. Cloquet.

The *bodies of the first row* or phalanx are convex on the dorsal surface, and flat from side to side on the palmar, but arched from before backwards; the palmar surface is bounded by two margins which give insertion to the fibrous sheaths of the flexor tendons.

The larger or *posterior extremities* present an oval concave surface, whose greatest diameter is from side to side, intended to receive the convex heads of the corresponding metacarpal bones. The *anterior extremities*, smaller than the other, end in two small lateral condyles, with a slight groove between them, both being adapted to the base of



the contiguous bones, so as to form ginglymoid, or hinge joints. The articular surface is prolonged farther on the palmar than on the dorsal aspect, which allows a more free range to the motion of flexion. The margins of the articular surfaces are rough and prominent for the attachment of ligaments.

The *second* or *middle row* consists of four bones, the thumb having only two pieces corresponding with those of the first and last phalanx. Smaller than the preceding set, they still resemble them in their general outline. The broader, or posterior extremity, ends in an articular surface, divided by a slight ridge extending from before backwards, the lateral parts being concave, for the reception of the two eminences on the contiguous bone; the anterior extremity is divided into two lateral convex surfaces, which are lodged in depressions in the base of the last phalanx.

The *third row* (phalanges unguium,) consists of five pieces, that of the thumb being the largest. They are convex on the dorsal, flat on the palmar surface, rough at the summit, which corresponds with the points of the fingers, and at the base, for the attachment of ligaments and the flexor tendons. The articular surface, at the base, resembles that of the base of the second phalanx, in having two shallow concavities divided by a central convex line.

*Attachments of muscles.*—1. To the carpal bones. The *pisiform* bone gives origin to the abductor minimi digiti, and insertion to the flexor carpi ulnaris; the *trapezium* to the opponens and abductor pollicis; the *trapezoid* to part of the flexor brevis pollicis; the *os magnum* to part of the same; the *unciform* to the flexor brevis minimi digiti and to the adductor.

2. To the metacarpal bones. The *first*, or that of the thumb, gives insertion to the extensor ossis metacarpi pollicis and to the opponens pollicis, and origin to part of the abductor indicis: the *second*, or that of the fore-finger, to the flexor carpi radialis at its palmar end, and to the extensor carpi radialis longior on the dorsal surface of its base, and by its lateral surfaces, to the first two dorsal interossei muscles and one palmar: the *third*, to the extensor carpi radialis brevior, to the adductor pollicis, and also to two dorsal interossei: the *fourth*, to two dorsal interossei and one palmar: the *fifth*, to the extensor carpi ulnaris, the abductor minimi digiti, and to one dorsal and one palmar interosseous muscle.

3. To the bones of the fingers. Those of the *first* range of the four fingers give attachment by their lateral borders to the tendinous sheaths of the flexor tendons; their dorsal surface is covered by the expansion of the extensor tendons. The bones of the *second* row give insertion at their dorsal surface to the tendons of the extensor communis; the tendons of the flexor sublimis are inserted into their bases at the palmar surface. The *third* set gives insertion to the tendons of the flexor profundus; the fibres of the extensor communis are also continued on their dorsal aspect.

The *first* phalanx of the thumb gives insertion to the extensor primi internodii, to the flexor brevis, to the adductor and abductor pollicis:

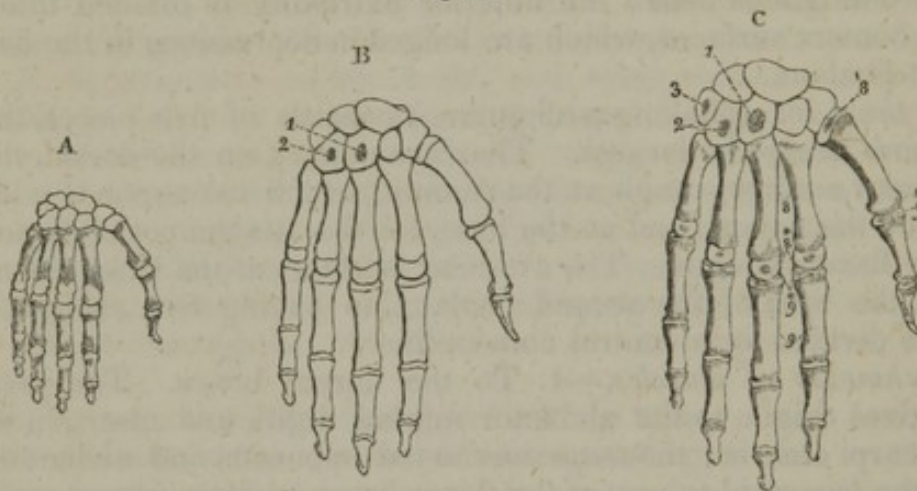


the *second* phalanx to the flexor longus, and to the extensor secundi internodii.

#### OSSIFICATION OF THE CARPAL BONES.

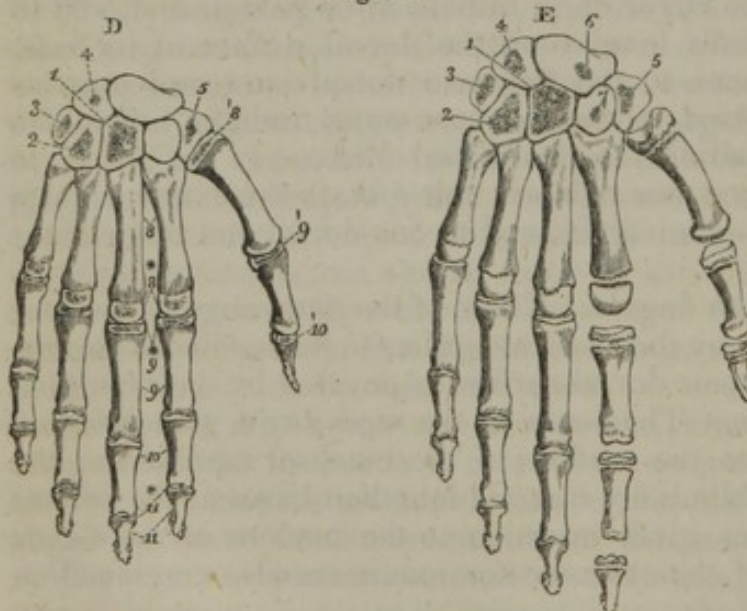
The carpus is altogether cartilaginous at the general period of birth (fig. 93, A). In the course of the first year after, ossification begins in the os magnum, which is followed speedily by the unciform bone (B. <sup>1 2</sup>)

Fig. 93.



A. The state of the various parts of the hand in a full-grown fœtus is shown in this figure. There is no osseous point in the carpus, but the metacarpal bones and the phalanges are ossified to a considerable extent. B. This figure represents the state of the bones about the end of the first year after birth; C. shows their condition about the third year; D. at the fifth year; and E. about the ninth.

Fig. 94.



1. Os magnum. 2. The unciform bone. 3. The pyramidal or cuneiform. 4. Semilunar. 5. Trapezium. 6. Scaphoid. 7. Trapezoid. 8. Metacarpal bones—the principal piece. 8.\* The epiphyses of the metacarpal bones of fingers. 8.<sup>1</sup> The epiphysis of the metacarpal bone of the thumb. 9. The first range of phalanges; 9.\* their epiphyses. 9.<sup>1</sup> Epiphysis of the first bone of the thumb. 10. The second row of phalanges. 10.<sup>1</sup> The epiphysis of the second bone of the thumb. 11. The last row of the fingers; 11.\* their epiphyses.

N. B. The carpal bones are numbered according to the order of their appearance, except the trapezium

and semilunar, whose numbers have been accidentally transposed.—An appearance of ossification ought to have been shown in figure D. for the epiphyses of the second range of phalanges.



The pyramidal or cuneiform is the next to receive an osseous deposit, and this occurs in the third year (c.<sup>3</sup>)

In the fifth year nuclei are formed in the trapezium and semilunar; and, as at the end of that year the nucleus in the former bone is the larger, it is to be inferred that it preceded the other in its growth (fig. 90, D.<sup>4 5</sup>)

At about six years of age the scaphoid, and soon after eight the trapezoid, begin to ossify. The granule for the first makes its appearance near the lower end of the bone (E.<sup>6 7</sup>)

Lastly, the pisiform contains an osseous granule about the twelfth year.

The carpal bones are formed each from a single centre. It may be observed that, in examining their condition during the first years of life, the relative periods at which their ossification begins, may, in a great degree, be determined by the comparative extent to which the deposit of bone has encroached on the pre-existing cartilages.

#### OSSIFICATION OF THE METACARPAL BONES.

The other parts of the framework of the hand differ widely from the carpus in the time at which their ossification commences, inasmuch as the process is far advanced before the end of fœtal life. Each metacarpal bone is formed from two parts, or of what may be considered a principal piece and an epiphysis. Its ossification begins shortly after the bones of the fore-arm in the middle of the body, and the process extends over the greater part of the bone, including its upper extremity, (fig. 93, c.; fig. 94, D. E.<sup>8\*</sup>) About the third year of age an osseous granule appears in the lower end, and the epiphysis resulting from its increase joins the principal piece before mentioned towards the twentieth year. Such is the mode of construction of the metacarpal bones of the fingers. That of the thumb differs in the position of the epiphysis, which is formed on its upper or carpal extremity, instead of the lower extremity,—this being produced by an extension from the larger or principal piece of the bone (c. D. E.<sup>8</sup>) And thus, in the manner of its growth, as well as in its shape, the metacarpal bone of the thumb assimilates to the phalanges.

#### OSSIFICATION OF THE BONES OF THE FINGERS.

These bones are likewise formed from two parts. The ossification begins about the same time as in the metacarpal bones; but it is stated by Meckel and others, that the primary nuclei do not appear in the bones of the second row for some time after they have been perceptible in those of the first and last. The deposit of osseous matter from each primary nucleus, involves all the corresponding bone except its upper extremity.

The additional piece or epiphysis begins to ossify at the third or fourth year in the first row, and a year later in the others;\* and the

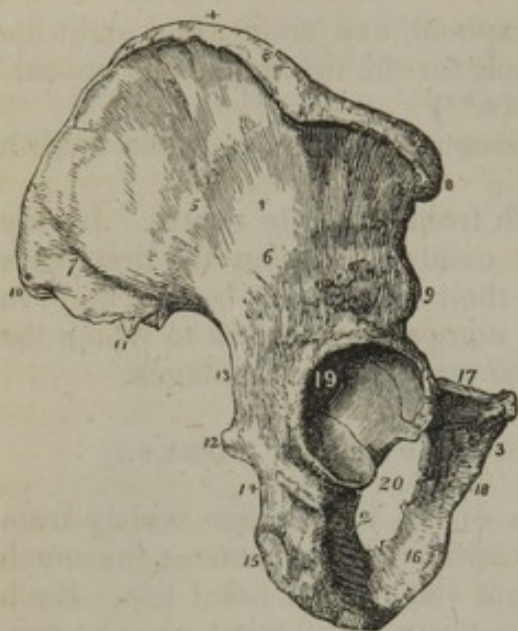
\* The periods assigned by Bôclard for the appearance of ossific granules in the epiphyses



bones are completed by the junction of their parts before the twentieth year.

### INNOMINATE BONE. (OS INNOMINATUM.—OS COXÆ.)

[Fig. 95.]



The os innominatum of the right side. 1. The ilium; its external surface. 2. The ischium. 3. The os pubis. 4. The crest of the ilium. 5. The superior curved line. 6. The inferior curved line. 7. The surface for the gluteus maximus. 8. The anterior superior spinous process. 9. The anterior inferior spinous process. 10. The posterior superior spinous process. 11. The posterior inferior spinous process. 12. The spine of the ischium. 13. The great sacro-ischiatic notch. 14. The lesser sacro-ischiatic notch. 15. The tuberosity of the ischium, showing its three facets. 16. The ramus of the ischium. 17. The body of the os pubis. 18. The ramus of the pubis. 19. The acetabulum. 20. The foramen thyroideum.—W.]

### THE ILIUM. (OS ILIUM.)

The ilium, or iliac portion of the os innominatum, constitutes the upper part of the bone, where it is broad and expanded; it is situated at the superior and lateral part of the pelvis. Its surfaces, borders, and angles must be considered successively.

The external surface (*dorsum*),<sup>1</sup> convex before, concave posteriorly, is marked by two curved lines running from before backwards. The

of the phalanges are as follows:—for those of the first range, three or four years; for the second or middle range, seven years; and for the last, or ungual, four or five years.

Some preparations in my collection demonstrate that the time here connected with the appearance of bone for the epiphyses of the second phalanges cannot be generally correct. One case bearing on the point may be specially referred to, because no doubt could exist concerning the age, or with respect to the previously healthy state of the limb. I amputated the arm of a delicate female child, who, on the day before the operation, had attained the age of five years. The removal of the limb was rendered necessary in consequence of an injury. In the hand of this child the epiphyses of the three sets of bones of the fingers are advanced in ossification, and proportionally to the size of the cartilage those of the ungual row appear smallest.

This bone, fig. 95, is of so complex and irregular a form, that it bears no perceptible resemblance to any other known object, and therefore remains “unnamed” and unnameable. The two bones thus distinguished by the negation of a name are situated at the inferior and lateral parts of the trunk, extending from the sacrum forwards to the median line, where they are connected together. Through the intervention of the sacrum, which is wedged in between them, they receive the weight of the body from the vertebral column, and transmit it to the lower extremities; thus placed, and being somewhat curved in their general outline, they circumscribe the greater part of the cavity of the pelvis, the sides and fore part of which they form.

To facilitate the description of this very irregular bone, it is convenient to consider separately each of the parts into which it is found divided in early life, viz. the ilium, os pubis, and ischium.



superior one,<sup>5</sup> commencing at the anterior superior spinous process, arches downwards to the margin of the sacro-sciatic notch. A space, narrowed before, and wider posteriorly, is included between the line just noticed, and the margin of the crista ilii, and the border of the rough surface for the attachment of the gluteus maximus; from this space the gluteus medius arises. The inferior curved line<sup>6</sup> is shorter and less strongly marked than the superior; it commences at the anterior inferior spinous process, and inclines backward to the sacro-sciatic notch. The space between these lines gives origin to the gluteus minimus. On its posterior and superior part is observed a rough surface,<sup>7</sup> which gives attachment to the gluteus maximus muscle. The internal surface of the ilium is divided into three parts. One anterior, smooth, concave, and of considerable extent, is called the *iliac fossa*; the posterior one is partly rough and uneven for the attachment of ligaments, and in part smooth for its articulation with the "auricular" surface of the sacrum; whilst the third is smooth, much smaller than the others, and is the only part that enters into the formation of the true pelvis.

The superior border,<sup>4</sup> (*crista ilii*), extending from before backwards, is thick, convex, and arched; it forms an epiphysis in infancy, and is sometimes called the spine of the ilium, but more properly its crest or crista; its anterior extremity curves inwards, the posterior outwards. This border presents an external and internal lip (*labium*), and a rough interval, to each of which muscles are attached.

The anterior border, depressed and excavated, descends from the superior border or crista towards the os pubis, with which it is continuous; its junction with the crista is marked by a prominent point, called the *anterior superior spinous process*;<sup>8</sup> and that with the pubes, by an obtuse elevation, common to the two bones, called the *ilio-pectineal* eminence. This border presents two excavations, separated by a prominent point, called the *anterior inferior spinous process*.<sup>9</sup> The interval between the latter and the ilio-pectineal eminence gives transmission to the iliacus and psoas muscles, and that between the spinous processes transmits the external cutaneous nerve, and gives origin to some fibres of the sartorius muscle.

The posterior border also presents two notches, separated by a prominent point of bone, called the *posterior inferior spinous process*;<sup>11</sup> above which is another bony eminence, called the *posterior superior spinous process*;<sup>10</sup> of the notches, the inferior and larger one<sup>12</sup> contributes to form the sacro-sciatic notch.

Of the three angles of the bone, the two superior ones correspond with the spinous processes (anterior and posterior); the inferior is represented by the constricted part of the bone. Here we observe, besides the surfaces by which the ilium joins the os pubis and ischium, one external, smooth, concave part, forming a portion of the acetabulum, the deep cavity which receives the head of the femur.

*Attachments of muscles.*—To the interval between the crista and the superior curved line on the dorsal surface, is attached the gluteus medius; to the space between the curved lines, the gluteus minimus; to the posterior rough surface, the gluteus maximus; to the internal surface, or iliac fossa, the iliacus muscle:



To the anterior half of the external lip of its crista is attached the obliquus externus abdominis; to the posterior third of the same lip, the latissimus dorsi; to the anterior two-thirds of the interval between the lips, the obliquus internus; and to the remainder, the erector spinæ; to the anterior three-fourths of the inner lip, the transversalis abdominis; to the posterior fourth of the same lip, the quadratus lumborum.

To the external surface of the anterior superior spinous process is attached the tensor vaginæ femoris; to the process and the notch beneath it, the sartorius; to the anterior inferior spine, the straight tendon of the rectus femoris; and to a depression above the brim of the acetabulum, the external tendon of that same muscle.

*Articulations.*—This bone articulates with the sacrum, and joins by bony union with the os pubis and the ischium.

#### OS PUBIS. (OS PECTINIS.)

The pubic bone forms the anterior and inner part of the os innominatum; and is divisible into two elongated portions, (branches, rami,) connected by a more expanded part, which may be considered the body of the bone.\*

Of the *rami*, the superior one<sup>17</sup> is thick and horizontal in its direction (*ramus horizontalis; crus superius*, Alb.), and presents three surfaces, separated by three prominent lines. The superior surface, slightly depressed, is covered by the pectineus muscle; the internal is smooth, and forms part of the pelvic cavity; the external or inferior, overhanging the obturator foramen, and looking downwards to the top of the thigh, is deeply grooved. The groove is directed obliquely forwards and inwards, and marks the course of the obturator vessels and nerve.

The external extremity of the bone is thick, and presents three faces; one, concave, forms part of the acetabulum; another, superior, connects it with the ilium (the junction being marked by a rounded elevation, called the *ilio-pectineal eminence*); the third, inferior, is joined with the ischium.

The internal extremity, *the body*,<sup>3</sup> flat and compressed, is irregularly quadrilateral in shape. In front it gives attachment to muscles, and behind, forming part of the cavity of the pelvis, it looks towards the

\* As the description here given of the pubic division of the innominate bone differs from that contained in other anatomical works, in so far as the part named "the body" is concerned, it is necessary to make reference briefly to some of those works, in order to prevent misapprehension.—Monro, Bichat, and Cloquet neither recognise the division into "rami," nor apply the name "body" to any part of the bone. Albinus usually mentions the rami under the name "*crura*," and refers to them as "*cornua tanquam crura*," but he does not use the term "body;" and Sæmmerring and Blumenbach pursue the same plan. Winslow, Sabatier, Boyer, and Cruveilhier treat of the pubes as divisible into the two branches, and likewise mention the horizontal branch as the body of the bone, using indifferently either term. Hildebrandt and Weber, and Meckel differ from the last-mentioned manner of naming the parts only by applying the word "body," not to the entire of the horizontal branch, but to its outer and thickest part, which joins with the ilium and ischium, and contributes to form the acetabulum.—Considering the difference thus shown to exist among anatomical authorities, and that the central expanded part, at which the rami meet, requires some designation (for more easy reference in the description of other structures), while it does not seem necessary so to distinguish the outer end of the bone, the plan pursued in the text is perhaps admissible.



urinary bladder. The inner margin of the body is joined to the corresponding part of the opposite bone by an intervening cartilage, the junction being termed the *symphysis pubis* (συνφυσις, to grow together). Leading outwards from the symphysis, whose direction is vertical, may be observed another margin, nearly an inch in length, which is placed horizontally, and named the *crista*. The angle formed by the crista and symphysis, is termed the *angle* of the pubes; the crista is terminated externally by a projecting nodule of bone—the *tuberosity* or spine, from which runs outwards a sharp line (*pecten*), a portion of the ilio-pectineal line, giving attachment to Gimbernat's ligament, and to the pectineus muscle, and marking the margin or upper boundary of the true pelvis.

The *descending ramus*, or branch of the bone,<sup>18</sup> inclines outwards and downwards from the body, forming an angle with it, becomes thin, and unites with the ascending ramus of the ischium. Its inner surface is smooth; the external is rough, for the attachment of muscles. One of its borders, thick and rough and somewhat everted, forms with the opposite bone an arch, called the arch of the pubes; the other border, sharp and thin, forms part of the margin of the obturator foramen.

*Attachment of muscles.*—To the crista are attached the pyramidalis and rectus abdominis; to the tuberosity and anterior surface, the obliquus externus; to the pectineal line, the pectineus and Gimbernat's ligament; to the crista, and part of the same line, the obliquus internus and transversalis.

To the external surface, at the tuberosity, and a little below it, the adductor longus; to the body, the adductor brevis; to the line of the symphysis and the ramus, the gracilis; and to the margin of the foramen, at its inner side, the obturator externus. To the pelvic surface, part of the obturator internus and levator ani.

#### ISCHIUM. (OS ISCHII; OS COXENDICIS.)

The *ischium* forms the posterior and lowest part of the os innominatum; it consists of two parts, a body and a ramus, united at an angle, so as to give the bone somewhat the figure of a hook.

The *body*,<sup>2</sup> or larger part, short, thick, and somewhat triangular in form, presents three surfaces or aspects, which look in different directions; there are three borders, and two extremities. On its external surface may be observed a smooth concave part, which forms more than two-fifths of the acetabulum, and is surrounded by a curved prominent line, which forms the lower border of that cavity; beneath this is a groove, directed horizontally backwards, corresponding with the tendon of the obturator externus muscle; and still lower a rough line, which bounds the tuberosity of the ischium, and gives attachment to the quadratus femoris. The internal surface of this portion of the bone is smooth, and forms part of the cavity of the pelvis. This is broad at its upper part, as it comprises the interval between the spine or spinous process<sup>12</sup> and the margin of the obturator foramen. Below this process it becomes narrowed, constricted, and rounded off at its back, so as to form a pulley-like surface, in the interval between the spine and the



tuberosity where the obturator internus muscle winds round its border. The posterior surface, broad at its upper part where it comprises the space between the spine and the margin of the acetabulum, then becomes narrowed and depressed, and finally ends in a rough and rather prominent surface bounded by well-defined borders, which is the tuberosity of the ischium.

The *tuberosity*,<sup>16</sup> (*tuber ischii*), thick and rounded, forms the part on which the body is supported in the sitting position; to this circumstance the name of the bone has been supposed to refer (*ἰσχεῖν καθήμενους*—quod sustineat sedentes).<sup>\*</sup> This rough prominence presents three impressions upon it, corresponding with the points of attachment of the three long flexor muscles of the leg.

The superior extremity of the bone (if it be examined in early life, when the bone can be detached from the ilium and os pubis, or after a section has been made of the os innominatum, so as to divide it into its three parts,) presents three surfaces, of which two are flat and triangular, and mark its junction with the ilium and os pubis; the other, concave and smooth, forms part of the acetabulum. The inferior extremity of the body of the bone is identified with the tuberosity.

The *ramus* of the ischium<sup>16</sup> is the flat, thin part, which ascends forwards and inwards from the tuberosity, towards the ramus of the os pubis, with which it is united. One margin of the ramus, thick, rough, and somewhat everted, forms part of the inferior outlet of the pelvis; the other, thin and sharp, bounds the obturator foramen; its external surface looks outwards and downwards, is rough for the attachment of muscles; the inner surface forms part of the lower circumference of the pelvis.

*Attachments of muscles.*—To the outer border of the tuberosity and the contiguous part of the ramus, the adductor magnus; to the inner margin of the tuberosity at its fore part, the erector penis and the transversus perinæi; to the ramus, the compressor urethræ; the internal obturator muscle to the posterior surface of the bone behind the thyroid or obturator foramen; the external muscle of the same name to the inner margin of the obturator foramen in front of the bone.

To the posterior surface of the tuberosity, the three flexors of the leg, *i. e.* the biceps, semi-tendinosus, and semi-membranosus; to the rough line on the outer surface which bounds the tuberosity, the quadratus femoris; to the external surface of the spine, the gemellus superior; to the adjacent border of the tuberosity, the gemellus inferior; to the spinous process, the levator ani and the coccygeus.

*Acetabulum.*—At the junction of the three pieces of the os innominatum is situated the cavity which articulates with the head of the femur. It is called *acetabulum*,<sup>19</sup> also the *cotyloid* or cup-shaped cavity (*κοτυλή*, a cup; *εἶδος*). Of this the ischium forms somewhat more than two-fifths, the ilium somewhat less than two-fifths, the remainder being made up by the os pubis. It is surrounded in the greater part of its extent by a margin or supercilium, which is most prominent towards

<sup>\*</sup> Riolanus "In librum Galeni de ossibus, ad tyrones commentarius," &c., cap. 26, in "Oper." p. 512.—The name in the German language—Sitzbein, or Sitzstück—has reference to the same circumstance.



the superior and external part; but at the opposite point, or towards the obturator foramen, it is deficient, leaving a notch, (*cotyloid notch*, sometimes also called *incisura acetabuli*). The greater part of the cavity is covered with cartilage in the natural condition; but at the bottom and towards the notch there is a part depressed beneath the rest, which lodges a mass of fat with some synovial fringes: this has no cartilaginous coating.

When we examine the pelvis as a whole, we observe that these articulating cavities, placed toward the lateral walls of the pelvis, look downwards and forwards, with an inclination outwards, and that they rest, when the body is erect, upon the globular heads of the thigh-bones, which they lodge. The margin of each cavity is rough and uneven; but in the recent state it is rendered smooth by a fibro-cartilaginous rim, which runs round it, and increases its depth. Where the osseous margin is deficient (at the cotyloid notch), its place is supplied by a fibrous band, so stretched across as not altogether to fill it up, but rather to bridge it over, leaving a space beneath it for the entrance of vessels into the interior of the joint.

To the inner side of the acetabulum is found, in the dried bone, a large aperture,<sup>20</sup> which, however, in the natural condition, is almost completely closed by a fibrous membrane. It is called *obturator foramen*, (f. *obturatorium*, perhaps more properly *obturatum*,) from the circumstance of its being closed by a membrane or ligament. It is also called *foramen thyroideum* (shield-shaped, *θυροειδές*, a shield), from its shape; and not unfrequently *foramen ovale*. It is somewhat of an oval form in the male, its longest diameter being extended obliquely downwards and outwards; in the female it is a three-sided figure, with rounded angles.

*Ossification*.—The innominate bone is formed from three principal pieces, one for each of the divisions of the bone, and four epiphyses, together with a thin stratum interposed between the principal divisions of the bone at their place of junction.

Osseous matter becomes apparent in the ilium at a very early period,—about the time it shows itself in the vertebral column, or soon after. It is first discernible at the lower part of this division of the bone, immediately above the sciatic notch.

After a considerable interval of time, and about the third month from conception, a nucleus appears in the ischium, in the thick part below the acetabulum. And between the fourth and fifth months the last of the principal centres of ossification is distinguishable in the horizontal branch of the pubes.

At the usual time of birth the deposit of bone has extended considerably from the primitive nuclei; but the crest of the ilium is still largely cartilaginous, and the internal parts of the ischium and pubes are in the same condition, bony matter having at this period only begun to incline to the inner side of the obturator foramen, fig. 96, A.

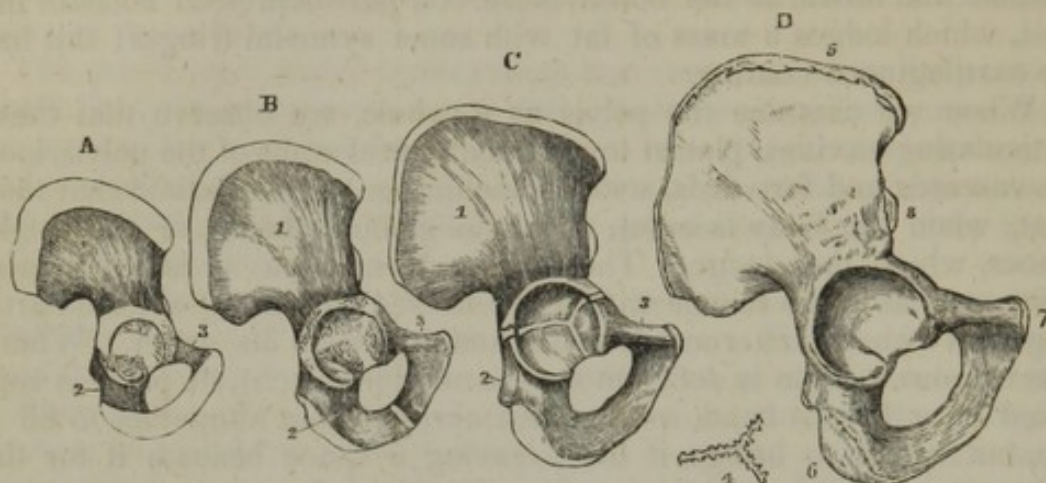
About the sixth year after birth the rami of the ischium and pubes are nearly altogether ossified, (B,) and they join about the tenth year (C.)

The three divisions of the bone approach one to the other in the acetabulum, by the extension of the ossific process from the primary



nuclei (A, B, c); and about the thirteenth or fourteenth year a distinct deposit of bony matter is observable in the cartilage which separates

Fig. 96.



Some stages of the growth of the innominate bone are here exemplified.

Figure A. shows its condition in a full-grown fœtus. Ossification has extended from the primitive nuclei. But the crista ilii is largely cartilaginous; the pubes and ischium are in the same condition at the inner side of the obturator foramen, and a considerable cartilaginous interval separates the pieces in the acetabulum. B. This has been sketched from a preparation taken from a child under six years of age. Bony matter, spreading over the bone, has involved the inner side of the ischium and pubes, but the osseous parts of their rami are still at some distance apart. C. The rami of the ischium and pubes are joined; a cartilaginous Y-shaped interspace is apparent in the acetabulum. D. This figure is from the body of a person aged about twenty years. Union has taken place in the acetabulum, and the epiphyses are fully formed.

1. Ilium. 2. Ischium. 3. Pubes. 4. Y-shaped piece. (This is a plan. In the preparations of my collection this formation occurs in several fragments, which together would constitute a piece of this kind.) 5. Epiphysis of the crest of the ilium. 6. That for the tuber ischii. 7. For the pubes. 8. For the antero-inferior spine of the ilium.

them in this situation. The added formation may occur in a single mass (I have hitherto found it to consist of several fragments); and, from the shape it necessarily assumes, it is named the Y-shaped piece. The union, therefore, of the ilium, ischium, and pubes occurs through the medium of the interposed piece or pieces now described, and it takes place after the usual time of puberty; the two first named joining in the first instance.

About the age of puberty epiphyses begin to make their appearance as follows:

- a. On the crest of the ilium reaching over its whole length (D<sup>5</sup>).
- b. In the anterior inferior spine of the same part (D<sup>8</sup>). This epiphysis is not constant; it is said to occur more frequently in the male than the female.
- c. The tuberosity of the ischium becomes covered by a broad, curved crust, which reaches upwards some way in a pointed form on the ramus (D<sup>6</sup>).
- d. Lastly, the inner margin of the pubes receives a small epiphysary plate (D<sup>7</sup>), which is stated by Béclard to be present more frequently in the female than the male skeleton.

The epiphyses are all joined to the bone about the twenty-fifth year.



## THE PELVIS.

The *pelvis*, or basin-shaped cavity, which is made up of the ossa innominata, the sacrum, and coccyx, deserves to be attentively examined, not merely as to the details of the parts which compose it, but as to its general conformation.

The *external surface*.—Taking the objects which are deserving of notice on the external surface, from before backwards, and beginning at the median line, we observe the *symphysis pubis*, or the line of junction between the two bones of that name; its direction is vertical, its depth greater in the male than in the female; beneath it is an angular space, the *pubic* or *sub-pubic arch*, bounded by the rami of the ossa pubis and ischia at each side. On each side of the arch is the *thyroid* or *obturator foramen* above noticed, and still more laterally the *acetabulum*, above which rises the broad convex part of the ilium (*dorsum ilii*). Posteriorly, along the middle line, are situated the tubercles or spinous processes of the sacrum; external to these, the posterior sacral foramina, and next, a broad, unequal surface, to which the sciatic ligaments and gluteus maximus are attached; and lastly, the large, deep excavation (*sacro-sciatic notch*), bounded by the margins of the sacrum and os innominatum.

The *internal surface* is divided into two parts by a prominent line (*ilio-pectineal*) leading from the tuberosities of the ossa pubis, outwards and backwards, to the prominent point of the sacrum (*the promontory*). This constitutes the margin or *brim* or *inlet of the true pelvis*, all the part above it being called the *false pelvis*; as in reality it belongs to the abdomen.

The *superior circumference* of the false pelvis is formed on each side by the crista ilii; posteriorly may be observed a deep notch, which is divided into two parts by the base of the sacrum, and anteriorly (in the interval between the antero-superior spinous processes of the ilia) the margin of the bone subsides, so as to present a deep excavation, which in the natural condition is filled up by the soft parietes of the abdomen. Along this margin are placed the antero-inferior spinous processes of the ilia, the ilio-pectineal eminences, the spines or tuberosities of the ossa pubis, with their cristæ and angles. The *inferior circumference* or *outlet of the pelvis* presents three bony eminences (the tuberosities of the ischia on the sides, and the sacrum and coccyx behind in the middle line), which are like so many promontories, separated by deep excavations. The anterior of these (*pubic arch*), triangular in its form, is bounded on each side by the rami of the ischia and ossa pubis, extending upwards and inwards from the tuberosities of the ischia to the symphysis pubis. The two other notches (*sacro-sciatic*) are placed behind and above the tuberosities, and correspond with the interval between the sacrum and os innominatum. When examined in the dried bones, their extent is considerable; but in the natural condition they are divided into lesser spaces by the sacro-sciatic ligaments.

*Obliquity of the pelvis*.—In the erect attitude of the body, the direction of the pelvis is so oblique (fig. 97,) that the anterior wall (pubes)



looks towards the cavity upwards as well as backwards, and the posterior wall (sacrum and coccyx) is directed downwards and forwards. At the same time, the upper and lower apertures are inclined forwards. The base of the sacrum<sup>2</sup> is considerably higher than the upper margin of the symphysis of the pubes;<sup>4</sup> the extent varies in different cases, but in a large number of well-formed female bodies it has been found by M. Naegelé to be three inches and nine or ten lines. The point of the coccyx is stated by the same observer to be—taking the average of a large number of cases—seven or eight lines higher than the inferior margin of the symphysis of the pubes.\*—The obliquity of the pelvis is considerably greater in the fœtus and in young children than in the adult.

Fig. 97.

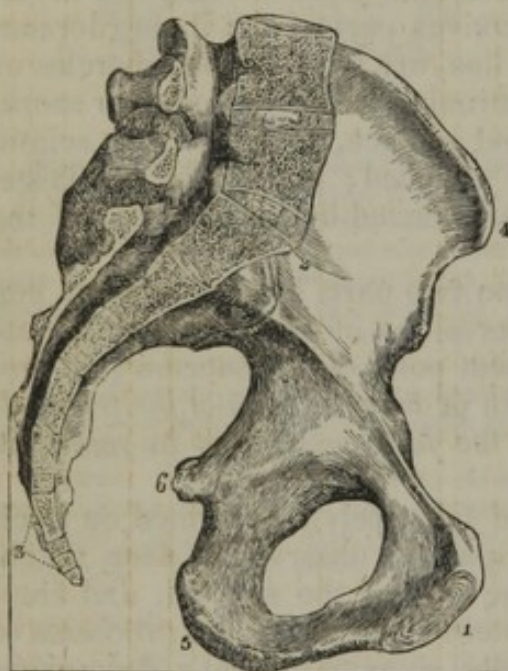

Fig. 98.

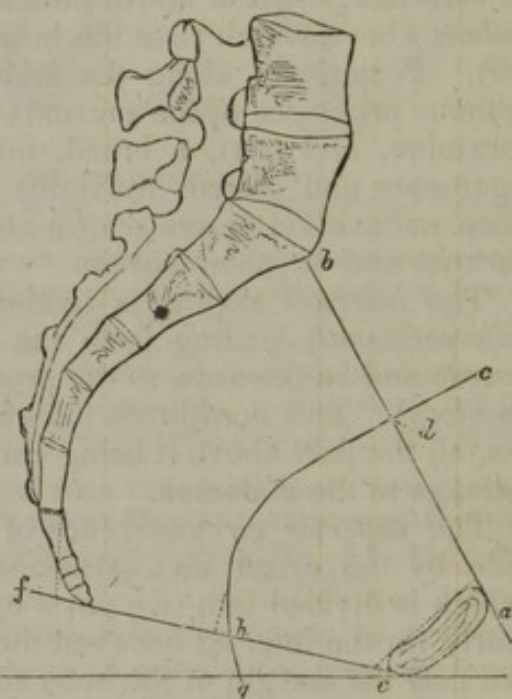

Fig. 93. A vertical section of a female pelvis made through the symphysis of the pubes and the middle of the sacrum, and showing the left lateral half; (reduced from Naegelé's figure). 1. Symphysis of pubes. 2. Base of sacrum. 3. Coccyx. 4. Anterior-superior spine of ilium. 5. Tuberosity of ischium. 6. Spine of ischium.

Fig. 94. A vertical section in outline of the pelvis at its middle, with lines indicating the axis of the pelvis and a horizontal line below the figure.

*Axis of the pelvis.*—In determining the line which would be equally distant from the inner surface of the pelvis on all sides, it will be un-

\* M. Naegelé made observations on five hundred healthy females who had borne children without the occurrence of unwonted difficulty: one hundred and forty-nine of the number were tall persons, fifty-seven of short stature, and the remainder were of middle height; and he found

That the point of the coccyx was higher than the inferior margin of the symphysis pubis (the upper angle of the pubic arch) in	-	-	-	-	454
That it was lower than the same point in	-	-	-	-	26
And that it was on the same level in	-	-	-	-	20

The maximum of elevation of the point of the coccyx above the apex of the arch of the pubes was twenty-two lines, and its maximum of depression below the same point nine lines. The average of all is stated in the text.—“Das weibliche Becken,” &c. Carlsruhe 1825.



necessary to dwell on the lateral walls, inasmuch as these resemble one another exactly, and the middle point does not in any degree deviate to either side in the whole extent of the cavity. But there is so much difference between the anterior and posterior walls,—the one  $1\frac{1}{2}$  to 2 inches in length, and oblique in direction, the other about 5 inches long, likewise oblique and much curved,—that the axis must be differently situated at different positions. It is for this reason that several axes or axes for several parts are recognised; viz., one for the inlet to the true pelvis, another for the outlet, and another again for the intervening space, the cavity; and each of these require some notice. It must be premised that the direction of the axis at any point of the cavity will be marked by a line running at right angles with the middle of the plane of that part.

*The axis of the inlet* of the true pelvis.—The plane of the true pelvis will, in the section of the cavity, (fig. 97,) be represented by a line drawn between the base of the sacrum and the upper margin of the pubes, (fig. 98, *a*, *b*,) and a line at right angles with its middle, *c*, *d*, will give the direction of the axis. The axis of this part is therefore directed downwards and backwards, and it is usually said to coincide with a line drawn from the umbilicus to the lower part of the sacrum; and this is not far removed from correctness, for M. Naegelé found that in the average of a large number of female pelves the lower end of such a line would fall against the coccyx (below the middle). As regards the *axis of the outlet*: it is indicated by the line *h*, *g*, at right angles with the middle of *e*, *f*, which represents, in the section, the plane of this part of the cavity. It is, therefore, directed downwards and forwards; and, if extended into the cavity, would cross an extension of the axis of the inlet. When the coccyx is moved backwards, this axis undergoes a corresponding alteration, as indicated by the dotted lines behind *h*.

The cavity of the pelvis being much curved, so likewise must its axis be; and for general purposes it will be sufficiently correct to say that, beginning with the axis of the inlet, and following the curve of the sacrum and coccyx in the middle of the cavity, it will terminate in that of the outlet—in the course of the curved line between *d* and *h*.\*

It is to be borne in mind that the foregoing observations have reference to the pelvis in the skeleton, its osseous boundaries only being considered. To prevent any misapprehension, it may be well to add, even here, concerning the pelvis of the female (in respect to whom the direction of the cavity is of especial practical importance), that in the natural state, the bones being clothed with soft parts, there is a difference which mainly affects the outlet. In that (the natural) condition, the anterior wall is not materially altered, but the posterior one is elongated at the lower end, the sacrum and coccyx being continued forward by the perineum. And therefore the axis of the real outlet is situated much further forward than the position assigned to it in the osseous cavity alone.

\* The exact course of the line may be determined by finding the axes of different parts at very short intervals, from above downward, through the cavity, on the principle already referred to, and drawing a line through them.



The size and conformation of the pelvis differ very remarkably in the two sexes. In the female the bones are thinner, more smooth on the surface, the muscular impressions being less strongly marked, and, though its perpendicular depth is less, its breadth and capacity are greater. [The increase in circumference of the cavity of the pelvis in the female over that of the male, is dependent upon the greater breadth of the sacrum and the greater transverse measurement along the iliopectineal line.] The alæ of the iliac bones are more expanded; the upper aperture is more nearly circular, the projection of the sacrum less perceptible; and the space between the tuberosities of the ischia greater. The depth of the symphysis pubis is less in the female than in the male, whilst the breadth of the pubic arch is greater.

The different dimensions of the male and female pelvis are stated as follows, by Meckel, Cloquet, and Burns:—

	MECKEL.				CLOQUET.		BURNS.	
	In the male pelvis.		In the female pelvis.		Female.		Female.	
	inch.	lines.	inch.	lines.	inch.	lines.	inch.	lines.
Between the anterior-superior spinous processes of the ilia	7	8	8	6	10	0	10	0
Between the middle points of the cristæ of the ilia	8	3	9	4	11	1	11	1
The transverse diameter	4	6	5	0	5	6	5	6
The oblique	4	5	4	5	4	7	5	5
The antero-posterior	4	0	4	4	4	4	4	0
The transverse diameter	4	0	4	8	—	—	—	—
The oblique	5	0	5	4	—	—	—	—
The antero-posterior	5	0	4	8	—	—	—	—
The transverse	3	0	4	5	4	4	4	0
The antero-posterior	3	3	4	4	4	4	4	0
The last may be increased to five inches in consequence of the mobility of the coccyx.								

In the fœtus and young children the capacity of the pelvis is very small, and, at the same time, those viscera, which may be said to belong to the pelvis, lie chiefly in the abdomen. The obliquity of the cavity is greatest in early life.

### BONES OF THE LOWER EXTREMITY.

The lower extremity is made up of three parts: the thigh, leg, and foot.

The osseous part of the first consists of one bone—the femur; that of the leg, of two—the tibia and fibula. The adjacent extremities of these, together with the patella (a sort of sesamoid bone), form the knee.

The foot is composed of three parts: the tarsus, metatarsus, and phalanges.

### THE FEMUR.

The femur or thigh-bone, fig. 99, (*os femoris*), the longest and largest bone of the skeleton, is situated between the pelvis and the

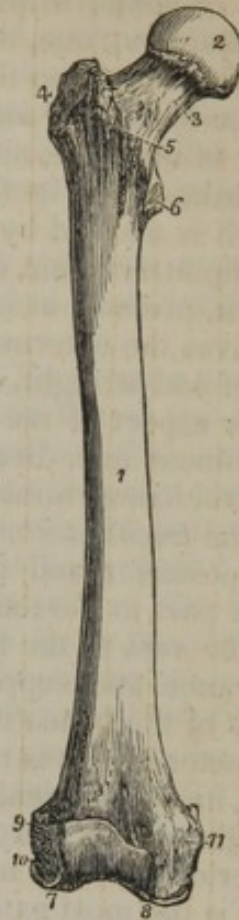


tibia. In the erect position of the body, its general direction is not vertical; it gradually inclines inwards towards the lower part, so that the bones of opposite sides, though separated at a considerable distance where they are connected with the pelvis, approach each other inferiorly, and come nearly in contact. The degree of this inclination varies in different persons, and is more marked in the female than the male. The femur presents a central part or body, and two extremities.

The *body*,<sup>1</sup> or *shaft*, as it is sometimes called, compressed, but nearly cylindrical towards the centre, and at the same time slightly convex or arched forwards, is expanded superiorly and inferiorly. Its anterior surface, convex and smooth, is broader towards the lower than the upper extremity. Both its lateral surfaces are compressed and somewhat flat; but it may be observed that the external is somewhat concave: it affords attachment to the vastus externus muscle. The surface, which superiorly looks inwards, is, in the lower third of the bone, inclined somewhat backwards, and gives attachment to the vastus internus. The anterior surface is separated, though not in a very marked degree, from the lateral surfaces by two lines, which may be traced upwards from the condyles, towards the superior extremity of the bone; but posteriorly, at the union of the two lateral surfaces, is a rough and prominent line (*linea aspera*), which gives attachment to several muscles.

The *linea aspera* is most prominent towards the centre of the bone, and, when examined with attention, presents two margins and a rough interstice, each giving attachment to muscles. Above and below the centre, it subsides as it were towards the extremities, and also becomes bifurcated. The two superior divisions or branches of the line terminate, the one (internal and somewhat shorter) at the lesser trochanter; the other, external, at the greater trochanter; in the course of the latter a rough and often strongly-marked ridge exists, which gives insertion to the gluteus maximus. The inferior divisions spread more asunder, and terminate at the condyles, enclosing between them and the margins of these prominences, a flat triangular portion of the bone, which corresponds with the popliteal vessels. Towards the superior part of the *linea aspera* may be observed a foramen directed from below upwards, which transmits the medullary vessels.

[Fig. 93.]



The right femur, seen upon the anterior aspect. 1. The shaft. 2. The head. 3. The neck. 4. The great trochanter. 5. The anterior intertrochanteric line. 6. The lesser trochanter. 7. The external condyle. 8. The internal condyle. 9. The tuberosity for the attachment of the external lateral ligament. 10. The fossa for the tendon of origin of the popliteus muscle. 11. The tuberosity for the attachment of the internal lateral ligament.—W.]



At the *superior extremity* of the bone is placed its neck, which is directed upwards and inwards, so as to form an obtuse angle with the body or shaft; at its point of union with the latter are two eminences (trochanters), one, the larger, on the outer, the other on the inner side; it is from between these that the neck arises.

The *trochanter major*<sup>4</sup> is prolonged from the external surface of the body of the bone, and nearly in a line with its axis. This apophysis, quadrilateral in its form, is convex and rough on its external surface, which is marked by a line directed obliquely downwards and forwards for the attachment of the gluteus medius; the internal surface, of less extent, presents at its base a pit (*trochanteric* or *digital fossa*,) which receives the external rotator muscles; its superior, or terminal border, is flat and straight, and the posterior thick and rounded. At the posterior aspect of the great trochanter may be observed an oblique and prominent line, directed downwards and inwards, and terminating in the trochanter minor.

The *trochanter minor*,<sup>5</sup> a conical rounded eminence, projects from the posterior and inner side of the bone, and gives attachment at its back part to the tendon of the psoas and iliacus muscles.

The *neck* of the femur,<sup>3</sup> which is so named from its constricted appearance and supporting the head, forms an obtuse angle with the body of the bone; it is compressed from before backwards, so that its diameter in this is much less considerable than in the vertical direction, in which greater power of resistance is required, for sustaining the weight of the body; its anterior surface is broad and smooth; the superior, inclined upwards, is short and somewhat concave; the inferior is the most extensive. The union of the neck with the rest of the bone is marked by the trochanters and two intervening oblique lines, (*inter-trochanteric*,) of which, the anterior one is rough, and but slightly prominent; the other, situated posteriorly, forms a smooth projecting ridge, which overhangs the trochanteric fossa.

The neck is surmounted by the globular *head*,<sup>2</sup> which forms a considerable segment of a sphere, is tipped with cartilage in the fresh state, and lodged in the acetabulum. A little beneath its most prominent point is a small cavity, which gives attachment to the round ligament.

The *inferior extremity* of the bone, much thicker and broader than the superior, is terminated by two eminences, separated posteriorly by a deep fossa; these are named condyles, of which one is internal, the other external.

The *external condyle*,<sup>7</sup> is larger, and projects forwards more than the internal; its articulating surface also is broader, and mounts higher up anteriorly; its external surface, rough and unequal, presents a deep pit,<sup>10</sup> inferiorly, which gives attachment to the tendon of the popliteus muscle; and immediately above it, a projection,<sup>9</sup> (*external tuberosity*,) which gives attachment to the external lateral ligament of the knee-joint.

The *internal condyle*<sup>8</sup> appears longer, and also to descend lower down than the other; but this is rather apparent than real, for, by means of the obliquity of the shaft of the bone, both condyles are



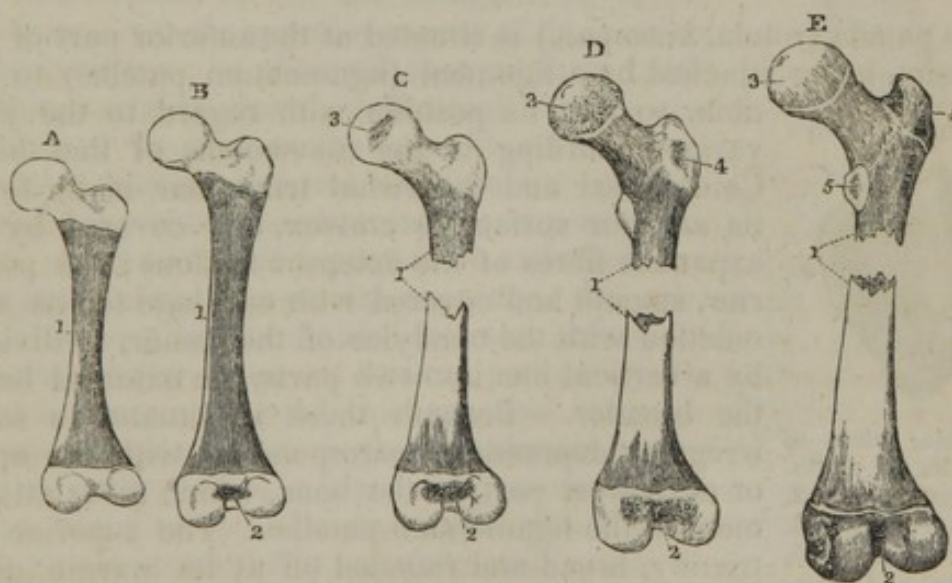
brought to the same plane. The internal condyle presents at its inner side a *tuberosity*,<sup>11</sup> which gives attachment to the internal lateral ligament of the knee-joint and the tendon of the adductor magnus.

The *articular surfaces* of both condyles, covered with cartilage in the fresh state, are united anteriorly where they form a pulley-like surface, concave from side to side, on which the patella glides. Inferiorly, these surfaces diverge as they pass backwards, and, when they terminate at the posterior surface of the bone, are separated by a considerable interval (*the inter-condyloid fossa*).

*Articulations.*—The femur articulates superiorly with the acetabulum; by its condyles with, inferiorly, the tibia, and, anteriorly, the patella.

*Attachments of muscles.*—To the anterior surface, the crureus and the sub-crureus; to the two lateral surfaces and to both lips of the linea aspera, the vastus internus and externus; to the centre of that line, the adductors and the short head of the biceps flexor; to the outer surface of the trochanter major, the gluteus medius; to the anterior part of its upper border, the gluteus minimus; to the fossa, at its posterior surface, the other external rotators; to the posterior part of the same border, the pyramidalis; to the posterior part of the lesser trochanter, and to a small portion of the line below it, the tendon of the psoas and iliacus; to the line descending from the great trochanter, posteriorly, the quadratus femoris; to the line below the lesser trochanter, the pectineus; to the rough impression beneath the great trochanter, the gluteus maximus; just above the inner and the outer condyle, the corre-

Fig. 100.



Successive stages of the growth of the femur are shown in these figures, up to the time when the union only of the parts is wanting to the completion of the bone.

A. Ossification has extended from the primitive centre over the shaft of the femur. The preparation was taken from the body of a fetus of eight months. B. A nucleus is apparent in the interval between the condyles. This illustrates the condition of the bone in a full-grown fetus. C. A granule is added in the head. D. One is present in the great trochanter, and E. in the smaller trochanter.

1. The shaft. 2. The lower extremity. 3. The head. 4. The great trochanter. 5. The small trochanter.



sponding heads of the gastrocnemius; above the external condyle, the plantaris; to the fossa beneath the external tuberosity, the popliteus.

*Ossification.*—The femur begins to ossify before the vertebræ, and the process is first apparent at the middle of the shaft. From the osseous ring formed in this position, the ossification extends towards both ends, ultimately involving the shaft and neck of the bone (fig. 100). As it advances on the last-named part (the neck), osseous matter will be found first on its lower surface (B, C.)

*Epiphyses.*—The first of these additional centres of ossification appears in the lower end of the bone (B.<sup>2</sup>), in the last month of fœtal life, and from it the entire of the lower extremity of the femur (including both the condyles and tuberosities) is constructed (C, D, E.<sup>2</sup>)

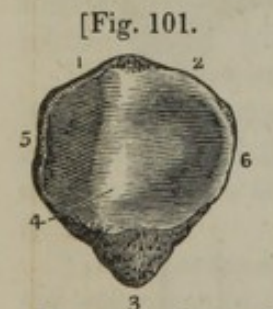In the end of the first year after birth a nucleus is discernible in the head (C.<sup>3</sup>), and the ossification radiates from it over the globular end of the bone (C, D, E.<sup>3</sup>)

The trochanters are distinct formations. Ossification begins in the larger (D.<sup>4</sup>) in the course of the fourth year,\* and it does not show itself in the smaller till a considerably later period—the thirteenth or fourteenth year (E.<sup>5</sup>)

*Consolidation.*—The order in which the epiphyses are joined to the rest of the bone is the reverse of that in which they appear: the small trochanter joins first, the great trochanter follows next, then succeeds the head, and lastly the lower epiphysis, whose ossification was the first to begin, ceases to be a separate piece. The bone is complete by the union of its parts after the twentieth year.

#### THE PATELLA.

The patella (rotula, knee-pan,) is situated at the anterior part of the knee-joint, being attached by a ligament (ligamentum patellæ) to the tibia, so that its position with regard to the joint



Posterior view of the patella. 1, 2. Superior extremity. 3. Inferior extremity. 4. Vertical elevation. 5, 6. Internal and external sides.—Smith and Horner.]

varies according to the movements of that bone. Compressed and somewhat triangular in its form, its anterior surface is convex, and covered by the expanded fibres of the extensor tendons; the posterior, smooth and covered with cartilage for its articulation with the condyles of the femur, is divided by a vertical line into two parts, the external being the broader. Beneath these is situated a small irregular depression, corresponding with the apex, or narrowest part of the bone, which gives attachment to the ligamentum patellæ. The superior extremity, broad and rounded off at its margin, gives attachment to the extensor muscles; the inferior, narrow and pointed, to the ligament already named; the lateral borders are convex, the external being thinner than the internal.

The patella is ossified from a single centre, which, according to Béclard, is apparent in the middle of the third year.

\* In the thigh-bones taken from the body of a child, stated with correctness (as well as could be judged) to have been three years and a half old, I found at the base of each great trochanter a granule of bone equal in size to half a common pea.



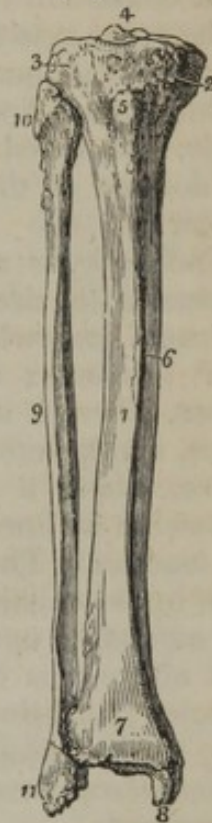
## THE TIBIA.

The tibia, next to the femur, is the longest bone in the skeleton; situated at the anterior and inner side of the leg, it alone receives from the femur (under which it is placed vertically) the weight of the trunk, and communicates it to the foot. Like the other long bones, it is divided into a body and two extremities.

The *superior extremity*, fig. 102,<sup>4</sup> much thicker and more expanded than any other part of the bone, (being proportioned in size to the lower extremity of the femur,) is broader from side to side than from before backwards; its circumference is somewhat rounded and convex in front and at the sides, but slightly hollowed posteriorly; at the fore part, a little below the head, is situated an eminence,<sup>5</sup> sometimes called the anterior tuberosity, more properly the *tubercle*, which is somewhat rough at its lower part, for the attachment of the ligament of the patella, and smooth superiorly, where it corresponds to a small synovial bursa, intervening between that ligament and the bone. On the sides, and above this, are two rounded eminences (*tuberosities*), the external one<sup>3</sup> being somewhat smaller than the other,<sup>2</sup> and marked posteriorly by a flat surface, which articulates with the head of the fibula; these processes give attachment to the lateral ligaments of the knee-joint. On the superior aspect of this portion of the bone may be observed two concave cartilaginous surfaces, (*condyles*), which sustain the condyles of the femur; the internal one is somewhat the deeper; its greatest diameter is from before backwards; the external one is nearly circular. In the interval between the articular surfaces is situated a pyramidal eminence,<sup>4</sup> the summit of which is usually divided into two tubercles; it is named the spine or spinous process of the tibia; before and behind this are two irregular depressed surfaces, which give attachment to the crucial ligaments and to the semilunar cartilages.

The *lower or tarsal extremity*<sup>7</sup> of the bone is much smaller than the upper, and nearly quadrilateral in its form; the anterior surface, convex and smooth, is bounded below by a slightly rough margin which gives attachment to the anterior tibio-tarsal ligament; the posterior is flat, and slightly marked by a groove for the flexor longus pollicis: the external, slightly concave, is rough superiorly, for the attachment of the transverse ligament, and smooth below, to receive the extremity of the fibula. From the inner border of this end of the

[Fig. 102.]



The tibia and fibula of the right leg, articulated and seen from the front. 1. The shaft of the tibia. 2. The inner tuberosity. 3. The outer tuberosity. 4. The spinous process. 5. The tubercle. 6. The internal or subcutaneous surface of the shaft. 7. The lower extremity of the tibia. 8. The internal malleolus. 9. The shaft of the fibula. 10. Its upper extremity. 11. Its lower extremity, the external malleolus. The sharp border between 1 and 6 is the crest of the tibia.—W.]



bone projects downwards a triangular apophysis,<sup>6</sup> the *internal malleolus*; the inner surface of which is convex, and covered merely by the skin, the external is smooth, and articulates with the side of the astragalus; the anterior forms a rounded border, whilst the posterior is marked by two grooves for the tendons of the *tibialis posticus*, and *flexor longus digitorum*; to the most dependent part of the process is attached the internal lateral ligament. The lower articular surface of the tibia, or that part which enters into the formation of the ankle-joint, consists of two parts, one vertical, just described as being situated at the outer side of the malleolus; the other horizontal in its direction, concave and quadrilateral in its form, divided into two parts by a slightly raised line; of these two surfaces, which are united at a right angle, and tipped with cartilage in the fresh state, the latter rests on the dorsum of the astragalus, the former is applied to its inner flat border.

The *body* or *shaft*<sup>1</sup> of the tibia, triangular in its form, diminishes gradually in size for about two-thirds of its length, after which it increases somewhat towards its lower extremity. The *internal surface*<sup>6</sup> is convex and subcutaneous, except at the upper part of its extent, where it is covered by the tendons of the *sartorius*, *semi-tendinosus*, and *gracilis* muscles. The *external surface*, slightly hollowed above, where it gives origin to the *tibialis anticus*, is convex, and somewhat inclined forwards below,<sup>7</sup> where it is covered by the extensor tendons. The *posterior surface* is very deeply seated; not so uniform in its outline as the others, it is marked at its upper third by a line extending upwards and outwards to the external tuberosity; the part above this is triangular, and gives attachment to the *popliteus* muscle; that below it to the *tibialis posticus* and *flexor digitorum*; and from the line itself arises the *soleus*. Near this line may be observed a *medullary foramen* of large size, whose direction is from above downwards.

The surfaces here indicated are separated by an equal number of borders. The *anterior border*, more or less sinuous in direction, sometimes considerably curved, is for the most part subcutaneous; sharp and prominent, especially towards the middle, and hence named the *crista* or *spine* of the tibia; it subsides towards the lower end of the bone, as if to allow a smooth surface for the passage forwards of the vessels and muscles, which superiorly are placed on the outer side. The *inner border*, thick and rounded, gives attachment to the *soleus* and *flexor longus digitorum*; whilst the *external*, somewhat sharp, divides inferiorly into two lines, which diverge towards the surface of articulation with the fibula. The interosseous ligament is inserted into this external border. The body of the tibia is slightly twisted, so that the internal tuberosity inclines a little backwards, and the internal malleolus forwards, which conformation deserves attention in the diagnosis and adjustment of fractures.

*Articulations.*—The tibia articulates with the femur, the fibula, and the astragalus.

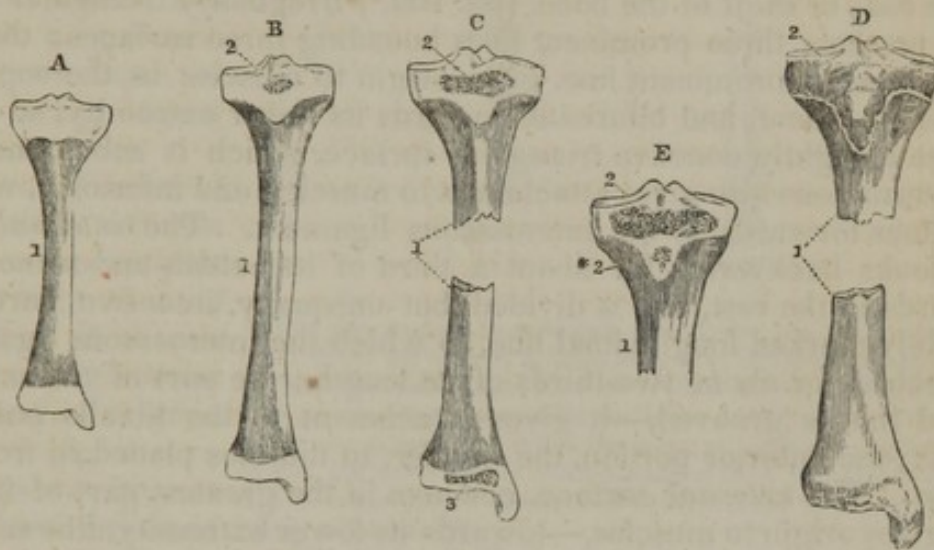
*Attachments of muscles.*—To the external surface and external tuberosity, the *tibialis anticus*; to the latter also, the head of the extensor



longus digitorum; to the inner surface, the sartorius, gracilis, semi-tendinosus, and semi-membranosus; the popliteus to the triangular space on the posterior surface; the soleus, tibialis posticus, and flexor longus digitorum to the rest of its extent, and, through the medium of the patella and its ligament, it may be said to give insertion to the extensors of the leg.

*Ossification.*—The tibia is formed from one principal centre of ossification and two for epiphyses. The process begins at the middle of the bone, about the same time as in the femur,—M. Cruveilhier mentions a case in which it preceded that bone,—and from this point extends over the shaft (fig. 103.<sup>1</sup>)

Fig. 103.



A. This figure represents the state of the tibia some time before the usual period of birth. The shaft is ossified, the ends of the bone are cartilaginous. In B. (taken from a full-grown fœtus) the osseous centre of the upper epiphysis is discernible; and in C. that of the lower one is added. D. The lower end of the bone has been completed by the junction of the epiphysis, the upper one is still separable. E. There is in this case a second centre for the superior epiphysis.

1. The shaft. 2. The superior epiphysis. 2\*. A second granule for the same. 3. The inferior epiphysis.

*Epiphyses.*—A small osseous nucleus is apparent in the upper extremity of the tibia in the full-grown fœtus (or, according to most authorities, in the first year after birth\*) (B. c.<sup>2</sup>); and the epiphysis when fully formed is flat, with a thin pointed elongation in front for the anterior tuberosity of the bone (D.<sup>2</sup>).

In the second year osseous matter is manifest in the cartilage of the lower extremity at its middle, and it extends from this as a centre over the entire of that part of the bone, including the malleolus.

The epiphyses join the shaft between the eighteenth and the twenty-fifth year; the inferior preceding the other by a considerable time (D.).

Peculiarities are occasionally met with in the manner of the ossi-

\* Albinus, Béclard, Cruveilhier, and others, date the commencement of ossification in this epiphysis in the first year after birth. But Nesbitt and Meckel state that bony matter is present at the usual time of birth, and I have found it so in two cases, while engaged in preparing these sheets for the printer. This difference respecting a fact so easily ascertained, suggests the probability that the period actually varies.



fication of the epiphyses. I have observed a separate nucleus in the tongue-shaped process of the superior one (E.<sup>2</sup> \*); and Bécclard has recorded an example of the malleolus being formed from an independent centre.

#### THE FIBULA.

This bone (fibula, peroné, *περονή*, a clasp,) is situated at the external side of the leg; it is nearly equal to the tibia in length, but is much more slender. When the fibula is placed beside the tibia in its natural position, its lower extremity will be found a little farther forward than the upper one, and its shaft inclined backwards and a little inwards so as to be convex in that direction.

The *body* or *shaft* of the bone, (fig. 102,<sup>9</sup>) irregularly triangular in its form, presents three prominent lines bounding three surfaces; the anterior, or most prominent line, gives origin to muscles in the superior part of its extent, and bifurcates towards its lower extremity, so as to enclose a slightly concave triangular surface, which is subcutaneous; the internal one also gives attachment to muscles, and inferiorly, where it inclines forwards, to the interosseous ligament. The *internal* surface looks backwards for about a third of its extent, and somewhat forwards in the rest, and is divided, but unequally, into two parts, by a slightly marked longitudinal line, to which the interosseous ligament is attached for about two-thirds of its length; the part of the surface behind this is grooved,—it gives attachment to the tibialis posticus muscle; the anterior portion, the smaller, to muscles placed in front of the leg. The *external* surface, concave in the greatest part of its extent, gives origin to muscles,—towards its lower extremity, this surface is inclined backwards, conforming with the peronei muscles, which are connected with the superior part of the bone, and incline in that direction to pass behind the external malleolus. The *posterior* surface, convex and smooth, affords attachment to muscles, and presents towards its middle a small foramen, directed obliquely downwards for the transmission of the medullary vessels; in the lower part it inclines inwards, and is terminated by a rough surface connected with the tibia.

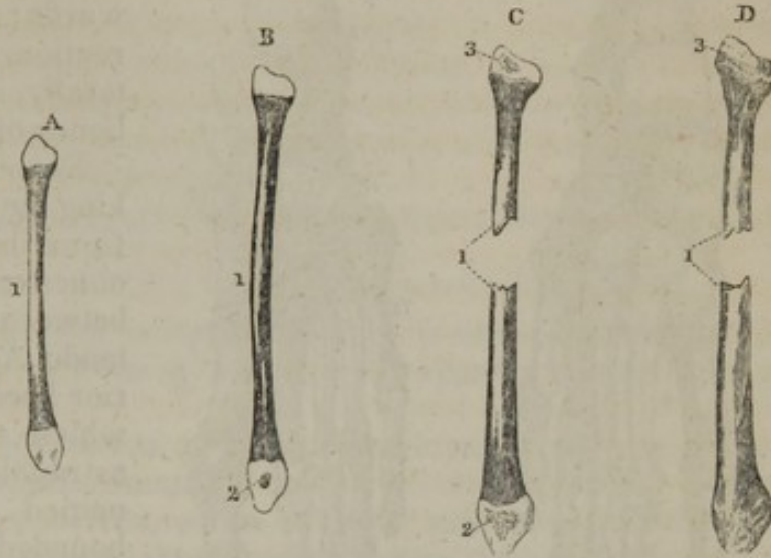
The *superior extremity*<sup>10</sup> of the bone, called also *the head*, is smaller than the inferior one; it presents on the supero-internal part a small oval and nearly flat surface, for its articulation with the corresponding part of the external tuberosity of the tibia; the remainder is unequal, and gives insertion to the biceps flexor cruris, to the external lateral ligament of the knee-joint, and to those which connect the tibia and fibula. The *inferior* or *tarsal extremity*<sup>11</sup> forms the *external malleolus*, which is longer and more prominent than the internal one: in front it projects rather abruptly forwards; behind is situated a shallow groove traversed by the tendons of the peronei muscles; the outer side is convex and subcutaneous; the inner presents a small triangular surface, convex in the perpendicular, and nearly plain in the antero-posterior direction, which articulates with the astragalus, and is bounded posteriorly by a rough depression, affording attachment to the transverse ligament of the ankle-joint, whilst the apex gives origin to the external lateral ligament.



*Articulations.*—The fibula articulates at both extremities with the tibia, and at the inferior one with the outer border of the astragalus.

*Attachments of muscles.*—The internal surface, by its anterior portion, to the extensor communis digitorum, extensor proprius pollicis, and peroneus tertius; by the depression on its posterior part, to the tibialis posticus: the external surface, to the peronei; the posterior surface, to the soleus and flexor longus pollicis; its head, to the biceps flexor cruris.

Fig. 104.



The ossification of the shaft of this bone occurs a little later than that of the tibia. Both ends are cartilaginous at the ordinary time of birth (fig. 104, A.)

The epiphyses are likewise formed after those of the

tibia. Their ossification begins with the lower one, in which an osseous granule appears in the second year (B.<sup>2</sup>); and a commencement of the process is discernible in the upper epiphysis, between the third and the fourth year (C.<sup>3</sup>)

*Consolidation.*—Contrary to the order which prevails in the union of the parts of the femur and the tibia, that epiphysis of the fibula which is the first to take on the osseous state, namely, the lower and larger one, is at the same time the first to join the shaft of the bone (D.) The parts appear to unite somewhat later than in the tibia; the consolidation is complete between the twentieth and twenty-fifth year.

## BONES OF THE FOOT.

The foot is composed, like the hand, of three parts, viz. the tarsus, metatarsus, and toes; their upper and under aspects are shown in fig. 105 and 106. These parts will in the first place be described separately, and they will then be reviewed in their connexion one with the other, constituting the framework of the foot.

### TARSUS.

The tarsus is composed of seven bones, viz. the os calcis, astragalus, cuboid, scaphoid, and three cuneiform.



## THE CALCANEUM.

This bone, fig. 105,<sup>3</sup> (os calcis—calcaneum,) is situated at the posterior and inferior part of

[Fig. 105.

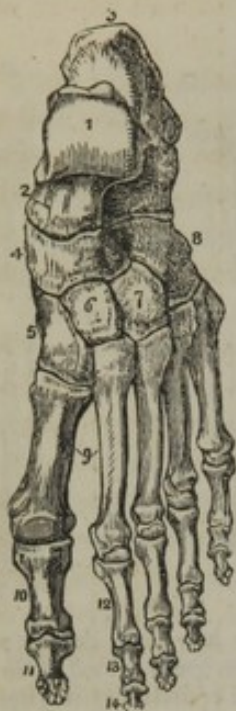

Fig. 106.

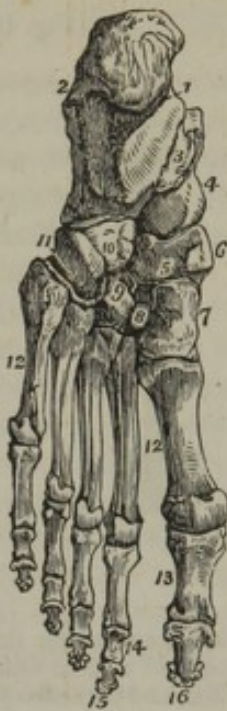

Fig. 105. The dorsal surface of the left foot. 1. The astragalus; its superior quadrilateral articular surface. 2. The anterior extremity of the astragalus, which articulates with (4) the scaphoid bone. 3. The os calcis. 4. The scaphoid bone. 5. The internal cuneiform bone. 6. The middle cuneiform bone. 7. The external cuneiform bone. 8. The cuboid bone. 9. The metatarsal bones of the first and second toes. 10. The first phalanx of the great toe. 11. The second phalanx of the great toe. 12. The first phalanx of the second toe. 13. Its second phalanx. 14. Its third phalanx.

Fig. 106. The sole of the left foot. 1. The inner tuberosity of the os calcis. 2. The outer tuberosity. 3. The groove for the tendon of the flexor longus digitorum; this figure indicates also the sustentaculum tali. 4. The rounded head of the astragalus. 5. The scaphoid bone. 6. Its tuberosity. 7. The internal cuneiform bone; its broad extremity. 8. The middle cuneiform bone. 9. The external cuneiform bone. 10, 11. The cuboid bone. 11. Refers to the groove for the tendon of the peroneus longus: the prominence between this groove and figure 10 is the tuberosity. 12. The metatarsal bones. 13. The first phalanges. 14. The second phalanges of the four lesser toes. 15. The third, or ungual phalanx of the four lesser toes. 16. The last phalanx of the great toe.—W.]

the tarsus, and forms the heel by its projection backwards; elongated in that direction, and compressed laterally, it is the largest of the bones of the foot.

*Superiorly* it presents (taking the objects successively from behind forwards) a concave portion, intervening between the insertion of the tendo Achillis into its posterior border, and the surface which articulates with the astragalus; then the last-named surface, which is bounded by a rough depression for the insertion of a ligament (interosseous), and lastly a narrow concave surface, which also articulates with the astragalus. On the *inferior surface*, which is narrower than the preceding, and broader behind than before, are observed posteriorly two tubercles, fig. 106,<sup>1 2</sup> (the internal being the larger,) serving for the attachment of the plantar fascia and the superficial plantar muscles; between them a depression for the origin of the long plantar ligament, and in front another eminence, giving attachment to the inferior ligament (calcaneo-scaphoid) connecting this bone with the scaphoid. The *anterior surface*, the smallest,

is slightly concave, and articulates with the cuboid bone. The *posterior surface*, convex, forms a rough projection inferiorly, (tuber calcis,) which receives the attachment of the tendo Achillis, and is continued into the tubercles, on the lower surface of the bone, more especially the inner one. The upper part of the posterior surface, less prominent



and smooth, is, in part, separated from the tendo Achillis by a synovial bursa. The *external surface*, nearly flat, broader behind than before, presents in the latter direction superficial grooves, for the tendons of the peronei muscles, and is subcutaneous in the rest of its extent. The *inner surface*, deeply concave, is traversed by the plantar vessels and nerves, and the tendons of the flexor muscles. At the anterior and upper part of this surface is a prominent process, which deepens the concavity; it is grooved beneath for the tendon of the flexor longus pollicis, and above contributes to form the concave articular surface which supports the fore part of the astragalus, and hence the name "*sustentaculum tali*" applied to it.\*

The calcaneum articulates with the astragalus and the cuboid bone.

#### THE ASTRAGALUS. (TALUS.)

The astragalus, fig. 105,<sup>1</sup> (*αστραγαλος*, a die,) is situated at the superior part of the tarsus; its form is irregular; it appears as if twisted on itself.

The *upper surface* presents, in front, a rough and slightly excavated part, serving for the attachment of ligaments; and behind it a large convex cartilaginous surface, which is longer and more prominent on the outer than on the inner side, broader before than behind, and articulated with the lower extremity of the tibia. On the *outer* and *inner sides* are situated two smooth surfaces, (the former the larger,) which are continuous with the preceding, and articulated with the inferior extremities of the tibia and fibula (the *malleoli*). On the *inferior surface* are observed, in front and somewhat internally, a narrow convex surface, and behind, a broad concave one, both articulating with the os calcis; these are separated by a groove, which receives the ligament that proceeds upwards from the last-named bone. The *anterior surface*, convex, is received into the hollow in the scaphoid bone; it is called the *head*, and the constricted part by which it is supported, the *neck* of the astragalus. The *posterior surface*, or rather border, is grooved and traversed by the tendon of the flexor longus pollicis.

The astragalus articulates with the tibia and fibula above, with the os calcis below, and with the scaphoid in front.

#### THE CUBOID BONE.

This bone, fig. 105,<sup>2</sup> (*os cuboides*, *cuboideum*,) is situated at the external side of the tarsus; its form is indicated by its name.

The *superior surface*, rather rough, inclined obliquely outwards and upwards, gives attachment to ligaments. The *inferior surface*, (fig. 106,) presents in front a depression, traversed by the tendon of the peroneus longus muscle, in the middle a transverse ridge, (tuberosity,<sup>10</sup>) and behind it an irregular surface, both of which give attachment to the calcaneo-cuboid ligament; the former also to some fibres of the ligamentum longum plantæ. At the *anterior aspect* of the bone is a smooth surface, directed from without inwards and forwards, and

\* Or "*sustentaculum cervicis tali*,"—"Albini de scelecto liber," p. 302-4.



divided into two parts, the internal one being square, the external triangular, and articulated, the former with the fourth, the latter with the fifth metatarsal bone; at the posterior is a surface by which it articulates with the os calcis. The *external border*, which is short and rounded, presents a groove<sup>11</sup> continuous with that on the inferior surface, and serving for the transmission of the tendon of the peroneus longus muscle. On the *internal surface* may be observed, towards its middle, an elongated, smooth, and nearly flat portion, which articulates with the third cuneiform bone, the part before and behind it being rough for the attachment of ligaments. This surface likewise often articulates with the scaphoid.

The cuboid articulates with the fourth and fifth metatarsal bones before, with the os calcis behind, with the external cuneiform, and sometimes with the scaphoid.

#### THE SCAPHOID BONE.

The scaphoid or navicular bone, (fig. 105,<sup>4</sup>) [os scaphoideum], so named from its excavated form (*σκαφη*, *navis*), is placed at the inner border of the foot, between the astragalus, and the cuneiform bones.

It presents a concave surface which looks backwards, and a convex one which is turned forwards. Its inner margin projects in the form of a tubercle toward the sole of the foot. Upon its upper and inner surface are inequalities for the attachment of ligaments,—behind, a concavity for the head of the astragalus,—in front, three distinct surfaces for articulation with the three cuneiform bones; at its lower and inner border is the prominence or tubercle, above noticed, which gives attachment to the tibialis posticus muscle; on the outer side, in some instances, is a small articular surface, by which it is united to the cuboid bone.

It articulates with the three cuneiform bones, with the astragalus, and sometimes with the cuboid.

#### THE CUNEIFORM BONES.

These bones, (figs. 105, 106,) (*ossa cuneiformia*, wedge-shaped,) constitute the anterior and inner part of the tarsus; the name expresses their form. In number three, they are distinguished by their numerical order from within outwards.

The first is the largest, and has its base or broad border turned down into the sole of the foot,—the second, or middle, the smallest. The base, or broad border, of the second and third is at the upper or dorsal surface of the foot, and contributes to give it its arched form. They articulate behind with the navicular, and in front with the first, second, and third metatarsal bones. In consequence of their excess in length over the second, the first and third, in addition to articulating laterally with the corresponding sides of that bone, they are in apposition with the base of the second metatarsal bone, which is inserted between them. The inner side of the first is subcutaneous, and the outer side of the third articulates, by a smooth flat surface, with the cuboid, and by a small linear facet with the fourth metatarsal bone.

*Attachments of muscles to the tarsal bones.*—The os calcis, by its



dorsal surface, to the extensor brevis digitorum pedis; the inferior half of the posterior surface to the common tendon of the gastrocnemius and soleus (*tendo Achillis*), and to that of the plantaris; the inferior surface on the inner side, to the flexor accessorius, and part of the abductor pollicis: on the outer side, to the abductor digiti minimi; and between the two abductors, to the flexor brevis digitorum.

The cuboid bone, by the inferior surface, to a portion of the adductor pollicis and flexor brevis pollicis.

The scaphoid bone, by its tuberosity, to a portion of the tendon of the tibialis posticus.

The cuneiform bones. The first, by its base, to portions of the tendons of the tibialis anticus and posticus, and the second and third to part of the flexor brevis pollicis.

#### METATARSAL BONES.

The metatarsus, (figs. 105, 106,) the second division of the foot, is placed between the tarsus and the toes, and consists of five bones, one for each toe. They are separated, except at their posterior extremities, where they are in contact, by four interspaces, (*interosseous spaces*,) which decrease in size from the inner to the outer side of the foot. These bones are named according to their numerical order from within outwards—that of the great toe being the first, and that of the little toe, the fifth or last; and the interosseous spaces are named in the same manner.

*Common characters of the metatarsal bones.*—They are long bones in miniature, and, like them, each may conveniently be considered to consist of a body and two extremities.

The *bodies* are in the longitudinal direction, somewhat concave on the plantar and convex on the dorsal aspect; and they have each, with more or less regularity, three sides and as many borders. One side corresponds with the dorsum of the foot, and the others bound the interosseous space.

The *posterior* or *tarsal ends* (*bases*) of these bones are broad and squared on the dorsal surface, and becoming narrower in the opposite direction they contribute in consequence of their cuneiform or wedge shape to the general transverse arching of the foot. They terminate behind with plane articular surfaces for connexion with the tarsal bones; and, with exceptions to be noticed presently, they have likewise small articular faces on their sides, where they are in contact one with another.

The *anterior* or *digital ends* (*heads*).—In front, the metatarsal bones are apart one from the other, and are marked on their sides by depressions and small tubercular projections. These are much smaller than the tarsal extremities, and they support the bones of the first phalanx of the toes by convex articular surfaces, which extend beneath the bones to their plantar aspect—the direction in which the toes are flexed.

While the metatarsal bones thus resemble one another in some respects, or have certain characters in common, each presents peculiarities which serve to distinguish it from its fellows.



*Special or individual characters.*—The great size is the most prominent distinctive mark of the *first*. It is much thicker, more massive, though shorter than any of the other bones. The tarsal end, or base, rough at its circumference, especially towards the plantar aspect, has no lateral articular facet, and wants the square shape which belongs to the others. The surface, which rests against the first cuneiform bone, is oval and slightly concave, and the joint formed between them is directed obliquely forwards and outwards. The digital end (*head*) forms the ball of the great toe. It is in contact, on the plantar surface, with two sesamoid bones; the part of the articular surface appropriated to these little bones is divided into two parts by a ridge, and is often grooved on one or both sides.

The *second* is the longest of the metatarsal bones. The posterior end has articular surfaces for the three cuneiform bones—it rests against the second, and is supported laterally by the first and third. On the outer side it is likewise articulated with the third metatarsal.

The distinction between the *third* and *fourth* is by no means so readily made as between others of the series. They have nearly the same length, but the third is slightly the longer. Moreover, the lateral articular surface on the inner side of the fourth is not so close to the end of the bone as it is on the neighbouring side of the third; from this it results, that, when the two bones are adapted one to the other in their proper relative position, the fourth projects behind the third; and this is necessary, in order that the bone should reach the cuboid, whose articular surface is in a corresponding degree behind that of the third cuneiform bone. It will likewise usually be found that the fourth has on its inner side, for connexion with the tarsal bone last mentioned (third cuneiform), a small additional facet, which would serve to characterize the bone.

The *fifth* is readily recognised by several striking characters, viz., the length, (which is less than that of any of the other metatarsal bones except the first,) the large size of its base, and some further peculiarities of this extremity: namely, the presence of a single lateral articular surface, (for the fourth metatarsal bone,) and a large rough tuberosity on the opposite side, which projects beyond the other bones at the outer side of the foot. This projection, which of itself at once distinguishes the fifth metatarsal bone, is readily felt through the integuments, and it marks, on the outer side, the position of the tarso-metatarsal articulation. The corresponding surfaces of this metatarsal bone and the cuboid are so oblique in direction, that, if a line drawn between them were extended across the foot, it would, on the inner side, reach the digital end of the first metatarsal bone.

#### PHALANGES OF THE TOES.

The number, form, and general conformation of the phalanges (figs. 105, 106,) of the toes correspond with those of the fingers, in so much that, besides referring to the description of the latter, as being likewise generally applicable to the bones before us, it will only be necessary to add a statement of some points of difference.

The principal difference consists in the much smaller size of the



phalanges of the foot. An exception is however afforded by the great toe, the bones of which are larger than those of the thumb.

In addition to the small comparative size of the first phalanx of the four outer toes, they have this further peculiarity, viz., that the bodies are compressed laterally; and the bodies of the second row are so short that little of these bones remains beyond what is necessary to support their articular surfaces. The last two phalangeal bones of the little toe are not unfrequently found connected by bony union in the skeletons of adults.

*Attachments of muscles* to the metatarsal bones and the phalanges of the toes.—The *first* gives attachment to the prolonged tendon of the peroneus longus, and the first dorsal interosseous muscle; the *second*, to the transversalis pedis, to the first and second dorsal interossei; the *third*, to part of the adductor pollicis, to three interossei, and part of the transversalis pedis; the *fourth*, to three interossei also, and the transversalis pedis; the *fifth*, to the peroneus brevis and tertius, the transversalis pedis, part of the flexor brevis minimi digiti, to the fourth dorsal and third plantar interosseous muscle.

The *first* phalanx of the great toe gives insertion to the extensor brevis digitorum and to the abductor, flexor brevis, and adductor pollicis, with the transversalis pedis; the *second* phalanx, to the extensor proprius pollicis and flexor pollicis longus. The *second* phalanges of the other toes receive the insertion of the tendons of the flexor sublimis and of the extensors; and the *third*, those of the flexor profundus and of the extensors.

#### SESAMOID BONES.

These do not properly form part of the skeleton; they may be considered as accessories to the tendons of muscles, and are found only in the limbs, never in the trunk. In the superior extremity, two are always found in the articulation of the metacarpal bone of the thumb with its first phalanx. In the lower extremity, two are frequently found behind the femoral condyles, and constantly beneath the first joint of the great toe, as well as in the tendons of the tibialis posticus and peroneus longus. They are situated in the direction of flexion (the only exception being the patella, which belongs to this class of bones), and serve the purpose of increasing the power of muscles, by removing them farther from the axis of the bone on which they are intended to act.

#### BONES OF THE FOOT AS A WHOLE.

The osseous framework of the foot, constructed from the parts above separately described—tarsus, metatarsus, and phalanges of the toes—is placed horizontally beneath the leg, which rests on its upper surface.

The posterior end (the heel), projecting behind the leg, is narrow and thick; the anterior part is broad, thinner, and expanded towards the toes. The upper surface ("dorsum" of the foot) is convex in two directions—longitudinally and from side to side. But in the latter direction the arch of the foot is much higher at the inner than at the



outer side; and it is towards the inner and more arched, which is at the same time the longer and more massive side, that the weight of the body is received from the leg. The lower or plantar surface (sole of the foot) presents corresponding concavities. From this shape it results, that, when resting on a plane surface, the heel, the digital ends of the metatarsal bones, the toes, and the outer part of the sole of the foot, are in contact with the surface; but the middle, especially towards the inner side, is elevated from it.

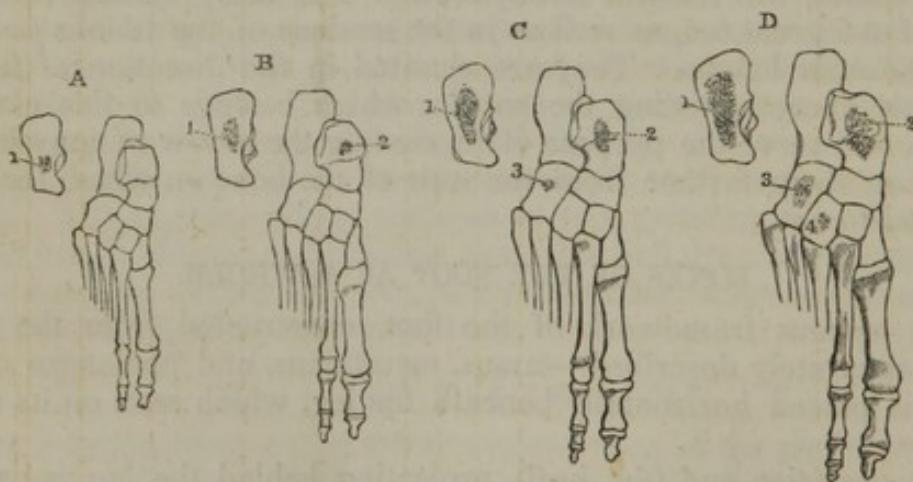
The constituent elements of the hand and foot are strictly analogous one to the other; but, by differences in the size and relative proportion of the parts, they are adapted to the very different uses of the limbs to which they respectively belong.

Thus: the prehensile organ is in the same line with the rest of the limb; the fingers are elongated, and comparatively free from the palmar part; and the thumb (including its metacarpal bone) has independent motion, and may be opposed to the other fingers. At the same time the carpus is small, serving only to connect the metacarpus to the bones of the fore-arm, and to contribute to the free motion of the wrist. On the contrary, the foot, an organ of support, is set on at right angles with the leg, and has no provision for the variety and facility of motion which belong to the upper limb. The toes, small in size, are cushioned at their roots by the soft parts of the sole of the foot, in which they are impacted; the great toe moves only with its fellows; and the tarsus is large in correspondence with the solidity required to bear the weight of the trunk. (For observations on the construction of the different parts of both limbs see *ante*, p. 166.)

#### OSSIFICATION OF THE TARSUS, METATARSUS, AND PHALANGES OF THE TOES.

*The tarsus.*—Each of the pieces of the tarsus is ossified from a

Fig. 107.



The progressive advance of ossification over the tarsus is here illustrated. The metatarsal bones and phalanges are largely ossified long before the period to which the earliest of these cases belongs. A. This has been taken from a fœtus about the sixth month; a nucleus is distinct towards the anterior part of the os calcis. B. The age being from the seventh to the eighth month, the astragalus has received an osseous deposit. C. From a full-grown fœtus;—the cuboid has begun to ossify. D. The period being the end of the first or beginning of the second year, a commencement of ossification is apparent in the external cuneiform.

1. Nucleus of the os calcis. 1.\* Fig. 108. Epiphysis of the os calcis. 2. Of the astragalus. 3. Of the cuboid. 4. Of the external cuneiform.



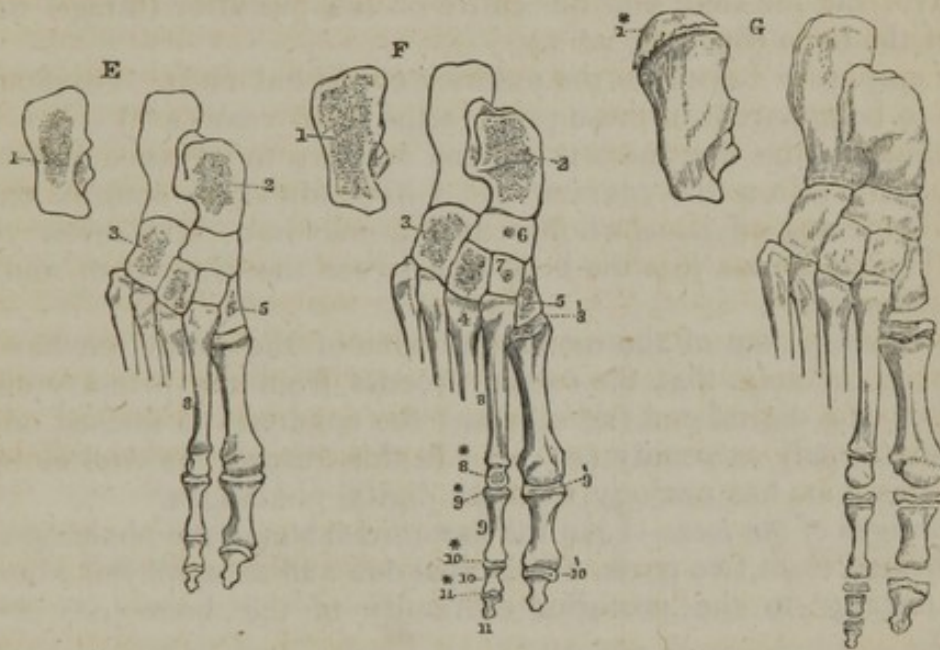
single centre, except the os calcis. The process of ossification begins at a much earlier period than in the corresponding part of the hand. It becomes apparent in the os calcis in the sixth month of foetal life (fig. 107, A.<sup>1</sup>), and about a month later in the astragalus (B.<sup>2</sup>).

In the full-grown foetus a nucleus is apparent in the cuboid (C.<sup>3</sup>); but many good observers state that this bone does not begin to ossify till after birth.\*

The external cuneiform succeeds to the cuboid, beginning to ossify in the course of the first year after birth (D.<sup>4</sup>).†

The ossification of the first or internal cuneiform follows—in the third year (E.<sup>5</sup>)

Fig. 108.



The progress of ossification in the foot is continued from fig. 107.—E. The state of the tarsus in the third year. Ossification has reached the internal cuneiform. Between the time to which this condition belongs and that to which the next figure is to be assigned, the epiphyses of the phalanges and metatarsal bones begin to form. F. The preparation here sketched was taken from the body of a child, stated to be between three and four years old. The middle cuneiform and scaphoid contain osseous nuclei; the former appears the more advanced. The epiphyses of the metatarsal bones and phalanges are partly ossified; the latter apparently more fully in proportion than the former. G. From the foot of a person about the age of puberty. The epiphysis of the os calcis is shown as if separated from the rest of the bone. The epiphyses of the metatarsal and phalangeal bones are separable, and have been represented apart from the shafts of the bones.

5. Nucleus for the first or internal cuneiform. 6. The scaphoid. 7. The middle cuneiform.—The numbers before those here explained correspond with those of figure 107, and those which follow them are noticed in the text.

The middle cuneiform and the scaphoid are the last to be developed.

\* Among others, Nesbitt, Albinus, and Béclard represent it to be cartilaginous at birth. Meckel specifically denies the correctness of the statement of Albinus, and describes the ossification to be far advanced at that time. The period of ossification mentioned by Wagner (in "*Sæmmerring v. Baue d. menschlich. Körpers*") agrees with that last mentioned: but this writer makes no reference to the grounds of his statement; neither does he refer to authorities, or to the difference among them.—In two cases, which I have lately examined, (full-grown foetuses,) a very distinct osseous nucleus was present in each of the cuboid bones.

† It is remarkable, that some anatomical writers, who treat of the growth of bones, (including Béclard,) attribute to the first (internal) cuneiform the earliest ossification after the cuboid. I possess preparations which clearly show that the external one (third) precedes the first cuneiform by a considerable period, and Meckel's observations led him to the same conclusion.



The deposit of osseous matter in them is apparent in the fourth year; and it is first discernible in the cuneiform bone (F.<sup>6 7</sup>)

*Epiphysis.*—Only one of the bones of the tarsus, the os calcis, has an epiphysis. It is formed as a concave incrustation on the posterior or free end of that bone (G.<sup>1\*</sup>) This additional piece begins to ossify about the tenth year, and is joined to the rest of the bone after puberty.

*Metatarsal bones.*—These bones are severally formed from two parts,—a principal piece and an epiphysis,—each of which has a single centre of ossification.

The process of ossification begins at a very early period, about the same time that it is distinguishable in the vertebræ. It is first discernible in the middle of the body, and extends from this towards each end, involving the shaft and the entire of the posterior (tarsal) extremity of the bone (fig. 108, F.<sup>8</sup> G.)

*The epiphyses* belong to the anterior or digital ends. Ossification begins to be apparent in these parts in the third year (F.<sup>8\*</sup>) It is first discernible in the first metatarsal, and appears to advance outwards, reaching the fifth a few years after. I have found the anterior end of the fifth metatarsal bone wholly cartilaginous in a child seven years old. The epiphyses join the bone at between the eighteenth and the twentieth year.

The development of the metatarsal bone of the great toe has this peculiarity, namely, that the ossific process from the primary centre extends to the digital end (F.<sup>8</sup> G.); and the epiphysis is formed on the opposite (tarsal) extremity (F.<sup>8'</sup> G.) In this respect, as well as in its shape, this bone has analogy with the digital phalanges.

*Phalanges of the toes.*—Like the metatarsal bones, the phalanges are each formed from two parts, a principal one and an epiphysis; but the latter belongs to the posterior extremity of the bone (F.<sup>9\*</sup> 10\* 11\* and G.)

The centres from which the bodies and the anterior ends of the phalanges of each toe are ossified become apparent some time after that of the corresponding metatarsal bone; and their epiphyses begin to ossify about the same time with the epiphysis of that bone. The ossification appears at an earlier period in the bones of the great toe than in the others, and latest in those of the little toe.\*

\* In the foot of a child aged seven years and a month, the ossification of the epiphyses had begun in the metatarsal bones and the phalanges of all the toes, except the fifth. The great toe was much more advanced than either of the rest.



## CELLULAR OR AREOLAR TISSUE.

---

IF we make a cut through the skin and proceed to raise it from the subjacent parts, we observe that it is loosely connected to them by a soft filamentous substance, of considerable tenacity and elasticity, and having, when free from fat, a white fleecy aspect: this is the substance known by the names of "cellular," "areolar," "filamentous," and "reticular" tissue; it is often also called "cellular membrane." In like manner the cellular tissue is found underneath the serous and mucous membranes which are spread over various internal surfaces, and serves to attach these membranes to the parts which they line or invest; and as under the skin it is named "subcutaneous," so in the last-mentioned situations it is called "subserous" and "submucous" cellular tissue. But on proceeding further we find this substance lying between the muscles, the blood-vessels, and other deep-seated parts, occupying, in short, the intervals between the different organs of the body where they are not otherwise insulated, and thence named "intermediate;" very generally, also, it becomes more consistent and membranous immediately around these organs, and, under the name of the "investing" cellular tissue, affords each of them a special sheath. It thus forms inclosing sheaths for the muscles, the nerves, the blood-vessels, and other parts. Whilst the cellular tissue might thus be said in some sense both to connect and to insulate entire organs, it also performs the same office in regard to the finer parts of which these organs are made up; for this end it enters between the fibres of the muscles, uniting them into bundles; it connects the several membranous layers of the hollow viscera, and binds together the lobes and lobules of many compound glands; it also accompanies the vessels and nerves within these organs, following their branches nearly to their finest divisions, and affording them support and protection. This portion of the cellular tissue has been named the "penetrating," "constituent," or "parenchymal."

It thus appears that the cellular is one of the most general and most extensively distributed of the tissues. It is, moreover, continuous throughout the body, and from one region it may be traced without interruption into any other, however distant; a fact not without interest in practical medicine, seeing that in this way dropsical waters, air, blood, and urine, effused into the cellular tissue, and even the matter of suppuration when not confined in an abscess, may spread far from the spot where they were first introduced or deposited.

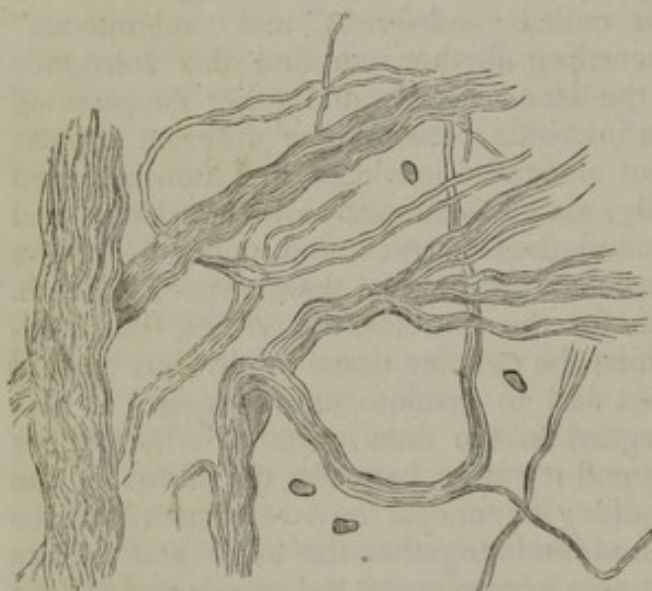
On stretching out a portion of cellular tissue by drawing gently asunder the parts between which it lies, it presents an appearance to the naked eye of a multitude of fine, soft, elastic threads, quite transparent and colourless, like spun glass; these are intermixed with fine transparent films or delicate membranous laminæ, and both threads and laminæ cross one another irregularly, and in all imaginable direc-



tions, leaving open interstices or areolæ between them. These areolæ are, of course, more apparent when the tissue is thus stretched out; it is plain also that they are not closed cells, as the term "cellular tissue" might seem to imply, but merely interspaces which open freely into one another: many of them are occupied by the fat, which, however, as already explained, does not lie loose in the areolar spaces, but is inclosed in its own vesicles. A small quantity of colourless transparent fluid is also present in the cellular tissue, but, in health, not more than is sufficient to moisten it. This fluid is generally said to be of the nature of serum; but it is not improbable that, when not unduly increased in quantity or altered in nature by disease, it may resemble more the liquor sanguinis, as is the case with the fluid of most of the serous membranes.

On comparing the cellular tissue of different parts, it is observed in

Fig. 109.



Filaments of cellular tissue, in larger and smaller bundles, as seen under a magnifying power of 400 diameters. Two or three corpuscles are represented among them.

some to be more loose and open in texture, in others more dense and close, according as free movement or firm connexion between parts is to be provided for. In some situations, too, the laminæ are more numerous; in others the filamentous structure predominates, or even prevails exclusively; but it does not seem necessary to designate these varieties by particular names, as is sometimes done.

When examined under the microscope, the cellular tissue is seen to be principally made up of exceedingly fine, transparent, and apparently homogeneous filaments, from about  $\frac{1}{13000}$  to  $\frac{1}{23000}$  of an inch in thick-

ness, or even less (fig. 109). These are seldom single, being mostly united into bundles and filamentous laminæ of various sizes, which to the naked eye appear as simple threads and films. Though the bundles may intersect in every direction, the filaments of the same bundle run nearly parallel to each other, and no one filament is ever seen to divide into branches or to unite with another. The associated filaments take an alternate bending or waving course as they proceed along the bundle, but still maintain their mutual parallelism. This wavy aspect, which is very characteristic of these filaments, disappears on stretching the bundle, but returns again when it is relaxed.

The filaments just described, though transparent when seen with transmitted light under the microscope, have a white colour when collected in considerable quantity and seen with reflected light; and they

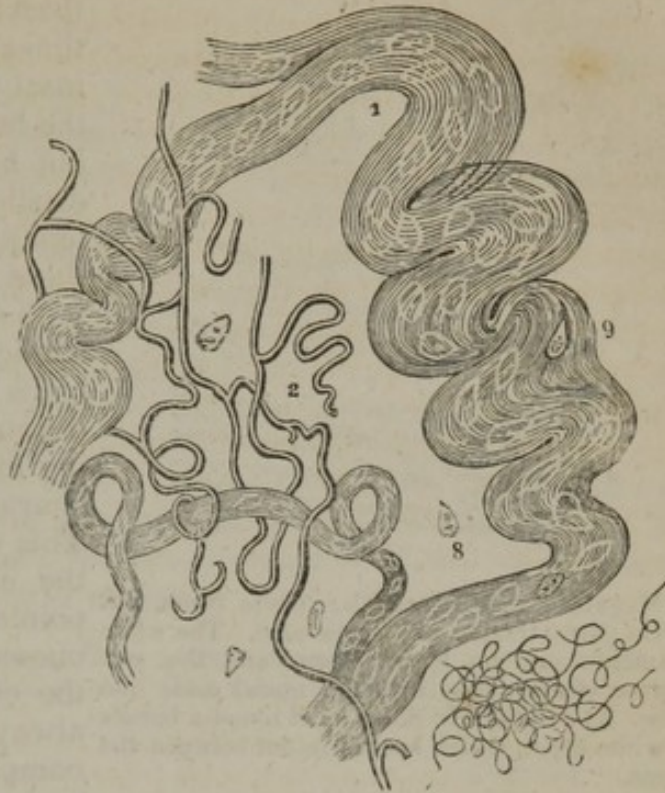

not only occur in the cellular tissue, strictly so called, but form the chief part of the tendons, ligaments, and other white fibrous textures. They were long supposed to be the only fibrous constituent existing in the cellular tissue, but it has lately been shown (and chiefly through the inquiries of Eulenberg, Henlé, and Bowman) that fibres of another kind are intermixed with them; these either are identical with the fibres of the yellow elastic tissue, or at least approach them very closely in character, and they have accordingly been named the yellow or elastic fibres, to distinguish them from the white or waved filaments above described. They were termed nuclear

fibres (Kernfasern) by Gerber and Henlé, on account of their supposed origin from nuclei; but as this opinion is at best but doubtful, the former appellation seems preferable.

In certain portions of the cellular tissue, as for instance in that which lies under the serous and mucous membranes in particular regions, the yellow or elastic fibres are large and abundant, so that they cannot well be overlooked; but in other parts they are few in number and small, and are then in a great measure hidden by the white filaments; in such cases, however, they can always be rendered conspicuous under the microscope by means of acetic acid, which causes the white filaments to swell up and become indistinct, whilst the yellow fibres, not being affected by that reagent, come then more clearly into view (fig. 111). Under the microscope these fibres appear transparent and colourless, with a strong, well-defined, dark outline. They are, moreover, remarkable for their tendency to curl up, especially at their broken ends, which gives them a very peculiar aspect (*b*), and in many parts of the cellular tissue they divide into branches and join or anastomose with one another, in the same manner as in

[Fig. 110.]

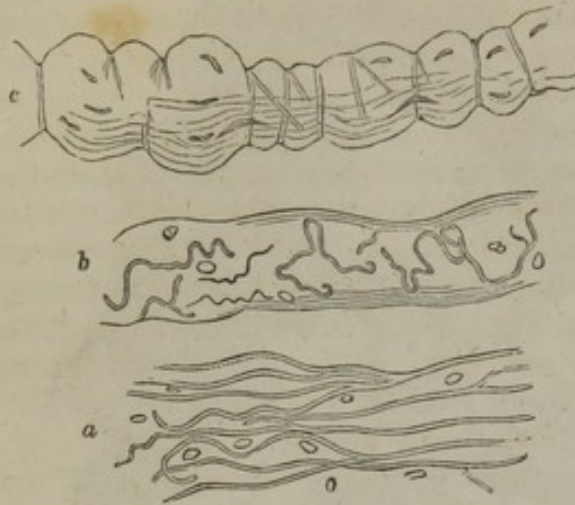

The two elements of areolar tissue, in their natural relations to one another:—1. The white fibrous element, with cell-nuclei, 9, sparingly visible in it. 2. The yellow fibrous element, showing the branching or anastomosing character of its fibrillæ. 3. Fibrillæ of the yellow element, far finer than the rest, but having a similar curly character. 8. Nucleolated cell-nuclei, often seen apparently loose.—From the areolar tissue under the pectoral muscle, magnified 320 diameters.—Todd and Bowman.]



the pure elastic tissue (a). They differ among themselves very widely

Fig. 111.



Magnified view of cellular tissue (from different parts) treated with acetic acid. The white filaments are no longer seen, and the yellow or elastic fibres with the nuclei come into view. At *c* the elastic fibres wind round a bundle of white fibres, which is swollen out between the turns.

in size, some being as fine as the white filaments, others many times larger. They lie for the most part without order among the bundles of white filaments; but here and there we see an elastic fibre, generally of great tenuity, winding round one of these bundles, and encircling it with several spiral turns. When acetic acid is applied, the fasciculus swells out between the constricting turns of the winding fibre, and presents a highly characteristic appearance (*c*). This remarkable disposition of the elastic fibres, which was pointed out by Henlé, is not uncommon in certain parts of the cellular tissue; it may be always seen in that which accompanies the arteries at the base of the brain.

A few rounded and oval corpuscles (fig. 109) and irregular particles are now and then met with in the interstices of the tissue, and others are seen attached to the surface of the filamentous bundles, or in their interior. The former are probably to be considered as belonging to the interstitial fluid. The latter, which are best seen after the application of acetic acid (fig. 111), are generally supposed to be of the nature of cell nuclei; many of them are elongated and attenuated, and they often appear disposed in longitudinal series on the surface of or within the fasciculi (*c*). As already mentioned, the elastic fibres, on this account also called nuclear, have been supposed to be produced by the junction of these elongated nuclei.

In reference to the structure of cellular tissue, it may be further remarked, that there are other textures of the body which are made up of the same elements; the tendons and ligaments, the periosteum, and other fibrous membranes, belong to this class.

The cellular tissue contains a considerable quantity of water, and consequently loses much of its weight by drying. It is almost wholly resolved into gelatin by boiling in water. Acetic acid causes it to swell up into a soft, transparent, jelly-like mass.

Numerous blood-vessels are seen in the cellular tissue after a minute injection. These for the most part only pass through it on their way to other more vascular textures, but a few seem to end in capillaries destined for the tissue itself, and dense clusters of vessels are distributed to the fat lobules. Large lymphatic vessels proceeding to distant parts also pass along this texture, and abundant lymphatic networks may



be discovered in many parts of the subcutaneous, subserous, and submucous cellular tissue, having evident relation to the function of the membranes under which they lie. Absorption readily takes place from the interstices of the texture, but that process may be effected through the agency of blood-vessels as well as of lymphatics.

Larger and smaller branches of nerves also traverse this tissue on their way to other parts; but it has not been shown that any remain in it, and accordingly it may be cut in a living animal apparently without giving pain, except when the instrument meets with any of these traversing branches. It is not improbable, however, that nerves end in those parts of the cellular tissue which, like that of the scrotum, contain contractile fibres; but, if present in such cases, the nerves, like the vessels of the fat, are, after all, destined not to the cellular tissue, but to another mixed with it.

The physical properties of this texture have been sufficiently indicated in the foregoing description; also its want of sensibility. The vital contractility ascribed to certain portions of it will be considered after discussing the subject of muscle.

The cellular tissue is developed from a blastema containing cells or nuclei, but the process is not yet fully understood. The chief statements regarding it have

[Fig. 112.]

Fig. 113.

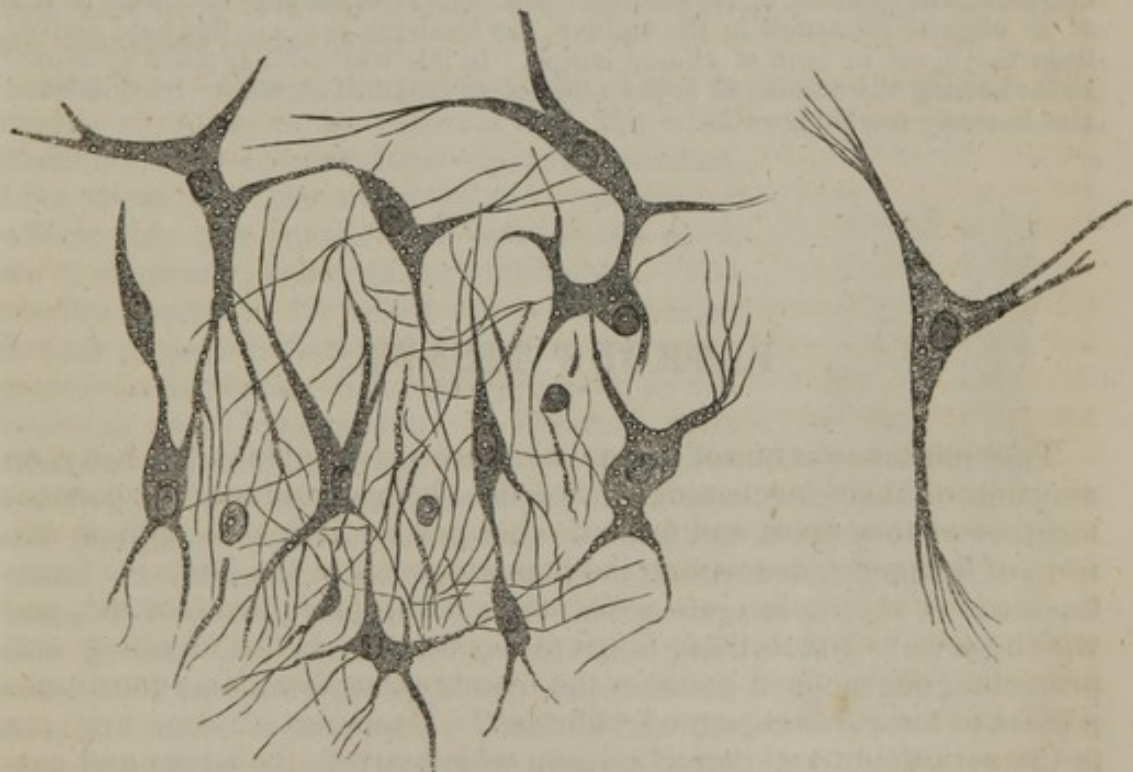


Fig. 112 represents a portion of areolar tissue in the process of development, highly magnified, from the inner surface of the amnion, enveloping the umbilical cord of a human embryo of seven weeks.

Fig. 113 represents an organic cell of the developing areolar tissue, isolated and highly magnified, exhibiting the division of the extremities of its prolongations into the ultimate filamentary structure.—From nature, by J. L.]



already been given at sufficient length (pages 65, and 67.) We may here add that it undergoes a change in chemical nature in the course of its development; for when the immature tissue is boiled in water, even for a long time, a considerable part remains undissolved, and the matter extracted from it is not gelatin, but agrees very nearly in chemical characters with the animal principle named "pyin." Perfectly-formed cellular tissue is found in the spinal region and some other parts as early as the beginning of the fourth month of intra-uterine life; but fasciculi are met with even in the adult, in which it seems probable that fibrils are not completely developed; in such cases the bundle appears to be merely striped or fluted longitudinally, and not divided into distinct threads.

[In a human embryo, of about seven weeks, I found a good position for studying the development of the cellular or areolar tissue to be upon the inner surface of the amnion enveloping the umbilical cord, and in the gelatinoid matter of the same. At this period, the areolar tissue (figs. 112 and 113) consists of organic cells with prolongations sent off from their circumference, giving them a very irregular outline, and containing a finely granular matter intermingled with coarser and more refractive granules, which also extends into the prolongations of the cells. Some of the cells anastomose through means of the prolongations; and in such cases the granular matter of the cells intercommunicates. The extremities of many of the prolongations are broken up into filaments of different degrees of fineness, the coarser filaments still presenting a granular constitution, but is entirely lost in the more delicate ones. These filaments form an intricate intertexture; and I could not detect whether those of one cell anastomosed with those of another. The cells contain a round or elliptical, finely granular nucleus, with a minute, transparent nucleolus. Some of the cells are already entirely broken up into areolar filaments, among which are seen some of the coarse granular filaments not yet having undergone ultimate division, and the unchanged nuclei.—J. L.]

With the exception of epithelium, no tissue is so readily regenerated as the cellular. The process of reproduction seems to be essentially the same as that of its original formation in the embryo, the blastema being in this case derived from the blood in form of effused lymph. In this way cellular tissue is formed in the healing of wounds and in the adhesion of inflamed surfaces. It is produced also in many morbid growths.

## FIBROUS TISSUE.

THIS substance is one of those which are serviceable in the body, on account of their mechanical properties, being employed to connect together or to support and protect other parts. It is met with in the form of ligaments, connecting the bones together at the joints; it forms the tendons of muscles, into which their fleshy fibres are inserted, and which serve to attach these fibres to the bones. In its investing and protecting character it assumes the membranous form, and constitutes a class of membranes termed "fibrous." Examples of these are seen in the periosteum and perichondrium which covers the bones and cartilages, in the dura mater which lines the skull and protects the brain, and the fibrous layer which strengthens the pericardium, also in the albugineous coat of the testicle and ovary, and the sclerotic coat of the eye, which enclose the tender internal parts of these organs. Fibrous membranes, named "aponeuroses" or "fasciæ," are also



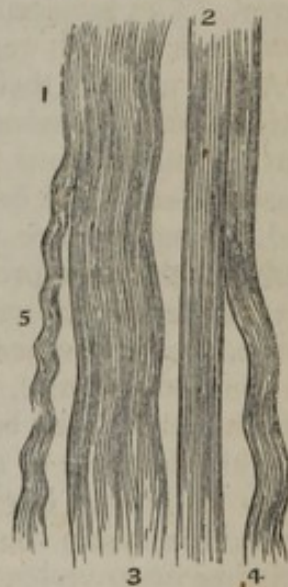employed to envelope and bind down the muscles of different regions, of which the great fascia enclosing the muscles of the thigh and leg is a well-known example. The tendons of muscles, too, may assume the expanded form of aponeuroses, as those of the broad muscles of the abdomen, which form strong fibrous layers in the walls of that cavity and add to their strength. It thus appears that the fibrous tissue presents itself under two principal forms, the *fascicular* and the *membranous*.

*Physical Properties.*—The fibrous tissue is white or yellowish white, with a shining, silvery, or nacreous aspect. It is exceedingly strong and tough, yet perfectly pliant; but it is almost devoid of elasticity and extensibility. By these qualities it is admirably suited to the purposes to which it is applied in the animal frame. By its inextensible character it maintains in apposition the parts which it connects against any severing force short of actual rupture, and this is resisted by its great strength, whilst its flexibility permits of easy motion. Accordingly the ligaments and tendons do not sensibly yield to extension in the strongest muscular efforts; and though they sometimes snap asunder, it is well known that bones will break more readily than tendons of equal thickness. The fibrous membranes are proportionally strong and alike inextensible; they will gradually yield, it is true, when the extending force acts slowly and for a long time, as when tumours or fluids slowly gather beneath them; but perhaps this gradual extension is accompanied with some nutritive change affecting the properties of the tissue.

*Structure.*—The fibrous tissue, (fig. 114,) is made up of fine filaments, agreeing in all respects with the white filaments of the cellular tissue already described. Like these they are collected into bundles, in which they run parallel and exhibit the same wavy character, cohering very intimately. The bundles appear to the naked eye as fine shining threads or narrow flattened bands, for they vary greatly in thickness. They either run all in one direction as in long tendons, or intersect each other in different planes as in some aponeuroses, or they take various directions and decussate irregularly with each other as in the dura mater. A variable amount of dense cellular tissue lies between the larger fasciculi; very little in tendons, more in some fibrous membranes. The filaments swell up and become indistinct when acted on by acetic acid, like those of cellular tissue, and here also the acid discloses the existence of nuclei, and of nuclear or elastic fibres, intermixed in small proportion with the rest of the tissue.

The surface of a tendon or of any other part consisting of this texture, appears marked

[Fig. 114.



White fibrous tissue:—2. Straight appearance of the tissue when stretched. 1. 3. 4. 5. Various wavy appearances which the tissue exhibits when not stretched. — Magnified 320 diameters.—Todd and Bowman.]



across the direction of the fasciculi with alternate light and dark streaks, which give it a peculiar aspect, not unlike that of a watered ribbon. This appearance is owing to the wavy course of the filaments, for when the light falls on them their bendings naturally give rise to alternate lights and shadows.

The fibrous and cellular tissues thus agreeing in their ultimate structure, it is not to be wondered at that sometimes the limits between the two should be but ill defined, and that the one should pass by inconspicuous gradations into the other. Instances of such a transition may be seen in many of the fasciæ; these at certain parts consist of dense cellular tissue, but on being traced farther are seen gradually to take on the fibrous character; and we often see that fasciæ, which in one body are merely cellular, are decidedly fibrous in another.

In chemical constitution, also, the fibrous tissue is similar to the cellular. It contains about two-thirds of its weight of water; it becomes transparent, hard, and brittle, when dried, but readily imbibes water again and regains its original properties. It is resolved into gelatin by boiling.

The fibrous tissue receives blood-vessels, but in general they are inconsiderable both in number and size compared with the mass of tissue to which they belong. In tendons and ligaments with longitudinal fasciculi, the chief branches of the vessels run parallel with and between the larger fasciculi, and, sending communicating branches across them, eventually form a very open network with large oblong meshes. Some fibrous membranes, as the periosteum and dura mater, are much more vascular; but the vessels seen in these membranes do not strictly belong to them, being destined for the bones which they cover. The lymphatics of fibrous tissue are not sufficiently known to be spoken of with certainty.

As to nerves, their general existence in this texture has not been satisfactorily demonstrated by anatomical investigation. It is true that minute nervous fibrils have been traced into the dura mater, but these appear to be confined to a very limited extent of the membrane, and, moreover, are perhaps destined for its blood-vessels. Accordingly, it has been proved by numerous observations and experiments, that the tendons, ligaments, and other structures composed of fibrous tissue, are, in the healthy state, quite insensible; but then it is known, on the other hand, that they occasion severe pain when inflamed, which cannot well be accounted for on the supposition that they are entirely destitute of nerves.\* Bichat, while he admitted their insensibility to cutting, burning, and most other kinds of stimuli, which cause pain in sensible textures, ascribed to them a peculiar sensibility to twisting or to violent extension, and this opinion has been supported by other authorities of weight, but the proofs of it are not clear.

\* Pappenheim has lately announced the discovery of numerous nervous filaments in the ligaments and periosteum, but he has not stated the evidence on which he founds his assertion with sufficient explicitness to enable us to judge of its accuracy. See Müller's Archiv. 1843.



This texture is developed in the same manner as the cellular. It is said to want at first its shining aspect, and in its early condition it is more vascular.

It readily heals and unites when divided, as is seen in cases of broken tendo Achillis. From experiments on the lower animals, it appears that blood is effused in the first instance, but soon gives place to coagulable lymph, which surrounds the divided ends of the tendon and fills up the space between them. Fibres and blood-vessels are then formed in the lymph, probably in the same manner as in the original process of development, and the uniting mass gradually acquires consistence. Its fibres are irregularly interwoven, and it wants the lustre of the rest of the tendon, but is equally strong. Fibrous tissue is very generally produced as a uniting medium of broken bones when osseous union fails to take place; it is common as a diseased production in various kinds of tumours.

---

## YELLOW OR ELASTIC TISSUE.

WHILST the fibrous tissue is remarkable for its want of elasticity and of extensibility, and owes its usefulness as a constituent of the frame in a great measure to this circumstance, the substance we have now to consider is characterized by possessing these properties in a very high degree, and is employed wherever an extensible and highly elastic material is required in the animal structure.

Examples of this texture on a large scale are seen in the horse, ox, elephant, and other large quadrupeds, in which it forms the great elastic ligament, called *ligamentum nuchæ*, that extends from the spines of the vertebræ to the occiput and aids in sustaining the head; in the same animals it also forms an elastic subcutaneous fascia, which is spread over the muscles of the abdomen and assists in supporting the contents of that cavity. In the human body it is met with chiefly in the following situations, viz.:—

1. Forming the *ligamenta subflava*, which extend between the arches of adjacent vertebræ; these ligaments, while they permit the bones to be drawn apart in flexion of the body, aid in restoring and maintaining their habitual approximation in the erect posture,—so far, therefore, relieving the constant effort of the erector muscles.
2. Constituting the chief part of the stylo-hyoid, thyro-hyoid, and crico-thyroid ligaments, and those named the vocal cords. Also extending in form of longitudinal bands, underneath the mucous membrane of the trachea and its ramifications.
3. Entering, along with other textures, into the formation of the coats of the blood-vessels, especially the arteries, and conferring elasticity on these tubes.
4. Beneath the mucous membrane of the gullet and lower part of the rectum, also in the tissue which surrounds the muscular coat of the gullet externally.
5. In the tissue which lies under the serous membranes in certain

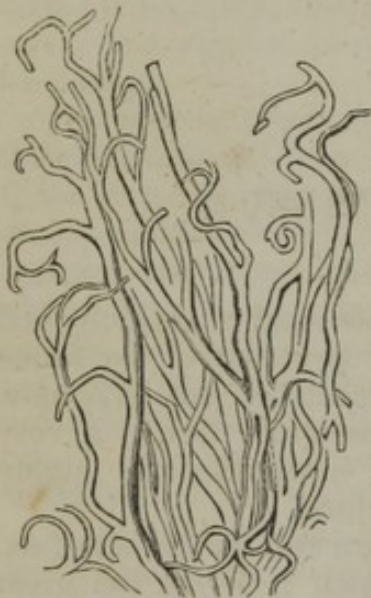

- parts. 6. In many of the fasciæ, where it is mixed with much cellular tissue.  
7. In considerable quantity in the tissue of the skin.

The elastic tissue in its purest and most typical condition, such as is seen in the ligamentum nuchæ of quadrupeds and the ligamenta subflava of the human spine, has a yellow colour, more or less decided; it is extensible and elastic in the highest degree, but is not nearly so strong as ordinary fibrous tissue, and it breaks across the direction of its fibres when forcibly stretched. Its fibres may be easily torn separate in a longitudinal direction; they are often gathered into irregular fasciculi which run side by side but join at short distances with one another, and are further connected by cellular tissue, which is always intermixed with them in greater or less quantity. Elastic ligaments are also covered outwardly with a sheath of cellular tissue.

When the elastic fibres are mixed up with a large proportion of some other kind of tissue, their yellow colour may not appear, but they can always be recognised by their microscopic characters. When viewed under a tolerably high magnifying power, they appear quite transparent, with a remarkably well-defined dark outline (fig. 115). They run side by side, following a somewhat bending course, but with bold and wide curves, unlike the undulations of the cellular fibres.

Fig. 115.



Elastic fibres from the ligamenta subflava, magnified about 200 diameters.

As they proceed they divide into branches, and join or anastomose together in a reticular manner. Another remarkable character which they exhibit in many specimens, is their singular tendency to curl up at their broken ends; and these ends are not pointed, but abruptly broken across. Their size is very various; the largest are nearly  $\frac{1}{4000}$  of an inch in diameter, the smallest perhaps not more than  $\frac{1}{24000}$ . In some varieties of the tissue the larger sized fibres prevail; this is the case with the ligamenta subflava, where their general diameter is about  $\frac{1}{7300}$  of an inch; in other instances, as in the chordæ vocales for example, they are exceedingly fine. Acetic acid produces no change on the elastic fibres, while it speedily alters the wavy cellular fibres that are usually intermixed with them in greater or less number.

The elastic tissue, of course, contains water, and loses much of its weight by drying; but the proportion is said not to be so great as in most other soft tissues. By very long boiling it yields gelatin, or at least a gelatinizing substance, while a portion, equal to rather more than half, remains undissolved.

The gelatin is not pure, for it is precipitated by acetic acid, and by some other reagents which do not disturb a pure solution of gelatin. The nature of the matter which remains undissolved has not been determined. Elastic tissue is



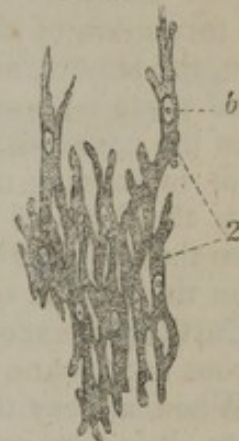also soluble in dilute sulphuric and nitric acids, but more easily in the former; the solution is precipitated by infusion of galls, but not by ferro-cyanide of potassium.

Little is known respecting the blood-vessels and nerves of this texture. The yellow ligaments, which contain it in its purest form, are but scantily supplied with vessels; and no nerves have been traced into them. I am not aware of any experiments or observations as to their sensibility, but there is no reason for supposing it to be greater than that of ordinary ligaments; nor has it been shown that structures containing this tissue possess vital contractility, unless they also contain contractile fibres, of another kind.

The mode of development of the elastic tissue is unknown. Various opinions have, it is true, been advanced in explanation of the process, but they cannot be relied on.

[According to some observations made, in the autumn of 1847, upon the ligamenta subflava of the human embryo, the yellow elastic tissue originates in flattened granular cells. The cells contain a central, oval, transparent nucleus, with a minute, transparent nucleolus. They become elongated and divide at the opposite ends; the divisions of the different cells fuse with each other; for I could detect no separating line, but the granular matter of the divisions of one cell appeared to communicate immediately with that of the divisions of another. After a time the granular matter becomes indistinct and appears to dissolve away with the nucleus, at the same time the cell divisions have elongated into closely packed and anastomosing fibres, which are characteristic of the elastic tissue.—J. L.]

[Fig. 116.



Represents a portion of one of the ligamenta subflava, of a human embryo of two and a half months, highly magnified, representing the development of the yellow elastic tissue. 2. Elongated, granular, divided cells. b. The nuclei.—From nature, by J. L., 1847.]

## CARTILAGE.

This is the well-known substance commonly called "gristle." The following are its more obvious characters. When in mass, it is opaque and of a pearly or bluish white colour, in some varieties yellow; but in thin slices it is translucent. Although it can be easily cut with a sharp knife, it is nevertheless of very firm consistence, but at the same time highly elastic, so that it readily yields to pressure or torsion, and immediately recovers its original shape when the constraining force is withdrawn. By reason of these mechanical properties, it is rather extensively used in the construction of the body. Its specific gravity is 1.15.



In the early embryo, the skeleton is in great part, cartilaginous; but the cartilage forming its different pieces, which have the outward form of the future bones, in due time undergoes ossification or gives place to bone, in the greater part of its extent at least, and hence this variety of cartilage is named "temporary."

Of the permanent cartilages a great many are in immediate connexion with bone, and may still be said to form part of the skeleton. The chief of these are the articular and the costal cartilages; the former cover the ends or surfaces of bones in the joints, and afford these harder parts a thick springy coating, which breaks the force of concussion and gives ease to their motions; the costal or rib-cartilages form a considerable part of the solid framework of the thorax, and impart elasticity to its walls. Other permanent cartilages enter into the formation of the external ear, the nose, the eyelids, the eustachian tube, the larynx, and the windpipe. They strengthen the substance of these parts without undue rigidity: maintaining their shape, keeping open the passages through them where such exist, and giving attachment to moving muscles and connecting ligaments. Many of these have the form of plates or lamellæ of greater or less thickness, and have thence been called "membraniform cartilages;" but to some of them the term is scarcely applicable.

Cartilages, except those of the joints, are covered externally with a fibrous membrane named the *perichondrium*.

When a very thin slice of cartilage is examined with the microscope, it is seen to consist of nucleated cells disseminated in a solid mass of matrix. (Figs. 117, 118, and 119.)

The matrix is sometimes transparent, and to all appearance homogeneous; in other instances it is dim and faintly granular, like ground glass, and in some varieties of cartilage it is pervaded by fine fibres.

The cells, named also cartilage corpuscles, have often the appearance of mere excavations in the matrix, their walls not being distinguishable from the surrounding mass; in other instances, the cell-wall is plainly to be seen: and even in cases of the former kind, though the cell-wall is invisible so long as the cells remain surrounded by the matrix, it may be seen in such as are occasionally left projecting beyond the enveloping mass at the edge of a section.

The nuclei, which may vary from  $\frac{1}{2400}$  to  $\frac{1}{4000}$  of an inch in diameter, are round, oval, angular or irregular. They are granulated or smooth on the surface, and they sometimes, though not often, exhibit one or two nucleoli. Sometimes the nucleus contains fat globules, or is entirely converted into fat. It is often difficult to say whether a body contained within a cartilage-cell is its nucleus, or merely the granular contents which have shrunk away from its sides and formed a mass of the same shape as the cell itself, in which the true nucleus is concealed.

The cells are rarely dispersed singly in the matrix; they usually form groups of different shapes and sizes. Towards the surface of the cartilage the groups are generally flattened conformably with the surface (fig. 118), appearing narrow and almost linear when seen



edgeways, as in a perpendicular section (fig. 117, *a*). The cells in a group have a straight outline where they adjoin or approach one another, but at the circumference of the group their outline is rounded.

Fig. 117.

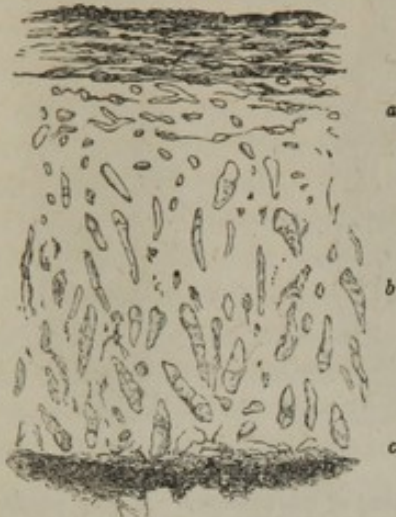


Fig. 118.

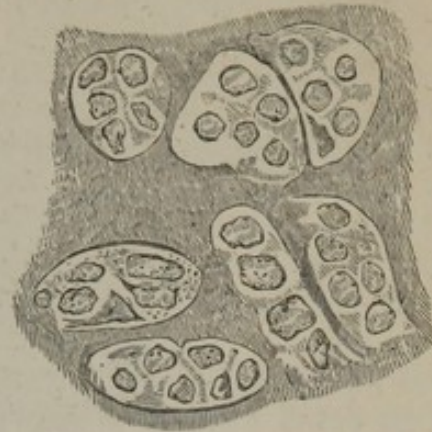


Fig. 117. Diagram representing a vertical section of articular cartilage, seen with a low magnifying power. *a*. Flattened groups of cells near the surface. *b*. Oblong groups, for the most part directed vertically. *c*. Part of the bone.

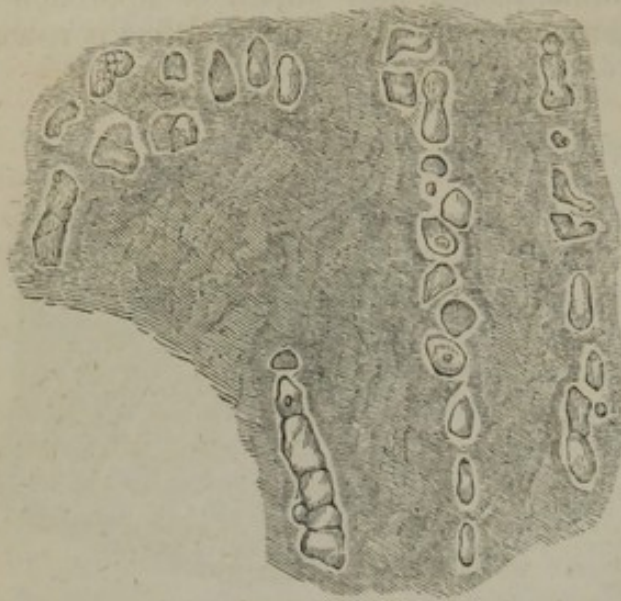Fig. 118. A thin layer peeled off from the surface of the cartilage of the head of the humerus, showing flattened groups of cells. The nuclei are distinctly seen, but the limits of the cells where they adjoin one another are but faintly indicated. Magnified 400 diameters.

Such is the structure of cartilage in general, but it is more or less modified in the several varieties of the tissue.

In articular cartilage, the matrix in a thin section appears dim, like ground glass, and has an almost granular aspect. The cells and nuclei are small. The groups which they form are flattened at or near to the surface, and lie parallel with it (fig. 117, *a*, and fig. 118); deeper and nearer the bone, on the other hand, they are narrow and oblong, like short strings of beads, and are mostly directed vertically. (Fig. 117, *b*; fig. 119.) It is well known that articular cartilages readily break in a direction perpendicular to their surface, and the surface of the fracture appears to the naked eye to be striated in the same direction, as if they had a columnar structure; this has been ascribed to the vertical arrangement of the rows of cells, and the explanation is probably correct, unless, perhaps, it should turn out that both the arrangement of the cells and the direction of the fracture are the result of some determinate structure in the matrix not yet detected. [As has been suspected, the arrangement of the rows of cells and the direction of the fracture are the result of a determinate structure in the matrix. From repeated and careful observation I am fully convinced that the matrix or intercellular substance of articular cartilage has a filamentous structure, (fig. 120,) the filaments being parallel to each other, and in the deeper part of the cartilage are placed in a direction vertical to the surface, but parallel to it in the most superficial layer. And it is this arrangement which not only determines the course of fracture, but the position of the cells in relation to each other in the progress of their development by division, and the formation of the



Fig. 119.



[Fig. 120.]

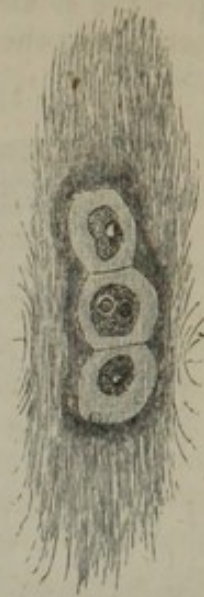


Fig. 119. Vertical section of articular cartilage of the head of the humerus. A deep portion near the bone. Magnified 400 diameters. Each cell contains a mass shaped like itself, in the midst of which a round nucleus is probably concealed.

[Fig. 120. Represents a shred of articular cartilage, with a row of three cartilage-cells, torn from a broken edge of the articular cartilage of the condyles of the os femoris, highly magnified, exhibiting the filamentary structure. From nature, by J. L.]

lamina which has for so long a time been mistaken for the synovial membrane.

The filaments of the cartilaginous matrix are exceedingly fine, present considerable uniformity, and have an average measurement of  $\frac{1}{28000}$  of an inch in diameter. They adhere very tenaciously together, and under ordinary circumstances are hardly demonstrable, although I have occasionally seen them at the extremity of a torn shred of the cartilage. But if an articular cartilage be taken from a bone which has been macerated in diluted muriatic acid, and be broken, and a fibre be torn from the fractured edge and be submitted to the microscope in the ordinary manner, numerous detached, and exceedingly delicate, spider-threadlike filaments will be readily seen along the sides of the fibre.—J. L.\*]

The free surface of articular cartilage is said to be covered with epithelium continued from that of the synovial membrane, a thin stratum of cellular tissue being interposed; but the existence of such a covering is certainly not general, at least in the adult. It is easy, no doubt, to peel off a thin film from the surface of the cartilage of the head of the humerus or femur; but this superficial layer is really part of the cartilage, and its broad patches of cells with the intermediate matrix are not to be mistaken. (See fig. 118.) At the same time, it is true that near the margin of these cartilages a layer of fine filamentous tissue, covered with epithelium, is prolonged a certain way over their surface from the synovial membrane. The matrix of arti-

[\* For a more detailed description of this arrangement, see a memoir entitled, "On the Intimate Structure and History of Articular Cartilages. By Joseph Leidy, M.D.," in the American Journal of Med. Sci., No. 2, 1849. Philada., edited by Isaac Hays, M.D.]



cular cartilage rarely, or perhaps never, becomes pervaded by fibres, nor is it prone to ossify.

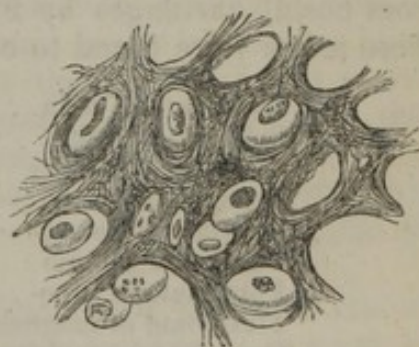
In the cartilages of the ribs, the corpuscles or cells, which are of large size, are also collected into groups. Near the exterior of the cartilage they are flattened, and lie parallel with the surface, forming a superficial stratum from  $\frac{1}{200}$  to  $\frac{1}{300}$  of an inch thick. As to those situated more inwardly, we can sometimes observe, in a transverse slice, that they form oblong groups disposed in lines radiating to the circumference; but this arrangement is not constant, and they often appear quite irregular. The matrix is tolerably clear, except where fibres have been developed in it, in which parts it is opaque and yellowish. Such fibrous patches are very frequent; the fibres are fine, straight and parallel, appearing transparent when few together; they withstand the action of acetic acid. It is common to find the rib cartilages extensively ossified.

It was observed by Herissant\* that the costal cartilages, after many months' maceration in putrid water, would sometimes break up into thin plates, directed across the axis of the cartilage; from which he inferred that these cartilages were naturally made up of such transverse lamellæ: but this point does not appear to have been further investigated.

The description given of the microscopic characters of the costal cartilages will apply with little variation to the ensiform cartilage of the sternum, to the cartilages of the larynx and windpipe, except the epiglottis and cornicula laryngis, and to the cartilages of the nose. With the exception of the last, these resemble the rib cartilages also in their tendency to ossify.

The epiglottis and cornicula, the cartilages of the ear and of the eyelid, differ so much from the foregoing, both in intimate structure and outward characters, that they have been included in a class apart, under the name of the "yellow" or "spongy" cartilages. These are opaque and yellow, are more flexible than the ordinary cartilages, and have little tendency to ossify. They are made up of cells and a matrix, but the latter is everywhere pervaded with fibres. (Fig. 121.) These fibres resist the action of acetic acid; they are in most parts short, straight, and confusedly intersecting each other in all directions, like the filaments in a piece of felt; in such parts the matrix has a rough indistinctly granular look. Here and there the fibres are longer and more fasciculated, but still interlace at short distances. In thin sections the cells readily drop out from the matrix, leaving empty the cavities which they occupied.

Fig. 121.



Section of the epiglottis, magnified 380 diameters. (After Baly in Müller's Physiology, page 391.)

\* Mem. de l'Acad. des Sc. de Paris, 1748.



The characters of the temporary cartilages are given in the account of the formation of bone.

No nerves have been traced into any of the cartilages, and they are known to be destitute of sensibility.

In the healthy state, no blood-vessels penetrate the articular cartilages. Whatever nutrient fluid they require seems to be derived from the vessels of adjoining textures, especially the bone, and to be conveyed through the tissue by imbibition. In the embryo a layer of vessels is prolonged some way over the surface, underneath the synovial membrane; but, as development proceeds, these subsynovial vessels retire towards the circumference of the cartilage, and eventually form a narrow vascular border round it, which has been named the *circulus articuli vasculosus*.

When the tissue exists in thicker masses, as in the cartilages of the ribs, canals are excavated in its substance, along which vessels are conducted to supply nourishment to the part too distant to receive it from the vessels of the perichondrium. But these canals are few and wide apart, and the vessels do not leave them to ramify in the intermediate mass, which is accordingly quite extra-vascular. It must be further remembered respecting these vascular canals, that many of them lead to spots where the cartilage is undergoing ossification, and convey vessels to supply the bony deposits.

Ordinary permanent cartilage contains about three-fifths of its weight of water, and becomes transparent by drying. By boiling it in water for 15 or 20 hours it is resolved into chondrin (see page 46). The temporary cartilages are resolved into a matter which has the chemical reactions of chondrin, but does not gelatinize. The yellow cartilages, by several days' boiling, yield a small quantity of the same variety of chondrin. Cartilage affords by incineration a certain amount of mineral ingredients; 3·4 per cent of ashes were obtained from costal cartilages by Frommherz and Gugert, and 100 parts of these ashes were found to consist of

Carbonate of soda . . . . .	35·07
Sulphate of soda . . . . .	24·24
Chloride of sodium . . . . .	8·23
Phosphate of soda . . . . .	0·92
Sulphate of potash - . . . . .	1·20
Carbonate of lime . . . . .	18·37
Phosphate of lime . . . . .	4·06
Phosphate of magnesia . . . . .	6·91
Oxide of iron and loss . . . . .	1·00

The process by which cartilage is developed is very imperfectly known: the following is a summary of Schwann's observations and views respecting it:—

At first, nucleated cells are seen in a transparent intercellular substance or blastema, much softer than the future matrix. The cells augment in number and enlarge in size, though in some cases, as will be explained, their cavity is subsequently narrowed. Their multiplication may take place by endogenous generation; that is, by the production of young cells within those already existing, whilst the parietes of the old ones become blended with the matrix; or they may increase in number by the independent formation of new cells in the inter-



vals of the old. Schwann considers the latter to be the common mode. He states that new cells arise in the intercellular substance near the surface of the cartilage and between the more recent of those already formed, (see fig. 6,<sup>3</sup>) and that free nuclei are first generated in the mass and then the cell-wall formed round them, (fig. 6,<sup>1</sup> and <sup>2</sup>). The intercellular substance is at first in very small proportion compared with the cells, but soon increases in quantity and acquires greater consistency. Its increase may take place by the cell-walls becoming thickened and then more or less blended with the surrounding mass, as already described in the case of the branchial cartilage of the fish, (p. 55, figs. 7, 8, 9,) or new matter may be deposited between the cells and independently of them; or both processes may be combined. As already stated, the matrix in many parts subsequently becomes fibrous, affording an example of the production of fibres in amorphous matter without the intervention of cells or nuclei.

The vital changes which occur in cartilage take place very slowly. Its mode of nutrition has been already referred to; it is subject to absorption, and when a portion is absorbed in disease or removed by the knife, it is not regenerated. Also, when fractured, as sometimes happens with the rib-cartilages, there is no reunion by cartilaginous matter, but the broken surfaces become connected, especially at their circumference, by fibrous or dense cellular tissue, often by a bony clasp.

#### FIBRO-CARTILAGE.

This is a substance consisting of a mixture of the fibrous and cartilaginous tissues, and so far partaking of the qualities of both. Like cartilage, it possesses firmness and elasticity, but these properties are united with a much greater degree of flexibility and toughness. It presents itself under various forms, which may be enumerated under the following heads:—

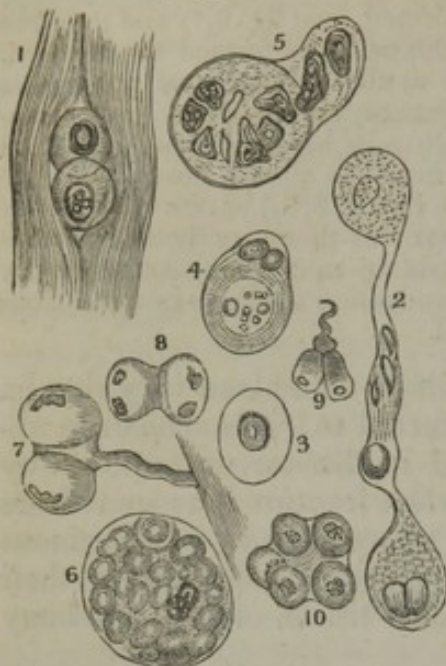
1. *Interarticular* fibro-cartilages. These are interposed between the moving surfaces of bone, or rather of articular cartilages, in several of the joints. They serve to maintain the apposition of the opposed surfaces in their various motions, to give ease to the gliding movement, and to moderate the effects of great pressure. In the joint of the lower jaw and in that of the clavicle they have the form of round or oval plates, growing thinner towards their centre; in the knee-joint they are curved in form of a sickle, and thinned away towards their concave free edge. In all cases their surfaces are free and covered by the synovial membrane of the joint, while they are fixed at their circumference or extremities.

2. The articular cavities of bones are sometimes deepened and extended by means of a rim or border of fibro-cartilage. A good example of one of these *circumferential* or *marginal* fibro-cartilages, is seen in the hip-joint, attached round the lip of the cotyloid cavity.

3. *Connecting* fibro-cartilages are such as pass between the adjacent surfaces of bones in joints which do not admit of gliding motion, as at the symphysis of the pubes and between the bodies of the vertebræ. They have the general form of disks, and are composed of concentric rings of fibrous tissue with cartilage interposed; the former predominating at the circumference, the latter increasing towards the centre. The modifications which they present in particular instances are described in the special anatomy of the joints.



[Fig. 122.]



Elementary structures from an intervertebral disk. — 1. Two cartilage-cells lying amongst the white fibrous tissue. The remaining objects are from the central pulpy substance, and exhibit various forms of cells. In several of these there is an appearance of multiplication by subdivision of the nucleus, and some seem attached by a fibrous tissue. The full meaning of this does not yet appear.—Todd and Bowman.]

4. The bony grooves in which tendons of muscles glide are lined with a thin layer of fibro-cartilage. Small nodules of this tissue (sesamoid fibro-cartilages) may also be developed in the substance of tendons, of which there is an example in the tendon of the *tibialis posticus*, where it passes beneath the head of the astragalus. Lastly, fibro-cartilage is sometimes connected with muscular tissue, and gives attachment to muscular fibres, like that which is known to exist at the orifice of the heart.

Fibro-cartilage appears under the microscope to be made up of bundles of fibres, like those of ordinary ligament, with cartilage-cells intermixed; but the proportion of the two elements varies exceedingly in the different instances above enumerated. In general the fibrous tissue very greatly predominates, and in some cases, as in the interarticular laminae of the knee-joint, it constitutes almost the entire structure.

In the intervertebral disks the cartilage corpuscles are abundant towards the centre of the mass where the cartilaginous tissue prevails, and the substance is softer.

In chemical composition this texture agrees most with ligament, yielding gelatin when boiled.

Its blood-vessels are very few, and, according to Mr. Toynbee,\* are confined to the parts that are fibrous. Its vital changes are slow; it is subject to absorption, but much less readily so than bone; hence it is no uncommon thing to find the intervertebral disks entire when the adjacent bodies of the vertebrae have been destroyed by disease. It has not much tendency to ossify.

Little is known concerning the mode of development of fibro-cartilage. Mr. Toynbee concludes from his researches that the cartilaginous element is relatively more abundant at early periods.

#### SYNOVIAL MEMBRANES.

Resembling serous membranes in general form and structure, the synovial membranes are distinguished by the nature of the secretion which lubricates their surface, for this is a viscid glairy fluid resembling the white of an egg, and thence named *synovia*.

These membranes line the cavities of joints and are interposed between moving parts in certain other situations; being in all cases intended to lessen friction and thereby facilitate motion. Like the serous membranes they are composed of a scaly epithelium which, according to Henlé, may consist of several strata; a basement mem-

\* Phil. Trans. 1841.



brane; and a layer of dense cellular tissue pervaded by vessels and attached by tissue of the same kind to the parts beneath.

The different synovial membranes of the body are referred to three classes, viz., *articular*, *vesicular* and *vaginal*.

1. *Articular synovial membranes*, or *Synovial capsules of joints*. These line and by their synovial secretion lubricate the cavities of the diarthrodial articulations, that is, those articulations in which the opposed surfaces glide on each other. In these cases the membrane may be readily seen covering internally the surface of the capsular or other ligaments which bound the cavity of the joint, and affording also an investment to tendons or ligaments which happen to pass through the articular cavity, as in the instance of the long tendon of the biceps muscle in the shoulder-joint. On approaching the articular cartilages the membrane passes over their margins, and, becoming much more firmly adherent, terminates after advancing but a little way on their surface. This, as already explained (page 240), is the condition in the adult, but in the *fœtus*, the membrane, closely adhering, is continued over the whole surface of the cartilage, so that it would seem to become obliterated or absorbed in consequence of pressure or friction when the joint comes to be exercised. The blood-vessels in and immediately underneath the membrane are sufficiently manifest in most parts of the joint. They advance but a little way upon the cartilages, forming a vascular zone round the margin of each, named "*circulus articuli vasculosus*," in which they end by loops of vessels dilated at the bent part greatly beyond the diameter of ordinary capillaries. In the *fœtus*, according to Mr. Toynbee, these vessels, like the membrane itself, advance further upon the surface of the cartilage.

In several of the joints, folds of the synovial membrane, often containing more or less fat, pass across the cavity; these have been called synovial or mucous ligaments. Other processes of the membrane simply project into the cavity at various points. These are very generally cleft into fringes at their free border, upon which their blood-vessels, which are numerous, are densely distributed. They often contain fat, and then, when of tolerable size, are sufficiently obvious; but many of them are very small and inconspicuous. The fringed vascular folds of the synovial membrane were described, by Dr. Clopton Havers (1691), under the name of the *mucilaginous glands*, and he regarded them as an apparatus for secreting synovia. Subsequent anatomists, while admitting that, as so many extensions of the secreting membrane, these folds must contribute to increase the secretion, have, for the most part, denied them the special character of glands, considering them rather in the light of a mechanical provision for occupying spaces which would otherwise be left void in the motion of the joints. Havers's view has, however, been lately revived by Mr. Rainey,\* who finds that the processes in question exist in the bursal and vaginal synovial membranes as well as in those of joints, wherever, in short, synovia is secreted. He states that their blood-vessels have a peculiar convoluted arrangement, differing from that of the vessels of fat, and that the epithelium covering them, "besides inclosing separately each packet of convoluted vessels, sends off from each tubular sheath secondary processes of various shapes, into which no blood-vessels enter." Kölliker, who has since taken up the inquiry, also finds that fringed membranes exist in all joints and synovial sheaths, as well as in most synovial bursæ, and that they consist of vascular tufts of the synovial membrane, covered by epithelium, and now and then containing fat-cells. He also observed the curious

\* Proceedings of the Royal Society, May 7th, 1846.



"nonvascular secondary processes," described by Mr. Rainey, the larger of which, he says, consist of fibres of areolar tissue in the centre, and a covering of epithelium cells, which seem not unfrequently to be converted into a homogeneous membrane, studded over with cell-nuclei.

2. *Vesicular or Bursal synovial membranes, Synovial bursæ, Bursæ mucosæ.*—In these the membrane has the form of a simple sac, interposed, so as to prevent friction, between two surfaces which move upon each other. The synovial sac in such cases is flattened and has its two opposite sides in apposition by their inner surface, which is free and lubricated with synovia, whilst the outer surface is attached by cellular tissue to the moving parts between which the sac is placed.

In point of situation the bursæ may be either deep-seated or subcutaneous. The former are for the most part placed between a muscle or its tendon and a bone or the exterior of a joint, less commonly between two muscles or tendons: certain of the bursæ situated in the neighbourhood of joints not unfrequently open into them. The subcutaneous bursæ lie immediately under the skin, and are found in various regions of the body interposed between the skin and some firm prominence beneath it. The large bursa, situated over the patella, is a well-known example of this class, but similar though smaller bursæ are found also over the olecranon, the malleoli, the knuckles and various other prominent parts. It must, however, be observed, that, among these subcutaneous bursæ, some are reckoned which do not always present the characters of true synovial sacs, but look more like mere recesses in the subcutaneous cellular tissue, larger and more defined than the neighbouring areolæ, but still not bounded by an evident synovial membrane. These have been looked on as examples of less developed structure, forming a transition between the cellular tissue and perfect synovial membrane.

3. *Vaginal Synovial membranes or Synovial sheaths.*—These are intended to facilitate the motion of tendons as they glide in the fibrous sheaths which bind them down against the bones in various situations. The best-marked examples of such fibrous sheaths are to be seen in the hand and foot, and especially on the palmar aspect of the digital phalanges, where they confine the long tendons of the flexor muscles. In such instances one part of the synovial membrane forms a lining to the osseo-fibrous tube in which the tendon runs, and another part is reflected at each end upon the tendon and affords it a close investment. The space between the parietal and reflected portions of the membrane is lubricated with synovia and crossed obliquely by one or more folds or duplications of the membrane, named "fræna," which pass from the one part of it to the other.

*Synovia.*—As already stated, this is a viscid transparent fluid; it has a yellowish or faintly reddish tint, and a slightly saline taste. It is an albuminous fluid, consisting of water, with about six per cent. of albumen and a minute quantity of extractive matter and salts.



## THE CONNEXIONS OF THE PIECES OF THE SKELETON ONE WITH ANOTHER.

### ARTICULATIONS.

The different pieces of the osseous system being connected together so as to form a skeleton, their modes of union must be as various as their forms and uses. When the union is not immediate, as is the case in the cranial bones, it is effected by means of different substances, such as ligament, cartilage, fibro-cartilage, and fibrous membrane, variously arranged and disposed, so as to permit, in some instances, no perceptible motion; whilst in others a free and extended range is allowed in every direction. Still, all the varieties, however numerous, are usually included under the general term "articulation."

*Classification of articulations.*—The articulations are divided into three classes, viz., the immovable, the movable, and mixed; the last being intermediate in degree between the others. The first form obtains where flat and broad bones are united to enclose cavities for the lodgment of important organs, as in the cranium and pelvis. In some instances the surfaces are indented and reciprocally impacted one into the other, so that complete solidity is insured by the structure of the part; and, as this mode of union occurs only amongst flat bones, their deficiency in extent of contact is compensated by the indentations in their margins. There is another set of immovable articulations, in which the surfaces are merely in apposition with one another, yet total immobility is secured by what may be termed a mechanical contrivance. Thus, though the squamous part of the temporal bone merely rests against the inferior border of the parietal, no motion can exist between them, in consequence of the manner in which the petrous portion of the former bone projects into the base of the skull.

#### A. IMMOVABLE ARTICULATIONS.—SYNARTHROSIS.

All the bones of the head and face, except the lower jaw, are joined by immovable articulation, or synarthrosis (*συν*, together; *αρθρον*, articulation), of which there are several forms.

1. The first is called *suture* (*sutura*, a seam). In the true suture the union is effected by indentations in the contiguous margins of bones which are mutually received into one another, as may be seen between the two parietal, the occipital, and frontal bones; any varieties that occur being referrible to the form of the prominences. Thus, when they are tooth-shaped, the suture is termed *sutura dentata*; if like the teeth of a saw, *sutura serrata*; if the adjacent borders be bevelled off, as where the temporal and parietal bones are applied to one another, it is called a squamous suture (*sutura squamosa*). In some parts it may be observed that the mode of union and adaptation are alternated, in order to increase their power of resistance. Thus, at the superior part of the arch of the skull, the frontal overlies the parietal bones, and rests on them; but inferiorly and laterally the reverse takes place, where the parietal rests against the frontal.



When the surfaces are merely placed in apposition with one another, as in the superior maxillary bones, the union is called *harmonia* (ἁρμονία, to adapt).

When a ridge in one bone is received into a groove in another, the articulation is called *schindylesis* (σχινδύλησις, a slit or fissure). The rostrum of the sphenoid, and the descending plate of the ethmoid bone, are joined in this way with the vomer. When a conical surface is impacted into a cavity, the term *gomphosis* (γομφόσις, a nail,) is adopted, which may be exemplified by the manner in which the teeth are lodged in the alveoli.

#### B. MIXED ARTICULATIONS. — AMPHI-ARTHROSIS.

In the mixed form of articulation, or *amphi-arthritis* (ἀμφι in the sense of ἀμφω, ambo, both, and ἀρθρον), the bones are connected by an intermediate substance, which allows some degree of motion. The articulations between the bodies of the vertebræ, the union at the pubic symphysis, and that between the first two bones of the sternum, are all constructed on this principle. As the surfaces in these cases are flat and plane, they possess, in themselves, no mechanical advantage; so that their union is maintained partly by the cartilages interposed between them, and partly by ligamentous and fibrous structures disposed round the articulations.

#### C. MOVABLE ARTICULATIONS. — DIARTHROSIS.

In the movable articulations, or *diarthrosis* (δια, through; ἀρθρον, articulation), as the surfaces are merely in contact with one another, the connexion between the parts is maintained by means of ligaments and fibrous membranes; for though cartilages are interposed between their adjacent extremities, they do not form a bond of union between them; on the contrary, they are calculated to facilitate motion, rather than to restrain it. But the muscles which surround the different movable articulations contribute materially to retain the articular surfaces in their natural situations, and to prevent displacement. This is particularly evident in the shoulder-joint, in which the head of the humerus is kept in contact with the glenoid cavity of the scapula, not so much by the fibrous capsule, which is weak and loose, as by the surrounding muscles; for, if these be weakened by paralysis, luxation may be readily produced.

The joints in the extremities are all referrible to the movable class: so is that of the lower jaw with the skull, and of the latter with the vertebral column.

In the greater number of instances one of the articular surfaces is convex, the other concave; but each of these forms exhibits some varieties of conformation, which are marked by particular names. Thus, an articulating surface, which is rounded and globular, so as to represent a segment of a sphere, is called a *head*; but if it be elongated, the term *condyle* is used. These are in some cases supported by a contracted or thin portion (*neck*), which connects them with the body of the bone. If two condyles be placed in apposition, so as to leave a fossa between them, and constitute a pulley-like surface, it is



termed *trochlea*. When plain even surfaces articulate, it is not necessary to mark them by any particular name; in describing them they are referred to generally as articulating surfaces. Some of the articulating depressions have also received names taken from certain peculiarities in their conformation. Thus, the superior extremity of the ulna, which receives the trochlea of the humerus, is called the sigmoid cavity, from some resemblance to the Greek letter Σ (σιγμα, εἶδος, form); others are denominated from their greater or less degree of depth or shallowness. The deep cup-shaped cavity which receives the head of the femur is called cotyloid (from κοτυλη, a cup, and εἶδος, form); and the shallow oval depression to which the head of the humerus is applied, receives the name of *glenoid* cavity (from γληνη, a shallow cavity, and εἶδος, form).

The varieties of diarthrosis are:—1. *Enarthrosis* (εν, in; αρθρον, a joint), which in common language is called the “ball-and socket” joint; such as we see in the hip and shoulder. In these great freedom of motion is provided for.

2. *Arthrodia* (αρθρον, a joint; ἄρω, to adapt); which comprises joints with a limited motion, as in the case of the carpal and tarsal bones, which merely slide for a little way upon each other. The articulations between the tubercles of the ribs and the transverse processes of the vertebræ, and those between the articular processes of the last-named bones, also come under this head.

#### THE KINDS OF MOVEMENT ADMITTED IN JOINTS.

As the extent and form of the articulating surfaces of joints, as well as their ligamentous connexions, vary in different instances, so must their degrees of solidity and mobility; and on a review of the whole of the articulations, it may be laid down as a general principle, that the greater their mobility, the less their solidity; or, in other words, that the one is inversely as the other. All the motions, however, which are admissible in joints may be arranged under four heads, viz. motions of gliding, angular movement or opposition, circumduction, and rotation.

1st. The contiguous surfaces of every movable articulation admit a certain degree of *gliding* motion upon one another, so that it may be regarded as common to all; but in some cases it is the only one which takes place, for instance, between the different bones of the carpus and tarsus. We thus observe that some joints admit of all the motions here indicated; some are deprived of rotation, retaining the rest; whilst in others nothing more than a mere gliding can take place between the surfaces; so that a regular gradation is established in their degrees of mobility between the most movable and those which are least so. The shoulder-joint admits of the greatest extent and variety of movement; those between the carpal and tarsal bones are exceedingly limited in these particulars; and, finally, between the latter and those which are altogether immovable, an intermediate grade may be traced, of which the pubic symphysis presents an example.

2d. The *angular* movement, or opposition, can only take place between long bones. If these be made to move in opposite directions, as from extension to flexion, or from abduction to adduction, they form



with one another angles varying in degree according to the extent of the motion. This, in some cases, as in the elbow and knee, is confined to flexion and extension, which makes them strictly ginglymoid or hinge-joints (*γινγλυμος*, a hinge); in others, the motion is general, and extends to four opposite directions, including each of the points intermediate between them, as may be observed in the shoulder, in the hip, and the metacarpal joint of the thumb, all which joints admit of a circumduction in the part to which they belong.

3d. The motion of *circumduction* is performed when the shaft of a bone is made to describe a cone, its summit corresponding with the superior articulation, the base being at the inferior extremity of the bone. While this motion is being executed, the limb passes successively through the states of elevation, abduction, depression, adduction, and of course through all the intermediate points; and if a pencil be held between the fingers, and its point applied to any plain surface, such as a wall, it will trace a circle corresponding with the base of a cone, whose summit is at the shoulder-joint, whilst its side coincides with the line described by the outstretched limb as it traverses the different points just enumerated.

4th. *Rotation* differs altogether from circumduction. In the latter the bone suffers a change of place as it moves from one point to another; in the former, it merely turns on its own axis, and therefore retains the same relative situation with respect to the adjacent parts. This movement, however, admits of two varieties: in one, it is performed on a pivot, as in the motion of the axis on the vertebra dentata; in the other there is a sort of compound motion, for instance, where the radius rolls on its own axis at one end, whilst at the other it moves upon the extremity of the ulna, by which its lower part describes a segment of a circle, and therefore changes place to a certain extent. The femur and humerus also admit of a rotatory motion; in the latter, as the head is closely applied upon the shaft, the axis of motion nearly coincides with that of the bone; but in the former, in consequence of the length of the neck and the angle which it forms with the bone, the rotation is performed round an imaginary axis, which may be conceived to pass from the globular head to the condyles.

There are but two articulations in which all the motions of opposition, circumduction, and rotation can be performed, namely, the hip and the shoulder joint. In these a convex surface is applied to one which is concave, the former being hemispherical, which is essentially necessary to such a freedom of motion. As joints constructed on this principle are more liable to displacement than any others, their security is in a great measure provided for by their being placed at the superior extremity of the limb, by which they are withdrawn from the influence of external forces. This arrangement is made subservient not to the security of the joint solely, but also to a very important purpose in the functions of the limb. For as these free and extended motions are performed in the superior articulation, their effect is communicated to the whole limb, so as to compensate for the more restricted movements in the lower joints.

Though all the motions above mentioned take place in the hip and shoulder joints, each of them, considered singly, is not performed with



equal facility in both. Thus, circumduction is executed with greater ease in the shoulder than in the hip. Rotation, on the contrary, is more free and perfect in the latter than in the former. Circumduction can be executed with ease only when the axis of motion coincides (or very nearly so) with that of the lever to be moved, as is the case in the humerus; but in the femur, the length of the neck of the bone removes the axis of motion considerably from that of the shaft, and thereby impedes circumduction in proportion as it facilitates the rotation of the limb. These differences of structure in the superior joints of the two extremities bear a distinct relation to the conformation of their other articulations, and to the purposes for which they are adapted. For, as the inferior extremity is intended to sustain the weight of the body and for progression, the bones of the leg must be securely fixed, which could be effected only by diminishing their mobility; on this account no rotation or supination is allowed between the tibia and fibula; but, to compensate for this deficiency, rotation is permitted in the hip. But as the superior extremity, on the contrary, is fitted for the prehension of objects, and for quick and varied movements, free motion is allowed between the bones of the fore-arm, and between the latter and the carpus, in order that the hand and fingers may be more readily directed and applied to such objects as are required to be seized for different purposes; and the power of pronation and supination, thus conferred, more than compensates for any deficiency in the rotatory motion of the humerus.

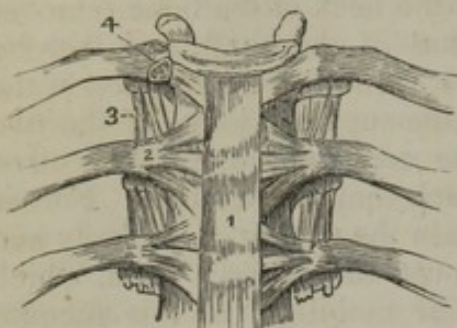
It has been already observed, that rotatory motion in a bone presupposes the existence of a globular head, placed so that its axis shall form an angle with the shaft. Wherever this requisite is wanted, motion is confined to opposition and circumduction, as occurs in the articulation of the thumb with the carpus, in the phalanges with the metacarpal bones, and in the clavicle with the sternum. In these joints, the articulating surfaces are placed at the ends of the more movable bones; and as their axes coincide with that of motion, rotation is prevented, but circumduction and opposition are freely performed. When these are limited in extent, as in the sterno-clavicular articulation, it arises rather from the accessory ligaments of the part than from any impediment in the surfaces of the bones; and if motion in one direction be more free than in another, as in the digital phalanges with the metacarpus, where flexion and extension are more free than abduction and adduction, it proceeds partly from the existence of the lateral ligaments, and partly from the great power possessed by the flexor and extensor muscles compared with those which perform the other movements. Though in the knee and elbow the axis of motion coincides with that of the bones, yet their movement is confined to two directions, viz., to flexion and extension. In these joints, all other motions besides those just mentioned are prevented by the breadth of the articulating surfaces, and by their mode of adaptation: however, when they are flexed, some degree of lateral motion, and also of circumduction, can be performed; as any individual may ascertain by resting his elbow on a table, when he will find that the fore-arm may be made to describe a cone with its summit at the olecranon and base towards the fingers.



## ARTICULATIONS OF THE VERTEBRAL COLUMN.

The different pieces of the spine are connected together by ligaments,

[Fig. 123.]



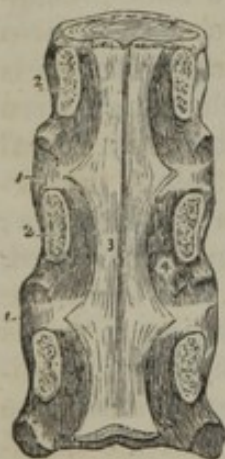The anterior ligaments of the vertebræ, and ligaments of the ribs. 1. The anterior common ligament. 2. The anterior costo-vertebral or stellate ligament. 3. The anterior costo-transverse ligament. 4. The interarticular ligament connecting the head of the rib to the intervertebral substance, and separating the two synovial membranes of this articulation.—W.]

by fibro-cartilage, and in some parts by synovial membranes; the former serving to retain them in their situation, the latter to facilitate motion between the different bones. The bodies are joined by two ligamentous bands, extending the whole length of the chain, and also by the intervertebral substances.

1. The *anterior common ligament*, (fig. 123,<sup>1</sup>) (*ligamentum corporibus vertebrarum commune anterius*, seu *fascia longitudinalis anterior*,—Weitbrecht,) is a strong band of fibres which is placed on the front of the bodies of the vertebræ, and reaches from the axis to the first bone of the sacrum,

becoming broader as it descends. It consists of longitudinal fibres which are dense, firm, and well-marked. The superficial fibres extend

[Fig. 124.]



A posterior view of the bodies of three dorsal vertebræ, connected by their intervertebral substance 1, 1. The laminae (2) have been sawn through near the bodies of the vertebræ, and the arches and processes removed, in order to show (3) the posterior common ligament. A part of one of the openings in the posterior surface of the vertebræ, for the transmission of the vena basis vertebræ, is seen at 4, by the side of the narrow and unattached portion of the ligament.—W.]

from a given vertebra to the fourth or fifth below it; the set subjacent to these passes from the body of one to about the third beneath it; whilst the deeper ones pass only from one vertebra to that next it. The fibres are thicker towards the middle of the bodies of the vertebræ than at their margins, or over the intervertebral cartilages; by which means their transverse depressions are filled up, and the surface of the column rendered even. It may also be observed that they adhere more closely to the margins of the bones than to the middle of their bodies, and still more closely to the intervertebral cartilages. Upon the sides of the vertebræ there are some fibres which are thin and scattered, and reach from one bone to the other.

2. The *posterior common ligament*, (fig. 124,<sup>3</sup>) (*ligamentum commune posterius*, seu *fascia longitudinalis postica*,—Weitbrecht,) is situated within the spinal canal, and attached to the posterior surface of the bodies of the vertebræ, extending from the occiput to the sacrum. It is smooth, shining, and broader opposite the intervertebral cartilages than opposite the bodies of the bones, so that its margins present a series of points or dentations with intervening concave spaces. And the ligament is altogether broader at the upper than the lower part of the spine. It adheres firmly to the fibro-cartilages and to the contiguous margins of the bodies of the vertebræ, but



it is separated from the middle of the vertebræ by the transverse parts of the large venous plexus which is in contact with the bones. Between the ligament and the prolongation of the dura mater, which lines the canal, some loose cellular membrane is interposed.

3. The *intervertebral substance* (ligamenta intervertebralia—Weitb.) is a plate or disk of fibro-cartilage, (fig. 124,<sup>1</sup>) placed between the bodies of each pair of vertebræ, from the axis to the base of the sacrum; corresponding in shape to the parts of the vertebræ between which they are interposed. They are covered anteriorly and posteriorly by the common ligaments, which are intimately adherent to them; in the dorsal region they are connected laterally, by short ligaments, to the heads of all the ribs, each of which articulates with two vertebræ.

The intervertebral substance is composed, towards its circumference, of thin plates of fibro-cartilage, resting on their edges, and placed one within the other, as it were, concentrically (fig. 125,<sup>1</sup>). Thus the outer plate like a rim runs round the disk, its lower edge resting on the vertebra beneath it; its anterior and convex surface being subjacent to the anterior common ligament, whilst its concave surface is in

Fig. 125.

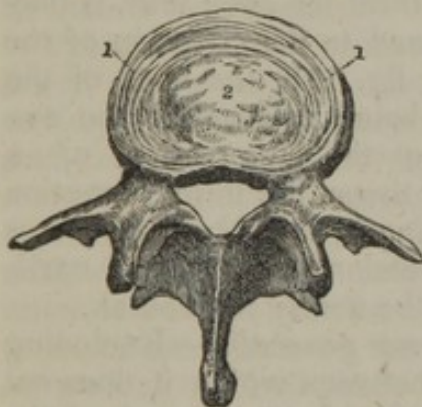


Fig. 126.

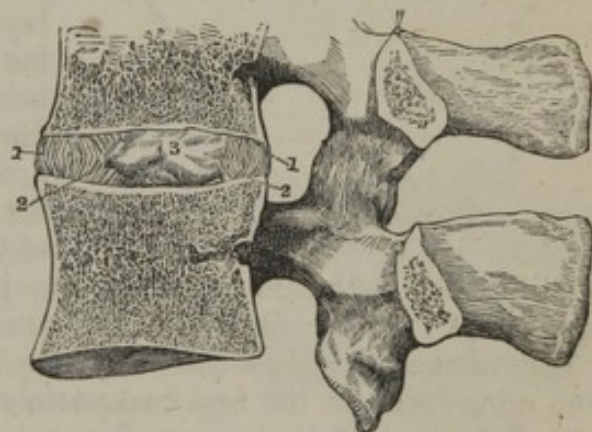

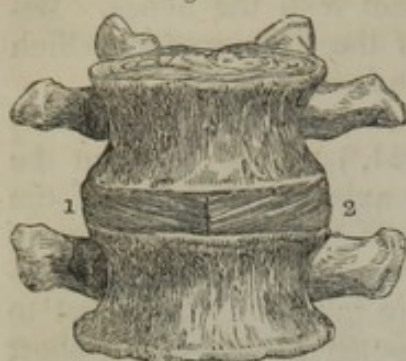
Fig. 125. A lumbar vertebra, with a horizontal section of intervertebral substance above it. At the circumference the concentric arrangement of the layers of the latter is shown, and in the middle the pulpy substance is indicated.

Fig. 126. A vertical section of two vertebræ, and the substance interposed between their bodies. The direction of the layers of the intervertebral substance is displayed. 1. Layers curved outwards. 2. Those curved inwards. 3. Pulpy substance in the middle.

apposition with and connected by some fibres to the plate next within it. The plates are not vertical in their direction. On making a vertical section of a disk, (fig. 126,) it will be seen that a certain number of those nearest the circumference <sup>1 1</sup> curve outwards, while others situated more deeply are inclined in the opposite direction <sup>2 2</sup>; the former are more closely compacted together. When the spine is bent in any direction the curves formed by the different layers are augmented on the side towards which the column is inclined. The interstices between the plates are filled by a pulpy and apparently elastic substance; and as the number of plates gradually decreases towards the centre, (fig. 125,<sup>2</sup> and 126,<sup>3</sup>) whilst the pulpy matter increases, the quantity of the latter is such, that, when the pressure which confines it is taken off by cutting through the intervertebral substance, it will rise up so as to assume a conical form.

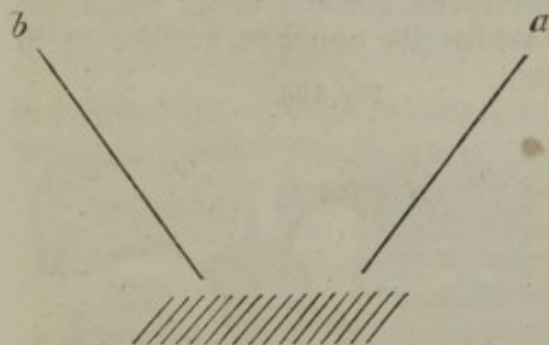


Fig. 127.



Two lumbar vertebræ with the intervertebral substance are seen from before. By removing a portion of one layer of the latter, another layer is partly exposed, and the difference in the direction of their fibres is made manifest.

[Fig. 128.]



blending with each other produce the impression of a layer of cartilage.—J. L.] Some fibres will be found to be nearly horizontal.

*The intervertebral substance in the column generally.*—Excluding from consideration the first two vertebræ, between which it does not exist, the intervertebral tissue forms in length about a fourth of the movable part of the column. But it is not equally distributed among the different parts. It varies in thickness from point to point, and the dorsal division of the spine has, comparatively with the length, a much smaller proportion, and has accordingly less provision for pliancy than the cervical or lumbar portions of the column.\*

Moreover, the disks are not uniform in their thickness. In the cervical and lumbar regions, which are convex forwards, they are thickest in front; and by comparing the heights of the fore and back parts of the bodies of the vertebræ, and comparing in like manner the heights of the anterior with the posterior margins of the intervertebral

The plates of the intervertebral tissue being examined singly, it will be found that each consists for the most part of fibres extending obliquely between the vertebræ, into both of which they are firmly fixed; and the direction of the fibres varies from layer to layer,—in one being from right to left, and in the next the reverse (fig. 127, <sup>1 2</sup>). [This arrangement of the concentric layers of fibres, when viewed upon either surface of the intervertebral disk, gives rise to the impression of the existence of alternating layers of white fibrous tissue, distinguished by its silvery, shining appearance, and of cartilage, distinguishable by its dull, translucent appearance. This illusion, which has frequently proved deceptive, arises from the different direction in which the extremities of the fibres of the layers meet the eye; thus, if they be viewed in the direction of the line *a*, fig. 118, the ends of the fibres being opposed to the eye produce the impression of a fibrous tissue, but in the direction of the line *b*, the ends of the fibres

\* In an elaborate work on the joints and their various movements, the brothers W. and E. Weber have given various measurements of the individual vertebræ, and the interposed tissues, and have grounded on them calculations of the degree of flexibility of the column in different parts. In order to render their measurements more exact by preventing all separation of the parts, they placed a body in plaster of Paris, (after having removed some of the soft parts, but without interfering with the ligaments,) and when it was immovably fixed by this means, a vertical section was made through the middle of the trunk, dividing it into two equal lateral parts.—See "Mechanik der menschl. Gehwerkzeuge," S. 90, et seq. Göttingen, 1836.



disks, it has been determined that the convexity of the cervical and lumbar portions of the column is chiefly due to the latter structure,—to it much more than to the bodies of the vertebræ; while the arching of the dorsal region was, on the contrary, found to be owing rather to the shape of the bones.

The *articulating processes* of the vertebræ are connected by irregular fibrous bands (*ligamenta processuum obliquorum*, Weitbr.), forming a capsule outside the synovial membrane which belongs to each of the joints. The latter are longer and more loose in the cervical than in the dorsal or lumbar regions.

The arches, or plates of the vertebræ, are connected by the *ligamenta subflava*, (fig. 129,) (*ligamenta vertebrarum subflava*,—Weitbr.) as their bodies are by the intervertebral fibro-cartilages. They are most distinctly seen when the pedicles and arches are detached from the bodies of the vertebræ, so that they may be viewed from within the spinal canal, as in this drawing (fig. 129); at the posterior aspect of the spine they appear short, and, as it were, overlaid by the arches (fig. 138,<sup>2</sup>). They extend from the root of the transverse process at each side backwards to the point where the two arches converge at the origin of the spinous process. In this situation the ligaments are thickest, and the margins of the lateral halves may be observed to be merely in contact.

These ligaments consist of yellow elastic fibres, almost perpendicular in their direction as they pass from the inferior border of one arch to the adjacent border of that immediately below it. The superior border of the ligament is attached, not to the margin exactly of the arch, but rather higher up on its anterior surface; whilst the inferior border is prolonged a little on the posterior surface, as well as the margin of its corresponding arch.

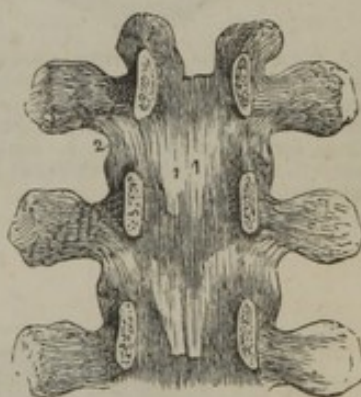
The *ligamenta subflava* do not exist between the occiput and the atlas, or between the latter and the axis; common fibrous membrane supplies their place in these two spaces.

The connexion of the spinous processes is effected by means of the supra-spinous and interspinous ligaments.

1. The *supra-spinous ligament* (*ligamenta, queis apices committuntur*,—Weitbr.) consists of small, compressed bundles of longitudinal fibres, which connect the summits of the spinous processes, and form a continuous chain from the seventh cervical vertebra to the spine of the sacrum. (See fig. 138,<sup>1</sup>) The posterior fibres pass down from a given vertebra to the third or fourth below it; those more deeply seated reach only from one to the next, or the second beneath it.

2. The *interspinous ligaments* (*membrana interspinalis*—Weitbr.), thin and rather membranous, extend from the root to near the summit

[Fig. 129.]



An internal view of the arches of three vertebræ. To obtain this view the laminae have been divided through their pedicles. 1. One of the ligamenta subflava. 2. The capsular ligament of one side.—W.]



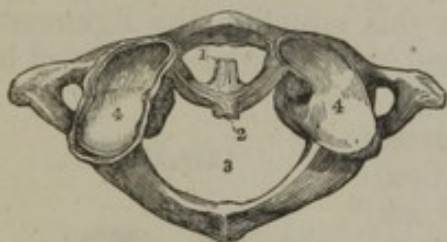
of each spinous process, connecting the inferior border of one with the superior border of that next below it. They exist in the dorsal and lumbar regions only, and are intimately connected with the extensor muscles of the spine.

The *intertransverse ligaments* (lig. process. transv.—Weitbr.) are found only between the transverse processes of the inferior dorsal vertebræ, and even there very indistinctly, for they are united so intimately with the sacro-lumbalis muscle, that their fibres are quite confused; indeed, they appear to be rather appendages to the muscles than ligaments to connect the bones; and they are so considered by Weitbrecht, Meckel, and Sæmmerring. By the last-named author they are recognised as present in the lumbar as well as the dorsal region.

#### ARTICULATIONS OF THE TWO UPPER VERTEBRÆ ONE WITH THE OTHER.

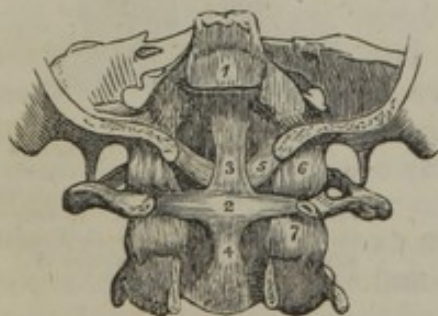
The articulation of the axis with the atlas is effected by means of their articulating processes, also, (in the place of intervertebral substance, which would be altogether incompatible with the requisite movements,) by the odontoid process of the former, which is connected in a particular manner with the arch of the latter, and constitutes the pivot on which the head turns in its rotatory motions. There are three ligaments and four synovial membranes in this articulation.

Fig. 130.



A view of the atlas from above, showing the transverse ligament, with fragments of its appendages. 1. The space for the odontoid process. 2. The transverse ligament. 3. Space for the spinal cord. 4. Articular processes;—on one of these a remnant of the capsular membrane is seen.

[Fig. 131.



A posterior view of the ligaments connecting the atlas, the axis, and the occipital bone. The posterior part of the occipital bone has been sawn away, and the arches of the atlas and axis removed. 1. The superior part of the occipito-axoid ligament, which has been cut away in order to show the ligaments beneath. 2. The transverse ligament of the atlas. 3. 4. The ascending and descending slips of the transverse ligament, which have obtained for it the title of cruciform ligament. 5. One of the odontoid ligaments; the other ligament is seen on the opposite side. 6. One of the occipito-atloid capsular ligaments. 7. One of the atlo-axoid capsular ligaments.—W.]

The *transverse ligament*, (fig. 130,<sup>2</sup>) (ligamentum transversale: pars principalis,—Weitbr.), is placed transversely behind the odontoid process of the axis, and forms with the anterior arch of the atlas a ring,<sup>1</sup> in which that process is lodged; dividing thus the great foramen of the first vertebra into two parts of unequal size, of which the larger<sup>2</sup> is appropriated to the spinal cord, and the smaller<sup>1</sup> is occupied in the manner already stated.

The ligament is a strong, thick, fasciculus of fibres, compressed from before backwards, arched in its direction, as it crosses the odontoid process, and attached on each side to the inner border of the superior articulating processes of the atlas. The ligament is broader and thicker at the middle than at its extremities; and from the middle of its posterior sur-



face a short thin bundle of fibres passes down to be attached to the root of the odontoid process, whilst another passes up to the basilar process. *These appendages* (lig. transv. appendices,—Weitbr.) form a cross with the transverse ligament, and serve to bind the occiput to the first two vertebræ; from this is derived the term *cruciform*, which is sometimes applied to the transverse ligament and its appendages together. (Fig. 131.)

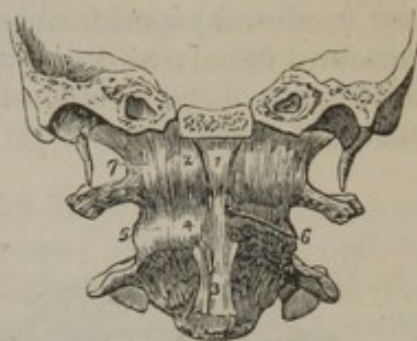The *anterior atlo-axoid ligament* passes from the border of the anterior arch of the atlas, and its tubercle, to the body of the axis and the root of its odontoid process. It is thin and membranous, except at the middle, where it is more thickened (fig. 132,<sup>4</sup>).

The *posterior atlo-axoid ligament*, which is also thin and membranous, connects the posterior arch of the atlas with the plates of the axis (fig. 133,<sup>5</sup>). Thus the interstices between the plates or arches, which in all the other vertebræ are filled by the ligamenta subflava, are occupied by a loose membrane between the second and first, as well as between the latter and the occiput.

The edges of the articulating processes are connected by irregular fibres passing from one to the other.

Two *synovial membranes* are placed between the articulating processes of the atlas and axis. One between the odontoid process and the transverse ligament, another between it and the arch of the atlas.

[Fig. 132.]



An anterior view of the ligaments connecting the atlas, the axis, and the occipital bone. A transverse section has been carried through the base of the skull, dividing the basilar process of the occipital bone and the petrous portions of the temporal bones. 1. The anterior middle occipito-atloid ligament. 2. The anterior occipito-atloid ligament. 3. The commencement of the anterior common ligament. 4. The anterior atlo-axoid ligament, which is continuous inferiorly with the commencement of the anterior common ligament. 5. One of the atlo-axoid capsular ligaments; the one on the opposite side has been removed, to show the approximated surfaces of the articular processes (6). 7. One of the occipito-atloid capsular ligaments. The most external of these fibres constitute the lateral occipito-atloid ligament.—W.]

#### ARTICULATIONS OF THE CRANIUM WITH THE FIRST TWO VERTEBRÆ.

The cranium is articulated with the atlas, and is connected by ligaments with the axis.

The *articulation of the cranium with the atlas* takes place between the condyles of the occipital bone and the superior articulating processes of that vertebra, which are connected by ligaments and synovial membranes; it is also connected with the same by the two following ligaments.

The *anterior occipito-atloidean ligament* (fig. 132,<sup>2</sup>) (*membrana annuli anterioris vertebræ primæ*) extends from the anterior border of the occipital foramen, between the condyles, to the margin of the arch of the atlas between its superior articulating processes. This is thin, broad, and membranous; but in the median line, a sort of accessory ligament<sup>1</sup> is placed in front of it, which is thick, round, and composed of vertical fibres, attached above to the surface of the basilar process, and below to the small tubercle on the front of the atlas. The anterior



surface of these ligaments is covered by the recti antici muscles, the posterior covers the upper end of the odontoid process and its ligaments.

The *posterior occipito-atloidean ligament*, (*membrana annuli posterioris atlantis*;) (fig. 133,<sup>3</sup>) also broad and membranous, is attached superiorly to all that part of the margin of the occipital foramen which is behind the condyles, and inferiorly to the adjacent border of the posterior arch of the atlas. It is partly blended with the dura mater. The posterior surface of the ligament is in apposition with the posterior recti and superior oblique muscles, the anterior looks towards the vertebral canal; at each side near the articular process the ligament forms part of the foramen through which the vertebral artery and suboccipital nerve pass.

[Fig. 133.]

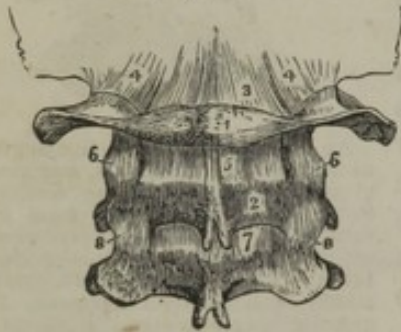

Fig. 134.

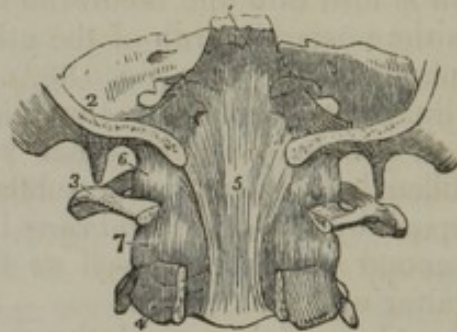

Fig. 133. The posterior ligaments of the occipito-atloid, and atlo-axoid articulations. 1. The atlas. 2. The axis. 3. The posterior ligament of the occipito-atloid articulation. 4, 4'. The capsular and lateral ligaments of this articulation. 5. The posterior ligament of the atlo-axoid articulation. 6, 6'. Its capsular ligaments. 7. The first of the ligamenta subflava passing between the axis and the third cervical vertebra. 8, 8'. The capsular ligaments of those vertebrae.

Fig. 134. The upper part of the vertebral canal, opened from behind in order to show the occipito-axoid ligament. 1. The basilar portion of the sphenoid bone. 2. Section of the occipital bone. 3. The atlas, its posterior arch removed. 4. The axis, the posterior arch also removed. 5. The occipito-axoid ligament, rendered prominent at its middle by the projection of the odontoid process. 6. Lateral and capsular ligament of the occipito-atloid articulation. 7. Capsular ligament between the articulating processes of the atlas and axis.—W.]

The *articulation of the occipital bone with the axis* is effected through the medium of ligaments, as no part of their surfaces comes into contact, and the ligaments are placed within the vertebral canal, which must be laid open to exhibit them.

The *occipito-axoidean ligament* (*apparatus ligamentosus*) (fig. 134,<sup>5</sup>) seems to be a prolongation of the posterior common ligament; it is attached above to the inner surface of the basilar groove, from which it descends perpendicularly, becoming narrow, and opposite the axis is blended with the posterior common ligament. It covers the odontoid process and its check ligaments, and is intimately connected with the transverse ligament.

The *odontoid ligaments* (fig. 131,<sup>5</sup>) (*ligamenta alaria*) are two thick bundles of fibres attached below to each side of the summit of the odontoid process, and passing up diverging to be implanted into the rough depressions at the inner side of the condyles of the occiput, and also to a small part of the margin of the occipital foramen. Their direction, therefore, is obliquely upwards and outwards; the triangular interval which they thus leave is filled by some fibres (*ligamentum*



rectum medium, seu dentis suspensorium) passing almost perpendicularly from the margin of the foramen to the summit of the process. These are strictly check ligaments; the middle set, last described, assist in preventing what may be termed a retroversion of the head, whilst the lateral pair check its rotatory motions.

ARTICULATION OF THE LOWER JAW WITH THE  
CRANIUM—TEMPORO-MAXILLARY.

The lower jaw articulates at each side by one of its condyles with two parts of the temporal bone; viz. the glenoid fossa in front of the Glaserian fissure, and the articular root of the zygoma. Between the bones is placed an interarticular cartilage, with a synovial membrane above, and another below it, and around the joint are disposed the ligaments.

The *external lateral ligament* (fig. 135,<sup>5</sup>) is a short fasciculus of fibres, attached above to the external surface of the zygoma, and to the tubercle at the bifurcation of its root; below, to the external surface and posterior border of the neck of the condyle, its fibres being directed downwards and backwards. Externally it is covered by the parotid gland, internally it is in relation with the interarticular cartilage and synovial membranes.

[Fig. 135.

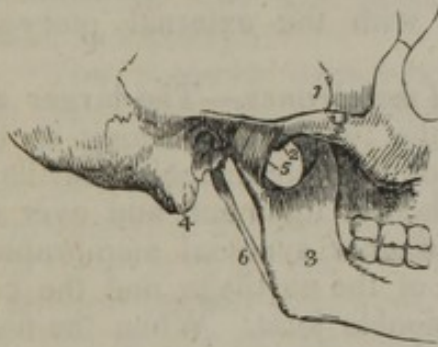

Fig. 136.

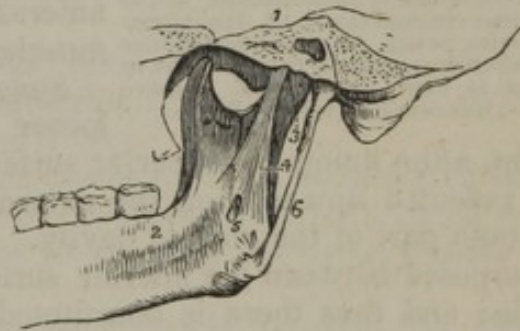

Fig. 135. An external view of the articulation of the lower jaw. 1. The zygomatic arch. 2. The tubercle of the zygoma. 3. The ramus of the lower jaw. 4. The mastoid portion of the temporal bone. 5. The external lateral ligament. 6. The stylo-maxillary ligament.

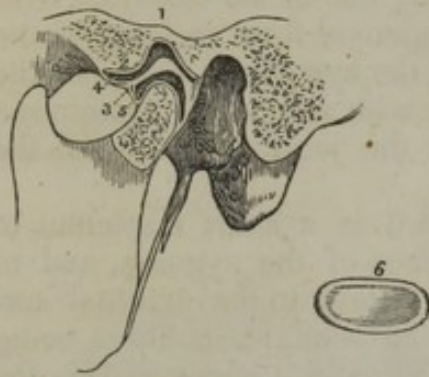Fig. 136. An internal view of the articulation of the lower jaw. 1. A section through the petrous portion of the temporal bone and spinous process of the sphenoid. 2. An internal view of the ramus, and part of the body of the lower jaw. 3. The internal portion of the capsular ligament. 4. The internal lateral ligament. 5. A small interval at its insertion, through which the mylo-hyoidean nerve passes. 6. The stylo-maxillary ligament, a process of the deep cervical fascia.—W.]

The *internal lateral ligament*, (fig. 136,<sup>4</sup>) thin, loose, and elongated, lies at some distance from the joint. It extends from the spinous process of the sphenoid bone downwards, and a little forwards, to be attached to the inferior maxillary bone at the lower border of the dental foramen, where it is somewhat expanded. Its external surface is in relation superiorly with the external pterygoid muscle, and in the rest of its extent with the ramus of the jaw, from which it is separated by the internal maxillary artery and dental nerve. Its inner surface is concealed by the internal pterygoid muscle. The structure described here as a ligament has more connexion with vessels and muscles than with the joint. It is not recognised as a ligament by several anatomists.



The *stylo-maxillary ligament* (figs. 135, 136,<sup>6</sup>) thin and aponeurotic, being, in fact, a portion of the cervical fascia, passes from near the point of the styloid process to the inferior border of the angle of the jaw, where it is inserted between the masseter and internal pterygoid muscles. This membrane separates the parotid gland from the submaxillary. It has little claim to be considered an appendage to the temporo-maxillary articulation.

[Fig. 137.



In this sketch a section has been carried through the joint, in order to show the natural position of the interarticular fibro-cartilage, and the manner in which it is adapted to the difference of form of the articulating surfaces. 1. The glenoid fossa. 2. The eminentia articularis. 3. The interarticular fibro-cartilage. 4. The superior synovial cavity. 5. The inferior synovial cavity. 6. An interarticular fibro-cartilage, removed from the joint, in order to show its oval and concave form; it is seen from below.—W.]

The *interarticular fibro-cartilage*, (*operculum cartilagineum mobile*,—Weitbr.) (fig. 137,<sup>3, 6</sup>) is a thin plate, placed horizontally between the articular surfaces of the bones; but is not, like most other similar structures, directly fixed to either. It is of an oval form, and thicker at its margins than at its centre, where it is sometimes perforated. The inferior surface, which is in contact with the condyle, is concave; the superior is alternately concave and convex when taken from before backwards, conforming in some way with the outline of the articular cavity. Its circumference is connected at the outside with the external lateral ligament, and anteriorly with the external pterygoid muscle.

*Synovial membranes*.—The larger and looser of the two which belong to this joint, after lining the superior surface of the interarticular cartilage, is reflected upwards on the external lateral ligament, and over the smooth part of the glenoid cavity. The other synovial membrane is interposed between the inferior surface of the cartilage and the condyle; and thus there is constituted a double joint. When the fibro-cartilage is incomplete (perforated), the synovial membranes are continuous one with the other.

Thin and short additional ligamentous fibres surround a considerable part of the joint (*membrana articularis*,—Weitbr.), and serve to cover over the synovial membranes, as well as to maintain the connexion between the bones and the interposed fibro-cartilage.

#### ARTICULATIONS OF THE RIBS.

The ligaments of the ribs may be divided into three sets: those which connect them—with the bodies of the vertebræ; with their transverse processes; and with the sternum.

A. The rib is connected with the bodies of two vertebræ, forming with each a joint lined with synovial membrane, and supported by ligaments, as follows:—

The *costo-vertebral ligaments* (*lig. capitulorum costarum*) consist,—  
1. of an anterior ligament which connects the head of each rib with the sides of the bodies of the vertebræ (figs. 123, 139,<sup>3</sup>); its fibres, flat and radiated, are divided into three bundles, of which the middle one



passes horizontally forwards upon the corresponding intervertebral cartilage, whilst the superior ascends to the body of the vertebra above it, and the inferior descends to that below. From the divergence of its fibres, this is usually called the *stellate ligament*. 2dly. Of an *interarticular ligament*, a thin and short band of fibres, which passes transversely from the ridge separating the two articular surfaces on the head of the rib to the intervertebral substance, and divides the articulation into two parts, each lined by a separate synovial membrane. The ligament does not exist in the articulation of the first, eleventh, or twelfth ribs, and in consequence there is in them but one synovial capsule.

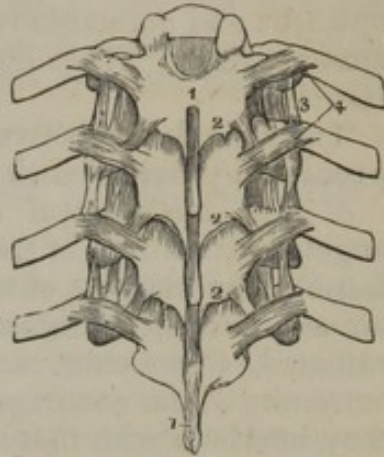
B. The rib is connected with the transverse process of two vertebræ; with one it forms a joint lined by synovial membrane; to the other (being separated from it by a considerable interval) it is connected by ligamentous structure of some length.

The *costo-transverse ligaments* connect the tubercle and neck of the rib with the transverse process of the vertebræ; from their position they are named posterior, middle, and anterior.

1. The *posterior costo-transverse ligament* (fig. 138,<sup>4</sup>) (lig. transversarium externum costarum,—Weitbr.) consists of a very short thick fasciculus of fibres which passes from the posterior surface of the summit of the transverse process, to the rough unarticulated part of the tubercle of the rib. Those of the superior ribs ascend, those of the inferior descend somewhat.

2. The *middle or interosseous costo-transverse ligament* (fig. 139,<sup>6</sup>)

[Fig. 138.



A posterior view of a part of the thoracic portion of the vertebral column, showing the ligaments connecting the vertebrae with each other, and the ribs with the vertebræ. 1, 1. The supra-spinous ligament. 2, 2. The ligamenta subflava, connecting the laminae. 3. The anterior costo-transverse ligament. 4. The posterior costo-transverse ligaments.—W.]

Fig. 139.

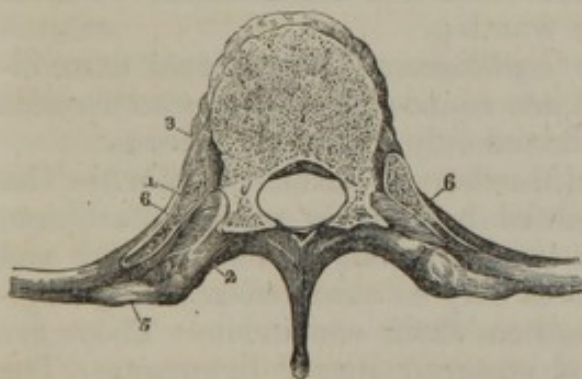
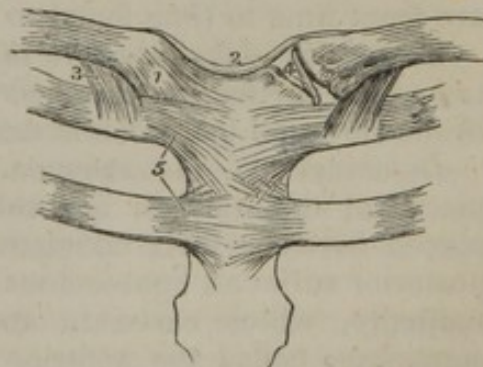


Fig. 139. A horizontal section of a vertebra and portions of two ribs, to show the interosseous ligament connecting the neck of the rib to the transverse process of the vertebra on each side. 1. The rib. 2. Transverse process. 3. Lig. capit. costæ. 5. Posterior costo-transverse. 6. Interosseous or middle costo-transverse.

[Fig. 140. The ligament of the sterno-clavicular and costo-sternal articulations. 1. The anterior sterno-clavicular ligament. 2. The inter-clavicular ligament. 3. The costo-clavicular or rhomboid ligament, seen on both sides. 4. The interarticular fibro cartilage, brought into view by the removal of the anterior and posterior ligaments. 5. The anterior costo-sternal ligaments of the first and second ribs.—W.]

[Fig. 140.





consists of a series of very short parallel fibres, which unite the neck of the rib to the anterior surface of the contiguous transverse process. These fibres are seen by removing horizontally a portion of the rib and transverse process, and forcibly drawing one from the other.

3. The *anterior* or *long costo-transverse ligament* (fig. 138,<sup>3</sup>) (lig. transversarium internum, seu cervicis costæ internum,—Weitbr.) is usually divided into two fasciculi of fibres, both nearly in apposition, and on the same plane. They pass from the neck of the rib obliquely upwards and outwards to the lower margin of the transverse process next above it. These do not exist in the articulations of the first and last ribs.

The articulation between the tubercle of the rib and the transverse process is provided with a synovial capsule.

c. The *costo-sternal articulations*, situated between the anterior angular extremities of the cartilages of the ribs and the corresponding fossæ in the margins of the sternum, are covered and supported by, *a*, an anterior set of ligamentous fibres, (fig. 140,<sup>5</sup>) thin, scattered, and radiated, (ligamenta radiatim disiecta,—Weitbr.) passing from the extremity of the cartilage to the anterior surface of the sternum, where they interlace with those of the opposite side, and are blended with the aponeurosis of the pectoralis major muscle; *b*, a posterior set of fibres similarly disposed, but not so thick or numerous, connecting the thoracic surfaces of the same parts; *c*, some ligamentous fibres placed above and others below the joint; *d*, a synovial membrane, interposed between the ends of each true rib and the sternum. These can be demonstrated by slicing off a little of the anterior surface of the sternum and cartilages.

A thin fasciculus of fibres connects the cartilage of the seventh rib (and, it may be likewise, the sixth) with the xiphoid cartilage, and is thence called the *costo-xiphoid ligament*.

*Articulation of the cartilages one with the other.*—The neighbouring edges of the cartilages of the ribs, from the sixth to the ninth, have articular surfaces, which are lined by synovial membranes, and held in connexion by ligamentous fibres. Some of the articular surfaces are from time to time found to be wanting.

*Connexion of the ribs with their cartilages.*—The external extremities of the cartilages are received into rounded depressions on the ends of the ribs, and the union is maintained only by the periosteum.

*Ligaments of the sternum.* (Membrana sterni,—Weitbr.)—The pieces of the sternum are connected by a layer of fibro-cartilage, placed between their contiguous borders; and, on the anterior and posterior surfaces, ligamentous fibres may be observed running longitudinally, which serve to strengthen their connexion. They are sometimes called the anterior and posterior sternal ligaments. The longitudinal fibres are mixed with those radiating from the costal cartilages, especially in front of the sternum, where likewise they blend with the aponeuroses of the pectoral muscles. The anterior portion has thus most of the accessory fibres, and is rough and irregular; the posterior one is smooth and pearly in its aspect.



## ARTICULATIONS OF THE SUPERIOR EXTREMITIES.

The superior extremity has but one point of bony attachment to the trunk, namely, that at the sterno-clavicular articulation, the scapula being connected with the trunk by muscles only.

The articulations of the upper extremity may be arranged under the following heads, taking them in their anatomical order, from above downwards: 1, the articulations of the clavicle at one end with the sternum, and at the other end with the scapula; 2, that of the scapula and humerus; 3, of the elbow; 4, of the wrist; 5, of the hand; 6, of the fingers.

## ARTICULATION OF THE CLAVICLE WITH THE TRUNK AND WITH THE SCAPULA.

The clavicle by its inner end articulates with the first bone of the sternum, and is connected by ligaments to its fellow of the opposite side and to the first rib. The outer end of the bone is joined in the same way with the scapula.

*Sterno-clavicular articulation.*—The inner end of the clavicle is considerably thicker than the articular part of the sternum, and the surface of each of the bones is somewhat concave and convex. The other structures of which the joint consists are, an anterior and posterior ligament, an interarticular cartilage, and two synovial membranes.

The *anterior sterno-clavicular ligament* (fig. 140,<sup>1</sup>) passes from the inner extremity of the clavicle, downwards and inwards, upon the surface of the sternum. It is broad, and consists of parallel fibres, and corresponds, internally, with the synovial membranes of the articulation, and with the interarticular cartilage to which it is adherent; externally, with the sternal origin of the sterno-mastoid muscle.

The *posterior sterno-clavicular ligament*, of similar conformation with the last, but not so broad or strongly marked, is placed between the same bones lying at the thoracic aspect of the joint. Its posterior surface is in relation with the sterno-hyoideus and sterno-thyroideus muscles.

The *interarticular fibro-cartilage*,<sup>4</sup> nearly circular in its form, and thicker at the border than at its centre, is interposed between the articulating surfaces of the sternum and clavicle. Towards its superior and posterior part it is attached to the margin of the clavicle, and at the opposite point to the cartilage of the first rib. In the latter situation it is thin and somewhat prolonged, so that the inferior border of the clavicle rests upon it.

*Synovial membranes.*—In this articulation, as in that of the lower jaw, there are two synovial membranes, of which one is reflected over the sternal end of the clavicle and adjacent surface of the fibro-cartilage, the other is disposed similarly between the cartilage and the articulating surface of the sternum.

The *interclavicular ligament*<sup>2</sup> is a dense fasciculus of fibres, placed transversely between the contiguous extremities of the clavicles. Its fibres do not pass directly across from one to the other; they dip



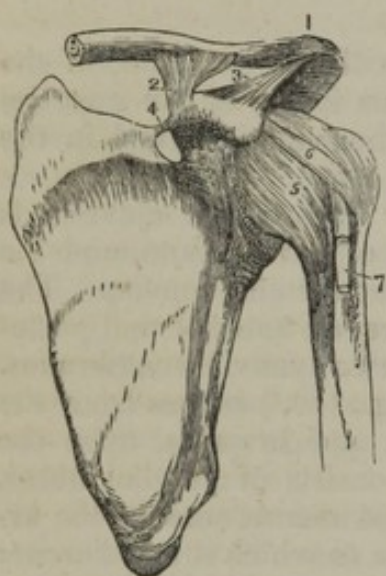
down, and are attached to the upper margin of the sternum, by which the ligament is rendered concave from side to side.

The *costo-clavicular ligament*<sup>3</sup> (ligamentum rhomboides,—Weitbr.) does not properly form part of the articulation; yet it contributes materially to retain the clavicle in its situation. It is attached inferiorly to the cartilage of the first rib near its sternal end, and passes obliquely backwards and upwards, to be fixed to a roughness at the under surface of the clavicle.

*Connexion of the clavicle with the scapula.*—At its outer end the clavicle articulates directly with the acromion, and is connected by ligamentous fibres with the coracoid process.

The *acromio-clavicular articulation* is effected between the acromion

[Fig. 141.



The ligaments of the scapula and shoulder joint. 1. The superior acromio-clavicular ligament. 2. The coraco-clavicular ligament; this aspect of the ligament is named trapezoid. 3. The coraco-acromial ligament. 4. The coracoid ligament. 5. The capsular ligament. 6. The coraco-humeral ligament. 7. The long tendon of the biceps issuing from the capsular ligament, and entering the bicipital groove.—W.]

process of the scapula and the external end of the clavicle, each of which presents a small oval articular surface. These points are connected, 1st, by a *superior ligament*, (fig. 141,<sup>1</sup>) which is a thick, broad band of fibres, passing from the superior surface of the acromion to the adjacent extremity of the clavicle; 2dly, by an *inferior ligament*, similar to the preceding, but less thick, and placed at the under surfaces of the same bones; 3dly, by a synovial membrane lining the two articular surfaces of the bones.

An *interarticular fibro-cartilage* is sometimes present, but it is more frequently wanting.\* It has, in some instances, been found to extend through part of the joint, so as only partially to separate the bones.† I have seen the fibro-cartilage as distinct in this joint as it is in the temporo-maxillary articulation. Such cases, however, are of rare occurrence.

A *synovial membrane* lines the ligaments, and covers the articular surfaces of the bones in the usual manner. When there

is an interarticular cartilage which separates the bones completely, there are two narrow synovial sacs, disposed in the same way as those in the sterno-clavicular articulation.

The *coraco-clavicular ligament* (fig. 141,<sup>2</sup>) which connects the clavicle with the coracoid process of the scapula, presents two parts, each marked by a particular name. There is, however, no division between them, nor other distinction than that they look different ways.

The *conoid ligament*, which is the posterior or internal fasciculus, broad above, narrow below, is attached, inferiorly, to the root of the

\* "Mihi vix vna alteraue vice inuenire contigit, etiamsi saepius studiose quaesiuierim."—Weitbrecht, "Syndesmologia," p. 17.

† Monro, "The Anatomy of the Human Bones," &c. fourth ed. p. 173; and Weitbrecht, Op. cit. p. 17, and tab. i. fig. 4.



coracoid process; superiorly to a rough space at the inferior surface of the clavicle, its fibres being directed backwards and upwards. The *trapezoid ligament*—the anterior or external fasciculus—passes from the superior surface of the coracoid process upwards, to an oblique line extending outwards from the tuberosity into which the conoid ligament is inserted; with the latter it unites at an angle, one of its aspects being directed forwards and upwards, the other downwards and backwards.

*Ligaments of the scapula.*—There are two ligaments proper to the scapula: 1. The *coracoid ligament*,<sup>4</sup> (ligamentum proprium posterius) is a thin flat band of fibres, attached by its extremities to the opposite margins of the notch at the root of the coracoid process, which it thus converts into a foramen for the transmission of the supra-scapular nerve, the artery most commonly passing external to it. 2. The *coraco-acromial ligament*<sup>3</sup> (ligamentum proprium anterius) is a broad, firm, triangular fasciculus, attached by its broader extremity to the coracoid process, and by the narrower to the acromion, between which it is stretched almost horizontally. Its inferior surface looks downwards upon the shoulder-joint, the superior is covered by the deltoid muscle.

#### THE SHOULDER-JOINT.

The globular head of the humerus and the glenoid cavity of the scapula are the osseous parts which compose this articulation (*scapulo-humeral*). As the head of the humerus is large and prominent, whilst the cavity is merely a superficial depression, it must be evident that they are retained in their situation not by any mechanical contrivance, but by the capsular ligament, and the muscles which are attached to the two tuberosities of the humerus.

The *capsular ligament* (fig. 141,<sup>5</sup>) is attached superiorly round the margin of the glenoid cavity, and inferiorly round the neck of the humerus, or rather a little beyond this, and more so on the lower than the upper part of the bone. It is much broader in the latter than in the former situation; and its laxity is such, that, if the muscular connexions of the humerus be detached, this bone drops away from the glenoid cavity. The superior and inner part of this membrane is covered and strengthened by a bundle of fibres<sup>6</sup> passing outwards and forwards from the coracoid process to the great tuberosity of the humerus (*coraco-humeral ligament*). Besides this, it receives additions from the thick tendons of the supra and infra spinatus, and the teres minor muscles, which are intimately connected with it, as they proceed to be attached to the tuberosities of the humerus. By means of these accessory structures the superior part of the capsule is thick and firm, while the inferior is comparatively thin and weak. At the inner side the ligamentous fibres of the capsule are wanting for a small space; and here the upper part of the tendon of the subscapularis muscle, passing through the opening (foramen ovale) comes into contact with the synovial membrane. The fibrous capsule is lined by the synovial membrane; the external surface, besides the muscles already mentioned, is covered by the deltoid; inferiorly, it is in relation with the



long head of the triceps and the circumflex vessels. The insertion of its inferior border is interrupted to give passage to the long tendon of the biceps muscle.

The *coraco-humeral*, or accessory ligament,<sup>6</sup> above noticed, extends obliquely over the upper and outer part of the articulation; it is attached to the coracoid process, and thence descends, intimately connected with the capsule, to the greater tuberosity of the humerus.

The *glenoid ligament* appears to be continuous with the tendon of the long head of the biceps muscle: this, at its point of attachment to the superior margin of the glenoid cavity, separates into two sets of fibres, which, after encircling it, meet and unite inferiorly. These fibres, by elevating the border of the cavity, render it a little deeper.

The *synovial membrane* lines the glenoid cavity, and is reflected over its lower margin until it reaches the inner surface of the fibrous capsule, on which it is prolonged as far as the neck of the humerus, where it separates from the capsule, and is applied upon the articular surface of the head of that bone, giving it a smooth investment. Viewed in this way, it appears a simple shut sac; and such it would be but for the peculiar relation of the long tendon of the biceps muscle to the shoulder-joint. The tendon is in fact enclosed in a tubular sheath, formed by an offset or process of the synovial membrane, which is reflected upon it where it is about to pass through the fibrous capsule, and is thence continued up to the summit of the glenoid cavity, where it is continuous with that part of the membrane which invests it. By this provision the integrity of the articulation and of the membrane is preserved.

On the superior and external surface of the capsule a considerable bursa mucosa is situated, by means of which the contiguous surfaces of the coracoid and acromion processes, and of the coraco-acromial ligament, are rendered smooth and lubricated, to facilitate the movements of the subjacent capsule, and the head of the humerus.

#### THE ELBOW-JOINT.

The lower extremity of the humerus is connected with the ulna and radius at the elbow, so as to form a hinge-joint. The sigmoid cavity of the ulna articulates with the trochlea of the humerus, so as to admit of flexion and extension only, while the cup-shaped depression on the head of the radius can turn freely on the rounded tuberosity to which it is applied. The bones are connected by four ligaments and a synovial membrane.

The *internal lateral ligament*, (fig. 142,<sup>1</sup>) composed of diverging and radiated fibres, presents two parts, each with a different aspect, one looking obliquely forwards, the other backwards. The anterior part is attached above, where it is narrow and pointed, to the front of the internal condyle of the humerus; its fibres, as they descend, become broad and expanded, and are inserted into the coronoid process, along the inner margin of the sigmoid cavity. The posterior part, of the same form (triangular), passes from the under and back part of the same process of bone downwards to the inner border of the olecranon; the superior fibres of this portion extend transversely



between the points just named, the rest become successively more and more oblique.

The *external lateral ligament*, (fig. 143,<sup>2</sup>) shorter and much narrower than the internal, is attached superiorly to the external condyle of the humerus, and inferiorly becomes blended with the annular ligament of the radius; none of its fibres are prolonged to the surface of that bone—if they were, they would check its rotatory motion. It is intimately connected with the tendinous attachment of the extensor muscles; on which account, when dissected, it presents a jagged irregular appearance.

The *anterior ligament* (fig. 142,<sup>3</sup>) is a broad thin membrane, placed in front of the joint, extending from the rough margin of the fossa, which receives the coronoid process during flexion, downwards to the anterior border of the coronoid process, and to the annular ligament of the radius. Some of its fibres are directed obliquely downwards and outwards, others are vertical. It is continuous at each side with the two preceding ligaments.

The *posterior ligament*, (fig. 143,<sup>4</sup>) loose and weak, consists of fibres proceeding in opposite directions; thus some pass transversely between the adjacent margins of the fossa which receives the head of the olecranon; whilst others, subjacent to these, but not very well marked, pass vertically from the superior concave margin of that fossa to the extremity of the olecranon.

Though these structures are described and named as separate ligaments, it will be found, on examination, that they form a continuous membrane placed round the joint, as fibrous capsules usually are, except only that the irregularity of the surfaces to which they are attached prevents their continuity from being readily perceived, and

Fig. 142.

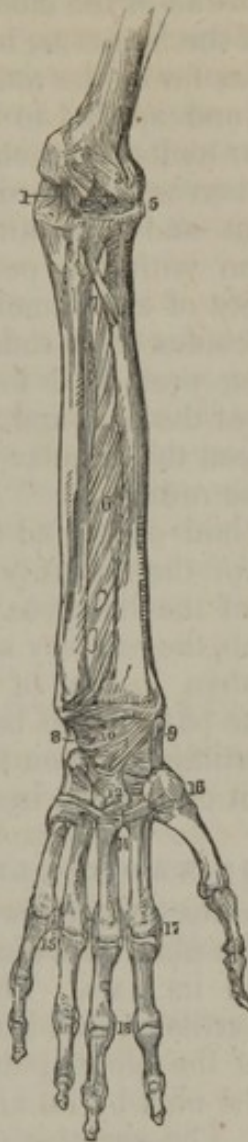
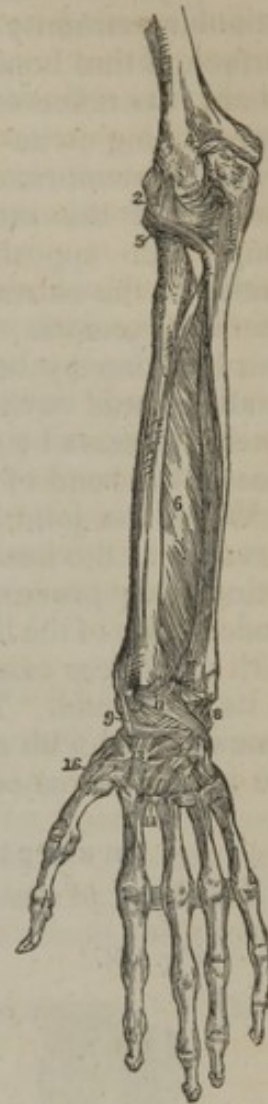
Fig. 143.



Figures 142 and 143 are front and back views of the bones and ligaments of the left fore-arm and hand. 1. The internal lateral ligament. 2. The external lateral. 3. The anterior. 4. Points to the posterior. 5. Orbicular ligament of the radius. 6. Interosseous membrane. 7. Round ligament. 8. Internal ligament of the wrist. 9. External of the same. 10. Anterior. 11. Posterior. 12. Palmar, and 13. dorsal carpo-metacarpal ligament. 14. Ligaments connecting metacarpal bones. 15. Transverse metacarpal ligament. 16. Carpo-metacarpal ligament of thumb (capsular). 17. Lateral ligaments connecting the phalangeal with the metacarpal bones. 18. Lateral ligaments of phalanges.



gives them the appearance of distinct ligamentous connexions passing from one point of bone to another.

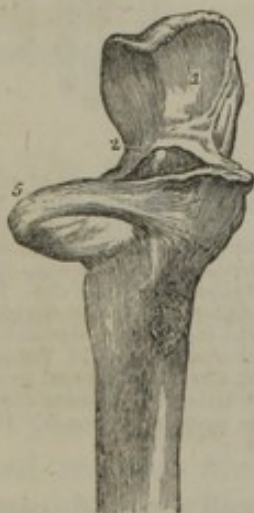The *synovial membrane* of the elbow-joint, after having covered the articular extremity of the humerus, is prolonged a little on the anterior surface of that bone, as far as the attachment of the anterior ligament, where it is reflected, and applied to the internal surface of that membrane, lining it as far as its radio-cubital insertion; at that point the synovial membrane leaves the fibrous one, and invests the articular surfaces of the radius and ulna, and is extended over them until it comes into apposition with the posterior ligament, by which it is guided to the extremity of the humerus; in the same way, it lines the lateral ligaments. Besides these reflections, the membrane forms two pouches, one by being prolonged into the joint formed between the small sigmoid cavity of the ulna and the head of the radius; the other, where it passes between the annular ligament and the contiguous surface of the head of the radius.

When the joint is laid open, and the bones extended, it will be observed that the head of the radius is not in contact with the rounded articulating process of the humerus. On which account, in the extended state of the limb, the rotatory motions of this bone are performed with much less ease than in that of flexion, from its wanting support at its upper end. The part of the humerus here referred to is moreover covered with cartilage only on its anterior aspect, indicating that the radius moves on it only when in the flexed position.

#### THE UPPER RADIO-ULNAR ARTICULATION.

The head of the radius articulates with the small sigmoid cavity of the ulna, on which it rolls when it is made to turn on its axis. These surfaces are covered with cartilage, and invested by the synovial membrane of the elbow-joint. The radius is connected to the ulna by an annular ligament.

[Fig. 144.



The *annular* or *orbicular ligament* (lig. orbiculare radii,—Weitbr.) (figs. 142, 143,<sup>5</sup>) is a strong band of circular fibres, which, by being attached to the borders of the small sigmoid cavity, forms a ring (fig. 144,<sup>5</sup>) encircling the head of the radius, and binding it firmly in its situation. Its external surface is connected with the external lateral ligament of the elbow, whose fibres are inserted into it; the internal is smooth, and lined by the synovial membrane of the elbow-joint.

#### THE MIDDLE RADIO-ULNAR ARTICULATION.

1. Articular surface of olecranon process of the ulna. 2. Coronoid process. 3. Orbicular ligament surrounding the neck of the radius.—W.]

The interval between the radius and ulna in the fore-arm is occupied by an interosseous ligament and a round ligament, which serve to connect them together, and form what is called the middle radio-ulnar articulation.

The *interosseous membrane* (figs. 142, 143,<sup>6</sup>) (*membrana interossea*) is a thin, flat, fibrous membrane, the direction of its fibres being



obliquely downwards and inwards, from the inner sharp border of the radius to the contiguous one of the ulna. It does not reach the whole length of the bones, as it commences about an inch below the tubercle of the radius. The surfaces of this membrane are intimately connected with the deep-seated muscles of the fore-arm, serving to increase their points of origin as well as to connect the bones. Above the lower margin it leaves an opening for the transmission of the anterior interosseous vessels to the back of the fore-arm; and the posterior interosseous vessels pass backwards in the space above the membrane (*hiatus interosseus*).

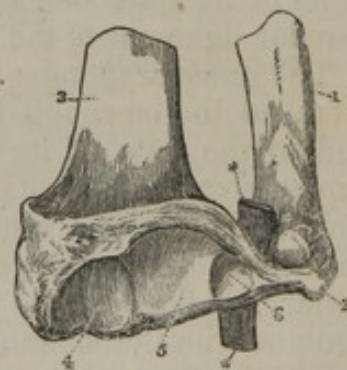
The *round ligament* (*ligamentum teres, v. chorda transversalis*,—Weitbr.) (fig. 142,<sup>7</sup>) in some measure supplies the deficiency left by the interosseous ligament at the superior part of the arm. It is a thin narrow fasciculus of fibres, extending obliquely from the coronoid process, downwards and outwards, to be attached to the radius, about half an inch below its tubercle. The direction of its fibres is therefore altogether different from that of the fibres of the interosseous ligament. Some small bundles of fibres, having the same direction as the round ligament, are often to be found at intervals on the posterior surface of the interosseous membrane.\*

#### THE LOWER RADIO-ULNAR ARTICULATION.

At the lower or carpal end of the radius and ulna, the former rotates on the latter as its point of support, the articulating surface of the radius being concave, that of the ulna convex. The bones are connected anteriorly and posteriorly by some fibres passing between their extremities, so thin and scattered as scarcely to admit or require description, but internally they are joined by a fibro-cartilage and a synovial membrane.

The *fibro-cartilage*, (*cartilago intermedia triangularis*,—Weitbr.) *triangular* in form and thick, is placed transversely between the bones (fig. 145,<sup>6</sup>). It is attached by its base to a rough line separating the carpal from the ulnar articulating surface of the radius, and by its summit to a depression at the root of the styloid process of the ulna, and to the side of that process. The superior surface of the fibro-cartilage looks towards the head of the ulna, the inferior to the cuneiform bone: both are smooth, and lined by synovial membrane; the inferior one by the large membrane of the wrist-joint, the superior by a small one peculiar to the radio-ulnar articulation. Its two borders are connected with the carpal ligaments. There is occasionally a perforation at the middle of the fibro-cartilage. As the radius rolls on the ulna, this cartilage is carried with it, and forms its chief bond of union with the latter bone.

Fig. 145.



The lower ends of the radius and ulna, with the triangular fibro-cartilage connecting them. 1. Ulna. 2. Its styloid process; 3. Radius; 4, its articular process for the scaphoid bone, and 5, that for the semilunar. 6. The triangular fibro-cartilage; its lower surface. A piece of whalebone (\*) has been passed between the upper surface and the head of the ulna.

\* Weitbrecht, Op. citat. p. 34, and fig. 11.



The *synovial membrane* is frequently called *membrana sacciformis*, though there is nothing in its conformation, except, perhaps, its looseness, which distinguishes it from other synovial sacs. It may be considered as presenting two parts, one projecting perpendicularly upwards into the articulation of the radius and ulna, lining the contiguous surfaces of each, the other placed horizontally between the head of the ulna and the corresponding surface of the fibro-cartilage, lining them also; both, however, are formed by a continuous membrane. This "sacciform" synovial membrane is continuous with that of the wrist-joint, when the triangular fibro-cartilage, being perforated, is insufficient to form a complete barrier between the two membranes.

#### THE WRIST-JOINT.

This articulation (*radio-carpal*) is formed above by the radius and triangular fibro-cartilage, and the first three bones of the carpus below. The articular aspect of the former, when viewed in the fresh state, presents an oval and slightly concave surface, its greatest breadth being from side to side. The surface of the radius is divided into parts, by a line extending from before backwards; so that these, together with the cartilage, present three articular surfaces, one for each carpal bone. The scaphoid, semilunar, and cuneiform bones are articulated together, so as to form a rounded convex surface, which is received into the concavity above described. Four ligaments and a synovial membrane retain these parts in their situation, as follows:—

The *internal lateral ligament* (figs. 142, 143,<sup>8</sup>) passes directly downwards, from the extremity of the styloid process of the ulna, to be attached to the cuneiform bone; it also sends some fibres to the anterior annular ligament and the pisiform bone. Its form is that of a rounded cord; its inner surface is in contact with the synovial membrane of the radio-carpal articulation.

The *external lateral ligament*<sup>9</sup> extends from the styloid process of the radius to a rough surface on the outer side of the scaphoid bone, some of its fibres being prolonged to the trapezium, and also to the annular ligament of the wrist.

The *anterior ligament*,<sup>10</sup> (*radio-carpal*), broad and membranous, is attached to the rough border of the carpal extremity of the radius, and to the base of its styloid process; from which, and to a small extent from the ulna, its fibres pass down to be inserted into the anterior surface of the scaphoid, semilunar, and cuneiform bones. It is pierced by several foramina for the transmission of vessels: one of its surfaces is lined by the synovial membrane of the joint, the other is in contact with the tendons of the flexor muscles.

The *posterior ligament*,<sup>11</sup> extends obliquely downwards and inwards, from the extremity of the radius, and from a small portion of the ulna, to the posterior surface of the semilunar and cuneiform bones; its fibres appear to be prolonged for some way on the carpal bones. One surface is in contact with the synovial membrane, the other with the extensor tendons. Both the anterior and posterior ligaments are connected to the sides of the triangular fibro-cartilage which binds the radius to the ulna. The whole of the preceding ligaments are continued one into the other around the wrist-joint without interruption.



The *synovial membrane*, after having lined the articular surface of the radius, and the triangular fibro-cartilage, is reflected on the anterior and posterior ligaments, and thence over the surface of the carpal bones.

#### ARTICULATIONS OF THE CARPAL BONES ONE WITH ANOTHER.

The bones of the carpus consist of two sets, each united by its proper connexions, so as to form a row; and the two rows are connected by fibrous bands and a synovial membrane, so as to form between them a joint.

The connexions proper to the first row are interosseous fibro-cartilages, and ligaments placed on their dorsal and palmar surfaces.

The *interosseous fibro-cartilages* are two lamellæ, one placed at each side of the semilunar bone, connecting it with the scaphoid and cuneiform bones. The carpal extremity of these is smooth, and lined by the synovial membrane of the wrist-joint.

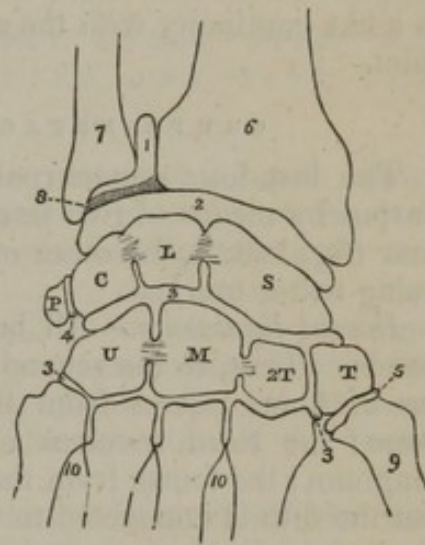
The *palmar ligaments* are two, one extending from the scaphoid bone to the semilunar, the other from the semilunar to the cuneiform, their direction being transverse; and, as their fibres are partly united, they may be considered as a continuous band connecting these bones. The *dorsal ligaments* are also two, disposed similarly, and connecting the same bones on their posterior surfaces.

The pisiform bone stands out of the range, and rests on the palmar surface of the cuneiform, with which it is articulated by an irregular fibrous capsule and a synovial membrane. There are likewise two strong ligaments, by one of which the bone is connected to the unciform, and by the other to the fifth metacarpal bone.

The carpal bones of the second range are also connected by similar means. Three *dorsal* and *palmar ligaments* pass transversely from one bone to the other. There are, however, but two *interosseous fibro-cartilages*, placed one at each side of the os magnum, connecting it with the trapezoid externally, and the unciform internally. Such are the means of connexion peculiar to each row.

The ligaments which connect the upper to the lower row of bones are placed at their palmar, dorsal, and lateral aspects.

[Fig. 146.



A diagram showing the disposition of the five synovial membranes of the wrist-joint. 1. The sacciform membrane. 2. The second synovial membrane. 3, 3. The third, or large synovial membrane. 4. The synovial membrane between the pisiform bone and the cuneiform. 5. The synovial membrane of the metacarpal articulation of the thumb. 6. The lower extremity of the radius. 7. The lower extremity of the ulna. 8. The inter-articular fibro-cartilage. S. The scaphoid bone. L. The semilunar. C. The cuneiform; the interosseous ligaments are seen passing between these three bones and separating the articulations of the wrist (2) from the articulation of the carpal bones (3). P. The pisiforme. T. The trapezium. 2 T. The trapezoides. M. The os magnum. U. The unciform; interosseous ligaments are seen connecting the os magnum with the trapezoides and unciform. 9. The base of the metacarpal bone of the thumb. 10, 10. The bases of the other metacarpal bones.—W.]



The *lateral ligaments* are placed one at the radial, the other at the ulnar border of the carpus; the former connects the scaphoid bone with the trapezium, the latter the cuneiform with the unciform.

The *palmar* or anterior ligament consists of fibres, which pass obliquely from the bones of the first to those of the second range. The *dorsal*, or posterior, is similar in structure and arrangement.

*Synovial membrane.*—It may be observed, that the first range of carpal bones forms a concavity; the second, particularly the os magnum and unciform, a convexity, which is received within it; by these means a ball-and-socket joint is formed, which is completed by a synovial membrane reflected over the articular surfaces of the different osseous pieces which compose it. The membrane, likewise, sends two processes between the three bones of the first row, and three between those of the second, so as to facilitate their respective motions. It moreover continues downwards to the joints formed between the carpal and the four inner metacarpal bones; and in some cases there is a like continuity with the synovial membrane belonging to the wrist-joint.

#### CARPO-METACARPAL ARTICULATIONS.

The last four metacarpal bones are connected with those of the carpus by means of two sets of fibrous bands, situated one on the palmar (fig. 142,<sup>12</sup>), the other on the dorsal surface (fig. 143,<sup>13</sup>), the latter being better marked.

*Dorsal ligaments.*—All but the fifth metacarpal bone receive two bands. Thus, to the second, or that of the fore-finger, a thin fasciculus of fibres passes from the trapezium, another from the trapezoid bone; the third receives one from the latter, and also from the os magnum; the fourth from the os magnum and also from the unciform; but the fifth is connected to the latter only. On the *palmar* surface a similar mode of connexion exists, but the fibres are not so well defined.

*Interosseous ligament.*—There are likewise, short, thick, interosseous fibres in one part of the carpo-metacarpal articulation,—connecting the lower and contiguous corners of the os magnum and unciform to the neighbouring angles of the third and fourth metacarpal bones. This ligament is displayed by removing the dorsal ligaments, and with them a portion or layer of the osseous structure. The *synovial membrane* for the four inner carpo-metacarpal articulations is continued from that which lines the articulations of the carpal bones one with another.

The *metacarpal bone of the thumb* is articulated on quite a different principle from the others; for, as it admits of all the motions except rotation, it is connected to the trapezium by a capsular ligament (*membranula capsularis*,—Weitbr.),<sup>14</sup> which passes from the rough border bounding its articular surface to the trapezium. These parts are lined by a separate synovial membrane.

#### CONNEXION OF THE METACARPAL BONES ONE WITH THE OTHER.

The *carpal extremities*, or *bases*, of the last four metacarpal bones are



bound together by three transverse fibrous bands,<sup>14</sup> (which are slight, and often ill-defined,) on the palmar, and the same on the dorsal surface, passing from one to the other. These bones are likewise bound together by numerous *interosseous* ligamentous fibres which occupy part of their lateral surfaces. Another portion of each of these surfaces is covered with cartilage, and lined with synovial membrane continued down between the metacarpal bones from the carpo-metacarpal articulation.

The *digital extremities (heads)* of the metacarpal bones are connected at their palmar aspect by thin ligamentous fibres passing across them from one to the other, and blended with the ligaments connecting the metacarpal bones to the phalanges. The whole is called the *transverse ligament* (*membrana ligamentosa*,—Weitbr.) Its place is indicated, fig. 142,<sup>15</sup> but it is better shown, though not numbered, in fig. 143, at the metacarpo-phalangeal joints.

ARTICULATION OF THE METACARPAL BONES WITH THE PHALANGES, AND OF THE LATTER ONE WITH THE OTHER.

The rounded head of each of the last four metacarpal bones being received into the slight concavity situated in the extremity of the first phalanx, is maintained in its position by two lateral ligaments, an anterior ligament, and a synovial membrane.

The *lateral ligaments* consist of dense and thick fasciculi of fibres (fig. 142,<sup>17</sup>), placed one at each side of the joint, and attached each by one extremity to the side of the metacarpal, by the other to the contiguous extremity of the phalangeal bone, the direction of the fibres being downwards and forwards.

The *anterior* or *palmar* ligament occupies the interval between the foregoing on the palmar aspect of each joint; it is very thick and dense, and is firmly united to the first phalangeal bone, and but loosely adherent to the metacarpal. The anterior ligament is continuous at each side with the lateral, so that the three form one undivided structure which covers the joint, except on its dorsal aspect. Its palmar surface is grooved for the flexor tendons, whose sheath is connected to it at each side; the other surface, looking to the interior of the joint, is lined by the synovial membrane, and supports the head of the metacarpal bone.\* In the ligaments of the thumb there are two sesamoid bones, placed one at each side.

The synovial membrane invests the surfaces of the heads of the bones, and is reflected on the ligaments which connect them.

The *phalanges are articulated with one another*,<sup>18</sup> on the same principle as that which obtains in the articulation between their bases and the metacarpal bones; it is therefore unnecessary to repeat what has been just stated on that subject.

\* M. Cruveilhier (Op. cit. t. i. p. 440) considers the name "glenoid ligament" to be most appropriate to these ligaments, on the ground that they serve to continue and complete the shallow (glenoid) articular cavity of the first phalanx; the size of which he regards as otherwise disproportionately small in comparison with the head of the metacarpal bone.



There are some other fibrous and ligamentous structures which deserve to be noticed in this place, but not as being connected immediately with the joints; they are rather accessories to the tendons of the muscles. Thus: along the margins of the phalanges, on their palmar aspect, are attached the *vaginal ligaments* which form sheaths for the flexor tendons, and bind them securely in their situation; these are thick and firm along the body of the phalanges, but over the flexures of the joints they are thin, so as not to impede their movements; their inner surface is lined by a fine membrane resembling the synovial class, which is reflected over the tendons, giving to each a smooth and shining appearance.

The *posterior annular ligament* of the wrist is continuous with the fascia of the fore-arm, of which it may be considered a part. It extends from the extremity of the radius, at its outer border, to the inner border of the ulna and the pisiform bone, and serves to bind down the extensor tendons.

The *anterior annular ligament* is a dense fasciculus of fibres, extended across the carpus from the pisiform and unciform bones to the trapezium] and scaphoides, so as to form a canal which transmits the flexor tendons, retains them in their situation, and modifies their direction and power of action on the hand.

#### ARTICULATIONS OF THE PELVIS.

The os sacrum, considered as the common point of support of the vertebral column above, the os coccygis below, and ossa innominata on each side, is connected with each of these in the following manner:—

*Sacro-vertebral articulation.*—The base of the sacrum is articulated with the last lumbar vertebra by means similar to those which connect the different pairs of vertebræ throughout the column; 1, by an intervertebral substance placed between their oval surfaces; 2, by the continuation of the anterior and posterior common ligaments; 3, a ligamentum subflavum connecting the arches of the last vertebra with the posterior border of the sacral canal; 4, an interspinous ligament; 5, two synovial membranes and fibrous structure for the articulating processes; and lastly, a sacro-vertebral ligament. All these, except the last, being similar to the connecting media throughout the column, require no farther description in this place.

The *sacro-vertebral ligament* (fig. 149,<sup>2</sup>) extends obliquely from the transverse process of the last lumbar vertebra downwards to the depressed lateral surface at the base of the sacrum; its form is triangular, as its fibres diverge and expand towards the sacro-iliac symphysis.

The *ilio-lumbar ligament*<sup>3</sup> is extended horizontally between the summit of the transverse process of the last lumbar vertebra and the posterior extremity of the crista of the ilium, where its fibres expand somewhat, so as to give it a triangular form. This is the only bond of union between the true vertebræ and the os ilium.

The *sacro-coccygean articulation* is effected by, 1, an *anterior ligament* (fig. 148,<sup>3</sup>), consisting of irregular fibres, placed in front of these bones, subjacent to the rectum; 2, by a *posterior ligament* more strongly marked, composed of fibres which descend upon the bones of the



coccyx, from the margin of the inferior orifice of the sacral canal, which it serves to close in and complete; 3, by a thin layer of *fibro-cartilage*, which is of soft consistence, interposed between the contiguous extremities of the sacrum and coccyx.

The several *pieces of the coccyx* are connected one to the other by a continuation of the anterior and posterior ligaments which unite the sacrum and coccyx, and by very thin interposed fibro-cartilages. M. Velpeau\* states that he had found the fibro-cartilage to be annular in shape, and that the bones were covered with cartilage towards the middle of the joint. There is, in some instances, much softness and pliancy; and a synovial membrane has been mentioned† as present in those cases in which the coccyx is freely movable.

In the adult male, the union between the sacrum and coccyx, and that between the pieces of the latter, is usually ossific. In the female this change most commonly does not occur till a more advanced period of life; the pieces of the coccyx unite one to the other in the first place, and the joint between the sacrum and coccyx is not ossified till old age comes on. The mobility increases during pregnancy.

The *sacro-iliac articulation*, often named the sacro-iliac symphysis, or synchondrosis, is formed between the rough lateral surfaces of the sacrum and ilium closely applied to one another, and connected by an irregular lamella of a cartilaginous structure.

[Fig. 147.]

Fig. 148.

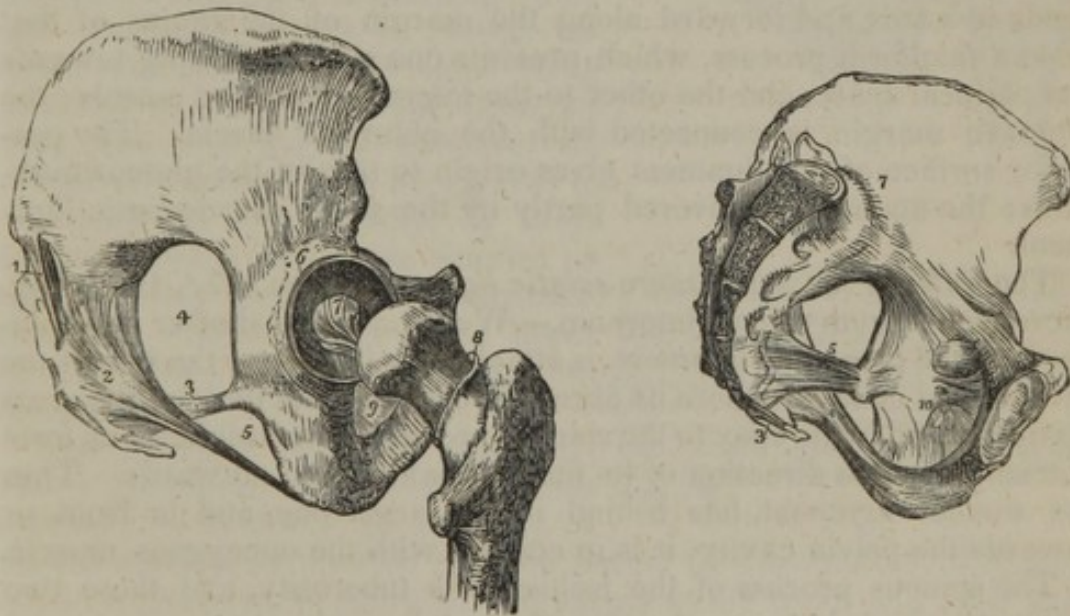


Fig. 147. Ligaments of the pelvis and hip-joint. The view is taken from the side. 1. The oblique sacro-iliac ligament. The other fasciculi of the posterior sacro-iliac ligaments are not seen in this view of the pelvis. 2. The posterior sacro-ischiatic ligament. 3. The anterior sacro-ischiatic ligament. 4. The great sacro-ischiatic foramen. 5. The lesser sacro-ischiatic foramen. 6. The cotyloid ligament of the acetabulum. 7. The ligamentum teres. 8. The cut edge of the capsular ligament, showing its extent posteriorly, as compared with its anterior attachment. 9. The obturator membrane only partly seen.—W.]

Fig. 148. A section of the pelvis having been made, the left lateral half is seen on the inner side with ligaments: viz. 3. Sacro-coccygean. 4. Great sacro-sciatic. 5. Small sacro-sciatic. 7. Anterior sacro-iliac. 10. Obturator.

\* "Traité compl. de l'art des Accouchemens," tom. i. p. 9. Paris, 1835.

† M. Cruveilhier, "Anatomie Descriptive," tom. i. p. 356. Paris, 1834.



The *posterior sacro-iliac ligaments* consist of three or four sets of short irregular fibres, extended between the posterior rough portion of the surface on the side of the sacrum and the corresponding part of the ilium, behind the articular surfaces of the bones. Some of the fibres pass horizontally between the bones, others obliquely; of the latter, one band, (fig. 147,<sup>1</sup>) extending downwards from the posterior superior spine of the ilium to the tubercles on the third or fourth piece of the sacrum, is described separately, under the name of (from its direction) the *oblique*, or (from being situated superficially to the others) the *posterior sacro-iliac ligament*. They are all placed deeply in the groove formed by the ilium and sacrum, and covered by the origin of the lumbar muscles. The *anterior sacro-iliac ligament* consists of some thin irregular fibres (figs. 148, 149,<sup>4</sup>) placed at the anterior aspect of the sacro-iliac symphysis, and attached to the pelvic surfaces of the sacrum and ilium.

The sacrum and coccyx are likewise connected with the ischium by the following ligaments:—

The *posterior or great sacro-sciatic ligament*, (figs. 147,<sup>2</sup>, 148) (ligam. sacro-ischiaticum majus,—Weitbr.) elongated, broad, and triangular, is placed at the inferior and posterior part of the pelvis, whose lower aperture it assists materially in closing. Its base or broader part is attached to the postero-inferior spine of the ilium and to the side of the sacrum and coccyx; whilst its other extremity is fixed along the inner margin of the tuber ischii, where it expands somewhat, and sends upwards and forward along the margin of the ramus of that bone a falciform process, which presents one surface looking towards the perineal space, and the other to the internal obturator muscle; the concave margin is connected with the obturator fascia. The posterior surface of this ligament gives origin to part of the gluteus maximus; the anterior is covered partly by the small sacro-sciatic ligament.

The *anterior or small sacro-sciatic ligament*, (figs. 147,<sup>3</sup>, 148,<sup>5</sup>) (lig. sacro-ischiaticum minus, internum,—Weitbr.) much shorter and thinner than the preceding ligament, is attached by its base to the side of the sacrum and coccyx, where its fibres are blended with those of the great ligament, and by its apex to the spinous process of the ischium; its form is triangular, the direction of its fibres forwards and outwards. This, the smaller ligament, has behind it the larger one, and in front, or towards the pelvic cavity, it is in contact with the coccygeus muscle.

The spinous process of the ischium, its tuberosity, and these two ligaments, bound an oval interval, (small sacro-sciatic foramen,) through which pass the obturator internus muscle, and the internal pudic vessels and nerve; and above the border of the shorter ligament is a large oval opening, (larger sacro-sciatic foramen,) bounded before and above by the margin of the ilium and ischium, and behind by the great ligament, which transmits the pyramidalis muscle, the great sciatic nerve, the gluteal and ischiadic vessels and nerves. The ligaments, therefore, convert the sacro-sciatic notches of the bones into foramina.

The *pubic articulation* (symphysis pubis) is formed by the junction



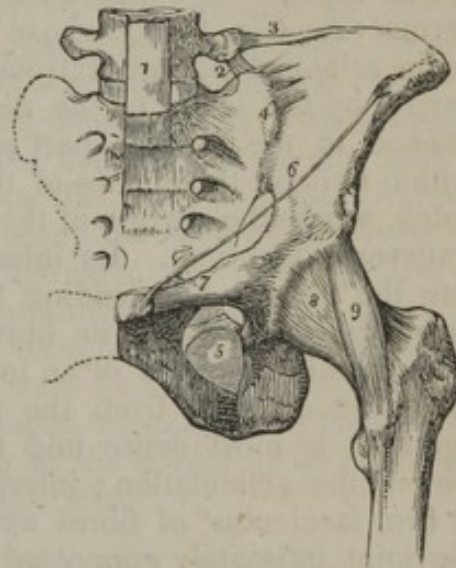
of the ossa pubis in the median line anteriorly. This is effected by an elongated piece of fibro-cartilage, interposed between their surfaces, and connected to each, and ligaments surrounding the joints.

The *fibro-cartilage* consists of concentric lamellæ, as indicated in fig. 148, is thicker anteriorly than posteriorly, and frequently projects beyond the level of the bones in the latter direction. A provision is made in this part for a slight degree of movement, which, however, is more perceptible in the female than in the male. Each pubic bone, properly speaking, has its own plate of fibro-cartilage. These plates are connected by fibres passing transversely from one to the other at the fore part as well as at the upper and lower border; but at the middle and back part they are smooth, and often lined by a slight synovial membrane.

The union between the bones is strengthened, 1st, by an *anterior pubic ligament*, which consists of irregular fibres passing obliquely across from one bone to the other, and decussating on the anterior surface of the fibro-cartilage; the fibres are intermixed with those of the aponeuroses of the external oblique muscles of the abdomen; 2dly, the *sub-pubic ligament*, (ligamentum triangulare, arcuatum,) thick and triangular, which is placed beneath the symphysis, its sides being attached to the rami of the pubis, its base free and slightly concave, directed downwards and backwards to the perinæal space; 3dly, by some indistinct fibres which are situated on the posterior surface of the articulation, and others placed on its upper border; these may be named from their position.

The *obturator ligament* (figs. 147, 149,<sup>s</sup>) (*membrana obturans foraminis thyroidis*, — Weitbr.) is properly a fibrous membrane, inserted into the border of the obturator foramen, which it closes in its entire extent, except at the upper and outer part of its circumference, where a small oval aperture is left for the exit of the obturator vessels. The membrane is fixed accurately to the margin of the bone at the upper and outer side of the foramen, and to its posterior surface on the inner side.\* The obturator muscles are attached to its surfaces.

[Fig. 149.]



The ligaments of the pelvis and hip joint. 1. The lower part of the anterior common ligament of the vertebræ, extending downwards over the front of the sacrum. 2. The lumbo-sacral ligament. 3. The lumbo-iliac ligament. 4. The anterior sacro-iliac ligament. 5. The obturator ligament. 6. Poupart's ligament. 7. Gimbernat's ligament. 8. The capsular ligament of the hip-joint. 9. The ilio-femoral or accessory ligament.—W.]

\* A detailed description of the exact manner of connexion with the bone is given by Winslow in "An Anatomical Exposition," &c. Sect. ii. § 115.



## ARTICULATIONS OF THE LOWER EXTREMITY.

## HIP-JOINT.

This is a true ball-and-socket joint, in which the globular head of the femur is received into the acetabulum or cotyloid cavity. The articulating surfaces are covered by cartilage in the greater part of their extent. It is deficient, however, at the bottom of the cavity, and also a little beneath the central point of the head of the femur; the latter marking the insertion of the round ligament, the former a shallow fossa for the lodgment of the structure which has been called the synovial gland. The connecting means in this articulation are three ligaments, viz. a capsular, cotyloid, and interarticular ligament, together with a synovial membrane.

The *capsular ligament*, dense and firm in its texture, represents a fibrous tube (fig. 149,<sup>s</sup>) whose direction is downwards and outwards; being attached by one extremity round the margin of the cotyloid cavity, by the other to the neck of the femur. Its superior circumference, in the greater part of its extent, is attached to the bone, within two or three lines of the cotyloid ligament; but opposite the notch, where the margin of the cavity is deficient, it is attached to the transverse ligament. Its inferior circumference is inserted in front into the oblique line leading from one trochanter to the other; but, superiorly and behind, its fibres are implanted into the neck of the bone, within a quarter of an inch of the trochanteric fossa, and about the same distance from the posterior inter-trochanteric line. The ligament is most dense and firm towards the superior and anterior part of the articulation; inferiorly, its fibres are comparatively thin. A firm fasciculus<sup>9</sup> of fibres extends obliquely downwards in front of the joint intimately connected with the capsule, being calculated to strengthen it, hence it is called its "accessory" ligament; but as one extremity of it is attached to the anterior inferior spinous process of the ilium, and the other to the anterior trochanteric line, it may be called the *ilio-femoral* ligament.

The capsular ligament is rough on the outer surface, which is covered by many muscles; a synovial bursa separates it in front from the conjoined psoas and iliacus. The inner surface is lined with the synovial membrane of the joint. The bursa has been found to be continuous with the synovial membrane through an opening of the fibrous capsule.

The *cotyloid ligament* [lig. cotyloideum] is a fibro-cartilaginous ring, (fig. 147,<sup>s</sup>) placed round the cavity, and serving the purpose of increasing its depth, and completing its border, where it is deficient. It is inclined inwards from the point of its connexion with the bone, so as to narrow the acetabulum, and as it were to embrace the head of the femur. The broader part or base of this structure is attached to the bone, its thin edge is free, and both its surfaces are covered by the synovial membrane, the external being in contact with the capsular ligament, the internal with the head of the femur. Its fibres are not continued all round; they rather pass obliquely from without inwards, over



the margin of the cavity, one extremity being attached to the outer, the other to its inner surface. At the cotyloid notch these fibres are continued from side to side, crossing one another, so as to render the circumference complete. Some additional fibres are superadded in this part; from which circumstance, as well as its being stretched across from one margin of the notch to the other, it is usually named the *transverse-ligament*. Subjacent to the transverse portion an interval is left for the admission of the articular vessels.

The *interarticular ligament* (fig. 147,<sup>7</sup>) is not unfrequently called the "round" ligament (tapering?) (*ligamentum teres capitis femoris*, —Weitbr.) It is a thick dense fasciculus of fibres, implanted by one extremity, which is round, into the fossa in the head of the femur; by the other, where it is broad, flat, and bifid, into the margins of the cotyloid notch, where its fibres become blended with those of the transverse ligament. The outer surface of this ligament is covered with a tubular process of the synovial membrane of the joint. It presents many varieties as to thickness and strength in different cases.

The *synovial membrane* lines the contiguous surfaces of all the parts which enter into the composition of the articulation, giving them a smooth and shining appearance. From the margin of the articular surface of the femur, it may be traced along the neck of that bone as far as the insertion of the capsular ligament, the inner surface of which it lines as far as its superior attachment. There it turns inwards over the cotyloid ligament, and dips into the cavity, lining its entire extent, and finally, guided as it were by the interarticular ligament (which it invests by a funnel-shaped process), it reaches the head of the femur, and invests it as far as the border of its cartilage, whence we proceeded in tracing its reflections.

#### THE KNEE-JOINT. (FEMORO-TIBIAL.)

This is a ginglymus, or hinge-joint, formed by the condyles of the femur above, the head of the tibia below, (with two interposed fibro-cartilages,) and the patella in front, the contiguous surfaces of each of the bones being tipped with cartilage, and invested by a common synovial membrane. The joint is supported by the following ligaments, viz., the external and internal lateral, a posterior, two crucial, some fibrous membrane, which may be considered a partial capsular ligament; besides these, the *ligamentum patellæ* may be enumerated, and one or two other structures of minor importance will be mentioned in describing the details.

The *internal lateral ligament* (figs. 150,<sup>5</sup> 151,) broad and flat, connects the tuberosity of the internal condyle of the femur with the inner surface of the tibia. Inferiorly it is covered by the tendons of the sartorius, gracilis, and semitendinosus muscles, with a synovial bursa interposed; internally it rests on the synovial membrane, and is attached to the internal semilunar cartilage.

The *external lateral ligament*<sup>6</sup> is a rounded cord-like fasciculus of fibres, shorter than the preceding ligament, which passes from the tuberosity of the external condyle of the femur, to the head of the fibula; its direction is almost vertical; its internal surface corresponds



with the tendon of the popliteus muscle and the external articular artery, the external being covered by the tendon of the biceps flexor cruris, and the expanded fascia of the extensor muscles. Posterior to this, but parallel with it, another ligament (fig. 151,<sup>7</sup>) is placed, connecting the femur and fibula; it is called the *short external lateral ligament*. The arrangement of this second or accessory part varies; it will occasionally be found to terminate in the capsular ligament.

[Fig. 150.]

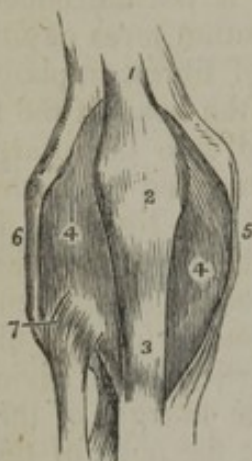


Fig. 151.

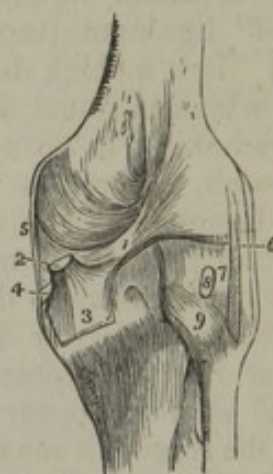


Fig. 150. An anterior view of the ligaments of the knee joint. 1. The tendon of the quadriceps extensor muscle of the leg. 2. The patella. 3. The ligamentum patellæ, near its insertion. 4, 4. The synovial membrane. 5. The internal lateral ligament. 6. The long external lateral ligament. 7. The anterior superior tibio-fibular ligament.

Fig. 151. A posterior view of the ligaments of the knee joint. 1. The fasciculus of the ligamentum posticum Winslowii, which is derived from 2, the tendon of the semi-membranosus muscle; the latter is cut short. 3. The process of the tendon which spreads out in the fascia of the popliteus muscle. 4. The process which is sent inwards beneath the internal lateral ligament. 5. The posterior part of the internal lateral ligament. 6. The long external lateral ligament. 7. The short external lateral ligament. 8. The tendon of the popliteus muscle cut short. 9. The posterior superior tibio-fibular ligament. —W.]

The *posterior ligament*, (fig. 151,<sup>1</sup>) (ligamentum posticum Winslowii, —Weitbr.) broad and expanded, is a flat plane of fibres, stretched obliquely behind the articulation from the internal tuberosity of the tibia to the external condyle of the femur. The direction of the greater part of its fibres is from below upwards and outwards, running diagonally across the joint, being evidently continuous with the tendon of the semi-membranosus muscle, of which they may be regarded as a prolongation. This ligament, however, cannot be considered as formed solely by a reflection of the tendon of the semi-membranosus, or merely as the third insertion of that muscle; for several transverse and perpendicular fibres are observed in it, distinct from those of the reflected tendon. Some apertures may be observed between its fibres, which transmit the posterior articular vessels.

The *ligamentum patellæ* (fig. 150,<sup>3</sup>) is a flat strong band of tendinous fibres, which connects the patella with the anterior tuberosity of the tibia, and through the medium of it the extensor muscles are inserted to this bone.\* Its superior extremity is attached to the apex of the

\* From this circumstance, together with the fact that it does not connect pieces of the skeleton one to the other, (the patella can be regarded only as a large sesamoid bone and an appendage to muscles,) the so-named ligament is not unfrequently or unfitly regarded as the tendon of a muscle. It seems well, however, that it should, according to usage, be noticed among the ligaments, in consequence of its close connexion with the joint; and, in the words of Weitbrecht, it may be added, "Si quis vero illud cum Walthero pro vero ligamento habere malit, parum refragabor."



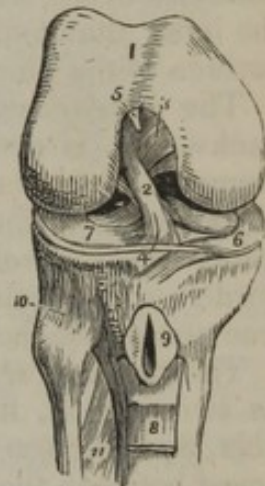patella, and to a depression on its posterior surface; its superficial fibres pass upwards on the anterior aspect of the bone, and become continuous with those of the tendon of the rectus femoris; the inferior extremity is a little expanded; towards the middle its borders are slightly tucked in. The posterior surface of this ligament looks to the synovial membrane of the knee-joint, from which it is separated by some adipose substance, as it is inferiorly from the tibia by a synovial bursa.

*Capsular membrane* (membrana capsularis,—Weitbr.)—Under this name are described portions of fibrous membrane, which cover the synovial membrane in the intervals of the proper ligaments of the joint above described. This structure is very thin, and is connected to the patella, to the femur, tibia, and the interarticular cartilages. Posteriorly it covers the condyles of the femur beneath the heads of the gastrocnemius muscle. In this situation the web is peculiarly slight, and a sesamoid bone will often be found in connexion with it over one, and less frequently over both condyles.

But the joint is much more efficiently supported by other accessory structures (“corroborationes accessoriæ,” as they have been named,) than by the slender membrane now pointed out. These are derived from the fibrous expansion of the vasti muscles and the fascia lata, which blend anteriorly and laterally with the capsular membrane, and are sometimes considered to form part of it: and under the same denomination may be included the heads of the gastrocnemius and the tendon of the popliteus muscle, because of the support they afford to the joint.

The *crucial* or *oblique ligaments* (ligamenta cruciata in poplite,—Weitbr.) are placed at the posterior part of the joint, external to the synovial membrane, but partially invested by it. As the name imports, their direction is oblique, so that they cross or decussate somewhat like the lines of the letter X; the posterior one, however, approaches more nearly a perpendicular direction. One is named anterior, the other posterior. The *anterior ligament* (fig. 152,<sup>2</sup>) is fixed by its lower extremity to a pit, situated before the spine of the tibia, where it is connected with the anterior cornu of the internal semilunar cartilage; its upper extremity is inserted into the inner side of the external condyle of the femur; hence its direction is upwards, backwards, and outwards.

[Fig. 152.]



The right knee joint laid open from the front, in order to show the internal ligaments. 1. The cartilaginous surface of the lower extremity of the femur with its two condyles; the figure 5 rests upon the external; the figure 3 upon the internal condyle. 2. The anterior crucial ligament. 3. The posterior crucial ligament. 4. The transverse ligament. 5. The attachment of the ligamentum mucosum; the rest has been removed. 6. The internal semilunar cartilage. 7. The external semilunar cartilage. 8. A part of the ligamentum patellæ turned down. 9. The bursa, situated between the ligamentum patellæ and the head of the tibia; it has been laid open. 10. The anterior superior tibio-fibular ligament. 11. The upper part of the interosseous membrane; the opening above this membrane is for the passage of the anterior tibial artery. —W.]

The *posterior liga-*



*ment*<sup>3</sup> is attached inferiorly to the pit behind the spine of the tibia (where it is intimately connected with the posterior cornu of the external semilunar cartilage), and superiorly to the side of the inner condyle; its fibres being directed upwards and a little forwards. Its anterior surface is in contact with the last-mentioned ligament, and the posterior with the *ligamentum posticum*. Both are thus implanted into the fossa between the condyles.

The *semilunar cartilages* are two crescent-shaped lamellæ of fibro-cartilage, placed on the articulating surfaces of the head of the tibia, (to which they are firmly fixed,) and interposed between them and the condyles of the femur. The outer border of each is thick and convex, the inner thin and concave, leaving the central part of the superior surface of the tibia uncovered.

The *internal semilunar cartilage*, (fig. 152,<sup>6</sup>) elongated from before backwards, is nearly of a semicircular form; its anterior cornu is connected with the anterior crucial ligament, and is inserted into the pit before the spine of the tibia; the posterior is attached behind the spine, and is in relation with the posterior crucial ligament; its thick border is connected with the internal lateral ligament, the thin one is free and unattached.

The *external semilunar cartilage*<sup>7</sup> forms nearly a complete circle; its two cornua, fixed one before, the other behind the spine of the tibia, are so close at their insertion that they may be said to be interposed between the insertions of the internal semilunar cartilage. Its external border is connected behind with the tendon of the popliteus muscle, and in the middle with the external lateral ligament. The superior surface of the fibro-cartilages is concave, and in apposition with the condyles of the femur; the inferior plane rests on the head of the tibia.

Both surfaces of each semilunar cartilage are invested in nearly their entire extent by the synovial membrane.

*Transverse ligament.*—Towards the front of the joint the convex borders of the interarticular cartilages are connected by a slight transverse band,<sup>4</sup> which receives this name. Its thickness varies much in different bodies.

The *synovial membrane*, like all similar structures, forms a shut sac, whose surface is continuous throughout its entire extent, and, as it lines the contiguous surfaces of all the parts entering into the composition of the knee-joint, it must necessarily present rather a complex arrangement. This complexity is increased by the existence of a small funnel-shaped fold (improperly named *ligamentum mucosum*), which is stretched across the joint, reaching from the anterior part of the joint at some distance below the patella backwards to the margin of the fossa, between the condyles of the femur. In order to exhibit the arrangement of the membrane, the joint should be laid open by a vertical incision carried along the inner margin of the patella and its ligament, leaving the *ligamentum mucosum* untouched. A lateral view of the joint being thus obtained, all the parts remaining in their natural position, it will be observed that the synovial sac is intersected and in a manner divided into two parts by a transverse funnel-shaped process (*ligamentum mucosum*); the superior one, elongated and pyramidal, projects by its summit more than an inch above the patella, its base corresponding with the breadth of the process just named. The inferior division of the membrane is quadrilateral, one side being made up of the lower border of the

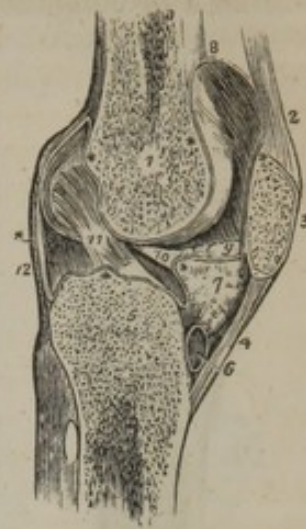


same process, and the smooth surface of the femur with which it is continuous; another, by the articulating surface of the tibia; posteriorly it corresponds with the posterior crucial ligament, and anteriorly with the part of the membrane reflected on the ligamentum patellæ.

If we commence at the superior border of the patella to trace the reflections of the membrane, we find that it descends, lining its articulating surface; below its inferior border it corresponds with the ligamentum patellæ, from which it is separated by a considerable quantity of adipose matter; on reaching the margin of the tibia, it is reflected over its articulating surfaces, and also on both aspects of the semilunar cartilages, giving them a smooth investment; round the crucial ligaments also it forms partial investments, enclosing them as far as their attachments to the femur. The membrane will thus be found to be guided to the articulating surface of that bone at several points, viz., by the two crucial ligaments, by the funnel-shaped process, and by the external margin of the semilunar cartilages; from these points it expands over the condyles, and, after ascending for some way in front of the femur (forming a cul-de-sac between it and the tendon of the extensor muscles), it passes downwards to the margin of the patella, from which we proceeded to trace its reflections. At the sides of the patella the membrane forms two slight folds which are named "alar" ligaments (ligamenta alaria.)

head of the tibia. 7. The mass of fat projecting into the cavity of the joint below the patella. \*\*The synovial membrane. 8. The pouch of synovial membrane which ascends between the tendon of the extensor muscles of the leg, and the front of the lower extremity of the femur. 9. One of the alar ligaments; the other has been removed with the opposite section. 10. The ligamentum mucosum left entire; the section being made to its inner side. 11. The anterior or external crucial ligament. 12. The posterior ligament. The scheme of the synovial membrane, which is here presented to the student, is divested of all unnecessary complications. It may be traced from the sacculus (at 8), along the inner surface of the patella; then over the adipose mass (7), from which it throws off the mucous ligament (10); then over the head of the tibia, forming a sheath to the crucial ligaments; then upwards along the posterior ligament and condyles of the femur to the sacculus, whence its examination commenced.—W.]

[Fig. 153.]



A longitudinal section of the left knee joint, showing the reflection of its synovial membrane. 1. The cancellous structure of the lower part of the femur. 2. The tendon of the extensor muscles of the leg. 3. The patella. 4. The ligamentum patellæ. 5. The cancellous structure of the head of the tibia. 6. A bursa situated between the ligamentum patellæ and the

## PERONEO-TIBIAL ARTICULATION.

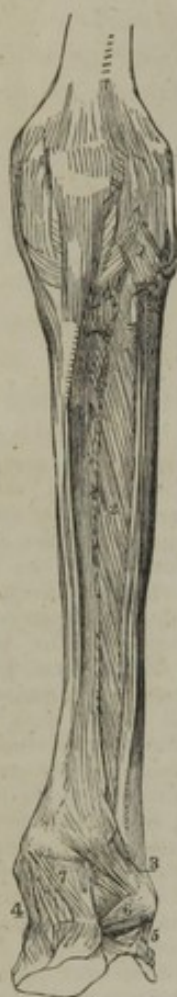The superior and inferior extremities of the tibia and fibula are connected by ligaments and synovial membranes, and the shafts of these bones are moreover maintained in relation by an interosseous membrane.

The contiguous extremities of the bones present superiorly two flat oval surfaces covered with cartilage, which are closely applied to one another, and retained *in situ*, 1, by an *anterior ligament*, (ligamentum superius anticum,) (figs. 152,<sup>10</sup> 154,<sup>1</sup>) which is a broad flat band of fibres, passing obliquely upwards and inwards, from the head of the fibula to the internal tuberosity of the tibia; it is covered and strengthened by the tendon of the biceps flexor cruris; 2, by a *posterior ligament*, (ligamentum superius posticum,) (fig. 151,<sup>9</sup>) similarly disposed behind the articulation, but stronger and thicker; 3, by a *synovial membrane*, which lines the articulating surfaces of the bones and ligaments. It not unfrequently happens that the synovial membrane is continuous



with that of the knee-joint, of which, in such cases, it might be considered a prolongation.

Fig. 154.



A part of the femur, the patella, the bones of the leg, and a range of those of the foot of the left side are viewed in front. Some ligaments of the knee-joint are distinguishable. 1. Superior anterior tibio-fibular ligament. 2. Interosseous membrane. 3. points to the anterior inferior ligament. 4. Deltoid of ankle-joint. 5. Middle division of external lateral; and 6, anterior division of same. 7. Anterior ligament of ankle-joint.

The *interosseous membrane*, (septum longitudinale interossum,) (fig. 154,<sup>2</sup>) which connects the bodies of the tibia and fibula, flat and membranous, is composed of a series of parallel fibres, extending obliquely between the external ridge of the tibia, and the ridge on the inner surface of the fibula. Most of the fibres run outwards and downwards, others cross them; and the membrane they compose is broader above than below, and presents in the former situation an elongated opening for the transmission of the anterior tibial vessels, and inferiorly a small aperture for the passage of the anterior branch of the fibular artery.

The inferior extremities of the tibia and fibula present two articulating surfaces, of which that of the former is concave, and receives the latter, which is convex, both being for a little way covered with cartilage; these are connected by four ligaments and a synovial membrane.

1. The *anterior ligament* (tibio-fibular) (fig. 154,<sup>3</sup>) is a flat band of fibres, extended obliquely between the heads of the bones, the direction of its fibres being downwards from the tibia to the fibula.

2. The *posterior ligament*, (fig. 155,<sup>2</sup>) somewhat triangular, is similarly disposed behind the articulation; its external surface is covered by the peronei muscles.

3. The *transverse ligament*, (fig. 155,<sup>3</sup>) longer but narrower than the former, with which its fibres are closely connected, being placed immediately below it, extends from the external malleolus to the tibia at a short distance from its malleolar process; it forms the posterior boundary of the ankle-joint.

4. The *inferior interosseous ligament* consists of some short dense fibres, which connect the lower ends of the bones, as the great interosseous ligament does their bodies; it cannot be seen until the anterior and posterior ligaments are removed, and the bones in some degree separated.

The *synovial membrane* which covers the articular surfaces of the bones is derived from that of the ankle-joint.

#### THE ANKLE-JOINT.

This articulation consists of the inferior extremities of the tibia and fibula, united so as to form an arch, into which the superior convex surface of the astragalus is received. Their contiguous surfaces are



covered with cartilage, lined by a synovial membrane, and retained in contact by the following ligaments. The *internal lateral ligament* (figs. 154,<sup>4</sup> and 155,<sup>4</sup>) (*ligamentum deltoides*) is a flat fasciculus of fibres much broader at the lower than the upper extremity. One extremity is attached to the inferior border of the internal malleolus, the other to the inner side of the astragalus, the os calcis, and the scaphoid bone. The ligament is covered by the tendons of the *tibialis posticus* and *flexor longus digitorum pedis* muscle.

The *external lateral ligament* consists of three distinct fasciculi of fibres, separated by intervals, and disposed in different directions. 1. The central one (figs. 154,<sup>5</sup>; 155,<sup>6</sup>) (*ligamentum fibulæ medium*) descends from the extremity of the fibula, and is inserted into the middle of the external surface of the os calcis. It is crossed by the tendons of the *peroneus longus* and *brevis* muscles. 2. The anterior fasciculus (fig. 154<sup>6</sup>) (*ligamentum fibulæ anterius*) passes obliquely forwards from the inferior extremity of the fibula, to the anterior border of the articular surface of the astragalus; it is the shortest of the three. 3. The posterior, (fig. 155,<sup>5</sup>) (*ligamentum fibulæ posterius*), the strongest of the three ligaments, passes obliquely backwards from the extremity of the fibula towards the posterior surface of the astragalus, where it is inserted into the border of the groove for the tendon of the *flexor longus pollicis*.

*Anterior tibio-tarsal ligament.*—At the anterior aspect of the joint is a broad thin membranous band, (fig. 154,<sup>7</sup>) composed of irregular fibres, extended obliquely from the border of the articulating surface of the tibia to the margin of the pulley-like surface of the astragalus. This ligament is covered by the tendons of the extensor muscles.

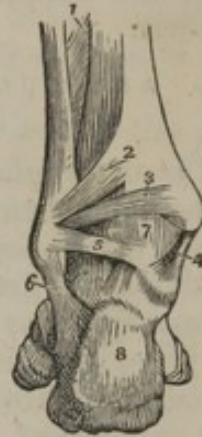The *synovial membrane*, after having invested the articulating surface of the astragalus, is reflected upwards at each side upon the lateral ligaments, and, at the anterior and posterior part of the joint, upon the corresponding fibrous structures, so as to reach the articulating surfaces of the tibia and fibula by several points at once. These it lines in their entire extent, and also sends upwards between them a process which reaches as far as the inferior interosseous ligament; so that the inferior articulation between these bones may be said to form part of the ankle-joint, as both are lined by the same synovial membrane.

#### ARTICULATIONS OF THE FOOT.

The foot being divided into the tarsus, metatarsus, and phalanges, its different parts are respectively bound together by ligaments, and all are united so as to form a whole.

The seven bones of which the tarsus consists may be divided into

[Fig. 155.



A posterior view of the ankle-joint. 1. The lower part of the interosseous membrane. 2. The posterior inferior ligament connecting the tibia and fibula. 3. The transverse ligament. 4. The internal lateral ligament. 5. The posterior fasciculus of the internal lateral ligament. 6. The middle fasciculus of the external lateral ligament. 7. The synovial membrane of the ankle-joint. 8. The os calcis.—W.]



two sets: the os calcis and astragalus forming the first; the scaphoid, cuboid, and three cuneiform bones, the second. And their complicated articulations will be arranged in three divisions.—*a.* In the first will be placed the articulations of the bones of the first row or set one with the other.—*b.* The second division will contain the connexion of the first set with the bones of the second.—*c.* And the last will comprise the connexions of those (the second set of bones) one with another.

A. ARTICULATION OF THE FIRST RANGE OF TARSAL BONES ONE WITH THE OTHER.

*The astragalus with the calcaneum.*—The astragalus is connected to the calcaneum by three ligaments, the chief of which is situated between the bones, and unites them somewhat after the manner that bivalve shells are connected by their muscle. This is termed the *interosseous ligament*; its breadth from side to side is more than an inch; the fibres of which it is composed pass perpendicularly between the bones, one extremity being fixed to the groove between the articulating surfaces of the calcaneum, the other to a corresponding depression in the astragalus. The *posterior ligament* connects the posterior border of the astragalus with the upper surface of the calcaneum; its fibres are oblique, its length and breadth not more than three or four lines. The *external ligament* is a slight fasciculus which descends perpendicularly from the under surface of the astragalus to the external side of the calcaneum; its direction is parallel with the middle division of the external lateral ligament of the ankle-joint. It may be farther observed, that as the astragalus is wedged in between the malleoli, and as the lateral ligaments pass downwards from these to the os calcis, they must contribute somewhat to retain the astragalus in its proper position with regard to the latter bone.

*Synovial membrane.*—There are two sets of articular surfaces by which the astragalus and calcaneum are in contact. The posterior one has a separate synovial sac; while the membrane which lines the anterior articulation is continued forwards between the astragalus and the scaphoid bone.

B. ARTICULATION OF THE FIRST SET OF TARSAL BONES WITH THE SECOND.

This heading includes—1. The articulation of the os calcis with the cuboid. 2. The os calcis with the scaphoid. 3. The astragalus with the scaphoid.

*The calcaneum with the cuboid bone.*—The connexion between these bones is maintained by three ligaments and a synovial membrane. The *superior calcaneo-cuboid ligament* is a broad flat band of fibres, which connects the anterior and superior surface of the calcaneum with the adjacent part of the cuboid bone. The *inferior ligament* consists of two distinct fasciculi of fibres, differing in form and attachments; of which one is superficial, the other deep-seated. The superficial one, called the *long plantar ligament* (fig. 156,<sup>4</sup>) (ligamentum longum plantæ) is the longest of the tarsal ligaments. Its fibres, attached posteriorly to the inferior surface of the calcaneum, pass hori-

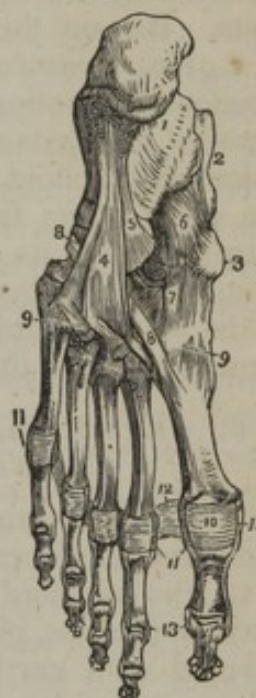

zonally forwards, and become intimately connected with the rough tuberosity on the under surface of the cuboid bone; the greater number of them are continued forwards, and terminate at the base of the third and fourth metatarsal bones, after covering the tendon of the peroneus longus muscle. The *deep-seated plantar calcaneo-cuboid ligament*<sup>5</sup> lies close to the bones, being separated from the former by some cellular tissue; its breadth is considerable, its length scarcely an inch, one extremity being attached to the calcaneum before the long ligament, the other (somewhat expanded) to the under surface of the cuboid bone.

*Internal or interosseous calcaneo-cuboid ligament.*—Besides the preceding ligaments there is another series of fibres placed deeply between the bones in the sinus or pit between the astragalus and os calcis (its anterior part). These extend from the os calcis to the inner side of the cuboid; and with these are others which are directed from the same part of the os calcis inwards to the scaphoid bone. Both may be considered as interosseous ligaments.—A *synovial membrane* lines the contiguous surfaces of the two bones, and is necessarily reflected upon the articular aspects of the ligaments.

*The calcaneum with the scaphoid bone.*—This is effected by means of two ligaments, their surfaces not being in contact. Of these ligaments, the inferior, or plantar one, (fig. 156,<sup>a</sup>) (*ligamentum calcaneo-scaphoideum inferius*, — Meckel,) much the larger, passes forwards and inwards from the extremity of the calcaneum to the inferior surface of the scaphoid bone; its fibres are flat and horizontal, and in contact inferiorly with the tendon of the tibialis posticus muscle; superiorly they form part of the fossa which receives the head of the astragalus, and are lined by the synovial membrane, which is continued forward from the anterior articulation of the astragalus and os calcis. The *external, dorsal, or interosseous ligament* (lig. calcaneo-scaphoideum externum) forms the external boundary of the cavity just mentioned; its fibres, very short, are directed from behind forwards between the contiguous extremities of the bones. As it lies deeply at the anterior part of the fossa between the astragalus and os calcis (sinus pedis), and is actually between the bones, the ligament may be regarded as interosseous. In connexion with it is another bundle of fibres already described as reaching from the os calcis to the inner part of the cuboid.

[Fig. 156.]



The ligaments of the sole of the foot. 1. The os calcis. 2. The astragalus. 3. The tuberosity of the scaphoid bone. 4. The long plantar ligament. 5. Part of the deep-seated calcaneo-cuboid ligament. 6. The calcaneo-scaphoid ligament. 7. The plantar tarsal ligaments. 8, 8. The tendon of the peroneus longus muscle. 9, 9. Plantar tarso-metatarsal ligaments. 10. Plantar ligament of the metatarsophalangeal articulation of the great toe; the same ligament is seen upon the other toes. 11. Lateral ligaments of the metatarsophalangeal articulation. 12. Transverse ligament. 13. The lateral ligaments of the phalanges of the great toe; the same ligaments are seen upon the other toes.—W.]



*The astragalus with the scaphoid bone.*—The astragalus forms with the scaphoid bone a ball-and-socket joint. The anterior articulating surface of the calcaneum, and the inferior calcaneo-scaphoid ligament, also may be said to enter into this articulation, as all the parts here mentioned are lined by a common synovial membrane. On the dorsum of the foot the astragalus is retained in its situation by the *ligamentum astragalo-scaphoideum*, a broad band of fibres extending obliquely forwards from the anterior extremity of the astragalus to the superior surface of the scaphoid bone. It is covered by the extensor tendons. The place of an inferior ligament to connect these bones is occupied by the calcaneo-scaphoid ligament, on which the astragalus rests; and this bone wants the security against displacement which would be afforded by the connexion of its inferior surface with the scaphoid bone. But on this arrangement of the bones and ligaments depends in a great measure the elasticity of the arch of the foot, as well as the freedom of motion which belongs to this part of the tarsus.—The *synovial membrane* lines the concave surface of the scaphoid bone, the calcaneo-scaphoid ligament, and the elongated articulating surface of the calcaneum; from these it is reflected to the under surface of the astragalus and its scaphoid ligament, and so to the bone of that name from which we began to trace it. In other words, the synovial membrane of this joint is continued from the anterior of the two joints formed between the os calcis and astragalus.

C. ARTICULATIONS OF THE SECOND SET OR RANGE OF  
TARSAL BONES ONE WITH ANOTHER.

The second range of the tarsal bones, viz., the scaphoid, cuboid, and three cuneiform, are connected together in the following manner.

1. The *scaphoid* and *cuboid* bones, when in contact, which is not always the case, present two small articulating surfaces, at their edges covered with cartilage, and lined by a synovial membrane. They are connected by a *dorsal ligament*, composed of short thin fibres, extended obliquely between the two bones; a *plantar*, situated in the sole of the foot, and composed of transverse fibres; and an *interosseous* ligament, which intervenes between the bones, and is attached to their contiguous surfaces.

2. The *cuboid* and the *external cuneiform bones* are connected by a *dorsal* ligament, which is a thin fasciculus of fibres extended between them; a *plantar ligament*, whose fibres are transverse, and rather indistinct; and a series of *interosseous* fibres connected to their neighbouring sides. Between these two bones a distinct articulation is formed by cartilaginous surfaces, lined by a process of the same synovial membrane which belongs to the scaphoid and cuneiform bones.

3. The *scaphoid* and the *cuneiform bones* are held together by dorsal and plantar ligaments. It will be recollected that the scaphoid bone articulates with the three cuneiform, by the smooth faces on its anterior surface. The *dorsal* ligaments, three in number, pass from the superior surface of the scaphoid to the first, second, and third cuneiform bones, into which they are inserted. The *plantar ligaments*, which



are similarly disposed on the under surface of the bones, but not so strongly marked, are continuous with, or offsets from, the tendon of the *tibialis posticus*.

4. The three *cuneiform* bones are connected by transverse *dorsal ligaments* and strong *interosseous* fibres, which (latter) are their most efficient means of union. Plantar ligaments can scarcely be said to exist for the connexion of these bones; the internal one is broader and stronger than the other. The contiguous smooth surfaces of the bones are lined by synovial membrane continued forward from the articulations last described.

#### ARTICULATION OF THE TARSUS WITH THE METATARSUS.

The four anterior bones of the tarsus, viz., the three cuneiform and the cuboid, articulate with the metatarsus. The first and third cuneiform bones project beyond the others, so that the anterior extremity of the tarsus is very irregular. The first metatarsal bone articulates with the internal cuneiform; the second is wedged in between the first and third cuneiform, and rests against the middle one; the third metatarsal bone articulates with the extremity of the corresponding cuneiform, and the two last with the cuboid bone. The articular surfaces of the bones are lined by synovial membranes, and they are held in contact by dorsal and plantar and interosseous ligaments.

The *dorsal* ligaments are flat, thin bands of parallel fibres, which pass from behind forwards, connecting the contiguous extremities of the bones just mentioned. Thus the first metatarsal bone receives a broad thin band from the corresponding cuneiform bone; the second receives three, which converge to its upper surface, one passing from each cuneiform bone; the third has one from the third bone of that name; and, finally, the two last are bound by broad fasciculi to the cuboid bone. The *plantar* set is disposed with less regularity; the first and second are more strongly marked than the corresponding ligaments on the dorsal surface; and the fourth and fifth metatarsal bones, which are connected by but a few scanty fibres to the cuboid, receive support from the sheath of the *peroneus longus* muscle. Ligamentous bands stretch in an oblique or transverse direction from the internal cuneiform to the second and third metatarsal bones, and from the external cuneiform to the fifth metatarsal.

The *interosseous* ligaments have especial interest, because of the difficulty they would occasion in separating the metatarsus from the tarsus (should this operation be considered a desirable one) in consequence of their deep position between the bones.\* *a.* The *internal* and largest of these lies to the outer side of the first cuneiform bone, and extends from this bone to the neighbouring side of the second metatarsal, as well as to the first metatarsal. *b.* The *external* interosseous ligament separates the articulation of the fourth and fifth metatarsal bones from the rest. It connects the outer side of the external

\* Attention was first particularly directed to these ligaments by M. Lisfranc, in connexion with the amputation of the foot through the tarso-metatarsal articulation. See "Manuel des Opérations Chirurgicales, &c. Par J. Coster." 3e edit. Paris, 1829.



cuneiform bone to the same side of the third metatarsal. *c.* Some fibres, of less strength and importance than the preceding, are observable in another situation, namely, on the outer side of the second metatarsal bone, connecting it to the middle cuneiform. These fibres, from their position, constitute a *middle* interosseous ligament.—The connexions of the interosseous ligaments may be found to vary somewhat from those here stated. They may be connected at the same time to the contiguous angles of two tarsal and two metatarsal bones.

*Synovial membranes.*—There are three synovial membranes in this irregular series of articulations. *a.* One belongs to the internal cuneiform and the first metatarsal bone. The joint formed between these two bones is altogether distinct and out of the range of the rest. *b.* Another synovial membrane is reflected from the cuboid to the fourth and fifth metatarsal bones; and this is isolated on the inner side by the external interosseous ligament. *c.* The third or middle one is an elongation of the synovial membrane lining the articulations of the scaphoid and cuneiform bones, which is continued to the articulations formed between the two external of the last-named bones, and the second and third metatarsal.

#### CONNEXION OF THE METATARSAL BONES WITH ONE ANOTHER.

The metatarsal bones are bound together at their tarsal and digital ends; very firmly in the former, and, on the other hand, loosely in the latter situation.

The tarsal ends or bases of the four outer bones articulate one with another, having lateral articular surfaces which are covered by synovial membrane, and they are connected by dorsal, plantar, and interosseous ligaments. The *dorsal* and *plantar* (fig. 156,<sup>9</sup>) ligaments are short transverse bands stretching from one bone to another, and placed in the manner which their names sufficiently indicate. The *interosseous* fibres, lying deeply between the bones, occupy the non-articular parts of their lateral surfaces. They are very resistant. The articular surfaces are covered by *synovial membrane*, which in each is continued forward between these bones from that lining the joints formed by their terminal surface and the tarsal bones. The first metatarsal does not articulate with the second.

*Transverse metatarsal ligament.*—The digital extremities or heads of the metatarsal bones are loosely connected by a transverse band (fig. 156,<sup>12</sup>) which is identical in its arrangement with the corresponding structure in the hand; but with this exception, namely, that it extends to the great toe, whereas the other does not reach the thumb.

#### ARTICULATIONS OF THE METATARSAL BONES WITH THE DIGITAL PHALANGES, AND OF THE LATTER ONE WITH ANOTHER.

The heads of the metatarsal bones are connected with the small concave articular surfaces of the first phalanges by two lateral liga-



ments, an inferior ligament, and a synovial membrane, similar in every respect to those which belong to the corresponding parts of the hand (*ante*, page 273).

The articulations of the phalanges with one another are also constructed on the same principle as those of the superior extremity (page 273). In each, the bones are held in contact by two lateral ligaments (fig. 156,<sup>13</sup>) and an anterior ligament, the surfaces being lined by a synovial membrane.



# APONEUROLOGY.

## F A S C I Æ.

THE fasciæ, composed ultimately of layers of shining fibres arranged in a more or less reticular form and connected by dense cellular tissue, constitute a series of comparatively inelastic and unyielding fibrous membranes, which invest and support the various soft parts composing the trunk and the limbs.

Connected through the medium of the periosteum with certain parts of the skeleton, the fasciæ serve not only to encase individually, but to bind down collectively, and keep in place, the muscles and their tendons. They vary much from the ordinary thickness in certain situations, being thin and indistinct in some parts, while they become stronger and more defined in others, especially where, from some cause, as the sudden change in the direction of a tendon, there is more than usual danger of displacement of parts during muscular action.

Where flat muscles enclose certain large viscera (as on the abdomen), fasciæ form similar continuous expansions on their inner surface, and these also vary in their strength in different parts, as it were with the necessity for their existence.

By Bichat, fasciæ have been named *aponeuroses of investment*, to distinguish them from proper tendinous expansions or *aponeuroses of insertion* (of muscles), of which the tendons of the occipito-frontalis and of the external abdominal muscles may be taken as examples. Practically, however, this distinction is not so absolute as it may, for systematic description, be convenient to assume, inasmuch as in both classes some aponeuroses are found to serve the double purpose of investment and insertion. Thus fasciæ are often observed, on the one hand, to give origin to muscular fibres, as illustrated in the gluteus medius and the muscles of the fore-arm; and on the other hand, to afford insertion to tendons, or to offsets from tendons, passing in their immediate neighbourhood. Examples of the insertion of tendinous fibres to fasciæ are afforded by the gluteus maximus and the biceps brachialis. The connexion between fasciæ and muscles is met with on the surface of the limbs, and more particularly over parts which undergo much change in figure during muscular action; and the effect of the arrangement would therefore appear to be,—in addition to its use in enlarging the extent of origin for muscular fibres, and in economising the osseous surface for the insertion of muscles,—to insure a proper degree of tension in membranes which are not well fitted by their physical properties alone to accommodate themselves completely and accurately to such changes. Hence, also, in certain situations



distinct muscles are provided for this especial purpose, as, for example, the tensor of the fascia of the thigh (tensor vaginæ femoris), and that of the palmar fascia (palmaris longus).

The connexion between investing fasciæ and the periosteum is of much importance, and it is so intimate as to have induced Bichat to consider the periosteum as the centre of the aponeurotic system generally.\*

Wherever a margin or surface of bone is unoccupied or uncovered by muscle or tendon (*i. e.* where it is subcutaneous, as the spine of the tibia, or where it forms part of a large visceral cavity, as the brim of the pelvis), the investing fascia is immediately connected with the periosteum, thus constituting a sort of septum, which would prevent the handle of a scalpel, for example, from being pushed freely under every part of what appears a continuous membrane.

Where the bone lies at a considerable distance from the surface, the fasciæ are still freely connected with the periosteum through the medium of deep prolongations which pass between the muscles. Some of these, usually stronger than the rest, dip directly between separate groups of muscles, and are named *intermuscular septa*, as the intermuscular partitions of the thigh, which separating respectively the extensor, the adductor, and the flexor muscles of the leg, connect the fascia lata with the periosteum of the femur.

In other situations, where the organs of various kinds are assembled together, and where the muscles are less clearly divided into parallel groups, as in the neck, these deeper processes of fascia have a much more complicated course and mode of insertion, often appearing to split and encase muscles, and occasionally strengthening the sheaths of important vessels. The complication is, in fact, a consequence of the complication of the parts held together by the fascia. In parts which are frequently the seat of surgical operation (as the groin, in consequence of the occurrence of herniæ), some of these secondary processes of fascia have much interest for the practical surgeon, and they are therefore deemed worthy of a careful description; but in other cases it is unnecessary to enter on any detailed description of them.

#### SUPERFICIAL FASCIA.

Under this name has been described another series of membranes, differing in strength, texture, appearance, connexions, and uses from those just alluded to, and allied to them only in the fact of their forming a general membranous investment to the body and limbs.

Immediately beneath the skin, and between it and the true fascia, is found in most parts of the body an imperfectly membranous structure, composed of fibrous and cellulo-fibrous tissue, containing within its meshes a varying quantity of fat, and between its laminæ the superficial vessels and nerves as they course obliquely from under the deep or true fascia to enter the integument.

The superficial fascia may be traced as a continuous membrane

\* "Anatomie Générale," nouvelle édit. par Béclard et Blandin; Paris, 1830; t. 3, p. 209.



over nearly the whole body ; but, whilst in some parts, as in the groin, it is so thick as to be capable of subdivision into several layers by the knife, in others, as the palms of the hands, it is so closely united with the skin on one aspect, and with the true fascia on the other, that it cannot be demonstrated, and can only theoretically be said to exist.

The principal function of the superficial fascia appears to be that of permitting with safety a certain amount of motion between the elastic skin and the less yielding fascia beneath it, whilst it also unites those structures one to the other.

In accordance with this view, it will generally be found that the structure in question is most distinct wherever the skin is loose and movable over the subjacent soft parts, as over the groin, the scrotum, and the anterior part of the perineum ; and that, where bursæ are superadded to facilitate this movement still further, it is in the superficial fascia that they are developed. Where muscular fibres are directly inserted into, and act upon, the skin, the superficial fascia can be hardly said to exist. For example, over the platysma myoides in the neck, the superficial sphincter of the anus, and the orbicularis palpebrarum and other muscles of the face, the muscular fibre so closely adheres to the under surface of the skin, that there is no substance intervening of sufficient importance to require description as an independent structure.

The superficial fascia is irregularly adherent on both its surfaces ; but the only connexions that it will be desirable further to particularise are those which, in certain situations, it contracts with the true investing fasciæ.

Having thus pointed out the distinction between superficial and true fasciæ, it will be more convenient to examine them together as they exist in different parts of the body, than to treat of them under separate and independent heads.

#### FASCIÆ OF THE HEAD AND NECK.

The *superficial fascia* is but imperfectly developed on the head and neck. Over the upper and fore part of the cranium it cannot be demonstrated, owing to the close adherence of the skin to the frontal part of the occipito-frontalis and to the epicranial aponeurosis. Over the occipital division of this muscle, however, the superficial fascia is to be recognised, and it is continuous with that covering the back of the neck ; and on either side of the epicranial aponeurosis it is again recognised, descending over the temporal fascia, and containing between its laminæ the attrahens and attollens aurem, with the superficial temporal vessels and nerves. (See p. 333.)

In the face the muscular fibres are so frequently inserted into the skin, that there is no intervening cellular tissue worthy the name of a continuous membrane ; and the same remark applies to the side of the neck, where the representative of the superficial fascia is found in the cellular tissue under the platysma myoides muscle, in which the external jugular vein and some superficial branches of nerves are contained.

*Deep fasciæ.*—The chief fasciæ of the head and neck, therefore, belong to the proper investing class ; and owing to the arrangement of



muscles in the neck, and the presence in the same part of several important parts in a small space (*e. g.* vessels, nerves, glands, the windpipe, &c.), the subdivisions and attachments of these membranes are proportionably complicated.

The *temporal fascia* will be further described (p. 344), in connexion with the muscle of the same name, to which it affords an extensive origin. Single above, where it is fixed to the curved margin of the temporal fossa, it divides below into two layers, one of which is attached to the outer, and the other to the inner surface of the zygoma; and in this situation there is deposited between its layers a quantity of fat, the absorption of which gives the hollowness to the temples of those who have suffered from illness of long standing. This dense fascia is separated from the skin by the layer of thin membrane descending from the epicranial aponeurosis, and by small muscles of the pinna of the ear.

*Parotid fascia.*—The fascia covering the parotid gland might not inaptly be considered a portion of, or an elongation from the cervical fascia. From the lower margin of the zygoma a strong layer of fascia descends over the parotid gland. Below, it is continuous with the deep fascia of the neck; behind, it attaches itself firmly to the cartilaginous portion of the external meatus of the ear (particularly on its lower aspect), and afterwards continues over the mastoid process and upper portion of the sterno-mastoid muscle; in front, the membrane gradually dwindles over the masseter muscle, where it has sometimes been named the *masseteric fascia*.

On the inner or deeper surface of the parotid a similar, though weaker membrane, exists; and along its anterior margin the two, uniting together, complete the proper investment of the gland, with the vessels and nerves passing through it, and likewise encase the *socii parotidis* and Stenson's duct.

The *cervical fascia* (named also proper or deep cervical), when fully laid bare, by removing the platysma myoides, and turning back the trapezius muscle beneath which it lies, is seen to form one continuous sheath to the neck. Commencing with the thinnest and weakest part at the back of the neck, it is attached to the spinous processes of the cervical vertebræ and to the ligamentum nuchæ, whence it extends over the splenius and levator anguli scapulæ to the sterno-mastoid muscle. Here the fascia separates into two layers, one of which covering the cutaneous surface of the muscle last named appears on a superficial dissection, whilst the other passing on its deeper aspect has additional connexions, hereafter to be examined. After thus encasing the sterno-mastoid, these layers reunite along the anterior margin of the muscle, and the single membrane thus formed stretches to the middle line in front, where it is continuous with the part of the fascia covering the opposite side of the neck. The connexions of the continuous sheath thus given to the entire neck will first be followed out, and then the deeper processes sent between the muscles will be proceeded with.

When traced upwards, the layer of fascia on the cutaneous surface of the sterno-mastoid is found in front of the ear continuous with the



fascia covering the parotid gland and the masseter muscle, and, still further forward, is attached to the base of the lower jaw. Followed downwards, it is seen extending from the tendon of the sterno-mastoid over the clavicle, losing itself gradually in the thinner covering of the pectoral muscle; and this portion is pierced, above the clavicle, by the external jugular vein hitherto superficial to the membrane. In front, the fascia is comparatively thin above, where it is fixed to the hyoid bone; but, becoming stronger as it descends, it splits, a little below the level of the thyroid gland, into two distinct layers. Of these the more superficial and weaker, guided by the sterno-mastoid muscles, expands in front of the sternum; whilst the stronger layer, lying under the former, and closely covering the sterno-hyoid and sterno-thyroid muscles, is attached to the deeper surface of that bone. These layers materially assist in closing the cavity of the chest, above the sternum; and between them there exists a quantity of cellular tissue and fat, with sometimes a small lymphatic gland.

The processes of cervical fascia which dip between the muscles of the neck, and remain to be followed, may be said to be continued from the deeper of the two layers already alluded to as enclosing the sterno-mastoid muscle. A process of the fascia of considerable density, extending *upwards* behind and to the inner side of the parotid gland, is fixed to the styloid process and angle of the lower maxilla, and is known under the name of the *stylo-maxillary ligament*. (See p. 260.) When the head is thrown back, and still more if it is at the same time inclined to the opposite side, this band may be felt cord-like beneath the angle of the maxilla. *Downwards*, and a little outwards, another strong portion of the fascia encloses the omo-hyoid; and this embracing the tendon between the two muscular bellies, binds it down and maintains the angular direction of the muscle. This portion of the fascia descends to be partially inserted into the clavicle; but, at the same time, it sends a covering round the *subclavius muscle*, which is continuous (over the subclavian and axillary vessels) with the costo-coracoid membrane which is situate below the clavicle.

Another and somewhat irregular process of the fascia assists in forming the *common sheath of the large cervical blood-vessels* (the carotid artery and jugular vein, with the pneumogastric nerve), a thin fibro-cellular septum intervening between the two vessels and thus completing a separate sheath for each.

Lastly, a thin membranous partition is continued *inwards* across the trachea and thyroid body (to which latter it sends an investment), and immediately behind the sterno-thyroid muscles. This layer has been traced, over the large vessels at the root of the neck, to the fibrous layer of the pericardium.\*

\* Godman, having traced the cervical fascia into the pericardium, strongly insisted on considering the fibrous investment of the heart as *formed from* the fascia; but from this mode of expression, which is often met with in anatomical language, no more should be understood than the mere fact of continuity, for, on the same grounds, the pericardium might as well be said to form the cervical fascia. I have succeeded in tracing the fascia over the vessels into the fibrous layer of the pericardium; but in some instances I have failed to trace the continuity of the two structures, in consequence of the fascia degenerating (as it often does in other places) into mere cellular membrane at some distance from



Interposed between the pharynx and the muscles immediately applied to the fore part of the vertebral column is another layer of the general fascia of the neck known as the *prevertebral fascia*. Attached to the basilar process of the occipital bone, and on each side to the transverse processes of the vertebræ (the anterior tubercles of these processes), this layer immediately covers the rectus capitis anticus and lateralis, and the longus colli muscles, and it is likewise expanded over the scaleni muscles and the cervical nerves.

## FASCIÆ OF THE THORAX.

The *superficial fascia* covering the thorax, continuous with that of the neck and of the upper limb above, and with that of the abdomen below, is loose and distinct over the greater part of the surface of the chest. In the neighbourhood of the mamma this membrane divides into two layers, which enclose the gland, one lying before, the other behind it. From both these layers offsets are continued into the glandular substance, separating it into parts and supporting them. The posterior layer is likewise connected with the immediate investment of the pectoral muscle by bands of a similar kind; and processes containing between them masses of fat are extended from the anterior lamina forward to the skin and to the nipple. From the support they afford to the mammary gland, and the connexion they establish between it and the skin and nipple, the last-mentioned processes were named by Sir A. Cooper the "*ligamenta suspensoria*"\* of the organ they serve to support. The superficial fascia covering the thorax is thinner and denser, and contains less fat near the middle line in front, where its surfaces are closely adherent to the skin and to the deeper fascia.

The *deeper fascia* of the thorax, firmly adherent to the surface of the sternum and to the clavicle, under the platysma myoides, is thin and weak over the upper part of the pectoral muscle, to which it is adherent through the medium of cellular elongations extended between the fasciculi of muscular fibres. It becomes somewhat stronger in the interval between the margins of the pectoralis major and latissimus dorsi muscles, where it closes in the axillary space; and is most developed near the epigastric region, where it is intimately connected with the dense aponeurotic fibres covering the upper part of the recti muscles. At the margin of the latissimus dorsi the fascia appears to split, one layer continuing on the cutaneous, the other on the deep aspect of that muscle; and both layers become attached to the spines of the dorsal vertebræ.

By reflecting the great pectoral muscle a deep layer of fascia is brought into view, which is strongest at the upper and outer part, where it is stretched between bones, but becomes weaker, and degenerates into mere cellular membrane in front of and behind the smaller pectoral muscle. The upper and stronger portion of this deep layer of fascia is named the *costo-coracoid ligament* or membrane. The

the upper end of the pericardium. See "*Anatomical Investigations*, by John Godman, M.D." Philadelphia, 1824.

\* "*On the Anatomy of the Breast*." London, 1840.



fibres of which this structure is composed are aggregated together on the outer side, and are here inserted into the end of the coracoid process of the scapula, from which point they diverge upwards and inwards, becoming proportionally weaker, and are attached above along the under margin of the clavicle and to the inner extremity of the first rib. The band thus formed stretches across and protects the axillary vessels and nerves, and offers considerable resistance to the finger when pressed between the coracoid process of the scapula and the clavicle. It does not present any defined margin, in consequence of its continuity with the thinner membrane already noticed as descending to the pectoralis minor. Lastly, a thinner layer, passing behind the subclavius, completes the investment for that muscle, and is continuous with a layer we have already traced as descending towards this point from the deep cervical fascia where it is connected with the omo-hyoid muscle (page 296).

*Intercostal fasciæ.*—On the cutaneous surface of the external intercostal, and on the internal aspect of the internal intercostal muscle, exist distinct and firm though thin layers of fascia; and there is also a delicate cellular prolongation between the two sets of muscles. These layers of fascia become much stronger at the points at which the corresponding muscles are deficient; namely, between the external intercostal muscle and the sternum in front, and between the internal intercostals and the vertebral column behind.

The *vertebral aponeurosis*, which might be enumerated amongst the fasciæ of the thorax, will be described hereafter, in connexion with the muscles it separates.

#### FASCIÆ OF THE UPPER LIMB.

The *superficial fascia* of the arm requires but little notice. It is most distinct opposite the bend of the elbow, where the superficial veins, contained within its laminæ, are numerous and large. In the palm of the hand, on the contrary, it is so adherent to the skin and true palmar fascia, (or rather these two structures are here so connected by dense fibro-cellular bands,) that it is impossible to demonstrate the existence of superficial fascia as a separate layer. Subcutaneous bursæ are usually found in this fascia over the acromion, the olecranon, and the knuckles.

The *deep fascia* over the greater part of the *deltoid* is coarse and cellular, adhering closely to the surface of the muscle, and continuous with the septa which dip between its fasciculi. Over that portion of the muscle which arises from the posterior end of the spine of the scapula, however, the fascia becomes more dense, and descends to join with that investing the infra-spinatus, and to strengthen the fascia over the back of the arm.

The *fascia of the arm*, composed chiefly of transverse fibres held together by others having an oblique or longitudinal course, differs much in density at different parts. Thus it is thin and cellular over the biceps muscle, stronger where it covers the triceps, and particularly dense as it approaches the outer and inner condyles of the hu-



merus. It is strengthened above, and during muscular action is kept tense, by tendinous fibres prolonged from the pectoralis major and latissimus dorsi on the inner side, and from the deltoid on the outer side. The fascia of the arm may be considered as a continuation downwards of the fascia already described as covering these several muscles.

This fascia is connected to the shaft and condyles of the humerus by two processes, which extend directly to the bone, and, separating the muscles on the posterior from those on the anterior aspect of the limb, are named *intermuscular septa*. Of these the *external*, which is not well marked, reaches from the insertion of the deltoid, along the outer ridge on the shaft of the humerus to the external condyle. It receives tendinous fibres from the deltoid, and gives partial origin to the muscles between which it is interposed, namely, the triceps behind, and the supinator longus and extensor carpi radialis longior in front. It is pierced from behind forwards by the musculo-spiral nerve and the superior profunda artery. The *internal septum*, much thicker and stronger than the other, begins near the insertion of the coraco-brachialis, from which it receives fibres; it extends between the triceps and brachialis anticus, affording points of attachment to some of the fibres of these muscles. It is traversed from before backwards by the ulnar nerve and the lower profunda and anastomotic arteries. Besides these septa, the fascia of the arm sends thinner offsets to separate the different muscles (as the biceps from the brachialis anticus) from each other, and to assist in forming the sheath to the brachial vessels and median nerve.

The *fascia of the fore-arm*, continuous above with that descending from the upper arm, is closely connected at the bend of the elbow with the periosteum covering the superficial portions of the condyles of the humerus and the olecranon process of the ulna; and it is strengthened by tendinous fibres sent from the triceps and biceps muscles. Below the elbow this fascia is composed principally of circular fibres attached to the olecranon and the inner margin of the ulna, crossed however by longitudinal and oblique fibres, which descend from the points of bone and tendons of muscles just indicated. Of these accessory fibres, the band sent from the biceps tendon is worthy of particular notice. It expands over the muscles arising from the inner condyle of the humerus; and it forms a firm though thin septum between the median basilic vein, which lies before it, and the brachial artery, with its accompanying veins and median nerves, situated behind it. The fascia thus strengthened by the expansion from the biceps muscle is intimately connected with the muscles below the inner condyle of the humerus, giving origin to many of their fibres; and it is also united to the fibrous bands (*intermuscular septa*) placed between those muscles, so that the muscles lie in several cells or sheaths of fibrous structure.

The attachment of the fascia of the fore-arm to the subcutaneous margin of the ulna conveniently divides it into an anterior and a posterior portion.

The *anterior* division of the fascia of the fore-arm, continuing from that at the bend of the elbow, is much weaker than the membrane on



the posterior aspect of the limb. In the hollow just below the bend of the elbow, this fascia presents a small oval aperture for the transmission of a short communicating branch between the superficial and the deep veins of the fore-arm. It increases in density towards the hand; and a little above the wrist affords a sheath to the tendon of the long palmar muscle, which passes over the annular ligament to be inserted into the narrow end of the palmar fascia. Several white lines seen on the surface of the fascia mark the *intermuscular septa* which are continuous with it. Between the superficial and the deep layer of flexor muscles, another layer of fascia is stretched from side to side; it is stronger below than above, where it is generally little more than cellular membrane.

The *anterior annular ligament* of the carpus, composed of close white fibres, extends transversely from the scaphoid and trapezium on the outer side, to the unciform and pisiform bones on the inner side, bridging over a space through which, sheathed by synovial membrane, run the tendons of the long flexor muscles with the median nerve. The upper margin of this structure is continuous with the fascia of the fore-arm, and receives some fibres from the tendon of the flexor carpi ulnaris. The anterior surface is crossed by the tendon of the palmaris longus, the ulnar artery and nerve, and a cutaneous branch of the median nerve; the lower margin is connected with the palmar fascia, and gives partial origin to most of the short muscles of the thumb and of the little finger. The anterior annular ligament should be considered as a highly developed portion of the fascia of the wrist, and not as a true ligament. It is thicker and apparently more independent than the posterior annular ligament, merely because the flexors of the fingers are larger and more powerful than the extensors.

The *posterior division* of the fascia of the fore-arm, by far the thicker of the two, binds down the soft parts in the hollow between the bones of the fore-arm, is intimately connected with the strong septa between the several superficial muscles immediately beneath it, and sends off a thin and nearly cellular transverse membrane to separate the superficial from the deeper group of muscles. Approaching the back of the wrist, the transverse fibres increase in number and strength, and these being stretched, from the outer margin of the radius on one side to the pisiform bone and the palmar fascia on the other, constitute the *posterior annular ligament* of the carpus. (See p. 274.) This structure, however, is attached not only to the points just indicated, but it is likewise connected to the several parallel ridges on the posterior flat surface of the radius, and thus converts the intermediate grooves into complete fibro-osseous canals to lodge the tendons of the extensor muscles.

The *fasciæ of the hand*.—On the *dorsal* aspect is found a thin layer of fascia, which is prolonged from the posterior annular ligament over the extensor tendons, separating them from the superficial veins and nerves.

The *palmar fascia* consists of a central and two lateral portions. The lateral divisions are very thin; they afford a delicate covering to the muscles composing respectively the thenar and hypothenar eminences. The central portion is one of the strongest fasciæ of the



body. Occupying the interval between the eminences just named, and expanding towards the fingers, it has a somewhat triangular or fan-like form. The narrow end of the fascia, thicker than any other part, and composed of close parallel fibres, is continuous with the anterior annular ligament, and receives the tendon of the palmaris longus muscle; the broader portion, becoming thinner and flatter as it advances towards the fingers, has a much more irregular and interlaced texture, and adheres more closely to the skin of the palm. Opposite the heads of the metacarpal bones it divides into four processes, each of which, corresponding to a finger, soon splits again to arch over the sheath of the flexor tendons; and the bundles of fibres thus separated, and dipping on each side of the joints between the metacarpal bone and the first phalanx, are attached to the ligaments of these joints, and to the sheaths of the tendons, some fibres continuing to the transverse ligament which binds the metacarpal bones one to the other. These divisions of the palmar fascia are held together by irregular transverse fibres, which (lying immediately under the skin, and frequently adhering to it, and on this account rendering the structure indistinct,) serve to give great additional strength at the points of divergence. Interposed between the digital processes now described are the digital arteries and nerves.

The palmar fascia on its cutaneous surface gives origin to some of the fibres of the palmaris brevis. It covers immediately the palmar arteries and nerves with the tendons of the flexor muscles.

#### FASCIÆ OF THE ABDOMEN.

As the fasciæ are merely accessory to other structures, especially the muscles, it is to be expected that they should vary in different situations with the purposes to which they are subservient. In the limbs the muscles are arranged in elongated masses; and, being frequently unattached to the bone except at their opposite ends, they have a considerable tendency to displacement during the varied and extended motions of the limbs. Here, therefore, the investing fasciæ are for obvious reasons strong and distinct. But over the abdomen, the muscles, having a regular stratiform arrangement, are held fixed not only at their ends, but at the margins, and they are not liable to such alteration in position as in the limbs results from the extensive movements of the joints. Under such circumstances an investing fascia is little required, and it is in fact proportionably little developed. One muscle (the rectus), which, differently from the rest, is long, narrow, and fixed only at the ends, is retained in its position by a peculiar arrangement of aponeurotic structure.

On the abdomen there are recognised—*a.* the superficial fascia, as in other situations; *b.* on the inner surface of the deepest muscle, and immediately lining the cavity, a peculiar layer of fascia, named from the muscle with which it is in contact; *c.* a delicate layer of membrane immediately investing the muscular fibres, and the representative of the well-developed deep fascia which encases the muscles of the limbs and the neck.—The structure last referred to needs only to be indicated; the other fasciæ require detailed examination.



*External or superficial fascia.*—Over the greater part of the abdomen this fascia presents the appearance of a single membrane; but in the inguinal region it consists obviously of two layers, which differ so materially from each other in appearance, structure, and connexions, as to require distinct mention. The *subcutaneous layer* consists, like the superficial fascia of the neck and thigh, of cellular membrane containing fat in greater or less quantity, superficial vessels, and lymphatic glands. In fat subjects this structure may be partially separated by dissections into several irregular layers. In lean bodies it has more of a membranous character, but is still split as it were at certain points to embrace and contain the superficial vessels. Traced towards the linea alba, the penis, and scrotum, this superficial portion is found to contain less and less fat, until finally it ceases to exist as a distinct structure, becoming by degrees inseparably united to the deeper layer. Over Poupart's ligament it is continuous with the superficial fascia of the thigh, and more externally with that covering the gluteal region.

The *deeper layer* of the superficial fascia is thinner than that just described, and more distinctly membranous in its appearance and structure. Between this layer of the superficial fascia and the subcutaneous one already noticed are placed the superficial inguinal blood-vessels and the lymphatics. The deep layer being traced downwards over the external oblique muscle, is found to be fixed to Poupart's ligament near the anterior superior spine of the ilium and to the fascia lata—a little below that structure—across the thigh. Over the spermatic cord, the superficial fascia (its two layers being here blended one with the other, and at the same time altered in structure, and devoid of fat) descends to the scrotum, and so becomes continuous with the corresponding structure in the perineum. Lastly, nearer the middle line, it is continuous with the membranous sheath of the penis.

*Lining membrane of the abdomen.*—On the inner surface of the walls of the abdomen is a membranous structure, which lines the visceral aspect of the deepest layer of the muscles. This membrane or fascia is continuous all around the cavity, which it assists in closing; and it has been differently named in different parts, according to the muscles with which it is in immediate contact—fascia transversalis, fascia iliaca. Descending into the pelvis, the lining membrane of the cavity assumes the name pelvic fascia, &c.

*Fascia transversalis* (A. Cooper).—The larger portion of the membranous lining of the abdomen, namely, that corresponding with the anterior and lateral parietes, has been described under this name, on account of its close connexion with the inner surface of the transversalis muscle. As in the case of other abdominal fasciæ, it is strongest and most clearly demonstrable in the inguinal region, where the muscles are somewhat defective; and here also it is of particular interest, on account of its connexion with the structure of the parts through which inguinal herniæ are protruded. Followed upwards from this situation, the transversalis fascia becomes gradually thinner, and beyond the margin of the ribs it degenerates into a mere cellular covering to the under surface of the diaphragm. Traced on either side, also, it is found thinner and more cellular as it approaches the



loins, where, from the thickness and comparative immobility of the abdominal walls, it may be said to be less required to support the viscera. The transversalis fascia is continuous with the iliac fascia—the smaller portion of the lining membrane of the abdominal walls; but the connexion between them is somewhat complex inferiorly in consequence of a prolongation being sent over the large vessels as they pass from the abdomen to supply the lower limb.

Along the inner surface of the crest of the ilium, between the iliacus and transversalis muscles, the fascia transversalis is connected with the periosteum along the line of attachment of the fascia iliaca. For about two inches from the anterior superior spine of the ilium inwards, it is closely connected with the posterior surface of Poupart's ligament, and is there directly continuous with the fascia iliaca, which comes forward from the iliac fossa, a white line sometimes marking the place at which one is continued into the other. At this point, also, and to the same extent, the fascia lata of the thigh is closely connected with Poupart's ligament, which is here very strong, and forms thus a point of union of several layers of fascia. About midway between the spine of the ilium and that of the pubes, the large artery and vein (which lie in front of the iliac fascia) prevent, as they pass out into the thigh, the fascia transversalis from joining the fascia iliaca, and from this point to the edge of Gimbernat's ligament the fascia transversalis is prolonged downwards over the artery and vein, forming the anterior portion of the femoral sheath. This part or prolongation of the fascia transversalis is not very closely connected with Poupart's ligament, under which it passes. It is here strengthened by a dense band of fibres, which arches over the vessels, and is inserted into the crest and pectineal line of the pubes, behind the conjoined tendons of the transversalis and internal oblique, and the reflected insertion of the external oblique aponeurosis. This band is sometimes called the *deep crural arch*.

Lastly, about half-way between the anterior superior spine of the ilium and the symphysis pubis, and about half an inch above Poupart's ligament, the spermatic cord in the male, and the round ligament in the female, pierce the fascia transversalis; and these structures, instead of passing through a mere foramen in the membrane, receive respectively from the fascia, a delicate funnel-shaped covering, which is prolonged upon them. The opening thus formed in the transversalis fascia is called the *internal abdominal ring*; but the scalpel must be used to cut the delicate sheath around the cord, before anything like a ring or defined aperture can be seen.

The *fascia iliaca*, more limited in extent, but stronger than the fascia transversalis, lines the back part of the abdominal cavity, and covers not only the muscle from which it derives its name, but also the psoas. The densest portion of its fibres is stretched transversely from the crest of the ilium, over the margin of the psoas muscle to the brim of the pelvis, where it is intimately blended with the periosteum. Upwards, this membrane, becoming much weaker, is connected with the sacrum, and by small and distinct processes with the intervertebral substances and neighbouring margins of the lumbar vertebræ; and



finally it becomes blended with the lumbar fascia at the *ligamentum arcuatum externum*. The external iliac vessels lie on or in front of this part of the iliac fascia.

Along the line corresponding to the division between the abdomen and the thigh, the iliac fascia is variously disposed. Thus, to the outer side of the external iliac artery, it turns forwards to be connected with Poupart's ligament and the fascia transversalis, as already described; to the inner side of the femoral vein it is attached to the ilio-pectineal line, where also the pubic portion of the fascia lata, being traced upwards, is found to terminate; and between these two points, namely, behind the femoral vessels, it continues downwards over the margin of the pelvis, forming the back part of the sheath of those vessels. As regards this sheath, it may here be stated, that though its fore part is said to be continued from the fascia transversalis, and its back part from the fascia iliaca, still the sheath is formed of continuous membrane,—the mode of describing it, which appears to imply a separation, necessarily resulting from the division of the internal abdominal fascia into these two parts. When it is considered that the transversalis and iliac fasciæ are but parts of the same structure, (differently named, for reasons already noticed,) the femoral sheath will appear to correspond in its construction with the funnel-shaped covering given to the spermatic cord.

The *psoas parvus*, when present, is closely connected, by means of fibres sent off from its tendon, with the inner portion of the iliac fascia.

The lumbar fascia (*fascia lumborum*) will be described in connexion with the abdominal muscles; with which structures, indeed, it is anatomically more closely related than it is with the fasciæ properly so called.

#### FASCIÆ OF THE PERINÆUM.

The fasciæ of the perinæum correspond in a great measure with those at the lower part of the abdomen. They consist of the superficial fascia, which covers the muscles, and a deeper fascia, which is to be considered the boundary of the pelvic cavity.

*Superficial fascia of the Perinæum.*—The two laminæ of which this is composed, as has been said of the corresponding fascia of the groin, differ so materially from each other that they must be separately described. The outer or *subcutaneous layer*, is thick and cellular, contains a quantity of fat, is more adherent to the skin than to the subjacent layer, and is prolonged continuously over the buttocks and thighs, without any attachment to periosteum. Traced forwards, however, it is gradually lost sight of in the scrotum, where, losing its fat, it joins inseparably with the deep layer.

The *deeper layer* of superficial fascia, is thinner but more distinctly membranous, contains little or no fat, invests closely the perinæal muscles, does not extend laterally over the thighs, and has some important connexions with other structures. Thus, on each side, the deep layer is closely connected with the rami of the pubes and ischium as far as the tuberosity of the latter bone, so much so that air injected under it cannot be made to pass any farther in this direction. In front



it is continued into the scrotum, and thus becomes connected with the deeper layer of the superficial fascia of the abdomen. Between the perinæal muscles it sends cellular processes or septa, and finally, (avoiding the sphincter ani, which lies immediately under the skin,) it turns round the posterior margin of the transversus perinæi muscle to join with a thin prolongation sent forwards from the deep perinæal fascia, to be presently described. The attachment of this layer of superficial fascia laterally and behind, and its continuity with other similar structures in front, account for the course taken (as long as this fascia remains entire) by urine extravasated from rupture of the urethra.

The *deep perinæal fascia* (triangular ligament,—Douglas; triangular ligament of the urethra,—Camper) lies under the proper perinæal muscles, closing in the anterior portion of the outlet of the pelvis. It is a very strong and resistant membrane. Necessarily triangular in form in consequence of the direction of the bones with which it is connected, the apex of this fascia corresponds to the arch of the pubes, and is connected with the sub-pubic ligament; the two sides are firmly attached to the rami of the pubes and a small portion of the ischia, behind the insertion of the crura penis; and the base turned towards the rectum has connexions to be presently described. It is pierced by the membranous portion of the urethra, about an inch behind the pubic arch, and just above or in front of this, by the dorsal veins of the penis.

The deep perinæal fascia is composed of two layers, between which are contained the arteries of the bulb, Cowper's glands, and the compressor muscles of the urethra. These two layers are differently disposed at the urethral aperture and at the base or free margin of the fascia. Thus, from around the margin of the urethral aperture the layers are prolonged,—the one forwards to become continuous with the coverings of the bulb and the corpus spongiosum urethræ, the other backwards towards the fibrous investment of the prostate gland, so as to leave the opening imperfectly defined on both its outer and its inner aspect.

Towards its base the fascia becomes weaker, and about half an inch behind the urethral aperture, the two layers, in place of terminating abruptly, separate again from each other, diminishing in strength and distinctness as they thus diverge. The anterior layer, turning forwards behind the transverse muscles of the perinæum, joins with the deep layer of superficial fascia already described as turning in to meet it. The posterior layer extends on each side into the thin membrane which is spread over the outer surface of the levator ani.

#### FASCIÆ OF THE PELVIS.

The pelvis is lined with fascia in the same manner as the abdomen. But there is here a peculiar layer, which may be considered a visceral layer, directed inwards from the parietal portion to the viscera. The visceral layer belongs to the levator ani muscle. This muscle extends from the walls of the pelvis to the organs in that cavity and supports them; and the fascia or layer of fascia in question lines the upper sur-



face of the muscle. From this statement it results that the fascia in the pelvis consists of two parts—one lining the cavity, the other assisting to support the viscera. There are, however, three portions recognised by anatomists, and a distinctive name is assigned to each. Thus, the membrane descending from the brim of the pelvis (to which the iliac fascia was traced) and lining the cavity, is named “pelvic fascia;” but it assumes the name “obturator fascia” (from the muscle it is chiefly in contact with) below the point at which the visceral layer is given off. And this last is called “vesical” or “recto-vesical.” It might be said that the pelvic fascia, after descending a certain way, splits into the obturator and recto-vesical fasciæ.

The deep perinæal fascia already described (page 305) has likewise a claim to be referred to among the fasciæ of the pelvis, inasmuch as it closes in this cavity beneath the arch of the pubes.

The membranes, or layers of membrane, whose arrangement has thus been noticed generally and in connexion, will now be separately examined.

The *pelvic fascia* lines the upper part of the cavity of the pelvis. At the side of the cavity this fascia is attached to the brim of the pelvis, where the iliac fascia was said to end, and the two membranes are for some space continuous one with the other. Further forward, the attachment of the pelvic fascia to the bone or periosteum inclines downwards behind the pubes, following the margin of the obturator internus towards the lower part of the symphysis of the pubes. Descending in the cavity, the fascia covers the internal obturator muscle, and is connected with, or gives origin to, some of its fibres. At the back part of the pelvis, degenerating into a thin cellular layer, it spreads over the pyriform muscle and the sacral nerves, and is here perforated by branches of the internal iliac artery and vein. In front, the fascia is connected with the fibrous part of the canal by which the obturator vessels and nerve escape from the pelvis; and close to the symphysis pubis, a short band is directed backwards, above the prostate gland, to the bladder, with which it is intimately connected. A similar band exists at the opposite side of the symphysis of the pubes, and the two are separated by a narrow depression, in or opposite which the dorsal veins of the penis lie, after entering the pelvis. The bands in question are named the *anterior true ligaments of the urinary bladder*.

The pelvic fascia is considered to end at a white thickened band, which stretches from near the symphysis pubis to the spine of the ischium. From the under surface of this band the levator ani muscle arises, and in the same place springs a layer of fascia which follows the upper surface of that muscle to the viscera—the vesical fascia.

*Obturator fascia.*—This is the continuation of the pelvic fascia over the lower part of the internal obturator muscle; and being so,—to recognise it under a separate designation seems superfluous. The obturator fascia is fixed below to the rami of the pubes and ischium, and to the great sacro-sciatic ligament, receiving some strengthening fibres from the last-named structure. The internal pudic vessels and nerve, in their progress upwards to the perinæum, are contained in a canal formed in this fascia.



The *vesical fascia* (recto-vesical), the visceral layer of the pelvic fascia, takes its rise from the band (ischio-pubic) before mentioned as stretching from the pubes to the spine of the ischium, and descends, immediately in contact with the inner surface of the levator ani muscle, to the prostate gland, the urinary bladder, and the rectum. It is reflected to some extent on each of those organs from the point at which it comes into contact with them. Thus, arrived at the base or back part of the prostate, it gives an elongation forwards on the veins (prostatic) which cover the prostate, and, continued backwards to the bladder, it forms the *lateral true ligament* of this viscus. It invests the vesiculæ seminales, and is extended across between the bladder and the rectum; here continuing into the membrane of the opposite side, it supports the bladder, and separates that organ from the rectum. On the rectum the fascia is also reflected upwards and downwards, gradually degenerating into cellular membrane over the surface of the bowel, as it likewise does on the bladder.

In the female, the pelvic fascia is connected with the vagina as with the other pelvic organs.

#### FASCIÆ OF THE LOWER LIMB.

As in most other situations, these consist of two very distinct structures,—the one subcutaneous, and composed of cellular membrane more or less loaded with fat, and the other forming an immediate and strong fibrous investment to the muscles of the limb.

The *superficial fascia* is more distinctly membranous in the upper part of the thigh, and in the popliteal region, than in the other parts of the limb; but in the sole of the foot it is so adherent to the skin on one surface, and to the deep fascia on the other, or these two structures are so closely connected together, that the superficial fascia can be hardly said to exist. In the groin it is described more minutely than elsewhere, on account of its connexions with the deep fascia (*fascia lata*), and the influence which it consequently exercises over herniæ, or effusions of fluid, in this neighbourhood. Besides the subcutaneous fat, the superficial vessels and glands are contained in this membrane; and as these are large and numerous, and are covered on both surfaces, it follows that the superficial fascia is here capable of partial subdivision into either two or more imperfect laminæ. The outermost of these is continuous uninterruptedly with the subcutaneous layer of the superficial abdominal fascia above, and with the corresponding structure in the thigh below; but the innermost layer is closely connected a little below the level of Poupart's ligament with the *fascia lata*. This connexion has already been noticed in tracing the superficial fascia of the abdomen downwards to the groin; it is so complete, that air or liquid injected under the superficial fascia of the abdomen cannot be made to pass, without direct rupture, into the thigh, or *vice versa*; and the union between the two fasciæ takes place, not by a mere narrow line, but over a tolerably broad surface, particularly over the saphenous opening, where the superficial fascia adheres to the margin of the aperture, and assists in closing it. As the



portion of the superficial fascia covering the saphenous opening is perforated by several superficial vessels, it has received the distinctive appellation of the *cribriform fascia*. About two inches below Poupart's ligament the superficial fascia is again found wholly distinct from, and scarcely attached to, the fascia lata.

*Synovial bursæ* are found in the superficial fascia of the lower limb over the patella, the point of the heel, and the phalangeal articulations of the toes.

#### DEEP FASCIA.

Beneath the skin and superficial fascia is found the proper investing fascia of the limb, which is named in the thigh fascia lata, but is designated in the leg and foot merely according to the part actually covered.

The *fascia of the thigh* (*fascia lata*) forms a perfectly continuous sheath to the thigh, varying, however, much in thickness in different parts. It is strongest on the outer aspect of the limb, where its dense and glistening parallel fibres give it much the appearance of a tendinous aponeurosis; indeed, it here serves the purpose of a tendon to the tensor vaginæ femoris, and to a large part of the gluteus maximus, both which muscles act on the limb through the intervention of the fascia. This membrane is thinnest in the upper and inner part of the thigh, where it covers the short adductor muscles. Near the knee, it is considerably strengthened by a tendinous expansion given off from the lower termination of the extensor muscles of the leg in front, and from the tendon of the biceps behind.

Direct connexions between the fascia lata and the periosteum occur at various points, more especially at the sides of the sacrum and coccyx, along the crest of the ilium, the pectineal line, the crest and the rami of the pubes, and the ramus of the ischium above, as well as over the condyles of the femur, the tuberosities of the tibia, and head of the fibula below. Indirectly the fascia is still further connected with the periosteum by means of septa which pass between the muscles to the shaft of the femur. These will be hereafter more particularly described.

The sheath-like arrangement of the fascia round the entire limb is simple over the greater part of the thigh; but a little below Poupart's ligament an interruption to this continuity exists in consequence of the presence of an oval and somewhat oblique opening (*saphenous opening*) for the transmission of the principal superficial vessels. Here also femoral hernia descends; and it is with the view of permitting a more precise description of the mode of formation of this opening that the two portions of the fascia lata which lie respectively on its outer and inner side are separately named,—that at the outer or iliac side, and attached to the ilium, being called the iliac portion; and that on the inner side, and connected with the pubes, being named the pubic portion.

Up to the lower margin of the saphenous opening, and immediately behind the long saphenous vein, the membrane is single; but at that



point, and immediately below the junction of the saphenous with the femoral vein, the two portions above named separate to enclose the saphenous opening. The lower curved margin of this aperture is called its *inferior cornu*.

The *external* or *iliac* portion, traced upwards from this point, is found lying on, and intimately united with, the anterior portion of the sheath of the femoral vessels; crossing to the inner side of this sheath it forms an arched margin (*upper cornu* of the saphenous opening) which looks downwards and inwards. This margin is less perfectly defined than the inferior cornu, partly from its connexion with the cribriform fascia, and partly from its adhesion to the femoral sheath beneath, in the manner already indicated. Approaching yet nearer the fold of the groin, the iliac portion of the fascia lata expands transversely, and corresponds to nearly the entire width of the groin. At the crest and anterior superior spine of the ilium it is attached, through the medium of the periosteum, to the bone; and from this point inwards it is closely connected with Poupart's ligament and the deep layer of the superficial fascia of the abdomen. At its inner termination, beneath the attachment of the external pillar of the ring to the spine of the pubes, it is attached to the pectineal line in close connexion with the reflected insertion of the aponeurosis of the external oblique muscle.

The *inner* or *pubic* portion of the fascia lata, also followed from the inferior cornu, rises over the pectineus muscle, and, passing deeply behind the saphenous vein and femoral sheath, lies on a plane posterior to the iliac portion just described. On the outer side it becomes closely connected with the femoral sheath (its posterior surface), and may be traced even to the sheath of the psoas muscle and to the fibrous capsule of the hip-joint. On the inner side it is connected with the margin of the rami of the pubes and ischium. Above, it is attached to the pectineal line, close in front of the insertion of the external oblique aponeurosis. The cribriform fascia is less firmly connected with the pubic than with the iliac portion of fascia.

As occurs in other situations, this investing fascia sends partitions between the several muscles composing the bulk of the limb; these partitions are indicated on the surface by dense white lines. The strongest and deepest of the partitions is called the *external intermuscular septum*. It passes between the vastus externus and the short head of the biceps, is inserted into the linea aspera of the femur from the lower edge of the tendon of the gluteus maximus to the outer condyle of the bone, and serves to bind the muscles down to the bone, and retain them in their situations during their different actions, by fixing the strong external portion of the fascia lata. The *internal intermuscular septum* is a much thinner structure; it is inserted into the linea aspera between the vastus internus and the adductor muscles.

Several muscles are partially inserted into the fascia lata, and act more or less as tensors of that membrane. The tensor vaginæ femoris, indeed, has no other insertion, and is the proper tensor muscle of the fascia; its fibres are enclosed between two layers of



the fascia, which unite together at the distance of three or four inches below the anterior superior spine of the ilium. The gluteus maximus, which is somewhat similarly enclosed between two layers, is also partly inserted into the fascia over the great trochanter of the femur. In the same manner, though to a smaller extent, the tendons of the biceps and semi-membranosus behind, and of the sartorius and quadriceps extensor cruris in front, send bundles of fibres to strengthen and support the fascia round the upper part of the knee-joint. Other muscles, again, take a partial origin from the fascia lata or its prolongation inwards. Thus, many of the fibres of the gluteus medius arise from the dense portion of fascia stretched between the tensor vaginæ femoris and the gluteus maximus. From the external intermuscular septum also arise many muscular fibres of the vastus externus and of the short head of the biceps. Lastly it may be mentioned, that the fascia lata forms a very distinct sheath for the sartorius by splitting on the outer margin and reuniting at the inner margin of that muscle, as the cervical fascia does for the sterno-mastoid.

The *fascia of the leg* is continuous around the knee with the fascia lata of the thigh, and over the ankle with the corresponding investment of the foot. It is particularly dense in the upper and fore part of the leg, where it is strengthened by fibres sent from the tendons of the biceps on the outer, and the sartorius on the inner sides; but it becomes much thinner behind, where it covers the gastrocnemius and soleus muscles. This fascia is adherent to the periosteum, covering the head, the spine, and the posterior and inner margin of the tibia, to the head of the fibula, and to the outer and inner malleoli; and it invests the leg all round except the inner surface of the tibia. From its under surface intermuscular septa are prolonged inwards. The situation of these septa is marked on the surface of the fascia by several white lines in front and on the outer side of the leg. The first, on the outer side of the spine of the tibia, runs between the tibialis anticus and the extensor longus digitorum, and is attached deeply to the interosseous ligament; and the second, extending between the long extensor and peroneus tertius in front, and the peroneus longus and brevis behind, is inserted along the outer margin of the shaft of the fibula. These septa, as also the upper and anterior portion of the fascia itself, afford attachment to the muscular fibres next to them, and thus increase greatly the extent of the surfaces giving origin to the muscles.

Between the superficial and the deep muscles on the back of the leg, a layer of fascia is stretched from side to side across the limb. This membranous septum, known as the *deep fascia of the leg*, extends downwards from the fascia covering the popliteus muscle or the place of origin of the soleus muscle. Where covered by the soleus and gastrocnemius muscles, the fascia is weak, but it becomes stronger as it escapes from under cover of those muscles and approaches the malleoli.

Around the ankle, the fascia of the leg becomes continuous with that of the foot; but in front, and on the inner side of that joint, strong bands of fibres are superadded, which are called annular ligaments. As they are merely stronger portions of the ordinary fascia,



it is often difficult in dissection to mark satisfactorily the outline of these bands, or to discover anything like an upper and lower margin. Their function is that of confining the tendons in their natural positions.

The *anterior annular ligament* is partially separated opposite the flexure of the joint into two portions or bands, the one properly belonging to the leg, and the other to the foot. The *upper band* stretches from the lower end of the fibula to the lower end of the tibia, and binds down the vertical portion of the extensor tendons to the point at which they make their turn forwards to the foot. The *lower band* extends from the lower end of the tibia, near the point of the inner ankle, to the upper surface of the calcaneum, and confines the horizontal portions of the same tendons to the dorsal surface of the tarsal bones. By splitting into two layers, and passing partly in front and partly behind the tendons, these bands form several sheaths, which are lined by synovial membranes. The compartment of the annular ligament next the fibula, is appropriated to the peroneus tertius and extensor communis digitorum; a second, next the tibia, contains the tendon of the tibialis anticus; and a third, found only in the lower portion, transmits the extensor proprius pollicis. The entire structure covers the anterior tibial vessels and nerve.

The *internal annular ligament* crosses the space between the inner ankle and the heel, through which the tendons of the flexor muscles run. Its upper border, continuous with the fascia of the leg (more especially the deep layer), is very imperfectly defined; and its lower border, giving origin to many fibres of the abductor pollicis, is but little more distinct. Its anterior extremity is attached to the inner malleolus, and its posterior termination is inserted into the inner margin of the calcaneum; but between these two points it is further connected to the bone by means of septa, which thus enclose several arched canals. The first canal (next the malleolus) contains the tendon of the tibialis posticus, and the second, that of the flexor longus digitorum, both being provided with a synovial lining. Then follows a wider space for the passage of the posterior tibial vessels and nerve; lastly, against the astragalus, a fourth canal lined like the two first by a synovial bursa transmits the tendon of the flexor longus pollicis.

The *external annular ligament* extends from the point of the outer malleolus to the outer surface of the calcaneum, and keeps in place the tendons of the long and short peronei muscles. The tendons are close together and they are surrounded by a synovial sac.

The *fascia on the dorsum of the foot* is a thin membrane prolonged from the anterior annular ligament over the extensor tendons. It is attached, more or less closely, to points of the tarsal and metatarsal bones left uncovered by tendon or muscle, and is continuous round the outer and inner margins of the foot and between the clefts of the toes, with thinner and degenerated portions of the plantar fascia.

The *plantar fascia* is a much stronger and more important part, being, indeed, the thickest of any of the structures composing this class of fibrous membranes. It is composed of dense, white, glistening fibres, the greater number of which are arranged in a longitudinal



direction, and extends from the under surface of the os calcis forwards to the heads of the metatarsal bones. This fascia may be described as composed of three divisions, (a central and two lateral,) of very different degrees of thickness, and clearly marked off from each other by two strong intermuscular septa. The *inner* division, very thin and unlike the other portions, invests the abductor pollicis, and is often partly removed with the skin in dissection. It is continuous round the inner border of the foot with the dorsal fascia, and with the internal annular ligament. The *outer* division covers the abductor minimi digiti, and is much stronger, particularly between the under surface of the calcaneum and the base of the fifth metatarsal bone, to both which points it is firmly attached. It is continuous round the outer border of the foot with the dorsal fascia, and sends a thin prolongation forwards over the insertion of the abductor and the short flexor of the little toe. The *central* division, like the corresponding part in the palmar fascia, is narrow behind, and becomes wider and thinner towards the toes. At the back part, where it is thickest, the fascia is attached to the tubercles on the under surface of the calcaneum immediately behind the origin of the flexor brevis digitorum, with which muscle it is closely connected. Nearly opposite the middle of the metatarsal bones, this fascia, becoming broader and thinner as it advances, begins to divide into five processes, one for each of the toes; and from this point forwards to the bases of the toes, numerous strong transverse fibres are superadded, which bind the processes together, and connect them closely with the skin. Opposite the articulation of the toe with the metatarsal bone, each of the five processes divides, to permit the passage of the flexor tendons; and the two bundles of fibres resulting from the division of each process, after strengthening the sheath of the tendons over which they pass, are blended with the ligaments of the joints.

It has already been intimated that the three divisions of the plantar fascia are united together along the whole length of the foot, so as to form a continuous structure, and the union is marked on the surface by two longitudinal depressions or grooves. Opposite these grooves two strong *intermuscular septa* are prolonged deeply upwards into the sole of the foot, separating the flexor brevis digitorum from the abductor pollicis on the inner side, and from the abductor minimi digiti on the outer side, and giving partial origin to each of these muscles. Finally, the intermuscular septa are connected with thin membranous partitions, which are found interposed between the respective layers of muscle in the sole of the foot.



# MYOLOGY.

---

## MUSCULAR TISSUE.

THE muscular tissue is that by means of which the active movements of the body are produced. It consists of fine fibres, which are for the most part collected into distinct organs, called muscles, and in this form it is familiarly known as the flesh of animals; these fibres are also disposed round the sides of cavities and between the coats of hollow viscera, forming strata of greater or less thickness. The muscular fibres are endowed with *contractility*, a remarkable and characteristic property, by virtue of which they shrink or contract more or less rapidly under the influence of certain causes which are capable of exciting or calling into play the property in question, and which are therefore named *stimuli*. A large class of muscles, comprehending those of locomotion, respiration, expression, and some others, are excited by the stimulus of the will or volition, acting on them through the nerves; these are therefore named "voluntary muscles," although some of them habitually, and all occasionally, act also in obedience to other stimuli. There are other muscles or muscular fibres which are entirely withdrawn from the control of the will, such as those of the heart and intestinal canal, and these are accordingly named "involuntary." These two classes of muscles differ not only in the mode in which they are excited to act, but also to a certain extent in their anatomical characters; and on this account we shall consider the structure of each class separately.

*Of the structure of voluntary muscles.*—The voluntary muscular fibres are for the most part gathered into distinct masses or muscles of various sizes and shapes, but most generally of an oblong form, and furnished with tendons at either extremity, by which they are fixed to the bones.

The two attached extremities of a muscle are named, in anatomical descriptions, its origin and insertion,—the former term being usually applied to the attachment which is considered to be most fixed, although the rule cannot be always applied strictly. The fleshy part is named the belly, which in some cases is interrupted in the middle or divided into two by a tendon, and then the muscle is said to be bi-ventral or digastric; on the other hand it may be cleft at one end into two or three portions, in which case it is named bicipital or tricipital, &c.

The muscular fibres are collected into packets or bundles, of greater or less thickness, named fasciculi or lacerti, (fig. 157,) and the fibres themselves consist of much finer threads, visible by the aid of



the microscope, which are termed muscular filaments or fibrillæ, (fig. 158, c.) The fibrillæ run parallel with each other in the fibres, and the fibres are parallel in the fasciculi, and both extend continuously from one terminal tendon to the other, unless in those instances, like the rectus muscle of the abdomen and the digastric of the inferior

Fig. 157.

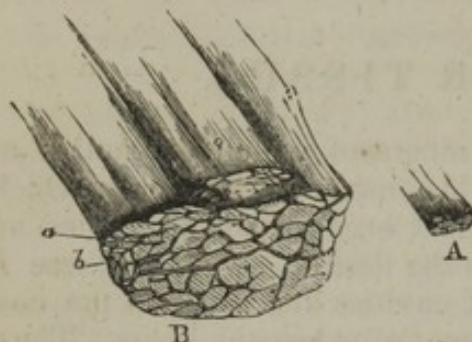


Fig. 158.

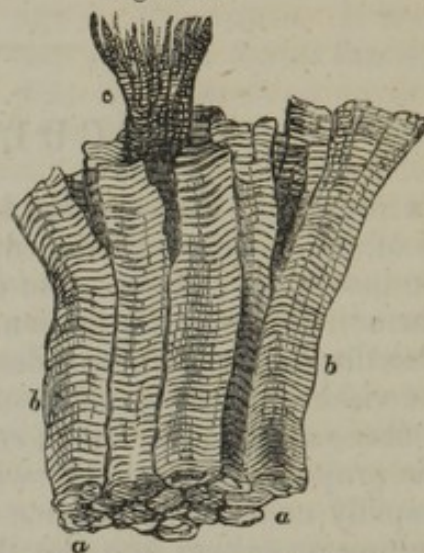


Fig. 157.—A, a small portion of muscle, natural size; B, the same magnified 5 diameters, of larger and smaller fasciculi, seen in a transverse section.

Fig. 158.—A few muscular fibres, being part of a small fasciculus, highly magnified, showing the transverse striæ. *a*, End view of *b b*, fibres; *c*, a fibre split into its fibrillæ.

maxilla, in which the fleshy part is interrupted by interposed tendinous tissue. The fasciculi also very generally run parallel, and although in many instances they converge towards their tendinous attachment with various degrees of inclination, yet in the voluntary muscles they never interlace with one another.

*Sheath.*—An outward investment or sheath of cellular tissue surrounds the entire muscle, and sends partitions inwards between the fasciculi; furnishing to each of them a special sheath. The cellular tissue extends also between the fibres, but does not afford to each a continuous investment, and therefore cannot be said to form sheaths for them. Every fibre, it is true, has a tubular sheath; but this, as will be afterwards explained, is not derived from the cellular tissue. The chief uses of the cellular tissue are no doubt to connect the fibres and fasciculi together, and to conduct and support the blood-vessels and nerves in their ramifications between these parts. The relation of these different subdivisions of a muscle to each other, as well as the shape of the fasciculi and fibres, is well shown by a transverse section. (Figs. 157 and 158.)

*Fasciculi.*—The fasciculi are of a prismatic figure, and their sections have therefore an angular outline. The number of fibres of which they consist varies, so that they differ in thickness, and a larger fasciculus may be divisible into two or three orders of successively smaller bundles, but of no regularly diminishing magnitude. Some muscles have large, others only small fasciculi; and the coarse or fine texture of a muscle, as recognised by the dissector, depends on this circumstance. The length of the fasciculi (and consequently that




of the fibres and filaments) is not always proportioned to the length of the muscle, but depends on the arrangement of the tendons to which their extremities are attached. When the tendons are limited to the ends of a long muscle, as in the sartorius, the fasciculi having to pass from one extremity to the other, are of great length; but a long muscle may be made up of a series of short fasciculi attached obliquely to one or both sides of a tendon, which advances some way upon the surface or into the midst of the fleshy part, as in the instance of the rectus muscle of the thigh, and the tibialis posticus. Muscles of the kind last referred to are named "penniform," from their resemblance to the plume of a feather, and other modifications of the arrangement, which can be readily conceived, are named "semipenniform" and "compound penniform." Many short fasciculi connected thus to a long tendon, produce by their combined effect a more forcible contraction than a few fasciculi running nearly the whole length of the muscle; but by the latter arrangement the extent of motion is greater, for the points of attachment are moved through a larger space.

*Of the fibres.*—The fibres, although they differ somewhat in size individually, have the same average diameter in all the voluntary muscles, namely, about  $\frac{1}{400}$ th of an inch; and this holds good whether the muscles be coarse or fine in their obvious texture. According to Mr. Bowman\* their average size is somewhat greater in the male than in the female, being in the former  $\frac{1}{352}$ , and in the latter  $\frac{1}{434}$ , or more than a fourth smaller. When viewed by transmitted light with a sufficiently high power of the microscope, the fibres, which are then clear and pellucid in their aspect, appear marked with very fine dark parallel lines passing across them directly or somewhat obliquely, at exceedingly short but regular intervals. (Figs. 158 and 159.) The lines, as just mentioned, are dark, and the intervals between them light; their distance apart is about  $\frac{1}{9400}$ th of an inch, and they are even closer together in parts of a muscle which happen to be contracted. This cross-striped appearance, which is most beautiful and characteristic, is found in all the voluntary muscles; but it is not altogether confined to them, for it is seen in the fibres of the heart, which is a strictly involuntary organ: striped fibres are also found in the pharynx and upper part of the gullet, in the muscles of the internal ear, and those of the urethra, parts which are not under the direct control of the will.

As to the structure of the fibres, it has been ascertained that each is

[Fig. 159.]



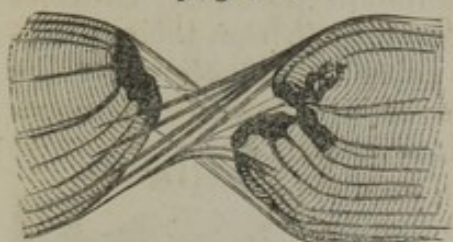Two muscular fibres, highly magnified, from the pectoralis major muscle of an adult human male subject. They exhibit the cross-striped appearance, and also some dark, short, longitudinal lines which are shades, often observed beneath the microscope, and indicate the course of the fibrillous arrangement of the sarcoous element. From nature, by J. L., 1847.]

\* I shall have frequent occasion in this chapter to refer to Mr. Bowman's important researches on muscle. Phil. Trans. 1840 and 1841, and Cyclopaedia of Anatomy, art. "Muscle," and "Muscular Motion."



made up of a large number of extremely fine filaments or fibrils, enclosed in a tubular sheath. The proper sheath of the fibre, which was discovered nearly about the same time and independently by Schwann and by Bowman, has been named by the latter the "sarcolemma."\* It consists of transparent and apparently homogeneous membrane, and, being comparatively tough and elastic, will sometimes remain entire when the included fibrils are ruptured by stretching the fibre, as represented in fig. 160.

[Fig. 160.]

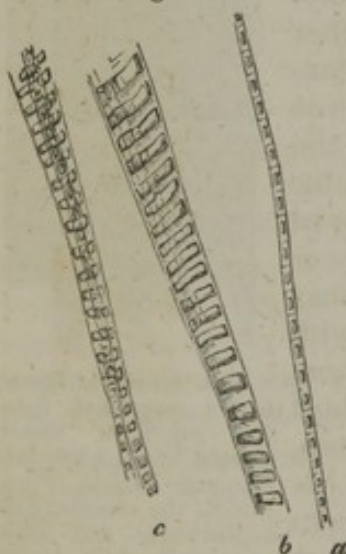


Fragments of an elementary fibre of the skate, held together by the untorn but twisted sarcolemma.—Todd & Bowman.]

the fibre and its sheath, and raises the membrane into vesicles or bullæ.

In this way its existence may be demonstrated, and it is especially well seen in fish and other animals which have large fibres, for in such instances it is thicker and stronger. It may also be shown by immersing a fibre in water before irritability is extinguished; the fluid is in this case first imbibed by the fibre, and then, exciting contraction, is squeezed out of its substance, when it usually collects between

Fig. 161.



Muscular fibrillæ of the pig magnified 720 diameters. *a*. An apparently single fibril, showing the quadrangular outline of the component particles, their dark central part and bright margin, and their lines of junction, crossing the light intervals. *b*. A longitudinal segment of a fibre consisting of a number of fibrils still connected together. The dark cross stripes and light intervals on *b* are obviously occasioned by the dark specks and intervening light spaces respectively corresponding in the different fibrils. *c*. Other smaller collections of fibrillæ. From a preparation by Mr. Lealand.

*Filaments or fibrillæ*.—Lines and fissures are sometimes seen running lengthwise in the substance of the fibres, and indicating their fibrillar structure, as in those represented in fig. 159; and when these longitudinal lines are well marked, the transverse striæ are comparatively indistinct. In a thin transverse section the ends of the fibrillæ may be seen, when highly magnified, as small dots or points, which occupy the whole sectional area of the fibre, showing plainly that the latter is not hollow, as has sometimes been maintained, but possesses the same fibrillar structure throughout its whole thickness. The fibrils may be partially separated and spread out by breaking across a fibre, and gently bruising the broken end, as at *c*, fig. 158, or by splitting up its substance with fine needles. But it is no easy matter to insulate a single fibril; and to succeed in this, a perfectly fresh and favourable specimen, as well as nice manipulation, is required. When a fibril thus completely insulated is highly magnified, it is seen to consist of a single row of minute particles, connected together like a string of beads. These particles (named "sarcous elements" by Bowman), when viewed with a magnifying power of 400 or 600, appear like little dark quadrangular and generally rectangular bodies, with bright

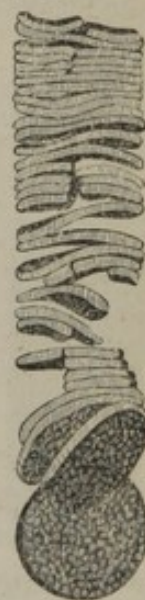[\* Called "myolemma," by Wilson.]



intervals between them, as if they were connected together by some pellucid substance, *a*, fig. 161; but on closer examination, provided the defining power of the instrument is good, a very faint dark line or shadow will be discovered passing across the fibril in the middle of each of the bright spaces, and sometimes also a bright border may be perceived on either side of the fibril, so that each of the rectangular dark bodies appears then to be surrounded with a bright area having a similar quadrangular outline, as represented in the figure, and it may therefore be inferred that the pellucid substance incloses it on all sides. In short, it would seem that the elementary particles of which the fibril is made up, are little masses of pellucid substance, presenting a rectangular outline, and appearing dark in the centre. Their appearance, indeed, suggests the notion of minute vesicular bodies or cells, cohering in a linear series, the faint transverse marks between being the lines of junction. But although this idea very naturally presents itself, we must not assume that the reality of it is established. With a still higher magnifying power, the dark central part appears constricted in the middle, or looks as if it consisted of two portions joined together. When the focus is altered, the internal dark part becomes light; it is therefore evidently transparent, and its dark aspect is probably owing to its refracting the light differently from the surrounding substance.\* Minute pellucid objects indeed exhibit, when highly magnified, a dark centre surrounded by a bright halo, if viewed a little within the true focal distance; but the bright circumference of the muscular particles seems to be something more than can be accounted for in this way.

When the fibrillæ lie undisturbed in the fibre, the elementary particles of collateral fibrils are situated in the same transverse plane, and it is to this lateral coaptation of the particles that the transverse striping of the fibre is due. (See *b*, fig. 161.) Accordingly, the cross lines are not confined to the surface of the fibre, but may be seen throughout its entire thickness on successively deepening the focus of the microscope. The fibres moreover often show a tendency to cleave across in the direction of these lines, and even to break up into transverse plates or disks, [fig. 162,] which are formed by the lateral cohesion of the particles of adjacent fibrils. To make up such a disk, therefore, every fibril contributes a particle, which separates from those of its own fibril, but coheres with

[Fig. 162.]



Represents a muscular fibre, highly magnified, of Triton dorsalis, with its sarcolemma removed, and its sarcous substance broken up into disks.—From nature, by J. L., 1847.]

\* Various observers, from the time of Hooke, in the seventeenth century till the present day, have recognised a beaded structure in the muscular filaments. Muys, who however considered the beaded appearance as only occasional, and seems to have been a good deal perplexed by it, represents the particles as rectangular. *Invest. Fabricæ quæ in part. musc. comp. extat. Lugd. Bat. 1741. Tab. i. fig. 17.* Their quadrangular outline was fully and clearly shown by Mr. Bowman. The faint lines passing across the light intervals between the dark particles, as well as the surrounding bright areas, were, as far as I know, first pointed out by Mr. Lealand, a skilful optician in this city. The figure (161) was drawn by my friend, Mr. J. Marshall, from a specimen prepared by Mr. L.



its neighbours on either side, and this with perfect regularity. Indeed, Mr. Bowman conceives that the subdivision of a fibre into fibrillæ is merely a phenomenon of the same kind, only of more common occurrence, the cleavage in the latter case taking place longitudinally in place of transversely: accordingly, he considers that the fibrillæ have no existence as such in the fibre, any more than the disks; but that both the one and the other owe their origin to the regular arrangement of the particles of the fibre longitudinally and transversely, whereby, on the application of violence, it cleaves in the one or in the other direction into regular segments.

[I also entertain the same opinion as Mr. Bowman in regard to the division of the sarcous substance contained within the muscular fibres. The particles adhere to each other with greater tenacity in the direc-

[Fig. 163.



The upper figure represents a portion of a human muscular fibre, highly magnified, which has undergone maceration in water a few days; putrefaction has commenced, and the transverse stripes are disappearing.

The lower figure represents a portion of the same, in which putrefaction has farther advanced. The myolemma is exhibited with the broken up sarcous matter within it.—From nature, by J. L.]

tion of the length of the fibres than laterally in the living muscle and in the fresh dead muscle, which will permit its being torn into fibrillæ in preference to being torn in any other direction. The fibrillæ vary considerably in their diameter, apparently depending upon the skill of the operator in separating this delicate structure; for I have frequently observed fibrillæ torn a short distance through their length into two or more divisions, each presenting as much integrity as the part of the fibrillæ exhibiting no trace of division. Of course, when we arrive at the ultimate sarcous particles, the power of separating the fibrillæ will cease. But when the muscular fibre has been macerated a short time in water, or in weak alcohol, or solution of certain salts, especially in the reptiles, fishes, and insects, the tenacity of cohesion of the particles of the sarcous substance appears to be weakened in the direction of the length of the fibres, and they adhere with a greater degree of firmness laterally, and hence they separate into disks.—J. L.]

The length of the elementary particles is of course measured by finding the number of cross lines in a given space; it is thus estimated by Mr. Bowman at  $\frac{1}{9400}$ th of an inch, while their transverse diameter is less, often by one half,—at least in specimens which have not been altered by contraction: he finds that their size is remarkably uniform in mammalia, birds, reptiles, fishes, and insects.

[When a portion of muscle is macerated in water until putrefaction commences, the sarcous substance of the fibres is broken up into its ultimate particles. The cross-striped appearance first and gradually disappears; and as the sarcolemma resists change much longer, it is readily detected as a delicate tube of homogeneous membrane filled with the detached sarcous particles (fig. 163).—J. L.]

A number of flat, oval corpuscles, resembling cell-nuclei, are scattered among the fibrillæ in the substance of the fibres. These have been supposed to be connected with the growth and nutrition of the muscle.



They are obvious in the foetus some time before birth, but afterwards the addition of acetic acid is required in order to render them visible.

[From my own observations, the nuclei of the muscular fibres have always appeared to be connected with the sarcolemma, instead of being imbedded in the sarcous substance. They are always elongated in the direction of the length of the fibre,—are frequently very numerous, as represented in fig. 164, which was taken from a fibre from the biceps flexor of the arm, and are granular in structure, (fig. 165.)—J. L.]

*Connexion with tendons.*—The precise mode in which the extremities of the muscular fibres are connected with the tendinous tissue is still somewhat doubtful. It has been maintained that their ends are rounded off or gradually taper to a point, and are received into the centre of a bundle of tendinous filaments. Mr. Bowman states that he has not been able satisfactorily to find out what is the arrangement in mammalia or birds; but in some animals lower in the scale, he has observed two modes of connexion. In the one case, the extremity of the muscular fibre is abruptly truncated, or terminates with a perfect disk, and the little bundle of tendinous filaments spread out and fix themselves over the whole surface of this disk, and, in a small extent also, to the sarcolemma, which ceases abruptly at the circumference of the terminal disk.

This kind of connexion may be seen in fishes and insects. In the other mode, which occurs when the muscle is attached obliquely to a membranous surface, and which may be observed in the limbs of the crustacea, the fibre is truncated obliquely at its end, and more or less acutely, according to the angle which the fibres make with the surface of attachment.

[Although it is undoubtedly the case that in insects, &c., the muscular fibres are abruptly truncated at their extremities, as I have also frequently observed, yet in man, especially in the foetal state, I have several times distinctly seen the extremities of the muscular fibres, and also the fasciculi, terminate in a rounded manner.

The filaments of areolar tissue, which form the sheaths of the muscular fasciculi, for the most part pass in a diagonally crossing manner around the fasciculi, occasionally passing in between the fibres, and intermingling with some fine filaments of elastic tissue which are found in this situation. The sheaths are also connected together by filaments from them, having the same diagonally crossing course.

At the extremities of the muscular fasciculi, the filaments of the areolar sheaths become more or less straight, and combine with the fibrous filaments originating in this position, to form the tendinous connexion of the muscle.\*—J. L.]

[Fig. 164.



Fig. 165.

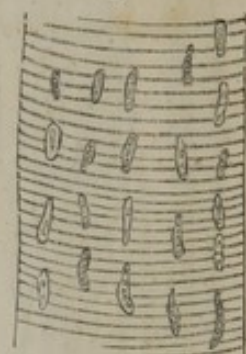


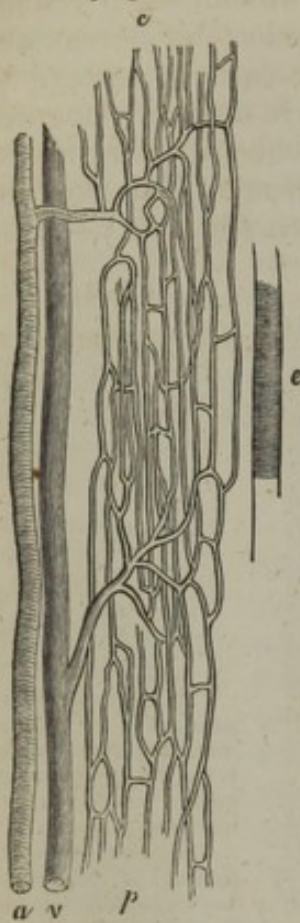
Fig. 164 represents a portion of a human muscular fibre, treated with acetic acid, and highly magnified, exhibiting its nuclei.

Fig. 165 represents a portion of the same, and treated by the same menstruum, much more highly magnified, so as to exhibit the granular structure of the nuclei.—From nature, by J. L., 1847.]

\* [Proceedings of the Academy of Natural Sciences of Philadelphia, vol. iv., No. 6, 1848.]



[Fig. 166.



Capillaries of a small fasciculus of muscular fibres from the neck of the dog:—*a*. Terminal twig of the artery. *v*. Terminal twig of the vein. *p*. Plexus of capillaries. *e*. Elementary fibre, to show the relative size and direction of those to which the capillaries, here represented, are distributed.—Todd and Bowman.]

it is found that when the fibres are small, the vessels are numerous and form a close network, and *vice versa*: in other words, the smaller the fibres, the greater is the quantity of blood supplied to the same bulk of muscle, or to the same amount of elementary muscular particles; for, amidst the variations which the fibre presents in different animals, the size of its minuter elements remains wonderfully constant. In conformity with this, we see that in birds and mammalia, in which the process of nutrition is active, and where the rapid change requires a copious supply of material, the muscular fibres are much smaller and the vessels more numerous than in cold-blooded animals, in which the opposite conditions prevail.

**Nerves.**—The nerves of a voluntary muscle are of considerable size. Their branches pass between the fasciculi, and in their progress repeatedly unite with each other in form of a plexus, the finer branches of which may be seen running between the smallest order of fasciculi, often in company with blood-vessels; at last the nervous plexus is reduced into minute bundles consisting of two or three primitive tubules each, some of them separating into single tubules. (Fig. 167.) By

**Blood-vessels.**—The blood-vessels of the muscular tissue are extremely abundant, so that, when they are successfully filled with coloured injection, the fleshy part of the muscle contrasts strongly with its tendons. The arteries, accompanied by their associate veins, enter the muscle at various points, and divide into branches; these pass among the fasciculi, crossing over them, and dividing more and more as they get between the finer divisions of the muscle; at length, penetrating the smallest fasciculi, they end in capillary vessels which run between the fibres. The vessels are supported in their progress by the subdivisions of the cellular sheath of the muscle, to which also they supply capillaries. The capillaries destined for the proper tissue of the muscle, (fig. 166,) form among the fibres a fine network, with narrow oblong meshes, which are stretched out in the direction of the fibres: in other words, they consist of longitudinal and transverse vessels, the former running parallel with the muscular fibres, and lying in the angular intervals between them,—the latter, which are much shorter, crossing between the longitudinal ones, and passing over or under the intervening fibres.



means of the microscope these fine nervous bundles and single tubules may be observed to pass between the muscular fibres, and after a longer or shorter course, to return to the plexus. They cross the direction of the muscular fibres directly or obliquely, forming wide arches; and on their return they either rejoin the larger nervous bundles from which they set out, or enter other divisions of the plexus. The nervous filaments, therefore, do not come to an end in the muscle, but form loops or slings among its fibres. The tubules of the nerves never penetrate the sarcolemma or sheath of the fibre; in this respect they resemble the capillary vessels, but they do not accompany the capillaries, being not only much less numerous, but distributed after a different fashion.

[Fig. 167.




Fig. 168.

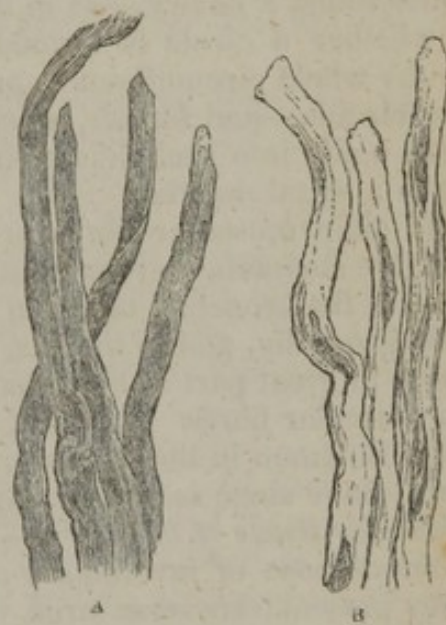


Fig. 167. Loop-like termination of the nerves in voluntary muscle.—After Burdach.—Todd and Bowman.]

Fig. 168. Plain muscular fibres from the human bladder, magnified 250 diameters. A, in their natural state; B, treated with acetic acid to show the nuclei.

*Involuntary muscles.*—The involuntary muscular tissue differs from the voluntary kind, not only in its want of subjection to the will, but also in its structure. The most remarkable difference is observed in the aspect and structure of the fibres which, except in the heart and a few instances of less note, are unmarked by the cross lines so characteristic of the striped fibre. These plain or unstriped fibres (fig. 168) are generally of a pale colour; their figure is for the most part flattened, though sometimes it might be rather said to be prismatic, and their diameter is from  $\frac{1}{2000}$ th to  $\frac{1}{3000}$ th of an inch. Under the microscope they have a peculiar soft aspect, without a strongly shaded border; and they are marked at short intervals with oblong corpuscles or nuclei, which give them a very characteristic appearance, especially after the application of acetic acid, which renders the corpuscles much more conspicuous. The substance of the fibres is translucent, but



clouded or even finely granular; and in the latter case the granules are sometimes arranged in longitudinal lines. Mr. Bowman considers this last-mentioned appearance as indicative of an approximation towards the structure of the striped fibre, for he has observed the granules to be about the size of the elementary particles of voluntary muscle already described.\* It is doubtful whether they have a sarcolemma or special sheath.

The plain fibres are for the most part disposed between the coats of the membranous viscera, as the stomach, intestines, and bladder, in the parietes of the air tubes, excretory ducts of glands, and the like. They are generally collected into larger and smaller fasciculi, in which they run parallel with each other, but the fasciculi in many cases cross one another and interlace. It is not known how the fibres are fixed at their extremities; and when they are disposed in a circular manner round a cavity,—as in the intestine, for example,—it is uncertain whether a circle is formed by two or three fibres, each shorter than the whole circumference, or whether a single fibre performs the entire circuit,—and further, whether on the latter supposition the fibre returns again into itself like a ring, or is continued round more than once in a spiral manner.

The plain muscular fibres are met with in the lower half of the gullet, the stomach, and the whole intestinal canal, in the bladder and uterus, in the bronchial tubes, in the ureters and the ducts of the larger glands generally, and in the iris. The middle coat of the arteries also consists in great part of fibres having the anatomical characters of the plain muscular fibres. Fibres of the same kind have also been detected by Mr. Bowman in the dartos or subcutaneous tissue of the scrotum, where I have since seen them myself.

*Muscular tissue of the heart.*—The fibres of the heart differ remarkably from those of involuntary muscular organs in general, inasmuch as they present transverse striæ. The striæ, however, are less strongly marked, and less regular, and the fibres are smaller in diameter than in the voluntary muscles. Many of the fibres are attached to the tendinous structure connected with the orifices and valves. The tissue of the heart differs also from most other involuntary muscular structures by its deep colour, but it agrees with them in the interlacement of the fasciculi, and in the small amount of cellular texture intermixed with the fibres.

*Chemical composition of muscle.*—The chief as well as the characteristic constituent of the muscular tissue is fibrin, of which the nature and properties have already been stated. There can be little doubt that this animal principle is the essential constituent of the muscular fibre; but it must be remembered that a piece of muscle subjected to analysis comprehends along with the proper muscular fibres a certain amount of cellular texture, bloodvessels, and nerves; moreover that the blood cannot be entirely extracted from its small vessels, and that more or less serum (an albuminous fluid) remains in its moist tissue. Accordingly, other ingredients besides fibrin, though in smaller propor-

\* Cyclopaedia of Anat. vol. ii. p. 514.



tion, present themselves in the analysis, and are ascribed to the presence of the accessory substances just mentioned. In 100 parts of fresh voluntary muscle of the ox, Berzelius found

Fibrin, . . . . .	15.8
Gelatin, . . . . .	1.9
Albumen, with colouring matter, . . . . .	2.2
Alcoholic extractive, with salts, . . . . .	1.8
Watery extractive, with salts, . . . . .	1.05
Phosphate of lime, with albumen, . . . . .	0.08
Water and loss, . . . . .	77.17
	<hr/>
	100.

Braconnot obtained similar results from an analysis of the tissue of the heart, and through the researches of different experimenters, essentially the same chemical constitution has been discovered in the fibres of the iris, in the uterus, in the muscular coat of the intestine, and in that of the gall bladder and gall ducts of the ox and ureter of the horse, also in the hypertrophied muscular coat of the human ureter.


*Physical properties.*—A dead muscle possesses little strength, and may be lacerated by a force of no great amount. Although it has but little elasticity, the muscular tissue is nevertheless capable of being slowly stretched out in the living body, and will afterwards return to its original state, as happens from the growth of tumours, the accumulation and subsequent removal of dropsical waters, the enlargement and subsidence of the uterus, and such like causes. The red colour of muscle is well known, but it differs greatly in degree in different cases. It is usually paler in the involuntary muscles; but here the heart again is a striking exception. In fish the chief muscles of the body are nearly colourless, and in the breast of wild fowl we see a difference in the depth of colour in different strata of the same muscles. The redness is no doubt partly due to blood contained in the vessels, but not entirely so, for a red colouring matter, apparently of the same nature as that of the blood is obviously incorporated with the fibres.

*Development of muscle.*—From the researches of Valentin and Schwann, (fig. 169) it appears that the muscular fibres are derived from nucleated cells, which coalesce together in rows, and undergo other changes. Nuclei are first formed in a soft blastema; these are arranged in linear series and become surrounded with delicate envelopes, so as to form a string of cohering cells (<sup>1</sup>). The cells contain, besides the nuclei, a few detached round granules. By absorption of their adhering parts, the cells coalesce into a tube; and within the tube so produced, the fibrillæ begin to be formed, by deposition and linear arrangement of their elementary particles on its inner surface. The formation of fibrils goes on until they fill up the tube, which after this, according to Schwann, becomes the sarcolemma; but the last-mentioned point is doubtful, and some consider that the sarcolemma is a subsequent formation. The nuclei remain for a time in the axis of the growing fibre,—a condition which is persistent in the muscles of insects; but in higher animals they become dispersed among the fibrils, and increased in number, for those seen in the perfect fibre are more numerous than can be accounted for merely by the persistence of the original cell nuclei.



The above account of the manner in which the muscular fibres are produced is no doubt to a certain extent correct. I have seen growing fibres from the fœtal sheep, which were in the condition represented by Schwann, in fig. 169,<sup>2</sup> only the granules within were somewhat regularly disposed in transverse lines between the nuclei. But much still remains to be explained by future investigation.

Fig. 169.



Development of muscular fibre, after Schwann. 1, 2, 3, are fibres from the dorsal muscles of a fœtal pig,  $3\frac{1}{2}$  inches long. 3, represents the fibre (2) after the action of acetic acid. 4, 5, 6, are fibres from the muscles about the humerus of a fœtal pig five inches long. 5, shows the nuclei attached to the wall of the tube; in 4 and 6 is also seen the gradual deposition of the substance from which the fibrillæ are formed on the inner surface of the tubular fibre (magnified about 450 diameters).

The fibres are at first smaller than at subsequent periods, as has been noticed by Leeuwenhoek and most succeeding observers. In the embryo frog, at the earliest period that I could detect a muscular structure, the fibres seemed almost to consist of single fibrillæ, connected with remnants of coalesced and apparently flattened cells and nuclei; at a later stage the number of fibrillæ in the fibres had increased, and the fibres were of course thicker. Prevost and Lebert state that in the frog's embryo the fibrillæ (*cylindres primitifs*) are formed out of cells which lengthen into narrow tubuli, and contain globular particles ranged in moniliform lines.\*

Henlé has suggested that the nucleated cells may first coalesce to form an axis, round which the fibrillæ are deposited from without,—and that the sarcolemma is then formed on the surface of the fibre, whilst the axis disappears from its centre.

It is well known that the muscular system, after acquiring its full development, is subject to frequent variations of bulk in the progress of life, and it still remains a question whether in such cases the number of the muscular fibres is increased by new formation and diminished by absorption, or whether the variation of the whole muscle is due to an increase or diminution of the bulk of the individual fibres while their number remains unaltered.

As far as can be concluded from observations and experiments that have hitherto been made on the subject, the muscular tissue is not regenerated in warm-blooded animals. It is true that when a portion of muscle is cut out the breach will heal, but the loss of substance is not repaired by new-formed muscular tissue.

*Vital properties of Muscle.*—The muscular tissue possesses a considerable degree of *sensibility*, but its characteristic vital endowment, as already said, is its *irritability* or *contractility*, by which it serves as a moving agent in the animal body.

*Sensibility.*—This property is manifested by the pain which is felt when a muscle is cut, lacerated, or otherwise violently injured, or when it is seized with spasm. Here, as in other instances, the sensibility, properly speaking, belongs to the nerves which are distributed through the tissue, and accordingly when the nerves going to a muscle are cut, it forthwith becomes insensible. It is by means of this property, which is sometimes called the “muscular sense,” that

\* *Annales des Sc. Nat.* 1844.



we become conscious of the existing state of the muscles which are subject to the will, or rather of the condition of the limbs and other parts which are moved through means of the voluntary muscles, and we are thereby guided in directing our voluntary movements towards the end in view. Accordingly, when this muscular sense is lost, while the power of motion remains,—a case which, though rare, yet sometimes occurs,—the person cannot direct the movements of the affected limbs without the guidance of the eye.

*Irritability or Contractility.*—The merit of distinguishing this property of the animal body from sensibility on the one hand and from mere mechanical phenomena on the other, is due to Dr. Francis Glisson, a celebrated English physician of the seventeenth century; but irritability, according to the view which he took of it, was supposed to give rise to various other phenomena in the animal economy, besides the visible contraction of muscle, and his comprehensive acceptance of the term has been adopted by many succeeding authorities, especially by writers on pathology. Haller, in his use of the term irritability, restricted it to the peculiar property of muscle.

In order to cause contraction, the muscle must be excited by a stimulus. The stimulus may be applied immediately to the muscular tissue, as when the fibres are irritated with a sharp point; or it may be applied to the nerve or nerves which belong to the muscle; in the former case, the stimulus is said to be “immediate,” in the latter, “remote.” The nerve does not contract, but it has the property, when stimulated, of exciting contractions in the muscular fibres to which it is distributed, and this property, named the “vis nervosa,” is distinguished from contractility, which is confined to the muscle. Again, a stimulus may be either directly applied to the nerve of the muscle, as when that nerve is itself mechanically irritated or galvanised; or it may be first made to act on certain other nerves, by which its influence is, so to speak, conducted in the first instance to the brain or spinal cord (or perhaps even to some subordinate nervous centre) and then transferred or reflected to the muscular nerve.

The stimuli to which muscles are obedient are of various kinds; those best ascertained are the following, viz., 1. Mechanical irritation of almost any sort, under which head is to be included sudden extension of the muscular fibres. 2. Chemical stimuli, as by the application of salt or acrid substances. 3. Electrical; usually by means of a galvanic current made to pass through the muscular fibres or along a certain length, however short, of the nerve: the effect taking place on closing or on breaking the circuit. 4. Sudden heat or cold; these four may be classed together as *physical stimuli*. Next, *mental stimuli*, viz. 1. The operation of the will, or volition. 2. Emotions, and some other involuntary states of the mind. Lastly, there still remain exciting causes of muscular motions in the economy, which, although they may probably turn out to be physical, are as yet of doubtful nature, and these until better known may perhaps without impropriety be called *organic stimuli*; to this head may be also referred, at least provisionally, some of the stimuli which excite convulsions and other involuntary motions which occur in disease.

All muscles are not indifferently obedient to the same stimuli. The difference in their subjection to the will has been already mentioned, and there are other cases, though of less note, in which they differ either in their capability of being excited by a certain kind of stimulus, or in the readiness with which they are affected by it. Thus, for example, it would seem that the contractile fibres of the dartos are not excitable by electricity, though they are readily called into action by mechanical irritation, by cold, and by some other stimuli indirectly applied.\*

*Phenomena of muscular contraction.*—A muscle when in action is shortened, or exhibits a tendency to shorten; at the same time it swells in the middle and becomes firm and rigid to the feel. This condition, after continuing for a longer or shorter time, is succeeded by relaxation. Careful experiments have proved that the muscle undergoes no change of volume during its action, the shrinking in one direction being compensated by the enlargement in another.

\* Jordan in Möller's Archiv. 1834. From some experiments recently made under the direction of Professor Simpson, of Edinburgh, there seems reason to infer that the motions of the human uterus are not affected by electricity.



The fibres of a muscle which has been called into action, exhibit in certain circumstances a series of zigzag bendings, and from this appearance, which was noticed by Dr. Hales, and more recently by Prevost and Dumas, it was inferred that the shortening of the muscle was owing to its fibres assuming such serpentine flexures, in which condition of course their extremities are more approximated. But from a more careful investigation of this phenomenon there is reason to believe that the bent condition of the fibre is not coincident with its actual contraction. In the act of contracting, the fibre becomes shorter and thicker, but does not fall out of the straight line; on being subsequently relaxed, however, it is thrown into serpentine plicæ, and remains so until its extremities, which had been brought nearer by contraction, are drawn out again by some stretching force. Moreover, it may readily happen that fibres which are not in action may be corrugated by the contraction of others running along with them, and this is probably the most common cause of the zigzag plicæ.

During contraction the individual fibres are thickened or swollen out at short intervals, and with a high power of the microscope it may be seen that in the swollen parts the transverse lines characteristic of the striped fibre are approximated, whilst in the intermediate narrower portions they are more than the mean distance apart. The commencement and progress of this change has been carefully studied by Mr. Bowman, on detached muscular fibres of the crustacea. According to his observations, the approximation of the striæ and the simultaneous swelling, begin at isolated points along the fibre; at first not affecting its whole diameter, but being confined to one side and causing a series of bulgings on the margin. From its point of commencement the contraction spreads into the fibre equally in all directions, its progress not conforming to the arrangement either of the fibrillæ or the transverse stripes; and accordingly the latter may be closely approximated on one side of the fibre, while on the other side they are at their usual distance. Between the contracting points the fibres are narrower, and its cross striæ further apart. These contractions, however, do not remain stationary, but travel along the fibre; and parts which are shortened and swollen at one moment, become lengthened and narrowed the next, being drawn out by contraction of the neighbouring portions,—unless, indeed, the ends of the fibres are free and offer no resistance to their approximation; for in that case the contraction advancing to a fresh portion, merely causes a further approach of the ends, and for want of a fixed resistance cannot draw out the parts previously contracted. The contractions continuing to oscillate along the fibre from end to end, gradually involve its whole thickness; they increase in number and extent, and the ends of the fibre if free to move are drawn nearer and nearer, until at last it is greatly reduced in length, its motions cease, and it remains in that state of rigidity which affects all muscles sooner or later after death.

It thus appears that in the movements of detached portions of muscle, a multitude of partial contractions oscillate to and fro along each fibre, and from the appearances presented by muscular fibres which have been ruptured by tetanic spasm, Mr. Bowman is led to infer that the ordinary contraction of muscles in the living body takes place in this way. He concludes that "the sustained active contraction of a muscle is an act compounded of an infinite number of partial and momentary contractions, incessantly changing their place, and engaging new portions in succession."

This view strikingly accords with the fact that a remarkable sound is heard when the ear is applied over a muscle during its action. This "muscular sound," which was compared by Dr. Wollaston to the distant noise of carriage-wheels, has a thrilling or vibratory character, and may with great probability be ascribed to the friction of the oscillating fibres against each other. Indeed, Roger, who first seems to have specially called attention to the phenomenon, and at a later period, Dr. Wollaston, were led by it to form conclusions respecting the state of the contracting fibres agreeing very nearly with what Mr. Bowman has since proved by actual inspection. Dr. Wollaston inferred that the sustained effort exerted by a muscle contracting by the impulse of the will, consists in reality of a great number of contractions repeated at extremely short intervals, and excited by a succession of distinct impulses; and Roger supposed that the "susurrus," as he names the sound, was caused by a sort of peristaltic



motion of the fibrils.\* Again, it has been found by Breschet and Becquerel that a rise of temperature takes place in a muscle during its contraction, which may amount to one or two degrees of Fahrenheit's scale, and it seems most likely that the evolution of heat is due to the mutual friction of the fibres alluded to.

It remains to notice another important phenomenon which accompanies muscular contraction, namely, the development of electricity or of some force analogous to electricity. This is shown by an experiment of Matteucci, which I have frequently repeated, and which is performed in the following manner. Detach the posterior limb of a frog, dissect out the sciatic nerve as far as the knee, leaving it connected with the leg, and cut away the thigh; then lay this nerve across the denuded muscles of the remaining thigh or of the thigh of another recently killed frog, insulated on a plate of glass, and excite contractions in the muscles of the thigh by mechanical or galvanic irritation of their nerves. Every time this is done, contractions simultaneously occur in the detached leg; these of course are caused by excitation of its nerve, and this excitation is produced either by electricity or by some analogous force developed during the contraction of the muscles on which the nerve is laid. Matteucci at first believed the force to be actually electrical, and the evidence appeared to be satisfactory; but he has since found that the influence passing from the muscle to the nerve differs from ordinary electricity in regard to the substances which conduct or which insulate it, and he therefore thinks it may be a force peculiar to muscle, which is analogous to, but not identical with, ordinary electricity: in this condition we must leave the question until his more recent researches (which he has communicated to the Royal Society) are published. A frog's nerve and muscles may be excited in the same manner by the contracting muscles of a warm-blooded animal. The force produced, whether electrical or not, might, according to the prevalent views of the chemical physiologists, be very naturally ascribed to some chemical change accompanying muscular contraction; but this view as to its source, can by no means be considered as actually established. Apart from this, however, there are independent grounds for believing that chemical changes are concerned in the waste of the tissue which attends or immediately follows muscular action; and a recent inquirer, Dr. Helmholtz, has endeavoured to show by direct experiment, not only the fact of a change, but its nature.†

Although the point is not immediately connected with the contraction of muscle, it may be here added that Matteucci has also shown the existence in living and in recently killed animals of an electric current directed from the interior of a muscle towards its surface,—at least, from the centre to the surface of the mass of muscles composing a limb. This current, which he names the muscular current, may be made manifest by means of a galvanometer, or by employing the prepared nerve and leg of a frog as an electroscope.‡

Much ingenious speculation has been bestowed in endeavouring to explain the immediate or proximate cause of muscular contraction, but on this point we really know nothing more than that the contraction depends on a disposition which the muscular substance has to shrink in a particular direction, when acted on by stimuli. From what has been said, we must also conclude that it is between the minutest and to us invisible molecules that this tendency to approximation is exerted: thus, the contraction spreads through a striped fibre without reference to the arrangement of its visible elements; it occurs in the plain fibres, which though they agree in their chemical nature, have a different visible structure from the striped variety; and the embryo heart contracts whilst its tissue is yet but a mass of cells, without apparent fibres. It is plain, therefore, that any hypothesis or explanation which assumes the visible mechanical construction of a muscular fibre as a necessary condition of the contraction of its substance, must

\* Josephi Lud. Roger, *De perpetua fibrarum muscularium palpitazione, &c.* Gottingae, 1760. Roger supposed that the oscillation of the fibrils and accompanying sound are constant, but that they are greatly increased during contraction of the muscle. See also recent observations by Remak, on the oscillatory contractions of muscular fibres after death, in *Müller's Archiv.* 1843, p. 182.

† *Müller's Archiv.* 1845, p. 72. He finds that the watery extractive is diminished, while the spirituous and alcoholic extractive matters are increased.

‡ Matteucci, *Phénomènes électro-physiologiques des animaux*, 1844.



fall to the ground. We may further remark, that although in the higher animals the contractile substance is fashioned into fibres, more or less complex in structure, we can nevertheless conceive it to retain its peculiar property, though reduced to smaller masses, and existing under different forms; and it is with this understanding as to the nature of the material endowed with vital contractility, that we ascribe the motion of cilia to that property.

It has been keenly disputed since the days of Haller, whether the contractility of muscle is a property inherent in its substance,—a “*vis insita*,” as Haller believed,—or is derived from the nerves, and, as it were, conferred by them on the muscular fibre. To discuss at length the arguments of this controversy, would here obviously be out of place; I shall therefore only remark that the former view is the more simple, and is that to which we are naturally led on reflecting that muscle is of a different substance from nerve,—that wherever muscle is found, it manifests the contractile property,—and that, on the other hand, a nerve is never seen to contract in any circumstances. Nor is the straightforward view originally adopted by Haller in any way shaken by the experimental inquiries that have been instituted in order to determine the question,—that is, when the conditions of these experiments are duly attended to, and their results fairly appreciated. But, admitting that irritability is not *derived* from the nervous system, it has been held by some that this property can be *excited* only through the medium of the nerves, and that a stimulus apparently applied to the muscular fibres really acts on the fine nervous filaments intermixed with them; others again, think as Haller did, that although for obvious reasons muscles are generally, and in voluntary acts always stimulated through the intervention of the nerves, yet that stimuli may also act directly on the muscular fibre. The correctness of the latter opinion can scarcely now be doubted, since, in addition to what has been hitherto urged in its favour, we have now what may be considered as direct experimental evidence of its truth; for Mr. Bowman has observed, by means of the microscope, that contractions take place in small insulated fragments of muscular fibre, entirely free from nerves,—and further, that a minute foreign body, such as a hair or a particle of dust, when it touches a fibre, will cause a contraction which begins at the point of contact and is limited to its immediate vicinity, so as to show plainly that it is caused by the mechanical irritation of the particle acting directly on the fibre.

Forcible and prolonged action of the voluntary muscles is followed by a sense of fatigue, and the immediate effect of muscular contraction is to exhaust irritability. But this is recovered again by repose; and the exercise of muscles, provided it alternates with due intervals of rest, tends to maintain their power and promote their nutrition and growth. Indeed, we see examples, in some cases, of an overgrowth or hypertrophy of the muscular tissue from increased demands on its activity; as in the instance of the parietes of the heart and urinary bladder, when an impediment has long existed to the free issue of the fluids which these muscular organs are called on to propel. On the other hand the muscles become wasted, and their functional activity is impaired by disuse.

*Tonicity or tonic contraction.*—Although we say that contraction of a muscle is succeeded by relaxation, it must not be supposed that during the intervals of repose the muscle is inert and flaccid. On the contrary, it is still in a state of tension, and has still a certain tendency to approximate its points of attachment, although this tendency is counterbalanced by antagonist muscles, which are in the same condition, and the limb or other movable part is thus maintained at rest. This condition of muscles is named “*tonicity*,” or “*the tonic state*.” It is no doubt a species of contraction, as well as the more conspicuous and powerful action with which it alternates; but it is employed merely to maintain equilibrium, not to cause motion, and it is not temporary but enduring,—continuing during sleep, when volition is in abeyance, and occasioning no fatigue. It appears to be excited through the medium of the nerves, though independently of the will, for when the nerves are cut it ceases, and then the muscles really become flaccid: the stimulus which acts on the nerves is not known. The condition of the muscular fibres in this tonic state has scarcely yet been ascertained with certainty, but Mr. Bowman is disposed to think from observations he has made, that the cross striæ are approximated uniformly throughout the whole length of



the fibre. Roger, as already stated, believed that the fibres continue to oscillate, though with less intensity, than at the time of contraction.

*Force of contraction.*—It has been shown by Schwann, that the force exerted by a contracting muscle follows the same law as that produced by the shrinking of a stretched elastic substance; that it is greatest at the commencement of contraction, and diminishes as the muscle shortens, becoming equal to nothing when the muscle has contracted to its utmost degree. From the nature of their connexions in the living body, however, the muscles—at least, those of locomotion—are not permitted to shorten to their extreme point of contraction; it is estimated that the shortening seldom amounts to more than a third of their length, but it may go greatly beyond this when they are freed from their attachments. Other things being equal, the force exerted will be proportionate to the number of contracting fibres, and therefore greater in a thicker muscle. But the force varies with the state of nutrition of the muscle, with its previous vigour or exhaustion, and also according to the intensity of the stimulus applied to it. The last-mentioned circumstance is indeed one of the most wonderful provisions in the constitution of our frame, for by an effort of the will, we can not only call a muscle into exercise, but within certain limits regulate with the utmost nicety the force exerted by it. In the last place we may remark, that the force which a living muscle is able to exert, is much greater than that which the same muscle is able mechanically to sustain after death; a dead muscle, indeed, is torn across by a very moderate force.

*Velocity and order of contractions.*—Contraction for the most part takes place with considerable velocity, but there are differences in this respect; we see examples of extreme rapidity in the motion of the eyelids, and of slowness in the comparatively sluggish contractions of the alimentary canal and bladder. In some involuntary muscles the contraction varies also in other characters. In the muscular coats of certain hollow viscera, such as the alimentary canal, it travels along, so to speak, narrowing different parts of the cavity in succession; this is named "peristaltic," or "vermicular" contraction. In the heart the contraction is continually and regularly repeated after short and equal intervals of repose, and this is termed "rhythmic" contraction.

*Conditions necessary to muscular action.*—The necessity of a stimulus to the muscular fibre has been already mentioned. To this must be added a certain limit of temperature and the due nutrition of the muscle, both of which conditions have greater influence in warm-blooded animals. It is known that if the supply of nutrient material be cut off from a muscle by arresting the flow of blood into it, its contractility will be impaired, and soon extinguished altogether, but will, after a time, be recovered again if the supply of blood be restored. This experiment has been often repeated on dogs since the time of Stenon, to whom its first performance is generally ascribed, and the same effect, though less speedy and less marked, has been shown to result in cold-blooded animals, by recent experiments of Engelhardt and Valentin.\* In warm-blooded animals in which the nutritive process is more active, and the expenditure of force more rapid, the maintenance of irritability is more closely dependent on the supply of blood and the influence of oxygen, so that it sooner fails after these are cut off.

*Duration of irritability after death.*—In accordance with what has just been stated, it is known that while the muscles of man and quadrupeds all cease to be irritable within a few hours after death, and those of birds still sooner, the muscular irritability will remain in many reptiles and fish, even for days after the extinction of sensation and volition, and the final cessation of the respiration and circulation,—that is, after systemic death. A difference of the same kind is observed among warm-blooded animals in different conditions; thus, irritability endures longer in new-born animals than in those which have enjoyed respiration for some time and are more dependent on that function; and in like manner it is very lasting in hibernating animals during their winter sleep.

But the duration of this property differs also in different muscles of the same animal. From the researches of Nysten, it appears that in the human body its

\* Engelhardt, *De vitâ musculorum*, 1841, cited in Valentin's *Lehrbuch der Physiologie*, 1844. Band 2, p. 67.



extinction takes place in the following order, viz. 1, The left ventricle of the heart; 2, the intestines and stomach; 3, the urinary bladder; 4, the right ventricle: in these generally within an hour; 5, the gullet; 6, the iris; 7, the voluntary muscles, *a* of the trunk, *b*, of the lower, and *c*, the upper extremities; 8, the left auricle and, 9, the right auricle of the heart, which last was on this account styled by Galen the "*ultimum moriens*." In one case Nysten observed the right auricle to continue irritable for sixteen hours and a half after death.

The time of duration is affected by the mode of death. Thus the irritability is said to be almost wholly and immediately extinguished by a fatal stroke of lightning, and to disappear very speedily in the bodies of persons stifled by noxious vapours, such as carbonic acid, and especially sulphuretted hydrogen. In like manner certain causes acting locally on muscles, accelerate the extinction of their irritability; among these causes we may especially enumerate exposure to air, immersion of the muscle in cold water, and the application of watery solution of opium.

*Rigor mortis*.—The "*cadaveric rigidity*," or stiffness of the body, which ensues shortly after death, is a phenomenon depending on the muscles, which become fixed or set in a rigid state, so as to resist flexion of the joints. The rigidity almost invariably begins in the muscles of the lower jaw and neck, then invades those of the trunk, and afterwards those of the limbs,—the arms usually before the legs. After persisting for a time, it goes off in the same order. It usually comes on within a few hours after death; in some cases it has been observed to begin within ten minutes (Sommer), and in others not till sixteen or eighteen hours; and the later its access, the longer is its endurance. The rigidity comes on latest, attains its greatest intensity, and lasts longest in the bodies of robust persons, cut off by a rapidly fatal disease, or suddenly perishing by a violent death; in such cases it may last six or seven days. On the other hand it sets in speedily, is comparatively feeble, and soon goes off again in cases where the body has been much weakened and emaciated by lingering or exhausting diseases; also in new-born infants, and in the muscles of animals that have been hunted to death. It seems thus to be affected by the previous state of nutrition of the muscles. Destruction of the nervous centres does not prevent the occurrence of rigidity, nor are the muscles of paralysed limbs exempted from it, provided their nutrition has not been too deeply affected. The muscles in stiffening may cause a slight change in the position of the parts to which they are attached; thus the jaw is drawn up, the fore-arm and fingers slightly bent, and the thumb turned inwards on the palm.

The immediate cause of the muscular rigidity is doubtful: some conceive it to be an effect of vital contraction—the last effort of life as it were; some regard it as the result of coagulation of blood in the capillaries, which, however, does not seem a very probable cause; others ascribe it to an induration of the fibrin of the muscular tissue, like what occurs in the buffy coat of the blood; but, in truth, the nature of the change is not sufficiently understood. Its accession is an unequivocal sign of death.

Vital contractions, elicited by stimuli, occur in textures which have been supposed to contain no muscular fibres, and hence many physiologists have admitted the existence of a vital contractility, independent of muscle, which they have called "*non-muscular*," but in most of the tissues now in question, the presence of muscular fibres of the plain variety has been demonstrated; and this is notably the case as regards the dartos, which was looked upon as one of the best-marked examples of a non-muscular contractile texture. In this way the contractility in almost all those instances has been traced to muscular fibres. The small vessels, and the skin, it is true, still remain as exceptions; in both these cases the tissue possesses a low degree of vital contractility, which has not been unequivocally traced to a muscular structure of the ordinary kind; nevertheless, the point is not yet finally determined, and in regard to the skin, there seems much probability that its contractility will be eventually found to depend on plain muscular fibres, mixed up in greater or less numbers with the rest of the cutaneous tissue.



## MUSCLES.

---

THE muscles are divisible into a number of groups, which occupy different regions of the body, and combine in various ways for the performance of its actions. We shall in the first place name the individual muscles included in each group, then indicate the method of dissecting or exposing them to view; the detailed description of each shall follow, and the rationale of their actions conclude the section.

### EPICRANIAL REGION.

On the roof of the skull we find but one muscle, viz., the occipitofrontalis.

*Dissection.*—Care must be taken in making the first incisions to expose this muscle, particularly along the vertex; for the tegument is very thick, and at the same time firmly adherent to the thin aponeurosis of the muscle, which is by almost every beginner detached with the tegument: this is the more likely to happen, as the aponeurosis is lifted up from the bone in the effort made to render the tegument tense. The better plan, therefore, is to commence the dissection in such a way as to expose the fleshy fibres of the muscle; and then, taking these as a guide, to elevate the tegument from before and from behind upwards to the vertex from off the aponeurosis. Place a high block under the back of the neck, so as to raise the head nearly into the vertical position,—or, if the subject be turned prone, place the block under the chin. Make an incision across the forehead, about an inch above the upper margin of the orbit, and extending from the middle line outwards to the temple. Then a second incision may be carried from the inner termination of the one just indicated, upwards, over the middle of the forehead to the vertex; raise the skin at the angle formed by the junction of these

*NOTE.*—When proceeding with the dissection of a body, the examination of its upper and lower half is, for obvious reasons carried on at the same time by different persons. Begin the dissection of the upper half with the epicranial region, then take the auricular; observe the temporal fascia and muscle; then, without delay, open the skull, as the brain speedily decomposes, and proceed with the examination of its membranes, vessels, and internal structure (*see Brain, dissection of.*) When this is concluded, let the dissection of the different groups of muscles in the face, orbit, and neck, be continued in the order here set down. Do not pass over, or neglect, the brief directions given for the examination of each region.

Those to whom the lower half of the body is allotted, should commence with the abdominal muscles. These are confessedly of great importance; but still no time should be lost in inspecting them, as it is necessary, as soon as it can be effected, to proceed to the abdominal viscera. The perinæal muscles should in the next place engage attention, as they too become, in a short time, pale and flaccid. Then take the muscles of the lower extremity in the order in which they are here placed.

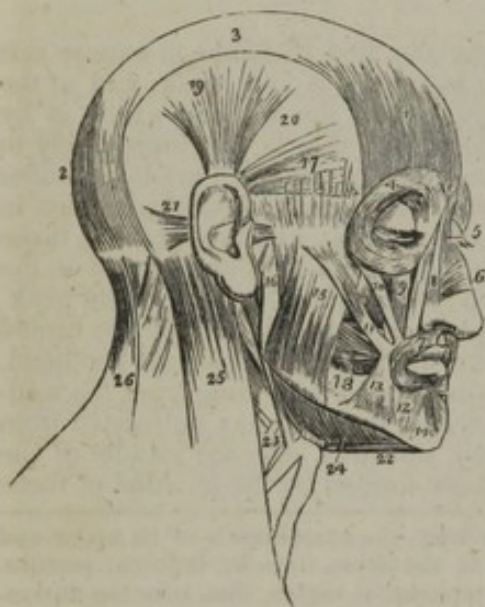If a student in his first essay at dissection has proceeded in this way, the author would suggest to him, to begin the second (its upper half) with the muscles of the back, which are usually left untouched till they are unfit for any purpose. As to the lower half, let that commence, for the like reason, with the gluteal and posterior femoral regions.

The remarks on the actions of muscles had better be passed over by junior students, until they become accurately acquainted with their points of attachment,—their form, and their lines of direction with regard to the axes of the bones. A perusal of them will then serve the purpose of a repetition, and suggest a strong motive to make another and a more careful dissection than could be expected in a first attempt. In doing this it will not suffice merely to trace the outline of each muscle; its points of attachment should be exactly defined by carefully removing the cellular tissue and every extraneous substance which obscures them. (*See the Table of Muscles, in the order of Dissection, at the end of this chapter.*)



incisions, and cautiously dissect it upwards and outwards, which will expose the fleshy fibres of the frontal part of the muscle. Having proceeded so far at the fore part, make a transverse incision from the occipital protuberance to the root of the mastoid process, a little above, but parallel with the superior curved line of the occipital bone. Another incision may be drawn at right angles with this from the occipital protuberance upwards to the vertex; and from the angle of union of these incisions begin and continue the dissection, raising the skin from the occipital part of the muscle, and so proceeding from the fleshy fibres upwards to the crown of the head. In conducting this dissection, the superficial filaments of the supraorbital nerves will be seen in front, the temporal branches of the portio dura at the sides, and the ascending branches of the posterior divisions of the cervical nerves behind; also the branches of the temporal and occipital arteries. When it is not deemed necessary to retain the large flap of tegument thus dissected off, and reflected down over the ear and side of the neck, it can be readily detached by an incision carried from the outer angle of the orbit backwards to the mastoid process.

[Fig. 170.]



The muscles of the head and face. 1. The frontal portion of the occipito-frontalis. 2. Its occipital portion. 3. Its aponeurosis. 4. The orbicularis palpebrarum, which conceals the corrugator supercilii and tensor tarsi. 5. The pyramidalis nasi. 6. The compressor nasi. 7. The orbicularis oris. 8. The levator labii superioris alæque nasi; the adjoining fasciculus between numbers 8 and 9 is the labial portion of the muscle. 9. The levator labii superioris proprius; the lower part of the levator anguli oris is seen between the muscles 10 and 11. 10. The zygomaticus minor. 11. The zygomaticus major. 12. The depressor labii inferioris. 13. The depressor anguli oris. 14. The levator labii inferioris. 15. The superficial portion of the masseter. 16. Its deep portion. 17. The attrahens aurem. 18. The buccinator. 19. The attollens aurem. 20. The temporal fascia which covers in the temporal muscle. 21. The retrahens aurem. 22. The anterior belly of the digastricus muscle; the tendon is seen passing through its aponeurotic pulley. 23. The stylo-hyoid muscle, pierced by the posterior belly of the digastricus. 24. The mylo-hyoideus muscle. 25. The upper part of the sterno-mastoid. 26. The upper part of the trapezius. The muscle between 25 and 26 is the splenius.—W.]

*Occipito-frontalis*; Douglas—(epicranius; Albinus.)—This is a flat, thin, digastric muscle (fig. 170), extended from the occiput to the forehead (from which circumstance its name is derived), and placed immediately beneath the cranial integument, to which it closely adheres, at the same time that it rests upon the arch of the skull, over which it slides. It consists of two broad but short fleshy bellies, united by an intervening aponeurosis.

The occipital part.<sup>2</sup>—The posterior fleshy portion is attached, by short tendinous fibres, to the external two-thirds, sometimes much less, of the superior curved line of the occipital bone, and to the mastoid portion of the temporal bone, immediately above the sterno-mastoid muscle. The fleshy fibres, which are from an inch to an inch and a half in length, proceed upwards and inwards, and terminate in distinct white tendinous fibres, which soon become continuous with the aponeurosis. Between the occipital muscles of opposite sides of the head there is a considerable, but in different cases a varying, interspace, which is occupied by the epicranial aponeurosis.

Frontal part.<sup>1</sup>—The fleshy fibres, of which this portion of the muscle

of which this portion of the muscle



is composed, extend downwards and forwards on the frontal bone; they are longer and broader than those of the occipital part, but the fibres are paler and less distinctly muscular; their upper margin, being their junction with the aponeurosis, presents a curved line, which is a little below the coronal suture; the inner fibres, corresponding with the median line, descend vertically, and become continuous with the pyramidalis nasi;<sup>5</sup> the middle fibres, longer than the others, terminate by becoming blended with the orbicularis,<sup>4</sup> and corrugator supercillii; and the external fibres curve inwards somewhat, and become blended with those of the orbicularis palpebrarum over the external angular process. The inner margins of the right and left frontal muscles are blended together for some space above the root of the nose.

The *aponeurosis*<sup>3</sup> of the occipito-frontalis (*membrana epicrania*; *galea aponeurotica capitis*) extends over the upper surface of the cranium uniformly from side to side, without any separation into lateral parts. It must therefore be regarded as a single structure, having connected with it the occipital and frontal muscular strata above described, and at the same time uniting the muscles of one side with the other, and combining their action.

Posteriorly, in the interval between the occipital parts of the muscles, the aponeurosis is fixed to the occipital protuberance and curved line above the trapezius; in front it presents in the middle an angular elongation, which intervenes for a short distance between the margins of the frontal muscles before they join; laterally, it has connected with it the superior and anterior auricular muscles. In the situation of the temporal ridge it loses the aponeurotic character, and is continued over the temporal fascia to the zygoma by a layer of laminated cellular membrane. The fibres are chiefly longitudinal, following the direction of the muscles; and they will be found distinctly tendinous where they receive the fibres of the occipital portions of the muscle.

The aponeurosis is firmly connected with the skin and subcutaneous granular fat (in which several blood-vessels and nerves ramify) by numerous short fibro-cellular bands; and it adheres loosely to the subjacent pericranium, through the medium of thin cellular membrane devoid of fat. Hence the muscles, when thrown into action, move the integuments with the aponeurosis (the hairy scalp) on the immediate investment of the skull. Hence, too, while they together admit of being easily and speedily stripped from the calvarium, the skin cannot be separated from the aponeurosis and muscle with facility. The integument is likewise closely connected with the frontal portion of the muscle, and the skin of the forehead is, in consequence, folded or wrinkled when this contracts.

Some anatomists consider the whole to be a four-headed muscle, having two fleshy portions behind, and two in front, all connected by a single layer of aponeurosis, which rests on the cranium. Others view it in a different way, the fleshy parts being taken as separate muscles, and named from their position, the anterior one being the "frontal" muscle, the posterior the "occipital."

*Actions.*—All the muscular parts having one broad common aponeurosis, they act together: their first effect is to draw up the eyebrows, the next to throw the skin of the forehead into transverse folds or wrinkles; and to move the hairy scalp



backwards and forwards, by bringing the occipital and frontal parts of the muscle alternately into action.

#### MUSCLES OF THE FACE AND SIDE OF THE HEAD.

The muscles of the face are easily and conveniently arranged in groups, each occupying what may be called a region. The circumference of the orbit with the eyebrow and eyelids forms the palpebral region; the side of the nose—the nasal; the cheek or side-face—the superior maxillary; the circumference of the mouth, and the space between the jaws—the intermaxillary; that corresponding with the lower jaw—inferior maxillary. The interior of the orbit forms a separate region—the orbital; so does the space round the ear—the auricular; that of the temple and side of the jaw, the temporo-maxillary; finally, the region of the pterygo-maxillary fossa. In consequence of their position and their connexion with the aponeurosis of the occipito-frontalis, the muscles of the auricle will now be examined.

#### AURICULAR REGION.

In the space round the external ear are placed three small muscles, which in the human subject may be considered rudimentary, as they are not required to perform any action. They are attached by small tendons to the fibro-cartilage of the ear, and are quite superficial.

*Dissection.*—These muscles are generally removed together with the skin, when their dissection is attempted in the usual way by the beginner, who seeks to expose the fleshy part first: better at once reverse the process—seek for the tendons, and take them as guides. For this purpose, draw the pinna or broad part of the ear downwards; a very small tense cord will be felt under the skin, where it is reflected from the head to the ear, running from above downwards to the upper bulging part of the concha. This is the tendon of the attollens. Cautiously divide the skin by an incision drawn over the tendon from below upwards: reflect it to each side, and continue the process thus upwards from the tendon to its muscular fibres, which spread upon the temporal fascia. Proceed in the same way to expose the two other muscles—draw the pinna forwards, and the tendon of the retrahens will be readily perceived where it is inserted into the bulging part of the concha behind. Let a hook be inserted into the extremity of the helix at the point corresponding with the line of the zygoma. When the helix is drawn backwards, the tendon of the attrahens muscle is rendered tense, and can be exposed and dissected as in the previous instances.

The *superior auricular* (fig. 170,<sup>19</sup>) (attollens auriculam; Alb.—temporo-auricularis,) is the largest. It arises from the aponeurosis of the occipito-frontalis, where it expands on the side of the head; its fibres, though delicate, being broad and radiated. The muscle ends in a compressed tendon, which is inserted into the upper and anterior part of the cartilage of the ear, on the outer side of the fossa between the division of the antihelix.

*Posterior auricular*<sup>21</sup> (retrahentes auriculam; Alb.—mastoido-auricularis).—This muscle consists of two or three thin fasciculi, ranged one over the other; they arise from the mastoid process by short aponeurotic fibres, and are inserted into the back part of the concha. The fibres are much more distinctly marked than in either of the other auricular muscles.

The *anterior auricular*<sup>27</sup> ([attrahens auriculam,] zygomato-auricularis) is pale and indistinct, and varies much in size. It is attached



to the thin lateral elongation of the aponeurosis of the occipito-frontalis above the zygoma, and passes backwards, to be inserted into the fore part of the helix.

To expose the muscles of the front and side of the face, begin by making an incision from the vertex along the middle line of the forehead and nose, taking care that it barely divides the skin. From this, two lines may be drawn outwards, one over the eyebrow to the side of the head, the other over the zygoma to the ear. The interval intercepted between these two parallel lines may be intersected, midway between the ear and orbit, by a perpendicular line drawn from one to the other. A square (*palpebral region*) is thus marked out over the orbicularis muscle, the skin of which should be carefully reflected from its borders and angles. The dissection is continued from its outer and upper border or circumference, the point of the scalpel being made to trace the course of the curved fibres of the muscle as far as the margin of the eyelids. The external flap may then be reflected back over the ear, so as to expose the temporal fascia, artery, &c. The skin, in the next place, is to be carefully raised and dissected off the frontal muscle, from below upwards over the forehead as far as the vertex.

The fibres of the orbicularis, after being carefully examined, particularly at the inner border of the orbit, may now be divided along the eyebrow, so as to expose the corrugator supercilii; and if the lower border of the orbicularis be raised, it will expose the origin of the elevator of the lip, which will afford a guide to the dissection of that muscle, as well as of the common elevator of the lip and nose, down to their termination (*nasal region*). The transversalis nasi is partly concealed by the latter, but it emerges from under its inner border as it advances upon the side of the nose.

In order to expose the muscles and vessels of the lower part of the face, an incision may be made from the most prominent point of the cheek downwards to the margin of the jaw, from which the skin may be reflected backwards off the masseter muscle and parotid gland, taking care not to injure the duct of the latter, or the nerves and artery which accompany it; but the other flap of skin is to be carried obliquely inwards to the lip, in the direction of the zygomaticus. By this measure, the last-named muscle, and the levator anguli oris, and also the facial artery, will be exposed; and, by removing some adipose substance, the buccinator will be brought into view (*intermaxillary region*). By turning aside the elevator of the lip, the second branch of the fifth nerve and the infra-orbital artery will be seen emerging from the foramen of that name.

#### PALPEBRAL REGION.

We have here four muscles, which act on the eyelids, two being placed outside the orbit; viz., orbicularis palpebrarum and corrugator supercilii; and two within it, viz., levator palpebræ and tensor tarsi.

*Orbicularis palpebrarum* (fig. 170,<sup>4</sup>) (*naso-palpebralis*).—This muscle is situated at the base of the orbit, forming a thin, flat plane of elliptic fibres, which is placed immediately under the skin of the eyelids, resting on the eyebrow above, and spreading outwards somewhat on the temple, and downwards on the cheek. The fibres form an ellipsis, whose great axis extends horizontally across the orbit from its inner angle to the temple, and corresponds with the fissure between the eyelids; all the fibres describing concentric curves, the concavities being directed towards the fissure of the lids. The only points of fixed attachment (to bone) which its fleshy fibres possess are at the inner margin of the orbit; they are free in the rest of their extent, except along the eyebrow, where they are blended with the occipito-frontalis and corrugator supercilii.

The *tendon* of the muscle (*tendo palpebrarum*).—At the inner commissure of the eyelids is a small tendon, which is often obscured by



the fibres of the muscle, but is rendered apparent by drawing the lids outwards: this tendon is about two lines in length, and one in breadth: it is attached to the anterior margin of the lachrymal groove, from which it runs horizontally outwards to the inner commissure of the eyelids, where it divides into two thin fibrous lamellæ, which diverge as they pass outwards in the substance of the eyelids, and terminate in the tarsal cartilages. One surface of the tendon is subcutaneous, the other crosses the lachrymal sac a little above its centre, and from it a thin but firm fascia is given off, which spreads over the lachrymal sac, and adheres to the margins of the groove which lodges it.

The *muscular fibres are attached*, 1st, to the upper margin and anterior surface of the tendon just described; 2d, to the surface of the nasal process of the superior maxilla, near the anterior margin of the lachrymal groove; 3d, to the nasal process of the frontal bone. The fibres of the orbicularis muscle thus arising arch upwards and outwards in the direction of the eyebrow and upper lid, and thence descend over the external angle of the orbit, returning to the points above stated. The anterior surface of the muscle is subcutaneous in its entire extent, and closely adheres to the skin; the posterior rests upon the lower border of the frontal muscle and the corrugator, with both of which it is intimately connected; farther down it rests upon the upper eyelid and the tarsal cartilage. The lower segment of the muscle rests on the origin of the elevator of the upper lip, and on the zygomatic muscles; and internally, on part of the common elevator of the lip and nose, and the lachrymal sac; also externally for a little way on the temporal fascia.

The fibres of the orbicularis are thin and pale where they correspond with the eyelids; they are also less curved; but those which rest on the cheek and margin of the orbit are well developed. These parts have been described as two muscles; the former being named "ciliaris," the latter "orbicularis latus."\*

The *corrugator supercilii* (fronto-superciliaris) is a small pyramidal muscle, placed in the eyebrow, whose direction it takes, being altogether concealed by the orbicularis palpebrarum and occipito-frontalis. It arises from the inner extremity of the superciliary ridge of the frontal bone, from which its fibres proceed outwards and a little upwards, and end at the middle of the orbital arch, by becoming blended with those of the orbicularis and occipito-frontalis lying between them and the bone. Its anterior surface is covered by the muscles just named; the posterior rests upon the frontal bone and crosses the frontal branch of the ophthalmic nerve and the accompanying artery as they emerge from the orbit; its inner extremity is somewhat thicker than the external one, which gradually narrows to a point.

*Levator palpebræ* (fig. 174,\*). This slender muscle is concealed, in the greater part of its extent, within the orbit; it arises above and before the margin of the optic foramen, from which it passes forwards and outwards, mounting over the globe of the eye, and separated from the roof of the orbit only by the fourth and frontal nerves. It is very narrow and tendinous at its origin; it soon becomes fleshy and

\* This division is mentioned by Riolanus as usual among the anatomical writers of his time.—"Anthropologia," lib. 5, cap. 10.



widens; finally it ends in a broad fibrous expansion, which curves downwards in the substance of the upper eyelid, to be inserted into the margin of the tarsal cartilage. This muscle lies above the rectus superior and the ball of the eye; and, in the lid, is placed between the orbicularis muscle and the conjunctiva.

The *tensor tarsi*—Horner, (*musculus sacci lachrymalis*,)—is a very thin small muscle, placed at the inner side of the orbit, resting against the fibrous covering of the lachrymal sac and behind the tendon of the orbicularis. Its fibres arise from the posterior part of the lachrymal bone, and as they pass forwards they divide into two narrow processes; these diverge, cover the lachrymal canals, and become attached to the tarsal cartilages near the puncta lachrymalia.

This little muscle has been described as an offset of the ciliaris of both lids, with which the fibres appear to be continuous (Theile, *Op. citat.*)—It is often indistinct.

*Actions.*—The corrugator muscle being fixed by its inner extremity, draws the eyebrow and eyelid inwards, and throws the skin into perpendicular lines or folds, as in frowning. The occipito-frontalis will, on the contrary, elevate the brow, and wrinkle the skin transversely; which actions are so frequently repeated by most persons, and so constantly by some of a particular temperament, that the skin is marked permanently by lines in the situations just referred to. The orbicular muscle is the sphincter of the eyelids. It closes them firmly, and at the same time draws them to the inner angle of the orbit, which is its fixed point of attachment. The levator palpebræ is the direct antagonist of the orbicular muscle; for it raises the upper eyelid, and uncovers the globe of the eye. The tensor tarsi draws the eyelids towards the nose, and presses the orifices of the lachrymal ducts closely to the surface of the globe of the eye. It may thus facilitate the entrance of the tears into the ducts, and promote their passage towards the nose.

NASAL REGION.

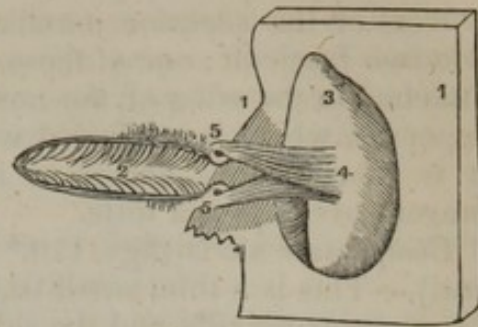
We here find several muscles as follows:—

*Pyramidalis nasi* (fig. 170,<sup>s</sup> and 172,<sup>1</sup>) (*naso-frontalis*) rests on the nasal bone, and appears like a prolongation of the occipito-frontalis, with whose fibres it is intimately connected, as well as with those of the corresponding muscle. It extends from the root of the nose, where its fibres are continuous with the occipito-frontalis, to about half-way down, where it becomes tendinous and unites with the compressor nasi. The two pyramidal muscles diverge as they descend, leaving an angular interval between them, and each terminates in a thin fibrous lamella, which covers the side of the nose. At its outer border the fleshy fibres are connected with those of the orbicularis palpebrarum. It is covered by the common tegument, and rests upon the nasal part of the frontal bone and the os nasi.

Its chief effect seems to be that of giving a fixed point of attachment to the frontal muscle; it also wrinkles the skin at the root of the nose.

The *levator labii superioris alæque nasi* (figs. 170,<sup>s</sup> and 172,<sup>2</sup>) (common elevator of the lip and nose) lies along the side and wing of the

[Fig. 171.



A view of the tensor tarsi muscle. 1, 1. Bony margins of the orbit. 2. Opening between the eyelids. 3. Internal face of the orbit. 4. Origin of the tensor tarsi. 5, 5. Insertion into the neighbourhood of the puncta lachrymalis.—W.]



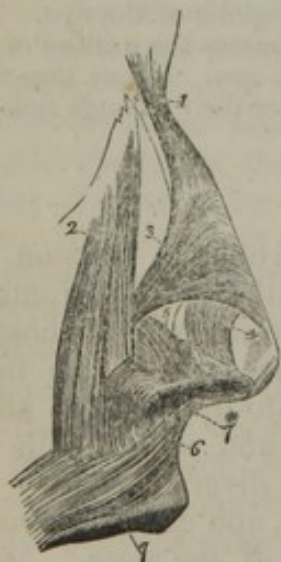nose, extending from the inner margin of the orbit to the upper lip. It *arises* by a pointed process from the upper extremity of the nasal process of the superior maxillary bone, and as it descends separates into two fasciculi; one of these, much smaller than the other, becomes attached to the wing of the nose, whilst the other is prolonged to the upper lip, where it is blended with the orbicular and elevator muscles. It is subcutaneous, except at its origin, where the orbicularis palpebrarum overlaps it a little.

*Compressor naris* (figs. 170,<sup>6</sup> and 172,<sup>3</sup>) (transversalis v. triangularis nasi).—This is a thin, small triangular muscle, which lies close upon the superior maxilla and the side of the nose, the direction of its fibres being transverse from without inwards and upwards; it is concealed at its origin by the proper elevator of the lip, and is crossed by the common elevator. It arises narrow and fleshy from the canine fossa in the superior maxillary bone, from which its fibres proceed inwards and upwards, gradually expanding into a thin aponeurosis, which is partly blended with that of the corresponding muscle of the opposite side and that of the pyramidalis nasi of the same side, and partly attached to the fibro-cartilage of the nose.

Beneath the common elevator of the lip and ala of the nose, and connected by the lower end with the origin of the compressor naris, will be found a longitudinal muscular slip, more than an inch in length, attached exclusively to the superior maxillary bone. It was named “rhomboideus” by Santorini, and (in consequence of being attached only to a bone, and having therefore no action,) “anomalus” by Albinus.

The *depressor alæ nasi* is a small flat muscle, lying between the

Fig. 172.



Represents the muscles of the nasal region, with some of those of the lip. 1. Pyramidalis nasi. 2. Levator labii superioris alæque nasi. 3. Compressor naris. 4. Levator proprius alæ nasi anterior. 5. Levator proprius alæ nasi posterior. 6. Depressor alæ nasi. 7. Orbicularis. 7\*. Nasolabialis.

mucous membrane and the muscular structure of the lip, with which its fibres are closely connected. From a depression (myrtiform) near the alveolar border of the superior maxilla, the fibres ascend to terminate in the septum and the ala of the nose—the posterior part of each—(fig. 172,<sup>6</sup>). The external fibres curve forwards and downwards to the ala.

Besides the muscles above described there are other muscular fibres which cover the small cartilages of the nose. They are usually very indistinct, partly in consequence of the close connexion of the skin and cartilages of the nose, between which they lie, and the necessary removal of a portion of the short fibres when the skin to which they are attached is cut away. The muscular fibres admit of being divided into two distinct parts, as follows:—

*Levator proprius alæ nasi posterior* (dilator naris poster.) (fig. 172,<sup>5</sup>).—After the careful removal of the common elevator of the nose and lip, this muscle will be apparent often to the naked eye, but always with the



aid of a lens. (Theile.)—Its fibres are attached to the margin of the mounting process of the superior maxillary bone and the smaller (sesamoid) cartilages of the ala nasi on the one hand, and to the skin on the other.—The anterior set of fibres (*lev. propr. alæ nasi anterior* v. *dilatator naris anterior*) (fig. 172,<sup>4</sup>) are interposed between the cartilage of the ala and the skin, to both of which they are attached.\*

## SUPERIOR MAXILLARY REGION.

Here are four muscles, viz., the elevator of the upper lip, the elevator of the angle of the mouth, and the two zygomatici.

The *levator labii superioris* (fig. 170<sup>9</sup>) (the proper elevator of the upper lip) extends from the lower border of the orbit to the upper lip, lying close to the outer border of the common elevator, with which and the smaller zygomatic muscle it is blended inferiorly. It *arises* immediately above the infra-orbital foramen, where its fibres are attached, partly to the superior maxillary bone, partly to the malar. Its direction is downwards and a little inwards, ceasing at the upper lip, where it unites with the rest of the muscular apparatus of that part. At its origin, this muscle is overlapped by the orbicularis palpebrarum, but its lower part is subcutaneous; it partly conceals the levator anguli oris, and the compressor nasi.

*Levator anguli oris* (fig. 170,) (*musculus caninus*).—The elevator of the angle of the mouth, lies beneath the preceding, and partly concealed by it. It *arises* immediately below the infra-orbital foramen, from the canine fossa, whence the name *caninus*, and is inserted into the angle of the mouth. It is broader above than below, and inclines outwards somewhat as it descends; it lies at the middle of the face, deeply behind the outer border of the elevator of the upper lip, escaping from under it at the lower end, in consequence of the different direction of the two muscles. Its anterior surface supports the infra-orbital nerve and artery, which separate it from the preceding muscle; the posterior lies on the superior maxilla and on the orbicularis and buccinator muscles, with which and the depressor anguli oris its fibres become united.

The *zygomatici* are two narrow fasciculi of muscular fibres, extended obliquely from the most prominent point of the cheek to the angle of the mouth, one being larger and longer than the other.—*Zygomaticus minor* (fig. 170,<sup>10</sup>). This irregular little muscle *arises* from the anterior and inferior part of the malar bone, and inclines downwards and forwards to terminate by joining with the outer margin of the levator labii superioris; the junction sometimes occurring close to the origin of the zygomaticus minor. It lies internally to the succeeding muscle, but distinct from it in the whole length, and is sometimes joined by some fibres of the orbicularis palpebrarum; or its place may be taken by a muscular slip from this muscle. It may be altogether wanting.

\* The muscular structure here described, or a great part of it, has been described and delineated under the name "pinnæ dilatator" by Santorini.—(Obs. Anat. cap. 1, § 14, and tab. 1.) But in recent observations two separate muscles (noticed in the text) have been recognised by Professor Theile, in the new ed. of "Sömmerring v. Baue d. menschlich. Körpers." M. Arnold (Tab. Anat. fascic. 2, tab. 8, figs. 6 and 7) apparently connects the posterior muscle with the depressor alæ nasi, describing both as one large "dilatator."



—The *zygomaticus major*<sup>11</sup> arises from the malar bone near the zygomatic suture, from which it descends, lying inferior and external to the smaller muscle of the same name, to the angle of the mouth, where it is continued into the orbicularis and depressor anguli oris. These muscles, at their origin, are concealed a little by the orbicularis palpebrarum, but become subcutaneous in the rest of their extent. The larger one crosses, just below its origin, a part of the masseter and buccinator muscles.

#### INFERIOR MAXILLARY REGION.

This space contains three muscles, viz., the depressor of the angle of the mouth, the depressor of the lower lip, and the elevator of the lower lip.

*Depressor anguli oris* (fig. 170,<sup>13</sup>) (triangularis oris; maxillo-labialis).—This muscle lies at the side and lower part of the face, being extended to the angle of the mouth from the lower jaw. It arises from the external surface of the inferior maxillary bone, particularly from the oblique line which is marked upon it. It is triangular in form; the base of the triangle corresponding with its origin, and its apex with its insertion into the angle of the mouth. Its fibres pass upwards, gradually contracting so as to form a narrow process, which is inserted into the angle of the mouth, by becoming blended with the orbicular and great zygomatic muscles, and also with the termination of the levator anguli oris. It is covered by the skin, and, at its insertion, by the zygomaticus major, under which its fibres pass; it conceals part of the buccinator and of the depressor of the lower lip.

*Depressor labii inferioris* (fig. 170,<sup>12</sup>) (quadratus menti; mento-labialis).—A small square muscle, lying nearer to the symphysis of the chin than the preceding muscle, by which it is partly concealed; it arises from the fore part of the inferior maxillary bone, and thence ascends to be inserted into the lower lip, its fibres becoming blended with those of the orbicularis oris, and also having previously united with those of its fellow of the opposite side. It has mixed up with it some of the fibres of the platysma, and it presents rather a peculiar appearance when dissected, owing to a quantity of yellow adipose matter being deposited in the interstices of its fibres.

*Levator menti* (elevator labii inferioris proprius—Cowper) (fig. 170,<sup>14</sup>) arises from a slight pit a little below the alveolar border of the lower jaw, near the symphysis. This pair of muscles occupies the interval between the two depressors of the lower lip. They are small, short, and somewhat tapering, being narrow at their point of origin, from which they increase in breadth towards their insertion. They incline downwards and a little forwards to reach the tegument of the chin, into which they are inserted.

*Actions.*—The names of most of the muscles included in the three foregoing groups sufficiently indicate their actions upon the lips, the nose, and the mouth. It will be found in conducting their dissection that they are intimately connected with the skin which covers them. Hence they are enabled to give to the face all those changes of state which are necessary for the expression of passion and feeling.



## INTER-MAXILLARY REGION.

At each side of the face, in the part called the "cheek," is a muscle, the buccinator; and round the margin of the mouth, one—the orbicularis oris.

The *buccinator* (fig. 170,<sup>18</sup>) (alveolo-labialis) is a thin flat plane of muscular fibres, quadrilateral in figure, occupying the interval between the jaws. It is attached, by its upper and lower margins, to the alveolar margins of the maxillary bones, from the first molar tooth in each, as far back as the last; and posteriorly between these bones it is fixed to a narrow fasciculus of tendinous fibres, extended from the internal pterygoid plate to the posterior extremity of the mylo-hyoid ridge of the lower jaw, close to the last dens molaris. From these points the fibres are directed forwards, approaching each other, so that the muscle is narrowed and proportionally thickened near the angle of the mouth. Here it lies beneath the other muscles, and blends with them. The fibres near the middle of the muscle cross each other, those from above entering into the lower lip, and those from below into the upper one; but the higher and lower fibres are directed immediately into the nearest lip.

The internal surface of the buccinator is lined throughout by the mucous membrane of the mouth; the external is covered and supported by a thin fascia, which is closely adherent to the muscular fibres, and is overlapped by the triangularis oris, the terminal fibres of the platysma myoides, and by the labial artery and vein; also by the masseter and zygomatici, from which it is separated by a quantity of soft adipose tissue of a peculiar character. Opposite the second dens molaris of the upper jaw its fibres give passage to the duct of the parotid gland.

The *pterygo-maxillary ligament* (fig. 178,<sup>14</sup>).—The tendinous band connected with the posterior margin of the muscle has, from its attachments, been thus called; one of its surfaces looks towards the mouth, and is lined by the mucous membrane; the other is separated from the ramus of the jaw by a quantity of adipose substance; the anterior border gives attachment, as has been here stated, to the buccinator muscle, and the posterior, to the superior constrictor of the pharynx. It is this connexion between the muscles just named which establishes a complete continuity of surface between the cavity of the mouth and that of the pharynx.

*Risorius* (Santorini).—By this name is known a small bundle of muscular fibres of varying size and shape, but usually broadest at the outer end, which commences over the masseter, and extends transversely inwards in the fat of the cheek, to join the other muscles of the mouth—usually the depressor anguli oris below the angle of the mouth. It is placed over (superficial to) the platysma where this reaches the face, and crosses its fibres, and for these reasons was described as a separate muscle by Santorini.

*Orbicularis oris* (fig. 170,<sup>7</sup>; fig. 172,<sup>7</sup>) (labialis).—It belongs to the class of sphincter muscles, and like them is elliptic in its form, and composed of concentric fibres so placed as to surround the aperture



of the mouth, but with this peculiarity, that the fibres are not continued from one lip into the other; if any fibres should be traceable from one lip to the other, they are few and slender. The muscle is flat and thin; its inner surface being in contact with the coronary artery of the lips, labial glands and the mucous membrane; the external with the skin and the fibres of the different muscles which converge towards the margin of the mouth. The longer axis of the ellipse is transverse, so as to correspond with the fissure between the lips; the curves described by the fibres of the upper segment look downwards, and those of the lower one upwards. One border of each segment is free, and corresponds with the red part of the lip; the other is blended with the several muscles which converge to the mouth from different parts of the face. The fibres are continued from these muscles, insomuch that they might be said to be borrowed from them.

The fibres nearest to its margin continue uninterruptedly from side to side of the mouth; but to the outer part of the muscle (that most remote from the edges of the lips) some special fibres are added. There are two sets of these, connected with the maxillary bones; one set or pair for the upper, the other for the lower lip (four altogether). They are slender and arched, and they resemble one another in a great degree in their arrangement. Thus: the two bands of fibres for the upper lip (*accessorii orbicularis inferioris*\*) arise close together above the alveolar border of the superior maxilla opposite the incisor teeth, and arch outwards, one on each side, to the angles of the mouth, to join with the other muscles.

Those for the lower lip (*accessorii orbicularis inferioris*†) are separated one from the other by a much larger interval than the preceding pair, and rather are accessory to the lower segment of the orbicularis than form a part of it. They are fixed to the lower maxilla, externally to the levatores menti, and arch outwards to the angles of the mouth to join the buccinator and the other muscles.

To the superior segment of the orbicularis two small fleshy slips (*naso-labiales*—Alb.) descend, one on each side, from the septum narium (fig. 172,\*). As they diverge to the lip, these little muscles leave an interval between them, and at the same place a narrow interspace likewise exists between the accessory or external portion of the orbicularis above described. This small intermuscular interval corresponds with the groove on the skin beneath the septum narium.

*Actions.*—The aperture of the mouth is susceptible of considerable dilatation and contraction; the former being effected by the different muscles which converge to it, and which may be compared to retractors drawing with different degrees of obliquity the lips, or their angles, in the direction of their respective points of attachment. The elevators are necessarily placed at the upper part of the face, the depressors in the opposite situation, and the proper retractors on each side; and these are the zygomatici and the buccinators. The buccinators also contract and compress the cheeks; this power is brought into play when any substance becomes lodged in the interval between them and the jaws. The fibres of the muscles are then elongated and pressed outwards; but, when they begin to act, they form a flat plane, which is pressed inwards, and so forces the substance back into the cavity of the mouth. It is obvious that the orbicular muscle must be the direct antagonist of all those that converge to it. When describing the muscles, we may commence at the lips as a common point of departure, and trace their fibres from thence as they diverge, radiating to their respective attachments.

#### TEMPORO-MAXILLARY REGION.

This space, extending from the side of the head to the angle of the jaw, contains the temporal and masseter muscles.

\* *Secundus fibrarum ordo* (Santorini); *sur-demi-orbiculaires* (Winslow).

† *Productores labii inferioris* (Santorini); *accessores buccinatoris* (Courcelles); *les accessoires du demi-orbiculaire inferieur* (Winslow).



*Dissection.*—To expose the masseter muscle, and with it the duct and the surface of the parotid gland, it will suffice to reflect back the skin from the lines of incision indicated in the previous dissections. In doing this, a large branch of the facial nerve will be found accompanying the parotid duct. This will serve as a clue to the trunk of that nerve, by following it back through the substance of the parotid gland; and, when the trunk is found, there can be no difficulty in pursuing all its branches, as they diverge from that point in three different directions over the face and side of the head. The superficial temporal vessels are at the same time brought into view. Cut the duct across, raise it and the accompanying piece of the parotid gland together, and draw it out towards the ear. This will expose the anterior margin of the gland and its relations to the ramus of the jaw. A little more dissection is required to get a view of its posterior border, and of its relations to the parts deeply seated between the jaw and the ear.

The next thing to be done is to get at the insertion of the temporal muscle, and at the same time bring into view the pterygo-maxillary region: proceed as follows:—

The masseter muscle and parotid gland having been examined, the parts concealed inside the ramus of the jaw may be brought into view in the following way:—With a sharp chisel and mallet the zygoma may be divided at both extremities, and the attachment of the temporal fascia to its upper border severed. The bony arch, with the masseter still connected with it, may be drawn down to the angle of the jaw, the fibres of the latter being at the same time detached from the ramus. In the next place, with Hey's saw, the ramus of the jaw may be divided by a perpendicular cut, carried from just before its condyle to a level with the alveolar border, and there met by another line carried forwards to the latter, so as to insulate and detach all that part of it which belongs to the coronoid process. This being done, the piece of bone, with the temporal muscle attached, may be drawn upwards, so as fully to expose the two pterygoid muscles, (*pterygo-maxillary region*), the internal maxillary artery, the gustatory and dental nerves, and the pterygo-maxillary ligament, which gives attachment to the buccinator and superior constrictor muscles.

The *masseter* (fig. 170,<sup>45</sup>) (*zygomato-maxillaris*) is extended from the malar bone and the zygomatic process of the temporal to the angle of the lower jaw. Its form is that of an oblong square; its direction downwards and a little backwards. It is a thick, compressed mass of fleshy and tendinous fibres, arranged so as to form two bundles, differing in size and direction.

The *external*, or larger portion of the muscle, arises chiefly by thick tendinous structures, (which afford a large surface for the origin of muscular fibres,) from the lower border of the malar bone, and somewhat from the malar tuberosity of the superior maxilla, from which its fibres proceed downwards, and a little backwards, to be inserted into the lower half of the ramus of the jaw, extending as far as its angle. The *internal*, or smaller part, is, for the most part, vertical in direction, (some fibres inclining a little forwards,) and, therefore, crosses the larger portion. Consisting chiefly of fleshy fibres, it arises from the lower border of the zygomatic process of the temporal bone, (reaching as far back as its tubercle,) and is inserted into the upper half of the ramus of the jaw. This part of the muscle is concealed, in the greater part of its extent, by the larger portion, with which its fibres become united at their insertion; part, however, projects behind it, and is covered by the parotid gland.

The external surface of the masseter muscle is covered, for the most part, only by the skin and fascia; it is, however, overlapped



above by the zygomaticus, below by the platysma, and behind by the parotid gland, whose duct also crosses it; the branches of the facial nerve and the transversalis faciei artery also rest upon it. Its inner surface overlays the buccinator, from which it is separated by some soft adipose tissue; also the tendinous insertion of the temporal muscle into the coronoid process; it is in intimate contact with the ramus of the jaw, and receives a nerve and artery which come from within over the sigmoid notch of the bone.

The *temporal* muscle (temporalis; temporo-maxillaris; crotaphite—Winslow) is placed at the side of the head, occupying the whole extent of the temporal fossa; it is of considerable size, being broad, thin, and expanded above, where it is attached to the side of the skull, but it becomes thick, compressed, and narrowed to a point below, at its insertion. The fibres of the muscle present a radiating appearance; they are concealed from view by the temporal fascia, which must be removed before they can be seen.

It *arises* from the whole of the temporal fossa, its fibres being implanted into all that depressed surface which extends from the external angular process of the frontal bone backwards to the root of the mastoid process, and from the curved line marked upon the parietal and frontal bones downwards to the ridge on the sphenoid bone which separates the temporal fossa from the zygomatic; it likewise takes origin from the inner surface of the temporal fascia. The fibres from this extensive origin converge as they descend, some being directed from before backwards, a considerable number obliquely forwards, whilst those in the middle descend almost vertically; but all terminate in a tendon whose fibres, at first radiating like those of the muscle itself, gradually become aggregated, so as to form a thick flat fasciculus, which is implanted into the inner surface as well as the anterior border of the coronoid process of the lower jaw-bone. The upper part of this tendon is in a great degree concealed by the muscular fibres, many of which descend to be implanted into its external surface, whilst the deep-seated fibres come forward from the lower part of the fossa to be attached to its inner surface; the lower part, or insertion of the tendon, is altogether concealed by the zygoma and the masseter.

Between the muscle and the temporal fossa are the deep temporal arteries and the temporal nerves which penetrate its substance.

The *temporal fascia* by which the muscle is covered and bound down is a remarkably dense firm membrane. It is attached inferiorly to the upper margin of the zygoma, where it is separated from the muscle by some loose adipose and cellular tissue; but higher up, the fascia expands, and becomes closely connected with the muscular fibres, and is attached along the curved line bounding the temporal fossa, where it gives origin to many of the superficial fibres of the muscle. The external surface of the fascia is overlaid by the aponeurosis of the occipito-frontalis muscle, by the orbicularis palpebrarum; moreover, two muscles of the ear—the superior and anterior—rest upon it, and the temporal artery and vein, with the ascending branches



of the facial nerve, cross it as they pass up towards the arch of the skull.

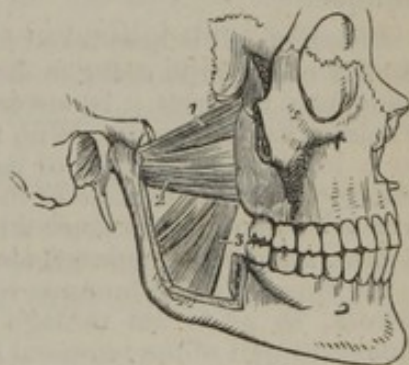## PTERYGO-MAXILLARY REGION.

The *internal pterygoid* muscle (fig. 173,<sup>3</sup>) (*pterygoideus internus*; *pterygo-maxillaris major*) is directed to the inner surface of the ramus of the jaw, somewhat as the masseter is to its outside; but it differs widely from that muscle in the extent of connexion with the bone. It is flat and elongated; its form, like that of the masseter, being an oblong square. It *arises* from the pterygoid groove, or fossa, its fibres, tendinous and fleshy, being attached to the inner surface of the external pterygoid plate of the sphenoid bone, and to the grooved surface in the tuberosity of the palate bone which is inserted between the pterygoid plates. From these points of attachment the muscle inclines downwards with an inclination backwards, and outwards, to be inserted into the inner surface of the ramus of the jaw, for about an inch above its angle.

The external surface of the muscle above the place of its insertion is separated from the ramus of the maxilla by the internal lateral ligament, and by the internal maxillary artery, dental artery and nerve; and at its upper part is crossed by the external pterygoid muscle. Its inner surface, whilst placed in the pterygoid groove, is in contact with the tensor palati muscle, and lower down with the superior constrictor of the pharynx.

The *external pterygoid* muscle (fig. 173,<sup>1 2</sup>) (*pterygoideus externus*; *pterygo-maxillaris minor*) is placed deeply in the zygomatic fossa, extending horizontally backwards and outwards from the process of that name to the condyle of the lower jaw. Its form is somewhat triangular, its base corresponding with its origin, and the apex with its insertion. The two extremities are tendinous, the rest of the muscle being a short, thick, fleshy mass, the upper fibres of which descend a little, and the lower ascend as they pass between their points of attachment, whilst those in the middle are horizontal. At its base the muscle appears to consist of two fasciculi, separated by a cellular interval; the upper fasciculus is attached to that part of the external surface of the great wing of the sphenoid bone which is near the root of the pterygoid process, including the ridge separating the temporal and the zygomatic fossæ; the other (the larger part) is attached to the outer surface of the external pterygoid plate, and to a small part of the tuberosity of the palate bone. It is inserted into the fore part of the neck of the condyle of the lower jaw, and also into its interarticular fibro-cartilage.

[Fig. 173.]



The two pterygoid muscles. The zygomatic arch and the greater part of the ramus of the lower jaw have been removed, in order to bring these muscles into view. 1. The sphenoid origin of the external pterygoid muscle. 2. Its pterygoid origin. 3. The internal pterygoid muscle.—W.]



This muscle, from its position in the zygomatic fossa is concealed by the coronoid process of the jaw, and the insertion of the temporal muscle; but when the masseter is removed, part of it can be seen between that process and the condyle. Its external surface is crossed by the internal maxillary artery and the tendon of the temporal muscle as it passes to the coronoid process, and is further covered by the masseter; the inner surface rests against the upper part of the internal pterygoid muscle, whose direction it crosses, also the internal lateral ligament of the lower jaw, and the inferior maxillary nerve and middle meningeal artery; the upper border is in contact with the great wing of the sphenoid bone, where it forms part of the zygomatic fossa, and is crossed by the temporal and masseteric nerves. As the pterygoid muscles diverge to their destinations, they leave between them an angular interval, which transmits the gustatory and dental nerves, and the internal maxillary artery.

*Actions.*—The lower jaw is elevated by the temporal, masseter, and internal pterygoid muscles, which conspire to this end. If the two first act together, the elevation is direct; but if the two last act, the obliquity of their direction enables them to carry the angle of the jaw a little forwards. The triturating movement is performed exclusively by the external pterygoid muscles. If both act together, they draw the condyles, and therefore the whole jaw, directly forwards, so as to make the lower teeth, project beyond the upper; but when only one acts at a given time, it draws the corresponding condyle forwards, the other remaining fixed, and so makes the symphysis of the jaw deviate to the opposite side. A similar movement can be given by the corresponding muscle, and the alternation of these horizontal motions constitutes trituration.

#### ORBITAL REGION.

In the orbit, in connexion with the eye, and its appendages, eight muscles are enclosed, viz., the levator palpebræ, and tensor tarsi, together with six muscles of the eyeball, namely, four recti and two oblique.

*Dissection.*—It is here taken for granted that the arch of the skull has been previously removed in order to dissect the brain. Now, to gain a clear view of the contents of the orbit, it is necessary to remove the greater part of its roof, and the whole of its outer wall. With this intent the malar bone may be sawed through on a level with the floor of the orbit, and as far back as the spheno-maxillary fissure. The orbital plate of the frontal should in the next place be cut through with a chisel along its inner third, and back to the anterior clinoid process; this incision should be continued along the floor of the middle fossa of the skull, close to the outside of the foramen rotundum and ovale, and thence back to the pars petrosa, so as to cut through the great wing of the sphenoid bone and the squamous part of the temporal bone. When this has been done, the whole may be pressed down and detached, by cutting along the base of the skull, from within outwards, the knife being inserted into the fissure thus made. These measures should first be considered, and marked out on the dried skull. A complete lateral view is thus obtained of the divisions of the fifth nerve, of all those in the cavernous sinus, as well as of the parts in the orbit.

Puncture the optic nerve with a coarse needle near the globe of the eye, and push it on into the latter, so as to make a free passage into it, through which you may convey a curved blow-pipe, and with a little air distend the globe; ligature the extremity of the nerve to prevent the air from escaping. Draw the eyelids forward, fill them with a little cotton, and apply a few points of suture along their margin. The eyelids and the globe can now be drawn gently forward, which will put all the muscles on the stretch; and their dissection merely consists in taking out cautiously the fat which fills the orbit.



The four recti muscles of the eye at their origin surround the optic nerve, and at their insertion correspond with the opposite points of the globe of the eye; each of them has a double name, one being founded on its situation, the other on its action, as follows: viz., rectus superior vel attollens; rectus inferior v. depressor; rectus internus v. adductor; and rectus externus v. abductor.

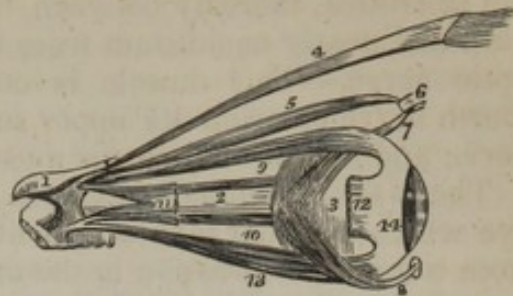
The *rectus superior* (fig. 174,<sup>9</sup>) arises close by the foramen opticum, and beneath the levator palpebræ;<sup>4</sup> it curves over the globe, and is inserted tendinous into the anterior part of the sclerotica.

The *rectus inferior*,<sup>13</sup> *rectus internus*, and *rectus externus*,<sup>11</sup> all arise by a common tendon, which is attached to the bony lamella that separates the foramen opticum from the sphenoidal fissure; but the external rectus has another attachment besides that of the common tendon. Its second head arises from the margin of the sphenoidal fissure, near the superior rectus. Between these heads is a narrow interval, which gives transmission to the third and sixth nerves and the nasal branch of the fifth. The four recti, thus attached posteriorly, pass forwards diverging, and, after curving over the middle of the globe of the eye (to which they present a flattened surface) in the position implied by their names respectively, are inserted by short tendinous fibres into the fore part of its sclerotic coat at an average distance of four lines from the margin of the cornea.

In length and breadth there are some differences among these muscles. The external rectus exceeds the internal one in length. On the other hand, the latter (internal rectus) has some advantage in width, being broader than any, and the superior one appears slightly the narrowest of all.

The *superior oblique*,<sup>5</sup> (obliquus superior v. major; trochlearis—Cowper) is placed at the upper and inner part of the orbit, internally to the levator palpebræ. It arises about a line from the optic foramen at its upper and inner part. From thence, this long slender muscle proceeds towards the internal angular process, and terminates in a round tendon, which passes through a fibro-cartilaginous ring, or pulley (trochlea) attached to a depression on the frontal bone at the inner margin of the orbit. To facilitate movement, a delicate synovial sheath lines the contiguous surfaces of the pulley and the tendon, and they are covered over by a loose cellular or cellulo-fibrous membrane. At this point the tendon is reflected outwards and backwards,

[Fig. 174.]



The muscles of the eyeball; the view is taken from the outer side of the right orbit. 1. A small fragment of the sphenoid bone around the entrance of the optic nerve into the orbit. 2. The optic nerve. 3. The globe of the eye. 4. The levator palpebræ muscle. 5. The superior oblique muscle. 6. Its cartilaginous pulley. 7. Its reflected tendon. 8. The inferior oblique muscle; the small square knob at its commencement is a piece of its bony origin broken off. 9. The superior rectus. 10. The internal rectus almost concealed by the optic nerve. 11. Part of the external rectus, showing its two heads of origin. 12. The extremity of the external rectus at its insertion; the intermediate portion of the muscle having been removed. 13. The inferior rectus. 14. The tunica albuginea, formed by the expansion of the tendons of the four recti.—W.]



passing between the globe and the superior rectus, to be inserted into the sclerotica, midway between the superior and external recti muscles, and nearly equidistant from the cornea and the entrance of the optic nerve.—This muscle is covered by the roof of the orbit, the fourth nerve entering its upper surface, and beneath it lie the nasal nerve and the internal rectus muscle.

The *inferior oblique*,<sup>s</sup> (obliquus inferior) is the only muscle of the eye which does not take origin at the bottom of the orbit. It arises from a minute depression in the orbital plate of the superior maxillary bone just within the inferior margin of the orbit and close by the external border of the lachrymal groove. The muscle inclines outwards and backwards between the inferior rectus and the floor of the orbit, and ends in a tendinous expansion, which passes between the external rectus and the globe to be inserted into the sclerotica, at its external and posterior aspect.

Besides the six muscles here described as the special motors of the globe of the eye, two others are found within the orbit, and have been already described with the muscles of the eyelids, to which they belong, viz., the levator palpebræ and tensor tarsi (page 336).

*Actions.*—The four straight muscles are attached in such a way at opposite points of the circumference of the globe of the eye, that, when the parts are viewed together in their natural position, the muscles with the globe represent a pyramid, whose summit is at the optic foramen, and base at the points of insertion. Now, as these points are anterior to the transverse diameter of the globe, and as each muscle, to reach its insertion, curves over the convexity of the eye, it will be obvious that, when in action, their effect must be to turn or rotate the globe, so that the cornea will be directed by them either upwards or downwards, outwards or inwards, as their names severally express. This will be better seen if a needle be inserted into the middle of the cornea, and each muscle be pulled by holding it with a pair of forceps near its origin. If any two recti act together, the cornea will be turned to a point intermediate between those to which they direct it separately. Thus the superior and external recti acting together turn the cornea upwards and outwards, the inferior and internal recti downwards and inwards. By this succession, combination, and alternation of action, the recti are enabled to direct the eye with the minutest precision to every point in the field of view. Sir E. Home attributes to them also the power of compressing the globe so as to lengthen its antero-posterior diameter, thereby becoming the principal means of its adjustment to seeing at different distances.

What is the action of the obliqui? They were at one time supposed to serve as antagonists to the recti, and to draw forward the globe of the eye, after it had been retracted into the orbit by the latter muscles. This cannot be the case; for they exist in animals in which the globe cannot be retracted, and they receive no increase of development in those which possess a large retractor muscle in addition to the recti. The obliqui were considered by Sir Charles Bell to perform all the involuntary and revolving movements; the recti all those which are governed by the will. When volition is suspended in sleep, or during coma, the cornea is observed to be turned upwards under the upper eyelid; and when the lid descends, as in winking, the globes revolve upwards at the same time, and for a special purpose. When the eyelid descends like a curtain over the globe, it brings down any extraneous matters which may have lodged upon it. These would necessarily be collected into a line across the centre of the cornea and obstruct vision; but, by the revolving motion, the cornea is carried upwards as the lid descends, and all extraneous matters are brushed away.

The opinion above noticed that the oblique muscles preside over the involuntary movements of the eye seems to have been suggested by a theory concerning the influence of the fourth nerve, which is distributed to the superior one. And



it is liable to the objection (among others) that, supposing the view respecting that nerve to be correct, there is no more reason for attributing involuntary movements to the inferior oblique than to the recti, which receive nerves from the same source. On the whole, it appears most probable that these muscles produce the revolving movements which have been described, and little more, and that they may with Dr. Jacob be regarded as "rotatory muscles," their office being, when acting together, to revolve the eye "round a longitudinal axis, directed from the anterior part of the orbit to its bottom."\* But, supposing them to act singly, the axis would, in all probability, be slightly altered during the rotation. So that under the influence of the superior muscle alone, while the eyeball was rotated, the pupil would at the same time be directed to the outer and lower side of the orbit; and, during the action of the inferior oblique, the rotatory movement of the eye would be attended with an inclination of the pupil upwards and inwards.

## MUSCLES OF THE NECK.

The muscles of the neck are numerous, and at first sight appear to be rather complex in their distribution. They may be grouped into sets as follows:—

- |  |                              |
|--|------------------------------|
| 1. The muscles placed along the side of the neck being, at least comparatively, superficial, viz., the platysma myoides, and sterno-mastoideus             | } Superficial region.        |
| 2. Those placed obliquely at the upper part of the neck, viz., digastricus, stylo-hyoideus, stylo-glossus, stylo-pharyngeus                                |                              |
| 3. Muscles placed towards the fore part, and above the hyoides, viz., mylo-hyoideus, genio-hyoideus, hyo-glossus, genio-hyo-glossus, and lingualis         | } Submaxillary region.       |
| 4. The muscles placed in front, lying beneath the os hyoides, viz., sterno-hyoideus, sterno-thyroideus, thyro-hyoideus, crico-thyroideus, and omo-hyoideus |                              |
| 5. Those placed deeply at the side and front of the vertebral column, viz., scaleni, rectus lateralis, rectus anticus major and minor, and longus colli    | } Genio-hyoid region.        |
|  |                              |
|  | } Sterno-hyoid region.       |
|  |                              |
|  | } Anterior vertebral region. |
|  |                              |
- All these are in pairs at each side.

*Dissection and general view of the Muscles of the Neck.*—The head being allowed to hang over a block placed behind the neck, and the side of the latter being turned forward, we may proceed to examine it as a separate region. In this view it presents itself to our notice as a quadrilateral space, bounded below by the clavicle, above by the margin of the jaw, and a line continued back from it to the mastoid process; before, by the median line, extended from the chin to the sternum, and behind, by another from the mastoid process to near the external end of the clavicle. Now, the whole space is divided into two triangles by the sterno-mastoid muscle, which runs diagonally through its area. Each of these requires a particular examination; for in the upper triangle, whose base corresponds with the margin of the jaw, and whose apex lies at the sternum, is lodged the carotid artery; and in the external and inferior space, the base of which corresponds with the clavicle, the subclavian artery is placed in the situation in which it may be compressed or tied. When *proceeding with the dissection*, two incisions may be made through the skin; one directed transversely along the base of the lower maxilla to the mastoid process of the temporal bone; the other in the course of the sterno-mastoid, from the mastoid process to the sternum, so that the angular flap thus marked out may be raised and reflected forwards. By means of an incision made along the clavicle, another flap of skin may be turned backwards, and then the platysma will be exposed in its entire extent; the direction of its fibres should be carefully considered in reference to the operation of opening the jugular vein. If the point of the lancet be directed upwards and forwards in the course of its fibres, it will merely make a fissure between

\* "On Paralytic, Neuralgic, and other Nervous Diseases of the Eye. By Arthur Jacob, M. D." In Dublin Med. Press. 1841.



them, and when withdrawn they will contract and close over the wound in the vein; so that the operation is rendered ineffectual, and probably an ecchymosis will be produced. But if it be directed upwards and outwards, the fibres will be cut across and retract, so as to expose the vein and the aperture made in it.

The platysma being now reflected, the cervical fascia will be fully exposed, particularly if the trapezius be turned back. (See the description with other structures of the same kind.) When the platysma is dissected off the sterno-mastoid, we see lying on it the ascending nerves of the cervical plexus, and passing downwards the descending set. In the area of the internal superior triangular space, will be found the os hyoides and larynx and the muscles connected with them; together with the submaxillary gland and the large blood-vessels (carotid artery and jugular vein) enclosed with the vagus nerve in a sheath which has over it the nerves coursing to the infra-hyoid muscles. A smaller triangle is recognised within the larger space now described. It is circumscribed by the digastric muscle above, the omo-hyoid below, and the sterno-mastoid externally.

The external inferior triangular space, which is commonly said to be bounded by the sterno-mastoid, the trapezius, and the clavicle, will be found divided into two parts by the omo-hyoideus passing across it. The upper division contains the cervical nerves and several muscles. The lower and most important (supra-clavicular) part is very small, and is, in general, distinctly triangular. It is bounded by the sterno-mastoid and omo-hyoid as its sides, and the clavicle as its base; and contains the subclavian artery and the brachial nerves, with a part of the anterior scalenus muscle.

#### SUPERFICIAL CERVICAL REGION.

Two muscles are extended beneath the skin, along the side of the neck:—

The *platysma myoides* (*latissimus colli*,—Alb.; cutaneus; peaucier) is a flat, thin plane of muscular fibres, forming a fleshy membrane, placed immediately beneath the skin of the neck. Its fibres, which are pale and thin in their entire extent, commence in the cellular tissue, covering the upper part of the deltoid and pectoral muscles, and thence proceed upward and inwards over the clavicle, and upon the side of the neck, gradually narrowing and approaching the muscle of the opposite side. They pass over the margin of the inferior maxillary bone; some of them adhere to its external oblique line, becoming blended with the *depressores labii inferioris* and *anguli oris*; some incline inwards and mingle with those of the opposite platysma in front of the symphysis of the jaw, and even cross from one side to the other, those of the right side overlapping those of the left; whilst others farther back are prolonged upon the side of the cheek as far as the angle of the mouth, where they become blended with the muscles in that situation. In some subjects, a few fibres may be traced higher up on the face to the zygomatic muscles, or even to the margin of the *orbicularis palpebrarum*.

The platysma is covered by the skin, to which it is connected by cellular tissue, usually called the superficial fascia of the neck. It covers slightly the pectoralis major, its upper or clavicular portion, as well as the clavicular part of the deltoid, and the clavicle; higher up it lies upon the sterno-mastoid muscle, external jugular vein, the sheath of the great cervical vessels, the submaxillary gland, the labial artery, the body of the jaw-bone and the side of the cheek.

The *sterno-cleido-mastoid* muscle [*sterno-cleido-mastoideus*] (fig. 175,<sup>11</sup>) is extended, as it were, diagonally across the side of the neck,

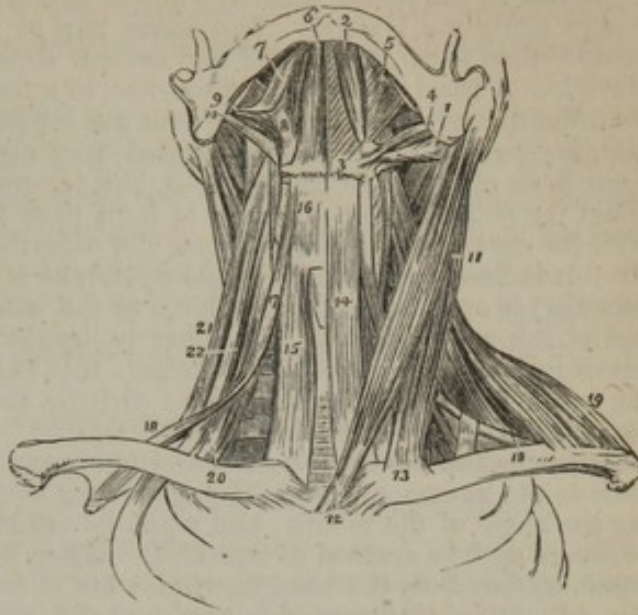


from the top of the sternum to the mastoid process behind the ear: it is thick and rounded at the middle, so as to be at all times prominent, particularly when in action, but becomes broader and thinner at its extremities. It arises from the anterior surface of the sternum and the anterior and upper part of the clavicle, at its inner third, the attachment to the former being by a thick rounded fasciculus composed of tendinous fibres at its cutaneous aspect, the rest being fleshy: The clavicular portion, separated at first from the preceding by a cellular interval, is flat, and in form somewhat triangular; it is composed of fleshy and aponeurotic fibres, which pass perpendicularly upwards, whilst the sternal part inclines backwards as it ascends, so that both become inseparably blended, below the middle of the neck, into a thick rounded muscle, which is finally inserted into the anterior border and external surface of the mastoid process, and for some way into the rough ridge behind it, by a thin layer of aponeurotic fibres.

The external surface of the muscle is covered by the platysma in the middle three-fifths of its extent, its upper and lower portions being left uncovered, so that its sternal origin and its insertion are covered only by the fascia and skin; part of the parotid gland overlaps it superiorly. In the middle it is crossed by the external jugular vein, and by the ascending superficial branches of the cervical plexus. It rests on part of the sterno-hyoid and sterno-thyroid muscles, crosses the omo-hyoid muscle, covers the cervical plexus of nerves and great cervical vessels in the lower part of the neck, and in the upper part the digastricus and stylo-hyoideus muscles, and spinal accessory nerve, which pierces it.—The two sterno-cleido-mastoidei are placed closely together at their sternal attachment, whilst their insertions are separated by the whole breadth of the basis of the skull.

The sterno-cleido-mastoid has been, and indeed still occasionally is, described in anatomical works as two muscles, under the names sterno-mastoideus and

[Fig. 175.]



The muscles of the anterior aspect of the neck; on the left side the superficial muscles are seen, and on the right the deep. 1. The posterior belly of the digastricus muscle. 2. Its anterior belly. The aponeurotic pulley, through which its tendon is seen passing, is attached to the body of the os hyoides. 3, 4. The stylo-hyoideus muscle, transfixed by the posterior belly of the digastricus. 5. The mylo-hyoideus. 6. The genio-hyoideus. 7. The tongue. 8. The hyo-glossus. 9. The stylo-glossus. 10. The stylo-pharyngeus. 11. The sterno-mastoid muscle. 12. Its sternal origin. 13. Its clavicular origin. 14. The sterno-hyoid. 15. The sterno-thyroid of the right side. 16. The thyro-hyoid. 17. The hyoid portion of the omo-hyoid. 18, 18. Its scapular portion; on the left side, the tendon of the muscle is seen to be bound down by a portion of the deep cervical fascia. 19. The clavicular portion of the trapezius. 20. The scalenus anticus of the right side. 21. The scalenus posticus. 22. The scalenus medius.—W.]



cleido-mastoideus.—The muscle varies much in breadth at the lower end, the variation being due altogether to the clavicular part, which in one case may be as narrow as the sternal tendon, while in another it reaches to the extent of three inches along the clavicle. The same part of the muscle may likewise, when broader than usual, be divided into several slips separated by intervals near the clavicle. A band of muscular fibres has, in a few instances, been found reaching from the trapezius to this muscle over the subclavian artery; their corresponding margins (which are usually separated by a considerable but varying interval) have been observed in contact.\*—A slender rounded and elongated muscle, of about the length of the sternum, is from time to time to be seen lying parallel with the outer margin of that bone, and over the inner part of the pectoral muscle. It is fleshy in the middle and tendinous at both ends, and one of these (the superior) is attached to the first bone of the sternum, in connexion with the tendon of the sterno-mastoid; the other is usually connected with the aponeurosis covering the rectus abdominis muscle. It is very rarely present on both sides of the same body. The names *rectus sternalis* and *sternalis brutorum* have been assigned to this "occasional" muscle.

*Actions.*—The lower part of the *platysma* can exert no action of much importance in the human subject. The upper part of the muscle may assist in depressing the angle of the mouth; and when its action is general the skin of the neck becomes slightly creased or wrinkled. When the two *sterno-mastoid* muscles act together, they bow the head forwards; but if one acts by itself, it is enabled by the obliquity of its direction to turn the head, and therefore the chin, to the opposite side. It has been said that this muscle can draw the head down to its own side, approximating the ear to the shoulder. But, to effect this, its action must be combined with that of some other muscle, as the *splenius*; for then, as the latter arises from the spinous processes, whilst the former comes from the sternum, both converging to the mastoid process, the head may, by their combined effort, be drawn down to the point intermediate between their attachments, namely, to the shoulder.

#### SUBMAXILLARY REGION.

The *digastric* muscle (fig. 175,<sup>1 2</sup>) (*digastricus*; *biventer maxillæ inferioris*,—*Alb.*; *mastoido-mentalis*) is placed in a curved direction across the upper part of the neck, a little below the margin of the lower maxillary bone. As its name implies, it consists of two fleshy bellies, united by a rounded middle tendon, each of which parts has a separate attachment. The posterior belly, which is longer than the anterior, arises from the digastric groove in the temporal bone and the fore part of the mastoid process: the anterior is inserted into a rough depression at the inside of the lower border of the jaw-bone, close to its symphysis, whilst the tendon is connected with the side of the *os hyoides* by a dense fascia, and by the fleshy fibres of the *stylo-hyoideus* muscle,<sup>3</sup> through which it (the tendon) passes. The posterior, or sub-mastoid portion, descends inwards and forwards, gradually tapering until it ends in the tendon; the anterior, or submental portion, arising from the tendon, passes upwards and forwards, gradually widening towards its insertion, where it is in contact with the *digastricus* of the opposite side. Now, as the side of the *os hyoides* is beneath both points of attachment, and nearly in the middle between them, the fleshy bellies, where they end in the tendon, must form an angle with one another.

The anterior belly, lying immediately under the fascia, rests on the *mylo-hyoideus* muscle, and is connected by dense fascia with its fel-

\* "The Anatomy and Operative Surgery of Arteries," by R. Quain, p. 186, and plate 25.



low of the opposite side; the posterior is covered by the mastoid process and the muscles arising from it, and crosses both carotid arteries and the jugular vein. Its upper margin bounds the submaxillary gland. The lower one forms one of the sides of the smaller anterior triangle of the neck.

The *stylo-hyoid* muscle (*stylo-hyoideus*) (figs. 175,<sup>34</sup>; 176,<sup>10</sup>) lies close to the posterior belly of the preceding muscle, being a little behind and beneath it. It *arises* from the middle of the external surface of the styloid process of the temporal bone, from which it inclines downwards and forwards, to be inserted into the os hyoides at the union of its great cornu with the body. Its fibres are usually divided into two fasciculi near its insertion, for the transmission of the tendon of the digastricus.

Its upper part lies deeply, being covered by the sterno-mastoid and digastric muscles, and by part of the parotid gland: the middle crosses the carotid arteries; the insertion is comparatively superficial.

This muscle is sometimes wanting; occasionally a second is present (*stylo-hyoideus alter*,—Alb.) The position too may be altered—it has been found beneath the external carotid artery instead of over that vessel.\*

The *stylo-glossus* (figs. 175,<sup>9</sup>; 176,<sup>9</sup>) lies higher up, and is also shorter than any of the three muscles which arise from the styloid process. Its direction is forwards and a little downwards, so that it becomes nearly horizontal. It *arises* from the styloid process near its point, and from the stylo-maxillary ligament, to which, in some cases, the greater number of its fibres are attached by a thin aponeurosis, and is inserted along the side of the tongue, its fibres expanding somewhat as they become blended with its substance; they overlay those of the hyo-glossus muscle, (the fibres of the two slightly decussating,) and a few are continued forwards into the lingualis.

This muscle lies very deeply beneath the parotid gland, and between the external and internal carotid arteries.—It occasionally is seen to arise from the inner side of the angle of the lower maxilla, and cases have been observed in which it was altogether absent.

*Stylo-pharyngeus* (figs. 175,<sup>10</sup> 176,<sup>11</sup>).—This is larger and longer than the other styloid muscles, and also more deeply seated; it extends from the styloid process downwards, along the side of the pharynx, slender and round at the upper part. It *arises* from the inner surface of the styloid process, near its root, from which it proceeds downwards and inwards to the side of the pharynx, where it passes under cover of the middle constrictor muscle, and gradually expanding, it detaches some fibres to the constrictors of the pharynx, and, having joined with the palato-pharyngeus, ends in the superior and posterior borders of the thyroid cartilage.

The external surface of the muscle is, in the upper part of its extent, in contact with the styloid process and stylo-hyoideus muscle and external carotid artery; in the lower, with the middle constrictor of the pharynx. Internally it rests on the internal carotid artery and jugular vein; but more inferiorly it is in contact with the mucous

\* The work on Arteries, before referred to, plate 12, fig. 5.



membrane of the pharynx. The glosso-pharyngeal nerve is close to the muscle, and crosses over it in turning forward to the tongue.

*Actions.*—The *stylo-hyoidei* and *stylo-pharyngei* conspire in elevating the base of the tongue and the bag of the pharynx at the moment when deglutition is taking place, the latter pair of muscles tending at the same time to widen the pharynx. The peculiar mechanism of the *digastric* muscles enables them to contribute to the elevation of the os hyoides also; for when the two fleshy parts contract together, they come nearly into a straight line, and thereby draw up the bone just named, by means of the connexion of the middle tendon of the muscle with its cornu. As a preparatory measure, the mouth must be closed, and the lower jaw fixed, which is one of the first steps in the process of deglutition. If the os hyoides be kept down by the sterno-hyoideus, the anterior belly of the digastricus will serve to depress the lower jaw. The *stylo-glossi* muscles retract the tongue; they also act on its margins, and elevate them; if the *genio-hyo-glossi* (fig. 176,) come into action at the same time, and draw down its raphe, or middle line, its upper surface will be converted into a groove.

#### GENIO-HYOID REGION.

The *mylo-hyoid* muscle (*mylo-hyoideus*) (fig. 175,<sup>a</sup>) is a flat triangular muscle, placed immediately beneath the anterior belly of the digastric, and extended from the inside of the inferior maxilla to the os hyoides; its base, or broader part, being above, the apex being below. It *arises* from the mylo-hyoid ridge, along the inner surface of the lower jaw. The posterior fibres incline obliquely forwards as they descend to be inserted into the body of the os hyoides; the rest proceed, with different degrees of obliquity, to join at an angle with those of the corresponding muscle, forming, with them, a sort of raphe along the middle line, from the symphysis of the jaw to the os hyoides.

The external surface of the mylo-hyoid muscle (which in the erect position of the head is inferior) is covered by the digastricus and submaxillary gland and submental artery; the internal, which looks upwards and inwards to the mouth, conceals the *genio-hyoideus* and part of the *hyo-glossus* and *stylo-glossus* muscles, the ninth and gustatory nerves, and the sublingual gland with the duct of the submaxillary; its posterior border alone is free and unattached, and behind it the duct of the submaxillary gland turns in its passage to the mouth.

The two muscles of this name, by their junction in front, and by the inclination of the plane which they form, support the mucous membrane of the mouth and the tongue, constituting a muscular floor for that cavity.

The *genio-hyoid* muscle (*genio-hyoideus*) (fig. 175,<sup>b</sup>; fig. 176,<sup>d</sup>) is a narrow muscle concealed by the preceding, and lying close to the median line. It *arises* from the inside of the symphysis of the chin (its inferior submental tubercle), and thence descends in contact with the corresponding muscle, and increasing a little in breadth, to be *inserted* into the body of the os hyoides. This pair of muscles lies between the mylo-hyoideus and the lower or free border of the *genio-hyo-glossus*.

The *hyo-glossus* (fig. 176,<sup>e</sup>) is a flat, thin four-sided band of muscular fibres, extended upwards upon the side of the tongue from the lateral portion of the os hyoides. It *arises* from the whole length of the great cornu of the os hyoides, and from part of the body of that bone, and sometimes derives fibres from the small cornu. From this the muscular fibres incline upwards and outwards, (those from the body of the



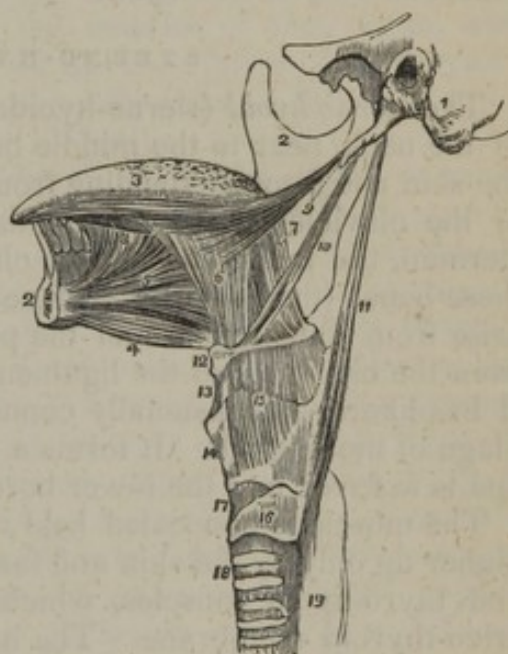
bone overlapping the others a little,) to be *inserted* into the side of the tongue, where they expand, becoming blended with its substance: the direction of this muscle is almost vertically upwards, and that of the stylo-glossus horizontally forwards, so that they decussate upon the side of the tongue.

The hyo-glossus muscle is covered by the digastric and mylo-hyoid, and by other structures just mentioned as lying beneath the latter muscle. It covers the genio-hyo-glossus and the origin of the middle constrictor of the pharynx, together with the lingual artery and glosso-pharyngeal nerve.

Until a comparatively late period, the hyo-glossus was described by anatomists as three muscles; and they were named by Albinus, from the part of the hyoid bone with which they are each connected, basio-glossus, cerato-glossus, and chondro-glossus. The name by which the whole, considered as one muscle, is now usually known, was suggested by Winslow.

The *genio-hyo-glossus* (fig. 176,<sup>a</sup>) is so called from its triple connexion with the chin, os hyoides, and tongue. The muscle forms a flat, triangular plane of fleshy fibres, placed vertically in the median line, the apex of the triangle being represented by its origin from the inside of the symphysis of the lower jaw, the base by its insertion along the whole length of the tongue from its point to its root, for the fibres spread out radiating like the ribs of a fan; one of the sides (the lower one) corresponds with the border which extends from the symphysis to the os hyoides, the other (upper and anterior) with the frænum linguæ. The inner surface is in contact with the corresponding muscle, the external being covered by those last described. It *arises*, by a short tendon, from the superior submental tubercle on the inner side of the symphysis of the chin. To this the fleshy fibres succeed and diverge from one another, the inferior ones passing down to the os hyoides, above which a few are continued into the side of the pharynx; the anterior fibres are directed upwards to the tip of the tongue, and the rest proceed in different directions to the under surface of the tongue, with which they are blended in its entire length from base to apex.

[Fig. 176.



The styloid muscles and the muscles of the tongue. 1. A portion of the temporal bone of the left side of the skull, including the styloid and mastoid processes, and the meatus auditorius externus. 2, 2. The right side of the lower jaw, divided at its symphysis; the left side having been removed. 3. The tongue. 4. The genio-hyoideus muscle. 5. The genio-hyo-glossus. 6. The hyo-glossus muscle, its basio-glossus portion. 7. Its cerato-glossus portion. 8. The anterior fibres of the lingualis issuing from between the hyo-glossus and genio-hyo-glossus. 9. The stylo-glossus muscle, with a small portion of the stylo-maxillary ligament. 10. The stylo-hyoid. 11. The stylo-pharyngeus muscle. 12. The os hyoides. 13. The thyro-hyoidean membrane. 14. The thyroid cartilage. 15. The thyro-hyoideus muscle arising from the oblique line on the thyroid cartilage. 16. The cricoid cartilage. 17. The crico-thyroidean membrane, through which the operation of laryngotomy is performed. 18. The trachea. 19. The commencement of the œsophagus.—W.]



The internal surface of the muscle is in contact with that of its fellow, from which it is at first separated towards the posterior part of the tongue by the fibro-cellular structure which runs for some way through the middle of that organ, but both become closely adherent towards their termination. The external surface is in contact with the lingualis, hyo-glossus, and stylo-glossus, the sublingual gland, the ranine artery, and the gustatory and motor nerves of the tongue.

—The proper or “intrinsic” lingual muscles will be described with the other structures of the tongue.

*Actions.*—The muscles that pass from the jaw-bone to the os hyoides are ordinarily employed in elevating the latter, and with it the base of the tongue, more particularly in deglutition. The genio-hyo-glossi, by means of their posterior and inferior fibres, can draw up the os hyoides, at the same time bringing it and the base of the tongue forwards, so as to make its apex protrude beyond the mouth. The anterior fibres will, subsequently, act in retracting the tongue within the mouth. The mylo-hyoidei may be compared to a movable floor or bed, which closes in the inferior and anterior part of the mouth, at the same time serving to sustain the body of the tongue.

#### STERNO-HYOID REGION.

The *sterno-hyoid* (sterno-hyoideus) (fig. 175,<sup>14</sup>) lies at the fore part of the neck, near to the middle line, and in part immediately beneath the skin and fascia, extending from the thoracic surface of the sternum or the clavicle to the os hyoides. The *origin* varies between the sternum, the inner end of the clavicle, and the ligament connecting these bones (the posterior surface of each). Thus: it will be found to arise from the sternum and the posterior sterno-clavicular ligaments; from the clavicle and the ligament; or from the last-named bone only. It has likewise occasionally connexion to a small extent with the cartilage of the first rib. It forms a flat, narrow band of muscular fibres, and is *inserted* into the lower border of the body of the os hyoides.

The muscle is concealed below by the sternum and sterno-mastoid, higher up only by the skin and fascia; and it lies on the sterno-thyroid and thyro-hyoid muscles, which it partly conceals, as well as the crico-thyroid membrane. The inner border is in contact with that of the corresponding muscle towards the middle of its extent, but is separated from it by an interval superiorly, and usually by a larger one near the sternum; the outer margin is in contact with the omo-hyoideus near the os hyoides.—The muscular fibres are, in many cases, interrupted by a transverse tendinous intersection.

The *sterno-thyroid*, (sterno-thyroideus; sterno-thyreöideus,—Alb.) (fig. 175,<sup>15</sup>) broader and shorter than the preceding, behind which it lies, *arises* lower down than that muscle, from the thoracic surface of the first bone of the sternum, from which it ascends, diverging a little from the corresponding muscle, to be *inserted* into the oblique line on the side of the ala of the thyroid cartilage.

The greater part of its anterior surface is concealed by the sternum and the sterno-hyoid, as well as by the sterno-mastoid; the posterior rests on the vena innominata, the lower part of the common carotid artery, the trachea, and the thyroid gland. The inner margin is in close contact with the muscle of the other side in the lower part of the neck and behind the sternum.



This muscle is often partially crossed by transverse or oblique tendinous lines.—At the upper extremity a few fibres are often found to blend with the other muscles connected with the same part of the thyroid cartilage (the thyro-hyoid and inferior constrictor of the pharynx), and it sometimes happens that a few extend to the os hyoides.

*Thyro-hyoid* muscle (thyro-hyoideus; hyo-thyreöideus,—Alb.) (fig. 175,<sup>16</sup>).—This appears like a continuation of the preceding muscle, as it *arises* from the oblique line on the side of the thyroid cartilage, and thence passes up to be *inserted* into the lower border of the great cornu and the body of the os hyoides (a portion of each). Some fibres may be found to continue upwards from the sterno-thyroid.—It is concealed by the sterno-hyoid and omo-hyoid muscles, and rests on the ala of the thyroid cartilage, and on the thyro-hyoid membrane; between the latter structure and the muscle are placed the superior laryngeal nerve and artery before they enter to the larynx.

The *crico-thyroid* comes into view with the muscles now under observation. But, as it belongs exclusively to the larynx, the account of it will be more fitly placed among the muscles of that organ, with which it is associated in function.—See the description of the larynx.

The *omo-hyoid* (omo-hyoideus; coraco-hyoideus—Alb.; scapulo-hyoideus) (fig. 175,<sup>17 18</sup>) is in structure a digastric muscle, as it consists of two bellies, united by a tendon. One of these (the upper and inner one) lies close to the external border of the sterno-hyoideus muscle, and is covered only by the platysma and fascia; the other is deeply seated, being concealed, in the greater part of its extent, by the clavicle and sterno-mastoid. It *arises* from the upper border of the scapula, near the supra-scapular notch, and from occasionally, likewise, the ligament which crosses it. From thence the muscle, forming a narrow, flat fasciculus, inclines forwards across the root of the neck, where it suddenly changes its direction, and ascends almost vertically, to be *inserted* into the lower border of the os hyoides, at the union of its body and cornu. The two parts of the muscle here described form an angle, where they lie behind the sterno-mastoid, and are connected to each other by a tendon, which varies much in length and form in different subjects. The tendon is enclosed within two lamellæ of the deep cervical fascia, which, after forming a sort of sheath for it, are prolonged down, and become attached to the cartilage of the first rib. It is by this mode of connexion that the angular position of the muscle is maintained.

The omo-hyoid crosses over the scaleni muscles, the cervical nerves, the sheath of the common carotid artery and jugular vein with the nerves lying on it, and the sterno-thyroid and thyro-hyoid muscles. It subdivides the two large triangles into which the side of the neck is formed by the sterno-mastoid in the manner stated at page 349.

Deviations from the ordinary arrangement and size are not uncommon in the omo-hyoid. One of the most frequent is the decrease of the extent of tendinous intersection which may be found to intercept only a few of the muscular fibres; and it may be altogether wanting. The muscle occasionally reaches only from the clavicle to the os hyoides, arising from the former bone about its middle, so that the posterior belly is absent.\* In one case, on the other hand, the posterior

\* See "Anatomy and Oper. Surg. of Arteries," by R. Quain, p. 186, plate xxv.



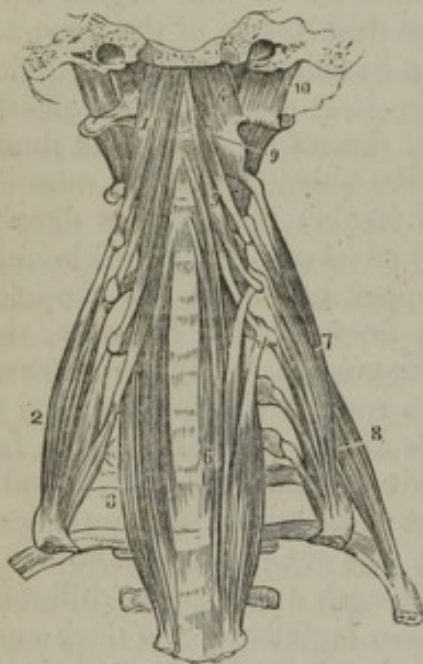
part alone was present, and it was connected to the hyoid bone by a band of fascia.

*Actions.*—All the individuals of this group of muscles take their fixed point below, and therefore conspire in being depressors of the larynx and os hyoides, for they draw down these parts, as deglutition is being performed. As a preparatory measure to swallowing, the pharynx is drawn up, so also is the os hyoides; and, moreover, as a means of security, the larynx at the same moment is made to ascend, so as to be brought under cover of the epiglottis. After the ascent has been effected, the parts do not return to their original position by the mere relaxation of the elevators; they are drawn down by the action of the five muscles just described. The thyro-hyoideus is the only one of them that can act as an elevator; for when the os hyoides ascends, this muscle can draw upwards the thyroïd cartilage with it.

#### VERTEBRAL REGION (LATERAL).

The *anterior scalenus* (scalenus anticus; scal. prior.—Alb.), (figure 175,<sup>20</sup>; fig. 177,<sup>9</sup>) lies deeply at the side of the neck, behind and

[Fig. 177.



beneath the sterno-mastoid muscle. It arises by a flat, narrow tendon, from a rough surface (more or less prominent in different cases) on the inner border and upper surface of the first rib, from which its fleshy fibres ascend vertically, to be inserted into the anterior tubercles of four cervical vertebræ, from the third to the sixth inclusive.

The muscle is partly covered by the sterno-mastoid (a small part only projecting behind its outer border), and the clavicle, and is crossed by the omohyoid. The lower part separates the subclavian artery and vein; the latter being in front of the muscle, and the former with the brachial nerves behind it. To its inner side lie the jugular vein and the branches of the subclavian artery.

The prævertebral group of muscles of the neck. 1. The rectus anticus major muscle. 2. The scalenus anticus. 3. The lower part of the longus colli of the right side; it is concealed superiorly by the rectus anticus major. 4. The rectus anticus minor. 5. The upper portion of the longus colli muscle. 6. Its lower portion; the figure rests upon the seventh cervical vertebra. 7. The scalenus medius. 8. The scalenus posticus. 9. One of the intertransversarii muscles. 10. The rectus capitis lateralis.—W.]

The *middle scalenus*, (scalenus medius,) (fig. 175,<sup>22</sup>; fig. 177,<sup>7</sup>) is larger and longer than the preceding muscle, from which it is separated below by the subclavian artery, and above by the cervical nerves, as they issue from the intervertebral foramina. It arises from the first rib, a little behind the anterior muscle of the same name, the interval on the rib being slightly grooved for the large artery just named. The fleshy fibres ascend along the sides of the vertebral column, and are inserted by tendinous processes, into the posterior tubercles of the last six, or it may be, to all the cervical vertebræ.



The middle scalenus is covered partly by the sterno-mastoid, and is crossed by the clavicle, the omo-hyoid muscle, and arterial branches. To the inner side, and intervening between this muscle on the one hand and the anterior scalenus and rectus major on the other, are the cervical nerves as they issue from the foramina; to the outer side lies the levator anguli scapulæ with the posterior scalenus muscle.

The *posterior scalenus* (fig. 177,<sup>8</sup>) (*scalenus posticus*).—This is the smallest of the three *scaleni* muscles, and is deeply placed behind that last described, in some cases blending with it. It *arises* by a thin tendon from the second rib between the tubercle and angle, and after enlarging as it ascends, divides into three or two small tendons, which are fixed into the transverse processes of as many of the lowest cervical vertebræ on their posterior tubercles.

Two accessory or supernumerary bundles of muscular fibres are occasionally observed in contact or connexion with the preceding muscles, of which they in general appear to be detached parts. The anterior of these (*scalenus minimus* of Albinus), lying between the anterior and the middle scalenus, is placed behind the subclavian artery interposed between the vessel and the large nerves. It is but partially separated from the anterior scalenus, and apparently results from the splitting of this muscle at the lower end by the passage of the subclavian artery through it.\* The second accessory muscle (*scalenus lateralis*,—Alb.) is situated between the middle and posterior *scaleni*. After arising from the second rib or the first, it ends in tendons varying in number in different cases, and is connected to the vertebræ with the two muscles between which it lies, or close to them.

There is much difference among anatomical writers of authority as to the number of these muscles.† The difference appears to depend chiefly on the fact that one or more (the number varying in different instances) of the short clefts of the upper part of the muscles happen occasionally to be continued to the lower end, as occurs so frequently in the muscle next behind the *scaleni*, viz., the levator anguli scapulæ. Something, too, depends on the degree in which the cellular membrane intervening between the muscular bundles happens to be removed.

*Actions*.—These muscles draw down the transverse processes of the cervical vertebræ, and thereby bend that part of the spinal column to one side. The *intertransversales*,<sup>9</sup> and *rectus lateralis*,<sup>10</sup> of each side act in the same way, all conspiring to incline the head as well as the vertebræ laterally. This movement may be alternated by bringing the opposite muscles into action. If both act together, the head and spine will be maintained erect. When the *scaleni* take their fixed points above, they draw on the first ribs, rendering them fixed, as a preparatory step to making a forcible inspiration.

#### VERTEBRAL REGION (ANTERIOR).

This includes the muscles placed in front of the spine upon the cervical and upper dorsal vertebræ; viz., the *rectus capitis anticus major* and *minor*, with the *longus colli*.

\* See the work on arteries before referred to, p. 151, and plate xxi.

† The *scaleni* were originally looked on as a single muscle perforated by the subclavian artery and nerves (Vesalius, l. 2, c. 38); and the name "triangular" or "scalene" was applied to the mass (Spigelius, l. 4, c. 7). Cheselden speaks of one muscle dividing into two parts. Cowper (Myot. reform. p. 52) describes three; Winslow (sect. 3, § 574) two—but the anterior scalenus of this author consists of two branches separated by the subclavian artery and the brachial nerves; Albinus (and he is followed by Sæmmerring) five—those mentioned in the text, with the accessories. Haller (El. Physiol. l. 8, sect. 1, § 20), remarked the "*auctorum dissidia*," and, from his own observation, named seven. The modern French anatomists, joining the middle and posterior muscles, admit the presence of but two. While the plan pursued in this work, which has been modified from Albinus, accords with that of Meckel, Hildebrandt and Weber, and more recent German anatomical writers, as well as, in great part at least, Sabatier and Fyfe.



The *rectus capitis anticus major*, (fig. 177,<sup>1</sup>) appears like a continuation of the anterior scalenus, being prolonged upwards from the points at which that muscle ceases. *Arising* from the anterior tubercles of the transverse processes of four cervical vertebræ (from the third to the sixth inclusive) by so many tendinous processes, it ascends, converging somewhat to the corresponding muscle, and is *inserted* into the basilar process of the occipital bone, in front of the foramen magnum. It is tendinous and fleshy in its structure.

The anterior surface supports the pharynx, the sympathetic nerve, and the great cervical vessels, (the carotid artery, the jugular vein,) with the vagus nerve, or rather the sheath which encloses it. The posterior surface overlays part of the longus colli, and the rectus anticus minor, also the articulation of the second with the first vertebra and of the latter with the occipital bone. The muscles of opposite sides are considerably nearer one to the other at their upper than their lower extremities.

The *rectus capitis anticus minor* (fig. 177,<sup>4</sup>) is a short, narrow muscle, lying behind the superior part of the preceding, between it and the ligament connecting the first vertebra to the occiput. It *arises* from the fore part of the lateral mass of the atlas and a little from the root of its transverse process, and is *inserted* into the basilar process, between the margin of the foramen magnum and the preceding muscle, but a little farther out than the latter.

The *rectus lateralis* (fig. 177,<sup>10</sup>) is a short flat muscle placed between the transverse process of the atlas and the occipital bone. It *arises* from the upper surface of the transverse process of the atlas, and is *inserted* into the jugular process of the occipital bone.—The anterior surface supports the internal jugular vein at its exit from the skull, and the posterior is in relation with the vertebral artery. This little muscle and the rectus anticus minor may be considered as completing the series of intertransversales.<sup>9</sup>

*Longus colli*.—This muscle rests on the fore part of the spinal column, from the atlas to the third dorsal vertebra. It is narrowed and pointed at the extremities, but becomes wider along the middle part; it is compressed throughout, and appears to consist of three sets of fibres, differing in length and in direction—two being oblique, the third vertical. *a.* The superior oblique portion (fig. 177,<sup>5</sup>) arises, by a narrow, tendinous process, from the anterior tubercle of the atlas, from which its fibres descend obliquely outwards, to be inserted into the fore part of the transverse processes of the third, fourth, and fifth cervical vertebræ. *b.* The inferior oblique,<sup>3</sup> the smallest part of the muscle, extends obliquely inwards from the transverse processes of the fifth and sixth cervical vertebræ to the bodies of the first three dorsal. *c.* The vertical part,<sup>6</sup> is placed altogether on the bodies of the vertebræ, and is connected with the two preceding divisions, which are joined one to its superior and the other to its inferior extremity. It is fixed above to the bodies of the second, third, and fourth cervical vertebræ; and the tendinous and fleshy fibres, derived from these attachments, pass vertically downwards, to be inserted into the bodies of the three lower cervical vertebræ and the three upper dorsal. The two muscles of



this name are separated by an interval inferiorly, but are joined one to the other at their superior extremities. They consist of tendinous and fleshy fibres; the former occupy the anterior surface, particularly at the extremities, some being also deep-seated; and the fleshy fibres, which are in general short, are placed obliquely between them. These muscles support the pharynx, the œsophagus, the sympathetic nerves, the carotid arteries, and the eighth pair of nerves.

*Actions.*—The anterior recti muscles are the natural antagonists of those placed at the back of the neck. They restore the head to its natural position when it has been drawn backwards by the posterior muscles, and, continuing their effort, bow it slightly forwards. Beneath the base of the skull, and at opposite points, we find short and straight muscles, two in front (recti antici), two behind (rectus posticus, major and minor), one on each side (rectus lateralis), which are the direct agents in the restricted motions that take place between the head and the first vertebra. The horizontal movement of the head is effected by the obliqui, particularly by the inferior one. It is obvious that, if the inferior oblique acted by itself, the first vertebra only would be rotated on the second, the head remaining unmoved; but the recti minores and the superior oblique muscle conspire to fix the skull on the first vertebra, and thereby communicate to it any movement impressed on the latter by the inferior oblique muscle.

#### PHARYNGEAL REGION.

We have here the following muscles forming a hollow bag, open in front, the pharynx; viz., constrictor superior, constrictor medius, constrictor inferior, together with the stylo-pharyngeus and palato-pharyngeus.

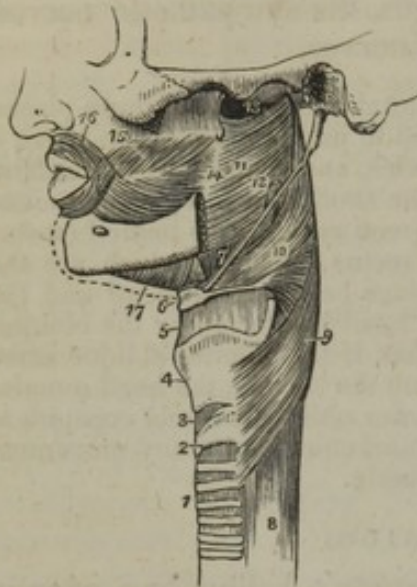
*Dissection.*—After having examined the sides and fore part of the neck, when you are about to dissect the pharynx, larynx, and soft palate, proceed as follows:—Cut across the trachea and œsophagus a little above the sternum, and draw both together forwards. There then can be no difficulty in detaching the pharynx from the muscles in front of the vertebral column, as they are merely connected by loose cellular tissue. When this is done, a piece of cloth should be carried deeply to the base of the skull, and drawn across the pharynx, to serve as a retractor whilst the saw is being used. The edge of the saw should, in the next place, be applied behind the styloid processes, so as to cut through the base of the skull, from below upwards, thereby detaching the face, with the pharynx and larynx all pendent from beneath it. The pharynx should be stuffed, to render its muscles tense. When its exterior is sufficiently examined, a longitudinal slit made along the middle line posteriorly will expose its cavity, and that of the mouth and larynx.

The pharynx is extended from the centre of the base of the skull to the œsophagus, with which it is continuous, and placed in front of the vertebral column, between the great vessels of the neck; it is immediately behind the nasal fossæ, the mouth, and larynx. The posterior and lateral parts of the pharynx are loosely connected to the adjacent structures by cellular tissue, and anteriorly it presents the several apertures that lead into the nose, mouth, and larynx. Its structure is made up, externally, of muscular fibres, (disposed in a very peculiar way, being formed into three lamellæ on each side, and partially overlapping one another, the lowest being the most superficial,) and, internally, of mucous membrane, prolonged from the mouth and nares. These layers of muscle are called the constrictors of the pharynx; they have likewise received other names, taken from their points of



attachment, which will be noticed in the detailed description of each muscle. The constrictors form the lateral and posterior boundary of the cavity, and as this is continuous or communicates with the nasal

[Fig. 178.



A side view of the muscles of the pharynx. 1. The trachea. 2. The cricoid cartilage. 3. The crico-thyroid membrane. 4. The thyroid cartilage. 5. The thyro-hyoidean membrane. 6. The os hyoides. 7. The stylo-hyoidean ligament. 8. The œsophagus. 9. The inferior constrictor. 10. The middle constrictor. 11. The superior constrictor. 12. The stylo-pharyngeus muscle passing down between the superior and middle constrictor. 13. The upper concave border of the superior constrictor; at this point the muscular fibres of the pharynx are deficient. 14. The pterygo-maxillary ligament. 15. The buccinator muscle. 16. The orbicularis oris. 17. The mylo-hyoideus.—W.]

stricter, where both muscles meet on the thyroid cartilage. The two laryngeal nerves pass inwards to the larynx, close respectively to the upper and lower margins of this constrictor—one being interposed between it and the middle constrictor, the other between it and the œsophagus.

The inferior constrictor was described by the older anatomists as two muscles which received various names, the most appropriate of these being thyro- or thyreo-pharyngeus and crico-pharyngeus.

The *middle constrictor*, (constrictor medius,—Alb.; hyo-pharyngeus,) (fig. 178,<sup>10</sup>) smaller than the preceding, is triangular or fan-shaped. It arises from the side of the great cornu of the os hyoides, also from its smaller cornu. From these points of attachment the fibres proceed backwards, diverging from one another, and are blended with those of the corresponding muscle along the middle line. The lower fibres incline downwards, and are concealed by the inferior muscle; the

fossæ, the mouth, and the larynx, the anterior margins of the muscles are connected on each side successively with the outer part of the posterior nares, the boundary of the mouth, the lower maxilla, the tongue, the hyoid bone, and the large cartilages of the larynx. The lowest muscle, being the most superficial, will most conveniently be examined first.

The *inferior constrictor* of the pharynx (pharyngis constrictor inferior,—Alb.; laryngo-pharyngeus,—Fyfe) (fig. 178,<sup>9</sup>) arises from the external surface of the cricoid cartilage, and from the oblique ridge on the side of the great ala of the thyroid. From these attachments the fibres curve backwards and inwards, converging to those of the corresponding muscle of the opposite side, with which they unite along the middle line. The direction of the inferior fibres is horizontal, concealing and overlapping the commencement of the œsophagus; the rest ascend with increasing degrees of obliquity, and cover the lower part of the middle constrictor.

The outer surface of the muscle is in contact at the side of the larynx with the thyroid body, the carotid artery, and the sterno-thyroid muscle, from which last some fibres are continued into the con-



middle run transversely; the rest ascend and overlap the superior constrictor.

This muscle is separated from the superior constrictor by the stylo-pharyngeus muscle and the glosso-pharyngeal nerve, and from the inferior constrictor by the superior laryngeal nerve. Near its origin it is covered by the hyo-glossus muscle, the lingual artery being interposed; and it covers the superior constrictor, the stylo-pharyngeus, the palato-pharyngeus, and the mucous membrane.

The portions of this muscle derived from different places of origin were at one time described as distinct muscles, under names taken from those parts, *e. g.* cerato-pharyngeus, chondro-pharyngeus, &c.

Fibres of the middle constrictor have likewise been observed to arise from one of the following parts, *viz.*, the body of the os hyoides, the thyro-hyoid ligament (syndesmo-pharyngeus of Douglas), and the stylo-hyoid ligament; and a few are occasionally continued into it from the genio-hyo-glossus muscle. The upper extremity of the two middle constrictors, where they join, has been found (Albinus) connected to the base of the skull by a fibrous band.

The *superior constrictor* (constrictor superior,—Alb.; cephalo-pharyngeus,—Fyfe,) (fig. 178,<sup>11</sup>) is attached slightly to the side of the tongue (in connexion with the genio-hyo-glossus), and to the extremity of the mylo-hyoid ridge, also to the pterygo-maxillary ligament,<sup>14</sup> and the lower third of the internal pterygoid lamella. From these different points the fibres of the muscle curve backwards, becoming blended with those of the corresponding muscle along the middle line, and are also prolonged, by means of the posterior aponeurosis, to the basilar process of the occipital bone. The upper margin curves beneath the levator palati molliis and the Eustachian tube, and the space intervening between this concave margin of the constrictor and the base of the skull is closed by fibrous membrane.

In contact with the outer surface of this muscle are the internal carotid artery, and the large nerves, as well as the middle constrictor, which overlaps a considerable portion, and the stylo-pharyngeus, which enters to the pharynx between the two constrictors. It conceals the palato-pharyngeus and the tonsil, and is lined by mucous membrane.

This, like the other constrictors, has been described as several muscles, each separate origin being considered a distinct muscle, named usually by prefixing the name of the place of its origin to the word pharyngeus.

*Salpingo-pharyngeus* (Santorini). Under this name is described a small muscle, which arising from the Eustachian tube, as the name implies, (σαλπιγξ, a trumpet,) descends in the interior of the pharynx towards its back part, and, after joining with the palato-pharyngeus, is lost in the muscular structure of the cavity. This little muscle is often indistinct, and is frequently absent.

By the peculiar mode of attachment of the constrictor muscles, the bag of the pharynx is completed on the sides and posteriorly, and left open in front; and by the connexion of the upper constrictor with the pterygoid processes, and with the buccinator, (through the pterygo-maxillary ligament,) a continuous smooth surface is established from the nasal fossæ and from the commissure of the lips along the side of the mouth and fauces.—Besides the constrictors, we find at each side, in the pharynx, two other muscular fasciculi. One of these derived



from the stylo-pharyngeus,<sup>12</sup> which is insinuated between the adjacent borders of the superior and middle constrictor, has been already described (page 353). The other, the palato-pharyngeus, lies more internally, and shall be described with the muscles of the palate (page 366).

*Actions.*—The pharynx is drawn up when deglutition is about to be performed, and at the same time dilated in opposite directions. It is widened from side to side by the stylo-pharyngei, which are farther removed from one another at their origin than at their insertion, and can thereby draw outwards the sides of the cavity; and as the os hyoides and larynx are carried forwards in their ascent, the breadth of the pharynx from before backwards is also increased, inasmuch as its fore part is drawn in the same direction, by reason of its connexion with the larynx. When the morsel of food is propelled into the pharynx, the elevator muscles relax, the bag descends, and then the fibres of its own muscular wall begin to contract, and force the mass down into the œsophagus.

When we contrast the structure of the pharynx with that of the œsophagus, comparing the complex arrangement observable in the one with the simplicity of the other, we see abundant evidence of its being intended for something more than a mere recipient and propellant of such matters as are to be conveyed to the stomach. It exerts an important influence in the modulation of the voice, in the production of the higher tones of which it is brought into action.

The description of the muscular structure of the pharynx may be given briefly as follows: it may be considered as a single muscle, consisting of two symmetrical halves, united by a raphé posteriorly along the middle line, the union extending from the basilar process to the œsophagus. The superior fibres curve downwards and outwards, to be fixed to the lower third of the internal pterygoid plate, to the pterygo-maxillary ligament, and to the mylo-hyoid ridge and side of the tongue; the middle set of fibres, broad, and expanded posteriorly at the line of junction, converge as they proceed forwards to be attached to the cornu of the os hyoides and the stylo-hyoid ligament, and are so disposed, that part is concealed by the succeeding set, whilst others overlap the preceding muscle. The lower fibres proceed forwards in the same way, to be attached to the side of the cricoid and thyroid cartilages. The tube is thus shown to be complete posteriorly and at the sides, being open in front, where it communicates with the nose, mouth, and larynx.

When the pharynx is slit open, we expose the cavities just mentioned, and the apertures which lead into them, as well as the orifices of the Eustachian tubes. (Fig. 179.)

#### PALATAL REGION.

The soft or pendulous palate (*velum pendulum palati*) forms a partial and movable curtain between the mouth and the pharynx. Its upper border is straight, and attached to the posterior margin of the palate bones; the lower presents, when viewed from before, a curved or arched border at each side, and in the middle a conical depending process, called the *uvula*. From this, as from a common point of departure, two curved prominent lines will be observed to extend, one at each side, and proceed downwards and forwards, to the side of the tongue. These correspond with the lower or free border of the palate, and mark the limits of the cavities of the mouth and pharynx, for they represent a narrowed or constricted line between them, which is termed the *isthmus* of the fauces. Farther back two other curved lines project, one at each side, which also commence at the uvula, and extend downwards and backwards along the sides of the pharynx. They diverge from the preceding curved lines so as to leave between



them an angular interval, in which is lodged the *tonsil* or *amygdala*. The curved lines here described are usually called the *arches* of the palate, one pair being anterior to the other, and also more prominent.

The soft palate consists of five pairs of muscles, enclosed by mucous membrane.

*Dissection.*—When the pharynx has been dissected and examined, it may be opened by an incision along the middle line or *raphé*; this will expose the soft palate: let the uvula be drawn down so as to render it tense; then the small muscles of the palate are at once exhibited by detaching the mucous membrane. The levatores palati are brought into view by merely removing the mucous membrane from the posterior surface of the soft palate; the circumflexi will be found along the internal pterygoid plates: their aponeuroses, which form the principal support of the soft palate, will be seen in front by dissecting off a thick layer of glandular substance, which is continued downwards upon it beneath the mucous membrane.

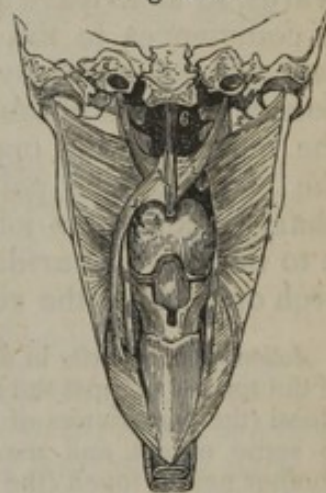
*Levator palati mollis* (fig. 179,<sup>1</sup>).—This is a long, thin, flat muscle, which, after passing to the interior of the pharynx above the concave upper margin of the superior constrictor, occupies the posterior surface of the soft palate. It arises from the extremity of the petrous portion of the temporal bone, before the orifice of the carotid canal, and from the cartilaginous part of the Eustachian tube. The two muscles, converging as they descend, join one with the other at the middle of the palate, and blend with the other structures; at the same time that they are placed behind them with the exception of the azygos uvulæ and some fibres of the palato-pharyngeus.

This muscle has been described by anatomists under the names (among others) *salpingo-staphylinus* and *petro-salpingo-staphylin*, which express its points of attachment more or less completely.

*Circumflexus* or *tensor palati*, (*pterygo-staphylinus*; *spheno-salpingo-staphylin*.) (fig. 179,<sup>2</sup>) presents two portions which differ in their direction and relations. The muscle arises broad and thin from the small fossa (*navicularis*) at the root of the internal pterygoid plate of the sphenoid bone, from the anterior surface of the cartilage of the Eustachian tube, and from the bone in immediate connexion with it. From these points it descends perpendicularly between the internal pterygoid muscle and the osseous lamella of the same name, and ends in a tendon, which winds round the hamular process; there it inclines inwards, and expands at the same time into a broad aponeurosis, the fibres of which are inserted into the transverse ridge on the under surface of the palate process of the palate bone, and on reaching the middle line they unite with the aponeurosis of the corresponding muscle of the opposite side.

*Azygos uvulæ* (*Morgagni*) (fig. 179,<sup>3</sup>) (*palato-staphylinus*—Douglas)

Fig. 179.



The pharynx having been laid open from behind, the constrictors were turned outwards, and the mucous membrane was removed from them and from the soft palate. The posterior nares, the tongue, and the opening into the larynx are seen, together with the following muscles, viz.—1. Levator palati mollis. 2. Circumflexus palati. 3. Azygos uvulæ. 4. This number rests on the tongue; it points to the palato-glossus. 5. Palato-pharyngeus. 6. Posterior naris of one side.



was so called from its having been supposed to be a single muscle; but there are really two thin fasciculi, separated by a slight cellular interval above, which usually unite towards the lower part. Each arises from the tendinous structure of the soft palate, and, it may be from the pointed process (spine) of the palate plate, and, descending vertically, becomes blended with the other structures in the uvula. The muscle of the uvula lies behind the other muscles of the soft palate.

*Palato-glossus*, or *constrictor isthmi faucium* (fig. 179,<sup>4</sup>).—This small muscle inclines from the uvula forwards and outwards in front of the tonsil to the side of the tongue, where it may be considered as inserted. In the soft palate some of the fibres of this little muscle are continued into that of the opposite side, so that the two palato-glossi form to a certain extent but one muscle. It is merely covered by the mucous membrane, which it renders prominent, so as to form the anterior arch of the palate.

The *palato-pharyngeus* (fig. 179,<sup>5</sup>) arches downwards and backwards, so as to leave an angular interval between it and the preceding. It commences in the soft palate, where the fibres are separated into two unequal parts by the levator palati mollis, and are partly connected with the fibrous structure of the palate, partly continuous with the muscle of the opposite side. Descending behind the tonsil into the pharynx, the palato-pharyngeus distributes some fibres in the pharynx, and after joining with the stylo-pharyngeus is attached with it to the thyroid cartilage. This muscle forms the posterior and larger arch or pillar of the velum palati.

*Action of the muscles in deglutition.*—The mass of food having, by the pressure of the tongue against the hard palate, been carried back to the fauces, the palato-glossi (the constrictors of the fauces) contract behind it; the soft palate is raised to some extent, and made tense; and the palato-pharyngei approaching one another nearly touch (the uvula lying in the small interval between them), and prevent the passage of the food towards the upper part of the pharynx, or the posterior nares, at the same time that they form an inclined surface for its guidance into the lower part of the pharynx, which is raised to receive the mass by elevator muscles already described (page 364). The concurrent elevation of the larynx, and closing down of the epiglottis over the entrance to the air-tube, have likewise been previously noticed (page 359).

#### MUSCLES OF THE BACK.

The muscles placed along the posterior part of the trunk are found to be arranged in layers, or strata, placed one over the other, and differing materially in extent, attachments, and use. The superficial muscles are so broad as to cover all the others; and, as their extent is considerable, their number is proportionably diminished, being only two, viz., the trapezius and latissimus dorsi. We shall here place them in the order in which we find them in our dissections, proceeding from the tegument to the spine and ribs. Those in each group or layer diminish in size as they increase in number.

In the first layer are the trapezius and latissimus dorsi.

In the second the rhomboidei and levator scapulæ.

In the third, the splenii and serrati postici.

In the fourth, the erector spinæ, sacro-lumbales, longissimus dorsi,



cervicalis ascendens, transversalis colli, trachelo-mastoideus, and complexus.

In the fifth, the semi-spinales dorsi and colli, recti and obliqui.

In the sixth, the interspinales, intertransversales, multifidus spinæ, and levatores costarum.

*Dissection.*—The subject being turned prone, the chest and abdomen should be supported by blocks, and the arms allowed to hang over the sides of the table. An incision may be made through the integument, along the spinal column, from the occipital protuberance to the sacrum. This should be bounded at its superior extremity by a transverse incision, carried outwards to the mastoid process, and below by another extended along the spine of the ilium. The intervening space may, in the next place, be intersected by two lines; one drawn from the first dorsal vertebra, over the spine of the scapula, the other commencing at the last dorsal vertebra, and carried horizontally outwards.

As the space here marked out is so very extensive, it may be advisable to make an incision obliquely upwards from the last dorsal vertebra to the spine of the scapula, which will correspond with the lower border of the trapezius muscle; and the dissection may be commenced by raising the angular flap of skin thus included, proceeding in the direction of the fibres of that muscle, that is to say, from below upwards and outwards. The other portions of integument should be successively raised, taking care to expose accurately the tendinous fibres where they arise from the spinous processes, as they afford a guide to the fleshy part of the muscle.

When the latissimus and trapezius have been exposed and examined in their entire extent, which will take some time, in consequence of the quantity of surface that is to be gone over, they are to be removed, in order to bring into view the muscles that lie beneath them.

#### FIRST LAYER OF DORSAL MUSCLES.

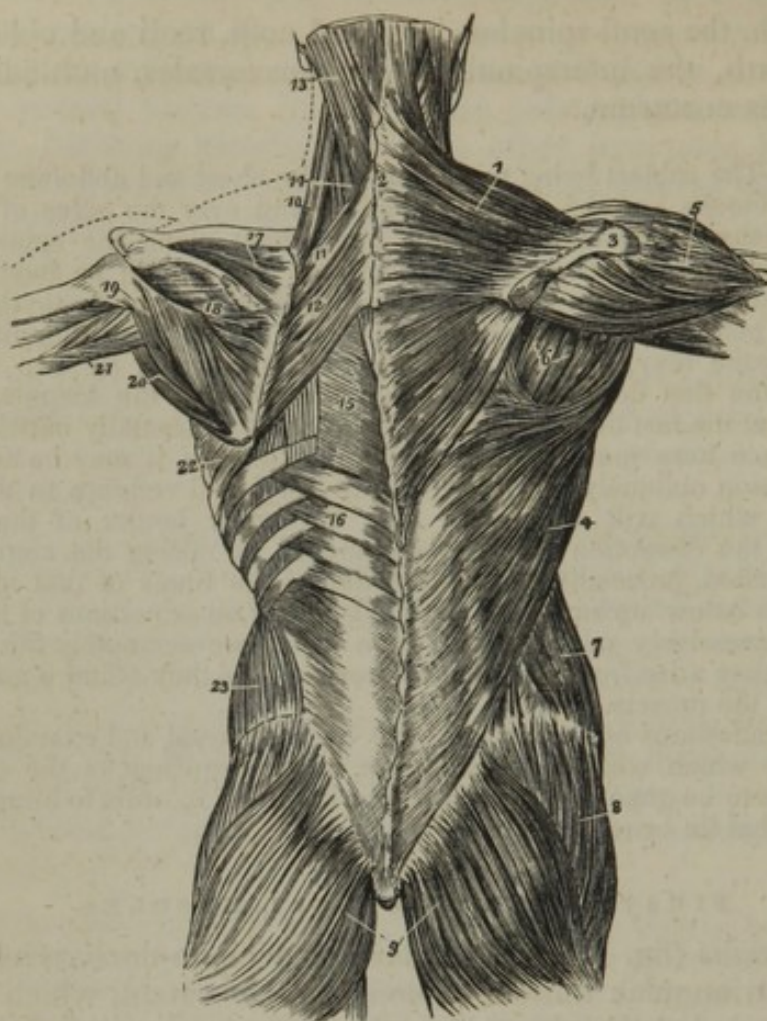
The *trapezius* (fig. 180,<sup>1</sup>) (*cucullaris*; \* *occipito-dorsi-acromialis*) is a flat thin triangular muscle of considerable extent, which is placed immediately under the skin along the posterior part of the neck, as well as of the back and shoulder. If the two muscles of this name be taken together, they represent a four-sided figure, (hence the name,) two angles of which correspond with the points of the shoulders, one with the occipital protuberance, and the fourth with the spinous process of the last dorsal vertebra.

The *trapezius* arises, 1, from the occipital protuberance, and from about a third of the curved line, extending forwards from it; 2, in the cervical region, from a tendinous band, called *ligamentum nuchæ*; 3, from the spinous process of the last cervical, and all those of the dorsal vertebræ, as well as from the supra-spinous ligament. From these different points of origin the fibres proceed towards their insertion into the clavicle, the acromion process, and the spine of the scapula, following very different directions; those from the occiput inclining downwards and outwards, and those from the lower part of the back upwards and outwards, the obliquity of each set diminishing, so that those intermediate between the two extremes become horizontal. The superior fibres turn forwards a little, and are inserted into the external third of the clavicle; the middle pass transversely to the upper border of the acromion process; whilst the inferior ones ascend

\* "*Cucullaris dicitur, quod cum conjuge suo cucullos monachorum non inepte exprimat.*" Spigelius, "*De Hum. Corp. Fabr.*" l. 4, § 13.



[Fig. 180.]



The first and second and part of the third layer of muscles of the back; the first layer being shown upon the right, and the second on the left side. 1. The trapezius muscle. 2. The tendinous portion which, with a corresponding portion in the opposite muscle, forms the tendinous ellipse on the back of the neck. 3. The acromion process and spine of the scapula. 4. The latissimus dorsi muscle. 5. The deltoid. 6. The muscles of the dorsum of the scapula, infra-spinatus, teres minor, and teres major. 7. The external oblique muscle. 8. The gluteus medius. 9. The glutei maximi. 10. The levator anguli scapulæ. 11. The rhomboideus minor. 12. The rhomboideus major. 13. The splenius capitis; the muscle immediately above, and overlaid by the splenius, is the complexus. 14. The splenius colli, only partially seen; the common origin of the splenius is seen attached to the spinous processes below the lower border of the rhomboideus major. 15. The vertebral aponeurosis. 16. The serratus posticus inferior. 17. The supra-spinatus muscle. 18. The infra-spinatus. 19. The teres minor muscle. 20. The teres major. 21. The long head of the triceps, passing between the teres minor and major to the upper arm. 22. The serratus magnus, proceeding forwards from its origin at the base of the scapula. 23. The internal oblique muscle.—W.]

to reach the upper border of the spine, to which they are attached as far back as the triangular surface at which it commences.

Structure:—the trapezius is fleshy in the greater part of its extent, and tendinous at its attachments. The tendinous fibres by which the muscle arises are rather short along the interval from the last dorsal vertebra as high as the fourth; there they lengthen gradually, but opposite the fourth cervical vertebra they again acquire about the same extent, so that in the interval between these points the tendinous part is extensive, and, if the two muscles are dissected at the same time, the tendons of both together will be seen to have an oval or



elliptic form. Again, the muscle is attached to the occiput by fibro-cellular membrane, which from its close connexion with the dense cellular structure beneath the skin, and from its wanting the lustre of tendon, is often inadvertently removed by the dissector. At the insertion to the spine of the scapula, near the base of that bone, will likewise be found a tendinous piece which receives the lowest muscular fibres, and glides over the smooth triangular surface on that part of the bone by means of a synovial bursa.

This large muscle is covered by dense cellular membrane, which alone separates it from the skin, so that in the living body its outline is readily discerned when in action. It conceals in part or altogether the following muscles, viz., the complexus, the splenii, levator anguli scapulæ, the supra-spinatus, infra-spinatus, the rhomboidei, and the latissimus dorsi (a small part). The anterior border, which may be said to turn forward near the clavicle, forms one of the limits of the posterior triangular space at the side of the neck.

The trapezius is not unfrequently shorter than usual, and the number of dorsal vertebræ with which it is connected may be found diminished even to six or seven. In a very muscular body Tiedemann\* found the trapezius and some other muscles (the pectoralis major and gluteus maximus) to a certain degree doubled (an additional muscular layer of some extent being under the ordinary one).—And here it may be mentioned, that, where the muscular development is large, added slips or portions will often be found in connexion with several of the muscles.

*Ligamentum nuchæ* (ligamentum cervicis).—From the line of union of the two trapezii along the neck, a band of condensed cellular membrane, mixed with tendinous fibres, projects forwards, so as to reach the spinous processes of the vertebræ, forming a septum between the sets of muscles on each side of the middle line. It is attached by its upper extremity to the occipital protuberance, by the lower to the spinous process of the seventh cervical vertebra; its posterior border is blended with the fibres of the trapezii, whilst the anterior is fixed to the spinous processes of the last six cervical vertebræ. This structure is usually named as above. In the human subject it can only be considered as a rudiment of that peculiar elastic band which serves to sustain the weight of the head in the lower animals.

The *latissimus dorsi*, (fig. 180,\*) (dorsi-lumbo-sacro-humeralis,) as its name implies, is of considerable extent, for it occupies the whole of the posterior part of the lumbar region, and the lower half of the dorsal. It is flat, broad, and thin in the greater part of its extent, but it gradually becomes contracted into a narrow fasciculus towards its insertion into the humerus.

It arises by tendinous fibres, 1, from the spinous processes of five or six lower dorsal vertebræ, from all those of the lumbar region and of the sacrum, and from the supra-spinous ligament: over the sacrum the aponeurosis is blended with the tendon of the erector spinæ. The muscle takes origin likewise, 2, from the external border of the crista ilii (its posterior third); 3, and by fleshy digitations from the last three

\* "Deutsches Archiv," 1818.



or four ribs, where they are interposed between similar processes of the obliquus externus. The tendinous fibres from the two first lines of origin form by their intertexture, or union, a broad aponeurosis, from which the fleshy fibres proceed, converging towards the axilla. The fibres at the upper part are the shortest, and pass almost horizontally outwards over the lower angle of the scapula, from which it frequently receives a fasciculus of fleshy fibres; those lower down become longer and incline from below upwards, gradually increasing in the degree of their obliquity; finally, those which are attached to the ribs ascend almost vertically. By this convergence, the fibres form a narrow and thick fasciculus. This rests on the teres major, which it accompanies towards the axilla, but gradually folding on itself, (the fibres from below passing under or in front of those from above, and eventually above them,) it likewise turns on that muscle, so as to get to its anterior aspect, and is *inserted* into the bicipital groove in the humerus by means of a tendon about two or three inches long. The flat tendon by which the latissimus dorsi is inserted becomes united, particularly by its lower border, with that of the teres major: it ascends higher than this muscle, and also lies nearer to the brachial vessels.

Structure:—tendinous along its point of origin from the spine and the ilium, aponeurotic in the lumbar region, tendinous at its insertion, fleshy in the rest of its extent,—where it lies over the ribs, the angle of the scapula, and the fold of the axilla.

The latissimus dorsi is covered by the trapezius at its dorsal origin, and is subcutaneous in the rest of its extent, except where it ascends into the axilla. The anterior surface rests on part of the rhomboideus major, infra-spinatus, teres major, the serratus posticus inferior, and the deep lumbar muscles; and, between the crest of the ilium and the last rib, its tendon is united with the fascia lumborum, and binds down the erector spinæ muscle. The internal border is blended with the fibres of the corresponding muscle, along the middle line. The superior border is free, and describes a slight curve, whose concavity looks upwards—between it and the margins of the trapezius and the rhomboid may in some positions of the arm be observed a small angular space in which the intercostal muscles are not covered by other muscles; the anterior one, also free in the greater part of its extent, slightly overlaps the obliquus externus below, and higher up the serratus magnus; on the humerus the tendon is in contact with the axillary vessels and nerves.

The latissimus dorsi, like most other muscles of the back, varies in the extent of connexion with the bones; thus: the number of dorsal vertebræ to which it is attached varies from four to seven or eight, and the number of the ribs is not constant, as has been already mentioned. A muscular band is often seen to stretch from this muscle across the axilla to its anterior part, where it terminates variously—in the tendon of the greater pectoral, or the coraco-brachialis muscle, or in the fascia.

*Actions.*—The trapezius and latissimus dorsi direct or influence the motion of several parts, as must be evident from the extent of their attachments. If the shoulders be fixed, the *trapezii muscles*, acting together, draw the head directly backwards; but, if only one of them acts, it inclines the head to the corresponding side. If the head be fixed, the superior part of the trapezius elevates the



point of the shoulder, and sustains it in that position, as, when a burden is supported upon it; but if the effort required be considerable, or if it must be continued for any length of time, the co-operation of the serratus magnus becomes indispensable. It would appear at first sight, from a mere inspection of the fibres of this muscle, that those in the middle part of it could draw the scapula directly backwards, and the lower ones draw it downwards. This, however, is far from being the fact. As the muscle is attached to the spine of the scapula and the acromion, it will rather, in consequence of the obliquity of the direction of these processes, communicate a certain degree of rotatory motion to the whole bone, by means of which, when the acromion ascends, the posterior angle descends, and the inferior one comes forward; and, should the acromion be made to resume its previous position, the inferior angle will move backwards, the superior one upwards. The scapula, then, by the action of the trapezius alone, cannot be made to ascend or descend, to go backwards or forwards, in such a way that the direction of its different parts may remain exactly parallel, in their new situations, to those which they had previously occupied:—this bone will, on the contrary, be found to rotate, as it were, on a pivot driven through the centre of its dorsum. To draw the scapula directly backwards requires the combined effort of the trapezius and rhomboid muscles; for, as their fibres decussate, the direction of the one being obliquely downwards, that of the other upwards, the bone, by their combined action, is made to move in the direction of the diagonal of their forces, that is to say, towards the spinal column.

The *latissimus dorsi*, when it acts on the shaft of the humerus, necessarily draws it downwards, and gives it at the same time a rotatory motion on its own axis, particularly if it had been previously everted, or turned outwards. When the shoulder and arm are rendered fixed, the muscle acts in various ways on the trunk. Thus it assists in forcible inspiration, by drawing on the lower ribs and elevating them. By conspiring with the abdominal and great pectoral muscles, it elevates and sustains the body in the effort of climbing; and, when an individual is constrained to resort to the assistance of crutches, the *latissimus* and *pectoralis major* are the chief agents in progression.

The trapezius and *latissimus dorsi*, more particularly the latter, can act under certain circumstances on the spine, preparatory to which the shoulder and arm must become (at least relatively) the fixed points of their attachment. When a man walks close to the margin of a raised footpath, or of a curbstone, and happens to incline a little beyond it, the body becomes curved to that side, and by its own weight would carry him over it, if a particular effort were not made to prevent such an occurrence. For this purpose the arm of the opposite side is, as it were, instinctively thrown out somewhat from the body, so as to render the insertion of the *latissimus dorsi* into that bone its fixed point of attachment. Thus sustained, the fibres of the muscle are enabled to act on the spine, and, by pulling on those parts of it which are curved, they draw them into a right line with the rest, and so restore the equilibrium of the body.

#### SECOND LAYER.

*Dissection.*—To expose the rhomboid muscles and the levator scapulæ, the trapezius must be removed. For this purpose, the fibres of the trapezius may be detached from their connexion with the clavicle and spine of the scapula, and reflected back to the spine. This will be found easier than the usual plan of detaching it from the latter, both because it is there very thin, and also because its fibres are connected with those of the rhomboid muscle. Its dorsal portion conceals the rhomboidei, and part of the *latissimus dorsi*; and the cervical, the levator scapulæ, the splenius, and complexus. These may be dissected in the course of their fibres, as the trapezius is being reflected back towards the middle line, where it may be separated from its fellow of the opposite side along the cervical region, so as to expose the ligamentum nuchæ. In doing this, insert the edge of the knife under the muscle at the occiput, and draw it from above downwards, in the line of the spinous process.

The *rhomboides muscle* (*rhomboides; dorso-scapularis*) is usually divided into two muscles, though they lie on the same plane, are similar



in structure and use, and are separated only by a slight cellular interval. It is extended obliquely from the spinous processes of the lower cervical and upper dorsal vertebræ, to the base of the scapula.

The *rhomboides minor* (fig. 180,<sup>11</sup>) arises from the spinous process of the seventh cervical vertebra, and from the ligamentum nuchæ, its fibres being also closely united with those of the trapezius. It inclines downwards and outwards, to be *inserted* into that part of the base of the scapula which corresponds with the triangular surface from which the spine commences.

*Rhomboides major*.<sup>12</sup>—This is three or four times broader than the other, placed in close contact, and immediately below it. It arises from the spinous processes of the four or five upper dorsal vertebræ, and their interspinous ligaments, and is *inserted* into that part of the base of the scapula included between its spine and inferior angle; some of the fibres, instead of being fixed to the bone, end on a tendon which is connected to the scapula above the lower angle, and in consequence of this arrangement, the muscle may, in part, be separated from the bone without division of its muscular or tendinous fibres.

The *rhomboides major* is covered by the trapezius in the greater part of its extent, and towards the lower part by the latissimus dorsi; but when the arm is drawn away from the side, a small portion is left uncovered by these muscles, where they diverge at the base of the scapula. The *rhomboides* rest against the serratus posticus superior and the posterior scapular artery with the ribs and deep muscles.

The *levator anguli scapulæ*<sup>10</sup> (trachelo-scapularis)\* is placed along the side and posterior part of the neck, forming a long and rather thick fasciculus of fleshy fibres. It arises from the posterior tubercles of the first three or four cervical vertebræ, by so many tendinous points. From these the fleshy fibres proceed, being at first slightly separated, but soon united to form a flat muscle, which is directed along the side of the neck downwards and a little backwards, and is *inserted* into that part of the base of the scapula included between its spine and superior angle.

The muscle is covered by the sterno-mastoid muscle above, and by the trapezius below; it rests on the splenius colli, transversalis cervicis, and the posterior scapular artery.

The *levator anguli scapulæ* may be found connected with but two vertebræ, or the number may be increased to five. A slip has been observed to extend to it from the mastoid process of the temporal bone (Theile), and from the second rib (Meckel). It often appears as several muscles, the parts connected with the vertebræ remaining separate, even to the place of insertion.

### THIRD LAYER.

*Dissection*.—After having examined the muscles of the second layer, they must be removed in order to gain a view of those underneath them. For this purpose, the *rhomboides* may be detached from the base of the scapula, and re-

\* This muscle was known as the "musculus patientiæ," having been so named by Spigelius for the reason which he thus expresses:—"Secundus, scapulam attollens et levator dictus, à me vero per jocum *patientiæ musculus*, quod ægrè ferentes, quæ nobis aduersa accidere, scapulam huius ope, cum humero, patientiæ amarum ingeminantes nomen, eleuamus."—Spigelius, "De h. corp. fabr." l. 4, § 13.



flected backwards, which is the easier mode of attaining the end desired, and avoids any risk of raising with them the serratus superior, which is intimately connected with their origin. The aponeurosis of the latissimus dorsi may be divided by an incision carried from above downwards, along its middle; and, as the external half is reflected outwards, its intimate connexion may be observed with the obliquus abdominis, along the border of the deep lumbar muscles. The other portion of the aponeurosis may be drawn back towards the spine, by which means the serratus posticus is left untouched. The serrati and their connecting membrane may then be inspected.

*Serratus posticus superior* (cervici-dorso-costalis) is placed under cover of the rhomboideus; it is flat, and very thin. It arises from the ligamentum nuchæ, the spinous process of the last cervical, and from those of two or three upper dorsal vertebræ, by a thin aponeurosis, which inclines downwards and outwards, and, becoming muscular, is inserted by four fleshy digitations into the bodies of the second, third, fourth, and sometimes fifth ribs, a little beyond their angles. Its direction is obliquely downwards and outwards, resting on the deep muscles and the angles of the ribs. The aponeurosis forms a large part of this little muscle.—It is covered by the rhomboid and levator anguli scapulæ, and lies against the deeper muscles of the back. The vertebral aponeurosis is occasionally found to be connected with it.

*Serratus posticus inferior* (fig. 180,<sup>6</sup>) (dorsi-lumbo-costalis).—This is broader than the preceding muscle, from which it is separated by a considerable interval, as one of them corresponds with the upper, the other with the lower ribs. It arises from the spinous processes and interspinous ligaments of the last two dorsal and two or three upper lumbar vertebræ, by a thin aponeurosis, which forms the greater part of the muscle. It ends in a fleshy lamella, which is inserted by four broad digitations into the bodies of the last four ribs. Its direction is oblique upwards and outwards. The posterior surface is covered by the latissimus dorsi, with whose tendon the aponeurotic part is firmly united for some extent; the anterior rests on the deep lumbar muscles. The upper margin is connected with the vertebral aponeurosis.

*Vertebral aponeurosis*.—On the same plane with the serrati is a thin, semitransparent lamellæ thus named, which forms a septum between the third and fourth layer of muscles, separating those which belong to the shoulder and the arm from those which support the spine and head. Its fibres are for the most part transverse; some, however, take a contrary direction. It is connected below with the inferior serratus, and above passes usually beneath the superior serratus; and as the two muscles, with their connecting aponeurosis, are stretched from the spinous process to the angles of the ribs, they form with the vertebral grooves a sort of angular canal, in which are lodged the long extensor muscles.

The *splenius muscle* (fig. 180,) is placed obliquely along the posterior part of the neck, diverging from the muscle of the opposite side, near the occiput, so that the two leave between them an interspace, in which the muscles beneath (complexi) come into view. The splenius is extended from the spinous processes of the upper dorsal and lower cervical vertebræ, to the side of the base of the skull, and the



transverse processes of the superior cervical vertebræ. This separation at the superior attachment has given occasion for the division of this muscle into two parts; the lower being named *splenius colli*, the upper *splenius capitis*.

The *splenius colli*<sup>14</sup> (dorso-trachelius) arises from the spinous processes of four dorsal vertebræ, from the third to the sixth inclusive: the fibres ascend, forming a flat, muscular plane, which is inserted by separate points into the transverse processes of the first three cervical vertebræ, close to the origin of the levator anguli scapulæ.

The *splenius capitis*<sup>15</sup> (cervico-mastoideus) is placed above the preceding, and is also broader and thicker than it. It arises from the spinous processes of the first two dorsal vertebræ, and of the seventh cervical; also from the ligamentum nuchæ opposite the sixth, fifth, and fourth. From these points its fibres proceed upwards and outwards, to be inserted into the lower end of the mastoid process (which it embraces), to the posterior part of the same process, and the line curving upwards and backwards from it. Structure:—tendinous at its attachments, fleshy in the rest of its extent.

The splenius (the cranial and cervical parts being taken together) is covered by the trapezius, the rhomboid, and the serratus posticus superior; by the sterno-mastoid on the cranium. It conceals, in part, the complexus and trachelo-mastoid.

The splenius differs, in different cases, as to the number of the vertebræ with which it is connected; and the two parts into which it is considered divisible vary in the extent to which they are really distinct one from the other.

*Actions.*—The levator anguli scapulæ conspires with the rhomboideus in one of its more obvious actions. When the acromion process is elevated, the posterior angle of the scapula is depressed, and the inferior one carried forwards; but, as soon as the more powerful muscles cease to act, the levator draws upwards the posterior angle of the bone, whilst the rhomboid carries backwards and upwards the inferior angle, thus giving a slight rotatory motion to the whole bone, and at the same time depressing the acromion and point of the shoulder.—If the shoulder be fixed, the levator may incline the neck down to the same side, just as the trapezius draws the head under the like circumstances. If the rhomboid muscle conspires with the middle and lower part of the trapezius, the base of the scapula will, by their joint effort, be carried directly towards the spine.

The serrati postici, in their action on the thorax (which, from their size, is necessarily insignificant), are antagonists. The inferior one is enabled, by the direction of its fibres, to depress the ribs, and to assist in expiration; but the other elevates the ribs, into which it is inserted.—Moreover, the serratus inferior, in consequence of its connexion with the vertebral aponeurosis, probably exerts some influence on the deeper muscles, by making that membrane tense; and the serratus superior will produce a like effect when it happens to be connected with the membrane.

If the splenii muscles of both sides act together, they draw the head directly backwards, in which they conspire with the complexus and trapezius. When those of one side act separately, they incline the head laterally, giving it at the same time a slight rotatory motion. The complexus, too, by reason of the oblique direction of its fibres, can give a certain degree of horizontal motion to the head, but in a direction contrary to that of the splenii, as must be evident from the fact, that the fibres of the one incline outwards as they ascend, and those of the other inwards.

#### FOURTH LAYER.

*Dissection.*—When you have sufficiently examined the muscles of the third layer, divide the serrati and their aponeurosis in the middle, and reflect the

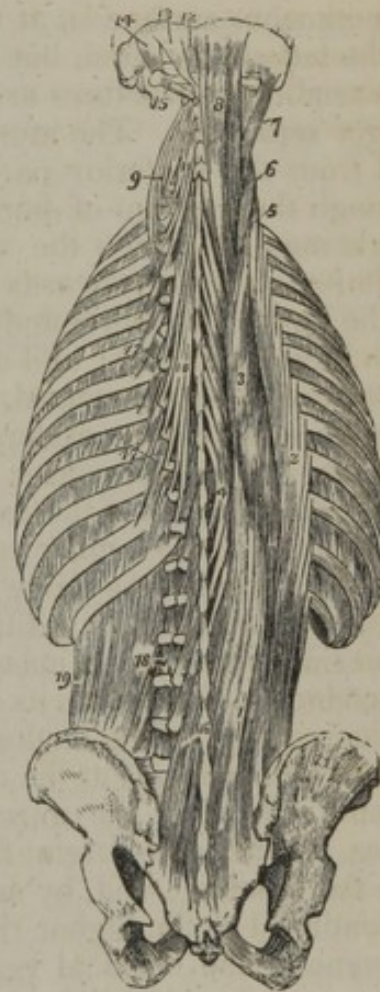


pieces, one inwards, the other outwards. When this is done, the sacro-lumbalis and longissimus dorsi may be traced from below upwards, by merely passing the handle of the scalpel along the cellular interval which separates them. The next step is to detach the splenii at their origin, by an incision carried from above downwards, close to the spinous processes. These muscles diverge at their upper part, and leave between them an interval, in which the complexi are seen. When the splenius has been detached from the vertebræ and reflected outwards, the transversalis cervicis and trachelo-mastoideus can be followed along the neck, taking them as continuations of the long dorsal muscles.

*Erector spinæ* (extensor dorsi-communis; sacro-spinalis; lumbo-costalis) (fig. 181).—Beneath the vertebral aponeurosis and the serrati muscles in the dorsal region, beneath the tendon of the latissimus dorsi in the lumbar, and a layer of cervical fascia continued under the trapezius in the cervical, lie the large muscles which support the trunk and the head in the erect position of the body. These muscles generally have little of the distinct and independent arrangement presented where the joints are few, and the extent of movement in each well defined, as in the limbs. On the contrary, as the number of joints in the spine is very considerable, as the movement of each is indistinct, and as many associate for every change in the position or direction of the trunk, the points of attachment for the muscles are very numerous, and their fibres are short and incompletely separated; insomuch that they are more or less conjoined one with another from end to end of the vertebral column.

The erector spinæ is small and pointed over the sacrum, where little more exists than the tendon of origin, and becomes suddenly enlarged in the lumbar region;—and this part may be considered the source from which fibres spread upwards to the bones. In the dorsal region it gradually lessens, being expended on the vertebræ and the ribs, till, in the neck, no more than a vestige of the lumbar mass remains. Finally, in this situation there are added, as it were to support the neck and the head in the erect position, special muscles of considerable size (splenius and complexus), between which the slender prolongations of the erector spinæ will be found.

[Fig. 181.]



The fourth and fifth, and part of the sixth layer of the muscles of the back. 1. The common origin of the erector spinæ muscle. 2. The sacro-lumbalis. 3. The longissimus dorsi. 4. The spinalis dorsi. 5. The cervicalis ascendens. 6. The transversalis cervicis. 7. The trachelo-mastoideus. 8. The complexus. 9. The transversalis cervicis, showing its origin. 10. The semi-spinalis dorsi. 11. The semi-spinalis colli. 12. The rectus posticus minor. 13. The rectus posticus major. 14. The obliquus superior. 15. The obliquus inferior. 16. The multifidus spinæ. 17. The levatores costarum. 18. Intertransversales. 19. The quadratus lumborum.—W.]



*Origin of the erector spinæ.*—At the lower end, where it is not divided on the surface, and where, the connexions being more fixed, it must be said to take origin, the mass is covered by a broad thick tendon, the most extensive source of its muscular fibres. The tendon is attached to the spines of the sacrum, and to some of the highest of the external row of tubercles on that bone—blending, in the latter situation, with the sacro-sciatic ligament, and connected with the origin of the gluteus maximus muscle; it is likewise attached to the spines of most of the lumbar vertebræ, and to the posterior part of the crest of the ilium. Thus fixed, the tendon gives origin, by the entire of its deeper surface, to a large part of the great muscular mass; and its cutaneous surface is, at the upper part, covered by the aponeurosis of the latissimus dorsi, but at a lower point—over the sacrum—the two tendinous structures are united one with the other, so as to be no longer separable. The muscular fibres, taking origin from the tendon and from the posterior part of the crest of the ilium (directly, and through the medium of fibrous structure in their substance), form a single mass, to which the name erector spinæ might be confined. It is limited in front (towards the abdomen) by the transverse processes of the lumbar vertebræ and the layer of the lumbar fascia connected with these processes; and divides, near the last rib, into two parts of unequal size—one external, the other internal and larger—which will now be separately considered.

*Sacro-lumbalis* (extensor dorsi-externus) (fig. 181.<sup>a</sup>).—The external and smaller portion of the erector spinæ having no direct connexion with the sacrum or the lumbar vertebræ—none, except through the general tendon of origin—the name by which it is generally known conveys an incorrect notion of its position and connexions. Separating from the outer side of the general mass near the last rib, this muscle ends in a series of tendons which lie on its posterior surface, and are fixed to the ribs at their angles. The tendons derived from the lumbar mass may be said to be exhausted at the middle of the dorsal region (at the sixth or seventh rib); but the muscle is reinforced by bundles of muscular fibres, which take origin from the upper margins of all the ribs by thin flat tendons; and, by means of these additions, the sacro-lumbalis is continued to the higher ribs, as well as to the transverse processes of some of the cervical vertebræ. There is no separation between these accessory bundles, but they are usually considered to form two muscles, which are named “accessorius” and “cervicalis descendens.”

*Accessorius ad sacro-lumbalem.*—The bundles of muscular fibres, derived from the lower six or eight ribs, are known under this name. They commence by flat tendons connected with the upper margins of the ribs, and, again ending in tendons, constitute that part of the sacro-lumbalis which is inserted into the higher ribs. To expose the accessorius, the lower part of the sacro-lumbalis (beneath which it lies) must be separated from the longissimus dorsi, and turned outwards.

*Cervicalis descendens v. ascendens.*<sup>b</sup>—Thus are named the accessory slips, taking origin from four or five of the higher ribs, and continued upwards to terminate on the transverse processes of three or



four cervical vertebræ. This part of the muscle lies to the inner side of the tendons of the sacro-lumbalis, which terminates on the highest ribs, and is recognised by this position and its muscular appearance. In the neck it is overlapped by the levator anguli scapulæ lying between it and the complexus. It blends with the transversalis cervicis—an elongation from the muscle to be next described,—and, if long enough, with the cervical insertion of the splenius.

Some anatomists, considering the name sacro-lumbalis not an appropriate one for the muscle, have suggested substitutes, *e. g.* sacro-costalis; ilio-costalis (Theile). But neither of these is unobjectionable; and indeed the points of attachment of the muscle are so numerous that any name derived from them must either be imperfect or very long.

Under the name "*cervicalis descendens*," Diemerbroeck\* described the fibres connected with the cervical vertebræ and with all the ribs; but he regarded them as descending from the vertebræ to the ribs, and having the opposite direction to the sacro-lumbalis. The contrary direction of its two sets of fibres this anatomist held to account for the opposite effects ascribed to the sacro-lumbalis muscle, namely, the alternately raising and depressing the ribs in inspiration and expiration. (Stenonis,† it should be observed, had previously given an account of the fibres on the ribs, now known as the *accessorius*.) The name thus applied to all the accessory part of the sacro-lumbalis was subsequently appropriated to the upper portion of it, which is commonly described as extending from below upwards, and on this account it was that Meckel suggested the alteration to *cervicalis "ascendens."*

*Longissimus dorsi*.<sup>3</sup>—The internal larger and longer portion of the erector spinæ is attached to parts situated internally to those which receive the sacro-lumbalis, *viz.*, the lumbar vertebræ, the dorsal vertebræ, and the ribs within their angles. While the muscular mass of the lumbar region is yet undivided, its inner part (which may be assigned to the *longissimus dorsi*) is inserted into the whole length of the transverse processes of the lumbar vertebræ on their posterior aspect, including the tubercles (*processus accessorii*) projecting from the processes near their bases and the small depressions internal to them. Fibres will likewise be found inserted beyond the transverse processes to the layer of the lumbar fascia connected with their points; and this part, with the preceding, forms one broad insertion.

In the dorsal region, the *longissimus dorsi* is attached to the extremities of the transverse processes of all the dorsal vertebræ, and to a less number (varying from seven to eleven) of the ribs within their angles. This muscle is continued upwards to the neck and to the cranium by a slender accessory portion, which is described as two muscles—*transversalis cervicis*, and *trachelo-mastoid*.

*Transversalis cervicis*.<sup>6</sup>—This slender part is placed at the inner side of the *longissimus dorsi*, and arises from the ends of the transverse processes of the highest dorsal vertebræ, and occasionally the last cervical, (about five altogether, but the number and their position are very variable,) and is inserted into the transverse processes of about four cervical vertebræ above the last. It blends with the *cervicalis descendens*, and still more with the *trachelo-mastoid*, with which latter the fibres are in great part continuous.

\* "*Anat. corp. hum.*" l. 5, c. 6.

† "*De musculis observationum specimen*" in Mangetus, "*Bibliotheca Anatom.*" t. 2, p. 528.



The *trachelo-mastoid* muscle<sup>7</sup> (part of the complexus; complexus minor), the continuation of the longissimus dorsi to the head, extends, as the name implies, from the neck to the mastoid process of the temporal bone. Placed to the inner side of the transversalis cervicis, and inseparable from it, except with the aid of a knife, it arises from the last three or four cervical vertebræ—the tendons being attached to or immediately near the oblique processes. The narrow flat muscle, constructed from the several small points of origin, and frequently crossed by a tendinous intersection, is inserted into the posterior margin of the mastoid process under the splenius and sterno-mastoid muscles. It conceals partly the complexus and the obliqui capitis; and, on the cranium, the occipital artery crosses immediately beneath it, or, as not unfrequently happens, over it.

The spinous processes of the superior lumbar and the dorsal vertebræ, hitherto left unoccupied by the large muscles, (erector spinæ and its divisions,) have connected with them a series of tendinous fibres, which are in reality a part of the longissimus, but are described as a distinct muscle as follows:—

*Spinalis dorsi*.<sup>4</sup>—Placed at the inner side of the longissimus dorsi, and connected exclusively with the spinous processes, (whence the name,) this little muscle arises by tendons (three or four in number,) from the first two lumbar and the lowest dorsal vertebræ; and the slender bundle of muscular fibres, which springs from the tendons, ends by being connected with the higher dorsal vertebræ, the number of attachments varying from four to eight. The spinalis is separable from the longissimus dorsi only by artificial means; and it is connected with the muscle beneath it—the semi-spinalis.

*Spinalis cervicis* (interspinales supernumerarii,—Albinus). In this place must be mentioned, because of the analogy with the spinalis dorsi, a small muscle, like it exclusively connected with the spines of the vertebræ. The fibres have seldom the same arrangement in two bodies, and they often differ on both sides of the same body. But it may be said that the muscle arises by tendinous or fleshy fibres, forming from two to four heads, from the spinous processes of the fifth and sixth cervical vertebræ, or likewise from others in the immediate neighbourhood of these, including one or two dorsal, and is again fixed by tendons into the spine of the axis, and, in some instances, to the two vertebræ next below it. The spinalis cervicis is connected with the semi-spinalis and the ligamentum nuchæ.

This muscle is sometimes placed over the spinous processes, and hence has been named super-spinalis (Cowper). It may be reduced to a single slip; and not unfrequently is altogether wanting. Its absence was found to occur in five cases out of twenty-four.\*

*Complexus*<sup>8</sup> (*trachelo-occipitalis*) is a thick and rather broad muscle, situated upon the posterior part of the cervical region. It is directed obliquely inwards from the transverse processes towards the spines and the middle line, so that the two muscles of this name approach

\* A detailed account of a series of observations made with respect to this muscle, by MM. Henlé and Heilenbeck, will be found in Müller's "Archiv. f. Anat. Physiol.," &c. 1837.



one another, whereas the fibres of the splenius, which cover it, have the opposite direction, and the complexi, therefore, are partly seen in the interval left between the splenii of both sides as they diverge to their connexion with the sides of the cranium. The complexus arises by about seven tendinous points from the posterior and upper part of the transverse processes of the first three dorsal and seventh cervical vertebræ, and from the oblique or articular processes of three more cervical (covering the joints and adhering to the ligamentous fibres which support them). The muscular fibres are soon aggregated into a mass, which is directed upwards and inwards to be inserted between the two curved lines of the occipital bone. Above its middle the muscle is partially intersected by a transverse tendinous intersection.

The muscle is covered by the trapezius, splenius, and the slender muscles attached to the transverse processes of the cervical vertebræ; and is crossed by the occipital artery. It conceals the semi-spinalis colli, the posterior recti and obliqui capitis, together with the deep artery of the neck and several nerves, some of which (last) perforate it.

*Biventer cervicis*.—Close by the inner border of the complexus, and in most cases forming a part of it, is a long fasciculus, consisting of two fleshy bellies united by a tendon, and hence named as above. The lower end presents from two to four tendinous and fleshy points attached to as many transverse processes of the dorsal vertebræ from the fourth to the sixth or seventh, and the upper one is inserted into the occipital bone near the complexus. The tendon which divides this muscle is of considerable length, and is usually placed opposite the last cervical or first dorsal vertebra. And from the spines of one of the vertebræ now named, an accessory slip is often furnished to the biventer at its inner side.

The name complexus being little applicable to the muscle now so called, it should be mentioned that the term originally included three muscles, viz., the complexus (of modern writers), the biventer, and the trachelo-mastoid.

The complexus and the biventer together constitute the second of the two principal muscles destined to maintain the head poised on the vertebral column in the erect position of the trunk; the splenius, which in a great measure covers it, being the first. Both these muscles may be considered as succeeding to the sacro-lumbalis and longissimus dorsi, and performing at the upper extremity of the spine the functions which the muscles just named fulfil at its lower part. It will be observed, too, that the slender elongations of the divisions of the erector spinæ are placed between the two large cervical muscles.

#### FIFTH LAYER.

To continue the examination of the muscles of the back, those which have hitherto been under observations are to be removed:—the complexus must be divided and turned aside (in doing this, the artery and nerves beneath it should be noticed); the spinalis and the longissimus dorsi are to be separated in the dorsal region; and its large tendon being divided longitudinally near the spinous processes of the lumbar vertebræ and the sacrum, the erector spinæ is to be raised from the inner side and thrown outwards. Then there will lie exposed the muscles which fill the grooves of the spine from the middle of the sacrum upwards, excepting from the axis to the occiput, where a different arrangement prevails, to be afterwards noticed. The fibres will be found stretching obliquely from the transverse or the articular processes to the spines of the vertebræ. In the dorsal and cervical regions a layer of muscular and tendinous structure (semi-



spinalis) is distinguished from the more general one, which lies beneath it, and extends from the sacrum to the axis (*multifidus spinæ*).

The *semi-spinalis* reaches from the lower part of the dorsal vertebræ to the second cervical; and, though there is no separation, it is described as two muscles, distinguished by their position.

*Semi-spinalis dorsi*<sup>10</sup> (*transversaire épineux du dos*,—Winslow).—This thin and narrow stratum consists of a small portion of muscular structure, interposed between tendons of considerable length. The lower tendons are connected to the transverse processes of the inferior dorsal vertebræ (from the tenth to the fifth, inclusive), and the upper tendons to the spines of the higher dorsal and neighbouring cervical vertebræ (four of the former, and two of the latter).—It is covered by the spinalis and the *longissimus dorsi*, and in some degree by the *semi-spinalis colli*, and lies on the *multifidus spinæ*.

*Semi-spinalis colli*<sup>11</sup> (*transversaire épineux du col*).—Considerably thicker than the preceding, this part of the *semi-spinalis* takes origin from the transverse processes of usually the first five or six dorsal vertebræ, by as many tendinous and fleshy points, and terminates in about four parts on the spines of the cervical vertebræ, from the second to the fifth inclusive. The part connected with the axis is the largest, and is chiefly muscular. This portion of the *semi-spinalis* is covered by the *complexus* and *biventer cervicis*; it rests against the *multifidus spinæ*, and is firmly united with it towards the upper end.

Both the parts of the preceding muscle vary in their length, and consequently in the number of vertebræ with which they are connected. Their average extent is mentioned above.

The greater thickness of the cervical portion is dependent on the freedom of motion in that part of the column.

*Multifidus spinæ*<sup>12</sup>.—This long and narrow mass of muscular, with an admixture of tendinous fibres, occupies the vertebral groove at the side of the spinous processes. It is fixed to the sacrum, and to all the vertebræ, except the atlas, covering them to a considerable thickness; some of its fibres (the deepest) reaching from one vertebra to the next, while others, placed over those, extend to a greater distance. In conformity with the plan usually followed in the description of muscles, the origin and insertion of the fibres of this muscle may be stated as follows.

At the lower end (where the muscle reaches to the interval between the second and third sacral foramina, and is adherent to the aponeurosis described in connexion with the *erector spinæ*), the fibres may be said to arise from the higher external tubercles of the sacrum, from the ilium, and the ligament connecting both these bones; in the lumbar and cervical regions they take origin from the oblique or articular processes; and in the dorsal region from the transverse processes. From these several points the muscular bundles ascend obliquely, to be inserted into the laminæ of the vertebræ and the spines, from their bases nearly to their extremities. The fibres vary in length, for those from each point of origin are fixed to several vertebræ; some to the next above, while others extend further—from the second even to the fifth beyond. And thus they are placed fibre over fibre, and each



vertebra receives some from different points of origin, and of different lengths, the longest being necessarily most superficial.

*Rotatores spinæ*.—Under this name have been described\* a series of eleven small, flat, nearly square muscles, placed at intervals on the dorsal part of the spine, under the multifidus spinæ, from which they are separated by a little cellular membrane. Each arises from the upper and back part of the transverse process, and is inserted into the vertebra next above, at the inferior margin of the lamina, and on part of its surface, as far as the root of the spinous process. The first occurs between the first and second dorsal vertebræ, the last between the eleventh and twelfth. But it not unfrequently happens that the number is diminished, by the absence of one or more from the upper or lower end. The bundles of muscular fibres thus described as distinct muscles, do not appear to be distinguishable from the deeper part of the multifidus spinæ, except by the interposition of a little cellular membrane.

The *interspinales* are short fasciculi of fleshy fibres, placed in pairs between the spinous processes of the contiguous vertebræ—as their name implies.

They are best marked in the neck, where they are connected one to each of the two parts into which the spinous process is divided. Six pairs may be counted, the first being between the second and third vertebræ, the last between the seventh and the first dorsal.

In the dorsal division of the column only a few of the interspinous muscles are met with, and these are not constant. They will not unfrequently be found between the first and second vertebræ of this region, and occasionally between the eleventh and twelfth. A vestige of them likewise sometimes occurs in the second dorsal “interspinous” space.

Four pairs of very thin layers occur in the intervals of the five lumbar vertebræ. One will likewise be, in some instances, found connecting the last of these vertebræ with the sacrum, and another connecting the first with the dorsal vertebræ above it.

Slender muscular fibres have been mentioned as occasionally found to extend over the lower part of the sacrum and coccyx, and apart from other muscles; and the name *sacro-coccygeus posticus*, or *extensor coccygis*, has been assigned them.† They arise by tendinous fibres from the first piece of the coccyx, or the last bone of the sacrum, or even at a higher point, and, reaching downwards, are fixed to the lower part of the coccyx. These have been considered a rudiment of the extensor of the caudal vertebræ of some animals.

Coinciding with the peculiar conformation of the joint formed between the first two vertebræ, and the kind of movement which belongs to it, the deep-seated muscular structure between the axis and the occiput is found to differ widely in arrangement from that which has been met with over the rest of the vertebral column, being aggregated into small muscles, which are independent one of the other, viz., the obliqui and recti, the “circumagentes” of some of the older anatomists.

*Rectus capitis posticus major*<sup>13</sup> (axoido-occipitalis).—This muscle

\* Prof. Theile in Müller's “Archiv. f. Anat.” &c. 1839.

† Günther and Milde, “Chirurgische Muskellehre,” quoted in “Sommerring von Baue,” &c.



extends from the spinous process of the axis to the under surface of the base of the skull. It *arises* by a tendinous origin from the process just mentioned, and, enlarging considerably as it ascends, passes over the atlas, and is *inserted* into the inferior curved line of the occipital bone and beneath it. It diverges from the corresponding muscle of the opposite side, so as to be much more oblique than straight, as the name would imply.

The *Rectus capitis posticus minor*<sup>12</sup> (atlo-occipitalis) extends from the atlas to the base of the skull, being smaller every way than the preceding. It *arises* from the posterior border of the atlas, and, expanding towards the other extremity, is *inserted* into the rough surface between the inferior curved line on the occipital bone and the foramen magnum. It lies nearer to the middle line than the preceding muscle at the occiput, and can therefore be seen without disturbing it.

The recti muscles take the place of the interspinales. The smaller pair may be considered strictly analogous; but the larger undergo a change in attachment and direction, referrible to the movements which they are required to effect. The latter do not remain on the atlas, for the movement of extension belonging to other parts of the spine does not exist between the first two vertebræ; and, moreover, their course upwards to the occiput, to which they are fixed, being oblique, they are calculated (besides the influence they exert in drawing the occiput backwards) to assist in the rotatory movements of which the axis is the pivot.

The *obliquus capitis inferior* v. *major*<sup>15</sup> (axo-atloideus), the largest of these muscles, is placed obliquely between the first two cervical vertebræ. It *arises* from the spinous process of the axis in its whole length, between the origin of the rectus posticus major and the insertion of the semispinalis colli, and is *inserted* into the extremity of the transverse process of the atlas.

The *obliquus capitis superior*<sup>14</sup> (atlo-post-mastoideus) extends from the atlas, where the preceding muscle terminates, to the lateral and inferior part of the base of the skull. It *arises* from the extremity of the transverse process of the first cervical vertebra, inclines from thence obliquely upwards and inwards, expanding somewhat as it ascends, and is *inserted*, close behind the mastoid process, into the interval between the curved lines of the occipital bone. The two oblique muscles, with the rectus major, form the sides of a small triangular space, in the area of which branches of the suboccipital nerve will be found.

*Inter-transversales*<sup>18</sup> (Cowper), (inter-transversarii, — Albinus). — These little muscles occupy the spaces between the transverse processes of the vertebræ, and are most developed in the neck, and least so between the dorsal vertebræ.

In the cervical part of the spine there are, in each space, two rounded bundles of muscular fibres, with tendinous filaments intermixed, attached, one to the anterior, the other to the posterior tubercle of the transverse processes—the cervical nerve, which lies in the groove between the tubercles, separating one muscle from the other. There are seven pairs in the neck, the first between the atlas and axis, the last connecting the seventh cervical to the first dorsal vertebra.

The rectus lateralis, which extends from the transverse process of the atlas to the base of the skull (jugular process of the occipital bone), may well be re-



garded as an inter-transversalis, and the rectus anticus minor might be considered its fellow—but displaced, as it were, forwards, to the anterior part of the vertebra.

In the loins, the inter-transversales are four in number, one between each pair of vertebræ. Those connected with the lowest vertebræ are attached to nearly the whole of the transverse process, while those at the upper part of this division of the spine do not exceed half the breadth of the process. The muscles now described are in single layers; but the small round fasciculi which are stretched between the accessory processes of the lumbar vertebræ, and hence named *musculi inter-accessorii*, or *inter-obliqui*, may be looked on as rudiments of posterior inter-transversales.

In the dorsal region narrow rounded cords are found between the transverse processes. They are tendinous in structure, except in the lowest three interspaces and between the last dorsal and first lumbar vertebræ, in which they are muscular. These fasciculi range with the inter-accessorii above described, at the same time that they correspond with them in shape and size.

When proceeding with the dissection of the muscles here noticed, a series of fleshy and tendinous bundles, extended downwards and forwards from the transverse processes of the vertebræ to the margins of the ribs—the levatores costarum—will be exposed, to be described hereafter.

*Combined actions.*—The *sacro-lumbalis*, *longissimus dorsi*, and *multifidus spinæ* conspire in fixing the spinal column, and thereby maintaining the trunk erect. If they continue their effort, the body will be drawn somewhat backwards, as may be observed when a considerable weight is suspended from the neck, or in persons who have become excessively fat. In both these cases, the extensor muscles are required to make increased efforts to counterpoise the influence of the weight appended to the fore part of the body.

As these muscles have to sustain the trunk in the sitting as well as in the standing posture, it might be supposed that they scarcely admitted of any relaxation, and therefore are kept almost constantly in action. But it does not appear necessary, except in making great efforts, that all of them should be in action at the same moment, and even the different parts of the same muscle must, in most cases, act successively. Thus the lower fibres of the multifidus spinæ pass from the sacrum to the lumbar spines, and materially assist the quadratus lumborum and other muscles in fixing the lumbar vertebræ. These, or rather their transverse processes, become the fixed points from which the succeeding parts of the multifidus act on the spines throughout the entire length of the column, so that a succession of efforts is propagated from below upwards by a sort of vermicular motion. When, by such an arrangement, the action of one set of fibres succeeds that of another, each will have its alternations of contraction and relaxation, as well as the fibres of those muscles in which the change is more perceptible. The sacro-lumbalis can draw down the lower ribs; and if the effort be continued, this influence must speedily be propagated to the spinal column, which is thus bent towards the side by means of the intimate connexion between the heads of the ribs and the vertebræ. The longissimus dorsi conspires to produce the same effect.

The spine admits, to a certain extent, of a rotatory movement. Thus the head may be carried round by a horizontal motion, until the chin comes nearly on a line with the point of the shoulder, after which the spine may be made to turn on its own axis, until the face shall have completed almost a semicircle from the point at which its first movement began. The latter movement is effected by that peculiar action of the multifidus spinæ above alluded to; but it is the muscle of the opposite side from that towards which the movement takes place that produces the rotation, assisted by the obliquus externus abdominis.



The influence of the sacro-lumbalis, in depressing the lower ribs, must be evident from its mode of attachment to them. But its accessory muscle (*cervicalis descendens*), by taking its fixed point at the cervical vertebræ, is enabled to draw up, and therefore elevate, the ribs into which it is inserted.

#### MUSCLES OF THE UPPER EXTREMITY.

The muscles of the upper extremity, taken in the order of their situation, may be divided into four groups, viz., those placed on the shoulder, on the arm, on the fore-arm, and on the hand. We must, however, commence the description of the moving powers of the limb with that of the two pectoral muscles and the *serratus magnus*.

*Dissection of the upper arm.*—The subject being laid on its back, and the arm drawn away from the side, an incision may be made through the skin, commencing at the middle of the clavicle, and extending down the centre of the axilla. From this another line may be drawn, downwards and inwards, along the lower border of the *pectoralis major*. The angular flap thus included should then be raised from off the muscle just named, its dissection being conducted from without inwards to the fore part of the sternum, so as to expose the muscle. It may be necessary to make another incision through the skin, along the clavicle, to the sternum, from the point above indicated. The external flap of the skin may then be dissected off the remainder of the pectoral muscle, and part of the deltoid. When the external surface of the *pectoralis major* has been examined, it may be detached easily by drawing forwards its lower border, and inserting the scalpel between it and the costal cartilages, and cutting through its attachments to them, as well as to the sternum and clavicle, successively. The muscle may then be drawn outwards, and the fold in its tendon examined. The *pectoralis minor* is thus exposed, and the axillary vessels partly. The costal attachment of this muscle may be separated in the same way as the other. The axillary vessels are by these measures brought fully into view, little else remaining to be done than to remove the cellular tissue in which they are imbedded. For the Axillary Artery,—the Vein, and the Plexus of Nerves, see the account of those structures.

When commencing the dissection of the arm, an incision may be made from the middle of the interval between the folds of the axilla, and thence drawn down to the middle of the space between the condyles of the humerus. This indicates the course of the brachial artery. It should barely divide the skin, care being taken not to injure the fascia beneath it. It will be found convenient to bound it below by a transverse incision; after which, the skin may be cautiously raised from the fascia all round the arm. In order to expose the deltoid, it will be necessary to make an incision through the integument, commencing at the external third of the clavicle, and extended along the acromion and spine of the scapula; after which, it may be dissected off the muscle, proceeding from above downwards and outwards, until the whole flap of skin is removed. When the muscle has been examined, it may be easily detached from its origin, and reflected down on the arm, by inserting the scalpel under its posterior border, and cutting from within outwards, close along the margin of the spine of the scapula, and so successively along the acromion and clavicle. This will expose the circumflex vessels and the external rotator muscles.

The fascia of the arm may in the next place be divided, and reflected in the same way as the integument. In doing so, care should be taken not to injure the internal cutaneous nerve. As the fascia is being reflected, the biceps muscle and the brachial artery and the nerves, except the circumflex and spiral, are brought into view. Their relative position, particularly at the bend of the arm, should be attentively considered. If the arm be rotated outward, the direction of the spiral nerve and profunda artery can easily be traced, for some way, between the heads of the triceps muscle. At the outer side of the arm, the nerve will be found in the deep sulcus between the *brachialis anticus* and *supinator longus*, after it has made its turn behind the humerus. The external cutaneous nerve also has to reach the external side of the arm, but it runs in front of the

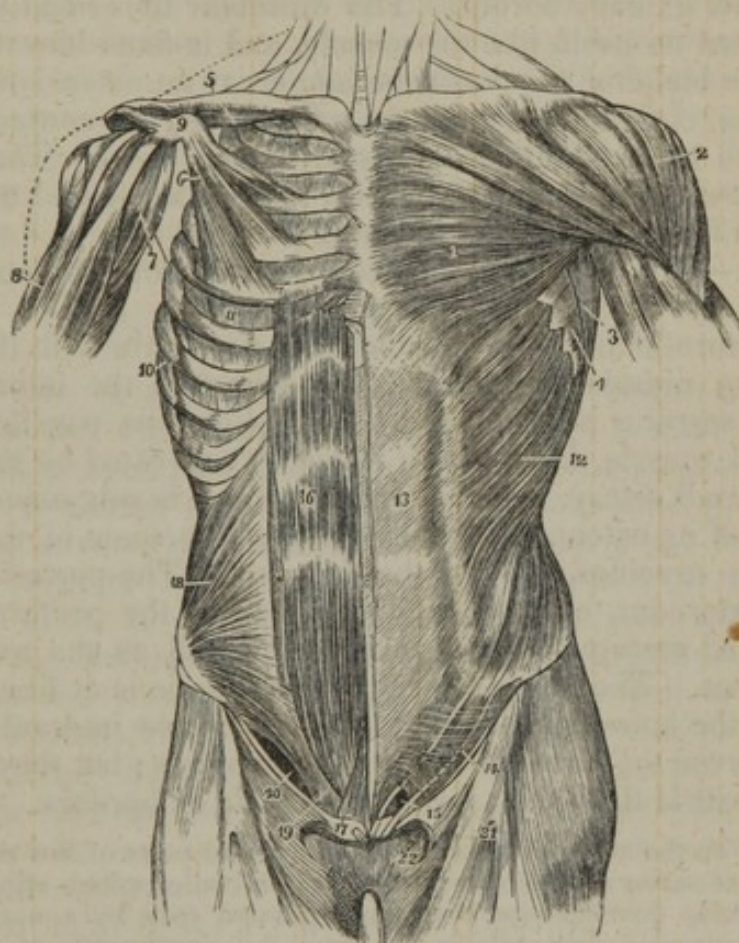


humerus, piercing the coraco-brachialis and then lying between the biceps and brachialis anticus. The examination of the triceps had better be conducted from below upwards, and, when its three heads have been carefully traced out, a longitudinal incision may be made through the substance of the muscle; after which, when the two parts are drawn back, the manner in which the fleshy fibres proceed to the bone, from its tendon or aponeurosis, will be distinctly seen.

#### THORACIC REGION (ANTERIOR).

The *pectoralis major* (fig. 182,<sup>1</sup>) (*pectoralis*; *sterno-costo-clavi-humeralis*) is placed on the anterior and upper part of the thorax, and in front of the axilla. It is broad and expanded at the former situation, narrowing gradually towards the latter, and *arises* from the sternal

[Fig. 182.



The muscles of the anterior aspect of the trunk. 1. The pectoralis major muscle. 2. The deltoid. 3. The anterior border of the latissimus dorsi. 4. The serrations of the serratus magnus. 5. The subclavius muscle of the right side. 6. The pectoralis minor. 7. The coraco-brachialis muscle. 8. The upper part of the biceps muscle, showing its two heads. 9. The coracoid process of the scapula. 10. The serratus magnus of the right side. 11. The external intercostal muscle of the fifth intercostal space. 12. The external oblique muscle. 13. Its aponeurosis; the median line to the right of this number is the linea alba; the flexuous line to its left is the linea semilunaris; and the transverse lines above and below the number, the lineæ transversæ. 14. Poupart's ligament. 15. The external abdominal ring. The numbers 14 and 15 are situated upon the fascia lata of the thigh; the opening immediately to the right of 15 is the saphenous opening. 16. The rectus muscle of the right side. 17. The pyramidalis muscle. 18. The internal oblique muscle. 19. The conjoint tendon of the internal oblique and transversalis descending behind Poupart's ligament to the pectineal line. 20. The arch formed between the lower curved border of the internal oblique muscle and Poupart's ligament. —W.]



half, or a little more, of the clavicle, from the anterior surface of the sternum, extending as far down as the insertion of the cartilage of the sixth rib, from the cartilages of the true ribs, except the first and last, and from the aponeurosis of the external oblique muscle. From this extensive origin the fleshy fibres proceed, converging towards the tendon of insertion; those from the clavicle, which are usually separated from the rest by a cellular interval, pass downwards and outwards; those from the lower cartilages obliquely outwards; the middle set horizontally. The muscular fibres become continuous with those of the tendon, and still retain their original direction as they proceed to their respective points of insertion into the humerus; and as the superior fibres descend, whilst the inferior ones ascend, the latter passing behind the former, the muscle is folded, the middle of the fold being along its axillary border. The muscular fibres end in a tendon which is folded on itself, like the muscle, and is fixed into the anterior margin of the bicipital groove of the humerus; an extension from it, at the same time, continuing across the groove, and in contact with the bone, to blend with the tendon of the latissimus dorsi. The tendon is likewise connected at its insertion with that of the deltoid muscle, and an expansion from it joins the fascia of the arm.

Structure:—The muscle is aponeurotic at its internal and external attachments, and fleshy in the rest of its extent.

The aponeurotic fibres of this muscle decussate with those of the corresponding muscle in front of the sternum; the inferior border overlaps the serratus magnus, and the superior runs parallel with that of the deltoid muscle, from which it is only separated by the cephalic vein and a small artery. The anterior surface is subcutaneous in the greater part of its extent, being only covered by some of the fibres of the platysma myoides, and by the mamma. The posterior surface, besides the sternum, clavicle, and ribs, covers the pectoralis minor, subclavius, and serratus magnus muscles, as well as the axillary vessels and nerves. The lower border of this muscle is at first separated from that of the latissimus dorsi by a considerable interval, in which may be observed the fibres of the serratus magnus; but they gradually converge towards the axilla, forming its folds or borders.

The interval on the sternum between the muscular parts of the right and left pectoral muscles varies in different cases; in some bodies which afford examples of large muscular development, they are separated only by a narrow groove. One or two muscular slips, taking rise from the aponeurosis of the external oblique muscle, are occasionally added to the lower margin of the pectoral muscle; and, on the contrary, a deficiency may be met with in the same situation. This was, in one case, found to be so extensive as to amount to the absence of all except the clavicular part of the muscle.\*

*Pectoralis minor* (fig. 182,\* ) (serratus anticus,—Alb.; costo-coracoideus.)—The smaller pectoral muscle lies at the superior part of the thorax, covered by the preceding muscle, and extended obliquely across the axilla. It arises from the upper margin, or the upper margin and external surface, of three ribs, usually the third, fourth,

\* See the work on Arteries before cited, page 233.



and fifth, near their cartilages; the origin being notched or serrated, so that by some of the older anatomists the muscle was named from that circumstance. The fleshy fibres, as they proceed obliquely upwards and outwards, converge to a narrow tendon, which is *inserted* into the inner and upper border of the coracoid process near its extremity, and is joined to the coraco-brachialis and the biceps muscle, which are likewise attached to the same process.—The anterior surface is covered by the pectoralis major, the posterior crosses the axillary vessels and nerves.

The *subclavius muscle* (fig. 182,<sup>5</sup>) (*costo-clavicularis*) is, as the name implies, placed under the clavicle, in the interval between it and the first rib. It *arises* by a short thick tendon from the cartilage of the first rib, close to the rhomboid ligament, from which it is directed outwards beneath the clavicle, forming a rounded fleshy fasciculus, which is *inserted* into the grooved and rough surface, along the costal aspect of the clavicle, for nearly half its length.—The upper surface is covered by the clavicle, a small part beneath it being overlapped by the pectoralis major, but which is at first not perceptible, until a dense fascia that covers it is dissected off; the costal surface lies in front of the subclavian vessels as they pass down from the neck.

#### THORACIC REGION (LATERAL).

The *serratus magnus* (figs. 180,<sup>23</sup> 182,<sup>4</sup>) (*costo-basi-scapularis*) is placed upon the upper and lateral parts of the thorax, between the ribs and the scapula, being deeply seated in the greater part of its extent. It is broad, thin, and irregularly four-sided (trapezoid) in form. The anterior border presents nine fleshy points or digitations, giving it a serrated appearance, whence its name is taken. By these digitations at its points of attachment the muscle arises from the surface of the first eight ribs (two of the processes being connected with the second rib); and opposite the first as well as a few other intercostal spaces, fibres are derived from slender tendinous structures over the external intercostal muscles. From this extensive origin, the fibres of the muscle, forming a thin stratum and curving as they proceed backwards over the convexity of the ribs, are inserted into the base of the scapula on its inner or costal aspect, being interposed between the subscapularis on the one side and the rhomboidei and levator anguli scapulæ on the other.

To receive insertions on an extent of surface so much less than that from which they arise, the fibres converge; but as their convergence is not uniform, and the fibres are differently arranged at the upper, middle, and lower ends, three parts of the muscle are recognised as follows. *a.* The fibres from the first and second digitations form a narrow and thick band which terminates on the inner surface of the scapula immediately below the upper angle. *b.* Those of the third and fourth digitations spread out into a thin layer, (the thinnest part of the muscle,) which occupies the scapula from the preceding part nearly to the lower angle of the bone.—Much the larger portion of



this, the middle division of the muscle, is formed by the third digitation, which expands into a triangular form. *c.* From the five remaining digitations, (which are received into notches in the external oblique muscle of the abdomen,) the muscular structure converges to a thick and partly tendinous mass, and is inserted close to the lower angle of the scapula on its inner surface.

The fibres of the first part of the muscle coalesce from their origin, but the rest remain more distinct, being separated by linear depressions until they approach the scapula; and they have, therefore, a more fasciculated appearance.

One surface of the serratus magnus rests on the superior ribs, the intercostal muscles, and part of the serratus posticus superior; the other is subcutaneous in the angular interval between the pectoralis and latissimus dorsi; higher up it is covered by both the pectoral muscles; in the rest of its extent it is in relation with the subscapular muscle and the axillary vessels.

Not unfrequently the number of digitations, and the number of the ribs with which the muscle is connected, are augmented by one or two; and occasionally the attachment to the first rib is wanting. Examples are recorded of the absence of the thin middle part of the muscle, and some other peculiarities of minor importance, e. g., the presence of additional muscular bands have been noticed.

*Combined actions.*—The most obvious actions of these muscles are exerted upon the shoulder and arm, as being their more movable points of attachment. The *pectoralis major*, conjointly with the latissimus dorsi and teres major, depresses the humerus, if it has been previously elevated; it then conspires with them in pressing the arm closely to the side, and, continuing the same effort, will by itself trail it along the side and front of the chest. The *pectoralis minor* draws the point of the shoulder downwards and inwards to the thorax. If the arms be fixed, these muscles act on the ribs and assist in dilating the chest. This is frequently observed during the forcible efforts at inspiration made by asthmatic persons; the arms are rendered fixed, by seizing hold of some object, and then every muscular effort is called into play which can elevate the ribs.

When the scapula is rendered fixed by the trapezius and rhomboid muscles, the *serratus* acts on the chest in the same way as the pectoral muscles do; but its most ordinary action is to draw the base and inferior angle of the scapula forwards, so as to elevate the point of the shoulder by means of the rotatory motion it can impress upon it conjointly with the trapezius, as has been observed when treating of the latter muscle. The continuation of the same effort retains the shoulder elevated, as when a burden is sustained upon it; but, as a preparatory measure, the thorax must be fixed. Whilst any important muscular exertion is being performed, the thorax must be fixed, and retained so by preventing the escape of the included air. This may be inferred from observation on what takes place under such circumstances, but was reduced to the test of experiment by M. Bourdon.\* He opened the trachea, or larynx, of a dog that had been in the habit of jumping and tumbling when bidden; after which, the animal was no longer able to make any similar efforts, though evidently willing to do so. But when the aperture was closed, by drawing the margins of the wound together, the lost power was instantly restored.

#### ACROMIAL REGION.

The *deltoid muscle* (fig. 182,<sup>2</sup>) (*deltoides*; sub-acromio-humeralis) is situated at the superior and external part of the arm, covering the shoulder-joint over which it is curved,—being placed at the same time

\* Mémoire sur les Efforts.



in front and behind it as well as on its outer side. Its form is triangular, the base above, and the apex below, and is thus the shape of the Greek letter  $\Delta$  reversed, from which circumstance the muscle has been named.

It *arises* from the external third of the clavicle, from the lower border of the acromion, and from the spine of the scapula as far back as the small triangular surface in which it terminates; and is *inserted* into the rough prominence on the middle of the outer side of the humerus. At its origin the deltoid is tendinous and fleshy, except at the back part of the spine of the scapula, where it is tendinous only. Moreover, the surface of origin is much increased by means of processes of fibrous structure, which extend from the acromion downwards through the muscle and give rise to fleshy fibres. The lower end is muscular on the cutaneous surface, and its deeper part is formed by a thick tendon. The whole appearance of the muscle is coarse, the muscular bundles being separated by broad cellular interspaces.

As the fibres converge, they necessarily have different directions. All are directed downwards,—those in the middle vertically, those from before and behind obliquely, the former being inclined backwards, the latter forwards.

The deltoid is separated from the integuments by a thin layer of fascia, with a portion of the platysma and a few nerves. It covers the tendon of the pectoralis major, the circumflex vessels and nerve, the outer side of the humerus, the fibrous capsule of the shoulder-joint (a synovial bursa or laminated cellular membrane being interposed,) the coracoid process, the pectoralis minor, coraco-brachialis, biceps, subscapularis, coraco-acromial ligament, the external rotator muscles, and the triceps. The anterior border is in contact with the pectoralis major (from which it is partly separated by the cephalic vein,) and more inferiorly with the biceps; the posterior border is bound down by fascia.

From the manner in which the tendinous structure is mixed with the fleshy fibres of this muscle at its middle, several subdivisions are to be recognised. Albinus\* points out seven portions arranged into two orders. The first order consists of four parts, which are each characterized by being broad at the upper end, and narrowing downwards. Two of these, which are large, constitute the anterior and posterior parts of the muscle, and occupy, one the clavicle, the other the spine of the scapula; the two smaller are connected with the acromion. The second order consists of three slender parts. They are interposed between the former, and are distinguished from them by being narrow at the upper part of the muscle, where they begin as tendinous bands.

The arrangement here pointed out appears to resolve itself into the facts before indicated, namely, that most of the muscular fibres are derived from the bones directly, or from a short tendinous structure; and that tendinous bands descending from the acromion at intervals divide these fibres into parts (the first order of Albinus), and give origin to other fibres at some distance downwards (the second order of the same author). It should be added, that the arrangement of the fibres does not in all cases conform with the description of Albinus, though the general character is the same.—The extent to which the muscle reaches on the humerus varies in different persons.

\* The mode of considering the structure of the muscle, or the facts on which it was founded, appear to have been suggested by Douglas, in personal communication with Albinus.—See the "Hist. muscul. hom." p. 423.



## SCAPULAR REGION (POSTERIOR).

*Supraspinatus* (fig. 180,<sup>17</sup>).—This muscle is placed at the superior part of the shoulder, in the supraspinous fossa of the scapula. Its form is elongated and triangular. It *arises* from the posterior two-thirds of the fossa above mentioned, and from the fascia which covers the muscle; the muscular fibres converge to a tendon in their middle, which adheres to the capsule of the shoulder-joint, and is *inserted* into the superior surface of the greater tuberosity of the humerus.

The supraspinatus is covered by the trapezius, coraco-acromion ligament, and deltoid. It lies against the scapula and the ligamentum proprium posticum, together with the suprascapular nerve and vessels, the omo-hyoideus muscle, and the fibrous capsule of the shoulder-joint, with which it is intimately united.

The *infraspinatus* (fig. 180,<sup>18</sup>) occupies the chief part of the infraspinous fossa, and is triangular in shape. It *arises* from the lower surface of the spine of the scapula, and from the posterior two-thirds of the convex part of its dorsum. The fibres converge to a tendon, at first concealed in a great degree within the substance of the muscle, but which afterwards proceeds forwards over the capsular ligament of the joint, to be *inserted* into the middle facet of the great tuberosity of the humerus. The superior fibres are nearly horizontal, the inferior ones ascend obliquely to meet them.

The posterior surface is covered, partly by the deltoid, the latissimus dorsi, and trapezius, a small part also being separated from the integument only by the fascia. The anterior one rests on the bone, (vessels and nerves being interposed,) and the capsular ligament, to which it is intimately adherent. The lower border is in contact with the teres minor, and is united posteriorly with it and the teres major.

The *teres minor* (fig. 180,<sup>19</sup>) lies along the inferior border of the scapula; its form is elongated, narrow and round. It *arises* by a series of oblique fibres from the dorsal surface of that ridge which surmounts the axillary border of the scapula, and from two aponeurotic septa, placed between it and the infraspinatus and teres major muscles. Its *insertion*, which lies immediately below that of the infraspinatus into the greater tuberosity of the humerus, is effected by means of a thick tendon.

The teres minor is covered by the integuments and the deltoid muscle. It is supported by the scapula, (the dorsal branch of the subscapular artery ramifying between them,) the long head of the triceps muscle, and the fibrous capsule of the shoulder-joint, to which it adheres like the preceding muscles. The upper border lies in contact with the infraspinatus; the lower with the teres major, from which it is separated anteriorly by the long head of the triceps; the posterior extremity is, as it were, inserted between the teres major and infraspinatus, being connected with both, as has been above stated.

—The three flat surfaces marked on the upper part of the great tuberosity of the humerus give insertion to the three muscles last described, taken in their regular order, from above downwards.

The *teres major* (fig. 180,<sup>20</sup>) extends from the inferior angle of the



scapula to the humerus, contributing to form the posterior border of the axilla. It is rather broad and compressed than round or tapering, as its name would imply. It *arises* from the flat expanded surface placed at the inferior angle of the scapula, and from the septa interposed between it and the teres minor and infraspinatus. The *insertion* takes place by a broad flat tendon into the posterior border of the bicipital groove in the humerus, and is in close contact with the tendon of the latissimus dorsi. The direction of the muscle must necessarily vary according to the different positions of the scapula and humerus. Towards their insertion the fibres of the teres major appear to descend somewhat, whilst those of the latissimus ascend, so that the margin of the former is placed lower down than that of the latter muscle.

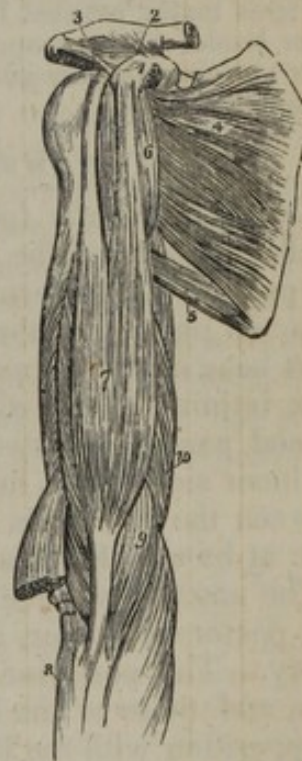This muscle is covered by the latissimus dorsi and integument, and is crossed by the long head of the triceps, which separates it from the teres minor; the anterior surface, in part of its extent, is in contact with the latissimus (in consequence of the change of direction of the latter), and slightly with the coraco-brachialis and the brachial vessels.

#### SCAPULAR REGION (ANTERIOR).

*Subscapularis* (fig. 183,\*)—The subscapular muscle, triangular in form, fills up the hollow of the scapula, lying between that bone and the thorax, from which, however, it is separated by the serratus magnus muscle. It *arises* from the posterior two-thirds of the subscapular fossa, with the exception of a narrow line along the base, and two wider spaces near the upper and lower angles of the bone, which are occupied by the serratus magnus; a portion of the muscle is likewise derived from slender tendinous laminae intersecting it and connected with the ridges on the bone. From this extensive origin the fibres are directed outwards, converging and augmenting the thickness of the muscle, and end in the tendon of insertion, (which is at first concealed among them,) as well as in several elongations of it, which penetrate deeply into the substance of the muscular structure. The tendon is attached to the small tuberosity of the humerus.

The subscapular muscle is very deeply placed. It is in contact by the outer surface with the scapula and the capsule of the

[Fig. 183.



The muscles of the anterior aspect of the upper arm. 1. The coracoid process of the scapula. 2. The coraco-clavicular ligament (trapezoid), passing upwards to the scapular end of the clavicle. 3. The coraco-acromial ligament, passing outwards to the acromion. 4. The subscapularis muscle. 5. The teres major. 6. The coraco-brachialis. 7. The biceps. 8. The upper end of the radius. 9. The brachialis anticus; a portion of the muscle is seen on the outer side of the tendon of the biceps. 10. The internal head of the triceps—W.]



shoulder-joint (partly with the synovial membrane through an aperture in the fibrous structure); and, by the inner or anterior surface, with the serratus magnus, (loose cellular substance being interposed,) and the coraco-brachialis and biceps, with the axillary vessels and nerves. The upper margin is close to the coracoid process of the scapula, and a synovial membrane has been found between them.

A band of muscular fibres, from two to three inches in length, is sometimes found extending from the scapula to the neck of the humerus immediately below the subscapularis.

*Actions.*—The *deltoid* can raise the arm directly from the side, so as to bring it at right angles with the body; after which, by means of its anterior and posterior fibres, it can carry the limb alternately backwards and forwards, being assisted in the former movement by the *teres major* and *latissimus dorsi*, in the latter by the *pectoralis major*. The mass of its muscular fibres is so considerable, that it is enabled, by pressing down the head of the humerus, to make it glide upon the surface of the glenoid cavity of the scapula, and then, by continuing the effort, to raise the limb directly upwards, so as to bring it to the vertical position. Its only assistant in elevating the arm is the *supra-spinatus* (whose power in this respect must be trivial, as it is inserted so near the centre of motion).

The *supra-spinatus*, *infra-spinatus*, and *teres minor* are the external rotators of the arm, whilst the *subscapularis* rotates it inwards; for, as they are opposed in situation, so they are antagonists in action. The power of these muscles is increased in no small degree by passing over the globular head of the humerus, and also by being inserted into the prominent processes of bone which remove the line of their direction to a distance from the axis of the humerus.

The *teres major* conspires with the *latissimus dorsi* in its actions; it depresses the arm, if raised, and rotates it on its axis. If the arm be fixed, as when, in the reclining posture, the elbow is removed from the side, these muscles, particularly the *teres major*, assisted by the long head of the *triceps*, can approximate the lower border of the scapula to the shaft of the humerus, thus conspiring with other muscles, viz., the *pectoralis* and *latissimus dorsi*, to trail the body after the outstretched limb.

#### HUMERAL REGION (ANTERIOR).

*Coraco-brachialis* (*perforatus*,—Casseri<sup>us</sup>\*) (fig. 183,<sup>6</sup>).—This, the smallest muscle of the upper arm, is placed along the superior and inner part of the humerus for about half its length. It *arises* from the coracoid process of the scapula, between the *pectoralis minor* and the short head of the *biceps*; also from the tendon of the latter, with which it is intimately united for some way. The fleshy fasciculus thus formed passes downwards and a little outwards, to be inserted into the inner side of the humerus about its middle, where it is interposed between the *brachialis anticus* and the *triceps*. Structure:—aponeurotic at its attachments, fleshy in the middle.

The anterior surface of this muscle is covered above by the *deltoid* and *pectoralis major*, and at its insertion is crossed by the *brachial artery*. The posterior surface runs over the tendon of the *subscapularis*, and those of the *latissimus dorsi* and *teres major*; one border is in apposition with the *biceps*, the other with the *brachial artery*. The muscle is usually pierced by the *musculo-cutaneous nerve*.

The *biceps* muscle (fig. 183,<sup>7</sup>) (*biceps flexor cubiti*; *coraco-scapulo-radialis*) lies along the anterior part of the arm for its entire length,

\* "Tabulæ Anatom." edited by Daniel Bucretius (Rindfleisch), tab. 19 and 20. The name has reference to the perforation by the *musculo-cutaneous nerve*.



extending from the scapula to the fore-arm. Superiorly it is divided into two heads, whence its name is derived. Of these, the internal or short head arises conjointly with the coraco-brachialis from the coracoid process of the scapula by a thick tendon, which spreads out and gives origin to the muscular fibres. The external or long head commences by an elongated and rounded tendon, which springs from the upper margin of the glenoid cavity of the scapula, and is continuous with the glenoid ligament. The tendon passing immediately over the head of the humerus, covered by a special tube of the synovial membrane of the joint, pierces the fibrous capsule at its humeral attachment, and, after descending some way in the groove of the bone appropriated to it, spreads into a round expansion from which the muscular fibres take their rise. The fleshy fibres of the two heads join and form what is named the belly of the muscle, which is broad and somewhat flattened, and ends above the bend of the elbow in the tendon of insertion. This sinks between the muscles of the fore-arm, to be inserted into the posterior part of the "bicipital" tuberosity of the radius; from the anterior part of which process it is separated by a synovial bursa. The tendon is at first broad and thin, but it gradually narrows, and when approaching the radius is twisted on itself, so as to be applied by a flat surface to the bone on which it ends. At its commencement a fibrous expansion, presenting an arched border, is sent off from the tendon, and this process passes obliquely downwards and inwards, and becomes blended with the fascia of the fore-arm somewhat below the inner condyle.—The expansion is stretched across the brachial artery, median nerve, and part of the pronator teres muscle.

The anterior surface of the muscle is overlapped superiorly for some way by the deltoid and pectoral muscles; but in all the rest of its extent it is covered only by the integument and fascia, with the exception, however, of the lower tendon, which sinks deeply between the muscles, and at its termination corresponds with a notch in the margin of the supinator brevis. The posterior surface, for about half its length, rests on the humerus and shoulder-joint, and in the rest on the brachialis anticus, being separated from the latter by the musculocutaneous nerve. The inner border is in contact with the coraco-brachialis for half its length, and with the brachial artery for the rest. The connexion of the long tendon of origin with the shoulder-joint has been sufficiently noticed.

A third head, taking origin from the humerus, is occasionally added to this muscle. The fibres are usually more or less blended at their origin with the brachialis anticus (I have seen them arise between it and the lower end of the coraco-brachialis); and they were, therefore, considered by Albinus to be an offset from that muscle to the biceps. The added part, which is sometimes equal to half the size of the coraco-brachialis, joins the biceps at its posterior and inner side near the tendon, and lies outside the brachial artery; but in at least two instances I found such an accessory piece crossing over the artery. A muscular band has been observed to extend in the opposite direction to the foregoing, viz. from the biceps to the intermuscular septum above the inner condyle of the humerus. This had the appearance of a second coraco-brachialis; it lay over the brachial artery.\*

\* See a Treatise on Arteries, before cited, page 270 and plate 57.



*Brachialis anticus* (brachialis internus,—Douglas and Albinus: humero-cubitalis) (fig. 183,<sup>9</sup>).—This muscle lies under cover of the biceps, along the lower half of the arm. In form it is somewhat compressed, and is broader in the middle than at the extremities. It arises from the fore part of the humerus, commencing at the insertion of the deltoid, (which it embraces by two angular fleshy processes,) and extending nearly to the border of the trochlea; some fibres also arise from the intermuscular septum at the inner side. After passing in front of the elbow-joint, the muscular portion ends in a thick fasciculus of tendinous fibres, which is inserted into the rough surface on the fore part of the coronoid process of the ulna, where it is received into a notch on the upper extremity of the flexor digitorum profundus. The middle fibres are vertical, those on each side converge a little to them.—The posterior surface rests on the bone and capsular ligament; the anterior, partly concealed by the biceps, projects somewhat at each side of it, and supports the brachial artery and median nerve.

Some fibres from the middle of the brachialis anticus have been found to pass in an unusual direction inwards over the brachial artery to be connected with the internal intermuscular septum.\*

*Combined Actions.*—The most obvious action of the biceps is that of flexing the fore-arm, in which it conspires with the *brachialis anticus*; it also serves to render tense the fascia of the fore-arm by means of the process which connects its tendon with that membrane. If the arm be placed in the prone position, the biceps can turn it supine, being in this particular the direct antagonist of the pronator radii teres. When the fore-arm is rendered fixed by holding some firm object, the biceps and brachialis muscles can draw on the humerus, and bend it forwards on the arm, which is exemplified in the effort of climbing. They also can move the humerus on the scapula; but their influence in this respect must be very limited, as they run parallel with the axis of the bone. When the humerus is fixed, these muscles, by drawing on the coracoid process, move the scapula, and therefore the glenoid cavity on the head of the bone, so that the latter may receive support from the former, rather than that it should be pressed up against the capsular ligament solely.

#### HUMERAL REGION (POSTERIOR).

The *triceps* [*extensor*] *cubiti*,—Douglas; triceps brachii,—Alb. (fig. 184,) the only muscle that lies behind the bone and intermuscular septa, rests against the posterior surface of the humerus in its entire length, and extends from the lower border of the scapula to the upper extremity of the ulna. Superiorly it is divided into three processes or heads, whence its name is derived, whilst its lower half, or more, is single and undivided. The *long head*<sup>2</sup> arises from the lower part of the glenoid cavity and an adjoining rough portion of the inferior costa of the scapula, by a tendon which spreads over the sides of the muscular structure to whose fibres it gives origin. The muscular fibres from this source, passing downwards between those of the other two parts or heads, end by joining with them in the common tendon of insertion. The *external head*<sup>1</sup> takes origin by tendinous and fleshy fibres from the humerus immediately below the great tuberosity, where it gives insertion to the teres minor, and from the surface of the bone below that point: from likewise the ridge above the external condyle, together with the external intermuscular septum. The fibres proceed-

\* See the work referred to for peculiarities of the biceps, p. 271.



ing from this extended origin follow different directions to terminate in the general mass on the common tendon. The *short head*,<sup>3</sup> placed to the inner side, and derived likewise from the humerus, commences by muscular fibres having a narrow and pointed form, near to the insertion of the *teres major*, taking their rise from this part, from the intermuscular septum above the inner condyle and the posterior surface of the humerus; the fibres are directed, some immediately to the olecranon, the rest to the general tendon of insertion.

The tendinous structure on which the large mass of muscular fibres is received inferiorly, consists of two strata. One of these, which is subcutaneous, covers the muscle to a considerable extent, and is the cause of the flatness above the elbow which is especially apparent when the muscle is put into action. The second layer is placed deeply, and both, after giving insertion to the muscular fibres, and joining together above the olecranon, are fixed to the posterior and upper part of that process.

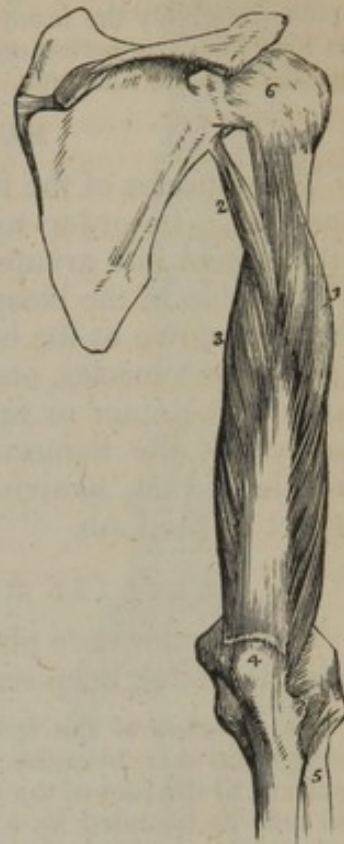
The long head of the triceps lies between the two "*teres*" muscles, and is in contact with the capsule of the shoulder-joint. The muscle is separated from the bone by the musculo-spiral nerve and the superior profunda artery, which correspond with a groove before noticed, and are covered by slender fibrous structure. It is separated at each side of the bone from the muscles in front of the arm by the intermuscular septa connected with the ridges above the condyles of the humerus. The lower part covers the elbow-joint; and between the tendon and the top of the olecranon is interposed a synovial bursa, which in some instances is multilocular.

M. Theile\* limits the origin of the second head of the triceps muscle to the part of the humerus above the spiral groove for the musculo-spiral nerve; and this anatomist assigns to the short head all the fibres given from the posterior surface of the bone below that groove, as well as those from the ridge above the external condyle of the humerus.

On removing the triceps from the lower part of the humerus, some muscular fibres will be found connected with the capsule of the elbow-joint. Two slips extending from the bone above the fossa for the olecranon to the capsule have been described as distinct from the triceps, under the name *sub-anconæus*.† These fibres are analogous to the *subcrureus*, which occupies a corresponding place in the lower limb.

*Actions*.—When the fore-arm is flexed, the triceps, by drawing on the extremity of the ulna, is enabled to extend it on the humerus, and so bring both parts of

[Fig. 184.]



A posterior view of the upper arm, showing the triceps muscle. 1. Its external head. 2. Its long, or scapular head. 3. Its internal, or short head. 4. The olecranon process of the ulna. 5. The radius. 6. The capsular ligament of the shoulder joint.—W.]

\* Müller's "Archiv." &c. 1839, S. 420, and "Sæmmerring v. Baue," &c.

† Theile in "Sæmmerring v. Baue," &c.



the limb into a right line. In situation, as well as in action, it is thus the direct antagonist of the biceps and brachialis anticus. When the arm is in the extended position, the long head of the triceps may assist, in some degree, the teres major and latissimus in carrying it backwards. If the elbow be fixed, the scapula becomes relatively the more movable point of attachment of the muscle; and then its long head, by acting on the lower border of that bone, can approximate it to the shaft of the humerus.

#### MUSCLES OF THE FORE-ARM.

The muscles of the fore-arm are very numerous, and their relations complex. In order to facilitate the examination of them, we shall divide them into groups, according to the positions which they occupy. The tendon of the biceps muscle, together with the brachial vessels, as they dip down at the bend of the elbow-joint, is placed between two masses of muscles, one of which lies to the inner or ulnar side, the other to the outer or radial; the former being attached to the internal condyle of the humerus, the latter to the external. Another set of muscles, which likewise admits of subdivision, occupies the posterior aspect of the limb.

#### BRACHIAL REGION (INNER AND ANTERIOR).

The muscles here placed are disposed in two sets, one being superficial, the other deep-seated.

The *dissection* of the fore-arm may be commenced by making an incision through the skin, from the middle of the interval between the condyles of the humerus to the root of the thumb; this marks out the course of the radial artery, and may be bounded by a transverse incision at each extremity. If the integument be drawn tightly forwards, and reflected inwards, the cutaneous nerves may be seen running in the cellular tissue between it and the fascia; and, when once found, there can be little difficulty in tracing them in their entire extent, as they can be made to rest on the fascia, which gives them a firm support, whilst the scalpel is carried from above downwards along their cutaneous surface. After the superficial nerves and veins have been examined, the fascia may be dissected off the muscles. The examination of the muscles should be conducted in the order in which they are described, commencing with those attached to the inner condyle.

The *superficial muscles* of the anterior and inner part of the fore-arm are, the pronator radii teres, flexor carpi radialis, palmaris longus, flexor carpi ulnaris, and flexor digitorum sublimis. These are all intimately united at their origin from the inner condyle, to which they are attached by a *common tendon* that gives a fasciculus of fibres to each, and also sends septa between them.

*Pronator teres*,—Douglas and Albinus; pronator radii teres,—Cowper (fig. 185,\*).—This muscle is extended obliquely across the front of the arm at its upper third. It *arises* by two distinct heads; one, large and superficial, is derived from the upper part of the inner condyle of the humerus, also from the common tendon above mentioned, from the fascia of the fore-arm, and the septum between this muscle and those nearest to it. The second head, a thin fasciculus deeply placed, comes from the inner margin of the coronoid process, and joins the other at an acute angle, being previously separated from it by the median nerve. The fleshy belly thus formed proceeds outwards and downwards, and ends in a flat tendon which turns over the radius, and



is inserted into a rough surface on the outer side of that bone.

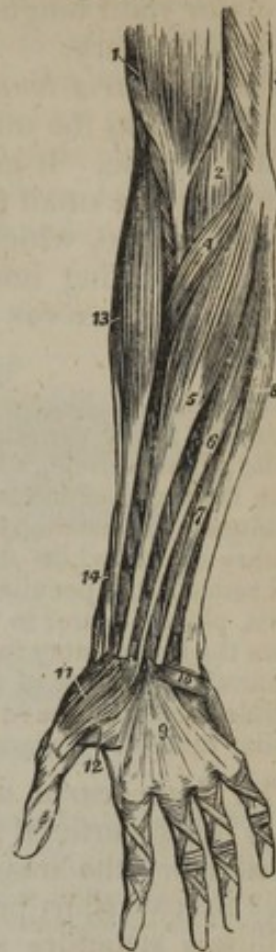The anterior surface of the pronator teres is superficial in the greater part of its extent; but towards its insertion it is crossed by the radial artery and nerve, and the supinator longus muscle. The ulnar border is in contact with the flexor carpi radialis and palmaris longus: the radial border bounds, with the supinator longus, an angular space, in which are placed the brachial artery, the median nerve, and the tendon of the biceps muscle. The pronator teres covers the flexor sublimis digitorum and ulnar artery; and the fibres which arise from the ulna pass between the last-named artery and the median nerve.

The origin of the pronator teres sometimes increases in extent, the additional fibres being derived from the intermuscular partition above the inner condyle of the humerus. The added portion is usually continuous with the upper margin of the muscle; but in some instances it will be found separated at first from it by an interval. This peculiarity of the muscle I have repeatedly found associated with a change in the direction of the brachial artery.

The *flexor carpi radialis*,—Cowper, (*radialis internus*,—Alb.) (fig. 185,<sup>s</sup>) is situated in front of the fore-arm, extending from the inner condyle to the outer side of the metacarpus. It arises from the inner condyle by the common tendon, from the fascia of the arm, and from the intermuscular septa placed between it and the pronator teres on one side, the palmaris longus on the other, and the flexor sublimis posteriorly. The fleshy fibres soon end in a fibrous expansion, which narrows into a flat tendon, and is free from the muscular part a little below the middle of the fore-arm. Arrived at the carpus, the tendon passes in a special compartment at the outer side of the anterior annular ligament of the wrist, and runs through a groove in the os trapezium (to which it is bound by a thin fibrous sheath, lined by a synovial membrane), to be inserted into the extremity of the second metacarpal bone.

The anterior surface is covered by the fascia and integument; the posterior rests on the flexor sublimis, the flexor pollicis longus, prona-

[Fig. 185.]



Superficial layer of the muscles of the fore-arm. 1. The lower part of the biceps, with its tendon. 2. A part of the brachialis anticus, seen beneath the biceps. 3. A part of the triceps. 4. The pronator radii teres. 5. The flexor carpi radialis. 6. The palmaris longus. 7. One of the fasciculi of the flexor sublimis digitorum; the rest of the muscle is seen beneath the tendons of the palmaris longus and flexor carpi radialis. 8. The flexor carpi ulnaris. 9. The palmar fascia. 10. The palmaris brevis muscle. 11. The abductor pollicis muscle. 12. One portion of the flexor brevis pollicis; the leading line crosses a part of the adductor pollicis. 13. The supinator longus muscle. 14. The extensor ossis metacarpi, and extensor primi internodii pollicis, curving around the lower border of the fore-arm. —W.]



tor quadratus, and wrist-joint. Its tendon lies between those of the supinator radii longus and palmaris longus, and to its outer side lies the radial artery.

The *palmaris longus* (fig. 185,<sup>6</sup>), the smallest of this mass of muscles, lies along the middle of the fore-arm, on the ulnar side of the preceding muscle. It *arises* from the inner condyle and the intermuscular septa; the small fleshy belly of the upper part soon ends in a long slender tendon, which is *inserted* into the annular ligament of the wrist, continuing into the palmar fascia.<sup>9</sup>—This muscle is placed between the flexores carpi radialis and ulnaris, resting on the flexor sublimis.

The palmaris longus is frequently altogether wanting. When present, it is subject to many variations of form, e. g., the muscular fibres may occupy the middle of the muscle, which then commences and ends by an elongated tendon; or the muscular structure may occur towards the lower end, the upper part being tendinous. Occasionally there are two long palmar muscles, one having the ordinary shape, while the other has one of the forms above referred to. The most remarkable peculiarity is that in which a small muscle (a second palmaris longus, placed nearer to the inner border of the fore-arm than the usual muscle) covers the ulnar artery for some space above the carpus, and terminates, partly in the annular ligament of the carpus or fascia, and partly in the short muscles of the little finger. I have elsewhere given an account of some examples of this peculiar muscle.\*

The *flexor carpi ulnaris*,—Cowper, (ulnaris internus,—Alb.,) (fig. 185,<sup>8</sup>) lies superficial along the ulnar border of the fore-arm, being extended from the inner condyle to the inner margin of the wrist. It *arises* by two short processes, the interval between which is occupied by fibrous structure arching over the ulnar nerve. One of these is attached to the inner condyle, the other to the border of the olecranon. The muscle is also connected with intermuscular septa, and for some distance with the inner side of the ulna by a dense fascia. The muscular fibres from these different points of attachment terminate in a tendon, which is *inserted* into the pisiform bone, and into the base of the fifth metacarpal bone. The tendon is at first concealed within the muscle, but it afterwards appears on the outer side, and receives muscular fibres on the opposite side nearly to its termination, and is therefore, semipenniform.

The anterior surface is covered by the skin and fascia, the posterior rests on the flexor profundus, and overlaps the ulnar nerve and artery;—towards the lower part of the fore-arm the artery is opposite the outer margin of the muscle, and this is taken by surgeons as a guide to the position of the vessel.

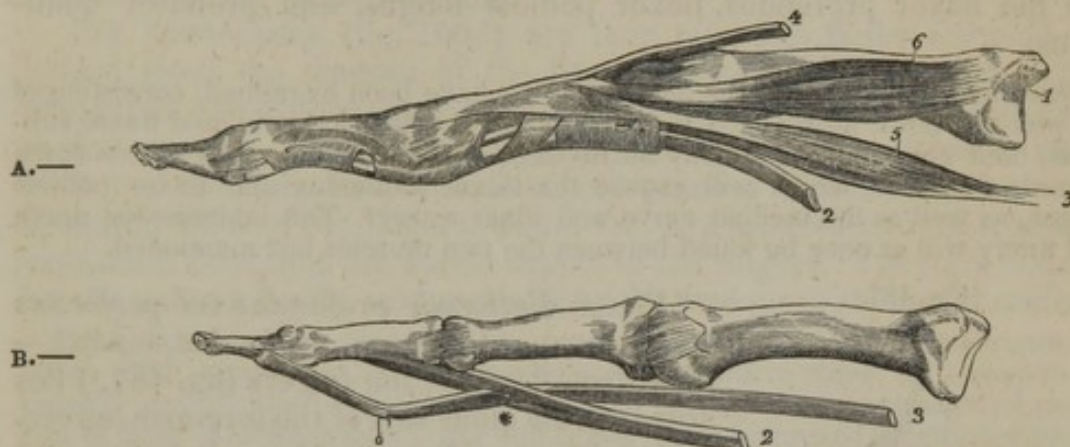
The *flexor digitorum sublimis vel perforatus* (perforatus,—Cowper; sublimis,—Alb.)—The superficial flexor of the fingers (fig. 185,<sup>7</sup>) is placed at the anterior part of the fore-arm, between the preceding muscles, which conceal it, and the flexor profundus and flexor longus pollicis, which are beneath it. It is flat and broad in the upper part, and inferiorly divides into four tendons. It *arises* from the inner condyle, by the common tendon and the fibrous septa common to it and

\* "The Arteries," &c. page 334, and plate 45.



the other muscles, also from the internal lateral ligament, from the anterior surface of the coronoid process at its inner side, and from the oblique line extended downwards from the tubercle of the radius. The fleshy belly enlarges towards the middle of the arm, but diminishes somewhat before its division. The four tendons pass under the annular ligament of the wrist in pairs, one of which is placed in front of the other; the anterior pair consists of the tendons for the middle and the ring fingers, the posterior of those for the index and the little fingers.

Fig. 186.



The metacarpal and phalangeal bones of two fingers, with the tendons. In the first figure the tendons of the flexor muscles are bound to the finger by the fibrous bands; in the second they are freed from that structure, as well as from the synovial membrane and the vincula accessoria. 1. Metacarpal bone. 2. Tendon of flexor sublimis. 3. Tendon of flexor profundus. \* The perforation of the former by the latter. 4. Tendon of extensor digitorum communis. 5. A lumbricalis muscle. 6. An interosseous muscle.

As they proceed to their destinations the tendons diverge, (the largest being that for the middle finger, the smallest for the little finger,) and each, accompanied by a tendon from the flexor profundus, enters beneath fibrous bands (ligamenta vaginalia), (fig. 186, A,) which are firmly fixed to the margins of the phalanges, and bind both tendons together down to the palmar surface of the bones;—and thus a fibro-osseous canal is constructed for the tendons. Opposite the first phalanx the tendon of the flexor sublimis presents a fissured interval, (fig. 186, B,) which transmits that of the deep flexor, (whence the name perforatus,) and finally, after expanding somewhat and forming on its palmar surface a groove, which is adapted to the accompanying tendon, it is *inserted* into the fore part of the second phalanx. The same arrangement obtains in each instance within the canals on the fingers. A few slender and loose filaments are extended from the phalangeal bones to both the tendons. They have been named “vincula accessoria tendinum,” or “vincula vasculosa.”

Superiorly, the flexor sublimis is concealed by the other muscles of this set, and is crossed near the radius by the radial artery; it rests on the flexor pollicis longus and flexor profundus, separated from the latter by the median nerve and the ulnar artery. In the palm of the hand, its tendons are covered by the palmar fascia, the superficial palmar arch of arteries, and the branches of the median nerve, and they lie in front of the accompanying tendons of the flexor profundus,



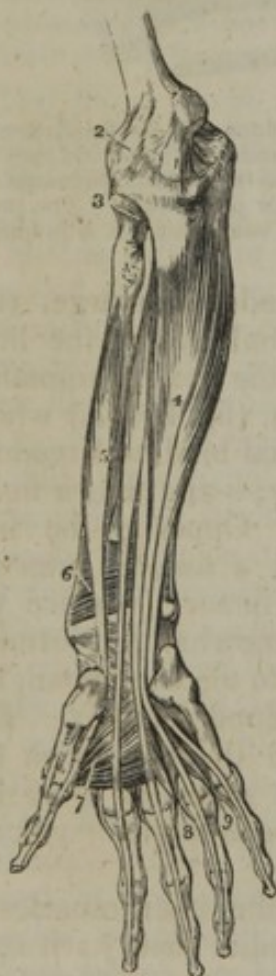except after they have been perforated by these. Where the tendons slide beneath the annular ligament, they are invested by a synovial membrane, and a similar provision for easy movement exists on the phalanges of each of the fingers.

This muscle is subject to several slight variations from the arrangement above described. One or two may be referred to. A muscular slip is frequently given from it to the flexor profundus, or to the flexor longus pollicis. The tendon for the little finger is sometimes wanting, and I have seen this coincide with a similar deficiency in the foot.

The *deep-seated* muscles, on the anterior surface of the fore-arm, are the flexor profundus, flexor pollicis longus, and pronator quadratus.

*Dissection.*—When the superficial muscles have been examined, consisting of the pronator teres, flexor radialis, palmaris longus, flexor ulnaris, and flexor sublimis, their common origin may be divided, and the whole mass drawn down towards the hand, which will expose the flexor profundus and flexor pollicis longus, as well as the median nerve and ulnar artery. The interosseous nerve and artery will at once be found between the two muscles last mentioned.

[Fig. 187.



*Flexor digitorum profundus vel perforans* (perforans, — Cowper; profundus, — Alb.)—The deep flexor of the fingers (fig. 187,<sup>4</sup>) lies towards the ulnar side of the fore-arm, covered by the preceding muscles. It is thin and compressed above, presents in the middle a fleshy belly of considerable size, and inferiorly is divided into four tendons. The muscle arises from the hollow at the inner side of the olecranon,—from the inner border and anterior surface of the ulna, to within a few lines of the edge of the pronator quadratus, and from the ulnar half of the interosseous ligament. The tendons are free from the muscular substance above the wrist, and that destined for the index-finger is distinct from the others, which are connected together as far as the palm. Under the annular ligament, they lie behind the tendons of the flexor sublimis, and they maintain the same relation to these latter as they pass along the metacarpal bones and digital phalanges. Opposite the first phalanx, the tendon of each finger passes through the fissure formed for its transmission in the tendon of the flexor sublimis (fig. 186, B), and proceeds to be inserted into the base of the last phalanx. The tendons are bound to the phalanges by fibrous bands,

The deep layer of muscles of the fore-arm. 1. The internal lateral ligament of the elbow joint. 2. The anterior ligament. 3. The orbicular ligament of the head of the radius. 4. The flexor profundus digitorum muscle. 5. The flexor longus pollicis. 6. The pronator quadratus. 7. The adductor pollicis muscle. 8. The dorsal interosseous muscle of the middle finger, and palmar interosseous of the ring finger. 9. The dorsal interosseous muscle of the ring finger, and palmar interosseous of the little finger.—W.]



and loosely connected with those bones by the slender vincula accessoria, in the manner mentioned in describing the last muscle.

The upper extremity of the muscle in a manner embraces the insertion of the brachialis anticus. The posterior surface rests on the ulna, the interosseous ligament, and pronator quadratus; the anterior one is covered by the ulnar artery and nerve, the median nerve, and the other flexor muscles. The external border is parallel with the flexor pollicis longus, from which it is separated, on the interosseous membrane, by the anterior interosseous artery and nerve. The tendons are covered by the synovial sacs which have been mentioned in connexion with the flexor sublimis.

The *lumbricales* (fig. 190,<sup>7</sup>) are four tapering, fleshy fasciculi, extended from the tendons of the flexor profundus to the first digital phalanges, and are therefore to be considered accessories or appendages to that muscle. They arise by fleshy fibres from the outer or radial border of the deep flexor tendons, and proceed forwards to the corresponding sides of the fingers, where they are inserted into the tendinous expansion covering the dorsal aspect of the fingers. They are covered by the palmar fascia, and partially by the tendons of the flexor sublimis.

These little muscles are subject to many deviations from the ordinary arrangement. The number is not unfrequently diminished to three, or it may be increased (much more rarely, however,) to five or six. The destination of one or two of them is often changed, and one finger (most frequently the third or fourth) is found to be provided with two. Lastly, one may be divided between two fingers.

*Flexor longus pollicis manus* (fig. 187,<sup>5</sup>). The long flexor of the thumb lies on the same plane as the flexor profundus, resting on the radius. It arises from the grooved surface on the fore part of the radius,—commencing just below the oblique line which extends downwards from its tubercle, and reaching nearly to the edge of the pronator quadratus,—also from the adjacent part of the interosseous ligament. The fleshy fibres come forward to a tendon, which, after passing beneath the annular ligament of the wrist, turns outwards, lying between the two heads of the flexor brevis and the sesamoid bones, and then enters a canal, similar to those for the other flexor tendons. Finally the tendon is inserted into the base of the second phalanx of the thumb.

This muscle is covered by the flexor carpi radialis, flexor sublimis, and somewhat by the pronator teres, also by the radial vessels. The inner border is in contact with the flexor profundus, the anterior interosseous artery and nerve being interposed. Towards the lower part of the arm, its fibres can be readily perceived between the tendon of the supinator longus and flexor carpi radialis.—In some cases the flexor pollicis receives a bundle of fibres from the flexor sublimis.

*Pronator quadratus* (fig. 187,<sup>6</sup>; fig. 191,<sup>1</sup>). This small square muscle is placed behind the other muscles, and is extended across the radius and ulna, immediately above their carpal extremities; it is flat and thick (especially so at the middle), and about two inches in breadth. Its origin, or fixed attachment, is from the anterior surface and the inner border of the ulna (curving over the bone), in the situation and extent just mentioned, and from a tendinous layer on its sur-



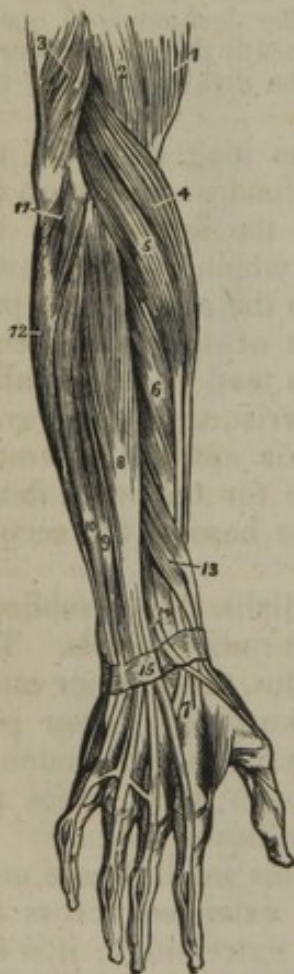face. The fibres pass directly across, to be inserted into the fore part and anterior surface of the radius.

One surface of the muscle rests on the bones and interosseous membrane, and covers the anterior interosseous artery and nerve; the other is covered by the tendons of the flexor muscles and the radial artery.

*Combined Actions.*—These muscles act on the fore-arm, the hand, and the digital phalanges.—The radius is made to turn on the ulna, and the hand thereby pronated by the *pronator teres* and *quadratus*, which take their fixed points, the one on the humerus, the other on the ulna, and draw the radius inwards across the latter bone. Should the *pronator teres*, after having effected so much, continue its action, it becomes virtually a flexor, and will assist the other muscles in bending the fore-arm on the arm.—So also the *flexors of the fingers*, after having bent the phalanges towards the palm, begin to act on the wrist, and then contribute to the flexion of the fore-arm by means of the mechanical advantage they derive by passing under the annular ligament of the wrist. The *flexores carpi*, too, after having bent the wrist, become subsequently flexors of the fore-arm. The flexion of the phalanges is obviously effected by the superficial and deep common flexors, and by the flexor pollicis.

#### RADIAL REGION.

[Fig. 188.]



The muscles placed along the outer side of the fore-arm are the supinator radii longus and brevis, the extensor carpi radialis longior and brevior.

*Dissection.*—These muscles are readily exposed by reflecting the skin and the fascia outwards, from a few inches above the external condyle down to the wrist; the preceding dissections obviously mark out the way of conducting this.

*Supinator longus*,—Douglas and Alb. (supinator radii longus,—Cowper; brachioradialis,—Sæmmerring), (fig. 185,<sup>13</sup>; fig. 188,<sup>4</sup>).—This is the first and most prominent muscle of the external set, and lies upon the radial border of the arm, extended from nearly the middle of the humerus to the end of the radius. It arises from the external condyloid ridge of the humerus, nearly as high up as the insertion of the deltoid, where it is interposed between the brachialis anticus and the external intermuscular septum, to which also its fibres are attached. The

The superficial layer of muscles of the posterior aspect of the fore-arm. 1. The lower part of the biceps. 2. Part of the brachialis anticus. 3. The lower part of the triceps, inserted into the olecranon. 4. The supinator longus. 5. The extensor carpi radialis longior. 6. The extensor carpi radialis brevior. 7. The tendons of insertion of these two muscles. 8. The extensor communis digitorum. 9. The extensor minimi digiti. 10. The extensor carpi ulnaris. 11. The an-

coneus. 12. Part of the flexor carpi ulnaris. 13. The extensor ossis metacarpi and extensor primi internodii muscle, lying together. 14. The extensor secundi internodii; its tendon is seen crossing the two tendons of the extensor carpi radialis longior and brevior. 15. The posterior annular ligament. The tendons of the common extensors are seen upon the back of the hand, and their mode of distribution on the dorsum of the fingers.—W.]



thin fleshy mass proceeding from this elongated source descends upon the anterior and outer border of the arm, and, about its middle, ends in a flat tendon, which, continuing the same course, is *inserted* into the external border of the radius, close to the base of its styloid process.

This muscle is covered only by the skin and fascia, except the insertion, which is covered by the extensor muscles of the thumb. It rests on the humerus, extensor carpi radialis (longior and brevior), the insertion of the pronator teres, and the supinator radii brevis. The inner border is in contact, above the bend of the elbow, with the brachialis anticus, and with the musculo-spiral nerve and the accompanying artery; along the fore-arm it is in contact with the radial artery and nerve, and serves as a guide to the position of the vessel.

The *extensor carpi radialis longior* (radialis externus longior,—Alb.) (fig. 188,<sup>5</sup>) is partly covered by the preceding muscle, but its external border projects beyond it. It *arises* lower down than the supinator longus, from the external condyloid ridge as well as from the intermuscular septum, and a tendon common to it and other muscles connected with the outer condyle. After passing along the outside of the articulation, it ends, at the upper third of the arm, in rather a broad, flat tendon, which descends along the outer and back part of the radius. The tendon passes, conjointly with that of the following muscle, in a groove in the lower extremity of the bone, and is inserted into the base of the metacarpal bone of the fore-finger. The fleshy part of the muscle is partly covered by the supinator longus, and the upper fibres are often continuous with the lower part of that muscle. Its tendon passes beneath the extensors of the thumb, and the posterior annular ligament of the wrist.

*Extensor carpi radialis brevior*,—Douglas (radialis externus brev.—Alb.) (fig. 188,<sup>6</sup>).—Shorter, as the name implies, than the preceding, to which it immediately succeeds on the fore-arm, this muscle *arises* from the extremity of the outer condyle of the humerus, by the common tendon and the fibrous processes which intervene between it and other extensor muscles, also from a tendinous expansion on its surface, and from the external lateral ligament of the elbow-joint. The fleshy belly ends in a flat tendon, which remains closely applied to that of the preceding muscle, and with it proceeds in the groove in the radius, and under the annular ligament, where it diverges somewhat, in order to be *inserted* into the base of the metacarpal bone of the middle finger.

*Combined Actions*.—These are the direct antagonists of the pronators of the hand and flexors of the wrist. If the hand be previously pronated, the supinators, by rolling the radius on the ulna, turn the palm supine; but the extent and power of action of each differ considerably. The *supinator longus*, notwithstanding its length and size, can act but feebly in supinating the hand, inasmuch as its direction is parallel with that of the radius: its direction and attachments indicate it to be a flexor of the fore-arm. The *supinator brevis*, both by its direction and mode of attachment, is by far the more efficient agent in moving the radius on the ulna. The action of the *radial extensors* is fully indicated by their name; if their effort be continued, they assist in extending the fore-arm on the arm.



## BRACHIAL REGION, (POSTERIOR AND SUPERFICIAL.)

The muscles situated on the posterior aspect of the fore-arm are the anconeus, the extensor communis digitorum, extensor carpi ulnaris, and extensor minimi digiti, which are superficial; whilst the rest are deep-seated, viz., the three extensors of the thumb, the extensor indicis, and the supinator radii brevis.

*Dissection.*—The muscles on the posterior side of the fore-arm are numerous and closely connected together, so that their dissection and arrangement are sometimes deemed difficult. An incision may, in the first place, be made from the olecranon to the middle of the back of the hand, which should be bounded at each extremity by a transverse incision. The skin, having been thus divided, may be reflected off the fascia in its entire extent; and, when the fascia has been examined, it may be divided in the same way as the skin, and dissected off the muscles, which will be facilitated by proceeding from below upwards, taking the different tendons as guides to their respective muscles, until all of them are exposed, and their borders defined. When this has been effected, little difficulty will be experienced in distinguishing them from one another, if the first line of the description given of them be attended to, as it indicates the situation and direction of each; and, when the name of a muscle is known, everything relative to its anatomical characters will be found in the section which treats of it.

The *anconeus* (fig. 188,<sup>11</sup>; ἀγκών, the elbow) is placed immediately behind and beneath the elbow-joint, being a small triangular muscle. It *arises*, by a tendon, from the extremity of the outer condyle of the humerus, at its posterior aspect. From this the fibres proceed, diverging from one another, the upper ones being horizontal, the rest passing downwards with increasing degrees of obliquity; and all are *inserted* into the radial aspect of the olecranon and the adjacent surface of the ulna itself.

The anconeus is superficial in its entire extent, and lies below the outer part of the triceps extensor, with which it is continuous by its upper margin. It covers part of the ligament of the elbow-joint and of the supinator brevis, together with the recurrent branch of the interosseous artery.

The *extensor communis digitorum* (fig. 188,<sup>8</sup>) lies along the posterior part of the fore-arm. It *arises* by a tendon common to it and the other superficial extensor muscles, also from the fascia of the arm, and the septa between it and the adjoining muscles. Somewhat below the middle of the fore-arm the muscular part ends in four tendons, which, after passing beneath the posterior annular ligament of the wrist, diverge as they proceed along the carpus and metacarpus to reach the fingers. Each tendon expands, and, being increased by tendinous fibres derived from the lumbricales and interosseous muscles, forms a fibrous expansion (see fig. 186), which encases the back of the first and second digital phalanges, and terminates upon the third. It is attached to the second and third phalanges in the following manner. Opposite the second joint, the tendon appears to divide into two fasciculi, which leave, apparently, an elliptic interval between them. The tendon, however, is not deficient at this part: it is much thinner than at the sides, and this thin middle portion is inserted into the base of the second phalanx. The two lateral parts, continuing



onwards, are joined together towards the middle or lower part of the second phalanx; and, having passed beyond this, are inserted into the last phalanx. On the index finger and the little finger the tendons are joined, before their division, by those from the special extensors of those fingers. Moreover, the tendon furnished from the common extensor to the fore-finger is separate from the rest; while the others are connected by transverse bands over the metacarpus.

At its origin, this muscle lies between the extensor carpi radialis brevis and the extensor digiti minimi, and maintains the same relation as it descends towards the wrist. It covers the supinator radii brevis, the extensors of the thumb at their origin, and the indicator. A synovial membrane encases the tendons as they pass under the annular ligament.

*Extensor minimi digiti* (extensor proprius auricularis,—Alb.), (fig. 188,<sup>9</sup>).—The extensor of the little finger is usually united with the common extensor. It is placed between that muscle and the extensor carpi ulnaris. It *arises*, in common with the extensor communis, by a thin tendinous part, giving origin to a slender bundle of fleshy fibres. The tendon in which it ends passes through a ring in the annular ligament appropriated to itself, and joins with the fourth digital tendon of the common extensor, conjointly with which it expands upon the posterior surface of the phalanges of the little finger.

*Extensor carpi ulnaris* (ulnaris externus,—Alb.), (fig. 188,<sup>10</sup>) lies towards the ulnar border of the fore-arm, being extended from the external condyle to the root of the little finger. It *arises* from the external condyle of the humerus, by the common tendon and an elongation from it; from the ulna, for some space below the anconeus; and from the fascia of the arm. The muscular fibres derived from this source incline somewhat inwards, and end in a tendon, which runs through a special groove in the carpal end of the ulna, and, after passing between the carpus and annular ligaments, is inserted into the posterior extremity of the metacarpal bone, sustaining the little finger.—Like the foregoing muscles, it is covered only by the skin and fascia, and it conceals the supinator brevis in part, as well as the extensor of the index finger.

#### BRACHIAL REGION (DEEP POSTERIOR).

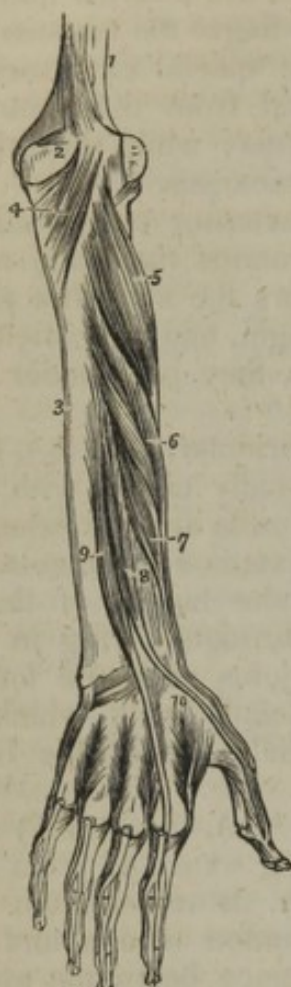The deep-seated muscles on the back of the arm are all less in size and length than the superficial set, from which they are readily distinguishable by the obliquity of their direction.

*Dissection*.—When the long extensors which arise from the external condyle have been examined, they may be detached from their origin, and drawn outwards, so as to expose those which lie deeply between, or on the bones. The supinator brevis and anconeus, both short muscles, and oblique in the direction of their fibres, will be seen close below the elbow-joint, whilst the extensors of the thumb, and the indicator, lie obliquely over the middle and lower part of the radius.

*Extensor ossis metacarpi pollicis* (fig. 189,<sup>6</sup>), (abductor longus pollicis



[Fig. 189.]



The deep layer of muscles on the posterior aspect of the fore-arm. 1. The lower part of the humerus. 2. The olecranon. 3. The ulna. 4. The anconeus muscle. 5. The supinator brevis muscle. 6. The extensor ossis metacarpi pollicis. 7. The extensor primi internodii pollicis. 8. The extensor secundi internodii pollicis. 9. The extensor indicis. 10. The first dorsal interosseous muscle. The other three dorsal interossei are seen between the metacarpal bones of their respective fingers.—W.]

liquely downwards and forwards from the ulna to the thumb. It *arises* from the back part of the ulna, immediately below the great abductor, and from the adjacent part of the interosseous ligament. The fleshy belly derived from these attachments soon ends in a tendon, which is bound down in a separate compartment by the annular ligament, and runs through the narrow oblique groove (specially appropriated to it) at the middle of the carpal end of the radius, to be *inserted* into the base of the second phalanx of the thumb.

A part of the tendon of the extensor ossis metacarpi is often found to terminate in the upper end of the abductor pollicis.—The extensor primi internodii is not unfrequently united with the extensor of the metacarpal bone, and only a slender

manus,—Alb.)—This muscle, the extensor of the metacarpal bone of the thumb, which is the largest of the deep extensor muscles, descends obliquely over the bones of the fore-arm, from the posterior to the outer side, lying immediately below the border of the supinator brevis. It *arises* from the external surface of the ulna, and from the interosseous ligament and the radius, as it crosses each; its fleshy belly ends in a tendon, which passes through a groove in the outer border of the radius, common to it and the extensor of the first phalanx of the thumb, and is *inserted* into the base of the metacarpal bone of the thumb.

The origin and upper part of the muscle are concealed by the common extensor, but it becomes superficial where it lies on the external border of the radius; and, whilst passing over the carpus, its tendon crosses those of the radial extensors.

*Extensor primi internodii pollicis* (extensor minor pollicis manus,—Alb.)—The extensor of the first phalanx (fig. 189,<sup>7</sup>) is much smaller than the preceding, and lies close to its lower border. The muscle *arises* from the interosseous ligament and radius, and slightly, if at all, from the ulna; it takes the same direction as the abductor, which it accompanies through the groove in the radius, and over the corresponding border of the carpus. The tendon proceeds onwards to the thumb, and is *inserted* into the upper end of its first phalanx.

*Extensor secundi internodii pollicis* (extensor major pollicis manus,—Alb.)—The extensor of the second phalanx (fig. 189,<sup>8</sup>) is much larger than the preceding muscle, which it partly covers; its direction is ob-



tendinous filament reaches the first phalanx.—A portion of the third muscle (extensor secundi internodii) has been found attached to the first phalanx.

Whilst passing along the groove, the tendon of this muscle is separated from those of the other extensors of the thumb, by the groove which lodges the radial extensors: and near the base of the first metacarpal bone, the radial artery is lodged in the interval which separates them.

*Extensor indicis* (fig. 189,<sup>o</sup>) (indicator).—The extensor of the index finger is nearly of the same size as the preceding muscle, whose lower border it accompanies. It *arises* from the posterior surface of the ulna, about its middle, also from the interosseous ligament. The tendon, which is continued from the muscular part, passes, together with the common extensor, beneath the annular ligament, comes in contact with the digital tendon of the latter, which is destined for the index finger, and unites with it to form the tendinous expansion; and through it both are *inserted* into the posterior surface of the second and third phalanges, in the manner mentioned in the description of the common extensor muscle.

The *supinator brevis* (supinator radii brevis,—Cowper), (fig. 189,<sup>s</sup>) is a short triangular muscle, lying in close contact with the bones, and extended obliquely from the outer condyle of the humerus to the upper third of the radius, over which it is curved. It *arises* from the external condyle, and from the external lateral ligament, as far as its insertion into the annular ligament of the radius, also from a rough ridge and a depressed surface below the sigmoid cavity of the ulna. The fibres of the muscle, derived from these points of attachment, as well as from a tendinous expansion over the muscle, pass obliquely round the upper part of the radius, covering it, and connected with it, except at its inner side.

The supinator brevis is covered by several muscles. It lies on the ligaments at the outer side of the elbow-joint; and the posterior branch of the musculo-spiral nerve passes through its fibres. By means of a notch in the anterior margin, it is adapted to the bicipital tuberosity of the radius.

*Combined Actions.*—These muscles act on the fingers and hand in the first instance, and then, by a continuance of their effort, on the fore-arm, which they assist in extending. The common extensor, as well as those of the thumb, the fore-finger, and little finger, are, from their situation and attachments, the direct antagonists of the flexors; the latter, however, being, from their size and number, the more powerful agents. If the bones of the thumb be drawn inwards to the palm, as when an object is firmly grasped, their extensor muscles may, by reason of the obliquity of their direction, assist in supinating the hand. Their names indicate their more ordinary action. The anconeus assists the triceps in extending the fore-arm. The supinator brevis turns the radius on its axis, so as to bring the hand into the supine position.

## MUSCLES OF THE HAND.

The muscles of the palmar surface of the hand admit of being divided into three sets or groups, viz., those of the thumb, those of the little finger, and thirdly, those placed in the middle of the palm. The extensors, which have been described in the foregoing pages, and the dorsal interossei, are the only muscles on the back of the hand.



*Dissection.*—The first step in the dissection of the hand consists in exposing the palmar fascia in its entire extent. (See its description among the structures of the same class.) For this purpose a transverse incision may be made at the wrist, down to the annular ligament; for, as the fascia arises from it, it affords an easy guide to that membrane. The integument may then be raised, and reflected forwards to the fingers, or to either side. When the fascia has been examined, it may be detached from its connexion with the annular ligament, and removed altogether; by which means the flexor tendons, the superficial arch of arteries, and the branches of the ulnar and median nerves, are brought into view. The digital prolongations of these different structures can, in the next place, be traced along the fingers by merely removing the integument. The short muscles of the thumb, and those of the little finger, may next engage attention. But it will not be necessary to add anything to what is stated in the description of the muscles, as they are placed in their anatomical order, care being also taken to indicate their situation and general characters, so that no mistake can occur. Deep in the palm of the hand are situated one set of interossei muscles; these cannot be seen until the flexor tendons are all removed. The extensor tendons must be displaced, in order to expose fully the dorsal interossei. Particular attention should be paid to the position of the superficial palmar arch of arteries, as well as to its digital branches.

#### EXTERNAL PALMAR REGION:—THENAR.\*

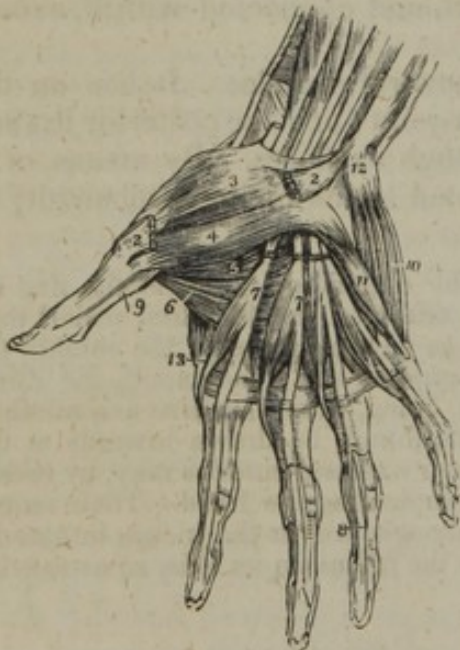
##### (MUSCLES OF THE THUMB.)

The fleshy mass which forms the ball of the thumb consists of four muscles, which are inserted into its metacarpal bone and the first phalanx—one to the former, and three to the latter.

The *abductor pollicis manus* (abductor brevis pollicis manus,—Alb.) (fig. 190,<sup>2</sup>) is a flat, narrow muscle, placed immediately beneath the skin. It arises from the annular ligament of the wrist,<sup>1</sup> and from

[Fig. 190.

the os trapezium, and proceeds outwards and forwards, to be inserted,



The muscles of the hand. 1. The annular ligament. 2, 2. The origin and insertion of the abductor pollicis muscle; the middle portion has been removed. 3. The flexor ossis metacarpi, or opponens pollicis. 4. One portion of the flexor brevis pollicis. 5. The deep portion of the flexor brevis pollicis. 6. The adductor pollicis. 7. The lumbricales muscles, arising from the deep flexor tendons, upon which the numbers are placed. The tendons of the flexor sublimis have been removed from the palm of the hand. 8. One of the tendons of the deep flexor, passing between the two terminal slips of the tendon of the flexor sublimis, to reach the last phalanx. 9. The tendon of the flexor longus pollicis, passing between the two portions of the flexor brevis to the last phalanx. 10. The abductor minimi digiti. 11. The flexor brevis minimi digiti. The edge of the flexor ossis metacarpi, or adductor minimi digiti, is seen projecting beyond the inner border of the flexor brevis. 12. The prominence of the pisiform bone. 13. The first dorsal interosseous muscle.—W.]

\* "Græci prominentiores partes palmarum appellant θήραρα, deducto vocabulo ἀπὸ τοῦ θέρειν (θέρειν), à percutiendo. Alii non omnes prominentiores palmæ partes sic appellatas existimant, sed eas tantùm quæ pollicis subiiciuntur," &c. Riolanus, "Anthropol." l. 5, c. 20.

Riolanus himself, however, used the word to designate one of the muscles, and applied the name "antithenar" to another. Winslow adopted and extended that plan of naming the muscles.



by a short thin tendon, into the base of the first phalanx of the thumb, at its radial border.—The muscle is superficial in its entire extent, and rests on the *opponens pollicis*.

*Opponens pollicis manus* (fig. 190,<sup>3</sup> fig. 191,<sup>2</sup>) [*flexor ossis metacarpi pollicis*.]—The part of the muscular substance thus named is triangular in shape and is placed beneath the preceding, but its borders project laterally, so as to be perceptible at each side of it. The fibres *arise* from the annular ligament and from the *os trapezium*, and thence proceed outwards and forwards, to be *inserted* into the whole length of the metacarpal bone of the thumb at its radial border.

One surface is covered by the abductor and integument, the other rests on bones and ligaments.

*Flexor brevis pollicis manus* (fig. 190,<sup>4</sup> \*).—This is larger than either of the preceding muscles, beneath which it is placed. Its carpal extremity is divided into two processes or heads, the interval between which transmits the tendon of the long flexor. One of these, which is anterior, and therefore superficial, relatively to the other, *arises* from the inner surface of the annular ligament, and from the *os trapezium*; the other is attached to the *os trapezoides* and *os magnum*. The fleshy fibres from these points of origin soon unite to form a single mass, but this again resolves itself into two short processes, which are *inserted* into the opposite borders of the base of the first phalanx of the thumb. In each of these tendons of insertion a sesamoid bone is placed, where it passes over the first joint of the thumb: and one of them is connected with the abductor, and the other with the adductor.

*Adductor pollicis manus* (fig. 190,<sup>5</sup>; fig. 191,<sup>4</sup>).—The adductor of the thumb is partly placed in the fold of skin between the thumb and the index finger, being extended from the metacarpal bone that sustains the middle finger, to the base of the first phalanx of the thumb. Its form is triangular, and the base is attached to the former bone, the apex to the latter. It *arises* from the palmar border of the third metacarpal bone, from which the fibres proceed outwards, converging to a short tendon, which is *inserted* into the base of the first phalanx of the thumb, where its fibres are blended with the inner insertion of the short flexor (fig. 191,<sup>3</sup>).

Near its origin this muscle is covered by the tendons of the flexor muscles; a portion of it is subcutaneous.

*Combined Actions*.—The names applied to the muscles of the thumb sufficiently indicate their actions and use; they are eight in all, and may be arranged as follows. In the first place, it should be recollected that there are three movable osseous pieces in the thumb, so articulated as to admit of the four movements of extension, flexion, abduction, and adduction. There are three extensors, one for each bone, viz., the extensor of the metacarpal bone, and those of the first and second phalanges; these are long muscles, placed on the dorsal aspect of the fore-arm and hand. Opposed in situation and action to these are the three flexors, lying on the palmar aspect of the thumb, viz., the *opponens* (which may be considered a flexor of the metacarpal bone), the *flexor brevis*, or flexor of the first phalanx, and *flexor longus*, which is the flexor of the second phalanx. There remain the abductor and adductor, which likewise are opposed to one another in situation and action; one being superficial and external, and therefore well calculated to draw the thumb away from the fingers, whilst the other is internal and deep-seated, and thereby enabled to approximate it to them. If these moving



powers be made to act successively, circumduction is performed; or, in other words, the thumb moves so as to describe a cone, whose summit is at its carpal articulation, and base at the line traversed by its extremity.

#### INTERNAL PALMAR REGION:—HYPOTHENAR.

##### (MUSCLES OF THE LITTLE FINGER.)

The thick fleshy mass at the inner border of the hand also consists of four muscles. One of them is cutaneous, the others are the proper muscles of the little finger.

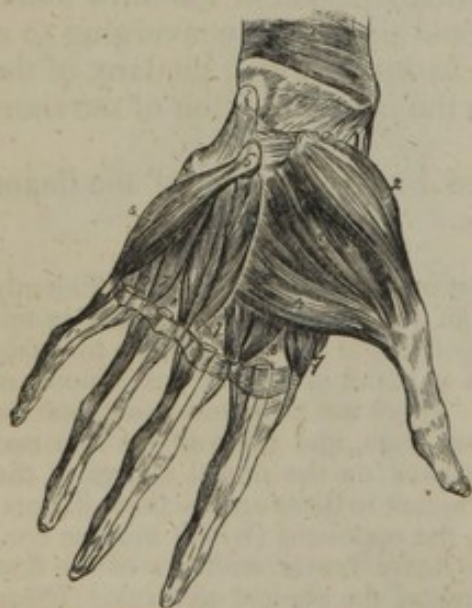*Palmaris brevis* (fig. 185,<sup>10</sup>).—This is a very small “cutaneous” muscle. It forms a thin and square plane of pale fibres, placed immediately beneath the skin. It *arises* from the annular ligament and palmar fascia, from which its fibres proceed transversely inwards, and are *inserted* into the skin along the inner border of the palm of the hand.—It is superficial to the muscles of the little finger and the ulnar artery and nerve; but these parts are covered immediately, and separated from the palmaris brevis by a thin elongation of the palmar fascia.

*Abductor digiti minimi manus* (fig. 190,<sup>10</sup>).—The abductor of the little finger runs along the ulnar border of the palm of the hand, *arising* by tendinous fibres from the pisiform bone,<sup>12</sup> and annular ligament, where they are blended with the insertion of the flexor carpi ulnaris. The fleshy belly, of which the muscle consists, ends in a tendon, which is *inserted* into the base of the first phalanx of the little finger at its ulnar border.—The muscle rests on the fifth metacarpal bone, and on the “opponens” of the little finger, and is covered by the palmaris brevis and palmar fascia.

The *flexor brevis digiti minimi* (fig. 190,<sup>11</sup>) is placed on the same plane with the abductor, lying to its outer side and joined with it at the insertion, so that in this situation both constitute but one muscle. But at their origin, where an interspace exists between them, they are separated by the deep palmar branch of the ulnar nerve, and the communicating branch of the artery. It *arises* from the anterior surface of the annular ligament, and from the unciform bone, and is *inserted* into the base of the first phalanx of the little finger in connexion with the preceding muscle.—In some instances the flexor does not exist, in which cases the abductor is found larger than usual. From this circumstance, as well as from its position and direction, it may be inferred that, in addition to its ordinary action of abduction, the last-named muscle can become also a flexor.

*Opponens digiti minimi* (adductor ossis metacarpi digiti minimi,—Alb.)

Fig. 191.



Chiefly the deep-seated muscles of the hand. 1. Pronator quadratus. 2. Opponens; 3. Flexor brevis; and 4. Adductor pollicis. 5. Opponens digiti minimi. 6. Unciform bone. 7, 8. Interosseous muscles.



(fig. 191,<sup>5</sup>).—This muscle is somewhat triangular in its form, and placed under cover of the others. It arises from the annular ligament, and from the hooked process of the unciform bone;<sup>6</sup> from these points the fibres incline forwards and inwards, to be *inserted* into a large part of the fifth metacarpal bone.

## MIDDLE PALMAR REGION.

The muscles placed in the space intervening between the two borders of the hand, are the lumbricales and interossei. The former have been already described with the flexor digitorum profundus.

The *interosseous* muscles (interossei) occupy the intervals between the bones (metacarpal), and are named from that circumstance. They extend from the sides of those bones to the first row of phalanges (métacarpo-phalangiens lateraux,—Chaussier); and are divided into two sets, viz., those which are visible at the dorsal aspect of the metacarpus, and those seen only in the palm.

The *dorsal interosseous* muscles (interossei externi v. bicipites) (fig. 190,<sup>10</sup>) are four in number, and occupy each one of the spaces between the metacarpal bones. They are named, like the spaces, numerically, from without inwards (fig. 192,<sup>1 2 3 4</sup>). One of them is known as the abductor indicis, and placed amongst some of the other groups of muscles, though in position, mode of attachment, and structure, it is strictly an interosseous muscle. The general characters of these muscles are as follows:—They lie between the metacarpal bones, and appear on their dorsal aspect, yet project into the palm, where they are shown in fig. 191,<sup>7 7</sup>. They arise from the contiguous sides of the bones between which they are placed, but more extensively

Fig. 192.

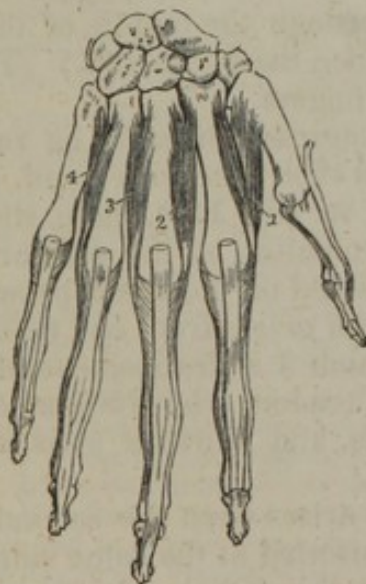

Fig. 193.

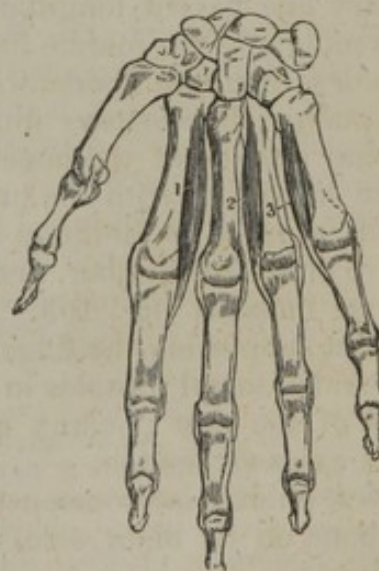

Fig. 192.—The dorsal interosseous muscles of the right hand, and their connexion with the tendons of the long extensor muscles of the fingers, are here represented.

Fig. 193.—The palmar interosseous muscles are shown in connexion with the bones of the right hand.

from the metacarpal bone supporting the finger into which the muscle is inserted, and the fibres from these sources converge to a common



tendon placed in the middle. The two parts or heads of this double origin are separated, at the upper extremity, by a narrow angular interval, in which a perforating arterial branch passes from one surface of the hand to the other. Lastly, the tendon of insertion of each terminates partly in the first phalanx at the side of its base, and partly also by joining with the tendon of the common extensor muscle on the dorsum of the finger (fig. 186).

The *first* dorsal interosseous muscle (fig. 192,<sup>1</sup>) (abductor indicis) is larger than the others, and lies in the interval between the thumb and the index finger. It arises by two heads, of which one, external and larger, is attached to the ulnar border of the first metacarpal bone at its upper part, the other to the contiguous margin of the second in nearly its whole length, the angular interval between them serving to transmit the radial artery into the palm of the hand. Both soon unite, and become inserted, by a thin tendon, on the outer side of the index finger, in the manner stated above. The *second* dorsal interosseous muscle<sup>2</sup> lies in the second metacarpal space. It arises from both bones, and terminates on the middle finger at its outer side. The *third*,<sup>3</sup> similarly placed in the third metacarpal space, is inserted likewise into the middle finger, but on the opposite side to the preceding. And the *fourth*,<sup>4</sup> lying in the corresponding space, is inserted into the ulnar side of the ring finger.

Thus:—the index finger is furnished with one of these muscles, and it is placed on the outer side; the ring finger, likewise, with one, but situated on the opposite (inner) side; and the middle finger has two muscles, one on each side. From this position the muscles are calculated to separate the fingers, and thus to increase the breadth of the hand. Or, according to the ingenious method of explaining their action, suggested by M. Cruveilhier, they move the fingers from an imaginary line passed longitudinally through the middle of the hand, *i. e.* the middle of the middle finger. (See the figure 192.) The dorsal muscles, then, are abductors of the fingers.

The *palmar interosseous* muscles (*interossei interni*) lie rather on the palmar surface of the bones than in their intervals; and, as they are here mixed up with the preceding set (fig. 191), these should be removed, in order to facilitate the examination of the palmar series. They are three in number, and are named on the same principle as the dorsal muscles (fig. 193,<sup>1 2 3</sup>). Each *arises* from one metacarpal bone—that supporting the finger for which it is destined,—and terminates like the dorsal muscles in a small tendon, which is *inserted* into the base of the first phalanx at its side, and likewise joins with the common extensor tendon.

The *first* palmar interosseous<sup>1</sup> muscle arises from the second metacarpal bone on its ulnar side, and is inserted at the same side of the index finger. The *second*<sup>2</sup> arises from the radial side of the fourth metacarpal bone, and is inserted on the same side of the ring-finger. The *third*<sup>3</sup> arises from the radial side of the fifth metacarpal bone, and is inserted into the little finger.

The palmar interosseous are opponents of the dorsal muscles. Each



moves the finger towards its fellows, or towards the middle of the hand; they are, therefore, adductors of the fingers.\*

*Actions.*—Besides the influence they exert in separating the fingers and bringing them together, which has been already noticed, the interosseous muscles may, to a certain extent, assist the extensor communis in extending or drawing back the fingers; and again, if the fingers be but slightly bent, as the direction of the interossei in that position forms an angle with that of the phalanges, they may assist in drawing them to the palm of the hand, that is, in flexing them.

#### ABDOMINAL REGION.

The abdomen is surrounded, except in the situation of the spine, by muscular and fibrous structures, which are called its "walls" or "parietes." The fibrous structure is usually considered an offset from the lateral muscles—these (the muscles) being said to end in the membranes or aponeuroses.

At each side, the abdominal wall is formed of muscular substance only, and consists of three muscular strata, the fibres of which are disposed in different directions. Viewing them as extending from behind towards the anterior part of the body, the fibres of the first stratum or muscle are directed obliquely downwards; those of the second, obliquely upwards; of the third, transversely. And they are named accordingly,—“descending oblique,” “ascending oblique,” and “transverse.” The first two are also distinguished as “external” and “internal,” on account of the position they hold one with respect to the other.

In front, the abdomen is bounded by aponeurotic as well as muscular structure. The former, being continued from the lateral muscles, is in layers, between which is placed a single muscle, close to the middle line on each side. The fleshy fibres of the muscle found in this situation have a vertical or straight course, and from this circumstance it is named “rectus.”

The posterior is much the thickest part of the abdominal parietes, for here the vertebræ and the large muscles of the back enter into its composition. Exclusive of these, and anteriorly to them, layers of thin fibrous membrane extend from the “transverse” muscle to the vertebræ, encasing a single muscle, as in front. This muscle reaches between the ilium and the last rib, and is square; it is named “quadratus lumborum.” And the membrane is called the “lumbar fascia.”

\* [In the medical schools of the United States, it has been most usual to follow Albinus<sup>1</sup> in the description of the interossei muscles, there being, according to this anatomist, four on the palm and three on the back of the hand, just the reverse of what is stated in the above description, and which is the one most generally adopted in Europe at the present time. This difference arises from Albinus having considered the first dorsal interosseous muscle as consisting of two distinct muscles, probably because its two heads are separated by a wider interval, for the transmission of the radial artery to the palm, than in the other dorsal interossei. The first of these muscles corresponds to the external head of the first dorsal interosseous, and is called by him the abductor indicis manus, the other, or that corresponding to the internal head, is named by him the prior indicis, and is included in the interossei of the palm.

This is not the true arrangement nor is it even the best description, for besides the two heads of the first dorsal interosseous muscle being associated together for more than half their length as they approach their insertion, the muscle occupies a position corresponding to that of the other dorsal interossei and has the same action,—that of abduction, while the three palmar interossei are adductors.—J. L.]

<sup>1</sup> B. S. Albini, Tab. Scel. et Musc. Corp. Hum., Londini, 1749.]



The structures above briefly noticed as constituting the walls of the abdomen, extend on each side from the middle line in front to the vertebral column, and occupy the interval between the ribs and sternum on the one hand, and the pelvis on the other. As their extent depends in a great measure on the interval to be filled up, a glance at the skeleton will show the length the muscles and membranes must have in different positions, and will make it evident that on the fore part of the abdomen they must have considerably greater length than on the posterior or lateral aspect. To the above general statement concerning the length of these structures the external oblique muscle affords an exception, inasmuch as it reaches for some space above the margin of the ribs, and in so far forms a portion of the walls of the thorax.

The parts just reviewed in their combination will now be examined singly.

*Dissection. To expose the external oblique muscle:*—When commencing the dissection of the abdominal muscles, an incision may be made through the skin from the ensiform cartilage to the umbilicus, and another from thence to the most depending part of the margin of the thorax. The angular flap of skin, bounded by these lines, may be easily reflected by commencing at its point, and taking the tendinous fibres of the external oblique muscle as a guide, each stroke of the scalpel being directed obliquely upwards and outwards. The flap should be reflected until its base, or attached border, is brought on a line with the ensiform cartilage, or somewhat higher, which is necessary in order to expose the digitated processes of the muscle and their intermixture with those of the serratus magnus. An incision may, in the next place, be carried horizontally inwards from the anterior superior spinous process of the ilium to the linea alba, and there met by another drawn down from the umbilicus. The enclosed flap of skin should be reflected back to the posterior part of the lumbar region. If it be required to exhibit the muscle in its entire extent, the portion of integument still remaining on the lower part of the abdomen may be divided by an incision drawn from the pubes upwards, and the flap reflected down over Poupart's ligament. For the present, however, we shall leave untouched the integument, muscle, &c. in the iliac region, as they will require to be examined attentively when treating of the dissection of the parts connected with hernia.

The *external oblique* muscle of the abdomen (fig. 182,<sup>12</sup>) (*obliquus externus abdominis*; *obliquus descendens*; *costo-abdominalis*; *ilio-pubi-costo-abdominalis*;) the largest of the three lateral muscles, is situated on the lateral and anterior parts of the abdomen, and consists of two parts: one, muscular, occupies the side of the abdomen; the other, aponeurotic, extends over the fore part of that cavity.

Broad, thin, and irregularly quadrilateral in form, this muscle *arises* from the anterior surfaces of the eight or nine inferior ribs, by fibres arranged in so many angular processes, named *digitations*. These are placed between similarly formed parts (*digitations*) of the serratus magnus and latissimus dorsi (five in connexion with the former, and three or four with the latter), in the manner the fingers of one hand may be interposed between those of the other; and it is from this circumstance that the processes are named. The lower and the upper *digitations* of the muscle are connected with the ribs near their cartilages; but those in the middle are attached at some distance from them; the lowest embraces the point of the twelfth rib. The fleshy fibres from the last ribs pass down in nearly a vertical direction to be *inserted* into the external margin of the crista ilii, the anterior half of



its length; all the rest incline downwards and forwards, and terminate in tendinous fibres, which form a broad aponeurosis.<sup>13</sup>

This structure (the *aponeurosis* of the external oblique), which is wider at the lower than at the upper part, and is larger than that of either of the other abdominal muscles, covers the fore part of the abdomen, and terminates by uniting with that of the opposite muscle along the median line, from the ensiform cartilage to the symphysis pubis. The upper part of the aponeurosis is connected with the larger pectoral muscle. Its lower fibres are closely aggregated together, and extended across from the anterior superior spinous process of the ilium to the os pubis, in the form of a broad band,<sup>14</sup> which is called Fallopius', or, more commonly, *Poupart's ligament*. This band is curved at the middle and outer part, the convexity of the curve being directed towards the thigh; and it is connected with the fascia lata of the thigh.

Near the pubes the fibres of the aponeurosis diverge from one another, leaving between them a triangular opening, called the *external abdominal ring*,<sup>15</sup> for the passage of the spermatic cord in the male, and the round ligament in the female. The direction of this opening is upwards and outwards, its base being formed by the crista of the os pubis, and the sides by the two sets of diverging fibres, called its *pillars*. One of these is attached to the anterior surface of the symphysis pubis, interlacing with the corresponding fibres of the opposite muscle; the other pillar, which is the part before mentioned as Poupart's ligament, is external and inferior to the preceding, and is fixed to the spinous process of the pubes; whilst a third portion, reflected backwards and outwards from the latter, with which it is continuous, is inserted along the pectineal line. This last small part is triangular in form, and nearly horizontal in direction, and is considered to be a third insertion of the muscle into the pubes. It is in reality but a portion of the internal extremity of Poupart's ligament, which being expanded has here a broad connexion with the bone. Upon the aponeurosis at its lower part is laid a series of transverse fibres, most of which commencing from a narrow bundle over the outer part of Poupart's ligament, are directed inwards, and cross the fibres of the structure on which they are laid, binding them together. And a delicate web stretched between the "pillars" of the abdominal ring, and hence named *intercolumnar fascia*, gives a very thin prolongation downwards to the cord occupying that aperture.

The external oblique muscle is covered by the superficial fascia, which in some cases is loaded with a large quantity of fat. It conceals the internal oblique muscle and the intercostal muscles. The posterior margin is overlapped by the latissimus dorsi, or the two muscles are separated by a small interval.

*To expose the internal oblique muscle:*—When the external oblique muscle has been examined, it may be detached and reflected so as to bring into view the one subjacent to it, by cutting through its muscular fibres midway between its digitations and the margin of the ribs. Its posterior, or free border, will be found extending from the last rib to the crista of the ilium, and can be readily distinguished from the internal oblique muscle by the different course of its fibres. When this is effected, the fleshy fibres can be dissected from the crista ilii, as far



as its spine, and the whole plane of muscle turned over to the opposite side. The internal oblique is thus exposed for two-thirds of its extent.

The *internal oblique* muscle, (fig. 182,<sup>18</sup>) (*obliquus internus; obliquus ascendens; ilio-abdominalis; ilio-lumbo-costi-abdominalis*;) placed under cover of the preceding, is of an irregularly quadrilateral form. The fleshy fibres *arise* inferiorly from the external half, not unfrequently from two-thirds of the inner surface of Poupart's ligament, from the crista ilii for two-thirds of its length, also from the lumbar fascia (page 420). From these attachments the fibres of the muscle pass in different directions, to be inserted as follows: those from Poupart's ligament, which are usually paler than the rest, arch downwards and inwards, over the spermatic cord, or the round ligament of the uterus, to be fixed into the crista of the pubes, and also for some way into the pectineal line, conjointly with those of the transversalis muscle, and behind the tendon of the external oblique where it is inserted into that line. A small interval is left between the lower margin of the muscle and the inner end of Poupart's ligament. The fibres, from the anterior part of the crista ilii, pass horizontally inwards, whilst the rest ascend obliquely, and terminate, some in an aponeurosis expanded in front of the abdomen, the rest at the lower margin of the cartilages of the last four ribs, on a plane corresponding with the internal intercostal muscles.

The *aponeurosis* continues the muscle to the middle line in front, where it joins with that from the opposite side of the body, and extends from the margin of the thorax to the pubes. It is wider at the upper than the lower end. At the outer border of the rectus muscle this structure divides into two layers, one passing before, the other behind that muscle; and they reunite at its inner border, so as to enclose it in a sheath. The anterior layer becomes identified with the aponeurosis of the external oblique muscle, and the posterior one with that of the transversalis. The upper border of the posterior lamina is attached to the margin of the first false rib, and the last true one, as well as to the ensiform cartilage. Towards the lower part of the abdomen, (between the umbilicus and the pubes,) the aponeurosis is undivided and is altogether in front of the rectus.

The internal oblique muscle is covered by the external oblique, and behind, to a small extent, by the latissimus dorsi, with whose tendon it is connected, and through its medium may be said to be continued to the spines of the vertebræ. It lies on the transversalis. At the anterior ends of the last two intercostal spaces the fibres are continuous with those of the last two layers of internal intercostal muscles.

*To expose the transversalis muscle:*—When the examination of the internal oblique muscle has been completed, it is said to be difficult to detach it without injuring the muscle beneath it; yet, if just above the spine of the ilium the fibres be rendered tense by pressing the thumb and fore-finger of the left hand on them, and so straining the interval, they can be divided with perfect precision, without interfering with the subjacent muscle; for the fibres are retracted when divided, and, after about three parts are cut through, the cellular interval between the muscles begins to be perceived, which, with the difference in the direction of their fibres, affords an unerring guide to their line of separation. Moreover, near the spine and crista of the ilium, these muscles are separated by the circumflex (ilii) vessels; and this is the part usually selected for cutting through the internal

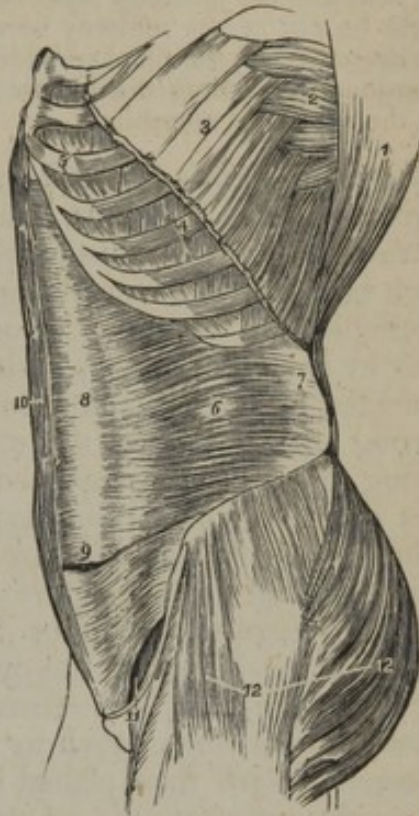


oblique, in order to expose the transversalis. When the line of separation is found, the muscular fibres should be detached from the crista ilii far back towards the lumbar region; after which they may be dissected from the cartilages of the ribs by insinuating the scalpel between the two planes of fibres, and then turning it so as to cut outwards. In this way the internal oblique muscle may be detached from its connexions, and reflected to the opposite side, so as to expose the transversalis.

The *transversalis* muscle (fig. 194,<sup>6</sup>) (*transversalis v. transversus abdominis*; *lumbo-abdominalis*) is subjacent to the internal oblique, and of the same form. It arises from the iliac half of Poupart's ligament: from the inner margin of the crista ilii for three-fourths of its length: from the cartilages of the last six or seven ribs on their inner surface: and, in the space intermediate between the crista ilii and the ribs, from an aponeurosis which is attached to the transverse processes of the lumbar vertebræ (see fascia lumborum). From these different points of origin the fibres pass horizontally forwards, and near the border of the rectus muscle they end in an aponeurosis,<sup>8</sup> which unites with the posterior layer of the internal oblique, and, together with it, joins with that of the opposite side at the linea alba. The inferior fibres curve downwards, and are inserted into the crista of the os pubis, and into the pectineal line. This insertion is so intimately connected with that of the internal oblique, that both together have received the name of the *conjoined tendon* of these muscles. At its attachment to the under surface of the cartilages of the ribs, the transversalis digitates with the diaphragm, and is continuous with that muscle in the last two intercostal spaces. This muscle is lined by the fascia transversalis, which separates it from the peritoneum.

The lower parts of the three foregoing muscles, and the manner of their connexion with the spermatic cord, or the round ligament of the uterus, together with the cremaster muscle and other coverings given

[Fig. 194.]



A lateral view of the trunk of the body, showing its muscles, and particularly the transversalis abdominis. 1. The costal origin of the latissimus dorsi muscle. 2. The serratus magnus. 3. The upper part of the external oblique muscle, divided in the direction best calculated to show the muscles beneath, without interfering with its indigitations with the serratus magnus. 4. Two of the external intercostal muscles. 5. Two of the internal intercostals. 6. The transversalis muscle. 7. Its posterior aponeurosis. 8. Its anterior aponeurosis, forming the most posterior layer of the sheath of the rectus. 9. The lower part of the left rectus, with the aponeurosis of the transversalis passing in front. 10. The right rectus muscle. 11. The arched opening left between the lower border of the transversalis muscle and Poupart's ligament, through which the spermatic cord and hernia pass. 12. The gluteus maximus, and medius, and tensor vaginæ femoris muscles invested by fascia lata.—W.]



to the cord in this situation, will be considered in the account of the "inguinal region."

*To expose the rectus muscle:*—The sheath of the rectus muscle should in the next place be examined. When this is being done, the connexions of the sheath with transverse tendinous bands, which intersect the muscle, must be cut through. Its anterior layer must be divided in its whole length, by an incision drawn down from the margin of the thorax to the pubes, and reflected off the rectus. By inserting the handle of the scalpel beneath the outer border of the muscle, it may be raised, and the posterior layer of the sheath brought into view. Lastly, if the muscle be cut across midway between the umbilicus and pubes, and the two parts drawn aside, the point at which the sheath is imperfect, posteriorly, can be determined by pushing the handle of the scalpel against it, so as to separate it from the subjacent membrane.

*Rectus abdominis* (fig. 182,<sup>16</sup>; fig. 194,<sup>10</sup>) (sterno-pubius).—This long, narrow, and flat muscle is situated at the fore part of the abdomen, separated from the muscle of the other side by a narrow interval, which however is wider at the upper than towards the lower end, and is occupied by tendinous structure (*linea alba*). It *arises* from the pubes by two tendons, of which the internal is much the smaller, and is connected to the ligaments covering the pubic symphysis, while the external one is fixed to the crista of the bone. Expanding and becoming thinner at the upper end, the muscle is *inserted* into the cartilages of three ribs, (fifth, sixth, and seventh,) and usually by three distinct parts of unequal size. In some cases a few fibres will be found attached to the ensiform cartilage. The fibres are interrupted by three irregular tendinous intersections (*lineæ transversæ*), one of which corresponds with the umbilicus, another with the ensiform cartilage, and the third is intermediate between them. Their number is in some cases augmented to four or even five, and the additional intersections are then placed below the umbilicus. These bands do not usually penetrate the whole substance of the muscle, and some of them extend only halfway across it.—The epigastric artery is placed behind the rectus muscle.

The rectus is enclosed in a sheath (*sheath of the rectus*), formed by the aponeuroses of the abdominal muscles, in the following manner:—The aponeurosis of the internal oblique, on arriving at the external border of the rectus, divides into two layers, of which the anterior one passes in front of this muscle, together with the aponeurosis of the external oblique, whilst the other is placed behind it, conjointly with that of the transversalis, and both are again united at the inner margin of the muscle along the *linea alba*. This arrangement obtains from the margin of the thorax, as far as to midway between the umbilicus and the pubes, but at this point all the aponeuroses pass in front of the rectus; so that the posterior part of its sheath is deficient in the lower third, the muscle being separated from the peritoneum by the fascia transversalis only. The deficiency in the sheath here indicated is usually marked by a well-defined lunated edge, whose concavity looks downwards towards the pubes. The sheath is firmly connected in front with the tendinous bands by which the muscle is intersected.

The *pyramidalis* muscle, (fig. 182,<sup>17</sup>) triangular in its form, (the base being below, and the apex upwards,) and situated close to the *linea*



alba, arises from the crista of the os pubis, and the ligaments of the symphysis, and, becoming narrow as it ascends, and extending over about a third of the interval between the umbilicus and pubes, is inserted into the linea alba, of which it may be considered as a tensor muscle. It is covered in front by the aponeuroses of the other muscles, and posteriorly rests on the rectus, to which it is in some degree accessory, for the size of the lower part of that muscle is augmented when the pyramidalis is wanting.

This little muscle is often absent on one or both sides, and, in some instances, has been found to be double. It occasionally exceeds the ordinary length above stated.

Some tendinous structures, which have already been incidentally referred to, require a special notice in this place, viz., the linea alba, linea semilunaris, and lineæ transversæ.

The *linea alba* may be considered as a tendinous cord, extended perpendicularly downwards from the ensiform cartilage to the pubes, and formed by the juncture of the aponeuroses of the two oblique and the transverse muscles, the tendinous fibres being continued from the muscles of one side to those of the other. Some longitudinal fibres are distinguishable towards its lower end. This structure is covered in front by the common integument; posteriorly it rests on the fascia transversalis, which separates it from the peritoneum, and on each side it is limited by the recti muscles; it is therefore broader above than below, as these muscles diverge from one another in the former situation. In the linea alba below its middle is situated the *umbilicus*, which in the foetal state is a foramen for the transmission of the umbilical vein and arteries, but afterwards becomes obliterated.

The *lineæ semilunares* are two curved tendinous lines extending, one on each side, from the cartilage of the eighth rib to the tuberosity of the os pubis. They thus correspond with the external borders of the recti muscles (the enclosed space being broad above and narrow below), and are formed by the aponeurosis of the internal oblique on each side, as it divides to enclose the rectus muscle.

The *lineæ transversæ* have been already noticed with the rectus muscle, as the tendinous bands which cross the substance of that muscle.

The *quadratus lumborum*, (fig. 181,<sup>19</sup>) (*ilio-costalis*,) situated deeply in the lumbar region close to the vertebral column, is in form irregularly quadrilateral, being somewhat broader below than above. One part arises by tendinous fibres from the crista of the ilium behind the middle, and from the ilio-lumbar ligament; and it is inserted into the inferior border of the last rib for about half its length, and by four tendinous points into the transverse processes of the four superior lumbar vertebræ. Another series of fibres, arising by two or three tendinous points from as many of the inferior transverse processes at their upper margins, passes in front of those inserted into the same processes, and joins with the part of the muscle attached to the rib. This muscle is enclosed in a sheath resembling that of the rectus, but not so dense or firm in its structure (see the fascia lumborum).



The number of the points of insertion of this muscle to the vertebræ, and the extent of its connexion with the last rib, vary in different cases. It is in some instances attached to the last dorsal vertebra—the body or transverse process.

*Dissection to show the fascia lumborum.*—If the internal oblique be traced back, its muscular fibres will be found to end in an aponeurosis, which becomes intimately connected externally with the latissimus dorsi, close to the border of the deep lumbar muscles, and internally with the membranous elongation from the transversalis. Now, if the aponeurosis of the latissimus be divided in the middle of its breadth, by an incision drawn from the ilium to the last rib, and the two parts reflected, the thick mass of lumbar muscles will be exposed; and if the handle of the scalpel be inserted beneath their outer border, they will be found to lie on a membrane, which is connected with the lumbar vertebræ on the one hand, and with the abdominal muscles on the other, being, in fact, a prolongation of one of the latter (the transversalis). The mass of lumbar muscles may now be cut across by two incisions, one opposite the last rib, the other at the crista ilii, and then removed altogether. When this is effected, if attention be directed to the internal oblique muscle, it will be found that after contracting adhesion with the fascia derived from the transversalis, as above stated, it becomes likewise connected with the aponeurosis of the latissimus dorsi. In this stage of the dissection, an aponeurotic layer will be found stretched back from the transversalis to the transverse processes of the lumbar vertebræ. If this be divided by a perpendicular incision from the last rib to the ilium, the quadratus lumborum will be exposed; and, if the external border of this muscle be raised, another thin layer will be found resting on its abdominal surface, and connected with the roots of the transverse processes.

*Fascia lumborum.*—The two membranous layers now exposed to view have received this name. They extend backwards from the transversalis muscle to the lumbar vertebræ, encasing the quadratus lumborum. That which is in front of this muscle is very thin, and is attached to the anterior part of the transverse processes of the vertebræ at their roots, and superiorly, where it is connected with the last rib, it forms the ligamentum arcuatum externum of the diaphragm. The posterior layer, which is much thicker than the preceding, and may be considered aponeurotic, is attached to the points and the margins of the same (transverse) processes. It separates the quadratus lumborum from the large muscular mass behind it.

The internal oblique muscle springs from the membranous elongation just noticed (the posterior one); and the tendon of the latissimus dorsi is connected with it further back, viz., at the outer margin of the erector spinæ. And thus, while the quadratus is sheathed by the layers of the lumbar fascia, the erector spinæ is encased with one of the layers of that fascia and the tendon of the latissimus dorsi which are joined at its outer margin.

*Actions of the abdominal muscles.*—The muscles here described not only enclose and support the abdominal viscera, but by their contractile power are capable of acting successively on them, on the thorax, and on the pelvis. When the pelvis and thorax are fixed, the abdominal muscles can constrict the cavity and compress its viscera, particularly if the diaphragm be made to descend at the same time, as occurs in vomiting, or in the expulsion of the fœtus, of fæces, or urine. If the vertebral column be fixed, these muscles compress the lower border of the thorax, and so contribute to expiration. When it is intended to continue the effort, so as to produce a forced expiration, the quadratus lumborum draws down the last rib, and makes it relatively the fixed point to which all the rest are drawn by their intercostal muscles; but if the vertebral column be not fixed, the thorax may be bent directly forwards, when the muscles of both sides act; or it may be rotated to either side, should they act alternately. Thus, if the external oblique of the



right side be made to act on the thorax, the first effect appears to be that of drawing its margin down towards the pelvis; but, if the effort be continued, the trunk will be rotated towards the opposite side. The left internal oblique will cooperate in this action, for the direction of its fibres coincides with that of the right external oblique. The pyramidales also contribute to the same effect, by rendering the *linea alba* tense. If the thorax be fixed, the abdominal muscles may be made to act on the pelvis; thus, in the action of climbing, the trunk and arms being elevated and fixed, the pelvis is drawn upwards, either directly, or to one side, as a preparatory step to the elevation of the lower limbs. A similar effect may be produced when the trunk is in the horizontal position, for the pelvis may be drawn forward and flexed upon the vertebral column by the recti and pyramidales.

## COSTAL REGION.

Between the ribs we find two planes of muscular fibres filling up the intervening spaces, hence named "intercostal,"—upon the ribs posteriorly the *levator costarum*, and at their inner surface, and in front, the *triangularis sterni*.

It is not necessary to prescribe any particular mode of examining these, as they are necessarily exposed when the pectoral, the serratus, and external oblique muscles are removed.

The intercostal muscles are disposed in the form of two thin planes, one over the other, and named, from their relative position, "external," and "internal."

The *external intercostal* muscles (*intercostales externi*) are placed between the contiguous borders of each pair of ribs. There are, therefore, eleven such muscular layers on each side, the direction of the fibres of all being obliquely downwards and forwards (fig. 194,<sup>4</sup>). Their extent in each instance is from the tubercles of the ribs nearly to the external extremity of their cartilages. From this point a thin fascia is continued forwards to the sternum, overlaying the inner intercostals. There are many tendinous fibres mixed up with the muscular structure.

The external intercostal muscles are covered by several large muscles, which are attached to the ribs. They conceal the corresponding internal muscle, the intercostal nerves and vessels being interposed.

The *internal intercostal* muscles, (*intercostales interni*), (fig. 194,<sup>5</sup>) placed under the preceding, are attached to the inner margins of the ribs and their cartilages. Commencing at the sternum in the spaces between the true ribs, and at the anterior extremities of the cartilages of the false ribs, they extend as far back as their angles. The fibres incline downwards and backwards, and decussate with or cross the former; but they are somewhat shorter and less oblique in their direction.

The internal are separated from the external intercostal muscles by the intercostal vessels and nerves; they are lined internally by the pleura.

*Infra-costales* (Verheyen).—In connexion with the inner surface of the ribs several small bundles of fleshy and tendinous fibres, which are thus named, will be found extending over two, and in some instances over three, intercostal spaces. They have the same direction with the internal intercostals, and are often described as parts of those muscles. The fasciculi vary in size and number, and may be found



covering all the intercostal spaces, except perhaps the first, but they are most constant on the lower ribs.

The *levatores costarum* (*levatores breviores costarum*,—Alb.), (fig. 181,<sup>17</sup>) are narrow, tendinous, and fleshy fasciculi, which extend obliquely downwards and forwards (in this particular resembling the external intercostals), from the extremities of the transverse processes of the dorsal vertebræ, to be inserted into the margins of the ribs between their angles and tubercles. Their fibres spread out and become flat at their insertion. Each rib receives one from the vertebra next above; there are therefore twelve muscles on each side, and that for the first rib is derived from the last cervical vertebra.

The inferior muscles of this series divide into two parts, one of which is distributed as above stated, but the other consisting of longer fibres passes over one rib and terminates on the second below; and thus each of these ribs receives muscular fibres from the transverse processes of two vertebræ. The longer bundles have been described as separate muscles under the name *levatores longiores costarum* (Albinus).

The *triangularis sterni* (*sterno-costales*, Verheyen) is a thin flat plane of muscular and tendinous fibres, placed within the thorax, immediately behind the costal cartilages. This muscle *arises* from the inner surface of the ensiform cartilage, and of the lower part of the sternum and the cartilages of the lower true ribs, from which its fibres pass outwards and upwards, diverging, the lowest horizontally, the rest obliquely, and approaching more and more the vertical direction towards the upper part of the muscle. It is inserted by digitations (which give to the outer margin a serrated appearance) into the cartilages of the true ribs from the fifth to the second inclusive—on the lower border and inner surface of each.

One surface of the *triangularis sterni* is in apposition with the parts just mentioned, together with the internal mammary artery and the internal intercostal muscle; the other surface is in contact partly with the pleura, which is reflected upon it, and partly with the pericardium and the interval called anterior mediastinum. At the lower margin the fibres are continuous with those of the *transversalis* muscle.

The *triangularis sterni* varies constantly in its extent and points of attachment in different bodies, and even on the opposite side of the same body.

*Actions.*—The two planes of intercostals act simultaneously; and, as they decussate with one another, the ribs on which they act are made to move in the direction of the diagonal of the moving powers, that is to say, directly upwards when the first rib is relatively the more fixed point, and downwards when the last happens to be so. In drawing up the ribs, they slightly rotate the bodies, and evert the lower borders of those bones; at the same time the middle and lower intercostal spaces are widened, for the ribs are spread asunder somewhat like those of a fan. This arises from the peculiar mode of attachment of the last rib, which is prevented from ascending with the rest by the manner in which the *quadratus lumborum* binds it to the ilium, so that it serves to spread or separate them from one another.

The *diaphragm* (fig. 195,) (*διαφραγμα*\*: *φρένες*: *septum transversum*:

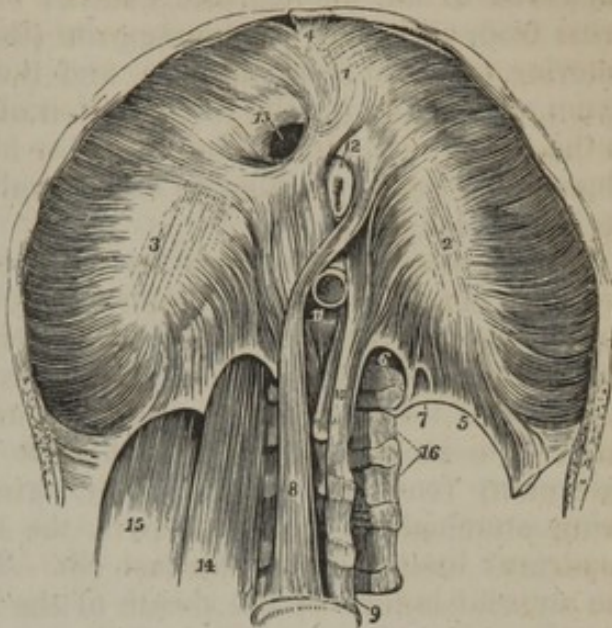
\* *Διαφύσσω*, to separate two parts.



midriff) is a thin muscular and fibrous partition between the thorax and abdomen, and is perforated for the passage of certain organs from

The under or abdominal side of the diaphragm. 1, 2, 3. The greater muscle; the figure 1 rests upon the central leaflet of the tendinous centre; the number 2 on the left or smallest leaflet; and number 3 on the right leaflet. 4. The thin fasciculus which arises from the ensiform cartilage; a small triangular space is left on either side of this fasciculus, which is closed only by the serous membranes of the abdomen and chest. 5. The ligamentum arcuatum externum of the left side. 6. The ligamentum arcuatum internum. 7. A small arched opening occasionally found, through which the lesser splanchnic nerve passes. 8. The right or larger tendon of the lesser muscle; a muscular fasciculus from this tendon curves to the left side of the greater muscle between the œsophageal and aortic openings. 9. The fourth lumbar vertebra. 10. The left or shorter tendon of the lesser muscle. 11. The aortic opening occupied by the aorta, which is cut short off. 12. A portion of the œsophagus issuing through the œsophageal opening. 13. The opening for the inferior vena cava, in the tendinous centre of the diaphragm. 14. The psoas magnus muscle passing beneath the ligamentum arcuatum internum; it has been removed on the opposite side to show the arch more distinctly. 15. The quadratus lumborum passing beneath the ligamentum arcuatum externum; this muscle has also been removed on the left side.—W.]

[Fig. 195.]



one of these cavities to the other. From the lower margin of the thorax, to which it is attached at its circumference, the septum arches deeply upwards, and from this shape it results that some of the viscera situated at the upper part of the abdomen are, to a considerable extent, under the protection of the ribs; and as the height to which the septum arches is liable to variation, and is actually varied constantly during life, the capacity of the thorax and the abdomen is alternately enlarged and diminished, the enlargement of the one coinciding with the diminution of the other. It is connected directly with the thorax at its anterior and lateral part; but as the aorta is placed immediately against the spine, and the psoas muscles are attached to the sides of that column, at the same time that the last rib on each side is occupied by the quadratus lumborum, the diaphragm is separated from the bones by these structures, and tendinous arches extending over them give origin to the fibres of the diaphragm.

*Origin of the fibres.—a. The crura—*(fig. 195,<sup>s 10</sup>). On the bodies of the lumbar vertebræ, and on each side of the aorta, is a thick tendinous band which consists of several sets of fibres. These tendinous fibres are usually aggregated into two bundles, and are attached over a considerable but varying extent of surface. On the right side they are connected with the first, second, and third lumbar vertebræ, and the interposed fibro-cartilages, or to the second, third, and fourth; on the left side, the attachment is higher by the breadth of one vertebra. The tendons of both sides unite by their inner margins on the bones to which they are attached, and they are continued one into the other



over the aorta by a small fibrous arch. Proceeding upwards they give origin to muscular fibres, and these with the tendons are named the *crura*, or sometimes the *pillars* of the diaphragm. The external muscular fibres emanating from this source are directed upwards and outwards to the aponeurotic centre; but the fibres near the middle cross from each side to the opposite (those of the right usually being anterior to those from the left), and then curving upwards they construct an opening for the transmission of the œsophagus before ending in the common centre of the muscular fibres. The decussation of the fibres was found by Haller to be generally fourfold; it measures about an inch in length.

*b. Ligamenta arcuata.*—Externally to the bodies of the vertebræ are two fibrous arches on each side.\* The first<sup>6</sup> extends from the body of the first lumbar vertebra to the transverse process of the same vertebra, or likewise to the second, and crosses over the psoas muscle. It is named the ligamentum arcuatum internum (arcus interior,—Haller). The second and broader fibrous arch<sup>5</sup> (ligamentum arcuatum externum) reaches from the outer extremity of the preceding (both being attached to the same part, the transverse process), over the quadratus lumborum, to the last rib. This band is continuous with the anterior lamina of the sheath of the muscle just mentioned, and is but the upper margin of that structure somewhat increased in thickness. From both these tendinous bands muscular fibres take rise, and are directed to the posterior part of the common centre. Those above the last rib are usually thin, and separated one from the other by interspaces.

*c. Origin from ribs and the ensiform cartilage.*—The remaining muscular part of the diaphragm is derived from the inner surface of the cartilages, and a little of the osseous part of all the ribs which form the margin of the thorax; viz., the five false ribs and the last true one (with in some instances one other,—the sixth). A narrow muscular slip likewise takes rise from the ensiform cartilage, and at each side of it there occurs an interval in which no more than cellular membrane is interposed between the abdomen and thorax, or rather between the proper lining membranes of those cavities. The extensive part of the muscle derived from the ribs commences by a serrated margin, and its angular processes are adapted to the transversalis muscle, whose edge is disposed in a corresponding manner.

The muscular fibres proceeding from the several sources now reviewed have various lengths: those situated at the posterior and lateral part of the thorax are the longest, those in front are much the shortest. They all curve upwards and inwards to join the central tendon.

The *central tendon* (cordiform tendon; phrenic centre; tendo diaphragmatis; centrum nerveum) is a thin tendinous lamina or aponeurosis, and is the highest part of the diaphragm. Elongated from side to side, and curved on itself at its circumference, the concavity of the curve being directed back towards the vertebral column, it consists of three parts,<sup>1 2 3</sup> partially separated one from the other by indentations.

\* They appear to have been first clearly described by Senac, "Mém. sur le Diaphragme," in "Histoire de l'Acad. Royale des Sciences," 1729, p. 118.



The middle part is described as the largest; and the left division, which is elongated and narrow, is considered the smallest of the three. From being partly tripartite, the whole has been likened to a trefoil leaf, and each part has been named an "ala." The tendon is insulated by the muscular portion of the diaphragm, with which it is intimately connected—the fibres of the one being directly continued into those of the other. The tendinous fibres cross one another, and are interwoven at various points and in various directions, and thus the strength of this structure is assured.

*Foramina* of the diaphragm.—There are three large perforations for the passage respectively of the aorta, the œsophagus, and the vena cava, besides some holes or fissures, which are small and less regular than those.—*a.* The foramen for the aorta,<sup>11</sup> (hiatus aorticus) is almost altogether behind the diaphragm, for no more than a few of the tendinous fibres of the crura are posterior to the vessel. It is lower than any of the other openings, and is placed in the middle line immediately in front of the bodies of the vertebræ. The circumference is tendinous, being formed by the tendinous appendices of the crura and the curved band which connects them in front. Besides the aorta, this opening transmits the thoracic duct, and frequently likewise the vena azygos.—*b.* The foramen for the œsophagus,<sup>12</sup> higher, and at the same time anterior, as well as a little to the left of the preceding, is separated from that opening by the decussating fibres of the crura. It is oval in form, and muscular in structure; but in some cases a small part, the anterior margin, will be found to be tendinous, being formed by the margin of the central tendon.—*c.* The opening for the vena cava,<sup>13</sup> (foramen quadratum,) is placed in the highest part of the diaphragm, in the tendinous centre at the commencement of its right ala, or between this and the middle one. Its form is quadrangular, or nearly so, and it is bounded by four bundles of tendinous fibres running parallel with its sides.

Besides the foregoing large foramina, there are small perforations through the crura for the sympathetic and splanchnic nerves on both sides, and for the vena azygos minor on the left side. Moreover, the larger azygos vein often takes its course through the right crus.

The upper or thoracic surface of the diaphragm, which is very convex at its middle, and rises higher on the right side than the left, is covered by the pleuræ and the pericardium; the fibrous layer of the latter structure blends with the tendinous centre. And, inasmuch as the lateral and posterior parts of the muscle ascend very obliquely from their connexion with the lower margin of the thorax, a considerable extent of the upper surface (in the situations now mentioned) is close to the ribs, and is separated from them only by a thin portion of the lung.—The lower surface, deeply concave, is lined by the peritoneum, and has in apposition with it the liver, (which is bound to the diaphragm by folds of the peritoneum,) and the stomach, the spleen, and kidneys.

The diaphragm has received much of the attention of anatomists at all times, and their descriptions often contain expressions of their admiration of its structure and general disposition. These may be represented by the words of Spigelius,



"*Musculus unus omnium fama celeberrimus;*" or by those of Haller, whose account of the muscle begins thus, "*Nobilissimi, post cor, musculi historiam ultimo loco recensemus, ut eam pro dignitate aliquanto fusius exponere liceat.*" The diaphragm has been described as a digastric muscle; one end of the fibres being represented to be on the vertebræ, the other end on the ribs, and the tendon interrupting them in the middle.\*—It was likewise considered to be a double muscle,† and one part was named superior, the other inferior; the central tendon being the demarcation between the two. The inferior part, that which is connected with the lumbar vertebræ, was known as the "*musculus inferior v. minor;*" and in some modern books it is mentioned as the lumbar part—"pars lumbalis."

*Actions.*—When the fibres of the diaphragm contract, the muscle descends, and becomes an inclined plane, whose direction is downwards and forwards. By these means the abdominal viscera are pressed against the lower and fore part of the parietes of the cavity, so that the capacity of the abdomen is diminished in proportion as the thorax is enlarged. Should the abdominal muscles and the diaphragm be both brought into action together, the viscera will be compressed between them, and forced towards the lower part of the cavity, as occurs in the expulsive efforts of accouchement, &c. After a complete expiration, the upper surface of the diaphragm is on a level with the lower border of the fourth rib.

#### PERINEÆAL REGION.

The history of the muscles of this part will most conveniently accompany the description of the other structures of the perineum, with which they are connected.

### MUSCLES OF THE INFERIOR EXTREMITY.

#### ILIAC REGION.

In the iliac fossa, and along the upper border of the pelvis, we find placed the iliacus and psoas muscles. We need not give any particular directions for their dissection, as it is never undertaken until the abdominal muscles have been examined and the viscera removed, and then they are at once brought into view, being merely concealed by the fascia iliaca.

The *psoas magnus* (figs. 195,<sup>14</sup>; 198,<sup>11</sup>) (*lumbalis prælumbo-trochantineus*;—*ῥόα*, the loins) is situated along the sides of the lumbar vertebræ, the margin of the pelvis, and deeply at the superior part of the thigh, extending from the last dorsal vertebra to the small trochanter of the femur. It is thick and round at the centre, and gradually diminishes in size towards the extremities. The muscle *arises* from the sides of the bodies of the last dorsal and lumbar vertebræ, with the interposed fibro-cartilages, also from the anterior surface and lower margins of the transverse processes of the last-named vertebræ near their base. With the bodies of the bones the connexion is effected by means of five distinct parts, which are each attached to the upper and lower margins of the vertebræ and the interposed fibro-cartilage;—the highest to the neighbouring margins of the last dorsal vertebræ, and the first lumbar, and the lowest to the edges of the fourth and fifth lumbar vertebræ with the intervertebral substance. These attachments are connected by thin tendinous arches, which

\* N. Stenonis, "de musc. et gland. observ. specimen," p. 8.

† Casp. Bartholini, "Diaphragmatis structura nova," p. 19.



extend over the middle of the bones and cover the lumbar vessels and some nerves. From these several attachments the muscle passes across the brim of the pelvis, beneath Poupart's ligament, and ends in a tendon, which is *inserted* into the posterior half of the small trochanter of the femur. The tendon is lodged at first in the substance of the muscle, and begins to receive the muscular fibres near its upper part. At a lower point it lies along the outer side of the psoas, between it and the iliacus, and receives the fibres of both muscles.

The muscles of opposite sides diverge one from the other in proceeding downwards, and at the lower end each is directed backwards to reach its destination.

The posterior surface of the psoas muscle corresponds above with the transverse processes of the lumbar vertebræ, the lumbar plexus of nerves, and the quadratus lumborum muscle, from which last it is separated by the anterior lamina of the fascia lumborum; towards the lower end it rests against the ilium and the capsular ligament of the hip-joint, a synovial membrane being interposed; in the middle this surface overlays a portion of the pelvic cavity, and the muscles of both sides therefore limit the extent of the inlet to the cavity in the transverse direction. The anterior surface, placed behind the peritoneum, is in relation successively with the diaphragm, its ligamentum arcuatum internum, and the renal vessels, the ureter and the spermatic vessels. This surface is covered by the iliac fascia, and, while on the margin of the pelvis, it supports the femoral artery. The inner border is in contact superiorly with the bodies of the vertebræ, and with the sympathetic ganglia resting on these. From the middle of these bones it is separated by the lumbar arteries, and branches of communication between the spinal and sympathetic nerves, as already stated. In the pelvic region the same border is in contact with the iliac artery; and on the thigh, with the pectineus muscle, from which it is separated by the internal circumflex artery. Finally, the outer border of the psoas looks towards the iliacus muscle, from which it is at first separated by a slight cellular interval, and then by the anterior crural nerve.

The upper extremity of the muscle is occasionally connected with the head of the last rib, or with the upper margin of the first lumbar vertebra only. The connexion with the transverse process of that vertebra is sometimes wanting. A portion of the fibres derived from the transverse processes may be found to be distinct from the rest of the muscle in its whole course.—(Albinus and Meckel.)

*Iliacus* (fig. 198,<sup>10</sup>) (iliacus internus,—Spigel. and Alb.; ilio-trochanteric).—This muscle is situated in the iliac fossa, which it fills up, and at the upper and fore part of the thigh. Expanded in the former, and narrowing in the latter situation, it is somewhat triangular in shape. It *arises* from the fossa of the ilium, together with the inner margin of the crista of that bone, as well as its anterior border (the vertical part), including the two spinous processes. Fibres are likewise derived from the capsule of the hip-joint and the ilio-lumbar ligament, in some instances likewise from the base of the sacrum.



From these different sources the fibres pass down, and the greater number inclining obliquely inwards terminate in the side of the tendon common to this muscle and the *psoas magnus*; some of them are prolonged into the oblique line which leads downwards from the small trochanter of the femur—the process to which the tendon is attached.

The *iliacus* rests on the ilium and the capsular ligament of the hip-joint, a synovial membrane separating it to some extent from this last, and the margin of the bone. It is subjacent to the iliac fascia and fascia lata of the thigh; and to its inner side is the *psoas* muscle, the anterior crural nerve being interposed. In the abdomen the viscera of the iliac region are before the muscle, and some small nerves pass across it.—The *psoas* and *iliacus*, with the fascia which covers them, fill up completely the interval between Poupart's ligament and the margin of the ilium, from the ilio-pectineal eminence outwards.

This muscle is often still named *iliacus internus*, though there is now no correlative term in use, no muscle being called *iliacus externus*. Several of the older anatomists called the *pyriformis* by that name.—Some of the external fibres of the *iliacus*, those derived from the anterior inferior spine of the ilium close to the *rectus femoris*, are from time to time found separated from the rest, even from their origin to the termination on the femur below the small trochanter.—The *psoas* and *iliacus* are so completely united by their common tendon that they might be regarded as a single muscle. They have been so considered by several anatomists.

*Psoas parvus* (*præ-lumbo-pubius*).—This long and slender muscle is situated along the anterior side of the *psoas magnus*. It *arises* from the bodies of the last dorsal and first lumbar vertebræ, with the fibro-cartilage between them, and soon ends in a flat tendon, which passes along the anterior and inner side of the *psoas magnus*, to be *inserted* into the ilio-pectineal eminence.—The muscle is covered at its origin by the diaphragm, and rests in its whole length on the *psoas magnus*. Its tendon is united with the fascia iliaca, and may exercise some influence on the tension of that membrane.

The *psoas parvus* is most frequently absent. It was present in no more than one out of twenty bodies which M. Theile\* examined with special reference to the muscle. When present, it is liable to many changes in the place of origin; thus, it may be connected only with the first lumbar vertebra, or with the second and the fibro-cartilage above it, and it has been observed to commence by two parts or heads separated by an interval.

*Combined Actions*.—The *psoas* and *iliacus*, when they take their fixed point above, can bend the thigh on the pelvis, and rotate the limb somewhat outwards,—the latter power being derived from the direction of their common tendon and the mechanical advantages given them by the projection of the trochanter minor. These muscles assist materially in maintaining the erect position of the body, in which case they take their fixed point at their insertion into the femur, and then act upon the pelvis and spinal column, drawing them forwards so as to keep them erect upon the thighs. If this action be continued, the trunk may be bent forwards as in bowing. It is scarcely necessary to add, that this bending of the body will be directly forwards if the muscles of opposite sides act together, and obliquely to one side if they act separately.

#### GLUTEAL REGION.

In this space, which comprehends the posterior and external sur-

\* In Sæmmerring, op. ante citat.



face of the pelvis, we find the glutei, and the "external rotator" muscles of the thigh.

*Dissection.*—The subject being placed in the prone position, and the abdomen supported on a high block, the foot should be rotated inwards, and the limb abducted, in order to put the gluteus on the stretch. An incision may be made through the skin, from the coccyx obliquely upwards over the side of the sacrum and posterior spine of the ilium, and as high as its crista; from which point draw another obliquely downwards over the great trochanter. The flap thus included should be dissected cleanly off the muscle in the course of its fibres; that is to say, downwards and outwards. The remainder of the skin which covers the pelvis may be reflected upwards and outwards, the fascia serving as a guide. This will expose the tensor vaginæ femoris and part of the gluteus medius. The rest of the latter can be seen only when the gluteus maximus is detached. To effect this, let its lower border be drawn a little forwards, and the scalpel be inserted beneath it, so as to raise it from the sciatic ligament, and so successively from the side of the coccyx, sacrum, and ilium, proceeding from below upwards. When the muscle is detached, and turned down on the femur, the external rotators and gluteus medius come into view, and require little further dissection. As the gluteus medius covers the third muscle of that name, the easiest mode of reflecting it is by cutting through its tendinous insertion, and drawing it upwards. The external rotators should be attentively examined, more particularly the two obturator muscles. The internal one cannot be fully seen until the pelvis is divided; but the direction of its two parts, and the peculiar appearance presented by its tendon, where it slides over the ischium, can be observed by cutting it across near its insertion, and reflecting it outwards.

*Gluteus maximus* (fig. 196,<sup>2</sup>) (*gluteus magnus*,—Alb.; *ilio-sacro-femoralis*).—This is a very large muscular mass; and its great size is characteristic of man, being connected with the power he has to maintain the trunk in a line with the lower limbs. It is placed at the back part of the pelvis, extending from it to the outer and upper part of the thigh, and it forms the prominence of the nates.\* The great gluteal muscle *arises* from the posterior fifth of the crista of the ilium, and the irregular rough surface subjacent to that part: from the lateral tubercles on the posterior surface of the sacrum; from the posterior sacro-iliac ligament, the great sacro-sciatic ligament, and the side of the coccyx. From this extensive origin the fibres of which the muscle consists pass downwards and outwards, and terminate as follows:—the lower fibres are inserted into the femur (between the vastus externus and adductor magnus) on the rough line or irregular ridge (as it to some extent is in cases of large muscular development) which lies between the base of the great trochanter and the linea aspera. The upper and larger part of the muscle ends in a thick tendinous structure, which covers the great trochanter, and joins with the fascia lata of the thigh.—The fleshy fibres generally are parallel one with the other, and they are aggregated into large bundles separated by cellular membrane and fat; and thus the muscle is characterized by a more than usually coarse appearance.

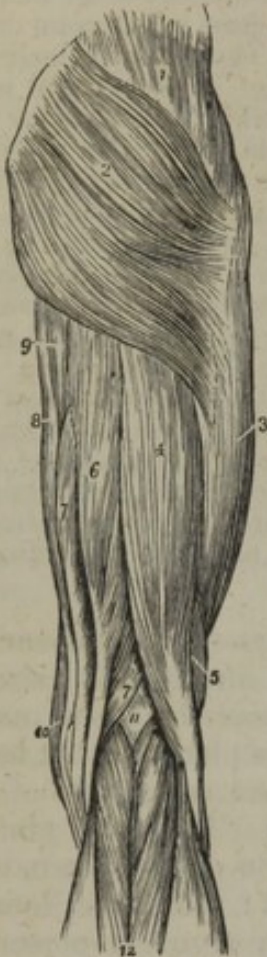The muscle is covered by a thin elongation of the fascia lata. The upper border is firmly connected with the gluteus medius by that membrane; the lower one (the longest), which is free, forms the fold of the nates, and looks towards the perineum. When the muscle is separated

\* Hence the name "gluteus" applied to the muscles in this situation,—Γλουτός, the nates. Riolanus writes the name of the muscles "gloutius."



from its superior connexions and reflected downwards, it will be found that its inner surface covers (besides the parts with which it is connected) the gluteus medius, the gluteal, sciatic, and pudic vessels and

[Fig. 196.



The muscles of the posterior femoral and gluteal region. 1. The gluteus medius. 2. The gluteus maximus. 3. The vastus externus, covered in by fascia lata. 4. The long head of the biceps. 5. Its short head. 6. The semi-tendinosus. 7. The semi-membranosus. 8. The gracilis. 9. A part of the inner border of the adductor magnus. 10. The edge of the sartorius. 11. The popliteal space. 12. The gastrocnemius muscle; its two heads. The tendon of the biceps forms the outer hamstring; and the sartorius with the tendons of the gracilis, semi-tendinosus and semi-membranosus, the inner hamstring.—W.]

nerves, the external rotator muscles, the great sciatic nerve, the trochanter major, and the tuberosity of the ischium, with the muscles arising from it. Between the tendon and the great trochanter of the femur are placed two or three synovial bursæ, or a single multilocular sac of large size. A bursa is also beneath it on the tendon of the vastus externus, and another on the tuber ischii.

The *gluteus medius* (fig. 196,<sup>1</sup>); (ilio-trochanterus major) is situated on the external surface of the pelvis, partly covered by the preceding muscle, partly by the integument and fascia. Broad, and, as it were, radiating at its upper part, it becomes narrow and thick at the lower extremity. It arises by short aponeurotic fibres from an elongated surface of the ilium, which is broader behind than in front, and is bounded by the outer margin of the crista (its anterior four-fifths), the superior curved line on the dorsum, and the line which marks the extent of the gluteus maximus on the bone. Numerous fibres likewise take origin from the dense fascia which covers the muscle in front of the gluteus maximus. The fleshy fibres descending from the different parts of this broad surface of origin proceed in different directions, (obliquely backwards, obliquely forwards, and vertically,) and converge on a fibrous expansion, which becomes narrowed into a thick tendon. This (the tendon) is *inserted* into the outer surface of the great trochanter on a prominent line which crosses that process obliquely forwards and downwards. It is separated by a synovial bursa from the upper part of the trochanter.

The gluteus medius covers the third gluteal muscle, with the branches of the gluteal vessels and nerve. Its anterior border is blended with the gluteus minimus, and is connected with the special tensors of the fascia lata; and the posterior border is close to the pyramiformis, the gluteal artery being interposed.

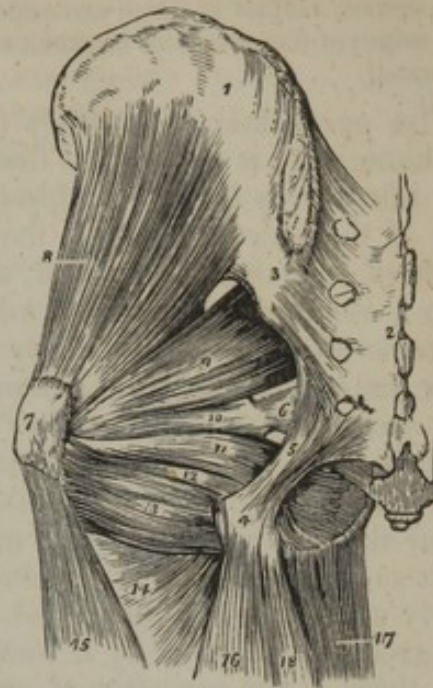
The *gluteus minimus* (fig. 197,<sup>2</sup>) (ilio-trochanterus minor), the third and smallest of the gluteal muscles, is placed under the gluteus medius, which must be removed to bring it into view; and, like that muscle, it is triangular or fan-shaped, the fibres converging from a broad



surface of origin on the pelvis to a narrow place of insertion on the femur. It *arises* from all that space on the dorsum ilii between the superior curved line and the inferior one, which runs at a short distance above the brim of the acetabulum. A small part is likewise derived from the margin of the sciatic notch for a short space further back than the gluteus medius. The fibres approach one another; they descend and terminate on an aponeurotic expansion, which covers the muscle towards its lower end, and that structure narrows into a tendon, which is *inserted* into a portion of the upper margin and the anterior part of the great trochanter.

Between this muscle and the preceding one are placed a large part of the gluteal vessels and nerve, and a small portion is covered by the piriformis, where it extends farther back than the gluteus medius. The anterior margin blends with the last-named muscle, and the posterior part of the tendon is often joined with that of the piriformis.—A synovial bursa is interposed between the tendon (its anterior part) and the trochanter.

[Fig. 197.]



The deep muscles of the gluteal region. 1. The external surface of the ilium. 2. The posterior surface of the sacrum. 3. The posterior sacro-iliac ligaments. 4. The tuberosity of the ischium. 5. The great or posterior sacro-sciatic ligament. 6. The lesser or anterior sacro-sciatic ligament. 7. The trochanter major. 8. The gluteus minimus. 9. The piriformis. 10. The gemellus superior. 11. The obturator internus muscle, passing out of the lesser sacro-sciatic foramen. 12. The gemellus inferior. 13. The quadratus femoris. 14. The upper part of the adductor magnus. 15. The vastus externus. 16. The biceps. 17. The gracilis. 18. The semitendinosus.—W.]

*Actions.*—The glutei act alternately on the femur and pelvis, according as the one or the other becomes relatively their fixed point of attachment. All three act as abductors; the anterior fibres of the gluteus medius and minimus draw the trochanter forwards, the posterior backwards, giving it a slight rotatory motion. The gluteus maximus is a powerful abductor, and by the direction of its fibres is calculated to draw the femur backwards, at the same time that it rotates the whole limb outwards if it be kept extended. When the thighs become the fixed points, these muscles act on the pelvis. The great glutei draw it backwards, and maintain it and the body in the erect position; in this they are assisted by the semitendinosus, semi-membranosus, and biceps of each side, which act on the tuberosities of the ischia, and draw them downwards, so as to elevate the fore part of the pelvis. The gluteus medius and minimus are chiefly called into action in progression, and in standing on one leg; they draw the pelvis towards the femur, which is fixed, and by this action counterbalance the weight of the trunk, and maintain it erect on the limb. This alternation of action of the muscles of opposite sides during progression, gives to the pelvis that rotatory motion so perceptible in those who walk irregularly, and which is strikingly evident in females, in consequence of the great breadth of the pelvis.

The "external rotator" muscles form a group by themselves, being



placed deeply at the back of the pelvis. They are the *pyriformis*, two *gemelli*, two *obturatores*, and *quadratus femoris*.

*Dissection*.—Most of these are exposed by the removal of the *gluteus maximus*. The origin of the *obturator internus* and *pyriformis* cannot be seen until the pelvis is opened.

The *pyriformis* (fig. 197,<sup>9</sup>) (*pyramidalis*; *iliacus externus*; *sacro-trochantereus*) is situated at first within the pelvis at its posterior part, and afterwards behind the hip-joint, extending from the anterior surface of the sacrum through the great sacro-sciatic notch to the great trochanter of the femur; and, as in this course it gradually decreases from a considerable size to a small tendon, the muscle has the shape its name implies. It *arises*, by three fleshy and tendinous digitations, from the second, third, and fourth divisions of the sacrum, interposed as it were between the anterior sacral foramina; a few fibres are also derived from the inner surface of the ilium, near its lower curved border (the sacro-sciatic notch), and from the sacro-sciatic ligament. From these attachments the muscle passes out of the pelvis by the great sacro-sciatic notch, becoming gradually narrow, and following nearly a horizontal course, and is *inserted* into the posterior border of the great trochanter by a rounded tendon, whose fibres are blended with those of the *gemelli* and often with the *gluteus minimus*.

Within the pelvis the *pyriform* muscle is placed behind the sciatic plexus of nerves, the internal iliac vessels, and the rectum (the last more especially at the left side). Outside the pelvis one surface rests on the ischium and the fibrous capsule of the hip-joint, the other is covered by the *gluteus maximus*. Its upper border is parallel with the *gluteus medius*, from which it is separated by the gluteal vessels as they emerge from the pelvis: and the lower border is a little above the *gemellus superior*, the interval being occupied by the great sciatic nerve, the sciatic and pudic arteries, and nerves.—A small synovial bursa is interposed between the tendon at its termination, and that of the *gluteus medius*.—The separation always existing at its points of origin sometimes continues to be apparent even after the muscle has passed out by the pelvis; when this is the case, the interval gives passage to one of the divisions of the great sciatic nerve.

The *obturator internus* (fig. 197,<sup>11</sup>) (*sub-pubio-trochantereus*), like the preceding muscle, is partly lodged within the pelvis, (and this is much its largest portion,) partly also over the posterior aspect of the hip-joint. From the anterior surface of the pelvis, which it covers to a large extent, it is directed outwards, and, having escaped from the cavity, turns forwards to the femur, with which it is connected through the medium of a narrow tendon. The two portions of the muscle have therefore different directions; and the angle between them, or turning part, is supported by the small sciatic notch of the ischium.

The internal obturator muscle *arises* from the obturator membrane, together with the fibrous arch which protects the obturator vessels and nerve in passing by the muscle: from likewise the broad flat surface of the ischium external to the membrane, as far as the sciatic notch, and upwards to the brim of the pelvis. The fleshy fibres from



this extensive surface are received within the pelvis on four or five tendinous bands, and by this arrangement the muscle becomes narrowed before emerging from the cavity. The tendinous bands turn over the small notch of the ischium, which is grooved, and covered with cartilage, lubricated with a synovial bursa. In proceeding forward, the fibrous processes soon unite into a single tendon; and this, passing horizontally onward, is inserted into the fossa beneath the upper margin of the great trochanter, and in connexion with the gemelli.

In the pelvis this muscle is covered by the pelvic and obturator fascia, and is crossed by the internal pudic artery and nerve; and the same surface forms the outer boundary of the ischio-rectal fossa. The tendon, having united to it on each side the gemelli, is covered by the gluteus maximus, and is crossed by the great sciatic nerve. It is in contact with the capsule of the hip-joint.—There are usually two synovial bursæ connected with the tendinous part of the muscle. One has been already referred to, as occurring between it and the surface of bone over which it turns. The other, of much smaller size, is elongated and narrow, and is in contact with the tendon where it rests against the fibrous capsule of the hip-joint. In some instances the two are continuous one with the other, and form but a single sac.

The *gemelli* (*gemini*; *ischio-trochanterei*) are two small narrow fasciculi, consisting chiefly of fleshy fibres extended horizontally at each side of the tendon of the obturator internus; and they are named from their relative position. The superior one (*gemellus superior*, fig. 197,<sup>10</sup>) which is the smaller, *arises* from the spine of the ischium; the inferior (*gemellus inferior*<sup>12</sup>) takes origin from the upper and back part of the tuberosity of the same bone. Passing outwards, they join with a tendon of the internal obturator muscle placed between them, in some instances covering and concealing it from view, and are *inserted* with that tendon into the fossa under the upper margin of the great trochanter of the femur. A part of the fibres end on the tendon of the obturator, and this is especially the case as regards those of the superior muscle.

One of the gemelli is immediately below the pyriformis; the other is parallel with, and close to, the quadratus femoris, and at its termination is in contact with the tendon of the obturator externus muscle. With other parts they have the same immediate connexions as the part of the obturator internus which they enclose. They partly cover the synovial bursæ connected with that muscle.

The obturator muscles were so named, because of closing or covering the thyroid foramen.\* The internal muscle was likewise named "*marsupialis*," or "*bursalis*," from having connected with it a synovial bursa, which is perhaps more than usually distinct.

The gemelli might well be considered by the older anatomists† as appendages to the obturator, with which they are blended. From their connexion with its synovial bursa they were regarded by some authors as the muscular "*marsu-*

\* "*Propterea quod foramen ossium pubis principiis suis obturent.*" Spigelius, "*De h. corp. fabr.*" lib. iv. cap. 22.

† e. g. Vesalius, "*Oper.*" p. 414.



pium" of that muscle.\* The gemellus superior is often very small, and in some cases is altogether absent.

The *quadratus femoris* (tuber-ischio-trochantereus), (fig. 197,<sup>13</sup>) succeeds immediately to the muscles last described, intervening between them and the adductor magnus, and extending from the ischium to the great trochanter of the femur. It is short, flat, and square in shape; and from this last circumstance its name is taken.

The fibres *arise* from the external curved border of the tuber ischii, and, proceeding horizontally outwards, are *inserted* into the lower part of the posterior, and outer part of the great trochanter, on a slight ridge which terminates on that leading to the linea aspera. The line of insertion of this muscle may properly be called *linea quadrati*, to distinguish it from the intertrochanteric line; the latter being oblique in its direction, the former vertical.

This muscular plane has an admixture of tendinous fibres at its attachments. It is covered by the same parts as the muscles immediately above it, and likewise, to a small extent, by the origin of the semi-membranosus muscle. On removing it, the outer part of the obturator externus is brought into view.

The *obturator externus* (sub-pubio-trochantereus externus), is triangular in shape, and is placed very deeply, extending horizontally from the anterior surface of the pelvis to the trochanteric fossa of the femur, which it reaches by passing behind the hip-joint. To expose its origin requires the removal of the muscles placed in front and to the inner side of the thyroid foramen, viz., the psoas, iliacus, pectineus, adductor longus, and brevis; and the tendon is shown by the removal of the gluteus maximus and quadratus femoris.

The muscle *arises* from the rami of the os pubis and ischium, as far as the margin of the thyroid foramen, and from about half the surface of the obturator membrane. From this extensive origin the fibres pass outwards, converging to a tendon, which is directed behind the neck of the femur, to be *inserted* into the trochanteric fossa, beneath the inferior gemellus. The immediate connexions of the obturator externus with other muscles are sufficiently stated above. The obturator nerve lies on its upper part.

*Actions.*—The transverse direction of these muscles, and their mode of insertion into the trochanter, together with the great mechanical advantage afforded them by the length of the cervix femoris, enables them to act powerfully in rotating the thigh, and therefore the whole limb, outwards. In position, direction, and action, they are analogous to the muscles which pass from the dorsum of the scapula to the great tuberosity of the humerus; the latter, however, are nearly equalled in strength by their antagonist, the subscapularis. But the external rotators of the thigh are very feebly opposed by the tensor vaginæ femoris, and the anterior fibres of the gluteus medius, which alone act directly in rotating the limb inwards, if we except the semi-tendinosus, which may, under some circumstances, co-operate in this action. If the femur be bent on the pelvis, the line of direction of these muscles nearly coincides with the axis of the bone; their power of rotation then ceases, but they may in a slight degree become abductors; at least this may be said of the pyriformis, both from its direction and point of insertion.

\* Among others, Spigelius, loc. cit.; Cowper, "Myot. Reform." § 155.



## ANTERIOR FEMORAL REGION.

At the fore part of the thigh, we find immediately beneath the skin and fascia these muscles, viz., the tensor vaginæ femoris, sartorius, rectus, vastus externus and internus, and crureus.

*Dissection.*—*To expose the fascia lata:*—In the first place, let the knee be slightly bent,—the limb rotated outwards and supported on a block. And, as in this position the course of the femoral artery is indicated by a line extended from midway between the anterior superior spine of the ilium and the pubic symphysis to the lower border of the patella, the first incision through the skin should be made to the same extent, and in the same direction. In order to reflect the integuments with facility, a second incision may be made transversely at the junction of the upper with the middle third of the thigh; and, finally, another in the same direction at the junction of the middle with the lower third: this marks the termination of the femoral artery. The flaps of skin thus formed are to be dissected back, so as to expose the fascia lata. This membranous investment should be attentively examined in its entire extent, particularly at the upper part; the differences of texture and thickness which it presents in different parts should also be carefully noted.

*To expose the muscles:*—In prosecuting the dissection, in order to expose the muscles on the fore part of the thigh (and it is with these the dissection usually commences), nothing more is necessary, after the skin has been removed, than to pinch up the fascia with the blades of the forceps, divide it with your scalpel, and reflect it from above downwards, in the direction of the fibres of each muscle. After the sartorius and rectus have been dissected in their entire length, and their attachments and relations attentively examined, the former may be cut across in the middle, and the parts drawn aside; the latter too may be divided near its origin, and turned down on the leg. The triceps extensor is thus brought fully into view, so that its three parts (the two vasti and the crureus) may be inspected successively, at the same time that it is considered as a whole. The muscle, in fact, may be compared to a hollow splint, encasing the anterior and lateral surfaces of the shaft of the femur, leaving unoccupied only the linea aspera and its bifurcations (superior and inferior).

*To detach the vasti:*—A perpendicular incision may, in the next place, be made through the muscle, extending from one extremity to the other over the middle of the femur. If the margins of the incision be drawn aside, a clear view will be obtained of the manner in which the fibres pass to be implanted, by so many separate points, into the surface of the bone. Holding the border of the incision tense, and with the blade of the scalpel placed in the horizontal position, the muscle may be detached from the bone inwards as far as the insertion of the adductors, and outwards to the attachment of the gluteus maximus, and the short head of the biceps, so as to denude the front and sides of the thigh-bone. Having proceeded so far, cut from within outwards through the vasti, so as to detach them altogether. When this is done, the two parts thus separated may be turned down on the leg, still left connected with the patella.

By these measures we shall bring into view the inferior attachments of the next set of muscles (adductors), which would otherwise lie in a great degree concealed.

Before the extensors are detached and reflected, the form and boundaries of the opening for the femoral vessels should be attentively examined, as the vastus internus constitutes a part of it; nor should the fascia be omitted which passes from the latter muscle to the adductors, covering the vessels.

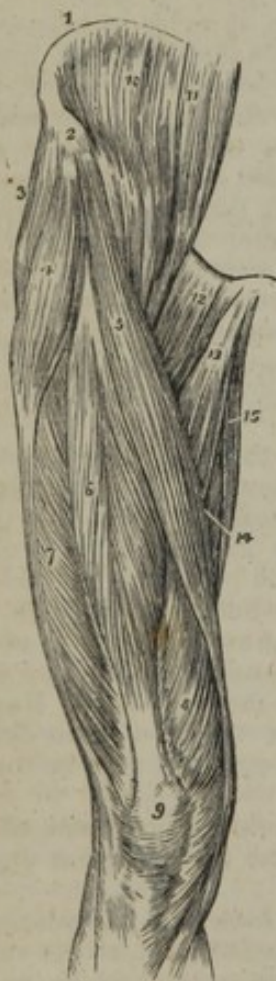The *tensor vaginæ femoris*,—Alb. (musculus fasciæ latæ; membranosus; ilio-aponeurosi-femoralis), (fig. 198,\*) is situated at the upper and outer part of the thigh, extending obliquely downwards, outwards and backwards, from the anterior superior spinous process of the ilium for some space below the great trochanter. The muscle is elongated and flat, and it is broader at the lower than at the upper extremity. It arises by aponeurotic fibres from the external surface of the ante-



rior superior spinous process of the ilium, between the gluteus medius,<sup>3</sup> and the sartorius,<sup>5</sup> and terminates below the great trochanter of the femur, its fleshy fibres being received between two laminae of the fascia lata, into which they are thus inserted.—The external surface of the muscle is covered by a layer of the fascia lata; the internal one is separated by another process of the same membrane from the rectus femoris and the vastus externus. Its anterior border is at first close to the sartorius; but lower down it diverges, and leaves an angular interval occupied by the rectus femoris. The posterior border is for some way applied to the gluteus medius, and is connected with it at its origin; but lower down these muscles are separated by an interval.

*Actions.*—As its name imports, the direct action of this muscle is to render the fascia tense, and thereby assist the other muscles. If this effort be farther continued, the obliquity of its direction will enable it to rotate the whole limb inwards, provided the other muscles remain quiescent. In the erect position, by taking its fixed point below, it will act on the pelvis.

[Fig. 198.



The muscles of the anterior femoral region. 1. The crest of the ilium. 2. Its anterior superior spinous process. 3. The gluteus medius. 4. The tensor vaginae femoris; its insertion into the fascia lata is shown inferiorly. 5. The sartorius. 6. The rectus. 7. The vastus externus. 8. The vastus internus. 9. The patella. 10. The iliacus internus. 11. The psoas magnus. 12. The pectineus. 13. The adductor longus. 14. Part of the adductor magnus. 15. The gracilis.—W.]

*Sartorius* (fig. 198,<sup>5</sup>) (ilio-præ-tibialis.)

This flat, narrow muscle extends from the outer side of the pelvis to the inner and fore part of the tibia, and its fibres are longer than those of any other muscle in the body. It arises, by tendinous fibres, from the curved margin of the ilium, between its anterior superior and inferior spinous processes, and from the former point of bone; and is inserted, by an expanded aponeurosis, into the upper and inner side of the tibia, just below its tuberosity. In this long course the muscle is directed over the anterior part of the thigh, obliquely inwards in the upper third, then vertically at the inner aspect of the limb as far as the knee, and below this it turns obliquely forwards to its place of attachment. The tendon of insertion, broad and expanded, covers those of the gracilis and semi-tendinosus (a synovial bursa being interposed,) and sends off an expansion which strengthens the fascia of the leg, by becoming identified with it.

The sartorius is covered only by the fascia lata and integument. It covers the iliacus, psoas, and rectus femoris muscles, the femoral vessels, the adductor longus, adductor magnus, vastus internus, gracilis, and semi-tendinosus muscles. Its internal border and the adductor longus form the sides, and Poupart's ligament the base, of a triangular space on the upper third of the thigh, through the centre and apex of which the femoral artery passes.



The name of this muscle has been taken from the influence ascribed to it on the position of the limb peculiar to tailors. It appears to have been first introduced by Spigelius.\*

As the direction the sartorius takes inwards varies in different cases, the position at which it covers the femoral artery (the most important practical point in the anatomy of the muscle) is by no means constant. In some cases it crosses inwards so speedily as to be placed over the vessel at a comparatively short distance from Poupart's ligament.†

*Quadriceps extensor cruris* (Sæmmerring).—The mass of the extensor muscles of the leg, which is distinguished by this general name, is of very large size, and covers the whole of the anterior and lateral surfaces of the thigh-bone. It is connected with the tibia by tendinous structure, which is undivided and common to the whole mass; but the upper extremity is separated into parts or heads, which are more or less distinct one from the other. One of the heads has no direct connexion with the femur. It reaches from the ilium to join with the other divisions of the muscle near the patella, having a straight course between these points over the fore part of the thigh; and hence is named "rectus femoris." The other divisions of the quadriceps are in immediate connexion with the femur, covering it from the trochanters to the condyles, except on the *linea aspera* and the intervals between the lines which extend from it towards the upper and lower ends of the bone. The portion laid on the outer side of the bone is named "vastus externus;" that on the inner side, "vastus internus;" these names being derived from the large number of the muscular fibres and the position they occupy. Another part placed on the anterior surface of the femur is named "crureus." This (last), it will however be found, is really not separable from the vastus internus.

a. The *rectus femoris* (ilio-rotuleus,—Cowper), (fig. 198,<sup>6</sup>) is situated in front of the thigh, and is extended in a straight line from the pelvis to the patella—whence the name. It *arises* by two tendons, one of which embraces the anterior inferior spinous process of the ilium; the other, the "reflected" part or tendon, turns outwards, and is attached above the brim of the acetabulum. The tendons unite at an angle, and then spread out into an aponeurosis from which fibres arise. The muscle gradually increases in breadth and thickness towards its middle, from which it again diminishes towards its lower part; the fleshy fibres ending in another tendinous expansion, which gradually narrows, and is *inserted* into the patella in conjunction with the triceps extensor. The muscle tapers from the middle to both ends, and the fibres are disposed in two sets, united at acute angles along the middle line, from which they pass off obliquely, diverging to the borders. From this arrangement, which resembles that of the lateral fibrillæ of a quill or feather, the muscle is said to be penniform. The fibres of the superior tendon run down a considerable way on the fore part of the muscle; those of the inferior tendon are prolonged upon its posterior aspect.

The anterior surface of the rectus is covered in all its extent by the

\* "Quem ego *Sartorium musculum* vocare soleo, quodd sartores eo maximè utantur, dum crur cruri inter consuendum imponunt."—Spigelius, "De h. Corp. fabr." l. 4, c. 23.—Riolanus named the muscle "*longus sive sutorius*."

† This point is illustrated in the work on Arteries before quoted, plate 74, figure 4.



fascia lata, except a small portion superiorly, where it is overlaid by the tensor vaginæ femoris, iliacus, and sartorius muscles (the reflected tendon is covered by the gluteus minimus). By the posterior surface the muscle is in contact with the fibrous capsule of the hip-joint and the vastus externus and crureus.

*b. Vastus externus*<sup>7</sup> (venter externus,—Sæmmerring).—This is the largest part of the muscle. It *arises* by an extensive aponeurosis, which is attached to the base of the great trochanter at its anterior aspect, and on a well-marked horizontal ridge on the outer side; likewise to the line or ridge extended between the trochanter and the linea aspera, as well as to the linea aspera itself (its outer margin). The aponeurosis thus connected spreads over the muscle, and gives origin to a very large number of muscular fibres. To these are added others, which spring from the intermuscular fibrous layer attached to the line of the femur, reaching between the linea aspera and the external condyle; and the whole end in a large tendinous expansion, which is laid on the deeper surface of the muscle towards its lower end. This tendinous structure becoming narrowed is fixed to the patella, and joins with the other parts of the general extensor muscle. The fibres vary in direction,—the highest are perpendicular, the lowest nearly horizontal, and the rest gradually pass from one of those courses to the other.

The vastus externus is covered to a small extent by the rectus, and the special tensor of the fascia lata; and the rest lies immediately beneath that membrane—the thickest (external) part of it. The muscle conceals, in part, the crureus; and some large branches of the external circumflex artery are likewise beneath it.

*c, d. Vastus internus*<sup>a</sup> and *crureus* (venter internus and venter posterior,—Sæmmerring).—There is no real separation between the parts which are distinguished by these names. Their position on the bone and the disposition of the tendon at the lower end alone serve to make the distinction.—The *vastus internus*, which occupies the inner aspect of the femur, increases considerably in thickness towards its lower end. It *arises* by a small aponeurosis from the line running downwards to the linea aspera of the femur, on the inner side, close to the small trochanter; from the linea aspera on its inner margin; and from the fibrous partition attached to the line extended between the linea aspera and the inner condyle in connexion with the tendon of the adductor magnus. From this extensive line of origin, and likewise from the inner surface of the bone, the fibres proceed downwards and outwards in directions necessarily varying, and are received on the tendon of insertion, which is for the most part on the deep surface of the muscle. The tendon terminates by joining with the like structures from the other divisions of the extensor muscle in the neighbourhood of the patella.—The *crureus* (seu femoreus,—Cowper).—To this head is assigned the muscular structure arising on the anterior surface of the femur, from the line between the trochanters to within a couple of inches of the patella. The tendon in which the fibres terminate inferiorly is laid on their anterior surface, and has, therefore, a different



position with respect to the muscular substance from the tendon in which the vastus internus ends.

The vastus internus is covered by the fascia lata and the sartorius, and is in contact at its inner side with the femoral vessels. The inner border is connected with the tendons of the adductor muscles. The crureus is covered by the rectus muscle, and partly by the vastus externus. Its lower end lies on the synovial membrane of the knee-joint.

*Subcrureus.*—Under this name is described a small band of muscular fibres, which extends from the anterior surface of the femur to the upper part of the synovial membrane of the knee-joint, on which it ends in scattered fibres. This little muscle is placed beneath the crureus, (hence the name applied to it,) and in some cases it is united with that muscle. It is not unfrequently double, or consists of two separate bundles.

The *tendons of insertion* of the different parts of the great extensor muscle above described are joined together at the lower end of the thigh, (constituting the whole a single muscle,) and are attached to the patella, or more properly continue downwards to be fixed to the anterior tuberosity of the tibia. The patella is contained in the tendon; and the part of the tendinous structure below that bone, consisting of thick longitudinal fibres, is named the ligament of the patella (ante, p. 280). Moreover, an aponeurotic laminae is extended at each side of the patella from the vasti to the upper extremities of the tibia and fibula. The fibrous structure on the outer side is strengthened by, and for the most part is derived from, the fascia lata, which is very resistant in that situation. The tendinous structure covers the knee-joint.

By most French anatomists the vasti and crureus are described apart from the rectus as a three-headed muscle, and the name "triceps crural" is applied to the mass (see Sabatier, Gavard, Boyer, &c.); though that name had been assigned to the adductors by several anatomical writers, and even by one eminent authority in France (Winslow).

*Actions.*—The most ordinary action of the foregoing muscles is to extend the leg upon the thigh, which they are enabled to do by their connexion with the patella and its ligament, the latter being inserted into the tibia. The immediate action of the sartorius is to bend the leg upon the thigh.

If the leg be fixed, as in the standing posture, the extensor muscles, taking their fixed point below, will act upon the femur and keep it perpendicularly on the condyles of the tibia, so as to counteract the influence of the weight of the body, which tends to flex the knee as well as the other articulations. The rectus and sartorius assist materially in maintaining the erect position of the body, for instance, when we stand on both legs, for they act on the pelvis and draw it forwards, so as to keep it fixed and upright on the femur; in this they become assistants to the psoas and iliacus. It may be observed that the oblique direction of the sartorius enables it to give a slight rotatory motion to the pelvis when we stand on one leg, by drawing the spinous process downwards and inwards.

#### INTERNAL FEMORAL REGION.

Along the inside of the thigh we find the following muscles, viz., the gracilis, pectineus, adductor longus, and adductor brevis and magnus. The pectineus at its origin is rather at the fore part of the limb, but at its insertion it lies to the inner side.



*Dissection.*—To expose the muscles of this group, nothing more is required, after examining the extensor muscles, than to remove the fascia from the inner and fore part of the thigh. The direction and attachments of the adductor longus, running obliquely from the angle of the os pubis to the middle of the thigh, are at once obvious. The gracilis, too, will be observed running along its inner border. If the thigh be abducted, the fibres of these muscles will be rendered tense, and their dissection facilitated.

When proceeding with the dissection, the adductor longus may be severed from its superior attachment, and drawn downwards on the femur. In doing this, its posterior surface will be observed to be connected to the adductor magnus for a little way before their fibres reach the bone. The pectineus, lying to the outer side of the adductor, may in the next place be examined, and reflected after the same manner, which will bring into view the adductor brevis and the obturator externus.

Whilst these measures are being executed, both surfaces of each muscle should be dissected, or, in other words, all the cellular tissue connected with them should be removed by successive strokes of the knife, the edge being carried in the course of the fibres; and when their attachments, external conformation, and structure have been thus fully made out, each of them may be again restored to its place, that their mutual relations and bearings may be reconsidered. It is usual to direct that muscles, more especially the long ones, should be divided in the centre, and the two portions reflected. But if this precept be followed, it will be observed that students seldom examine, with any degree of accuracy, the points of attachment of muscles, without a precise knowledge of which it is quite impossible to reason correctly on their actions and uses. When a student is performing the dissection of the limb for the first time, it may be well if he confine his attention to the muscles, observing merely the general outline of the vessels and their branches; after which they may all be dissected away, in order to obtain an uninterrupted view of the muscles in their whole extent.

The *gracilis* (fig. 196,<sup>s</sup>; fig. 198,<sup>15</sup>) (pubio-præ-tibialis) is situated along the inner side of the thigh, extending from the os pubis and its ramus to the inner and upper part of the tibia. The muscle is flat and thin; broad at its upper extremity, narrow and tapering at the lower. It *arises* by a thin aponeurosis from the body of the os pubis, close to its symphysis (the lower half of its depth), also from the border of its ramus; and is *inserted* by a tendon (which is at first round, but afterwards becomes flat) into the inner side of the tibia, close below its tuberosity, on the same plane with the semi-tendinosus, and under the expanded tendon of the sartorius. The direction of the muscle is vertical, but at the lower extremity it inclines forwards to the point of attachment.

The inner surface of this slender muscle is covered by the fascia lata, except a small part inferiorly, where it is overlapped by the sartorius; the external rests against the adductor longus, adductor magnus, and semi-membranosus, the knee-joint, and its internal lateral ligament.

The *pectineus* (fig. 198,<sup>12</sup>) (pectinalis,—Douglas; pubio-femoralis), is situated at the superior and fore part of the thigh, and is extended from the horizontal branch of the os pubis (its upper surface) to the posterior and inner aspect of the femur. Flat and nearly quadrangular in form, it *arises* from the ilio-pectineal line, with the surface in front of it, between the eminence of the same name and the spine of the os pubis, and is *inserted* into the line which connects the smaller trochanter to the linea aspera of the femur, immediately below the united attachment of the psoas and iliacus muscles. In its course downwards, the



muscle inclines outwards, and backwards, and opposite the smaller trochanter turns on itself, so that the anterior surface looks somewhat outwards. It consists of fleshy fibres, except at the attachments, the lower of which is aponeurotic, and the upper one slightly so.

The pectineus is in contact, by the anterior surface, with the fascia lata and femoral vessels; by the posterior surface, with the obturator vessels and nerves, and the external obturator and adductor brevis muscles; by the outer border with the psoas magnus, by the inner border with the adductor longus.

The *adductor longus* (fig. 198,<sup>13</sup>) (adductor primus; pubio-femoralis), situated on the same plane with the preceding muscle, is flat, irregularly triangular, and extends obliquely from the anterior and upper part of the os pubis to the middle of the linea aspera of the femur. It *arises* by a tendon from the fore part of the tuberosity of the pubes, and a small portion of the body of the same bone, and is *inserted* into the middle third of the linea aspera, between the vastus internus and the adductor magnus. Between these points it is directed downwards, with an inclination outwards, and backwards. And the fleshy fibres commencing by a tendon end in an aponeurosis inferiorly. From the aponeurosis several fibres are detached, which unite with those of the adductor magnus.

The muscle is covered by the fascia lata, the sartorius, and femoral vessels; the posterior surface rests on two other adductor muscles. The external border is parallel with the pectineus (a small portion of the adductor brevis being observable behind and between them); the inner border, which is much the longer, is in apposition with the gracilis.

The *adductor brevis* (adductor secundus; sub-pubio-femoralis) lies behind the two preceding muscles. Its form is nearly triangular, being thick and narrow at its upper part, but gradually becoming broader and thinner towards its insertion. It *arises* by a narrow origin from the external surface of the os pubis, and is directed obliquely backwards and outwards, to be *inserted* (by a tendon) into the oblique line leading from the lesser trochanter of the femur to the linea aspera, immediately behind the insertion of the pectineus.

The short adductor is in contact, by the anterior surface, with the pectineus and adductor longus; by the posterior, with the adductor magnus; by the external border, with the obturator externus, and the tendon of the psoas and iliacus; by the inner border, with the gracilis in part of its extent, the rest being concealed between the two other adductors. It is pierced by some of the perforating branches of the profunda artery.

*Adductor magnus* (ischio-femoralis).—This very large muscle is situated deeply at the posterior and inner part of the thigh,—hence but a few of its fibres<sup>14</sup> can be seen in this view; and it extends from the tuberosity and ramus of the ischium to the whole length of the linea aspera of the femur, and to the inner condyle. It *arises* from the ramus of the os pubis and that of the ischium, also from the border of the tuberosity of the latter bone. The muscular fibres diverge from their origin, somewhat like the ribs of a fan from their central pivot;



those from the os pubis, shorter than the rest, pass transversely outwards, and are inserted into the rough line prolonged from the linea aspera directly upwards; others pass with varying degrees of obliquity downwards and outwards, to be inserted into the whole length of the linea aspera, and a small part of its internal bifurcation, where they end in a pointed process; finally, some of the fibres descend almost vertically, forming the inner border of the muscle, and terminate in a rounded tendon, which is inserted into the tuberosity on the inner condyle of the femur. The muscle thus presents two parts: one, a flat broad plane, inserted into the linea aspera, and forming a septum between the anterior and posterior muscles of the thigh; the other being the elongated part which goes to the condyle; and between them an angular interval is left for the transmission of the femoral vessels backwards into the popliteal space. This muscle forms the greater part of the muscular structure at the inner side of the thigh. The fleshy substance is arranged in large and easily separable bundles; it is connected by tendinous fibres with the pelvis, and ends on the femur in a broad aponeurosis and the tendon already noticed.

The superior, or shortest border, of the adductor magnus is parallel with and close to the quadratus femoris; the internal, or longest border, is covered by the fascia lata, the gracilis, and sartorius; the external border (its femoral attachment) is interposed between the two other adductors and the vastus internus, which lie in front of it and the gluteus maximus, and short head of the biceps, which separate it from the vastus externus. The posterior surface is covered by the great sciatic nerve and hamstring muscles; the anterior by the sartorius, the adductor brevis and longus, and the femoral vessels. The anterior surface of the muscle is intimately blended with the adductor longus before it reaches its insertion; it also sends off an aponeurosis, which passes in front of the femoral vessels, and becomes blended with the vastus internus; finally, its prolonged portion is intimately connected with the last-named muscle. The interval left between the two parts of this muscle for the passage of the femoral vessels is triangular in its form, and fleshy and tendinous in its structure, when viewed from behind; but at its anterior aspect it is altogether tendinous in its entire extent, and oval in its form.

*Actions.*—These are the direct adductors of the femur, and their force must be considerable, both from their strength and number. As the linea aspera projects from the shaft of the bone, the adductors are removed proportionally from its axis, and so are enabled to rotate it outwards, thus conspiring with a distinct class of muscles, the external rotators. If the whole limb be in the extended position, they will draw it inwards, the gracilis assisting. The femur is bent on the pelvis by the action of the pectineus (and slightly by the adductor longus and brevis), thus conspiring with the psoas and iliacus. When the lower extremities are firmly fixed on the ground, these muscles contribute to maintain the body in the erect position, by taking their fixed point below, and thence acting on the pelvis. If this effort be continued, the pectineus and adductor longus may be made to flex the pelvis on the femur, by drawing the os pubis downwards.

#### POSTERIOR FEMORAL REGION.

At the back of the thigh are placed the three long flexor muscles of the leg, viz., the biceps, semi-tendinosus, and semi-membranosus.



They are immediately subjacent to the skin and fascia, except at their superior attachment.

The *dissection* of this group should follow that of the muscles in the gluteal region. From the middle of the incision made along the fold of the nates, or, what will answer just as well, from opposite the middle point between the tuber ischii and the great trochanter, carry an incision through the skin straight down along the back of the thigh and popliteal space, so as to mark out the median line of both. Let this extend to about three inches below the flexure of the knee-joint, and be there bounded by a transverse incision five or six inches in length. Make a similar transverse incision at the union of the middle with the lower third of the thigh. Now with your forceps pinch up the angles of these flaps of skin, and carefully dissect them off the subjacent fascia, which you will recognise as a smooth shining membrane. Examine this carefully in its whole extent. At the lower part of the thigh you will see it stretched tightly across from side to side, covering an angular space (popliteal space, or the ham in popular language), enclosed by the flexor or hamstring muscles, viz., those which you are now about to examine. Make an incision through the fascia from above downwards, along the middle of this space; bound it above and below by two transverse cuts. Pinch up the flaps of fascia tightly, and dissect them off the muscles, and so proceed downwards to their insertion into the tibia and fibula: continue the same process upwards, until you expose the muscles in their entire extent.

The attachments of the semi-membranosus require attention. To gain a clear view of them, the muscle may be cut across in the ham and drawn down, when, by holding it tense, one set of fibres will be observed to pass along the inner tuberosity of the tibia, another obliquely behind the joint, whilst the third goes perpendicularly downwards, which, after being fixed to the posterior surface of the tuberosity of the tibia, sends a dense fascia over the popliteus muscle, which is ultimately continuous with the deep fascia of the leg.

*Biceps femoris* (biceps flexor cruris; ischio-femoro-peronealis).—This muscle is situated at the posterior part of the thigh, and consists superiorly of two parts. These extend, one from the ischium (the long head), the other from the femur (short head), and unite to terminate on the fibula. The long head (fig. 196,<sup>4</sup>) *arises*, by a tendon common to it and the semi-tendinosus, from the upper and back part of the tuberosity of the ischium,—the femoral portion,<sup>5</sup> (or short head,) from the linea aspera of the femur, between the adductor magnus and vastus externus muscle, nearly as high up as the insertion of the gluteus maximus. The fibres of the former end on an aponeurosis which covers the lower part of the muscle. This aponeurosis likewise receives the muscular substance of the short head, and is then narrowed into a tendon which is *inserted* into the head of the fibula. Moreover, the tendon, whilst being attached, separates into two portions, which embrace the external lateral ligament of the knee-joint; and one of these passing forwards is inserted into the tibia. An expansion is likewise given off, which strengthens the fascia of the leg.

This muscle is covered by the gluteus maximus and fascia lata. In front it lies against the semi-membranosus, the sciatic nerve, and adductor magnus, and inferiorly, the gastrocnemius, with the external articular arteries. The peroneal nerve is to the inner side.

The *semi-tendinosus*, (fig. 196,<sup>6</sup>) (ischio-præ-tibialis), is situated at the posterior and inner part of the thigh. It *arises* from the posterior part of the tuber ischii, close to the inner side of the biceps, and continues to arise from the tendon of that muscle for three inches lower



down, somewhat in the same way as the coraco-brachialis does from the biceps of the arm. A little below the middle of the thigh it ends in a long round tendon, from the length of which the muscle is named. The tendon, after passing on the semi-membranosus along the inner side of the popliteal space, is reflected forwards, to be *inserted* into the inside of the upper part of the tibia, below its tuberosity, where the tendon is on the same plane, and below that of the gracilis—both being under cover of the sartorius.

The semi-tendinosus, except where it is slightly overlapped by the biceps, is covered by the fascia lata; the anterior surface rests on the semi-membranosus in the greater part of its extent; towards its termination, it runs beside the knee-joint.

*Semi-membranosus*, (fig. 196,<sup>7</sup>) (ischio-poplito-tibialis.)—This muscle *arises* from the posterior part of the tuberosity of the ischium, in front of the biceps and semi-tendinosus and behind the quadratus femoris, and is *inserted* by three portions, of which the middle one is fixed to the tibia, behind its inner tuberosity, and sends an expansion which covers the popliteus muscle; the internal portion passes forwards under the internal lateral ligament, and is inserted along the side of the inner tuberosity of the tibia; the third, broad and expanded, is reflected backwards and upwards behind the joint, and is inserted into the external condyle of the femur, becoming identified with the ligamentum posticum. The muscle begins by a strong flat tendon which spreads out to give origin to short and very numerous fleshy fibres, and these are directed obliquely downwards to another aponeurosis which is narrowed into the tendon of insertion.

It is in contact by the posterior surface with the biceps, semi-tendinosus, and fascia lata; by the anterior surface with the quadratus femoris, adductor magnus, the popliteal artery, inner head of the gastrocnemius and knee-joint; by the inner border with the gracilis and fascia lata; by the outer border with the sciatic nerve. This muscle forms the larger part of the inner boundary of the popliteal space.—At the upper end it is separated from the conjoined origin of the two preceding muscles by a synovial bursa.

*Combined Actions.*—These are usually called the hamstring muscles, as they enclose the ham, or space at the posterior aspect of the knee-joint: the biceps being placed at its external side, the other two at the internal. Their direct action is that of flexing the leg on the thigh, and this they do directly backwards, when they conspire in their action; but if they be made to act alternately, the leg will be rotated slightly inwards or outwards; the latter motion, however, can only take place in the semi-flexed position of the limb. In the standing posture, these muscles, by taking their fixed point below, will act on the pelvis so as to prevent its flexion forwards; and, if the effort be continued, they will draw it directly backwards, and commence that series of muscular actions observable in tumbling and other feats of activity, in which the body is thrown backwards so as to form an arch.

## MUSCLES OF THE LEG.

### ANTERIOR TIBIO-FIBULAR REGION.

In the interval between the tibia and fibula we find three long muscles, viz., tibialis anticus, extensor proprius pollicis, and extensor communis digitorum.



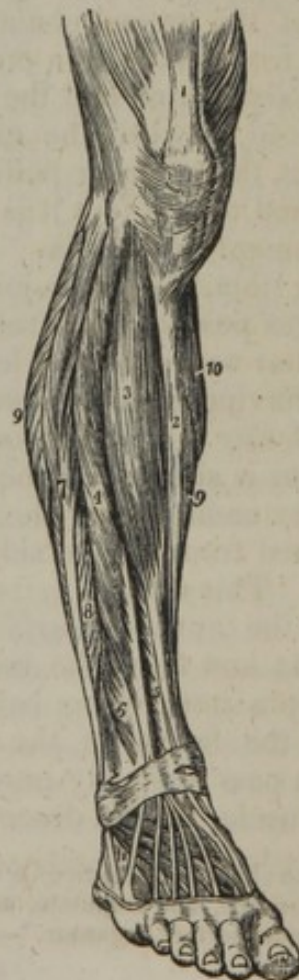*Dissection. To expose the fascia.*—The subject being placed on its back, bend the knee and place under it a high block, so that the leg should form an inclined plane; turn the foot inwards, and fix it in that position. Now, make an incision through the skin, beginning above at the middle point, between the head of the fibula and the spine of the tibia, and continue it straight down over the middle of the ankle-joint and dorsum of the foot. As this is a very long incision, intersect it by a transverse one at each end, and another in the middle; raise the flaps of skin tightly, you will see the dense fascia of the leg beneath it; dissect back the flaps, and expose this membrane in its entire extent.

*To expose the muscles.*—Divide the fascia along the leg as you did the skin, but opposite the flexure of the ankle-joint leave undivided a band of it about an inch wide, where it stretches across obliquely from one ankle to the other, forming the anterior annular ligament. Beginning a little above the ankle, raise the fascia from the tendons, and, taking them as your guide, dissect it from below upwards from the muscles.

The muscles of the leg, taken altogether, may, to facilitate their classification, be divided into sets, each consisting of three. Thus, on the fore part of the leg, and lying between the tibia and fibula, we find the *tibialis anticus*, the *extensor communis*, and *extensor pollicis*, being the group which we are now examining. On the external side of the leg, and in close contact with the fibula, are placed the *peroneus longus* and *brevis*. The third muscle of this name is, in reality, a part of the *extensor communis*, and is separated from the other two by the breadth of the fibula. It still, however, is described as a separate muscle, probably to keep up the ternary division. Posteriorly there are two sets, one being superficial, consisting of the *gastrocnemius*, *soleus*, and *plantaris*; and the other deep-seated, viz., *tibialis posticus*, *flexor longus digitorum*, and *flexor longus pollicis*.

The *tibialis anticus*,—Cowper, (*tibio-super-tarseus*), (fig. 199,<sup>3</sup>) is situated at the front of the leg, being extended along the outer side of the tibia and reaching to the inner part of the tarsus. It arises from the external tuberosity of the tibia, and about two-thirds of the flat surface beneath it: from a small portion of the interosseous ligament: from the fascia of the leg: and an aponeurotic septum placed between the muscle and the *extensor digitorum communis* muscle. The fleshy fibres end in a tendon which is at first concealed in their substance, and becomes apparent at the anterior surface of the muscle towards the lower third of the leg. The tendon, freed from the muscular substance, passes through a separate compartment of the anterior annular ligament, and is inserted into the internal and lower part of the first cuneiform bone, and the contiguous extremity of the first metatarsal bone. This muscle has considerable

[Fig. 199.]



The muscles of the anterior tibial region. 1. The extensor muscles inserted into the patella. 2. The subcutaneous surface of the tibia. 3. The *tibialis anticus*. 4. The *extensor longus digitorum*. 5. The *extensor proprius pollicis*. 6. The *peroneus tertius*. 7. The *peroneus longus*. 8. The *peroneus brevis*. 9, 9. The borders of the *soleus* muscle. 10. A part of the inner belly of the *gastrocnemius*. 11. The *extensor brevis digitorum*; the tendon in front of this number is that of the *peroneus tertius*; and that behind it, the tendon of the *peroneus brevis*.—W.]



breadth at its commencement, but it gradually lessens in size towards the lower part of the leg, as the fleshy fibres end on the tendon.

The tibialis anticus is covered by the fascia, which adheres to the muscular structure superiorly, and gives origin to a considerable number of its fibres. It rests against the interosseous membrane in the greater part of the leg, but inferiorly the tendon is supported by the fore part of the tibia. And it has on one side the bone just named; on the other side, the extensor digitorum communis and extensor pollicis pedis. The anterior tibial artery and nerve lie along the outer side of the muscle, between it and the two muscles last mentioned.

The tibialis anticus was named "*musculus catenæ*" by Spigelius, for a reason which, even if it were correct as to the fact, seems a singular one to found a nomenclature on, namely, that the tendon being divided or removed, the sufferer is compelled to raise the foot in walking with the aid of a sling.\*

*Extensor proprius pollicis*,—Alb. (fig. 199,<sup>5</sup>).—The special extensor of the great toe is placed at the fore part of the leg and on the dorsum of the foot along its inner border, between the muscle last described and the extensor digitorum communis. This muscle is elongated, flat, and compressed in the middle, pointed at the extremities. It *arises* from the internal surface of the fibula for more than the middle third of its extent, and from the contiguous surface of the interosseous ligament, nearly as far as the ankle. The fleshy fibres run obliquely forwards into a tendon placed at the anterior border of the muscle; and the tendon, after passing beneath the annular ligament in a distinct compartment, and along the dorsum of the foot, is *inserted* into the base of the second phalanx of the great toe. A delicate expansion given from the tendon on each side spreads over the joint between the metacarpal bone and the first phalanx.

Placed between the extensor digitorum communis, and the tibialis anticus, the extensor pollicis is overlapped for some way by these muscles, and on the foot it is covered, like the other tendons, only by the integument and fascia. It rests successively on the anterior surface of the tibia, the ankle-joint, and the bones of the foot. This muscle changes position with respect to the anterior tibial artery, being outside that vessel on the leg, while it lies to the inner side on the foot, after having crossed over it.

*Extensor longus digitorum pedis* (fig. 199,<sup>4</sup>).—The long extensor of the toes is situated at the fore part of the leg and on the dorsum of the foot, extending from the head of the tibia to the toes. It is thin, or flattened from side to side, and at the lower end divides into four tendons. This muscle *arises* from the external tuberosity of the tibia: from the anterior surface of the fibula for about two-thirds of its length: and from the interosseous ligament: also from the aponeurotic septa intervening between it and the muscles, on each side, and from the fascia of the leg. The fleshy fibres from this extensive origin pass obliquely into three flat tendons placed on the fore part of the muscle. These descend beneath the annular ligament, in the same

\* "Ab aliis tibieus anticus, à me *catenæ musculus* vocatus, quòd dissecto per transversum huius tendine, aut amputato, catenam ægri, cuius beneficio ambulantes pedem flectant eleventque, portare cogantur."—"De h. corp. fabr." l. iv. c. 24.



sheath with the peroneus tertius; and on the dorsum of the foot the inner one divides into two parts, so as to increase the number of tendons to four, corresponding in number with the four smaller toes. Each of these tendons is joined on the first phalanx by the tendon of the extensor brevis digitorum on the outer side, as well as by tendinous processes from the lumbricales and interosseous muscles; and thus a fibrous expansion is produced, which covers that (the first) phalangeal bone of the toe. The tendinous expansion divides, in the manner of those of the corresponding muscle of the hand, into three parts. The small middle division is inserted into the base of the second phalanx; and the two lateral parts, after joining together, terminate on the last phalanx. But the fourth tendon (that of the little toe) is not joined by an offset from the short extensor of the toes. From these tendons, slender bands spread over the joints of the metatarsal bones with the phalanges on each side. The same arrangement occurs in the hand.

The long extensor of the toes is covered only by the integument and fascia. It is placed between the tibialis anticus with the extensor of the great toe, which lie on one side, and the peronei muscles on the opposite side; and it rests successively against the bones of the leg, with their connecting (interosseous) membrane, the ankle-joint, and the short extensor of the toes.

Five tendons are ascribed to this muscle by Cowper;\* the fifth, with the fleshy fibres it receives, being the muscle, or, more properly, the part of the long extensor commonly known as the "peroneus tertius."

The *peroneus tertius* is placed along the fore part of the fibula at its lower third, and lies just below the extensor longus, with which its muscular fibres<sup>6</sup> are united, and of which it is really but a part. It *arises* from the lower third of the fibula, being attached to the anterior border and inner surface of the bone; also from the interosseous ligament, and an aponeurosis which connects it on the outer side with the peroneus brevis. The muscular fibres end in a tendon, which, after passing through the annular ligament with the long extensor of the toes, is *inserted* into the upper surface of the fifth metatarsal bone, and likewise in some instances into the fourth.

The peroneus tertius is liable to some deviations from the ordinary disposition. The part of the muscular structure which would be assigned to it may be equal in size to that which belongs to the extensor tendons of the toes. The tendon only may have much more than the ordinary size. It has been observed to terminate on the fourth metatarsal bone and the fascia covering the foot. And the muscle may be altogether wanting.

*Extensor brevis digitorum pedis.*<sup>11</sup>—The short extensor of the toes is a broad and thin plane of muscular fibres situated on the dorsum of the foot, and dividing at its anterior extremity into four small parts. It *arises* from the dorsal surface of the calcaneum, and from the ligament connecting that bone with the astragalus, as well as from the annular ligament of the tarsus, and terminates in four tendons, the first or most internal of which is inserted into the tarsal end of the first phalanx of the great toe; the other three become severally united to the outer borders of the extensor tendons, proceeding to the three

\* Myot. Reform., c. 36, p. 111.



next toes.—This muscle is covered by the tendons of the long extensor and peroneus tertius, and it rests on the tarsus, metatarsus, and the dorsal interosseous muscles. The part destined for the great toe crosses over the dorsal artery of the foot.

*Actions.*—A very slight effort of the extensor communis and extensor proprius pollicis extends the digital phalanges, and, if their action be continued, they will be made to bend the foot upon the leg. This they are enabled to do by the manner in which their line of direction is altered by the annular ligament of the ankle-joint, as it gives them all the mechanical advantage of a pulley. The tibialis anticus and the peroneus tertius are the direct flexors of the foot on the leg, and, if either act separately, it will give a slight inclination towards the corresponding side. In the erect position, these muscles take their fixed point below, and, by drawing on the bones of the leg, keep them perpendicular on the foot. The extensor brevis is obviously but an accessory to the long extensor; but, from the obliquity of its direction, it is fitted not only to extend the toes, but also to draw them somewhat outwards.

*Peroneus longus* (peroneo-sub-tarsus) (fig. 199,<sup>7</sup>) is situated at the outer side of the leg, and under the foot. It *arises* from the two upper thirds of the external surface of the fibula—from a small part of the external tuberosity of the tibia, and from the fascia of the leg; also from aponeuroses interposed between it and the contiguous muscles, viz., the extensor communis digitorum on one side, and the soleus and flexor longus pollicis on the other. Proceeding from these attachments, it descends and becomes tendinous. The tendon, freed from the muscular structure at some distance from the foot, passes, with that of the peroneus brevis, in a groove on the posterior surface of the external malleolus, where they are covered by a fibrous band extended from the end of the fibula to the calcaneum, and invested by a common synovial membrane. The tendons then separate; that of the peroneus longus proceeds obliquely forwards in another groove on the external surface of the calcaneum, to which it is connected by a separate fibrous band, lubricated with a synovial bursa. It then turns over the outer margin of the foot, and enters a groove on the lower surface of the cuboid bone, resting against the ridge behind that groove, and covered by a synovial membrane. From this point the tendon inclines forwards and inwards across the foot immediately beneath the bones, to be inserted into the tarsal end of the first metatarsal bone. The muscle therefore changes its direction at two points, namely, behind the lower end of the fibula and on the cuboid bone; and the bones on which it turns are to be considered as pulleys, changing the direction of the muscular power. At the two points of reflection the tendon is thickened and indurated; at the lower one a sesamoid bone is often deposited in it.

The peroneus longus is placed immediately beneath the fascia of the leg, and lies between the extensor longus digitorum, with the peroneus tertius which is before it, and the soleus and flexor longus pollicis placed in the opposite direction. In the foot, being near the bones, it is above all the plantar muscles.

*Peroneus brevis* (semi-fibulæus,—Spigelius), (fig. 199,<sup>8</sup>).—This muscle lies beneath the preceding, and is considerably shorter than it, neither reaching so high on the leg, nor extending so far on the foot.

It *arises* from the external surface of the fibula for about the lower half of its extent, and from the intermuscular septa which dip in



between it and the contiguous muscles. From these sources the fibres are directed to a tendon lying on their outer surface, a portion of them reaching as low as the malleolus. The tendon passes behind the external malleolus in the same groove and sheath; is invested by the same synovial membrane with the preceding muscle; and, after inclining forwards beneath the fibula, is *inserted* into the base of the last metatarsal bone, after having traversed a separate groove in the calcaneum, situated above that for the tendon of the peroneus longus.

*Actions.*—The peroneus longus and brevis, by the change of their direction, after turning behind the external ankle, are enabled to draw the foot back, and so extend it on the leg. The peroneus tertius is, on the contrary, a flexor of the foot; it lies before the fibula, and combines with the extensor communis. The peroneus longus is enabled to evert the sole of the foot, by means of the mechanical advantage which it derives from turning round its external margin. This, however, is not readily perceptible in the natural condition of the limb; but, if the fibula be fractured, and the check afforded by the external ankle be in consequence diminished, it will take place to a considerable extent. When the peronei take their fixed point below, they act on the bones of the leg, and assist in maintaining them erect on the foot. This power is chiefly called into action when we stand on one leg. The weight of the body must then tend to incline the leg inwards; but the peroneus longus, acting from its fixed point in the sole of the foot, with the additional power given it by the pulley round which it turns, draws on the external side of the bones of the leg, and prevents them from obeying the influence which otherwise would incline them inwards.

#### POSTERIOR TIBIO-FIBULAR REGION (SUPERFICIAL).

On the posterior part of the leg there are two sets of muscles; one superficial, the other deep-seated. The latter consists of muscles, which are the antagonists of those in front, viz., the tibialis posticus, flexor digitorum longus, and flexor longus pollicis; together with the popliteus, which is placed above these muscles, and close to the knee-joint.

The superficial muscular structure (extensor tarsi suralis vel extensor magnus,—Douglas; musculus suræ, Sæmmerring) is a large mass, and constitutes the calf of the leg. The great size is characteristic of man. It is connected with his peculiar mode of progression, and is calculated to elevate the heel in opposition to the weight of the entire body.

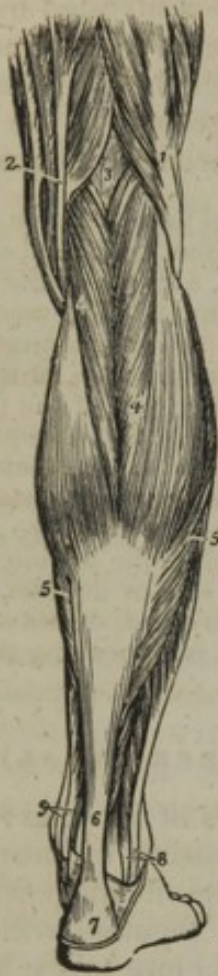At the lower end the mass is narrowed into a single tendon (tendo Achillis), which is attached to the heel; but the muscular substance is divided into two thick strata, which are connected one with the femur, the other with the bones of the leg.

*Dissection.*—The gastrocnemius may be exposed without any difficulty, by dissecting off the fascia, commencing where it is continuous with that covering the popliteal space; after which, the internal head of the gastrocnemius may be raised, and its border reflected outwards. By this expedient the thin tendon of the plantaris will come into view, and afford a guide to its muscular belly, which may otherwise be raised with the external head of the gastrocnemius, with which it is closely in contact. The soleus may in the next place be detached, taking the inner surface of the tendo Achillis as a guide; previously to which, attention should be directed to the structure of that part of its upper border, between its tibial and fibular origins, which is arranged for the transmission of the posterior tibial vessels.



The *gastrocnemius* (fig. 200,<sup>4</sup>) (gemellus,—Cowp.; bi-femoro-cal-caneus) is situated at the posterior aspect of the leg, forming the greater part of what is named the calf (*γαστήρ*, a belly; *κνήμη*, the leg).

[Fig. 200.]



The superficial muscles of the posterior aspect of the leg. 1. The biceps muscle forming the outer hamstring. 2. The tendons forming the inner hamstring. 3. The popliteal space. 4. The *gastrocnemius* muscle. 5, 5. The soleus. 6. The tendo Achillis. 7. The posterior tuberosity of the os calcis. 8. The tendons of the peroneus longus and brevis muscles passing behind the outer ankle. 9. The tendons of the *tibialis posticus* and *flexor longus digitorum* passing into the foot behind the inner ankle.—W.]

It consists of two parts (hence the second of the names above applied to the muscle\*), the internal of which is the larger. At the upper extremity the two parts diverge, and form the lower boundaries of the popliteal space. They are named "heads," and are distinguished as "external" and "internal." Each head arises by a thick tendon which is fixed to an irregular and depressed surface above the corresponding condyle of the femur, as well as by a few tendinous and fleshy fibres attached higher up, especially on the inner side, on which they are connected for a short space with the ridge running to the *linea aspera*. The tendon spreads out behind the muscle, and gives origin on its anterior surface to a large mass of muscular fibres. Some of the innermost muscular fibres from both sides meet at an angle on a fibrous structure which is common to them, but the two parts are not confounded one with the other; and a groove indicates the place of separation. The great mass of the fleshy fibres are directed downwards and forwards, from the aponeurosis of origin behind, to one of insertion in front of the muscle; and the latter, gradually contracting, joins with another from the soleus. The tendo Achillis results from their union.

The *gastrocnemius* is covered by the fascia of the leg, and the short saphenous vein lies on it opposite the interval between its two parts. It conceals the plantaris, the soleus, and the popliteus, with the popliteal vessels and the internal division of the sciatic nerve. The "heads" are placed between the hamstring muscles; and between the external one and the biceps is lodged the peroneal nerve. Over the condyles, these parts of the muscle are in contact with the thin fibrous membrane of the knee-joint. A synovial bursa (which in some cases communicates with the synovial membrane of the knee-joint) is interposed on the left side. And a sesamoid fibro-cartilage will sometimes be met with over the outer condyle, occasionally over the inner likewise. The last-mentioned substance is rarely osseous.

The *soleus*<sup>5</sup> (*tibio-peroneo-calcaneus*) is situated beneath the pre-

\* "Sunt gemelli, quia mole, robore, et actione pares."—Riolanus, l. 5, c. 43.



ceding muscle, in conjunction with which it forms the calf of the leg. It is shorter than that muscle, but it extends farther down, before ending in the common tendon. In form the soleus is elliptic, and the name is said to be taken from the likeness to the shape of a sole-fish. Like the gastrocnemius, it presents superiorly two attachments, though by no means so distinctly separated.

Of these, the external one, the longer and larger, *arises* from the posterior part of the head of the fibula, and from the surface beneath it, for half of its extent; the inner portion *arises* from the oblique line which gives insertion to the popliteus, and from the inner edge of the tibia, two inches below that line; and, in the space intermediate between the bones, the muscular fibres are attached to a tendinous band extended from one to the other, over the posterior tibial vessels, which it secures from pressure or injury. The attachments to the bones are effected by tendinous structure, which expands on the anterior surface of this muscle and enters to some extent into its interior. The muscular fibres, taking origin from the tendinous expansion referred to, are directed backwards to a thin aponeurosis which spreads over the posterior surface; and this aponeurosis, diminishing in breadth and increasing in thickness, joins with that from the gastrocnemius to form the tendo Achillis.—The fibrous structure likewise forms a longitudinal partition, which divides the muscle into two parts towards the lower end.

The soleus is covered by the gastrocnemius, and between the two muscles is placed the slender tendon of the plantaris. It covers the deep-seated muscles, and the posterior tibial vessels and nerve.

The *tendo Achillis*,<sup>6\*</sup> (chorda magna) is much the thickest and strongest tendon in the body. Formed by the junction of the terminal aponeuroses of the two preceding muscles, it measures about six inches in length, and is inserted into the tuberosity of the os calcis. It is expanded at its extremities, and most so at the upper one. The tendon is covered by the fascia and integument; and it is separated from the fascia, which lies over the deep-seated muscle and vessels, by a considerable interval, which is occupied with fat and cellular substance. And between the upper part of the os calcis and the tendon a synovial bursa is interposed.

The gastrocnemius is, in some cases, joined by a bundle, which arises separately from the femur, above one of the condyles. This accessory slip ends variously, either joining the middle of the muscle on its deeper surface, or by blending with one of its heads. I have elsewhere† given illustrations of different forms of this peculiarity. In one of the cases referred to, the unusual muscular fibres passed between the popliteal artery and vein. To the soleus an accessory portion is occasionally added at the lower part of its inner margin. The thick bundle of muscular fibres, added to this muscle, presents some variations in its extent and manner of termination. It usually ends on the inner side of the tendo Achillis. I have found it form a tendon which was attached separately to the os calcis.‡

The *plantaris* is situated immediately behind the knee-joint and leg, between the gastrocnemius and soleus; it consists of a very long thin

\* So named because Achilles was vulnerable only at the heel.

† Op. citat. plate 80, figures 4 and 5.

‡ Ibid.



tendon, and a small pyriform muscular part, about two inches in length. It *arises* from the femur just above the external condyle, and from the posterior ligament of the knee-joint, where it is covered by the corresponding head of the gastrocnemius, and soon ends in a delicate tendon, which inclines inwards between the two large muscles of the calf of the leg, and running along the inner border of the tendo Achillis is inserted conjointly with it into the posterior part of the calcaneum.

The designation by which this little muscle is known has no reference to its position or connexion; but that name was assigned to it when the tendon was thought to terminate in the plantar fascia, as the palmaris longus does in the fascia of the hand. It was so described by Galen; and, though the real manner of termination was correctly pointed out by Vesalius, (*Oper.* l. 2, p. 419,) the error was continued through many valuable works. It exists even in Cowper's "*Myotomia Reformata*" (p. 105).

The plantaris varies in its mode of termination. I have seen it encased in the lower part of the tendo Achillis; and, in one case, the tendon ended in the internal annular ligament, which binds down the tendons and vessels behind the inner malleolus.

*Actions.*—The power of these muscles, as they are exerted successively in standing, walking, running, &c., is very considerable.

In walking, the gastrocnemius and soleus take their fixed point above, and by drawing on the os calcis lift it from the ground, so that the foot is made to represent an inclined plane. By this action an impulse is communicated to the body, and a direct tendency is given to progression. When the body is thus supported on the elevated foot, the opposite limb can be carried forward to its destination unimpeded by the inequalities of the surface over which it has to pass.

In standing, the soleus takes its fixed point at the os calcis, and, by drawing on the bones of the leg, retains them perpendicularly on the foot, thus preventing them from obeying the influence of the weight of the body, which constantly tends to bend them forwards. If this effort be carried as far as it will admit of, the gastrocnemius and popliteus will bend the femur on the tibia, and if at the same time the semi-tendinosus, semi-membranosus and biceps be made to act on the ischium, so as to draw it downwards and backwards, the commencement of that series of muscular actions is made by which the body is retroverted, and carried towards the ground, as we see when a tumbler or mountebank arches his body backwards, the head and heels being brought to the same plane.

#### POSTERIOR TIBIO-FIBULAR REGION (DEEP-SEATED).

The muscles here placed are in close contact with the bones; they are the popliteus, flexor longus digitorum, flexor longus pollicis, and tibialis posticus.

*Dissection.* To expose the deep fascia.—Detach the two heads of the gastrocnemius from the condyles, also the plantaris: then separate the soleus from the tibia and fibula, proceeding from below upwards. When this is done, turn these muscles down towards the foot, and you will find behind and just beneath the knee-joint the popliteus muscle; and you will observe, that this as well as the long muscles, which lie lower down, and the posterior tibial vessels, are bound down by a thin fascia (the deep-seated fascia of the leg). This membrane extends down from the tendon of the semi-membranosus muscle, becoming connected on each side with the borders of the bones, and towards the ankles with the sheaths of the tendons; and, if traced along the interval between the inner ankle and the heel, it will be found to cover the vessels, and to terminate at the internal annular ligament.

To expose the deep-seated muscles.—Pinch up the fascia with your forceps, and detach it from the tendons of the muscles behind the ankle:—taking these as a guide, proceed upwards to the popliteus. In this way the deep-seated set of muscles becomes exposed, (*viz.* the flexor communis, placed along the tibia, the



flexor pollicis on the fibula, and the tibialis posticus between both, and partly concealed by them,) and also the vessels which rest upon them.

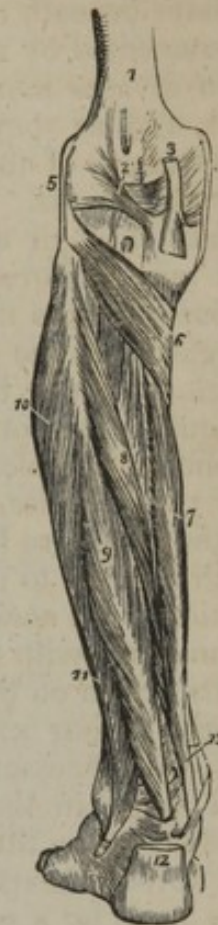The *popliteus* (fig. 201,<sup>6</sup>) is situated immediately behind and beneath the knee-joint, extending from the outer surface of the external condyle of the femur downwards and inwards to the tibia. It is flat and somewhat triangular in its form, for it gradually widens as it descends. The *popliteus* arises by a flat, thick tendon, about an inch in length, from a depression on the outer side of the external condyle, beneath the attachment of the corresponding lateral ligament of the knee-joint, and is inserted into all that triangular surface of the tibia which is above the posterior oblique line.

A tendinous expansion from the semi-membranosus is adherent to the posterior surface of the muscle. It is covered by the gastrocnemius and plantaris, with the popliteal vessels, and the internal popliteal nerve; and it rests against the knee-joint and the tibia.—The tendon by which it is connected to the femur adheres to the external semilunar cartilage, (which sometimes is grooved for it,) and is invested by the synovial membrane of the knee-joint; and it is covered by the external lateral ligament of the knee-joint and by the biceps muscle.

*Actions.*—The *popliteus* assists in flexing the leg on the thigh, and vice versa; but, when the leg is flexed, it draws the inner border of the tibia backwards, turning it in such a way that the toe is inclined towards the foot of the opposite side.

*Flexor longus digitorum pedis* (fig. 201,<sup>7</sup>) (flexor perforans). The long flexor of the toes is one of the muscles deeply seated behind the bones of the leg, from which it is prolonged horizontally into the sole of the foot. It extends from the upper part of the tibia to the phalanges of the toes. The muscle at its commencement is thin and pointed, but gradually increases in size, and then diminishes again as its fibres end in a tendon. Finally, the tendon becomes divided into four slips previously to its insertion. It arises from the posterior surface of the tibia, below the oblique line which gives attachment to the *popliteus* and *soleus*, and continues its attachment to within three inches of the inner ankle; some fibres also arise from an aponeurosis which covers the *tibialis posticus*. The fleshy fibres pass obliquely backwards into a tendon situated at the posterior aspect of the

[Fig. 201.]



The deep layer of muscles of the posterior tibial region.

1. The lower extremity of the femur. 2. The ligamentum posticum Winslowii. 3. The tendon of the semi-membranosus muscle dividing into its three slips. 4. The internal lateral ligament of the knee-joint. 5. The external lateral ligament. 6. The *popliteus* muscle. 7. The *flexor longus digitorum*. 8. The *tibialis posticus*. 9. The *flexor longus pollicis*. 10. The *peroneus longus* muscle. 11. The *peroneus brevis*. 12. The *tendo Achillis* divided near its insertion into the *os calcis*. 13. The tendons of the *tibialis posticus* and *flexor longus digitorum* muscles, just as they are about to pass beneath the internal annular ligament of the ankle; the interval between the latter tendon and the tendon of the *flexor longus pollicis* is occupied by the posterior tibial vessels and nerve.—W.]



muscle. The tendon passes behind the internal malleolus, along a groove common to it and the tibialis posticus (the latter being next to the bone); thence it is directed beneath the arch of the os calcis, obliquely forwards and outwards, into the sole of the foot, where it crosses beneath the tendon of the flexor longus pollicis, with which it is connected by a transverse tendinous slip. The tendon (fig. 203,<sup>2</sup>) then divides into four processes, corresponding with the four smaller toes, and, as they run along their under surface, they, together with the tendons of the short flexor, are bound down to the phalanges by fibrous sheaths. Opposite the middle of the first phalanx, each tendon passes through a fissure in the tendon of the flexor brevis, (whence the term *perforans* is applied to the one, *perforatus* to the other,) and is inserted into the last phalanx of the toe at its base.—To the phalangeal bones the tendons of the flexor muscles of the toes are bound by vaginal fibrous bands, and they are provided with synovial sacs and *vincula accessoria* in the same manner as the tendons of the corresponding muscles of the hand. The arrangement of the tendons of the two muscles, one with respect to the other, and their attachment to the bone, are likewise similar.

Previously to its division, the tendon of the flexor longus gives insertion to an accessory muscular structure (*flexor accessorius*), which connects it with the calcaneum, and materially modifies the direction of its action on the toes. At the point of separation the tendons give origin to four small muscles (*lumbricales*), which may also be considered as accessories to the flexor longus.

Though in the dried bone only one impression is marked for the tendons of the tibialis posticus and flexor longus, behind the malleolus, the fibrous sheath which retains them in their situation is divided into two parts by a septum, or partition, so that each runs in a separate groove lined by a distinct synovial membrane. The direction of the muscle is vertical in the leg, horizontal in the foot.—In the former situation it is bound down by the deep fascia, and covered by the posterior tibial vessels, which separate it from the soleus; and the anterior surface rests against the tibia, and overlaps the tibialis posticus muscle. In the foot its tendon lies between those of the flexor longus pollicis, which is above it, and the flexor brevis digitorum, which lies beneath it.

*Flexor longus pollicis pedis*.—Alb. (fig. 201,<sup>9</sup>).—The long flexor of the great toe is situated on the fibula, along the external side of the leg, and at the under and inner part of the foot. It *arises* from the posterior surface of the fibula (its inferior two-thirds): from the lower part of the interosseous membrane (to a very small extent): from the intermuscular septum interposed between it and the peronei: and from the aponeurosis covering the tibialis posticus. The fleshy fibres, continuing to arise nearly as far as the external ankle, pass obliquely backwards into a tendon placed on their posterior surface. The tendon traverses a groove on the tibia, external to that which transmits the tibialis posticus and flexor digitorum, and passes through another in the posterior border of the astragalus, in which it is retained by a fibrous band and a synovial membrane. It then runs in a groove beneath the tubercle of the os calcis (the *sustentaculum*



tali), and so reaches the sole of the foot, where, after being connected to the common flexor by a tendinous slip, it turns forwards beneath the metatarsal bone of the great toe (fig. 203,<sup>1</sup>). Lastly, the tendon is continued onward between the two heads of the flexor brevis pollicis, and after running through a fibrous sheath, which binds it to the first phalanx of the great toe, is *inserted* into the base of the second.

In the leg this muscle is bound down by the deep fascia which separates it from the soleus; its anterior surface rests on the fibula, and overlaps the tibialis posticus muscle and the peroneal artery. Its connexions in the sole of the foot have already been sufficiently indicated.

The *tibialis posticus* (fig. 201,<sup>2</sup>) (tibio-sub-tarsus) lies between the two preceding muscles, but commences considerably higher up than either. Its superior extremity is divided into two processes, or heads, by an angular interval, and the anterior tibial vessels pass forward between them. It *arises* from the posterior surface of the tibia, beginning along the oblique line of insertion of the popliteus: from the whole of the interosseous membrane, except two inches at the lower end: from the sides of the tibia and fibula for the same extent: and from the aponeurosis which covers the muscle behind. The muscular fibres end in a flat strong tendon, which turns beneath the internal malleolus in a groove of the bone, and in a sheath appropriated to itself. The tendon now changes direction, turning forward along the internal lateral ligament, and beneath the os calcis, to which it is bound by a short transverse fibrous band (which is connected with the tendon and the bone), and likewise beneath the calcaneo-scaphoid ligament, and is *inserted* into the tuberosity of the scaphoid and the base of the first metatarsal bone. Fibres of the tendon are likewise prolonged to the external cuneiform. The tendon is covered by a synovial membrane behind the malleolus, and likewise beneath the tarsus.

In the leg the tibialis posticus is overlapped and concealed in the greater part of its extent by the two flexor muscles, but superiorly the part which is left uncovered by them supports the posterior tibial vessels. The anterior surface rests against the interosseous ligament and the tibia and fibula, from which it arises. Its tendon runs close to the inner ankle and tarsal bones, and where it slides under the latter near its termination is thickened by a cartilaginous or bony deposit within its fibres, analogous in form and use to the sesamoid bones in other situations.

Spigelius named this muscle "*nauticus*," because "sailors bring it chiefly into action in climbing the mast of a ship."—Op. citat. l. iv. c. 24.—The tibialis posticus is said by Albinus to have in some cases additional points of insertion into one or more of the following bones; viz., the second and third metatarsal, the cuboid, and second cuneiform.

*Actions*.—Like their antagonists on the fore part of the leg, the two flexor muscles act, in the first instance, on the phalanges of the toes, which they curve or bend, and then, by continuing their effort, they act on the foot. The latter effect they are enabled to produce by means of the mechanical advantage afforded to them by the pulley-like surface on which they slide as they pass from the leg into the sole of the foot. By this provision the flexor muscles conspire with the soleus and gemellus in extending the foot on the leg, for instance, in the effort to stand on tip-toe.

The direct agent in extending the foot upon the leg is the tibialis posticus; but



from its position it is also enabled to incline the foot inwards, thus antagonizing the peroneus tertius, which tends to turn it outwards. It may also, by elevating the inner border of the foot, turn the sole inwards; which action is directly opposed to that of the peroneus longus, which tends to incline it outwards.

It may be observed, that the toes would, in all cases, be drawn inwards whilst they are being flexed by the flexor communis, in consequence of the oblique direction of its tendon, but for the influence exerted upon it by the accessory muscle, which is connected with it in the sole of the foot. The direction of the latter being from behind forwards, it is well fitted by its contraction to modify the action of the long flexor on the toes, and to draw them towards the heel, where its fixed point of attachment is situated.

The action of these muscles may be reversed; for they may take their fixed points below at the foot, and from thence draw on the bones of the leg, so as to keep them in the erect position and prevent their inclining forwards.

#### MUSCLES OF THE FOOT.

The only muscle on the dorsum of the foot is the extensor brevis digitorum, which has been already described (page 447), together with the extensor longus, as they conspire in their actions; the present section therefore includes only the muscles in the sole of the foot. These may be considered as divisible into three regions, corresponding with the two borders and the intermediate space; the internal set consisting of the muscles of the great toe, the external, those of the little toe, those in the middle being common to all. But, in order to facilitate the examination of the parts contained in the sole of the foot, it is found more convenient to divide them into layers, lying one beneath the other; more particularly as, like the muscles on the back part of the leg, they are found to be separated into a superficial and deep set by a layer of fascia interposed between them and binding down the latter.

*Dissection. To expose the plantar fascia.*—The subject, or the limb, if it be detached, being placed in the prone position, lay the dorsum of the foot on a high block, so as to bring the sole fully into view; secure it in that position. Make an incision from behind forwards in the middle of the sole, beginning over the heel. Cut down through the thick skin and the cushion of granular fat at the heel, until you see the white fibres of the fascia: then taking these as a guide, and everting the margins of the incision, incline your knife and dissect the skin off the fascia from behind forwards. You will observe its middle part to spread out beneath the metatarsus, and to give off five processes, which run along to the extremities of the metatarsal bones: the external portion, which binds down the muscles of the little toe, is thick and firm: but the internal one, which corresponds with the muscles of the great toe, is a thin membrane which appears to be prolonged from the fascia on the dorsum of the foot, and not to be properly an offset of the true plantar fascia (see its description, among other structures of the same kind).

*To expose the first layer of muscles.*—These are three, viz., the abductor pollicis at the inner side, abductor of the little toe at the outer, and the short flexor of the toes in the middle. The abductor pollicis is readily brought into view by raising the thin fascia which covers it, and dissecting it off, beginning over its tendon and thence proceeding backwards. The abductor of the little toe is exposed by raising the outer division of the plantar fascia from its attachment to the fifth metatarsal bone and reflecting it backwards. Now observe that the broad part of the fascia appears as if tucked in at its sides by processes or septa, which separate the middle from the lateral groups of muscles. Insert the knife under the fascia, raise it from the muscles a little, and then cautiously detach it from them, proceeding from before backwards. When severed from the calcaneum, you may carry it forwards, still leaving it attached by its digital processes. By these means you bring into view the short flexor muscle.



*Abductor pollicis pedis* (fig. 202,<sup>3</sup>).—The abductor of the great toe is placed horizontally along the inner side of the sole of the foot. It *arises* from the inner border of the protuberance of the calcaneum, from the internal annular ligament, from the septum between it and the flexor brevis digitorum, and from the superior surface of the plantar fascia. The fleshy fibres end in a tendon, which, after uniting with the external head of the flexor brevis pollicis, is inserted into the inner border of the base of the first phalanx of the great toe.

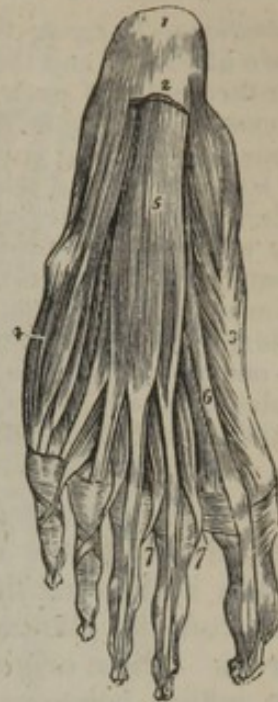The plantar surface of this muscle is covered by the skin and fascia; the superior surface is in contact with the tendinous insertion of the tibialis posticus, with the flexor brevis pollicis, with which it is identified, and with the internal plantar vessels.

*Flexor brevis digitorum*<sup>5</sup> (flexor perforatus).—The short flexor of the toes is placed in the middle of the sole of the foot, in contact with the plantar fascia. It *arises* from the internal or greater tuberosity of the calcaneum: from the plantar fascia:<sup>2</sup> and the intermuscular septa on each side. The muscle soon terminates in four thin tendons corresponding with the four smaller toes; and opposite the extremity of the first phalanx each tendon divides into two fasciculi, so as to leave a fissure for the transmission of the tendon of the flexor longus, after which the fibres unite again into a broad lamella, which is inserted into the under surface of the second phalanx. The manner of its division for the passage of the other flexor tendon, and the mode of connexion with the bones, are strictly analogous to those in the hand. The lower surface of this muscle is in intimate contact with the plantar fascia; the upper with the flexor accessorius, with the tendons of the flexor longus digitorum, the lumbricales, and the plantar vessels.

*Abductor digiti minimi*.<sup>4</sup>—This, the third muscle of the superficial stratum, is placed along the external border of the foot. It *arises* from the external border of the calcaneum, from the under surface of that bone in front of both tubercles, and from the upper surface of the process of the plantar fascia, which extends from the external tubercle to the base of the fifth metatarsal bone. The fleshy fibres end in a tendon, which, after sliding along a smooth impression on the inferior surface of the head of the fifth metatarsal bone, is *inserted* into the external surface of the base of the first phalanx of the little toe.

This muscle is covered by the plantar fascia. Its upper surface

[Fig. 202.]



The first layer of muscles in the sole of the foot; this layer is exposed by the removal of the plantar fascia. 1. The os calcis. 2. The posterior part of the plantar fascia divided transversely. 3. The abductor pollicis. 4. The abductor digiti minimi. 5. The flexor brevis digitorum. 6. The tendon of the flexor longus pollicis muscle. 7, 7. The lumbricales. On the second and third toes, the tendons of the flexor longus digitorum are seen passing through the bifurcation of the tendons of the flexor brevis digitorum.—W.]



is in contact with the external head of the flexor accessorius, the ligamentum longum plantæ, and the flexor brevis digiti minimi.

*Dissection.*—To expose the second layer of plantar muscles (fig. 203). Separate the two abductors and the short flexor from the calcaneum by inserting the knife under the border of each successively, and cutting obliquely backwards close to the bone. Then draw them forwards, leaving them still attached by their insertions, in order that you may restore them to their original positions, and inspect their attachments and relations again.

When these muscles are removed, a thin lamella (*deep plantar fascia*) of membrane will be observed, extending across from one side of the foot to the other, separating the first from the second layer of muscles, consisting of the tendons of the flexor longus pollicis, those of the flexor communis, and its accessories, viz., the flexor accessorius and lumbricales. The long tendons will be observed to cross one another at an acute angle, that of the flexor pollicis inclining inwards, and placed on a plane superior to the tendon of the flexor communis, whose direction is obliquely outwards, as if towards the base of the fifth metatarsal bone.

The *flexor accessorius* is divided posteriorly into two heads (fig. 203,<sup>3</sup>), of which the internal, or larger one, *arises* from the inner or concave surface of the calcaneum; the external, flat and tendinous, arises from the plantar surface of that bone, a little before its external tubercle. These origins unite at an acute angle, and form a flat fleshy mass, which becomes united to the external border, as well as to the upper surface, and slightly also to the lower surface of the tendon of the flexor longus, at its point of division. It may be observed, that the fibres of the accessory muscle, where they enclose the tendon of the long flexor, are tendinous, and so arranged as to form a groove, within which it is lodged.

The flexor accessorius is the "moles carnea" of Sylvius.\*

The *lumbricales* (fig. 203,<sup>4</sup>) are four small tapering muscles, in form like worms, whence their name is derived; they *arise* from the tendons of the flexor communis digitorum, at their point of division; from which they pass forwards to the inner side of each of the lesser toes, where each becomes a thin tendon, which is *inserted* into the base of the first phalanx at its inner border, and also becomes united to the tendinous expansions of the extensor muscles on the dorsal surface of the phalanges.

These little muscles are less distinct than those of the hand. They are liable to the same variations of arrangement.

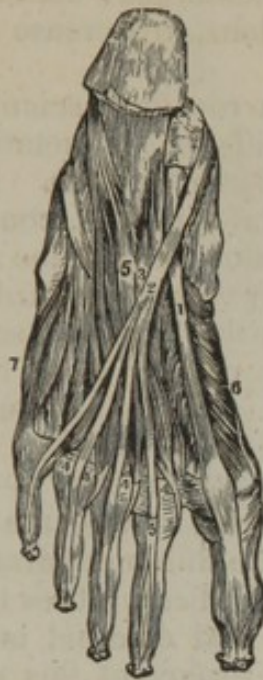*Dissection.*—Cut the flexor tendons across, detach the flexor accessorius from its origin, and draw them forwards or over the sides of the foot. When these muscles are removed, the third layer is exposed, filling up the deep irregular part of the sole of the foot.

*Flexor brevis pollicis pedis* (fig. 204,<sup>5</sup>).—The short flexor of the great toe is single and pointed behind, but divided into two parts or heads in front. It *arises* by a flat tendinous process, which extends along the greater part of its upper surface, from the inner border of the cuboid bone, slightly from the contiguous margin of the external cuneiform bone, and from the tendinous band sent to that bone from the tendon of the tibialis posticus. These origins can be best per-

\* "In Hippocratis et Galeni Physiologiæ partem Anatomicam Isagoge a Jacobo Sylvio."  
—Cap. vii. Venet. 1556.



Fig. 203.



[Fig. 204.]

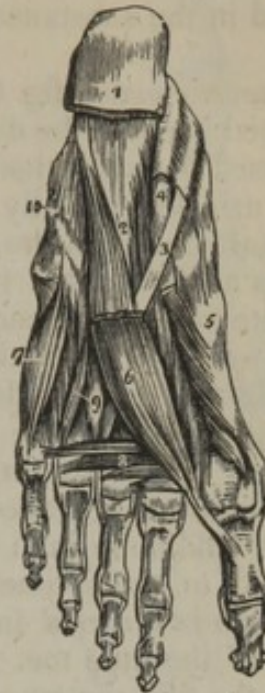

Fig. 203. Deep-seated muscles in the sole of the foot. 1. Tendon of the flexor longus pollicis. 2. Tendon of the flexor communis digitorum pedis. 3. Flexor accessorius. 4, 4. Lumbricales. 5. Flexor brevis digitorum. 6. Flexor brevis pollicis pedis. 7. Flexor brevis minimi digiti pedis.

[Fig. 204. The third and a part of the second layer of muscles of the sole of the foot. 1. The divided edge of the plantar fascia. 2. The musculus accessorius. 3. The tendon of the flexor longus digitorum. 4. The tendon of the flexor longus pollicis. 5. The flexor brevis pollicis. 6. The adductor pollicis. 7. The flexor brevis minimi digiti. 8. The transversus pedis. 9. Interossei muscles, plantar and dorsal. 10. Convex ridge formed by the tendon of the peroneus longus muscle in its oblique course across the foot.—W.]

ceived when the muscle is cut across and detached carefully from before backwards. The fleshy mass divides into two parts, which are inserted, one into the inner, the other into the external border of the base of the first phalanx of the great toe; each head is also intimately connected with one of the sesamoid bones beneath the articulation. Moreover, before reaching its points of insertion, an intimate union is established between this muscle and the abductor pollicis on the one side, and adductor on the other. The tendon of the flexor longus runs along the interval between the heads of the short flexor.

*Adductor pollicis pedis* (fig. 204,<sup>6</sup>).—The adductor of the great toe is situated obliquely in the sole of the foot, forming a short, thick, fleshy mass. It arises from the cuboid bone, from the tarsal extremity of the third and fourth metatarsal bones, also from the sheath of the peroneus longus muscle,<sup>10</sup> and is directed obliquely inwards to be inserted, conjointly with the external head of the flexor brevis pollicis, into the base of the first phalanx of the great toe.

The adductor of the great toe and its short flexor are thus found to be intimately united at their insertion, and if they be cut across about an inch behind the first joint, and reflected forwards, two small sesamoid bones will be found connected with their tendons, just as the patella is with the extensor tendon of the knee-joint. Like the patella,



one of their surfaces is smooth, and enters into the composition of the articulation, being lined by the synovial membrane; and, like it, they are developed in the substance of the tendons, to increase their power of action.

The *transversus pedis* (fig. 204,<sup>8</sup>) is a narrow flat fasciculus of fleshy fibres, stretched beneath the digital extremities of the metatarsal bones, being interposed between them and the flexor tendons. Its external extremity is attached usually to the lateral ligament, connecting the fifth metatarsal bone with the first phalanx of the little toe; sometimes it commences at the fourth: it passes from without inwards, its fibres being connected with the heads of the fourth, third, and second metatarsal bones, or rather with the ligaments passing from them to the phalanges. It thus reaches the ball of the great toe, where it becomes blended with the fibres of the adductor pollicis.

*Flexor brevis digiti minimi pedis* (fig. 203,<sup>7</sup>; 204,<sup>7</sup>).—The short flexor of the little toe is placed at the external side of the sole of the foot; it arises tendinous from the base of the fifth metatarsal bone, and from the sheath of the peroneus longus; the fleshy fibres terminate in a tendon, which is inserted into the base and external border of the first phalanx of the little toe. The upper surface of this muscle is in contact with the fifth metatarsal bone; the inferior is covered partly by the abductor digiti minimi, partly by the plantar fascia.

The *interosseous* muscles (*interossei*), as their name implies, are placed between the metatarsal bones, filling up the intervening spaces. There are seven in all, and they are divided into two sets, which differ from one another in their position and arrangement. On the *dorsal* aspect of the metatarsus four of the muscles are perceptible, and they are named from this circumstance. The other set exists only on the *plantar* surface, and they are named accordingly. The seven interosseous muscles are distinguished numerically from within outwards, like the spaces which they occupy.

a. The *dorsal interosseous* muscles (fig. 205) closely resemble one another in appearance, structure, and attachment. Their fibres arise from the contiguous surfaces of the bones between which they are placed, and pass obliquely forwards to a slight tendon that runs along the centre of each, so that they form a penniform muscle. Their posterior extremities are bifid, leaving angular intervals occupied by the perforating branches, which pass from the plantar to the dorsal arteries. These muscles dip down into the sole of the foot, where the plantar series are altogether placed; hence it is that, in this latter situation, their appearance and arrangement are somewhat complicated (fig. 204).

The first *two* dorsal interosseous muscles belong to the second toe, being inserted, the one (fig. 205,<sup>1</sup>) into the internal, the other<sup>2</sup> into the external side of its first phalanx, and into the margins of the extensor tendon as it expands upon its dorsal surface. The dorsal artery of the foot passes in the angular interval at the posterior end of the first, in its course downwards to join the plantar artery.—The *third* dorsal muscle<sup>3</sup> is inserted into the external side of the first phalanx of the third toe.—And the *fourth*<sup>4</sup> terminates in like manner on the first phalanx of the fourth toe.



Fig. 205.

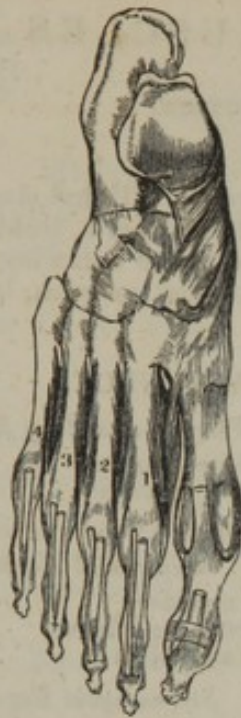

Fig. 206.

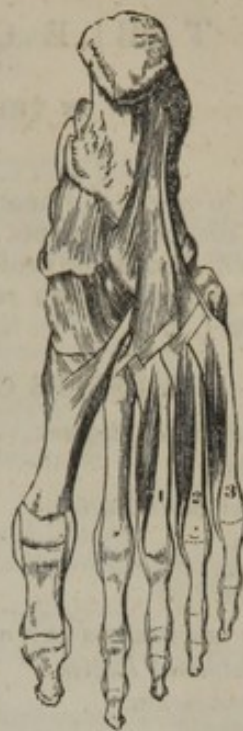

Fig. 205. The bones of the foot, with the dorsal interossei muscles, seen from above.

Fig. 206. The bones and ligaments of the foot seen on the plantar aspect, with the plantar interossei muscles.

*b.* The *plantar interossei* muscles are not, strictly speaking, situated between the metatarsal bones; they are placed rather beneath the third, fourth, and fifth metatarsal bones, inclining somewhat towards their inner border. These are single muscles, and are connected each with but one metatarsal bone.

The *first* plantar interosseous muscle (fig. 206,<sup>1</sup>) arises along the inner border of the third metatarsal bone. The fleshy fibres end in a tendon, which is inserted into the base of the first phalanx of the same (third) toe, becoming blended with the tendinous expansion of the *extensor communis*.

The *second* plantar interosseous muscle<sup>2</sup> arises from the inner side of the fourth metatarsal bone, and is inserted into the inner border of the first phalanx of the corresponding toe and the *extensor tendon*.

The *third* plantar interosseous muscle<sup>3</sup> arises from the inner side of the fifth metatarsal bone, and is inserted into the base of the first phalanx of the little toe and the *extensor tendon*.

—From the foregoing description it results, that the interosseous muscles now examined correspond with those of the hand, with the exception that, while the latter are so disposed as to abduct the fingers from, or adduct them towards, a line running through the *middle of the middle finger*, the dorsal muscles of the foot are calculated to move the toes from the *middle of the second toe*, and the plantar series incline them towards that point.—The dorsal muscles, therefore, increase the breadth of the foot, and the plantar muscles lessen it or restore the toes to the position from which they are removed by the former.



## TABLE OF THE MUSCLES

IN THE ORDER OF DISSECTION.

The student to whom the head and neck are allotted, will find sixty-six muscles at each side, disposed in sets or groups in particular parts, technically termed regions. He will find it convenient to dissect them in the following order. When a muscle forms part of two regions, it is enumerated in each, but is included within brackets ( ).

## MUSCLES OF THE HEAD AND NECK.

*Epicranial Region.*

Occipito-frontalis.

*Auricular Region.*

Attollens aurem.

Retrahens aurem.

Attrahens aurem.

## MUSCLES OF THE EYELIDS AND ORBIT.

*Palpebral Region.*

Orbicularis palpebrarum.

Corrugator supercilii.

(Levator palpebræ.)

(Tensor tarsi.)

*Orbital Region.*

Rectus superior.

" inferior.

" internus.

" externus.

Obliquus superior.

" inferior.

Levator palpebræ.

Tensor tarsi.

## MUSCLES OF THE FACE.

*Nasal Region.*

Pyramidalis nasi.

Compressor narium.

Levator labii superioris alæque nasi.

Depressor alæ nasi.

Levator prop. alæ nasi posterior.

" " " " anterior.

*Superior Maxillary Region.*

Levator labii superioris.

" anguli oris.

Zygomaticus major.

" minor.

*Inferior Maxillary Region.*

Triangularis oris.

Depressor labii inferioris.

Levator labii inferioris.

*Inter-maxillary Region.*

Buccinator.

Risorius.

Orbicularis.

Naso-labialis.

*Temporo-maxillary Region.*

Masseter.

Temporalis.

*Pterygo-maxillary Region.*

Pterygoideus internus.

" externus.

## MUSCLES OF THE NECK.

*Superficial Region.*

Platysma myoides.

Sterno-cleido-mastoideus.

(Rectus sternalis.)

*Sterno-hyoid Region.*

Sterno-hyoideus.

Sterno-thyroideus.

Thyro-hyoideus.

Crico-thyroideus.

Omo-hyoideus.

*Sub-maxillary Region.*

Digastricus.

Stylo-hyoideus.

" " alter.

Stylo-glossus.

Stylo-pharyngeus.

*Genio-hyoid Region.*

Mylo-hyoideus.

Genio-hyoideus.

Hyo-glossus.

Genio-hyo-glossus.

Lingualis, and other muscles of the tongue.

*Muscles of the Pharynx.*

Constrictor inferior.

" medius.

" superior.

(Salpingo-pharyngeus.)

(Stylo-pharyngeus.)

(Palato-pharyngeus.)

*Muscles of the Soft Palate.*

Levator palati.

Circumflexus palati.

Azygos uvulæ.

Palato-glossus.

(Palato-pharyngeus.)

*Muscles of the Larynx.*

(Crico-thyroideus.)

Crico-arytænoideus posticus.

Crico-arytænoideus lateralis.

Thyro-arytænoideus.

Arytænoideus.

Arytæno-epiglottideus.

Thyro-epiglottideus.



*Vertebral Region, lateral.*  
 Scalenus anticus.  
 " medius.  
 " posticus.  
 " minimus.  
 " lateralis.

*Vertebral Region, anterior.*  
 Rectus capitis anticus major.  
 " " minor.  
 Rectus lateralis.  
 Longus colli.

### MUSCLES OF THE UPPER EXTREMITY

There are fifty-three muscles in each limb (including the pectorales, subclavius, and serratus), which may be examined one after another, in the order here set down.

*Anterior Thoracic Region.*  
 Pectoralis major.  
 " minor.  
 Subclavius.  
 (Rectus sternalis.)

*Lateral Thoracic Region.*  
 Serratus magnus.

#### MUSCLES OF THE SHOULDER.

*Acromial Region.*  
 Deltoideus.  
*Scapular Region, posterior.*  
 Supra-spinatus.  
 Infra-spinatus.  
 Teres minor.  
 " major.

*Scapular Region, anterior.*  
 Sub-scapularis.

#### MUSCLES OF THE ARM.

*Humeral Region.*  
 Coraco-brachialis.  
 Biceps flexor cubiti.  
 Brachialis anticus.  
 Triceps extensor cubiti.  
 Sub-anconeus.

#### MUSCLES OF THE FORE-ARM.

*Brachial Region, inner and anterior.*  
 Pronator radii teres.  
 Flexor carpi radialis.  
 Palmaris longus.

Flexor carpi ulnaris.  
 " digitorum sublimis.  
 " " profundus.  
 (Lumbricales.)  
 Flexor pollicis longus.  
 Pronator quadratus.

*Radial Region.*  
 Supinator radii longus.  
 Extensor carpi radialis longior.  
 " " brevior.  
 Supinator radii brevis.

*Brachial Region, posterior.*  
 Anconeus.  
 Extensor digitorum communis.  
 " minimi digiti.  
 " carpi ulnaris.  
 " ossis metacarpi pollicis.  
 " primi internodii pollicis.  
 " secundi internodii pollicis.  
 " indicis.

#### MUSCLES OF THE HAND.

*Palmar Region.*  
 Abductor pollicis.  
 Opponens pollicis.  
 Flexor brevis pollicis.  
 Adductor pollicis.  
 Palmaris brevis.  
 Abductor digiti minimi.  
 Flexor brevis digiti minimi.  
 Adductor digiti minimi.  
 Lumbricales.  
 Interossei.

### MUSCLES OF THE TRUNK.

Omitting the pectorales, subclavius, and serratus magnus, which are usually taken with the upper extremity, we find in the trunk of the body ninety muscles at each side, together with the diaphragm and levator ani, which are single.

#### MUSCLES OF THE ABDOMEN.

*Abdominal Region.*  
 Obliquus externus abdominis.  
 " internus.  
 Cremaster.  
 Transversalis.  
 Rectus abdominis.  
 Pyramidalis.  
 Quadratus lumborum.

#### MUSCLES OF THE THORAX.

*Anterior Thoracic Region.*  
 (Pectoralis major.)

(Pectoralis minor.)  
 (Subclavius.)

*Lateral Thoracic Region.*  
 (Serratus magnus.)

*Costal Region.*  
 Inter-costales [externi, interni.]  
 Infra-costales.  
 Levatores costarum.  
 Triangularis sterni.  
 Diaphragma.



## MUSCLES OF THE PELVIS AND PERINEUM.

*Iliac Region.*

Psoas magnus.

" parvus.

Iliacus.

*Perineal Region.*

Sphincter ani.

Transversus perinæi.

Accelerator urinæ.

Erector penis.

Levator ani.

Coccygeus.

Compressor urethræ.

(Erector clitoridis.

(Constrictor vaginæ.)

## MUSCLES OF THE BACK.

These are arranged in layers.

*Dorsal Region.*

1. Trapezius.

Latissimus dorsi.

2. Levator anguli scapulæ.

Rhomboides minor.

" major.

3. Serratus posticus superior.

" " inferior.

Splenius colli.

" capitis.

4. Erector spinæ.

Sacro-lumbalis.

Cervicalis descendens.

Accessorius ad sacro-lumbalem.

Longissimus dorsi.

Transversalis cervicis.

Trachelo-mastoideus.

Spinalis dorsi.

" cervicis.

Complexus.

Biventer cervicis.

5. Semi-spinalis dorsi.

Semi-spinalis colli.

Inter-spinales.

Inter-transversales.

Inter-accessorii.

Multifidus spinæ.

Rotatores spinæ.

Extensores coccygis.

(Levatores costarum.)

Rectus capitis posticus major.

" " minor.

Obliquus capitis superior.

" " inferior.

## MUSCLES OF THE LOWER EXTREMITY.

In each limb there are fifty-six muscles, which may be dissected in the following order.

## MUSCLES OF THE THIGH.

*Femoral Region, anterior.*

Tensor vaginæ femoris.

Sartorius.

Rectus.

Crureus.

Sub-crureus.

Vastus externus.

" internus.

*Femoral Region, internal.*

Gracilis.

Pectineus.

Adductor longus.

" brevis.

" magnus.

*Gluteal Region, superficial.*

Gluteus maximus.

" medius.

" minimus.

*Gluteal Region, deep-seated.*

Pyriformis.

Gemellus superior.

Obturator internus.

Gemellus inferior.

Quadratus femoris.

Obturator externus.

*Femoral Region, posterior.*

Biceps femoris.

Semi-tendinosus.

Semi-membranosus.

## MUSCLES OF THE LEG.

*Tibio-fibular Region, anterior.*

Tibialis anticus.

Extensor pollicis.

" digitorum longus.

Peroneus tertius.

(Extensor digitorum brevis.)

Peroneus longus.

" brevis.

*Tibio-fibular Region, posterior superficial.*

Gastrocnemius.

Plantaris.

Soleus.

*Deep-seated.*

Popliteus.

Flexor longus digitorum pedis.

" " pollicis pedis.

Tibialis posticus.

## MUSCLES OF THE FOOT.

*Dorsal Region.*

Extensor digitorum brevis.

*Plantar Region.*

Abductor pollicis.

Flexor brevis digitorum.

Abductor digiti minimi.

Flexor accessorius.

Lumbricales.

Flexor brevis pollicis.

Adductor pollicis.

Flexor brevis digiti minimi.

Transversus pedis.

Interossei.



## TABLE OF THE MUSCLES,

ARRANGED AFTER THE MANNER OF DR. BARCLAY, ACCORDING TO  
THEIR ACTIONS.

## THE HEAD IS MOVED

<i>Forwards by</i>	<i>Backwards by</i>	<i>To either side by</i>
Platysma myoides, Sterno-mastoideus, Rectus anticus major, "    "    minor, <i>Assisted (when the lower jaw     is fixed) by</i> Mylo-hyoideus, Genio-hyoideus, Genio-hyo-glossus, Digastrici.	Part of trapezius, Splenius capitis, Complexus, Trachelo-mastoideus, Rectus posticus major, "    "    minor, Obliquus capitis superior.	Platysma myoides, Sterno-mastoideus, Part of trapezius, Splenius capitis, "    colli, Trachelo-mastoideus, Complexus.

## THE NECK IS MOVED

<i>Forwards by</i>	<i>Backwards by</i>	<i>Laterally by</i>
Platysma myoides, Sterno-mastoideus, Digastricus, Mylo-hyoideus, Genio-hyoideus, Genio-hyo-glossus, Omo-hyoidei, Sterno-hyoidei, Thyro-hyoidei, Rectus anticus minor, Longus colli.	Part of trapezius, Rhomboideus minor, Serratus posticus superior, Splenius capitis, "    colli, Complexus, Trachelo-mastoideus, Transversalis colli, Inter-spinales colli, Semi-spinales colli, Rectus posticus major, "    "    minor, Obliquus capitis superior, "    "    inferior, Scaleni postici, Levator scapulæ.	Various combinations of those muscles which sepa- rately move it forwards and backwards, assisted by the scaleni, intertransversales, and recti laterales.

## THE TRUNK IS MOVED

<i>Forwards by</i>	<i>Backwards by</i>	<i>Laterally by</i>
Rectus abdominis, Pyramidalis, Obliquus externus abdo- minis. Obliquus internus, Psoas magnus, "    parvus, <i>Assisted (when the arms are     carried forwards) by</i> Pectoralis major, "    minor, Serratus magnus.	Trapezius, Rhomboideus major, Latissimus dorsi, Serratus posticus superior, "    "    inferior, Sacro-lumbalis, Longissimus dorsi, Spinales dorsi, Semi-spinales dorsi, Multifidus spinæ, Inter-transversales dorsi et lumborum.	Obliquus externus, "    internus, Quadratus lumborum, Longissimus dorsi, Sacro-lumbalis, Serrati postici, Latissimus dorsi.

## THE SCAPULA IS MOVED

<i>Upwards by</i>	<i>Downwards by</i>	<i>Forwards by</i>	<i>Backwards by</i>
Trapezius, Levator scapulæ, Rhomboidei.	Lower part of trape- zium, Latissimus dorsi, Pectoralis minor.	Pectoralis minor, Serratus magnus.	Part of trapezius, Rhomboidei, Latissimus dorsi.



## THE HUMERUS IS MOVED

<i>Forwards by</i>	<i>Backwards by</i>	<i>Inwards by</i>	<i>Rotated inwards by</i>
Part of deltoid, Part of pectoralis major, <i>Assisted in some cir- cumstances by</i> Biceps, Coraco-brachialis.	Part of deltoid, Teres major, " minor, Long head of triceps, Latissimus dorsi.	Part of pectoralis major, Latissimus dorsi.	Subscapularis,  <i>Assisted occasionally by</i> Pectoralis major, Latissimus and teres major.  <i>Outwards by</i> Supra-spinatus, Infra-spinatus, Teres minor.

## THE FORE-ARM IS MOVED

<i>Forwards by</i>	<i>Backwards by</i>	<i>Rotated inwards by</i>
Biceps, Brachialis anticus, Pronator teres,  <i>Assisted by</i> Flexor carpi radialis, " sublimis, " ulnaris, Supinator longus.	Triceps, Anconeus.	Pronator teres, Flexor carpi radialis, Palmaris longus, Flexor sublimis, Pronator quadratus.  <i>Outwards by</i> Biceps, Supinator brevis, Extensor secundi in- ternodii.

## THE CARPUS IS MOVED

<i>Forwards by</i>	<i>Backwards by</i>	<i>Outwards by</i>	<i>Inwards by</i>
Flexor carpi radialis, Palmaris longus, Flexor sublimis, " carpi ulnaris, " profundus, " longus pollicis.	Extensor carpi radi- alis longior, Extensor carpi radi- alis brevior, Extensor secundi in- ternodii, Indicator, Extensor communis digitorum, Extensor proprius pollicis.	Flexor carpi radialis, Extensor carpi radi- alis longior, Extensor carpi radi- alis brevior, Extensor ossis meta- carpi, Extensor primi inter- nodii.	Flexor sublimis, " carpi ulnaris, " profundus, Extensor communis digitorum, Extensor minimi di- giti, Extensor carpi ul- naris.

## THE THUMB IS MOVED

<i>Inwards and for- wards, across the palm, by</i>	<i>Outwards and back- wards by</i>	<i>Upwards and for- wards, away from the other fingers, by</i>	<i>Backwards and in- wards, to the other fingers, by</i>
Opponens pollicis, Flexor brevis, " longus.	Extensor ossis meta- carpi pollicis, Extensor primi inter- nodii, Extensor secundi in- ternodii.	Abductor,  <i>Assisted by part of the</i> Flexor brevis.	Adductor, Extensor primi inter- nodii, Extensor secundi in- ternodii.

## THE FINGERS ARE MOVED

<i>Forwards, or flexed, by</i>	<i>Backwards, or ex- tended, by</i>	<i>Outwards, to radial border, by</i>	<i>Inwards by</i>
Flexor sublimis, " profundus, Lumbricales, Interossei, Flexor brevis digiti minimi, Abductor digiti mi- nimi.	Extensor communis, " minimi digiti. Indicator.	Abductor indicis, " digiti minimi, Interossei.	Abductor digiti mi- nimi, Interossei.



## THE THIGH IS MOVED

<i>Forwards by</i>	<i>Backwards by</i>	<i>Inwards by</i>	<i>Outwards by</i>
Psoas magnus, Iliacus, Tensor vaginæ femo- ris, Pectineus, Adductor longus, " brevis.	Gluteus maximus, Part of gluteus me- dius, Pyriformis, Obturator internus, Part of adductor mag- nus, Long head of biceps, Semi-tendinosus, Semi-membranosus.	Psoas magnus, Iliacus, Pectineus, Gracilis, Adductor longus, " brevis, " magnus, Obturator externus, Quadratus femoris.	Tensor vaginæ femo- ris, Gluteus maximus, " medius, " minimus, Pyriformis.

## THE THIGH IS ROTATED

<i>Inwards by</i>	<i>Outwards by</i>
Tensor vaginæ femo- ris, Part of gluteus me- dius, <i>And, when the leg is extended, by</i> Sartorius, Semi-tendinosus.	Gluteus maximus, Part of gluteus medius. Pyriformis, Gemellus superior, Obturator internus, Gemellus inferior, Quadratus femoris, Obturator externus, Psoas magnus, Iliacus, Adductor longus, " brevis, " magnus, Biceps cruris, slightly.

## THE LEG IS MOVED

<i>Backwards, or flexed, by</i>	<i>Extended by</i>
Semi-tendinosus, Biceps, Semi-membranosus, Gracilis, Sartorius, Popliteus.	Rectus, Crureus, Vastus externus, " internus.

## THE FOOT IS MOVED

<i>Forwards, or flexed, by</i>	<i>Backwards, or extend- ed, by</i>	<i>Inclined inwards by</i>	<i>Outwards by</i>
Tibialis anticus, Extensor proprius pollicis, Extensor longus digi- torum, Peroneus tertius.	Gastrocnemius, Plantaris, Soleus, Flexor longus digi- torum, Flexor longus pollicis, Tibialis posticus, Peroneus longus, " brevis.	Extensor proprius pollicis, Flexor longus digi- torum, Flexor longus pollicis, Tibialis posticus.	Peroneus longus, " brevis, Extensor longus digi- torum, Peroneus tertius.

## THE TOES ARE MOVED

<i>Backwards, or flexed, by</i>	<i>Forwards, or extend- ed, by</i>	<i>Inclined inwards by</i>	<i>Outwards by</i>
Abductor pollicis, Flexor brevis digi- torum, Abductor minimi di- giti, Flexor longus pollicis, " digitorum, " accessorius, Lumbricales, Flexor brevis pollicis, Adductor pollicis, Flexor brevis minimi digiti, Interossei.	Extensor longus digi- torum, Extensor proprius pollicis, Extensor brevis digi- torum.	Abductor pollicis, Interossei.	Adductor pollicis, " digiti minimi, Interossei.



# ANGIOLOGY.

---

## ORGANS OF CIRCULATION.

THE heart or central organ of the circulation, the membranous sac or pericardium in which it is enclosed, as well as the lungs, the pleuræ, and several other parts, are lodged in the chest or thorax, which will be first briefly described.

### THE THORAX.

The thorax resembles a truncated cone, somewhat flattened before and behind, so that its greatest width is transverse. Its narrow truncated apex is above, and its broader base below.

The walls of the thorax are formed in front by the sternum and the costal cartilages, together with the muscles attached to those parts; at the sides by the ribs and intercostal muscles, and behind by the ribs and the dorsal portion of the vertebral column.

The upper opening of the thorax is bounded at each side by the first rib, in front by the top of the sternum, and behind by the first dorsal vertebra: the diameter of this aperture from side to side is longer than from before backwards; its plane slants backwards and upwards; and through it pass many parts: viz., commencing from the front, the sterno-hyoid and sterno-thyroid muscles, the trachea, œsophagus, and thoracic duct, and the longi colli muscles; on each side are the great arteries and veins of the head, neck, and upper limbs, together with the pneumogastric, sympathetic, and phrenic nerves. The summit of each lung, together with the upper end of its containing sac or pleura, also mounts a short distance through this aperture of the thorax, above the level of the first rib.

The lower opening or base of the thorax is bounded in front by the ensiform cartilage, behind by the last dorsal and first lumbar vertebrae, and at the sides by the last six ribs; its plane is also oblique in its direction, but, contrary to that of the upper opening, it is inclined backwards and downwards, so that the cavity of the thorax reaches lower down, and is of greater vertical extent behind than in front. The diaphragm, which is attached to and closes the base of the thorax, forms a convex floor, which is alternately elevated and depressed in the acts of expiration and inspiration. On the right side the diaphragm rises higher than on the left, so that the thoracic cavity is not so deep on that side of the chest.



In the natural condition, the thorax is divided into two lateral cavities or chambers, which contain the right and left lungs. Each of these compartments is lined throughout by a serous membrane, named the pleura, which forms a distinct shut sac, and, besides investing the lung, is reflected, near the middle line, from the front to the back of the thorax. The partition formed by the two pleuræ, named generally the *mediastinum*, extends from the summit to the base of the cavity, and from the sternum back to the spine, inclining somewhat to the left side below: between its two layers, which are separated a considerable distance from each other, are lodged the heart and the great blood-vessels, enclosed in the sac of the pericardium, and, besides this, several other parts. The two layers of the mediastinum separate from one another in approaching the sternum in front and the vertebræ behind, and the intervals between them in these situations are called respectively the cavities of the *anterior and posterior mediastinum*. Between the layers of the anterior mediastinum are found the triangulares sterni muscles, and the remains of the thymus gland; and in the cavity of the posterior mediastinum, behind the pericardium, are situated the trachea, the œsophagus, the thoracic duct, the descending aorta, the vena azygos, and the pneumogastric and splanchnic nerves, with lymphatics and cellular tissue.

The heart, great vessels, and pericardium are seated behind the sternum and costal cartilages, occupying a region of about four inches in width, extending from the second intercostal space on the right side to the fifth space on the left, and reaching further on the left than on the right of the middle line. The principal part of the remainder of the thoracic cavity is occupied by the lungs.

On striking the walls of the chest, the difference between the sounds emitted by the spongy lung and by the compact mass of the heart, enables us to determine by the ear the relative situation of those organs during life; and the height to which the liver ascends beneath the ribs may be ascertained in a similar manner. In cases of thoracic disease, percussion, in addition to auscultation, is also an invaluable means of diagnosis; and, in order to give precision to the employment of both methods, the healthy physical signs have been minutely described over many different regions of the chest, which are artificially distinguished by writers on these subjects.\*

#### THE PERICARDIUM.

The *pericardium* (περι, and καρ, the heart) is a membranous sac, which encloses the heart and the commencement of the large vessels connected with that organ.

It is of a conical shape, its base being attached below to the upper surface of the diaphragm, whilst the apex surrounds the great vessels springing from the base of the heart, as high as their first subdivisions. The heart itself, being attached only at its base, which is placed upwards, is thus suspended freely in the pericardiac cavity.

The pericardium is situated behind the sternum and the cartilages of the fourth, fifth, sixth, and seventh ribs of the left side. The lower

\* See the different works on auscultation, also a paper by Mr. Sibson, "On the Changes induced in the situation, &c. of Organs in Health and Disease," Transact. Prov. Med. and Surg. Association, 1844.



part of the front of the sac is connected, by means of cellular tissue, with the sternum, but higher up it recedes from that bone, and is covered by the remains of the thymus gland. Behind, it is in contact with the bronchi, œsophagus, and descending aorta. On the sides it is covered by the reflected layers of the right and left pleuræ, which separate it from the lungs. Below, it rests on and is attached to the central aponeurosis or cordiform tendon of the diaphragm, and extends further to the left side, encroaching on the muscular portion on that side.

The pericardium is a fibro-serous structure, composed of two membranous layers, one external and fibrous, the other internal and serous.

The *fibrous* layer enters into the formation of the free portion or sac of the pericardium, but is not reflected on to the heart. It is a dense, thick, and unyielding membrane, consisting of fibres which interlace in every direction. At the base of the pericardium these fibres are blended with those of the central aponeurosis of the diaphragm; and above, where the pericardium embraces the large blood-vessels, the fibrous layer is continued on to them in the form of tubular prolongations, which become gradually lost upon their external coats. The superior vena cava, the four pulmonary veins, the aorta, and the right and left divisions of the pulmonary artery, in all eight vessels, receive prolongations of this kind.

The internal or *serous* layer is of much greater extent than the fibrous membrane, for, representing a shut sac, part of which is inverted or thrust into itself, it not only lines the inner surface of the fibrous layer, and the part of the diaphragm to which that layer is attached, but is also reflected upon the commencement of the great vessels and surface of the heart. It has, therefore, a visceral and a parietal portion. The latter of these adheres firmly by its outer surface to the fibrous membrane, and becomes continuous with the visceral portion, upon the arch of the aorta and other great vessels, about two or two and a half inches from the base of the heart. In passing round the aorta and pulmonary artery, it encloses both those vessels in a single sheath. It is reflected also upon the superior cava, and on the four pulmonary veins, and forms a deep cul-de-sac between the entrance of the last-named vessels into the left auricle. The inferior cava receives but a very scanty covering of this coat, inasmuch as that vessel enters the right auricle almost immediately after passing through the diaphragm.

The inner surface of the serous layer, which is free and smooth, is moistened with a small quantity of a thin fluid, which facilitates the movements of the heart within its enclosing sac. The use of the pericardium is evidently to suspend the heart in its place, to insulate it from other parts, and to facilitate its movements.

Cases of congenital absence of the pericardium have sometimes been met with; the heart, in these cases, lies with the left lung in the cavity of the left pleura, and receives its serous covering from that membrane.

#### THE HEART.

The heart [cor] lies between the lungs, enclosed in the sac of the

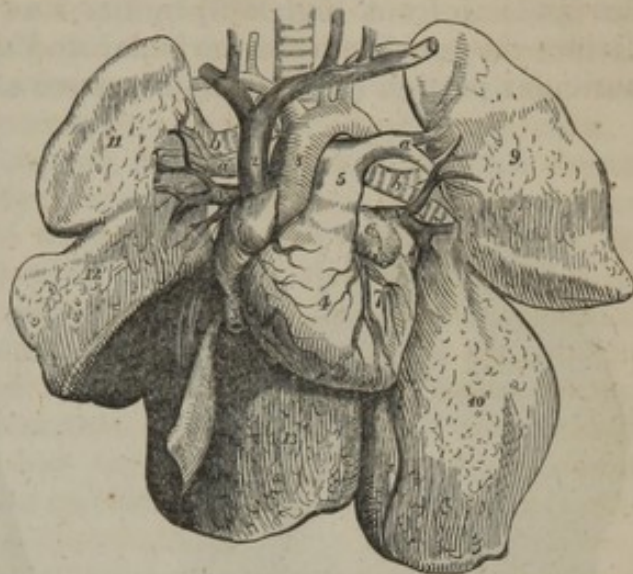


pericardium, and connected with the large veins and arteries of the lungs and body (see fig. 207).

Its general form is that of a blunt cone, flattened on its under surface. The broader end or base by which it is attached, is directed upwards, backwards, and to the right, against a part of the vertebral column extending from about the fourth to the eighth dorsal vertebra. The apex is turned downwards, forwards, and to the left, and corresponds in the dead body with the cartilage of the sixth rib, but in the living subject strikes against the walls of the chest, in the space between the cartilages of the fifth and sixth ribs, a little below the left mamilla. The heart, therefore, has an oblique position in the chest; and, besides this, it projects further into the left than into the right half of the thoracic cavity, passing about an inch or an inch and a half beyond the middle line in the one direction, and upwards of three inches in the other. Its position is affected more or less by that of the body, and it comes more extensively into contact with the anterior walls of the chest when the body is in the prone posture or lying on the left side. In inspiration, also, when the diaphragm sinks and the lungs expand, its apex is withdrawn from the thoracic parietes.

At its base the heart is attached to the great blood-vessels, and is also connected with them by the serous layer of the pericardium, which passes from one to the other. In other directions it is free, and movable in the sac of the pericardium. The anterior surface is convex in its general form; it is turned upwards as well as forwards, and is directed towards the sternum and costal cartilages, from which, however, it is partly separated by the lungs, these advancing over it especially during inspiration, in which condition only about two square inches are left uncovered. The posterior, which is also the under surface, is flattened, and rests on the diaphragm. Of the two borders or margins formed by the meeting of the anterior and posterior surfaces, the right or lower border, called *margo acutus*, is comparatively thin, and is longer than the upper or left border, which is more rounded, and is named *margo obtusus*.

Fig. 207.



A shaded diagram, representing the heart and great vessels, injected and in connexion with the lungs: the pericardium is removed.—1. Right auricle. 2. Vena cava superior. 3. Vena cava inferior. 4. Right ventricle. 5. Pulmonary artery, dividing into two branches, *a a*, one for the right, the other for the left lung. 6. Point of the left auricle. 7. Part of left ventricle. 8. Aorta. 9, 10. Two lobes of the left lung. 11, 12, 13. Three lobes of the right lung. *a, a*. Right and left pulmonary arteries. *b, b*. Right and left bronchi. *v, v*. Right and left pulmonary veins. The relative position of these three vessels is seen to differ on the two sides.



The heart is a hollow muscular organ, divided by a longitudinal septum into a right and left half, each of which is again subdivided by a transverse constriction into two compartments, communicating with each other, and named an *auricle* and a *ventricle*. These subdivisions are indicated even on the surface of the organ: thus, a deep transverse groove (fig. 209, *d, e*: the *auriculo-ventricular furrow*), interrupted in front (fig. 208) by the root of the pulmonary artery, *a*, divides the heart into the auricular and the ventricular portion. The auricular portion (*m n*), situated above and behind the transverse fur-

Fig. 208.

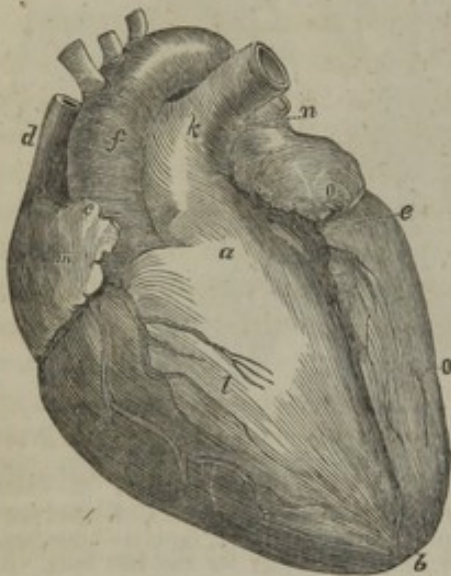


Fig. 209.

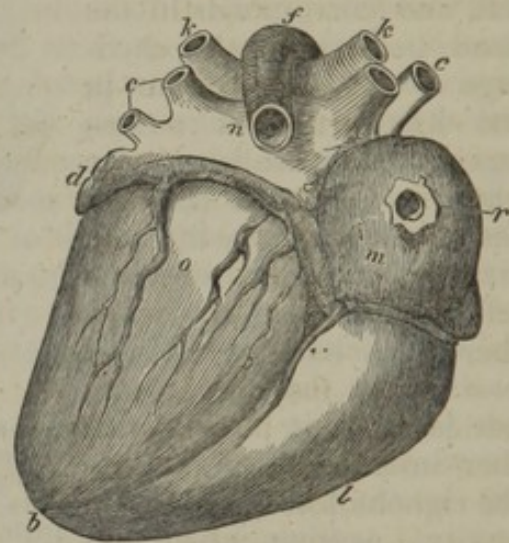


Fig. 208.—Front or upper surface of the heart and great vessels injected and placed obliquely, but its apex is not tilted forward as in the body. *a*. Conus arteriosus or infundibulum of right ventricle. *b*. Notch at apex of heart. *c*. Auricular appendage of right auricle. *d*. Vena cava superior. *e, b*. Anterior longitudinal furrow, marking the division between the ventricles. *f*. The aorta. *k*. Pulmonary artery. *l*. Right ventricle, of which the chief part is seen in front. *m*. Right auricle. *n*. Left auricle, seen only to a small extent, with its appendage projecting forward. There is another letter *o*, on the left ventricle.

Fig. 209.—Back or under surface of the same heart. *b*. Apex of heart, slightly notched. *c, c*. Pulmonary veins, two on each side. *d*. Auricle of left auricle. *e*. Point of entrance of coronary vein into the back of right auricle, *m*. *d, e*, indicate part of the transverse or auriculo-ventricular furrow, occupied by the large coronary vein. *f*. The aorta. *k, k*. Right and left division of the pulmonary artery. *l*. Right ventricle, only the smaller part seen. *m*. The right, and *n*, the left auricle: the division or furrow between them is distinctly seen. *o*. The left ventricle, of which the greater part is seen behind. *r*. Orifice of the vena cava inferior, constricted by the ligature used to keep in the injection.

row, is comparatively thin and flaccid in its structure, and is immediately connected with the great veins; it is divided by an internal septum into two distinct cavities, named the right (*m*) and left (*n*) *auricles*, from the circumstance that each is provided with an appendage resembling an ear (*auricula*).

Below and before the transverse groove is the ventricular portion (*l o*), which is conical, and flattened on its posterior or under surface, has very thick walls, and is connected with the great arterial trunks. It is marked off into a *right* (*l*) and a *left* (*o*) *ventricle* by two longitudinal furrows (*sulci longitudinales*), situated one (fig. 208, *e, b*) on the anterior, the other (fig. 209, *e b*) on the posterior surface of the heart, and extending from the base of the ventricular portion towards the



apex, a little to the right of which they meet and form a slight notch (*b*). The anterior longitudinal furrow is nearer to the left border, whilst the posterior furrow approaches nearer to the right border of the heart, so that the right ventricle (*l*) forms more of the anterior, and the left (*o*) more of the posterior surface of this organ (see figs. 208, 209.) Since, also, the two longitudinal furrows meet a little to the right of the apex, it follows that the left ventricle is somewhat the longer of the two and forms the point of the heart. Lying within the transverse and longitudinal furrows are found the proper nutrient vessels of the heart, named the coronary or cardiac arteries and veins.

Considered in respect of function, the heart is also a double organ, composed of two functionally distinct parts, each consisting of an auricle and a ventricle. The right portion receives into its auricle, from the two *venæ cavæ* and other small veins, the dark venous blood returning from the various parts of the body, and, by means of its ventricle, propels it through the pulmonary artery into the lungs. The red blood returning from the lungs by the pulmonary veins, reaches the left part of the heart at its auricle, and is forced onwards by the left ventricle, through the aorta, into the body. In this order, pursuing the course of the blood, the four cavities of the heart may conveniently be described.

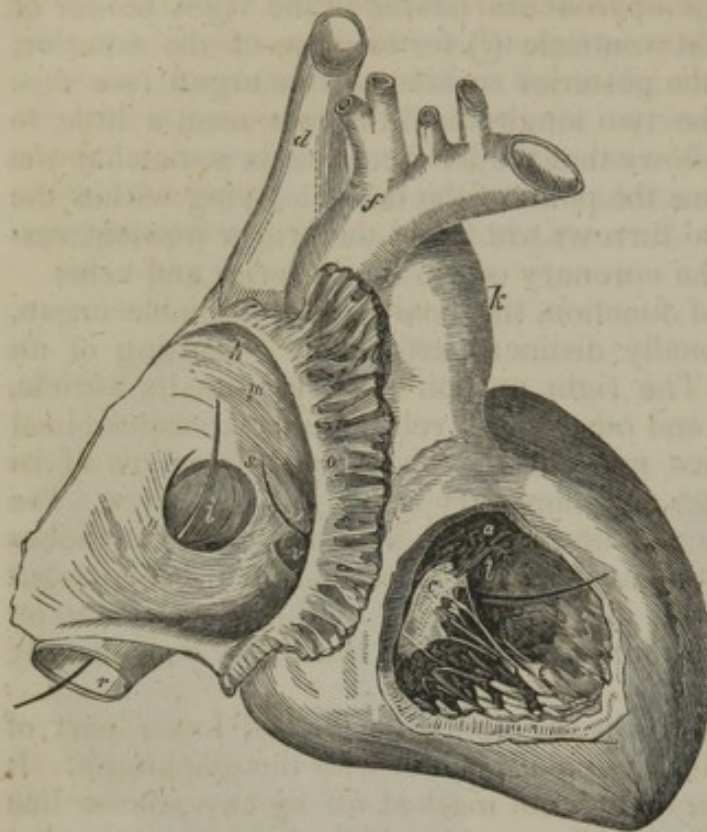
1. The *right auricle* (*m*) forms the right anterior and lower part of the base of the heart, and is in contact below with the diaphragm. It presents two parts, which, though not marked off by any precise line of division, yet differ in size and form. One of these, large, somewhat quadrangular, and composed of very thin walls, occupies the interval between the two *venæ cavæ*, so as to receive directly the blood which they convey; hence it is named *sinus venosus*, and also *atrium*. The other part forms a small conical pouch (fig. 208, *c*), which projects forwards and to the left, between the right ventricle (*l*) and the aorta (*f*), like an appendage to the general cavity: it is sometimes named "auricular appendage," but more frequently *auricula*, or the "proper auricle," from its resemblance in shape to a dog's ear. It is triangular in form, compressed, and slightly dentated at its border. Its walls are thicker and more muscular than those of the *sinus venosus*.

The external surface of the auricle, unattached in the greater part of its extent, is prolonged upwards, forwards, and to the left side into its auricular appendage; below it is connected with the right ventricle, and internally and posteriorly with the left auricle. Into its upper and posterior corner opens the *vena cava superior* (*d*), and into the lower and posterior part the *inferior vena cava* (fig. 209, *r*).

To examine its interior, an incision may be made from the conflux of the *venæ cavæ* horizontally across its anterior wall, and from the middle of this cut another may be carried upwards into the superior cava. On laying open the cavity of the auricle, (fig. 210, *m*.) it is seen to be lined throughout by a very thin, smooth, transparent, shining membrane, similar to the lining membrane of the veins, with which it is continuous. The inner surface of the *sinus venosus* is for the most part even, but the interior of the auricular appendage, and of the adjoining anterior wall of the *sinus*, is marked by several prominent



Fig. 210.



Heart placed with its anterior surface upwards, and its apex turned to the right hand of the spectator. The right auricle and right ventricle are both opened. Parts in right auricle:—*h*. Entrance of vena cava superior, which is itself marked, *d*. Inferior cava, marked *r*, has a probe passed through it into the auricle. *m*. The smooth part of the auricle. *o*. Musculi pectinati, seen in the auricular appendix which is cut open. *n*. Eustachian valve placed over the mouth of the inferior cava. *i*. Fossa ovalis, or vestige of the foramen ovale. *s*. Annulus ovalis. The probe leading from *s* into the right ventricle passes through the auriculo-ventricular opening. *v*. Mouth of the coronary vein. Parts in the right ventricle, in which the other end of the probe, from *s*, appears:—*a*. Cavity of conus arteriosus, leading to the pulmonary artery, *k*. *l*. Convex septum between the ventricles. *c*. Anterior segment of the tricuspid valve connected by slender cords, the chordæ tendineæ, to the musculi papillares, *e*. *f*. The aorta.

*ovalis*, which is the vestige of the foramen ovale (figs. 220–1, *o*) of the foetal heart, (*vestigium foraminis ovalis*), and indicates the original place of communication between the two auricles. It is bounded above and at the sides by a prominent ridge or border (*s*), which is deficient below, and is called *annulus ovalis*—*isthmus Vieussenii*. Between the highest part of the floor of the depression and the corresponding portion of the annulus there sometimes exists a small slit, which leads upwards beneath the annulus into the left auricle, forming thus an oblique and valved aperture between the two cavities. At the line of union between the anterior margin of the inferior cava and the auricle is situated a thin crescentic membranous fold (*n*), called the *Eustachian valve*, which crosses over the mouth of the vein. One border of this valve is convex, and is continuous with the wall of

muscular fasciculi, running transversely, and named *musculi pectinati* (*o*). The opening (*h*) of the superior cava (*d*) into the auricle is directed downwards and forwards, whilst that of the inferior cava (*r*), which is considerably larger than the other, is turned upwards and inwards (*i*). At the angle of union of these two veins there exists in the hearts of certain quadrupeds a prominence of the inner surface, which was named by Lower a tubercle, (*tubercle of Lower*.) In the human heart this elevation is so little marked as scarcely to deserve the name assigned to it. The left and posterior side of the auricle is formed by the *septum auricularum*, a partition which separates it from the left auricle. At the lower part of this septum, and just above the orifice of the inferior vena cava, is situated an oval depression (*i*), named *fossa*



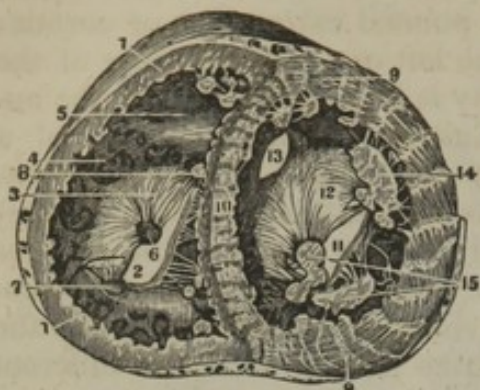the auricle and the anterior margin of the venous orifice. The other, which is free and concave, ends in two pointed extremities or cornua; of these, the left cornu is attached to the left or anterior border of the annulus ovalis, whilst the right extremity is lost on the wall of the auricle between the two cavæ. The Eustachian valve consists of a duplicature of the lining membrane of the auricle, containing occasionally a few muscular fasciculi. In the fœtus, this valve (fig. 220, *e*) is proportionably large, and serves to direct the blood of the inferior cava towards the foramen ovale; whilst in after life it may tend somewhat to prevent the reflux of the blood into the inferior cava. In the adult it is comparatively small, but varies greatly in size in different cases. It is often cribriform or perforated by numerous foramina, and sometimes it is reduced to a few slender filaments, or is even altogether wanting. To the left of this valve, between it and the opening into the ventricle, to be presently noticed, is situated the orifice of the large coronary vein (*v*), protected by a semicircular valve, which is sometimes double, and which, though figured by Eustachius, is often named the *valve of Thebesius*. Besides this opening, numerous small foramina may be observed in different parts of the auricle, which are called *foramina Thebesii*. Some of them are little recesses closed at the bottom; whilst others are the mouths of minute veins, (*venæ minimæ cordis*.) Lastly, in the floor of the auricle, and situated in front and to the left of the inferior cava, is a large opening, (indicated by the probe drawn from near *s*.) leading into the right ventricle, named the *right auriculo-ventricular* opening. It is of an oval form, and at least an inch in diameter, admitting three fingers easily: its margin is surrounded by a whitish tendinous ring to which is attached the base of the tricuspid valve, to be presently described with the right ventricle.

2. The *right* or *anterior* ventricle (figs. 208, 209, *l*.) occupies the right border of the heart, the larger part of its anterior surface, and the smaller part of its posterior surface, reaching from the right auricle to the apex. Its form is somewhat pyramidal; and the upper and anterior part of its base, which is turned upwards, forms a conical prolongation, named *infundibulum*, or *conus arteriosus*, (fig. 208, *a*.) from which the pulmonary artery (*k*) arises.

To examine the interior of this ventricle, it is best to reflect upwards a V-shaped flap, made in its anterior wall, (fig. 210.) In doing this, it will be found that its muscular parietes are much thicker than those of the auricle, and, moreover, that they are thickest at the base of the ventricle, becoming gradually thinner towards its point. The left wall formed by the *septum ventriculorum* (*l*), is convex and bulges into the ventricular cavity, so that a cross section of this has a crescentic figure, (fig. 211, *1*.) The interior of the ventricle is lined with a thin membrane, continuous with that of the auricle on the one hand, and with that of the pulmonary artery on the other. The inner surface is covered with a number of irregular rounded muscular bands, named *columnæ carneæ*, which form quite a network in some parts of the ventricle, and may be classified into three kinds. The *first* kind merely form slightly prominent ridges on the walls of the ventricle, being attached by their under side as well as by the two extremities;



[Fig. 211.]



A transverse section of the top of the ventricles just below the base of the auricles. 1, 1. Section of the right ventricle. 2. Right auriculo-ventricular opening or ostium venosum. 3. The largest fold of the tricuspid valve. 4. Depression to direct the blood to the pulmonary artery. 5. Funnel-shaped enlargement near the pulmonary artery. 6. Section of one of the muscoli papillares attached by the chordæ tendineæ to the tricuspid valve. 7, 8. Other columnæ carneæ. 9. Section of the external parietes of the left ventricle. 10. Section showing the thickness of the ventricular septum. 11. Left ostium venosum. 12. The mitral valve. 13. Ventricular opening of the aorta. 14, 15. Musculi papillares of the mitral valve—S. and H.]

*tricuspid valve* (valvulæ triglochines). The *arterial* orifice, which is circular in form, is situated, as already mentioned, at the summit of the conus arteriosus (*a*); it is placed in front and to the left of the auricular opening, and is also higher up. Its orifice is guarded by three small membranous folds, called the *sigmoid* or *semilunar* valves. Between these two openings the muscular substance of the heart forms a prominent rounded ridge, which projects into the ventricle, and seems to mark off its cavity into two compartments,—one immediately following the auricular opening, the other adjacent to the arterial orifice, and forming the funnel-shaped portion or conus arteriosus previously mentioned.

The *tricuspid* valve, (fig. 210, *c*) consists of three pointed flaps or segments, of a triangular, or rather trapezoidal shape, formed by a doubling of the lining membrane of the auricle and ventricle, containing within it numerous tendinous fibres. At their bases these segments are continuous with one another, so as to form an annular membrane, and are thus attached to the tendinous ring around the margin of the auricular opening; in the rest of their extent they lie in the cavity of the ventricle, having the chordæ tendineæ attached to their free margin and outer surface. One of the segments is turned towards the septum of the ventricles, another is placed more to the right, against the anterior and right wall of the cavity; whilst the third and largest division of the valve, lying more on the left, is interposed, as it were, between the auricular and arterial openings, and has its ventricular surface directed forwards and upwards. The chordæ tendineæ, already referred to, arising chiefly from the muscoli papillares, but some also from the wall and especially the septum of the ventricle, proceed to

the second are adherent by their two ends only, and are free in the rest of their extent; whilst the third kind form three or four bundles, named *musculi papillares*, (fig. 210, *e*), which are directed from the apex towards the base of the ventricle, and end in small tendinous cords, *chordæ tendineæ*, through which they are connected with the segments of the tricuspid valve (*c*). These columnæ carneæ disappear in the conus arteriosus, where the surface is smooth and even (*a*).

There are two openings in the right ventricle, viz., the auriculo-ventricular orifice, leading from the right auricle, and the arterial orifice, conducting to the pulmonary artery. The *auriculo-ventricular* opening, (through which, in fig. 210, the probe is passed,) already seen from the auricle, is situated in the base of the ventricle; it is oval in form, and is guarded by a large valve, named, from its tripartite figure, the



be inserted into the margins of the valvular segments, and also into their ventricular surface, i. e. the one turned towards the ventricle. The cords arising from one papillary muscle or group of muscles run up in the angular interval between two adjacent segments of the valve, and, diverging from each other, are attached to both.

The structure of the tricuspid valve, and also that of the corresponding valve in the left ventricle, named the mitral valve, and especially the mode of attachment of the chordæ tendineæ, have been carefully studied by Kürschner.\* He finds, that, between the three principal segments of this valve, there are, though not constantly, as many smaller intermediate lobes. The middle part of each segment is thicker than the rest, whilst the marginal part is thinner, more transparent, and jagged at the edges. He further states that the papillary muscles of the ventricle are arranged into three groups. The chordæ tendineæ from each group are connected some with the two adjacent principal segments, between which they run, and some with the smaller intermediate lobe. Three kinds of cords belong to each segment: *a*, the first set, generally two to four in number, and proceeding from two different muscular groups, or from one group and the wall of the ventricle, run to the base or attached margin of the segment, and are there connected also with the tendinous ring around the auriculo-ventricular opening; *b*, the second set, four to six in number, and smaller than the first, proceed also from two adjacent papillary muscular groups, and are attached to the back or ventricular surface of each segment at intervals along two or more lines extending from the points of attachment of the tendons of the first order at the base of the valve to near its free extremity; *c*, the third set, which are still more numerous and much finer, branch off from the preceding ones, and are attached to the back and edge of the thinner marginal portion of the valves. Their points of attachment lie in straight lines proceeding from the insertions of the tendons of the second order to the margin of the valve. Lastly, it may be remarked, that Kürschner has confirmed the observation of Senac, that muscular fibres may be found passing down into the segments of the tricuspid valve from the parietes of the right auricle.

During the contraction of the ventricle, the tricuspid valve is applied over the opening leading from the auricle, and prevents the blood from rushing back into that cavity. Being retained by the chordæ tendineæ, the expanded flaps of the valve resist the pressure of the blood, which would otherwise force them back through the auricular orifice; the papillary muscles, contracting as the cavity of the ventricle itself is shortened during its systole, are supposed thus to prevent the valves from yielding too much towards the auricle, which might have been the case had the chordæ tendineæ been longer, and fixed directly into the wall of the ventricle.

The *semilunar* valves,† placed at the mouth of the pulmonary artery,

\* Wagner's Handwörterbuch, art, "Herzthätigkeit."

† The form and structure of these valves is precisely similar to those at the commencement of the aorta, though they are not so thick and strong. The letters of reference introduced into the following description apply to the aortic valves, fig. 213.



consist of three semicircular folds, each of which is attached by its convex border to the side of the artery where it joins with the ventricle, whilst its straight border is free, is directed towards the area of the vessel, and presents in its middle a small fibro-cartilaginous knot, called *nodulus*, or *corpus Arantii*, (fig. 213, c.) These valves consist of a duplicature of the lining membrane with enclosed tendinous structure. Part of the latter runs along and strengthens the free margin of the valve, and is there attached to the nodule. Other tendinous fibres, again, may be described as spreading out from the nodule, and extending to the attached border of the valve, occupying its whole extent, except two narrow lunated portions (e), one on each side of the nodule and adjoining the free margin of the valve. These parts, which are named *lunulae*, are therefore thinner than the rest. During the contraction of the ventricle the valves lie against the sides of the pulmonary artery, and allow the blood to flow on; but during the ventricular diastole, when the column of fluid in the pulmonary artery is checked, and is partially thrown back by the elasticity of the coats of that vessel, the sigmoid valves spread out across the arterial orifice, and completely close it. When the valves are thus closed, the three nodules meet in the centre of the vessel, and the thin lunated parts are closely applied by their opposed surfaces to each other, and are held together as well as exempted from strain, by the opposite and equal pressure of the blood on either side, so that, the greater the pressure, the more accurate must be the closure. The force of the reflux is sustained by the stouter and more tendinous part of the valve.\*

Beyond the sigmoid valves the commencement of the pulmonary artery presents three slight dilatations or recesses in its wall, one being placed behind each valve. These are the sinuses of Valsalva, which, however, are much more marked at the root of the aorta.

3. The *left auricle* occupies the left and posterior part of the base of the heart. Like the right auricle, it consists of a larger portion, named the atrium or sinus venosus, and of an auricular appendix. The *sinus* of the auricle is to a great extent concealed by the pulmonary artery and the aorta, which cover it in front, the appendix alone being visible without detaching those vessels or inverting the position of the heart (fig. 208, o). When distended, the atrium (fig. 210, n) is four sided, or rather cuboid in form. In front it rests against the aorta and pulmonary artery (fig. 208, f, k); behind, on each side, it receives two pulmonary veins (fig. 209, c, c), those of the left lung entering very close together. On the right it is in contact with the other auricle (m), and from its upper and left side projects the *auricular appendage* (d), which is narrower, longer, and more curved than that of the right auricle; the margins of the appendix are also more deeply indented, and its point, which advances forwards, and towards the right side, rests upon the root of the pulmonary artery.

The interior of the appendix presents *musculi pectinati* similar to those in the right side of the heart, but the cavity of the sinus venosus generally (fig. 212, a) is smooth; besides which, its walls are thicker

\* On this subject, see A. Retzius in Müller's Archiv., 1843, p. 14.



than those of the right auricle, and its lining membrane is less transparent. Posteriorly are the openings of the pulmonary veins (*c c*), two on each side, which are entirely without valves. The two veins of either or both sides may unite into one before entering the auricle, whilst in other cases there is found an additional opening on one side. On the septum between the auricles, a slight lunated mark or depression (*e*) may be observed, which is the vestige of the foramen ovale, as it appears upon the left side. The depression is limited below by a slight crescentic ridge, the concavity of which is turned upwards. This ridge is in fact the now adherent border of a membranous valve, which is applied in the fœtus to the left side of the then open foramen ovale; when the adhesion of this valve occurs lower down than usual, a small pouch is left, reaching a variable distance from the depression; and, as formerly mentioned, when the adhesion is imperfect, a narrow passage permanently exists between the two auricles, through which, however, unless when unusually direct and open, the blood can scarcely be supposed to pass. Lastly, in the lower and fore part of this auricle is situated the left *auriculo-ventricular* opening, (indicated by the probe passed from *e*.) to the margin of which is attached the mitral valve of the left ventricle. It is of an oval form, and is rather smaller than the corresponding opening between the right auricle and ventricle.

4. The *left* or *posterior ventricle* occupies the left border of the heart, but owing to the obliquity of the septum between the ventricles, only about a third of its extent appears on the anterior surface of the organ, the rest being seen behind, (figs. 208, 209, *o*.) It is longer than the right ventricle, and it reaches lower down at the apex of the heart. The cross section of its cavity is oval (fig. 211, *a*), not crescentic, for the septum on this side is concave. To expose its interior, two incisions may be made through its walls, parallel with the anterior and posterior longitudinal furrows of the heart, and uniting near the apex. On raising up the flap so formed, the great thickness of the walls of this ventricle (fig. 212, *o o*), as compared with the right, is conspicuously seen, the proportion between them in this respect being as 3 to 1. The walls are thickest towards the widest part of the ventricle, about one-third of its length from the base: from this point they become thinner towards the auricular opening; but they are still thinner towards the apex, which is the weakest part. The lining membrane of this ventricle, which is continuous with that of the left auricle and the aorta, is usually less transparent than that of the right ventricle, especially after a certain age. In the interior of the cavity are found *columnæ carneæ*, *musculi papillares*, with *chordæ tendineæ*, and two orifices guarded with valves. The *columnæ carneæ*, like those of the right side, are of three different kinds; they are, on the whole, smaller, but are more numerous and more densely reticulated, and are directed for the most part from the base to the point of the heart. Their intersections are very numerous near the apex of the cavity, and also along its posterior wall, but the upper part of the anterior wall is comparatively smooth. Two large fleshy eminences (*n n*), *musculi papillares*, larger than those of the



Fig. 212.

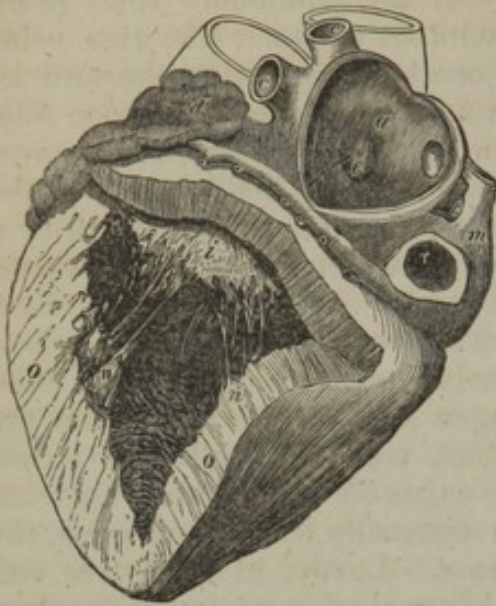


Fig. 213.

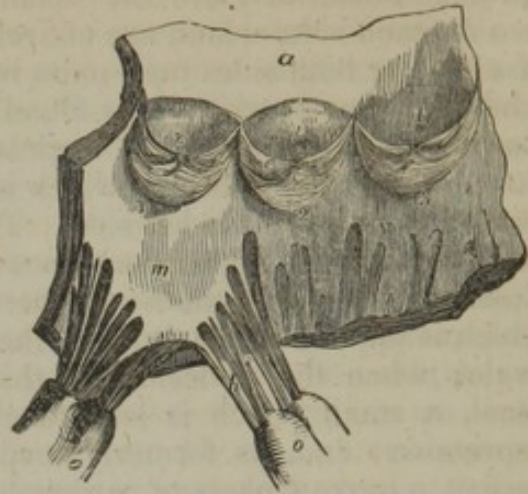


Fig. 212. Heart seen from behind, and having the left auricle and ventricle opened. Parts in left auricle:—*a*. Smooth wall of auricular septum. *c, c, c*. Openings of the four pulmonary veins. *d*. Left auricular appendage. *e*. Slight depression in the septum, corresponding to the fossa ovalis on the right side. A probe is seen which passes down into the ventricle through the auriculo-ventricular orifice. Parts in left ventricle:—*i*. Posterior segment of the mitral valve, behind which is the probe passed from the left auricle. *n, n*. The two groups of muscoli papillares. *o*. Section of the thick walls of this ventricle, which may be compared with that of the walls of the right ventricle, fig. 210. *r*. Entrance of inferior cava.

Fig. 213. Part of the left ventricle, and commencement of the aorta laid open to show the sigmoid valves.—*a*. Portion of the aorta. *v*. Muscular wall of left ventricle. 1, 2, 3. Semilunar or sigmoid valves. *c*. Corpus arantii in one of them. *e*. Thin lunated marginal portion or lunula. *s, t, t*. Sinuses of Valvula. *t, t*. Mouths of the two coronary arteries of the heart. *m*. Anterior segment of the mitral valve, the fibrous structure of which is continuous above with the aortic tendinous zone, opposite the attached margin of the sigmoid valve, marked 1. Opposite the valves, 2 and 3, the tendinous zone receives below the muscular substance of the ventricle *v*. *h*. Larger chordae tendineae. *o o*. Muscoli papillares.

right ventricle, formed of lesser bundles, one from the anterior, the other from the posterior surface, pass upwards and terminate each in a blunted extremity, from which numerous *chordae tendineae* branch off to be inserted into the edges of a large valve (*i*), which protects the opening leading from the left auricle. This opening (*left auriculo-ventricular*, through which the probe descends) is placed at the left and posterior part of the base of the ventricle, behind and to the left of another orifice (*aortic*) which leads into the aorta. It is surrounded by a tendinous margin, to which the valve above alluded to is attached. This valve resembles in structure the tricuspid valve of the right ventricle, but it is much thicker and stronger in all its parts, and, moreover, it consists of only two pointed divisions or segments, continuous at their attached bases, whence it is named the *bicuspid* or *mitral* valve. The larger of the two segments is suspended in front of the other, between the auricular and the aortic orifices. There are usually two smaller lobes at the angles of junction of the two principal segments, more apparent than those of the tricuspid valve. The *chordae tendineae* are attached in the same way as to the tricuspid valve, but they are altogether stronger, and perhaps less numerous. A few muscular fibres also occur in this valve. (Kürschner.) The arterial or *aortic* orifice is a smaller circular opening, placed in front and to the right of the auriculo-ventricular opening, and very close to



it, being separated from it only by the attachment of the anterior segment of the mitral valve. It leads to the aorta, and is guarded by three valvular semilunar folds, resembling in form and structure those found at the root of the pulmonary artery, and called, like them, *sigmoid* or *semilunar* valves. These aortic semilunar valves (fig. 213, 1, 2, 3) are, however, thicker and stronger than those of the right side of the heart, the lunulæ (*e*) are more strongly marked off, and the central nodules, or *corpora Arantii* (*c*), are larger. Their structure and mode of connexion with the artery will be presently described. Behind each valve, the wall of the aorta (*a*) is dilated into three almost hemispherical pouches (*s, t, t*), named the sinuses of Valsalva, from two of which (*t t*) the two nutrient arteries of the heart arise. These sinuses are much more marked than those at the root of the pulmonary artery.

#### STRUCTURE OF THE HEART.

The heart consists chiefly of muscular tissue which is attached to certain fibrous structures, and is covered externally by a serous coat, while the cavities are lined by a proper membrane. Its walls are also supplied with blood-vessels, absorbents, and nerves, and contain more or less fat, with some cellular tissue.

The external serous membrane is the visceral or reflected portion of the pericardium. The internal covering, or *endocardium*, is a thin transparent membrane, differing somewhat on the two sides of the heart. On the left side of the heart it is continuous with the lining membrane of the pulmonary veins and aorta, and is usually found more opaque than on the right side, where it is prolonged into the veins of the body and into the pulmonary artery. Like the corresponding membrane of the arteries, it appears to be more liable to disease in the left cavities of the heart.

According to Theile, the endocardium is very thin on the muscoli pectinati of the auricles and on the columnæ carneæ of the ventricles. It is thicker, however, on the smooth walls of the auricular and ventricular cavities, and on the muscoli papillares, especially near their tips. It is, on the whole, thicker in the auricles than in the ventricles, and attains its greatest thickness in the left auricle. In both auricles the endocardium may be separated into two layers; one superficial or internal and thin, the other deeper, thicker, and composed of elastic fibres and cellular tissue: this deep layer is not prolonged with the inner one upon the valves and into the ventricles. Purkinje and Raeuschel\* found elastic fibres beneath the endocardium, in both auricles, and in the corpora Arantii, but not in the ventricles.

The *fibrous* structure of the heart consists of the firm rings which surround the auriculo-ventricular and great arterial orifices, of the fibrous tissue already mentioned as entering into the formation of the different valves, and also of the chordæ tendineæ. All of these fibrous structures are more strongly developed on the left side of the heart. The auriculo-ventricular rings serve as points of attachment to the muscular substance of the auricles and ventricles, and also to the base of the tricuspid and mitral valves and to some of their tendinous cords.

\* De Arteriarum et Venarum Structura. Breslau, 1836.



The left auriculo-ventricular ring is firmly blended, at the fore part of its right margin, with the fibrous structure surrounding the aortic orifice; and behind the aortic opening, between it and the two auriculo-ventricular openings, there is found a fibro-cartilaginous mass, which is connected with the several fibrous rings, and to which the muscular substance also is attached. In some large animals, as in the ox and elephant, there is a small piece of bone in this situation.

Around the pulmonary and aortic orifices are found tendinous rings to which the commencement of the large vessel is fixed.\* Each of these rings is formed by a fibrous band or zone, one edge of which is even, and gives attachment to the muscular fasciculi of the ventricle, whilst the other is scalloped into three deep semilunar notches, and is firmly fixed to the middle coat of the large artery. The semicircular margins of the notches just mentioned are much thicker and stronger than the rest of the tissue, and from the small depth of the tendinous zone the notches descend nearly through to its ventricular edge, almost reaching the muscular substance, which, indeed, is attached to the middle of the stout tendinous semicircular margins. The middle coat of the artery presents a festooned border, divided into three convex semicircular segments, which are received into and attached to the corresponding notches of the tendinous ring. In this part of the artery its middle coat is thinner, and the sides of the vessel are slightly dilated to form the sinuses of Valsalva. It is further to be observed, that the fibres of the middle coat have here a peculiar arrangement; for, instead of being all annular, they appear to diverge from the projecting points of the tendinous ring, and spread out upwards and laterally upon the walls of the vessel. In the same situation the external or cellular coat of the artery is also thin, but the connexion of the vessel to the heart is strengthened by the serous layer of the pericardium without and by the endocardium within. Moreover, the convex or attached borders of the semilunar valves are also connected with the inner surface of the upper notched border of the arterial fibrous ring; that is to say, a semilunar fold of the lining membrane is projected inwards along the margin of each semilunar notch to form the valve, and the tendinous structure contained within it is continuous with that of the ring. Lastly, it must be remarked, that, on the left side of the heart, the tendinous zone of the aortic orifice, whilst it gives attachment to the aorta and the semilunar valves above, is continuous below, in the posterior part of its circumference, not with the muscular substance of the left ventricle, but with a part of the anterior segment of the mitral valve. (Fig. 213.)

#### MUSCULAR FIBRES OF THE HEART.

The muscular substance of which the walls of the heart are principally composed consists of bands of fibres, arranged in an intricate manner, and connected together by a very fine filamentous cellular tissue, so small in quantity that its existence has been denied. The

\* The mode in which the two great arteries are attached has been carefully examined, described, and figured by Dr. John Reid. *Cyclop. Anat. and Physiology*, art. Heart, p. 587.



muscular fibres belong to the involuntary class, but are of a deep red colour, and are marked with transverse striæ.

The fibres of the auricles are independent of those of the ventricles, the two sets being connected together only by the intervention of the fibrous rings around the auriculo-ventricular orifices; so that when these rings are destroyed by boiling a heart for some hours, the auricles may be easily separated from the ventricles.

*Fibres of the auricles.*—These consist of a superficial set, common to both cavities, and of deeper fibres proper to each. 1. The *superficial* common or *transverse* fibres (fig. 214, *a a b*; 215, *a h*) run transversely over both sinuses, near the base of which, especially on the anterior surface, they are most distinctly marked. They form only a thin and incomplete layer: those near the surface are longer than those which lie deeper; some of them pass into the interauricular septum (fig. 215, *e*). The deeper fibres, which are *proper* to each auricle, consist of two sets, viz. the looped and the annular fibres. 2. The *looped* fibres (fig. 214, *c c, p r*; 215, *c c*) pass over the auricle and are attached by both extremities to the corresponding auriculo-ventricular rings. 3. The *annular* fibres encircle the auricular appendages (fig. 214, *n m*) from end to end, some longitudinal fibres running within them. These annular fibres also surround the entrances of the venæ cavæ and coronary vein on the right (fig. 214, 215, *v v*), and of the pulmonary veins (*d d*) on the left side of the

Fig. 214.

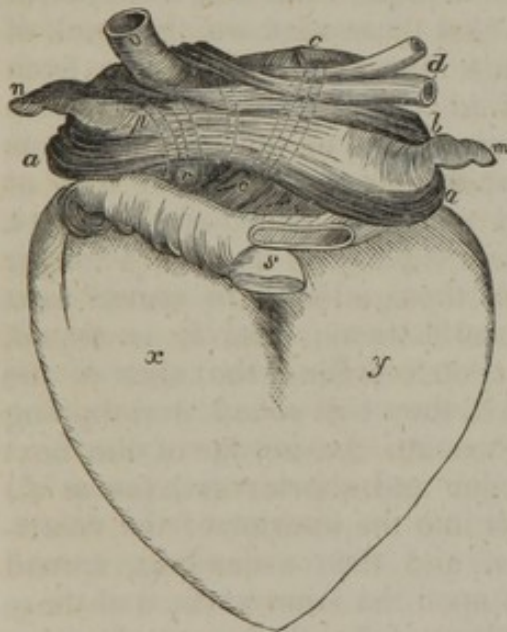


Fig. 215.

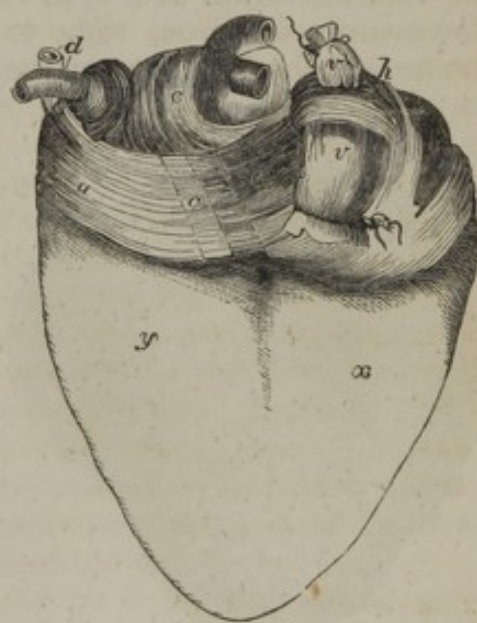

Fig. 214. Anterior view of the auricles, showing the arrangement of their muscular fasciculi. (Gerdy.)—*a, a, b*. The superficial or transverse fibres, forming an incomplete layer, more numerous near the base of the auricles, *a a*; and opening to embrace the veins, *v, d*, and the auricular appendages, *m n*. *c c*. Deeper layer, or looped fibres of left auricle. *p, r*. Looped fibres of right auricle. *n*. Right, and *m*, left auricular appendix, surrounded by the annular fibres. *v*. Vena cava superior. *d*. Pulmonary veins. *s*. Arterial orifices for pulmonary artery and aorta. *x*. Right, and *y*, left ventricle.

Fig. 215. Posterior view of auricles, showing the muscular fasciculi. (Gerdy.)—*a*. Superficial or transverse fibres passing to the septum auricularum at *e*. *c*. Looped fibres of left auricle. *d*. The two left pulmonary veins: the two right veins are seen, but are not marked. *h*. Looped fibres of right auricle. *v, v*. Venæ cavæ superior and inferior, entering right auricle. *x*. Right, and *y*, left ventricle.



heart,—the muscular fibres extending for some distance from the auricle upon the veins, especially upon the superior vena cava and the pulmonary veins.

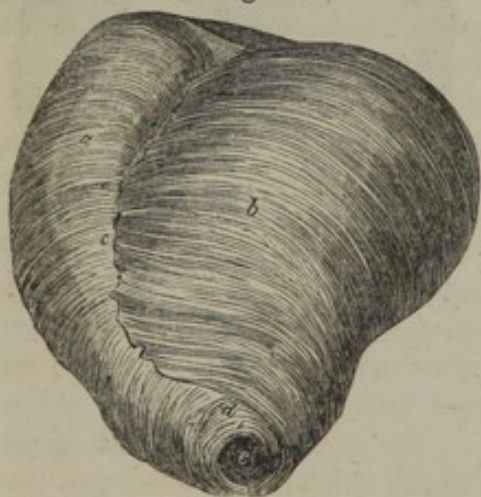*Fibres of the ventricles.*—The muscular fibres of the ventricles have a much more intricate arrangement, which has in a great measure baffled all the attempts yet made to unravel it. We shall here confine ourselves to a very brief statement of what is most generally received.

In the first place, it may be observed, that, as in the case of the auricular fibres, some of the ventricular muscular bands are common to both ventricles, whilst others, which are principally found at or near the base of the heart, belong exclusively to one ventricle. It further appears that most of the fibres are connected by both ends to the auriculo-ventricular fibrous rings, either directly or by means of the chordæ tendineæ; some of them, however, are inserted into the fibrous zones around the arterial openings. The length of these ventricular fibres accordingly varies in different bundles. As to direction, a few of them only have a longitudinal course; the greater number run obliquely or spirally across the ventricles, and even form twisted loops towards the point of the heart, whilst the deeper fibres become more and more transverse, and at length assume almost a circular direction.

*Twisted or spiral fibres.*—These are disposed in a succession of layers of various thickness. The *superficial* fibres on the fore part of the ventricles (fig. 216, *a*, *b*) run in an oblique direction from above downwards, and from right to left, whilst those seen on the back of the heart, where, however, they become more vertical, incline from

left to right. Hence the entire arrangement of these outer fibres is spiral, as may be best seen at and near the point of the heart. These superficial fibres are longer than those which are seated next beneath them; and it is found, that, on reaching the apex of the heart, they coil round, and dipping in beneath the border of the next deeper and shorter set, (as at *d*,) pass into the interior of the ventricles, and then ascending, spread out upon the inner surface of those cavities. As they are about to penetrate at the apex of the heart, they are arranged in a whorl, called the *vortex* (as represented in the figure at *e*). In this situation the coiling fibres in a boiled heart may be unravelled so as to lay open the point of the left ventricle

Fig. 216.



Superficial muscular fibres of ventricles, shown from the front in a heart, after boiling and removal of the serous coat. (Reid.)—*a*. Oblique fibres of the right ventricle. *b*. Left ventricle. *c*. Anterior longitudinal furrow, into which most of the fibres appear to penetrate, though a few pass across. *d*. The superficial fibres turning round to reach the interior of the ventricles, and forming the vortex, *e*.

without tearing a single fibre. The cavity of the right ventricle is



afterwards reached in the same way. (Reid.) Those fibres which lie immediately beneath the superficial set have a similar arrangement; that is, they turn round the lower border of those which are still deeper, and so on, forming shorter and shorter loops; the more superficial including, as it were, the deeper loops. Having reached the interior of the ventricles, they pass up to form the walls, the septum, and the muscoli papillares of those cavities, and are ultimately fixed to the auriculo-ventricular tendinous rings, either at once or through the intervention of the larger chordæ tendineæ. In consequence of the preceding arrangement, some anatomists have represented the fibres of the ventricles as consisting of a middle layer, incomplete at the apex, and of an external and internal layer, which are continuous with each other at the apex, through the aperture there left in the middle layer. According to Dr. John Reid, to whose description reference has already been made, even the intermediate fibres (or the middle layer) have a similar arrangement to those which cover them, that is, the more superficial turn in beneath the still shorter and deeper bands.

Some of this spiral set of fibres pass in or out at the interventricular furrows before and behind, and then turn round one or the other ventricles; but others pass over the furrows and embrace both cavities. Comparatively few fibres pass across the anterior longitudinal furrow (c). Part of the fibres which join in forming the vortex (d e), appear to come out of the anterior fissure (c). On tracing these back into the fissure, they are seen to be dovetailed, as it were, with fibres from the right ventricle, which may be traced into the same fissure, and then they take an almost longitudinal direction in the septum, contributing especially to form its right part, and extending as far as its base. (Reid.)

*Circular fibres.*—Near the base of each ventricle there are found nearly circular fibres, which dip into the anterior or posterior longitudinal furrows, or pass across to the opposite side, and then entering the substance of the ventricle, turn up towards the tendinous rings at the base. More of these fibres cross over the posterior than the anterior furrow; when these latter are removed, the two ventricles may, with very little force, be separated from each other.

The deepest fibres of all are also circular, or nearly so. Towards the base of the ventricles they form imbricated bands, both ends of which turn upwards to reach the tendinous rings. Some of these embrace both ventricles, but the innermost only one.

*Vessels and nerves.*—The substance of the heart receives its blood through the two coronary arteries. All its veins terminate in the right auricle; besides the great cardiac or coronary vein, (seen in fig. 209,) and another principal branch, there are two smaller orders of veins which will be described hereafter. The cardiac nerves given off by the cardiac plexuses appear rather small in comparison with the bulk of the organ: they are derived partly from the spinal and partly from the sympathetic system. Besides the large ganglia in the cardiac plexuses at the base of the heart, the nerves present minute



ganglia at different points along their course in its substance: these have been figured and described by Remak.\*

#### WEIGHT AND DIMENSIONS OF THE HEART.

The size and weight of the heart, the thickness of its walls, the capacity of its several cavities, and the width of its great orifices, have been made the subject of extensive observation, more especially with the view to determine some standard dimensions with which to compare the deviations occurring in disease.

*Size.*—It was stated by Laennec, as the result of his experience, that the heart in its natural condition is about equal in size to the closed hand of the individual. This, however, is but an imperfect kind of comparison. It is usually said to be about five inches long, about three and a half in its greatest width, and two and a half in its extreme thickness from the anterior to the posterior surface; but linear measurements of a flaccid organ like the heart are not of much value.

*Weight.*—The average weight of the heart in the adult can be more satisfactorily determined than its size, although, besides the differences resulting from sex, it ranges between rather wide limits, depending on the general weight of the body.

Its mean weight has been stated differently at 10 oz. (Meckel), 7 or 8 oz. (Cruveilhier),  $8\frac{1}{2}$  oz. (Bouillaud), and 9 to 10 oz. (Lobstein). From the tables of Dr. Clendinning, who examined its weight in nearly 400 cases, the average is found to be  $9\frac{1}{2}$  oz. in the male, and  $8\frac{1}{2}$  in the female. Dr. John Reid observes, that in an athletic male it would be expected to be 10 oz., but in a moderately sized individual about 8 oz. More recently the last-named observer has published tables† which appear to show that all the preceding estimates are rather too low; for in eighty-nine adult males, between twenty-five and fifty-five years of age, (who died of diseases not of the heart,) the *average* weight was full 11 oz., and in fifty-three females under similar circumstances the average was full 9 oz.,—giving a difference, therefore, of 2 oz. between the sexes.‡ Moreover, the mean weight of the heart in twelve previously healthy adult males, who perished by accidents, was found by Dr. Reid to be as high as  $12\frac{1}{2}$  oz. The *prevalent* weights, as deduced from the tables of Drs. Reid and Peacock, are from 10 to 12 oz. in the male, and from 8 to 10 oz. in the female.

The weight of the heart maintains some general proportion to that of the body. According to Tiedemann this is about 1 to 160; by Clendinning it was found to be 1 to 158 in males, and 1 to 149 in females; and by Reid, to be 1 to 169 in a series of thirty-seven males, and 1 to 176 in twelve females; but in the healthy males dying suddenly the ratio was as 1 to 173.

It was shown by Clendinning§ that the heart continued to increase in weight up to an advanced period of life, but at a comparatively slower rate subsequently to the age of twenty-nine years. We subjoin his results, as well as some derived from Reid's observations. It would seem from both tables that the progressive increase in weight is more marked in men than in women.

CLENDINNING.				REID.			
Age in years.		Weight in oz.		Age in years.		Weight in oz. and drms.	
		Males.	Females.			Males.	Females.
15 to 29	....	$8\frac{1}{2}$	$8\frac{1}{2}$	16 to 20	....	8·10	6·13
30 — 50	....	$9\frac{1}{2}$	$8\frac{1}{2}$	20 — 30	....	10·4	8·
50 — 60	....	$10\frac{1}{2}$	8	30 — 40	....	10·8	9·3
60 — +	....	$10\frac{1}{2}$	8	40 — 50	....	11·7	9·8
				50 — 60	....	11·10	9·14
				60 — 70	....	12·6	9·5
				70 — +	....	9·6	12·6

Entirely in accordance with these observations upon the increase of the heart's

\* Froriep's Notizen, 1838, p. 137; and Müller's Archiv., 1844, p. 463, taf. xii.

† Lond. and Edin. Monthly Journal of Med. Science, April, 1843, p. 323.

‡ These results are confirmed by the tables since published by Dr. T. B. Peacock, in the same journal, in 1846.

§ Medic. Chir. Transact., 1838.



weight according to the age, it has been found by M. Bizot\* that this organ continues to enlarge in all its dimensions as life advances, viz., in length, breadth, and thickness of its walls. The greatest increase was detected in the substance of the left ventricle and the ventricular septum.

*Thickness of the walls.*—Of the two auricles the left is rather the thicker, and the left ventricle is very much more so than the right. The ordinary thickness of the right auricle is stated by Bouillaud to be 1 line, and of the left  $1\frac{1}{2}$  line.

The walls of the left ventricle, as compared with those of the right, have been said to have a proportionate thickness of 2 to 1 by Laennec and Andral, 3 to 1 by Cruveilhier, and 4 or even 5 to 1, by Sæmmerring. In infancy and old age the ratio, according to Andral, is as 3 or 4 to 1. The measurements made by M. Bizot on this point are very precise. In the adult he found the proportion between the two ventricles to be about  $2\frac{1}{2}$  to 1.

The walls of the right ventricle he found to be thickest at the base, from whence they gradually become thinner towards the apex, where they are thinnest. In the left ventricle, on the contrary, the walls are thickest in the middle, thinner at the base, and thinnest at the apex. The annexed table indicates the mean thickness of the ventricular walls in lines, from the age of sixteen years upwards, in males and females:—

		Right Ventricle.	Left Ventricle.	Ventricular Septum.
Male Heart.	{ Base. ....	$1\frac{11}{12}$	$4\frac{6}{12}$	—
	{ Middle. ...	$1\frac{5}{12}$	$5\frac{19}{12}$	$5\frac{1}{8}$
	{ Apex. ....	$1\frac{4}{12}$	$3\frac{9}{12}$	—
Female Heart.	{ Base. ....	$1\frac{8}{12}$	$4\frac{3}{8}$	—
	{ Middle. ...	$1\frac{3}{12}$	$4\frac{1}{4}$	5
	{ Apex. ....	$0\frac{11}{12}$	$3\frac{13}{36}$	—

*Capacity of the auricles and ventricles.*—To determine with precision the absolute and relative capacities of the four cavities of the heart, as they exist during life, is impossible; and their capacity is so much influenced by their different states of distension, and also by the different degrees of contraction of their muscular walls at the moment of death, that no constant numerical relation in this respect can be looked for between them. Hence the most opposite statements prevail, especially with regard to the size of the ventricular cavities.

The capacity of the left ventricle, from which the other cavities can at any rate differ but little, has been calculated by different anatomists at  $1\frac{1}{2}$  fluid ounces and 4 oz.; it probably does not exceed 2 oz., which is the quantity usually stated.

The auricles are generally admitted to be a trifle less than the ventricles. The right auricle is also said to be a little larger than the left, in the proportion of 5 to 4. (Cruveilhier.) With regard to the two ventricles, it is asserted by some that the right is really larger than the left; by others (Lower, Sabatier, Andral) that the two have an equal capacity; whilst Cruveilhier, who judges from the effect of injections, has found the left to be the larger of the two. In the ordinary modes of death, the right ventricle is always found more capacious than the left, and this is probably owing to its being distended with blood, in consequence of the cessation of the circulation through the lungs. The left ventricle, on the other hand, is found nearly empty. There are reasons for believing, however, that during life any difference between the two cavities is very trifling, if it exist at all.

*Size of the ventricular openings.*—The right auriculo-ventricular opening, and the orifice of the pulmonary artery, are both found to be somewhat larger after death than the corresponding openings on the left side of the heart. Their circumference given in inches is thus stated by Bouillaud.†

		Max.	Med.	Min.
Auriculo-ventricular orifices.	{ Right . . . . .	4	$3\frac{10}{12}$	$3\frac{9}{12}$
	{ Left . . . . .	$3\frac{10}{12}$	$3\frac{6}{12}$	$3\frac{3}{12}$
Arterial orifices.	{ Right (Pulmonary) . . . .	$2\frac{10}{12}$	$2\frac{7}{12}$	$2\frac{6}{12}$
	{ Left (Aortic) . . . . .	$2\frac{8}{12}$	$2\frac{5}{12}$	$2\frac{4}{12}$

\* Mém. de la Soc. Medic. d'Observation de Paris, tom. i. p. 262. 1836.

† Traité des Malad. du Cœur, tom. i. p. 52. Paris, 1835.



[*Mechanism of the action of the heart.*—By means of an inherent power of dilating, which is called the diastole, and contracting, called the systole, the heart is the great agent in moving or producing the circulation of the blood. During the diastole of the auricles, which is synchronous, they become filled with blood rushing in from the *venæ cavæ* and the pulmonary veins, and during the diastole of the ventricles, which is also synchronous and commences immediately upon the cessation of the former action, and is isochronous or occurs at the same time with the systole of the auricles, they are filled with the blood from the latter, and by their systole, isochronous with a repetition of the diastole of the auricles, the blood is forced into the pulmonary artery and aorta.

The right half of the heart receives only dark or venous blood, and hence its denomination of *venous heart*, and as it is particularly appropriated to sending the blood to the lungs, it is also called the *pulmonary heart*; while the left half, receiving only red or arterial blood, to be sent throughout the body, is called the *arterial, aortic, or systemic heart*.\* These two are not necessarily connected together, but are fused into one organ, because they are developed from a single vascular sac in the embryo; and it may be considered as a provision of nature to economise space. In the herbivorous cetacea the ventricles of the heart are separated by a deep fissure, and Hyrtl† mentions a case in the Museum at Prague, of an anencephalous fœtus in which the heart is split to the base of the ventricles, and Meckel mentions one in which there was complete division of the two halves of the heart.

The systole of the auricles is followed by that of the ventricles almost as if a continuous action, and after a very short interval the systole of the auricles again takes place, and this alternating movement is such that each compartment of the heart contracts and dilates about seventy times in the minute.

From the veins being unprotected by valves at their orifices in the auricles, during the systole of the latter a portion of the received blood is regurgitated or thrown back; on the contrary, the blood is almost wholly driven into the arteries during the systole of the ventricles, regurgitation into the auricles being prevented by the valves at the *ostia venosa*. The valves themselves would be thrown back, and thus allow the blood to pass, if the *chordæ tendineæ* originating from the *musculi papillares* were not attached to their free edge, and even with this arrangement they would be driven back, from the *chordæ* becoming loose during the shortening of the ventricles consequent upon their systole, if it were not that as the ventricles shorten from the apex towards the base in their systole, the *musculi papillares* partake in the contraction, and thus retain the valves in a fixed position, like the line of a wind-swelled sail of a vessel.

The different thickness or strength of the different chambers of the heart, depends upon the resistance to the passage of the blood and the distance to which it is to be sent, hence the left ventricle is the thickest, &c.

During the diastole of the ventricles there is a disposition to regurgitation of the blood from the arteries, which is prevented by the semilunar valves at their orifices being closed by the attempt, and at the next systole the mass of blood driven out, communicates an impulse to the column of blood throughout the whole arterial system, and produces an elongation and dilatation of the elastic arteries which is perceptible to the feel, and is known as the "beating of the pulse."—J. L.]

#### DEVELOPMENT OF THE HEART AND GREAT BLOOD-VESSELS.

*The Heart.*—The heart first appears as an elongated sac or dilated tube lying at

[\* The term of pulmonary heart is sometimes applied by human anatomists to the right ventricle and left auricle, because the former sends the blood to, and the latter receives it from the lungs; and the *systemic heart*, to the right auricle and the left ventricle: but this is not a necessary arrangement, for in fishes, the blood passes at once from the branchiæ throughout the system; and in mollusca, it passes from the system directly to the lungs; and analogy therefore teaches us that the right half of the heart of man corresponds to the true, physiological pulmonary heart of fishes, and the left half, to the true, physiological systemic heart of the mollusca.—J. L.]

[† *Lehrbuch der Anatomie*, Prag. 1846.]



the fore part of the embryo, and having two veins connected with it behind, and a large arterial trunk proceeding from it in front. Very soon this tube, which has contractile walls, becomes curved or bent upon itself like a horseshoe, and projects on the ventral aspect of the body.

As this bending increases the venous end approaches the arterial, and at the same time, the tube, which goes on growing, becomes divided by two slight constrictions into three compartments, opening successively into each other (fig. 217). The first next to the veins (<sup>1</sup>) is the *auricular* portion (<sup>2</sup>), the one following is the *ventricular* (<sup>3</sup>), and the last, from which certain arteries proceed, is named the *arterial bulb* (*bulbus arteriosus*,<sup>4</sup>. See also fig. 218, A. B., with the description.) From the arterial bulb five vessels arise on each side, and, turning round the pharyngeal cavity, meet in front of the vertebræ, and join into a single vessel, which is the future thoracic aorta. These vascular arches make their appearance

[Fig. 217.

Fig. 218.

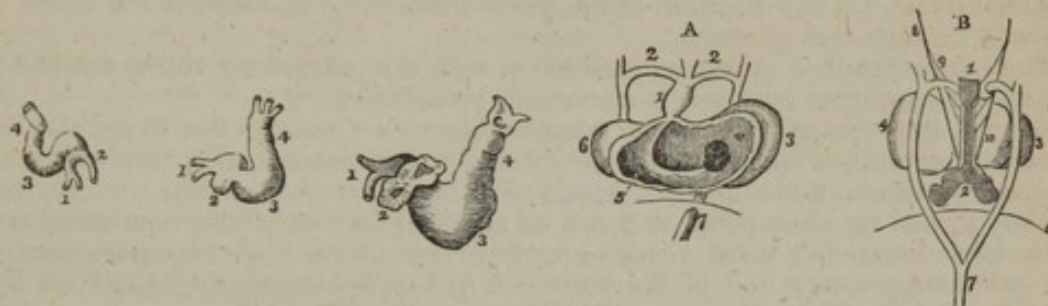

Fig. 217. Heart of the chick at the 45th, 65th, and 85th hours of incubation.—1, the venous trunks—2, the auricle—3, the ventricle—4, the bulbus arteriosus. (After Dr. Allen Thomson.)

Fig. 218. Heart of a human embryo about the fifth week. A, the heart opened on the abdominal aspect:—1, the bulbus arteriosus. 2, The aortic arches which unite posteriorly to form the aorta. 3, The auricle. 4, The opening from the auricle into the ventricle (6), which is laid open. 5, The septum rising from the lowest part of the cavity of the ventricle. 7, The vena cava inferior. B, The same heart viewed from behind. 1, The trachea. 2, The lungs. 3, The ventricle. 4, 5, The large atrium cordis or auricle. 6, The diaphragm. 7, The aorta descendens. 8, The nervus vagus. 9, Its branches. 10, Continuation of the nervus vagus. After Von Baer.]

in succession from before backwards, and never all co-exist, for those which first appear become obliterated before the last or posterior ones are formed. This rudimentary condition of the heart and great vessels is, to a certain degree, analogous to the heart and branchial vessels of fishes.

In the mean time, the auricular portion has become placed behind the ventricular compartment, and relatively to that cavity considerably enlarged. Moreover, two little pouches appear upon it, one at each side, which form the future auricular appendages. The walls of the ventricular portion are already thicker than the rest.

The next series of changes consists in the gradual subdivision of the single auricle, ventricle, and arterial bulb, each respectively into two, to form the right and left auricles, the right and left ventricles, and the pulmonary artery and aorta.

This subdivision commences first in the single *ventricular* portion of the heart (fig. 218, <sup>6</sup>). A small notch appears externally to the right of the apex, which goes on increasing in depth for some weeks, and then is again gradually obliterated. In the mean time, about the fourth week, a septum (<sup>5</sup>) begins to arise up internally from the right side of the apex and anterior wall of the cavity, and proceeds in the direction of the base, where the arterial bulb (<sup>1</sup>) leads off; and about the eighth week this interventricular septum is complete. Traces of the subdivision of the *auricular* portion commence early in the form of a slight constriction on the outer surface, which marks off the future auricles, the left being at first the smaller of the two; but the auricular septum is not begun until after that of the ventricles is finished. About the ninth week it appears growing from above and behind downwards and forwards, and at length comes to meet and coalesce below with the rising edge of the interventricular septum. The interauricular septum, however, remains incomplete, and leaves an opening in the middle which forms



the *foramen ovale* (figs. 220-1, o). The further steps in the separation of the auricles are connected with the changes which take place at the entrance of the great veins. The two large vessels terminating in the auricular extremity of the heart now correspond with the superior and the inferior vena cava, (fig. 220, s, c,) and open into it at some distance apart. At first, after the interauricular septum is partly formed above, the inferior cava opens into the left auricle, which is the smaller of the two, and for some time there is no valve to the foramen ovale. About the twelfth week, that valve rises up on the left side of the entrance of the vein, which thus comes to open into the right auricle; whilst at the same time the separation of the two auricles is also rendered more complete by the gradual advance of the valve (v) over the foramen ovale, but the passage, nevertheless, continues open until after birth.

Another valvular fold is developed on the right and anterior border of the orifice of the inferior cava, between it and the superior cava; this is the Eustachian valve (e). It appears to continue the opening of the inferior cava (c) towards the foramen ovale, (in the direction of the probe marked b,) and directs the blood of the vein through that passage.

The left auricle has at first no connexion with the pulmonary veins, nor has it yet been ascertained how this is afterwards established.

As the interventricular septum is approaching the base of the heart, that is, about the seventh or eighth week, the arterial bulb becomes also divided by an internal partition, meeting from opposite sides, into two vessels, which are slightly turned on each other, and are so adjusted as to become connected one with each ventricle: these vessels afterwards constitute the commencement of the pulmonary artery and of the aorta. A furrow subsequently begins on the outside, and completes the separation into two vessels.

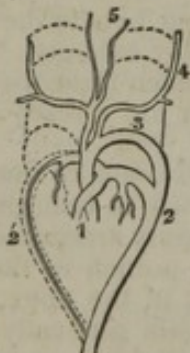*The great vessels.*—Whilst the arterial bulb (diagram, 219,') is thus converted into the commencement of the pulmonary artery and aorta, the five vascular arches already described as arising from it undergo metamorphosis; but embryologists are not agreed as to the precise way in which this takes place.

It is generally admitted, however, that the fourth arch on the left side (<sup>3</sup>), (counting from before,) which receives blood from the aortic division of the bulb, is persistent and continuing to enlarge, eventually becomes the arch of the aorta. The fourth arch on the right side, as well as all the more anterior arches on both sides, are obliterated to a greater or less extent, but certain portions of them remaining pervious and connected with the aortic arch (<sup>3</sup>) are supposed to form

the commencement of the great vessels rising from it (<sup>4</sup>,<sup>5</sup>). The fifth pair of arches (<sup>2</sup>,<sup>2'</sup>) are, according to Baer, connected with the pulmonary division of the bulb, and sending ramifications into the lungs, form the right and left branches of the pulmonary artery: the further or distal portion (<sup>2'</sup>) of the right arch is understood to be obliterated, whilst the corresponding part of the left side (<sup>2</sup>) is continued into the aorta as the *ductus arteriosus*.

Rathké's statement is somewhat different.\* According to him, the fifth arch of the right side is wholly obliterated. The right division of the arterial bulb is dilated at its commencement into the conus arteriosus of the right ventricle, and by its other end is continued into the fifth arch of the left side, and forms the commencement of the pulmonary artery. From this arch, near its commencement, a branch proceeds to the lungs, dividing into two, and forming along with the right division of the arterial bulb the pulmonary artery and its two

Fig. 219.



Illustrates Baer's view of the transformation of the arterial bulb and vascular arches in mammiferous animals.—1. Two tubes resulting from the division of the arterial bulb. 3. Fourth arch of left side remaining as arch of the aorta. 4. 5. Great vessels arising from it. 2, 2'. Fifth pair of arches sending branches into the lungs and forming the right and left divisions of the pulmonary artery. 2'. Further portion of the right arch obliterated. 2. Corresponding part of left arch joining the aorta and forming the *ductus arteriosus*.

\* Müller's Archiv. 1843, p. 276.



primary divisions. That part of this arch which is beyond the origin of the vessel sent to the lungs is continued into the aorta, and forms the *ductus arteriosus*, a passage which continues open until after birth.

*Valves.*—The development of the auriculo-ventricular and sigmoid valves has not been satisfactorily traced in the heart of mammalia.

*Muscular substance.*—Originally the heart is composed of a mass of nucleated cells, similar in character to those which primarily constitute the other organs of the body. Muscular tissue is subsequently formed in it; but its motion commences and proceeds for some time, whilst it is yet composed of cells and before any fibres appear.

PECULIARITIES OF THE FŒTAL HEART AND GREAT VESSELS.—FŒTAL CIRCULATION.

*Position.*—The fœtal heart, even after all its parts are formed, continues to be placed vertically in the thorax until about the fourth month, when the apex begins to turn towards the left side, so as to give it an oblique position.

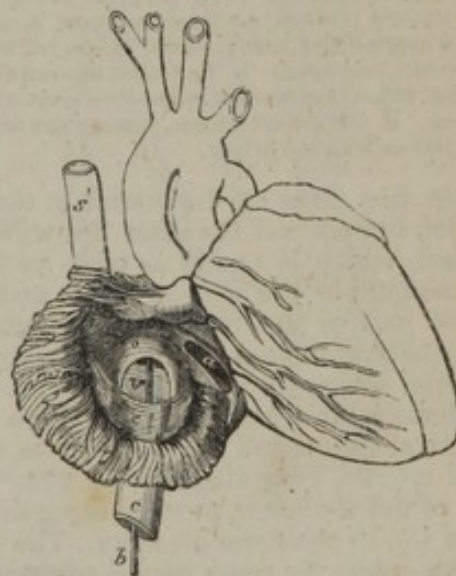
*Size.*—As compared with the body the heart is very much larger in the early fœtus than at later periods or subsequently to birth. At one time, indeed, it occupies nearly the whole thoracic cavity. At the second month its weight to that of the body is said by Meckel to be 1 to 50; but the ratio becomes gradually reduced to 1 to 120 at birth. In the adult the average is about 1 to 160.

For a long period the auricular portion is larger than the ventricular, and the right auricle is more capacious than the left; but towards birth these peculiarities disappear, and the ventricular portion becomes the larger part of the heart. As to the ventricles themselves, the right is at first the smaller; afterwards it becomes the larger of the two, and at birth their proportion is about equal. In the right ventricle the infundibulum is at first less marked than afterwards.

*Structure.*—For a time the walls of the ventricles are, comparatively speaking, very thick, and the thickness of both is about the same. In approaching the full period, however, the left begins to be the thicker of the two. But the two chief differences in the internal economy of the fœtal heart are the communication which exists between the two auricles by the foramen ovale, and the large size of the Eustachian valve.

The large oval orifice named the *foramen ovale* (figs. 220, 221, *o*) is placed at the lower and back part of the auricular septum, and is said to attain its greatest size at the sixth month. The valve (*v*) by which it is more or less covered, and the mode in which it is eventually obliterated after birth, have been already alluded to (p. 490). Being developed from the posterior border of the entrance of the inferior cava, the valve turns off that orifice from the left into the right auricle. At the same time, it rises up on the left side (see fig. 221) of the rim of the foramen ovale, which becomes continuous with it at the sides, but (as indicated by the probe in both figures) remains open above the free margin of the valve, which is concave and turned upwards. At length the valve passes beyond the upper part of the foramen altogether; and even then, owing to its position on the left side of the opening, it admits the passage of blood from the right to the left auricle, but not in the reverse direction. This valve consists of a duplicature of the lining membrane, containing a few muscular fasciculi and some dense cellular tissue.

Fig. 220.



Front view of heart of fœtus at four months, the right auricle being laid open. (Kilian.)—*s*. Vena cava superior. *s'*. Mouth of the same vein. *c*. Vena cava inferior. *b*. A probe passed along that vein into the right auricle, behind the Eustachian valve, *e*, and on the right aspect of the valve, *v*, of the foramen ovale, and through that opening, *o*, into the left auricle. *a*. The right auriculo-ventricular opening.



The formation, connexions, and structure of the *Eustachian valve*, which is very large in the fœtus (fig. 220, *e*), have been already described (pp. 474, 490).

The pulmonary artery of the fœtus, (fig. 222, *p*,) in passing from the right ven-

Fig. 221.

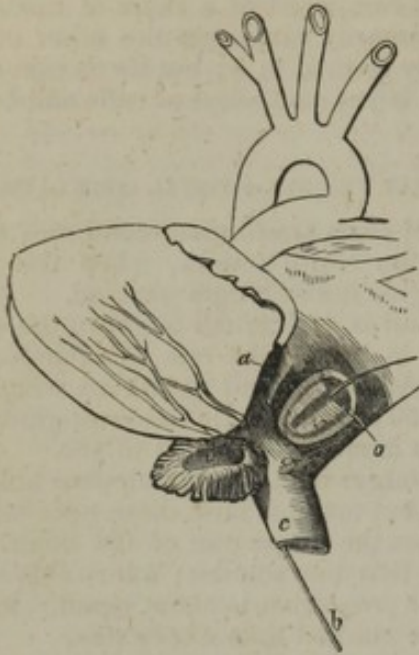

Fig. 222.

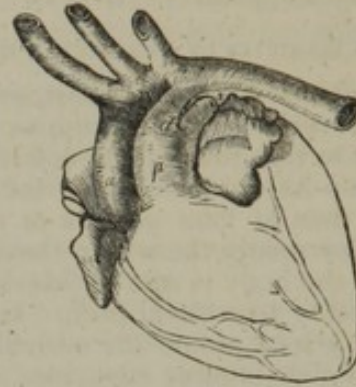

Fig. 221.—Back view of heart of same fœtus at four months, with the left auricle opened. (Kilian.)—*c*. Inferior cava, through which the probe is passed, the upper end reaching into the left auricle through the foramen ovale, *o*, and on the right aspect of the valve, *v*, which is seen to be applied and partly affixed to the left margin of the opening or foramen, *o*. *e*. Left auricular appendix laid open. *a*. Left auriculo-ventricular orifice.

Fig. 222.—Heart of an infant five days old. Front view. (Kilian.)—*a*. Aorta. *p*. Pulmonary artery. *d*. Ductus arteriosus, joining the termination of the aortic arch, just beyond the origin of the left subclavian artery.

tricle, first gives off the branch to the right lung, and then appears to divide into its left branch and the short but wide tube named the *ductus arteriosus* (*d*). This vessel, which is nearly as wide as the pulmonary artery itself, is the size of a goose-quill at the time of birth, and about half an inch long. It conducts the chief part of the blood of the right ventricle into the aorta (*a*), which it joins obliquely at the termination of the arch, a little below the origin of the left subclavian artery.

Besides the usual branches of the descending aorta intended to supply the abdominal viscera and the lower limbs, two large vessels, named hypogastric or *umbilical arteries*, (see diagram, fig. 223,<sup>19</sup>) arise from the common iliacs, and passing out of the abdomen, proceed along the umbilical cord, coiling round the umbilical vein (<sup>1</sup>), to reach the placenta. The commencement of each of these vessels afterwards forms the trunk of the corresponding internal iliac artery, and, from their size, they might even be regarded in the fœtus as the continuations of the common iliac arteries into which the aorta divides. From the placenta the blood is returned by the umbilical vein (<sup>1</sup>), which, after entering the abdomen, communicates by one branch with the portal vein of the liver, and sends another, named the *ductus venosus* (<sup>5</sup>), to join the vena cava inferior (<sup>6</sup>), as more fully described in the account of the vessels of the liver.

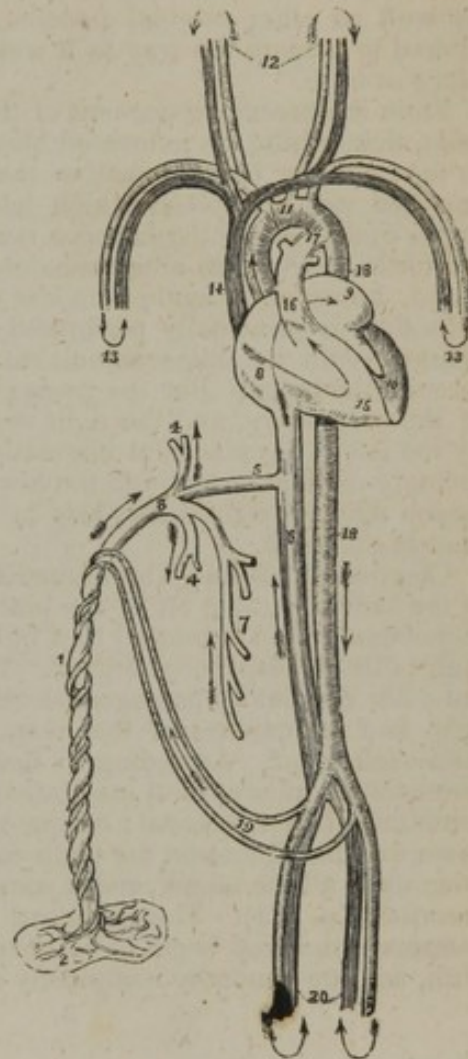
*Course of the blood in the fœtus.*—The right auricle, at which it is convenient to commence, receives its blood from the two venæ cavæ. The blood brought by the superior cava (fig. 223,<sup>14</sup>) is simply the venous blood returned from the head and upper half of the body; whilst, on the other hand, the inferior cava (<sup>6</sup>), which is considerably larger than the superior, conveys not only the blood from the lower half of the body, but also that which is sent back from the placenta through the umbilical vein (<sup>1</sup>). This latter stream of blood reaches the vena cava inferior, partly by the ductus venosus direct (<sup>5</sup>), and partly by the hepatic veins



after circulating through the liver in connexion with the blood of the vena portæ (<sup>4</sup>).

Now, the blood of the superior cava (<sup>14</sup>), descending over the Eustachian valve, and mixed with a small portion of that from the inferior cava, passes on into the right ventricle (<sup>15</sup>), and is thence propelled into the trunk of the pulmonary artery (<sup>16</sup>). A small part of it is then distributed through the branches of that vessel to the lungs, and returns by the pulmonary veins to the left auricle; but by far the larger part passes through the ductus arteriosus (<sup>17</sup>) into the aorta (<sup>18</sup>), below the place of origin of the arteries of the head and upper limbs, and mixed probably with a small quantity of the blood flowing along the aorta from the left ventricle, descends partly to supply the lower half of the body and the viscera, but principally to be conveyed along the umbilical arteries (<sup>19</sup>) to the placenta. From all these parts it is returned by the vena cava inferior, the vena portæ, and the umbilical vein; and, as already noticed, reaches the right auricle through the trunk of the inferior cava.

[Fig. 223.]



The fœtal circulation. 1. The umbilical cord, consisting of the umbilical vein and two umbilical arteries; proceeding from the placenta (2). 3. The umbilical vein dividing into three branches; two (4, 4) to be distributed to the liver; and one (5), the ductus venosus, which enters the inferior vena cava (6). 7. The portal vein, returning the blood from the intestines, and uniting with the right hepatic branch. 8. The right auricle; the course of the blood is denoted by the arrow, proceeding from 8 to 9, the left auricle. 10. The left ventricle; the blood following the arrow to the arch of the aorta (11), to be distributed through the branches given off by the arch to the head and upper extremities. The arrows 12 and 13, represent the return of the blood from the head and upper extremities through the jugular and subclavian veins, to the superior vena cava (14), to the right auricle (8), and in the course of the arrow through the right ventricle (15), to the pulmonary artery (16). 17. The ductus arteriosus, which appears to be a proper continuation of the pulmonary artery; the offsets at each side are the right and left pulmonary artery cut off; these are of extremely small size as compared with the ductus arteriosus. The ductus arteriosus joins the descending aorta (18, 18), which divides into the common iliacs, and these into the internal iliacs, which become the hypogastric or the umbilical arteries (19), and return the blood along the umbilical cord to the placenta; while the other divisions, the external iliacs (20), are continued into the lower extremities. The arrows at the terminations of these vessels mark the return of the venous blood by the veins to the inferior cava.—W.]

The blood of the inferior cava (<sup>6</sup>) is partly distributed with that of the superior cava as already described, but the larger portion, directed, as is supposed, by the Eustachian valve through the foramen ovale, flows from the right (<sup>8</sup>) into the left auricle (<sup>9</sup>), and thence, together with the comparatively small quantity of blood returned from the lungs by the pulmonary veins, passes into the left ventricle (<sup>10</sup>), from whence it is sent into the arch of the aorta (<sup>11</sup>), to be distributed almost entirely to the head and upper limbs. A certain portion of it, however, probably flows on into the descending aorta and joins the large stream of blood from the ductus arteriosus. From the upper half of the body the blood is returned by the branches of the superior cava to the right auricle, from which its course has been already traced.

Sabatier was of opinion that no mixture of the two streams of blood from the



two vena cavæ took place in the right auricle, but that all the blood of the inferior cava went into the left auricle and ventricle, whilst that of the superior cava reached the right ventricle. He thought, however, that the two kinds of blood were intermixed at the junction of the ductus arteriosus with the aorta. The entire separation of the two streams of blood of the venæ cavæ, as supposed by Sabatier, is not generally admitted in the mature fœtus; but there is reason to believe that it does take place in earlier stages. In fact, the inferior cava, as already mentioned, at first opens into the left auricle, and must therefore convey its blood immediately into that cavity. As the fœtus approaches maturity, more and more of the blood of the inferior cava joins the stream from the superior cava; and, indeed, the course of the blood, and the relative position of the veins, as well as other original peculiarities of the fœtal heart, become gradually altered to prepare the way as it were for the more important changes which take place at birth.

From the preceding account of the course of the blood in the fœtus, it will be seen, that, whilst the renovated blood from the placenta is principally conveyed to the upper or cephalic half of the fœtus, the lower half of the body is chiefly supplied with the blood which has already circulated through the head and upper limbs, exhibiting in this a certain analogy with the mode of circulation in the turtle and various other reptiles. The larger portion of this latter stream of blood, however, is again sent out of the body to be changed in the placenta. This duty is principally performed by the right ventricle, which after birth is charged with an office somewhat analogous, in having to propel the blood through the lungs. But the passage of the placental blood is longer than that of the pulmonary, and the right ventricle of the fœtus, although probably aided by the left in the placental circulation, also takes at least a large share in the ordinary circulation through the lower half of the body; and hence, perhaps, the reason why the right differs less in thickness from the left ventricle in the fœtus than in the adult.

*Changes after birth.*—The immediate changes which take place at birth consist of the sudden cutting off of the placental circulation and the simultaneous commencement of an increased flow of blood through the lungs, which then perform their office as respiratory organs. The foramen ovale, the ductus arteriosus, and the other circulatory passages peculiar to the fœtus are gradually closed, and the right and left cavities of the heart henceforth cease to communicate directly with each other. According to Bernt, the ductus arteriosus begins to contract immediately after several inspirations have taken place: in three or four days he sometimes found it closed; on the eighth day it was obliterated in one half the cases examined, and on the tenth day in all. The foramen ovale appears to continue open a little longer, and it sometimes remains so throughout life, as already described (p. 479). The umbilical arteries, the umbilical vein and the ductus venosus shrink and begin to be obliterated from the second to the fourth day after birth, and are generally completely closed by the fourth or fifth day.




## THE BLOOD.

### PHYSICAL AND ORGANIC CONSTITUTION.

THE most striking external character of the blood is its well-known colour, which is florid red in the arteries, but of a dark purple or modena tint in the veins. It is a somewhat clammy and consistent liquid, a little heavier than water, its specific gravity being 1052 to 1057; it has a saltish taste and a peculiar faint odour.

To the naked eye the blood appears homogeneous; but when examined with the microscope, either while within the minute vessels, or when spread out into a thin layer upon a piece of glass, it is seen to consist of a transparent colourless fluid, named the "lymph of the blood," "liquor sanguinis," or "plasma," and minute solid particles or corpuscles immersed in it. These corpuscles are of two kinds, the red, and the colourless: the former are by far the most abundant, and have been long known as "the red particles," or "globules," of the blood; the "colourless," or "pale corpuscles," on the other hand, being fewer in number, and less conspicuous, have only within the last few years been generally recognised by microscopic observers. When blood is drawn from the vessels, the liquor sanguinis separates into two parts;—into fibrin, which becomes solid, and a pale yellowish liquid named *serum*. The fibrin in solidifying involves the corpuscles and forms a red consistent mass, named the clot or *crassamentum* of the blood, from which the serum gradually separates. The relation between the above-mentioned constituents of the blood in the liquid and the coagulated states may be represented by the subjoined scheme:



*Red corpuscles.*—These are not spherical, as the name "globules," by which they have been so generally designated, would seem to imply, but flattened or disk-shaped. Those of the human blood (fig. 224,<sup>1, 2</sup>) have a nearly circular outline, like a piece of coin, and most of them also present a shallow cup-like depression or dimple on both surfaces; their usual figure is, therefore, that of biconcave disks. Their magnitude differs somewhat even in the same drop of blood, and it has been variously assigned by authors; but the prevalent size may be stated at from  $\frac{1}{3300}$ th to  $\frac{1}{3200}$ th of an inch in diameter, and about one-fourth of that in thickness.



Fig. 224.

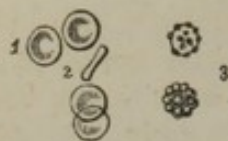

Fig. 225.

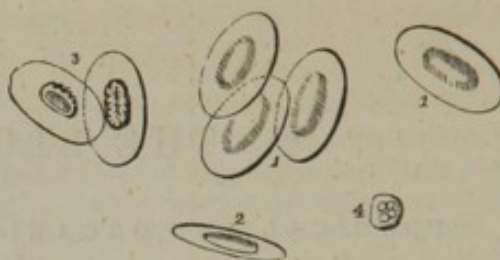


Fig. 224. Red corpuscles of human blood, magnified about five hundred diameters (Wagner). 1, shows depression on the surface. 2. A corpuscle seen edgewise. 3. Red corpuscles altered by exposure.

Fig. 225. Particles of frog's blood, magnified about five hundred diameters. 1. 1. Their flattened face. 2. A particle turned edgewise. 3. A lymph globule. Blood corpuscles altered by dilute acetic acid.

In mammiferous animals generally the red corpuscles are shaped as in man, except in the camel tribe, in which they have an elliptical outline. In birds, reptiles, and most fishes, they are oval disks with a central elevation on both surfaces, (fig. 225, from the frog,) the height and extent of which, as well as the proportionate length and breadth of the oval, vary in different instances, so that in some osseous fishes the elliptical form is almost shortened into a circle. The blood-disks of the lamprey and other cyclostomatous fishes, are circular and biconcave; thus in figure exactly resembling those of man. The blood corpuscles of invertebrata, though they want the red colour, are also, for the most part, flattened or disk-shaped; being in some cases circular, in others oblong, as in the larvæ of aquatic insects. Sometimes they appear granulated on the surface like a raspberry, but this is probably due to some alteration occurring in them.

The size of the corpuscles differs greatly in different kinds of animals; it is greater in birds than in mammalia, and largest of all in the naked amphibia. They are for the most part smaller in quadrupeds than in man; in the elephant, however, they are larger, being  $\frac{1}{2700}$ th of an inch, which is the largest size yet observed in the blood corpuscles of any mammiferous animal: the goat was long supposed to have the smallest, viz. about  $\frac{1}{8400}$ th of an inch; but Mr. Gulliver has found that they are much smaller in the Napu musk-deer, being less than  $\frac{1}{12000}$ th of an inch in that animal. In birds they do not vary in size so much: from Mr. Gulliver's very elaborate tables of measurement it appears that they range in length from about  $\frac{1}{1700}$ th to  $\frac{1}{2400}$ th of an inch; he states that their breadth is usually a little more than half the length, and their thickness about a third of the breadth, or rather more. He found a remarkable exception in the corpuscles of the snowy owl, which measure  $\frac{1}{1330}$ th of an inch in length, and are only about a third of this in breadth. In scaly reptiles they are from  $\frac{1}{1800}$ th to  $\frac{1}{1300}$ th in length; in the naked amphibia they are much larger: thus, in the frog they are  $\frac{1}{1000}$ th of an inch long, and  $\frac{1}{1700}$ th broad; in the salamander they are larger still; but the largest yet known in any animal are those of the proteus, which are upwards of  $\frac{1}{400}$ th of an inch in length: the siren, which is so much allied to the proteus in other respects, agrees with it also in the



very large size of its blood corpuscles; they measure  $\frac{1}{43}$ th of an inch in length, and  $\frac{1}{800}$ th in breadth. In the skate and shark tribe the corpuscles resemble those of the frog, in other fishes they are smaller.

From what has been stated, it will be seen that the size of the blood corpuscles in animals generally is not proportionate to the size of the body; at the same time Mr. Gulliver remarks, that, "if we compare the measurements made from a great number of different species of the same order, it will be found that there is a closer connexion between the size of the animal and that of its blood corpuscles than has been generally supposed;" and he has pointed out at least one example of a very natural group of quadrupeds, the ruminants, in which there is a gradation of the size of the corpuscles in relation to that of the body.

Structure.—The large corpuscles of the frog and salamander can be easily shown to consist of a thin, transparent, vesicular *envelope*, enclosing an apparently solid oval *nucleus* in the centre, with a quantity of softer *red-coloured matter* disposed round the nucleus and filling up the space between it and the envelope. When exposed to the action of weak acetic acid, (fig. 225,<sup>3</sup>) the colouring matter is speedily extracted, and the nucleus becomes distinct, whilst the delicate envelope is rendered so faint as to be scarcely visible; but its presence may be still made obvious by adding solution of iodine, which gives it colour and opacity. If strong acid be used, the envelope will at length be dissolved entirely. Pure water extracts the colour and distends the vesicle by imbibition, altering its shape from oval to round, and making the nucleus more conspicuous. Both the one and the other of these reagents sometimes cause the envelope to burst; the nucleus then escapes, and the structure of the corpuscle is demonstrated still more plainly. These effects are caused by the thinner exterior fluid passing through, by endosmosis, to the thicker matter within the vesicle; and precisely the opposite effect may be produced by immersing the corpuscles in a fluid of a sufficiently high degree of concentration, so as to cause the predominant current to pass from within outwards. Accordingly, on using a strong solution of salt or of sugar, the vesicles will shrink and become thinner; and, no doubt, the variations in plumpness which the corpuscles often naturally present are owing to differences in the degree of concentration of the surrounding liquid. The nucleus (fig. 225,<sup>3</sup>) is rather more than a third of the length of the corpuscles; it appears, especially after being exposed to the action of vinegar, to be composed of tolerably large granules, and, when so treated at least, it is quite free from colour. The envelope appears as an exceedingly fine, homogeneous, and pellucid membrane. The coloured contents of the corpuscle is a pale red matter, very faintly granular; it surrounds the nucleus, and occupies the space between it and the vesicular envelope. The envelope and red matter are obviously of a soft and yielding nature, for the corpuscles alter their shape on the slightest pressure, as is beautifully seen while they move within the vessels; they are also elastic, for they readily recover their original form again. It must be remarked, that the blood corpuscles when



viewed singly appear very faintly coloured, and it is only when collected in considerable quantity that they produce a strong deep red.

A structure consisting of envelope, nucleus, and red matter, as shown in the large blood-disks of amphibia, may be demonstrated in many other instances, and by analogy has been inferred to exist in all, man not excepted. But the existence of a nucleus in the blood corpuscles of man and mammalia is, at best, extremely doubtful; and few inquirers have been able to satisfy themselves of it by actual observation. Hewson and Müller, it is true, believed that they had actually seen the nucleus in the human blood-disk, and that they could demonstrate its existence by the action of water (Hewson), or acetic acid (Müller); but, although the human corpuscle changes its figure and loses its colour when exposed to these agents, and although its pellucid vesicular envelope, and the pale, red, soft substance contained within, can be readily shown, yet some of the most careful observers who have recently inquired into the subject, and among them Mr. Gulliver, with whom my own observations would lead me to concur, profess not to have been able to discover a nucleus by any mode of examination they could devise; others deny its general existence in the human blood corpuscles, but believe it is present in a few of them.

The human blood corpuscles, as well as those of the lower animals, often present deviations from the natural shape, which are most probably due to causes acting after the blood has been drawn from the vessels. Thus, it is not unusual for many of them to appear indented or jagged at the margin, when exposed under the microscope (fig. 224,<sup>3</sup>) and the number of corpuscles so altered often appears to increase during the time of observation. This is, perhaps, the most common change; but they may become distorted in various other ways, and corrugated on the surface; not unfrequently one of their concave sides is bent out, and they acquire a cup-like figure. It is even a question with some observers, whether the biconcave figure which the corpuscles generally present may not be due to a distention of the circumferential part of an originally flat disk. Mr. Gulliver made the curious discovery, that the corpuscles of the Mexican deer and some allied species

present very singular forms, probably in consequence of exposure; the figures they assume are various, but most of them become lengthened and pointed at the ends, and then often slightly bent, not unlike caraway seeds.

The red disks, when drawn from the vessels, have a singular tendency to run together, and to cohere by their broad surfaces, so as to form by their aggregation cylindrical columns, like piles or rouleaus of money, and the rolls or piles themselves join together into an irregular network (fig.

Fig. 226.

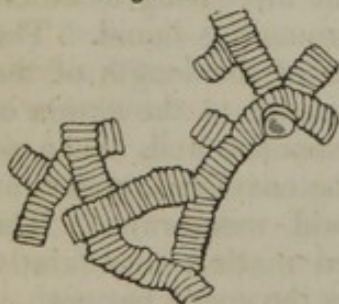


Fig. 226. Red corpuscles collected into rolls (after Henlé).

Fig. 227.

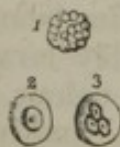

Fig. 227. Pale corpuscles of human blood, magnified about five hundred diameters. 1. Natural aspect. 2 and 3. Acted on by weak acetic acid, which brings into view the single or composite nucleus.



226). In a few moments after this has taken place, a heaving or slowly oscillating motion is observable in the mass, and the rolls may then become broken up, and the corpuscles more or less completely disjoined (Jones). Generally the corpuscles separate on a slight impulse, and they may then unite again. The nature of the attraction exerted between the corpuscles is doubtful; but it may be remarked, that the phenomenon will take place in blood that has stood for some hours after it has been drawn, and also when the globules are immersed in serum in place of liquor sanguinis.

*Pale or Colourless Corpuscles* (fig. 227).—These are comparatively few in number, of a rounded and slightly flattened figure, rather larger in man and mammalia than the red disks, and varying much less than the latter in size and aspect in different animals. They are destitute of colour, finely granulated on the surface, and specifically lighter than the red corpuscles. Water has little effect on them; acetic acid brings speedily into view a nucleus, consisting sometimes of one, but more commonly of two or three, rarely four, large clear granules (fig. 227,<sup>23</sup>); a delicate envelope at the same time comes into view, which becomes distended so as to augment the size of the globule, and is eventually dissolved, the nucleus remaining.

*Liquor Sanguinis, or Plasma*.—This is the pale clear fluid in which the corpuscles are naturally immersed. Its great character is its strong tendency to coagulate when the blood is withdrawn from the circulating current, and on this account it is difficult to procure it free from the corpuscles. Nevertheless, by filtering the slowly coagulable blood of the frog, as was first practised by Müller, the large corpuscles are retained by the filter, while the liquor sanguinis comes through in perfectly clear and colourless drops, which, while yet clinging to the funnel, or after they have fallen into the recipient, separate into a pellucid glassy film of fibrin, and an equally transparent diffuent serum. When human blood is drawn in inflammatory diseases, as well as in some other conditions of the system, the red particles separate from the liquor sanguinis before coagulation, and leave the upper part of the liquid clear. In this case, however, the plasma is still mixed with the pale corpuscles, which, being light, accumulate at the top. On coagulation taking place in these circumstances, the upper part of the clot remains free from redness, and forms the well-known "buffy-coat" so apt to appear in inflammatory blood. Now, in such cases, a portion of the clear liquor may be taken up with a spoon, and allowed to separate by coagulation into its fibrin and serum, so as to demonstrate its nature. Dr. A. Buchanan has pointed out another method of separating the liquor sanguinis from the red corpuscles, which I have repeatedly tried with success: it consists in mixing fresh-drawn blood with six or eight times its bulk of serum, and filtering through blotting paper; the admixture of serum delays coagulation, and a great part of the liquor sanguinis, of course diluted, passes through the filter, and subsequently coagulates.

Coagulated plasma, whether obtained from buffy blood, or exuded on inflamed surfaces, presents, under the microscope, a multitude of fine filaments confusedly interwoven, as in a piece of felt; but these



are more or less obscured by the intermixture of corpuscles and fine granules, the former having all the characters of the pale corpuscles of the blood. The filaments are no doubt formed by the fibrin, as it solidifies in the coagulation of the liquor sanguinis.

Blood may be freed from fibrin by stirring it with a bundle of twigs, which entangle the fibrin as it concretes.

#### COAGULATION OF THE BLOOD.

In explaining the constitution of the plasma, we have been obliged so far to anticipate the account of the coagulation of the blood. The following are the phenomena which usher in and which accompany this remarkable change. Immediately after it is drawn, the blood emits a sort of exhalation, the "halitus," having a faint smell; in about three or four minutes a film appears on the surface, quickly spreading from the circumference to the middle; a minute or two later the part of the blood in contact with the inside of the vessel becomes solid, then speedily the whole mass; so that, in about eight or nine minutes after being drawn, the blood is completely gelatinized. At about fifteen or twenty minutes, or it may be much later, the jelly-like mass begins to shrink away from the sides of the vessel, and the serum to exude from it. The clot continues to contract, and the serum to escape, for several hours, the quickness and extent of the process varying exceedingly in different cases; and, if the serum be poured off, more will usually continue to drain slowly from the clot for two or three days.

The nature of the change which takes place in the coagulation of the blood has been already spoken of; it is essentially owing to the coagulation of the liquor sanguinis, the fibrin of that liquid separating in form of a solid mass, which involves the corpuscles, but allows the serum to escape from it in greater or less quantity. But although the solidification of the fibrin, and formation of a red clot, would undoubtedly take place independently of any co-operation on the part of the corpuscles, still it must not be forgotten that, in point of fact, the red disks are not altogether passive while coagulation goes on; for they run together into rolls, as already described, and the circumstance of their doing so with greater or with less promptitude materially affects the result of the coagulating process. Thus, there seems good reason to believe that, as H. Nasse has pointed out, one of the causes, and in inflammatory blood probably the chief cause, of the production of the buffy coat, is an exaltation of the natural tendency of the red disks to run together, whereby, being more promptly and more closely aggregated into compact masses, they more speedily subside through the liquid plasma, leaving the upper part of it colourless by the time coagulation sets in; and Mr. Jones has drawn attention to another influential circumstance derived from the same source, namely, the more rapid and close contraction of the network, or spongework, as he terms it, into which the little rolls of corpuscles unite, and the consequent expulsion of great part of the liquor sanguinis from its meshes before the fibrin solidifies, the mass of aggregated corpuscles naturally tending to the lower part of the vessel, whilst the expressed plasma, being lighter, accumulates at the top. Of course, it is not meant to deny that more



tardy coagulation of the blood would produce the same result as more speedy aggregation of the corpuscles; it is well known, indeed, that blood may be made to show the buffy coat by delaying its coagulation, but buffed inflammatory blood is not always slow in coagulating.

Various causes accelerate, retard, or entirely prevent the coagulation of the blood; of these, it will here suffice to indicate the more important and best ascertained.

1. Temperature.—Cold delays, and at or below 40 degrees Fahr. prevents coagulation; but even frozen blood, when thawed and heated again, will coagulate. Moderate elevation of temperature above that of the body promotes coagulation.

2. Coagulation is accelerated by free exposure of the blood, even *in vacuo*, but especially by exposure to air and various other gases; also, but in a less degree, by contact with foreign bodies generally. On the other hand, the maintenance of its fluidity is favoured by exclusion of air, and by contact with the natural tissues of the body, so long at least as these retain their usual vital and physical properties.

3. Cessation of the blood's motion *within the body* favours coagulation, probably by arresting those perpetual changes of material, both destructive and renovative, to which it is naturally subject in its rapid course through the system. Agitation of *exposed* blood, even *in vacuo*, accelerates coagulation, most probably by increasing its exposure.

4. Water, in a proportion not exceeding twice the bulk of the blood, hastens coagulation; a larger quantity retards it. Blood also coagulates more speedily when the serum is of low specific gravity, indicative of much water in proportion to the saline ingredients.

5. Almost every substance that has been tried, except caustic potash and soda, when added to the blood *in minute proportion*, hastens its coagulation; although many of the same substances, when mixed with it in somewhat larger quantity, have an opposite effect. The salts of the alkalies and earths, added in the proportion of two or three per cent. and upwards, retard, and, when above a certain quantity, suspend or prevent coagulation; but, though the process be thus suspended, it speedily ensues on diluting the mixture with water. The caustic alkalies permanently destroy the coagulability of the blood. Acids delay or prevent coagulation. Opium, belladonna, and many other medicinal agents from the vegetable kingdom, are said to have a similar effect; but the statements of experimenters by no means entirely agree respecting them.

6. Certain states of the system.—Faintness occasioned by loss of blood favours coagulation; states of excitement are said to have, though not invariably, the opposite effect. Impeded aëration of the blood in disease, or in suffocative modes of death, makes it slow to coagulate. So also in cold-blooded animals, with slow circulation and low respiration, the blood coagulates less rapidly than in the warm-blooded; and, among the latter, the tendency of the blood to coagulate is strongest in birds, which have the greatest amount of respiration and highest temperature.



7. Coagulation commences earlier, and is sooner completed, in arterial, than in venous blood. Dr. Nasse finds that woman's blood begins to coagulate nearly two minutes sooner than that of the male sex.

In general, when blood coagulates quickly, the clot is more bulky and less firm, and the serum is less effectually expressed from it; and causes which affect the rapidity of coagulation will also occasion differences in the proportion of the moist clot to the exuded serum.

There is no sufficient evidence of evolution of heat or of disengagement of carbonic acid from blood during its coagulation, which some have supposed to occur.

#### CHEMICAL COMPOSITION OF THE BLOOD.

The blood is slightly alkaline; it has been found that a drachm of blood is capable of saturating more than a drop of vinegar. Carbonic acid, oxygen and nitrogen gases, may be extracted from it in proportions which differ in arterial and venous blood, and which will be subsequently given. On being evaporated, 1000 parts of blood yield, on an average, about 790 of water, and 210 of solid residue.

It has been ascertained by analysis that blood has the same ultimate composition as flesh; an observation which is obviously of great interest in reference to the office performed by the blood in nutrition. A comparative examination of dried ox-blood and dried flesh (beef), by Playfair and Bœckmann, gave the following mean result:

	Flesh.	Blood.
Carbon . . . . .	51.86	51.96
Hydrogen . . . . .	7.58	7.25
Nitrogen . . . . .	15.03	15.07
Oxygen . . . . .	21.30	21.30
Ashes . . . . .	4.23	4.42

Deducting the ashes, or inorganic matter, the composition of the organic part is such as corresponds with the formula  $C_{48}, H_{39}, N_6, O_{15}$ .

*Red Corpuscles.*—These consist, as already stated, of envelope, red contents, and, in many animals, a nucleus. The nucleus is, by some writers, considered to be of the nature of fibrin; but others have likened it to coagulated albumen, from the manner in which it withstands the action of acetic acid. The envelope approaches most to fibrin in its characters. The included red matter consists of two substances,—one named *globulin*, of itself colourless, and very nearly allied to albumen in its nature; the other, a colouring principle named *hæmatin*, or *hæmatosin*, which imparts redness to the first. These may be separated by the following process.

Blood deprived of fibrin by stirring is mixed with at least four times its bulk of saturated solution of sulphate of soda, and thrown on a filter; a few of the corpuscles pass through with the liquid, but the greater part remain on the filter in form of a moist red mass, named the *cruor*. This is boiled with alcohol slightly acidulated with sulphuric acid; the hæmatin is thereby dissolved, while the colourless globulin remains behind in combination with part of the sulphuric acid. Carbonate of ammonia is then added to the acid solution of hæmatin while it is yet hot, to remove the sulphuric acid, and, after being cleared by filtration from



sulphate of ammonia, and a little globulin which is precipitated, the liquor is evaporated to a twelfth of its bulk; it then deposits the hæmatin in form of a dark brown or almost black powder, from which a minute proportion of fat may be extracted by means of ether.

*Hæmatin*, as obtained by the above process, is insoluble in water, alcohol, and ether; but it readily dissolves in any of these liquids after being mixed with potash, soda, or ammonia, forming deep red solutions. It dissolves also in alcohol, to which an acid has been added, but its acid combinations are insoluble in water. When burned, it yields nearly ten per cent. of peroxide of iron, representing near seven per cent. of iron. According to Mulder, it is composed of carbon 65·84, hydrogen 5·37, nitrogen 10·40, oxygen 11·75, and iron 6·64; or  $C_{44}, H_{22}, N_3, O_6, Fe$ .

Chemists have differed in opinion as to the condition in which iron exists in the hæmatin: some have supposed that the metal enters into the formation of the organic compound, and holds the same rank in its constitution as the carbon, hydrogen, and other constituents; but others conceive that it is in the state of oxide or salt, and, as such, combined or mixed with the organic matter, in a similar manner, perhaps, as oxides and salts may be combined with albumen. An experiment of Scherer seems conclusive against the former view, and shows that the iron, though a constant ingredient in the red corpuscle, is not an essential constituent of the hæmatin. By treating cruor with sulphuric acid, the chemist named succeeded in entirely separating the iron from it, and after this it nevertheless imparted an intensely red colour to alcohol. This fact also proves that the red colour of the blood is not due to iron, as some have believed.

*Globulin*.—When the hæmatin has been extracted from the blood corpuscles by the foregoing method, the globulin remains in combination with sulphuric acid. It is a protein compound, agreeing with albumen in composition, and in all its properties, except the two following, viz., its insolubility in serum, that is, in a saline solution which holds albumen dissolved; and, secondly, its coagulation, by heat, in form of a granular mass, different in aspect from coagulated albumen. Henlé suggests that both peculiarities may be due to the circumstance, that the albuminous matter is enclosed, and, in some degree, protected, by the envelopes of the corpuscles, which remain after extraction of the hæmatin; and he thinks that globulin is probably nothing but albumen with the membranous envelopes (and nuclei, when present,) of the blood particles. Lecanu and Liebig consider it albumen.

The *cruor*, or matter of the red corpuscles, which consists of the globulin and hæmatin together, may be dissolved in water; and its solution, which contains the envelopes in suspension, coagulates by a heat of 181 degrees. Its effects with reagents, both in its soluble and coagulated state, resemble those of albumen under like circumstances. Berzelius reckons the relative proportions of globulin and hæmatin as 94·5 of the former, and 5·5 of the latter. The corpuscles are supposed also to contain a solid phosphoretted fat in small quantity, but its proportion has not been determined. 100 parts of dry cruor yield by calcination about 1·3 of brown alkaline ashes, which consist of carbonate of soda with traces of phosphate 0·3, phosphate of lime 0·1, lime 0·2, subphosphate of iron 0·1, peroxide of iron 0·5, carbonic acid and loss 0·1.



The red corpuscles form by far the largest part of the organic matter in the blood: their proportion may be ascertained by filtering beat blood mixed with solution of Glauber's salt, as already mentioned; or by weighing the dried clot, and making allowance for the fibrin it contains. From Lecanu's determinations we may reckon the amount of the corpuscles as about 120 or 130 parts in 1000 of blood. Simon gives a lower estimate; but, apart from differences due to the methods of determining it, the quantity is really subject to great fluctuation.

Denis and Lecanu state that, as a general rule, the proportion of red particles is greater in the blood of the male sex than in that of the female, whilst the proportion of albumen is about the same in both. Lecanu gives the following mean result, derived from numerous analyses, exhibiting the proportion of crassamentum and water in the blood of the two sexes. No deduction is made for the fibrin; but, considering its small relative quantity, any possible variation in it cannot materially affect the general conclusion.

	Male.		Female.
Crassamentum, from	115.8 to 148	- - -	68.3 to 129.9
Water	- - - 778 to 805	- - -	790 to 853.

He found the following differences according to temperament:

	Male.		Female.
Sanguine temperament	- - - 136.4	- - -	126.1
Lymphatic temperament	- - - 116.6	- - -	117.3

As regards age, Denis found the proportion of crassamentum greatest between the ages of 30 and 40. Sudden loss of blood rapidly diminishes the proportion of the crassamentum. In two women, who had suffered from uterine hemorrhage, the crassamentum amounted to only 70 parts in 1000. The same effect may be observed to follow ordinary venesection. In a person bled three times in one day, Lecanu found in the first drawn blood 139, and in the last only 76 parts of crassamentum in the 1000. This effect may be produced very suddenly after a bleeding. Prevost and Dumas bled a cat from the jugular vein, and found 116 parts of crassamentum in 1000, but, in blood drawn five minutes afterwards, it was reduced to 93. The sudden loss of blood probably causes a rapid absorption of serous and watery fluid into the vessels, and thus diminishes the relative amount of the red particles. It is found that the blood of warm-blooded animals is richer in crassamentum than that of the cold-blooded; and, among the former, the proportion is highest in the class of birds.

*Liquor Sanguinis.*—The fluid part of the blood, as already described, separates spontaneously into fibrin and serum. The fibrin may be obtained by stirring the blood as soon as possible after it is drawn, or by washing the crassamentum with water, to free it from cruor. Procured in either of these ways, the fibrin contains pale corpuscles and a small portion of fat. From dried fibrin of healthy human blood, Nasse obtained near 5 per cent. of fat and still more from the fibrin of buffy blood. The proportion of fibrin in the blood does not exceed  $2\frac{1}{2}$  parts in 1000; indeed, according to the greater number of observers, it is not more than 2<sup>1</sup>. As a general rule, the quantity is somewhat greater in arterial than in venous blood, and it is increased in certain states of the body, especially in inflammatory diseases and in pregnancy. Nasse thinks that the whole fibrin cannot be separated from the blood by the processes employed, for he believes that a portion remains suspended in the liquid in form of minute microscopic scales or films.



Denis pointed out, that fibrin obtained from the coagulum of venous blood, if quite recent, and not previously much exposed to the air, is capable of being slowly dissolved in a slightly-heated solution of nitre. Scherer and Nasse have confirmed this statement, and the latter finds that fibrin got by stirring may also be dissolved in the same way, provided it is quite fresh. On the other hand, nitre does not dissolve fibrin of arterial blood, nor fibrin that has been some time exposed to the air, from whatever source it may be derived; nor, according to Scherer, the fibrin of the buffy coat. The properties of pure fibrin have been already described (p. 44).

*Serum.*—This is a thin and usually transparent liquid, of a pale yellowish hue; its specific gravity ranges from 1025 to 1030, but is most commonly between 1027 and 1028 (Nasse). It is always more or less alkaline. When heated, it coagulates, in consequence of the large quantity of albumen it contains; and, after separation of the albumen, a thin saline liquid remains, sometimes named “serosity.” The following ingredients are found in the serum.

*Albumen.*—The properties of this substance have been already stated; its quantity may be determined by precipitating it in the solid form by means of heat or alcohol, washing with distilled water, drying, and weighing the mass. Its proportion is about 80 in 1000 of serum, or nearly 70 in 1000 of blood.

*Casein.*—A minute quantity of casein was detected in the serum of ox’s blood by Gmelin; it has also been found in human blood.

*Fatty compounds.*—It has been already stated that the red corpuscles and the fibrin yield a minute quantity of fat; but the greatest part of the fat of the blood remains in the serum, partly dissolved, and partly diffused in the liquid. It may be separated by gently agitating the serum with about a third of its bulk of ether, or by evaporating the serum and digesting the dry residue in ether, or in boiling alcohol. The turbid milky aspect which serum often exhibits, is in most cases due to a redundancy of fat, and may accordingly be removed by agitation with ether.

The fatty matters of the blood are of various kinds, viz. *cholesterin*, *serolin*, and the ordinary saponifiable fats of the body (*margarates* and *oleates*); also, according to Berzelius and Lecanu, a *phosphuretted fat*, similar to that found in the brain. Berzelius, indeed, is disposed to think that the blood contains every variety of fat that is found in other parts of the body. Lecanu could not obtain the phosphuretted fat from either the serum or the fibrin, and Berzelius therefore supposes that it is associated with the red corpuscles; he also states that the fat extracted from the fibrin is different from ordinary fat. The properties of most of these fatty principles have been already discussed (page 47). The usual quantity of fat of all kinds in 1000 parts of blood is stated by Lecanu to be 5.15, by Simon 2.3, and by Nasse 2.0.

*Extractive matters.*—When the serum has been freed from albumen by coagulation, and from fat by ether, and is evaporated to dryness, a yellowish or brown mass remains, consisting of organic matters mixed with salts; the former belonging principally to the ill-defined class of substances denominated “extractive matters.”

To examine them, Berzelius directs that the mass should be first treated with anhydrous alcohol; this takes up a substance which he thinks is probably derived (by decomposition or some other change) from the albuminous ingredients of the blood. Next, rectified spirit (of .833 spec. grav.) is to be used, which dissolves from the residue chlorides of sodium and potassium, and lactate of soda,



together with the heterogeneous mixture of extractive matters known under the name of *osmazome*, of which an account has been already given (page 47). The residual mass, after this, contains alkaline carbonates, phosphates, and sulphates, and one or more animal substances, in small quantity. Among the latter may be noticed,—1, one that is precipitable by tannin, and which, like the one taken up by the pure alcohol, appears to be derived from the albuminous constituents of the blood: 2, a remnant of coagulated albumen, which has been kept in solution by free or carbonated alkali, but is thrown down when the alkali is saturated by acetic acid. Lecanu found, in 1000 parts of blood, 1·8 parts of extractive soluble in spirit, and 1·6 of extractive soluble in water only.

*Colouring principles.*—A yellow or greenish-yellow colouring principle, which appears to be the same as that of the bile, has been found by various chemists in the blood of persons affected with jaundice, and, according to Lecanu and Denis, a certain amount of it may be detected even in healthy blood.

Sanson extracted a blue colouring matter from bullocks' blood; but his observation seems not to have been repeated by other chemists. He diluted the beat blood (red particles and serum) with water, precipitated it by acetate of lead, and boiled the dried precipitate in alcohol, which deposited the blue matter on cooling.

*Odoriferous matters.*—Denis describes three. 1. One combined with fat, and of a garlic smell. 2. One supposed to depend on volatile oil, with an odour said to be of peculiar character in each species of animal, and to be heightened by adding sulphuric acid to the blood. 3. One of a variable character, derived from the food.

*Urea.*—This substance, which accumulates in the blood of animals after extirpation of the kidneys or ligature of the renal arteries, as well as in certain diseases, has been found in very minute quantity in the healthy blood of the ox and of the calf, by Marchand and Simon.

*Salts.*—1. Having soda and potash as bases, combined with lactic, carbonic, phosphoric, sulphuric, and fatty acids. Also chlorides of sodium and potassium, the former in large proportion. 2. Lactate of ammonia. 3. Salts with earthy bases, viz., lime and magnesia with phosphoric, carbonic, and sulphuric acids.

The earthy salts are for the most part associated with the albumen, but partly with the crassamentum. As they are obtained by calcination, it has been suspected that the phosphoric and sulphuric acids may be in part formed by oxidation of the phosphorus and sulphur of the protein compounds. Nasse found in 1000 parts of blood 4 to 7 of alkaline, and 0·53 of earthy salts.

*Gaseous contents.*—In a well-exhausted receiver of an air-pump, blood yields carbonic acid, and, according to Magnus, also oxygen and nitrogen gases. Carbonic acid may also be extracted from it by exposing it for some time to a stream of hydrogen. Chemists, however, are by no means all satisfied that the gas obtained by any of these methods exists in the blood in a free state.

Liebig brings arguments to prove that the carbonic acid extricated *in vacuo* is derived from bicarbonate of soda; a solution of which, it is well known, yields up a portion of its carbonic acid when atmospheric pressure is removed from it. It is also worthy of remark that hydrogen extracts more carbonic acid when the blood has stood for some time than when it is perfectly recent; from which it is suspected that the carbonic acid evolved in that process may have been liberated by some reaction of the ingredients of the blood on each other.

Magnus found that, when arterial and venous blood were submitted to the air-



pump, the former afforded all the three gases in larger proportion than the latter, but that the ratio of the carbonic acid to the oxygen was greater in the venous than in the arterial. The actual amount was very variable, but the mean quantities (by volume) obtained from 100 parts of blood were as under, viz.

Gases.	From arterial blood.	From venous blood.
Carbonic acid . . . . .	7.10	5.35
Oxygen . . . . .	2.65	1.21
Nitrogen . . . . .	1.35	1.13
	<hr/> 11.10	<hr/> 7.69

There is, however, some ambiguity as to the oxygen, since neither Dr. J. Davy nor Ensclut could obtain that gas from either kind of blood. Both these experimenters obtained more carbonic acid from venous than from arterial blood.

The following statement of the mean composition of human venous blood is from Lecanu. (*Etudes chimiques sur le sang humain*, Paris, 1837.)

Free oxygen, nitrogen, and carbonic acid	}	10.98	}	Serum . . . . .	869.15
Extractive matters					
Fatty matters, viz.					
Phosphuretted fat					
Cholesterin					
Serolin					
Oleic and margaric acids (free)					
Ditto combined with soda					
Volatile odoriferous oily acid (combined with a base).					
Salts, viz.					
Chloride of sodium	}	67.80	}	Crassamentum	130.85
" potassium					
Hydrochlorate of ammonia					
Carbonate of soda					
" lime					
" magnesia					
Phosphate of soda					
" lime					
" magnesia					
Lactate of soda					
Yellow colouring matter	}	67.80	}		
Albumen . . . . .					
Water . . . . .					
Fibrin . . . . .					
Hæmatin . . . . .	}	2.27	}		
Albumen (globulin) 125.63					
	Corpuscles	127.90			
					1000

*Differences between Arterial and Venous blood.*—The different effects they are capable of producing in the living body are not considered here. Arterial blood is, according to most observers, near two degrees Fahr. warmer than venous. It is said to coagulate sooner (Nasse). Its specific gravity is a very little lower than that of venous blood, and it contains a very little more water (about 5 parts in 1000) in proportion to its solid ingredients (Nasse, Simon, and Hering). The amount of albumen, fat, extractive matter, and salts taken together scarcely differs in the two kinds of blood. The fibrin is somewhat more abundant in arterial blood, and differs from that of venous in being insoluble in nitre. The amount of red corpuscles is said, by



Lecanu and Letellier, to be greater in arterial blood; but this is denied by Nasse and others. The red corpuscles of venous blood contain more hæmatin in proportion to their globulin than those of arterial blood (Simon). Marcet and Macaire found, by ultimate analysis, more oxygen and hydrogen, and less carbon, in the elementary composition of arterial than in that of venous blood; Michaelis maintained that there was a larger proportion of oxygen in the red corpuscles of arterial blood, but not in its other ingredients. Berzelius doubts the correctness of both statements. The alleged difference in the proportion of gases, and the discrepancies of the observations on that head, have been already mentioned. The most striking and well-known difference between the two bloods is in their colour. Venous blood is rendered bright red by exposure to atmospheric air, or to oxygen. This effect is greatly promoted by the saline matter of the serum, and may be accelerated by adding salts or sugar to the blood, especially by carbonate of soda and by nitre; but, according to Nasse, the presence of serum, or of saline matter, is not indispensable to its production, for although the clot, when washed free from serum, does not redden on exposure to oxygen, yet he found that the fresh clot, or red matter of the blood, when deprived of serum, and dissolved or diffused in water, still becomes perceptibly brighter and more transparent on exposure to oxygen, though the effect is slow in appearing, whilst the colour is deepened, and the solution acquires a turbid aspect, on being agitated with carbonic acid. Salts added to dark blood, without exposure to air or oxygen, cause it to assume a red colour, which, however, Nasse maintains, does not equal in brightness the arterial red. Exposure to carbonic acid darkens arterial blood. The immediate cause of the change of colour is uncertain; it has with most probability been ascribed to a change in the state of aggregation of the colouring matter, and in the figure of the corpuscles.

*Portal blood.*—The blood of the portal vein is said to contain proportionally less fibrin than other blood, more fat, and, though perhaps not constantly, more hæmatin and more carbonated alkali.

#### FORMATION OF THE BLOOD CORPUSCLES.

In the early embryo of the frog, (in which, perhaps, the steps of the process are best ascertained,) at the time when the circulation of the blood commences, the corpuscles of that fluid appear as rounded cells filled with granular matter, and of larger average size than the future blood corpuscles. The cells in question have an envelope so delicate, that it is rather inferred to exist from the regular limitation of their outline than actually seen. They contain, concealed in the midst of the granular mass, a pellucid globular vesicle, which usually presents one or two small clear specks, situated eccentrically. The granular contents consist partly of fine molecules, exhibiting the usual molecular movements; and partly of little angular plates, or tablets, of a solid substance, probably of a fatty nature. After a few days, most of the cells have assumed an oval figure, and are somewhat reduced in size; the envelope has become more consistent, and can now be readily distinguished; and the granular matter is greatly diminished in quantity, so that the vesicular nucleus is conspicuous. Now, also, the blood corpuscles, previously colourless, have acquired a yellowish or faintly red colour. In a further stage, the already oval cell is flattened, the granules entirely disappear, the colour is more decided, and, in short, the blood corpuscle acquires its permanent characters. From this description it will be seen, that the blood cells which first appear, agree in nature with the cleavage cells (described at



page 60), and their production is probably connected with the process of cleaving, which is known to take place in the frog's ovum. The different parts of the embryo in its early condition, the heart, for example, are for a time entirely composed of cells of the same kind, and all have probably a common origin.

In the egg of the bird, the first appearance of blood corpuscles, as well as of blood-vessels, is seen in the blastodermis, or germinal membrane, a structure formed by the extension of the cicatrix in the early stages of incubation. The commencing embryo, with its simple tubular heart, is seen in the centre of this circular membrane, and blood-vessels appear over a great part of its area. These first vessels, therefore, though connected with the heart, and intended to convey nutriment to the embryo, are formed in an exterior structure; but in a somewhat later stage, blood-vessels are developed in various textures and organs within the body. The formation of blood corpuscles in the vascular area of the blastodermis, has been sedulously investigated by various inquirers: and from their concurrent statements we learn, that these corpuscles, at a certain stage of their progress, are rounded cells, larger than the blood-disks of the adult. They contain a granular nucleus, and are quite devoid of colour. These spheroidal colourless vesicles in their further advancement become flattened, but at first with a circular outline, and at length assume an oval figure. While undergoing these changes of form, they acquire a red colour, which is at first faint and yellowish, but gradually deepens; their envelope, too, becomes thicker and stronger.

As to the earlier part of the process,—the production of the above-mentioned round cells, whose subsequent conversion into coloured oval disks has just been described,—the statements of observers differ so widely, that no consistent account can be founded on them. By one\* it has been imagined, that they are formed from the oil globules known to exist in the yolk, which serve as nuclei, and become enclosed in envelopes. Reichert† supposes that they are produced within parent cells, which proceed from the central part of the yolk to the germinal membrane, generate round nucleated blood corpuscles in their interior, and discharge them, by rupture, into the blood-vessels. Another inquirer‡ finds, that the blood corpuscle begins as a small granule, which rapidly enlarges into a spherical cell, and separates into nucleus and envelope. Lastly, Prevost and Lebert§ declare, that the blood corpuscles, even on their first appearance, are round, slightly flattened, colourless, nucleated cells, which differ from all other cells in the ovum; and they could find no transitional forms indicating a transformation of any of the pre-existing cells of the ovum into these early blood-cells.

In the embryo of mammiferous animals, the corpuscles which first circulate in the blood-vessels, are round, nucleated, colourless cells. In this condition they were observed by Wagner,|| in very young embryos of rabbits, bats, and sheep; and Bischoff,¶ who confirmed the observation as regards the rabbit's embryo, remarks, that the primary blood-cells do not differ in appearance from the common primary cells, of which all the solid parts of the embryo are at first composed. This last-mentioned observation is important, and entirely agrees with what has been seen in the frog's ovum. The primary blood-cells are much larger than the future corpuscles—for the most part double their size;—they acquire a reddish colour, and are gradually converted into, or, at least, are succeeded by, smaller disk-shaped corpuscles without nuclei, possessing all the characters of the blood-disks of the adult. The mode in which the change or substitution is effected, has not been traced.

Throughout life the mass of blood is subject to continual change; a portion of it is constantly expended, and its place taken by a fresh supply. It is certain, that the corpuscles are not exempted from this general change, but it is not known in what manner they are consumed, nor by what process new ones are continually formed to supply the place of the old. With regard to the latter question, it may be stated, that the explanation which has hitherto found most favour

\* C. H. Schultz, *System der Circulation*, p. 33.

† *Das Entwicklungsleben im Wirbelthierreich*.

‡ Macleod, *Edin. Journal of Med. Sc.* Sept. 1840.

§ *Annales des Sc. Nat.* 1844, p. 265.

|| *Nachtraege zur vergleichenden Physiologie des Blutes*, p. 36.

¶ *Entwicklungsgeschichte des Kanincheneyes*, p. 135.



with physiologists, is, that the corpuscles of the chyle and lymph passing into the sanguiferous system, become the pale corpuscles of the blood; and that these last become flattened, acquire colouring matter, lose their nuclei, and are so gradually converted into red disks. At the same time it is not improbable, that pale corpuscles may be also generated in the blood-vessels, independently of those derived from the chyle and lymph.

---

## BLOOD-VESSELS.

THE blood, from which the solid textures immediately derive material for their nourishment, is conveyed through the body by branched tubes named blood-vessels. It is driven along these channels by the action of the heart, which is a hollow muscular organ placed in the centre of the sanguiferous system. One set of vessels, named *arteries*, conduct the blood out from the heart and distribute it to the different regions of the body, whilst other vessels named *veins* bring it back to the heart again. From the extreme branches of the arteries the blood gets into the commencing branches of the veins or revehent vessels, by passing through a set of very fine tubes which connect the two, and which, though not abruptly or very definitely marked off from either, are generally spoken of as an intermediate set of vessels, and by reason of their smallness are called the *capillary* (*i. e.* hair-like) *vessels*, or, simply, *the capillaries*.

The conical hollow muscular heart is divided internally into four cavities, two placed at its base, and named auricles, and two occupying the body and apex, named ventricles. The auricles are destined to receive the returning blood from the great veins, which accordingly open into them, and to deliver it into the ventricles; whilst it is the office of the latter to propel the blood through the body. The ventricles have therefore much thicker and stronger sides than the auricles, and the great arterial trunks lead off from them. Each auricle opens into the ventricle of the same side, but the right auricle and ventricle are entirely shut off from those of the left side by an impervious partition placed lengthwise in the heart.

The blood passes out from the left ventricle by the main artery of the body, named the aorta, and is sent through the numerous subordinate arteries, which are branches of that great trunk, to the different parts of the system, then, traversing the capillaries, it enters the veins, and is returned by two great venous trunks, named the superior and inferior venæ cavæ, to the right auricle. In passing from the arteries to the veins the blood changes in colour from red to dark and is otherwise altered in quality, and in this condition it is unfit to be again immediately circulated through the body. On returning, therefore, to the right side of the heart, the blood, now dark and venous, must re-acquire the florid hue and other though less obvious qualities of arterial blood before it is permitted to resume its course. For this purpose, being discharged by the right auricle into the right ventricle, it is



driven, by the contraction of that ventricle, along the pulmonary artery and its branches to the lungs, where, passing through the capillary vessels of these organs, it is exposed to the influence of the air, and undergoes the requisite change, and having now become florid again, it enters the commencing branches of the pulmonary veins, which, ending by four trunks in the left auricle, convey it into that cavity, whence it is immediately discharged into the left ventricle, to be sent again along the aorta and through the system as before.

The blood may thus be considered as setting out from any given point of the sanguiferous system and returning to the same place again after performing a circuit, and this motion is what is properly termed the *circulation* of the blood. Its course from the left ventricle along the aorta, through the system and back by the venæ cavæ to the right ventricle, is named the *greater* or *systemic circulation*, and its passage through the lungs by the pulmonary artery and pulmonary veins from the right to the left side of the heart, is termed the *lesser* or *pulmonary circulation*; but the blood must go through both the greater and the lesser circulation in order to perform a complete circuit, or to return to the point from which it started. As the vessels employed in the circulation through the lungs have been named pulmonary, so the aorta which conveys the blood to the system at large is named the systemic artery, and the venæ cavæ the systemic veins, whilst the two sets of capillaries interposed between the arteries and veins, the one in the lungs the other in the body generally, are respectively termed the pulmonary and the systemic capillaries.

The blood flows in the arteries from trunk to branches, and from larger to smaller but more numerous tubes; it is the reverse in the veins, except in the case of the *vena portæ*, a vein which carries blood into the liver. This advehent vein, though constituted like other veins in the first part of its course, divides on entering the liver into numerous branches, after the manner of an artery, sending its blood through these branches and through the capillary vessels of the liver into the efferent hepatic veins to be by them conducted to the inferior vena cava and the heart.

The different parts of the sanguiferous system above enumerated may be contemplated in another point of view, namely, according to the kind of blood which they contain or convey. Thus the left cavities of the heart, the pulmonary veins and the aorta or systemic artery, contain red or florid blood fit to circulate through the body; the right cavities of the heart with the venæ cavæ, or systemic veins, and pulmonary artery, on the other hand, contain dark blood, requiring to be transmitted through the lungs for renovation. The former or red-blooded division of the sanguiferous system, commencing by the capillaries of the lungs ends in the capillaries of the body at large, the latter or dark-blooded part commences in the systemic capillaries and terminates in those of the lungs. The heart occupies an intermediate position between the origin and termination of each, and the capillaries connect the dark and the red set of vessels together at their extremities and serve as the channels through which the blood passes from the one part of the sanguiferous system to the other, and in which it



undergoes its alternate changes of colour, since it becomes dark as it traverses the systemic capillaries and red again in passing through those of the lungs.

#### ARTERIES.

These vessels were so named from the notion that they naturally contained air. This error which had long prevailed in the schools of medicine was refuted by Galen, who showed that the vessels called arteries, though for the most part found empty after death, really contained blood in the living body.

*Mode of Distribution.*—The arteries usually occupy protected situations; thus, after coming out of the great visceral cavities of the body they run along the limbs on the aspect of flexion, and not upon that of extension, where they would be more exposed to accidental injury.

As they proceed in their course the arteries divide into branches, and the division may take place in different modes. An artery may at once resolve itself into two or more branches, no one of which greatly exceeds the rest in magnitude, or it may give off several branches in succession and still maintain its character as a trunk. The branches come off at different angles, most commonly at an acute angle with the further part of the trunk, but sometimes at a right or an obtuse angle, of which there are examples in the origin of the intercostal arteries. The degree of deviation of a branch from the direction of the trunk was supposed to affect the force of the stream of blood, but Weber maintains, that it can produce little or no effect in a system of elastic tubes maintained, like the arteries, in a state of distension.

An artery, after a branch has gone off from it, is smaller than before, but usually continues uniform in diameter or cylindrical until the next secession; thus it was found by Mr. Hunter that the long carotid artery of the camel does not diminish in calibre throughout its length. A branch of an artery is less than the trunk from which it springs, but the combined area or collective capacity of all the branches into which an artery divides, is greater than the calibre of the parent vessel immediately above the point of division. The increase in the joint capacity of the branches over that of the trunk is not in the same proportion in every instance of division, and there is at least one case known in which there is no enlargement, namely, the division of the aorta into the common iliac and sacral arteries; still, notwithstanding this and other possible exceptions, it must be admitted as a general rule that an enlargement of area takes place. From this it is plain, that, the area of the arterial system increasing as its vessels divide, the capacity of the smallest vessels and capillaries will be greatest, and as the same rule applies to the veins, it follows that the arterial and venous system may be represented, as regards capacity, by two cones whose apices (truncated it is true) are at the heart, and whose bases are united in the capillary system. The effect of this must be to make the blood move slower as it advances along the arteries to the capillaries, like the current of a river when it flows in a wider and



deeper channel, and to accelerate its speed as it returns from the capillaries to the venous trunks.

When arteries unite they are said to anastomose or inosculate. Anastomoses may occur in tolerably large arteries, as those of the brain, the hand and foot, and the mesentery, but they are much more frequent in the smaller vessels. Such inosculation admits of a free communication between the currents of blood, and must tend to promote equability of distribution and of pressure, obviating the effects of local interruption.

Arteries commonly pursue a tolerably straight course, but in some parts they are tortuous. Examples of this in the human body are afforded by the arteries of the lips and of the uterus, but more striking instances may be seen in some of the lower animals, as in the well-known case of the long and tortuous spermatic arteries of the ram and bull. In very movable parts like the lips this tortuosity will allow the vessel to follow their motions without undue stretching; but in other cases its purpose is not clear. The physical effect of such a condition of the vessel on the blood flowing along it must be to reduce the velocity by increasing the extent of surface over which the blood moves, and consequently the amount of impediment from friction; still it does not satisfactorily appear why such an end should be provided for in the several cases in which arteries are known to follow a tortuous course. The same remark applies to the peculiar arrangement of vessels named a "rete mirabile," in which an artery suddenly divides into small anastomosing branches which in many cases unite again to reconstruct and continue the trunk. Of such retia mirabilia there are many examples in the lower animals, but, as already remarked, the purpose which they serve is not apparent. The best known instance is that named the rete mirabile of Galen, which is formed by the intracranial part of the internal carotid artery of the sheep and several other quadrupeds.

*Physical Properties.*—Arteries possess considerable strength and a very high degree of elasticity, being extensible and retractile both in their length and width. When cut across, they present, although empty, an open orifice; the veins, on the other hand, collapse, unless when prevented by connexion with surrounding rigid parts.

*Structure.*—In most parts of the body the arteries are inclosed in a sheath formed of dense cellular tissue, and their outer coat is connected to the sheath by filaments of the same tissue, but so loosely that when the vessel is cut across its ends readily shrink some way within the sheath. The sheath may inclose other parts along with the artery, as in the case of that enveloping the carotid artery, which also includes the internal jugular vein and pneumogastric nerve. Some arteries want sheaths, as those for example which are situated within the cavity of the cranium.

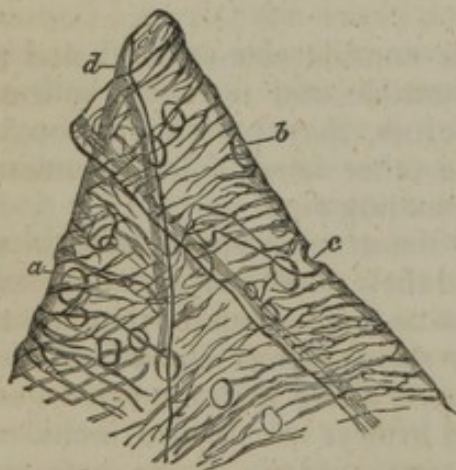
Independently of this sheath, arteries (except those of minute size, whose structure will be afterwards described with that of the capillaries) have been usually described as formed of three coats, named from their relative position, internal, middle, and external; and as this nomenclature is so generally followed in medical and surgical



works, and also correctly applies to the structure of arteries so far as it is discernible by the naked eye, it seems best to adhere to it as the basis of our description, although it will be seen, as we proceed, that some of these coats are found by microscopic examination really to consist of two or more strata differing from each other in texture, and therefore reckoned as so many distinct coats by some recent authorities.

**Internal coat.** This may be raised from the inner surface of the arteries as a fine transparent colourless membrane, elastic but very easily broken, especially in the circular or transverse direction, so that it cannot be stripped off in large pieces. It is very commonly corrugated with very fine and close longitudinal wrinkles, caused most probably by a contracted state of the artery after death. Such is the appearance presented by the internal coat to the naked eye, but by the aid of the microscope it is found to consist of two different structures, namely; 1. A scaly epithelium, forming the innermost part or lining. This is described by Henlé as a thin simple layer of elliptical or irregularly rhombic particles, which are sometimes elongated so as to resemble spindle-shaped fibres. These epithelial elements have round or oval nuclei, which, however, may disappear; indeed the whole structure sometimes becomes indistinct. 2. One or more layers of a peculiar structure, forming the chief substance of the inner coat, and styled by Henlé the "striated," "perforated," or "fenestrated membrane." This consists of a thin and brittle transparent film, forming one or several layers, in which latter case it may be stripped off in small shreds, which have a remarkable tendency to curl in at their upper and lower borders, and roll themselves up as represented in the figure (fig. 228). The films of membrane are

Fig. 228.



Portion of fenestrated membrane from the crural artery, magnified 200 diameters. After Henlé. *a*, *b*, and *c*. Perforations.

marked by very fine pale streaks, following principally a longitudinal direction, and joining each other obliquely in a sort of network. Henlé considers these lines to be reticulating fibres formed upon the membranous layer. This membrane is further remarkable by being perforated with numerous round, oval, or irregularly shaped apertures of different sizes. In some part of the arteries the perforated membrane is very thin, and therefore difficult to strip off; in other situations it is of considerable thickness, consisting of several layers; but it often happens that the deeper layers of this structure, *i. e.*, those farther from the inner surface, lose their membranous

character, and degenerate into a mere network of longitudinal anastomosing fibres, quite similar to fine fibres of elastic tissue; indeed there seems much reason to think that the perforated membrane is merely a form or modification of that tissue. These longitudinal reticulating



fibres are, however, sometimes spoken of as constituting a distinct coat.

**Middle coat.** This consists of distinct fibres disposed circularly round the vessel, and consequently tearing off in a circular direction, although the individual fibres do not form complete rings. The considerable thickness of the walls of the larger arteries is due chiefly to this coat; and, in the smaller ones, it is said to be thicker in comparison with the calibre of the vessel. In the largest vessels it is made up of many layers; thus, upwards of forty have been counted in the aorta, twenty-eight in the carotid, and fifteen in the subclavian artery (Räuschel); and shreds of perforated membrane, similar to that of the inner coat, are often found between the layers. The middle coat is of a tawny or reddish-yellow colour, not unlike that of the elastic tissue, but, when quite fresh, it has a softer and more translucent aspect than the last-named tissue. Its more internal part is often described as redder than the rest, but the deeper tint is probably due to staining by the blood after death. The fibres forming this coat are highly elastic, and were regarded by many, especially among the French anatomists, as being identical in nature with those of the yellow elastic tissue: but it consists in reality of two kinds of fibres, namely, 1st, pale, translucent, soft, flattened fibres, measuring from  $\frac{1}{3000}$ th to  $\frac{1}{300}$  of an inch in breadth, presenting here and there a few elongated nuclei-form corpuscles, and having the other characters of the plain variety of muscular fibres; and, 2dly, fine elastic fibres mixed with the former, and joining together as usual in an irregularly reticular manner. The contractility (vital) of the arteries is due to this coat.

**External coat.** This has usually been described as made up of interwoven filaments of cellular and elastic tissues; but Henlé has correctly pointed out that it consists, in the larger arteries, of two layers of different texture, viz., 1st, an internal stratum of genuine elastic tissue, most obvious in arteries of large calibre, and becoming thinner and at length disappearing in those of small size; 2dly, an outer layer, consisting of ordinary cellular or areolar tissue, in which the filaments are closely interwoven, and in large and middle-sized arteries chiefly run diagonally or obliquely round the vessel; the interlacement of these filaments becomes much more open and lax towards the surface of the artery, where they connect the vessel with its sheath, or with other surrounding parts. This cellular layer is usually of great proportionate thickness in the smaller arteries.

Some arteries have much thinner coats than the rest, in proportion to their calibre. This is strikingly the case with those contained within the cavity of the cranium, and in the vertebral canal; the difference depends on the external and middle coats, which, in the vessels referred to, are thinner than elsewhere.

The coats of arteries receive small vessels, both arterial and venous, named *vasa vasorum*, which serve for their nutrition. The little nutrient arteries do not pass immediately from the cavity of the main vessel into its coats, but are derived from branches which arise from the artery, (or sometimes from a neighbouring artery,) at some dis-



tance from the point where they are ultimately distributed, and divide into smaller branches within the sheath and upon the surface of the vessel before entering its coats. They form a network in the tissue of the external coat, from which a few penetrate into the middle coat, and follow the circular course of its fibres: none have been discovered in the internal coat. Minute venules return the blood from these nutrient arteries, which however they do not closely accompany, and discharge it into the vein, or pair of veins, which usually run alongside the artery.

Arteries are generally accompanied by larger or smaller nerves; and when, in the operation of tying an artery, these happen to be included along with it in the ligature, great pain is experienced; but the vessel itself, when in a healthy condition, is insensible. Nerves are, nevertheless, distributed to the coats of arteries, probably for governing their contractile movements. The nerves come chiefly from the sympathetic, and in a smaller proportion from the cerebro-spinal system. They form plexuses round the larger arteries, and run along the smaller branches in form of fine bundles of fibres, which here and there twist round the vessel, and single nerve-fibres have been seen closely accompanying minute arteries. There is less certainty as to the extent and mode of distribution of the nerves in the arterial coats; some observers state, that filaments may be traced as far as the middle coat; and Valentin describes them as ending there in a plexus.

*Vital properties.—Contractility.* Besides the merely mechanical property of elasticity, arteries are endowed in a greater or less degree with vital contractility, by means of which they can narrow their calibre. This vital contractility, which has doubtless its seat in the soft, pale fibres of the middle coat, does not cause rapid contractions following in rhythmic succession like those of the heart; its operation is, on the contrary, slow, and the contraction produced is of long endurance. Its effect, or its tendency, is to contract the area of the arterial tube, and to offer a certain amount of resistance to the distending force of the blood; and as the contracting vessel will shrink the more, the less the amount of fluid contained in it, the vital contractility would thus seem to adjust the capacity of the arterial system to the quantity and force of the blood passing through it, bracing up the vessels, as it were, and maintaining them in a constant state of tension. In producing this effect, it co-operates with the elasticity of the arterial tubes, but it can be shown that after that has reached its limit of operation the vital contraction can go no further in narrowing the artery. The vital or muscular contractility of the arteries, then, counteracts the distending force of the heart and seems to be in constant operation. Hence it is often named "tonicity," and, so far, justly, but at the same time, like the contractility of other muscular structures, it can, by the application of various stimuli, be artificially excited to more vivid action than is displayed in this natural tonic or balanced state; and, on the other hand, it sometimes relaxes more than the habitual degree, and then the vessels yielding to the distending force of the heart become unusually dilated. Such a remission in their contractile force (taking place rather suddenly) is probably the cause of the turgescence of the small vessels of the skin which occurs in blushing, and the arteries of erectile organs are probably affected in the same manner, so as to permit of an augmented flow of blood into the veins or venous cavities when erection begins.

The vital contractility of small-sized arteries is easily demonstrated in the transparent parts of cold-blooded animals. If the point of a needle be two or three times drawn quickly across one of the little arteries (not capillaries) in the web of a frog's foot placed under the microscope, the vessel will be seen slowly to contract, and the stream of blood passing through it becomes smaller and smaller,



and, by a repetition of the process, may be made almost entirely to disappear. After persisting in this contracted state for some minutes, the vessel will gradually dilate again to its original size. The same effect may be produced by the application of ice-cold water, and also by galvanism, especially when a rapid succession of shocks is sent through the vessel by means of a coil, as practised by Edward and Ernest H. Weber.\* Moreover, if one of the small arteries in the mesentery of a frog or of a small warm-blooded animal, such as a mouse (Poiseuille), be compressed so as to take off the distending force of the blood from the part beyond the point where the pressure is applied, that part will diminish in calibre, at first no doubt from its elasticity, and therefore suddenly, but afterwards slowly. This gradual shrinking of an emptying artery after its elasticity has ceased to operate, may be shown also by cutting out the frog's heart or dividing the main trunks of the vessels: it is obviously due to vital contraction.

The contractility of the middle-sized and larger arteries is not so conspicuous, and many excellent observers have failed to elicit any satisfactory manifestation of such property on the application of stimuli to these vessels. Others, however, have observed a sufficiently decided, though by no means a striking degree of contraction slowly to follow mechanical irritation or repeated application of the galvanic wires to these arteries in recently killed animals. To render this effect more evident, my colleague, Dr. C. J. B. Williams, adopted a method of experimenting which he had successfully employed to test the irritability of the bronchial tubes. He tied a bent glass tube into a cut end of an artery, and filled the vessel, as well as the bend of the tube, with water; the application of galvanism caused a narrowing of the artery, the reality of which was made manifest by a rise of the fluid in the tube. Contraction is said also to follow the application of chemical stimulants, but as these may directly corrugate the tissue by their chemical action, the evidence they afford is less satisfactory. Cold causes contraction of the larger arteries, according to the testimony of various inquirers; and, as in the smaller arteries, a gradual shrinking in calibre ensues in these vessels, when the distending pressure of the blood is taken off, by the extinction or impairment of the force of the heart on the approach of death. From the experiments of Dr. Parry, it would appear that the contraction thus ensuing, proceeds considerably beyond what would be produced by elasticity alone, and that it relaxes after death, when vitality is completely extinct, so that the artery widens again, to a certain point, at which it is finally maintained by its elasticity.

## VEINS.

*Mode of distribution.*—The veins are ramified throughout the body, like the arteries, but there are some differences in their proportionate number and size, as well as in their arrangement, which require to be noticed.

In most regions and organs of the body, the veins are more numerous and also larger than the arteries, so that the venous system is altogether more capacious than the arterial, but the proportionate capacity of the two cannot be assigned with exactness. The pulmonary veins form an exception to this rule, for they do not exceed in capacity the pulmonary arteries.

The veins are arranged in a superficial and deep set, the former running immediately beneath the skin, [unaccompanied by arteries,] and thence named subcutaneous, the latter commonly accompanying the arteries, [having the same names,] and called *venæ comites vel satellites arteriarum*. The large arteries have usually one accompanying vein, and the medium-sized and smaller arteries two; but there are exceptions to this rule: thus the veins within the skull and spinal

\* Müller's Archiv. 1847, p. 232.



canal, the hepatic veins, and the most considerable of those belonging to the bones, run apart from the arteries.

The communications or anastomoses between veins of considerable size, are more frequent than those of arteries of equal magnitude.

*Structure.*—The veins have much thinner coats than the arteries, and collapse when cut across or emptied; whereas a cut artery presents a patent orifice. Notwithstanding their comparative thinness, however, the veins possess considerable strength, more even, according to some authorities, than arteries of the same calibre. The number of their coats has been differently reckoned, and the tissues composing them differently described by different writers, and this discrepancy of statement is perhaps partly due to the circumstance that all veins are not perfectly alike in structure. In most veins of tolerable size, three coats may be distinguished, which, as in the arteries, have been named external, middle, and internal. The *external coat* is thin, but strong and tough: it is composed of fibres, and bundles of fibres, of the same nature as those of the cellular and fibrous tissues, interlacing in all directions, with some elastic fibres intermixed. The *internal coat* is less brittle than that of the arteries, and therefore admits of being more easily peeled off without tearing; but in other respects the two are very much alike. That of the veins consists inwardly of an epithelium, as in the arteries, and next to that, of one or more layers of very fine elastic fibres, though not all of equal fineness, forming close longitudinal reticulations, with or without portions of perforated membrane. Between the external and internal coats, are one, two, or even more layers of fibres, which may be said to constitute the *middle coat*. These layers consist of fibres, agreeing in all respects with the white or waved filaments of the cellular or areolar tissue, either quite pure, or mixed in one or other of the layers with a greater or less amount of fibres resembling those of the middle coat of the arteries, that is, having the anatomical characters of the plain muscular fibres. The fibres usually run circularly in one of these layers, and, when another is present, its fibres are longitudinal, oblique, or irregular. According to Dr. Chevers,\* in the deep as well as in some of the superficial veins of the trunk and neck, the middle coat is composed of several layers of circular fibres, with only here and there a few that take a longitudinal course; whilst that of the veins of the limbs, whether superficial or deep, consists of a circular layer, and immediately within that a strong layer of longitudinal fibres. The muscular tissue of the auricles of the heart is prolonged for some way on the adjoining part of the venæ cavæ and pulmonary veins. The veins in the cancelli of bones, those which form the sinuses, or at least the lining of the sinuses of the dura mater, as well as the veins of the cavernous body of the penis, being supported by firm structures, have thinner coats; but it seems to be an error to deny to them all but the internal coat.

The coats of the veins are supplied with nutrient vessels, *vasa vasorum*, in the same manner as those of the arteries. *Nerves* have not been

\* Medical Gazette, 1845, p. 638.



demonstrated in the coats of veins generally; but some observers have succeeded in tracing small branches of nerves on the vena cava inferior, where it passes behind the liver, and filaments, supposed to be nervous, have been seen by Pappenheim on some of the cerebral veins.

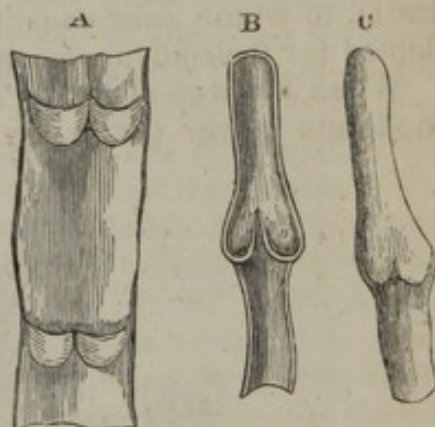
*Vital properties.*—Veins, when in a healthy condition, appear to be almost devoid of sensibility. They possess vital contractility, which shows itself in the same manner as that of the arteries, but is greatly inferior in degree, and much less manifest. The muscular parts of the great veins, near the auricles of the heart, on being stimulated, in recently killed quadrupeds, exhibit quick and decided contractions, somewhat resembling those of the auricles themselves.

*Valves.*—Most of the veins are provided with valves, a mechanical contrivance beautifully adapted to prevent the reflux of the blood. The valves are formed of semilunar folds of the lining membrane, strengthened by some included fibro-cellular tissue, which project obliquely into the vein. Most commonly two such folds or flaps are placed opposite each other (fig. 229, A); the convex border of each, which, according to Haller, forms a parabolical curve, is connected with the side of the vein; the other edge is free, and points towards the heart, or at least in the natural direction of the current of the blood along the vessel, and the two flaps obliquely incline towards each other in this direction. Moreover, the wall of the vein immediately above (or nearer the heart than) the curved line of attachment of the valves, is dilated into a pouch or *sinus* on either side (fig. 229, B a), so that when distended with blood or by artificial injection, the vessel bulges out on each side, and thus gives rise to the appearance of a knot or swelling wherever a valve is placed (as in fig. c). From the above description, it is plain that the valves are so directed as to offer no obstacle to the blood in its onward flow, but that when from pressure or any other cause it is driven backwards, the reflux blood, getting between the dilated wall of the vein and the flaps of the valve, will press them inwards until their edges meet in the middle of the channel and close it up.

The valvular folds are usually placed in pairs, as above described; in the veins of the horse and other large quadrupeds three are often found ranged round the inside of the vessel, but this rarely occurs in the human body. On the other hand, the valves are placed singly in some of the smaller veins, and in large veins single valves are not unfrequently placed over the openings of smaller entering branches; also in the right auricular sinus of the heart there is a single crescentic fold at the orifice of the vena cava inferior, and another more completely covering the opening of the principal coronary vein.

Many veins are destitute of valves. Those which measure less than a line in diameter rarely, if ever, have valves. Valves are wanting in the trunks of the superior and inferior venæ cavæ, in the trunk and branches of the portal vein, in the hepatic, renal, and uterine veins; also in the spermatic veins of the female.

Fig. 229.



Diagrams showing valves of veins. A. Part of a vein laid open and spread out, with two pairs of valves. B. Longitudinal section of a vein, showing the apposition of the edges of the valves in their closed state. C. Portion of a distended vein, exhibiting a swelling in the situation of a pair of valves.



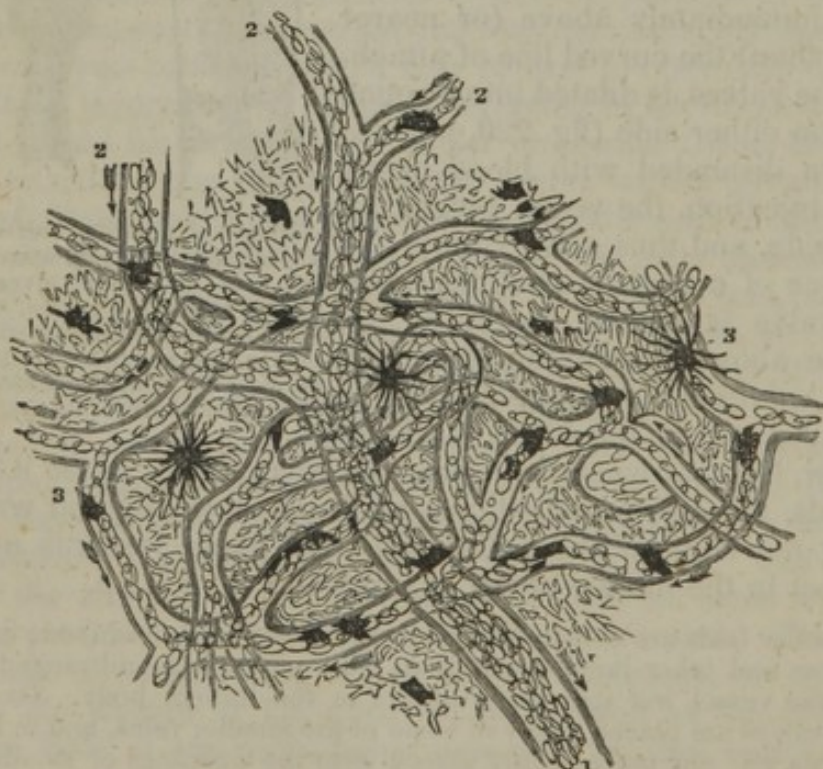
In the male, these last-mentioned veins have valves in their course, and in either sex a little valve is occasionally found in the renal vein, placed over the entrance of the spermatic. The pulmonary veins, those within the cranium and vertebral canal, and those of the cancellated texture of bone, as well as the trunk and branches of the umbilical vein, are without valves. Valves are not generally found, and when present are few in number, in the azygos and intercostal veins. On the other hand, they are numerous in the veins of the limbs (and especially of the lower limbs), which are much exposed to pressure in the muscular movements, or from other causes, and have often to conduct the blood against the direction of gravity. No valves are met with in the veins of reptiles and fishes, and not many in those of birds.

#### CAPILLARY VESSELS.

That the blood passed from the arteries into the veins was of course a necessary part of the doctrine of the circulation, as demonstrated by Harvey; but the mode in which the passage took place was not ascertained until some time after the date of his great discovery. The discovery of the capillary vessels, and of the course of the blood through them, was destined to be one of the first fruits of the use of the microscope in anatomy and physiology, and was reserved for Malpighi (in 1661), to whose rare sagacity these sciences have been so greatly indebted for their advancement.

When the web of a frog's foot is viewed through a microscope of moderate power (as in fig. 230), the blood is seen passing rapidly

[Fig. 230.



A magnified view of the capillary circulation in the web of a frog's foot, magnified 110 diameters.  
1. Trunk of a vein. 2, 2. Its branches. 3, 3. Pigment cells. After Wagner.—C.]

along the small arteries, and thence more slowly through a network of finer channels, by which it is conducted into the veins. These small vessels, interposed between the finest branches of the arteries



and the commencing veins, are the capillary vessels. They may be seen also in the lungs or mesentery of the frog and other batrachians, and in the tail and gills of their larvæ; also in the tail of small fishes; in the mesentery of mice and other small quadrupeds; and generally, in short, in the transparent vascular parts of animals which can readily be brought under the microscope. These vessels can also be demonstrated by means of fine injections of opaque coloured material, not only in membranous parts, such as those above mentioned, but also in more thick and opaque tissues, which can be rendered transparent by drying.

The capillary vessels of a part are most commonly arranged in a network, the branches of which are of tolerably uniform size, though not all strictly equal; thus they do not divide into smaller branches like the arteries, or unite into larger ones like the veins; but the diameter of the tubes, as well as the shape and size of the reticular meshes which they form, differs in different textures. Their prevalent size in the human body may, speaking generally, be stated at from  $\frac{1}{3500}$ th to  $\frac{1}{2000}$ th of an inch, as measured when naturally filled with blood. But they are said to be in some parts considerably smaller, and in others larger than this standard: thus, Weber has measured injected capillaries in the brain, which he found to be not wider than  $\frac{1}{4700}$ th of an inch, and Henlé has observed some still smaller,—in both cases apparently smaller than the natural diameter of the blood corpuscles. The capillaries, however, when deprived of blood, probably shrink in calibre immediately after death; and this consideration, together with the fact that their distension by artificial injection may exceed or fall short of what is natural, should make us hesitate on such evidence to admit the existence of vessels incapable of receiving the red particles of the blood. The diameter of the capillaries of the marrow, or of the medullary membrane, is stated as high as  $\frac{1}{1200}$ th of an inch. In other parts, their size varies between these extremes: it is small in the lungs, small also in muscle; larger in the skin and mucous membranes. According to Mr. Toynbee, the extreme branches of the arteries and the commencing veins in certain parts of the synovial membranes are connected by loops of vessels, which are dilated at their point of flexure to a greater size even than the vessels which they immediately connect, and such can scarcely with propriety be termed capillaries.

There are differences also in the size or width of the meshes of the capillary network in different parts, and consequently in the number of vessels distributed in a given space, and the amount of blood supplied to the tissue. The network is very close in the lungs and in the choroid coat of the eye, close also in muscle, in the skin, and in most parts of the mucous membranes, in glands and secreting structures, and in the gray part of the brain and spinal cord. On the other hand, it has wide meshes and comparatively few vessels in the ligaments, tendons, and other allied textures. In infants and in young persons, the tissues are more vascular than in after life; growing parts, too, are more abundantly supplied with vessels than those which are stationary.

The figure of the capillary network is not the same in all textures.



In many cases the shape of the meshes seems accommodated to the arrangement of the elements of the tissue in which they lie. Thus in muscle, nerve, and tendon, the meshes are long and comparatively narrow, and run conformably with the fibres and fasciculi of these textures (fig. 231). In other parts the meshes are rounded or polygonal, with no one dimension greatly predominating (fig. 232). In the smaller-sized papillæ of the skin and mucous membranes, the vessels of the network are often drawn out into prominent loops.

*Structure of the small-sized vessels and capillaries.*—The capillary vessels have real coats, and are not mere channels drilled in the tissue which they pervade, as has sometimes been maintained. In various parts they are readily separable from the surrounding substance or

[Fig. 231.]

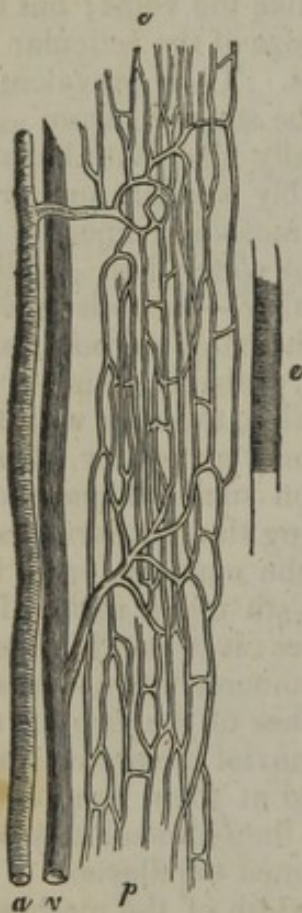


Fig. 232.

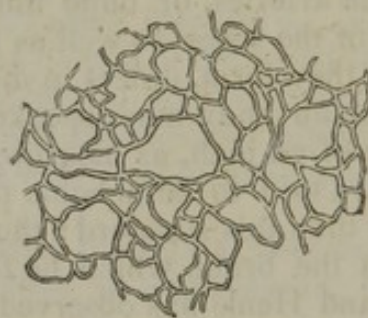


Fig. 233.

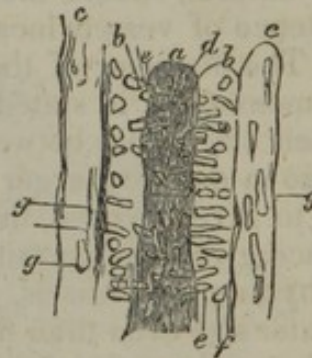

Fig. 231. Capillaries of a small fasciculus of muscular fibres from the neck of the dog:—*a*. Terminal twig of the artery. *v*. Terminal twig of the vein. *p*. Plexus of capillaries. *e*. Elementary fibre, to show the relative size and direction of those to which the capillaries, here represented, are distributed.—Todd and Bowman.]

Fig. 232. Injected capillaries of the skin magnified.

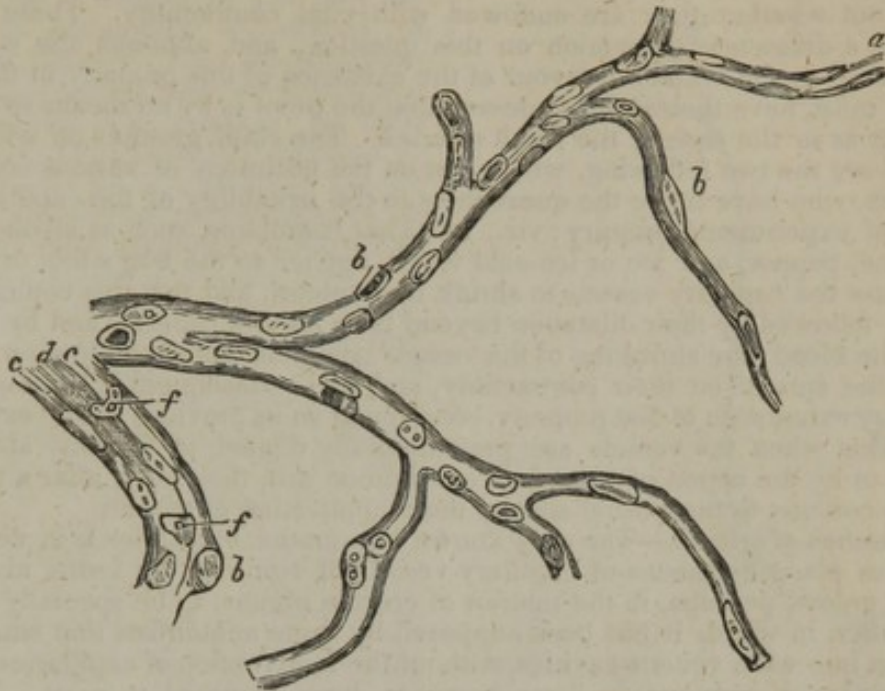
Fig. 233 represents a minute artery, treated with acetic acid, and magnified about 200 diameters (after Henlé). *a*. Cavity of the vessel and longitudinally-disposed nuclei of the primitive membrane; *b*, *b*, middle coat with elongated corpuscles disposed circularly; *e*, one of these corpuscles; *f*, another seen endwise; *c*, *c*. external coat, with longitudinal nuclei, *g*, *g*.

parenchyma, as in the brain and retina, and in such cases it is easy to display their independent membranous parietes. The number, as well as the structure of their coats, differs according to the size of the vessels. Capillaries of a diameter less than  $\frac{1}{2400}$ th of an inch have but a single coat, which is formed of simple homogeneous transparent



membrane, with nucleiform corpuscles attached at intervals on the outer surface, or inclosed as it were in the substance of the membrane (fig. 234). Some of these attached or imbedded corpuscles are round,

[Fig. 234.



Capillary vessels from the pia mater; *a*, calibre of the tube, partly occupied by oval nuclei, alternately arranged lengthways, and epithelial in their character; *b, b, b*, nuclei projecting on the exterior of the tube; *c, c*, walls, and *d*, calibre, of a large branch; *f, f*, oval nuclei, arranged transversely. Magnified 410 diameters. After Henlé.—C.]

others oval, the latter usually lying with their long diameter parallel to the axis of the vessel. In vessels one or two degrees larger (fig. 233,) the structure is more complex. The corpuscles of the primitive simple membrane are more numerous and more lengthened (*a*); an epithelium exists on the inside of the primitive membrane, and on its outside is added a layer (*b, b*) containing nucleiform corpuscles, elongated in a direction across the diameter of the vessel (*e, f*). This layer corresponds with the middle or muscular coat of the arteries, and accordingly, in vessels of somewhat greater size, the characteristic circular fibres of that tunic appear in the layer in question, as well as the nuclei. Outside of all is the cellular coat (*c, c*), marked by longitudinal nuclei (*g, g*). In vessels of  $\frac{1}{60}$ th of an inch in diameter, the striated or perforated membrane may be discovered; but, as formerly stated, this may be wanting altogether. In vessels of still larger size, the primitive membrane, with its longitudinal corpuscles, may have disappeared, and it generally does disappear in the arteries; in other cases, according to Henlé, (on whose statements the present description is founded,) it is converted into or is supplanted by one or more layers of longitudinal fibres, partly pale, flattened, and parallel, and partly of the nuclear or elastic kind. This longitudinal-fibrous coat is seen in many of the veins, between the circular-fibrous coat and the fenestrated membrane, or, when the latter is wanting, immediately under the epithelium. In small arteries and veins, but two or three removes from



the capillaries, no difference in structure can be perceived between the two kinds of vessels.

*Vital properties.*—From the share which the capillaries take in many vital actions, both healthy and diseased, and especially from the part they have been supposed to play in the process of inflammation, much pains has naturally been bestowed to find out whether they are endowed with vital contractility. There is still, however, a difference of opinion on this question; and, although the weight of evidence is, on the whole, in favour of the existence of this property in the capillaries, it must, nevertheless, be confessed that the proof is by no means so positive and clear as in the case of the small arteries. The chief grounds on which it is affirmed are the two following, which rest on the testimony of various competent observers, who have made the question as to the irritability of the capillaries the subject of experimental inquiry; viz., 1st. That stimulants, such as alcohol, oil of turpentine, pepper, and ice or ice-cold water, applied to the frog's foot or mesentery, cause the capillary vessels to shrink in diameter, and that this contraction is speedily followed by their dilatation beyond their natural capacity and by retardation of the blood; the shrinking of the vessels being attributed to the direct operation of the stimuli on their contractility, and their subsequent dilatation to the temporary exhaustion of that property, consequent on its previous undue excitation. 2dly. That when the vessels are preternaturally dilated, in the way above described, or by the action of ammonia or common salt, they may, after a time, be made to contract to their usual size by the reapplication of stimuli.

*Termination of arteries.*—The only known termination of arteries is in veins, and this takes place by means of capillary vessels of some of the forms above described, unless, perhaps, in the interior of erectile organs, to be specially referred to hereafter, in which it has been supposed by some anatomists that small arteries open into wide venous cavities, without the intervention of capillaries. Additional modes of termination have, however, been assumed to exist. Thus, it was believed that branches of arteries ended in exhalent vessels, which, in their turn, terminated by open orifices on the skin, on the surface of different internal cavities, or in the cellular tissue; other arterial branches were supposed to be continued into the ducts of secreting glands, and it was, moreover, imagined that, besides the red capillaries, there existed finer vessels, which passed between the arteries and the veins, and from their smallness were able to convey only the colourless part of the blood. The existence of these colourless or "serous" vessels, as they were called (*vasa serosa*, *vasa non rubra*), was held, by most authorities, to be universal, by others it was assumed as necessary, at least, in the colourless textures; but these views have now been generally abandoned, although they long prevailed almost without question, and were made the basis of not a few influential doctrines in pathology and practical medicine.

*Erectile, or cavernous tissue.*—By this term is understood a peculiar structure, forming the principal part of certain organs which are capable of being rendered turgid, or erected, by distension with blood. It consists of dilated and freely intercommunicating branches of veins, into which arteries pour their blood, occupying the areolæ of a network formed by fibrous, elastic, and probably contractile bands, named *trabeculæ*, and inclosed in a distensible fibrous envelope. This peculiar arrangement of the blood-vessels scarcely deserves to be regarded as constituting a distinct texture, though reckoned as such by some writers; it is restricted to a very few parts of the body, and in these is not altogether uniform in character; the details of its structure will, therefore, be considered with the special description of the organs in which it occurs.

#### DEVELOPMENT OF BLOOD-VESSELS.

The first vessels which appear are formed within the ovum, in the germinal membrane, and the process subsequently goes on in growing parts of the animal body. New vessels, also, are formed in the healing of wounds and sores, in the organization of effused lymph, in the restoration of lost parts, and in the production of adventitious growths. Passing over the earlier accounts, the following may serve as an outline of the process, as deduced from the observations of Schwann, on the formation of vessels in the germinal membrane of the incubated

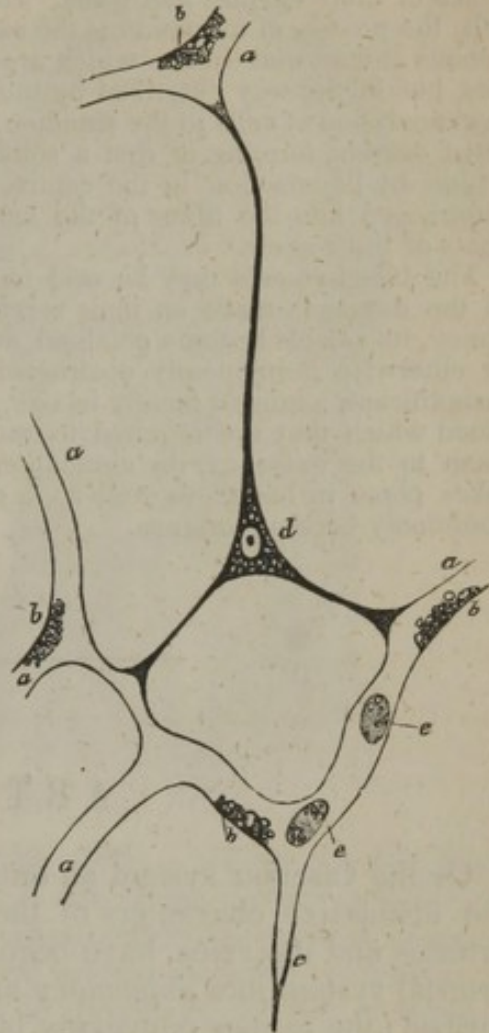


egg, and in the growing tail of batrachian larvæ, repeated and confirmed as they have recently been, in the latter case, by Kölliker.

The smaller vessels and capillaries originate from nucleated cells similar to those which at first constitute the different parts of the embryo. The cell-wall, or envelope, of these cells, shoots out into slender pointed processes, tending in different directions, so that they acquire an irregularly star-shaped or radiated figure. The prolongations from neighbouring cells encounter one another, and join together by their ends, and the irregularly ramified or reticular cavities thus produced are the channels of rudimentary capillaries. It is in this way, according to Schwann, that the network of vessels begins in the vascular area of the germinal membrane. In growing parts, where new vessels are formed in the vicinity of those already existing, as represented in the adjoining figure (235), not only do the processes of the stellate cells join those of neighbouring cells, but some of them meet and join with similar pointed processes which shoot out from the sides of neighbouring capillary vessels, and in this manner the new vessels are adopted into the existing system. The junctions of the cells with each other or with capillary vessels are, at first, of great tenuity, and contrast strongly with the central and wider parts of the cells; they appear then to be solid, but they afterwards become pervious and gradually widen, blood begins to pass through them, and the capillary network acquires a tolerably uniform calibre. The original vascular network may become closer by the formation of new vessels in its interstices, and this is effected by similarly metamorphosed cells, arising in the areolæ, and joining at various points with the surrounding vessels, and also, according to Kölliker, simply by pointed offshoots from the existing capillaries stretching across the intervals and meeting from opposite sides, so as when enlarged to form new connecting arches. From obser-

observations made on the fetal membranes of sheep, Mr. Paget has found that the mode of formation of capillaries described by Kölliker in batrachians, holds good also in mammiferous animals.\* The simple homogeneous coat of the capillaries is thus formed out of the walls of the coalescing cells; the nuclei on the capillaries seem, however, too numerous to be accounted for merely by the nuclei of these cells. Whilst the finest capillaries retain this simple structure, those that are larger acquire the additional coats already described, and it seems probable that the smaller arteries and veins are formed in the same manner; indeed, it would seem not unreasonable to presume, that the several gradations of structure seen as permanent conditions in vessels of successively larger calibre, may represent the

Fig. 235.



Capillary blood-vessels of the tail of a young larval frog. Magnified 350 times. After Kölliker. *a*, capillaries permeable to blood—*b*, fat granules attached to the walls of the vessels, and concealing the nuclei—*c*, hollow prolongation of a capillary, ending in a point—*d*, a branching cell with nucleus and fat-granules; it communicates by three branches with prolongations of capillaries already formed—*e*, blood-corpuscles still containing granules of fat.

\* Supplement to Müller's Physiology, by Baly and Kirkes, 1848, p. 104.



successive steps by which a vessel, having originally the small size and the simple membrane of a fine capillary, increases in width and acquires the complex tunics of a vein or artery. Further observations, however, are required on this point. Kölliker states, that many vessels which eventually attain a medium size, are originally derived from round cells, which unite in single or double rows, and form the primitive simple membranous tube of such vessels, by coalescence of their cavities and walls. He thinks that, in other moderate-sized vessels, the process of formation is the same as in the case of the heart and the large venous and arterial trunks, which are formed not after the manner of the capillaries, but in the way described by most preceding embryologists, namely, by an agglomeration of cells in the situation of the future heart and along the line of the great vessels, forming at first a solid mass, but subsequently becoming hollow within by liquefaction in the centre, whilst the circumferential cells are metamorphosed into the fibres of the heart and the several tissues constituting the coats of the vessels.

The blood-vessels may be said to increase in size and capacity in proportion to the demands made on their service. Thus, as the uterus enlarges in pregnancy, its vessels become enlarged, and when the main artery of a limb is tied, or otherwise permanently obstructed, collateral branches, originally small and insignificant, augment greatly in size, to afford passage to the increased share of blood which they are required to transmit, and by this admirable adaptation of them to the exigency, the circulation is restored. In such cases, an increase takes place in length, as well as in diameter, and accordingly, the vessels very commonly become tortuous.

---

## ARTERIES.

OF the vascular system an outline has already been given, in which the distinctive characters of the two great sets of blood-vessels, the arteries and the veins, have been pointed out. The subdivision of the arterial system into *pulmonary* and *systemic* arteries has also been described; the former conveying blood from the right side of the heart into the lungs, and the latter carrying that fluid from the left side of the heart to all parts of the body. The pulmonary artery and its divisions will be elsewhere noticed; in this place we enter upon the consideration of the systemic arteries. These commence by means of a large single vessel, named the aorta, from which, as from a large trunk, branches are distributed to all the organs of the body.

### THE AORTA.

The *aorta* or *great artery*, fig. 236, A B C, (*ἀορτή*; arteria magna,)\* is the large main trunk of a series of vessels which convey red or oxygenated blood from the heart over the entire body. It is situated in front of the vertebral column, partly within the thorax and partly in the abdomen. It commences at the left ventricle of the heart, with

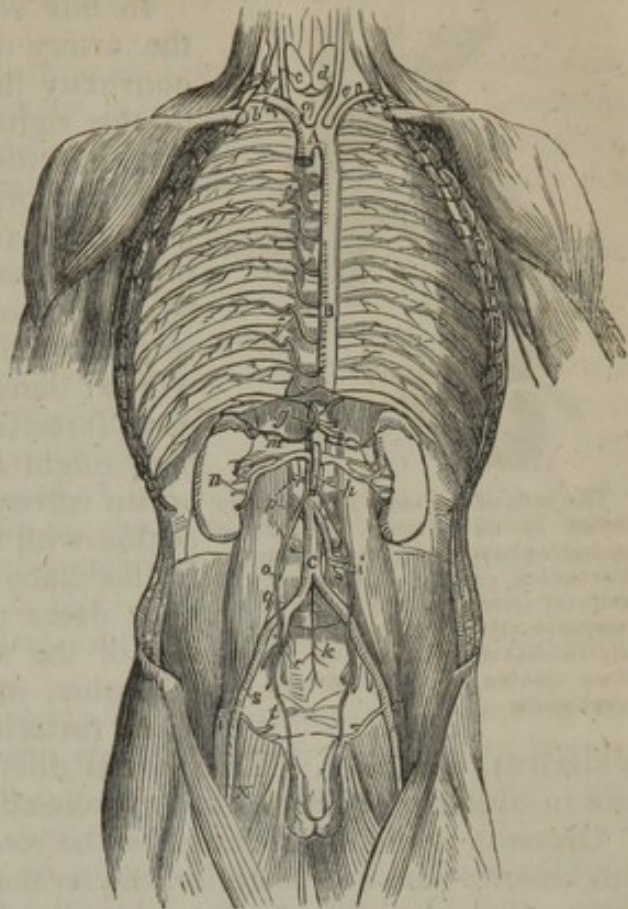
\* The terms *ἀορτή*, *ἀρτηρία*, are apparently compounded of the words *ἀήρ*, *air*, *spirit*, and *τηρεῖν*, *to keep or guard*; the ancients believing that the arteries contained vital air, or spirits, during life. [Others say it is derived from *ἀείρω*, *to lift up*, or compounded from *αἶ* and *ῥέω*, *ever flowing*.]



which it is intimately connected; and after ascending a short distance within the thorax, arches over to the left side, and then descending along the vertebral column, passes through the diaphragm into the abdominal cavity, and ends opposite the fourth lumbar vertebra, by dividing into the right and left common iliac arteries. In this course the primary systemic artery forms a continuous undivided trunk, which gradually diminishes in size from its commencement to its termination, and gives off larger or smaller branches at various points. Nevertheless, different parts of the vessel have received particular names, derived from their position or direction. The following are recognised, viz., the *arch of the aorta*, the *thoracic aorta*, and the *abdominal aorta*.

The short curved part, fig. 236, A, which reaches from the ventricle of the heart to the side of the third dorsal vertebra, is named the *arch*; the straight part, B, which extends from that vertebra to the diaphragm, is called the *thoracic aorta*; and the remainder of the vessel, C, down to its bifurcation, is spoken of as the *abdominal aorta*. These three parts will be examined separately, the first part or arch being described immediately, and the other divisions in subsequent pages.

Fig. 236.

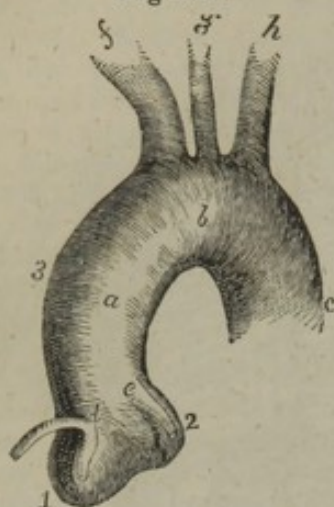


## ARCH OF THE AORTA.

The arch of the aorta, fig. 237, [arcus aortæ,] commences at the upper part or base of the left ventricle of the heart, in front of the left auriculo-ventricular orifice; it then passes upwards and to the right side, somewhat in the direction of the heart itself, crossing obliquely behind the sternum, and at the same time approaching more nearly to that bone; having gained the level of the upper border of the second costal cartilage of the right side, the vessel alters its course, and arches over from right to left, at the same time inclining backwards to reach the left side of the second dorsal vertebra; here it makes another turn, and changes its direction so as to incline downwards upon the left side of the third dorsal vertebra, at the lower border of which the arch of the aorta becomes continuous (without any mark of separation) with



Fig. 237.



The arch of the aorta as seen from before in its natural position. *a.* ascending part; *b.* transverse part; *c.* descending part; *d. e.* origin of the coronary arteries of the heart; *f.* innominate artery; *g.* left carotid; *h.* left subclavian. 1, 2, two of the three sinuses of the aorta; 3, the great sinus.

the straight descending portion of the vessel known as the thoracic aorta.

In this course it will be observed that the artery describes a curve, having its convexity turned upwards, forwards, and to the right side, and its concavity of course in the opposite direction. A little above its origin the aorta is larger than elsewhere, and is not quite cylindrical, for it presents externally three small bulgings, fig. 237,<sup>1 2</sup>, of about equal size, which correspond with as many dilatations or pouches within; these are named the *sinuses of the aorta* (*arteriæ magnæ sinus*,—Valsalva\*); they might be termed the sinuses of the aortic valves, in consequence of their connexion with the functions of those valves. In this place it may be mentioned, that in most cases there exists along the right side of the ascending part of the arch a dilatation, named the *great sinus of the aorta* (*arteriæ magnæ maximus sinus*,—

Valsalva), fig. 237,<sup>3</sup>. This partial dilatation of the vessel varies in size in different subjects, and occasionally is not to be detected.

Opposite to the three sinuses at the root of the aorta, of which two are anterior and one posterior, the section of the artery has a somewhat triangular figure; but immediately below them, where it is attached to the base of the left ventricle, the vessel is smaller, and its border circular. This circular border is connected with the margin of the aortic orifice of the left ventricle of the heart by means of a dense fibro-cartilaginous structure of an annular form, which enters into three indentations presented by the border of the vessel between the three sinuses. The aorta is also connected with the heart by the serous layer of the pericardium, which is prolonged for some distance upon the vessel, and by the lining membrane of the left ventricle (endocardium), which is continuous with that of the whole arterial system.

Around the inner side of the orifice of the aorta, and corresponding in position with the three sinuses, are attached three *semilunar valves*, the free margins of which meet together so as to close the mouth of the vessel, and prevent the reflux of the blood propelled from the ventricle into the aorta. Above two of the valves, and in the corresponding sinuses, are seen the orifices of the two coronary arteries of the heart, *d e*, the first branches given off by the aorta.

From the difference in the direction and connexions of different portions of the arch it is described as consisting of an *ascending*, a *transverse*, and a *descending* portion.

The *ascending* portion, fig. 237, *a*, of the arch of the aorta at its commencement is generally placed on a level with the upper border

\* Valsalvæ Opera. Venetiis, 1740. Dissert. Anatom. i., sect. ii., p. 129, tab. 21.



of the fourth costal cartilage of the left side, and it rises as high as the upper border of the second costal cartilage of the right side. Its length is about two inches or two inches and a quarter; and it is curved in its direction.

This portion of the aortic arch is enclosed in the pericardium, and, together with the pulmonary artery, is invested by a tube of the serous layer of that bag, in such a manner that both vessels are covered by the serous membrane, except where they are in contact one with the other.

At its commencement the ascending part of the arch is concealed by the pulmonary artery, and the right auricular appendage also overlaps it; but as, in ascending, the aorta passes forwards and to the right side, whilst the pulmonary artery turns backwards and to the left, the former vessel comes into view, and approaches very near to the sternum, from which it is separated only by the pericardium and by cellular tissue and the remains of the thymus gland lodged in the anterior mediastinum. Higher up, the aorta has the descending vena cava on the right side, and the pulmonary artery (in passing backwards) on the left: behind, it is supported on the right branch of the pulmonary artery with the other constituents of the root of the right lung.

The second, or *transverse*, part of the arch, fig. 237, *b*, is directed from right to left, and from the sternum to the body of the second dorsal vertebra. At its left side it is covered by the left pleura and lung, and is placed immediately in front of the trachea before its bifurcation into the bronchi. Here (on its posterior aspect) the aorta touches likewise the œsophagus, and is crossed by the thoracic duct. The upper border of this the transverse part of the arch has in contact with it the left innominate vein; and from it are given off the large arteries (innominate, left carotid, and left subclavian), which are furnished to the head and the upper limbs. The lower border rests on the bifurcation of the pulmonary artery, and is connected with the left division of that artery by the remains of the ductus arteriosus. At or near its end this part of the arch is crossed in front by the left vagus nerve, and the recurrent laryngeal branch of that nerve turns upwards, beneath and behind it.

The *descending* portion of the arch, fig. 237, *c*, which is straight in its direction, rests on the left side of the body of the third dorsal vertebra, and is covered by the left pleura and lung. In front of this part of the arch is the root of the left lung; and to its right side is the œsophagus with the thoracic duct.

If the pulmonary artery be cut across at its root and drawn upwards, it will be seen that the curve formed by the arch of the aorta encloses the pulmonary artery at its division, the root of the left lung, the left auricle of the heart, the left recurrent nerve, and the remains of the ductus arteriosus.—It may at the same time be observed that the aorta is connected with the pulmonary artery by the pericardium, and by the fibrous cord representing the ductus arteriosus of the fœtus.



## PECULIARITIES OF THE ARCH OF THE AORTA.

It is proposed to notice briefly under the head of *peculiarities*, all the more frequent deviations from the usual arrangement of each arterial trunk and its branches, and especially such as may be interesting in a surgical or physiological point of view. For more extended information on this part of the subject, reference may be made to a work on the arteries, recently published.\* In accordance with this plan, the peculiarities affecting the arch of the aorta will now be considered.

The *height* to which the arch of the aorta rises in the chest is liable to some variation. Although its highest part is usually placed about an inch below the upper margin of the sternum, it may reach very nearly to the level of that part of the bone; and, on the contrary, it has been occasionally found an inch and a half below it, and (but this appears to be of very rare occurrence) as much as three inches from the same point. In these cases, the length and position of the great branches which spring from the arch undergo corresponding modifications.

*Change of direction.*—The aorta sometimes presents the singular peculiarity of arching over the root of the right lung instead of that of the left, and afterwards continuing on the right side of the vertebral column. In these cases, the viscera are all transposed, and the vena azygos is removed from the right to the left side. In other instances again, which are less frequently met with, this change in the direction of the aorta is only temporary, for after arching over the right bronchus (with the vena azygos), it resumes within the thorax its usual position, to the left of the vertebral column.

*Peculiarities of Conformation.*—The aorta has been observed to divide,† without forming any arch, into an ascending and a descending branch; the former of which ascended vertically for some distance, and then subdivided, like a cross, into three branches, to supply the head and upper limbs. This very rare disposition of the aorta corresponds with the usual arrangement in some quadrupeds;‡ and since, at an early period in the history of anatomy, dissections were for the most part prosecuted on the bodies of the lower animals, the terms ascending and descending aorta came also to be applied by the older anatomists to parts of the great systemic artery in the human subject.

Another very unusual change of conformation is that in which the aorta divides soon after its commencement into two large branches, which unite again into a single trunk, corresponding to the descending portion of the aorta.§ In one case of this kind, (that recorded by Hommel,) the trachea and œsophagus were found to pass through the vascular ring formed by the divided aorta; and they probably occupied the same position in the other cases also.

It is interesting to find that many of the peculiar conditions of the great systemic artery just mentioned, resemble the ordinary arrangements of that vessel in the lower vertebrate animals. Of this, one example in the case of quadrupeds, has been already mentioned. The change in the direction of the arch over the right instead of the left bronchus, is similar to the ordinary condition in birds; and the bifurcation of the ascending aorta, and the subsequent reunion of its two parts has analogy with the arrangement of this vessel in the class of reptiles. It may further be remarked, that the mode in which these peculiarities may be supposed to be produced—by the pre-existence of certain fœtal conditions of the vessel in the human subject, or by slight changes effected during the progress of development—has in many cases been satisfactorily shown.

\* "The Anatomy of the Arteries of the Human Body, with its application to Pathology and Operative Surgery, by Richard Quain, in a series of plates and commentaries." London, 1844.

† Klinz in "Abhandlungen der Iosephinischen Med. Chir. Acad. zu Wien." Band 1, S. 271, 1787; Troussieres in "Le Journal des Sçavans," Paris, 1729.

‡ [Usually the case in the pachydermata and ruminantia.]

§ Hommel, in "Commercium Literarium," Hebdom. 21, Norimbergæ, 1737; Malacarne, "Delle osservazioni in chirurgia," &c., part II. 119; Zagorsky, in "Mem. de l'Acad. Imp. des Sciences de St. Petersburg," t. 9.



THE BRANCHES OF THE ARCH OF THE AORTA TAKEN  
COLLECTIVELY.

The branches given off by the first part of the aorta are five in number. Two of these, named the *coronary* arteries, fig. 237, *d, e*, are comparatively small, and are distributed to the walls of the heart: they arise very near to the commencement of the aorta, and will be examined hereafter (page 532).

The other three branches from the arch are the three large primitive trunks which supply the head and neck, the upper limbs, and, in part, the thorax.

They usually arise from the middle or highest part of the arch, in the following order, fig. 237; first, the innominate or brachio-cephalic artery, which soon subdivides into the right subclavian and the right carotid arteries; secondly, the left carotid; and thirdly, the left subclavian artery.

The origin of the left carotid artery is ordinarily somewhat nearer to the innominate artery than it is to the subclavian artery of its own side.

These three vessels, with the branches and the peculiarities presented by each, will be described in succession; but it is necessary so far to anticipate as to notice in this place the variations which have been observed in their mode of origin from the aorta, as connected with the peculiarities of that vessel.

PECULIARITIES OF THE BRANCHES ARISING FROM THE  
ARCH OF THE AORTA.

Variations in the number and arrangement of the branches which arise from the aortic arch are of more frequent occurrence than those of the arch itself. They may be arranged into two classes: 1. Those in which the primary trunks, viz., the carotid and subclavian, or the innominate arteries are concerned; and 2. Those in which one or more secondary branches usually given from the subclavian, take origin directly from the aorta.

1. *Peculiarities affecting the primary branches.*—These relate to the situation of the large branches upon the arch; to their contiguity to each other; or to an alteration in their number or arrangement.

*The situation of the branches.*—Instead of springing from the highest part of the arch, the branches are frequently moved altogether to the right, and take origin from the commencement of the transverse portion, or even from the end of the ascending portion of the arch. In these cases the vessels arise lower down than usual, especially the innominate artery; and they are generally crowded together on the aorta.

*Their contiguity to each other.*—In the ordinary arrangement, the origin of the left carotid is nearer to the innominate than to the left subclavian; but the branches sometimes arise at equal distances from each other, or they are unusually apart. A very frequent change consists in the approximation (in various degrees in different cases) of the left carotid towards the innominate artery.

*The number and arrangement of the branches.*—These are extremely various. In a large series of observations the most frequent change met with in the number of the primary branches was their *reduction to two*. This most frequently arose from the left carotid being derived from the innominate artery.\* In other

\* [A natural condition in many apes and marsupialia.]



cases of rare occurrence, the carotid and subclavian arteries of the left side (as well as those of the right) took origin by an innominate artery.\*

On the other hand, the number of the primary branches has been found to be *augmented* to four, by the decomposition, as it were, of the innominate artery into the right carotid and subclavian arteries, which arose directly from the aorta.

In some of these cases the right subclavian artery, as might be expected, was the first branch given off from the arch, the right carotid, the left carotid and the left subclavian following in regular order; but this vessel was likewise found to take origin beyond one or two of the remaining three branches, or, as in most instances, beyond them all—from the left end of the arch; and other variations, in the order in which the branches arise, have been noticed.

Again, examples have occurred of augmentation in the number of the branches to five or six. In these cases the common carotid of one or both sides being absent, the external and internal carotid arteries arose from the aorta separately.

In other forms of variety, the *number of the primary branches continues unchanged, but their arrangement is unusual*. Thus, when the aorta arches over to the right side, there may be three branches having the reverse of the ordinary arrangement, the innominate being on the left side. In other cases (the aorta having its usual course,) the two carotids have been seen to arise by a common trunk, and the two subclavians separately—the right subclavian in most instances being transferred beyond the other branches to the left end of the arch. [Meckel mentions† a rare case in which there were two innominatæ, one of which sent off the two carotids, the other the two subclavians.]

A very unusual change, referrible to this form of peculiarity, observed by Tiedemann, consists in there being but one innominate artery, and that on the left side, although the aorta had its usual course over the left bronchus.—The subject was an infant, and had hare-lip.

2. *Peculiarities in which one or more secondary branches, usually given from the subclavian, are derived directly from the aorta.*—In nearly all these, there is but a single secondary branch taking origin from the aorta; and such a branch, it may be remarked, has been found to accompany the ordinary arrangement of the primary branches, or to co-exist with a diminution or with an increase in their number; that is to say, with all the conditions of the primary branches which have been just noticed.

The additional branch is almost invariably the left vertebral, which in nearly all such cases arises between the left carotid and left subclavian arteries; but it has been observed to proceed from the aorta beyond the last-named trunk.

A thyroid artery has been, though but rarely, seen to arise from the arch of the aorta.

*Two secondary branches*, taking origin from the aorta, have been very rarely met with. Those hitherto observed are the right internal mammary and the left vertebral; or, as in one singular case, both vertebral arteries.

## BRANCHES OF THE ARCH OF THE AORTA.

### THE CORONARY ARTERIES.

The coronary arteries are small vessels, two in number, which arise near the root or commencement of the aorta, immediately above the semilunar valves, fig. 237, *d, e*. They are called *coronary*, from the manner in which they encircle the heart near its base, (*corona*, a wreath or garland). They have likewise been named *cardiac*, from their destination to the substance of that organ. The two arteries are distinguished as right and left coronary arteries from

\* [Normal in bats.

† Handbuch der menschlichen Anatomie. Berlin, 1815.]



the direction they take, or from the sides of the heart which they respectively supply.

The *right coronary artery* [art. coronaria dextra,] about the size of a crow's quill, is seen close to the right side of the pulmonary artery, between it and the right auricle. It arises from the aorta just above the free margin of the right semilunar valve, and runs obliquely towards the right side of the heart, lodged in the groove which separates the auricle from the corresponding ventricle. Having passed the right border of the heart, the vessel continues its course in the same way along the posterior aspect of the organ, until it reaches the groove of separation between the two ventricles, where it divides into two branches. One of these continues on transversely to the groove between the left auricle and ventricle, and anastomoses with the left coronary artery; whilst the other branch, assuming a different course, runs longitudinally downwards along the posterior wall of the septum between the ventricles, and giving branches to each ventricle and to the septum between them, terminates at the apex of the heart by anastomosing with the descending branch of the left coronary artery, which is seen on the fore part of the interventricular septum.

In its course, the right coronary artery, besides the offsets already noticed, gives small branches to the right auricle and ventricle, and also to the origin of the pulmonary artery. Along the right border of the ventricle a rather large branch usually descends towards the apex of the heart, and sends branches in its progress to the anterior and posterior surfaces of the ventricle.

The *left coronary artery* [art. cor. sinistra s. post.] is smaller than the preceding, and arises from the left side of the aorta higher up by a line or two. It passes behind and then to the left side of the pulmonary artery, appearing between that vessel and the left auricular appendage. At first it descends obliquely towards the sulcus, which separates the ventricles of the heart in front, where it divides into two branches. Of these, one continues to pursue a transverse direction, turning outwards and to the left side in the groove between the left ventricle and auricle, and after reaching the posterior aspect of the heart, anastomoses with the transverse branch of the right coronary artery; the other branch, much the larger, descends on the anterior surface of the heart along the line of the interventricular septum towards the apex of the organ, and anastomoses with the long descending branch of the right coronary artery.

The left coronary artery supplies some small branches at its commencement to the pulmonary artery, to the coats of the aorta itself, and to the left auricular appendage; its two branches also furnish smaller offsets throughout their course, which supply the left auricle, both ventricles, and the interventricular septum.

#### PECULIARITIES OF THE CORONARY ARTERIES.

The *coronary arteries* have been observed in a few instances to commence by a common trunk, from which they diverged and proceeded to their usual destination. The existence of three coronary arteries is not a very rare occurrence, the third being small, and arising close by one of the others. Meckel, in one



instance, observed four, the supplementary vessels appearing like branches of one of the coronary arteries transferred to the aorta.

#### THE INNOMINATE ARTERY.

The *innominate* artery (brachio-cephalic), [a. anonyma,] fig. 236, *a*, the largest of the vessels which proceed from the arch of the aorta, arises from the commencement of the transverse portion of the arch, before the left carotid. From this point the vessel ascends obliquely towards the right, until it arrives opposite the sterno-clavicular articulation of that side, nearly on a level with the upper margin of the clavicle, where it divides into the right subclavian, *b*, and the right carotid artery, *c*. Its place of bifurcation would, in most cases, be reached by a probe passed backwards through the cellular interval between the sternal and clavicular portions of the sterno-mastoid muscle. The length of the innominate artery is very variable, but usually ranges from an inch and a half to two inches.

This artery lying within the thorax for the most part, is placed behind the first bone of the sternum, from which it is separated by the sterno-hyoid and sterno-thyroid muscles, and a little lower down by the left innominate vein, which crosses the artery at its root. The innominate artery lies in front of the trachea, which it crosses obliquely; on its left side is the left carotid artery, with the thymus gland or its remains; and to the right, is the corresponding innominate vein and the pleura.

In the ordinary condition no branches arise from this vessel.

#### PECULIARITIES OF THE INNOMINATE ARTERY.

The length of the innominate artery now and then exceeds two inches, and occasionally it measures only one inch or less. Its place of division is a point of surgical interest, inasmuch as upon it in a great measure depends the accessibility of the innominate itself in the neck, as well as the length of the right subclavian artery. Though usually bifurcating nearly on a level with the upper margin of the clavicle at the sternal end, it has been sometimes found to divide at a considerable distance above that bone, and, but less frequently, below it also.

Lastly, though usually destitute of branches, this vessel has been observed to supply a thyroid branch, and sometimes a thymic branch, or one (bronchial) which descends in front of the trachea. Sometimes there is no innominate artery, the right subclavian arising as a separate trunk from the aorta. The innominate artery has not unfrequently been seen to give origin to the left carotid. In cases of transposition of the aorta, an innominate artery, as might be expected, exists on the left instead of the right side.

#### COMMON CAROTID ARTERIES.

The common or primitive carotid arteries of the right and left sides of the body [art. carotis dextra et sinistra] are nearly similar in their course and position, whilst they are in the neck; but they differ materially in their mode of origin, and consequently in their length, and position at their commencement. On the right side the carotid artery commences at the root of the neck behind the sterno-clavicular articulation, at the place of bifurcation of the innominate artery, whilst the carotid of the left side arises, within the thorax, from the highest part of the arch of the aorta, very near the origin of the innominate artery. The left carotid is therefore longer than the right, and it is at first placed deeply within the thorax.



In consequence of this difference, it is convenient to describe, at first, the thoracic portion of the left carotid, or that part which intervenes between the arch of the aorta and the sterno-clavicular articulation,—after completing which the same description will suffice for both vessels.

Whilst *within the thorax*, the *left carotid* ascends obliquely behind, and at some little distance from the upper piece of the sternum and the muscles (sterno-hyoid and sterno-thyroid) connected with that part of the bone; it is covered by the remains of the thymus gland, and is crossed by the left innominate vein. This part of the artery lies in front of the trachea; and the œsophagus (which, at the root of the neck, deviates a little to the left side) and the thoracic duct, are also behind it. The left carotid artery here lies between the innominate and the subclavian arteries, and the vagus nerve is to its outer side.

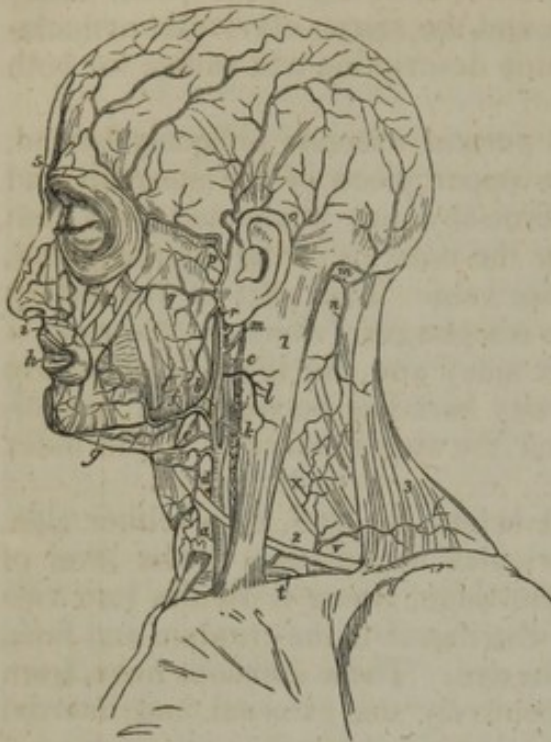
*In the neck* the common carotid artery, fig. 238, *a*, of either side, reaches from behind the sterno-clavicular articulation to the level of the upper border of the thyroid cartilage, where it divides into two great branches, of which one, *b*, is distributed to the cranium and face, and the other, *c*, to the brain and the eye. These divisions have, from their destination, been named respectively the external and internal carotid arteries.

The oblique course taken by the common carotid artery along the side of the neck, is indicated by a line drawn from the sterno-clavicular articulation to a point midway between the angle of the jaw and the mastoid process of the temporal bone. At the root of the neck, the arteries of both sides are separated from each other only by a narrow interval, corresponding with the width of the trachea; but, as they ascend, the two vessels are separated by a much larger interval,—corresponding with the breadth of the pharynx and larynx. The appearance which the carotid arteries have of being placed further back at the upper than at the lower part of the neck, is owing to the projection of the larynx forward in the former situation.

In considering the position of the common carotid artery with regard to the adjacent structures, it is first to be observed that this vessel is enclosed, together with the internal jugular vein and the vagus nerve, in a common membranous investment or sheath, derived from or continuous with the deep cervical fascia. Separated by means of this sheath from all the surrounding parts, except the vein and nerve just mentioned, the carotid artery is deeply placed at the lower part of the neck, but is comparatively superficial towards its upper end. It is covered below by the sterno-mastoid, sterno-hyoid, and sterno-thyroid muscles, in addition to the platysma and the different layers of fascia between and beneath the muscles; and it is crossed opposite the lower margin of the cricoid cartilage, or nearly in this situation, by the omo-hyoid muscle. From this last-named point upwards to its bifurcation, the sheath of the vessel is covered only by the common integument, the platysma and fascia; and this part of the artery lies in a triangular space bounded by the sterno-mastoid, the omo-hyoid, and the digastric muscles.



Fig. 238.



Behind, the artery is supported by the transverse processes of the cervical vertebræ, from which, however, it is separated by a thin stratum of muscular fibres,—parts of the longus colli and scalenus anticus muscles. From the muscles, as well as from the inferior thyroid artery, and the nerves which rest on those muscles, the vessel is separated by its sheath. In consequence of the contiguity of the bones, the circulation through the carotid artery may be commanded by pressure directed backwards against the vertebral column.

On the inner side the vessel is in juxtaposition (the sheath only intervening) with the trachea below, and with the thyroid body (which often overlaps the artery),

the larynx and the pharynx higher up. Along its outer side are placed the internal jugular vein and the vagus nerve.

*Veins.*—The *internal jugular vein*, as already mentioned, lies along the outer side of the artery, and is enclosed in the same sheath, but with a thin partition intervening. The vein is close to the artery at the upper part of the neck; but in approaching the thorax, and on the right side, it inclines outwards, and the two vessels are separated by a triangular interval, across the base of which lies the subclavian artery. A different arrangement obtains on the left side, the vein being usually nearer to the artery, and occasionally even in front of it, at the lower part of the neck. The inclination of the veins in both these cases is in the same direction—towards the right side—and it may be accounted for by their destination to the right side of the heart. Their tendency to the right side has necessarily the effect of approximating one to the artery which it accompanies, and removing the other from it.

Crossing over the upper part of the common carotid artery to join with the jugular vein, will be found two or more *superior thyroid veins*. These veins vary in number, and they occasionally form a sort of plexus over the artery. Another vein, likewise from the thyroid body (*middle thyroid vein*), not unfrequently crosses over the artery near its middle.

The *anterior jugular vein*, after descending along the front of the neck, usually near the middle line, turns outwards at the lower part of the neck, under the sterno-mastoid muscle, and thus crosses the artery. This vein is generally of small size. Occasionally, however, the vein is rather large, and is placed nearly over the carotid artery along the neck.

*Nerves.*—The descending branch of the ninth cerebral nerve (*descendens noni*) usually rests on the fore part of the sheath of the carotid artery (together with the branches of cervical nerves which



join it) and crosses it from the outer to the inner side. In some instances the branch of the ninth nerve descends within the sheath, and between the artery and vein. The vagus nerve, as already mentioned, lies within the sheath of the vessels between the artery and vein. This nerve was in one case observed to descend over the artery. The sympathetic nerve descends along the back of the sheath, between it and the rectus anticus muscle; and the recurrent laryngeal nerve crosses inwards behind the sheath.

The common carotid artery usually gives off no branch, and therefore continues of equal size in its whole length, except at its bifurcation, where an enlargement is observable.

#### PECULIARITIES OF THE COMMON CAROTID ARTERIES.

*Origin.*—The peculiarities affecting the origin of the common carotids of the two sides must necessarily be considered separately.

The *right carotid* artery, instead of forming one of the divisions of the innominate trunk, occasionally arises directly from the aorta, or in conjunction with the left carotid. When it arises from the aorta, it is usually the first vessel from the arch; but it has been found to occupy the second place,—the right subclavian, or, very rarely, the left carotid, being the first.

The place at which the right carotid artery commences, varies of course with the point of bifurcation of the innominate artery. A change from the usual position (on a level with the upper border of the clavicle) was found in the proportion of about one case in eight and a half; and it was found to occur more frequently above than below that point.

The *left carotid* artery varies in its *origin* much more frequently than the right. In the greater number of its deviations from the ordinary place of origin, this artery arises from, or in conjunction with, the innominate artery; and in those cases in which the right subclavian is a separate offset from the aorta, the two carotids most frequently arise by a common trunk.

The left carotid may be said to have a tendency towards the right side.—Ordinarily placed nearer to the innominate than to the left subclavian, it not unfrequently unites with that (the innominate) artery, as already stated; and it has been observed, very rarely, however, to precede the other branches which arise from the transverse part of the aortic arch. On the other hand, the combination of the left carotid with the left subclavian, has been very seldom met with, except in cases of general transposition of the viscera.

*Place of division.*—The deviations from the usual place of division of the common carotids of both sides of the neck, into the external and internal carotids, may be considered together. The place of division often varies somewhat from the point mentioned as the usual one (the level of the upper margin of the thyroid cartilage), and it more frequently tends upwards than in the opposite direction. The arteries often bifurcate opposite the os hyoides, and, occasionally, much higher than that bone. On the contrary, the bifurcation from time to time occurs about the middle of the larynx, and (but with much less frequency) opposite the lower margin of the cricoid cartilage. Instances are recorded of the common carotid dividing at a still lower point. One was observed by Morgagni, in which the carotid artery, measuring one inch and a half in length, divided at the root of the neck.\*

The common carotid artery has, as a very rare occurrence, been found to ascend in the neck *without dividing* into its usual terminal branches,—the internal carotid artery being altogether wanting.

In two cases the common carotid artery was altogether wanting—the external and internal carotids arising directly from the arch of the aorta. This peculiarity occurred on both sides in one of the cases referred to, and on one side in the other.†

\* "De Sedibus et Causis morborum," &c. Epist. 29, Art. 20.

† Dr. Power's case—in "The Arteries," &c. by R. Quain, page 101.



*Occasional branches from common carotid.*—Though, in the ordinary condition, no branches arise from the common carotid, this is not always the case; for it not unfrequently gives origin to the superior thyroid artery, and, though very seldom, to a laryngeal, or an inferior thyroid branch. Lastly, the vertebral artery has in a few instances been observed to come from the common carotid.

#### SURGICAL ANATOMY OF THE COMMON CAROTID ARTERY.

The leading facts in the foregoing account of the common carotid artery will here be brought together in connexion with the performance of an operation for tying the artery, as in a case of aneurism.—As this artery does not, save in very rare instances, furnish any branch, (in a practical or surgical point of view the branches sometimes found to arise close to its upper end may be disregarded,) a ligature can be applied to any part of the vessel except immediately at its commencement or termination. When the case is such as to allow a choice, the point which probably combines most favourable circumstances for the operation, is opposite the lower end of the larynx. Here a large space would, in ordinary cases, intervene between the ligature and the ends of the vessel; and at the same time this part is free from the difficulties offered by the muscles lower down, and by the superior thyroid veins, if the artery be secured near its bifurcation. But it has been shown above that the carotid artery occasionally bifurcates below the usual position—opposite the lower margin of the larynx, and even, however rarely, lower than this. In such cases, should the artery be laid bare at the point of division, it would be best to tie the two parts separately, close to their origin, in preference to tying the common trunk near its end. If, in consequence of very early division of the common carotid or its entire absence (cases which, however, are of extremely rare occurrence) two arteries (the external and internal carotids) should happen to come into view in the operation supposed, the most judicious course would doubtless be to place the ligature on that artery which, upon trial, as by pressure, should prove to be connected with the disease.

In performing the operation, the direction of the vessel and the inner margin of the sterno-mastoid muscle are the surgeon's guides for the line of incision. Before dividing the integument it is well to ascertain whether the anterior jugular vein be in the line of incision. Should the operation be performed at the lower part of the neck, some fibres of the muscles will require to be cut across in order to lay the artery bare with facility; and the necessity for this step increases in approaching towards the clavicle. After the superficial structures have been divided, assistance will be derived from the trachea or the larynx, as well as from the pulsation, in determining the exact situation of the artery. The trachea, from its roughness, may be readily felt in the wound, even while the parts covering it have still some thickness. The sheath of the vessels is to be opened over the artery—near the trachea—for thus the jugular vein is most easily avoided. Should the vein lie in front of the artery, as it sometimes does on the left side, and especially at the lower part of the neck on that side, the vein in question will be a source of much difficulty in completing the operation, *i. e.* in passing the aneurism needle with the ligature about the artery. I have had occasion to observe the embarrassment arising from this cause in the living body in an operation on the left carotid artery. To surmount the difficulty much caution is required. The operator will find it advantageous to have the circulation in the vein (which in such operation becomes turgid and very large) arrested at the upper end of the wound by means of an assistant's finger. In most cases, if not in all, it is best to insert the aneurism needle conveying the ligature, on the outer side of the artery, for thus the vagus nerve and the jugular vein will be most effectually avoided.

#### EXTERNAL CAROTID ARTERY.

The external carotid artery (*carotis superficialis s. externa*,—Haller), fig. 238, *b*, is smaller than the internal carotid in young subjects, but about of equal size in the adult. It reaches in the neck from the point of division of the common carotid (opposite the upper mar-



gin of the thyroid cartilage) to the neck of the condyle of the lower jaw-bone, or a little lower, where it divides into two branches, the temporal and the internal maxillary. This artery diminishes rapidly in size as it ascends in the neck, owing to the number and size of the branches which spring from it.

At first the external carotid lies to the inner side, *i. e.* nearer to the middle line of the body, than the internal carotid,—the distinctive names of the two arteries having reference to their destination to parts nearer or more remote from the surface. Soon after its origin the external carotid crosses over or becomes superficial to the internal carotid, and then curves slightly forward as it ascends to its place of division. For a short distance after its origin this artery is covered only by the platysma muscle, and the fascia, and is placed in the triangular intermuscular space, bounded by the sterno-mastoid, omo-hyoid and digastric muscles; but it soon becomes deeply placed passing beneath the stylo-hyoid and digastric muscles, and finally becomes embedded in the substance of the parotid gland.\* On its inner side it is close to the hyoid bone, and afterwards to the back part of the ramus of the lower maxilla, a portion of the parotid gland being interposed between the bone and the artery. It is close to the pharynx for a short space, and afterwards rests upon the stylo-glossus and stylo-pharyngeus muscles, which, with the glosso-pharyngeal nerve, are interposed between it and the internal carotid artery.

*Veins.*—Two small veins accompany the external carotid artery, and it is crossed by superficial venous branches belonging to the external jugular, and other veins.

*Nerves.*—Near its commencement the external carotid is crossed by the hypoglossal nerve, and at a short distance from its upper end, in the substance of the parotid gland, by the portio dura of the seventh. The glosso-pharyngeal nerve, as already mentioned, lies between this artery and the internal carotid, and the superior laryngeal nerve is under both vessels.

#### PECULIARITIES OF THE EXTERNAL CAROTID ARTERY.

The variations in the place of origin, and consequently in the length of the external carotid artery, are determined by the point of division of the common carotid, which has been already described. In the same place will be found reference to examples of the external carotid taking rise from the arch of the aorta.

#### BRANCHES OF THE EXTERNAL CAROTID ARTERY.

The external carotid artery gives origin to eight branches, including the two into which it finally divides. For the purposes of description these may be arranged into three sets. 1. Those which are directed forwards, *viz.*, the superior thyroid, the lingual, and the facial. 2. Those which run backwards,—the occipital and posterior auricular; and 3, those which ascend, *viz.*, the ascending pharyngeal branch with the temporal and internal maxillary,—the two terminal branches.

In addition to the principal branches here enumerated, the external carotid gives off several small offsets to the parotid gland.

*Peculiarities of the branches.*—The peculiarities relating to the origin of the



branches of this artery will be mentioned under the description of each ; but a general view may be here taken of the deviations they present in respect of position and number.

*Position of branches.*—They are not unfrequently crowded together on the parent artery, in some cases, near the commencement, and in others at a higher point of that vessel. Occasionally the branches are found to be distributed at regular distances upon the whole length of the external carotid.

*Their number.*—The usual number of branches (eight) has been found to be diminished in two principal ways,—viz., by the removal to another artery of one of the ordinary branches, or by the union into a single trunk of two or three branches which are usually derived separately from the artery under consideration.

The number of branches derived from the external carotid artery may be augmented by the transfer to this vessel of some branch not ordinarily derived from it, or by the addition to it of some unusual branch. Illustrations of these various peculiarities will be referred to in treating of the individual branches. In this place may be mentioned the not unfrequent presence of a distinct branch for the sterno-mastoid muscle.

#### SUPERIOR THYROID ARTERY.

The *superior thyroid* artery, fig. 238, *d*, [*a. thyroidea sup.*] the first of the anterior set of branches, is given off close to the commencement of the external carotid, immediately below the great cornu of the hyoid bone. From this point the artery curves forwards and downwards, to the upper margin of the thyroid cartilage ; it then descends a short distance beneath the omo-hyoid, sterno-hyoid, and sterno-thyroid muscles, furnishing offsets to these muscles, and reaching the anterior surface of the thyroid body, distributes branches to its substance, and communicates freely with the branches of the inferior thyroid artery. The inferior thyroid, it will be afterwards seen in the description of the artery, is distributed to the under surface of the thyroid body.

The superior thyroid artery, taking its rise from the external carotid, while that vessel is placed in the triangular intermuscular space referred to in describing the upper part of the common carotid artery, is covered at first only by the platysma and fascia ; but afterwards it is more deeply seated, being beneath the muscles before mentioned.

*Branches.*—Besides the branches furnished to the muscles and the thyroid body, as already noticed, together with some to the lowest constrictor of the pharynx, the superior thyroid furnishes the following offsets, which have received distinctive names :

(*a*) The *hyoid*, a very small branch, runs transversely inwards just below the os hyoides, and assists in supplying the soft parts connected with that bone. This little artery sometimes forms an arch with its fellow from the opposite side.

(*b*) A *superficial descending* branch, which passes downwards a short distance over the sheath of the large cervical vessels, and ramifies in the sterno-mastoid, and the muscles attached to the thyroid cartilage, as well as in the platysma and neighbouring integuments. The position of this branch with respect to the sheath of the carotid artery, is the only circumstance which attaches a degree of interest to it.

(*c*) The *laryngeal* branch (superior laryngeal artery) proceeds inwards in company with the superior laryngeal nerve, and pierces the thyro-hyoid membrane. Before entering the larynx this branch is covered by the thyro-hyoid muscle. On reaching the interior of the larynx, it ramifies in the small muscles, the glands, and mucous membrane of that organ.

(*d*) *Crico-thyroid.*—A small branch, to be noticed on account of its position rather



than its size, crosses over the membrane connecting the thyroid and cricoid cartilages, and communicates with a similar branch from the other side. This little artery may be the source of troublesome hemorrhage in an operation for laryngotomy.

*Peculiarities.—Size.*—The superior thyroid artery is frequently much larger, or, on the other hand, it may be smaller than usual. In either case the deviation from the accustomed size is accompanied with an opposite alteration in other thyroid arteries; one change compensating for another.—(See observations on the inferior thyroid artery.)

*Origin.*—The superior thyroid is often transferred to the common carotid, and it has been seen, but rarely, conjoined with the lingual branch, or with that and the facial branch of the external carotid.

There are sometimes two superior thyroid arteries. The single vessel has been seen so small that it ended in branches to the sterno-mastoid muscle and the larynx.

*Peculiarities of the branches.*—The *hyoid* branch is frequently very small or absent.

The *laryngeal* branch arises not unfrequently from the external carotid artery, and likewise, but rarely, from the common carotid.

Examples have occurred of this branch being of very large size. In the case here referred to, the laryngeal artery after passing along the inner side of the thyroid cartilage escaped beneath that cartilage to the thyroid body.

The laryngeal artery occasionally enters the larynx through a foramen to the thyroid cartilage; and it has likewise been observed to pass inwards below the cartilage, afterwards distributing branches upwards to the interior of the larynx.

#### LINGUAL ARTERY.

The *lingual artery*, fig. 238, *e*, [*a. lingualis*] arises from the inner side of the external carotid, between the origin of the superior thyroid and facial arteries. Curving from its origin upwards and inwards, this artery reaches the upper margin of the hyoid bone (its greater cornu), by which it is separated from the superior thyroid artery; it then passes forwards deeply between the muscles above the hyoid bone, and soon ascends almost perpendicularly to reach the under surface of the tongue, beneath which it makes its final turn forwards to the tip of that organ, assuming the name of *ranine* artery.

Taking origin in the triangular intermuscular space in which the commencement of the external carotid artery is lodged, the lingual artery is at first comparatively superficial, covered only by the *platysma* and *fascia* of the neck; soon, however, it is crossed by the *stylo-hyoid* muscle, and then sinks beneath the *hyo-glossus* muscle, between it and the middle constrictor of the pharynx. It is likewise covered by the anterior belly of the *digastric*, and by the *mylo-hyoid* muscle, and rests against the middle constrictor of the pharynx, afterwards against the *genio-hyo-glossus*.

The *hypoglossal* nerve courses forwards nearly parallel with the artery, until they both reach the posterior border of the *hyo-glossus* muscle, where the nerve passes over or on the cutaneous surface of the muscle, and the artery beneath it. At the anterior margin of the *hyo-glossus* muscle, the nerve is lower than the artery.

The branches of the lingual artery, including the *ranine*, are as follow:—

The *hyoid* branch [*ram. hyoideus*] takes the direction of the hyoid bone, running along its upper border; it supplies the contiguous muscles and skin.

The *dorsal artery of the tongue* (*dorsalis linguæ*), which is often represented by several smaller branches, arises from the deep portion of the lingual artery, be-



neath the hyo-glossus muscle. It is named *dorsal* from its destination, for it ascends to supply the upper part and substance of the tongue, ramifying as far back as the epiglottis.

The *sublingual* branch, [a. sublingualis] taking origin at the anterior margin of the hyo-glossus, turns slightly outwards beneath the mylo-hyoid muscle, between it and the sublingual gland. It supplies the substance of the gland, and gives branches to the mylo-hyoid and other muscles connected with the maxillary bone. Small branches are also distributed to the mucous membrane of the mouth, and the inside of the gums.

The *ranine* artery, [a. ranina s. profunda linguæ], from its direction, may be considered the continuation of the lingual artery. It runs forwards beneath the tongue, covered by the mucous membrane, and resting on the genio-hyo-glossus muscle. It is accompanied by the gustatory branch of the fifth nerve. Having reached the tip of the tongue, which it supplies with blood, it anastomoses with the corresponding artery of the other side. The two ranine arteries are placed one on each side of the frænum of the tongue, covered only by the mucous membrane of the mouth.

*Peculiarities.*—The origin of the lingual artery is sometimes by a common trunk with the next branch above it, viz., the facial artery. It is occasionally joined with the superior thyroid.

*Branches.*—The *hyoid* branch is often deficient; and it appears that there is an inverse condition as to size between this branch and the hyoid branch of the superior thyroid.

The *sublingual* branch varies in size. It is sometimes derived from the facial artery, and then perforates the mylo-hyoid muscle.

The lingual artery has been seen to give off as *unusual* branches, the submental and ascending palatine.

## FACIAL ARTERY.

The *facial* artery (art. maxillaris externa,—Anatom. varior. : labialis, —Haller), fig. 238, *f.* This artery is named from the distribution of its greater part. Taking origin a little above the lingual artery, it is first directed obliquely forwards and upwards beneath the base of the maxillary bone; and this may be considered the cervical part of the artery. Changing its direction, it passes upwards over the base of the lower maxilla, immediately before the ramus of that bone, at the anterior margin of the masseter muscle which covers the ramus. Commencing here its course upon the face, the facial artery is directed forwards near to the angle of the mouth; and after ascending externally to the nose, terminates near the inner canthus of the eye, where it anastomoses with the ophthalmic artery. In its whole course the artery is tortuous, and this condition is connected in the neck with the changes in size to which the pharynx is liable, and on the face with the mobility of the cheeks and of the lower maxilla.

The cervical part of the facial artery immediately after its origin (which is comparatively superficial, being covered only by the platysma and fascia), sinks beneath the digastric and stylo-hyoid muscles, and then beneath the submaxillary gland near its upper part. Emerging from the gland and ascending over the maxilla, it is covered by the platysma, and here the pulsation of the artery is easily felt, and the circulation through it readily controlled by pressure against the bone. In its further progress over the face the facial artery is covered successively (in addition to the integument and a varying quantity of fat) by the platysma and the zygomatic muscles, and it rests against the buccinator, the levator anguli oris, and the levator labii superioris.



The facial *vein* is separated by a considerable interval from the artery on the face. It takes nearly a straight course upwards instead of inclining forward near the angle of the mouth, and it is not tortuous like the artery.

Branches of the portio dura nerve cross the vessel, and the infra-orbital nerve is beneath it, separated by the fibres of the elevator of the upper lip.

**BRANCHES OF THE FACIAL ARTERY.**—The branches of the facial artery are numerous, and may conveniently be divided into two sets,—the first consisting of those given off before the vessel turns over the lower maxillary bone (cervical branches), usually three or four in number; the second, which varies from five to six, being those distributed to the face.

*Cervical branches.*—The following branches are derived from the facial artery below the maxillary bone:

The *inferior* or *ascending palatine* (palatina adscendens,—Haller), ascends between the stylo-glossus and the stylo-pharyngeus muscles, and reaches the pharynx close by the border of the internal pterygoid muscle. After having given small branches to the tonsil, the styloid muscles, and the Eustachian tube, it divides, near the levator palati muscle, into two branches, one of which follows the course of the circumflexus palati muscle, and is distributed to the soft palate and its glands, whilst the other penetrates to the tonsil, and ramifies upon it with the branch to be next described.—The place of this artery upon the palate is often taken by the ascending pharyngeal. For the distribution of the vessels in that case, see the ascending pharyngeal artery.

The *tonsillar* branch [a. tonsillaris] ascends along the side of the pharynx, and penetrates the superior constrictor of the pharynx to terminate in small vessels upon the tonsil and the side of the tongue near its root.

The *glandular* branches are a numerous series which enter the substance of the submaxillary gland, whilst the artery is in contact with it; some of them are prolonged upon the side of the tongue.

The *submental* (submentalis arteria,—Haller), fig 238, g, the largest branch arising from the facial in the neck, leaves that artery near the point at which it turns upwards to the face, and runs forwards below the base of the maxillary bone upon the mylo-hyoid muscle and beneath the digastric. Giving branches in its course to the submaxillary gland and to the muscles attached to the jaw, it reaches the symphysis of the chin and divides into two branches; one of which, running more superficially than the other, passes between the depressor muscle of the lower lip and the skin, supplying both, whilst the other enters between that muscle and the bone, and ramifies in the substance of the lip, communicating with the inferior labial artery, which is to be next described.

Of the second series of branches,—those derived from the facial artery upon the side of the face,—some which are directed outwards to the muscles, as the masseter and buccinator, require only to be indicated. Those which are described with some detail have the opposite course inwards, and they are as follows:—

The *inferior labial* branch [a. mentalis], arises immediately after the facial artery has turned over the maxilla, and running forwards beneath the depressor anguli oris, distributes branches to the skin, and the muscles of the lower lip, anastomosing with the inferior coronary and submental branches, and with the inferior dental branch derived from the internal maxillary.

The *coronary artery* of the lower lip (coronaria labii inferioris,—Haller), arises near the angle of the mouth, as often in conjunction with the superior coronary as from the facial separately, and after penetrating the muscular fibres surrounding the orifice of the mouth, takes a transverse and tortuous course between those fibres and the mucous membrane of the lip, and inosculates with the corresponding artery of the opposite side. Small branches from this artery ascend to supply the orbicular and depressor muscles, the glands, and other structures of



the lower lip, whilst others descend towards the chin, and communicate there with branches from other sources.

The *coronary artery* of the upper lip,\* (*coronaria labri superioris*,—Haller,) *i*, is larger and more tortuous than the preceding branch, with which it often arises. Like the artery of the lower lip, it runs across between the muscles and mucous membrane of the upper lip, and inosculates with the corresponding artery of the opposite side. In addition to supplying the whole thickness of the upper lip, this artery gives two or three small branches to the nose. One of these, named the *artery of the septum*, runs along the septum of the nares, on which it ramifies as far as the point of the nose; another reaches the ala of the nose.

The *lateral nasal artery* turns inwards to the side of the nose beneath the common elevator of the nose and lip, and sends branches to the ala and the dorsum of the nose. This artery anastomoses with the nasal branch of the ophthalmic, with the artery of the septum narium, and with the infra-orbital artery.

*Angular artery* [*a. angularis*].—Under this name is recognised the end of the facial artery, which inosculates at the inner side of the orbit with the ophthalmic artery. It is accompanied by a considerable vein (the angular vein).

It may here be remarked, that a communication between the superficial and deep branches of the external carotid is established by the anastomoses of the facial artery with the infra-orbital, inferior dental, and nasal branches of the internal maxillary, and between the external and the internal carotids by the anastomoses of the facial with the ophthalmic arteries.

#### PECULIARITIES OF THE FACIAL ARTERY AND ITS BRANCHES.

*Origin*.—The facial artery not unfrequently arises by a common trunk with the lingual. Occasionally it arises above its usual position, and then descends beneath the angle of the jaw to assume its ordinary course.

This artery varies much in *size*, and in the extent to which it is distributed. It has been observed, very rarely, however, to end as the submental, not reaching the side of the face; in some cases it supplies the face only as high as the lower lip. The deficiency of the facial artery is most frequently compensated for by an enlargement of the nasal branches of the ophthalmic at the inner side of the orbit; occasionally by branches from the transverse facial or internal maxillary.

*Branches*.—The *ascending palatine* artery is in some instances transferred to the external carotid. This branch varies in size and the extent to which it reaches. Not unfrequently it is expended without furnishing any branch to the soft palate. When it is thus reduced in size, the pharyngeal artery takes its place on the soft palate.—(See the observations on the pharyngeal artery.)

The *tonsillar* branch is not unfrequently altogether wanting.

The *submental* branch has been observed to take its rise from the lingual artery. On the other hand, the facial artery, instead of the lingual, has been found to furnish the branch which supplies the sublingual gland.

#### OCCIPITAL ARTERY.

The *occipital* artery, (fig. 23S, *m, m*), [*a. occipitalis*,] has a long and winding course, running at first deeply upwards before the upper cervical vertebræ, then horizontally along the outer part of the base

\* The name *coronary* artery of the upper and lower lips respectively (*coronaria labri superioris v. inferioris*), is stated by Haller to have been taken by him from Winslow. But this anatomist, ("Anatomical Exposition," &c., sect. 4, 56, translated by Douglas,) after describing the course of the arteries, concludes by mentioning that they anastomose one with the other, "and thereby form a kind of *arteria coronaria labiorum*." So that the designation originally, and not inaptly, applied to the circle formed by the union of the labial arteries of opposite sides around the mouth, has come to be used for each vessel singly.



of the skull, and finally turning upwards on the occiput, to ramify beneath the integument. Arising from the posterior aspect of the external carotid, usually opposite the facial artery, this vessel in its upward course sinks beneath the posterior belly of the digastric muscle and the parotid gland, and reaches the interval between the transverse process of the atlas and the mastoid process of the temporal bone. From that point it turns horizontally backwards along the skull, beneath the mastoid process of the temporal bone and the sterno-mastoid, splenius, digastric and trachelo-mastoid muscles. In this part of its course the vessel rests against the upper end of the complexus, by which and by the fibres of the superior oblique and larger rectus muscles, it is separated from the occipital bone. Lastly, changing its direction a second time, and piercing the cranial attachment of the trapezius, it ascends beneath the integument on the back of the head, accompanied by the great occipital nerve, and divides into numerous branches. Whilst in the neck, the occipital artery crosses over the internal carotid artery, the vagus and spinal accessory nerves, and the internal jugular vein; and the hypoglossal nerve turns from behind over it at its origin.

The following branches are given from the occipital artery:

Small muscular offsets to the digastric and stylo-hyoid muscles, and one of larger size to the sterno-mastoid. This last is so regular a branch that it is known as the *sterno-mastoid* branch. Afterwards—

An *auricular* branch to the back part of the concha of the ear, and two or three other muscular branches to the splenius and trachelo-mastoid.

*Cervical branch.*—(Ramus princeps cervicalis,—Haller.)—To the back part of the neck the occipital artery furnishes a branch thus designated. Descending a short way, this vessel divides into a superficial and a deep branch. The former ramifies beneath the splenius, sending offsets through that muscle to the trapezius; while the deep branch passes beneath the complexus and anastomoses with the vertebral and the deep cervical branch of the superior intercostal. The muscles in the immediate neighbourhood are furnished with small arteries from the cervical branch of the occipital.—The size of this branch varies very much.

The *meningeal* branch runs up with the internal jugular vein, enters the skull through the foramen lacerum posterius, and ramifies in the dura mater of the posterior fossa of the base of the skull. A branch from the pharyngeal artery may be found to enter the skull through the same foramen.

The *superficial* or cranial branches of the occipital artery pursue a tortuous course between the integument and occipito-frontalis muscle; and in proceeding upwards on the skull they separate into diverging branches, which communicate with the branches of the opposite artery, as well as with those of the posterior auricular artery, and of the temporal artery at the vertex and side of the skull. Branches are distributed to the fleshy fibres of the occipital muscle, to the epicranial aponeurosis, and to the pericranium, others to the skin, and one (a *mastoid* branch) enters the skull through the mastoid foramen, and ramifies in the dura mater.

*Peculiarities.*—The *origin* of the occipital, though usually opposite the facial, is sometimes placed higher or lower than that point. This artery is occasionally derived from the internal carotid, and from the ascending cervical branch of the inferior thyroid—an offset of the subclavian artery.

The occipital artery sometimes passes over the trachelo-mastoid muscle, instead of beneath it. The chief portion of the vessel was found, but in a single instance however, to pass over the sterno-mastoid muscle, only a small artery being placed in the usual position. The artery has, in a few instances, been seen to turn backwards *below* the transverse process of the atlas.



*Branches.*—The posterior auricular and the pharyngeal arteries sometimes take origin from the occipital.

#### POSTERIOR AURICULAR ARTERY.

The *posterior auricular* artery [a. auricularis post.], a small vessel, arises from the carotid, a little higher up than the latter. It ascends, under cover of the parotid gland, and resting upon the styloid process of the temporal bone, to reach the angle formed by the cartilage of the ear with the mastoid process at the side of the head. The portio dura of the seventh nerve crosses over this little artery, and the spinal accessory turns behind it. Somewhat above the mastoid portion of the temporal bone it divides (fig. 238, o,) into two sets of branches, of which one set inclines forwards to anastomose with the posterior divisions of the temporal artery, and the other backwards towards the occiput, on which they communicate with the occipital artery. The following are the branches given from the posterior auricular artery:

Several small branches to the parotid gland and the digastric muscle.

The *stylo-mastoid* branch enters the foramen of that name in the temporal bone, and, on reaching the tympanum, divides into delicate vessels, which pass, some to the mastoid cells, others to the labyrinth. One branch will constantly be found, in young subjects, to form, with the tympanic branch of the internal maxillary artery, which enters the fissure of Glaser, a vascular circle around the auditory meatus, from which delicate offsets ramify upon the membrana tympani. This small tympanic branch sometimes arises from the occipital artery.

As it passes the back of the ear, the auricular artery gives one or two proper *auricular* branches, which supply the posterior surface of the concha, and turn over the margin, or perforate the substance of the auricle to gain its anterior surface.

*Peculiarities.*—The posterior auricular artery is frequently very small, and has been seen to end in the stylo-mastoid branch. It is often a branch of the occipital.

**STERNO-MASTOID ARTERY.**—Associated by its position with the posterior branches of the external carotid, viz., the occipital and posterior auricular, a small vessel named from its destination *sterno-mastoid*, is not unfrequently met with.

#### TEMPORAL ARTERY.

The *temporal* artery, fig. 238, p, [a. temporalis] is one of the two branches into which the external carotid artery divides a little below the condyle of the lower jaw. It continues upwards in the direction of the parent vessel, whilst the other branch (the internal maxillary) sinks under the lower maxillary bone. The temporal artery is at first embedded in the substance of the parotid gland, where it lies in the interval between the meatus of the ear and the condyle of the lower jaw. Pursuing its course upwards, this vessel soon reaches the cutaneous surface of the zygoma (at its root), on which it may be readily compressed. Continuing to ascend it lies close beneath the skin, supported by the temporal muscle and its fascia; and, about two inches above the zygoma, divides into two branches, which again subdivide and ramify beneath the integument on the side and upper part of the head.

The temporal artery gives off the following branches:

Several small offsets to the parotid gland, some articular branches to the articulation of the lower jaw, and one or two branches to the masseter muscle.



The *transverse* artery of the face, *q*, (*transversalis faciei*) arises whilst the temporal artery is deeply seated in the parotid gland, through the substance of which it runs forwards, so as to get between the parotid duct and the zygoma, resting on the masseter muscle, and accompanied by one or two transverse branches of the facial nerve. It gives small vessels to the parotid gland, the masseter muscle, and the neighbouring integument, and divides into three or four branches, which are distributed to the side of the face, anastomosing with the infra-orbital and facial arteries.

The *middle temporal* branch [*a. temporalis media*] arises close above the zygoma, and immediately perforating the temporal fascia, sends branches to the temporal muscle, which often communicate with the deep temporal branches of the internal maxillary artery. An offset from this artery is sometimes found to run on to the outer angle of the orbit, where, after giving branches to the orbicularis palpebrarum, it anastomoses with the lachrymal branch of the ophthalmic artery.

The *anterior auricular* branches, [*a. auriculares ant.*] two or more in number (superior and inferior), arise above the branch last described. They are distributed to the fore part of the pinna and the lobe of the ear, and a part of the external meatus, anastomosing with the ramifications of the posterior auricular artery.

One of the two terminal branches of the temporal artery, the *anterior temporal*, inclines forwards as it ascends over the temporal fascia, and ramifies extensively over the forehead, supplying the orbicular and occipito-frontal muscles, the pericranium, and the skin, and communicating with the supra-orbital and frontal branches of the ophthalmic artery. On the upper part of the cranium the branches of this artery are directed from before backwards.—When it is desired to take blood from the temporal artery, the anterior temporal branch is selected for the operation.

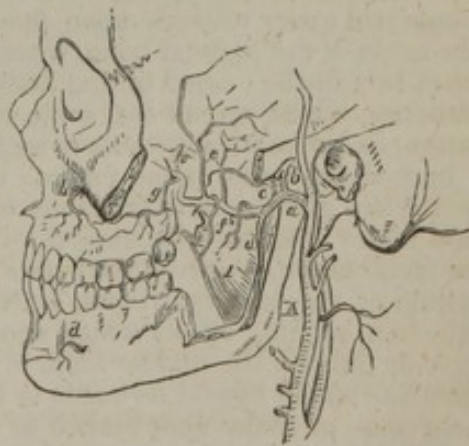The *posterior temporal*, which is larger than the anterior, passes back on the side of the head, above the ear, and over the temporal fascia; its branches ramify freely in the coverings of the cranium, both upwards to the vertex, where they communicate with those of the corresponding vessel on the opposite side, and backwards to join with those of the occipital and posterior auricular arteries.

*Peculiarities.*—The temporal artery is frequently tortuous, especially in aged persons. Occasionally a large unusual branch runs forward above the zygoma to the upper part of the orbit. The temporal artery may join with the ophthalmic, and furnish large frontal arteries.—The *transverse artery of the face* varies in size; occasionally it is much larger than usual, and takes the place of a defective facial artery. In some instances the transverse artery is transferred to the external carotid.

#### INTERNAL MAXILLARY ARTERY.

The *internal maxillary* artery, fig. 239, *a*, [*a. maxillaris interna*] the deep terminal branch of the external carotid *A*, and which in size, though not in direction, is the continuation of that vessel, pursues a winding course under cover of the ramus of the lower maxilla. From its place of origin, where it is concealed by the parotid gland, the artery curves forward and assumes for a short space a horizontal course, sinking immediately under the maxilla, between that bone and the internal lateral ligament of the temporo-maxillary joint; and here it lies below

Fig. 239.





the narrow end of the external pterygoid muscle, and crosses over the inferior dental nerve. Speedily changing its course, the internal maxillary artery passes obliquely forward and upward over the outer surface of the same muscle (not unfrequently beneath it), and under cover of the ramus of the lower maxilla, and of the lower end of the temporal muscle. Approaching the superior maxillary bone, and opposite the interval between the two heads of the external pterygoid muscle, the artery bends inwards to the sphenomaxillary fossa, where it furnishes the terminal branches.

For sake of greater facility in arranging the numerous branches furnished by this artery, it will be considered as divisible into three parts, each giving origin to a group of branches. The first division is that short part connected with the ramus of the lower maxilla, and placed between that bone and the internal lateral ligament of the temporo-maxillary articulation; the second is defined by the connexion of the vessel with the muscles; while the third division includes that portion which is again in close connexion with bone, viz., with the superior maxilla and the fossa which it contributes to form.—It is to be understood that this, like most other methods of merely artificial arrangement, is not free from objection.

A. The branches given from the first part of the internal maxillary artery,—that between the lower maxilla and the lateral ligament of the joint,—are the tympanic, the middle and small meningeal, and the inferior dental, each of which, it may be observed, passes into an osseous foramen or canal.

The *tympanic branch* [a. tympanica] passes deeply behind the articulation of the lower jaw, and enters the fissure of Glaser, supplying the laxator tympani muscle, and the tympanic cavity, where it ramifies upon the membrana tympani. It anastomoses in the tympanum with the stylo-mastoid and vidian arteries. This little artery varies in its place of origin, in different cases.

The *middle meningeal* or *great meningeal* artery, fig. 239, b, [a. meningea media, s. magna, s. spinosa] is by far the largest of the branches which supply the dura mater. It arises from the internal maxillary artery between the lateral ligament and the lower jaw, and passes directly upwards under cover of the external pterygoid muscle to the spinous foramen of the sphenoid bone. Through that foramen it reaches the interior of the skull, where it ramifies between the dura mater and the internal surface of the cranial bones, its numerous ramifications spreading over the sides and top of the cranium, along the deep arborescent grooves formed on the inner surface of the bones. In its course within the cranium the middle meningeal artery ascends upon the middle fossa of the skull to the anterior inferior angle of the parietal bone, where it becomes lodged in a deep groove—sometimes in a distinct canal in that bone. From this point it divides into numerous branches, which spread out, some upwards over the parietal bone as high as the vertex, and others backwards even to the occipital bone.

Immediately after it has entered the cavity of the cranium, the middle meningeal artery gives minute branches to the ganglion of the fifth nerve, and to the dura mater near the sella turcica. One small branch (petrosal branch: artery of the facial nerve,—Cruveilhier) runs backwards and outwards over the petrous portion of the temporal bone, enters the hiatus Fallopii, and passes along the aqueduct, sending offsets which anastomose with the stylo-mastoid artery. As it ascends through the middle fossa of the skull, the middle meningeal artery sends branches which extend forwards to the orbit, and are found to inosculate with the lachrymal, or some other branch of the ophthalmic artery.—The branches of this artery supply the bones as well as the dura mater, to which membrane they adhere closely when the skull is detached from it.

The middle meningeal artery is accompanied by two veins.



The *small meningeal artery*, *c*, [a. meningea parva,] sometimes arises from the preceding branch. It enters the skull through the foramen ovale, to supply the dura mater in the middle fossa.

The *inferior maxillary, or dental artery*, *d d*, [a. dentalis s. alveolaris inferior] descends to enter the dental canal, accompanied by the inferior dental nerve, and then runs along the canal together with the nerve as far forwards as the mental foramen, through which it escapes on the face. As it enters the foramen in the lower maxilla this artery gives off the *mylo-hyoid* branch, which with a nerve runs in a groove below the dental foramen, and ramifies on the under surface of the mylo-hyoid muscle.

In its course through the bone the inferior dental artery lies beneath the roots of the teeth, and gives off at intervals small offsets, which ascend to enter the minute apertures in the extremities of the fangs, and supply the pulp of each tooth. From the mental foramen a branch is continued forwards beneath the incisor teeth, supplying them with minute vessels, and inosculating at the symphysis of the chin with a corresponding artery from the opposite side. The terminal or mental branches of the inferior dental artery anastomose on the face with the inferior coronary and submental arteries, and assist in supplying the soft parts covering the front of the lower jaw.

B. The second group of branches (those given from the internal maxillary artery whilst in connexion with the muscles) are, the deep temporal, the pterygoid, the masseteric, and the buccal,—that is to say, the branches which supply the muscles.

The *deep temporal* branches, *e*, [a. temporalis profunda ant. et. post.] two in number (anterior and posterior), ascend between the temporal muscle and the pericranium, along which they ramify, supplying that muscle, and anastomosing with the branches of the other temporal arteries, and also through small foramina in the malar bone, with minute branches of the lachrymal artery.

The *pterygoid* branches [a. pterygoideæ] include several small, short offsets, irregular in their number and place of origin, which are distributed to the pterygoid muscles.

The *masseteric* [a. masseterica] is a small but regular branch which passes from within outwards, above the sigmoid notch of the lower maxillary bone, and is distributed to the inner or deeper surface of the masseter muscle. This branch is often joined at its origin with the posterior temporal branch. It anastomoses with the masseteric branches derived from other arteries.

The *buccal* branch [a. buccalis] runs obliquely forwards upon the buccinator muscle with the buccal nerve; it is distributed to that and other muscles of the cheek, and anastomoses with the branches of the facial artery.

c. The branches given from the last part of the internal maxillary artery—while it is in connexion with the superior maxillary bone, and in the spheeno-maxillary fossa,—are the following, viz., the alveolar, and the infra-orbital, directed forwards; the descending palatine, turning downwards; the vidian and pterygo-palatine which run backwards; and the nasal or spheeno-palatine, proceeding inwards. These branches, like the first series, enter bony foramina or canals.

The *alveolar or superior maxillary branch*, *g*, arises near the tuberosity of the maxillary bone, usually in common with the infra-orbital branch, and runs tortuously forwards upon its outer surface, giving several branches (one being larger than the remainder, the *superior dental*—dentalis maxillæ superioris,—Haller) which enter the foramina in the bone and reach the alveolar cavities, where they pass into the fangs, and supply the pulps of the upper molar and bicuspid teeth; other branches supply the gums; and some small ones pierce the bone, and ramify in the lining membrane of the antrum of Highmore.

The *infra-orbital* artery, *h h*, [a. infra-orbitalis] arising generally by a common trunk with the preceding branch, runs horizontally forwards from the artery just as it is about to enter the spheeno-maxillary fossa, and though much smaller, is continuous in direction with the parent vessel. It passes into the infra-orbital



canal, and after having traversed the canal accompanied with the superior maxillary nerve, emerges upon the face at the infra-orbital foramen, under cover of the levator labii superioris.

Whilst in the canal, the infra-orbital artery gives off small vessels, which pass upwards into the orbit, and enter the inferior rectus and the inferior oblique muscle of the eye, and the lachrymal gland. Other small branches proceed downwards to supply the front teeth. On the face it gives branches upwards to the lachrymal sac and inner angle of the orbit, anastomosing with the nasal branches of the ophthalmic and facial arteries, and it sends other branches downwards beneath the levator labii superioris, which join with the ramifications of the transverse facial and buccal branches.

The *descending palatine* (palatina superior,—Haller), is one of the three branches which are given off deeply within the spheno-maxillary fossa. It descends perpendicularly through the posterior palatine canal, with the palatine nerve, and thus reaches the back part of the roof of the mouth, where it runs along the hard palate to the inner side of the alveolar border, supplying the gums, and the mucous membrane, and other parts of the palate. In front it ends in a small vessel which ascends through the anterior palatine foramen, and anastomoses with the artery of the septum (nasal) derived from the spheno-palatine branch.

While descending in the proper osseous canal, or before entering it, the palatine artery gives small branches which pass away through small diverging canals in the bone, to end in the soft palate, upon which they communicate with the ascending palatine artery.

*Vidian* [a. vidiana].—Near the origin of the descending palatine artery, or from a common trunk with it, a small branch, having a reflex course, passes directly backwards to enter the vidian canal with the vidian nerve. Hence it is termed the *vidian* or *pterygoid* branch. It is distributed to the Eustachian tube and top of the pharynx, and sends a small vessel into the tympanum.

The *pterygo-palatine* (pharyngeus supremus,—Haller), [a. pterygo-palatina, s. palatina sup.] a very small branch, often arises with the spheno-palatine. It passes backwards through the pterygo-palatine canal to reach the top of the pharynx, to which and to the Eustachian tube and sphenoidal cells, it is distributed.

The *nasal* or *spheno-palatine* artery [a. spheno-palatina s. nasalis post.] enters the foramen of that name, by which it reaches the cavity of the nose at the back part of the superior meatus. There, lying between the mucous membrane and the periosteum, it divides into two or three branches; of these some ramify extensively over the spongy bones, and others supply the posterior ethmoidal cells as well as the antrum. One long branch (the *artery of the septum*) runs forwards along the septum nasi, between the mucous membrane and the periosteum, to the fore part of the nasal fossa, where it ends in a small vessel which enters the upper end of the anterior palatine canal, and joins an ascending branch from the descending palatine artery.

*Peculiarities.*—The internal maxillary artery is very constant in its *place of origin*. It has, however, been seen to arise from the facial.

But this artery often deviates from the *course* described as the more usual one—passing under cover of the external pterygoid muscle (between the two pterygoids), and crossing the third division of the fifth nerve. In this case the artery comes forward in the interval between the two heads of the muscle to its accustomed position near the superior maxillary bone. It has likewise been observed to escape from under cover of the external pterygoid by piercing the middle of that muscle. When the artery is placed beneath the muscle, it has been found lodged in a notch in the posterior margin of the external pterygoid plate, and bound down by fibrous structure. In the process of bone referred to, instead of a depression there is occasionally a foramen, which probably lodges the artery.

The *branches* of the internal maxillary artery present few peculiarities worthy of note.

The *middle meningeal* artery occasionally furnishes the lachrymal artery (usually an offset of the ophthalmic),—a peculiarity which may be looked on as resulting from the enlargement of an ordinary anastomosing branch.

In a case in which the internal carotid was wanting, two tortuous branches from the internal maxillary entered the foramen rotundum and foramen ovale, to supply its place.



## PHARYNGEAL ARTERY.

The *pharyngeal* artery, fig. 238, *k*, [*a. pharyngeus adscendens*] is a long slender vessel, (the smallest branch of the external carotid which has received a distinctive designation,) ascends deeply in the neck, and lies concealed from view until some of the branches of the external carotid artery and the stylo-pharyngeus muscle are drawn aside. It arises most commonly from half an inch to an inch above the origin of the external carotid, and in its straight course upwards rests on the rectus capitis anticus, close to the surface of the pharynx, between it and the internal carotid artery, and is thus directed up towards the base of the skull. Its branches, which are necessarily very small, may, from a consideration of their destination, be divided into three sets, viz., those to the pharynx: a set directed outwards: and meningeal branches.

The *pharyngeal* branches, for the most part, pass inwards to the pharynx. One or two small and variable branches ramify in the middle and inferior constrictors. Higher up than these is a larger and more regular branch, which runs upon the upper constrictor, and sends small ramifications to the Eustachian tube, the soft palate, and the tonsil.

This last-named, or *palatine* branch, is sometimes of considerable size, and supplies the soft palate, taking the place of the inferior palatine branch of the facial artery, which, in such cases, is small. The arrangement of this artery of the palate is as follows. After passing above the superior constrictor it divides into two branches, of which one arches across the upper part of the soft palate, running beneath the mucous membrane on its fore part; whilst the other and larger branch is disposed in a similar manner near the free margin of the same part, both vessels anastomosing with those of the opposite side. Other small branches likewise ramify beneath the mucous membrane behind the soft palate.

The *external* branches of the pharyngeal artery consist of very small and irregular vessels, which are distributed to the following parts, viz.—the rectus anticus muscle, the first cervical ganglion of the sympathetic nerve, some of the cerebral nerves as they issue from the skull, and the lymphatic glands of the neck. Some of them anastomose with the ascending cervical branch of the subclavian artery.

The *meningeal* branches, the terminal branches of the ascending pharyngeal artery, are those which pass through the foramina at the base of the skull: one or two of them accompany the internal jugular vein through the foramen lacerum posterius; whilst another, which passes through the foramen lacerum medium basis cranii, enters the cranial cavity, and is distributed to the dura mater.

*Peculiarities.*—The *place of origin* of the pharyngeal from the external carotid artery varies considerably. It is not unfrequently distant from the commencement of the external carotid less than half an inch, or more than one inch (the limits within which it has been stated to take its origin in most cases); and it is occasionally found to spring from the bifurcation of the common carotid. Moreover, examples from time to time present themselves of this artery being given from an unusual source—as from the occipital or the internal carotid artery.

Two pharyngeal arteries have been observed in a few instances.

## INTERNAL CAROTID ARTERY.

The *internal carotid* artery (fig. 238, *o*) (*carotis interna, v. cerebialis*) is that branch of the common carotid which is distributed to the brain, and to the eye with its appendages. It extends from the place of bifurcation of the common carotid, usually in a straight direction, to the base of the skull, where it ascends in a winding course through the temporal bone, and after entering the cranial cavity, ends by the side of the anterior clinoid process of the sphenoid bone.

The internal carotid artery may thus be conveniently studied in



three parts of its course, viz., while in the neck; in passing through the carotid canal in the base of the skull; and within the cavity of the cranium.

*Cervical part.*—In the neck, the artery, fig. 238, c, commencing at the bifurcation of the common carotid, opposite the upper border of the thyroid cartilage, ascends nearly vertically to the base of the skull to reach the carotid foramen in the temporal bone. Like the common carotid, it is accompanied in this course by the internal jugular vein, which lies external to the artery.

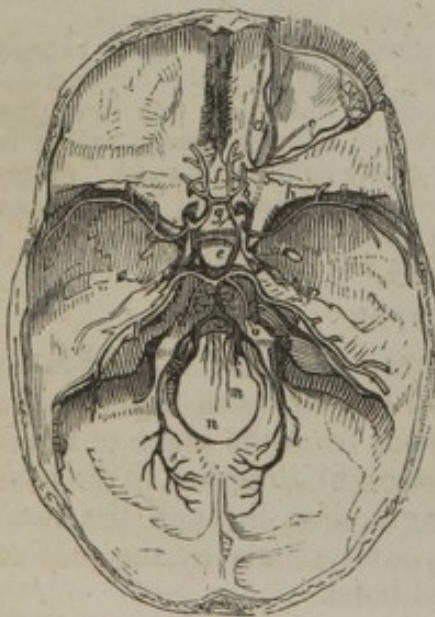
This portion of the artery varies much in length. The length in different persons is in general dependent on the stature; but it is also materially influenced by the extent to which the common carotid reaches upwards in the neck; and the length of the internal carotid may be said to be inversely as the length of that vessel. At first the internal carotid is easily accessible in the neck, inasmuch as it is placed in the intermuscular space in which the division of the common carotid artery occurs, and is covered only by the platysma and fascia, besides its sheath. Placed here to the *outer* side of the external carotid artery, it soon sinks beneath the parotid gland and becomes deep-seated, as it turns from behind under the external carotid. In its course upwards the internal carotid is crossed by the hypoglossal nerve, and the digastric and stylo-hyoid muscles, as well as by the external carotid and occipital arteries. Higher up, and under cover of the parotid gland, the vessel is likewise covered by the stylo-glossus and stylo-pharyngeus muscles, together with the glosso-pharyngeal nerve,—these structures being interposed between it and the external carotid artery.

Behind, this artery rests against the rectus anticus major, which muscle, with the sympathetic and vagus nerves, is placed between it and the transverse process of the upper cervical vertebræ: the pharynx and the tonsil, with the pharyngeal artery, are on its inner side.

On reaching the base of the skull, the internal carotid, following the direction of its proper canal in the petrous portion of the temporal bone, ascends perpendicularly a little way, then inclines forwards and inwards, near the inner side of the Eustachian tube, and again ascends as it escapes from the carotid canal. Whilst within the canal, the artery has in contact with it the carotid plexus of nerves.

On passing out of its canal in the temporal bone, the artery, now within the skull, ascends a short distance to gain the body of the sphenoid bone, where it enters the cavernous sinus, having perforated the layer of dura mater, which forms the outer boundary of that cavity. Then, still contained within the sinus, and, according to some anatomists, invested by the lining mem-

Fig. 240.





brane, it runs horizontally forwards along the side of the sphenoid bone, which is grooved for its reception, and again curves upwards beneath the anterior clinoid process, where, piercing the upper or cerebral wall of the cavernous sinus, and becoming invested by the arachnoid membrane, it reaches the inner end of the fissure of Sylvius, and divides into its terminal branches. Whilst the internal carotid artery is within the cavernous sinus, it is crossed on its outer side by the following nerves, viz., the third, fourth, ophthalmic division of the fifth, and sixth.

#### PECULIARITIES OF THE INTERNAL CAROTID ARTERY.

The variations which occur in the length of this artery have been already noticed. Independently of the position at which it is given off in the neck from the bifurcation of the common carotid artery, the only change which has been observed in the place of origin of the internal carotid artery is that met with in those very rare cases already referred to (ante page 537), in which there was no common carotid artery—the external and internal carotids being both derived directly from the arch of the aorta. In these cases the internal carotid artery was nearer to the trachea than the external carotid, which curved forwards over the internal carotid opposite the larynx.

Instead of following a straight direction upwards in the neck, the internal carotid is often curved; and in one case it was observed, after having reached nearly to the base of the skull, to turn downwards for more than an inch, and then abruptly to ascend again, being thus twice closely curved or folded on itself.

A very few examples are recorded of entire absence of the internal carotid. In one of these cases the common carotid ascended in the neck, gave off all the usual branches of the external carotid and divided into the temporal and internal maxillary arteries. Supplying the place of the internal carotid, were two tortuous trunks from the internal maxillary, which entered the skull respectively through the oval and the round foramina of the sphenoid bone, and became united into a single vessel. The vessel thus formed was smaller than the ordinary internal carotid, but the internal carotid of the opposite side was larger than usual.

#### BRANCHES OF THE INTERNAL CAROTID ARTERY.

In the neck the internal carotid artery usually gives no branch; whilst within the carotid canal it sends a small offset to the tympanum, which anastomoses with the tympanic and stylo-mastoid arteries; within the cavernous sinus, some small branches, named *arteriæ receptaculi*, proceed from it to supply the walls of the sinus and the adjacent dura mater. One of these, distributed to the dura mater, is the *anterior meningeal*.

Opposite to the anterior clinoid process, the artery gives off the ophthalmic branch, and within the Sylvian fissure of the brain it divides into the anterior cerebral, the middle cerebral, and the posterior communicating arteries.

#### OPHTHALMIC ARTERY.

The *ophthalmic* artery, fig. 240, *b*, [*a. ophthalmica*] passes forwards from the internal carotid artery, where it lies by the anterior clinoid process, and enters the orbit by the foramen opticum, placed below and to the outer side of the optic nerve. It soon changes its direction, passing above and to the inner side of the nerve, to reach the



inner wall of the orbit, along which it runs forwards, to terminate in branches which ramify on the side of the nose.

In its course the ophthalmic artery gives off numerous branches, which are destined to supply the eye and its appendages. They are as follows:—

The *lachrymal* artery, *c*, [*a. lachrymalis*] the first of the branches of the ophthalmic, is a long branch which arises from that vessel whilst on the outer side of the optic nerve. It passes forwards beneath the periosteum of the roof of the orbit, along the upper border of the external rectus muscle, and guided by it to the lachrymal gland, in which the greater number of its branches are distributed. Some of the branches pass onwards to the eyelids and conjunctiva, joining with other palpebral branches; and one or two delicate vessels, *malar* branches, pierce the malar bone from the orbit to reach the temporal fossa, where they join branches from the deep temporal arteries. The lachrymal artery also sends branches through the sphenoidal fissure into the skull, which join with small offsets from the middle meningeal artery.

The *central artery of the retina*, [*a. centralis retinæ*] a very small vessel, pierces the sheath and substance of the optic nerve, and runs embedded within it until it reaches the retina, upon a vascular membrane in front of which it ramifies in minute branches. A very delicate vessel, demonstrable in the fœtus, passes forwards through the vitreous humour, to reach the posterior surface of the capsule of the crystalline lens.

The *supra-orbital* branch, *d*, [*a. supra-orbitalis*] ascends to get above the muscles, and in its course forwards to the supra-orbital notch, accompanied by the frontal nerve, lies immediately beneath the roof of the orbit. The artery mounts towards the forehead, and distributes several branches, which communicate with those of the temporal artery, besides some which are distributed upon the eyelids.

The *ciliary* arteries [*a. ciliares*] are divisible into three sets: viz., *short*, *long*, and *anterior* ciliary arteries. The *short* ciliary arteries vary from twelve to fifteen in number, and will be found to enclose the optic nerve as they pass forwards to reach the posterior aspect of the sclerotic coat, which they pierce, in order to enter the eyeball, about a line or two from the entrance of the optic nerve. The *long* ciliary arteries, two in number, also enter the back of the eye, and then pass forwards, one on each side of the middle of the eyeball, between the choroid membrane and the sclerotic, as far as the ciliary ligament, where they divide into branches. The *anterior* ciliary arteries are derived from some of the muscular branches; they form a vascular circle around the fore part of the eyeball, and then pierce the sclerotic within a line or two of the margin of the cornea. All of these ciliary arteries anastomose together within the eyeball, where their distribution will be particularly described with the anatomy of the eye itself.

The *muscular* branches are subject to much variety in their course and distribution, like all muscular vessels: they supply the muscles of the orbit.

The *ethmoidal* branches [*a. ethmoidalis post. et ant.*] are two in number, a *posterior* and an *anterior*. The former passes through the posterior ethmoidal foramen in the inner wall of the orbit, and having given some small branches to the posterior ethmoidal cells, enters the skull, and, after supplying the adjacent dura mater, sends minute vessels, which descend through the foramina of the cribriform plate of the ethmoid bone to the nasal fossæ. The other, or *anterior* ethmoidal branch, passes with the nasal division of the ophthalmic nerve through the anterior foramen, and having given branches to the anterior ethmoidal cells and frontal sinuses, reaches the interior of the skull, and like the preceding vessel, supplies the dura mater, and sends branches through the cribriform lamella to the nose.

The *palpebral* branches, *superior* and *inferior*, [*a. palpebralis interna sup. et inf.*] arise usually in common, but soon diverge as they pass forwards, one lying above, the other below, the tendon of the orbicularis muscle at the inner angle of the eye: they are distributed, as their names imply, to the upper and lower eyelids, branches being also sent to the caruncula lachrymalis and the lachrymal sac.

The *nasal* branch [*a. dorsalis nasi*] courses forwards above the tendon of the orbicularis muscle to the root of the nose, where it ramifies, maintaining a free communication with the nasal and the angular branches of the facial artery.



The *frontal* branch [a. frontalis] runs close to the preceding, but on reaching the margin of the orbit turns upwards on the forehead, where it anastomoses with the supra-orbital artery.

The *terminal branches* of the internal carotid artery, given off after it has pierced the layer of the dura mater forming the wall of the cavernous sinus, are those which supply the pia mater and the brain.

The *anterior cerebral* (anterior cerebri sive corporis callosi), *f*, commences at the subdivision of the internal carotid as it reaches the inner end of the fissure of Sylvius. From this point it turns forwards towards the middle line to reach the longitudinal fissure between the anterior lobes of the cerebral hemispheres, across which fissure it is connected with the corresponding vessel of the opposite side by a branch, *g*, not more than two lines in length, named the *anterior communicating*, [a. communicans ant.]. The two anterior cerebral arteries, lying close together, in the next place turn round the anterior border of the corpus callosum, and, on reaching its upper surface, run from before backwards upon it, overlapped by the cerebral hemispheres, and end by anastomosing with the posterior cerebral artery in the back part of the fissure. In this course numerous branches are given off by both arteries in various directions.

The *middle cerebral* artery, *h* [a. media cerebri], the largest branch of the internal carotid, inclines obliquely outwards, taking the course of the fissure of Sylvius, within which it divides into several branches, which supply the pia mater investing the surfaces of the anterior and middle lobes of the brain, and join with the branches of both the anterior and posterior cerebral arteries. Some of its branches, as they ramify in the pia mater, turn forwards to and enter the brain at the anterior perforated spot, through which they reach the corpus striatum. One or two (*choroid* arteries) which sometimes arise directly from the internal carotid, will also be observed to enter the fissure between the middle lobe and the crus cerebri, to reach the descending cornu of the lateral ventricle, in which they are distributed to the choroid plexus.

The *posterior communicating*, fig. 239, *e*, [a. communicans post.], runs directly backwards, parallel with the corresponding artery of the opposite side, so that they enclose between them the infundibulum and the corpora albicantia; they terminate in the posterior cerebral arteries, and thus form the sides of the circle of Willis.

*Circle of Willis*, [circulus arteriosus Willisii].—A remarkable anastomosis exists between the branches of the vertebral and internal carotid arteries within the cranium, by which the circulation in the brain may be equalized, and any irregularity which might arise from the obliteration of one, or even two of the vessels, may speedily be remedied by a corresponding enlargement of the others. This anastomosis, which is known as the *circle of Willis*, results from a series of communications between the following branches. The anterior cerebral arteries are connected together in the longitudinal fissure by the anterior communicating artery. The internal carotids of each side, the trunks from which the anterior cerebral arteries arise, are united to the posterior cerebral arteries by the posterior communicating arteries, and the posterior cerebral arteries themselves arise behind from a single trunk—the basilar artery. Within, or opposite to the area of this vascular circle, will be observed the following parts of the encephalon, viz.,—the commissure of the optic nerves, lamina cinerea, infundibulum and tuber cinereum, corpora albicantia, locus perforatus with part of the crus cerebri, and the origin of the third pair of nerves of each side.

#### PECULIARITIES OF THE BRANCHES OF THE INTERNAL CAROTID ARTERY.

The *lacrimal* branch of the ophthalmic has been occasionally found, as already referred to, to be supplied by the anterior branches of the middle meningeal artery.

The deviations from the ordinary condition of the cerebral arteries mostly have reference to the mode in which the circle of Willis is completed. Thus the *anterior communicating* artery, which is usually very short and of good size, may be



longer and smaller than usual ; and it has been found double either in the whole or in part of its length. Sometimes, but very rarely, this communicating branch is wanting, the two anterior cerebral branches of the internal carotid being then united at once into a single trunk (like the basilar artery behind), which after a certain course, again divides into the right and left anterior cerebral arteries or arteries of the corpus callosum (J. F. Meckel).—Another very rare condition of the anterior cerebral artery has been described by Arnold,\* in which one large anterior cerebral artery supplied the place of both as to its distribution, and was connected only by slender branches to the internal carotid of the opposite side.

The *posterior communicating* artery varies much in size, being sometimes very small, whilst, on the contrary, it is often found so large that the posterior cerebral artery may be said to spring from the internal carotid instead of from the basilar. The posterior communicating artery on one side is very frequently found larger than on the other; and it has occasionally been seen to be represented by two very slender vessels.

The internal carotid was in one instance observed to furnish a remarkable branch, which, after passing backwards through the basilar portion of the sphenoid bone,† joined with the basilar artery, and formed the anterior part of that vessel.

#### ARTERIES OF THE UPPER LIMB.

The arterial trunk which supplies the upper limb continues undivided from its commencement as far as the bend of the elbow ; but different portions of the same vessel have received different names according to the parts through which they pass. This division, however artificial, serves for facility of reference and description. From the commencement of the vessel as far as the outer border of the first rib it is named *subclavian*, owing to its position beneath the clavicle ; from the first rib to the lower border of the axilla, it is named *axillary* ; and from thence along the arm to the bend of the elbow, *brachial*, with which the single trunk ends. This mode of division is similar to that of the artery of the lower limb into iliac, femoral, and popliteal ; and as this latter divides into tibial and fibular branches, so the brachial ends in the radial and ulnar arteries—the subdivision of the vessel into two parts coinciding with the occurrence of two bones in the skeleton of the limb.

#### SUBCLAVIAN ARTERIES.

In most parts of the body the description of the artery of one side serves for that of the other likewise ; but this is not the case as regards the vessels now under consideration, for, as the right subclavian artery commences at the division of the innominate artery, whilst the left subclavian arises at once from the arch of the aorta, it follows that the two vessels must, in the first part of their course, differ materially in their length, direction, and connexions with contiguous parts.

To facilitate the description of these important vessels, each subclavian artery is conveniently divided into three parts,—the *first* part extending from the origin of the vessel to the inner border of the anterior scalenus muscle ; the *second* consisting of the portion of the vessel which is situated beneath that muscle ; and the *third* reaching

\* "Bemerkungen über den Bau des Rückenmarks," &c. Taf. 2. Zurich, 1838.

† The preparation is in the Macartney collection in the Anatomical Museum at Cambridge. Drawings obligingly furnished by Professor Clark, will be found in the "Arteries," &c.



from the outer border of the same muscle to the end of the artery, opposite to the outer border of the first rib. Each of these parts will now be examined in detail. The first part only requires a separate description for the right and the left side, for in it alone is there any material difference in the anatomical history of the two vessels.

The *first part* of the *right subclavian artery*, [a. subclavia dextra,] commencing at the division of the innominate behind the upper part of the articulation of the sternum with the clavicle, close to the trachea, and ending at the inner margin of the anterior scalenus muscle, arches upwards and outwards away from the carotid artery across the root of the neck, and in doing so ascends above the level of the clavicle, the extent to which it reaches above that bone varying in different cases. The whole of this division of the artery is deeply placed, being covered by the platysma, the sterno-mastoid, the sterno-hyoid and sterno-thyroid, with the fascia separating those muscles. Behind, the artery is opposite to, but separated by an interval from, the transverse processes of the vertebræ, which here are covered by the longus colli muscle; and below it (along the concavity of its curve), and likewise somewhat behind it, is the pleura, which is in contact with the vessel till it rests on the first rib.

*Veins.*—The subclavian vein is lower than the first part of the right subclavian artery, close under the clavicle. In its course to join this vein, the internal jugular crosses in front of the artery near the scalenus muscle; and a vertebral vein lying along the inner side of the jugular, has the same position with reference to the artery. The anterior jugular vein, running outwards from the fore part of the neck beneath the sterno-mastoid muscle, will likewise be found to cross the course of the subclavian artery.

*Nerves.*—The vagus nerve crosses in front of the artery, and on the inner side of the internal jugular vein, as would be expected from the relative position maintained by the vein and nerve along the neck: the recurrent laryngeal branch of this nerve turns upwards behind the artery, hooking, as it were, under the vessel, between it and the pleura. Behind the vessel and the vertebral column, but not in contact with it, lies the chain of the sympathetic nerve; and some branches cross before the artery.

The *first part* of the *left subclavian*, [a. subclavia sinistra,] differs from the right subclavian in origin, and, as a consequence of this, differs likewise in length, direction, and connexions. It arises from the end of the transverse part of the arch of the aorta, and ascends to the margin of the first rib, behind the insertion of the anterior scalenus muscle to that bone. It is therefore longer than the first part of the right subclavian, and ascends almost vertically out of the chest, instead of arching, like that vessel, outwards across the neck. Commencing then from the deepest part of the aortic arch, the left subclavian is at first behind the left lung, and is covered in front and on the left side by the pleura; it is placed before the vertebral column (on which is laid the longus colli muscle), and lies, for a short space, in front of the œsophagus, (here deviating to the left side) and the thoracic duct.



To the inner or right side of the vessel are situated the left carotid, the trachea, œsophagus, and thoracic duct.

*Nerves.*—The pneumogastric nerve is anterior to the left subclavian, and parallel with it, the recurrent branch on this side turning round the aorta. The phrenic nerve descends over the artery along the inner margin of the scalenus muscle, immediately outside the thyroid axis.\* The cardiac nerves of the left side descending from the neck, are close to the artery.

*Veins.*—The internal jugular vein is immediately before the artery, where it turns outwards from the thorax—close to the scalenus muscle—and the left innominate vein is likewise anterior to it.

For the second and third divisions of both subclavian arteries, one description will suffice.

The *second* division of the subclavian artery, being only that portion which is concealed by the anterior scalenus muscle, is necessarily very short. It forms the highest part of the arch described by the vessel, and is therefore the most distant from the clavicle. Somewhat less deeply placed than the first division, this portion of the vessel is covered by the platysma, the sterno-mastoid, and omo-hyoid, with layers of the cervical fascia. Behind, it rests against the posterior scalenus muscle; and below, it is on the pleura.

*Veins and Nerves.*—The subclavian vein is lower than the artery, and the anterior scalenus muscle lies between the two vessels. The phrenic nerve, which descends obliquely inwards, is likewise separated from this part of the artery by the same muscle; and beneath the scalenus, immediately above the artery, are the large cervical nerves, which form the brachial plexus.

The *third* division of the subclavian artery, extends outwards and downwards from the border of the anterior scalenus to the upper surface of the first rib as far as its outer margin, where the vessel assumes the name axillary. In this part of its course, the artery lies in a small triangular space, the sides of which are formed by the omo-hyoid and anterior scalenus muscles, and its base by the clavicle: the omo-hyoid is in some instances immediately over the artery. The subclavian is here nearer to the surface than elsewhere, being covered only by (besides the common integuments) the platysma, and layers of the cervical fascia; but towards its termination the artery becomes deeper, sinking under the clavicle and the subclavius muscle.

The *subclavian vein* is anterior to, and lower than the artery. This vein is lower than the artery in its whole course, being close behind the clavicle, while the artery arches above that bone. The *external jugular vein* lies over the artery, and it receives on the outer side from the shoulder the two veins which accompany the supra-scapular and transverse cervical arteries. The veins in some cases form a sort of plexus over the artery.

*Nerves.*—Above the vessel, and to its outer side, are placed the large brachial nerves, the lowest cord formed by the union of the last

\* In two cases, the phrenic nerve was seen to cross the third part of the artery on the outer side of the scalenus muscle; but in both instances the thyroid axis arose beyond the scalenus, and the nerve was as usual on its outer side.



cervical and the first dorsal nerve, being in contact with it. It may be added, that the space which lodges the artery is crossed in front by the superficial descending (clavicular) branches from the cervical plexus, as well as by the little nerve of the subclavius muscle.

#### PECULIARITIES OF THE SUBCLAVIAN ARTERIES.

Most of the variations of the two subclavian arteries from their ordinary condition require to be separately noticed.

*The right subclavian.*—The *origin* of this artery, necessarily varying with the place of bifurcation of the innominate artery, in some cases commences within the thorax, instead of at the ordinary position (the upper margin of the sternoclavicular joint), and in a smaller number of instances it arises in the neck, at some distance above the level of the clavicle.

The right subclavian artery sometimes springs as a separate vessel from the aorta. And in such cases, it may be the first of the branches from the aortic arch, or, but more rarely, the second or third in order, or, as is most frequently the case, it may be the last of those branches. The course taken by the artery in each of these cases, and its position with regard to other parts, require notice. When the right subclavian is the first branch from the arch, it occupies the ordinary position of the innominate artery. In those very rare cases in which this vessel was the second or third of the aortic branches, it gained its usual position after crossing behind the right carotid. Lastly, when the right subclavian is the last branch given off from the arch of the aorta, it springs from the upper, or from the back part of the arch, or it may arise (but this is very rarely met with) much lower down from the descending portion of the aorta.

In any case of late origin of the subclavian, its *usual course* towards the right side of the neck is to cross obliquely in front of the vertebral column and behind the œsophagus. There would seem to be but one accurately recorded case, in which this artery, arising from the last part of the aortic arch, passed between the œsophagus and the trachea.

The *left subclavian* very seldom arises in common with another vessel; it has, however, been found in a few cases conjoined with the left carotid. When the aorta arches to the right side, the innominate, if present, exists on the left side, and the left subclavian springs from it. Independently of such cases, the connexion between the left subclavian and left carotid is of extremely rare occurrence.

It is an interesting fact, that although, in cases of transposition of the aorta, the left subclavian artery generally arises, as is usual on the right side, from an innominate trunk, it has also been observed to assume another arrangement occasionally presented as an unusual condition by the artery of the right side, viz., to be given off as the last of the branches derived from the arch of the aorta. In this case it crosses obliquely over the front of the vertebral column towards the left side of the neck.

The left subclavian artery has been observed in the fœtus to arise from the ductus arteriosus; and in the adult from a conical dilatation or pouch, which is connected with the cord formed by the obliterated portion of the "arterial canal." This pouch, which has been met with also in connexion with the origin of the right subclavian when that vessel is detached from the innominate, appears to be formed by a part of the canalis arteriosus, which continues pervious in consequence of the subclavian artery arising from it. A similar pouch, but of much smaller size, is sometimes seen at the attachment of the ductus arteriosus to the aorta, without having any branch connected with it.

*Peculiarities affecting both subclavian arteries.*—The height to which these vessels may reach in the neck is liable to variation to some extent. Most commonly the artery crosses the neck a little higher than the clavicle, but it is sometimes placed as high as an inch or even an inch and a half above the level of that bone. The greater extent of elevation above the clavicle, however, is especially seen in the artery of the right side. Now and then the subclavian artery perforates the anterior scalenus muscle, and in a few rare cases it was altogether in front of the



muscle, and was at the same time close to the subclavian vein. That vein has also been seen to pass with the artery behind the scalenus muscle.

#### BRANCHES OF THE SUBCLAVIAN ARTERIES, CONSIDERED WITH REFERENCE TO THE TRUNK.

The branches of the subclavian artery are so large and numerous in proportion to the length of the vessel from which they spring, that their number, and the place of their origin, are important considerations in the anatomical history of the artery itself, in consequence of the influence their position would have in determining the point best suited for the application of a ligature in a surgical operation.

Four branches usually arise from each subclavian artery. Of these, three generally spring together from the first division of the artery (namely, the vertebral, the internal mammary, and the thyroid axis,) and one from the second division, viz., the superior intercostal, to which may be added a small spinal branch. On the left side, the second division has usually no branch, the superior intercostal arising most frequently to the inner side of the scalenus muscle. The third part of the artery gives rise to no offset,—at least, it so happens in a majority of cases. But as considerable variations are found to occur in the position and number of the branches, it is necessary to refer more particularly to those given from each part of the artery in different cases, reserving the details respecting each branch for the description which will be given of them individually.

As the first part of the left subclavian artery does not admit of being tied in a surgical operation, the position of its branches has little interest in a practical point of view. It will be enough to say that the branches generally arise close together at the inner side of the anterior scalenus muscle.

On the right side also, the branches occupy usually the same position in regard to the scalenus muscle; and in consequence of this part being accessible in an operation for aneurism, it is desirable to determine the ordinary distance between the commencement of the artery and the nearest branches.

In a majority of many observations the interval measured from half an inch to an inch; in a smaller number, more than one inch and not exceeding an inch and a half. The space seldom varied from these limits; but in a few instances it was found to be less than half an inch, and it amounted, in one case only, to an inch and three-quarters.

It occasionally happens that, instead of the three branches arising close together, one is shifted inwards from the accustomed position. In a very few cases the branches were seen to arise at intervals, being, as it were, dispersed over the first part of the artery. Lastly, one or more of the branches have been (very unfrequently however) moved outwards to another division of the subclavian.

The *second* portion of the subclavian artery was found in about two-thirds of a large number of cases (upwards of two hundred and sixty) to give origin to only a single branch, which was usually the common trunk of the superior intercostal and deep cervical arteries. In the remaining third of the total number of cases examined, this part of the subclavian artery was, in most instances, quite destitute of branches, and this occurred more frequently on the left than on the right side. In some few cases, two and even three branches arose from it.

As regards the *third* part of the artery: in more than half of upwards of two hundred and sixty cases, it furnished no branch whatever; in less than half, it gave origin to a single branch, which was usually the posterior scapular artery. A few examples occurred of two, and much more rarely of three branches, arising from this part of the vessel.



## SURGICAL ANATOMY OF THE SUBCLAVIAN ARTERIES.

The subclavian artery is so deeply placed, its connexions with important parts are so intimate and varied, and the branches are so large in proportion to the length of the trunk, that operations on this vessel present, in most cases, considerable difficulties to the surgeon. But the difficulties, it will be found, vary in different cases.

The last division of the artery, that beyond the anterior scalenus muscle, is the part which is most favourably circumstanced for the application of a ligature in the cases in which such an operation is most frequently called for, namely, aneurism affecting the artery in the axilla. This part is preferable chiefly because the vessel is here nearest to the surface and most remote from the origin of the large branches. But though the subclavian artery appears to be easy of access above the clavicle, while the parts are in their natural position, it is to be remembered that when an aneurism exists in the axilla, the clavicle may be so much elevated in consequence of the presence of the tumour, as to be placed in front of the vessel, or even above it. In such circumstances, the artery lies at a great depth, at the same time that the structures in front and behind it (the clavicle on the one hand, the vertebræ with the muscles covering them on the other hand), cannot, in any degree, be drawn asunder to facilitate the steps of the operation. It is when the outer part of the clavicle is thus raised from the ordinary horizontal position, that the height to which the artery arches above the bone becomes a point of importance. In most cases it happens that a portion of the artery is a short distance (about an inch) above the clavicle; but occasionally, as before mentioned (p. 559) it rises much higher; or it may be lower than usual, lying close behind the bone. If, in a case rendering the operation necessary, the clavicle should be unusually raised, the accessibility of the vessel in the neck will differ in these several conditions. In one, the artery could be arrived at only by proceeding from above downwards behind the bone; in another, a part of it would still be higher than the bone. This will serve, in part at least, to account for differences in the time which the operation for tying the subclavian artery has occupied in the hands of different surgeons, and even in the hands of the same surgeon in different cases.\*

The principal facts bearing on the actual performance of an operation on the third part of the subclavian artery, will now be briefly recalled. The most prominent or convex part of the clavicle, the part of the bone opposite which the vessel lies, will serve as a guide for the middle of the first incision, which is to be made a little above the clavicle, and parallel with it. If, (after noting with the eye, or marking on the surface the line at which it is desired to make the incision,) the integument be drawn downwards over the clavicle, the parts covering the bone may be divided with freedom.

With the integument, the platysma and several nerves are divided in this incision, but no vessel is endangered, except in those rare cases in which the cephalic vein or the external jugular crosses over the clavicle. It will, in most cases, be an advantage to add a short vertical incision, directed downwards to the middle of the horizontal one. Should the sterno-mastoid muscle be broad at its lower end, or should the interval between that muscle and the trapezius be insufficient for the further steps of the operation, a portion of the former muscle, or even of both muscles, must be divided.

The external jugular vein next presents itself with the veins joining it from the shoulder, and, as this vein is usually over the artery, it must be held aside, or it

\* This statement will be illustrated by reference to two cases which occurred at nearly the same time in the practice of the same surgeon. In March, 1819, M. Dupuytren tied the subclavian artery for axillary aneurism, and the result was in all respects favourable.—See "*Leçons orales*," &c., t. iv.; and M. Marx in "*Repert. général d'anatomie*," &c., 1826.

Two or three weeks afterwards, the same surgeon being engaged in performing an operation of the same kind, was compelled to discontinue it for a time in consequence of the sufferings of the patient, and an hour and forty-eight minutes elapsed before the operation was concluded. The patient died of hemorrhage in four days; and, on examination after death, it was found that the artery had been perforated with the aneurism needle. One of the large nerves, and half the artery, had been included in the ligature. This case is reported by Dr. Rutherford, R.N., who was present at the operation, in "*Edinburgh Med. and Surg. Journal*," vol. xvi. 1820.



may be necessary to divide it. If divided, the lower end of the vessel requires the application of a ligature as well as the upper one, in consequence of the reflux of blood from the subclavian vein. The omo-hyoid muscle will be turned aside if necessary; and now must be determined the exact position at which the artery is to be sought by division of the deeper fasciæ. If the clavicle has its usual horizontal direction, the slight prominence on the first rib is the best guide to the vessel, where it rests on the rib. The brachial nerves are here, it is to be remembered, close to the vessel,—so much so, that the ligature has in several cases been passed in the first instance round one of them instead of the artery. But if, in consequence of the disease rendering the operation necessary, the outer end of the clavicle is much raised, then it will, in many cases, be more easy to place the ligature on the artery above the insertion of the scalenus muscle, or even behind that muscle. Above the tubercle on the first rib, the situation of the vessel may be ascertained by means of the brachial nerves and the scalenus muscle; and, before the membrane covering them is divided, the position of these structures may be ascertained by the difference they offer to the touch. The cord-like nerves and the smooth flat muscle may thus be readily distinguished. At the same time the influence of pressure at a particular point, in controlling the pulsation in the aneurism, will, in this, as in other operations on the arteries, assist the surgeon.

Before concluding the remarks on the third division of the artery, it should be mentioned that the suprascapular or transverse cervical artery may be met with in the operation, which in other cases may be complicated by the occurrence of a branch, or, however rarely, of branches taking rise beyond the scalenus muscle.

The *second division of the subclavian artery* is the part which rises highest in the neck, and on this account it may be advantageously selected for the application of a ligature when the vessel is difficult of access beyond the muscle. The chief objection to operating on the artery in this situation arises from the contiguity of the large branches. Care is necessary in dividing the scalenus muscle to avoid the phrenic nerve and the internal jugular vein. Moreover, the fact of the entire of the subclavian artery being in apposition with the pleura, except where it rests on the rib, must be borne in mind.

Some difficulty may arise from a change in the position of the artery, as when it lies between the fibres of the anterior scalenus, or when it is in front of that muscle; but such cases are of very rare occurrence, and the knowledge of the fact that the vessel may be thus displaced will assist the surgeon in the event of difficulty arising from this cause.

*Before it reaches the scaleni muscles* the left subclavian artery may be said to be inaccessible for the application of a ligature, in consequence of its depth and its close connexion with the lung and other structures calculated to create difficulty in an operation, among which may be mentioned the internal jugular and left innominate veins. To the difficulties resulting from the manner of its connexion with the parts now named, must be added the danger of performing an operation in the neighbourhood of the large branches.

On the right side, though deeply placed and closely connected with important parts, the first division of the subclavian artery may be tied without extreme difficulty. But inasmuch as the length of the vessel, between its three large branches on the one hand and the common carotid on the other, ordinarily measures no more than an inch, and often less, there is little likelihood of the operation in question being successfully performed in any case; and the probability of success must be held to be still further diminished when it is considered that the length of the free part of the artery is sometimes lessened by one of the large branches arising nearer than usual to its commencement.

In order to place a ligature on the portion of the right subclavian artery here referred to, it is necessary to divide by horizontal incisions the three muscles which cover it, together with the layers of fascia between and beneath them. While the muscles are being divided, a branch of the suprascapular artery will probably require to be secured. The position of the inner end of the clavicle and of the trachea, and the effect of pressure with the finger on the circulation in the aneurism or in the limb, will assist the surgeon in finding the artery without dissecting the surrounding parts to an unnecessary and injurious extent—a pre-



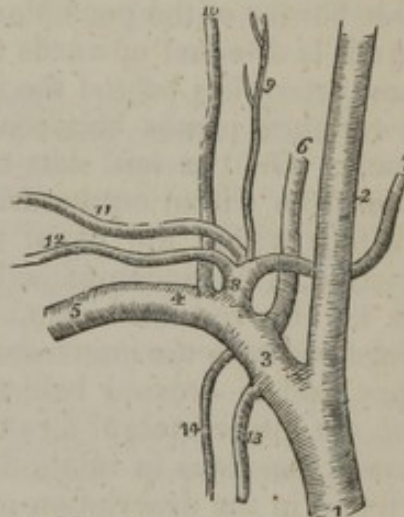
caution of importance in all cases. In the further steps of the operation, the exact position of the internal jugular vein, the vagus nerve, and the pleura, are to be well remembered.

The right subclavian artery is occasionally somewhat more deeply placed than usual in the first part of its course; and this occurs when it springs from the left side of the arch, or, more frequently, when it separates from the innominate behind the carotid. The advantage of a knowledge of this fact I had an opportunity of putting to the test in an operation for aneurism at which I assisted a few years ago. The same arrangement of the vessels has since repeatedly come under my observation.

#### BRANCHES OF THE SUBCLAVIAN ARTERIES.

The three large branches which arise from the first part of the subclavian artery spring from the parent trunk very close to each other, and are deeply seated at their origin under cover of the internal jugular vein. They proceed, however, from different sides of the parent vessel, pursue different directions, and are distributed to remotely separate parts. Thus, one (vertebral) (fig. 241,<sup>6</sup>) springs from the upper and back part of the subclavian, and ascends in the neck to reach the interior of the skull; another (internal mammary) proceeds from the lower or under side of the vessel, and descends into the fore part of the chest and abdomen; whilst the third (thyroid axis)<sup>8</sup> arises from the fore part of the artery, and divides into three branches, one of which (inferior thyroid)<sup>7</sup> is distributed in the fore part of the neck, whilst the other two (suprascapular<sup>12</sup> and transverse cervical)<sup>11</sup> pass outwards across the neck to the shoulder. Lastly, from the second part of the subclavian artery, two other branches arise by a common trunk; of which one (deep cervical)<sup>10</sup> passes upwards behind the neck, and the other (superior intercostal)<sup>14</sup> descends into the back part of the thorax.

[Fig. 241.



The branches of the right subclavian artery. 1. The arteria innominata. 2. The right carotid. 3. The first portion of the subclavian artery. 4. The second portion. 5. The third portion. 6. The vertebral artery. 7. The inferior thyroid. 8. The thyroid axis. 9. The superficialis cervicis. 10. The profunda cervicis. 11. The posterior scapular or transversalis cervicis. 12. The supra-scapular. 13. The internal mammary artery. 14. The superior intercostal.—W.]

#### VERTEBRAL ARTERY.

The *vertebral artery* (fig. 241,<sup>6</sup>) [vertebralis,] which is usually the first and largest branch of the subclavian, passes upwards through the foramina in the transverse processes of the cervical vertebræ; and after a winding course enters the skull through the foramen magnum, and terminates in front of the medulla oblongata, by uniting with the corresponding vessel of the opposite side, to form the basilar artery. The singular course of this vessel, thus generally indicated, requires a more precise examination.



Arising from the upper and back part of the subclavian, the vertebral artery passes upwards and a little backwards, and enters the foramen in the base of the transverse process of the sixth cervical vertebra—not unfrequently of some higher vertebra. The vessel then ascends in a vertical direction along the canal formed by the series of foramina in the transverse processes of the vertebræ, as far as to the upper border of the axis; here, in consequence of the greater width of the atlas, it inclines outwards to the foramen in the root of the transverse process of that bone. Having passed through this foramen, the artery alters its direction and winds backwards behind the articulating process of the atlas, resting in the shallow groove on the posterior arch of the vertebra. After piercing the ligament (posterior occipito-atloidean) connecting the atlas to the occiput, and also the dura mater, it enters the skull through the foramen magnum of the occipital bone, and finally, proceeding upwards and forwards, turns round the side of the medulla oblongata, and converging towards the corresponding vessel of the opposite side, unites with it opposite the lower border of the pons Varolii, to form the basilar artery.

As it is directed upwards from its origin towards the spine, the vertebral artery lies behind the internal jugular vein, and on approaching the vertebræ passes between the longus colli and the scalenus anticus muscle. On the left side, the thoracic duct crosses in front of the vessel from within outwards.

Whilst within the canal formed by the foramina of the cervical vertebræ, it is accompanied by a plexus of the sympathetic nerves and by the vertebral vein, which is before it. Here the artery is placed between the intertransverse muscle in the intervals between the bones, and is crossed behind by the cervical nerves as they emerge from the intervertebral foramina. The first and second nerves have peculiar positions in relation to this artery, an account of which will be found in the description of these nerves.

In the interval between the atlas and the occipital bone the vertebral artery is covered by the superior oblique, complexus, and rectus posticus major muscles. Within the skull, it turns round the side of the medulla oblongata between the origin of the ninth cranial nerve and the anterior root of the suboccipital, and then lies between the anterior surface of the medulla and the basilar process of the occipital bone.

*Peculiarities of the vertebral artery.*—There is no recorded instance of the origin of this vessel being transferred from the first part of the subclavian artery to the parts situated beneath and beyond the scalenus muscle.

On the *right* side, the origin of the vertebral artery in some cases approaches more nearly to the commencement of the subclavian than usual. The right vertebral has also been seen to arise from the common carotid of the same side, and in the examples of this peculiarity which have been observed, the right subclavian artery was given as a separate vessel from the aorta. The change in the subclavian artery is, however, far from being necessarily, or even generally, accompanied by an alteration in the place of origin of the vertebral. Lastly, the right vertebral artery has been observed, but only in two instances, to be a branch of the aorta.

The *left* vertebral artery is not unfrequently derived from the aorta, in which case it generally arises between the left carotid and subclavian arteries, but sometimes it is the last of the branches from the arch.



The left vertebral artery, in a few instances, and the right vertebral in one, have been found to arise by more than a single root. In most of these cases there were two roots, both of which proceeded from the subclavian artery, or one from that vessel and one from the aorta. Whatever their mode of origin, these two parts unite to form a single vessel, either before they enter the canal in the vertebræ, or after one of the vessels has passed through the transverse process of one or two vertebræ. An example of three roots to a vertebral artery has been placed on record.

Instead of entering the canal formed by the foramina in the transverse processes of the cervical vertebræ, through the foramen in the transverse process of the sixth vertebra, the vertebral artery of one side not unfrequently enters this canal higher up—through the foramen of the fifth, fourth, or third vertebra,—or even, according to several anatomists, of the second. On the other hand, the vertebral artery has been seen to enter the foramen in the transverse process of the seventh vertebra.

One of the vertebral arteries often exceeds the other in size. The left is said to be the larger vessel more frequently than the right.

#### BRANCHES OF THE VERTEBRAL ARTERY.

The branches of the vertebral artery are numerous. Some small ones are given off in the neck, and others of greater size within the skull.

*a. Cervical branches.*—In the neck, the vertebral artery sends off at different points of its course several small branches named *spinal* arteries. Each of these entering the spinal canal through an intervertebral foramen divides into two branches, of which one passes along the roots of the spinal nerve, assists in supplying the spinal cord and its membranes, and anastomoses with the other spinal arteries; whilst the other branch ramifies on the back part of the bodies of the vertebræ in the same manner as similar branches derived from the intercostal and lumbar arteries, which will be hereafter described.

The vertebral artery also gives muscular branches of variable size to the deep-seated cervical muscles.

*b. Cranial branches.*—The *posterior meningeal* [a. meningeæ post. int.] is a small branch which arises opposite to the foramen magnum, and ramifies between the dura mater and the bone in the occipital fossa and upon the falx cerebelli. There are sometimes two of these small vessels.

The *posterior spinal*, fig. 240, *m*, [a. spinalis post.], arising at an obtuse angle from the vertebral, inclines backwards round the medulla oblongata to reach the back part of the spinal cord, along which, aided by reinforcements from small arteries which ascend upon the cervical and dorsal nerves through the intervertebral foramina, it may be traced, lying behind the roots of the nerves, as a minute tortuous vessel, or rather a series of little inosculating vessels, as far as the second lumbar vertebra, where it terminates in ramifications on the cauda equina. Some of its branches run upon the cord around the roots of the nerves, whilst others maintain frequent transverse communications with similar branches from the vessel of the opposite side.

The *anterior spinal artery*, *n*, [a. spinalis ant.] somewhat larger than the preceding, arises near the end of the vertebral artery, and descends obliquely in front of the medulla oblongata. Immediately below the foramen magnum, it unites with the corresponding vessel of the opposite side, so as to form a single trunk, which descends a short distance only along the middle line in front of the spinal cord, forming the upper part or commencement of the anterior median artery of the cord. This anterior spinal branch of the vertebral artery supplies therefore only the upper part of the cord, the greater part being provided with a series of small arteries, which are derived in the neck from the vertebral and inferior thyroid arteries, in the back from the intercostal, and below this from the lumbar, ilio-lumbar, and lateral sacral arteries. These small vessels enter the spinal canal at irregular intervals through the intervertebral foramina, and reaching the anterior surface of the cord by passing along the roots of the nerves, communicate with



each other along the middle line by means of ascending and descending branches; so that, by a succession of anastomoses, a very slender single vessel, but of varying thickness, named the *anterior median artery*, appears to extend from one end to the other of the cord. This vessel, or chain of inosculating vessels, is placed beneath the pia mater along the anterior median fissure of the spinal cord. Its numerous branches supply the pia mater and the substance of the cord—some entering its anterior median fissure. At the lower end of the cord it sends branches downwards on the cauda equina.

On a part of the spinal cord near the lower end, and in front of the posterior roots of the nerves, may be found another small artery, about equal in size to the anterior spinal.

The *inferior cerebellar artery* [a. cerebelli inf.] (*profunda cerebelli*,—Haller), the largest of the branches of the vertebral, arises near the pons, and sometimes from the basilar artery: it turns backwards and outwards, between the hypoglossal and pneumogastric nerves, over the restiform body, and near the side of the opening of the fourth ventricle to reach the under surface of the cerebellum. Here, running backwards between the inferior vermiform process and the hemisphere, it divides into two branches, one of which continues backwards to the notch between the two hemispheres of the cerebellum; whilst the other, turning outwards, ramifies on the under surface of the cerebellum as far as its outer border, over which the ultimate divisions of each branch anastomose with those of the superior cerebellar arteries. This artery partly supplies the hemisphere and the vermiform process, and gives branches to the choroid plexus of the fourth ventricle.

The *basilar artery*, fig. 240, *k*, [a. basilaris] the single trunk, formed by the junction of the right and left vertebralis in the middle line, is so named from its lying on the basilar process of the occipital bone. It extends from the posterior to the anterior border of the pons Varolii, beneath the median groove of which it lies, under cover of the arachnoid. The length of this artery is therefore about equal to the breadth of the pons, at the anterior border of which it divides into two terminal branches, the posterior arteries of the cerebrum.

#### BRANCHES OF THE BASILAR ARTERY.

The basilar artery supplies many small branches to the substance of the pons. On each side it also gives several transverse branches, one of which accompanies the acoustic nerve into the internal auditory meatus and labyrinth of the ear, and another of more considerable size, the *anterior cerebellar artery* (*cerebelli inferior anterior*), which passes backwards along the fore part of the crus cerebelli to the anterior part of the under surface of the cerebellum.

The *superior cerebellar artery*, fig. 240, [a. cerebelli sup.]—The superior arteries of the cerebellum arise so close to the bifurcation of the basilar, that this artery is described by several anatomists as dividing into four branches. Each one turns backwards and outwards immediately behind the third nerve, and entering the groove between the pons Varolii and the crus cerebri, turns round the latter, close to the fourth nerve, to reach the upper surface of the cerebellum, where it divides into branches. Of these some extend outwards, and one or more backwards along the superior vermiform process, to reach the circumference of the cerebellum, where they anastomose with the branches of the inferior cerebellar arteries: other branches run inwards to supply the vermiform process and valve of Vieussens, and in part the velum interpositum—an extension of the pia mater into the interior of the brain.

The *posterior cerebral artery*, *p*, (*posterior aut profunda cerebri*,—Haller), is larger than the preceding vessel, and is separated from it at its origin by the third nerve, which comes forward between the two vessels. It turns backwards round the crus cerebri, at first parallel with the last-named vessel, and then runs outwards and upwards on the under surface of the posterior lobe of the cerebrum, passing near the posterior extremity of the corpus callosum. It divides beneath



the posterior lobe into many branches, which ramify upon its under, inner or median, and outer surfaces, and anastomose with the other cerebral arteries. Immediately after its origin, the posterior cerebral artery gives off numerous small parallel branches, which perforate the substance of the brain between its crura, at the point which is called from this circumstance the posterior perforated spot (*locus perforatus*). As it turns backwards, a short distance from its origin, this artery is joined by the *posterior communicating artery*, or communicating artery of Willis, a branch of the internal carotid, and in this way contributes, as already described (p. 555), to form the circle of Willis. Lastly, the posterior cerebral gives origin to a small branch, the *posterior choroid* (*choroidea posterior*), which arises from it soon after its junction with the communicating artery, turns backwards over the *crus cerebri* and the *tubercula quadrigemina*, supplying these with branches, and ending in the *velum interpositum* and *choroid plexus*, which enter the interior of the brain beneath the *corpus callosum*.

*Peculiarities of the branches of the vertebral artery.*—In the neck, the vertebral artery has been found, though very rarely, to give branches which are usually derived from the subclavian, as the superior intercostal and the inferior thyroid.

In two instances, the septum formed by the juxtaposition of the vertebral arteries behind the basilar, has been observed by Dr. Davy\* to be perforated by an opening as large as a probe. Not unfrequently the interior of the basilar artery itself is traversed by a fibrous band, which is attached to the sides of the vessel. This band varies in situation and dimensions, and is considered by Dr. Davy to be congenital, and not the result of disease.

In one instance the basilar artery was joined by a large branch of the internal carotid.

The posterior cerebral artery is occasionally given off on one side from the internal carotid artery. Sometimes a small "aberrant" branch is connected with the side of the basilar. Lastly, the basilar artery has been found to be perforated by a small foramen, owing to a partial fissuring of the vessel, along the median line.

#### THYROID AXIS.

Thyroid axis [fig. 241,<sup>s</sup>] (*inferior thyroid artery: thyreoidea inferior arteria*—Haller).—The name "axis" is applied to this artery because immediately after its origin it divides into branches, which diverge in different directions, viz. the inferior or ascending thyroid, the transverse cervical, and the suprascapular. The thyroid axis springs from the fore part of the subclavian artery close to the inner side of the anterior scalenus muscle. It is a short thick trunk, and usually divides a line or two from its origin into the branches above named.

*Peculiarities of the thyroid axis.*—Exceptions to the regular place of origin of the thyroid axis at the inner side of the scalenus muscle are very rare. The vessel has, in two cases, been found to arise beyond that muscle.

Sometimes the thyroid axis is associated at its origin with another branch. Thus, it gave origin to the internal mammary in about one case in twenty; and once only, in nearly three hundred cases, to the vertebral; once to the superior intercostal, and once to the profunda cervicis.

The deviations from the ordinary arrangement of the branches of the thyroid artery, will be examined under each branch.

The *inferior thyroid artery*<sup>7</sup> (*ramus thyreoideæ thyreoideus*,—Haller.)—This name is by most authorities applied to the common trunk here recognised as the axis. The artery passes directly upwards resting on the longus colli muscle, and, after a short course, bends inwards and downwards, behind the sheath of the large cervical vessels, and also behind the sympathetic nerve (the middle cervical ganglion of which, when present, often rests upon the vessel). The artery now makes another curve in the opposite direction to the former one, and is dis-

\* "Researches," &c., vol. i. p. 301.



tributed to the under surface of the thyroid body. Its branches communicate freely with those of the superior thyroid artery (an offset from the external carotid), and with the corresponding artery of the other side.

The inferior thyroid artery usually supplies a *laryngeal* branch of irregular size, which ascends on the trachea to the back of the larynx, and is distributed to the muscles and mucous membrane in that situation. It also gives off *tracheal* branches which ramify over the trachea, upon which they anastomose below with the bronchial arteries. Other small branches are supplied to the œsophagus, and one or more descend upon the trachea into the chest.

*Peculiarities.*—The inferior thyroid artery occasionally arises as an independent branch—generally from the subclavian artery, and rarely from the common carotid or the vertebral.

This artery is often smaller than usual, or it may be entirely wanting on one or both sides,—the deficiencies being generally compensated for by an enlargement of one or both superior thyroid arteries. On the contrary, one or both inferior thyroid arteries are sometimes larger than usual when the superior arteries are small. Instances have occurred—very rarely, however,—of the presence of two inferior thyroid arteries, one passing over the common carotid artery.

In this place may be noticed, in connexion with the peculiarities of the inferior thyroid arteries, that there is sometimes found an additional artery for the thyroid body, which has been named the *lowest thyroid artery* (*thyroidea ima*, of Neubauer and Erdmann). This artery usually arises from the innominate trunk, but in rare instances has been observed to come from the right common carotid artery, or from the aorta itself. It is of very different size in different cases, and compensates in various degrees for deficiencies or absence of the other thyroid arteries. This unusual thyroid artery ascends to its destination in front of the trachea, and its existence would therefore complicate the operation of tracheotomy.

The *ascending cervical artery* (*ramus thyreoidæ adscendens*,—Haller;) [*a. cervicalis ascendens*]. At the point where the inferior thyroid, changing its direction, turns inwards behind the carotid artery, a small branch thus named arises from it and proceeds upwards, close to the phrenic nerve, on the line of separation between the *scalenus anticus* and *rectus anticus major*, giving branches (muscular) to these muscles, and a few which pass transversely outwards across the neck. These muscular branches communicate with others sent outwards from the vertebral artery. To the spinal canal the ascending cervical artery sends one or two branches (*spinal branches*), which enter the intervertebral foramina along the cervical nerves, and assist in supplying the bodies of the vertebræ, the spinal cord, and its membranes.

*Peculiarities.*—The ascending cervical artery is occasionally derived from the subclavian artery or from one of the branches of that vessel, as from the transverse cervical, or the suprascapular, or from the trunk common to those two arteries.

It is sometimes much larger than usual, and takes the place of the occipital artery, a branch of the external carotid. A branch of the ascending cervical not unfrequently compensates for a small *profunda cervicis* artery.

#### SUPRASCAPULAR ARTERY.

The *suprascapular artery*,<sup>22</sup> (*ramus transversus scapularis*,—Haller), [*a. transversa scapulæ*] a smaller vessel than the succeeding branch, the transverse cervical, arises almost constantly from the thyroid axis, and runs from within outwards deeply at the root of the neck. At first it descends obliquely towards the clavicle, resting upon the *scalenus anticus*, and covered by the sterno-mastoid muscle; then crosses the subclavian artery, and continues transversely outwards behind and parallel with the clavicle and subclavius muscle, and below the posterior belly of the *omo-hyoid* muscle. At the outer side of the neck,



this artery approaches the upper margin of the scapula; and here, under cover of the trapezius muscle, it runs downwards with the suprascapular nerve towards the notch at the root of the coracoid process in the upper border of the scapula. At this point the nerve usually passes beneath the ligament stretched across the notch, whilst the artery turns over it to enter the supraspinous fossa; where, lying close to the bone, it gives off branches which ramify in the supraspinous fossa, beneath the supraspinatus muscle, and sends a small communicating branch into the subscapular fossa.

*Peculiarities.*—The suprascapular artery has in some cases been observed to spring directly from the subclavian, or to arise from that vessel by a common trunk with the transverse cervical, or more rarely with the internal mammary. It has been even found to proceed from the axillary artery, and from the subscapular branch of that vessel.

*Branches.*—At the root of the neck, whilst under cover of the sterno-mastoid, the suprascapular artery gives off a small branch which runs inwards through the attachment of that muscle, and supplies it. In its course across the neck, the artery sends small unnamed branches to the adjacent muscles.

It also gives a *supra-acromial branch*, which passes obliquely downwards through the attachment of the trapezius to reach the cutaneous surface of the acromion, on which it ramifies, anastomosing with offsets from the acromial thoracic artery.

As the artery passes over the notch of the scapula, a small branch arises from it, and turns forwards over the neck of the bone to enter the subscapular fossa, where it ramifies beneath the subscapular muscle, and anastomoses with the posterior scapular and subscapular arteries. After having given off this branch, the artery enters the supraspinous fossa and ramifies between the bone and the supraspinatus muscle, to which it is chiefly distributed.

The suprascapular artery also supplies branches to the bone and to the shoulder-joint; and sends downwards a communicating branch, which descends close upon the neck of the scapula, between the glenoid cavity and the spine of that bone and beneath the acromion process, in order to reach the infraspinous fossa, and join with the dorsal branch of the subscapular artery.

#### TRANSVERSE CERVICAL ARTERY.

The *transverse cervical artery*,<sup>11</sup> [a. transversa colli,] the third branch of the thyroid axis, passes outwards a short distance above the clavicle, and therefore higher than the suprascapular artery. It crosses over the scaleni muscles and the brachial nerves,—sometimes passing through the divisions of the latter. Beneath the anterior margin of the trapezius, and near the outer edge of the levator anguli scapulæ, it divides into two branches, the superficial cervical, and the posterior scapular. The transverse cervical artery lies deeply in its entire course; being covered by (besides the platysma and the fascia) the sterno-mastoid, the omo-hyoid, and the trapezius muscles. Its terminal branches are the two following:—

The *superficial cervical* (superficialis cervicis) ascends beneath the anterior border of the trapezius, and distributes branches to the trapezius, levator anguli scapulæ, and sterno-mastoid muscles, as well as to the cervical glands and the integuments in the interval between those muscles.

The descending or *posterior scapular branch*, [a. posterior scapulæ,] fig. 243, b, which may be considered the continuation of the transverse cervical, passes backwards to the posterior angle of the scapula under cover of the levator anguli scapulæ, and then changing its direction, runs downwards beneath the rhomboidei muscles and the base of the scapula, as far as the inferior angle of that bone. It



anastomoses freely on both sides of the scapula with the divisions of the suprascapular and the subscapular arteries; and supplies branches to the rhomboidei, serratus magnus, and latissimus dorsi, communicating at the same time with the posterior muscular branches of some of the intercostal arteries.

PECULIARITIES IN THE TRANSVERSE CERVICAL ARTERY,  
AND ITS BRANCHES.

The frequent varieties which occur in the arrangement of the transverse cervical artery and its two branches, have occasioned them to be very differently described and named by different anatomists.

The condition above noticed is that most commonly met with,—viz., that the transverse cervical artery is the third branch given off by the thyroid axis, and divides near the levator anguli scapulæ into the superficial cervical and the posterior scapular arteries.

In a number of cases, however, so great as to have been regarded by some as representing the ordinary condition, the *superficial cervical* portion of the artery only is derived from the thyroid axis, whilst the *posterior scapular* arises as a separate vessel from the subclavian artery, most commonly beyond the scalenus muscle.

In a third class of cases, not nearly so common, the vessel derived from the thyroid axis is very small, and represents only in part the superficial cervical artery; whilst a large vessel arising from the third part of the subclavian divides near the levator anguli scapulæ into two branches, of which one ascends and represents the remaining and larger portion of the superficial cervical artery, whilst the other forms the posterior scapular.

The transverse cervical artery is sometimes derived directly from the subclavian, or it arises from that vessel in common with the suprascapular, or occasionally with that and the internal mammary artery also. When the transverse cervical artery arises separately from the subclavian artery, its place of origin may be beneath or even beyond that muscle. The transverse cervical artery sometimes gives off the ascending cervical.

When the *superficial cervical* is separated from the posterior scapular, it sometimes arises from other sources than the thyroid axis, as from the suprascapular, or the subclavian.

The *posterior scapular* was observed, when derived from the subclavian as a separate branch, (a very common arrangement, it will be remembered,) to take its origin beyond the scalenus in more than two-thirds of a considerable number of cases, and, in less than one-third, beneath that muscle; in one case only did it arise to the inner side of the muscle.

INTERNAL MAMMARY ARTERY.

The *internal mammary artery*, (fig. 241,<sup>13</sup>) [*a. mammaria interna*], remarkable for its length and the number of its branches, arises from the under side of the subclavian, opposite to the thyroid axis. It runs forwards and downwards behind the clavicle, to reach the inner surface of the cartilage of the first rib, lying between it and the sac of the pleura; from this point it inclines a little inwards for a short space, and then descends vertically behind the costal cartilages, a short distance from the border of the sternum, as far as to the interval between the sixth and seventh costal cartilages, where the internal mammary artery is considered to end, by dividing into two branches. One of the branches into which the artery divides (musculo-phrenic) inclines outwards, along the margin of the thorax; whilst the other, under the name superior epigastric, continues in the original direction of the trunk, onwards to the abdomen.

Covered at its origin, like the other large branches of the subclavian artery, by the internal jugular vein, the internal mammary soon passes behind the subclavian vein, and is crossed in front by the



phrenic nerve, which is between the vein and the artery.\* In the chest it has at first the costal cartilages and the internal intercostal muscles before, and the pleura behind; but lower down it lies between the cartilages and the triangularis sterni muscle—the muscle separating the vessel from the pleura.—This artery has two companion veins, which, however, are united into a single venous trunk at the upper part of the chest.

*Peculiarities.*—The internal mammary is occasionally found connected at its origin with the thyroid axis, or with the scapular arteries—these being detached from the thyroid. It occasionally springs from the second or third part of the subclavian artery (the latter being the more frequent position of the two). The internal mammary is very rarely transferred away from the subclavian to another artery. The axillary, the innominate,† and the aorta, have been found to give origin to it. Of each of the last two changes but a single example has been recorded.

#### BRANCHES OF THE INTERNAL MAMMARY ARTERY.

The branches of this long artery are numerous, and are chiefly distributed to the walls of the chest and abdomen.

The *superior phrenic* or *comes nervi phrenici*, a very slender branch, arises high in the chest, and descends with the phrenic nerve (as its name implies), between the pleura and the pericardium, to the diaphragm, in which it is distributed, anastomosing with the other phrenic branches derived from the musculo-phrenic division of the internal mammary artery, and with the inferior phrenic arteries which come from the abdominal aorta.

The *mediastinal* or *thymic* branches, [a. mediastinicae s. thymicae,] of very small size, ramify in the cellular tissue of the anterior mediastinum, and supply the remains of the thymus body, which, when in full development, receives its principal branches from the internal mammary artery. *Pericardiac* branches are given off directly to the upper part of the pericardium, the lower part of which receives some from the musculo-phrenic division. Branches, named *sternal*, are also supplied to the triangularis sterni muscle and to both surfaces of the sternum.

The *anterior intercostal arteries*, [a. intercostales ant.] two in each space, arise from the internal mammary, either separately or by a trunk common to the two, which soon divides. The arteries pass outwards, at first between the pleura and the internal intercostal muscles, and afterwards between the two layers of intercostal muscles; they lie one near the upper, and one near the lower rib in each of the upper five or six intercostal spaces, and inosculate with the corresponding intercostal branches derived from the aortic intercostals. These branches supply the intercostal and pectoral muscles, and give some offsets to the mamma and integument.

The *anterior* or *perforating* branches, [rami perforantes] pass forwards from the internal mammary artery through from four to six intercostal spaces, and turning outwards ramify partly in the pectoralis major, and partly in the integument on the front of the chest. Some of these perforating branches (those placed nearest to the organ) supply the mammary gland, and in the female they are of comparatively large size, especially during lactation; and some offsets ramify on the sternum and on the articulations of that bone with the cartilages of the ribs.

The *musculo-phrenic* artery, [a. musculo-phrenica] the outer of the two branches into which the internal mammary artery divides, inclines downwards and outwards behind the cartilages of the false ribs, perforating the attachment of the diaphragm at the eighth or ninth rib, and becoming gradually reduced in size as it reaches the last intercostal space. It gives branches backwards into the diaphragm; others, which pass outwards to form the anterior intercostals of each space, and are disposed precisely like those which are derived higher up from the internal mammary itself; and some which descend into the abdominal mus-

\* The nerve has been observed in front of the vein.

† Erdmann, loc. citat. p. 37.



cles. Each of these sets of branches anastomose with those derived from other sources and distributed to the same parts.

The *superior epigastric* artery, [a. epigastrica sup.] the abdominal division of the internal mammary, continues in the direction of that artery, and descends behind the seventh costal cartilage to gain the wall of the abdomen, in which it lies behind the rectus, between the muscle and its sheath. From this artery, branches are furnished to the upper part of the rectus, and anastomose with the ascending ramifications of the epigastric artery, a branch of the external iliac. Small vessels are likewise supplied to the broad muscles of the belly, and to the skin; some are distributed to the diaphragm, and one runs forwards upon the side and front of the xiphoid cartilage, where it anastomoses with that of the opposite side.

*Unusual branches.*—The internal mammary artery occasionally gives origin to the suprascapular; or furnishes a bronchial artery. An unusual branch has also been observed descending vertically from the artery at the side of the thorax, and crossing the middle of a few of the ribs, on their inner surface, in contact with the pleura.

#### SUPERIOR INTERCOSTAL ARTERY.

The *superior intercostal artery*<sup>14</sup> [a. intercostalis sup. s. truncus costo-cervicalis] generally arises from the upper and back part of the subclavian, under the anterior scalenus muscle on the right side, and immediately at the inner side of the muscle on the left side. Taking its course backwards, it speedily gives off the deep cervical branch (*profunda cervicis*), and bends backwards and downwards in front of the neck of the first, or first two ribs, and ends in the first or second intercostal space. On the neck of the first rib, the artery is situated on the outer side of the first dorsal ganglion of the sympathetic nerve. In the first intercostal space the superior intercostal artery gives an intercostal branch similar in course and distribution to the aortic intercostals; in the second intercostal space, the branch usually joins with one from the first aortic intercostal. The intercostal vessel sends backwards a small offset to the posterior spinal muscles, and also a small one through the corresponding intervertebral foramen to the spinal cord and its membranes.

*Peculiarities.*—The place of origin of the superior intercostal artery is occasionally moved to the inner side of the scalenus anticus on the right side. At the left side it has that position in a majority of cases; but is never, as far as our observation extends, moved in the opposite direction—to the outer side of the muscle. It has been found, very rarely, however, to proceed from the vertebral artery, or from the thyroid axis. In a few instances the intercostal artery was observed to pass between the necks of one or two ribs and the corresponding transverse processes of the dorsal vertebra; and in one case, after arising from the vertebral artery, it descended through the foramen in the transverse process of the last cervical vertebra, and then continued, as in the cases just mentioned, between the necks of the ribs and the contiguous transverse processes of the vertebræ of the back. This intercostal artery is sometimes, though very rarely, wanting.

#### DEEP CERVICAL ARTERY.

The *deep cervical* branch<sup>10</sup> (*profunda cervicis*) often described as a separate branch from the subclavian, arises in most cases (13 out of 14) from the superior intercostal. Resembling the posterior branch of an aortic intercostal artery, it generally passes backwards in the interval between the transverse process of the last cervical vertebra and the first rib, to reach the posterior aspect of the neck. Here it ascends in the interval between the transverse and spinous processes, as high as the second vertebra, under cover of the complexus muscle,



between it and the semi-spinalis colli. To these and other contiguous muscles it furnishes ramifications. Some of the branches communicate with those given outwards by the vertebral artery, whilst others ascend to anastomose with the cervical branch (*princeps cervicis*) of the occipital artery.

*Peculiarities.*—The deep cervical artery occasionally takes its course backwards between the last two cervical vertebræ. In several instances among a large number in which the condition of this artery was noted, it was observed to arise from the intercostal within the thorax, and to proceed backwards below the first rib and the transverse process supporting it; and even, but with much less frequency, below the second rib and transverse process. It has likewise been seen between the rib and transverse process in passing backwards.

The place of *origin* is occasionally changed. In one case in twenty the deep cervical arose from the subclavian, either beneath the anterior scalenus muscle or at its inner side; and, in a small number of cases, the posterior scapular artery was the source from which it was derived.

The deep artery of the neck is not unfrequently small, the deficiency being compensated for by an additional branch. In most cases, this supplementary artery was observed to take origin from the ascending cervical (a branch of the inferior thyroid) which turned backwards beneath the transverse process of the third cervical vertebra, and supplied the defect at the upper part of the neck. This additional artery has likewise been seen to arise from the superior intercostal (as well as the ordinary profunda); and more rarely from the posterior scapular, or the inferior thyroid.

#### AXILLARY ARTERY.

The *axillary artery* [(fig. 242) *a. axillaris*], that part of the artery of the upper limb which intervenes between the subclavian and the brachial portions, lies obliquely upon the upper and lateral part of the thorax, extending from the outer border of the first rib to the lower margin of the tendons of the latissimus dorsi and teres major muscles. In this course it passes through the axilla or axillary space, and its direction varies with the position of the limb: when the arm hangs freely by the side, the vessel describes a curve having its concavity towards the chest; when the arm is at right angles with the trunk, the vessel is nearly straight, and if the limb be still more elevated, the concavity of the curve described by the vessel is directed upwards.

This artery is deeply seated, except towards its termination, near the floor or base of the axillary space, where it approaches the surface, and on the inner side is covered only by the skin and fascia; and here (in the armpit) the flow of blood through the artery may be controlled with the finger. In order to stop the circulation, the pressure should be directed outwards, as the vessel, after leaving the thorax, where it is close to the second rib, lies to the inner side of the humerus.

In front, the axillary artery is covered, after having passed below the clavicle, by the pectoral muscles, (the greater pectoral muscle lying over it in the whole of its course, and the smaller muscle crossing over the middle of the vessel) and beneath those muscles by the costo-coracoid membrane with the thin fascia continued from it, and by the subclavius muscle. On the side of the chest the vessel is immediately in contact with the serratus magnus, which is to its inner side; and after reaching the arm, it rests against the subscapular muscle, the latissimus dorsi, and teres major, (the muscles being behind the vessel); and has before it, and to the outer side, the coraco-brachialis muscle. Towards its lower end the artery is covered, on its inner



side, only by the integument and fascia, exclusive of the vein and nerves, the position of which is now to come under consideration.

The *axillary vein* lies in a great measure in front of the artery with an inclination to the inner or thoracic side. The vein is immediately in contact with the fascia continued from the costo-coracoid membrane over the vessels and nerves; the fascia is, in fact, adherent to it. Two small veins in some instances run along the surface of the artery in the manner of *venæ comites*. The *cephalic* vein crosses over the artery near its upper end to terminate in the axillary vein; and some veins from the neighbouring muscles will likewise be found crossing it in the same way.

*Nerves.*—At the upper part of the axilla the brachial nerves lie to the outer side of the artery; about the middle of the space the plexus of nerves surrounds the artery, the roots of the median nerve crossing before the vessel, and immediately in contact with it. Below this, the nerves emanating from the plexus are placed at different sides of the artery, and the position they bear to the vessel may be stated as follows, viz., behind it, the circumflex and musculo-spiral; to its inner side, the ulnar and two internal cutaneous; to the outer side, the external cutaneous and median. The external cutaneous and the circumflex nerves leave the artery in the axilla, and at the lower part of the space or in the armpit the median nerve is commonly before the vessel; and in an operation, that nerve would serve as a guide to the position of the artery. It might be distinguished from the other large nerves (ulnar and musculo-spiral) by the circumstance of its being the nearest to the pectoral muscle.

#### THE AXILLARY SPACE.

The *axilla* or *axillary space*, through which the artery passes, is somewhat of a pyramidal form, the summit or apex being above, at the interval between the insertions of the *scaleni* muscles, and the base below, closed in by the layer of fascia stretched across between the lower borders of the *pectoralis major* and *latissimus dorsi* muscles.\* This space is bounded in front by the *pectoralis major* and *pectoralis minor*, the latter forming only a narrow part of the anterior wall, which is completed above and below it by the *pectoralis major*. The posterior boundary is formed by portions of the *latissimus dorsi*, *teres major*, and *subscapular* muscles. On the inner side, the space is bounded by the *serratus magnus*, which is spread over the side of the thorax; and on the outer side by the *subscapular*, the *coraco-brachialis* and *biceps* muscles, which lie on the humerus. The anterior and posterior boundaries are at a considerable distance from each other upon the thorax, but they converge towards the arm, so that the axilla becomes narrower in that direction.

Through the space thus circumscribed, the axillary artery, accompanied by the axillary vein and the brachial plexus of nerves, and invested with a thin fascia, extends, from apex to base, along the outer and narrower side of the axilla, and is placed nearer to the anterior than the posterior wall. At the fore part of the axilla, in contact with the pectoral muscles, lie the thoracic branches of the main vessel; at the back part is the large subscapular branch; and it is only at the inner side, towards the thorax, that large blood-vessels do not occur. In the space are contained, besides the axillary vessels and the large nerves, a considerable number of lymphatic glands and also much loose cellular membrane, which facilitates the movements of the scapula and its muscles on the side of the chest.

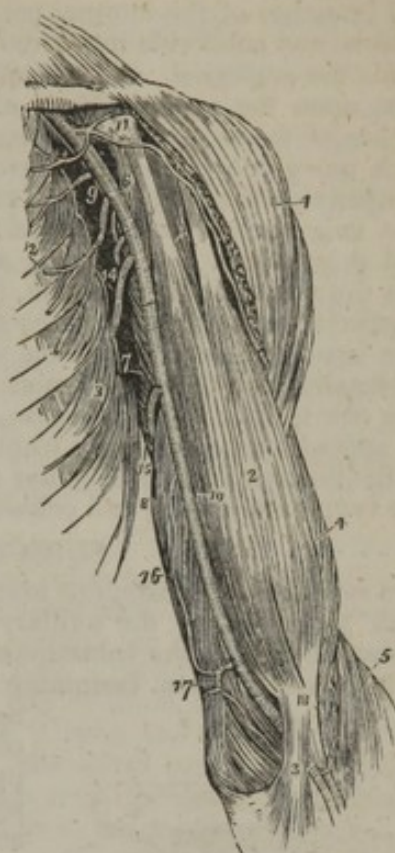\* The lower part of the axilla is sometimes crossed by a band of muscular fibres.



## PECULIARITIES IN THE AXILLARY ARTERY—THE TRUNK.

The most important peculiarity in the trunk of this vessel, consists in its giving off a much larger branch than usual,—an arrangement which has been observed in one case in every ten. In one set of cases, this large branch formed one of the arteries of the fore-arm; most frequently the radial (about 1 in 33), sometimes the ulnar (1 in 72), and, rarely, the interosseous artery (1 in 506). In another set of cases, the large branch gave origin to the subscapular, the two circumflex, and the two profunda arteries of the arm; but sometimes only one of the circumflex, or again, only one of the deep humeral arteries arose from the common trunk. In this second class of cases the divisions of the brachial plexus surround the common trunk of the branches instead of the main vessel.

[Fig. 242.]



## BRANCHES OF THE AXILLARY ARTERY.

The axillary artery, fig. 242,<sup>9</sup> gives off several branches, which supply the neighbouring structures. They consist of the branches furnished to the muscles on the chest (external thoracic); a large branch to the shoulder (subscapular); and two to the upper part of the arm (anterior circumflex and posterior circumflex). The branches are not constant in their number, size, or mode of origin.

*External thoracic branches.*—These branches vary much in number; but, after the method of Haller,\* four are usually described.

The *superior thoracic*<sup>12</sup> artery (thoracica suprema: prima—Haller) a branch of inconsiderable size, arises just above the border of the pectoralis minor, from the axillary artery itself, or, perhaps, as frequently from its next branch, the acromial thoracic. It inclines forwards and inwards, getting between the pectoral muscles, to which it is distributed; some of its branches anastomose with those of the internal mammary and intercostal arteries in the first and second intercostal spaces.

The *acromial-thoracic* artery (ar. thoracica humeraria: acromialis—Haller),<sup>11</sup> arises from the fore part of the axillary artery, being rather a large, and by far the most constant of the thoracic branches. It projects forwards at the upper border of the pectoralis minor, and soon divides

The axillary and brachial artery, with their branches. 1. The deltoid muscle. 2. The biceps. 3. The tendinous process given off from the tendon of the biceps, to the deep fascia of the fore-arm. It is this process which separates the median basilic vein from the brachial artery. 4. The outer border of the brachialis anticus muscle. 5. The supinator longus. 6. The coraco-brachialis. 7. The middle portion of the triceps muscle. 8. Its inner head. 9. The axillary artery. 10. The brachial artery, a dark line marks the limit between these two vessels. 11. The thoracica acromialis artery dividing into its three branches; the number rests upon the coracoid process. 12. The superior and long thoracic arteries. 13. The serratus magnus muscle. 14. The subscapular artery. The posterior circumflex and thoracica axillaris branches are seen in the figure between the inferior thoracic and subscapular. The anterior circumflex is observed, between the two heads of the biceps, crossing the neck of the humerus. 15. The superior profunda artery. 16. The inferior profunda. 17. The anastomotica inosculating inferiorly with the anterior ulnar recurrent. 18. The termination of the superior profunda, inosculating with the radial recurrent in the interspace between the brachialis anticus and supinator longus.—W.]

\* Icones Anatomicæ. Fascic. VI.



into branches, which take opposite directions. One set inclines inwards to the thorax, and the other outwards to the acromion, whence the vessel derives its name. The thoracic branches are two or three in number, and are distributed to the serratus magnus and pectoral muscles, their extreme ramifications communicating with those of the other thoracic branches, as well as with the intercostal branches of the internal mammary artery. The acromial branches incline outwards, and subdivide into a descending and transverse set. The latter proceed towards the acromion, and are distributed partly to the deltoid muscle; whilst others, upon the upper surface of that process, maintain an anastomosis with branches of the suprascapular and posterior circumflex arteries. A descending branch passes down in the interval between the pectoralis major and deltoid, accompanying the cephalic vein and ramifying in both muscles.

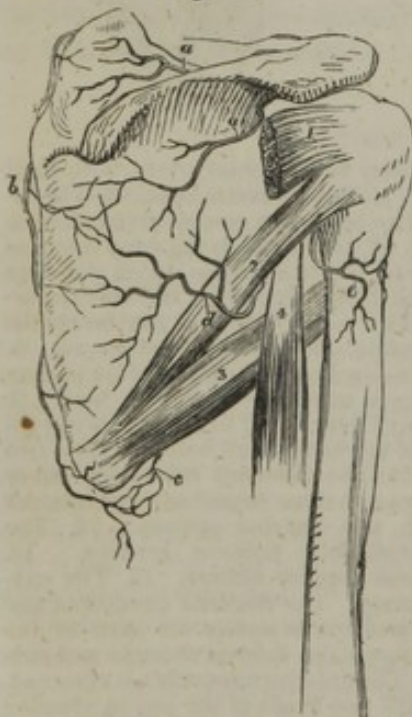The *long thoracic* artery (thoracica altera major sive longior,—Haller), is directed downwards and inwards, along the lower border of the pectoralis minor, and is distributed to the mamma, (hence it has been called *external mammary*,) to the serratus and pectoral muscles, and anastomoses with the external branches of the intercostal arteries. This vessel sometimes arises with the acromial, and occasionally with the subscapular.

The *alar thoracic* branch (alaris, ultima thoracicarum,—Haller), when it exists, for it appears to be generally wanting, and its place to be supplied by branches from the thoracic and subscapular arteries, is a very small vessel. It is distributed to the lymphatic glands and cellular tissue in the axilla.

#### SUBSCAPULAR ARTERY.

The *subscapular*<sup>14</sup> (scapularis inferior aut infrascapularis,—Haller), is the largest branch given off by the axillary artery. It arises from that vessel, close by the lower border of the subscapular muscle, along which it proceeds downwards and backwards, soon becoming considerably diminished in size, owing to

Fig. 243.



A sketch intended to illustrate the arteries on the back part of the shoulder. The dorsum of the scapula and a part of the humerus are shown. 1. Infra-spinatus muscle cut. 2. Teres minor. 3. Teres major. 4. Part of long head of triceps. Arteries: a. Suprascapular. b. Posterior scapular. c. Branch of subscapular, and d. dorsal branch of the same. e. Posterior circumflex.

its giving off a large branch to the dorsum of the scapula. The continuation of the vessel passes down towards the inferior angle of the scapula, accompanied by the subscapular nerve, and lying on the muscle of that name, to which it gives branches, as well as to the serratus magnus, teres major, and latissimus dorsi muscles. Its final ramifications anastomose with those of the posterior scapular artery, and with its own dorsal branch.

The *dorsal branch* (*dorsalis scapulæ*), fig. 243, d, turns backwards from the scapular artery, about an inch and a half from its origin, and is larger than the continuation of the vessel. Descending along the lower border of the scapula, the dorsal branch passes first through the interval between the subscapularis and latissimus dorsi muscles, and then between the teres major and teres minor, and may be found in the fissure between the last-named muscles, immediately behind the long head of the triceps. It gives several branches to these muscles, one of which descends between the teres major and teres minor towards the lower angle of the scapula. The dorsal artery next turns round the lower border of the scapula, which is frequently grooved to receive it; and on reaching the dorsum of that bone, ramifies extensively upon it in the infraspinous fossa, beneath the infraspinatus muscle, which it supplies, and ultimately anastomoses with the suprascapular and posterior scapular arteries.

From the subscapular artery (its dorsal division) is given a slender branch, which enters the subscapular fossa under the subscapularis muscle,



and, after ramifying between that muscle and the bone, anastomoses with other slender branches given to the same surface of the scapula from the suprascapular and the posterior scapular arteries.

### CIRCUMFLEX ARTERIES.

The two succeeding branches of the axillary artery belong to the arm, and are called *circumflex*, from the manner in which they wind round the neck of the humerus. They are distinguished as anterior and posterior, from the course they take respectively around the bone. These branches come off close to the lower border of the axilla, as the axillary artery is about to become the brachial.

The *posterior circumflex* artery [a. circumflexa humeri post.], fig. 242, is not so large as the subscapular, near which it arises. It takes origin opposite to the lower border of the subscapular muscle, passes backwards immediately after its origin, and winds round the humerus, lying between the bone and the long head of the triceps, having the teres major muscle below, and the teres minor above it, (fig. 243, e,) and being accompanied by the circumflex nerve. This artery terminates by ramifying in the deltoid muscle and on the shoulder-joint, and by anastomosing with the anterior circumflex and suprascapular arteries, as well as with the acromial thoracic.

The *anterior circumflex* [a. circumflexa humeri ant.], fig. 242, much smaller than the preceding, arises somewhat lower down, and from the outer side of the axillary artery. It passes from within outwards and forwards, under the coracobrachialis and inner head of the biceps muscle, resting on the fore part of the humerus, until it reaches the bicipital groove. There it divides into two branches, or, in some cases, into two sets of branches; one of these ascends by the long head of the biceps through the groove in which it runs, and is distributed to the head of the bone and the capsule of the joint; the other continues outwards in the original direction of the vessel, anastomoses with the posterior circumflex branch, and with the acromial thoracic, and is lost in the deltoid muscle.

### PECULIARITIES OF THE BRANCHES OF THE AXILLARY ARTERY.

The *external thoracic* arteries are, as has been already stated, most frequently three in number, the alar thoracic being wanting: often there are only two, the superior and the acromial thoracic arising by a single trunk: the number may vary to a still greater extent, for there may be four or five, or only one, from which the usual branches are then given off.

*The subscapular artery.*—The peculiarities affecting the subscapular and circumflex arteries are extremely various, and can only be generally indicated here. The most common change in the *subscapular* consists in its giving off one or more of the vessels usually derived from the axillary. Most commonly the posterior circumflex is thus associated with it; and less frequently a large thoracic branch. If there be two or more vessels arising with the subscapular, these may be the posterior circumflex and a thoracic artery, or both circumflex, or both circumflex with a thoracic branch. Again, one or more of the associated vessels may belong to those usually derived from the brachial; so that both profunda arteries, or the superior profunda alone, may arise together with both circumflex, or with the posterior circumflex only, from this common subscapular trunk. In very rare cases, the anastomotic, the interosseous, or the radial, have been also added to or associated with the subscapular. Lastly, the subscapular sometimes arises by two trunks,—the dorsal scapular branch springing directly from the axillary artery.

*Peculiarities of the circumflex arteries.*—Besides their occasional association with the subscapular, the circumflex arteries present other peculiarities, the most frequent of which consists in the removal of the posterior circumflex from the axillary to the superior profunda (a branch of the brachial), in which case it ascends behind the tendons of the latissimus dorsi and teres major. In another class of



cases, not quite so numerous, the posterior circumflex gives off one or more branches, usually derived from other sources; as, for example, placing them in order of frequency—the anterior circumflex, the superior profunda, the dorsal scapular, the anterior circumflex with the superior profunda, or some other rarer combination of those vessels. The posterior circumflex is sometimes double; and so is the anterior, but more seldom.

In the cases just mentioned as being rather frequent, in which the posterior circumflex arises from the superior profunda, it is evident that the axillary artery loses one of its ordinary branches; in other rare cases these are added to the additional branch supplying the place of one or two usually derived from other sources, or constituting what has been named a "*vas aberrans*," to be hereafter again alluded to.

### BRACHIAL ARTERY.

The *brachial* or *humeral* artery, [*a. brachialis*] fig. 242,<sup>10</sup> the continuation of the axillary, is placed along the inner and anterior aspect of the arm, extending from the lower border of the axilla, that is, of the tendons of the latissimus and teres major, to about a finger's breadth below the bend of the elbow, or opposite the neck of the radius, where it divides into the radial and ulnar arteries. The vessel gradually inclines from the inner side to the fore part of the limb, and its direction may be marked out by a line drawn from midway between the folds of the axilla to the middle point between the condyles of the humerus. From the position it bears with reference to the bone, it will be inferred that to command the flow of blood through the artery at its upper part, pressure should be directed outwards, while over the lower end of the vessel the pressure should be made from before backwards. The position of the artery in the greater part of its course is also indicated by the depression along the inner border of the coracobrachialis and biceps; and, except at the bend of the elbow, or where it is slightly overlaid by those muscles in the arm, it may be said to be superficial in its whole extent. It can be laid bare without dividing any muscular fibres.

The brachial artery is covered by the integument and fascia of the arm as far as the bend of the elbow, where it sinks deeply in the interval between the pronator teres and supinator longus muscles, and is covered by the fibrous expansion given from the tendon of the biceps to the fascia of the fore-arm. It rests at first on the triceps muscle,—the musculo-spiral nerve, however, and the superior profunda artery intervening,—then crosses over the insertion of the coracobrachialis muscle, and lies from thence to its termination on the brachialis anticus. At its outer side the artery is in apposition with the coracobrachialis, and afterwards and for the greater part of its length with the biceps, the inner border of one or both muscles sometimes slightly overlapping it.\*

*Veins.*—The basilic vein is placed over the brachial artery, (its lower half, sometimes its whole length,) except at the bend of the arm, where the median basilic occupies the same position with respect to the artery. Only the fascia, or opposite the elbow-joint, the expansion

\* For an account of certain unusual bands of muscle found in connexion with this artery—crossing over it, see *ante*, pp. 394, 395, 397.



from the tendon of the biceps, is interposed between the vein and artery. *Venæ comites* are in close contact with the artery, short transverse branches of communication passing from one to the other, so as at many points to encircle it.

*Nerves.*—The median nerve follows closely the course of the artery, lying immediately in front of it in the greater part of the arm; at the axilla this nerve is somewhat to the outer side of the vessel, but at the elbow it lies to the inner side, both being on the same plane, supported by the brachialis anticus muscle. The nerve usually crosses in front of the artery, but in some instances behind it.—Of the large branches of the brachial plexus which are closely connected with the axillary artery, none continue in the immediate neighbourhood of the brachial artery along the arm, except the median. The external cutaneous and circumflex separate at once from the vessel in the axilla, the musculo-spiral turns back immediately below the axilla, and the internal cutaneous and the ulnar incline gradually inwards from the vessel,—or perhaps more properly the vessel turns outwards from the nerves.

#### PECULIARITIES IN THE BRACHIAL ARTERY.

From their comparative frequency and surgical interest, the peculiarities of this artery, especially such as affect its trunk, deserve particular attention.

The brachial artery has been seen, though rarely, to deviate from its ordinary course in the following manner. At first it descends, accompanied by the median nerve, towards the inner condyle of the humerus as far as the origin of the pronator teres muscle, which is broader than usual, and then it inclines outwards under cover of or through that muscle, to gain its usual position at the bend of the elbow. In these cases the vessel may be found to turn round a prominence of bone, to which it is bound down by a fibrous band. This deviation of the artery and its connexion with the bony prominence, may be regarded as analogous to the ordinary condition of the vessel in some carnivorous animals, in which it is directed to the inner side of the humerus, and passes through an osseous ring, a short distance above the inner condyle of that bone.

The most frequent change from the ordinary arrangement of the brachial artery relates to its place of division into terminal branches. In 386 out of 481 examples recorded from observations made some on the right and some on the left side of the body, the vessel was found to divide at its usual position, a little below the elbow-joint. In one case only (and that complicated by another peculiarity, viz., the existence of a "*vas aberrans*" proceeding from the axillary to the radial,) was the place of division lower than usual, or between two and three inches lower than the elbow-joint. In 64 cases the brachial artery divided *above* the usual point, at various heights upwards to the lower border of the axilla. The branch prematurely given off from an early division is most frequently (in the proportion of nearly 3 cases out of 4) the radial artery; sometimes the ulnar is thus given off, and rarely the interosseous of the fore-arm, or a "*vas aberrans*."

Now, in all these cases it is evident that two arteries must exist in a certain portion of the arm, instead of one, as usual;\* and the extent to which they were found varied, of course, according to the height at which the artery divided. The point of division, in the entire number of cases, without reference to the particular branch given off, was most frequently in the upper, less so in the lower, and least so in the middle third of the arm. But the early division of the main artery of the upper limb may, as mentioned in speaking of the varieties of the axillary artery, take place within the axilla, in which case it follows that the brachial portion of the vessel is represented, throughout its whole extent, by two separate

\* In one instance only, the *three* arteries of the fore-arm (radial, ulnar, and interosseous,) arose together from the brachial artery at some distance above the elbow joint. A similar case is recorded by Dr. Barclay.



trunks. In 94 cases out of 481, or about 1 in  $5\frac{1}{2}$ , there were two arteries instead of one in some parts or in the whole of the arm.

*The position of the two arteries*, in these cases, is of much surgical interest: we shall here consider their position in the arm, and subsequently trace them in their irregular course in the fore-arm. Usually they are close together, and occupy the ordinary position of the brachial artery; but there are some peculiarities in their position which require to be noticed.

The *radial* artery, when thus given off in the arm, often arises from the inner side of the brachial, then runs parallel with the larger vessel (the brachial or ulnar-interosseous), and crosses over it, sometimes suddenly, opposite to the bend of the elbow, still covered by the fascia. It has been found to perforate the fascia, and run immediately under the skin, near the bend of the elbow; but very few instances of this arrangement have been recorded.

When the *ulnar* is the branch given off high from the brachial, it often inclines from the position of the brachial, at the lower part of the arm, towards the inner condyle of the humerus. This vessel generally lies beneath the fascia as it descends, and superficially to the flexor muscles. It is occasionally placed between the integuments and the fascia; and in a single instance was found beneath the muscles.

The *interosseous*, after arising from the axillary or brachial artery, is commonly situated behind the main artery, and, on reaching the bend of the elbow, passes deeply between the muscles, to assume its usual position in the fore-arm.

Lastly, when the radial has arisen high in the arm, the residuary portion of the brachial (*brachial: ulnar-interosseous*) has occasionally been observed descending, accompanied by the median nerve, along the intermuscular septum towards the inner condyle of the humerus, as far as the origin of the pronator teres (which in the case recorded was found broader than usual), whence it turned outwards, under cover of the muscle, to gain the usual position at the middle of the bend of the elbow.

*The two arteries connected or reunited.*—The two arteries representing the brachial are in some instances *connected* near the bend of the arm by an intervening trunk, which proceeds from the larger (or ulnar-interosseous) artery to the radial, or the radial recurrent, and varies somewhat in its size, form, and course. More rarely the two unusual arteries are actually *reunited*.

#### VASA ABERRANTIA.

The “*vasa aberrantia*,” alluded to in the preceding remarks, are long slender vessels, which arise either from the brachial or the axillary artery, and end by joining one of the arteries of the fore-arm, or a branch of these. In eight cases out of nine,—the total number observed,—this unusual vessel joined the radial; in the remaining case it joined the radial recurrent, which arose irregularly from the ulnar artery. Monro and Meckel have in one case each seen an aberrant vessel join the ulnar. This peculiarity may be regarded, perhaps, as an approach to that condition in which there is division of the brachial artery and subsequent connexion of its two parts by an intervening branch.

*State of arteries in both limbs.*—In most cases there is no correspondence between both arms of the same person with respect to the high division of the arteries. For, in 61 bodies in which the high division existed, it occurred on one side only in 43; on both sides, in different positions, in 13; and on both sides, in the same position, in the remaining 5.

#### SURGICAL ANATOMY OF THE BRACHIAL ARTERY.

In the operation for tying the brachial artery, the known direction of the vessel, and the inner margin of the biceps muscle chiefly aid in determining its position. In consequence of the thinness of the parts which cover the artery, and the position of the basilic and median basilic veins, with respect to it, even the integuments must be divided with care. After turning aside the superficial vein, should that be necessary, and dividing the fascia, the median nerve will probably come into view, and the artery will then be readily found. This is the course required under ordinary circumstances. But it may happen that after dividing the fascia it will be necessary to cut through a layer of muscular fibres in order to bring the



artery into view. The influence of pressure with the finger in controlling the circulation, will enable the surgeon to determine if the vessel be behind the muscular fibres, and will guide him to the place at which they ought to be divided.

Again, as the brachial artery occasionally deviates from its accustomed place in the arm, it is prudent, before beginning an operation on the living body, to be assured of its position by the pulsation. Should the vessel be thus displaced, it has the ordinary coverings of the brachial artery, except at the lower part of the arm, where some fibres of the pronator teres will require to be divided in an operation for securing the vessel.

When the brachial artery is double, or when two arteries are present in the arm, both being usually placed close together, they are accessible in the same operation. The circumstance of one being placed over the fascia (should this very unfrequent departure from the usual arrangement exist) will become manifest in the examination which ought to be made in all cases before an operation is begun. And, as regards the occasional position of one of the two arteries beneath a stratum of muscular fibres, or its removal to the inner side of the arm (in a line towards the inner condyle of the humerus) it need only be added that a knowledge of these exceptional cases will at once suggest the precautions which are necessary, and the steps which should be taken when they are met with.—The foregoing observations have reference to operations on the brachial artery above the bend of the elbow; the surgical anatomy of the vessel opposite that joint requires a separate notice.

At the *bend of the elbow* the disposition of the brachial artery is chiefly, or, at least, most commonly, of interest in a surgical point of view, because of its connexion with the veins from which blood is usually drawn in the treatment of disease. The vein (median basilic) which is generally the most prominent and apparently best suited for "venesection" is commonly placed over the course of the brachial artery, separated from it only by a thin layer of fibrous structure (the expansion from the tendon of the biceps muscle); and under such circumstances, it ought not, if it can be avoided, to be opened with a lancet, except in a part which is not contiguous to the artery.

If two arteries are present, instead of the ordinary single trunk, they are commonly close together; but it now and then happens that an interval exists between them—one being in the usual situation of the brachial, the other nearer, in different degrees in different cases, to the inner condyle of the humerus. There is on this account an additional reason for precaution when venesection is to be performed; and care is the more necessary as the second artery may be immediately under the vein without the interposition of fascia.

### BRANCHES OF THE BRACHIAL ARTERY.

The brachial artery gives some unnamed branches, which are directed outwards and backwards to the muscles in its immediate neighbourhood, viz., to the coraco-brachialis, biceps, and brachialis anticus; the following, which incline inwards, have received names, and require description.

#### SUPERIOR PROFUNDA.

The *superior profunda* artery (collateralis magna), [a. profunda brachii,] fig. 242,<sup>16</sup> arises from the inner and back part of the brachial, just below the border of the teres major, and inclines backwards, to reach the interval between the second and third heads of the triceps muscle. It is accompanied by the musculo-spiral nerve, and both, continuing the same oblique direction, enter the spiral groove, which winds round the back of the humerus, passing between it and the triceps, and perforating the external intermuscular septum, to reach the external and anterior aspect of the bone. In the latter situation, the artery lies deeply in the fissure between the brachialis anticus and supinator longus muscles, considerably diminished in size by having given off several branches, and descends to the elbow, where it anastomoses with the recurrent branch of the radial artery. The superior profunda in its first part gives off branches to the



deltoid, coraco-brachialis, and triceps; and many to the last-named muscle whilst it is between it and the bone. In this position it also gives one long branch, which descends perpendicularly between the muscle and the bone to the back part of the elbow-joint on its outer side, where it anastomoses with the interosseous recurrent branch, and another which anastomoses on the inner side with the ulnar recurrent, and the anastomotie or inferior profunda.

The most frequent departure from the usual disposition of the superior profunda consists in its giving origin to the posterior circumflex, which is usually a branch of the axillary. Not quite so frequently its own origin is transferred to one of the branches of the axillary; as, for example, to the subscapular, which then also gives off one or both circumflex; or to the posterior circumflex, which then gives origin to the anterior circumflex, or some other branch. The superior profunda sometimes arises from the axillary artery itself, either alone, or in conjunction with the inferior profunda. Lastly, it is occasionally represented by two, or even three separate branches. It not unfrequently furnishes the inferior profunda.

The *nutrient artery of the humerus* [a. nutiens humeri] is a very small branch given off by the brachial about the middle of the arm, or by one of its collateral branches. It inclines downwards, enters the oblique canal in the humerus near the insertion of the coraco-brachialis muscle, and is distributed to the medullary membrane.

#### INFERIOR PROFUNDA.

The *inferior profunda* artery (collateralis ulnaris prima, [s. superior,]) fig. 242,<sup>16</sup> is of small size, and arises from the brachial artery, a little below the middle of the arm. From the point just indicated, the artery is directed to the back part of the inner condyle of the humerus; to gain this position, it, in the first place, pierces the intermuscular septum, and then lies on the inner surface of the triceps (its third head), giving it branches. In this course the artery lies close to the ulnar nerve, and enters the interval between the olecranon and inner condyle, where it terminates by inosculating with the posterior recurrent branch of the ulnar artery, and with the anastomotie branch.

As already incidentally mentioned in the account of other branches, this artery often arises from the superior profunda, or from the axillary artery in combination with some other branch. It is occasionally altogether wanting. Owing to these frequent changes of condition the inferior profunda has not been recognised by some anatomists.

#### ANASTOMOTIC BRANCH.

The *anastomotie* artery (collateralis ulnaris secunda, [s. inferior, s. a. anastomotica,]) fig. 242,<sup>17</sup> though a small branch, is very constant in its occurrence. Arising from the brachial artery, about two inches above the bend of the arm, it is directed transversely inwards on the brachialis anticus muscle, above the inner condyle of the humerus, and, after perforating the intermuscular septum, turns in the opposite direction outwards behind the humerus, between it and the triceps muscle. In this situation the artery ends by joining with the superior profunda, the two forming an arch across the humerus immediately above the olecranon fossa (arcus dorsalis humeri posticus,—Haller).

In front of the humerus the anastomotie artery furnishes a branch which ramifies in the pronator teres, and anastomoses with the anterior ulnar recurrent branch. Behind the inner condyle another offset joins with the posterior ulnar recurrent, and behind the humerus several branches are given to the joint and the muscle.—This anastomotie artery is sometimes much reduced in size, and in that case the inferior profunda takes its place behind the humerus.

A little below the middle of the elbow joint, or opposite the neck of the radius, the brachial artery divides into its two terminal branches—radial and ulnar. Of these the radial artery appears, as far as direction is concerned, the continuation of the parent vessel, but the ulnar is the larger of the two.



## ULNAR ARTERY.

The *ulnar artery*, [a. ulnaris,] fig. 244,<sup>16</sup> extends from the point of bifurcation of the brachial just indicated, along the inner side of the fore-arm, into the palm of the hand, where, joining a branch of the radial, opposite the muscles of the thumb, it forms the superficial palmar arch. In this course it inclines first downwards and inwards, describing a slight curve, the convexity of which is directed inwards, and passes under cover of the superficial muscles arising from the inner condyle of the humerus, viz., the pronator teres, flexor carpi radialis, palmaris longus, and flexor sublimis, until it reaches the flexor carpi ulnaris, about the junction of the upper with the middle third of the fore-arm; at this point the artery comes into contact with the ulnar nerve, (previously separated from it by a considerable interval,) and, changing its direction, descends vertically with the nerve towards the inner border of the palm of the hand. Guided as it descends by the tendon of the flexor ulnaris muscle, along the radial border of which it is now placed, the ulnar artery reaches the outer or radial side of the pisiform bone, where, still accompanied by the nerve, it passes over the cutaneous surface of the anterior annular ligament of the wrist into the palm of the hand. Its disposition in the hand will be separately described.

In the first half of its course through the fore-arm, the artery is deep-seated, being covered by the muscles arising from the inner condyle of the humerus which have been already enumerated. About the middle of the fore-arm it is only slightly overlapped by the flexor carpi ulnaris; but below that, it becomes comparatively superficial, being covered only by the skin, the fascia of the fore-arm and a thin layer of membrane by which the vessel is bound down to the muscle beneath. At first the ulnar artery rests on the insertion of the brachialis anticus into the coronoid process of the ulna; then on the flexor profundus in the rest of the fore-arm; and lastly, on the annular ligament of the carpus. Below the point at which it emerges from under the flexor carpi ulnaris, (or a little below the middle of the fore-arm,) the tendon of that muscle is on its inner or ulnar side.

*Nerves.*—The median nerve lies immediately on the inner side of the ulnar artery at its origin, but the nerve soon passes over the vessel, and is then separated from it by the second head of the pronator teres muscle. As the ulnar nerve descends behind the inner condyle of the humerus, it is separated from the ulnar artery by a considerable interval at the upper part of the fore-arm; but as the artery inclines inwards, it approaches the nerve, and is accompanied by it in the lower half of its course—the nerve lying close to its inner side. A small branch of the ulnar nerve descends upon the lower part of the vessel.

*Veins.*—Two veins (venæ comites), which have the usual arrangement of such veins, accompany the ulnar artery.

On the wrist, the ulnar artery rests on the anterior annular ligament, and is covered by the skin and fascia. The pisiform bone is to its



inner side; the ulnar nerve is also on the same side, but somewhat behind the artery.

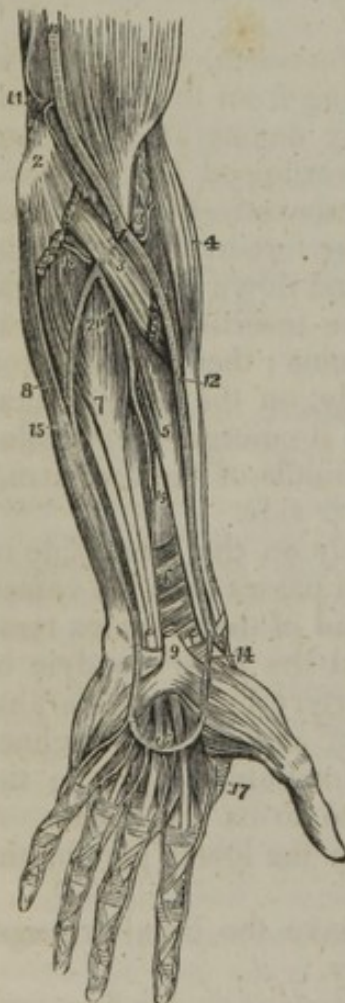#### PECULIARITIES OF THE ULNAR ARTERY.

Most of these peculiarities have reference to the *place of origin* of the artery, a subject already alluded to in the descriptions of the variations observed in the branches of the axillary and in the place of bifurcation of the brachial artery. In a considerable number of observations, the ulnar artery was found to deviate, in regard to its *origin*, in nearly the proportion of 1 in 13. In all cases but one, (in which it arose between two and three inches below the elbow-joint, in consequence of a late bifurcation of the brachial artery,) the place of origin of the ulnar artery was higher than usual. Moreover the brachial was, more frequently than the axillary, the source from which it sprang; indeed, the examples of its origin from the trunk at different parts appeared to decrease in number upwards.

The *position* of the ulnar artery in the fore-arm is more frequently altered than that of the radial. When it arises in the usual way, the course of this artery is not often changed; but it has been seen to descend apart from the tendon of the flexor carpi ulnaris, instead of being close to its radial border.

The position of the ulnar artery in the upper arm, when it arises high up, has been previously adverted to. In the fore-arm, it almost invariably, in cases of premature origin, descends over the muscles arising from the inner condyle of the humerus, only one exception to this rule having been met with. Most commonly it is covered by the fascia of the fore-arm; but now and then a case

[Fig. 244.



occurs in which the vessel rests on the fascia, and is subcutaneous. In a very few instances the artery lay partly beneath the skin, and partly beneath the fascia, being subcutaneous for a short distance in the upper part of the fore-arm, and subaponeurotic lower down.

As to *size*, the ulnar artery presents some peculiarities, which, being accompanied by deviations of an opposite and compensating character in the radial artery, will be noticed with that vessel.

#### BRANCHES OF THE ULNAR ARTERY.

In the fore-arm and on the wrist, the ulnar artery gives off several branches, which have received particular names. The branches in the fore-arm are the anterior and posterior recurrent, the interosseous, and several muscular branches. Those given at the wrist are named carpal branches (anterior and posterior).

Fig. 244. The arteries of the fore-arm. 1. The lower part of the biceps muscle. 2. The inner condyle of the humerus with the humeral origin of the pronator radii teres and flexor carpi radialis divided across. 3. The deep portion of the pronator radii teres. 4. The supinator longus muscle. 5. The flexor longus pollicis. 6. The pronator quadratus. 7. The flexor profundus digitorum. 8. The flexor carpi ulnaris. 9. The annular ligament with the tendons passing beneath it into the palm of the hand; the figure is placed on the tendon of the palmaris longus muscle, divided close to its insertion. 10. The brachial artery. 11. The anastomotica inosculating superiorly with the inferior profunda, and inferiorly with the anterior ulnar recurrent. 12. The radial artery. 13. The radial recurrent artery inosculating with the termination of the superior profunda. 14. The superficialis volæ. 15. The ulnar artery. 16. Its superficial palmar arch giving off digital branches to three fingers and a half. 17. The magna pollicis and radialis arteries. 18. The posterior ulnar recurrent. 19. The anterior interosseous artery. 20. The posterior interosseous, as it is passing through the interosseous membrane.—W.]



## RECURRENT BRANCHES.

The *anterior ulnar recurrent* artery, [a. recurrens ulnaris ant.] fig. 244, arches inwards from the upper part of the ulnar artery, running on the brachialis anticus muscle, and covered by the pronator teres, both which muscles it partly supplies. On reaching the front of the inner condyle, it anastomoses with the inferior profunda and anastomotic arteries, derived from the brachial.

The *posterior ulnar recurrent*<sup>19</sup> [a. recurrens ulnaris post.] is larger than the preceding, and comes off lower down; though not unfrequently the two arise by a short common trunk. The posterior recurrent runs inwards and backwards beneath the flexor sublimis, and then ascends behind the inner condyle. In the interval between that process and the olecranon it lies beneath the flexor carpi ulnaris, and passing between the heads of that muscle along the ulnar nerve, supplies branches to the muscles, to the elbow-joint, and to the nerve itself. This branch communicates with the inferior profunda, the anastomotic, and over the olecranon, with the interosseous recurrent likewise.

## INTEROSSEOUS ARTERY.

The *interosseous* artery, [a. interossea antibrachii communis,] the next and largest branch of the ulnar, is of considerable size, and is sometimes called the *common interosseous* artery, from the circumstance of its forming a common trunk to two vessels named the *anterior* and *posterior* interosseous. It is a short trunk, about an inch in length, which arises below the bicipital tuberosity of the radius, beneath the flexor sublimis, and passes backwards to reach the upper border of the interosseous ligament, where its division takes place.

The *anterior interosseous*<sup>19</sup> [a. interossea ant. s. int.] descends upon the anterior surface of the interosseous ligament, held down to it by a layer of fibro-cellular tissue, accompanied by the interosseous branch of the median nerve, and overlapped by the contiguous borders of the flexor profundus digitorum and flexor longus pollicis. Thus placed, it gives off some muscular branches, and also the *nutrient* arteries of the radius and ulna, which incline to either side and enter the oblique foramina in those bones to be distributed to the medullary membrane in their interior. The artery continues its course directly downwards until it reaches the upper border of the pronator quadratus muscle, where it gives off some small branches to supply that muscle, one of which descends to join upon the front of the carpus with the branches of the anterior carpal arteries. The larger branch of the artery, however, passes from before backwards, through an opening in the interosseous ligament; and, on reaching the dorsal surface of this structure, descends behind it to the carpus, where it maintains communications with the posterior carpal branches of the radial and ulnar arteries. The anterior interosseous artery gives off a long slender branch, which accompanies the median nerve and sends offsets into its substance. This artery of the median nerve, or *median* artery, is sometimes much enlarged, and in this case it presents several peculiarities to be hereafter noticed.

The *posterior interosseous* artery [a. interossea post. s. ext.] passes backwards, through the interval left between the oblique ligament and the upper border of the interosseous ligament. Continuing its course downwards, along the arm, covered by the superficial layer of extensor muscles, it gives several branches to them and the deep-seated muscles, and reaches the carpus considerably diminished in size, where its terminal branches anastomose with the posterior or terminal branch of the anterior interosseous artery, and with the carpal branches of the radial and ulnar arteries.

In addition to numerous muscular branches, which require no special notice, this artery gives off close to its origin, or as soon as it passes behind the ligament, a recurrent branch, the *posterior interosseous recurrent* [a. interossea recurrens], which is nearly as large as the continuation of the vessel. This branch passes directly upwards, covered by the supinator brevis and anconeus, to reach the interval between the olecranon and external condyle, where it divides into several offsets which anastomose with the superior profunda and the posterior ulnar recurrent.

Several *muscular* branches of the ulnar artery are distributed to the muscles in its course along the fore-arm: some of these perforate the interosseous ligament to reach the extensor muscles.



## CARPAL BRANCHES.

The *posterior* or *dorsal carpal* [ramus dorsalis], a branch of variable size, inclines backwards from the ulnar artery a little above the pisiform bone. It winds back under the tendon of the flexor carpi ulnaris, and reaches the dorsal surface of the carpus beneath the extensor tendons, where it gives a branch, which anastomoses with the posterior carpal artery derived from the radial, so as to form the *posterior carpal arch*; after which it runs along the metacarpal bone of the little finger, and forms its dorsal branch. Sometimes this *metacarpal branch* arises as a separate vessel, the posterior carpal being then very small. From the posterior carpal arch of anastomosis just referred to, the second and third dorsal interosseous branches are derived.

The *anterior* or *palmar carpal* branch is a very small artery, which runs on the anterior surface of the carpus, beneath the flexor profundus, anastomoses with a similar offset from the radial artery, and supplies the carpal bones and articulations.

## PECULIARITIES IN THE BRANCHES OF THE ULNAR ARTERY.

The transverse communications which sometimes exist between the ulnar and radial arteries have been already referred to at p. 580.

Of the branches of the ulnar in the fore-arm, the *anterior* and *posterior ulnar recurrents* frequently arise by a common trunk. When the ulnar artery has a high place of origin, its recurrent branches are derived from the common interosseous; one or both have been seen, but more rarely, to arise from the brachial.

The *anterior* and *posterior interosseous* arteries are occasionally given singly from the ulnar. But the common interosseous trunk is liable to much greater deviations from its ordinary course. Thus, when the ulnar arises high up, the interosseous is associated with the radial artery, and separates from that vessel at the bend of the elbow; the trunk common to the two vessels represents the brachial in these cases. Again, the interosseous itself has been found to arise above its ordinary situation, taking origin from the brachial, and even (but more rarely) from the axillary. The anterior interosseous presents some striking varieties of excess in its branches, usually connected with a deficiency in the radial or ulnar arteries. These cases are referred to in noticing the arteries which are thus reinforced.

*Median artery.*—The branch accompanying the median nerve is sometimes much enlarged, and in such case may be regarded as a reinforcing vessel. It is generally a branch of the anterior interosseous, but sometimes of the ulnar; and more rarely a median branch has been met with descending from the brachial artery. Accompanying the median nerve beneath the annular ligament into the palm of the hand, the median artery ends most frequently by joining the superficial palmar arch, sometimes by forming digital branches, or by joining digital branches given from other sources.

## SUPERFICIAL PALMAR ARCH.

The *superficial palmar arch* or artery (arcus superficialis volæ,—Haller), fig. 244,<sup>16</sup> is the continuation of the ulnar artery to the hand. Changing its course near the lower border of the annular ligament, this artery turns obliquely outwards across the palm of the hand towards the middle of the muscles of the thumb, where it terminates by inosculating with a branch of the radial artery. The branch of the radial artery which joins with the ulnar, and, as it may be said, completes the arch, varies in different cases; most commonly it is a small one emerging from among the muscles of the thumb or the superficial volar. In its course across the hand, the artery describes a curve, having its convexity directed towards the fingers, and reaching downwards somewhat lower than a line on a level with the flexure of the first joint of the thumb.



The superficial palmar artery, at its commencement, rests on the annular ligament of the wrist, and slightly on the short muscles of the little finger; then on the tendons of the superficial flexor of the fingers, and the divisions of the median and ulnar nerves, the latter of which accompanies the vessel for a time. It is covered towards the ulnar border of the hand by the palmaris brevis, and afterwards by the palmar fascia and the integument.

The branches given off by the superficial palmar arch, which are generally numerous, are as follows:

The *deep* or *communicating* branch (*cubitalis manûs profunda*,—Haller) arises from the ulnar artery at the commencement of the palmar arch, a little beyond the pisiform bone, sinks deeply between the flexor brevis and the abductor of the little finger, and then inosculates with the palmar termination of the radial artery, thereby completing the deep palmar arch.

Small branches, some following a retrograde course to the annular ligament, are given off to the parts in the palm of the hand from the upper or concave side of the palmar arch.

The *digital* branches [*digitales communes*], usually four in number, proceed downwards from the convexity of the palmar arch to supply both sides of the three inner fingers, and the ulnar side of the fore-finger. The *first digital* branch inclines inwards to the ulnar border of the hand, and after giving minute offsets to the small muscles of the little finger, runs along the inner margin of its phalanges. The *second* runs along the fourth metacarpal space, and at the root of the fingers divides into two branches, which proceed along the contiguous borders of the ring-finger and little finger. The *third* is similarly disposed of to the ring-finger and middle finger, and the *fourth* to the latter and the index-finger. The radial side of the index-finger and the thumb are supplied from the radial artery.

The digital arteries, placed at first superficial to the tendons, then lie between them, accompanied by the digital nerves as far as the clefts of the fingers, where they are joined by the anterior interosseous arteries, branches of the deep arch. On the sides of the fingers, each artery lies beneath the corresponding nerve, and gives branches which supply the sheaths of the tendons, and the joints, some of them anastomosing across the front of the bone with similar branches from the opposite side. At about the middle of the last phalanx, the two branches for each finger converge and form an arch, from which proceed numerous small offsets to supply the matrix of the nail and all the structures at the tip of the finger.

The peculiarities observed in the branches of the superficial palmar arch, will be noticed after the description of the deep arteries of the hand.

#### RADIAL ARTERY.

The *radial artery*, [*a. radialis*,] fig. 244,<sup>12</sup> in direction, though not in size, appears to be the continuation of the brachial. It extends from the bifurcation of the latter, obliquely along the front of the fore-arm as far as the lower end of the radius, below which it turns round the outer border of the wrist, and then descending to the back of the space between the metacarpal bones of the thumb and fore-finger, passes forwards to the palm of the hand, which it crosses towards the inner side, so as to form the deep palmar arch. From the change in its course at the lower end, the directions and connexions of the radial artery may be separately described in the fore-arm, on the wrist, and in the hand.

In the *fore-arm*, the direction of this artery is from the point of bifurcation of the brachial opposite to the neck of the radius towards the fore part of the styloid process of that bone. It descends at first



somewhat obliquely outwards in a line with the brachial artery, and then nearly vertically along the outer part of the front of the fore-arm, its course being indicated by a line drawn from the middle of the bend of the elbow to the narrow interval between the trapezium bone and the tendons of the extensors of the thumb, which can be readily felt towards the outer border of the wrist. Placed at first to the inner side of the radius, the vessel gradually inclines to the front of that bone, on which it lies below; it is in this part of the vessel that the pulse is usually felt during life. The radial artery is nearer to the surface than the ulnar, and is covered only by the common integument and fascia, except where it is overlapped by the fleshy part of the supinator longus, which must be drawn aside in order to bring the vessel into view. At first it rests on the tendon of the biceps, and is then supported by the branches of the musculo-spiral nerve, and some cellular tissue, which separate it from the short supinator muscle. It next passes over the insertion of the pronator teres, and the thin radial origin of the flexor sublimis; after which, it lies on the flexor pollicis longus and pronator quadratus, until it reaches the lower end of the radius. To the inner side of this vessel lie the pronator teres in the upper part of its course, and in the rest, the flexor carpi radialis; and on the outer side, in its whole course along the fore-arm, is the supinator longus or the tendon of that muscle.

The artery is accompanied by *venæ comites*, which have the usual arrangement of those veins.

*Nerves.*—The radial branch of the musculo-spiral nerve is placed on the outer side of the artery in the middle third of its course. At the elbow that nerve is separated from the artery by a considerable interval; and towards the lower end of the fore-arm, it turns backwards beneath the tendon of the supinator longus, to reach the dorsal aspect of the arm, and thus loses all connexion with the artery. Some filaments of the external cutaneous nerve pierce the fascia to reach the lower part of the artery, which they accompany to the back of the carpus.

*At the wrist*, the radial artery turns outwards between the styloid process of the radius and the carpus, beneath the tendons of the extensors of the metacarpal bone and of the first phalanx of the thumb, and upon the external lateral ligament of the wrist-joint, to reach the back of the carpus. It then runs downwards for a short distance, lying in the angular interval between the tendons of the two extensors of the thumb just alluded to, and that of the extensor of its second phalanx; and soon, being crossed by this last-named tendon, the vessel reaches the upper end of the space between the first and second metacarpal bones, where it turns forwards into the palm of the hand, by passing between the heads of the first dorsal interosseous muscle.

As it turns round below the end of the radius the artery is deep-seated, but afterwards comes nearer to the surface. It is accompanied by two veins and by some filaments of the external cutaneous nerve, and is crossed by subcutaneous veins and by filaments of the radial nerve.



## PECULIARITIES OF THE RADIAL ARTERY.

From the usual *place of origin* the radial was found, in 429 observations, to deviate in the proportion of nearly 1 case in 8. In all it arose higher than usual, with the exception of one case of low division of the brachial artery, and in this the radial artery was joined by a *vas aberrans*. The brachial artery (most commonly near its upper end) was the source from which the radial proceeded in case of high origin much more frequently than the axillary.

The *position* of this artery in the upper arm, in the case of its premature origin, having been already mentioned, it remains only to examine the peculiarities of its course in the fore-arm. The radial artery more rarely deviates from its usual position along the fore-arm than the ulnar. It has, however, been found lying upon the fibrous expansion from the tendon of the biceps, and over the fascia of the fore-arm, instead of beneath those structures. This vessel has also been observed to be placed on the surface of the long supinator, instead of on the inner border of that muscle. In turning round the wrist, it has likewise been seen to deviate from its ordinary course by passing over the extensor tendons of the thumb, instead of beneath them. But these several peculiarities are of very rare occurrence. As was previously stated (p. 580), the *vasa aberrantia* occasionally derived from the brachial and axillary arteries most commonly end by joining the radial, or one of its branches.

## SOME VARIATIONS IN THE ULNAR AND RADIAL ARTERIES COMPARED.

Some of the peculiarities observed in these vessels may be usefully contrasted with each other.

In the first place, it has been found that the radial artery much more frequently deviates in some important particular from its usual condition than the ulnar, the proportions in a large and about an equal number of cases being about 1 in 4½ for the radial artery, and 1 in 10 for the ulnar.

With respect to the *place of origin*, the radial offered more frequent peculiarities than the ulnar, in the proportion of 13 to 8. The radial artery arose from the axillary twice as often as the ulnar. In taking origin high up from the brachial, the radial artery sprung most frequently from the upper part of that trunk; while, on the contrary, the ulnar artery most commonly arose from the brachial, near its lower end.

There are certain *variations of size* presented by the radial and ulnar arteries which may be best explained together, for they exhibit a principle of compensation, according to which, if one be smaller, the other is larger.

The ulnar artery is the vessel which is the most frequently diminished in size, its deficiency being then usually compensated for on the hand by the radial, as will be shown in considering the arteries of the hand; but the palmar part of the ulnar artery may, when small, be reinforced by a large median artery, and in the fore-arm the ulnar artery itself has been found to be strengthened by another branch from the anterior interosseous.

A diminution in size of the radial is less frequent than of the ulnar artery. The defect, when it exists, is compensated, especially in the hand, by an increase in the size of the ulnar. In the fore-arm the radial artery has been observed to be reinforced by the anterior interosseous in front of the wrist, and by the perforating branch of that vessel behind the carpus. The last cases referred to may be regarded as a transition to an extremely rare variety, in which the radial artery ended by giving the recurrenents and a few muscular branches, the place of its descending trunk being supplied near the wrist by the interosseous. An example of this arrangement of the vessels is in the Museum of Professor Otto, at Breslau.

## BRANCHES OF THE RADIAL ARTERY.

The branches of the radial artery may be arranged according as they are given off in the fore-arm, on the wrist, and in the hand. The branches which arise from the radial in the fore-arm, are the radial



recurrent, the muscular branches, the anterior carpal, and the superficial volar.

The *radial recurrent artery*, [a. recurrens radialis,] fig. 244,<sup>13</sup> which varies much in size, arches upwards from the radial soon after its origin, running between the branches of the musculo-spiral nerve. It first lies on the supinator brevis, and then on the brachialis anticus, being covered by the supinator longus. In front of the outer condyle, and in the interval between the last two muscles, it anastomoses with the terminal branches of the superior profunda. From the lower or convex side of this artery are given off several branches; one, of considerable size, to the supinator and extensor muscles, and some beneath the latter to anastomose with the posterior interosseous branches. It also supplies the supinator brevis and brachialis anticus in part.

Several unnamed *muscular* branches are given to the muscles on the fore part of the arm.

The *anterior carpal* is a small branch which arises from the radial artery near the lower border of the pronator quadratus, and runs inwards in front of the radius. It is usually called the *anterior radial carpal*, to distinguish it from a similar branch from the ulnar artery, with which it anastomoses so as to form an arch above and in front of the radio-carpal articulation, from which branches descend to supply the joints of the wrist.

The *superficial volar*,<sup>14</sup> (ramus superficialis volæ) proceeds directly forwards from the radial artery, where it is about to turn backwards, following the direction of that vessel in the fore-arm. In its size this branch is subject to many varieties. Most commonly it is very small, and ends in the muscles of the thumb. When it attains considerable size, this artery runs over the small muscles of the thumb at their origin, lying upon the annular ligament, to which it is bound down by a thin process of fascia, and is usually described as inosculating with the radial extremity of the superficial palmar arch, which it thus completes.

The branches which arise from the second or carpal portion of the radial artery are the following:—the posterior carpal, the metacarpal, the dorsal arteries of the thumb, and the dorsal artery of the index-finger.

The *posterior carpal* (ar. dorsalis carpi radialis) is small but constant. It arises opposite the carpal articulations, beneath the extensor tendons of the thumb, and near the tendons of the radial extensor muscles, beneath which it runs inwards on the back of the carpus. Here it anastomoses with a similar branch from the ulnar artery, and with the terminations of the anterior interosseous artery, which, it will be remembered, perforates the interosseous ligament, and becomes dorsal in the lower part of the fore-arm. Branches descending from the carpal artery to the metacarpal spaces become the *dorsal interosseous arteries*, for the third and fourth interosseous spaces of the hand, after anastomosing, at the upper end of those spaces, with the posterior perforating branches from the deep palmar arch.

The *first dorsal interosseous* branch (metacarpal: ramus dorsalis interosseus primus,—Haller,) arises from beneath the extensors of the thumb, frequently with the posterior carpal, and descends obliquely towards the interval between the second and third metacarpal bones; it there becomes interosseous, and, after communicating with the corresponding perforating branch of the deep palmar arch, descends upon the second dorsal interosseous muscle, as far as the cleft of the index and middle fingers, where it gives off dorsal superficial arteries to those fingers, and ends by communicating with the palmar digital branch at its point of division between the fingers.

The *dorsal arteries of the thumb* (dorsales pollicis), small, and two in number, sometimes arise separately opposite the head of the metacarpal bone, and at others by a common trunk, which divides into two branches. They run upon the dorsal aspect of the bones of the thumb, one at its radial, the other at its ulnar border.

The *dorsal artery of the index-finger* (dorsalis indicis), a very small branch, arises lower down than the preceding, and after sending branches to the abductor indicis, runs along the radial side of the back of the index-finger.



PECULIARITIES OF THE BRANCHES OF THE RADIAL IN  
THE FORE-ARM.

Of these branches the radial *recurrent* is sometimes very large, or it may be represented by several separate branches. When the radial itself arises high up, the recurrent artery usually comes from the residual brachial trunk or from the ulnar artery, or more rarely from the interosseous. When given from the brachial trunk, the radial recurrent has been found crossing beneath the tendon of the biceps.

The *superficial volar* branch of the radial was found, in a large proportion of cases examined, 141 in 235, to be small, and to be lost in the short muscles of the thumb, without forming any connexion with the palmar arch, or, with any of the digital arteries. When the superficial volar had considerable size, its disposition varied as follows. In the majority of cases it simply ended in the superficial arch. In a smaller number, without joining the ulnar portion of the arch, it furnished one or more digital arteries. Lastly, the artery at the same time joined the arch, and furnished one or more digital branches to the thumb and index-finger.

The origin of the branch in question was also found to present some peculiarities. It occasionally arose from the radial at a distance of one inch and a half to two inches and a half above its ordinary position, in one case even nearly as high as the bend of the elbow. In these cases it usually descended with the radial; but when the latter turned outwards to reach the back of the limb sooner than usual, the superficial volar occupied the place of the radial in front.

The *first dorsal interosseous* branch (metacarpal), which descends on the second interosseous space to the cleft between the index and middle fingers, is not unfrequently so large as to furnish the collateral digital branch to each of those fingers. The carpal and interosseous (metacarpal) branches of the radial are sometimes small, their place being supplied by the perforating division of the anterior interosseous, apparently by an enlargement of the ordinary anastomosis between them.

PALMAR BRANCHES OF THE RADIAL ARTERY.

The branches derived from the radial after it has entered the hand, are, the great artery of the thumb, the radial branch of the index-finger, and its large terminal branch, which forms the deep palmar arch.

The *large artery of the thumb*<sup>17</sup> (arteria pollicaris: ar. princeps pollicis,—Haller), arises from the radial, where it is about to turn inwards across the palm of the hand. It descends in front of the abductor indicis, along the metacarpal bone of the thumb to its lower end (comes ossis metacarpi pollicis,—Haller), between the bone and the short muscles covering it, to the space between the lower ends of the short flexor of the thumb. At that point, and beneath the tendon of the long flexor, the artery divides into two branches, the collateral arteries of the thumb, which course along the borders of its phalanges on their palmar aspect, and inosculate on the last phalanx, forming an arch similar in its arrangement to that on the other fingers.

The *radial branch for the index-finger* (art. volaris radialis indicis,—Haller), generally arises close to the preceding branch; but though constantly found, it varies in size and in its mode of origin. It descends at first between the abductor indicis, which is behind it, and the flexor brevis and adductor pollicis in front; and continues, covered only by the skin and fascia, along the radial border of the index-finger, forming its radial collateral branch (whence its name), and anastomosing in the usual manner with the ulnar collateral branch for the same finger, derived from the superficial palmar arch. This artery very frequently gives a communicating branch to the superficial arch, near the lower border of the adductor pollicis.

The most frequent method of *communication* between the radial artery and the superficial arch is by a small branch, which proceeds from the former through the muscles of the thumb.



## DEEP PALMAR ARCH.

The *deep palmar arch* (arcus profundus volæ,—Haller), which is to be regarded as the palmar continuation of the radial artery, commences at the upper end of the first interosseous space, between the heads of the abductor indicis, turns transversely across the palm towards the upper end of the fourth metacarpal bone, near which it inosculates with the communicating branch from the ulnar artery, and thus forms the *deep palmar arch*. The convexity of this arch is directed downwards. It is, as its name implies, more deeply seated than the superficial arch derived from the ulnar artery,—being placed upon the interosseous muscles, and the metacarpal bones, immediately below the carpal extremities of these; and being covered by the flexor brevis pollicis, the flexor tendons of the fingers, the lumbricales muscles, and the muscles of the little finger. It is also higher or nearer to the carpus than the superficial arch, and differs from it in retaining its size almost undiminished. It is accompanied by the deep branch of the ulnar nerve, which runs from the inner end of the arch outwards.

*Branches.*—The *deep palmar arch* gives off *recurrent* branches (rami retrogradi,—Haller) from its upper concave side, which ascend and anastomose with the branches from the anterior carpal arch. It likewise furnishes *superior perforating* branches, three in number, which pass backwards through the upper extremities of the last three interosseous spaces to inosculate with the dorsal interosseous arteries. Lastly, the *deep palmar arch* affords origin, from its convexity, to the *palmar interosseous arteries* (interossee volares,—Haller), usually three in number, but very liable to variation, which lie upon the interosseous spaces, supply the muscles there, and anastomose at the clefts of the fingers with the digital branches from the superficial arch. It is by an enlargement of these small vessels that the *deep palmar arch* sometimes supplies the corresponding digital arteries in the absence of those usually derived from the superficial arch.

## ARTERIES OF THE HAND: VARIOUS CONDITIONS OF.

The arteries of the hand frequently vary from their usual mode of distribution. Ordinarily there are, it will be remembered, two sets of arteries in the hand communicating with each other, viz., an *ulnar* or *superficial* set on the inner side, and a *radial* or *deep* set on the outer. Now, from the usual arrangement presented by these two sets of arteries there are numerous deviations, which may be classed as follows. *a.* By far the larger number of deviations consist of a deficiency in one or other of these sets of arteries, accompanied by a corresponding increase in the opposite one; and it may be observed that the defect is much more commonly on the part of the superficial, and the increase on the part of the deep set. *b.* In a second and smaller class of variations a deficiency in one or other of the two systems above referred to is supplied, either by the enlargement of branches which descend in front of the limb, as the superficial volar (from the radial), or the median artery (from the anterior interosseous), or by the enlargement of a metacarpal branch (from the radial) on the back of the hand.

In illustration of these general remarks, the following modes of arrangement of the vessels may be mentioned.

In the greater number of cases the superficial palmar arch is diminished, and gives off fewer digital branches than usual. Generally only one branch is wanting, viz., that which supplies the adjacent sides of the fore and middle fingers; but sometimes two or three branches are absent, or even all four, as when the ulnar artery, after giving branches to the short muscles of the little finger, ends in the deep palmar arch. In the last-named case, which is rare, it is obvious that the superficial arch is altogether wanting.

These various deficiencies in the superficial palmar arch and its branches are usually compensated for by an enlargement of the deep arch, the palmar inter-



osseous branches of which, being increased in size, divide at the clefts of the fingers, and form such collateral digital branches as are not derived from the usual source. But a defective superficial arch may, as before mentioned, be reinforced from other vessels, viz., from the superficial volar, from an enlarged median artery, or from a large metacarpal branch.

It sometimes, but more rarely, happens, that the radial system of vessels is deficient; in which case the superficial arch (which belongs to the ulnar system) may supply all the digital arteries to the thumb and fingers, or one of these may be derived from the superficial volar, the median, or the radial interosseous.

#### DESCENDING AORTA—THORACIC AORTA.

From the point at which its arch is considered to terminate—the lower margin of the third dorsal vertebra—the aorta descends along the fore part of the spine to the fourth lumbar vertebra, where it divides into the common iliac arteries. The direction of this part of the vessel is not vertical, for as its course is influenced by the spine, upon which it rests, it is necessarily concave forwards in the dorsal region, and convex forwards in the lumbar. Again, its commencement is at the left side of the bodies of the vertebræ; its termination also inclines a little to the left, whilst about the last dorsal vertebra it is nearly upon the median line. From this arises another slight curve, the convexity of which is to the right side. Within the thorax, where the offsets are small, the aorta diminishes but little in size; in the abdomen the diminution is considerable, in consequence of large branches being furnished to the viscera in that cavity.

That part of the aorta (below the arch) which is situated in the thorax is called the *thoracic aorta* [*aorta thoracica descendens*], fig. 236, B.; it extends from the lower border of the third dorsal vertebra on its left side, to the opening in the diaphragm in front of the last dorsal vertebra. It lies in the back part of the interpleural space (the posterior mediastinum), being before the spine and behind the root of the left lung and the pericardium; its left side is in contact with the corresponding pleura and lung, and close on the right side are the azygos vein, the thoracic duct and œsophagus. The latter tube, however, towards the lower part of the thorax, inclines in front of the artery, and near the diaphragm gets somewhat to its left side. The small azygos vein crosses behind the thoracic aorta.

The branches derived from the thoracic aorta are numerous but small. They are distributed to the walls of the thorax, and to the viscera contained within it—the latter being much the smaller and least numerous branches.

The branches to the viscera are very irregular in their number and place of origin. They are as follows:—

The *pericardiac branches* [*a. pericardiacæ*] are some very small and irregular vessels which pass forwards and ramify on the pericardium.

The *bronchial arteries* (*bronchiales*) are the proper nutritious arteries of the substance of the lung: they accompany the bronchial tubes in their ramifications through that organ, and they also supply the bronchial glands, and in part the œsophagus. These vessels vary frequently in number, and in their mode of origin. The bronchial artery of the right side arises from the first aortic intercostal artery, or by a common trunk with the left bronchial artery from the thoracic aorta; on the left side there are generally two bronchial arteries, both of which arise from the thoracic aorta, one near the commencement of that trunk, and the other, named inferior bronchial, lower down. Each artery is usually



directed to the back part of the corresponding bronchus, along which it runs, dividing and subdividing with the successive bronchial ramifications in the substance of the lung.

*Peculiarities of the bronchial arteries.*—The place of origin is liable to much variation.

The artery of the right side has been found to arise singly from the aorta, from the internal mammary, or from the inferior thyroid. The bronchial arteries of the two sides have been seen to arise by a common trunk from the subclavian (Haller). Two such common trunks, each furnishing a branch to the right and left lungs, have been observed, in a single case, to descend into the thorax after arising, one from the internal mammary, and the other from the superior intercostal artery. Some other peculiarities in these arteries of less note have from time to time been recorded; it is necessary only to refer to one, viz., the occurrence of two distinct bronchial arteries for each lung.

The *œsophageal* arteries [a. *œsophageæ*,] are variable in size and number; there are usually four or five, which arise from the fore part or right side of the aorta, and run obliquely downwards upon the *œsophagus*, supplying its coats. The lower branches of these vessels anastomose with the ascending offsets of the coronary artery of the stomach, whilst the upper branches communicate in a similar way with those of the inferior thyroid artery.

The glands and loose tissue in the posterior mediastinum also receive small branches (*posterior mediastinal*), [a. *mediastinicæ*].

The branches furnished by the aorta to the walls of the thorax are named the *intercostal* from their course between the ribs.

The *intercostal* arteries, fig. 236, *f, f* (*inferior* or *aortic intercostals*) [*intercostales*], arise from the posterior part of the aorta, and run outwards upon the bodies of the vertebræ, after which they lie along the intercostal spaces. They are usually ten in number, the upper intercostal space and occasionally a second space also, being supplied by the superior intercostal (a branch of the subclavian artery). Owing to the position of the aorta to the left side of the spine, the right aortic intercostals cross over the front of the vertebræ, furnishing many small branches to those bones; and they are therefore a little longer than the arteries of the left side. As these vessels pass outwards, they are covered by the pleura, and crossed by the sympathetic nerve; those of the right side also pass behind the *œsophagus*, the thoracic duct, and the *azygos* vein.

Having reached the middle of its corresponding intercostal space, each aortic intercostal artery divides into two branches, of which one (a *dorsal branch*), passes backwards, and will be presently described; whilst the other or *anterior* division continues outwards between the ribs.

This *anterior* branch, or proper *intercostal* artery, [a. *intercostalis*,] passes outwards, at first between the pleura with a thin fascia (in front), and the external intercostal muscle (behind); and afterwards between the two layers of intercostal muscles. Having gained the lower border of the rib above, near the angle of the bone, by passing obliquely upwards from the middle of the intercostal space, the artery furnishes several small branches, and one long and slender branch which inclines downward and approaches the border of the rib below, supplying the bone and the intercostal muscles. After giving off these branches, the artery continues along the lower border of the rib above, and after supplying the intercostal muscles, anastomoses with the anterior intercostal branches derived from the internal mammary artery, and with the thoracic branches of the axillary artery.

The first of the aortic intercostal arteries has an anastomosis with the superior intercostal, which is derived from the subclavian artery, and the last three are prolonged amongst the abdominal muscles, where they communicate with the epigastric artery in front, with the phrenic arteries at the side, and with the lumbar branches of the abdominal aorta lower down.

Each intercostal artery is accompanied, as it runs outwards between the ribs, by a corresponding vein, and by one of the dorsal nerves.

The *posterior* or *dorsal* branch [*ramus dorsalis*], of each intercostal artery passes backwards to the inner side of the anterior costo-transverse ligament, with the posterior branch of the corresponding spinal nerve; and having furnished an



offset to the spinal canal, reaches the muscles of the back, and divides into an internal and an external branch. The internal branch is directed towards the spinous processes, on or through the semispinalis dorsi, and ramifies in the muscles and the skin. The external branch turns outwards under the longissimus dorsi, and is distributed between that muscle and the sacro-lumbalis; some reach the superficial muscles.

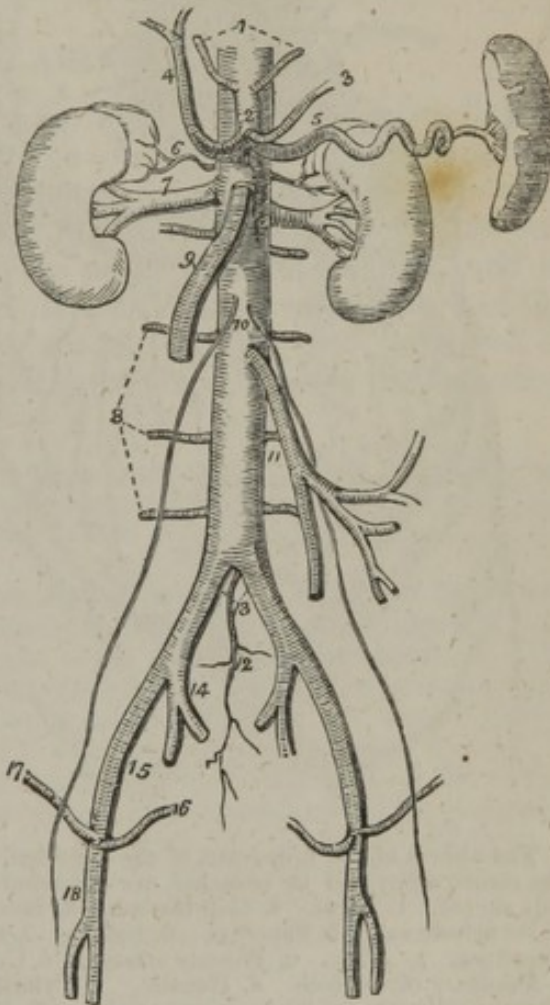
The *spinal* branches of the aortic intercostal arteries are distributed partly to the cord and its membranes, and partly to the bones, in the same manner as the spinal branches of the lumbar arteries, to the description of which reference is to be made.

## ABDOMINAL AORTA.

The aorta, after having passed the diaphragm is thus named. It rests on the bodies of the vertebræ, extending from the front of the last dorsal to the fourth lumbar vertebra, a little to the left of the median line, where it usually divides. The anterior surface of the great artery is successively in apposition with the liver, the splenic vein, the pancreas, the third portion of the duodenum, the left renal vein, and the peritoneum. The vena cava lies at its right side, the right crus of the diaphragm being interposed at the upper part of the abdomen; close to the same side, are the thoracic duct and the azygos vein, which are placed between the aorta and the right crus of the diaphragm. The aorta is surrounded by a mesh of nerves derived from the sympathetic.

The abdominal aorta, [aorta abdominalis,] fig. 236, c; 245, gives numerous branches, which may be divided into two sets, viz., those which supply the viscera, and those which are distributed to the walls of the abdomen. The former consist of the celiac artery, the superior mesenteric, the capsular, the renal, and the spermatic arteries; whilst among the latter are included the phrenic, the lumbar, and the middle sacral arteries. The first three of the visceral branches are single arteries.

[Fig. 245.]



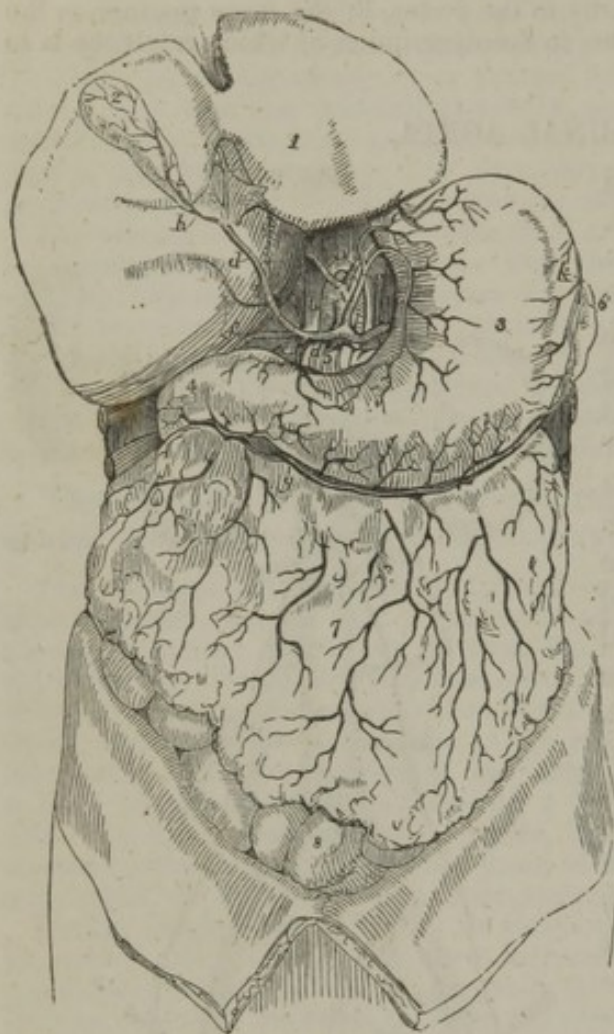The abdominal aorta with its branches. 1. The phrenic arteries. 2. The celiac axis. 3. The gastric artery. 4. The hepatic artery, dividing into the right and left hepatic branches. 5. The splenic artery, passing outwards to the spleen. 6. The supra-renal artery of the right side. 7. The right renal artery, which is longer than the left, passing outwards to the right kidney. 8. The lumbar arteries. 9. The superior mesenteric artery. 10. The two spermatic arteries. 11. The inferior mesenteric artery. 12. The sacra media. 13. The common iliacs. 14. The internal iliac of the right side. 15. The external iliac artery. 16. The epigastric artery. 17. The circumflexa ilii artery. 18. The femoral artery.—W.]



## CÆLIAC ARTERY OR AXIS.

The *cæliac artery*, [a. cœliaca,] fig. 236, g, fig. 246, b, a short and very thick vessel, arises from the aorta close to the margin of the diaphragm. In the erect position of the body its direction is nearly horizontal forwards, and it is not more than half an inch long. It is behind the small omentum, and lies close to the left side of the lobulus Spigelii of the liver, and above the pancreas, the two semilunar ganglia being in apposition with it, one on each side. After this very short course, the artery divides into three branches, viz., the coronary artery of the stomach, the hepatic, and the splenic. These three branches separate at the same time from the end of the artery like radii from an axis, whence, says Winslow, this trunk has been called axis arteriæ cœliacæ.

Fig. 246.



The viscera of the upper part of the abdomen, with the cœliac artery and its branches, are represented in this sketch. 1. Liver. 2. Gall-bladder. 3. Stomach. 4. Its pyloric end. 5. Pancreas. 6. Spleen. 7. Great omentum. A. Aorta. a. Phrenic arteries. b. Cœliac. c. Coronary of stomach. d. Hepatic. e. Pyloric. f. Gastro-duodenal. g. Right gastro-epiploic. h. Cystic artery to gall-bladder. i. Splenic. k. Left gastro-epiploic.

only two branches at its division, (the coronary and the splenic,) the hepatic being supplied from another source. Rarely, it gives more than three branches to the viscera, the additional vessel being a second coronary, or a separate gastro-duodenal artery. Both phrenic arteries are sometimes derived from this trunk. Cases have been met with in which a connexion existed between the cœliac axis and the superior mesenteric artery close to their origin.

Besides these branches which supply the viscera, the cœliac usually gives off one branch to the walls of the abdomen, viz., one of the phrenic arteries.

The *cæliac axis* is from time to time partly covered at its origin by the diaphragm. It may be longer than usual, in which case its branches are not given off together; or it may be wanting altogether, the coronary, hepatic, and splenic arteries, arising separately from the aorta. In some cases the cœliac artery gives off

## CORONARY ARTERY OF THE STOMACH.

The *coronary artery* of the stomach (*coronaria ventriculi*), fig. 246, c, the smallest of the three visceral branches derived from the cœliac



artery, inclines upwards, and to the left side, to reach the cardiac orifice of the stomach. At this point some branches are sent upwards on the œsophagus, which communicate with the aortic œsophageal arteries; others pass before and behind the cardiac extremity of the stomach, and join with branches of the splenic artery. The continuation of the vessel lies between the layers of the smaller omentum, and inclining from left to right along the upper curvature of the stomach, gives branches to its coats, and inosculates with the pyloric branch of the hepatic artery.

The coronary artery of the stomach is sometimes given off directly from the aorta; and is occasionally represented by two separate vessels. It sometimes furnishes an additional hepatic artery.

#### HEPATIC ARTERY.

The *hepatic artery*, [a. hepatica,] fig. 246, *d*, which is intermediate in size, at least in the adult, between the coronary and splenic arteries, gives branches to the stomach, the duodenum, and the pancreas, besides supplying the liver and gall-bladder. It inclines upwards, and to the right side, between the layers of the small omentum, and in front of the foramen of Winslow, to reach the transverse fissure of the liver, in which course it lies upon the vena portæ and to the left of the bile-duct. Previously to reaching the liver, it gives the following branches:

The *pyloric artery*, [a. pylorica,] *e*, descends to reach the pyloric end of the stomach, turning from right to left along its upper curvature, supplies it with branches, and inosculates with the coronary artery. This is sometimes a branch of the following artery (the *gastro-duodenal*).

The *gastro-duodenal*, [a. gastro-duodenalis] *f*, descends behind the duodenum near the pylorus, and on reaching the lower border of the stomach, changes both its name and direction. It runs from right to left along the great curvature of the stomach, between the layers of the great omentum, assuming the name of *right gastro-epiploic*, [a. gastro-epiploica dextra,] *g*, and inosculates with the left gastro-epiploic derived from the splenic artery. This artery gives branches upwards to both surfaces of the stomach, and long slender vessels downwards to the omentum. From the *gastro-duodenal* artery a branch, *pancreatico-duodenal* [a. pancreatico-duodenalis], fig. 247, *h*, descends along the inner margin of the duodenum, between it and the pancreas, and, after furnishing several branches to both these organs, anastomoses with a small offset of the superior mesenteric artery.

Near the transverse fissure of the liver, the hepatic artery divides into its right and left branches, which are intended for the supply of the corresponding lobes of that organ. The *left*, the smaller division, lying in front of the vena portæ, diverges at an acute angle from the other branch, and turns outwards to reach the left extremity of the transverse fissure of the liver, where it enters that organ.

The *right hepatic* artery inclines outwards to the right extremity of the transverse fissure. When crossing behind the cystic duct, it gives off a branch, <sup>19</sup>, the *cystic artery*, [a. cystica] which turns upwards and forwards upon the neck of the gall-bladder, and divides into two smaller branches, of which one ramifies between its coats at its depending surface, the other between it and the liver. The *right hepatic* artery then divides into two or three branches, which enter the liver by its transverse fissure, and ramify in its substance, accompanying the divisions of the vena portæ and hepatic ducts.

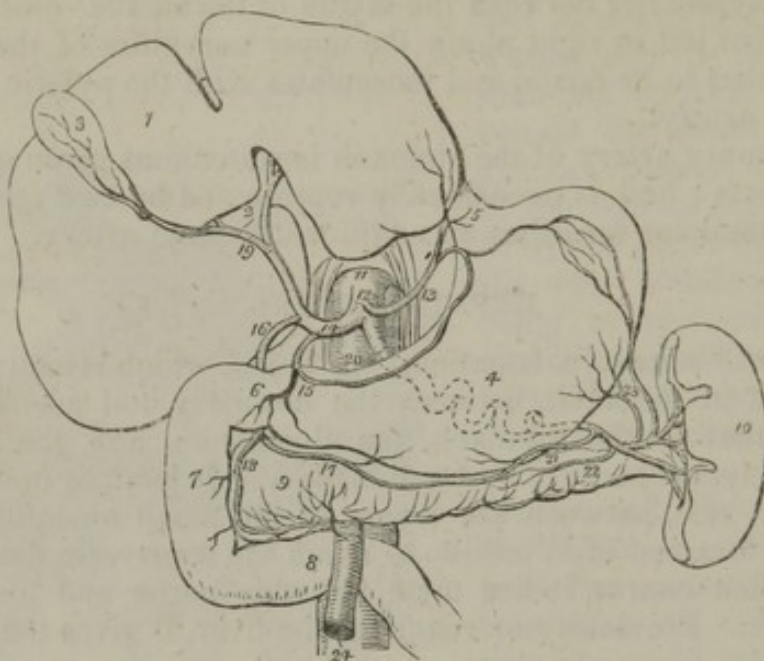
The hepatic artery may arise from the superior mesenteric artery, or from the aorta itself. Accessory hepatic arteries are often met with, usually coming from the coronary artery of the stomach. It has been found to furnish a phrenic branch.



## SPLENIC ARTERY.

The *splenic* artery, [a. splenica,] figs. 246, 247,<sup>20</sup> in the adult the largest branch of the cœliac artery, is destined to supply the spleen,

[Fig. 247.]



The distribution of the branches of the cœliac axis. 1. The liver. 2. Its transverse fissure. 3. The gall-bladder. 4. The stomach. 5. The entrance of the œsophagus. 6. The pylorus. 7. The duodenum, its descending portion. 8. The transverse portion of the duodenum. 9. The pancreas. 10. The spleen. 11. The aorta. 12. The cœliac axis. 13. The gastric artery. 14. The hepatic artery. 15. Its pyloric branch. 16. The gastro-duodenalis. 17. The gastro-epiploica dextra. 18. The pancreatico-duodenalis, inosculating with a branch of the superior mesenteric artery. 19. The division of the hepatic artery into its right and left branches; the right giving off the cystic branch. 20. The splenic artery, traced by dotted lines behind the stomach to the spleen. 21. The gastro-epiploica sinistra, inosculating along the great curvature of the stomach with the gastro-epiploica dextra. 22. The pancreatica magna. 23. The vasa brevia to the great end of the stomach, inosculating with branches of the gastric artery. 24. The superior mesenteric artery, emerging from between the pancreas and transverse portion of the duodenum.—W.]

and in part the stomach and pancreas. It is directed horizontally towards the left side. Waving and often tortuous in its course, it passes, together with the splenic vein, which is below it, behind the upper border of the pancreas, and divides near the spleen into several branches. Some of these enter the fissure in that organ, and are distributed to its substance; three or four are reflected towards the bulging end of the stomach, upon which they ramify. Its branches are the following:—

The *pancreatic* branches [a. pancreaticæ], fig. 247,<sup>22</sup> variable in size and number, are given off whilst the artery is passing along the pancreas, the middle and left part of which they supply with vessels. One of larger size not unfrequently runs from left to right, in the direction of the pancreatic duct, and is called *pancreatica magna*.

The *splenic* branches are the proper terminal branches of the artery; they are five or six, or even more in number, and vary in length and size; they enter the spleen by the hilus or fissure in its concave surface, and ramify within that organ.

The *gastric* branches,<sup>23</sup> (*vasa brevia*,) [s. a. gastricæ breves,] vary from five to seven in number; they are directed from left to right, some issuing from the trunk



of the splenic artery, others from its terminal branches. Enclosed within the gastro-splenic omentum, they reach the left extremity of the stomach, where they divide and spread out between its coats, communicating with the coronary and left gastro-epiploic arteries.

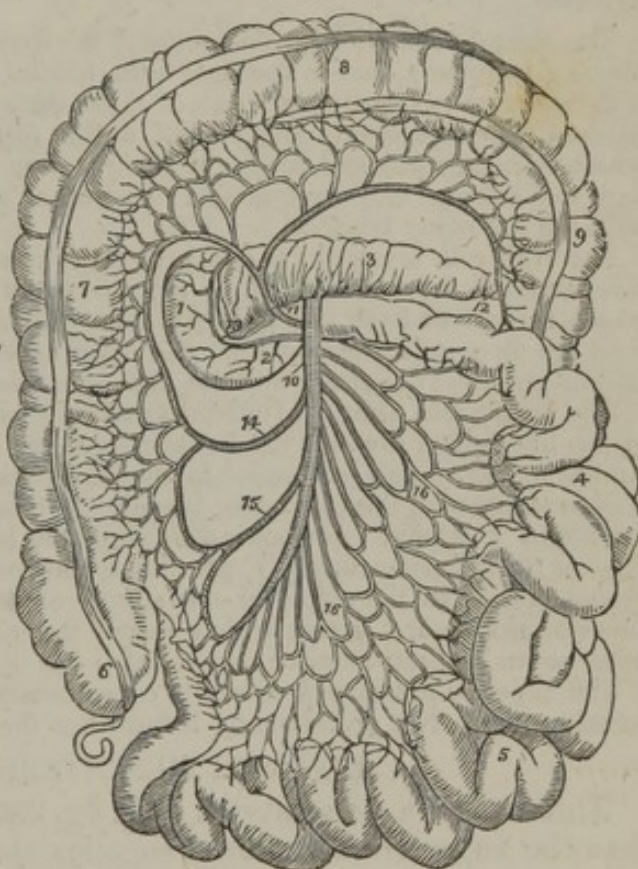
The left *gastro-epiploic* artery [a. gastro-epiploica sinistra], runs from left to right along the great curvature of the stomach, figs. 246, *k*, 247,<sup>21</sup> and inosculates with the right gastro-epiploic branch from the hepatic artery. In its course, this vessel lies between the layers of the peritoneum at the great border of the stomach, and gives several long and slender branches downwards to the omentum, and others upwards to both surfaces of the stomach, where they communicate with the other gastric arteries.

### SUPERIOR MESENTERIC ARTERY.

The *superior mesenteric*, [a. mesenterica s. mesaraica superior,] fig. 247,<sup>24</sup>; fig. 248,<sup>10</sup> an artery of large size, supplies

[Fig. 248.

the whole of the small intestine beyond the duodenum, and also a part of the great intestine. It arises from the fore part of the aorta, a little below the celiac artery. For a short space this artery is covered by the pancreas; on emerging from below that gland it descends in front of the duodenum at its end, and is thence continued between the layers of the mesentery. The splenic vein crosses over its root. In the mesentery the artery at first passes downwards and to the left side, but afterwards curves towards the right iliac fossa, opposite to which it inosculates with its own ileo-colic branch.



The course and distribution of the superior mesenteric artery. 1. The descending portion of the duodenum. 2. The transverse portion. 3. The pancreas. 4. The jejunum. 5. The ileum. 6. The cæcum, from which the appendix vermiformis is seen projecting. 7. The ascending colon. 8. The transverse colon. 9. The commencement of the descending colon. 10. The superior mesenteric artery. 11. The colica media. 12. The branch which inosculates with the colica sinistra. 13. The branch of the superior mesenteric artery, which inosculates with the pancreatico-duodenalis. 14. The colica dextra. 15. The ileo-colica. 16, 16. The branches from the convexity of the superior mesenteric to the small intestines.—W.]

*Branches.*—Whilst under cover of the pancreas, the superior mesenteric artery sends off a small branch, *inferior pancreatico-duodenal*, which runs along the concave border of the duodenum, and joins with the pancreatico-duodenal artery. Its other branches may be divided into two sets, viz., those from the left or convex, and those from the right or concave side.



Those which spring from the convex or left side of the vessel, fig. 248,<sup>16</sup> (*rami intestini tenuis*) are intended for the supply of the jejunum and ileum. They are usually twelve or more in number, and are all included between the layers of the mesentery. They run parallel to one another for some distance, and then divide into two branches, each of which forms an arch with the neighbouring branch. From the first set of arches other branches issue, which divide, and recommunicate in the same way, until, finally, after forming four or five\* such tiers of arches, each smaller than the other, the ultimate divisions of the vessels proceed directly to the intestine, turning upon it on both sides, and ramifying in its coats.

The branches from the right or concave side of the superior mesenteric artery are given to the colon, and hence are named the *colic arteries*.

The *ileo-colic artery*,<sup>15</sup> [a. ileo-colica,] the first in order from below upwards, inclines downwards, and to the right side, towards the ileo-colic valve, near which it divides into two branches: one of these descends to inosculate with the termination of the mesenteric artery itself, and to form an arch, from the convexity of which branches proceed to supply the junction of the small with the large intestine, the cæcum, and its appendix; the other division ascends and inosculates with the following branch.

The *right colic artery*,<sup>14</sup> [a. colica dextra,] passes transversely towards the right side, beneath the peritoneum, to the middle of the ascending colon, opposite to which it resolves itself into two branches, of which one descends to communicate with the ileo-colic artery, whilst the other ascends to join in an arch with the middle colic.—This artery and the ileo-colic often arise by a common trunk.

The *middle colic artery*,<sup>11</sup> [a. colica media,] passes upwards between the layers of the mesocolon towards the transverse colon, and divides in a manner exactly similar to the vessels just noticed. One of its branches inclines to the right, where it inosculates with the preceding vessel; the other<sup>12</sup> descends to the left side, and maintains a similar communication with the left colic branch, derived from the inferior mesenteric artery. From the arches of inosculature thus formed, small branches pass to the colon for the supply of its coats. Those branches of the superior mesenteric artery which supply the ascending colon have a layer of peritoneum on their anterior aspect only; the others lie between two layers.

The superior mesenteric artery is occasionally connected at its origin with the celiac artery. Not unfrequently it furnishes the hepatic artery.

#### INFERIOR MESENTERIC ARTERY.

This artery [a. mesenterica inf.], fig. 236, *i*; fig. 249,<sup>9</sup> much smaller than the superior mesenteric, supplies the left side of the colon, and the greater part of the rectum. It arises from the aorta, between an inch and two inches above the bifurcation of that trunk.

The inferior mesenteric artery deviates to the left side in the direction of the left iliac fossa, from which point it descends between the layers of the meso-rectum into the pelvis, and under the name of "superior hæmorrhoidal" artery, runs down behind the rectum. It lies at first close to the aorta, on its left side, and then crosses over the left common iliac artery. Its branches are the following:

The *left colic artery* (*colica sinistra*), fig. 249,<sup>10</sup> is directed to the left side behind the peritoneum, and across the left kidney to reach the descending colon. It divides into two branches, and forms a series of arches in the same way as the colic vessels of the opposite side. One of these two branches passes upwards along the colon, and inosculates with the descending branch of the middle colic;

\* [I think it rare to find more than three sets of these arterial arches.—J. L.]



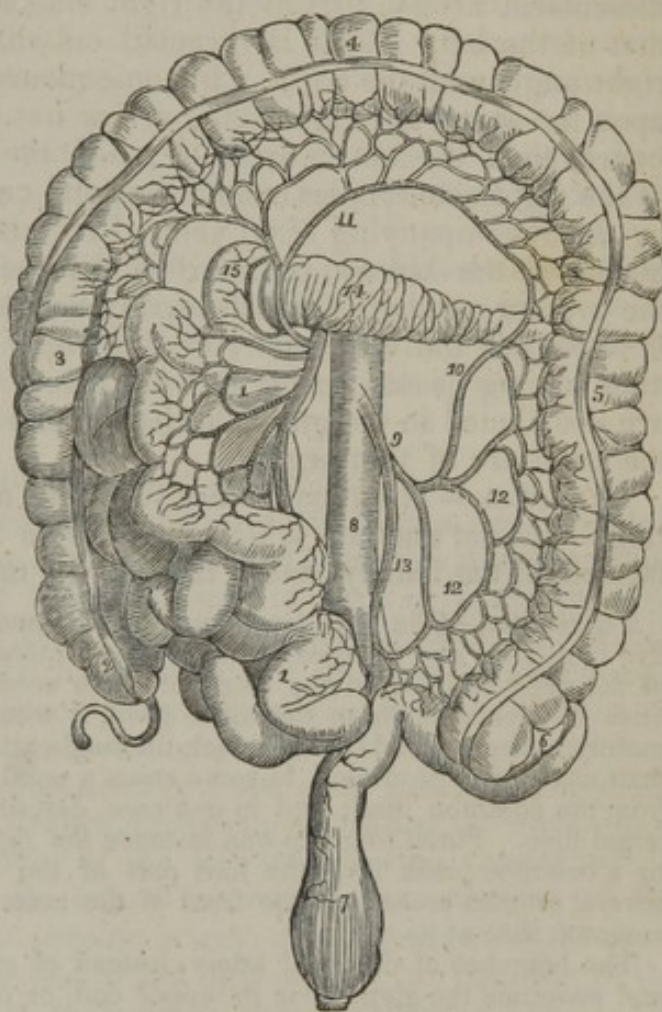
whilst the other descends towards the sigmoid flexure, and anastomoses with the sigmoid artery.

The *sigmoid artery*,<sup>12</sup> runs obliquely downwards to the sigmoid flexure of the colon, where it divides into branches, some of which incline upwards and form arches with the preceding vessel, others turn downwards to the rectum and anastomose with the following branch. Instead of a single sigmoid artery, two or three branches are sometimes present.

The *superior hæmorrhoidal artery*, (*hæmorrhoidalis*,<sup>13</sup> *interna*, — Haller, [s. sup.]), the continuation of the inferior mesenteric, passes into the pelvis behind the rectum, at first in the fold of the meso-rectum, and then divides into two branches which ramify one on each side of the intestine, extending to near its lower end, and anastomosing with the middle and inferior hæmorrhoidal arteries.

In this place it may be remarked that the arteries distributed to the alimentary canal communicate freely one with the other over the whole length of that canal. The arteries of the great intestine, derived from the two mesenteric arteries, form a range of vascular arches along the colon and rectum, at the lower end of which they anastomose with the middle and inferior hæmorrhoidal arteries, given from the internal iliac and pudic arteries. The branches from the left side of the superior mesenteric form another series of arches along the small intestine, which is connected with the former by the ileo-colic artery. Further, a branch of the superior mesenteric joins upon the duodenum with the pancreatoduodenal artery; the latter, at its commencement, is in a manner continuous with the pyloric artery; and so likewise, through the coronary artery of the stomach and its ascending branches, a similar connexion is formed with the œsophageal arteries, even up to the pharynx.

[Fig. 249.]



The distribution and branches of the inferior mesenteric artery. 1, 1. The superior mesenteric artery, with its branches and the small intestines turned over to the right side. 2. The cæcum and appendix cæci. 3. The ascending colon. 4. The transverse colon raised upwards. 5. The descending colon. 6. Its sigmoid flexure. 7. The rectum. 8. The aorta. 9. The inferior mesenteric artery. 10. The colica sinistra, inosculating with 11, the colica media, a branch of the superior mesenteric artery. 12, 12. Sigmoid branches. 13. The superior hæmorrhoidal artery. 14. The pancreas. 15. The descending portion of the duodenum.—W.]

#### CAPSULAR OR SUPRARENAL ARTERIES.

The *suprarenal* or *capsular* arteries [a. *suprarenales*], fig. 236, *m*, are two very small vessels which arise from the aorta on a level with the superior mesenteric artery, and incline obliquely outwards upon the



crura of the diaphragm to reach the under surface of the suprarenal capsules, to which bodies they are distributed, anastomosing at the same time with the other capsular branches derived from the phrenic and the renal arteries. In the fœtus these arteries are of large size.

#### RENAL OR EMULGENT ARTERIES.

The *renal* arteries [a. renales s. emulgentes], fig. 236, *n*, of large diameter in proportion to the size of the organs which they supply, arise from the sides of the aorta, about half an inch below the superior mesenteric artery, that of the right side somewhat lower down than that of the left. Each is directed outwards, so as to form nearly a right angle with the aorta. In consequence of the position of the aorta upon the spine, the right renal artery has to run a somewhat longer course than the left, in order to reach the right kidney. The artery of the right side crosses behind the vena cava, and both are overlapped by the accompanying renal vein. Previously to reaching the concave border of the kidney, each artery divides into four or five branches, the greater number of which usually lie intermediate between the vein in front, and the upper part of the ureter behind. These branches, after having passed deeply into the fissure of the kidney, subdivide and are distributed in the gland, in the manner described in the account of the structure of that organ.

*Branches.*—The renal artery furnishes a small branch to the suprarenal capsule, another which ramifies in the cellular membrane and fat behind the kidney, and a third to the ureter.

*Peculiarities.*—The renal artery may be represented by two, three, four, or even five branches; and the greatest difference is found to exist even on opposite sides of the same body, as to the origin of these accessory vessels. As they usually arise in succession from the aorta itself, it would seem as if the deviation is merely a step beyond that in which the single artery divides into branches sooner than usual after its origin. In some cases a renal artery has been seen to proceed from the common iliac; and in one case, described by Eustachius, from the internal iliac. Portal found in one instance the right and left renal arteries arising by a common trunk from the fore part of the aorta. In another case, one of several arteries arose from the front of the aorta at its bifurcation, or of the left common iliac at its origin.

The branches of the renal artery, instead of entering at the hilus, may reach and penetrate the gland near its upper end, or on its anterior surface. Lastly, cases occur, though very rarely, in which one of the renal arteries is wanting.

#### SPERMATIC ARTERIES.

The *spermatic* arteries [a. spermaticæ], fig. 236, *o*, two small and very long vessels, arise from the fore part of the aorta, a little below the renal arteries. In the fœtus they are short, as the testes, at an early period of development, are placed immediately beneath the kidneys; but the arteries become gradually lengthened as these organs are moved from the abdomen into the scrotum. Each spermatic artery is first directed outwards and downwards, crossing the ureter, and resting on the psoas muscle; after passing over the external iliac artery, it turns forwards to the internal abdominal ring, where it comes into contact with the vas deferens. With this and the other constituents of the spermatic cord, the artery courses along the inguinal canal and



descends to the scrotum to be finally distributed to the testis, after reaching the back part of that gland and anastomosing there with the artery of the vas deferens. The spermatic arteries are covered by the peritoneum until they reach the internal ring. Near the testis they become tortuous.

In the female, the arteries corresponding to the spermatic arteries in the male, named the *ovarian*, are shorter than those vessels, and do not pass out of the abdominal cavity. Their origin, direction, and connexions in the first part of their course, conform to what obtains in the male; but at the margin of the pelvis they incline inwards, and running tortuously between the layers of the broad ligaments of the uterus, are guided to the attached margin of the ovaries, which they supply with branches. Some small branches can also be traced along the round ligament into the inguinal canal, and others along the Fallopian tubes. One, continuing inwards towards the uterus, joins with the uterine artery.

The *spermatic* arteries occasionally arise by a common trunk. Two spermatic arteries are not unfrequently met with on one side; both of which usually arise from the aorta, though one may be a branch from the renal artery. A case has occurred of three arteries on one side,—two from the aorta and the third from the renal.

#### INFERIOR PHRENIC ARTERIES.

The *phrenic* arteries [a. phrenicæ inferiores], fig. 246, *a*, are two small vessels which arise from the aorta, on a level with the under surface of the diaphragm. These little arteries are very irregular in their origin. Supposing them to arise separately one from the other (which will be presently seen to be by no means a constant arrangement), most commonly one is derived from the celiac artery close to its origin, and the other from the aorta on a level with the under surface of the diaphragm. They soon diverge from each other, and passing across the crura of the diaphragm, incline upwards and outwards upon its under surface. The artery of the left side, having passed behind the œsophagus, ascends on the left of the œsophageal opening of the diaphragm; whilst the right phrenic artery, after having passed behind the liver and the vena cava, lies to the right side of the opening in the diaphragm which transmits that great vein. Before reaching the central tendon of the diaphragm, each of the arteries divides into two branches, of which one runs forwards towards the anterior margin of the thorax, distributing branches to the diaphragm, and finally anastomosing with the musculo-phrenic branch of the internal mammary artery. The other pursues a transverse direction towards the side of the thorax, and communicates with the terminations of the intercostal arteries.

Each phrenic artery gives small branches (superior capsular) to the suprarenal capsule of its own side; the left artery sends some branches to the œsophagus, whilst the artery of the right side gives small vessels, which reach the termination of the vena cava. Small offsets descend to the liver between the layers of the peritoneum.

The *phrenic* arteries are found to vary greatly in their mode of origin, but these deviations seem to have little influence on their course and distribution. In the



first place, they may arise either separately, or by a common trunk; and it would appear that the latter mode of origin is nearly as frequent as the former. When the two arteries are joined at their origin, the common trunk arises most frequently from the aorta; though, sometimes, it springs from the celiac axis. When arising separately, the phrenic arteries are given off sometimes from the aorta, more frequently from the celiac axis, and occasionally from the renal; but it most commonly happens that the artery of the right side is derived from one, and that of the left side from another of these sources.\* An additional phrenic artery (derived from the left hepatic) has been once met with.

#### LUMBAR ARTERIES.

The *lumbar* arteries, [a. lumbales] fig. 236, *p*, are analogous to the intercostal arteries, not only in their mode of origin, direction, and size, but in a great measure in the manner of their distribution also. Thus, as the intercostal arteries communicate with the branches of the internal mammary upon the thorax, so the lumbar arteries, by anastomosing with the epigastric, have a nearly similar relation to the walls of the abdomen. The lumbar arteries arising from the back part of the aorta, are usually four in number on each side. They pass outwards, (each crossing the middle of the body of the corresponding lumbar vertebra,) and soon dip deeply under the psoas muscle, between it and the bodies of the vertebræ. The two upper arteries are likewise under the pillars of the diaphragm; those on the right side are covered by the vena cava. At the interval between the transverse processes, each lumbar artery divides into a *dorsal* and an *abdominal* branch.

The *abdominal* branch of each lumbar artery runs outwards behind the quadratus lumborum,—the lowest of these branches not unfrequently in front of that muscle. Continuing outwards between the abdominal muscles, the artery ramifies within them, and maintains communications with branches of the epigastric and internal mammary in front, with the terminal branches of the intercostals above, and with those of the ilio-lumbar and circumflex iliac arteries below.

The *dorsal* branch [ramus dorsalis] of each lumbar artery, like the corresponding branch of the intercostal arteries, gives off, immediately after its origin, an offset (named *spinal*), which enters the spinal canal. The dorsal branch then, proceeding backwards with the posterior division of the corresponding lumbar nerve between the transverse processes of the vertebræ, divides into smaller vessels, which are distributed to the muscles and the integument of the back.

The *spinal artery* [ramus spinalis] enters the spinal canal through the intervertebral foramen, and, having given an offset which runs along the nerves to the dura mater and cauda equina and communicates with the other spinal arteries, divides into two branches, which are distributed to the bones in the following manner:—one curves upwards on the back part of the body of the vertebra above, near to the root of the pedicle, whilst the other descends in a similar manner on the vertebra below; and each communicates with a corresponding branch from the neighbouring spinal artery. As this arrangement prevails on both sides and throughout the whole length of the spine,

\* In only one out of thirty-six cases did the phrenic arteries arise in the mode ordinarily described: viz., as two separate vessels from the abdominal aorta.



there is formed a double series of arterial arches behind the bodies of the vertebræ, the convexities of which are turned towards each other. The arches are moreover joined together across the bodies of the vertebræ by transverse branches.

From this interlacement of vessels, numerous ramifications are distributed to the periosteum and the bone.

The *lumbar* arteries of opposite sides, instead of taking their origin separately from the aorta, occasionally commence by a common trunk, whose branches pass out laterally, and continue their course in the ordinary way. Two arteries of the same side are sometimes conjoined at their origin. On the last lumbar vertebra, the place of a lumbar artery is often taken by an offset from the middle sacral artery, and the ilio-lumbar compensates for the absence of the lumbar vessel amongst the muscles.

#### MIDDLE SACRAL ARTERY.

The *middle sacral* artery, [*a. sacralis media*], fig. 236, *k*, the last of the branches of the abdominal aorta, is a small vessel, about the size of a crowquill, which arises from the extremity of the aorta, just at its bifurcation. From this point the artery proceeds downwards upon the last lumbar vertebra and over the middle of the sacrum, as far as the coccyx, where it forms small arches of anastomosis with the lateral sacral arteries. From its anterior surface some small branches come forwards within the fold of the mesorectum, and ramify upon the posterior surface of the intestine, and on each side others spread out upon the sacrum, and anastomose with the lateral sacral arteries, occasionally sending small offsets into the anterior sacral foramina.

The middle sacral artery sometimes deviates a little to the side, and proceeds, not from the bifurcation of the aorta, but from one of the common iliac arteries, usually from that of the left side. This artery represents the caudal prolongation of the aorta of animals having a tail.

#### UNUSUAL PULMONARY BRANCH FROM THE ABDOMINAL AORTA.

A very remarkable case is recorded of the existence of a large pulmonary branch which arose from the abdominal aorta, close to the celiac artery, and after passing upwards through the œsophageal opening in the diaphragm, divided into two branches, which were distributed to the lungs, near their bases.\*

#### BIFURCATION OF THE AORTA.

The abdominal aorta ends by dividing into two trunks, named the common iliac arteries. The bifurcation usually takes place on the body of the fourth lumbar vertebra, a little to the left of the middle line. The point here indicated will be found nearly on a level with a line drawn from one crista of the ilium to the other, and is opposite to the left side of the umbilicus. It should, however, be observed, that the place of division is very inconstant in its position, as will be seen from the following statement—

In more than three-fourths of a considerable number of cases the aorta divided either upon the fourth lumbar vertebra, or upon the intervertebral disc below it;

\* Description d'un artère pulmonaire, &c., par A. Maugars d'Angers. *Journal de Médecine, Chirurgie, Pharm. &c.*, par les Citoyens Corvisart, Leroux, et Boyer. Paris, An. 10. Also, "The Arteries" by R. Quain, p. 426.



in one case in nine it was below, and in about one in eleven above the space thus indicated.—In ten bodies out of every thirteen, the division of the great artery took place within half an inch above or below the level of the crest of the ilium; and it occurred more frequently below than above that space.

The highest point at which the bifurcation of the aorta has been seen to take place is immediately after the origin of the right renal artery. In this case (only one is recorded) the two parts resulting from the division of the vessel were connected by a transverse branch, and then divided each into the external and internal iliac arteries.\*

#### COMMON ILIAC ARTERIES.

The common iliac arteries, fig. 236, *q*, [*a. iliacæ communes*], commencing at the bifurcation of the aorta, pass downwards and outwards, diverging from each other, and divide opposite the intervertebral substance between the last lumbar vertebra and the sacrum, into two branches, named the internal and external iliac arteries—the former being distributed to the walls and viscera of the pelvis, whilst the latter is prolonged into the lower limb, after having sent two important branches to the walls of the abdomen.

The common iliac arteries usually measure about two inches in length. They are both covered by the peritoneum and the intestines, and rest on the bodies of the vertebræ, approaching respectively the psoas muscles at their ends; they are crossed by the ureters at their point of division, and likewise by the branches of the sympathetic nerve, which are directed towards the hypogastric plexus.

The common iliac arteries of opposite sides differ in some degree in their connexions with other parts, but more especially with the neighbouring veins. Thus, the artery of the right side is placed at a distance from the front of the last lumbar vertebra, the two common iliac veins being interposed. The artery of the left side is crossed by the branches of the inferior mesenteric artery.

*Veins.*—The left iliac vein, supported on the last lumbar vertebra, lies to the inner side of, and below the left artery. On the right side there are three veins in connexion with the artery; the right iliac vein lying behind the lower part of the vessel, the iliac vein of the left side crossing behind it, and the vena cava (resulting from the union of the two others) being on the right side of the artery at its upper end.

#### PECULIARITIES OF THE COMMON ILIAC ARTERIES.

Besides slight differences between the arteries of the two sides, in length and direction, by no means of constant occurrence, the common iliac arteries vary in their place of origin, and in the point at which they divide.

The place of *origin* of the common iliac arteries coincides with that of the bifurcation of the aorta, the variations in which have been already noticed.

The *height* at which these arteries *divide* is subject to great variety. In two-thirds of a large number of cases, the place of division ranged between the middle of the last lumbar vertebra and the upper margin of the sacrum; in one case in eight it was above, and in one case in six below that space. Most frequently the left artery was found to divide lower down than the right.

The *length* also was observed to differ much in different instances. In five-sevenths of the cases examined, it varied from an inch and a half to three inches; of the remaining cases, in about half, the artery was longer, and in the other half, shorter; the minimum length being (only in one case) less than half

\* Sylloge observ. anatom. select., § 77, in Haller. "Disputat. Anatom." t. vi. p. 781. "The Arteries," by R. Quain, p. 416.



an inch, and the maximum four and a half inches. In estimating the relative lengths of the right and left arteries, it was found that the right was the longer in sixty-three, and the left in fifty-two, whilst the two were equal in fifty-three.

In one instance, recorded by Cruveilhier, (*Anat. descript.* t. iii., p. 186), the right common iliac was wanting, and the internal and external iliacs of that side arose as distinct branches from the aorta.

#### SURGICAL ANATOMY OF THE COMMON ILIAC ARTERIES.

The common iliac artery, extending in a line from the left side of the umbilicus towards the middle of Poupart's ligament, and being placed at its commencement on a level with the highest part of the crest of the ilium, may be approached in an operation, by dividing the abdominal muscles to a sufficient extent, in the iliac region and a little above this part of the abdomen. The incisions might be made, beginning above Poupart's ligament, to the outer side of its middle, and running parallel with that structure towards the anterior superior spine of the iliac bone, thence curving for a couple of inches towards the umbilicus. In this way the artery will be approached from below; but, if a tumour extends along the external iliac artery, this plan of operation would be objectionable, for the swelling itself, and, it may be, the adhesion of the peritoneum to its surface, would be sources of serious difficulty. Should the aneurism extend upwards in the abdomen it will be best to approach the artery from the side, or rather from above,—not from below. The essential part of the operation, so far as the abdominal muscles are concerned, is, that they should be divided to the extent of five or six inches at the side of the abdomen, beginning about two inches above the level of the umbilicus and ending lower than the spine of the ilium, the incision being curved outwards towards the lumbar region. Sir P. Crampton, in an operation to tie this artery, divided the muscles from the end of the lowest rib, straight down nearly to the crest of the ilium and thence forward a little above the border of the bone as far as its spine.\* This plan is well devised for the object.

The fascia behind the muscles (*fascia transversalis*) is to be cut through with care, and the peritoneum to be raised from that and the iliac fascia, as well as from the cellular membrane (sometimes containing a quantity of fat), which is interposed between the serous and the fibrous membranes. With the peritoneum will be raised the ureter, which adheres to it.

The artery will be seen on the last lumbar vertebra; and, on the right side of the body, large veins will be in view in close connexion with it, viz., both common iliac veins, and the commencement of the lower vena cava. It will be remembered, that in some cases, (without transposition of the viscera, as well as with that condition,) the iliac veins are joined on the left instead of the right side; and that in another small class of cases the junction of those veins is delayed, so to say. The effect of either of these conformations of the venous system, would be to give to the artery on the left side much more than the usual complication with veins. Lastly, the thin cellular membrane covering the artery is divided without any difficulty to admit the passage of the ligature.

The common iliac artery is in most cases of sufficient length to admit of the application of a ligature without much apprehension of secondary hemorrhage occurring in consequence of insufficiency in this respect. But it has been shown above to be in some instances very short—so short that the operation would be inadmissible. In any case in which the common trunk is thus short, it would probably be more prudent to place a ligature on the external iliac and another on the internal iliac, at the origin of each, than to tie the common iliac artery, or the external iliac alone near its commencement.

The surgeon has it in his power to judge of the length of the artery during the operation, and to determine as to the propriety of tying one vessel or the other, for the iliac arteries are under his view almost as fully as if dissected. Arteries in other parts of the body, are, on the contrary, only seen at the point at which it has been beforehand determined to place the ligature.

No branch that has received a name is given off by the common iliac arteries in their course; but somewhat above the sacro-iliac sym-

\* *Med. Chir. Trans.*, vol. xvi.







the artery being in the extreme cases about half an inch and three inches in extent.

The lengths of the common iliac and internal iliac arteries bear an inverse proportion to each other—the internal iliac being long when the common iliac is short, and *vice versa*. Moreover, when the common iliac is short, the internal iliac (arising higher than usual) is placed for some distance out of the pelvis, and descends by the side of the external iliac to reach that cavity.

The *place of division* of the internal iliac into its branches varies between the upper margin of the sacrum and the upper border of the sacro-sciatic foramen.

The length of the internal iliac arteries of the two sides was, in a series of cases, often found to differ, but neither seemed habitually to exceed the other.

#### SURGICAL ANATOMY OF THE INTERNAL ILIAC ARTERY.

This artery has been tied for aneurism affecting one of its large branches on the back of the pelvis—the gluteal or sciatic. It is arrived at by dividing the abdominal muscles before the iliac fossa to a greater extent than is required for exposing the external iliac—in the manner of the operation first mentioned for the common iliac. The vein, a large one is, it will be borne in mind, behind the artery and in contact with it: it is occasionally double.

There is some difference in the degree of difficulty that would be experienced in securing the internal iliac artery in different cases. This is owing to the fact that, when short, (and, as shown above, it often is so,) the artery is placed deeply in the pelvis; whereas, when the length is more considerable, it is accessible above that cavity.

Again, when the artery is very short, it would probably be more safe to tie the common iliac, or both the external and the internal iliacs at their origin than to place a ligature on the latter only, close to a strong current of blood.

The *internal iliac artery in the fœtus (hypogastric)*, curves forwards from the common iliac artery to the side of the urinary bladder. In this course it descends but little, as the bladder projects into the abdomen in early life. Coursing upwards by the side and fundus of that organ, the vessel reaches the anterior wall of the abdomen, along which it ascends towards the umbilicus, converging to the vessel of the opposite side. At the umbilicus the two arteries come into contact with the umbilical vein, and then escaping with that vein from the abdomen, coil round it in the umbilical cord, and ramify in the substance of the placenta. To that part of the vessel which is placed within the abdomen, the term *hypogastric* is applied; the remaining portion thence onward through the umbilicus to the placenta, being the proper *umbilical* artery. In the first part of its course each vessel lies along the margin and side of the pelvis, covered by the peritoneum and crossed by the ureter; it next lies between that membrane and the side of the bladder, to which it gives branches (*superior vesical*), and is crossed in the male by the vas deferens; and finally, it ascends towards the umbilicus, between the peritoneum and the fascia transversalis, the latter separating it from the rectus muscle and its sheath.

After the cessation of the placental circulation at birth, the two hypogastric arteries become impervious from the side of the bladder upwards to the umbilicus, and are converted into fibrous cords. These two cords, which extend from the sides of the bladder to behind the umbilicus, being shorter than the sac of the peritoneum on which they rest, cause the serous membrane to project inwards, and thus are formed two fossæ (fossæ of the peritoneum) on each side of the abdomen. The part of the artery intervening between the origin of



the vessel and the side of the bladder, still continues pervious, and though reduced proportionately in size, continues to convey blood to the bladder, constituting the superior vesical artery.

*Branches.*—The branches of the internal iliac artery, though constant and regular in their existence and general distribution, vary much in their origin. Some are distributed to the parts or organs within the pelvis, viz., to the rectum, the urinary bladder, the spinal canal, and the organs peculiar to the female; whilst others of larger size supply chiefly the muscles upon the outer side of the pelvis. The branches furnished to these several structures will, in most cases, be observed to arise from two principal divisions of the parent trunk, of which one is anterior to the other. From the anterior division the following branches usually arise, viz., the superior vesical (the pervious portion of the fœtal hypogastric artery), the inferior vesical, middle hæmorrhoidal, obturator, internal pudic, and sciatic arteries, with (in the female) the uterine and the vaginal. The posterior division gives off the gluteal, the ilio-lumbar and the lateral sacral arteries.

Sometimes all the branches of the internal iliac artery arise without the previous separation of that vessel into two divisions.

In more than a fourth of a large number of cases noted, a branch arose before the subdivision of the main trunk. This branch was usually the ilio-lumbar artery.

#### VESICAL ARTERIES.

The urinary bladder receives several arteries, amongst which, however, may be specially recognised two principal branches, a superior and an inferior vesical artery.

The *superior vesical* artery [a. vesicalis sup. fig. 250,<sup>10</sup>] is that part of the hypogastric artery (in the fœtus) which remains pervious after the changes that take place subsequently to birth. It extends from the anterior division of the internal iliac to the side of the bladder.

It distributes numerous branches to the upper part and sides of the bladder, from one of the lowest of which, a slender artery reaches the vas deferens, and accompanies that duct in its course to the back of the testicle, where it anastomoses with the spermatic artery. This is the *artery of the vas deferens*, or *deferent artery*. Other small branches ramify on the lower end of the ureter.

The *inferior vesical* artery,<sup>15</sup> ([a. vesicalis inf.], vesico-prostatic : vesicalis ima,—Haller), derived usually from the anterior division of the internal iliac, is directed downwards to the lower part of the bladder, where it divides into branches which are distributed to the base of the bladder, to the side of the prostate, and to the vesiculæ seminales. One offset, to be presently described, descends upon the rectum.

The branches upon the prostate communicate more or less freely upon that gland with the corresponding vessels of the opposite side, and, according to Haller, with the perineal arteries likewise.

*Middle hæmorrhoidal* artery<sup>13</sup> [a. hæmorrhoidalis media]. The branch supplied by the inferior vesical artery to the rectum is the middle hæmorrhoidal. It anastomoses with the branches of the other hæmorrhoidal arteries.

Besides the superior and inferior vesical arteries, other smaller



branches will be found to reach the bladder, and usually one slender vessel which is distributed particularly to the under surface of the vesiculæ seminales.

#### UTERINE ARTERY.

The *uterine* artery [a. uterina], is directed downwards from the anterior division of the internal iliac artery towards the neck of the uterus. Insinuating itself between the layers of the broad ligament, it passes upwards at the side of the uterus, pursuing an exceedingly tortuous course, and sends off numerous branches, which enter the substance of that organ.

This artery also supplies small branches to the bladder and the ureter; and near its termination, communicates with an offset directed inwards from the ovarian artery.

#### VAGINAL ARTERY.

The vagina principally derives its arteries from a branch which is analogous to the inferior vesical in the male. The *vaginal* artery [a. vaginalis] descends and ramifies upon the vagina, at the same time sending some offsets to the lower part of the bladder over its neck, and others to the contiguous part of the rectum.

#### OBTURATOR ARTERY.

The *obturator* artery<sup>17</sup> [a. obturatoria], when derived from the internal iliac, usually arises from the anterior division of that vessel, but not unfrequently from its posterior division. The artery is directed forwards through the pelvis to reach the groove on the under surface of the horizontal portion of the pubes, at the upper part of the thyroid foramen. Beneath this bone it passes out of the pelvis, and immediately divides into its terminal branches. In its course through the pelvis the artery is placed between the pelvic fascia and the peritoneum, a little below the obturator nerve. Beneath the pubes it lies with the nerve in an oblique canal, formed partly by the groove in the bone, and partly by fibrous tissue.

*Branches.*—Whilst within the pelvis, besides others of smaller size, the obturator artery often supplies a branch to the iliac fossa and muscle, and one which runs backwards upon the urinary bladder.

As it is about to enter the canal by which it escapes from the pelvis, it usually gives off one or more small anastomotic vessels, which ramify on the back of the pubes, and communicate behind that bone and behind the attachments of the abdominal muscles to its horizontal ramus, with small offsets from the epigastric artery. These anastomosing branches lie to the inner side of the femoral ring.

Having passed out of the pelvis through the canal beneath the horizontal ramus of the pubes, the obturator artery divides immediately into an external and an internal branch, which are deeply placed among the muscles at the upper part of the front of the thigh.

The *internal* branch curves inwards beneath the external obturator muscle, close to the inner margin of the thyroid foramen, and furnishes branches to the obturator muscles, the gracilis, and the adductor muscles.

The *external* branch has a similar arrangement near the outer margin of the thyroid foramen, descends as far as the tuberosity of the ischium, and supplies the obturator muscles and the upper ends of the long muscles which are attached to the tuberosity. This branch usually sends off a small artery, which enters the



hip-joint through the cotyloid notch, and ramifies along the round ligament as far as the head of the femur.

The two foregoing branches of the obturator artery communicate with each other near the lower margin of the obturator ligament, and anastomose with branches of the internal circumflex artery. Besides this, the external branch communicates with offsets from the sciatic artery near the tuberosity of the ischium.

#### VARIOUS CONDITIONS OF THE OBTURATOR ARTERY.

*Its origin.*—The anastomosis which exists between the obturator artery (when that vessel is derived from the internal iliac) and the epigastric, by means of those small branches of each which ramify behind the pubes, serves to afford some explanation of one of the most striking instances of variety of origin met with in the arterial system, viz., the transfer of the origin of the obturator from the internal iliac to the epigastric artery. Or at least, it may be said that the various modes in which the connexion between the two arteries is established in different cases, demonstrate the easy steps by which the obturator may be said to pass from one place of origin to the other. The anastomosis referred to is itself, in fact, the first stage in a series of varieties which have been observed connecting the ordinary mode of origin of the obturator (from the internal iliac), with that in which it arises from the epigastric. In the next stage, illustrated in another case, one of the anastomotic branches is a little enlarged in size, and forms a tolerably direct communication between the two vessels; then the anastomotic branch from the epigastric enlarges still more, whilst the posterior or usual obturator branch is proportionably diminished, in which case the obturator artery may be said to have two equal roots; a further diminution of the posterior branch, and a corresponding increase of that from the epigastric, conducts us to the final step, viz., the reduction of the former to the size of a small anastomosing branch, and the concurrent enlargement of the latter, which now becomes the only root or origin of the obturator artery. In this last-mentioned case, therefore, the obturator may be said to arise from the epigastric artery, and to receive a small anastomosing branch from the internal iliac, an arrangement the converse of that described at the commencement of these observations.

The relative frequency with which these various conditions of the obturator artery are met with, in a large number (361) of cases examined, may be thus shortly stated:—

In 2 cases out of 3, the obturator artery arose from the internal iliac.

In one case in 3 $\frac{1}{2}$ , from the epigastric.

In a very small number of cases (about 1 in 72), (by two roots) from both the above-named vessels.

And in about the same proportion, from the external iliac artery.

[Cloquet presents the following table as the result of an examination of 250 cases:—

Normal origin of the obturator artery from the internal iliac	-	160
From the epigastric artery on both sides	- - -	56
Do. do. on one side only	- - -	28
Do. femoral artery	- - -	6*

Sometimes the obturator artery arises from the epigastric on both sides of the same body, but, in the majority of instances, this mode of origin of the vessel is met with on one side only.†

When the obturator artery arises from the epigastric it turns backwards into the pelvis to reach the canal at the upper part of the thyroid foramen; and in this course it is necessarily close to the femoral ring—an opening at the inner side of the external iliac vein, through which hernial protrusions descend from the abdomen into the thigh. The artery is usually directed backwards close to the iliac vein, and therefore lies to the outer side of the femoral ring; but it occasionally crosses behind the ring, and, in some cases, curves to its inner side. The position of the vessel in such cases, and the practical inferences to be deduced from it,

\* [Traité d'Anatomie Descriptive. Paris 1836.

† This does not agree with the table just presented as the experience of Cloquet.]



will be again referred to in the anatomical history of the parts concerned in femoral hernia.

## PUDIC ARTERY.

The *pudic* or *internal pudic artery* (*pudica interna*; *pudica communis*,—Winslow; *pudenda* (*simpliciter*),—Haller), a branch of considerable size (smaller in the female than in the male), is distributed to the external generative organs. The following description of this artery has reference to its arrangement in the male;—its distribution in the female will be noticed separately.

The pudic artery arises from the anterior division of the internal iliac, sometimes by a trunk common to it and the sciatic artery. At first it inclines downwards and outwards to reach the great sacro-sciatic foramen, through which it escapes from the pelvis with the sciatic artery. Soon, however, it re-enters that cavity through the small sciatic foramen, turning round the spine of the ischium, which separates these two foramina one from the other. In this way the artery reaches the inner side of the tuber of the ischium, from which point it runs forwards and upwards along the rami of the ischium and pubes, (the pubic arch,) and divides into its two ultimate branches.

In this long course, it will be noticed, that the artery describes a large curve along the lower part of the pelvis, the concavity of which is directed upwards; whence, doubtless, the name once applied to it, *pudenda circumflexa*.

In the first part of its course, whilst within the pelvis, the pudic artery lies to the outer side of the rectum, and in front of the pyriformis muscle and the sacral nerves. The very short part of the vessel which is outside the pelvis, is immediately in contact with the spine of the ischium near its point, close to the attachment of the small sacro-sciatic ligament, and is deeply placed beneath the great gluteal muscle. After re-entering the pelvic cavity, the pudic artery lies to the inner side of the internal obturator muscle, lodged with its nerve in a fibrous canal formed in the obturator fascia. Here it lies along the outer side of the ischio-rectal fossa, and is in some degree protected by the falciform process of the great sacro-sciatic ligament.

Distant at first from the lower margin of the tuberosity of the ischium an inch or an inch and a half, and very deeply placed, the artery in curving forwards towards the perinæum, gains the inner margin of the ramus of the ischium, and at the same time gradually approaches nearer to the surface. Then, piercing the posterior layer of the deep perinæal fascia, it runs along the inner margin of the ramus of the pubes and close to the crus penis towards the pubic arch, at the same time converging towards its fellow of the opposite side. Finally, after perforating the superficial layer of the deep perinæal fascia, the pudic artery divides into its two ultimate branches, viz., the dorsal artery of the penis, and the artery of the corpus cavernosum.

The artery is accompanied by the pudic vein and internal pudic nerve.

*Peculiarities of the pudic artery.*—Changes in its place of origin have already been noticed. The artery itself is sometimes small, or defective in one or two,



or but rarely three of its usual branches. In these cases, its deficiencies are supplied by a supplemental vessel which has been elsewhere named the "*accessory pudic*." The defect most frequently met with is that in which the pudic ends as the artery of the bulb, whilst the artery of the corpus cavernosum and the dorsal branch of the penis are derived from the accessory pudic. But the three arteries of the penis may be supplied by the accessory pudic: the pudic itself ending as the superficial perinæal. In one case, a single accessory pudic supplied both "*cavernous*" arteries, whilst the pudic of the right side gave both dorsal arteries. And, on the other hand, cases have occurred in which only a single branch was furnished by the accessory artery, either to take the place of an ordinary branch altogether wanting, or to aid one of the branches which happened to be diminutive in size.

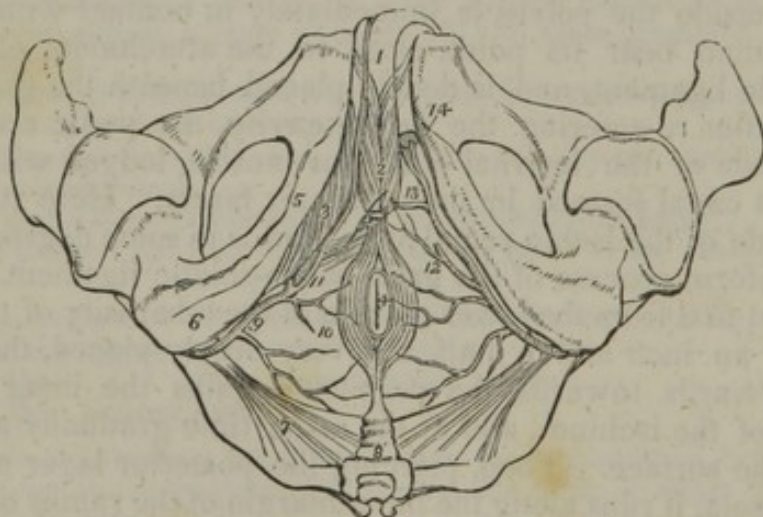
The *accessory pudic*, the occasional artery above alluded to, generally arises from the pudic itself, before the passage of that vessel from the sacro-sciatic foramen, and proceeds forwards near the lower part of the bladder. "In passing by the prostate and urethra—and it is here that the exact situation of this artery is of serious concern to the practical surgeon—the accessory pudic lies on the upper part of the gland, or it may be, for a short space, likewise on the posterior margin; and then proceeding forward above the membranous part of the urethra, it reaches the perinæum and divides into the terminal branches." In one case only it was seen to approach the side of the prostate.

The accessory pudic sometimes arises with the other branches from the internal iliac; and a vessel having a similar distribution may spring from the external iliac, through an irregular obturator, or through the epigastric; in the two last-named cases, it descends directly behind the body of the pubes.

#### BRANCHES OF THE PUDIC ARTERY.

Before escaping from the pelvis, the pudic artery occasionally gives small and irregular branches to the muscles and to the sacral nerves; and, besides its two terminal branches, it furnishes several named branches in the perinæum.

[Fig. 251.



The arteries of the perinæum; on the right side the superficial arteries are seen, and on the left the deep. 1. The penis, consisting of corpus spongiosum and corpus cavernosum. The crus penis on the left side is cut through. 2. The acceleratores urinæ muscles, enclosing the bulbous portion of the corpus spongiosum. 3. The erector penis, spread out upon the crus penis of the right side. 4. The anus, surrounded by the sphincter ani muscle. 5. The ramus of the ischium and os pubis. 6. The tuberosity of the ischium. 7. The lesser sacro-ischiatic ligament, attached by its small extremity to the spine of the ischium. 8. The coccyx. 9. The internal pudic artery, crossing the spine of the ischium, and entering the perinæum. 10. External hæmorrhoidal branches. 11. The superficialis perinæi artery, giving off a small branch, transversalis perinæi, upon the transversus perinæi muscle. 12. The same artery on the left side cut off. 13. The artery of the bulb. 14. The two terminal branches of the internal pudic artery; one is seen entering the divided extremity of the crus penis, the artery of the corpus cavernosum; the other, the dorsalis penis, ascends upon the dorsum of the organ.—W.]



The *inferior or external hæmorrhoidal* arteries, [a. hæmorrhoidalis inf.] fig. 251,<sup>10</sup> two or three in number, incline inwards from the pudic artery, as it crosses above the tuber ischii. These small vessels run across the ischio-rectal fossa, through the fat in that fossa, and are distributed to the sphincter and levator ani muscles, and to the parts about the anus.

The *superficial perinæal* artery, (fig. 251,<sup>11</sup>) [a. perinæa superficialis,] is a long, slender, but regular vessel, which supplies the scrotum and upper part of the perinæum. Given from the pudic artery in front of the preceding vessels, it turns upwards with the rami of the ischium and pubes. The perinæal artery crosses the transverse muscle of the perinæum, and runs forwards under cover of the superficial fascia, and between the erector penis and accelerator urinæ muscles, supplying both. In this course the artery gradually becomes superficial as it ascends, and is finally distributed to the skin of the scrotum and the dartos. It not unfrequently gives off the following branch.

The *transverse perinæal* artery, [a. transversa perinæa,] arises either from the pudic artery, or from the preceding branch, near the transversus perinæi muscle. This small vessel perforates the deep perinæal fascia near its base, and, as the name *transverse perinæal* implies, lies across the perinæum, and terminates in small branches which are distributed to the transverse muscle, and to the parts between the anus and the bulb of the urethra. It is a very small artery.

The *artery of the bulb*,<sup>12</sup> [a. bulbosa,] is, surgically considered, an important vessel. It is very short; arising from the pudic between the layers of the triangular ligament, and, passing transversely inwards, this artery reaches the bulb a little in front of its end. Having entered the bulb, it ramifies in the erectile tissue. It gives a branch to Cowper's gland.

*Peculiarities of the artery of the bulb.*—From the connexion of this vessel with the operation of lithotomy, its various conditions require a special notice. It is sometimes small, sometimes wanting on one side, and occasionally, it is double.

But a more important deviation from the common condition of the artery of the bulb, is one sometimes met with, in which the vessel, arising earlier than usual, crosses the perinæum further back than in the ordinary arrangement, and reaches the bulb from behind. In such a case there would be considerable risk of dividing the artery in performing the lateral operation for stone.

On the contrary, when this small vessel arises from an accessory pudic artery, it lies higher or more forward than usual, and out of danger in case of operation.

The *artery of the corpus cavernosum*,<sup>14</sup> ([a. cavernosa s.] profunda penis,) one of the terminal branches of the internal pudic, runs a short distance between the crus penis and the bone, and then, continuing forwards, penetrates the crus, and ramifies in the corpus cavernosum.

The *dorsal artery of the penis*, [a. dorsalis penis,] runs between the crus and the pubic symphysis, and, having pierced the suspensory ligament, continues along the dorsum of the penis immediately beneath the skin, and parallel with the dorsal vein, as well as with the corresponding artery of the opposite side. It supplies the integument of the penis, and the fibrous sheath of the corpus cavernosum, anastomosing with its deep arteries. Near the corona glandis, each dorsal artery divides into branches, which supply the glans and the prepuce.

The *dorsal artery of the penis* has been observed to arise from the deep femoral artery, and to pass obliquely upwards and inwards to reach the root of the penis. Tiedemann gives a drawing of this variety.

The *pudic artery in the female*.—In the female this vessel is much smaller than in the male. Its course is similar, and it supplies the following branches:

The *superficial perinæal* branch is distributed to the labia pudendi; the *artery of the bulb* supplies the mass of erectile tissue above and at the sides of the entrance of the vagina, named the bulb of the vagina; whilst the two terminal branches, analogous to the artery of the corpus cavernosum and to the dorsal artery of the penis, are distributed to the clitoris, and are named its *profunda* and *dorsal* arteries.

The arteries of the clitoris were found in one case to be derived from the accessory pudic artery, which took its origin from the epigastric artery.



## THE SCIATIC ARTERY.

The *sciatic or ischiatic artery*, fig. 250,<sup>14</sup> [a. ischiadica], the largest branch of the internal iliac artery, excepting the gluteal, is distributed to the muscles on the back of the pelvis. Continuing downwards from the anterior division of the internal iliac artery, it is placed for some distance upon the pelvic surface of the pyriformis muscle and the sacral plexus of nerves, and soon turning backwards beneath the border of that muscle, passes between it and the superior gemellus, and thus escapes from the pelvis, with the great sciatic nerve and the pudic artery, at the lower part of the great sciatic foramen. When on the outside of the pelvis, this artery lies in the interval between the tuber of the ischium and the great trochanter, covered by the gluteus maximus. The sciatic artery gives off several branches to the external rotator muscles of the thigh, on which it lies, and to the great gluteus, which conceals it. Two only of its branches have received special names: viz.,

One, an internal branch, named *coccygeal*, inclines inwards, and piercing the great sacro-sciatic ligament, reaches the posterior surface of the coccyx, and ramifies in the fat and skin about that bone.

The other named branch (*comes nervi ischiadici*) runs downwards, accompanying the sciatic nerve, along which it sends a slender vessel.

Some of the branches of this artery are distributed to the capsule of the hip-joint, whilst others, after supplying the contiguous muscle, anastomose with the gluteal, the internal circumflex, and the superior perforating arteries.

## GLUTEAL ARTERY.

The *gluteal artery*, fig. 250,<sup>15</sup> [a. glutæa] (iliaca posterior,—Haller), the largest branch of the internal iliac, is distributed to the muscles on the outside of the pelvis. It inclines downwards towards the upper border of the great sacro-sciatic foramen, beneath which it turns, and escapes from the cavity of the pelvis in the interval between the contiguous borders of the middle gluteal and pyriform muscles. Whilst within the pelvis, it gives off a few small branches to the muscles; as it turns out of that cavity it sends one larger offset (*nutritia magna*,—Haller), which enters the substance of the ilium. On reaching the outer surface of the bone, the gluteal artery immediately divides into a superficial and a deep branch. The first or *superficial* branch, running between the gluteus maximus and medius, sends off in its course many smaller branches, some of which (after piercing the tendinous origin of the great gluteal muscle) approach the side of the sacrum, anastomosing with the posterior branches of the sacral arteries, and supplying the integuments there; whilst others of considerable size pass outwards between the gluteal muscles, and supply them freely. The second or *deep* branch, situated as its name implies deeply between the gluteus medius and minimus, runs in an arched direction forwards, and divides into two other branches. One of these (the *superior* branch) continuing the course of the vessel from which it arises, runs along the upper border of the gluteus minimus beneath the middle gluteal muscle and the tensor of the fascia lata, towards the anterior spine of the ilium, anastomosing with the circumflex iliac and with the ascending branches of the external circumflex arteries, after having freely supplied the muscles between which it passes. The second or *inferior* branch descends



towards the great trochanter, supplies the gluteal muscles, and anastomoses with the external circumflex and the sciatic arteries.

#### ILIO-LUMBAR ARTERY.

The *ilio-lumbar artery*<sup>16</sup> (*ilio-lumbalis*,—Haller), resembles in a great measure the lumbar arteries. It passes outwards beneath the psoas muscle and external iliac vessels, to reach the margin of the iliac fossa, where it divides into two principal branches. One of these, the *lumbar* branch, passes upwards, ramifying in the psoas and quadratus muscles, communicating with the last lumbar artery; it also furnishes small vessels which enter the intervertebral foramina, and supply the parts lodged in the vertebral canal. The other branch or *iliac* portion of the artery turns downwards and outwards, either in the substance of the iliacus muscle, or between it and the surface of the ilium. Some of its branches reach the crest and spine of that bone, where they anastomose with the circumflex iliac artery, and may be traced forwards through the abdominal muscles, which they supply, and in which they communicate with the external branches of the epigastric artery.

The ilio-lumbar artery, as already mentioned, sometimes arises from the internal iliac, above the division of that trunk. It has also been found to spring from the common iliac, but this latter peculiarity is rare. The iliac and lumbar portions of the ilio-lumbar artery sometimes arise separately from the parent trunk.

When the lowest of the lumbar arteries is wanting, the ilio-lumbar is increased in size, and, with a small offset of the middle sacral artery, supplies its place.

#### LATERAL SACRAL ARTERIES.

The *lateral sacral arteries*<sup>18</sup>. [*a. sacrales laterales*], which are usually two in number on each side, occasionally but one, arise close together from the posterior division of the internal iliac artery. One of these arteries is distributed along the upper part, and the other along the lower part of the sacrum in the following manner.

Each artery passes downwards, at the same time inclining somewhat inwards in front of the pyriform muscle and sacral nerves, to reach the inner side of the anterior sacral foramina. Continuing to descend, the lower one approaches towards the middle line, and anastomoses with the middle sacral artery. Branches from these arteries ramify in front of the sacrum, and supply small offsets to the pyriform muscle and sacral nerves.

Besides these branches, the lateral sacral arteries give off a series of *dorsal* branches, which enter the anterior sacral foramina. Each of these, after having furnished (within the foramen) a spinal branch, which ramifies on the bones and membranes in the interior of the sacral canal, escapes by the corresponding posterior sacral foramen, and is distributed upon the dorsal surface of the sacrum.

#### EXTERNAL ILIAC ARTERY.

The vessel which supplies the lower extremity forms a continuous trunk from the point of division of the common iliac artery down to the lower border of the popliteus muscle, where it divides into the anterior and posterior tibial arteries; but though thus continued as a single trunk, different parts of the vessel have received different names, taken from the anatomical regions through which they pass. Whilst



within the pelvis, it is named iliac; in the upper two-thirds of the thigh, femoral; and thence to its termination, popliteal. These divisions, however, are artificial, and are intended merely to facilitate reference to the vessel in different situations.

The *external iliac artery* [a. iliaca externa], fig. 236, s; 250,<sup>3</sup> larger, except in the foetus, than the internal iliac artery, is placed within the abdomen, and extends from the division of the common iliac to the lower border of Poupart's ligament, where the vessel entering the thigh, assumes the name femoral. Descending obliquely outwards, its course through the abdominal cavity would be marked by a line drawn from the left side of the umbilicus to a point midway between the anterior superior process of the ilium and the symphysis pubis. This line, however, would also indicate the direction of the common iliac artery, from which the external iliac is directly continued.

Placed within the abdominal cavity, the vessel is covered by the peritoneum and intestines. It lies along the outer margin of the true pelvis, resting on the psoas muscle along its inner border. The artery, however, is separated from the muscle by the fascia iliaca, to which it is bound, together with the external iliac vein, by a thin layer of membrane.

The *external iliac vein* lies at first behind the artery with an inclination to its inner side; but as both vessels approach Poupart's ligament at the fore part of the pelvis, the vein is on the same plane with the artery to its inner side, being borne forwards by the bone. At a short distance from its lower end the artery is crossed by the *circumflex iliac vein*. Lymphatic glands are found resting upon the front and inner side of the vessel, and the spermatic vessels descend for some space upon it. A branch of the genito-crural nerve crosses over it just above Poupart's ligament.

The external iliac artery supplies some small branches to the psoas muscle and to the neighbouring lymphatic glands, and two other branches of considerable size, named the epigastric and the circumflex iliac, which are distributed to the walls of the abdomen.

The usual number of the two principal branches may be increased by the separation of the circumflex iliac into two branches; or by the addition of a branch usually derived from another source, as the internal circumflex artery of the thigh, or the obturator artery.

On the contrary, the branches are now and then diminished in number by the transference of the epigastric or the circumflex iliac artery to another trunk, which is commonly the femoral.

#### SURGICAL ANATOMY OF THE EXTERNAL ILIAC ARTERY.

The external iliac artery admits of being tied in a surgical operation at any part except near its upper and lower end; the near neighbourhood of the upper end being excepted on account of the circulation through the internal iliac, and the lower end on account of the common position of the branches (epigastric and circumflex iliac). Occasional deductions from this statement occur in consequence of a branch or branches taking origin near or at the middle of the artery; and as the operator may see such a branch he will avoid placing a ligature very near it.

The incision through the muscles to reach the artery, commencing a little above the middle of Poupart's ligament, may be directed parallel with the ligament up-



wards and outwards as far as its outer end, where the incision may be with advantage curved for a short space (about an inch) upwards.

This and the other iliac arteries might be operated on by means of straight incisions in a line from the umbilicus to the middle of Poupart's ligament, or a little to the outer side of this line. But the division of the muscles on the fore part of the abdomen is liable to the objection that the peritoneum must be disturbed in front as well as behind; and, moreover, a curved incision has the advantage of giving more room laterally than one which is merely straight.

The muscles and the fascia transversalis being divided, and the peritoneum (to which the spermatic vessels adhere) being raised, the artery is found where the finger of the surgeon, introduced into the wound, begins to descend into the true pelvis, along the border of the psoas muscle.

In contact with the artery will be seen the following structures, each occupying the position already mentioned, viz., lymphatic glands, the circumflex iliac vein, and the external iliac vein.

In order to pass the ligature, it is necessary to divide a thin and sometimes resistant membrane, which binds the vessels down to the fascia iliaca.

### EPIGASTRIC ARTERY.

The *epigastric* artery (*epigastrica inferior*) fig. 236, *t*; fig. 250,<sup>4</sup> arises from the fore part of the external iliac artery, usually a few lines above Poupart's ligament. At first the artery inclines downwards, so as to get on a level with the ligament, and then changing its direction, passes obliquely upwards and inwards between the fascia transversalis and the peritoneum, to reach the rectus muscle of the abdomen. It then ascends almost vertically behind that muscle (being placed between it and its sheath, where this latter exists). Having given off lateral muscular branches, the epigastric artery terminates above the umbilicus in several offsets, which ramify in the substance of the muscle, and anastomose with the terminal branches

[Fig. 252.]

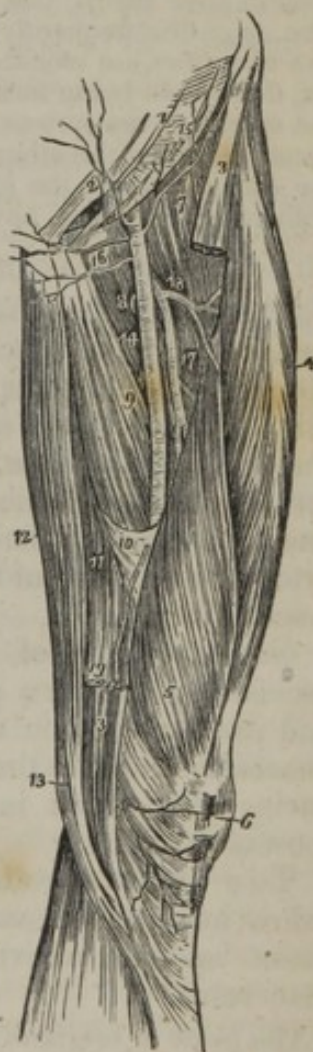

Fig. 252. A view of the anterior and inner aspect of the thigh, showing the course and branches of the femoral artery. 1. The lower part of the aponeurosis of the external oblique muscle; its inferior margin is Poupart's ligament. 2. The external abdominal ring. 3, 3. The upper and lower part of the sartorius muscle; its middle portion having been removed. 4. The rectus. 5. The vastus internus. 6. The patella. 7. The iliacus and psoas; the latter being nearest the artery. 8. The pectineus. 9. The adductor longus. 10. The tendinous canal for the femoral artery formed by the adductor magnus and vastus internus muscle. 11. The adductor magnus. 12. The gracilis. 13. The tendon of the semi-tendinosus. 14. The femoral artery. 15. The superficial circumflexa ilii artery taking its course along the line of Poupart's ligament, to the crest of the ilium. 16. The superficial epigastric artery. 17. The profunda artery, giving off 18, its external circumflex branch; and lower down the three perforantes. A small bend of the internal circumflex artery (8) is seen behind the inner margin of the femoral, just below the deep external pudic artery. 19. The anastomotica magna, descending to the knee, upon which it ramifies (6).—W.]

of the internal mammary and inferior intercostal arteries; some of its branches communicate also with offsets from the lumbar arteries.



The epigastric artery is accompanied by two veins, which unite into a single trunk before ending in the external iliac vein.

In its course upwards from Poupart's ligament to the rectus muscle, the artery crosses close to the inner side of the internal abdominal ring; and in this situation the vas deferens, escaping from the ring, turns behind the artery, in descending into the pelvis.

The *branches* of the epigastric artery are small, but numerous.

The *cremasteric* artery, a slender branch, accompanies the spermatic cord, and, after supplying the cremaster muscle and other coverings of the cord, anastomoses with the spermatic artery.

Several *muscular* branches arise from each side of the epigastric artery, ramify in the rectus muscle, and communicate with the branches of the lumbar and circumflex iliac arteries; whilst others (*superficial* branches) perforate the abdominal muscles, and, when beneath the skin, join with branches of the superficial epigastric artery.

The epigastric artery also furnishes a small *pubic* branch, which ramifies behind the pubes, and communicates by means of a descending branch or branches with a similar offset from the obturator artery, as already described in treating of the branches of that vessel.

*Peculiarities of the epigastric artery.*—This artery occasionally arises an inch and a half, or even two inches and a half, above Poupart's ligament, and it has been seen to arise below that ligament from the femoral, or from the deep femoral. The epigastric frequently furnishes the obturator artery; and on the other hand two examples are recorded in which the epigastric artery arose from the obturator, that vessel being furnished by the internal iliac artery.\* In a single instance, the epigastric artery was represented by two branches, one arising from the external iliac, and the other from the internal iliac artery.† Some combinations of the epigastric with the internal circumflex, or with the circumflex iliac, or with both of these vessels, have been noticed.

#### CIRCUMFLEX ILIAC ARTERY.

The *circumflex iliac* artery [circumflexa ilii], fig. 236, v; fig. 250,<sup>s</sup> smaller than the preceding vessel, arises from the outer side of the iliac artery near Poupart's ligament, and is directed outwards behind that structure to the anterior superior spine of the ilium. Following the crista of the bone, the artery gives branches to the iliacus muscle, furnishes others, which are distributed to the abdominal muscles, and anastomoses with the ilio-lumbar artery. In its course outwards this artery lies in front of the transversalis fascia, at its junction with the fascia iliaca.

Near the crest of the ilium, this artery gives off a branch which ascends on the fore part of the abdomen between the transversalis and internal oblique muscles; and having supplied those muscles, it anastomoses with the lumbar and epigastric arteries. This branch varies very much in size, and is occasionally represented by small muscular offsets.

Two veins accompany the circumflex iliac artery; these unite below into a single vessel, which crosses over the external iliac artery about an inch above Poupart's ligament, and enters the external iliac vein.

The place of *origin* of the circumflex iliac artery sometimes deviates from its ordinary position,—the artery arising at a distance not exceeding an inch above

\* Monro, "Morbid Anatomy of the Human Gullet," &c., p. 427. A. K. Hesselbach "Die sicherste Art des Bruchschnittes," &c.

† Lauth, in "Velpeau's Médecine Opératoire," t. ii. p. 452.



Poupart's ligament. Deviations in the opposite direction are more rarely met with; it has in a few cases been observed to arise below the ligament, and therefore from the femoral artery. The circumflex iliac artery is sometimes represented by two separate branches from the external iliac.

#### FEMORAL ARTERY.

The *femoral artery* (*femoralis s. cruralis*), fig. 252,<sup>14</sup> is that portion of the artery of the lower limb which lies along the upper two-thirds of the thigh,—its limits being marked, above, by Poupart's ligament, and below, by the opening in the great adductor muscle, after passing through which the artery assumes the name popliteal.

A general idea of the direction of the femoral artery over the fore part and inner side of the thigh would be obtained by a line reaching from a point midway between the anterior superior spine of the ilium and the symphysis of the pubes to the inner side of the patella. But the situation of the vessel is best ascertained by observation of the surface at the upper part of the thigh, inasmuch as it lies along the middle of a depression formed between the muscles covering the femur on the outer side, and the adductor muscles on the inner side of the limb. In this situation the beating of the artery may be felt, and the circulation through the vessel be most easily controlled by pressure.

Owing to the natural curvature of the femur, and to the passage of the femoral artery from the front towards the back of the thigh, the relative position of the vessel and the bone varies considerably at different points. Thus, at the groin, the artery, after having passed over the margin of the pelvis, is placed in front of the head of the femur; at its lower end, the vessel lies close to the inner side of the bone; whilst in the intervening space, in consequence of the projection of the neck and shaft of the femur outwards, while the artery holds a straight course, the two are separated by a considerable interval.

Becoming deeper as it descends, the femoral artery is at first comparatively near the surface, being covered in the upper third of the thigh by the common integuments and the fascia lata, in addition to the sheath, which contains both the artery and the vein. In this situation, a triangular space may, on dissection, be recognised, upon the fore part of the thigh, immediately below the fold of the groin. The apex of this triangle is directed downwards, its sides are formed respectively by the sartorius and the long adductor muscles, and its base by the lower margin of the abdominal wall, which is represented by Poupart's ligament. This triangular interval is divided into two nearly equal parts by the femoral vessels, which extend from the middle of its base to its apex.

Below the part just referred to, the femoral artery is deeply placed, being covered by the sartorius muscle, which, after crossing obliquely from the outer to the inner side of the thigh, descends vertically and covers the artery to its end. The vessel is likewise covered, beneath the muscle, by a dense band of fibrous structure, which stretches across from the tendons of the long and great adductors to the vastus internus muscle.

The artery rests successively against the following parts. First, upon the psoas muscle, by which it is separated from the margin of



the pelvis, and from the capsule of the hip-joint; next, upon, or rather in front of, the pectineus muscle, the deep femoral artery and vein being interposed; afterwards, upon the long adductor muscle; and lastly, upon the tendon of the great adductor, the femoral vein being placed between the tendon and the artery.

At the lower part of its course, the femoral artery has immediately on its outer side the vastus internus muscle, which intervenes between it and the inner side of the femur.

The *femoral vein* is very close to the artery, both being enclosed in the same sheath, separated from each other only by a thin partition. At the groin, the vein lies on the same plane as the artery to its inner side; but gradually inclining backwards, it afterwards sinks behind that vessel, and even gets somewhat to its outer side. The deep femoral vein, near its termination, crosses behind the femoral artery, and the long saphenous vein, as it ascends on the fore part of the limb, lies to its inner side; but it not unfrequently happens that a superficial vein of considerable size ascends for some space directly over the artery.

At the groin the anterior crural nerve lies a little to the outer side of the femoral artery (about a quarter of an inch), separated from the vessel by some fibres of the psoas muscle and by fibrous structure. Lower down in the thigh, the long saphenous nerve accompanies the artery until this vessel perforates the adductor magnus. There are likewise small cutaneous nerves which cross the artery.

#### PECULIARITIES OF THE FEMORAL ARTERY.

There does not appear to be any well-authenticated example of the femoral artery furnishing the arteries of the leg; and in this respect the vessels of the lower limb contrast strongly with those of the arm.\*

Four instances have been recorded of division of the femoral artery, below the origin of the profunda, into two vessels, which subsequently reunited near the opening of the adductor magnus so as to form a single popliteal artery.† In all these cases, the arrangement of the vessels appears to have been similar. To one of them (that first observed) special interest is attached, inasmuch as it was met with in a patient operated upon for popliteal aneurism.

#### BRANCHES OF THE FEMORAL ARTERY.

The femoral artery gives off the following branches. Some, small and superficial, which are distributed to the integument and glands of the groin, or ramify on the lower part of the abdomen, viz., the external pudic (superior and inferior), the superficial epigastric, and the superficial circumflex iliac; the great nutrient artery of the muscles of the thigh, named the deep femoral; several small muscular branches; and lastly, the anastomotic artery, which descends on the inner side of the knee-joint.

Besides the foregoing ordinary branches, the femoral artery sometimes gives origin to some offshoots, usually derived from other sources; as, for example, the circumflex arteries (branches of the deep femoral), or, but more rarely, the epi-

\* For an examination of the history of four cases, which have been regarded as examples of the early division of the femoral artery, see "The Arteries," &c. by R. Quain, p. 514.

† This case was treated and recorded by Sir C. Bell: "The London Medical and Physical Journal," vol. lvi. p. 134. London, 1826.



gastric, the circumflex iliac, or the obturator arteries. These will be noticed in the account of the individual branches.

The *external pudic arteries*, [a. pudendæ externæ] fig. 252,<sup>16</sup> arise either separately or by a common trunk from the inner side of the femoral artery. The *superior*, the more superficial branch (superior pudenda externa,—Haller), courses upwards and inwards to the spine of the pubes, crosses the external abdominal ring, passing, in the male, over the spermatic cord, and is distributed to the integuments on the lower part of the abdomen, and on the external organs of generation. The *inferior* branch (inferior pudenda externa), more deeply seated, extends inwards, resting on the pectineus muscle, and covered by the fascia lata, which it pierces on reaching the ramus of the pubes, and is distributed to the scrotum in the male, or to the labium in the female, its branches inosculating with those of the superficial perineal artery.

The *superficial epigastric artery*,<sup>2</sup> [a. epigastrica superficialis s. abdominalis subcutanea,—Halleri] arises from the femoral artery, about half an inch below Poupart's ligament, passes forwards through the saphenous opening in the fascia lata; after which it changes its direction, and runs upwards on the abdomen, in the superficial fascia covering the external oblique muscle. Its branches ramify in the superficial fascia and integument on the lower part of the abdomen; and some, ascending nearly as high as the umbilicus, anastomose with those of the epigastric and internal mammary arteries.

The *superficial circumflex iliac artery*,<sup>15</sup> [a. circumflexa ilii sup.] runs outwards in the direction of Poupart's ligament, towards the spine of the ilium, across the psoas and iliacus muscles; to both of these it gives small branches, as also some others which pierce the fascia lata, and are distributed to the integument.

All the preceding arteries give small branches to the lymphatic glands in the groin.

#### THE DEEP FEMORAL ARTERY.

The *deep femoral artery* (a. profunda femoris), fig. 252,<sup>17</sup> is the principal nutritious vessel of the thigh; its branches being mainly distributed to that part of the lower limb, whereas the femoral artery supplies the leg and foot. It is a vessel of considerable calibre, being nearly equal in size to the continuation of the femoral after the origin of this great branch.\* It usually arises from the outer and back part of the femoral artery, between an inch and two inches below Poupart's ligament. The artery at first inclines outwards in front of the iliacus muscle, but soon changes its course, running downwards and backwards behind the femoral artery. Opposite the junction of the upper with the middle third of the femur, the profunda artery passes behind the long adductor muscle, between it and the short and great adductors; and then inclining outwards towards the linea aspera of the femur, soon divides into its terminal branches, which pass backwards through the great adductor muscle, and ramify in the muscles at the back of the thigh.

The artery lies successively in front of the iliacus and pectineus muscles, and then on the adductor brevis and adductor magnus muscles. It is placed behind the femoral artery, the deep femoral and femoral veins and the long adductor muscle being interposed between the two arteries.

The *origin* of the deep femoral artery sometimes deviates from its usual position on the parent trunk, being occasionally given off from the inner side, and, but more rarely, from the back part of that vessel.

\* The artery of the lower limb, after emerging from the abdominal cavity, was described by Murray as the *common femoral*, and was regarded by him as dividing into two parts, which he named respectively, the *superficial*, and the *deep* femoral arteries. These terms are often conveniently used by surgical writers for easy reference to different parts of the vessel.



The *height* at which this artery arises from the femoral is subject to very great variation. In more than three-fourths of a large number of cases it was found to arise from the femoral at a distance of from one to two inches below the lower border of Poupart's ligament; in a few of the cases, the distance measured less than one inch; much more rarely, the profunda arose opposite to the ligament; and in a single instance above that structure, and, therefore, from the external iliac artery.

On the other hand, the distance between the origin of the artery and Poupart's ligament was sometimes found to exceed two inches; and, in one instance, the artery arose as low down as four inches from the ligament, but in that case the internal and external circumflex branches did not arise from it.

In addition to a number of small unnamed offsets to the muscles, the deep femoral artery furnishes the branches now to be described.

#### BRANCHES OF THE DEEP FEMORAL ARTERY.

The *external circumflex* artery,<sup>18</sup> [circumflexa femoris interna s. posterior,] a branch of considerable size, arises from the outer side of the profunda, and, after passing outwards for a short distance beneath the sartorius and rectus muscles, and through the divisions of the anterior crural nerve, gives off branches, which may be divided into three sets, according to the directions which they take. The *first* incline *transversely* outwards, and after passing over the crureus, pierce the vastus externus, so as to get between it and the bone just below the great trochanter of the femur, and reach the back part of the thigh, where they anastomose with the internal circumflex and the perforating branches, also with the gluteal and sciatic branches. The *second* set, or *ascending* branches, are directed upwards beneath the sartorius and rectus, and afterwards under the tensor muscle of the fascia lata; here they communicate with the terminal branches of the gluteal, and with some of the external descending branches of the circumflex iliac artery. The *third*, or *descending* set of branches, incline outwards and downwards upon the extensor muscles of the leg, covered by the rectus muscle. They are usually three or four in number, some being of a considerable size; most of them are distributed to the muscles on the fore part of the thigh, but one or two can be traced as far as the knee, beneath the vastus externus muscle, where they anastomose with the superior articular branches (internal and external) of the popliteal artery, and with the anastomotie branch of the femoral artery.

*Peculiarities.*—The external circumflex branch sometimes arises (as a single trunk) from the femoral artery; or it may be represented by two branches, of which, in most cases, one proceeds from the femoral, and one from the deep femoral; both branches, however, have been seen to arise from the deep femoral, or, but much more rarely, both from the femoral artery.

The *internal circumflex* artery,<sup>8</sup> [circumflexa fem. externa s. anterior,] smaller than the preceding branch, arises from the inner and back part of the deep femoral artery, and is directed backwards to the inner side of the femur, between the pectineus and the psoas muscles, so that only a small part of it can be seen without disturbing these muscles. On reaching the tendon of the external obturator, by which the vessel is guided to the back of the thigh, it divides into two principal branches. One, ascending, is distributed partly to the adductor brevis and gracilis, and partly to the external obturator muscle, near which it anastomoses with the obturator artery; the other, or transverse branch, passes backwards above the small trochanter, and appears on the back of the limb, between the quadratus femoris and great adductor muscle, where it anastomoses with the sciatic artery and with the superior perforating branches of the deep femoral artery. Opposite the hip-joint, this transverse branch gives off an *articular* vessel, which enters the hip-joint through the notch in the acetabulum, beneath the transverse ligament, and after supplying the adipose substance in that articulation, is guided to the head of the femur by the round ligament. In some instances the articular branch is derived from the obturator artery; sometimes the joint receives a branch from both sources.

*Peculiarities.*—With few exceptions, the peculiarities met with in the internal



circumflex branch depend upon its transference to the femoral artery, and, in almost all cases, to a point above the origin of the profunda artery. Examples have also been met with in which the internal circumflex arose from the epigastric, or the circumflex iliac, or from the external iliac artery.

The *perforating* arteries (*perforantes*), so called because they reach the back of the thigh by perforating the adductor brevis and the adductor magnus muscles, are three or four in number. The *first perforating* artery passes backwards below the pectineus muscle, and through the fibres of the short and great adductor muscles; after which it immediately divides into branches, which are distributed to both adductor muscles, to the biceps, and great gluteal muscles, and communicate with the sciatic and internal circumflex arteries. The *second perforating* artery, considerably larger than the first, passes through the adductor magnus; after which it divides into ascending and descending branches, which ramify in the hamstring muscles, and communicate with the other perforating branches. A branch, named the *nutrient artery* [*nutriens*] of the femur, enters the medullary foramen of that bone. The *third perforating* artery pierces the adductor magnus, and, like the others, is distributed to the long flexor muscles at the back of the thigh, anastomosing with the other perforating arteries above, and with the termination of the profunda artery itself below.

*Termination of the deep femoral artery.*—After having given off these different branches, the deep femoral artery becomes considerably diminished in size, and passing backwards close to the linea aspera, divides into smaller branches, some of which are distributed to the short head of the biceps, the rest to the other hamstring muscles.

These ultimate branches of the deep femoral artery communicate with those of the popliteal artery and with the lower perforating arteries already described.

The perforating arteries present no peculiarities of note. The terminal branch of the deep femoral, already described, is sometimes regarded as a fourth perforating artery.

#### MUSCULAR BRANCHES OF THE FEMORAL ARTERY.

In its course along the thigh the femoral artery gives off several branches [*rami musculares*] to the contiguous muscles. They vary in number from two to seven. They supply the sartorius and the vastus internus, with other muscles, which are close to the femoral artery. Their size appears to bear an inverse proportion to that of the descending branches of the external circumflex artery.

#### ANASTOMOTIC ARTERY.

Close to its termination the femoral artery gives off a branch constant, but of small size, named the *anastomotic artery* (*anastomotica magna*), fig. 252,<sup>10</sup> which descends in the same line as the femoral artery itself. Arising from that vessel, when about to enter the popliteal space, it descends upon the tendon of the adductor magnus, accompanied by the saphenous nerve. Having given off several branches, the anastomotic artery passes down to the inner condyle of the femur, covered for a short distance by some of the fibres of the vastus internus muscle, and, finally, anastomoses with the superior internal articular artery, and with the recurrent branch of the anterior tibial artery. Of its branches, one accompanies the saphenous nerve beneath the sartorius muscle; others pass obliquely outwards through the substance of the vastus internus, and communicate with the descending muscular branches in front of the thigh. From the lower part of the vessel, a branch crosses over the femur, a little above its articular surface, supplies branches to the knee-joint, and anastomoses with the superior external articular artery.—The anastomotic artery varies not unfrequently in size, and in the point at which it arises.

#### SURGICAL ANATOMY OF THE FEMORAL ARTERY.

The femoral artery is accessible to the surgeon for the application of a ligature without serious difficulty in its entire length; but as the lower half is deeply



placed, the difficulty of reaching this part is greatest, at the same time that the depth at which the vessel lies renders it necessary to divide and disturb the surrounding structures to a greater extent than where the vessel is nearer the surface. For these reasons the upper part of the artery is to be preferred for the performance of the operation adverted to, in all cases in which other circumstances do not control the choice of the surgeon. But the upper part of the femoral artery is not equally eligible for the application of a ligature at all points, in consequence of the position of the branches—an important consideration in the surgical anatomy of this vessel.

Close to the commencement of this artery are two considerable branches (epigastric and circumflex iliac); and between one and two inches lower down the deep femoral branch ordinarily takes its rise. A ligature placed on the arterial trunk in the interval between those branches, that is to say, on the common femoral artery, is in the near neighbourhood of two disturbing causes,—two sources of danger, so near that the prospect of a favourable issue to the operation is under ordinary circumstances very small.

Moreover it has been shown amid the facts detailed above, that the origin of the deep femoral is often less than the average distance from Poupart's ligament; and that, not unfrequently, a considerable branch (one of the circumflex arteries) takes its rise from the common femoral artery. When these circumstances are considered, the operation of tying the common femoral artery, or the femoral artery within two inches of its commencement, must be regarded as very unsafe. And it may be added, that the conclusion to which the anatomical facts would lead is fully confirmed by the results of cases in which the operation has been actually performed.

It remains to determine where a ligature applied to the main artery shall be sufficiently distant from the origin of the deep femoral, below it, to be free from the disturbing influence of the circulation through that great branch. It has been shown that now and then a case occurs in which the profunda is given off at the distance of from two to three inches below Poupart's ligament—in only a single instance out of a large number of observations (431) did the space referred to amount to four inches.

From the foregoing remarks the inference to be deduced is, that the part of the femoral artery to be preferred for the operation supposed, is at the distance of between four and five inches below the lower margin of the abdominal muscles.

*Remarks on the operation.*—The position of the artery being determined, and the integument and fat divided, a vein may be met with lying on the fascia, over the course of the artery. The saphenous vein being nearer to the inner side of the limb than the line of incision, is not seen in the operation. The fascia lata, which is now to be divided, has a more opaque appearance over the vessels than over the muscles, for the colour of the latter appears through the membrane. After dividing the fascia, the edge of the sartorius muscle will, in many cases, require to be turned aside; and occasionally this muscle crosses the thigh so directly that it must be drawn considerably outwards in order to reach the artery. To the exact point at which the sheath of the vessels, and even the fascia, should be cut through, the pulsation of the artery will guide the operator. A small nerve may present itself in this part of the operation. The immediate investment of the artery should be opened to the smallest possible extent, and the knife or other instrument should be sparingly used at this stage of the operation; the object being to disturb the artery from its connexions, including its nutrient vessels (*vasa vasorum*) as little as possible, and likewise to avoid wounding any of the small muscular branches which spring from most arteries at irregular intervals. The division of an artery of the size of those last referred to at a distance from the source from which it springs is of little importance. It contracts, and soon ceases to bleed. But when it is divided close to the trunk, blood issues from it as it would if an opening equal in size to the calibre of the little branch were made in the trunk itself.

In order to avoid injuring the vein, which is separated from the artery only by a thin cellular partition, the point of the aneurism needle, which conveys the ligature, is to be kept close to the artery.

Other veins of occasional occurrence may render increased care necessary, for example, those small branches which cross the artery or course along its surface;

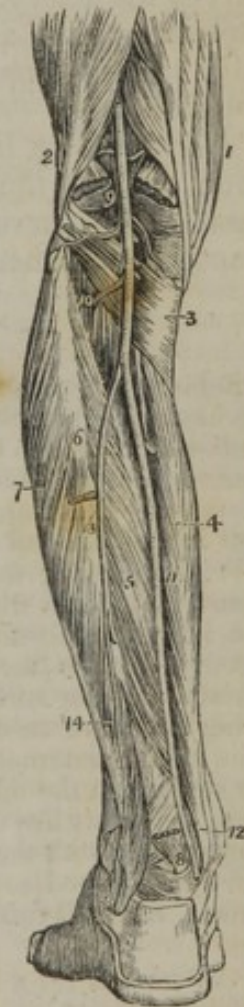

or it may be a larger vein—a division of the femoral vein when it is double, or the deep femoral vein when the ligature is applied a little higher than usual.

To reach the femoral artery in the middle of the thigh, the depth of the vessel being considerable, the incisions through the integuments must be proportionably long. As the sartorius is directly over the vessel, the operation may be performed by turning the muscle either towards the outer or the inner side of the limb; and the incision would be made, according to the plan adopted, at the inner or the outer margin of the muscle. The preferable mode appears to be, to divide the integument on or over the muscle, near its inner margin, so as to arrive directly upon the muscle and draw it outwards, after cutting freely through the investing fascia. The fibrous structure stretched over the vessels from the adductors to the vastus internus muscle being divided, the positions of the femoral vein and saphenous nerve are to be kept in view in completing the operation. In the first steps of the operation in this part of the thigh, injury to the long saphenous vein is to be guarded against.

Before concluding the observations on the femoral artery, a very small class of cases claims a word of notice. It has happened\* that the application of a ligature to a femoral artery has not been followed by the usual consequence of cessation of the pulsation in the aneurism; and the uninterrupted continuance of the circulation was found, on examination after death, to be attributable to the circumstance of the artery being double where the ligature was applied, while the two parts became reunited above the tumour. If such a case should be again met with in an operation, the surgeon, instructed by the case alluded to, and by other examples of the same arrangement of the arteries which have since been observed, might at once, under the guidance of the pulsation, or of the effect of pressure in controlling the circulation through the aneurism, divide the cellular covering of the second part of the artery, and tie it likewise.

[Fig. 253.



### POPLITEAL ARTERY.

The *popliteal artery* [a. poplitea], fig. 253,<sup>9</sup> at the back of the knee-joint, extends along the lower third of the thigh and the upper part of the leg, reaching from the opening in the great adductor to the lower border of the popliteus muscle. It is continuous above with the femoral, and divides at the lower end into the anterior and posterior tibial arteries.

This artery at first inclines from the inner side of the limb to reach the middle of the knee-joint, and

Fig. 253. Aposterior view of the leg, showing the popliteal and posterior tibial artery. 1. The tendons forming the inner hamstring. 2. The tendon of the biceps forming the outer hamstring. 3. The popliteus muscle. 4. The flexor longus digitorum. 5. The tibialis posticus. 6. The fibula; immediately below the figure is the origin of the flexor longus pollicis; the muscle has been removed in order to expose the peroneal artery. 7. The peronei muscles, longus and brevis. 8. The lower part of the flexor longus pollicis muscle with its tendon. 9. The popliteal artery giving off its articular and muscular branches; the two superior articular are seen in the upper part of the popliteal space passing above the two heads of the gastrocnemius muscle, which are cut through near their origin. The two inferior are in relation with the popliteus muscle. 10. The anterior tibial artery passing through the angular interspace between the two heads of the tibialis posticus muscle. 11. The posterior tibial artery. 12. The relative position of the tendons and artery at the inner ankle from within outwards, previously to their passing beneath the internal annular ligament. 13. The peroneal artery, dividing a little below the number, into two branches; the anterior peroneal is seen piercing the interosseous membrane. 14. The posterior peroneal.—W.]

\* Sir C. Bell's case before referred to (p. 622.)



thence continues vertically to its lower end. Lying deeply in its whole course, it is covered for some distance at its upper end by the semi-membranosus muscle; lower down, a little above the knee, it is placed in the intermuscular interval named the popliteal space, where it is covered by the fascia, and overlaid by the muscles which bound that space. The lower part of the artery is covered for a considerable distance by the gastrocnemius muscle, and at its termination by the upper margin of the soleus muscle.

At first this artery lies close to the inner side of the femur; in descending the vessel gets behind the bone, and as this is here curved forwards, while the course of the artery is straight, there is an interval between the two. The popliteal artery then rests against the posterior ligament of the knee-joint, and afterwards on the popliteus muscle.

*Vein.*—The popliteal vein lies close to the artery, behind and somewhat to its outer side. The vein is frequently double along the lower part of the artery, and, more rarely, at the upper part also. The short saphenous vein, ascending into the popliteal space over the gastrocnemius muscle, approaches the artery, as it is about to terminate in the popliteal vein.

*Nerve.*—The inner division of the sciatic nerve lies at first to the outer side of the artery, but much nearer to the surface than the vessel: the nerve afterwards crosses over the artery, and is then placed to its inner side.

#### POPLITEAL SPACE.

Behind the lower end of the femur the flexor muscles of the leg (called also the hamstring muscles) diverge to their places of attachment at each side of the limb—the biceps to the fibula, the semi-membranosus and semi-tendinosus to the inner side of the tibia. In this way there is formed an interval, which is bounded laterally by those muscles above, and by the head of the gastrocnemius below. This is the popliteal space.

Whilst passing through the popliteal space, the artery is surrounded by a quantity of fat, in which a few small lymphatic glands will be found. The fascia lata, it is to be observed, holds the muscles bounding the popliteal space so closely together that the line of separation between them is marked only by a slight depression on the surface of the membrane. By removing the fascia and the fat (which in some cases is abundant), the popliteal artery with its accompanying vein, and the internal popliteal nerve, will be brought into view; placed, as regards the surface, in the opposite order to that in which they have just been mentioned. Thus, the artery lies deepest, and midway between the sides of the limb; the vein is in contact with the artery, but superficial to it and to its outer side; whilst the nerve is removed to some distance from the vessels, lying much nearer to the surface, and still further to the outer side of the popliteal space.

#### PECULIARITIES OF THE POPLITEAL ARTERY.

Deviations from the ordinary condition of the popliteal artery are not frequently met with. The principal departure from the ordinary arrangement consists in its premature division into terminal branches. Such an early division has been found to take place most frequently opposite the flexure of the knee-joint, and not higher.

In a few instances, the popliteal artery has been seen to divide into the anterior tibial and peroneal arteries—the posterior tibial being small or absent. In a single case, the popliteal artery was found to furnish at its end the peroneal artery as well as its two usual branches, the anterior and posterior tibials.



## BRANCHES OF THE POPLITEAL ARTERY.

The popliteal artery gives off five articular branches, two above and two below the joint, and one which passes forwards into it; also some large muscular branches to the hamstring muscles, and to the gastrocnemius.

The *muscular* branches may be divided into a superior and an inferior set.

The *superior* branches, three or four in number, arise from the upper part of the popliteal artery, and are distributed to the lower ends of the flexor muscles of the leg, reaching also to the vasti muscles. They anastomose with the lower perforating arteries, with the terminal branches of the deep femoral artery, and with some of the articular arteries.

The *inferior muscular* branches, *sural* arteries, (*surales*, fig. 253,) usually two in number, and of considerable size, arise from the back of the popliteal artery, opposite the knee-joint, and enter, one the outer and the other the inner head of the gastrocnemius muscle, which they supply, as well as the fleshy part of the plantaris muscle.

Over the surface of the gastrocnemius will be found at each side, and in the middle of the limb, slender branches, which descend a considerable distance along the calf of the leg, beneath the integument. These small vessels arise separately from the popliteal artery, or from some of its branches.

The *articular* arteries.—Two of these pass off, nearly at right angles from the popliteal artery, one to each side, above the flexure of the joint, whilst two have a similar arrangement below it; hence they are named the *upper internal* and *external*, and the *lower internal* and *external*. Besides these, there is a fifth articular artery, called the *middle articular*, because it enters the middle of the back of the joint.

The *upper articular arteries*, [*a. articulares genu superiores*,] fig. 253.—That of the *inner side* turns over the femur just above the condyle; and, passing under the tendon of the great adductor and the vastus internus, divides into two branches. Of these, one, comparatively superficial, enters the substance of the vastus, which it supplies, and inosculates with the anastomotic branch of the femoral, and with the lower internal articular artery. The other branch runs close to the femur, ramifies upon it, and also on the knee-joint, and communicates with the upper external articular artery.

The *upper external* articular artery passes outwards, a little above the outer condyle of the femur, under cover of the biceps muscle, and, after perforating the intermuscular septum, divides into a superficial and a deep branch. The latter, lying close upon the femur, spreads branches upon it and the articulation, and anastomoses with the preceding vessel, with the anastomotic of the femoral, and with the lower external articular artery; the superficial branch descends through the vastus to the patella, anastomosing with other branches and assisting in the supply of the joint.

The *lower articular arteries*, [*a. articulares genu inferiores*.]—The *internal* artery passes downwards below the corresponding tuberosity of the tibia, lying between the bone and the internal lateral ligament; its branches ramify on the front and inner part of the joint, as far as the patella and its ligament. The *external* artery takes its course outwards, under cover of the outer head of the gastrocnemius in the first instance, and afterwards under the external lateral ligament of the knee, and the tendon of the biceps muscle, passing above the head of the fibula and along the border of the external semilunar cartilage. Having reached the fore part of the joint, it divides near the patella into branches, which communicate with the lower articular artery of the opposite side, and with the recurrent branch from the anterior tibial; whilst others ascend, and anastomose with the upper articular arteries.

In this manner the four articular branches form at the front and sides of the knee-joint a network of vessels.

The remaining articular artery, called, from its position, the *middle articular*, and, from its being a single vessel, *azygos*, [*a. articulationis genu media s. azygos*,] is a small branch which arises from the popliteal artery, opposite the flexure of



the joint. It pierces the posterior ligament, and supplies the crucial ligaments and the other structures, within the articulation. This small artery frequently arises from one of the other articular branches, especially from the upper and external branch.

#### POSTERIOR TIBIAL ARTERY.

The *posterior tibial artery* [a. tibialis postica] is situated along the back part of the leg, between the superficial and deep layers of muscles, being firmly bound down to the latter by the deep fascia.

This artery, fig. 253,<sup>11</sup> extends from the lower border of the popliteus muscle, where it is continuous with the popliteal artery, down to the inner border of the calcaneum, where it terminates beneath the origin of the abductor pollicis muscle, by dividing into the external and internal plantar arteries.

Placed, at its origin, at equal distances between the two sides of the limb, and opposite to the interval between the tibia and fibula, it approaches the inner side of the leg as it descends, and lies behind the tibia; and at its lower end is placed midway between the inner malleolus and the prominence of the heel. Very deeply seated at its upper part, where it is covered by the fleshy portion of the gastrocnemius and soleus muscles, it becomes comparatively superficial towards its lower part, being covered only by the integument and by two layers of fascia (the annular ligament) behind the inner malleolus. In front, the artery rests successively against the tibialis posticus, the flexor longus digitorum, and, at its lower end, directly on the tibia, and behind the ankle-joint.—The posterior tibial artery is accompanied by two veins. The posterior tibial nerve is at first on the inner side of the artery, but in the greater part of its course the nerve is close to the outer side of the vessel.

Behind the inner ankle, the tendons of the tibialis posticus and flexor longus digitorum lie between the artery and the malleolus; whilst the tendon of the flexor longus pollicis is to its outer side.

The posterior tibial artery furnishes numerous small branches; and, besides these, one large branch, named the peroneal artery, which will be presently described.

Several *muscular* branches [rami musculares] arise from this artery in its course along the leg, and are distributed principally to the deep-seated muscles in its neighbourhood, besides one or two of considerable size to the inner part of the soleus muscle.

The *nutrient artery* [nutriens tibiæ] of the tibia, the largest of this class of arteries in the body, arises from the posterior tibial artery, near its commencement, and, after giving small branches to the muscles, enters the nutrient foramen in the bone, and ramifies on the medullary membrane. This vessel not unfrequently arises from the anterior tibial artery.—A communicating branch from the peroneal artery joins the posterior tibial about two inches above the ankle-joint.

#### PECULIARITIES OF THE POSTERIOR TIBIAL ARTERY.

When the popliteal artery divides prematurely, the posterior tibial, as well as the anterior tibial, is necessarily longer than usual. In some of these cases, it has been observed that the posterior tibial artery does not give origin to the peroneal.

*Size.*—The posterior tibial artery is not unfrequently diminished in size in different degrees; this deficiency being compensated for by an enlarged peroneal artery in the leg, or by the anterior tibial artery in the foot. See the account of these arteries respectively.



The posterior tibial is sometimes absent; in which case the peroneal is enlarged, and takes its place from above the ankle downwards into the sole of the foot.

#### PERONEAL ARTERY.

The *peroneal* artery, [a. peronea] fig. 253,<sup>13</sup> lies deeply along the back part of the leg, close to the fibula: hence its names, peroneal or fibular. Arising from the posterior tibial artery, about an inch below the lower border of the popliteus muscle, it inclines at first obliquely towards the fibula, and then descends nearly perpendicularly along that bone and behind the outer ankle, to reach the side of the os calcis. In the upper part of its course, this artery is covered by the soleus muscle and the deep fascia, and afterwards by the flexor longus pollicis, which is placed over the artery as far as the outer malleolus; below this point, the vessel is covered only by the common integument and the fascia. The peroneal artery rests at first against the upper part of the tibialis posticus muscle, and afterwards in the greater part of its course on the back of the interosseous membrane, lying close under a projecting ridge of the fibula,—in a depression formed between the membrane and the bone.

Two veins accompany this artery.

*Branches.*—The upper part of the peroneal artery gives numerous muscular branches to the soleus, the tibialis posticus, the flexor longus pollicis, and the peronei muscles, the largest branches being those to the soleus. It likewise furnishes a *nutrient* artery to the fibula.

Having descended beyond the outer malleolus, the peroneal artery terminates by giving off a series of branches, which ramify on the outer surface of the os calcis. These anastomose with the external malleolar and with the tarsal arteries on the outer side of the foot; and behind the os calcis with ramifications of the posterior tibial artery.

*Anterior peroneal artery* [a. peronea ant.]—About two inches above the outer malleolus, the peroneal artery gives off its anterior branch, named anterior peroneal. This immediately pierces the interosseous membrane to reach the fore part of the leg. It then descends along the front of the fibula, covered by the peroneus tertius muscle, and dividing into branches, reaches the outer ankle, and anastomoses with the external malleolar branch of the anterior tibial artery. It supplies vessels to the ankle-joint, and ramifies on the front and outer side of the tarsus, inosculating more or less freely with the tarsal arteries.

*Communicating branch to posterior tibial artery.*—Lying close behind the tibia, about two inches from its lower end, a transverse branch will be found connecting the peroneal with the posterior tibial artery, and seeming, by its direction, to pass from the former to the latter vessel.

#### PECULIARITIES OF THE PERONEAL ARTERY.

The peroneal artery presents occasional deviations from its ordinary condition, in regard to its place of origin, its size, and the extent of its distribution.

This artery has been found to arise lower down than usual, about three inches below the popliteus muscle; and, on the contrary, it sometimes commences higher up, from the posterior tibial, or even from the popliteal artery itself.

When the popliteal artery divides prematurely, the peroneal artery is, in some cases, transferred to the anterior tibial.

Variations in its *size* constitute the most frequent peculiarities to which the peroneal artery is liable. It more frequently exceeds than falls short of the ordinary dimensions.

When larger than usual, it is often found to reinforce a small posterior tibial, either by a transverse vessel which joins the diminished artery in the lower part



of the leg; or two such reinforcing vessels may be present, one crossing close to the bone, and one over the deep muscles. But the occurrence of a second communicating branch is rare. Again, a large peroneal artery has been observed to take the place of the posterior tibial at the lower part of the leg, and thence onwards to the foot; the last-named vessel, in such cases, existing only as a short muscular branch at the upper part of the leg.

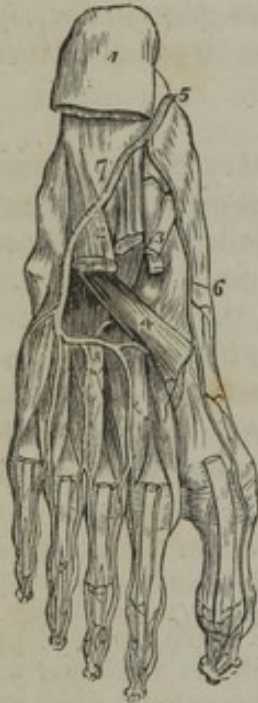The anterior division of the peroneal artery (anterior peroneal) has in some cases more than its ordinary size, and compensates for a small anterior tibial artery in the lower part of the leg or supplies the place of that artery on the dorsum of the foot.

The peroneal artery is rarely smaller than usual. When its anterior division only is wanting, a branch of the anterior tibial supplies the deficiency; but when the decrease is carried so far that the peroneal artery is expended before reaching the lower part of the leg, a branch of the posterior tibial supplies its place on the outer side of the foot.

In one singular case, recorded by Otto, the peroneal artery was wholly wanting.\*

[Fig. 254.

## PLANTAR ARTERIES.



The arteries of the sole of the foot; the first and a part of the second layer of muscles having been removed. 1. The under and posterior part of the os calcis; to which the origins of the first layer of muscles remain attached. 2. The musculus accessorius. 3. The long flexor tendons. 4. The tendon of the peroneus longus. 5. The termination of the posterior tibial artery. 6. The internal plantar. 7. The external plantar artery. 8. The plantar arch giving off four digital branches, which pass forwards on the interossei muscles. Three of these arteries are seen dividing, near the heads of the metatarsal bones, into collateral branches for adjoining toes. —W.]

*Terminal branches of the posterior tibial artery.*—When the tibial artery reaches the hollow of the calcaneum, and gets beneath the origin of the abductor pollicis, it divides into the two *plantar* arteries, which, from their position, are named internal and external.

The *internal plantar* artery, [a. plantaris interna] fig. 254,<sup>6</sup> much smaller than the other, is directed forwards, along the inner side of the foot. Placed at first (in the position of the foot during the erect posture) above the abductor pollicis, and afterwards between it and the short flexor of the toes, it gives branches to both; and also some offsets which incline towards the inner border of the foot, and communicate with branches of the dorsal arteries. On reaching the extremity of the first metatarsal bone, the internal plantar artery, considerably diminished in size, terminates by running along the inner border of the great toe, anastomosing with its digital branches. The direction of the artery corresponds with that of the line which separates the internal from the middle set of plantar muscles.

The *external plantar* artery,<sup>7</sup> [a. plantaris externa] much larger than the internal plantar, at first inclines outwards and then forwards, to reach the base of the fifth metatarsal bone: thence, changing its direction, it turns obliquely inwards across the foot, to gain the interval between the bases of the first and second metatarsal bones, where it

\* "Neues Verzeichniss der Anatomischen Sammlung," &c. Prep. 2093.



joins, by a communicating branch, with the dorsal artery of the foot; and thus is completed the plantar arch, the convexity of which is turned forward. In this long course the vessel lies at different degrees of depth. At first it is placed, together with the external plantar nerve, between the calcaneum and the abductor pollicis; then between the flexor brevis digitorum and flexor accessorius. As it turns forwards it lies comparatively near the surface in the interval between the short flexor of the toes and the abductor of the little toe, being placed along the line separating the middle from the external portion of the plantar fascia; by which membrane, and by the integuments and fat, the vessel is here covered. The remainder of the artery, which turns inwards and forms the plantar arch, is situated deeply against the interosseous muscles, and is covered by the flexors of the toes and the lumbricales muscles.

From the plantar arch numerous branches are given off, varying in size and importance. Of these some pass outwards over the border of the foot, and anastomose with the dorsal arteries; others go back to supply the parts in the hollow of the foot; and several down to the fascia, integument, and subcutaneous cellular substance. These branches are too irregular to admit of being named or described.

From its upper and fore part branches are given off which require particular notice.

The *posterior perforating* branches, (*perforantes post.*) three in number, pass upwards through the back part of the three outer interosseous spaces, between the heads of the dorsal interosseous muscles. On reaching the back of the foot, these small vessels inosculate with the interosseous arteries, branches of the metatarsal artery.

The *digital* branches, [*digitales*,] four in number, are named from the order in which they arise from the arch, counting from without inwards, first, second, third, and fourth digital arteries. The *first* digital branch inclines outwards from the outermost part of the plantar arch, opposite the end of the fourth metatarsal space, to gain the outer border of the little toe. In this course the vessel crosses under the abductor muscle of that toe, and then runs along the outer border of its phalanges, on the last of which it terminates. The *second* digital branch passes forwards along the fourth metatarsal space, and behind the cleft between the fourth and fifth toes divides into two vessels, which course along the contiguous borders of those toes, and end on the last phalanges; the *third* digital branch is similarly disposed of on the fourth and third toes; and the *fourth* on the third and second toes.

Near its point of bifurcation, each digital artery sends upwards through the fore part of the corresponding metatarsal space a small branch, *anterior perforating* [*perforantes ant.*] which communicates with the digital branch of the metatarsal artery.

The digital arteries of each toe, which, from their relation to the phalanges, are sometimes called collateral, incline one towards the other at their termination, and inosculate on the last phalanx near its base, so as to form an arch, from the convexity of which minute vessels pass forwards to the extremity of the toe, and to the matrix of the nail. In this, the ordinary arrangement of the vessels, both sides of the three outer toes, and one side of the second toe, are supplied by branches derived from the plantar arch; whilst, as will presently appear, both the collateral arteries of the great toe, and the inner one of the second, are furnished by the dorsal artery of the foot.

*Peculiarities of the plantar arteries.*—Some of these will be considered after the description of the anterior tibial artery and its branches in the foot. It may be stated here, however, that the posterior perforating branches, which are usually very small vessels, are sometimes enlarged, and furnish the interosseous arteries

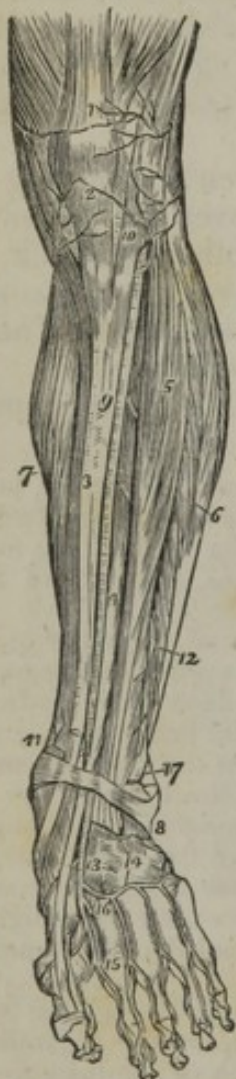

on the upper surface of the foot; the metatarsal branch of the dorsal artery, from which the interosseous arteries are usually derived, being in such cases very small.

#### ANTERIOR TIBIAL ARTERY.

The *anterior tibial artery*, [a. tibialis antica,] fig. 255,<sup>9</sup> placed along the fore part of the leg, is at first deeply seated, but, as it descends, gradually approaches nearer to the surface. It extends from the division of the popliteal artery to the bend of the ankle, whence it is afterwards prolonged to the interval between the first and second metatarsal bones, under the name of *dorsal artery* of the foot.

[Fig. 255.



The anterior tibial artery is at first directed forwards to reach the fore part of the interosseous ligament; and this short part of the vessel passes between the heads of the tibialis posticus, and through the interval between the bones left unoccupied by the interosseous ligament. Having reached the fore part of the leg, the artery extends obliquely downwards to the middle of the ankle-joint, so that its course may be nearly indicated by a line drawn from the inner side of the head of the fibula to midway between the two malleoli. Lying between the tibialis anticus (on its inner side), and the extensor communis digitorum, with, lower down, the extensor proprius pollicis (on its outer side), the vessel is deeply placed at the

Fig. 255. The anterior aspect of the leg and foot, showing the anterior tibial and dorsalis pedis arteries, with their branches. 1. The tendon of insertion of the quadriceps extensor muscle. 2. The insertion of the ligamentum patellæ into the lower border of the patella. 3. The tibia. 4. The extensor proprius pollicis muscle. 5. The extensor longus digitorum. 6. The peronei muscles. 7. The inner belly of the gastrocnemius and the soleus. 8. The annular ligament beneath which the extensor tendons and the anterior tibial artery pass into the dorsum of the foot. 9. The anterior tibial artery. 10. Its recurrent branch inosculating with (2) the inferior articular, and (1) the superior articular arteries, branches of the popliteal. 11. The internal malleolar artery. 17. The external malleolar inosculating with the anterior peroneal artery 12. 13. The dorsalis pedis artery. 14. The tarsea and metatarsea arteries; the tarsea is nearest the ankle, the metatarsea is seen giving off the interosseæ. 15. The dorsalis pollicis artery. 16. The communicating branch.—W.]

upper part of the leg, where those muscles are fleshy; but is comparatively superficial below, where the muscular fibres have ended in the tendons. At the bend of the ankle it is covered by the annular ligament, and is crossed by the tendon of the extensor proprius pollicis. In its oblique course downwards, the anterior tibial artery rests at first against the interosseous ligament, and is then at a considerable distance from the spine of the tibia; but in descending it gradually approaches that ridge, and towards the lower part of the leg is supported on the anterior surface of the bone.

The anterior tibial artery is accompanied by two veins (*venæ*



*comites*). The anterior tibial nerve, coming from the outer side of the head of the fibula, approaches the artery at a short distance after the appearance of the vessel in front of the interosseous ligament. Lower down, the nerve for the most part lies in front of the artery, but often changes its position from one side of the vessel to the other.

*Branches.*—The branches of the anterior tibial artery are small but very numerous, and are given off at short intervals along the parent vessel. Most of them are distributed to the neighbouring muscles, and are unnamed. The following named branches require special notice.

The *recurrent artery*, [*a. recurrens tibialis*,] fig. 255,<sup>10</sup>.—On reaching the front of the leg, the anterior tibial artery sends upwards a considerable branch, which, from its course, is thus named. This branch ascends through the fibres of the *tibialis anticus*, and, ramifying on the lateral and fore parts of the knee-joint, anastomoses with the inferior articular branches of the popliteal artery.

The *malleolar arteries*,<sup>11, 12</sup> [*a. malleolares*].—Near the ankle-joint two malleolar branches, named internal and external malleolar, are given off by the anterior tibial artery. The *internal* branch, having passed beneath the tendon of the *tibialis anticus*, reaches the inner ankle, and ramifies upon it, supplying the surrounding textures, and communicating with branches of the posterior tibial artery. The *external malleolar* branch bears a similar relation to the outer ankle; having passed under the tendon of the common extensor of the toes, it anastomoses with the anterior division of the peroneal artery, and also with some ascending or reflected branches from the tarsal branch of the dorsal artery of the foot.—These malleolar arteries supply articular branches to the neighbouring joints.

It should be further remarked, that they vary frequently in their mode of origin and in their size.

#### DORSAL ARTERY OF THE FOOT.

The *dorsal artery of the foot* (*a. dorsalis pedis*), fig. 255,<sup>13</sup> the continuation of the anterior tibial artery, extends from the termination of that vessel at the bend of the ankle, to the posterior end of the first metatarsal space, where it divides into two branches, of which one proceeds forwards in the first interosseous space, whilst the other dips into the sole of the foot, and terminates by inosculating with the plantar arch. This vessel, in its course forwards, rests upon the astragalus, the scaphoid, and internal cuneiform bones and their respective articulations. It lies in the interval between the tendon of the proper extensor of the great toe, and that of the long extensor of the other toes; and is covered by (besides the integument) the fascia of the foot, and by a layer of dense cellular membrane, which binds it to the parts beneath. Near its end, it is crossed by the innermost tendon of the short extensor of the toes.

Two veins accompany this artery; the anterior tibial nerve lies beneath it and on its outer side.

The *principal branches* of the dorsal artery of the foot are directed outwards and forwards upon the tarsus and metatarsus, and are named accordingly. Some small offsets also run obliquely inwards, and ramify upon the inner side of the foot.

The *tarsal* branch, [*tarsea*,] fig. 255,<sup>14</sup> arises from the artery usually where it crosses the scaphoid bone, but its point of origin varies in different instances. It inclines forwards and outwards upon the tarsal bones covered by the short extensor muscle of the toes, to which, and to the tarsal articulations, it gives small



vessels. The tarsal artery, then curving backwards towards the cuboid bone, divides into branches which take different directions: some of them run forwards, to anastomose with the divisions of the metatarsal artery; others outwards, to communicate at the outer border of the foot with branches of the external plantar artery; whilst a third set anastomoses with branches of the external malleolar, and with those of the peroneal artery upon the outside of the calcaneum.

The *metatarsal* branch, [metatarsæa,] arises farther forward than the preceding vessel, but, like it, is directed outwards beneath the short extensor muscle. Sometimes there are two metatarsal arteries, the second being of smaller size; and not unfrequently, when there is but a single vessel of this name, it arises in common with the tarsal artery. Its direction is necessarily influenced by these circumstances; being oblique when it arises far back, and almost transverse when its origin is situated farther forwards than usual. Branches pass off in different directions for the supply of the surrounding structures; some of these run outwards and anastomose with offsets from the external plantar artery, whilst others curve backwards, to join with those of the tarsal artery. The interosseous branches only require to be specially noticed:—

The *interosseous arteries*, [a. interosææ,] three in number, are so named from their position between the metatarsal bones. They are small straight vessels which pass forwards along the three outer interosseous spaces, resting upon the dorsal interosseous muscles. Somewhat behind the clefts between the toes each interosseous artery divides into two branches, which run forward along the contiguous borders of the corresponding toes, forming their dorsal collateral branches. Moreover, from the outermost of these interosseous arteries a small branch is given off, which gains the outer border of the little toe, and forms its external collateral branch. Hence it appears, that the interosseous branches derived from the metatarsal artery supply the dorsal surface of the three outer toes, and that of one side of the second toe.

As these vessels bifurcate opposite the fore part of the interosseous spaces, they communicate with the plantar artery by means of the *anterior perforating* branches; and at the back part of the interosseous spaces, they are likewise joined by the *posterior perforating* branches of the same artery.

*First interosseous branch* (dorsal artery of the great toe: *dorsalis pollicis*).—When the dorsal artery of the foot has reached the first metatarsal space, it gives off this branch,<sup>15</sup> which runs along the outer surface of the first metatarsal bone, and is analogous to the other interosseous arteries. On reaching the fissure between the first and the second toes this branch divides into two smaller vessels, which run along the contiguous borders of these two toes on their dorsal surface.

After having furnished this branch, the dorsal artery of the foot dips into the first interosseous space between the heads of the first dorsal interosseous muscle, and inosculates with the end of the external plantar artery, so as to complete the plantar arch.

*Digital branches*.—At this point it gives off two branches. One of these crosses beneath the first metatarsal bone, and runs along the inner side of the great toe on its plantar surface; the other is directed forwards opposite the first metatarsal space, and divides into two smaller branches, which proceed along the contiguous sides of the great and second toe.—In this way the series of digital arteries for the supply of the under surface of the toes is rendered complete.

#### PECULIARITIES OF THE ANTERIOR TIBIAL ARTERY.

The peculiarities of this artery relate to its origin, its course, its size, and the condition of its branches.

*Origin*.—In cases of premature division of the popliteal artery, the place of origin of the anterior tibial is necessarily higher up than usual, being sometimes found as high as the bend of the knee-joint. In some of these cases (the posterior tibial artery being small or wanting), the anterior tibial is conjoined with the peroneal artery. When the anterior tibial arose higher than usual, the additional upper part of the vessel has been seen resting on the popliteus muscle, and it has likewise been found between that muscle and the bone.



*Course.*—The anterior tibial, having its usual place of origin, has been found to deviate outwards towards the margin of the fibula in its course along the front of the leg, and then to return to its ordinary position beneath the annular ligament in front of the ankle-joint. This artery has also been noticed by Pelletan\* and by Velpeau† to approach the surface at the middle of the leg, and to continue downwards from that point, covered only by the fascia and integument.

The last-named observer states that he found the artery reach the fore part of the leg by passing round the outer side of the fibula.‡

*Size.*—This vessel more frequently undergoes a diminution than an increase of size.

It may be defective in various degrees. Thus, the dorsal branch of the foot may fail to give off digital branches to the great and second toes, which may then be derived from the internal plantar (a branch of the posterior tibial). In a further degree of diminution the anterior tibial ends in front of the ankle, or at the lower part of the leg; its place being then taken by the anterior division of the peroneal artery, which supplies the dorsal artery of the foot; the two vessels (anterior tibial and anterior peroneal) being either connected together, or separate.

Two cases are mentioned by Allan Burns, in which the anterior tibial artery was altogether wanting, its place in the leg being supplied by perforating branches from the posterior tibial artery, and on the dorsum of the foot by the anterior division of the peroneal artery.

The dorsal artery of the foot is occasionally larger than usual; in that case compensating for a defective plantar branch from the posterior tibial artery.

This artery has been repeatedly found to be curved outwards, between its commencement at the lower border of the annular ligament and its termination at the first interosseous space.

#### VARIATIONS OF THE ARTERIES OF THE LEG AND FOOT CONSIDERED COLLECTIVELY.

From the facts above-mentioned, concerning the peculiarities of the three arteries which supply the leg and foot, it will be seen that all the deviations from the ordinary arrangement, in regard to their size, display a general principle of compensation, by which deficiencies in one vessel are balanced by an increase in the size of another.

It will also be observed, that, whilst the anterior and posterior tibial arteries have a greater tendency to diminish than to increase in size, the peroneal artery, on the contrary, is the vessel which is the most frequently enlarged. The anterior and posterior tibials, however, occasionally assist each other, especially in the supply of arteries to the toes.

#### ANASTOMOSES OF ARTERIES IN THE LOWER LIMB.

Frequent mention has been made of the anastomoses which exist between the branches of the arteries in the lower limb; and a general view of them may now be taken, in order that some idea may be formed of the important influence which they exert in maintaining the circulation of the limb, when the principal artery is obliterated by an operation, or by disease.

It may be remarked, in the first place, that the more important of these anastomoses occur in the neighbourhood of the principal articulations of the limb. Thus, it will be remembered that branches from different directions converge towards the back part of the *hip-joint*. The circumflex arteries (internal and external) turn round the shaft of the femur, one from within, the other from without; the gluteal and sciatic arteries run from above downwards, and the superior perforating branches of the deep femoral from below upwards, towards the same point. At the anterior and upper part of the limb, a similar mode of connexion occurs, but by no means so extensive, between the ilio-lumbar and the circumflex

\* "Clinique Chirurgicale," &c. p. 101. Paris, 1810.

† "Nouveaux Elémens de Médecine Opératoire," &c. t. i. p. 137. Paris, 1837.

‡ Op. cit. p. 537.




iliac artery; and again between the latter vessel and the external circumflex on the one hand, and the epigastric artery on the other.

Around the *knee-joint* a very free communication exists between the four articular arteries (converging to its fore part), the recurrent tibial from below, and the anastomotic artery and descending branches of the external circumflex, from the opposite direction. This anastomosis is connected with that in the neighbourhood of the hip-joint by the descending branches of the external circumflex artery in front, and by the series of perforating branches of the deep femoral artery and some muscular branches of the popliteal artery, behind.

Lastly, the *ankle-joint* is likewise surrounded by a series of anastomotic vessels. Thus, the posterior tibial and the peroneal arteries communicate across the limb before they proceed to their final destination. In front of the joint, the anterior peroneal branch anastomoses with the external malleolar and with the tarsal arteries; the external malleolar artery communicates again with the peroneal, whilst the internal malleolar maintains a similar connexion with the posterior tibial artery or its branches.

END OF VOL. I.







NATIONAL LIBRARY OF MEDICINE



NLM 01001548 9