

**Cases of deformity from burns, successfully treated by plastic operations /  
by Thomas D. Mütter.**

**Contributors**

Mütter, Thomas D. 1811-1859.  
National Library of Medicine (U.S.)

**Publication/Creation**

Philadelphia : Merrihew & Thompson, printers, 1843.

**Persistent URL**

<https://wellcomecollection.org/works/uq5yzemw>

**License and attribution**

This material has been provided by This material has been provided by the National Library of Medicine (U.S.), through the Medical Heritage Library. The original may be consulted at the National Library of Medicine (U.S.) where the originals may be consulted.

This work has been identified as being free of known restrictions under copyright law, including all related and neighbouring rights and is being made available under the Creative Commons, Public Domain Mark.

You can copy, modify, distribute and perform the work, even for commercial purposes, without asking permission.



Wellcome Collection  
183 Euston Road  
London NW1 2BE UK  
T +44 (0)20 7611 8722  
E [library@wellcomecollection.org](mailto:library@wellcomecollection.org)  
<https://wellcomecollection.org>

21  
6510/10  
Auth the regard of  
S. Mutter

*J. Winslow*

CASES  
OF  
DEFORMITY FROM BURNS,  
SUCCESSFULLY TREATED  
BY  
PLASTIC OPERATIONS.

*Wash. '88*

BY  
THOMAS D. MÜTTER, M.D.,

PROFESSOR OF SURGERY IN JEFFERSON MEDICAL COLLEGE, PHILADELPHIA; CORRESPONDING MEMBER OF THE "NATIONAL INSTITUTE," AT WASHINGTON;  
FELLOW OF THE COLLEGE OF PHYSICIANS, PHILADA.; CORRESPONDING MEMBER OF THE NEW YORK MEDICAL SOCIETY, &c. &c.

PHILADELPHIA:  
Merrihew & Thompson, Printers,  
No. 7 CARTER'S ALLEY.

1843.







C A S E S  
OF  
DEFORMITY FROM BURNS,  
SUCCESSFULLY TREATED  
BY  
PLASTIC OPERATIONS.

BY  
THOMAS D. MÜTTER, M.D.,

PROFESSOR OF SURGERY IN JEFFERSON MEDICAL COLLEGE, PHILADELPHIA; CORRESPONDING MEMBER OF THE "NATIONAL INSTITUTE," AT WASHINGTON;  
FELLOW OF THE COLLEGE OF PHYSICIANS, PHILADA.; CORRESPONDING MEMBER OF THE NEW YORK MEDICAL SOCIETY, &c. &c.

---

PHILADELPHIA:  
MERRIHEW & THOMPSON, PRINTERS,  
No. 7 CARTER'S ALLEY.

1843.

## NOTE.

Two years and more have elapsed since the first of the operations reported was performed, and the patient still continues relieved. No contraction has taken place, and the success of the experiment may therefore be considered complete: the other cases are also doing well. I have performed similar operations in four other cases since this report was published in the American Journal of Medical Sciences for July, 1842, and, with but one exception, complete success has followed in every instance.

MAY 20, 1843.



John W. M. 1843  
15 Piccadilly  
Manchester

---

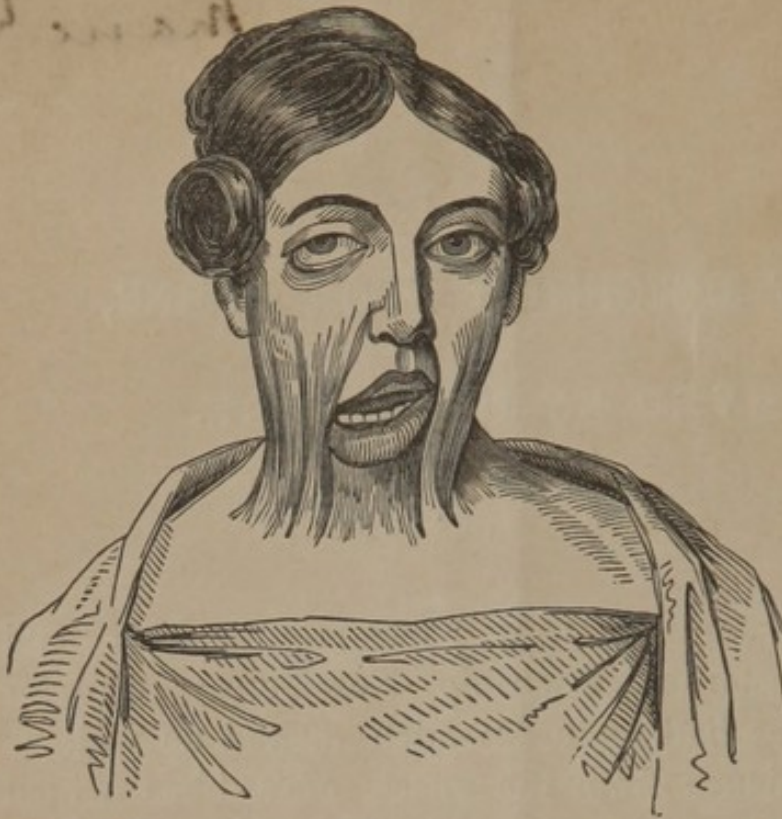CASES OF DEFORMITY FROM BURNS,  
RELIEVED BY OPERATION.

---

IN the month of January, 1841, I was requested to attend Miss A. T. of Chesterfield township, New Jersey, who for *twenty-three years* had endured much mental as well as physical inconvenience from the effects of a burn which occurred when she was five years old, and involved the face, throat, and upper part of the thorax in front. The following extract from her history of the case, will explain the nature of the accident, as well as the treatment to which she had been subjected before I saw her :—"I received a burn when five years old by my clothes taking fire. My grandmother being a great doctress nursed me, until prevented by indisposition; and as they wished me to remain in as comfortable a position as possible, my life being entirely despaired of by the family, medical aid was not called in. Dr. Burns, a neighbouring physician, hearing of the circumstances, could not refrain from calling to see me; he called twice as a friend, and was then forbidden to come again until sent for, which was never done. When about eleven years of age, an attempt was made by Dr. Cook, of Bordentown, to afford some relief. Being young, I was much alarmed, and opposed him. My near relations, being unwilling to see me suffer, united with me; and he was obliged to desist before completing his design. I therefore did not experience any relief, and have been unable to *throw my head to the left side*, or



Fig. 1.



*backwards, or to close my mouth for more than a few seconds at a time for 23 years. My right eye was also drawn down some distance below the other, and when I endeavored to turn my head, it was entirely closed. My condition has been most humiliating, and made*

life a burthen; but having good health, I strove to reconcile myself to my hard lot!" In addition to the symptoms so vividly described, I found the angles of the lower jaw altered, and the incisor teeth nearly *horizontal*, (as is seen in cases of chronic hypertrophy of the tongue,) by the pressure of the tongue, which organ, in consequence of the inability of the patient to close the mouth, was always visible, and indeed *protruded*, when she was silent. The clavicle on the right side was also so completely embedded in the cicatrix, that it could scarcely be felt, and there was no external indication of its location. The chin, from the shortness of the bands, was drawn down to within *one inch and a half* of the top of the sternum, and the head consequently inclined very much. The space between the chin and sternum was also filled up by the cicatrix, so that no depression existed in front of her neck. Fig. 1, which represents her full face, affords a very correct idea of her appearance. After carefully examining the case, and fully explaining to the patient and her friends the inutility of any of the usual operations for such deformities, I proposed to them one entirely



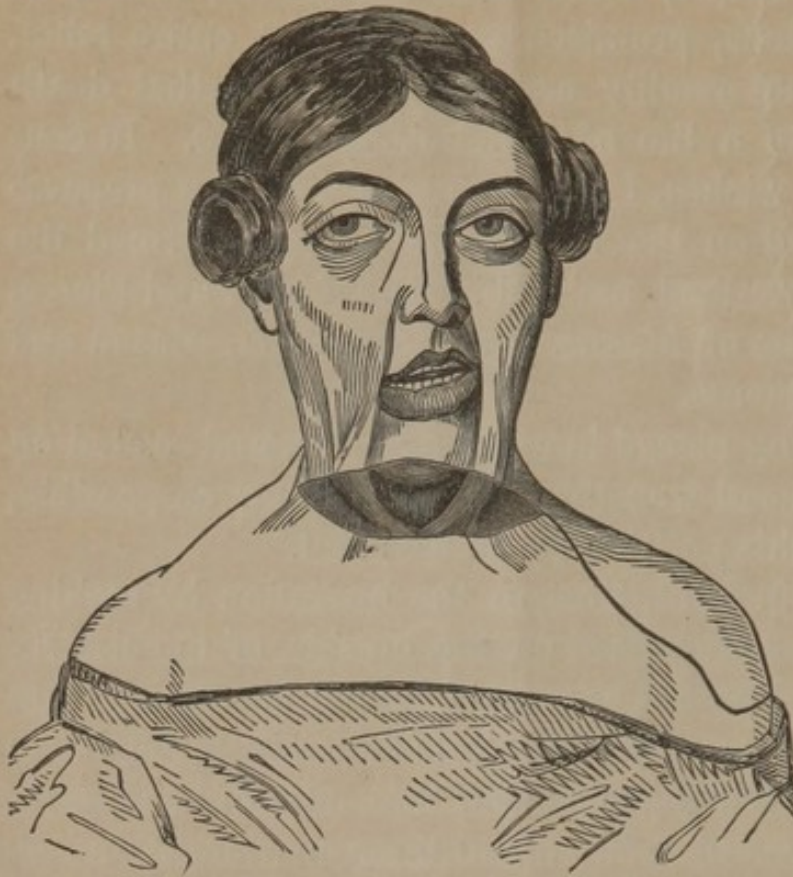
different in its principle, which although severe, as well as somewhat hazardous, promised partial, if not entire relief. To this my patient readily assented, declaring that death were preferable to a life of such misery as hers. In conformity with her wishes, I at once placed her on a preparatory treatment, and on the 12th of January, performed the operation to be described, assisted by Drs. Noble and Pierce, and in the presence of Messrs. Ward, Ducachet, Mason and Egan, medical students.

The patient being placed in a strong light, and seated on a low chair, her head was thrown back as far as possible, and sustained in this position by an assistant.

Seating myself in front, I began the operation by making an incision which commenced on the outside of the cicatrix in *sound skin*, and passed across the throat into *sound skin* on the opposite side. This penetrated merely through the integuments, and was made as near the centre of the cicatrix as possible. It was therefore about three quarters of an inch above the top of the sternum, and of course in the most vital part of the neck. My object in making it so low down was to get at the attachments of the sterno-cleido-mastoid muscles, which in consequence of the long flexion of the head, were not more than three inches in length, and required on one side *complete*, and on the other *partial* division, before the head could be raised. The integuments having been thus divided, I next carefully dissected through the cicatrix until I reached the fascia superficialis collî, which I could readily detect, and then going on still deeper, I exposed the sterno-cleido-mastoid muscle of the right side, and passing a director under it, as low down as possible, divided both its attachments. This enabled me to raise the head an inch or two; but finding that it was still kept down by the sterno-cleido-mastoid of the *left* side, I divided the sternal attachment of this muscle, and was much gratified to find that the head could at once be placed in its proper position, the clavicular attachment of the muscle offering little or no resistance. A most shocking wound *six inches in length* by *five*



Fig. 2.



very well, that if permitted to heal by granulation only, the patient, so far from being benefited, would be made worse

Fig. 3.



*and a half in width*, was thus made, and yet there was scarcely any hemorrhage; three or four vessels only requiring the ligature. (See fig. 2.)

The next step in the operation consisted in the detachment of a flap of *sound skin* with which this chasm could be filled; for I knew

than before. To obtain this flap, I commenced at the terminal extremity of the first incision, and carrying the scalpel *downwards and outwards* over the deltoid muscle, dissected up an oval piece of integument *six inches and a half in length*, by six



*in width*, leaving it attached at the upper part of the neck, (see fig. 2.) This dissection was painful, but not bloody, only one small vessel being opened. The flap thus detached was next brought round by making a half-turn in its pedicle, placed in the gap it was destined to fill, and carefully attached by several twisted sutures, to the edges of the wound, (see fig. 3.) Several straps were then applied to support the sutures, but no other dressing was deemed advisable. The edges of the wound on the shoulder from which the flap had been removed, were next brought together by straps and sutures, and, with the exception of its upper third, was completely covered in. A pledget of lint moistened with warm water was laid upon this raw surface, a bandage applied by which the head was carried backwards and maintained in this position, and the patient put to bed. The fortitude with which this truly severe operation was borne excited the admiration of all present. Scarcely a groan escaped the patient, nor was it necessary to give her more than a mouthful or two of wine and water during the whole period of its duration.

Rest and quietude were enjoined, and the patient prohibited from taking any kind of nourishment, in order that adhesion or union by the first intention might be accomplished.

*Jan.* 13th.—Patient has passed a good night; slight acceleration of the pulse, but no fever; not much thirst; complains of *stiffness* in the neck, and pain in the back from lying in one position so long. Slight headache from the anodyne which it was deemed advisable to administer *before* the operation.

14th.—Much as yesterday; a little nervous, but no fever; no swelling or pain in the wound; some thirst and hunger, but willing to go another day without sustenance.

15th.—A little feverish; wound painful at one point, thirst intense, bowels not opened; restless, and anxious; ordered an enema to be administered at once; and spoonfuls of cool barley water to be taken every hour or two.



16th.—Much better; enema operated well, fever gone; thirst less, skin moist; cheerful and in hope.

17th.—The same; took off straps and found the wound united along the edges, with the exception of here and there a point; a small pouch of pus at the most dependent part of the flap; patient rather restless under the dressing.

Evacuated the pus through a small opening in its vicinity; took out some of the pins, reapplied the straps; dressed the shoulder with poultice of slippery elm; ordered a little mutton broth, and an enema of salt and water.

It would be worse than needless to detail the daily symptoms and treatment from this time to the period at which the patient was enabled to move about, and enjoy the full benefit of the operation.

It will be sufficient to state that no unfavourable symptom made its appearance, that *union by the first intention* took place throughout the entire wound, with the exception of one small point which united by granulation; that the wound in the shoulder, except just over the acromion process, healed kindly: and that the patient, as her own words will testify, has been relieved of all or nearly all inconvenience. The following extract is from a letter received some time since.

“The comfort and satisfaction I feel, cannot be expressed; your exertions in my behalf have been blessed far beyond my most sanguine expectations. You have *set my head at liberty, so that I can turn it any way, at pleasure, and without pain*; you have relieved the drawing of my eye; and I am also enabled to close my mouth with comfort, a blessing that cannot be described!”

In order to accomplish the closure of the mouth, the lower incisor teeth were straightened, and one of them extracted by a dentist. The angles of the lower jaw have, in consequence of the change in the condition of the throat, regained in a great measure their proper shape, and the whole appearance of the patient is so much altered that persons who saw her before the operation, scarcely recognize her as the same individual. I should have mentioned that one troublesome cir-



cumstance occurred which will serve as a lesson in all subsequent operations of a similar character. Although very careful to extend my incisions from beyond what I supposed was the extent of the cicatrix, I yet left a band of this tissue, certainly not thicker or wider than a small wire. This band contracted, and before the patient could be entirely relieved I was obliged to loosen it by making an incision in the sound skin below on the neck.

To support the neck after the incision had healed, I gave the patient a *stiff stock* on which her chin rested, and this instrument also served to press the integuments back, by which the natural excavation or depth of the neck in front was readily effected. This stock is of course no longer

Fig. 4.



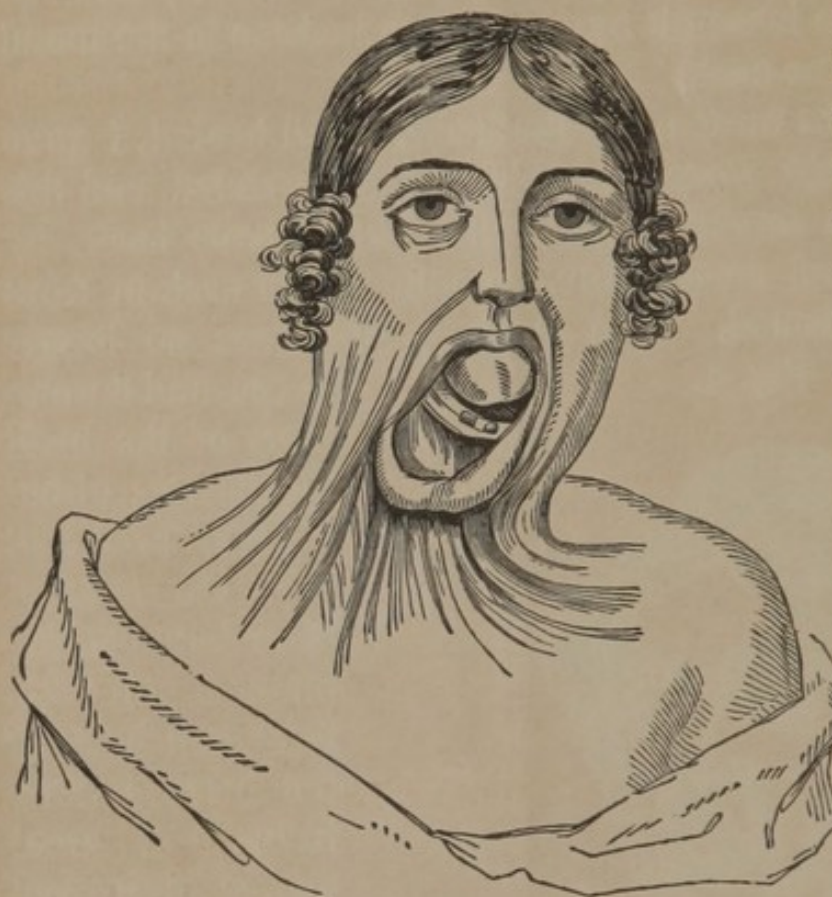
in use, and the motions of the head are perfect; altho' it was predicted that the antagonism between the muscles on the front and back of the neck having been in a great degree destroyed by the section of the mastoids, these motions would necessarily never be acquired. (Fig. 4 represents her as cured.)

More than a twelvemonth has elapsed since the operation was performed, and yet there is no contraction in the flap, and the relief of the patient is complete.



CASE II. In the month of June, 1841, I was requested to visit Margaret Ann Henderson, aged 12 years, who when four years old had received a severe burn of the chest, throat, and lower part of the cheek, from her clothes having taken fire.

Fig. 5.



For nearly 8 years she had been unable to turn her head to the left side, the lower lip was everted, and the chin drawn down nearly in contact with the sternum, while the front of the throat presented the rough, reddish cicatrix represented in fig. 5.

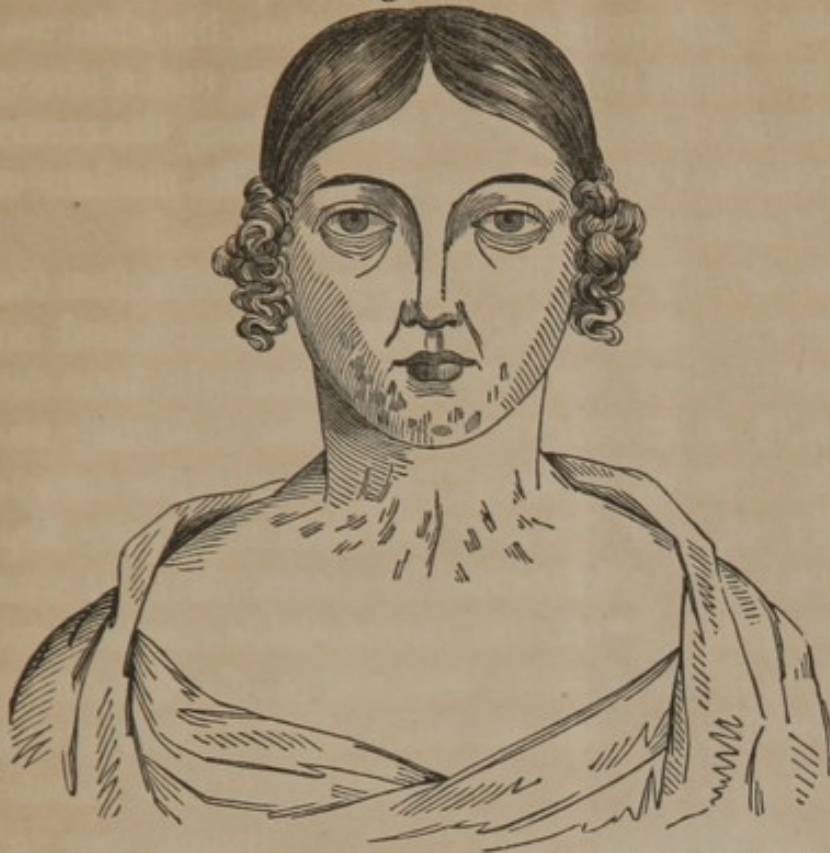This case was even more unfavourable than that of Miss A. T.; but still, with the view of rendering her condition somewhat more bearable, I determined to perform the operation which had proved so successful in the latter case, but a few weeks before; and accordingly on the 20th instant, assisted by Drs. Knox, Davis, E. Smith, and Marston, it was carried into execution. The operations were almost identical, with the exception that in the case of Miss Henderson the section of the tendon of the sterno-cleido-mastoid on the right side only, was sufficient to allow the head to assume its natural position.

The after treatment was also the same, nor did any symptom calling for energetic measures make its appearance; all



speaking, swallowing, or motions of the neck of any kind,

Fig. 6.

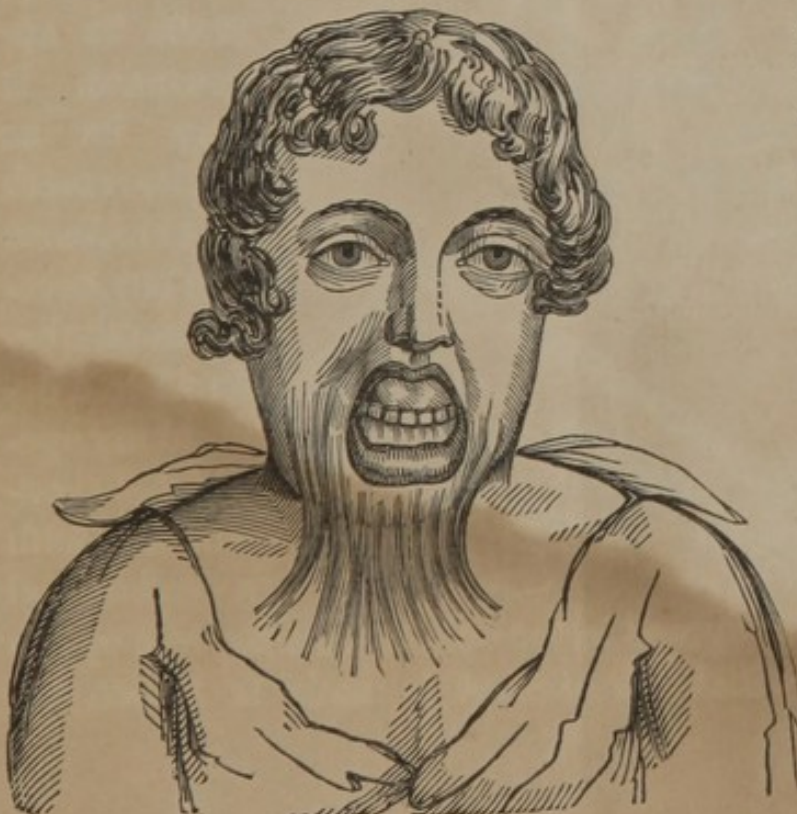

were carefully avoided until the fourth day, when the pins were taken out, and the patient allowed animal broths. Fig. 6 represents her appearance 5 weeks after the operation, and up to the present date, March 21, she continues as

well as at that period—the relief afforded is therefore as permanent as it is decided.

CASE III. About the 1st of January, 1842, I was requested

Fig. 7.



to attend Charles McAllister, aged nine years, for a deformity of the mouth and throat, produced by a burn. As is generally the case, the injury was the result of his clothes having accidentally taken fire, and he had suffered from its inconveniences for several years.



The appearance presented by this boy is well shown in fig. 7. His mouth was kept permanently open, his incisor teeth were losing their perpendicular position, his chin was drawn to within an inch or two of the sternum, and a strong band of the "tissue of the cicatrix" passed along the centre of the throat from the chin to the sternum. The motions of his head were of course very much impaired.

The operation already described was performed before the medical class on the second Wednesday in January, and on the first Wednesday in February he was brought into the amphitheatre with scarcely a vestige of the deformity remaining, and the wound healed throughout with the exception of a small spot near the shoulder from which the flap had been removed, and which united by granulation. It was found unnecessary to divide the sterno-cleido-mastoid on either side. Here, in *three weeks* time, a cure of a deformity hitherto considered hopeless, was effected, and during the

Fig. 8.



whole treatment not a symptom calculated to excite the slightest anxiety, made its appearance. It may be as well to remark that I had seen this boy several months before I had devised my operation, in consultation with a professional

friend, and we both agreed in the opinion that the best operation was that in which an attempt is made to loosen the



cicatrix by making incisions in the adjacent sound skin, and then dissecting up the cicatrix itself and separating the edges of the wound in the sound part, allow the latter to heal by granulation. In other words, the operation in which the tissue of the cicatrix is displaced from its natural position and made to form adhesions with new parts.

Although performed with the usual skill and accuracy of the accomplished surgeon under whose care the boy was placed, the operation failed; producing, it is true, some little relief, but leaving him in the condition described.

A fourth case of this deformity has been treated, and with success, but as it resembles the others in almost every respect, it is needless to enter into its details.

REMARKS.—Few subjects in surgery have excited more interest than the peculiarities of cicatrices resulting from burns, and the plans of treatment by which the deformities they occasion may be either alleviated or entirely removed. Much of the controversy, originating in the different views promulgated, may be traced to the fact that few have studied the subject in a proper manner; and great credit is due to Dupuytren, Delpech, Velpeau, and Cooper for the highly interesting, simple, and practical matter recently furnished by them—by the aid of which the confusion hitherto enveloping the pathology of this important lesion has been removed. In the investigation of this subject, with the view of determining the propriety of operations such as those reported, it is important to direct our attention to several points.

1. *The nature of the tissue to be divided or removed.*—Although the “*tissue of the cicatrix*,” as it is termed by Dupuytren, however produced, always presents certain characteristic peculiarities by which it may be distinguished from any healthy or natural structure, it yet exhibits *modifications* induced either by the *cause* or the *tissue* involved. The cicatrix of a *burn*, for example, can always be readily distinguished from that caused by sharp instruments; and



again, both these from those resulting from cancers, ulcers, herpetic diseases, syphilis, or scrofula. The cicatrix of an ulcer in mucous membrane differs, too, from one taking place in the skin.

Nearly all formations of this tissue, however, when dissected, present pretty much the same structure. We have, in the first place, a *delicate cuticle*, which may be detached by *vesication* or *maceration*. Beneath this inorganic tissue is a dense stratum composed of strong fibres, which cross each other at different angles, and are firmly bound together. This is the true "tissue of the cicatrix" of Dupuytren, and the "inodular tissue" of Delpech, between which and the cuticle there is no deposit, as a general rule, of rete mucosum; hence the whiteness of cicatrices in the African. It contains no hair bulbs, nor sebaceous follicles, at least when the lesion is profound; and although furnished with both nerves and blood-vessels, is usually less perfectly organized than the parts whose loss it supplies.

Lying under this tissue, we find a dense laminated substance, composed of the original cellular substance, which binds the cicatrix down, and offers, in many cases, the chief obstacle to the success of our operations. This is especially the case in severe burns; and whenever such adhesions exist, we must anticipate and be prepared for most extensive dissection if an operation be attempted.

Another difficulty occasionally, though very rarely, presents itself in cases dependent upon burns—namely, the *vascularity* of the cicatrix. Whenever this tissue is red, sensitive, soft, and moveable, we may fear hemorrhage; and this condition will therefore always render our prognosis, so far as loss of blood is concerned, more unfavourable than when the parts are pale, firm, inelastic, and adherent.

2. *The thickness or profundity of the cicatrix.*—The depth to which the ulcer upon which the formation of the cicatrix is dependent extends, should always be considered in our investigation of the case; for the prognosis, as well as the treatment turn chiefly upon this point.



When the integument merely is involved, the cicatrix is, for the most part, elevated, thrown into bands, moveable, and soft, the fascia beneath not being contracted. The motions of the subjacent parts are also normal; and hence, although the deformity may be considerable, yet the positive inconvenience is comparatively slight. In such a case the prognosis is favourable, and the operation required much less severe than under other circumstances. When, on the other hand, not only the integument, but the superficial fascia, cellular tissue, and muscles are attached, the inodular tissue is irregular, dense, thrown into hard ridges, immovable, or nearly so, and the parts which it unites are disturbed, displaced, or, as in the case of openings and cavities, obliterated, the prognosis is very unfavourable, and the operations indicated extensive and severe. This condition must not be confounded with that contraction of the fascia superficialis sometimes accompanying cutaneous burns, but often the result of other causes, many of which are inappreciable. For example, I have known the fascia of the palm of the hand gradually harden, contract, become thicker, and eventually inelastic, thus causing a permanent closure of the hand, the skin covering it being perfectly soft and pliable, while the cause of this change of structure was too subtle to admit of detection. Certain varieties of club foot are produced in the same way.

This contraction is also frequently brought about by keeping a part too long in one position, and it may result from chronic inflammation of parts either above or below the fascia.

3. *Location of cicatrix.*—The *location* of the cicatrices will also modify the prognosis and treatment. When vital or highly organized regions are involved, great caution must be exercised in the delivery of an opinion favourable to any attempt at relief by an operation; and when such a procedure is deemed advisable, we should always warn our patient, as well as his friends, of the probable risk. In deep cicatrices of such parts, there is less danger of hemorrhage than one would imagine, and for the reason that during the inflamma-



tion which accompanied or preceded the healing of the ulcer, the blood-vessels, especially the veins, in the vicinity were obliterated and converted into fibrous cords; but we should always be prepared for some bleeding, as all the vessels are not included in this obliteration.

4. *Extent of cicatrix.*—The *extent*, too, of the cicatrix is a point deserving attention. The wider and more extensive it is, the more difficult will it be to effect its removal. And we are hardly justified in the performance of an operation, unless there is an almost positive certainty of our obtaining a less deformed cicatrix than the one we wish to remove.

Dupuytren gives some very excellent advice relative to extensive operating on cicatrices: when, for instance, adhesions between the arm and thorax, or thigh and pelvis are to be divided, he cautions not to complete the operation at once, but to proceed by fractions, and let the wound of one operation heal before we undertake another. In this way we avoid the dangerous consequences which may follow so large a wound as would be requisite to separate the parts at once. The same rule is applicable to extensive callous prominences.

Another good rule is, to be certain, before any operation is attempted, that the limb retained in a faulty position is not incapable of being brought into a better one; if ankylosis, alterations of articular surfaces, or atrophy of the member is present, no operation should be attempted.

5. *Age of cicatrix.*—The *duration* or *age* of this inodular tissue must also be taken into account. The advice of Dupuytren is, "that no operation should be attempted until several *months* or even *years* have elapsed since the healing of the wound!" He believes that we run great risk of exciting inflammation and ulceration in the part, and, moreover, that inasmuch as the *disposition of the cicatrix to contract* is not lost for a long period after its complete formation, we do no good by an operation, which may indeed excite in this disposition a new energy. The *older* the cicatrix, then, according to him, the better, so far as an operation is concerned.



This advice is at variance with that of some other surgeons, but it is, nevertheless, as a general rule, the safest to adopt. Especially is it the case where the inodular tissue is superficial, and curable by simple incisions, followed by extension and pressure sufficient to keep the edges of the wound separate from each other. There are instances, as for example, where the cicatrix is so situated as materially to interfere with the comfort and convenience of the patient, where it would be proper to deviate from this rule, and operate as soon as possible: but these are rare exceptions, and do not militate against the correctness of the general proposition.

6. *Peculiar deformity of cicatrix.*—The power with which these cicatrices sometimes contract is well known to every surgeon, but is sometimes overlooked in the desire for an operation. Mr. Earle has known it sufficient to bring the shoulders towards one another by a partial absorption of the clavicles. He mentions another case, in which not only the whole head was bowed down towards the sternum, but the lower jaw curved downwards, so as only to admit of the last molar teeth coming in contact; the mouth being kept permanently open, and the direction of the incisor teeth so altered, that they projected nearly in a horizontal line. (This resembles very much the deformity in my own case, No. 1.) Cruveilhier mentions a case, in which the carpus was luxated from the radius by a cicatrix on the back of the hand; and I have in my possession a similar specimen, and another has been deposited in the museum of Jefferson College, by Professor Pancoast.

An almost endless list of deformities of this kind might be cited, but the examples given are sufficient; and I need hardly add, that in all such no ordinary operation will prove of the slightest benefit.

When, therefore, the original shape and function of a part have been destroyed, we should never operate unless there is a prospect of relieving at least the *deformity*. There are cases in which we must be content with this, while the loss of the function is an evil for which there is no remedy.



Diversified as are the deformities from burns, Dupuytren is of the opinion that they may all be referred to five classes :—

1. Those in which the cicatrix is too narrow.
2. Those in which it is too prominent.
3. Those in which it has formed extensive adhesions.
4. Those in which a cavity has been obliterated.
5. Those in which organs or an organ has been destroyed.

This classification has not been adopted by all, although to a certain extent it is correct.

*Operations.*—It must be obvious that as the cicatrices present a great variety of shapes, occupy different positions, and penetrate to different depths, the operations for their removal must be modified to suit the case.

I. *Narrow cicatrix—Incision.*—Suppose, for instance, the deformity consists in the formation of a narrow band of indurated tissue, which either causes inconvenience from the motion of the parts being interfered with, or from its unsightliness—what operation is most likely to relieve it? Surgeons are divided on this point. While some recommend *incision of the band*, as performed by the ancients, others tell us that such attempts are almost, if not always useless, and what is worse, that they even increase the difficulty, each incision in cicatrizing shortening the band more and more. The latter view, though in the main correct, is rather too exclusive, for there are many examples of entire relief having been obtained by incision and pressure, reported by Dupuytren, Velpeau, Hourmann, Bérard and others. Much depends on the duration of the case, and the depth to which the cicatrix extends. If of long standing, and sufficiently deep to involve the fascia superficialis, the probability is, that the operation will fail, owing, as Mr. Earle has clearly shown, to the contraction of the muscles, which thus acquire a new sphere of action, and to the adhesions of the fascia. In recent and superficial cicatrices, however, the plan will answer, and in its execution there are *three indications* to be observed.

1. The incisions are to be made at several points, and com-



pletely through the tissue ; a scalpel or bistoury is the instrument to be employed.

2. The parts are then to be separated from each other, and placed at once, if supple and yielding, in their natural position ; if rigid, a slow and gradual extension is to be kept up by splints and bandages until our end is accomplished.

3. Extension is to be kept up some time after the completion of the cicatrix, and if new fræna or bands form they must be divided.

II. *Prominent cicatrix—Excision.*—When the cicatrix is too *prominent*, forming, as it sometimes does, a most shocking deformity, and often causing neuralgic pains, there are several plans employed for its removal ; and as there is rarely any unnatural contraction of the parts beneath, the elevation being almost entirely confined to the skin, all the operations in use are limited in their extent to this tissue. The one most to be relied on is that proposed by Dupuytren, in which there are three things to be observed.

1. The projecting point is to be sliced off on a level with the skin.

2. The edges of the wound are to be kept apart by appropriate machinery.

3. The surface of the wound is to be frequently cauterized with argent. nit., so as to keep it rather below the level of the integuments.

Instead of slicing off the cicatrix, others, as Higginbottom, Cleghorn, &c., prefer the application of a caustic, by which the prominence is *sloughed out*. The nit. of silver, the chloride of zinc, nitric acid, and arsenical paste have all been employed ; but it is obvious that this process is more painful, more tedious, and more likely to leave a bad scar, than that recommended by Dupuytren, and should consequently be rejected.

III. *Extensive adhesions.*—When the deformity consists in adhesions by which parts are approximated that should remain separated, or others separated that should remain in contact, numerous operations have been proposed.



Dupuytren's practice was as follows :—

1. After having divided the adhesions, he dissected them freely to beyond their origin.

2. Then he drew the parts asunder.

3. Methodical and constant pressure was maintained on the point whence the cicatrix must proceed, which is always at the angle of union of the parts.—(*Clin. Chir.* tom. ii. p. 69.)

This plan succeeds in some cases, but very often fails.

In consequence of this operation so frequently failing in the accomplishment of a cure, Sir James Earle, and Delpech of Montpellier, revived the operation of Hildanus, which consists in—

1. Cutting out the cicatrix.

2. In bringing the edges of the wound together so as to cover the raw surface from which the cicatrix was removed.

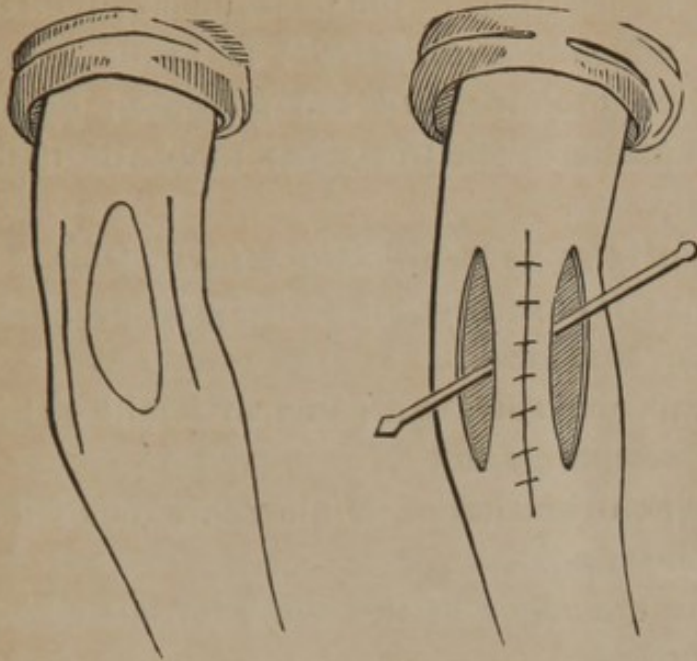
3. In extending the part by splints and bandages, and keeping them in this condition while cicatrization was going on, and for some weeks afterwards.

By this plan the contraction takes places in a lateral direction, and not in the long axis of the part upon which it is performed, and the cicatrix is soft, linear, moveable, and as extensible as natural integument. This is a favourite operation with Brodie, James of Exeter, Hodgson, and many others, and whenever practicable is probably as good as any that can be devised ; but where the cicatrix is broad, irregular, situated on the neck, or different parts of the face, it is obviously a method altogether improper.

I have succeeded, by slightly modifying this operation, in curing a very extensive cicatrix, involving the arm and forearm, by which the whole member was rendered useless. After cutting out the cicatrix, as advised by Hildanus, I found it impossible to draw the edges of the wound over the raw surface and it at once occurred to me that the only method by which I could secure success would be that which I have frequently resorted to in the operation for cleft palate, when there was difficulty in approximating the edges of the



cleft, and which consists in making *lateral incisions* at



some distance from the edges of the tissue to be displaced.\* Doing this, and then drawing the wound together, I covered the raw surface perfectly; and then dressing the two lateral wounds with warm water dressing, made them unite by granulation. The opera-

tion succeeded most beautifully, and may be resorted to in many similar cases.

A plan, the principle of which was clearly recognized by Celsus, has been put into execution by my friends, Drs. J. Rhea Barton, and G. W. Norris, and also by myself, in extensive cicatrices about the neck, without, however, deriving much benefit from its employment. The operation consists in—

1. Making an incision through the integuments at some distance from the origin of the cicatrix; in other words, in perfectly sound skin.

2. In dissecting up the skin and cicatrix as far as possible, without making any new incisions in the skin itself.

3. In the separation of the divided parts, so that the cicatrix slides from its original position, leaving a raw surface to heal by granulation. The operation is severe, and though sometimes useful, is not much to be relied on in cases of extensive contraction.

\* This is the same as the urethro-plastic operation practised by Dieffenbach; and of which there is a description and figure in the British and Foreign Medical Review, for April, 1839, p. 413.



The operation, which of all others, is most entitled to our confidence, especially in cicatrices of the neck, cheek, eyelids, nose, lip, is that in which "*autoplasty*" is brought into service. In all such operations, we are governed by the same principles, and pretty much the same mechanical details. They consist in,

1. Dividing the cicatrix so as to produce a raw surface, in some part of its extent ; or cutting it out entirely, as proposed by Hildanus.

2. In applying to this raw surface a piece of healthy skin taken from the neighbouring parts.

3. In attaching this skin by suture to the margins of the wound in which it is inserted.

4. In approximating the edges of the wound, from which the skin has been removed.

5. In separating, by appropriate agents, the parts too closely approximated, and keeping them in this condition, some time after the flap has united.

6. In applying oleaginous frictions, and motion to the new made parts to give them flexibility and softness.

Many shocking deformities from burns have been relieved by the performance of operations conducted on these principles ; for example, the eyelid, the cheek, the nose, and the lip have all been restored : but I believe I may claim the merit (if merit there be in adapting an old principle to a new operation,) of having first performed an operation of the kind for the relief of extensive cicatrices of the throat.

Mr. Liston, whose surgical acumen and boldness no one will deny, distinctly states, in his last edition of the "*Elements of Surgery*," p. 263, "that such defects are beyond the reach of surgery," and gives a drawing illustrative of the appearance of a person so afflicted—which drawing is almost a fac simile of my case No. 1. I have also carefully examined nearly all the modern works on the subject, and find no mention of such an operation having ever been performed. Velpeau, in his "*Médecine Opératoire*," article "*Cicatrices*



Vicieuses," merely hints at the possibility of such an operation, but this is all.

In very extensive cicatrices of the neck, it may be well to modify the operation so as to take a *flap from each side*, by which means we shall avoid the risk of a very large single flap.

4. *Cicatrices complicated with obliteration of cavities.*—Where the cicatrix produces partial or complete obliteration of a natural opening, as the mouth, &c., incision of the angles, and the introduction of tents *larger* than the *natural* opening, will occasionally do good; but for the most part all such attempts fail, and it becomes necessary to perform the operation of Dieffenbach, an account of which I published in the 18th No. of the American Journal of Medical Sciences, for 1836.

5. *Cicatrices complicated with loss of organs.*—Where organs are entirely destroyed, nothing short of a "plastic operation," the aim of which will be the construction of an organ as much like the original as possible, offers the slightest prospect of benefit to the patient.











