

The anatomist's manual, or, A treatise on the manner of preparing all the parts of anatomy : followed by a complete description of these parts / by J.P. Maygrier ; translated from the 4th French edition by Gunning S. Bedford.

Contributors

Maygrier, J. P. 1771-1835.
Bedford, Gunning S., 1806-1870.
National Library of Medicine (U.S.)

Publication/Creation

New-York : Collins, 1832.

Persistent URL

<https://wellcomecollection.org/works/ab8uukj6>

License and attribution


This material has been provided by This material has been provided by the National Library of Medicine (U.S.), through the Medical Heritage Library. The original may be consulted at the National Library of Medicine (U.S.) where the originals may be consulted.

This work has been identified as being free of known restrictions under copyright law, including all related and neighbouring rights and is being made available under the Creative Commons, Public Domain Mark.

You can copy, modify, distribute and perform the work, even for commercial purposes, without asking permission.

**wellcome
collection**

Wellcome Collection
183 Euston Road
London NW1 2BE UK
T +44 (0)20 7611 8722
E library@wellcomecollection.org
<https://wellcomecollection.org>



THE
ANATOMIST'S MANUAL:

OR

A TREATISE

ON THE

MANNER OF PREPARING ALL THE PARTS
OF ANATOMY, FOLLOWED BY A
COMPLETE DESCRIPTION
OF THESE PARTS.

IN TWO VOLUMES.

VOL. I.

BY

J. P. MAYGRIER, M. D. P.

Professor of Anatomy and Physiology; of Midwifery, and the Diseases of Women and Children; Physician to the Bureau de Charité of the 10th Arrondissement; Member of the Medical Society of Emulation of Paris, of that of *Practical Medicine* in the same city; of the Medical Societies of Liège and Toulouse; of those of *the Sciences* in Maçon, Marseilles, &c.

TRANSLATED FROM THE FOURTH FRENCH EDITION, BY

GUNNING S. BEDFORD, A.M., M.D.

Lecturer on Obstetrics, &c. in the New-York School of Medicine; Member of the Medical Society of the City and County of New-York; of the New-York Literary and Philosophical Society; of the Historical Society, &c.

NEW-YORK:

PUBLISHED BY COLLINS & CO.,

AND SOLD BY THE PRINCIPAL BOOKSELLERS.

1832.

SURGEON GENERAL'S OFFICE
110064
LIBRARY

DEDICATION.

TO GEORGE BUSHE, M.D.

SIR,—

THERE is no one to whom I could with more propriety dedicate the English version of "*Maygrier*" than to yourself. Your career has been a brilliant one—and the reputation you enjoy in Europe and America as a profound anatomist and accomplished physician, is the best test of your merit. For the many kindnesses received from you I beg to return my sincere acknowledgements, and permit me to express the high opinion I entertain of your talents and general erudition.

Very respectfully,

Your obedient servant,

G. S. BEDFORD, M.D.

DEDICATION

TO GEORGE BUSH, M.D.

There is no one to whom I could with more propriety dedicate
the history of my "Progress" than to yourself. You have
been a faithful one—and the reputation you enjoy in Europe and
America as a profound anatomist and accomplished physician, in the
estimation of your merit. For the many kindnesses which you
have bestowed on me, and for the many acknowledgments and favors
which I have received from you, I am ever
most gratefully and respectfully,
Your obedient servant,
G. N. Barstow, M.D.

17

OFFICE OF THE SURGEON GENERAL
LIBRARY

with the authority of the Surgeon General
with the advancement of Philosophy
on this, as on all other subjects of import
overseas to control all things and to avoid passing
unassured course which on mature investigation
The mind of Hunter was of a peculiar cast—he could
not bear the quietude of a dissection unless he had
rather to make it subservient to physiology; but while

TRANSLATOR'S PREFACE.

THE opinion of great men is entitled to respect ; but daily observation proves that master minds sometimes err, and ample evidence of this may be drawn from the assertion of the celebrated Hunter that, "Anatomy and Physiology should always be taught together." Had such an opinion been promulgated before the time of Lord Verulam, we should the less wonder at it ; but the great principle so fully insisted on by him, viz. "that the division of labor facilitates the advancement of science and art," is so amply tested by every day's experience that we are almost amazed at so sweeping a declaration, one too, on so important a topic, and, above all, carrying

with it the authority of a name so intimately connected with the advancement of philosophic pathology. But on this, as on all other subjects of import, it is a duty we owe reason to control our feelings, and to avoid passing unmeasured censure where, on mature investigation, praise should be awarded.

The mind of Hunter was of a peculiar cast—he could not bear the pure details of a descriptive science, he chose rather to make it subservient to physiology; but whilst he was thus befriending his fascinating study, he little thought that he was erecting a superstructure for the temporary downfall of descriptive Anatomy. Thus while he advanced physiology, he actually razed from the very foundation the school of Douglass; and so great has been the prejudice of his Brittanic successors, that, to the present day, Great Britain has not produced a complete treatise on descriptive Anatomy.

In France, where system appears to be the very life of science, *Bichat*, young, energetic, and eminently gifted,

stepped forward, and, with an "eagle eye," not only perceived the defects of his predecessors, but corrected them by establishing *General Anatomy*. Then, Winslow's value was appreciated, and though Bichat seized the gauntlets, and did compete with him on descriptive Anatomy, still the master was successful. Thus the friends of Xavier Bichat must be content that their *beau ideal* did more than any of his predecessors, and in a shorter time—he annihilated the rubbish of antiquity; he established general Anatomy the basis of inductive medicine; and though he did not equal Winslow in descriptive Anatomy, he surpassed all others. He brought to life the work of Winslow—that which was dead and forgotten became a new text book, the model which others have imitated. But for it, would we have had the classic treatises of Boyer and Cloquet? Would we have had, might I say with all propriety, the modern accurate and well digested abridgment of Maygrier? This is enough in commendation of the work, and should it ever pass through four editions in America in the short space of time that it has in France, the profession must be bene-

fitted, and my reward for the labor it has cost me, four times repaid.

G. S. BEDFORD, M. D.

New-York, 57, White-street, }
Oct. 10, 1832.

INTRODUCTION.

IN the study of anatomy, we should consider, 1st, its definition; 2d, its origin; 3d, its progress; 4th, the mode of examining and teaching it; 5th, its general and particular divisions.

1st, Definition.

Preparation of the constituent parts of animals; examination and knowledge of these parts; science of the animal organism.

This triple object is to be attained by constant and attentive dissection of the cadaver, by chemical analyses of animal substances; by experiments on living animals; and, finally, by the comparison of the same parts in different animals, whence is derived a perfect knowledge of the laws of nature for the maintenance of life, and the exercise of the functions which sustain it: this is the special object of anatomy. Considered in the human species, its object is the preservation of man in health.

2d, Origin.

The origin of anatomy, like that of all the other sciences, is lost in the darkness of ages. This, therefore, cannot inspire much interest, in consequence of the obscurity in which it is enveloped. It is said that Apis, an Egyptian prince, favored the study of anatomy; but that Acmeon, who lived some time before Hippocrates, was the first who occupied himself with it in an especial manner. His knowledge of anatomy must have been very limited; for he contended that goats respired through

their ears. However, this opinion, as singular as it may appear, is not as void of foundation as we may be induced to imagine. M. Cuvier very judiciously observes, that Acmeon might have been led into error by the communication of the eustachian tube in the pharynx; in admitting, it is true, the possibility of the external air passing through the different parts of the internal ear.

Empedocles and Anaxagoras followed him; but we have no accounts of them. Democritus next succeeded: an extremely retired life, and a profound study of the various branches of natural science, obtained for him such celebrity, that his cotemporaries, astounded at his extensive learning, and supposing him to be mad, consulted Hippocrates, who replied: *He whom you believe to be mad is the wisest of you all.*

Aristotle, who lived about this period, was much occupied with the study of animals; but his investigations, directed chiefly to natural history, did not tend to the advancement of human anatomy, properly so called. It is to Diocles that are due the first notions on the art of dissecting animals, although the works of this physician, who is believed to have been cotemporary with Plato, have not reached us. Such are the men who have fixed, as it were, the origin of anatomy. But as it is important that we should be acquainted with its progress, I shall now present a table by which its different advances may be ascertained. In order to render this exposition more perspicuous, and establish a certain order, I shall assign to anatomy four memorable epochs; during which, cultivated with great ardor and success, its progress has been unequivocal.

3d, Progress.

First Epoch.—This refers to the age of Erasistratus and Herophylus. These two celebrated physicians, cotemporaries of Hippocrates, but whom certain writers state were born a long time after the father of medicine,

were closely engaged in the study of anatomy. They were both pursued and persecuted for having dissected human bodies. It is even said that they carried their boldness, or rather their enthusiasm for anatomy, so far as to dissect living men. This is an error, accredited by the ignorance of the age in which Herophylus and Erasistratus lived, and by that love of the marvellous which is the ordinary partage of the multitude. How can it be conceived, that men, so distinguished as Herophylus and Erasistratus, regardless of every sentiment of humanity, would have thus exposed themselves to the fury of their cotemporaries, who considered the simple violation of *cadavera* a crime, for which death alone could expiate?

They determined on a visit to Alexandria, in order that they might there practise their profession, and enjoy the facilities of dissection, under the protection of the kings of Egypt.

Hippocrates, who belongs to the first epoch, likewise joined to his extensive knowledge the science of anatomy. We find among his works a treatise, incomplete it is true, on this science, but which is elaborate for the times in which he lived.

If it be true that Hippocrates lived a long time before Herophylus and Erasistratus, he could not have been aware of the valuable labors of these last in anatomy; and what he has left us on this subject, in his writings, should be still more precious.

From the time of these distinguished men to the age of Galen, that is, during the space of nearly seven hundred years, the science of anatomy was but little cultivated, and its progress was necessarily retarded. We meet only with a few facts scattered here and there, but which were far from giving a new face to the science. It was necessary that an individual, endowed equally with an active genius and extensive knowledge, should deliver himself up entirely to the prosecution of anatomy. Such was Galen, who was the glory of this science.

Second Epoch.—Physician to the emperor Marcus Aurelius, Galen gave a new impetus to the history of organized beings. He travelled considerably, and thus derived extensive knowledge, by which he enriched his country. He possessed great address in dissection, and was very skilful in his experiments on animals: of this we may have some idea from the facility with which he destroyed the voice, by the neat and prompt section of the recurrent nerve. We should, however, read his descriptions with a certain reserve, for he most frequently employed animals in his anatomical researches, and especially monkeys. We may convince ourselves of this fact by recollecting the astonishment he exhibited at the sight of a human skeleton. In his time, it was usual to travel to Alexandria, in order to view human bones; which, as has been remarked by Vicq-d'Azir, it would have been easier to prepare at Rome. But it is well known what a religious respect the Romans entertained for their dead, and the attention they paid to the funerals of the deceased. The efforts which Galen made in order to increase his knowledge in anatomy are, consequently, more commendable. We will find in his book, entitled *De usu Partium*, the result of his anatomical researches.

The most distinguished physicians of this epoch were, Asclepiades, Themison, Thessalus, Celsus, and Cœlius Aurelianus.

After the death of Galen, a dark veil was thrown over all the sciences. The continual wars among the people of the opposite extremities of the globe, the descent of the Goths, and of all the inhabitants of the north, on the fertile and temperate plains of the south, and especially the pillaging of Rome, produced the most horrible barbarity, and the sciences were entirely forgotten. Anatomy, especially, more than any of the others, felt the effects of this interruption; and nearly fourteen hundred years elapsed before it again shone forth with any sort of brilliancy.

Third Epoch.—This epoch commences from the sixteenth century. It is due to Vesalius, who was justly named the great Vesalius, the father and restorer of anatomy. He taught at Pavia, a city celebrated for its university. His attainments were immense; and his great work was written at twenty-nine years of age. All his labors referred to the science of human anatomy. His descriptions are perspicuous and accurate, and, as it were, complete, at least as regards the bones and muscles. His work is ornamented with very elegant plates.

Like Erasistratus, he was accused of having dissected a living body. The family of the deceased was powerful; and the enemies of Vesalius seized this opportunity to inflict upon him the severest reproaches. It is stated that chagrin hastened the termination of his life, and that he died on his return from Palestine, whither he was obliged to go in order to expiate the pretended crimes which calumny had generated against him.

Nearly at the same epoch there arose a number of great men, who, cultivating anatomy with the greatest success, caused it to make very rapid progress. The most celebrated were, Columbus, Fallopius, Fabricius, Casserius, Eustachius, Sylvius, &c.

Fourth Epoch.—The first epochs of anatomy have merely presented us with this science in its cradle, and reduced, as it were, to a very small number of facts, which it was easy to fix on the memory, without the aid of any method; but in proportion as it became enriched with new discoveries, and the descriptions were more faithful and detailed, authors began to feel the necessity of a method, which would present the science under a general point of view, and free it from the shackles which until then had opposed its advancement. It remained for the illustrious Bacon to demonstrate, and convince the world that it was impossible to progress in the sciences, and especially in anatomy, without the aid of a proper

method. What he had conceived, Winslow executed, with a success, the glory of which is not diminished, notwithstanding the splendid productions of modern anatomists. I date, therefore, the fourth epoch of anatomy from the middle of the last century. The immortal work of Winslow will preserve and render it forever memorable. No writer, before him, had presented the science of anatomy under such a luminous point of view. Beauty and elegance of description, ingenious method, order, perspicuity, and exactness, are pre-eminent in his book; and, in this respect, descriptive anatomy, at least, has attained perfection.

During the long interval which elapsed between the time of Vesalius and Winslow, several individuals of great merit made anatomy the object of their especial study, and enriched it with numerous facts and important discoveries. The gratitude of posterity will not permit to pass unnoticed the names of Sanctorius, Riolan, Spigel, Harvey, Pecquet, Glisson, Stenon, the two Barthollius, Willis, Vieussens, Ruysch, Malpighi, Morgagni, Paluin, Albinus, Heister, Duverney, Lieutaud, Senac, and numerous other learned anatomists, who confer honor on the science of man.

But a fifth epoch is at hand, more extensive, more philosophic, more majestic in its march, and more interesting in its results. It is, especially, to the immortal works of Haller, Buffon, Daubenton, Vicq-d'Azir, Sabatier, and Desault, that we are indebted for it; and their worthy successors, Cuvier, Walter, Boyer, Sœmmering, Chaussier, Blumenbach, Zinn, Scarpa, Bichât, Dumas, Laumonier, Meckle, Portal, Dumeril, Richeraud, Dupuytren, Ribes, Larrey, &c., justifying the high destinies which await them, will give to the present age an impetus, the object of which will be the complete knowledge of nature.

4th, Mode of studying and teaching Anatomy.

In the present state of anatomical science, it is very difficult to say what is the best mode to pursue, in order to cultivate it, and hasten its progress. This branch of medicine takes such a flight, its discoveries are so numerous, its facts so multiplied, the points of view under which it may be embraced so fruitful, that we can only offer some general rules. The teaching of anatomy having for its object the instruction of students, professors of this science should adopt a plan, a uniform method, from which their pupils may derive the greatest advantages. For if modern anatomists, in their noble enthusiasm and brilliant conceptions, do not specify some object towards which all their labors should be directed, then I am fearful that, of such united efforts to arrive at a perfection so much desired, there will only remain the painful certainty of not having known the true means of attaining it. I most ardently trust that my fears in this respect may prove chimerical.

Being no longer able to separate anatomy from physiology, and this latter being the result of knowledge derived from the former, it is absolutely necessary for the professor of anatomy, charged with the direction of students, to unite these two branches of the same science. But the facts which appertain to both are so numerous, that it would be very difficult to teach them together.

This truth has been experienced by all those who have been occupied in teaching anatomy; it is for this reason that anatomy and physiology each form a body of distinct and separate doctrines, having the same object, but proceeding by different channels. I shall not now discuss the question, whether it is more advantageous for science and more useful to students, that physiology be taught separately, or combined with anatomy; time and experience will decide in favor of one or other of these methods, the excellence of which will be justified by its success.

As it is not my intention to write a complete treatise of anatomy, but merely a work on anatomical preparations, and as, in the description of the different parts, I have pursued a plan different from that adopted by modern anatomists, it is quite unimportant what method I myself follow ; or, rather, I have imagined one peculiar to myself, and adapted, moreover, to the work which I now submit to the public. In a word, I have nothing in common with other books on anatomy, except the matter which is treated of in them. The object is not the same. It may, however, be proper to state in this place, that if I contemplated writing a voluminous work, in which I would wish to detail every thing which has connection with the science of man, I should certainly prefer the plan proposed by professor Chaussier, of which he has exhibited such fine developements in his "*Tables Synoptiques.*" But wishing only to prove useful to the student ; and the books, which serve him as guides in his anatomical labors, having another plan, I have thought it best to adhere to these latter. I shall follow particularly the steps of Winslow, whose work appears to me invaluable. Desault, who has such right to our gratitude, has, in my opinion, failed in his purpose, by deviating from the plan and method of Winslow. It would have been a very happy idea for him to have taken Winslow as a model, and to have issued a new edition of this work, corrected, and augmented with the fruits of his own knowledge, and thus to have united his name to a book, which his can never consign to oblivion, and which will endure as long as anatomy shall be cultivated.

5th, General and particular divisions.

The ancients divided the study of anatomy into skeletology and sarcology. Under the first head, they treated especially of the bones, but they likewise embraced the examination of the cartilages, ligaments, periosteum,

synovia, medullary matter, and juice. The second comprehended the history of all the soft parts, which they divided into myology, splanchnology, angeology, neurology, and adenology. This division, abandoned and again adopted by modern anatomists, has been followed, in part, by Sabatier: Desault and Bichât have neglected it; but professor Chaussier has preserved it in all its purity. I believe it to be correct and very reasonable; it is the one which I prefer. Winslow, in pursuing servilely the plan of Vesalius, has given evidence of a culpable condescension, and the general division of his *Anatomy* presents some errors. But as regards his particular descriptions, modern anatomists have offered nothing better than Winslow. M. Portal has approached him very close in his *Anatomie Medicale*, and his work is indebted to him for a great part of its reputation. Thus, to combine the general modern methods with the particular descriptions of Winslow, appears to me to be the best means of conveying an accurate and precise idea of the different parts of anatomy. We will find in the *Traité d'Anatomie*, of M. Boyer, a model of this kind, at the end of the volume on myology, under the title of *Myologie Analytique*.

Although my own dissections have been of great use to me in my present *Treatise*, and notwithstanding that I have scrupulously seen and verified for myself every thing that is contained in it, yet I have not neglected to consult the works of modern anatomists, and profited by the lights with which they have furnished me. Moreover, eighteen years, employed partly in the study of this science, and partly in teaching it, will, I think, entitle me to the confidence of those for whom this work is intended.

In the study, as in the teaching of anatomy, there is science and art. The first, which aims at perfection, is found exposed with the greatest accuracy in works which enjoy a just celebrity. The art of dissecting, on the

contrary, though recently cultivated with great success, is no where described with sufficient method or detail. It is true, that persons engaged in anatomical dissections in the private amphitheatres, possess this art in a very high degree of perfection; but the great majority of students are ignorant of its principles. Discouraged by the difficulties attending dissection, they often abandon the study of it, and their progress in the other branches of medicine suffer singularly from this neglect. It is for such, especially, that I have composed this *Treatise*.

I shall dispense with indicating those minute preparations, the fruit of patience and time, which please the eye, and are but little instructive; necessary, when we are obliged to present them to the view of a numerous auditory, or when they are destined to ornament anatomical cabinets, in which they are to be preserved. I shall, therefore, confine myself to those details which are indispensable.

INDEX.

VOL. I.

INTRODUCTION	9
PRELIMINARY EXPOSITION	25
Division of Anatomy	25
The bones in general and the manner of preparing them in order to form skeletons	25
General Considerations on the conformation and struc- ture of the bones	29
Articulations	37

SKELETOLOGY.

Bones of the head	39
Bones of the cranium	39
Anatomical preparation	39
Description	41
Bones of the face	48
Anatomical preparation	48
Description	49
Bones of the trunk	59
Anatomical preparation	59
Description	60
Bones of the extremities	69
Anatomical preparation	69
Bones of the superior extremities	70
Description	70
Bones of the inferior extremities	78
Description	78
Connection of bones	85
Ligaments in General	86
Anatomical preparation	86
Ligaments in particular	87
Temporo-maxillary articulation	87
Description	89
Articulations of the vertebral column	92
Anatomical preparation	92

Special or particular articulations of the vertebral column	92
Occipito-atloïdien articulation	93
Occipito-axoïdien articulation	94
Atloïdo-axoïdien articulation	95
Common and general articulations of the vertebræ	96
Description	99
Articulations of the chest	106
Anatomical preparation	106
Description	108
Articulations of the pelvis	111
Anatomical preparation	111
Description	113
Articulations of the shoulder	119
Anatomical preparation	119
Description	120
Articulations of the superior extremities	123
Anatomical preparation	123
Description	126
Articulations of the inferior extremities	133
Anatomical preparation	134
Description	135
Cartilages in general	146
Fibro-cartilages	148
Periosteum	148
Marrow and medullary juice	149
Synovia	151

MYOLOGY.

Preliminary exposition	151
Introduction to the art of dissecting	157
Particular dissection of myology	167
Muscles in particular, and divisions of Myology	169
First region, trachelo-dorso-lumbo-spinal	170
Anatomical preparation	172
Description	181
Second region, Abdominal, cutaneous or superficial	194
Muscles of the bas-ventre	194
Anatomical preparation	194
Description	200
Third region. Thoracic muscles on the anterior part of the chest	204
Anatomical preparation	205
Description	206
Fourth region—Lombo-abdominal. Profound muscles of the abdomen and generation	209
Anatomical preparation	209
Description	213
Fifth region, costo-thoracic. Muscles on the sides of the trunk	223

Anatomical preparation	224
Description	225
Sixth and seventh regions, Epicranial and facial. Muscles on the summit of the head and face	227
Anatomical preparation	228
Description	234
Eighth region, Temporo-zygomatic. Muscles on the lateral por- tions of the head, and those which surround the articulation of the maxilla	245
Anatomical preparation	245
Description	247
Ninth region, Superficial cervical. Muscles on the anterior part of the neck	250
Anatomical preparation	250
Description	253
Tenth and eleventh regions, Lingual-staphylo-pharyngienne. Muscles of the tongue, pharynx, and velum palati	259
Anatomical preparation	259
Description	265
Twelfth region, Laryngean. Muscles of the larynx	273
Anatomical preparation	273
Description	274
Thirteenth region, Profound cervical. Deep-seated muscles on the anterior part of the neck	277
Anatomical preparation	277
Description	278
Fourteenth and fifteenth regions, Scapulo-humeral. Muscles of the shoulder and arm	283
Anatomical preparation	283
Description	288
Sixteenth region, Radio-cubital. Muscles of the fore-arm	294
Anatomical preparation	295
Description	302
Seventeenth region, Carpo-metacarpienne. Muscles on the palmar and dorsal surfaces of the hand	314
Anatomical preparation	315
Description	319
Eighteenth region, Coxo-femorale. Muscles on the posterior part of the pelvis, superior and posterior of the thigh	326
Anatomical preparation	326
Description	332
Nineteenth and twentieth regions, Anterior and internal femoral Muscles	340
Anatomical preparation	340
Description	346
Twenty-first and twenty-second regions, Anterior and posterior tibial. Muscles on the anterior and posterior part of the leg	352
Anatomical preparation	353
Description	358

Twenty-third region, Tarso-metatarsienne. Muscles on the	
back and sole of the foot	366
Anatomical preparation	367
Description	371

VOL. II.

SPLANCHNOLOGY.

Preliminary exposition	3
Particular preparation of splanchnology	7
Digestive organs	8
The mouth, and its accessories	9
Anatomical preparation	9
Description	12
Arrière-bouche	15
Anatomical preparation	15
Description	16
Alimentary canal	17
Anatomical preparation	17
Description	22
Biliary and pancreatic organs	31
Anatomical preparation	31
Description	36
Peritoneum, mesentery, and epiploons	42
Urinary organs	43
Anatomical preparation	44
Description	48
Respiratory and circulatory organs	50
Anatomical preparation	51
Description	58
Organs appertaining especially to the chest	60
Mammæ	60
Thymus	61
Lungs	61
Heart	64
Encephalic organs, organs of sense	68
Encephalon	71
Anatomical preparation	71
Description	82
Meninges or membranes of the brain	90
Eye and its appendages	95
Anatomical preparation	95
Lachrymal organs	97

Muscles of the eye	98
Description	104
Organs of hearing	115
Anatomical preparation	116
Description	121
Nose	126
Genital organs of the male and female	129
Anatomical preparation	130
Description	134
Skin	145
Anatomical preparation	145
Description	147

ANGEOLOGY.

Preliminary exposition	149
Particular dissection of angeology	151
Arteries in particular,—carotids	156
Anatomical preparation	157
Description	164
Internal carotid	167
Anatomical preparation	167
Description	170
Subclavians	171
Anatomical preparation	171
Description	177
Descending aorta	182
Anatomical preparation	182
Description	188
Arteries which arise from the bifurcation of the aorta as far as the crural	195
Anatomical preparation	195
Description	199
Arteries of the inferior extremities	202
Anatomical preparation	203
Description	206

VEINS.

Superior vena cava	215
Anatomical preparation	215
Description	218
Inferior or abdominal vena cava	221
Vena azygos, pulmonary and cardiac vein	225

NEUROLOGY.

Preliminary exposition	226
Particular dissection of neurology	227
Nerves in particular	230

Nerves of the brain	230
Anatomical preparation	230
Description	252
Intercostal.—Great sympathetic	261
Anatomical preparation	262
Nerves of the spinal marrow.—Cervical, dorsal, lumbar, and sacral	265
Anatomical preparation	265
Description	266
Vertebral nerves	268
Brachial plexus and nerves of the superior extremities	271
Anatomical preparation	271
Description	273
Lumbar plexus	278
Anatomical preparation	278
Description	279
Sciatic plexus, and nerves of the inferior extremities	280
Anatomical preparation	280
Description	280

LYMPHATIC VESSELS.

General Considerations	283
Summary exposition of the lymphatics	288

ERRATA.

- Vol. I. p. 212, line 19, for *affected* read *effected*.
 “ p. 227, line 28, for *quadratis* read *quadratus*.
 Vol. II. p. 150, line 2, for veins destined read *veins are destined*.
 “ “ line 20, the semicolon should be after *first*.
 “ “ lines 27 and 28, read *arrangements claim*.

THE
ANATOMIST'S MANUAL.

THE study of man is composed of three distinct branches of the same science. The first has for its object, the knowledge of the parts constituting the animal economy, and is properly called anatomy; as a descriptive science, it appertains to natural history. The second embraces the study of the phenomena and acts of life; these last receive the name of functions, and the science, which results from them, is termed physiology. The third comprehends the derangements which occur, either in the exercise of these functions—this is medical physiology: or in the organs in which the functions are found to occur—this is pathological anatomy. Of these three branches, we shall only treat of the first.

It is divided into skeletology and sarcology: this last is subdivided into myology, splanchnology, angeology, neurology, and into the history of the lymphatic vessels. Skeletology comprehends the history of the bones, cartilages, ligaments, periosteum, and the pretended synovial glands.

The student who wishes to study anatomy should be provided with a skeleton and the bones in their separate state. In order to procure these last, he should, if possible, prepare them himself. The methodical arrangement of the bones, for the purpose of forming a skeleton, demands certain rules, which we shall allude to hereafter.

All *cadavera* are not equally fit for the preparation of bones ; there is a choice to be made, and without this precaution we would employ much time in a very unprofitable manner. In order to obtain them such as we desire, we must select an adult subject, from 25 to 30 years of age, at least five feet four inches in height, infiltrated if possible, or one whom a protracted disease has gradually conducted to the grave. We should be careful that no apparent deformities exist, and that the individual has not been subjected to any particular virus, which may have affected the integrity of the tissues. The preparation of the bones requires that we detach them, in the first place, from the soft parts, and separate them from their articulations : rubbed with a dry and coarse cloth, or with a brush, they are afterwards to be put into water, which must be renewed from time to time. At the end of two or three months they should be taken from the water, and exposed for some days to the fresh air, and after this, if possible, to the sun. The vertebræ, the bones of the pelvis, the ribs and sternum should not remain in the water as long as the other bones, for their tissue will become altered and destroyed by too long maceration. In order to prepare the sternum we must detach it with the intercostal cartilages, near their union with the ribs, and it must be dried without subjecting it to maceration.

One mode of making the bones very white in a short time, is to allow a portion of the flesh to be destroyed by worms. When they are nearly deprived of the soft parts, they should be macerated for about one month : then they are to be withdrawn from the water, and allowed to dry.

In our amphitheatres, we are in the habit of having recourse to a process still more expeditious. After having partially taken off a portion of the flesh, the whole, with

the exception of the sternum, is placed in a cauldron filled with water, which boils for seven or eight hours. The bones when withdrawn are in an instant freed from the soft parts which cover them. They are afterwards put into ordinary water for seven or eight days, and then taken out for the purpose of being dried.

Besides those just mentioned there are other modes of making the bones very white, and with equal rapidity; this may be done by adding lime, pure potash, or soap, whilst they are boiling: but these preparations demand an experienced hand, as likewise a knowledge of the ingredients and doses, which are necessary to be employed. I deem it my duty not to enter into any detail in reference to this matter, which, without being foreign to my subject, is at least to the plan which I have proposed.

After the bones have been well macerated, and sufficiently exposed to the air, we may use them for the purpose of forming a skeleton, or keep them in an isolated state with a view to study them separately. The art of putting together a skeleton supposes a perfect knowledge of the bones, without which we cannot place them in the respective relations which nature intended. This requires care, patience, address, and a certain dexterity, which all students do not possess: and for this reason, I would recommend them to have recourse to those of their companions, who are more especially acquainted with this business.

But when we wish to study osteology, it is necessary to have more than one kind of skeleton; we must, besides the one of which we have just spoken, and which is called *artificial skeleton*, possess another of the same size, the different bones of which are connected together by natural bands, and which is termed *natural skeleton*. In

fine, it will be requisite, for the same object, to have the skeleton of a fœtus, child, and aged person. If there be a desire to acquire a knowledge of comparative anatomy, it will be proper to procure skeletons of animals, in order to compare them with that of man from which great advantage will be derived. I do not fail, as far as I can, to have recourse to this sort of comparison in my lectures on anatomy. Many facts in physiology would yet be unknown were it not for the aid of comparative anatomy.

The natural skeleton does not require so much care, nor does it demand the same time for its preparation as the artificial skeleton. For the first, we select a cadaver presenting the same characters as when we wish to macerate the bones. It will suffice to free it from the soft parts, being careful not to destroy the articulations. After having dried it, it must be covered with several coats of varnish, and then preserved for study.

Young subjects are generally selected for the preparation of natural skeletons. But whatever may be the age of these last, the mode of evacuating the cranium is different from that employed in the artificial skeleton. As the foramen magnum is not exposed in the natural skeleton, and as the articulations are to be preserved entire, the brain cannot be discharged by this opening; but it may be easily emptied by removing from the lateral parts of the cranium two oblong portions, from before backwards, at a distance of two fingers breadth from each other, in order to protect the covering of the brain. When the cerebral mass is evacuated, it will be proper, in preserving the integrity of the meninges, to employ brass wires for the purpose of attaching the two portions, which have been removed: this will permit us to uncover at pleasure the interior of the cranium.

For the preparation of a natural skeleton in the fœtus, we may effect the discharge of the cerebral mass, by the separation of the parietal bones at their suture, or through one of the fontanelles.

We are to consider in the bones an external conformation and an internal structure.

A. The external conformation embraces:—

1st. *The name.*—Though it does not always correspond with the object it represents, yet we must preserve it, for otherwise there would be confusion in this science. It will suffice to indicate the name of each bone as we treat of it.

2d. *The number.*—It is absolute or relative. The absolute number of bones is composed of all those entering into the formation of the skeleton: they amount commonly to 240. They are enumerated in the following manner:

In the head.—The frontal, parietal, occipital, temporal, ethmoidal and sphenoidal, for the cranium; the maxillary, malar, bones proper to the nose, unguis, vomer, and inferior maxillary, for the face; to these are added thirty-two teeth and the os hyoides.

In the trunk.—Twenty-four vertebræ, for the spinal column; twenty-four ribs, twelve on each side, and the sternum, for the chest; the two ossa innominata, the sacrum, and coxycx, for the pelvis.

In the superior extremities.—The scapula and clavicle, for the shoulder; the humerus, for the arm; the cubitus and radius, for the fore-arm; the eight carpal bones, scaphoides, semilunare, pyramidale, and pisiforme, for the first range; trapezium, trapezoides, magnum, and unciforme, for the second range; five metacarpal bones, and five fingers, each composed of three phalanges, except the thumb, which has but two, for the hand.

In the inferior extremities.—The femur, for the thigh ; the tibia and peroneus, for the leg ; the rotula, for the knee ; the seven tarsal bones, which are : the calcaneum, astragalus, cuboides, scaphoides, and three cuneiformia ; the five metatarsal bones, and the five toes, each composed of five phalanges, except the large toe, which has but two, for the foot.

The relative number refers to the place, which the same bones occupy in the skeleton ; consequently they are *double* or *single* : the latter are always found situated in the centre of the skeleton ; they are regular in their conformation and represent perfectly on the right the objects placed on the left : divided in their middle, they are exactly similar to the *double bones* situated on the lateral parts. These, which sometimes are in contact with each other, as the parietal, palatine, &c., are most generally separated by the *single bones*, and are even situated at considerable distance from each other, as the bones of the extremities.

3d. *The position.*—It is absolute or relative : the first indicates in a general way the place occupied by the bone in the skeleton : the second determines its relations. *Example of the absolute position* : the coronal or frontal is situated in the head. *Example of the relative position* : the frontal is placed before the parietal, above the superior maxillary, &c. In order to comprehend perfectly the theory concerning the position of bones, it will be necessary to suppose the skeleton surrounded by seven lines or planes, which are : the anterior, the posterior, the two lateral, the superior, the inferior, and a seventh, which, commencing at the sinciput, and passing directly through the skeleton from above downwards, will terminate between the feet. In proportion as a bone, or a part of a bone, approaches

nearer to one of these planes, we will add to the part described the term of anterior, posterior, &c.

4th. *The size.*—Among the bones, some are large, some small, and others again possess a medium bulk; but the terms large and small are abstractions, and always suppose that several objects of a different size, placed in correspondence, are compared with each other. Thus, when we say the femur is a large bone, it is because, at the same moment, we compare it in idea with other bones of the skeleton which possess less dimensions, and it is for this reason, that we say bones are of a middle size or small.

According to this, the large bones of the skeleton are the femur, the tibia, the peroneus, the humerus, and the haunch bones: the bones of the fore-arm, the ribs, the large bones of the cranium, the sternum, the scapula, and clavicle, are of a middle size: and we range in the class of small bones all those not comprised in the two first.

5th. *The figure.*—It is by the aid of geometry that the particular figure of each bone has been determined; it is square, triangular, prismatic, cubic, long, short, flat, &c. This figure is likewise modified by the general disposition of their external conformation, and by the particular arrangement of the parts observed upon them: thus the *single* bones are called regular or symmetrical, for the reasons already stated, and the contrary is found to exist in reference to the *double bones*

6d. *The direction.*—It is the same with the direction of bones as with all other bodies in nature: consequently, they are in a vertical, horizontal or oblique direction. The long bones of the extremities are vertical; the clavicles are horizontal; the ribs, sternum, &c., are oblique. Each part of the same bone, isolated and distinct, may likewise

have a particular direction, independently of that of the bone itself. *Example*: The inferior maxillary is in a horizontal direction; but its coronoid apophysis is vertical.

Besides these general considerations, the bones present on their external surface depressions or cavities, elevations or eminences: the first are articular or not: the articular are profound or superficial. The profound bear the name of cotyloid cavities: the superficial, that of glenoid.

The non-articular cavities receive the names of fossæ, foramina, passages, grooves, sinuses, furrows, sinuosities, canals, aqueducts, &c., according as the cavities of the bones resemble those I have just indicated, and sometimes even according to arbitrary convention, but consecrated by usage.

The eminences are also articular or not: the first are called heads, when their surface is perfectly rounded; and condyles, when they are flattened in one sense and round in the other.

The non-articular eminences are called spines, crests, coracoids, coronoid, mastoid, styloid, odontoid, clinoid projections, &c., although very frequently there is not the slightest resemblance between the eminence and body with which it is compared.

B. The internal structure of bones embraces:

1st. *Their color*.—It varies in the different ages of life. It is reddish and more marked in young subjects on account of the superabundance of all the fluids; in proportion as life advances it turns pale, and in old age becomes white: it is of a greyish-white in the adult. The bones of the female are whiter than those of the male. In those individuals who have died in consequence of a protracted

disease the bones are of a lighter color than in such as have been carried off by a violent and sudden malady.

2d. *Their density and thickness.*—The one is always in an inverse proportion to the other. The first is not very evident in the bones of young subjects; but the second is considerable: the contrary is observed in old persons. The density being the result of the intimate union between the lamina of bone, is, as it were, entirely wanting in very young subjects, since at this early period their tissue is easily penetrated by an infinity of vessels pouring a quantity of fluid of every kind into it. With age, the osseous elements become superabundant. A great portion of the vessels being compressed, and identified with the bone itself, no longer receives any fluid, and every thing tends to afford to the bones of aged persons a remarkable density, and to diminish their thickness.

In the long bones, the density is in the centre, and the thickness at the extremities; in the flat bones the density has the same situation, but the thickness is at the circumference: in the short bones, this disposition is not so uniform. We remark that the greatest density of these bones is situated in those portions which sustain the most weight.

3d. *Their elements.*—We shall allude to the details of this article when we treat of the developement of bones.

4th. *Their cavities and vessels.*—Although the weakness of our senses, and the imperfection of our instruments do not permit us to trace very remotely the cavities and vessels of the bones, yet we are aware that their tissue, as compact as it may be imagined, is nothing more than a network, into which an incalculable quantity of blood-vessels of every sort enters: the sensibility manifested by old persons, even in their most advanced age, when these organs

are affected by disease, or when they are the seat of operations, removes all doubt as to the truth of this assertion.

In examining here that only which is known and avowed by all anatomists, we will find three kinds of cavities for the bones, and an equal number of vessels penetrating them. I except the large cavity of the long bones. These cavities receive the names of first, second, and third classes. In the large long bones, and in the flat bones, the cavities of the first class are perceived without any difficulty: they are situated at a short distance from the centre of the bone: they give passage to the vessels of nutrition. The cavities of the second class occupy the extremities of the long bones, the circumference of the flat bones, and all the external surface of the short bones. The cavities of the third class do not appear to penetrate the interior of the bone: distributed on their external surface, these cavities are very numerous, and the vessels entering them exceedingly delicate.

C. Developement of the bones.—At first pulpy, and as it were mucilaginous, the bones are confounded with the other parts, and cannot be distinguished from them; this continues at least for the first seven days after conception, when each system of organs appears to isolate itself, and presents differences as to the mode of its developement. Before becoming cartilaginous, the bones are in a gelatinous state, and they continue so until after the twentieth day of the first formation of the embryo. After twenty days, they pass rapidly from cartilage, and assume an osseous character; and at six weeks the clavicles and ribs are already osseous: the bones of the cranium, and those of the extremities follow this rapid developement of the clavicles and ribs. Some of the bones of the face, the ver-

tebræ, the sternum, those of the pelvis, the short bones of the hands and feet are the slowest in ossifying, and do not accomplish this process until after birth. Between fifteen and twenty years all the bones are entirely developed; but their growth, which does not increase in length nor thickness, continues until the most advanced old age. The mechanism of the developement of bones is as follows:—When the embryo has acquired a certain degree of force, which occurs about the fortieth or fiftieth day after pregnancy, nature transmits through the vessels going to the bones a solidifying material, to which has been given the name of lime, and even an impure phosphate of lime. This earthy material, destined to give strength and solidity to the bones, is deposited in a uniform manner on some determinate point of cartilage. To this first osseous point there are added fresh quantities of the earthy phosphate which, deposited always in a regular manner, takes the place of the cartilage and ultimately causes it to disappear altogether. The phosphate of lime which, in adult age, constitutes the largest portion of each bone, is not deposited in the bones at their commencement; it is furnished in a secondary manner, and is received in the interstices of the cartilaginous net-work. This truth is fully demonstrated by the experiments of Hèrissant: he plunged a bone, or a portion of bone, into weak nitric acid and allowed it to remain there until it became flexible, and, as it were, cartilaginous: an earthy substance remained in the bottom of the vase, which was nothing else than the phosphate of lime precipitated by the nitric acid.

Three substances appear to result from the developement of bones and the particular distribution of the solidifying matter; but by attending scrupulously to this point, we shall discover but two, namely, a gelatinous and earthy

substance. The first always preserves the particular form and figure of the bone itself; it is the rudiment of the bone: the second is merely a deposition, and may, during life or after death, be separated from it: the urine is sometimes found to be singularly charged with it.

In the natural order, the solid part identifies itself with the gelatinous, then under the form of cartilage, in the following manner:—In the long bones, it appears at first in the centre of the bone, in the shape of a small ring, becoming every day more extended, and eventually it occupies the place of almost the entire cartilage. Nearly the same process takes place at the extremities of the bone; the osseous points approach each other, and they remain for some time at the spot, which unites the head to the body of the bone: this is what constitutes the epiphyses. By a new effort in the growth, the epiphyses disappear, and at twenty years of age there is not one to be found in the whole osseous system.

Things go on differently in the flat bones: the first bony point is observed in the centre, and it gradually reaches the circumference by radii.

In the short bones, the first deposition of ossific matter takes place in some indeterminate point of their surface, until it successively covers the entire bone.

The compact, spongy, and reticular portions result from the particular arrangement of the earthy phosphate, and from the different degrees of adhesion existing among its molecules. The first is remarked in all the bones; it is found principally in their exterior: abundant in the middle portion of the long bones, it is less so at their extremities, where the spongy substance is observed to predominate. It forms in the flat bones two distinct tables, between which the spongy portion is found to exist, and

which is called diploe in the bones of the cranium. In the short bones it presents itself under the character of a very thin covering, these bones being almost entirely formed of a spongy substance. The reticular portion exists only in the long bones, and occupies their interior.

D. Connection of bones.—Two things constitute the connection of bones: articulation and symphysis. The first is the mode of union; the second, the means. Articulation is the approximation of two or more bones by surfaces, which continue always in relation with each other: the particular disposition of these surfaces, their degree of approximation, and the degree of motion peculiar to them, determine the kind and species of articulation. In considering them in their aggregate, two essential points fix the attention and give rise to two distinct classes of articulation: immobility constitutes the character of the first: mobility, on the contrary, is peculiar to the second. Let us first examine this latter; the other will occupy us afterwards.

1st. *Moveable articulation.*—This may be formed by continuous or contiguous surfaces. The first constitutes amphiarthrosis or the mixed articulation of the ancients. We will see examples of it in the articulation of the vertebræ, and of the bones of the pelvis with each other. This species of articulation does not admit of any sliding of the surfaces; and the motion, although obscure, takes place in the substance of the interarticular cartilage. When, in old age, the intermediate cartilage becomes hard or ossifies, the motion ceases.

2. The articulation by continuity of surface is more varied, and, according to the extent of the motion permitted by the

surfaces, it is divided into general or vague, and into alternative or gynglimoid articulation.

The first is called enarthrosis, when a head is received into a cavity, and arthrodia, when the surfaces are nearly even. The articulation of the head of the femur with the cotyloid cavity of the haunch bones is an enarthrosis, and that of the tibia with the femur, an arthrodia.

The gynglimus is angular or lateral ; the first is perfect or imperfect, according as the bones mutually receive each other or not : the articulation of the cubitus with the humerus is an instance of a perfect angular gynglimus : and the inferior maxilla, in its motion upwards and downwards, presents an example of an imperfect angular gynglimus.

The second is simple when the bones only touch by one point ; and double when they touch by two. The articulation of the occiput with the first cervical vertebra furnishes an instance of a simple lateral gynglimus ; and that of the radius and cubitus, of a double lateral gynglimus.

2d. *Immoveable articulation*.—This is termed synarthrosis. This species of articulation is found to exist only in the bones of the cranium. It is called *suture* when the bones are united by profound *engrenures* ; *harmonia*, when these *engrenures* are scarcely perceptible ; *squamous*, when the border of one bone overlaps another, like the shells of certain bivalves ; *gomphosis*, when one bone is received into the deep cavity of another. The ossa parietalia articulate by suture, the ossa unguis by harmonia, the large portion of the temporal by the squamous suture, and the teeth by gomphosis.

The symphysis may be cartilaginous, membranous, ligamentous or muscular. The first is called *synchondrosis* ; the second, *syneurosis* ; the third, *meningosis* ; and the fourth, *syssarcrosis*.

SKELETOLOGY.

The skeleton is commonly divided into the head, trunk, and extremities.

The head is divided into the cranium and face.

M. Chaussier divides the skeleton into the trunk and members. The trunk presents a middle portion and two extremities; the one superior *cephalic*, or the head, the other inferior *pelvic*, or the pelvis. The members are distinguished into thoracic or superior, and into abdominal or inferior. Although we shall not follow this division of M. Chaussier, yet we have adopted his nomenclature through the whole course of this work, in collating it with the ancient.

BONES OF THE CRANIUM.

Anatomical Preparation.

Notwithstanding the different rules which have been given for separating the bones of the Cranium and face without injuring them, it is rare that we are enabled to preserve them in all their integrity; their quantity, the small size of most of them, their want of thickness, the close connection which exists among them, will explain on the one hand the difficulty of separating them, and on the other the facility with which they may be broken. If we desire to detach the bones of the head, we should select a young subject, from fifteen to twenty-five years of age. Before commencing the operation, we should examine whether the interarticular cartilage between the basilar apophysis of the occipital bone and the body of the sphenoid still exists. If it be found that the reciprocal ossification

of these two bones has caused the disappearance of the cartilage, then there will be but little chance of succeeding; the bones will assuredly be broken. In the contrary case, we must proceed to detach the bones, by commencing with the ossa unguis, the inferior cornets, the vomer and the bones proper to the nose; the others being more solid will demand less précaution. After the malar bones are removed, the temporal, occipital, &c. may be separated without difficulty. We should be careful, as much as possible, to preserve the points of contact, in order that we may at pleasure approximate the bones, which articulate with each other. In order to effect this separation quickly it will suffice to fill the cavity of the cranium with dry peas or beans; the occipital foramen must be closed, and the head then plunged into hot water. The beans swell, detach the sutures, and thus separate the bones of the cranium. When the head, of which we wish to preserve the separate bones, is taken from a young subject from eight to ten years of age, for example, it will answer every purpose to let it simply boil in water. This will cause the gelatine and other white juices, so abundant at this period of life, to disappear. The separation of the bones of the cranium and face will then be very easily accomplished, which would not be the case in the head of an individual much advanced in age.

In order to have an exact idea of the capacity of the cranium, it will be necessary to make two sections of the head, the one vertical and the other horizontal. The first is made by carrying a saw from above downwards, and from before backwards from the frontal to the occipital protuberance. In this way, the head will be divided into two equal lateral portions. In the second section, the saw has a horizontal direction from one coronal protuberance to the external occipital protuberance, and from this it is

brought to the coronal protuberance of the opposite side, where it terminates. As regards the preparation of the bones of the head, I have never seen any thing more beautiful than the heads of men and animals, arranged in a particular and quite ingenious manner, in the anatomical museum at Charenton.

Description.

The bones of the Cranium are eight in number. The coronal, two parietal, two temporal, occipital, sphenoid, and ethmoid.

THE CORONAL OR FRONTAL.

Situation and figure.—A single symmetrical bone, situated at the anterior portion of the cranium and superior part of the face, in front of the parietal, above the nasal, maxillary, unguiforme, malar, ethmoid, and sphenoid bones.

Division.—*Anterior*, convex surface: it presents in its middle, and from below upwards, its nasal prominence and spine; above, the line indicating the primitive separation of the bones into two equal portions. On the sides we remark from below upwards, the superciliary arches, covered by a muscle of the same name; the two coronal protuberances; and a large smooth and polished surface, on which is spread the greatest portion of the occipito-frontalis muscle.

Posterior concave surface: it presents in the middle, and from below upwards, the foramen cœcum; above, a prominent line, something like a crest, which is placed at the commencement of the longitudinal sinus: diminishing gradually, the crest terminates in a fossa, which is continued along the parietal bones, and called the longitudinal fossa. On the sides, there are two depressions corresponding to the coronal protuberances, and others which

are less remarkable, resulting from the presence of the brain.

Inferior surface.—The ethmoidal *echancrure* in the centre; in front of the *echancrure*, the transverse suture and the two frontal sinuses separated by a partition, which is sometimes more to one side than the other; on the sides, the two orbital fossæ terminated in front by an arch of the same name. This presents inwards the internal orbital angle, which affords attachment to the great oblique muscle of the eye; without, is observed the external orbital angle: the lachrymal gland is lodged in a small depression situated in the internal portion of this angle.

The *circumference* offers two portions; one superior, which is united to the parietal bones by a deep suture, and an inferior horizontal portion, thinner than the other, which articulates with the sphenoid.

Internal structure and developement.—The compact substance is divided into two laminæ; one external and the other internal, called vitreous. The space between them is occupied by the diploe.

The coronal is developed by two points of ossification, which commence at the two coronal protuberances.

THE PARIETAL.

Situation and figure.—Double, irregular, placed at the superior and lateral part of the cranium, behind the coronal, in front of the occipital, above the temporal and sphenoid.

Division.—*External*, convex surface: the parietal protuberance is seen in the centre; above and behind, near the suture, there is a small foramen termed parietal; the occipito-frontalis muscle covers nearly the entire of the external surface.

Internal, concave surface, covered with digital impressions, furrows, one of which, more profound than the others, placed near the anterior angle, lodges the meningeal artery. In the centre of the parietal fossa, and towards the posterior angle, a portion of the lateral groove is remarked.

The *circumference* presents four borders: the superior, anterior, and posterior, articulate by a deep suture with the neighbouring bones; the inferior by a squamous suture with the temporal. Four angles are observed at the junction of the four borders: they are distinguished into anterior, posterior, superior, and inferior.

Internal structure and developement.—The internal structure of the parietal is the same as the coronal; but it is developed by one point of ossification commencing at the parietal protuberance.

THE OCCIPITAL.

Situation and figure.—Single, regular, lozenge-shape, situated at the posterior and inferior part of the cranium; behind the parietal and sphenoid, between the temporal, and above the first cervical vertebra.

Division.—*External*, or occipital convex surface. It presents, from above downwards, a portion covered by the occipito-frontalis muscle; lower down, and in the centre, the external occipital protuberance; below, a prominent line, which is lost in the great occipital foramen; on the sides, two curved lines, distinguished into superior and inferior; below, the great occipital foramen; on its sides, the two condyles, which articulate with the first cervical vertebra; behind, and in front of the condyles, the condyloid fossæ and foramina; in front of the great occipital foramen, the basilar process.

Internal surface.—It presents four fossæ divided by a sort of cross, the three superior hollow branches of which form the continuation of the longitudinal fossa. Below this, we remark the great occipital foramen, the internal opening of the condyloid foramina, and in front, the internal portion of the basilar process, hollowed in form of a groove.

The *circumference* offers four borders: the two superior articulate by a deep suture with the parietal bones: the two inferior articulate in the same way with the temporal, and likewise aid in forming the posterior foramen lacerum. The superior angle articulates with the two parietal; the inferior, truncated, articulates with the body of the sphenoid bone, and in old age, becomes ossified with this bone.

Internal structure and developement.—The internal structure is here the same as in the preceding bones. The occipital is developed by four points of ossification, one for the large portion, two for the condyloid region, and a fourth for the basilar.

THE TEMPORAL.

Situation and figure.—Double, irregular, situated at the lateral and inferior portions of the cranium, below the parietal, in front of the occipital, behind the sphenoid and malar bones.

Division.—Three principal parts: 1st. A squamous, situated above the two others. It presents an external surface, which forms part of the temporal fossa; at its inferior portion is observed the zygomatic apophysis, which articulates in front with the malar bone, and terminates behind at the meatus auditorius externus; in front of the glenoid cavity there is a portion, elongated and prominent, called the transverse apophysis. The internal surface cor-

responds with the middle fossæ of the cranium, and presents nothing remarkable: its circumference articulates with the parietal by the squamous suture.

2d. A mastoid, situated behind the two others. It presents an external surface in which is seen the mastoid apophysis, below the digastric groove: its internal surface enters into the formation of the posterior fossa of the cranium, and lodges a portion of the lateral groove: its circumference articulates with the occiput.

3d. A petrous (petrous apophysis) of a pyramidal form, triangular, situated between the two first. It has a superior surface, in which is observed the *hiatus Fallopii*; a posterior, where the meatus auditorius is remarked; and an inferior, on which, from behind forwards, the following objects are seen: the stylo-mastoid foramen, the styloid apophysis, the carotid canal, and a portion of the track of the jugular vein; these three surfaces are united by three borders, which do not offer any thing worthy of attention.

The base of the *petrous* portion is turned from without backwards. On it we remark the glenoid cavity, divided by the fissure of *Glaser*, and the meatus auditorius externus: the summit articulates with the sphenoid and occiput.

Internal structure and developement.—The internal structure of the temporal is different in the three portions: similar to that of the other flat bones of the cranium in the *squamous*, it is compact in the *petrous*, and nearly altogether cellular in the mastoid portion. The temporal is developed by three points of ossification; one for the squamous, one for the mastoid, and a third for the petrous, under the form of an osseous circle.

THE SPHENOID.

Situation and figure.—Single, regular, situated at the base of the cranium, in front of the occipital and temporal, behind the coronal, vomer, ethmoid, and palatine bones, and between the parietal and malar bones.

Division.—1st. A *body*, or middle portion, which presents four surfaces; a *superior*, on which, from behind forwards, we remark, the square plate, the sella turcica, or pituitary fossa, and a surface on which the olfactory nerves pass; and on the sides the wings of *Ingrassias*, or small wings of the sphenoid; at the point of their union with the body of the bone, is situated the foramen occipitale. An *inferior*, articulating with the vomer; an *anterior*, with the ethmoid. It likewise presents two cavities, known as the sphenoidal sinuses, formed in great part by two small osseous laminae, called *cornets of Bertin*. The posterior surface is united to the occiput.

2d. *Branches* or large wings; these present three surfaces. A *superior*, which corresponds to the middle fossæ of the cranium; we observe in it the spinous, the superior and inferior maxillary foramina. An *external*, divided into the temporal and zygomatic portions; below, and in front of this last, originate the pterygoid apophyses, elongated from above downwards, divided into external and internal surfaces, and into anterior and posterior borders. Behind these apophyses, we remark the external orifices of the spinous and inferior maxillary foramina. The *anterior* surface, orbital, forms a portion of the orbit, and aids in forming the external part of this cavity.

The *circumference* of the sphenoid presents numerous articulations. In front, with the coronal, ethmoid, palatine, and malar bones; behind, with the occipital and temporal;

on the sides, with the parietal; and below, with the vomer.

Internal structure and developement.—The structure is in great part spongy in the body, and compact in the branches.

The sphenoid is developed by five points of ossification, one for the body, two for the small wings, and two for the large wings.

ETHMOID.

Situation and figure.—Single, regular, situated at the anterior part of the base of the cranium, before the sphenoid and palatine bones, before and below the coronal and ossa unguis, above the superior maxillary, and behind the bones proper to the nose.

Divisions.—1st. A *middle* portion. It presents below the perpendicular plate; above, the apophysis crista-galli (*ethmoidal*,) and in the middle, the cribriform plate.

2d. *Lateral* portions, elongated, cuboidal. They are divided into a superior or cerebral surface, inferior or maxillary, external or orbital, and internal or nasal; this last presents, from above downwards, the superior cornet of the ethmoid or of *Morgagni*, and the os planum; below, the superior meatus, which communicates with the posterior cells; behind, the middle cornet; and lower down, a portion of the middle meatus. The anterior and posterior surfaces articulate by harmonia, the first with the os unguis, and the second with the sphenoid.

Internal structure and developement.—Except the crista galli apophysis, which has a small portion of cellular substance, the whole ethmoid is composed of a compact substance, arranged in thin layers, doubled several times on each other. This bone is developed by three points of ossifi-

cation ; one for the middle portion ; and one for each lateral mass.

BONES OF THE FACE.

The bones of the face are the superior maxillary, malar, unguis, those proper to the nose, inferior cornet, palatine, vomer, and inferior maxillary.—To these are added the teeth and os hyoides.

Anatomical preparation.

The anatomical preparation of the face demands but little care, or rather does not require any, and I should have passed over this article in silence, were it not that I desire in this place to make a few general remarks in reference to the particular disposition of the facial angle, and the mode of demonstrating it. The facial angle is an ideal measurement, imagined by anatomists, and especially by painters and sculptors, in order to have the proportions of the cerebral mass, and determine in this way the degree of intelligence of each species. Man is, of all the known species, the being whose facial angle is the most developed, and, consequently, his intellectual functions have attained the highest degree of perfection. In order to measure this angle, we will suppose two lines, one drawn from the superior dentes incisores to the forehead, the other from the same point, along the base of the cranium. In proportion as these two lines, in their respective developement, become farther distant or nearer to each other, they give the extent of the facial angle more or less developed.

Another mode of measuring the developement of the facial angle has been proposed ; it is to make a vertical section of the head, so as to separate exactly the cranium from the face ; in this way we have, by the height of the section

of the bones of the face, the exact extent of the facial angle. This section is also necessary in order to understand the relative volume and extent, which exist between the cranium and face: by comparing these results in the different periods of life, we will observe that, in infancy, the volume and extent of the face, compared with those of the cranium, exceed these last considerably, and that these proportions diminish as age advances, without, however, including old age; for then they return nearly to their original state, in consequence of the teeth falling out, and the loss of substance in the jaws. According to Camper and M. Cuvier, the facial angle is from 90° to 85° in the European adult; it is 77° in the negro; and 67° in the young ourang-outang.

The separation of the bones of the face having been mentioned when speaking of the head, I shall not recur to it: I will merely mention that it is very important for the student, in the study of these bones, to have them continually before his eyes, and frequently to place them in contact, in order to have an exact knowledge of their respective relations.

It is likewise important that the maxillary bones should be filled with teeth; and it is indispensable to have a number of the teeth in an isolated state, in order to study the number and direction of their roots. In fine, with a view to a perfect knowledge of their developement, it will be necessary to possess the maxillary bones of the fœtus, in which the germs can be perceived entire in the alveolar processes.

DESCRIPTION OF THE SUPERIOR MAXILLARY BONE.

(*Sus Maxillaire.*)

Situation and figure.—Double, irregular, situated in the middle of the face, beneath the coronal, ethmoid, unguis,

vomer, and the bones proper to the nose; above the inferior maxillary bones and upper teeth; in front of the palatine bones.

Division.—*External region*: it presents the ascending apophysis, which articulates with the coronal; below, the canine fossa and infra-orbital foramen; somewhat behind, the maxillary protuberance, which corresponds to the zygomatic fossa, the more prominent as age is less advanced, because then the tardy tooth is contained within its alveolar process; above, the orbital surface, called the floor of the orbit; we there perceive the commencement of the infra-orbital canal; in fine, the malar *échanerure*, unequal, articulating with the malar bone.

Internal region: it presents, in the middle, the palatine spine, elongated from behind forwards, making a part of the nasal fossæ above, of which it constitutes the floor or inferior wall, and forming below the palatine fossa. The union of the two spines gives rise, in front, to the formation of the foramen incisivum, or anterior palatine.

Above the palatine spine there is a large cavity; this is called the maxillary sinus, the opening of which is large and spacious in the osseous state, but singularly contracted by the articulation of the neighboring bones, and the disposition of the soft parts. There is an irregular surface behind this cavity, which articulates with the palatine bone and assists in forming the posterior palatine canal.

The circumference of the superior maxillary presents at its inferior portion the dental border, furnished with sixteen alveolar cavities, which are deeper in proportion as they are examined in front.

Internal structure and developement.—The superior maxillary is composed of a compact substance distributed in an unequal manner, and of a small quantity of cellular

matter, except towards its dental border. It is developed by a single point of ossification.

OF THE MALAR BONE.

(*Malaire.*)

Situation and figure.—Double, irregular, situated on the lateral and superior parts of the face, below the coronal, before the temporal, superior maxillary, and sphenoid.

Division.—*External*, convex surface, covered by the integuments of the cheeks and zygomatic muscles: *internal* surface, articulating in part with the superior maxillary and sphenoid, and assisting to form the temporal and zygomatic fossæ.

Four borders and four angles.—Of the two anterior borders, one is confounded in the articulation of this bone with the maxillary, the other forms part of the circumference of the orbit; this border, by extending backwards, aids in the formation of the inferior and external wall of the orbit. The two posterior borders limit, in front, the superior, the temporal fossa, the inferior, the zygomatic fossa.

Of the four angles, the superior articulates with the coronal; the inferior and anterior with the maxilla, and the posterior with the zygomatic apophysis of the temporal bone.

Internal structure and developement.—The proportions of the two substances are nearly the same in the malar bone; it is developed by one point of ossification.

OF THE BONE PROPER TO THE NOSE.

(*Nasal.*)

Situation and figure.—Double, irregular, situated at the middle and superior part of the face; below the coronal,

in front of the ethmoid and ascending apophysis of the maxillary bone.

Division.—*External* surface, slightly concave, covered by the integuments of the nose: the *internal* forms part of the superior wall of the nasal fossæ: the *anterior* border articulates with its fellow: the *posterior* border with the ascending apophysis of the maxillary bone; the *superior* border, large and short, with the coronal: the *inferior* is free, and has the cartilage of the nose attached to it.

Internal structure and developement.—What has been said in reference to the malar bone applies to the bones proper to the nose.

OF THE OS UNGUIS.

Division and figure.—Even, irregular, situated in the orbit, and aids in forming a portion of its internal wall; below the coronal, above and behind the superior maxillary, and in front of the ethmoid.

Division.—*External surface*: this corresponds to the orbit; *internal*, which articulates with the ethmoid; the *superior* border articulates with the coronal; the *inferior* border articulates with the superior maxillary bone, and a small portion of the inferior turbinated bone; the *anterior* with the ascending apophysis of the maxillary bone; the *posterior* with the flat portion of the ethmoid.

Internal structure and developement.—The os unguis is composed altogether of compact substance: it is developed by one point of ossification.

OF THE INFERIOR TURBINATED BONE.

(*Cornet inférieur.*)

Situation and figure.—Double, irregular, curved upon

itself, situated in the interior of the nasal fossæ, at the internal portion of the maxillary and palate bones, and below the os unguis.

Division.—*Internal*, convex surface: it corresponds to the nasal fossæ; *external* concave surface; it is placed behind on the palatine bone; in front, on the maxillary, and in the middle it assists in closing partially the opening of the maxillary sinus; its *superior* border articulates with the bones just mentioned; its *inferior* border is free: it has a *posterior* extremity, united to the palatine bone, and an *anterior* extremity, united to the os unguis and superior maxilla.

Internal structure and developement.—The inferior turbinated bone is the only one which has the compact substance within, and the cellular without; it is developed by one point of ossification.

OF THE PALATINE BONE.

Situation and figure.—Double, irregular, situated at the posterior part of the nasal fossæ and palatine arch, behind the superior maxillary bone, before the sphenoid, and on the outer side of the ethmoid.

Division.—1st. A *horizontal* portion: it presents a superior surface, which forms part of the floor of the nasal fossæ; an inferior, which is a portion of the palatine arch; an anterior border, articulating with the maxilla; a posterior which is free; an internal articulating with its fellow; an external which confounds itself with the perpendicular or vertical portion of the bone. The union of the internal border of the two bones gives origin behind to the posterior nasal spine, to which is attached the palato-staphylin muscle.

2d. A *vertical* portion, divided into a body and two superior extremities. The body presents an external surface applied to the maxillary bone; from the union of the two bones behind the posterior palatine canal is formed: an *internal* surface; it corresponds to the nasal fossæ, and forms part of their external wall; an anterior border, articulated with the maxillary bone, a posterior border, articulated with the pterygoid apophysis of the sphenoid. The superior extremities are, one orbital in front, the other sphenoidal behind.

At the point of union between the horizontal and vertical portion originates the pyramidal apophysis of the palatine bone, which is directed downwards, and articulates with the sphenoid.

Internal structure and developement.—Composed in great part of compact substance, the pyramidal apophysis alone offers a medium quantity of cellular substance: the palatine is developed by one point of ossification.

OF THE VOMER.

Situation and figure.—Single, regular, placed in the interior of the nasal fossæ, of which it forms, in great part, the septum; situated below the sphenoid, above the maxillary bones, and behind the perpendicular plate of the ethmoid.

Division.—It has two lateral surfaces, which correspond to the nasal fossæ, and four borders, the superior of which articulates with the sphenoid by a species of groove; the inferior, with the maxillary and palatine bones; the anterior with the perpendicular plate of the ethmoid: the posterior is free.

Internal structure and developement.—Almost entirely

composed of compact substance, the vomer is developed by one point of ossification.

OF THE INFERIOR MAXILLARY BONE.

(*Sous-Maxillaire.*)

Situation and figure.—Single, regular, situated below the superior maxillary bone, below and in front of the temporal.

Division.—*The body*: this presents an *external* convex surface, covered by the integuments and muscles of the inferior lip; in the centre of it, we remark the symphysis of the chin; on the sides, the external oblique lines, which extend as far as the coronoid apophysis; on the sides and in front is situated the mental foramen.

Internal, concave face: it presents in the middle the traces of the symphysis; below, the four genio-hyoid and genio-glossis tubercles (apophysis, &c.) on the sides, the digastric fossæ and internal oblique or mylo-hyoidean line; below, a depression for the lodgement of the maxillary and sublingual glands.

This bone has a superior dental and an inferior mental border. The first presents sixteen openings called alveoli, destined to lodge an equal number of teeth; the second forms the chin properly so called.

2d. *The branches*: these have an *external* surface, covered by the masseter muscle: an internal surface, by the pterygoid; we likewise observe the orifice of the dental canal; a posterior border which receives the parotid gland; an anterior free border: an inferior border, which forms part of the chin, and a superior which presents two eminences, one called coronoid (mylène,) and the other condyloid, separated by a depression of a crescent shape. The coronoid apophysis gives attachment to the temporal

muscle, and the condyle articulates by double arthrodia with the glenoid cavity of the temporal bone.

Internal structure and developement.—The compact and spongy substances are equally abundant, and distributed nearly in the same way as in the bones of the cranium. But the bone is traversed by a canal in the whole of its length, which bears the name of dental. The inferior maxilla is developed by two points of ossification, the union of which constitutes the centre of the bone.

Note. Here we perceive the first species of moveable articulation; all the other bones of the cranium present immoveable articulations, including those of the teeth.*

OF THE TEETH.

Situation and figure.—Double, irregular, concealed in part within the two maxillary bones, and projecting in part from them, they are in contact with each other by their free extremity, when the mouth is closed.

Division.—Three kinds: Incisivi, canini, and molares.

1st. *Incisivi*: eight in number; four in each jaw. They have a *crown*, which presents an *external* convex surface, turned in front; an *internal* concave surface, turned backwards: two sides; a base, called *neck*, confounded with the rest of the tooth; a summit forming a cutting border; a root flattened on the sides, elongated, and terminating in a point, pierced at its extremity by a foramen, which affords passage to an artery and nerve into the interior of the tooth. A *neck* placed between the *crown* and root; on this is situated the free border of the gums.

* The history of the ligaments and the mode of preparing them will be found at the end of osteology.

2d. *Canini*: four in number, two in each jaw, placed between the incisivi in front, and the molares behind. We remark on these, as on the incisivi, a *crown*: it presents an *external* convex surface, turned in front; an internal surface, slightly concave, turned backwards; two sides, a base confounded with the rest of the bone, and a summit of a diamond shape; a long root, flattened on the sides, terminating in a point, and pierced by a foramen for the same purposes as in the incisivi. The *neck* is embraced by the free border of the gums.

3d. *Molares*: ten in number in each jaw, five on each side, distinguished into two small and three large. They have a *crown* flattened on four sides, a base confounded with the rest of the tooth, and a summit terminating by four tubercles, separated by two small depressions in the form of grooves. These tubercles, more elevated without than within, result from the natural developement of the teeth: but they are worn out in consequence of mastication, and ultimately disappear with age. The root of the molares is rarely single, but most usually double, triple, and quadruple. The extremity of each branch of the same root is pierced by a foramen through which the vessels pass, which are destined to nourish it and give it sensibility. The neck presents the same peculiarities as in the preceding teeth.

Structure and developement.—The structure and developement of the teeth offer certain peculiarities, which it is necessary to understand. Of the three known substances, they only possess the compact; but the portion situated above the alveoli is covered by a layer of a particular substance, called enamel. Its organization is but little known, and yet its properties, very numerous, manifest themselves in a very energetic manner.

Of a shining white appearance, the enamel resists the action of the air and the greater number of external agents. If it is once destroyed it does not become regenerated; though vessels have not been discovered in it, we cannot doubt the exquisite sensibility of this substance; we judge of this by the extreme sensibility produced in it by odontalgia and the the immediate contact of certain bodies, such as acids, ice water, &c.

Each tooth is developed by one point of ossification, called germ. By a singular effect of this developement, instead of one germ, there are two in each alveolus, whence result two dentitions, which occur at different periods, but attended by similar phenomena. The following is the progress of each dentition:

From six to eight, ten or twelve months, the two middle incisivi of the inferior jaw show themselves first: they are soon followed by the corresponding incisivi of the upper jaw. Next in order are the inferior lateral incisivi, the superior lateral, and the canini of the two jaws. Nature now appears to repose, in order afterwards to commence a more painful operation at the eruption of the molares, which occurs from the second to the fourth or fifth year, always from below upwards.

At this epoch, the number of teeth called milk teeth, at the first dentition, amounts to twenty-four, the whole number of thirty-two being completed only at the second dentition.

The teeth which have resulted from the first dentition fall out at the sixth or seventh year. One tooth only resists this species of revolution—it is the large molar. At nine years the jaws are furnished with twenty-eight teeth, and at twenty or twenty-five years with thirty-two, in con-

sequence of the developement of the dentes sapientiæ, which occurs about this age.

OF THE OS HYOIDES.

Situation and figure.—Single, regular, elongated in its transverse diameter, situated at the anterior and superior part of the neck.

Division.—Body and branches. The body presents an anterior convex surface, covered by some of the muscles of the neck; a posterior concave surface, and two borders, one of which is superior, the other inferior.

The cornua of the os hyoides are prolongations of the extremities of the bone. They are distinguished, on account of their extent, into large and small: both lose themselves in the soft parts.

Structure and developement.—Composed in great part of compact substance, the use of the os hyoides is to afford attachment to a great number of muscles; it is the only bone which does not articulate with the other bones; it is, as it were, lost in the soft parts of the neck; and it is for this reason that it cannot be preserved except in its isolated state.

OF THE TRUNK.

The trunk is composed of the vertebral column, pelvis, and chest or thorax.

Anatomical preparation.

In proportion as we advance in the study of osteology, it becomes less necessary to occupy ourselves with the mode of preparing the objects of this study: the trunk exacts very little care in the preparation of it; a few ribs and vertebræ, together with the bones of the pelvis, will

suffice in order to arrive at the necessary knowledge of this part of the skeleton ; however, it will be well not to confine ourselves to this. It will be necessary to have constantly before our eyes the ribs, vertebræ and bones of the pelvis united together, and forming a whole. It is also indispensable that we have all the vertebræ placed on a flexible rod, which we may remove at pleasure, and incline in every direction. We may, in this manner, study the vertebræ successively one after the other, and likewise observe the different relations existing among them.

The ribs should be studied separately ; but it is also necessary to examine them in situ, in order to understand how their cartilages are connected to the sternum. The bones of the pelvis demand the same attention : we would have but a faint idea of the numerous uses of this osseous canal, if we were to study the bones only in their isolated state.

DESCRIPTION OF THE VERTEBRAL COLUMN.

(*Rachis.*)

A species of pyramid situated between the occiput, to which its summit corresponds, and the sacrum, on which its base reposes. The vertebral column is composed of twenty-four bones, which bear the name of vertebræ ; it presents two surfaces, a posterior (spinal,) and an anterior (prè-spinale.)

It likewise has three regions :

1st. A cervical, superior, composed of seven vertebræ, which corresponds to the neck. The anterior part is called the tracheal surface, and the posterior, the cervical.

2d. A dorsal composed of twelve vertebræ ; its posterior part is termed dorsal, the anterior præ-dorsal.

3d. A lumbar, composed of five vertebræ. Its posterior part called lumbar, and the anterior, pré-lombaire.

OF THE VERTEBRÆ.

Situation and figure.—Single, regular, twenty-four in number, placed one above the other, between the occiput and sacrum.

Division.—Cervical, dorsal, and lumbar. In all the regions each vertebra presents a *body*, the voluminous portion of the bone, placed in front, having above and below two articulating surfaces, encrusted with cartilage; a *spinous* apophysis, situated behind, giving attachment to all the muscles of the posterior part of the trunk; two *transverse* apophyses, situated on the sides, affording attachment to the same muscles; four *oblique* or articulating surfaces, parallel to the cartilaginous surfaces of the body, encrusted with a diarthrodial cartilage, which permits the surfaces to glide mutually on each other; two posterior *plates*; four *échancrures*, which form, with those of the adjoining vertebræ, the foramina through which pass the vertebral nerves (*rachidiens*;) and a *foramen*, the succession of which in all the vertebræ constitutes the vertebral or rachidien canal, which lodges the spinal marrow and a prolongation of the three membranes of the brain.

1st. *Cervical vertebræ*: they are seven in number. The general characters of the vertebræ of this region are: a small body; a spinous apophysis, bifurcated at its extremity; transverse apophyses, but little developed and pierced at their base by a foramen which, by its continuity with all the cervical vertebræ, forms a canal in which is lodged the vertebral artery; oblique apophyses, placed horizontally, and almost flat; and a spinal foramen triangular in its circumference, and very large. The first, se-

cond, and seventh vertebræ of this region present certain peculiarities.

The first called *atlas* (atloide,) has neither body nor spinous apophysis: these are replaced by two circles. The articulating apophyses are very much developed, and form, with the transverse, what are called the *lateral masses*. It articulates superiorly with the occiput, and inferiorly with the second cervical vertebra.

The second, called *axis* (axoid,) has a large body; from its superior part originates an apophysis, termed odontoid, which articulates with the atlas. Its spinous apophysis, large, is considerably bifurcated at its extremity.

The seventh bears the name of *proèminente*, on account of the great length of its spinous apophysis, which surpasses that of the other vertebræ in the same region.

2d. *Dorsal vertebræ*: they are twelve in number. Their general characters are a body, which, in size, is intermediate to those of the cervical and lumbar: we perceive on the sides small demi-articulating facettes which, united to similar ones in the adjoining vertebræ, form entire surfaces, which receive the posterior extremity of the ribs; a long spinous apophysis, terminating in a point, and looking downwards; transverse apophyses, elongated, tubercular at their extremity, inclined backwards, and articulating with the tuberosity of the ribs; articulating apophyses, the superior inclined backwards, the inferior forwards; a vertebral foramen (*rachidien*,) rounded in its circumference, and more narrow than in the vertebræ of the other regions. The first, eleventh, and twelfth offer as peculiarities, an entire facette on their bodies for articulation with the ribs, and do not present any on their transverse apophyses.

3d. *Lumbar vertebræ*: they are five in number; their general characters are: a large body; a broad, spinous apophysis; transverse apophyses, which are long and rather thin, terminating in a point; extensive articulating apophyses, the superior turned inwards, the inferior outwards; a vertebral foramen (*rachidien*) triangular in its circumference; it is smaller than in the cervical vertebræ, but larger than in the dorsal.

The vertebræ articulate with each other by amphiarthrosis or articulation by continuity, as also the last lumbar vertebra with the sacrum. The articulation of the head with the first cervical, and of this with the second, as also the dorsal vertebræ with the ribs, is effected by contiguity of surfaces; it is a double arthrodia; the articulation of the odontoid apophysis with the first cervical vertebra, is a simple lateral ginglymus.

Internal structure and developement.—The compact substance placed on the exterior, constitutes but a thin layer on the bodies of the vertebræ, which abound in cellular substance: they are developed by three points of ossification, one for the body, and one for each lateral portion.

OF THE PELVIS.

It is composed of the sacrum, coccyx, and the two haunch bones. From the union of these different portions results an osseous cavity, more spacious above than below, divided into large and small pelvis. They are separated by a contraction called the superior strait, (*abdominal*,) in order to distinguish it from a similar contraction at the bottom of the small pelvis, called the inferior strait (*perineal*.)

OF THE SACRUM.

Situation and figure.—Single, regular, situated below the last lumbar vertebra, above the os coxycy, and between the haunch bones.

Division.—A *posterior* surface: it presents in the middle a series of eminences, which correspond to the spinous apophyses of the true vertebræ; on the sides, the posterior sacral foramina; more outwards, prominences unequally distributed, which correspond to the transverse and articulating apophyses of the true vertebræ. An *anterior* surface: it corresponds to the interior of the pelvis, and presents, in its middle, surfaces corresponding to the bodies of the vertebræ; on the sides, the anterior sacral foramina, larger than the posterior, affording passage to the sacral nerves. *Lateral borders*: thick above, they articulate with the haunch bones, by a very obscure diarthrosis, and give attachment, below, to the large and small sacro-ischiatic ligaments. *Extremities*: the superior, called the base of the bone, is very thick and articulates, by an obscure diarthrosis on one part, and by a double arthrodia on the other, with the last vertebra of the loins; the inferior, called the summit, articulates with the coxycy by a species of amphiarthrosis. The intermediate cartilage, uniting the sacrum and coxycy, enjoys in the female, during accouchement, a considerable mobility, which allows the coxycy to be pushed backwards. In this way we can explain the facility of certain accouchements, which otherwise would prove very laborious.

A common canal, called sacral, larger above than below, traverses the whole length of the bone, and terminates the rachidien canal.

Internal structure and developement. The internal structure of the sacrum is in every respect similar to that of the vertebræ; it is developed by five points of ossification, and in infancy by fifteen.

OF THE COXCYX.

Situation and figure.—A sort of appendix to the sacrum, to which it bears a strong analogy, although infinitely smaller; single and regular, it is situated below the preceding.

Division.—A *posterior surface*, covered by the integuments: an *anterior surface*, which corresponds to the pelvis; *lateral borders*, giving attachment to the sacro-ischiatic ligaments; a base which articulates with the sacrum; a free summit lost in the soft parts.

The structure is the same as in the sacrum: it is developed by three points of ossification.

OF THE OSSA INNOMINATA OR HAUNCH BONES.

(Coxal.)

Situation and figure.—Double, irregular, placed on the sides of the pelvis, and above the femur.

Division.—*External femoral surface*: it presents above a broad surface, called the external iliac fossa; we can perceive on it traces of the insertion of the three glutei muscles; lower down, the cotyloid cavity, which receives the head of the femur; still lower, and in front, the obturatory foramen (*sous-pubien.*) *Internal, abdominal surface*; it presents, above, the internal iliac fossa and a foramen for the passage of vessels nourishing the bone: lower down, a portion of the superior strait; still lower, a broad surface and the obturatory foramen. The *circumference* commences above and in front by the anterior and superior spinous process of

the ilium; going backwards we will observe the crest, having the form of an italic *S*; behind this, is the great ischiatic notch; below, the spine and small notch of the same name; at the lowest point, the tuberosity of the ischium is observed, on which we repose when seated; in front, we notice a portion of the bone, called the ascending branch of the ischium, and descending branch of the pubis; higher up, the symphysis of the pubis, from 18 to 20 lines in length, and from 6 to 8 in width; in front, the spine and horizontal branch of the pubis, on which is remarked the pectineal eminence, along which the crural vessels pass; behind this a surface for the tendons of the Psoas and iliacus internus muscles; the rest of the circumference exhibits nothing remarkable.

Structure and internal development.—Anatomists have agreed to divide the haunch bones into three portions to which are given the names of *Ilium* above, and *ischium* below and behind, and *pubis* also below and in front. This division, which is arbitrary and reposes upon no solid basis, does not merit our attention. It may, however, be necessary to remark that the haunch bones are developed by three points of ossification, the traces of which are very visible within and without the cotyloid cavity in early age, and hence this division appears to be admissible.

OF THE CHEST.

(*Thorax.*)

It is situated at the anterior and superior part of the trunk, and is formed, in great part, by the ribs, species of osseous arcs, placed one above the other, and united in front to the sternum, by means of intercostal cartilages.

OF THE RIBS.

Situation and figure.—Double, irregular, twenty-four in number, twelve on each side, elongated from behind forwards, and slightly curved in their length, which increases from the first to the eighth, and diminishes from this to the twelfth.

Division.—*True ribs (sternal)*, the cartilages of which go directly to the sternum; they are seven in number; *false ribs (a-sternal)* the cartilages of which go to the sternum by means only of the first; they are five in number; the ribs, have for their general characters, an *external* and *internal* surface, two borders and two extremities.

The *External* surface is convex, smooth, polished, covered by the muscles of the chest and the integuments. The *internal* surface is concave, and covered by the pleura. The *borders* afford attachments to the intercostal muscles; the inferior border has a groove, which lodges the intercostal artery and nerve. The *posterior* extremity articulates, by arthrodia, with the sides of the bodies of the dorsal vertebræ and their transverse apophyses; the *anterior* extremity, also by arthrodia, with the intercostal cartilages. The first, eleventh, and twelfth offer certain peculiarities.

The first is much smaller than the others, its cartilage is scarcely visible; it does not articulate with the transverse apophysis of the corresponding vertebra; the eleventh and twelfth, likewise very short, have no cartilages in front, and for this reason, have been called the floating ribs: they do not articulate with the transverse apophyses of the corresponding vertebræ.

Internal structure and developement.—Here commences the general disposition of the structure of long bones, i. e. it presents a layer of compact substance, abundant in the centre, more rare in the extremities, where the spongy substance predominates. Some anatomists pretend that they have observed a reticulated substance, but we may be permitted to doubt it. The ribs begin to develope themselves at so early a period of intra-uterine life, and their developement is so rapid, that it is difficult to say exactly whether it commences by one or three points of ossification; most anatomists admit only one.

OF THE STERNUM.

Situation and figure.—Single, regular, extending from above downwards, situated at the anterior part of the chest, in the space between the seven first ribs.

Division.—*Anterior* surface covered by the integuments and aponeurotic expansions of the pectoral muscles. *Posterior* surface corresponding to the interior of the chest: the anterior mediastinum is attached to it in its whole length. The *lateral* borders present seven articulating *facettes* for the cartilages of the seven first ribs. On the *superior* extremity or base, we remark two articulating *facettes* for the sternal extremity of the clavicle; the sterno-mastoid, sterno-hyoid, and sterno-thyroid muscles are also attached to it. Its *inferior* extremity is called *xiphoid* appendage.

Structure and developement.—The sternum is composed of three pieces; the first and middle have a structure analogous to that of flat bones; each is developed by several points of ossification: the third is of a cartilaginous nature, and preserves this structure until advanced age.

OF THE EXTREMITIES OR MEMBERS.

They are divided into superior (*thoracic*) and into inferior (*abdominal*.)

Anatomical preparation.

The anatomical preparation of the extremities requires that all the bones composing them be placed in their exact relations by means of artificial attachments, which are better here, than their proper ligaments; for, besides the impossibility of inspecting and studying, in the natural skeleton, the external disposition of the articulating surfaces, the stiffness of all the articulations in consequence of the soft parts, (the *ligaments*,) which surround them, becoming dry and hard, prevents that freedom of motion in the joints, which it is necessary to understand with accuracy. It is for the same reasons that we should not content ourselves with a rapid survey of these articulating surfaces in their dry state: in order to have a clear idea of them, it will be necessary, at the same time, to procure bones recently detached, and on the surfaces of which the diarthrodial cartilages are still in their integrity. The study of the small bones of the hand, and particularly of those of the carpus, can only prove profitable by having them before our eyes still enveloped by their ligaments: by dividing them in proportion as we wish to study their articulating surfaces, we will acquire a knowledge of these parts, which would be impossible in studying the bones in their dry state. What I have just said of the bones of the hand applies equally to those of the foot, and especially to the tarsus. These few observations in reference to the anatomical preparation of the members will suffice in order to pass to the particular study of the bones, which compose them.

OF THE SUPERIOR OR THORACIC EXTREMITIES.

They are composed of the shoulder, arm, fore-arm, and hand.

OF THE SHOULDER.

Situated on the lateral and superior portions of the trunk, the shoulder is formed by the omoplate behind, and clavicle in front.

OF THE OMOPLATE.

(*Scapulum.*)

Situation and figure.—Double, irregular, triangular, situated at the posterior part of shoulder, corresponding to the seven first ribs.

Division.—Two surfaces, one posterior, the other anterior; three borders and three angles.—*Posterior* surface presents an eminence called the spine of the omoplate; it divides this surface into two regions, one superior termed supra-spinal; the other inferior, infra-spinal; both are covered by muscles of the same name. The spine itself terminates in front by the acromion apophysis, which articulates, by arthrodia, with the clavicle. *Anterior surface* corresponds to the ribs, and receives the subseapularis muscle. There are three *borders*: a superior, which is short and thin; it gives attachment to the omo-hyoideus; an anterior, called the rib of the omoplate, is thick and longer than the preceding; it affords attachment to the triceps brachialis, to the teres major and minor: a *posterior*, longer than either of the preceding; it is thin and gives attachment to the rhomboideus and serratus major. The omoplate has three *angles*: a superior, giving attachment

to the angularis ; an inferior, to the latissimus dorsi ; and an anterior, which is articular and truncated. We observe on it an articulating concave surface, called the glenoid cavity, which receives the head of the humerus : above, the coracoid apophysis, which affords attachment to the ligaments and to the biceps, coraco-brachialis and pectoralis minor muscles.

Internal structure and development.—As in all the flat bones, the two substances are unequally distributed in the omoplate, which is developed by one point of ossification.

OF THE CLAVICLE.

Situation and figure.—Double, long, irregular, the clavicle is situated transversely at the superior part of the thorax, between the *omoplate* and *sternum*.

Division.—*Body* and *extremities* : the body presents a superior surface, to which is attached the sterno-cleido and trapezius muscles ; an inferior surface, which gives attachment behind to the sub-clavian muscle ; and two borders, the anterior giving attachment to the pectoralis major and deltoid, the posterior is free.

Extremities.—One (*sternal*) is anterior, large, rounded, and articulates by arthrodia with the sternum ; the other (*acromiale*) is posterior, flattened, and articulates likewise by arthrodia, with the acromion apophysis.

Structure and development.—The three substances are found in the clavicle, which is developed by three points of ossification ; but the body is already ossified, when the extremities are yet in a cartilaginous state.

OF THE ARM.

The arm is composed of one bone, called the humerus.

OF THE HUMERUS.

Situation and figure.—Double, irregular, situated below the omoplate, above the cubitus, and on the lateral portions of the trunk.

Division.—Body and extremities. The body is prismatic, triangular, and somewhat curved; it presents three surfaces; the first, external, is covered above by the deltoid muscle, and below by a portion of the triceps-brachialis; it also has a groove for the passage of the radial nerve; the second, internal, is covered by the coraco-brachialis and triceps-brachialis; there is a foramen in it for the nutrient vessel; the third, posterior, is covered in all its length by the triceps. Three borders result from these three surfaces: the anterior presents, above, the bicipital groove, the others offer nothing particular.

Extremities.—One is *superior*, and presents a rounded, articular eminence, called the head of the humerus, which articulates with the glenoid cavity of the omoplate by enarthrosis; below and outwards, there are two non-articulating eminences, which bear the names of large and small tuberosities (*trochiter et trochin*;) below, there is a contraction, called the neck of the humerus.

The *inferior* extremity, flattened, elongated transversely, presents, without and within, an articular surface (*trochlée*;) composed of a rounded eminence, called the small head of the humerus, of two condyles and a groove; on the inner and outer portion are two tuberosities, one internal (*epitrochlée*;) the other external (*épicondyle*;) which afford attachment to the superficial muscles of the anterior and posterior part of the fore-arm.

Structure and developement.—Three substances enter into the composition of the humerus. The compact, very abundant, is found particularly near the middle of the bone,

the spongy at the two extremities, and the reticular in the centre; this bone is developed by three points of ossification.

ulna
OF THE FORE-ARM.

It is formed by two bones, the radius without, and ~~cubitus~~ *ulna* within.

OF THE RADIUS.

Situation and figure.—Double, irregular and triangular, situated below the humerus, above the hand, and at the external side of the cubitus.

Division.—Body and extremities. The body presents three surfaces. The first, anterior, is covered by the flexor longus pollicis manus; above, is observed the foramen for the nutrient artery; the second, posterior, is covered by the extensor muscles of the hand; and the third, external, by the radial muscles. Three borders result from these three surfaces; the anterior and posterior present nothing particular; the internal gives attachment to the interosseous ligament.

Extremities.—One is *superior*, rounded, concave; it articulates by enarthrosis with the small head of the humerus; on the side and within, it articulates with the cubitus by *gynglimus*; below, is remarked the neck of the radius; lower down and in front, the bicipital tuberosity, which affords attachment to the tendon of the biceps.

The *inferior* extremity, larger than the preceding, slightly flattened in four opposite directions, articulates below with the bones of the hand; on the side and within, with the cubitus; on the outside is the styloid apophysis, which gives attachment to the external lateral ligament; in front, it gives attachment to ligaments, and behind it presents three surfaces for the passage of certain muscles of the fore-arm

Structure and developement.—As in all the long bones, the radius is composed of three substances, and is developed by three points of ossification.

ulna
OF THE CUBITUS.

Situation and figure.—Double, irregular and triangular, situated below the humerus, above the os pisiforme, and at the internal side of the radius.

Division.—Body and extremities. The body presents three surfaces: the first, anterior, is covered by the deep flexor muscle: above, is observed the foramen for the passage of the nutrient artery; the second, posterior, is covered by the extensors of the fingers; the third, internal, by the internal cubital.

Extremities.—A superior, which is larger than the inferior; it presents the olecranon process, which gives attachment behind to the triceps brachialis; in front is the great sigmoid cavity, which articulates by gynglimus with the humerus; on the side and without, the small sigmoid cavity is remarked; it articulates by lateral gynglimus with the radius; below the large cavity of the olecranon is the coronoid apophysis; immediately below this, the bone presents a slight narrowing, which is called the neck of the cubitus.

The *inferior* extremity is smaller and rounded: within it presents the styloid apophysis, which affords attachment to the internal lateral ligament of the articulation of the cubitus with the hand, and without, a small articular surface is observed, articulating by lateral gynglimus with the radius.

Internal structure and developement.—The arrangement of the three substances and the developement are precisely as in the long bones.

OF THE HAND.

It is composed of three parts: the carpus, metacarpus, and fingers.

1st. The *carpus*.—Placed between the bones of the forearm and metacarpus, the carpus is formed of eight bones, disposed in two ranges: they are called, commencing with the upper range, and from without inwards, first, second, third, &c.; they likewise have the following names:

Scaphoides.—Double, irregular, situated below the radius, above the trapezium, and at the external side of the pyramidale.

~~Semi-lunare~~.—Double, irregular, situated below the radius, above the os magnum, at the external side of the pyramidale, and at the internal side of the scaphoides.

~~Pyramidale~~.—Double, irregular, situated below the cubitus by the intervention of a ligament, above the unciforme, on the internal side of the semi-lunare, at the external and posterior part of the pisiforme.

Pisiforme.—Double, irregular, situated in front of the pyramidale. The rest of the external surface of the bone gives attachment to the anterior cubital muscle, above, and to the adductor of the small finger below.

Trapezium.—This is the first bone of the second range. Double, irregular, situated below the scaphoides, above the first metacarpal bone, at the external side of the trapezoides, and of the second bone of the metacarpus.

Trapezoides.—Double, irregular, situated below the scaphoides, above the second bone of the metacarpus, at the internal side of the trapezium, and external to the os magnum.

Os Magnum.—This is the largest of the carpal bones. Double, irregular, situated below the scaphoides and semi-lunare, above the second, third, and fourth metacarpal bones, at the internal side of the trapezoides, and external to the unciforme.

Unciforme.—Double, irregular, situated below the semi-lunare, above the fourth and fifth metacarpal bones, at the

internal side of the os magnum, and external to the pyramidale.

The anterior and posterior sides of all the carpal bones give attachment to ligaments destined to strengthen their respective articulations, all of which are effected by arthrodia.

Structure and developement.—The compact and spongy substances enter into the composition of the bones of the carpus: they are all developed, but at a late period, by one point of ossification.

2d. The *Metacarpus*.—Placed between the bones of the carpus and the fingers, the metacarpus is composed of five bones, which are arranged numerically by the terms of first, second, &c., commencing at the thumb.

Situation and figure.—They all have an elongated form; the first is the largest and shortest. The second is the longest, and they diminish in length to the fifth. The first is situated below the trapezium and above the thumb; the second, below the trapezium and trapezoid, and above the index finger; the third, below the os magnum, and above the middle finger; the fourth, below the os magnum and unciforme, and above the ring finger; the fifth, below the unciforme, and above the small finger.

Division.—Body and extremities. The body is small in the middle, and slightly rounded; it presents an anterior side, which in all the metacarpal bones, is covered by the numerous short muscles of the hand; a posterior side, on which pass the tendons of the extensors of the thumb and fingers; the external and internal sides correspond to the inter-osseous spaces, and are covered by the muscles of the same name, except the external side of the first, and the internal of the fifth, which are free under the integuments.

Extremities.—One superior, irregularly disposed, articulating, as has been observed, with the bones of the car-

pus; the other, inferior, rounded, is called the head, and articulates in all by enarthrosis with the superior extremity of the first phalanges.

Structure and developement.—As in all the long bones, those of the metacarpus are composed of three substances, and are developed by three points of ossification; the reticulated substance alone is but little abundant.

3d. *Fingers.*—They are five in number, and bear the names of thumb, index finger, middle finger, ring finger, and little finger. Their relative size is such, that the middle finger is the longest, the ring finger next, then the index, and the little finger and thumb are the shortest. Each is composed of three phalanges, except the thumb, which has only two: they have the numerical names of first (*phalange*), second (*phalangine*), and third (*phalange*), commencing from above.

OF THE PHALANGES.

Situation and figure.—The first are the longest, and the third the shortest: some are placed below the others; the first are below the bones of the metacarpus, and the third below the second. All have an elongated form, slightly concave in front, and convex posteriorly; their relative size is the same as the fingers.

Division.—Body and extremities. The body, in all the phalanges, presents an anterior concave surface; it lodges the tendons of the superficial and deep-seated flexors; a posterior convex surface, on which pass the tendons of the extensors of the thumb and fingers.

Extremities.—The *superior* are concave and circular in the first phalanges; they articulate with the inferior extremities of the metacarpal bones; in the second, they are more prominent in the middle, concave on the sides, and

articulate with the inferior extremities of the first phalanges; in the third, they offer the same disposition as in the second.

The *inferior* extremities of the first and second phalanges present two small condyles; and in the third they are terminated by a rounded, non-articulating border, on the posterior part of which is implanted the nail, and a pulpy substance on the anterior: their mutual articulation is effected by an angular ginglymus.

Structure and developement.—Except in the third phalanges, in which the developement is very obscure, they are all composed of three substances; they are developed by three points of ossification.

OF THE INFERIOR EXTREMITIES, OR ABDOMINAL MEMBERS.

They are composed of the thigh, knee, leg, and foot.

OF THE THIGH.

It is formed by one bone, called the femur.

OF THE FEMUR.

Situation and figure.—Double, irregular, the longest bone in the skeleton: it is situated below the haunch bone, above the tibia, above and behind the rotula.

Division.—Body and extremities. The body, prismatic and triangular, presents an anterior convex surface, covered by the crural and femoral muscle; an external and internal surface, likewise covered by the same muscle. Three borders result from the disposition of these three surfaces; the external and internal offer nothing particular; the third, posterior, called *linea aspera femoris*, gives attachment, by its interstice, to the three adductors and to the short portion of the biceps. Two foramina are observed on

this line for the passage of nutrient vessels. It is divided above and below into two branches; the two superior give attachment, the external to the vastus externus, gluteus maximus, and third adductor; the internal, to the vastus internus and pectineus. The two inferior branches afford attachment, the external to the vastus externus, and quite low down, to the jumellus externus and plantaris; the internal to the vastus internus and third adductor.

Extremities.—The *superior* is composed of the head, neck, and two trochanters; the head is nearly spherical, smooth, polished, encrusted with a diarthrodial cartilage, and articulates by enarthrosis with the cotyloid cavity of the haunch bone; the round ligament is inserted into its middle. Below the head is the neck, elongated, flattened from before backwards, directed obliquely from within outwards; at this point are two trochanters, one external (*trokanter*), the largest, covered by the gluteus maximus; the other internal and posterior (*trokantin*,) smaller; it affords insertion to the united tendons of the psoas magnus and iliacus internus.

The *inferior* extremity, larger than the superior, presents two eminences rounded in one sense, and flattened in the other, called condyles of the femur; both are covered by a diarthrodial cartilage, and articulate by arthrodia with the tibia. Behind the condyles are two eminences, called tuberosities: the external gives attachment to the external lateral ligament of the articulation, and to the popliteal muscle; the internal, to the internal lateral ligament, and third adductor.

Structure and developement.—The three substances are found in great quantity in the femur; a long canal is remarked in the centre of the bone, in which the reticular substance abounds; the compact exists in the middle, and

in this part, the femur presents a *retrécissement*, which indicates the manner in which the laminae of this substance are bound together; the spongy substance is uniformly distributed in the extremities, where, though its volume be considerable, it does not increase the weight of the bone. The femur is developed by three points of ossification.

OF THE LEG.

It is composed of two bones: the tibia within, and peroneus without.

OF THE TIBIA.

Situation and figure.—Double, irregular, triangular and prismatic: situated below the femur, above the foot, and at the internal part of the peroneus.

Division.—Body and extremities. The body, thick at its superior part, diminishes in proportion as it approaches its inferior extremity. It presents three surfaces; an internal, slightly convex, covered by the integuments; an external (*pre-tibiale*), slightly concave, which lodges the anterior muscle of the leg, the long extensor of the toes, and proper extensor of the first toe; a posterior (*poplitée*) which lodges, above, the popliteal muscle, and in the rest of its extent the long flexor of the toes and posterior muscle of the leg; these last are covered by the soleus. The nutrient foramen, the largest of all those of its kind, is remarked a little above the superior third of this surface. Of the three borders, the external alone is remarkable; it gives attachment to the inter-osseous ligament.

Extremities.—The superior is very large, and presents two articulating surfaces, called condyles; they are slightly concave, and articulate by an angular *gynghlimus* with the femur; in the centre is a prominence, into which are implanted the cross ligaments; two tuberosities are placed on the

sides; the internal affords insertion to the demi-membranosus muscle.

The *inferior* extremity, much smaller than the superior, presents a concave articular surface, encrusted with a diarthrodial cartilage, which articulates by an angular ginglymus with the astragalus. The external side of this extremity offers a small articular surface, on which the peroneus is sustained, and, within, it presents an elongated and convex portion called the malleolus internus.

Structure and developement.—In structure and developement it is perfectly similar to the femur.

OF THE PERONEUS.

Situation and figure.—Double, irregular, situated at the external side of the tibia and astragalus, curved on itself, from within outwards.

Division.—Body and extremities. The body is prismatic and triangular: it presents three surfaces; one, external, covered by the peroneal muscles; the other, internal, divided in its whole length into two portions by a prominent line, which gives attachment to the interosseous ligament; in front, the muscles of the anterior part of the leg are observed; and behind, those of the posterior. The third surface, posterior, is covered by the soleus and flexor of the great toe; at its superior third is situated the nutrient foramen.

Extremities.—The *superior* is rounded; on the external side it has a tubercle for the insertion of the biceps muscle; on the inside a small articular surface, which articulates by arthrodia with the tibia. Just below, there is a slight *retrécissement*, called the neck of the peroneus.

The *inferior* extremity is somewhat more elongated than the superior; without, it forms the external malleolus;

within it offers a surface encrusted with a diarthrodial cartilage, for its articulation with the astragalus.

The *structure and developement* are the same as have already been stated to exist in the long bones.

OF THE KNEE.

In osteology, the rotula alone forms the knee.

OF THE ROTULA.

Situation and figure.—Double, irregular, short, situated below and before the femur.

Division.—*Anterior* surface, covered by the integuments and tendon of the anterior rectus. *Posterior* surface, smooth, polished, and formed by two articular surfaces, which move on the anterior part of the femoral condyles. A *superior* border, to which is fixed the tendon of the anterior rectus; an *inferior* border, a species of angle, affording attachment to the inferior ligament of the rotula, (*rotulien.*)

Structure and developement.—Like the short bones, the rotula is composed of two substances; it is developed, but very late, by one point of ossification.

OF THE FOOT.

Like the hand, it is composed of three portions: the tarsus, metatarsus, and toes.

1st. *The tarsus.*—Placed at the posterior part of the foot, it consists of seven bones, irregularly arranged, and named as follows:—

Calcaneum.—Double irregular, situated below the astragalus, and behind the cuboides: it forms the heel, and is the largest bone of the tarsus. It presents a superior surface, which articulates by arthrodia with the astragalus; an

inferior, which reposes upon the ground, giving attachment posteriorly to the muscles of the sole of the foot ; an external, on which nothing particular is observed ; an internal, on which there is a large groove, for the passage of the long flexor of the toes, for the arteries and nerves going to the sole of the foot ; a posterior extremity, which constitutes the heel, properly so called, and which gives attachment to the tendo Achillis ; an anterior, which articulates by arthrodia with the cuboides.

The astragalus.—Double, irregular, situated below the tibia, above the calcaneum, behind the scaphoides, and at the internal side of the peroneus. It presents a superior surface, which articulates by ginglymus with the tibia ; an inferior with the calcaneum ; two sides, the internal of which articulates with the tibia, and the external with the peroneus ; two extremities, the posterior of which offers nothing remarkable, the anterior articulates with the scaphoides.

The scaphoides.—Double, irregular, situated before the astragalus, and behind the three cuneiforme bones. Its posterior surface articulates with the astragalus ; the anterior with the three cuneiforme bones ; the external and internal sides, the superior and inferior surfaces present nothing particular.

The cuboides.—Double, irregular, situated before the calcaneum, behind the fourth and fifth metatarsal bones, at the external side of the third cuneiforme bone, with which it articulates by two reciprocal surfaces ; its external, superior, and inferior surfaces, present nothing particular.

The three cuneiforme bones.—Double, irregular, placed by the side of each other, before the scaphoides, behind the first, second, and third metatarsal bones, and at the internal side of the cuboides, by the means of the third.

Structure and developement.—Although larger than the bones of the carpus, those of the tarsus present the same phenomena, relatively to their structure and developement, which is effected by one point of ossification.

2d. *Metatarsus.*—It is composed of five bones, arranged as in the hand, and which are counted, commencing with the thumb, by the numerical names of first, second, &c.; they all have an elongated form; the first is the largest and shortest.

Situation and figure.—Double, irregular, situated between the cuboides, the three cuneiforme behind, and the toes in front.

Division.—A body, which occupies their middle portion, and presents nothing particular. *Extremities*, the posterior of which, in the first, second, and third, articulates with the three cuneiforme bones, and in the fourth and fifth with the cuboides. Their anterior, rounded extremity articulates with the first phalanges.

Structure and developement.—Like the bones of the carpus, they are composed of three substances, and are developed by three points of ossification.

3d. *The toes.*—They are five in number, which are called first, second, &c.; the largest is called the great toe. Each is composed of three phalanges. The first are termed *phalanges*, the second *phalangines*, and the third *phalangettes*. As in the hand, the great toe is composed only of two.

The first phalanges.—They are the longest, and are placed between the second in front, and the metatarsal bones behind; their bodies, small, rounded, are covered in part by the inter-osseous muscles. Their posterior *extremities* articulate with the metatarsal bones, and the anterior with the second phalanges.

The second phalanges.—Placed between the first and third, and articulating with the last, the second phalanges offer nothing remarkable.

The third phalanges.—They terminate the point of the feet, and their conformation is similar to that of the fingers in the hand; articulated with the second behind, they offer in front a rounded border, which receives the nail above, and a pulpy substance below.

Structure and developement.—Precisely the same as in the fingers.

THE CONNECTION OF BONES.

OF THE LIGAMENTS OR MEANS OF ARTICULATION, AND OF THE MODE OF PREPARING THEM.

After the example of certain anatomists, I might have placed the history of the ligaments immediately after the description of the bones offering moveable articulations. I have preferred to present their general history in this place. This method, which offers no inconveniences, possesses all the advantages of the others from which it differs. It is essential for the student to prepare and study, with care, this part of his subject. It is the only means by which he will be enabled to understand any thing in reference to the various articulations, and multiplied phenomena of the mechanism of animals, as likewise the theory and treatment of luxations.

The order which I shall follow will be that of the description of the bones, commencing with the ligaments of the articulation of the inferior jaw, and terminating with those of the feet, conforming, in this respect, to the course pursued by the best modern anatomists.

The classification of the articulations adopted by Bichât, appears to me clear and exact, and I shall therefore adopt it in preference.

The cartilages, spinal marrow, medullary juice, the periosteum, and synovia, forming, with the ligaments, the additional part of osteology, or what was formerly called *osteologie fraiche*, there will be found a succinct description of each of these objects in their turn.

OF THE LIGAMENTS IN GENERAL.

Anatomical Preparation.

The preparation of the ligaments exacts in general the removal of all the other parts surrounding the articulations; it is likewise necessary to scrape the bones, and detach the periosteum by which they are enveloped, so as to leave nothing but the ligaments, in order that these parts being perfectly isolated, we may not confound them with the numerous tendons, which are usually inserted in the neighborhood of the articulations. Many of these tendons even furnish aponeurotic expansions, which spread over the articulations, and become confounded with their proper ligaments, so that we are sometimes obliged to abandon their separation.

It is not, however, necessary, as some recommend, in order to render the ligament more apparent, to place the pieces from which we prepare them, in water; for the water removing the coloring principle, it will happen that the remains of muscles, &c., assuming a white color, will become confounded with the ligament, impede the progress of the scalpel, and prevent us from distinguishing and preparing them with that care, which this part of anatomy requires.

The ligaments surrounding the large articulations, such as the ilio-femoral, that of the knee, &c., are rather easy to prepare; but the difficulties increase in proportion as the articulations are more closely united, and the surfaces of the bones are in more intimate relations. Thus, for example, the preparation of the ligaments of the vertebral column is very difficult; so, likewise, are those of the hand and foot.

The ligaments are in general recognized by their white color, by a firm and resisting tissue. Their color is between the shining and silvery aspect of aponeuroses and tendons, and the dull color of the nerves.

OF LIGAMENTS IN PARTICULAR.

Temporo-maxillary articulation.—The mode of union between the inferior jaw and temporal bone consists of three ligaments, the stylo-maxillary and two lateral, divided into external and internal, a capsule of the articulation (synovial membrane), and an inter-articular cartilage (fibro cartilage.) In order to prepare these objects, it will be necessary in the first place to remove as much as possible, the soft parts surrounding the articulation; then, after having raised, by a circular section, all the upper portion of the cranium in order to extract the brain, which will render the piece lighter and less inconvenient, we then make a vertical section of this latter, so that the saw passes from right to left, behind the styloid and mastoid apophyses. To this first section we add another, which divides the two maxillary bones into two equal parts, passing through their centre; in this way we have two pieces precisely similar, on which we may prepare at leisure, the ligaments in question.

Stylo-maxillary ligament.—It extends from the styloid apophysis to the posterior part of the branches of the inferior maxillary. It is very thin, and is covered by the parotid gland. In order not to interfere with the ligament in the direction of this gland, it will be necessary to seize it with a hook, we will then be enabled to detach it more easily from its situation.

External lateral ligament.—This preparation likewise facilitates that of the external lateral ligament, which is in part covered by the superior extremity of the above gland, and by the *conque* of the ear, which we must raise as far as its insertion on the contour of the external auditory canal. Like the stylo-maxillary, the external lateral is very thin, and may be easily raised, when the articulation is freed from the cellular tissue and aponeurotic portions, which cover it.

This ligament, extremely short, extends from the tubercle, at the base of the zygomatic apophysis, to the adjoining part of the condyle of the jaw. Its flattened form, its points of insertion into the parts just indicated will readily cause it to be recognized.

Internal lateral ligament.—In order to have a satisfactory view of it, it will be necessary in the first place to draw outwards the corresponding portion of the divided jaw; the two pterygoid muscles are observed in the exposed interval; these are to be raised, but we must cut with great care on the side of the jaw, for the ligament in question is, as it were, adhering to the external side of the pterygoideus externus; with this precaution, we will preserve this ligament, which presents itself under the form of a small band, coming from the posterior part of the glenoid cavity, and which goes hence to attach itself to the environs of the dental or inferior maxillary foramen. The vessels

of the same name pass between this ligament and the branch of the jaw, in order to enter the dental canal. If we do not lose sight of this disposition of the parts, we will easily distinguish these vessels from the ligament.

The two lateral ligaments correspond likewise to the capsule, the form and extent of which we can recognize without any difficulty, by drawing the condyle of the jaw in different directions, as if we wished to isolate it from the glenoid cavity. Adipose cellular tissue is remarked before and behind the capsule; nothing can be easier than to remove it, as likewise all that may remain of the pterygoideus internus, the posterior extremity of which is fixed in part to the articulation.

The capsule of the articulation should in the first place be studied in situ; then in opening it from without and behind, we will readily discover its interior, in which, besides the articular surfaces, we remark the cartilage of the same name, which may be examined without any preparation.

Description.

Stylo-maxillary ligament. Situation and figure.—Elongated, thin, situated between the temporal and inferior maxillary bones.

Extent.—From the styloid apophysis, to the posterior part of the branches of the inferior maxillary bone.

Division.—It corresponds, without, to the parotid gland and masseter muscle; within, to the pterygoideus. Its superior extremity is attached to the styloid apophysis, and its inferior to the base of the angle of the inferior maxillary, of which it occupies the interstice.

Structure and uses.—All the ligaments have a uniform structure. This is composed of longitudinal and parallel

fibres. It limits, though feebly, the motion of the jaw in front.

External lateral ligament. Situation and figure.—Flat, very short, and situated at the external side of the articulation.

Extent.—From the temporal to the inferior maxillary bone.

Division.—Its external side is covered by the parotid gland; the internal corresponds to the articulation. Its superior extremity is attached to the tubercle at the base of the zygomatic apophysis; its inferior, to the external side of the condyle of the jaw.

Structure and uses.—Composed of longitudinal and parallel fibres, the external lateral ligament prevents the jaw falling too low, and likewise opposes its being drawn too far from the side opposite its insertion.

Internal lateral ligament. Situation and figure.—Somewhat elongated, and situated at the internal side of the articulation.

Extent.—From the temporal to the inferior maxillary bone.

Division.—Its internal side corresponds to the pterygoideus externus; its external to the internal portions of the branches of the jaw, from which it is separated by the inferior dental vessels.

Internal structure and uses.—Composed of longitudinal and parallel fibres, it seconds the action of the preceding during the descent of the jaw, and prevents it from being drawn too much to the outside.

Capsule of the articulation. Situation and figure.—Around the articulation, its figure approaches that of a small sac with two openings.

Extent.—From the temporal to the inferior maxillary bone.

Division.—Its external relations are with the external lateral ligament outwardly, and in the rest of its circumference with a quantity of cellular tissue. Within, it corresponds to the inter-articular cartilage, on which it is reflected in order to form two small sacs, without communication.* Superiorly, the capsule is implanted in front of the fissure of *Glaser* on the one part, and on the transverse apophysis of the temporal, on the other; inferiorly, it embraces the contour of the condyle of the inferior maxilla.

Structure and uses.—Composed of fibres intermingled in every direction, it retains the condyle in its articulating relations with the temporal bone, and secretes synovia.

Inter-articular cartilage. *Situation and figure.*—Circular, situated in the interval of the articulation, below the glenoid cavity, and above the condyle; convex above; concave below; its circumference touches the interior of the capsule on every side.

Structure and uses.—Composed of concentric fibres, this cartilage has for its uses to establish a more exact relation between the condyle and articular surface of the temporal bone, to facilitate the motion of these parts on each other, and to receive a portion of the efforts exercised by the condyle on the glenoid cavity.

The temporo-maxillary articulation permits the motions of descent and elevation of the jaw; in this respect, it is a simple angular ginglymus; it likewise permits the jaw to move forwards and backwards, and from right to left. Here, this articulation furnishes an example of double arthrodia.

* This disposition is observed in all the capsular articulations, whose use is to secrete synovia.

ARTICULATIONS OF THE VERTEBRAL COLUMN.

In all anatomy there is no preparation more-difficult than that of the different ligaments, which unite the vertebræ to each other. The great number of these last, the obscurity of their motion, the extreme approximation of their surfaces, the numerous spines projecting from them will easily explain the reason of these difficulties. In order to overcome them in part, it is necessary to have, besides considerable patience, a perfect knowledge of the articular surfaces, and to proceed to this work with the book in hand.

The articulations of the vertebral column may be distinguished into general and particular. The first are those which, repeated on a number of vertebræ at the same time, offer in all the same objects for study. The second are only observed in certain vertebræ; different in each of these last, they all require to be studied separately. Thus, the articulation of the head with the first cervical vertebra, of this with the second, and of this last with the head, are so many particular and special articulations. A common or general articulation is observed in all the other vertebræ, except in the last and the one next to it, which offer particular articulations with the bones of the pelvis.

Anatomical Preparation.

SPECIAL OR PARTICULAR ARTICULATIONS.

Although the cervical ligament in man is principally intended to serve as a point of support to the muscles of the posterior part of the head and neck, we may also consider it as the means of maintaining the first in its natural rectitude, in reference to the trunk, and of opposing, though feebly, its too great flexion. For this reason I would recommend the student to examine it for a moment before clearing it

of the soft parts, situated at the posterior part of the neck, and which it is indispensable to remove before passing to the preparation of the numerous ligaments appertaining to the articulations of this series.

These articulations are that of the occiput with the first vertebra or atlas, that of the same bone with the second vertebra or axis, and that of the two first vertebræ with each other. We may, on the same vertebral column, prepare not only the ligaments of the articulations in question, but also those of all the vertebræ, as likewise those between these last and the ribs.

The trunk being completely emptied of the thoracic and abdominal viscera, and, in general, of all the soft parts found along the spinal column, we make a section of the ribs about four fingers breadth from their articulation with the column. This is likewise to be separated from the pelvis; then, we make a horizontal section of the head, as if we wished to study its interior, after having removed the whole of the brain; we terminate by sawing the whole anterior part of the base of the cranium, carrying the saw on the basilar apophysis, as near as possible to the occipital foramen, without injuring its contour. We then pass without difficulty to the examination of the articulation between the occiput and atlas.

Occipito-atloidien articulation.—The ligaments which strengthen this articulation are the two vertebral, distinguished into anterior and posterior, and the two capsules.

The two vertebral ligaments, called by some anatomists *surtouts ligamenteux*, are a species of ligamentous band, placed, in front and behind, in the interval which separates the occiput from the first cervical vertebra. In order to render them visible, it will suffice to incline the head alternately forwards and backwards; but if we desire a more

perfect knowledge of them, we will be obliged to saw the posterior portion of the occiput, as near as possible to the foramen of the same name, as also its lateral parts; we must separate the first cervical vertebra from the third, and not be content with studying these ligaments outwardly, but likewise examine them within, after having raised carefully the portions of the membranes of the brain, which line the vertebral canal. We may also, by this preparation, observe the manner in which the vertebral ligaments of the *occipito-atloidien* articulation comport inwardly with each other. We should likewise examine the manner in which the vertebral arteries enter the cranium. They are received into a sort of canal furnished them by the ligamentous portion which, from the posterior arc of the first cervical vertebra, goes to the neighboring part of the foramen magnum occipitis.

The two capsules do not require any other preparation. But in order to see all their particularities at the same time, it will be proper to divide one, and leave the other entire. These capsules are extremely compact, and allow but very limited motion. We should not lose sight of this circumstance, and should remember that the instrument can scarcely pass between the osseous surfaces.

Occipito-axoidien articulation.—As the occipital bone has certain articulating relations with the second cervical vertebra, we must not hastily destroy those which the same bone presents with the first. The ligaments, uniting the occiput with the second vertebra of the neck, are all placed in the interior of the canal; these are the odontoidien and axoidien ligaments. In order to have a good view of these ligaments, we must make a section by means of which all the posterior part of the spinal canal will be exposed, which is also formed by the corresponding portion of the two first

vertebræ which we remove with the saw, guarding carefully the points of articulation of these vertebræ. We can then observe with facility those parts we may desire to prepare. The occipito-axoidien ligament extends from the basilar surface of the occiput, as far as the environs of the third cervical vertebra, passing, in order to arrive there, behind the odontoid apophysis. As it is intimately connected with the odontoidien ligaments placed below, we must, in order to see these last, raise the preceding by lames, which can easily be done with a hook or the extremity of a pair of pincers.

Next comes the odontoidien. It extends from the superior extremity of the odontoid to the two tubercles observed on the lateral and anterior portions of the circumference of the foramen magnum occipitis. By causing the *odontoid apophysis* to execute lateral motions, and similar motions, but in a contrary direction, being imparted to the portion of the occiput preserved for the study of these parts, we will obtain a very exact idea of the form and extent of the odontoidien ligament. We can then separate and raise the portion of the occiput, which is in contact with the first cervical vertebra, by cutting across the ligaments the preparation of which we have just indicated. This is even necessary in order to examine the articulation of the two vertebræ with each other.

Atlido-axoidien articulation.—This articulation is composed of the relations of the odontoid apophysis with the first cervical vertebra, and of those of the two vertebræ with each other. The first offers the transverse ligament, and small anterior and posterior capsules; the second the anterior and posterior ligaments, and the two capsules.

When we have removed with care, the portions of spinal marrow, meninges, and occipito-axoidien ligament, which are found at the entrance of the spinal canal, the transverse

is uncovered. It will be recognized by its direction, its annular figure, its strength and thickness. It will be rendered still more apparent by imparting a rotatory motion to the odontoid apophysis. After having examined it thoroughly, we cut it near one of its attachments, in order to turn it from the opposite side, and see at the same time the small capsule, which unites it to the odontoid. This last presents a second in front, for its articulation with the posterior part of the anterior arc of the first vertebra of the neck. We cut it at its superior portion, and by placing the two surfaces in a contrary direction, its interior may be very satisfactorily examined.

The anterior and posterior ligaments of the two first cervical vertebræ do not offer much difficulty in their preparation. As regards the capsules, it will suffice to divide one and leave the other entire in order to study them together.

COMMON OR GENERAL ARTICULATIONS OF THE VERTEBRÆ.

All the vertebræ articulate with each other: 1st, by their bodies; 2d, by their articulating apophyses; 3d, by plates; 4th, by their spinous apophyses.

The study of the ligaments of the vertebral column does not require that they should be prepared in all the vertebræ; two will suffice, the same mode of articulation being repeated for all the others. But as a ligamentous band extends from above downwards on the anterior and posterior surfaces of the body of each vertebra, so as to form a sort of chain which connects them altogether, we should, before commencing a particular examination of the ligaments of the vertebræ, look for a moment at this species of general envelope. Nothing is easier than to see it on the exterior, after having completely freed the anterior sur-

face of the column of all the soft parts with which it is covered. The ligament in question will be recognized by its situation and extent. It presents here and there portions detached from the bodies of the vertebræ, and under which the point of the scalpel may easily be passed; this cannot be done at the point of the inter-vertebral cartilages, on account of the intimate union which it contracts with these inter-articular substances.

As to the analogous band, placed at the posterior part of the bodies of the vertebræ, and which is only seen in the interior of the spinal canal, we may limit our examination of it to a few vertebræ, in order not to sacrifice the whole column, the preparation of which would be long and tedious. In the contrary case, the saw should remove from above downwards the whole posterior part of the vertebræ; in this way, we will have two semi-rachidien canals: the anterior half will serve for the study of the posterior ligamentous band, the other half for the internal part of the yellow ligaments.

Articulation of the bodies of the vertebræ.—There are no ligaments for the articulation of the bodies of the vertebræ; a cartilage serves as the bond of union; it is called the inter-articular cartilage, inter-vertebral cartilage, or fibro-cartilage. In viewing it successively between all the vertebræ, we perceive that it becomes sensibly thicker from above downwards. If it be cut across, it will be remarked, particularly in the lumbar region, that its centre is softer and whiter than the circumference. Its elasticity is very remarkable, and we may be convinced of this fact by plunging the point of a scalpel into the tissue, which will repel the extremity of the instrument. Whiter and softer in infancy, it becomes yellow in the adult, hard and compact in old age. It is detached with difficulty from the bodies of

the vertebræ; and its separation can only be effected by considerable efforts, unless we boil several of the vertebræ, or allow them to macerate for a long time. It is also necessary to remark the difference in thickness, which this cartilage presents in the three regions of the column, whence result the different curvatures of this part.

ARTICULATION OF THE ARTICULAR APOPHYSES, OF THE
PLATES AND SPINOUS APOPHYSES.

I embrace in one article the preparation of all these parts, because they do not present any great difficulty. It is, however, necessary to know how to distinguish each object. The capsules and yellow ligaments are easy to recognize, on account of their extent and situation; such is not the case with the super-spinous and inter-spinous ligaments. Authors do not agree as to their situation or number. There exists a species of thick, ligamentous band, which, passes successively over all those of this region from the extremity of the spinous apophysis of the last lumbar vertebra; this band appears to prolong itself over the same parts in the dorsal region, but there is no trace of it in the cervical. It is the same as regards the inter-spinous ligaments placed in the interval of the two spinous apophyses. They are observed in the loins and back: but certain anatomists do not admit them in the neck, and pretend that they are replaced by muscles of the same name. The limited extent of these small ligaments, the facility of confounding them with the whitish fibres of the muscles immediately around them, will prevent us from entering more in detail in reference to them.

Description.

OCCIPITO-ATLOIDIEN ARTICULATION.

Anterior ligament. *Situation and figure.*—Flat, thick, and situated between the occiput and first cervical vertebra.

Extent.—From the basilar apophysis to the anterior arc of the atlas.

Division.—The anterior surface is covered by the large and small anterior recti muscles of the head; the posterior corresponds to the ligaments of the odontoid apophysis. Its superior border is attached to the anterior part of the circumference of the foramen magnum occipitale, the inferior to the superior part of the anterior arc of the atlas. Its two extremities are inserted near the capsules.

Structure and uses.—Composed of two planes of fibres, which go in different directions, this ligament strengthens the articulation of the atlas with the head, and moderates the movement of extension in this latter.

Posterior ligament. *Situation and figure.*—Flat, thick, broader than the preceding, and situated between the occiput and atlas.

Extent.—From the posterior part of the foramen magnum to the posterior arc of the atlas.

Division.—Its posterior surface is covered by the large and small posterior recti muscles of the head; the anterior corresponds to the dura mater. Its superior border is attached to the posterior part of the circumference of the foramen magnum; the inferior to the superior part of the posterior arc of the atlas. Its two extremities correspond to the capsule. There is observed on it a groove for the passage of the vertebral artery.

Structure and uses.—Similar to the preceding, as respects its structure and uses, it differs from it only in moderating the flexion of the head.

Capsules. *Situation and figure.*—Circular, situated between the occiput and atlas.

Extent.—From the condyles of the occiput to the corresponding articular surfaces of the atlas.

Division.—The superficial surface of each capsule corresponds to the lateral recti muscles of the head, to the vertebral artery, and sub-occipital nerves; the deep surface corresponds to the articulation. The superior border is attached to the irregular lines on the contour of the occipital condyle, the inferior to those on the corresponding articular surface of the atlas.

The structure and uses are the same as in the other capsules. The articulation of the occiput with the first cervical vertebra permits movements in every direction; but the reciprocal surfaces being nearly even, this articulation is called arthrodia.

OCCIPITO-AXOIDIEN ARTICULATION.

Odontoidien ligaments. *Situation and figure.*—Two in number, elongated, parallel, and situated in the interior of the vertebral canal.

Extent.—From the odontoid apophysis to the occiput.

Division.—They correspond, behind, to the occipito-axoidien ligament; in front, to the occiput. Their inferior extremity is attached to the lateral parts of the summit of the odontoid apophysis, the superior to the internal part of the occipital condyles.

Structure and uses.—Composed of parallel fibres, strong and firm, they strengthen the odontoid articulation, and regulate its motions.

Occipito-axoidien ligament. *Situation and figure.*—Elongated, thin and flat, situated in the interior of the vertebral canal.

Extent.—From the second cervical vertebra to the occiput.

Division.—Its posterior surface is applied to the dura mater; its anterior corresponds to the axis and odontoid. Its superior extremity is fixed to the basilar surface, the inferior is lost in the transverse ligament of the odontoid, and in the posterior vertebral ligament.

Structure and uses.—Composed of parallel fibres, it strengthens the articulation of the occiput with the two first cervical vertebræ of the neck, and that of these last with each other.

ATLOIDO-AXOIDIEN ARTICULATION.

Transverse ligament. *Situation and figure.*—Elongated transversely, thick, nearly semi-circular, and situated in the interior of the vertebral canal.

Extent.—From one of the lateral portions of the atlas to the other.

Division.—Its posterior part is immediately covered by the *occipito-axoidien* ligament; the anterior, smooth and polished, corresponds to the posterior *facette* of the odontoid apophysis. Its two extremities are implanted into irregular lines on the internal part of the lateral portions of the atlas.

Structure and uses.—Composed of strong transverse fibres, the force of this ligament is considerable. It furnishes a point of solid support to the odontoid apophysis, favors its movements of rotation, and prevents this apophysis, when turned backwards, from exercising an injurious compression on the spinal marrow.

The two small capsular membranes of the odontoid apophysis are, one in front and the other behind. The first unites this apophysis to the anterior arc of the atlas, the

second fixes it to the transverse ligament. Both are intended to retain the odontoid apophysis in its place, without interfering with the rotatory movement.

We likewise find, between the two first cervical vertebræ, two ligaments destined to maintain the relations of these vertebræ with each other. One is placed at the anterior part; the other, more considerable, is found posteriorly. These two ligaments, of a very loose texture in order to admit freedom of motion between the two vertebræ, are analogous to those which unite the first of these vertebræ with the occiput.

Capsules.—These two capsules, remarkable for their extreme laxity, do not differ, as to their general form, from those of the first cervical vertebra with the occiput; they admit of free and extensive motion, without the great extension which they enjoy lacerating their tissue.

The articulation of the two first cervical vertebræ by their articular apophyses, is a double arthrodia; that of the odontoid apophysis is a simple lateral ginglymus.

GENERAL ARTICULATIONS OF THE VERTEBRÆ.

Anterior vertebral ligament. Situation and figure.—Elongated, flat, narrow at its superior part, broad inferiorly, situated on all the anterior portion of the vertebral column.

Extent.—From the second cervical vertebra to the anterior part of the sacrum.

Division.—Its anterior surface corresponds, above, to the pharynx, œsophagus, and long muscles of the neck; in the chest, to the aorta, thoracic duct and azygos vein; in the abdomen, to the ventral aorta, to the pillars of the diaphragm and psoas muscles. Its posterior surface is applied rather loosely to the anterior part of the bodies of

all the vertebræ and to the corresponding inter-vertebral cartilages, to which this ligament adheres. Its superior extremity is fixed to the second cervical vertebra, and the inferior in front of the sacrum.

Structure and uses.—The fibres of this ligament are, in general, longitudinal; but their length is not equal to that of the whole of the ligament. It will be perceived that the superficial, which are the longest, do not exceed the space of four or five vertebræ; in proportion as they are deeper seated, they become short. The fibres of this ligament are attached particularly to the inter-vertebral cartilages.

They are intended to bind the articulations of the vertebræ with each other.

Posterior vertebral ligament. *Situation and figure.*—Elongated, flattened, broad at its superior part, narrow inferiorly, situated in the vertebral canal, and lying in its whole extent on the posterior part of the bodies of the vertebræ.

Extent.—From the second cervical to the commencement of the sacral canal.

Division.—Posterior, concave surface, united to the dura mater by cellular tissue; anterior surface applied to the posterior part of the bodies of the vertebræ and inter-vertebral cartilages, with which the ligament contracts strong adhesions. Its superior extremity is fixed to the second cervical vertebra; the inferior, pointed, to the sacral canal.

Structure and uses.—Similar, in these respects, to the vertebral ligament.

ARTICULATION OF THE BODIES OF THE VERTEBRÆ.

Inter-vertebral cartilages. *Situation and figure.*—Twenty-three in number, broad, flat, semi-circular, situat-

ed between the bodies of the vertebræ, and thicker in proportion as they are examined near the inferior portion of the spinal column.

Extent.—The first inter-vertebral cartilage is found between the second and third cervical vertebra, and the last between the fifth lumbar and sacrum. The extent of each cartilage is always in correspondence with the extent of the articular surfaces.

Division.—The superior and inferior surfaces adhere to the corresponding articular surfaces of the vertebræ, with which they contract, as age advances, an intimate union. The circumference of each cartilage corresponds with the vertebral ligaments.

Structure and uses.—Composed of concentric fibres, more firm and dense without, softer and more elastic as they are examined near the centre. The uses of these cartilages are to unite the vertebræ with each other, to assist these last in the formation of the vertebral canal, and to permit limited motions for each cartilage, but which, repeated in all, are very extensive for the whole spinal column.

ARTICULATION OF THE ARTICULAR APOPHYSES.

Capsules.—These small synovial bags, very firm, embrace the circumference of each articular surface of the vertebræ. They correspond exteriorly to the different parts, which cover the column in the direction of the articular apophyses; within, they are extended on these surfaces. Their uses are to maintain the articulation of the vertebræ with each other, in admitting of but very limited motion.

ARTICULATION OF THE PLATES OF THE VERTEBRÆ.

Yellow ligaments. *Situation and figure.*—Broad, flat, quadri-lateral, more apparent within than without the

canal, and situated in the interval of the plates of all the vertebræ from the second.

Division.—The posterior surface is covered by all the muscles of the posterior and profound region of the trunk; the anterior corresponds to the spinal marrow. The superior and inferior borders are fixed to the corresponding borders of the plates of the vertebræ. Their internal extremity corresponds to the spinous apophysis of each vertebra; the external offers nothing remarkable.

Structure and uses.—Composed of transverse, parallel fibres, very firm and of a yellow color, they are intended to fix the vertebræ; and at the same time permit a moderate degree of motion in consequence of their elasticity.

ARTICULATION OF THE SPINOUS APOPHYSES.

Super-spinous and inter-spinous ligaments. *Situation and figure.*—Elongated, placed in the interval of the spinous apophyses of the dorsal and lumbar vertebræ. The super-spinous are attached to the extremity of these apophyses; the inter-spinous correspond to their interval. These last are double; a small space separates them.

Their uses are to maintain together the spinous apophyses of the dorsal and lumbar vertebræ, and to oppose a too extensive motion of the column forwards.

The union of the vertebræ presents several kinds of articulation. That of the articular apophyses is an arthrodia; that of the body furnishes the most remarkable example of the articulation called amphi-arthritis by the ancients, and articulation by continuity, by the moderns. Here there is no motion between the articular surfaces of the vertebræ, but in the proper tissue of the inter-vertebral cartilage, which, for this reason, offers a degree of elasticity, greater in proportion as the individual is less advanced in years; as

it loses its elasticity and becomes hard in old age, this motion, always more feeble, ultimately disappears altogether.

ARTICULATIONS OF THE CHEST.

The chest is, in great part, formed by osseous arcs, called ribs, presenting in front with the sternum, and behind with the vertebral column, articulations which result from these different relations.

At their posterior articulations, the ribs offer, on the one hand, an articular surface at their extremity, received into each of the articular surfaces of the bodies of the vertebræ; on the other hand, the tuberosity of each rib likewise presents an articular surface, received into a corresponding cavity of the transverse apophysis of the vertebra, except in the first and two last, in which these surfaces do not exist.

The anterior articulations of the ribs with the sternum are effected by means of intermediate cartilages, the superior of which join directly with the sternum, whilst the five lower, united only one with the other, have no direct relation with this last bone.

Anatomical Preparation.

The preparation of the articulations at the posterior part of the ribs with the corresponding vertebræ, composed of one capsule and an anterior ligament, requires that we should remove with care the articulated pieces of all the soft parts not connected with their articulation. It is not necessary to prepare all those of the ribs; one alone will suffice. But, in order to see those of the posterior extremity of the rib more satisfactorily, it is necessary in the first place to divide that of the tuberosity, which facilitates the motions of the rib on the vertebra, and gives a more exact

idea of its extent, and of the dispositions of the ligament and capsule. At this point, these are the only means of union. As in this last, the articulation of the tuberosity with the transverse apophysis is extremely firm: both one and the other require that we move the rib frequently in different directions, in order to distinguish more accurately the figure and limited extent of each capsule.

One costo-vertebral ligament only, as I have already remarked, increases the solidity of the articulation; it is seen in the interior of the chest. It is recognized by its exact application over the articulation, which however it exceeds, and by the radiated direction of its fibres.

But the articulation of the vertebral extremity of the rib presents a peculiarity not observed in that of the tuberosity; in a word, except in the first, eleventh, and twelfth, each rib, articulated with two vertebræ at the same time, is retained in place by a small cartilaginous prolongation, which is fixed, on the one hand, to the transverse prominence of the extremity of the rib; and on the other, to the corresponding inter-vertebral cartilage. Nothing is more easy than to observe this disposition, by opening, from above downwards, some of the costo-vertebral capsules.

The preparation of the articulations on the anterior part of the ribs is still less difficult than the preceding. Here the objects are not so concealed. By cutting the cartilages in their middle portion, and by moving in different directions each extremity of the cut cartilage, we may form a very exact idea of the extent and manner in which the ligaments intended to unite these cartilages with the ribs are disposed, on the one hand with these last, and on the other with the sternum.

In examining the costal extremity of each cartilage, we will observe that it is received into a small analogous cavity,

appertaining to the corresponding rib: two small radiated ligaments, strengthen this synchondrotic articulation. One is in front, and the other behind.

The articulation presents the same disposition at the side of the sternum, and the same ligaments are observed there. We, however, remark that between the seventh rib and xiphoid appendage there exists a particular ligament, which unites these two parts together. We should likewise examine the special articulation of the inter-costal cartilages, for nothing should escape the eye and researches of the attentive anatomist.

Description.

COSTO-VERTEBRAL ARTICULATIONS.

Anterior or internal ligament. *Situation and figure.*—Flat, radiated, situated at the anterior part of the articulation.

Extent.—From the head of the ribs to the bodies of the vertebræ.

Division.—The superficial surface is covered by the pleura and by the great inter-costal nerve. The profound surface is applied to the capsular ligament. Fixed in front of the extremity of the rib, it goes in a diverging manner towards the spine, and is attached by three species of fibres, the superior to the body of the vertebra which is above, the inferior to the body of the vertebra which is below, and the middle to the inter-articular cartilage. This disposition is not observed in the first, eleventh, and twelfth ribs, which only articulate with one vertebra.

Structure and uses.—Composed of long superficial, and short profound fibres, with rays from the rib to the vertebra, this ligament is intended to strengthen the articulation, and oppose the too extensive motion of the rib outwardly.

Capsules.—That of the extremity of each rib and of the bodies of the vertebræ is fixed, on one hand, to the circumference of the head of each rib; and on the other, to the contour of the articular surfaces of the vertebræ. It is in great part covered on the side of the chest, by the anterior ligament. In the interior, it corresponds to the inter-articular cartilage. The use of this capsule is not equivocal: extremely firm, it connects the rib to the vertebræ, and admits of very obscure and limited motions.

An inter-articular ligament is found in the interior of each costo-vertebral capsule, except in the first, eleventh, and twelfth. It is composed of a fibrous fasciculus, short and thick, fixed, on the one hand, to the prominent angle of the costal extremity; and on the other, to the angle of the cavity which receives it. This ligament separates, in the costo-vertebral articulations, provided with it, the capsule, which appears to be double; and on the other hand, it is implanted into the corresponding inter-vertebral cartilage.

The costo-vertebral articulations all furnish examples of arthrodia.

COSTO-TRANSVERSE ARTICULATIONS.

The articulation of the tuberosity of the rib with the transverse apophysis is surrounded by a fibrous fasciculus extremely short and firm: all the fibres go, from above downwards, from the transverse apophysis to the neck of the ribs. The costo-transverse capsule, covered in part by the preceding fasciculus, surrounds, on the one hand, the articular facette of the tuberosity of each rib; and, on the other, is fixed around the corresponding facette of the transverse apophyses of the vertebræ.

These different means of union contribute with the preced-

ing, to strengthen the costo-vertebral articulations, and oppose the too great motion of these articulations.

COSTO-STERNAL ARTICULATIONS.

Inter-costal cartilages. *Situation and figure.*—Twelve in number, situated transversely on the anterior part of the chest. Elongated, slightly flattened from before backwards, increasing in length from the first to the seventh, and then diminishing to the twelfth.

Extent.—From the anterior extremity of each rib to the sternum, for the seven first.

Division.—Body and extremities.

The body presents an anterior surface, covered by the pectoral muscles; a posterior or internal surface covered by the pleura; the superior and inferior borders give attachment to the inter-costal muscles. In addition, the superior border of the first affords attachment to the costo-clavicular, and the inferior border of the last to the small oblique muscle.

The external or costal extremity articulates with the corresponding extremity of each rib; the internal, in the seven first, with the sternum, and in the five last it is confounded with the last cartilage going to the sternum.

Structure and uses.—Of a dense and firm tissue, analogous to the general character of other cartilages, they are intended to increase the length of the ribs and afford an elasticity favorable to the dilatation and contraction of the chest.

The articulation of the costal cartilages with the sternum is effected by means of a capsule, an articular ligament and two radiated ligaments, divided into anterior and posterior.

The capsule, very firm, embraces, on one side, the extremity of each sternal cartilage, and on the other, is fixed to the contour of the articular facette of the sternum. Its

external surface adheres in front to the anterior radiated ligament, and behind, to the posterior radiated ligament. Its internal surface corresponds to the articulation.

The inter-articular ligament presents the same disposition as that of the posterior extremity of the ribs.

The anterior radiated ligaments, situated in front of the articulation, are covered outwardly by the great pectoral muscle, and correspond within to the capsule.

The posterior radiated ligaments, situated at the posterior part of the articulation, are covered in the interior of the chest by the pleura, and correspond on the other hand to the capsule.

Both, composed of fibres originating from the cartilage, go in radii to the neighboring part of the sternum.

The structure, uses, and mode of articulation are the same as in the costo-vertebral articulations.

OF THE ARTICULATIONS OF THE PELVIS.

These articulations consist of the sacrum with the vertebral column, of the same bone with the coccyx and haunch bone, of this with the last vertebra and with the haunch bone of the opposite side.

Anatomical preparation.

Although the means of union of every kind, which bind the bones of the pelvis to each other, are extremely multiplied, yet their preparation does not present any great difficulties. This is owing, on the one hand, to the extent of the articular surfaces, and on the other, to the separation and superficial situation of the ligaments, if we except the ligaments of the posterior part of the pelvis, which present, as it were, an inexplicable interlacement. We should, before the dissection of any particular ligament of the pelvis, perform for the whole of this preparation a long and

fatiguing preliminary operation, but which is indispensable. We commence, therefore, by removing the soft parts surrounding the pelvis; we do the same for the superior part of the thighs and inferior portion of the trunk; we then saw the femora about six or eight fingers' breadth from their iliac articulation, as likewise the vertebral column at the same distance; in this way, we shall have a piece on which, besides the proper ligaments of the pelvis, we may likewise study those which unite the sacrum with the last and even the next to the last lumbar vertebra and those of the ilio-femoral articulation, the preparation of which, however, does not belong to this series. From the piece thus isolated, we must remove, rather minutely, all the remaining soft parts, which adhere to the different articular surfaces, without leaving any trace of them on the bones. We should be careful to have the articular surfaces well-exposed; these parts must not, however, be injured by the instrument. Thus, besides the intermediate cartilage of the symphysis, there is a ligament above and below, which it is essential to preserve. Above the posterior symphysis we likewise observe ligaments, which we must preserve; below these same symphises are the great and small sacro-sciatic ligaments, which are not to be touched. In fine, a ligament occupies the totality of the obturator foramen; it must not be removed. Those of the coccyx with the sacrum demand the same attention; when all the parts have been examined and studied, we should then carry the instrument into the proper tissue of the inter-pubien cartilage, in order to understand its structure, and separate for the same purpose, by dividing the two pubes, the cartilages of the posterior symphises. These are the most simple preparations, and the only that are necessary, in order

to study the ligaments and other means of union in the pelvis.

Description.

Sacro-vertebral articulation.—The means intended to unite the sacrum with the last lumbar vertebra do not differ from those which I have already described, when speaking of the articulation of the bodies of the vertebræ with each other. The only difference is, that, in this last articulation, the inter-vertebral cartilage, very thick in front, thinner behind, contributes in this way to the formation of the sacro-vertebral prominence. This conformation, which is apparent in all the lumbar cartilages, is particularly so in the last.

Sacro-coccygien articulation.—The inferior part of the sacrum articulates with the first piece of the coxycy by a mode of union similar to the preceding, which will render it unnecessary for me to speak of it, as likewise of the manner in which the other pieces of the coxycy articulate with each other. But independently of the inter-articular cartilages, there are for the coxycy and sacrum two ligaments called sacro-coccygien. They require a brief notice.

Anterior sacro-coccygien ligament.—This is scarcely sensible, often it cannot be distinguished. It is an assemblage of ligamentous fibres, which go from the sacrum to the pelvic surface of the coxycy.

Posterior sacro-coccygien ligament.—This is much stronger and more distinct than the preceding: fixed superiorly to the borders of the notch terminating the sacral canal, it descends perpendicularly as far as the spinal region of the coxycy, and there expands itself. Its posterior surface, sub-cutaneous, is covered by a few fibres from the

gluteus maximus muscle; the anterior is applied to the coxycx, and contributes to complete posteriorly the end of the sacral canal.

The fibres of this ligament are very numerous, and strengthen the *sacro-coccygien articulation*.

VERTEBRO-ILIAIC ARTICULATION.

There is no direct articulation between the last lumbar vertebra and iliac bones. A ligament intended to strengthen their connection goes from the one to the other of these two bones. It is called the ileo-lumbar.

Ileo-lumbar ligament. *Situation and figure*.—In the lumbar region, elongated, flattened, and triangular.

Extent.—From the iliac bones to the last lumbar vertebra.

Division.—Its posterior surface is covered by the sacro-lumbar and longissimus dorsi muscles; the anterior, by the psoas and iliac muscles. It corresponds superiorly to the quadratus lumborum, and inferiorly to the sacro-iliac symphysis. Its summit, thick, is implanted into the internal part of the iliac tuberosity. From this the ligament goes, spreading in the form of a fan, towards the vertebral column, and its base is attached to the summit of the fifth and fourth lumbar vertebræ.

Structure and uses.—Composed of fibres, which diverge from the iliac bones to the vertebral column, the ileo-lumbar ligament is intended to strengthen the articulation of the inferior part of the vertebral column with the bones of the pelvis, and to oppose its falling on the sides.

SACRO-ILIAIC ARTICULATION.

The sacrum and haunch bones offer, for their reciprocal articulation, an articular surface encrusted with a diarthro-

dial cartilage, which is double [in youth, but becomes more dense and firm in proportion as age advances, and appears at this period to be formed only of one lamæ. This cartilage occupies the articular surface of the sacrum and haunch bones, to which it adheres so intimately, that it cannot be separated but by the greatest efforts.

The other points strengthening the sacro-iliac articulation are two sacro-sciatic ligaments, a sacro-spinous ligament, and a posterior sacro-iliac ligament: some ligamentous fibres, irregularly disposed around the articulation, complete the union; but they do not merit a particular description.

GREAT OR POSTERIOR SACRO-SCIATIC LIGAMENT.

Situation and figure.—Thin, flattened, triangular, situated at the posterior and inferior part of the pelvis.

Extent.—From the tuberosity of the ischium to the lateral part of the sacrum.

Division.—Its posterior surface is covered by the gluteus maximus muscle, to which it gives attachment; its anterior surface corresponds to the small sacro-iliac ligament with which it contracts adhesions; it, likewise, corresponds outwardly to the obturator muscle. Its superior border, oblique from above downwards, and from within outwards, aids in forming the large sciatic notch, and corresponds, in its extent, to the pyramidal muscle, to the sciatic vessels and large nerve of the same name. Its inferior border, oblique like the preceding, contributes to form the sides of the inferior strait. Its internal extremity arises from the two posterior iliac spines, and from the lateral parts of the sacrum; this ligament, at first very broad and thin, afterwards becomes narrow, and its thickness increases in proportion as it approaches the tuberosity of

the ischium, to which it fixes itself by again enlarging. In this spot it furnishes a small falciforme prolongation, which is lost in the internal obturator muscle.

Structure and uses.—The fibres of the great sacro-sciatic ligament, parallel to the side of the sacrum, pass in a converging manner to the tuberosity of the ischium. This ligament is intended to strengthen the articulation of the sacrum with the haunch bones, to present extensive and solid surfaces for the attachment of certain muscles, to complete the walls of the smaller pelvis, and to sustain the weight of the viscera lodged within it.

SMALL OR ANTERIOR SACRO-SCIATIC LIGAMENT.

Situation and figure.—Flattened, triangular, situated in front of the preceding at the posterior part of the pelvis.

Extent.—From the sciatic spine to the sacrum and coccyx.

Division.—Its posterior surface adheres to the great sacro-sciatic ligament. The anterior is covered by the levator ani. Its superior border corresponds in the first place to the inferior border of the preceding, it then crosses it, and contributes, in front, to the formation of the large sciatic notch. Its internal extremity, or base, is attached to the inferior and lateral part of the sacrum, and to the superior and lateral portion of the coccyx: from this, it goes outwards and forwards, crosses the direction of the great sacro-sciatic ligament, and fixes itself to the summit of the sciatic spine.

Structure and uses.—The small sacro-sciatic ligament presents absolutely the same dispositions as the preceding, as regards its structure and uses.

ILIO-SACRAL LIGAMENTS.

The name of ilio-sacral ligaments is given to an assemblage of ligamentous fibres placed at the superior, inferior, and posterior part of the sacro-iliac articulation.

The ligaments of the superior part cover the sacro-iliac symphysis. They extend from the posterior part of the internal iliac fossa to the adjoining portions of the sacrum. These fibres are very short and become confounded with the periosteum, which covers the same parts.

The inferior sacro-iliac ligaments are nothing more than ligamentous bands, which extend from the posterior and superior iliac spine to the last transverse apophysis of the false vertebra of the sacrum. This ligament is covered behind by the gluteus maximus, and it corresponds in front to the sacro-iliac symphysis. The posterior sacro-iliac ligaments are the most numerous and strongest. They consist of a flattened fasciculus, which extends from the iliac apophyses to the lateral and posterior parts of the sacrum. These ligaments are covered behind by the longissimus dorsi and sacro-lumbalis, to which they furnish attachments. They are separated by numerous intervals filled with adipose and cellular tissue.

The uses of all these ligaments are very evident. The multiplicity of their fibres, their limited length, and approximation, render them proper to secure, in a firm and solid manner, the union of the bones of the pelvis with each other.

PUBIC ARTICULATION.

The two haunch bones present in front, for their reciprocal articulation, an articular surface of an elliptical form, encrusted with a cartilaginous plate, the external surface of which adheres to the bone, and the internal sur-

face, free and lubricated with synovia, is simply continuous with the cartilaginous plate of the opposite side. In front and behind, ligamentous fibres are applied to the articulation, which pass from right to left, and in this way strengthen the union of the two bones of the pubis. But, besides these prolongations, there is observed below the symphysis a remarkable ligament, which bears the name of sub-pubien.

This ligament, the form of which is triangular, corresponds in front to the cavernous bodies in man, and to the clitoris in woman; behind, to the neck of the bladder, and to the prostate in man.

We observe, at the anterior and superior part of the symphysis pubis, several ligamentous fibres, which are nothing more than the mingling of the aponeurotic fibres from the pillars of the ring, with those of the recti muscles of the abdomen.

It may be conceived, that from such numerous means of strengthening the articulation of the bones of the pelvis, there would result a solidity, and, as it were, an absolute immobility. This in fact does exist in the ordinary state; but it is not rare to observe, in certain pregnancies, and particularly after laborious accouchemens, the cartilaginous and ligamentous substances, which serve as a means of union, become infiltrated and relaxed by a sort of stagnation of the fluids, caused by the compression of the vessels. A separation, more or less considerable, may then occur in the bones of the pelvis; experience and the examination of females, who have died in consequence of severe labors, confirm this opinion.

The articulations of the bones of the pelvis form what is commonly called an amphiarthrosis or mixed articulation. It is the articulation by continuity of the moderns. The motion, in this species of articulation, is not effected by the

sliding of the surfaces on each other, but in consequence of the elasticity of some of the inter-articular cartilages.

ARTICULATIONS OF THE SHOULDER.

The articulations of the shoulder are, 1st, that of the clavicle with the sternum; 2d, of the scapula with the clavicle. In the first of these articulations, the sternum presents on the one hand, on the lateral portions of its superior extremity, an articular facette, encrusted with a diarthrodial cartilage; on the other hand, there is on the sternal extremity of the clavicle, an articular facette, larger than the preceding, encrusted like it with a cartilaginous plate, separated from that of the opposite side by an inter-articular ligament. This articulation is strengthened by four ligaments, an anterior, posterior, costo-clavicular, inter-clavicular, and two capsules.

In the second articulation, the scapular extremity of the clavicle and the acromion apophysis present a narrow articular surface encrusted with a thin cartilage, which is united by two ligaments and a small capsule.

In addition, the clavicle is united to the coracoid apophysis, without contiguity of surfaces, by two ligaments called, one conoid, and the other rhomboid.

Anatomical preparation.

For the preparation of these different means of union, after removing the muscles which cover the sterno-clavicular and scapulo-clavicular articulations, we must separate the sternum from the ribs and one of the arms from the trunk; but it will not be necessary to have the whole member; it will suffice to saw the humerus in its middle, and as much of the clavicle of the opposite side.

We should preserve the two sternal extremities of the two clavicles, in order to examine the inter-clavicular ligament, which would necessarily be destroyed if only one clavicle were preserved. The ligaments of the sterno-clavicular articulation present but little difficulty, on account of their situation which is, as it were, sub-cutaneous. Such, however, is not the case with the ligaments of the scapulo-clavicular articulation; these are more profoundly seated, particularly the conoid and rhomboid ligaments, which go from the inferior part of the scapular extremity of the clavicle, in the environs of the origin of the coracoid apophysis, covered in part by the acromion.

In preserving the two clavicles in place, we may open, on one side only, the articular capsules, which fix this bone to the sternum and scapula; this will permit us to examine their interior, and preserve those of the opposite side in order to study their general form and extent.

Description.

ANTERIOR STERNO-CLAVICULAR LIGAMENT.

Situation and figure.—Flattened, quadri-lateral, situated in front of the sterno-clavicular articulation.

Extent.—From the clavicle to the sternum.

Division.—Its anterior surface is covered by some fibres of the great pectoral muscle; the posterior adheres to the capsule. It is inserted outwardly in front of the sternal extremity of the clavicle, within to the irregular lines which are seen in front of the articular facette of the sternum.

Structure and uses.—Composed of radiated fibres which go from the clavicle to the neighboring portion of the sternum; it opposes, though feebly, the displacement of the clavicle in front.

POSTERIOR STERNO-CLAVICULAR LIGAMENT.

Situation and figure.—Flattened, situated at the posterior part of the sterno-clavicular articulation.

Extent.—From the clavicle to the sternum.

Division.—It corresponds behind to the sterno-hyoideus and sterno-thyroideus muscles; in front it adheres to the capsule of the articulation. It is implanted exteriorly into the posterior part of the sternal extremity of the clavicle, and interiorly to the adjoining part of the sternum.

Structure and uses.—Although stronger than the preceding, it has the same structure and disposition. It opposes the displacement of the clavicle behind.

COSTO-CLAVICULAR LIGAMENT.

Situation and figure.—Elongated transversely, flattened from before backwards, situated between the clavicle and first rib.

Extent.—From the sternal extremity of the clavicle, to the adjoining part of the first rib.

Division.—Its anterior surface corresponds to the great pectoral muscle, its posterior to the cellular tissue. It fixes itself exteriorly and below to the posterior part of the cartilage of the first rib: above and within to a surface at the internal and inferior portion of the clavicle.

Structure and uses.—Composed of parallel fibres, the longest of which are external; this ligament fixes the clavicle in its sternal articulation, and prevents its separation when the shoulders are raised.

INTER-ARTICULAR LIGAMENT.

Situation and figure.—Elongated transversely, slightly flattened from before backwards, situated in the interval of the two sterno-clavicular articulations.

Extent.—From one clavicle to the other.

Division.—Its anterior surface corresponds to the sterno-cleido mastoid muscle, the posterior to the sterno-thyroid; superiorly, it is concave and free; inferiorly, it corresponds to that depression of the sternum which bears the name of fourchette. Its two extremities are implanted into the sternal extremities of the two clavicles.

Structure and uses.—Composed of parallel fibres, it is intended to maintain the two clavicles in place, and to oppose the separation of their extremities in the descent of the shoulders.

Capsule.—It surrounds the articulation. One of these borders is inserted around the articular facette of the clavicle, the other embraces the circumference of the corresponding facette of the sternum. The four ligaments, of which I have just spoken, encircle it on all sides. The structure and uses are the same as in the other moveable articulations. We remark in the interior of the clavicle a fibro-cartilage, which possesses a similar structure and the same uses as that of the temporo-maxillary articulation.

SCAPULO-CLAVICULAR ARTICULATION.

Capsule.—It attaches itself by its two borders to the circumference of the two articular facettes. Exteriorly, it is surrounded by numerous soft parts. In the interior, there is no inter-articular cartilage. It has the same uses as the other capsules of the same kind.

Several ligamentous fibres, which do not merit a particular description, cover it in all directions.

CORACO-CLAVICULAR LIGAMENT.

Situation and figure.—It results from the union of the conoid and rhomboid ligaments. It is thick and nearly triangular.

Extent.—From the clavicle to the coracoid apophysis.

Division.—Two fasciculi, the internal of which is conoidal, and corresponds to the trapezius muscle; and the external, longer and broader, to cellular tissue. It is fixed, on the one hand, to the posterior and external part of the coracoid apophysis; and, on the other, to the inferior part of the scapular extremity of the clavicle.

Structure and uses.—The fibres of this double ligament pass in different directions. It not only fixes the clavicle in its scapular articulation, but they likewise oppose the luxation of this bone, and retain its fragments in place, when it has been fractured behind. All these articulations are so many arthrodial or planiforme articulations.

ARTICULATIONS OF THE SUPERIOR EXTREMITIES.

These articulations are very multiplied and the ligaments very numerous, on account of the great variety of motions which they execute. These articulations are those of the shoulder with the arm, of the arm with the fore-arm, of this with the hand, and the articulations of this last. I shall examine them successively from the superior to the inferior parts.

Anatomical Preparation.

Scapulo-humeral articulation.—This articulation is composed of a capsule and glenoid ligament or cartilaginous bourrelet. The frequent luxations of the superior extremity are to be attributed to the small number of connecting media, and to the great laxity of the capsule. The head of the humerus surpasses considerably, by its volume, the surface of the glenoid cavity of the omoplate, into which, however, it is received. We may easily be convinced of the fact by regarding for a moment the reciprocal surfaces of

this articulation. Before commencing this examination, the capsule must be exposed; for this purpose, we must remove all the muscles which surround the humerus and omoplate, detach completely the clavicle, and leave nothing but the ligaments which are to constitute the immediate objects of attention. The piece on which the ligaments of the scapulo-clavicular articulation have already been prepared, will answer very well; it is even better than a new piece; because a part of the preparation is already made, at least that which regards the omoplate. It is, however, necessary to remark that we should not be too particular in endeavoring to remove the tendons of the supra-spinous muscles, infra-spinous and sub-scapularis from the capsule, to which they adhere in a very intimate manner.

When we have sufficiently exposed the capsule of the scapulo-humeral articulation, and examined it carefully in order to understand its different relations, we may remove the acromion and coracoid apophyses, which will somewhat interfere with the examination, as also with the preparation of what remains to be studied.

In preparing the ligaments in question on the **two** limbs at once, the same degree of attention will not be **necessary**, one of the two pieces being sacrificed for the **more** exact study of the other. We may also in this case **open** entirely one of the capsules, in order to examine the **interior** of the articulation, and particularly for the purpose of observing the direction of one of the tendons of the biceps which penetrates the articulation, by perforating, as it were, the capsule, and afterwards attaching itself to the circumference of the glenoid ligament.

Cubito-humeral articulation.—This articulation is composed of the relations of the humerus not only with the cubitus, but likewise with the radius. However, the mode

of union is not the same among these different bones. In a word, the humerus articulates, on the one hand, with the cubitus, on the other, with the radius, and these two last the one with the other, without the means of union of one of these articulations answering for the other, and *vice versa*.

It will be necessary to examine them all separately.— Their general preparation presents but little difficulty, when we merely wish to expose them, by separating the soft parts by which they are surrounded; but we must also penetrate their interior, in order to see its particular arrangement.

In order to dissect the capsule, we must displace from above downwards the common tendon of the extensors, cut the posterior ligament of the articulation, and free it from a mass of subjacent adipose matter. In examining it in this place, we will observe that it extends from the olecranon cavity to the superior part of the radius, descends between the two bones, prolongs itself along the neck of the radius, remounts afterwards in front of the articulation, in order to return to the olecranon, from which it is supposed to take origin.

Between the two bones of the fore-arm there is a ligamentous band, called inter-osseous ligament, which unites them, without contiguity of surface, in their whole length. We should also expose it, in order afterwards to pass to the preparation of the ligaments of the fore-arm with the hand, and to the mode of union inferiorly between the two bones of the fore-arm.

Radio-carpal articulation.—In proportion as we study the ligaments of the superior extremity, it will be perceived that the difficulties increase, on account of the multiplicity of the means of union, and of the more intimate ap-

proximation of the surfaces which will be more sensible in the hand, as we shall presently see.

The radio-carpal articulation is the result of the relations of the radius with the two first bones in the first range of the carpus. The radius likewise presents, as has already been observed, an articulation with the cubitus; we cannot separate the preparation nor examination of these two articulations. This rule should also be observed in reference to all the articulations of the hand, which present, 1st, that of the first and second ranges of carpal bones with each other; 2d, that of the second range with the superior part of the metacarpal bones; 3d, that of the head of these bones with the first phalanges; 4th, that of the phalanges with each other. We can only give some general precepts as regards the preparation of those different modes of union, the student continually aiding himself by the description of these parts in order to have a thorough knowledge of them. It is essential to remove carefully all the soft parts and this will prove long and tedious, but we must have the courage to accomplish it.

Description.

The ligaments of the scapulo-humeral articulation are a capsule and the glenoid ligament.

Those of the humero-cubital articulation are an external, internal, anterior, and posterior ligament, and a capsule.

The ligaments of the two bones of the fore-arm may be divided into those of the superior extremity, and those of the inferior extremity.

The first consist of an annular ligament and portion of the humero-cubital capsule. The second are composed of a capsule and cartilaginous portion intermediate to the two

bones; in addition, we find, in the interval of the two bones, from above downwards, the inter-osseous and round ligaments.

The ligaments of the radius with the hand are an external, an internal, an interior, a posterior, and a capsule.

Those of the bones of the carpus are the dorsal, palmar, inter-osseous ligaments, and capsules; for the whole of the carpal bones, there is an external and internal lateral ligament, and some anterior and posterior ligamentous fibres.

For the bones of the carpus with those of the metacarpus, there are dorsal, palmar ligaments, and as many capsules.

The general articulation of the metacarpal bones with the first phalanges, and of all the phalanges with each other, presents palmar, dorsal ligaments, and as many capsules; and for the phalanges, lateral ligaments.

HUMERO-SCAPULAR ARTICULATION.

Capsule. Situation and figure.—Its figure, which is that of a cone, encircles the articulation of the humerus and scapula.

Extent.—From the circumference of the glenoid cavity, to the base of the neck of the humerus.

Division.—It corresponds exteriorly to all the muscles of the shoulder, the tendons of which, in part confounded with its proper tissue, increase its thickness and strength. Interiorly, it corresponds to the articulation, and to the ligamentous bourrelet, to which it adheres in its inferior part. But at the bicipital groove, the insertion of the capsule is interrupted by an opening in which passes the tendon of the biceps. A synovial sheath envelopes this tendon and accompanies it in the interior of the articulation.

Structure and uses.—Its structure does not differ from other capsules : we remark only that it is very thin below, which circumstance favors luxations at this point. Very different from the capsules, which we have so far seen, it admits of very extensive motion.

Glenoid ligament. *Situation and figure.*—Of an annular form, and situated in the interior of the articulation.

Extent.—It encircles the circumference of the glenoid cavity.

Division.—It adheres, by one of its sides, to the glenoid cavity ; by the other, it is contiguous to the head of the humerus. Outwardly, it corresponds to the capsule. This ligament, composed of circular fibres, is intended to increase the extent and depth of the glenoid cavity, and to oppose in this way the displacement of the humerus. The thick synovia which is observed on it gives it a cartilaginous appearance.

Between the acromion and coracoid apophysis there is a ligament of a triangular form, covered by the clavicle and deltoid superiorly : this contributes, with the two preceding apophyses, to form the arch, which furnishes a point of support to the head of the humerus, and opposes its luxations superiorly.

CUBITO-HUMERAL ARTICULATION.

External lateral ligament. *Situation and figure.*—Elongated, somewhat flattened, and situated on the external side of the articulation.

Extent.—From the humerus to the radius.

Division.—Outwardly, it is covered by the extensor muscles of the fore-arm ; within, it is applied to the capsule. It is fixed above into the external tuberosity of the humerus ; it thence passes, in a diverging direction, to the an-

nular ligament, and becomes confounded with the capsule. It sustains the capsule and opposes the motion of the head of the radius outwardly.

Internal lateral ligament. Situation and figure.—Stronger than the preceding, it is flattened, triangular, and situated at the internal side of the articulation.

Extent.—From the humerus to the cubitus.

Division.—Its superficial surface corresponds to the flexor muscles of the fingers; its profound surface adheres to the capsule. It is fixed superiorly to the extremity of the internal condyle of the humerus; inferiorly, it is inserted, on the one hand, into the coronoid apophysis of the cubitus; and, on the other, into its olecranon apophysis. It strengthens the capsule.

At the anterior and posterior part of the articulation, we likewise observe ligamentous prolongations, which are not very apparent, and do not merit any particular description; they are also intended to fortify the capsule.

Capsule. Situation and figure.—It surrounds the articulation.

Extent.—From the cubitus to the humerus and radius.

Division.—It is covered within and without by two lateral ligaments; in front, by the anterior brachial; and behind, by the triceps, and more immediately by the ligamentous expansions of which I have just spoken. It is fixed, on the one hand, into the environs of the olecranon apophysis; and, on the other, below the grand sigmoid cavity of the cubitus. In this place, it furnishes a prolongation, which continues with the superior border of the annular ligament of the radius, in order afterwards to regain the small sigmoid cavity, and terminates at the point from which it started.

RADIO-CUBITAL ARTICULATION.

Annular ligament. *Situation and figure.*—Flattened, curved from without inwards, and describes around the head of the radius three quarters of a circle.

Extent.—From the radius to the cubitus.

Division.—Its superficial portion is covered by the external lateral ligament; its deep-seated surface corresponds to the articulation. Its superior and inferior borders present nothing remarkable.

The inferior articulation of the two bones of the forearm offers: 1st, an inter-articular cartilage, thin, and of a triangular form. It is fixed, on the one hand, into the depression which separates the styloid apophysis from the articular surface of the cubitus; in its course it unites with the fibres of the radio-carpal articulation, and maintains the two bones of the fore-arm in constant relation. 2d, A small capsule, which passes from the radius to the cubitus, and which permits by its extreme laxity considerable motion.

In fine, we remark, between the two bones of the forearm, the inter-osseous ligament and also the round ligament or ligamentous cord of Weitbrecht. The first is very considerable: it presents itself under the form of a thin web, covered in front by the flexor muscles, and behind by the extensors. Its two borders adhere, the external to the radius, the internal to the cubitus. It terminates inferiorly in a point; above, it corresponds to the round ligament, and leaves at this part a free space for the passage of the posterior inter-osseous vessels.

The round ligament is nothing more than a ligamentous faisceau, which goes from the external part of the tuberosity of the cubitus, and descends obliquely beneath the bi-

capital tuberosity of the radius to which it becomes attached.

These two ligaments maintain the relations between the two bones of the fore-arm, and serve as a support to the muscles of the anterior and posterior part of the fore-arm.

RADIO-CARPAL ARTICULATION.

An external lateral ligament is placed on the external side of the articulation; above, it is attached to the summit of the styloid apophysis of the radius; below, to the external part of the scaphoid bone.

An internal lateral ligament is situated on the internal side of the articulation. It is attached superiorly to the styloid apophysis of the cubitus; inferiorly, to the pisiforme bone.

These two ligaments are composed of parallel fibres, united to each other by firm cellular tissue. They limit the lateral motions of the hand.

The anterior or palmar ligament covers all the anterior part of the articulation of the fore-arm with the hand. The posterior or dorsal corresponds behind to the same parts.

The capsule is spread on the articular surface of the radius, then covers the internal surface of the two lateral ligaments, passes over the convexity of the carpal bones, and is fixed to the scaphoides, semilunare, and pyramidale.

CARPAL ARTICULATIONS.

The bones of the carpus are united to each other by ligaments, which may be divided into dorsal or posterior, and into palmar or anterior. Each space is occupied by one of these ligaments; in addition, a small capsule maintains the relations of these different bones, and ensures their so-

lidity. But besides these general means of union, there are, on the sides of the carpus, lateral ligaments, the structure and uses of which are the same as in the preceding articulations. In fine, a general capsule envelopes these small bones, and becomes confounded with all the other ligaments.

CARPO-METACARPAL ARTICULATIONS.

The articulation of the first bone of the metacarpus with the carpus differs from the four following, which have a uniform mode of union. For the first of these articulations, there is a capsular ligament, which attaches itself around the reciprocal articular facettes of the first metacarpal bone, on the one part, and trapezium, on the other.

For the articulation of the four following metacarpal bones, there are dorsal and palmar ligaments, the structure and disposition of which are the same. They originate from the inferior part of the metacarpal range of the carpal bones, and fix themselves into the adjoining part of the four last bones of the metacarpus.

The bones of the metacarpus likewise articulate with each other.

There is a ligamentous band placed at their anterior and posterior part, which serves to strengthen their union.

ARTICULATIONS BETWEEN THE METACARPUS AND PHALANGES AND BETWEEN THE PHALANGES THEMSELVES.

There are, for each articulation of the bones of the metacarpus with the superior extremity of the first phalanges, two small lateral ligaments and a capsule, which present the dispositions already mentioned in the analogous articulations.

The mode of articulation in the other phalanges, does not differ from what has just been said in reference to the articulation of the superior extremity of the first phalanges with the inferior extremity of the metacarpal bones.

The different articulations whose mode of union we have described, vary as to the extent and kind of motion they permit. Thus, the articulation of the head of the humerus with the glenoid cavity is an enarthrosis *par excellence*. That of the same bone with those of the forearm offer two kinds of articulation; the first is a perfect angular gynglimus; the second, a species of enarthrosis.

The articulation of the two bones of the fore-arm with each other presents two examples of lateral gynglimus, and that of these two bones with the carpus, a sort of enarthrosis.

That of the bones of the carpus with each other, as likewise with the metacarpus, is an arthrodia.

The articulation of the phalanges affords examples in all, of a simple or imperfect angular gynglimus.

ARTICULATIONS OF THE INFERIOR EXTREMITIES.

There is considerable analogy between the different articulations of the inferior extremities and those of the superior. If we except the extent and width of the surfaces, we shall find in them a perfect resemblance to what has just been described.

The articulations of the inferior extremities are composed of that of the femur with the cotyloid cavity of the haunch bone. It bears the name of ilio femoral. We find there a capsule, a cotyloid ligament, an inter-articular ligament and a cartilaginous bourrelet. The articulation of the femur with the bones of the leg, called femoro-tibial, is

composed of an external lateral ligament, of an internal lateral ligament, of the rotulien, of the posterior ligament, of two oblique or cross ligaments, and of a capsule, in which are observed semi-lunar or fibro-cartilages.

The peroneo-tibial articulation must be examined above, below, and in the centre. Above, we observe an anterior, a posterior ligament, and a capsule; below, likewise an anterior and posterior ligament, and, in addition, an inter-osseous ligament.

The middle articulation, or that of the centre, merely offers an inter-osseous ligament.

The tibio-tarsal articulation, as likewise those of the other parts of the foot, differ but little from the articulations of the hand.

Anatomical preparation.

The preparation of the ligaments of the superior extremities, bears so strong an analogy to that of the inferior, that this last may be regarded as a repetition of the preceding. I should, therefore, pass it over in silence, if I were not desirous of pointing out certain precautions relative to the particularities, indeed but little important, of the preparation of the inferior extremities. Thus, in the preparation of the ilio-femoral articulation, we must not forget to isolate one of the tendons of the superior extremity of the anterior rectus, which loses itself in the capsule. We must likewise observe the manner in which the inferior extremity of this muscle disposes itself over the articulation of the rotula with the femur. We should not neglect to open the capsule of the great ilio-femoral articulation, as likewise the femoro-tibial, in order to examine its interior, in which we will observe ligaments to be found in no other part. As to the preparation of

the other ligaments in the rest of the inferior extremities, I believe it unnecessary to speak of it, for reasons already stated.

Description.

ILIO-FEMORAL ARTICULATION.

Capsule. Situation and figure.—It encircles the articulation, is the largest and strongest of all those in the human body, but it does not differ from others of the same kind as regards its general form.

Extent.—From the contour of the cartilaginous bourrelet, fixed at the circumference of the cotyloid cavity, to the base of the neck of the femur.

Division.—Its superficial surface is covered by all the muscles which surround the articulation; but the tendons of the psoas and iliacus, of the anterior rectus and small gluteus muscle, furnish prolongations to it, with which it contracts strong adhesions. In the interior it corresponds to the articulation; its superior border is attached around the cotyloid cavity, on the outside of the cartilaginous bourrelet. Towards the anterior notch this border becomes reflected by dividing into two portions, the external of which is lost in the neighboring periosteum, and the internal penetrates the articulation in order to line the cartilaginous layer of the cotyloid cavity. Its inferior border attaches itself, around the base of the neck of the femur, to a prominence going from before backwards from the great to the small trochanter. Like the preceding, it becomes reflected by dividing into two portions, the internal of which is continuous with the cartilaginous covering of the head of the femur.

Structure and uses.—Very thick in front, less so below, and still less at its posterior part; the ilio-femoral capsule is composed of fibres mingling in every direction, more

firm in the interior, more relaxed in the exterior. Its uses are the same as those of all the capsules; but on account of its great thickness, it offers a more powerful resistance to the efforts proper to distend it, and opposes more efficiently in this way the displacement of the head of the femur, and consequently the luxation of this bone.

Ligamentous bourrelet, or cotyloid ligament. Situation and figure.—Of a circular form, situated around the cotyloid cavity, in the interior of the articulation.

Division.—It corresponds exteriorly to the capsule, and interiorly to the cotyloid cavity, passing above the notches, which are remarked around this cavity, and which it in part conceals; towards the anterior notch, it passes above the transverse ligament, which gives it support, and to which it strongly adheres. Its border is free, cutting, and corresponds to the cavity formed by the capsule.

Structure and uses.—The cotyloid ligament is composed of circular fibres which interlace, the spaces of which, filled by thick synovia, give it a cartilaginous appearance. It is intended to augment the extent and depth of the cotyloid cavity. It is not rare to see it ossify in proportion as age advances.

The anterior notch of the cotyloid cavity is closed by a ligament, which has received the names of transverse and inter-articular. Although this ligament only appears to extend from one of the borders of the notch to the other, a more attentive examination will show that it is placed on all the circumference of the cotyloid cavity, and that it becomes confounded with the cotyloid ligament.

We likewise observe, in the interior of the articulation, an elongated fibrous portion, somewhat of a rounded form which, from the roughness observed at the summit of the

head of the femur, where it is fixed, goes to the bottom of the cotyloid cavity, in order likewise to fix itself there.

FEMORO-TIBIAL ARTICULATION.

Rotulien ligament. *Situation and figure.*—Flattened, very broad, situated at the anterior part of the femoro-tibial articulation.

Extent.—From the rotula to the tuberosity of the tibia.

Division.—Its anterior surface is covered by the skin, from which it is separated by loose cellular tissue; the posterior corresponds to the articulation: in the interval there is a mass of fatty tissue, to which anatomists have given the name of adipose ligament. It becomes confounded on the sides with the aponeurosis of the fascia lata. Its superior extremity is fixed to the inferior angle of the rotula which it embraces, becoming confounded at this place with the inferior tendon of the anterior rectus of the thigh. Inferiorly, it is attached to the anterior tuberosity of the rotula.

Structure and uses.—The rotulien ligament is the strongest of all those, which serve for the connection of bones. It is composed of parallel fibres, united by a very dense cellular tissue. Its uses are to fix the rotula on the femur and tibia, to prevent its displacement, and to extend the action of the muscles of the thigh to the tibia.

External lateral ligament. *Situation and figure.*—Flattened transversely, situated at the external side of the articulation.

Extent.—From the femur to the peroneus.

Division.—Superficially, it is covered by the aponeurosis of the fascia lata, and by some fibres of the external portion of the femoral. Profoundly, it corresponds to the articulation from which it is separated by fat and one of the articular arteries. Its superior extremity is attached to

the external tuberosity of the femur, the inferior to the external side of the head of the peroneus.

Structure and uses.—Its structure gives it a tendinous aspect. Its uses are to oppose the too great extension of the leg.

Internal lateral ligament. *Situation and figure.*—Flattened, thinner than the preceding, situated at the internal side of the articulation.

Extent.—From the femur to the tibia.

Division.—It is covered superficially by some fibres of the internal portion of the femoral, and by the species of *patte d'oie* formed by the re-union of some of the muscles of the thigh, and which is observed at the superior and internal part of the tibia. Its profound surface is applied to the articulation, and is separated from it by fat and the internal articular vessels. Its two extremities are implanted into the internal tuberosity of the two bones, femur and tibia.

Structure and uses.—It differs from the preceding, as it is thinner, but it has the same uses.

Posterior ligament. *Situation and figure.*—Flattened, and of a triangular form, situated obliquely at the posterior part of the articulation.

Extent.—From the femur to the tibia.

Division.—Its posterior surface is covered by the plantar muscle, the external jumellus, and by the popliteal vessels. Its profound or anterior surface corresponds to the articulation, and posterior cross ligament. Its inferior extremity, pointed, is fixed to the internal tuberosity of the tibia, in the same spot with the semi-membranosus muscle, of which it appears to be the continuation. From this the ligament goes, spreading in form of a fan, towards the external condyle of the femur, where it becomes attached. It is intended to increase the strength of the capsule.

Capsule or capsular ligament. *Situation and figure.*—From the circumference of the articular facettes of the tibia, to those of the same facettes of the femur.

Division.—Its superficial surface is covered, in front, by the inferior tendon of the anterior rectus, and, below the rotula, by the inferior ligament of this bone; without, by the external lateral ligament; behind, by the oblique or cross ligaments; within, by the internal lateral ligament. Its profound surface is observed in the interior of the articulation. Superiorly, it takes origin from the anterior part of the condyles, covered in this spot by the extensors of the leg; from thence it goes to the posterior part of the articulation, after being reflected on the condyles, which it covers in all their extent; it furnishes a sort of sheath to the cross ligament, which, without this, would be enclosed within the articulation; in fine, it descends on the articular surface of the tibia, and terminates behind the inferior tendon of the rotula, which it embraces in all its extent.

The thickness of the capsule is not considerable. Its uses are the same as those of the other ligaments of the same kind.

The oblique or cross ligaments, so called on account of their direction, are two fibrous cords, very strong, placed at the posterior part of the articulation. One is anterior; it is implanted into the internal side of the external condyle, thence it goes obliquely to the spine of the tibia, and becomes confounded with the semi-lunar cartilage; the other, posterior, is fixed on the external side of the internal condyle, and goes from thence behind the spine of the tibia, where it is implanted, and becomes confounded with the semi-lunar cartilage.

The semi-lunar cartilages, two in number, are placed in the interior of the articulation. Inferiorly, they are ap-

plied one above the other to the corresponding surfaces of the tibia, to which they adhere. Superiorly, they correspond to the condyles of the femur. Their large circumference, the thickest, adheres to the lateral ligaments; their small circumference, very thin, regards the interior of the articulation. These two fibro-cartilages are united to each other, by means of a prolongation of the capsular ligament. They are composed of fibres, which, passing from one of their extremities, go, by describing concentric curves, to that of the opposite side.

Their uses are to line the articular surfaces, and to prevent the effect of pressure, which the extremities of the femur and tibia exert on each other in leaps and falls, and even in ordinary progression.

PERONEO-TIBIAL ARTICULATION.

There are, for the articulation of the peroneus and tibia, ligaments which unite them superiorly, others which have the same uses inferiorly, and finally an inter-osseous ligament.

The superior ligaments are: An anterior, posterior, and a capsule. The first or anterior, of a quadri-lateral form, flattened, is placed on the anterior part of the articulation. It is fixed, on the one hand, into the external tuberosity of the tibia, and, on the other, into the corresponding articular facette of the peroneus.

The posterior, of a figure similar to the preceding, situated at the posterior part of the articulation, is fixed, on the one hand, into the tibia, and, on the other, into the corresponding part of the peroneus.

The capsule has but little extent. It is implanted into the contour of the diarthrodial facette of the tibia, and into the corresponding facette of the peroneus. Superficially,

it corresponds to the two preceding ligaments, and, on the other hand, to the interior of the articulation.

The inferior articulation of the tibia with the peroneus is composed of two ligaments, an anterior and posterior.

The anterior is extended obliquely on the anterior part of the inferior articulation of the two bones of the leg.— Within, it is fixed to the external and anterior tubercle of the inferior extremity of the tibia; without, to the malleolus externus.

The posterior has a situation opposite to the preceding. It is attached; on the one part, to the external and posterior tubercle of the inferior extremity of the tibia, and, on the other, to the posterior portion of the malleolus externus.

These four ligaments have a similar structure, and are composed of parallel fibres, united by very firm cellular tissue. They are intended to strengthen the two bones of the leg against each other in such way as to give them the appearance of immobility, and in this respect, appear to form but one bone.

The inter-osseous ligament, elongated, flattened, placed in the interval of the two bones of the leg, is broad at its superior part, and narrow inferiorly. On its anterior surface the extensors of the toes are sustained; on its posterior, the flexors; its two borders are attached to the prominent lines of the external edge of the tibia, and internal surface of the peroneus. Superiorly, it leaves a large opening for the passage of the posterior tibial vessels. It is formed of fibres, interlaced in every direction, originating equally from the peroneus and tibia. Its uses are not only to unite the tibia and peroneus, but likewise to serve as a point of support to the muscles of the anterior and posterior part of the leg.

TIBIO-TARSAL ARTICULATION.

This articulation offers a capsule and four ligaments, distinguished into anterior, posterior, external, and internal.

The internal ligament, placed on the internal side of the articulation, fixes itself, on the one part, into the malleolus internus; on the other, it sends prolongations, which are implanted into the internal side of the astragalus.

The external ligament, narrow and thick, is placed on the external side of the articulation, and comes from the summit of the malleolus externus; from thence, it passes downwards in a vertical direction, and is inserted into the external side of the calcaneum.

The anterior ligament is composed of two fasciculi, which, from the tibia and peroneus, fix themselves into the external side of the astragalus.

The posterior ligament is likewise composed of two fasciculi, which are fixed, above, into the external and posterior part of the peroneus, and thence pass to the neighboring portion of the astragalus, where they are inserted.

The capsule, similar to all those of the same class, is, as it were, enveloped by the different ligaments, which we have just examined. It is fixed, above, into all the circumference of the large cavity formed by the inferior extremity of the tibia and peroneus. From this border, there goes a prolongation, which attaches itself beneath the two facettes by which these two bones articulate. In its inferior part, it embraces all the circumference of the articular facette of the astragalus.

This capsule, thin and very loose, serves to maintain the union of the bones of the leg with the astragalus, but particularly to secrete and contain a large quantity of synovia,

TARSAL ARTICULATIONS.

The calcaneum and astragalus articulate with each other by two and sometimes three articular surfaces. Each corresponding surface offers a capsule. In addition, there arises from the groove, observed on the inferior surface of the astragalus, a fibrous faisceau, which passes to the corresponding groove of the calcaneum, and maintains these two bones closely in contact. There also arise from the posterior part of the astragalus ligamentous fibres, which pass within to the neighboring part of the calcaneum.

Although the calcaneum is not directly articulated with the scaphoides, there are, however, two ligaments between these two bones, one inferior, going from the internal tuberosity of the calcaneum to the inferior part of the scaphoides; the other, passing from the same tuberosity to the external portion of the scaphoides.

But the calcaneum articulates with the cuboides: for this articulation, there is a capsule, which spreads itself over the two articular surfaces. In addition, there are two ligaments, the superior of which, broad and flattened, extends from the anterior and superior part of the calcaneum to the cuboides; the inferior, thick and very long, extends from the inferior and anterior part of the calcaneum, to the inferior portion of the cuboides.

The scaphoides and cuboides are united to each other, without contiguity of surfaces, by means of two ligaments, one dorsal, situated transversely and quadrilateral, the other, plantar, stronger than the preceding, and rounded.

The cuboides articulates immediately with the third cuneiforme bone by surfaces surrounded by a small capsule and two ligaments, one of which is the dorsal, the other the plantar.

The scaphoides, for its part, articulates by its anterior sur-

face, with the three cuneiforme bones. A common capsule strengthens the relation of these different bones. Three plantar ligaments and as many dorsal pass from the scaphoides to the cuneiforme bones, and increase their respective solidity.

In fine, the three cuneiforme bones articulate with each other. Three superior transverse ligaments, and as many inferior, extend from one to the other of these bones, and strengthen their respective articulation.

TARSO-METATARSAL ARTICULATIONS.

The bones of the metatarsus are articulated with some of the tarsal bones, viz: the first with the first cuneiforme; the second with the second cuneiforme, and likewise with the first and third, so that it is, as it were, enclosed in this triple articulation; the third with the third cuneiforme, and the two last with cuboides; two small cartilaginous plates facilitate the sliding of the bones. We observe, for these different articulations, a small capsule; moreover, between each bone of the metatarsus and the adjoining part of the bone of the tarsus, there are two ligaments, one dorsal, the other plantar. The second bone of the metatarsus alone receives three of them, one from each cuneiforme bone.

METATARSAL ARTICULATIONS.

The bones of the metatarsus articulate with each other by the lateral portions of their tarsal extremity. All present two articular surfaces, except the first, which has none at its internal side, and the fifth at its external. In order to strengthen these reciprocal articulations, the corresponding capsules of the bones of the tarsus, are spread in part over those of the bones of the metatarsus. Moreover, the dor-

sal and plantar ligaments, disposed as in the hand, consolidate these articulations.

Besides the dorsal and plantar ligaments, we find between the posterior extremities of the metatarsal bones, other inter-osseous fibres, which are very strong, and serve to maintain the different relations among the bones.

Finally, above their anterior extremities, there is a transverse ligament, which unites them, the situation and uses of which have considerable analogy with that of the bones of the metacarpus.

METATARSO-PHALANGIEN ARTICULATIONS.

The concave extremity of the first phalanges articulates with the corresponding heads of the metatarsal bones. For this articulation, we observe a small capsule, similar to those in the hand, but more loose, and lateral ligaments divided into external and internal.

PHALANGIEN ARTICULATIONS.

The phalanges of the toes articulate with each other in the same manner as those of the fingers; a small capsule, more extended in the action of flexion than extension, is spread over each of the articulations in particular. Two lateral ligaments, smaller than in the phalanges of the fingers, strengthen the phalangienn articulations.

The articulation of the head of the femur, with the glenoid cavity, is an enarthrosis; that of the femur with the tibia, a double arthrodia.

The two bones of the leg likewise form an arthrodia, notwithstanding the obscurity of the motion.

The articulation of the leg with the foot is a perfect angular ginglymus, when we consider merely the movements of flexion and extension; but it is an arthrodia, if we refer

to the movements in every direction which this articulation permits.

The articulation of the bones of the tarsus, and of those with the bones of the metatarsus, is an arthrodia.

The bones of the metatarsus articulate with the first phalanges by enarthrosis, and the phalanges with each other by angular gynglimi.

CARTILAGES IN GENERAL.

The cartilages, in general, are hard, whitish substances, placed in the different parts of the body, and which, by their situation, structure, and uses, deserve to be distinguished into different kinds; some serve for articulations, others to close or complete certain cavities.

The cartilages which serve for the articulations are those of the moveable articulations, those of the immoveable articulations, and those, in fine, which hold a middle place between the two first, and which are called mixed, or articulations by continuity. The first are observed at the extremity of the bones, which enter into these articulations. They present themselves generally, under the form of a plate more or less thick, which lines the articular surfaces to which they always adhere in a very solid manner. The surface, which corresponds to the interior of the articulation is smooth and polished, continually lubricated by a greater or less quantity of synovia, a greasy and unctuous humor, which facilitates the motion on the articular surfaces of bones. There is constantly spread over these cartilaginous plates a prolongation of the capsular ligament.

The cartilages of the immoveable articulations are only met with in the bones of the head. Visible only in extreme youth, they disappear with age, and ultimately become os-

sified, as we perceive in the solid connection of the flat bones of the cranium.

The cartilages of the mixed articulations are observed between the bodies of the vertebræ, between the bones of the pelvis, and in the interval which separates the ribs from the sternum. They are, in general, of a yellow color, hard, thick, elastic; these are the cartilages *par excellence*: intimately attached to the surfaces of the bones they keep in relation, they permit but limited motions, which are effected at the expense of their elasticity. They become hard with age, and ultimately attain an osseous consistence.

The cartilages of the second kind, or which do not serve for articulations, are of two sorts: they are intended, either to complete a cavity, as, for instance, the inter-costal cartilages, or to form it, as the cartilages of the larynx and nose.

The organization of cartilages presents an interlacement of fibres so very firm, that we can scarcely distinguish the particular direction they follow. Although we cannot perceive sanguineous vessels in them, and though every thing induces us to believe that they only receive, in their ordinary state, white juices, yet certain diseases leave no doubt as to the passage of blood into these substances.

The properties of cartilages are physical and vital. Elasticity is the peculiar character of the first, which is manifested by numerous experiments, whether during life or after death.

The vital properties of cartilages are very obscure; they can only be recognized when disease produces considerable sensibility in them.

These parts are developed nearly in the same way as bones. More thick and supple in the infant, they harden with age, and eventually ossify in great part in old age.

FIBRO-CARTILAGES.

We give, in general, the name of fibro-cartilages to hard, elastic, whitish substances, which hold a middle place, as regards force and thickness, between cartilage properly so called, and the greater number of ligaments. As respects their uses they may be divided into three classes. The first comprehends those which are found in the interior of certain articulations, and which are intermediate to the diarthrodial cartilages. Those of the second class we observe without the articulations. They aid in the formation of the trachea. In fine, the fibro-cartilages of the third class are nothing more than certain fibrous substances met with under the passage of some tendons, whose friction they modify.

As regards structure, properties, and developement, the fibro-cartilage has considerable analogy with the cartilage, but it ossifies both later and more rarely.

THE PERIOSTEUM.

The periosteum is a sort of fibrous membrane, which covers all the bones, except in those places covered by cartilages. This general envelope of the bones is of a dense, resisting tissue, of a greyish color, possessing greater thickness in infancy, thinner in proportion in the adult, where it is also more dense and firm.

The adherence of the periosteum to the bones is inconsiderable in infancy; it becomes greater in proportion as age advances, and in extreme old age it can with difficulty be isolated from the bones. Placed, on the one hand, on the superficies of the bones, the periosteum corresponds, most generally, on the other, to the muscles which send tendinous and aponeurotic prolongations to its proper tissue, and this causes it to appear, in some points, thicker than it really is.

Its organization is very difficult to demonstrate ; we can only perceive fibres, whose direction is very varied, and their density is extreme.

The periosteum, in the fœtus, is soft, spongy, and penetrated by a large quantity of gelatinous fluid. In proportion as age advances, it becomes more firm and dense, and its fibres are likewise more distinct.

Its properties, but little apparent in the ordinary state of life, are developed with remarkable rapidity and intensity in certain affections.

Its uses are numerous and important. Applied to all the external surfaces of the bones, it protects them from the changes they would otherwise undergo by the friction of the muscles, and the pulsation of the arteries. It replaces, under certain circumstances, the solid part of the bone, which has disappeared in consequence of necrosis; in fine, it is the means of affording to the smallest vessels a facility of penetrating the resisting tissue of the bones.

The perichondrium, a membrane of a fibrous nature, is applied to the cartilages, as the periosteum is to the bones.

The tendons and aponeuroses are parts of the fibrous system, whose presence serves to increase the force and extent of the muscles to which they constantly appertain.

As respects their organization, these parts bear a strong analogy to membranes in general.

THE MARROW AND MEDULLARY JUICE.

The marrow, or, if you prefer it, the medullary system, is not uniformly spread over the entire animal economy. It is, on the contrary, only seen in certain points of the osseous system, and especially in the cavities, which the different parts of this system present. Two kinds of cavities

receive the medullary tissue ; hence two modes of viewing it : 1st, in the large cavity of long bones ; 2d, in the smaller cavities of the extremities of these bones, and in the analogous cavities of the flat and short bones.

In the large cavity of the long bones, the marrow, or medullary system presents itself under the form of a membrane, lining all the cavity of the bone, doubling on itself a number of times ; it is of a cylindrical figure and spongy nature. This portion of the medullary system does not appear to communicate with the juice of the same name, placed at the extremities of the long bones.

Its organization is but little known. Certain diseases, scrophula, for example, furnish some means of developing it as likewise its properties. Its uses are better understood. The principal and least equivocal is to secrete the medullary juice by exhalation. It is also known that the medullary juice serves to nourish the bone, as may be ascertained by noticing what occurs to this last when the marrow has been destroyed : its death is the inevitable consequence.

In the numerous cavities at the extremity of the long bones, and in the analagous cavities of the flat and short bones, there will be found an oily juice, which bears considerable resemblance to that secreted by the medullary system of the large cavity in long bones, and which is called medullary. It appears to result from the exhalation furnished by the numerous vessels, which penetrate these cavities ; but it is very difficult to appreciate exactly its organization and properties.

Its uses do not seem to differ from the same juice, secreted by the medullary system in the cavity of long bones.

SYNOVIA.

This humor, which until now has been considered as furnished by the pretended glands situated in the interior of the moveable articulations, is viewed, with more reason, as a secretion of the synovial membranes or capsules of the articulations.

When it is examined, separated from the mass of blood, it presents itself under the appearance of a viscid, whitish, transparent fluid. Its nature, unctuous and ropy, renders it very fit to lubricate the moveable articular surfaces, to facilitate their reciprocal motions, and to prevent any bad effects from their pressure. Its quantity, which is not the same in the different articulations, is always in proportion to the extent and variety of motions, which these articulations permit. It is this, which appears to be the cause of the swelling more or less considerable observed in certain articulations, and which is termed dropsy of the articulations.

MYOLOGY.

Preliminary Exposition.

Notwithstanding the labors of modern anatomists, the muscular system has appeared to me susceptible of being presented under a more methodical arrangement, and which, moreover, accords better with the brilliant applications of modern physiology.

Anatomists have divided the muscles after particular combinations, which are contrary to nature; for it never was her intention to make long, broad, or short muscles; but she has distributed, in each region of the body, organs necessary for the exercise and support of the func-

tions proper to them, and the form which results appertains altogether to the conformation of the parts, and not to any particular arrangement, called natural ; in fine, the surfaces of the body have not been made to receive such and such muscle ; but, on the contrary, each muscle has been organized and disposed in such way as to accommodate itself to the figure of the surface on which it is developed, and particularly to the uses which it is destined to fulfil.

After this brief exposition, I think we may divide the whole muscular system into three distinct orders of muscles, which differ essentially by their situation, by their structure, and especially by their uses.

First Order. *Muscles of flexion, extension and rotation.*—They form the most considerable order of the muscular system ; the mass alone of each muscle, is ordinarily very voluminous. This order is found principally in the extremities : they are the locomotive muscles *par excellence* ; they are found in every part where it is necessary that extensive movements of flexion or extension should occur ; they are observed in the arm, fore-arm, hand, thigh, leg, at the posterior and lateral part of the neck ; in all these places the movements are extensive and very manifest. These are the muscles which have excited the most research, and fixed the particular attention of anatomists : those of the face have singularly embarrassed them, and not being able to place them in their system of general classification, the greater part have associated them with the study of splanchnology.

The elongated form appertains exclusively to the muscles of the first order : it is these that anatomists have called long muscles ; but this length differs singularly in the various muscles ; more considerable in the muscles of the thigh, it is almost reduced to nothing in those of the hand,

which have been placed among the short or small muscles; however, they are essentially the same organs, and all have the same dimension in part, that is their length; if they differ in extent, their structure and uses remain the same.

Structure.—All the muscles of this order have an analogous structure; composed in great part of red fibres, they are ordinarily terminated by an elongated, white portion, called tendon. By prolonging the real extent of the muscle, without increasing the length of its red portion, the tendon contributes to render its contraction more energetic, since it is proved that a muscle is stronger, in proportion as its fibres are shorter and more numerous.

As the extremities are those parts which execute the greatest motion, it is on them that we remark all the muscles of the first order. But we will observe that their form always differs from that we have assigned them, in proportion as they are destined to execute less extensive motions, but not less energetic; which will permit us to divide the first order into two genera.

1st. *Muscles of flexion and extension.*—Almost all of them are parallel to the length of the limbs, elongated, swelled in their middle, and always terminated by one or two tendons, the size and length of which are in proportion to the extent and energy of the motions.

2d. *Rotatory muscles, and muscles of station.*—Less elongated than the preceding, having all a broad point of insertion into the trunk, terminated, however, by a tendon which passes to the extremities.

Second Order. *Muscles of the trunk, of limited and concentrated action.*—Less numerous and strong than the muscles of the preceding order, they still occupy more considerable spaces. We remark them exclusively on the trunk; their principal character consists in their extreme

breadth and inconsiderable thickness; stretched over a very large surface, they would surcharge the body with an useless and inconvenient weight, if their volume equalled that of the muscles of extensive motions.

If the evidence and extent of motion especially characterize the muscles of the preceding order, those of the trunk are particularly remarkable on account of the efforts they manifest in resisting displacements. We cannot call them muscles of locomotion; for, in progression, far from precipitating it, their contraction, on the contrary, tends constantly to draw the line of gravity in the centre, and to maintain the equilibrium, continually broken by the displacement of the inferior extremities; it is true that, in fixing the trunk, in a manner, as it were, immoveable, they add to the security of progression; their numerous points of insertion and great breadth, explain the nature of their uses.

Structure.—Composed in great part of red, contractile fibres, the white portion predominates in several muscles of this order. This white portion is spread out under the form of a thin web, which, not being susceptible of contraction, deprives the contractile part of the faculty of acting on surfaces, which it would have been useless, and even injurious, to place in motion. The breadth of these muscles, which is their most striking character, is principally intended to accommodate itself to the figure of the surfaces, on which they are developed. The ancients admitted in all the muscles a fixed point or origin, and a moveable point or insertion, which induced them to compare them to a *rat à corchè*; but where is this figure found in the muscles of the abdomen?

Third Order. *Muscles of expression, cutaneous, or those of limited motions.*—The muscles of this order are found,

neither on the extremities, nor trunk: they appear to appertain more particularly to the face, to the organs of sense and deglutition; although submitted in great part to the will, we, however, have not always the power of increasing or diminishing their action.

Their varied action, the vivacity and celerity of their movements, have placed man far above other animals. These last, quadrupeds more particularly, and especially the carnivorous class, possess in great perfection the muscles of the two preceding orders: but it is the privilege of man alone to convey an idea of the passions that agitate him, and vary as he pleases the melody of his voice. In this respect, it has been observed that animals, even the most perfect of them, merely make grimaces, whereas man, on the contrary, may, at his will, exhibit the most violent passions, as also the gentlest sentiments.

The muscles of this order are, in general, of small size; but as they are entirely muscular, as it were, the most varied and prompt movement appears to be their essential character; almost all of them are lost in the integuments, or at least are inserted there in all directions: here, there is no tendon, no aponeurosis, no determinate and analogous figure for all; their figure is as varied as their action, and their action is more rapid than thought. But little known even at the present day, physiologists have disdained to study them, and appear to have abandoned their examination to necromancers, jugglers, to the pretended physiognomists, to all those charlatans in fine, who, relying upon our credulity, dare to speak of those things, of which they are absolutely ignorant. However, the muscles of the face are susceptible of the most ingenious and brilliant considerations. Who could ever imitate the viva-

city and fineness of expression of the muscles, which move the lips !

Structure.—Entirely fleshy, the muscles of this order are equally susceptible of contracting in all the points of their limited extent ; there are no tendinous or aponeurotic portions, which would only tend to interfere with the vivacity of their action. Charged with the most detailed expression of the passions, it was necessary that the whole muscle should be equally irritable. In this particular, they are, as it were, separated from the rest of the muscular system ; they have nothing to do with the movements of flexion, extension, rotation, &c. They form for themselves a separate and distinct muscular system, by their situation, structure, and uses. The fibre, which composes them, appears more fine and delicate, more perfectly organized, than in any of the other muscles, and the number and size of the vessels which penetrate them, appear to establish this difference in a still more remarkable manner. Such are the considerations, which I have thought proper to place at the head of Myology.

I shall now pass to the general and preliminary remarks on dissection, which I did not make at the commencement of Osteology, because this last exacts but simple preparations, and the students do not really begin to dissect until on the subject of myology. Do not let it be said that I have neglected method : if I have adopted from preference that which I now submit to the public in this work, it is because, after much reflection, I am convinced that I could not adopt any other ; for I have constantly had in view the interest of the student, and prefer that which would prove useful to him, to what might only serve to gratify my own imagination.

INTRODUCTION

TO THE ART OF DISSECTING.

It does not appear that the art of dissecting was carried to any perfection among the ancients: every thing, indeed seems to prove this, and among the causes which appear to have retarded its progress, we should consider especially their limited knowledge of anatomy, the pusillanimity so evident in their important surgical operations, and the scarcity of anatomical preparations. However, the frequent embalming and opening of animals fit for sacrifice, announce, at least, that they were not entire strangers to this part of anatomy; for certain precepts and rules were necessary in order to guide those who were charged with embalming the dead, and they were not less scrupulous in the autopsical examination of animals, in whose intestines they pretended to fix the destiny of certain men raised to dignities, or even of an entire people; and this deception often being connected with the superstition of the times, considerable address was necessary in order to deceive the eye of the assistants; it is well known that pretended oracles, founded on falsehood, sometimes destined the lot of people and empires.

No matter what might have been the notions acquired by those, who, every day, surveyed the entrails of the animals they had sacrificed, as also the durable monuments which the Greek painters and statuaries have left us of their knowledge in anatomy, this does not change my opinion in reference to the little progress of the ancients in the art of dissecting.

In a word, superficial anatomy was alone necessary for them. The beauty of external form, and the just proportions which they always had before their eyes, in contemplating their cotemporaries, sufficed for their pursuits; and we know that Praxitellus, in order to form his Venus, delineated a feature of each of the celebrated courtezans of his time.

Galen alone, with a view of advancing anatomical science, made the dissection of animals a particular study; since this celebrated man, several anatomists have pursued it with much ardor and success. What do we not owe to the works of Willis, Malpighi, and a host of other learned anatomists, who, embracing the art in its whole extent, or confining their researches to some particular points, equally enriched it with the most precious discoveries! It will be perfected, if anatomists, taking as a guide for their researches and efforts the plan and views proposed by M. Dumeril, which I have already alluded to, would give them more attention in future.

Dissection in anatomy is nothing else than the methodical and accurate preparation of the constituent parts of animals. In order to execute it with success, we must attend to the following considerations:—

Ist. To employ in our anatomical labors good instruments, and to have the necessary quantity for all the preparations. The first, and the most indispensable, are *Scalpels* well tempered, of a convenient form, and so varied as to suit every kind of preparation. Those employed for myology will not answer for angeology, and much less for neurology; stronger for the first, and, as it were, stouter, they should be more delicate, finer and smaller for the two last. The forceps and scissors do not demand less attention: the first, long and strong for myology, should

be smaller for neurology, and their teeth should cross each other in an exact manner. Students will consult neither their interest nor instruction by employing, in their anatomical dissections, instruments as clumsily made, as they are badly tempered. The cutlers Grangeret, Sir Henry, and the two Lesueurs, are alone in possession of very good ones.

2d. To have a general idea of the different regions of the human body, in order to make the proper sections and openings. I shall now present a rapid sketch of them.

The human body, like the skeleton, is divided into the head, trunk, and extremities. The head offers six regions: the first, superior, is called the summit; the second, inferior, the base; the third, anterior, the face; we observe on it, from above downwards, the regions of the forehead, eye-brows, eye-lids and eyes, cheeks, nose, mouth, lips, and chin; a fourth, posterior: on it we remark the neck; two lateral, which present the region of the ear, and that of the temple. Below the head is the neck, divided into an anterior, posterior, and two lateral portions.

The trunk offers four surfaces. *An anterior*; it exhibits the chest and bas-ventre. The first has, on its sides, the regions of the mammæ. The second is divided into three regions; a superior, called epigastric; a middle, umbilical, and an inferior, hypogastric; these three regions are found at equal distances from the curve of the stomach to the pubis, and present a middle and two lateral portions. The middle of the superior region, is called epigastrium, and the sides hypochondria; the centre of the middle region is termed umbilicus, and the sides, flanks, or loins; the centre of the inferior region is called hypogastrium, and the sides, haunches or ilia. Between the

hypogastrium and pubis, anatomists are in the habit of considering a fourth and last region, called inferior hypogastric : the middle is termed the region of the bladder or pubic region, and the sides, the groins.

The *posterior* surface is divided into the region of the back, and that of the loins : both are separated in the whole of their length by the spinous apophyses of the vertebræ, called vulgarly spine of the back ; on the sides of the first surface we observe the region of the shoulders, and the buttocks on that of the second.

The lateral surfaces do not present any particular divisions.

Some anatomists make an inferior region of the trunk ; it presents, in both sexes, the organs of generation. In man we observe, from before backwards, the penis or verge, terminated in front by the glans, on which there is a loose skin, termed prepuce ; below the verge, the scrotum ; farther back, the perineum, which terminates at the anus.

In woman, we observe, from before backwards, the penis and vulva, and, on the sides, the larger lips ; within these, the smaller lips, and clitoris ; lower down, the meatus urinarius, the external orifice of the vagina, the hymen in young girls and virgins, the fourchette, and behind, the perineum extending to the anus.

The superior extremities commence above by the shoulder, are continued by the arm, fore-arm, and hand. At the superior part of the arm and below is the axilla. Between the arm and fore-arm, we observe in front the folding of the arm, vulgarly called the *saignée* and behind, the elbow ; the hand presents internally the palm, and externally the dorsum of the hand ; it commences by the wrist.

The inferior extremities commence above and behind, by the buttocks, and are continued by the thigh, knee, leg, and foot. The posterior part of the knee is called ham, and the posterior part of the leg, calf; below, we observe within and without the two malleoli; the superior portion of the foot is called the dorsum, where we remark, near the articulation with the leg, the bend of the foot; and the inferior, the plantar surface, which terminates behind by the heel.

3d. To be accustomed to open cadavera; to perform it with method and precision. The following is the manner of proceeding :

Opening the head.—It is, without doubt, the longest and most difficult; the rounded form of the head, the hardness of its walls are the ordinary causes of the difficulty attending it. In order, however, to effect it, we must make on the external soft parts a circular section, which, commencing immediately above the region of the eyebrows, passes on the sides, and from this to the external occipital protuberance, and terminates at the same point in front; the head, then strongly held or placed in the centre of a circular body and raised on its borders, the saw must be carried progressively over all the points of the division, which has been made in the integuments. It is essential, in dividing the bones, not to injure the integrity of the dura mater, and that of the brain; this will be avoided, by sawing slowly in proportion as the resistance of the bones becomes less considerable. After this is accomplished, we remove the portion which has been sawed, a species of bowl which serves to receive the brain, or some of its parts, when they have been studied.

Another method, more easy and prompt, imagined and constantly employed by Bichât, consists in opening the

cranium circularly, by repeated blows with a pointed hammer, properly directed. The resistance of the dura mater prevents the concussion being imparted to the brain, and this organ remains untouched.

The other sections of the head, more scientific, and perfectly foreign to the business of students, are unnecessary to be mentioned in a work of this nature.

Opening of the chest.—Commence by making a crucial incision on the integuments of the chest; raise the four flaps and the flesh which cover the bones; then divide all the inter-costal cartilages from above downwards, and as near as possible to their union with the ribs, being careful not to carry the instrument on the lungs or heart: the sternum and cartilages must be raised from below upwards, detaching as we go, the anterior mediastinum; in this way, we will have the chest exposed, and we will be enabled to make the necessary researches. In order to render them more exact and extensive, we may break the ribs near their articulation with the vertebræ, by cutting at first the flesh, which is in the inter-costal spaces, and pulling afterwards strongly upon the ribs, from within outwards; the clavicles are to be treated in the same way. We may, by following a process different from that we have just indicated, commence by a longitudinal incision; which, from the superior extremity of the sternum, is prolonged as far as the xiphoid cartilage. From the inferior part of this first incision, we commence two others, which follow nearly the inferior border of the chest. The two flaps must be raised from within outwards, and from below upwards, and we terminate as in the preceding case.

Opening of the bas-ventre.—If this last is not the most difficult, it is that at least which demands the greatest attention, either as relates to the manner of practising it, or

to the numerous precautions which the abdominal viscera require: free and floating in the cavity of the bas-ventre, the slightest cause, the most trifling *secousse* is capable of changing their situation and numerous relations. To these first are frequently joined organic derangements, the consequence of long disease or serious lesions, occasioned by external blows, as with a sword, knife, &c. A large quantity of water, air, or a fœtus, contained within this cavity, sometimes gives rise to changes and differences, either in the external form of the walls or in the internal disposition of the parts, which merit particular attention. Too much precipitation in the examination of objects leads to error, injures science, and humbles our *amour-propre*. I have known individuals represented as skilful anatomists, err most grossly in autopsical examinations.

That of the bas-ventre requires that we make a first incision, which, from the xiphoid cartilage, is extended to the pubis, leaving the umbilicus untouched: a second incision cuts the first crosswise in the centre, and embraces the extent from one side to the other. The first strokes of the scalpel should comprehend only the skin, cellular tissue, muscles and fat, when there is any; the peritoneum should be divided the last; without this precaution, the intestines would be precipitated without, before the completion of the operation, and this must be avoided, particularly when there is an effusion of liquid in the abdomen. In order to attain this object, it has been proposed to make, at first, a very small incision on the peritoneum, in the environs of the umbilicus, sufficient to allow two fingers to be placed in it, and to pass a bistoury or scalpel, from above downwards, and from below upwards, whilst the fingers sustain and raise this membrane; the flaps are separated with precaution from right to left, as far backwards as possible, and in this way, the abdominal cavity is entirely exposed.

To fulfil the same object, it has been recommended to carry the first incision as far as the umbilicus, and from thence to carry two others obliquely towards the region of the groins; in this way, there will be only three flaps, two superior, which are to be thrown to the sides, and an inferior, which is carried below, in order to cover the organs of generation.

The opening of young infants requires a different process. It may be executed in two ways. The first consists in making an incision in form of an arcade into the abdominal parietes, the convexity of which is placed at the superior and middle part. We extend the two branches on the sides as far as the groins. From this there results a large flap, which is brought from above downwards, and on its internal part we observe the umbilical vessels, the examination of which should not be neglected at this age.

The process consists in making two longitudinal incisions in the whole extent of the abdominal parietes, separated superiorly by two fingers' breadth, and inferiorly by six. This flap is detached above and below, and we turn it towards the umbilicus, which must be preserved. In this manner we will likewise have a very good view of the umbilical vessels.

I shall now pass to some general considerations in reference to the precautions to be observed in the dissection of the different parts in anatomy. The choice of the subject, that of the season, the precautions to be taken by the student himself, form so many essential points, on which I shall make a few rapid remarks.

The choice of the subject for dissection is a thing not to be neglected. Such as would be proper for myology, would be very unfit for neurology. But as it is not always in his

power to make this choice, the student should select the best possible part of the cadaver assigned him; and his performance will deserve high commendation, if, address and intelligence supplying the want of a subject such as he would wish to select, he ultimately triumphs over his difficulties. It is proper that he should use certain precautions relatively to the cadavera of persons who have died of contagious diseases, or which are in an advanced state of putrefaction; but it is unnecessary to become alarmed without cause, and imagine that he will contract a fatal disease from the slightest wound. It is true, that I have seen young men fall victims to their zeal; but I have also seen a considerable number wound themselves rather profoundly and at several different times, without any fatal consequences ensuing.

The season for dissection is not always very favorable, and, with good reason, the winter is always selected as the most proper for anatomical pursuits. However, there are certain days in winter, such as are observed in the months of November and December, or after a thaw, which are as unfavorable as the most beautiful days in summer. This latter season is not proper on account of the rapidity with which the animal parts take on putrefaction. In seasons of intense cold, we cannot dissect, without having fire; but it is a bad practice to warm one's self whilst dissecting, and still worse to place the subject before the fire for the purpose of producing a thaw, nothing destroying it more quickly. Besides the choice of the season, it must be remembered that the morning is more preferable than the evening, and that we should not, if it can be avoided, dissect at night by a candle, for it is fully demonstrated that then the greater activity of the surrounding miasmata renders them more deleterious.

It is likewise necessary for the student to regulate the time of his dissection, and not to carry it beyond the limits prescribed by reason. Too much mental application, and a prolonged stay in the amphitheatres, will injure the health of the student, and make him fall a sacrifice to his industry. It is unnecessary to recommend cleanliness, for the student himself will feel the necessity of it. This cleanliness refers equally to the person who dissects, to the place and the parts under preparation. Nothing can be more præjudicial to the health than the neglect of these precautions. The student should have a dress destined for the amphitheatre; without this precaution he will often carry with him the germ of a disease, which would not have been the case if he had changed his garments. His food should be abundant and substantial, and wine should form part of it. Experience has convinced me that the most part of diseases, among students, during winter, is generally attributable to too great economy in diet, to bad quality of their aliment, and to abstinence from wine. They should never forget to wash their hands in fresh and cold water; of all the anti-septics it is, without contradiction, the best and most abundant; it should be frequently sprinkled over the tables, in the rooms of the amphitheatre; we should wash the parts contained in the large cavities of the human body with a sponge, for putrefaction very soon commences in them.

The aspersion of vinegar and camphorated brandy, fumigations with aromatic plants, particularly with ginger, but especially the disengaging of muriatic acid gas, are so many powerful agents, the frequent use of which will keep up the salubrity of the amphitheatres, and prevent the contagion of certain diseases. There is no need of recommending to the students never to close the windows of the apartment in which they dissect, except when the cold is

intense. The best of all ventilators will be found to be the currents of air, the free and continual passage of which is permitted through the open windows. With these precautions, as wise as they are easy to execute, anatomical amphitheatres, far from inspiring disgust, will become, on the contrary, agreeable and salubrious places of study.

PARTICULAR DISSECTION OF MYOLOGY.

Although of all the parts of anatomy, Myology is the easiest to prepare, as it is the first which students undertake to study, the dissection of it always appears to them to be attended with great difficulty: but this is to be attributed to their inexperience and want of skill. Time and patience, joined with certain indispensable precepts, will soon remove all difficulty, and the student animated with a desire to learn, and having taste for dissection, will, in a short time, become a skilful anatomist.

The muscles being composed of fibres nearly parallel to each other, seem to indicate, as it were, the manner of dissecting them; the most embarrassing part is to expose them, and separate them perfectly from the fat and cellular tissue, under which they are concealed. Certain muscles of the bas-ventre present in this particular very great difficulty. It is, therefore, necessary, in the dissection of muscles generally, that the scalpel follow, as much as possible, the dissection of the fibres, whilst the integuments which cover them is strongly pulled in a contrary sense, so that the point of the instrument, which should be held in the majority of cases as a pen, divides exactly the superficial and very thin layer of cellular tissue, which is found immediately covering the muscle.

The student must, at an early period, accustom himself

to dissect with confidence and promptitude, to extend the incisions with the scalpel as far as possible, to survey, from time to time, the portion of the labor he has accomplished, in order that he may observe more accurately its distribution and arrangement. The muscles of one layer being exposed, he must proceed to the dissection of the deep-seated, as he did for the first; that is, he must raise with care every thing that covers them, removing with the muscles just dissected and studied, the fat, cellular tissue, and every thing that can possibly interfere with the examination of the others.

Different rules have been given for removing momentarily a muscle, which conceals another that we are desirous of studying; some recommend to detach it at one of the points of its insertion; others advise to cut it in the centre, and to turn up the extremities in opposite directions. I do not think we can follow exclusively either of these rules; for that which will answer for one muscle cannot be applied to all indistinctly. The long muscles of the extremities should be divided in their middle, and the two points of insertion preserved. Some of the broad muscles of the trunk should be detached at their point of insertion; others may likewise be cut across; others again, those of the face, for example, are to remain in their situation. All this, moreover, will depend on the place the muscle occupies, the facility of exposing it, and on an infinity of circumstances in reference to which general precepts only can be given.

The best cadavera for the study of myology are those of an elevated stature, strong and vigorous complexion, somewhat advanced in age, and such as have died in a violent and prompt manner. Infiltrated cadavera, too thin or

too fat ; those whose death has been occasioned by a protracted disease are not proper : males are preferable to females.

MUSCLES IN PARTICULAR.

In the preparation, as in the description of muscles, I will be obliged to depart somewhat from the arrangement pursued by modern authors. This work being consecrated especially to the instruction of students, I must necessarily adopt, in the exposition of the different objects of anatomical study, the method which they are obliged to follow in their dissections. On this account, for example, I will commence with the muscles situated on the posterior part of the trunk, because I have remarked that students who have pursued any other mode for the study of myology, scarcely ever dissect these muscles : in a word, of four students who work together, two ordinarily commence with the muscles of the bas-ventre, the other two with those of the face ; but the first, having completed their task much sooner, have not patience to wait for the others ; and in order to be more at their ease in dissecting the inferior parts which have been assigned them, they cut the cadaver into two parts ; those, who are occupied in dissecting the muscles of the face, perform, on the second subject, the dissection of the parts, which were allotted to their companions on the first. In this way, the four students will have had an opportunity, by the end of the winter, of examining all the parts of anatomy, except the muscles on the posterior part of the trunk.

No matter what caution an individual may employ, in order to have method and arrangement in his pursuits, it is rare that he is not sometimes obliged to depart from them ; the human mind would in vain attempt to subject

the operations of nature to the feebleness of his conceptions. It is especially in descriptive sciences that this imperfection is most severely felt; and anatomy presents us numerous examples of it; every thing, in this science, gives us an idea of the most ingenious and wise combinations; but the art which formed them is removed from our sight, and the works of anatomists will always acknowledge it. I desire, and I dare hope, that these reasons will be a sufficient apology for the order I have pursued in the preparation, as also in the examination of the muscles. The following is a table of the principal distributions of myology, such as the dissection of these organs requires.

FIRST REGION.—*Trachelo-Dorso-Lombo-spinal.*

Muscles of the posterior part of the neck, back, and loins.

SECOND REGION.—*Abdominal, cutaneous or superficial.*

Muscles of the bas-ventre.

THIRD REGION.—*Thoracic.*

Muscles of the anterior part of the chest.

FOURTH REGION.—*Lombo-abdominal.*

Profound muscles of the abdomen and generation.

FIFTH REGION.—*Costo-Thoracic.*

Muscles of the sides of the trunk.

SIXTH REGION.—*Epicranial.*

Muscles of the summit of the head.

SEVENTH REGION.—*Facial.*

Muscles of the face.

EIGHTH REGION.—*Temporo-Zygomatic.*

Muscles of the lateral portions of the head, and those which surround the articulations of the inferior maxilla.

NINTH REGION.—*Superficial-cervical.*

Muscles of the anterior part of the neck.

TENTH REGION.—*Lingual.*

Muscles of the tongue.

ELEVENTH REGION.—*Staphylo-pharyngiel.*

Muscles of the pharynx and velum palati.

TWELFTH REGION.—*Laryngiel.*

Muscles of the larynx.

THIRTEENTH REGION.—*Profound-cervical.*

Profound muscles of the anterior part of the neck.

FOURTEENTH REGION.—*Scapulo-humeral.*

Muscles of the shoulder.

FIFTEENTH REGION.—*Humeral.*

Muscles of the arm.

SIXTEENTH REGION.—*Radio-cubital.*

Muscles of the fore-arm.

SEVENTEENTH REGION.—*Carpo-metacarpal.*

Muscles of the palmar and dorsal surfaces of the hand.

EIGHTEENTH REGION.—*Coxo-femoral.*

Muscles of the posterior part of the pelvis and superior part of the thigh.

NINETEENTH REGION.—*Posterior-femoral.*

Muscles of the posterior part of the thigh.

TWENTIETH REGION.—*Anterior, internal, and external femoral.*

Muscles of the anterior, external, and internal part of the thigh.

TWENTY-FIRST REGION.—*Anterior-tibial.*

Muscles of the anterior part of the leg.

TWENTY-SECOND REGION.—*Posterior-tibial.*

Muscles of the posterior part of the leg.

TWENTY-THIRD REGION.—*Tarso-metatarsal.*

Muscles of the dorsal and plantar surfaces of the foot.

FIRST REGION.

Trachelo-dorso-lombo-spinal.

Muscles of the posterior part of the neck, back, and loins.

The muscles of this region are: the trapezius, latissimus dorsi, rhomboideus, the two small posterior serrated muscles, splenius, angularis, two complexi, transversalis, the small and large posterior recti of the head, the small and great oblique, the longissimus dorsi, sacro-lombalis, inter-transversi, and inter-spinales.

Anatomical Preparation.

This preparation is long and fatiguing on account of the great quantity of skin it is necessary to detach, and the continual necessity of isolating exactly the muscles placed beneath. It will be necessary to make an incision which,

from the external occipital protuberance, extends as far as the coccyx, following the direction of the posterior cervical ligament, spinous apophyses of all the vertebræ, sacrum, and coccyx. To this first incision add three transverse : the first, from the spinous apophysis of the seventh cervical vertebra to the acromion ; the second, from the spinous apophysis of the twelfth dorsal process to the termination of the false ribs ; and the third, from the spinous apophysis of the sacrum to the anterior and superior spine of the ilium.

Of the three flaps resulting from these incisions, the superior must be detached obliquely from within outwards, from below upwards, so that the instrument goes continually in the direction of the fibres of the trapezius muscle. The two inferior flaps should likewise be detached from within outwards, and from above downwards. We will follow in this manner the direction of the fibres of the latissimus dorsi, as we did those of the trapezius. Both muscles are easy to recognize ; they terminate, without, by a free border, which furnishes a means of knowing perfectly their extent, and of appreciating more exactly their relations. When this, which is very tedious, and which demands patience and time, is finished, we will then have under our eye the trapezius and latissimus dorsi muscles accurately exposed, which occupy almost the whole of the posterior part of the trunk. The portion of the latissimus dorsi, which goes to the humerus, is not exposed in this preparation ; in pursuing this last portion, we must be careful not to interfere with the preparation of the muscles of the arm : I will hereafter describe these last. The skin of the posterior part of the trunk presents this difference, that from the external occipital protuberance, as far as the middle of the back, it is applied over the muscles, and in the rest of its extent it reposes

on the aponeuroses; its dissection demands more care above, and at its inferior part we may carry the instrument with less precaution, for at this place there is always a thick layer of fat and cellular tissue, which must be removed, before the external surface of the broad aponeuroses of the muscles of the back can be exposed. They will be known by their shining aspect and the great resistance they present to the instrument.

Trapezius.—Before commencing the study of one of these two superficial muscles of the back, it will be proper to detach one of them from each side, in order to examine the relations they present on their internal surface. The trapezius is the first, since it covers a very small portion, it is true, of the latissimus dorsi. Lauth, and the greater number of anatomists, recommend to cut it across, which is a very improper direction, for the rhomboideus, situated immediately below, is constantly interfered with by the instrument. It is much better to detach this muscle, by cutting very near the scapula the tendinous fibres which are attached to it; afterwards, we throw it progressively from without inwards, following, as much as possible, the fibres of the muscles placed beneath, and which are separated from it only by a thin layer of cellular tissue.

Latissimus dorsi.—It should be raised from one side only, from without inwards. I recommend to cut it, in the first place, at the point of its insertion into the omoplate; to abandon consequently the portion which goes to the arm, and which, moreover, may be examined on the opposite side. The dissection of the latissimus dorsi requires us to separate with care the muscle situated beneath, on account of the firm and thin layer of cellular tissue, which divides them.

The moment we perceive this muscle to become aponeurotic, we should abandon its separation; for its aponeurosis

is so confounded with that of the other muscles of the back, that we will endeavor in vain to detach it. As soon as the preparation of these two large muscles (*the trapezius and latissimus dorsi*) is completed, we should then study them, in order to pass to the preparation of the muscles which form the profound layer, and which present considerable difficulty.

In taking a rapid survey of all the objects, which the separation of these two muscles leaves exposed, we will perceive, from above downwards, the splenius; lower down and without, the angularis; still lower and within, the rhomboideus; and in a triangular space, circumscribed by these three muscles, a portion of the sacro-lumbalis, longissimus dorsi, and small superior serratus; below the rhomboideus, the continuation of the sacro lumbalis and longissimus dorsi, covered by the thin aponeurosis of the two posterior serrati muscles; on the last false ribs, the small inferior serrati; between these last and the crest of the iliac bones, a portion of the great and small oblique muscles of the bas-ventre; in fine, the six last false ribs are in part exposed, in consequence of the dissection of the latissimus dorsi.

Rhomboideus.—It is the most superficial, and the first which should occupy us after the dissection and examination of the trapezius and latissimus dorsi. After having studied its disposition and figure, we must cut it cautiously through the middle, and turn aside its two flaps, one within and the other without. I may, perhaps, be reproached here with falling into the same error, which I just now objected to in reference to the manner of isolating the trapezius; the greater thickness of the rhomboideus, its less extent, and the facility of raising it by placing the handle of a scalpel underneath, are the reasons which induce me to pursue this method.

The two serrati muscles.—These do not require much preparation: it will, however, be necessary to observe the common aponeurosis, which unites them, but which is sometimes so thin, that scarcely any traces of it can be seen. In order to expose the sacro-lumbalis and longissimus dorsi, we may either detach the serrati muscles from their insertion into the ribs and turn them within, or cut them across, like the rhomboideus, after having separated them from the loose cellular tissue which covers them, particularly the inferior.

Splenius.—It is only after having terminated the preparation and study of all the muscles of the posterior part of the neck and superior of the back, that we can pass to those of the sacro-lumbalis, and longissimus dorsi, which are to be examined the last. The simple separation of the superior flaps of the skin has exposed the splenius; the cellular tissue, interposed between the skin and this muscle, towards the mastoid apophysis, is very dense; it becomes also very abundant on the lateral parts of the neck; two circumstances which it is important to bear in mind. The splenius is difficult to expose well, and especially to recognize, on account of its attachments to the transverse apophyses of the cervical vertebræ, and the great separation found to exist between this portion called splenius colli, and that which is attached to the head, called splenius capitis. The anatomical study of the parts may admit this distinction, but dissection does not recognize it. The rest of this preparation consists in making an oblique incision into the splenius, which, from its insertion into the superior cervical ligament, goes to the transverse apophysis of the fourth cervical vertebra, and in placing the superior flap upwards and outwards, and the inferior downwards and inwards; this may be accomplished with facility, except towards the head,

where the cellular tissue is more dense and compact. When the splenius is removed, we observe, in all their extent, the angularis, great and small complexus, as also the transversalis.

Angularis.—In detaching the splenius, we will readily perceive the angularis, which is almost bare, under the skin of the lateral parts of the neck. In order to have a good view of it, it will suffice to detach it, with some attention, from the neighboring parts, and to remove the cellular tissue, which surrounds it in every direction. Before separating it entirely, it will be proper to examine it in its place, in order to observe its absolute position and its relations with the adjacent objects.

The large and small complexus.—The preparation and study of these muscles can scarcely be separated; they have nearly the same origin, they are connected in almost all their extent, and their inferior attachments are, as it were, confounded together. I have always remarked the embarrassment of the student in endeavoring to isolate and get a good view of the small complexus particularly. In order to effect it, it will be necessary in the first place to detach accurately and separate the splenius, principally above and outwards; then follow cautiously the external border of the large complexus, on which is situated the small complexus, which is attached, it is true, like the large, to the superior curved line of the occiput, but quite outwards, and it does not descend so low down; it is even useless to cut the small complexus to expose the great one; it will suffice to turn it outwards after having dissected it; both of these muscles will be recognized by the white and tendinous portions, which traverse and mingle with their red portion. After this preparation is terminated, cut across the large complexus, carry the instrument somewhat pro-

foundly, on account of the thickness of the muscle and quantity of cellular tissue, which separates it from the small muscles of the superior and posterior part of the neck. The two flaps of the complexus should be turned, one upwards, and the other downwards, which will very much facilitate the preparation of the muscles situated beneath.

Transversalis.—This small muscle, long and thin, is one of the most difficult to prepare; but this difficulty is to be attributed more to the complicated disposition of the parts, than to any want of skill in the student. Between the sacro-lumbalis and longissimus dorsi within, and the small complexus without, the transversalis is so connected with these different muscles at its two extremities, that it is almost impossible to separate it from them. I do not even recommend the student to attempt it. He must be content to follow, as much as possible, the prolongation upwards and downwards, and abandon it as soon as its connections with the adjacent muscles render its preparation too difficult. Many anatomists do not isolate it from the large muscles situated at the posterior part of the trunk, which M. Chaussier has confounded under the common name of *sacro-spinal*.

The small and large posterior recti muscles of the neck, and the small and large oblique of the same region.—The preparation of these muscles does not require that they should be detached from the parts on which they are placed; but as they are covered by a considerable quantity of cellular tissue, their dissection demands patience and address. By imparting to the head a movement of rotation, alternately to the right and left, we will place the recti and oblique muscles in a state of elongation and tension very favorable for their preparation; for the same reasons it will be necessary to put the head in a state of flexion, which may easily be done by placing it beyond the border of the table,

and abandoning it to its own weight; or by placing the anterior portion of the neck on a block, stone, or any other elevated and solid body, so as to cause a projection of its posterior part: the large rectus, the small and great oblique, circumscribe, by their respective borders, a triangular space, in which are observed the trunk of the occipital artery and first cervical pair.

Sacro-lumbalimus and longissimus dorsi.—They terminate the muscles of the posterior part of the trunk, the successive preparation of which will very much facilitate the study of these last; the only thing necessary to do is, to separate, above only, the sacro-lumbalis which is without, from the longissimus dorsi which is within; for this purpose, we carry the scalpel in the direction of a line, which would be nearly that of the tranverse apophyses of the dorsal vertebræ; but it is unnecessary to extend this separation too far, the two muscles being intimately confounded in their inferior half, and forming, as they descend, a very considerable common mass. The division just indicated will permit us to turn the portions of the sacro-lumbalis outwards; we will then observe the numerous tendons attached to the ribs, and which we must leave in their place. More ample details in reference to the preparation of these muscles would be perfectly useless, because it would be impossible to profit by them. I would recommend to be content with this short exposition, and not to engage in a host of difficulties, from which it will not be easy to extricate one's self; neither would I recommend the student to attempt the dissection of several muscles of the back, mentioned in certain works, but the research of which the most skilful anatomists are compelled to abandon, on account of the confusion resulting from their number, and especially the strong connections and approximation of all their parts.

It is not with these muscles, as with those of the extremities, for example, where the lines of separation are visible and well marked: each of these executing movements peculiar to them, it is indispensable that they should be isolated. On the back, on the contrary, the movement, limited to flexion and extension, is uniform: the muscles situated there are all placed in a parallel direction, and as it were the same; the strong and compact union of these muscles coincides with their uses and contributes to render them more perfect. All this applies especially to the preparation, as also to the study, of the sacro-lumbalis and longissimus dorsi, a fleshy mass, the divisions of which have been strangely multiplied by certain anatomists, but which Professor Chaussier has wisely comprehended under one muscle, to which he has given the name of *sacro-spinal*. In order, however, not to depart too much from the division generally received, I will divide this fleshy mass, which the dissection of the preceding muscles has left exposed, into two muscles, known as the sacro-lumbalis and longissimus dorsi. The transverse-spinous, the inter-spinous of the neck, back, and loins, are so completely confounded with the two preceding muscles, that I have thought it unnecessary to give a particular description of them.

The inter-spinous of the neck, back, and loins, as also the inter-transverse, are, moreover, nothing more than small, fleshy masses, placed, the first, in the interval of the spinous apophyses of the vertebræ, and the second in the interval of the transverse apophyses. In order to expose them to view, we must raise all the portions of the sacro-lumbalis, longissimus dorsi, and all the muscles imagined by authors under the names of long-spinous of the neck, long-spinous of the back, the multifidus of *Albinus*, &c. Even

after this it will be difficult to have a fair view of what are called the inter-spinous muscles of the back and loins.

Description.

TRAPEZIUS.

(*Dorso-sus-acromien.*)

Situation and figure.—Broad, flattened, and triangular, situated at the posterior part of the head and neck, and superior of the back.

Extent.—From the occiput, posterior cervical ligament, and spinous apophyses of the dorsal vertebræ, to the clavicle and omoplate.

Division.—Posterior surface covered by the integuments. Anterior surface, which covers a portion of the large complexus, the splenius, supra-spinatus, angularis, rhomboideus, the small superior serratus, and a portion of the sacro-lumbalis, and longissimus dorsi. An internal border: it commences at the external occipital protuberance, travels along the posterior cervical ligament, and terminates at the spinous apophysis of the eleventh or twelfth dorsal vertebra. A superior border: it extends obliquely from the superior curved line of the occiput, to the external third of the superior border of the clavicle. An inferior border, which extends obliquely from the spinous apophysis of the eleventh or twelfth dorsal vertebra, to the spine of the omoplate and acromion apophysis, and becomes confounded with the preceding.

Direction.—The superior fibres oblique from within outwards, and from above downwards; the inferior, from within outwards, and above downwards; the middle are transverse.

Structure and uses.—Almost entirely fleshy, aponeurotic only at its attachments. It draws the head backwards

and outwards, the shoulder inwards, and maintains the trunk in a vertical position.

L A T I S S I M U S D O R S I .

(*Lombo-Huméral.*)

Situation and figure.—Broad, flattened, nearly quadrilateral, situated at the posterior, lateral, and inferior part of the trunk.

Extent.—From the crest of the ilium, from the spinous apophyses of the sacrum and lumbar vertebræ, and from the six last dorsal, to the inferior angle of the omoplate and bicipital groove of the humerus.

Division.—A posterior surface: it covers a portion of the large and small oblique muscles of the bas-ventre, the inferior ribs, and the corresponding inter-costal muscles, the small posterior serratus, the inferior angle of the omoplate, the infra-spinatus, the large serratus, and the teres major. An inferior border, attached to the posterior fourth of the crest of the ilium. A superior border, free under the integuments; it extends from the spinous apophysis of the sixth or eighth dorsal, to the bicipital groove in the humerus. A posterior border: it is attached to the spinous apophyses of the last dorsal vertebræ, and to those of the lumbar and sacrum. An anterior border which, from the crest of the ilium, goes directly to the bicipital groove in the humerus. At its inferior portion, this border unites with the great oblique of the abdomen by three digitations.

Direction.—The anterior fibres are almost vertical, the following more and more oblique, and the superior horizontal.

Structure and uses.—Aponeurotic below and within, tendinous above, and fleshy in the rest of its extent; it draws the arm downwards and backwards, and keeps it

applied to the trunk ; when we are suspended by the hands and we wish to raise ourselves, this muscle elevates the trunk and approximates it to the arms ; it acts particularly when ascending a ladder, or in climbing, &c.

RHOMBOIDEUS.

(*Dorso-Scapulaire.*)

Situation and figure.—Flat, quadrilateral, situated at the posterior part of the neck, and superior of the back.

Extent.—From the posterior border of the omoplate to the spinous apophyses of the last cervical vertebra, and of the four or five first dorsal.

Division.—A posterior surface, covered in part by the integuments, and in part by the trapezius. An anterior surface : it covers the small superior serratus, splenius, sacrolumbalis, longissimus dorsi, several of the superior ribs and the corresponding inter-costal muscles. Four borders, the inferior and superior of which are free : the external is attached to the base of the omoplate, and the internal to the spinous apophyses of the seventh cervical, and four or five first dorsal vertebræ.

Direction.—All the fibres are slightly oblique from within outwards, and from above downwards.

Structure and uses.—Aponeurotic only at its attachments, fleshy in the rest of its extent, it draws the omoplate upwards and backwards, in approximating it to that of the opposite side.

SUPERIOR SERRATUS.

(*Dorso-Costal.*)

Situation and figure.—Flat, thin, quadrilateral, situated at the superior part of the back, posterior and inferior of the neck.

Extent.—From the seventh cervical and two or three first dorsal, to the second, third, fourth, and fifth ribs.

Division.—Posterior surface, covered by the rhomboid-eus, and a small portion of the angularis and trapezius. Anterior surface: it covers the transversalis, splenius, longissimus dorsi, and sacro-lumbalis. Its superior and inferior borders are free: the internal is fixed to the spinous apophyses of the seventh cervical, and two or three first dorsal: the external, serrated, is attached to the external and posterior surface of the second, third, fourth, and fifth ribs.

Direction.—Slightly oblique from within outwards, and from above downwards.

Structure and uses.—Aponeurotic within, fleshy without, it raises the ribs to which it is attached.

INFERIOR SERRATUS.

(*Lombo-Costal.*)

Situation and figure.—Thin, flat, quadrilateral, situated at the inferior part of the back.

Extent.—From the two last dorsal vertebræ, and two or three lumbar, to the four last ribs.

Division.—Posterior surface, covered by the latissimus dorsi, which is strongly attached to it: anterior surface, which covers a portion of the sacro-lumbalis, longissimus dorsi, the aponeurosis of the transversalis, and the three or four last ribs. Its superior and inferior borders are free: the internal is fixed to the spinous apophyses of the two last dorsal and three first lumbar vertebræ; the external to the posterior part of the four last ribs.

Direction.—Slightly oblique from within outwards, and from below upwards.

Structure and uses.—Aponeurotic within, fleshy without, it pulls down the last false ribs.

SPLENIUS.

(Cervico-mastoidien.)

(Dorso-trachélien.)

Situation and figure.—Flat, elongated, situated at the posterior part of the head, lateral of the neck, and superior of the back.

Extent.—From the occiput, posterior cervical ligament, and the two first cervical vertebræ, to the seventh of the neck, and to the five first of the back.

Division.—Posterior surface, covered by a portion of the sterno-cleido-mastoideus, angularis, superior serratus, rhomboideus, trapezius, and integuments. Anterior surface, which covers the large and small complexus, longissimus dorsi, and transversalis. Borders: the internal, free above, is attached below to the posterior cervical ligament, to the spinous apophyses of the seventh cervical, and four or five first dorsal vertebræ; the external is free from the spinous apophysis of the fifth dorsal, to the transverse apophyses of the two first cervical, to which it is attached. Extremities: the superior, broad, is inserted into the mastoid region of the temporal bone, and into the environs of the superior curved line of the occiput; the inferior, terminating in a point, is attached to the spinous apophysis of the fifth dorsal vertebra.

Direction.—Oblique from below upwards, and from within outwards.

Structure and uses.—Aponeurotico-tendinous at its attachments, fleshy in the rest of its extent, it draws the head from its side, by imparting to it a rotatory movement in the same sense,

ANGULARIS.

(*Trachelo-scapulaire.*)

Situation and figure.—Elongated, situated on the lateral portions of the neck.

Extent.—From the four first cervical vertebræ to the omoplate.

Division.—External surface, covered by the trapezius and sterno-mastoideus: internal surface, applied to the splenius, transversalis, and sacro-lumbalis. Extremities: the superior, divided into four portions, is attached to the transverse apophyses of the four first cervical vertebræ: the inferior is fixed to the superior angle of the omoplate.

Direction.—Oblique from above downwards, and from before backwards.

Structure and uses.—Tendinous at its attachments, fleshy in the rest of its extent, it raises the omoplate, and in some cases, draws the head and neck towards the shoulder.

COMPLEXUS MAJOR.

(*Trachelo-occipital.*)

Situation and figure.—Elongated, thick superiorly, terminating in a point inferiorly, and situated at the posterior part of the head and neck, and superior of the back.

Extent.—From the occiput, to the six last cervical, and five first dorsal vertebræ.

Division.—A posterior surface, covered above by a very small portion of the trapezius, lower down by the splenius, small complexus, and transversalis. An anterior surface, which covers the straight and oblique muscles of the head, and the posterior branches of the cervical nerves. Borders: the internal is parallel to that of the opposite side at its superior part; it departs from it in the rest of

its extent, and is separated from it by the spinous apophyses of the cervical vertebræ: the external, free superiorly, is attached, in the rest of its extent, to the transverse apophyses of the six last cervical vertebræ and five first dorsal. Extremities: the superior is inserted into the space between the two curved lines of the occiput, the inferior is fixed to the transverse apophysis of the fifth dorsal.

Direction.—Slightly oblique from above downwards, and from within outwards.

Structure and uses.—Aponeurotico-tendinous at its attachments; the fleshy portion, which is abundant, is often intersected by a species of tendon, but authors do not describe its figure and distribution: it draws the head backwards, and maintains its rectitude on the trunk.

COMPLEXUS MINOR.

(*Trachèlo-mastoidien.*)

Situation and figure.—Elongated, thin and narrow, situated at the posterior part of the head and neck.

Extent.—From the mastoid region of the temporal bone, to the four last cervical vertebræ.

Division.—A posterior surface, covered by the splenius and transversalis; an anterior surface, applied in nearly its whole length to the great complexus. Borders: the internal is confounded with the great complexus; the external is confounded above with the splenius, and attached below to the transverse apophyses of the four last cervical vertebræ. The superior extremity is fixed to the posterior part of the mastoid apophysis; the inferior to the transverse apophysis of the seventh cervical vertebra.

Direction.—Vertical.

Structure and uses.—Tendino-aponeurotic at its attachments, fleshy in the rest of its extent, it draws the head backwards.

RECTUS CAPITIS POSTICUS MAJOR.

(*Axoido-occipital.*)

Situation and figure.—Elongated, situated at the posterior part of the head.

Division.—A posterior surface, covered by the large complexus; an anterior surface, placed on the small rectus, and posterior arc of the atlas; borders, which offer nothing remarkable; a superior extremity attached to a small depression, which is remarked beneath the inferior curved line of the occiput; an inferior extremity, fixed to the spinous apophysis of the second cervical vertebra.

Direction.—Oblique from above downwards, and from without inwards.

Structure and uses.—Slightly tendinous at its attachments, fleshy in the rest of its extent, it carries the head backwards, and makes it execute a movement of rotation.

RECTUS CAPITIS POSTICUS MINOR.

(*Alloido-occipital.*)

Situation and figure.—Elongated, flat, situated at the posterior part of the head and superior of the neck.

Extent.—From the atlas, to the inferior curved line of the occiput.

Division.—Posterior surface, covered by the large complexus, and a part of the posterior rectus capitis major; anterior surface, applied to the occiput and vertebral artery; borders, which offer nothing remarkable; superior extremity, which is attached below the inferior curved line of the oc-

ciput; inferior extremity, fixed to the posterior arc of the atlas.

Direction.—Nearly vertical.

Structure and uses.—But slightly tendinous at its points of insertion, fleshy in the rest of its extent, it extends the head and maintains it erect on the trunk.

OBLIQUUS MINOR, OR OBLIQUUS CAPITIS SUPERIOR.

(*Atloido sous-occipital.*)

Situation and figure.—Elongated, slightly flat, situated at the posterior, superior, and lateral part of the neck.

Extent.—From the occiput to the transverse apophysis of the atlas.

Division.—A posterior surface, covered by the splenius, the large and small complexus; an anterior surface, applied to the occiput and vertebral artery; borders, which offer nothing particular; a superior extremity, which is attached to the inferior curved line of the occiput; an inferior extremity, which is fixed to the transverse apophysis of the first cervical vertebra.

Direction.—Oblique from above downwards, and from within outwards.

Structure and uses.—Its structure is similar to that of the preceding muscle, and its uses are to extend the head and incline it from the side,

OBLIQUUS MAJOR, OR OBLIQUUS CAPITIS INFERIOR.

(*Axoido-atloidien.*)

Situation and figure.—Elongated, slightly rounded, situated at the superior and lateral part of the neck.

Extent.—From the first to the second cervical vertebra.

Division.—A posterior surface covered by the great and small complexus; an anterior surface, applied to the ver

tebral artery and the space between the two first cervical vertebræ; there are no borders to this muscle. A superior extremity, which is attached to the transverse apophysis of the first cervical vertebra; an inferior extremity, to the spinous apophysis of the second.

Direction.—Oblique from above downwards, and from without inwards.

Structure and uses.—The structure is the same as that of the preceding muscles; its use is to impart to the head a movement of rotation.

TRANSVERSALIS.

(Comprised in the sacro-spinal.)

Situation and figure.—Elongated, thin at its two extremities, thickest at its middle portion; situated at the posterior and lateral part of the neck, and superior of the back.

Extent.—From the five or six cervical vertebræ, to the four or five first dorsal, after the second.

Division.—A posterior surface, covered, in part, by the sacro-lumbalis and longissimus dorsi; an anterior surface applied to the large and small complexus; it contracts strong adhesions with these muscles, which renders its examination and dissection very difficult. Its superior extremity is attached to the transverse apophysis of the fifth cervical, and the inferior to the transverse apophysis of the sixth or seventh dorsal vertebra; it is likewise attached to all the intermediate transverse apophyses.

Direction.—Oblique from above downwards, and from without inwards.

Structure and uses.—Tendinous at all its attachments to the vertebræ; fleshy in the interval, it extends the cer-

vical portion of the vertebral column, and inclines it from the side.

SACRO-LUMBALIS.

(Comprised in the sacro-spinal.)

Situation and figure.—Elongated, thick in its inferior part, thinner at its superior, and situated at the posterior portion of the trunk.

Extent.—From the sacrum, os ilium, and posterior part of all the ribs, to the four last cervical vertebræ.

Division.—A posterior surface covered by the latissimus dorsi, the two serrati, rhomboideus, trapezius, and aponeuroses of the small and great oblique of the abdomen; an anterior surface applied to the sacrum, the aponeurosis of the transversalis, external and posterior surface of the ribs, and to the corresponding inter-costal muscles; an internal border, the only one remarkable, united in nearly all its extent to the longissimus dorsi. Extremities: the inferior is attached to the posterior fourth of the crest of the ilium, and to the adjoining portion of the sacrum; the superior, to the transverse apophysis of the third or fourth cervical vertebra.

Direction.—Slightly oblique from above downwards, and from without inwards.

Structure and uses.—The aponeurotic and tendinous portion is more considerable than the fleshy. A broad aponeurosis is remarked below, and tendons at its attachment to the ribs and transverse apophyses of the vertebræ. It produces the direct extension of the trunk, which it maintains erect; its numerous points of attachment fit it very well for this purpose.

LONGISSIMUS DORSI.

(Comprised in the *sacro-spinal*.)

Situation and figure.—Elongated, thick at its inferior part, thinner superiorly; situated at the posterior part of the trunk, and occupies its whole length.

Extent.—From the sacrum, to the transverse apophysis of the first dorsal vertebra.

Division.—A posterior surface, covered by the aponeuroses of the oblique and transverse muscles of the bas-ventre, the two serrati, rhomboideus, latissimus dorsi, trapezius and splenius; an anterior surface, applied to the sacrum, transverse apophyses of the loins and back, and to the ribs and corresponding inter-costal muscles. The internal border corresponds to the spinous apophyses of all the vertebræ; the external is united to and confounded with the sacro-lumbalis. The inferior extremity is attached to the sacrum and posterior quarter of the crest of the os-iliium; the superior, to the transverse apophysis of the first dorsal vertebra.

Direction.—Vertical.

Structure and uses.—A broad aponeurosis, confounded with that of the sacro-lumbalis, is observed at its inferior part; tendons at its attachment to the transverse apophyses, and the fleshy mass in the intervals; it produces and maintains the direct extension of the trunk.

These three last muscles form with the inter-transverse of the loins, the *sacro-spinal*, which is composed of a *costo-trachélienne*, *dorso-trachélienne*, and *lombo-cervical* portion.

The muscles, we have just examined present various uses, which are independent of each other; we shall now consider them successively.

The trapezius, splenius, two complexus, and even the angularis have more especially for their uses to impart to the head extensive movements of rotation, to maintain its equilibrium on the trunk, and to oppose the efforts it continually makes to incline forward and fall on the chest. When the action of these muscles is very weak or momentarily suspended, as in syncope, intoxication or sleep, then the head, abandoned to its proper weight, and obedient to the laws of gravity, is carried forward, and even occasions the fall of the individual, if he be standing, sitting, or on his knees.

The rhomboideus acts only upon the shoulder, which it draws backwards, and fixes to the trunk.

The small muscles of the profound region of the neck, without producing very extensive movements, have nevertheless very important uses. They impart to the head, when it is perfectly in equilibrio, those numerous and rapid movements of rotation and slight inclination. Very near the centre of action, they have need only of a slight effort in order to make the head roll upon itself, which obeys with the more facility, as the surfaces by which it reposes on the cervical portion of the vertebral column are extremely smooth and polished.

As to the large muscles, which cover almost the whole of the posterior part of the trunk, their uses being nearly uniform, it is easy to form a correct idea of them; they maintain the trunk erect, preserve the centre of gravity, which the weight of the abdominal viscera, and of the chest and head, tends to incline forward. When, in old age, the dryness and want of elasticity of the inter-vertebral cartilages no longer permit these muscles, whose action is more and more exhausted, to support the vertebral column, the back becomes rounded, the trunk is curved in front,

and the individual can walk only with the aid of a cane or a foreign arm. Inevitable effect of our sad destiny—as if nature wished to apprise us that we must soon return from whence we originated!

SECOND REGION.

Abdominal, cutaneous, or superficial.

Muscles of the bas-ventre.

The muscles of this region are :---the obliquus externus, obliquus internus, transversalis, rectus, and pyramidalis.

Anatomical Preparation.

If the same cadaver, used for the preparation of the muscles of the posterior part of the trunk, serves for the study of those of the anterior, we may, by turning it over, continue the transverse incisions, so as to expose the muscles of the bas-ventre, which we should prepare the first after those of the posterior part of the trunk. This mode of raising the integuments, has, for the muscles of the anterior part of the trunk, an advantage which does not attend the ancient method. If we proceed, as has just been recommended, it will be necessary, in raising the skin, to remove the fat and cellular tissue found on the muscles of the abdomen or their aponeuroses: this error once committed, cannot be repaired, so difficult is it to return to the first dissection. We should, therefore, proceed with caution and carry the scalpel very exactly between the great oblique and integuments---being careful to pull strong on these last---until we arrive at the linea alba, which must not be touched. We may then, if we choose, retain the flaps in place or remove them, provided a portion be preserved in order to cover the parts exposed, when we cease to dissect, for nothing so soon destroys the

beauty of a preparation as immediate contact with the air. In certain subjects the adipose matter is extremely abundant between the muscles of the abdomen and integuments covering them: this circumstance, which renders the preparation of the muscles still more difficult, will not, however, authorise the student to allow it to remain on these parts.

If the ordinary method of dividing the integuments of the bas-ventre be preferred, it may be done as was mentioned in the article on *opening this cavity*, (page 117,) and which may be consulted; but I should observe that, in proceeding in this manner, it will be difficult to remove exactly all the fat and cellular tissue found at the place of the first incisions; an inconvenience, which we will not meet with in raising the integuments at the posterior part. In all cases, the superior flaps are to be detached very high up, so as to expose a large portion of the muscles of the chest, for those of the bas-ventre, the great oblique particularly, and the rectus, have their superior points of insertion as far up as the seventh rib. When, on the contrary, the integuments are raised from the posterior part, we have a good view of the muscles of the abdomen in their whole extent in this sense; but when this is done by the ancient method, it is rare that the student carries the dissection of the skin far enough backwards, for it is absolutely necessary to place the cadaver on the side. Thus the posterior part of these muscles is never well seen, and the generality of students have but an imperfect idea of the manner in which the posterior portion of the external oblique muscle especially, unites and confounds its digitations with those of the latissimus dorsi; on the contrary, by the process which I recommend, nothing can be more easy. Be it as it may, the extent of the preparation,

its great difficulty, the constant necessity which the student is under of carrying his observation in front and backwards, in order to see the muscles in all their extent, and the intimate union of their aponeuroses, will always render the dissection of the muscles of the bas-ventre tedious for any one who may wish to prepare them properly.

I shall now pass to their particular examination.

Obliquus Externus.—The dissection of the skin, and the particular care taken to remove all the fat and cellular tissue in raising the integuments of the anterior part of the abdomen, exposes to view, in its whole extent, the external or great oblique muscle. Independently of the general precepts given for the preparation of this muscle, we must also be careful not to injure the aponeurosis, which forms a great part of it, and to isolate the cord from the spermatic vessels, which, from the interior of the belly, goes to the testis through an opening of this muscle at its inferior part. In the female, there passes through this opening, which is much smaller than in man, a small cord, which likewise requires considerable attention: in both sexes, it is important to preserve the linea alba, which extends from the xiphoid appendix to the environs of the pubis. About its centre, there is observed the umbilical cicatrix, which must be left in situ, for those parts are to be studied in conjunction with the abdominal muscles. All the muscles, and those of the bas-ventre in particular, are immediately covered by a thin pellicle, strongly adhering to their external surface: it is with good reason that the student is directed to remove it with the skin; the dissection of it is no where so difficult as in the muscles of the abdomen, which should make us more careful in removing it with the skin; without this precaution, the preparation of these muscles will always be a

failure; it will be vain for us to attempt to remove it afterwards,—this never can be effected entirely, and for one blunder we shall have ten.

Obliquus Internus.—In order to expose this muscle, we must raise the great oblique, which covers it in nearly the whole of its extent. Lieutaud and other anatomists recommend to detach the great oblique from its points of insertion into the ribs and crest of the ilium; a very defective preparation. What avail will it be to examine a muscle which is separated from its attachments? It is, on the contrary, essentially necessary to preserve its points of insertion in order to examine fully its extent and direction, and in this way arrive at a more accurate notion of its uses. A good preparation can never pass as such, unless it renders the study of the part more precise and easy; consequently, I recommend the student to raise the external oblique in the following manner:—Make a transverse incision from behind forwards, in the middle of the space comprised between the crest of the os ilium and false ribs, as far as the point at which the aponeuroses of all the abdominal muscles become confounded with each other, which corresponds to the external border of the rectus muscle; extend a second incision from the xiphoid appendix to the anterior superior spinous process of the ilium, carrying the instrument in preference over the fleshy fibres. The two external flaps are turned outwards, one below and the other above; the internal is to be detached only as far as the sheath of the rectus; in this way we will preserve all the attachments of the great oblique, expose the internal oblique, as also the six last ribs and corresponding inter-costal muscles. The layer of cellular tissue, interposed between the great and small oblique muscles, is so thin, that we cannot be too cautious in separating these two

muscles : the greatest difficulty, it is true, is in commencing this separation, for when we once seize the space between the the two muscles, the rest of the dissection will be comparatively easy, if we do not hurry it. It is unnecessary to remark, that one of two muscles must always be left in its place, and even that the other should not be removed until we have a correct idea of their respective relations, particularly for those which are separated only by very small intervals, as the muscles of the bas-ventre.

N. B. In dissecting this muscle again, I have remarked that it may be detached, without inconvenience, in the manner recommended by Lieutaud. Either of the methods may be adopted.

Transversalis.—We cannot have an exact knowledge of this muscle, without exposing at the same time the rectus muscle, which is enveloped by the aponeuroses of the great, and likewise of the small oblique ; but in order not to spoil the dissection, we must expose the fleshy portion of the transversalis, which may be done by making a transverse incision along the whole extent of the fleshy portion of the small oblique, and turning over the flap, one above as far as the false ribs, the other below as far as the crest of the ilium. I would recommend not to touch the aponeuroses, the dissection of which would only tend to complicate the work without imparting any interest to it ; it will suffice to have an exact knowledge of the direction of the fibres of the transversalis, and to defer the preparation of all the aponeuroses until after the examination of the rectus muscle. This perhaps will not be deemed very methodical, but it is the only rule that can be well followed by the student who is just commencing dissection.

Rectus.—This muscle cannot be properly examined without raising the layers of aponeuroses with which it is

enveloped; this dissection is always difficult and vexatious, because these aponeuroses are firmly united to the tendinous intersections, which it is necessary to preserve; we should, therefore, be content to raise them in the intervals of the intersections, and in this way expose the whole of the rectus. At its inferior part, we ordinarily observe a very small muscle called pyramidalis, which must remain in situ, and be studied in connection with the rectus; but it is proper to mention that the pyramidalis sometimes is wanting on one, and even on both sides at the same time; the small size of this muscle renders this circumstance of minor importance.

As to the aponeuroses of all the muscles of the bas-ventre, the preparation of which has been deferred until now, I should remark that they cannot be prepared so as to be seen in as satisfactory manner as the muscles to which they appertain. The posterior part of these aponeuroses is so entirely confounded with those of the latissimus dorsi, sacro-lumbalis, and longissimus dorsi, that it is impossible to separate them; it is only by the aid of long maceration or immersion of the parts in hot water, that this can be effected, and the advantages to be derived will not compensate for the difficulty and labor of the operation. Such is not the case with the anterior part; with a little patience, we may follow them before and behind the rectus muscle, and have an exact notion of their distribution. The aponeurosis of the great oblique, and the anterior layer of the small, cover the rectus muscle in front; and the posterior part of this muscle is covered by the posterior layer of the small oblique, and aponeurosis of the transversalis; but all these aponeurosis pass in front of this muscle at its inferior third, and thus leave it exposed on the peritoneum. By cutting it at its superior part, and turning it downwards, this arrangement will be very well seen. In

general it is necessary, from time to time, to take a survey of the parts, in proportion as we dissect them, particularly when there is any difficulty in understanding the entire of a preparation.

Description.

OF THE OBLIQUUS EXTERNUS OR MAJOR.

(*Costo-abdominal.*)

Situation and figure.—Thin, broad, quadrilateral, situated on the anterior and lateral portions of the abdomen.

Extent.—From the linea alba to the lumbar region, and from the seven or eight last ribs to the os ilium.

Division.—An external surface, covered behind by a very small portion of the latissimus dorsi, and by the integuments in the rest of its extent. Below and within, there is observed an opening elongated from above downwards, and from without inwards, called the *inguinal ring*. Larger in man, this ring affords passage to the spermatic cord; considerably reduced in size in the female, it is traversed by the round ligament; the internal surface of the muscle is in contact with the internal oblique. Its anterior border is lost in the linea alba, which it contributes to form; the posterior is observed in the lumbar region, four fingers' breadth from the spinous apophyses of the lumbar vertebræ; the superior is attached to the seven or eight last ribs, and is united by digitations with the serratus magnus and latissimus dorsi; the inferior, after being attached to the three anterior fourths of the crest of the ilium, becomes free and forms in part the ligament of Fallopius, and terminates at the spine of the pubis.

Direction.—Oblique from behind forwards, and from above downwards.

Structure and uses.—Aponeurotic in front; fleshy in the rest of its extent, it approximates the pelvis and chest, and compresses the abdominal cavity.

OBLIQUUS INTERNUS OR MINOR.

(*Ilio-abdominal.*)

Situation and figure.—Broad, flat, quadrilateral, situated on the anterior and lateral portions of the abdomen.

Extent.—From the linea alba, to the last lumbar vertebræ and sacrum, and from the last false ribs to the ilium.

Division.—An external surface covered by the great oblique and latissimus dorsi; an internal surface, applied to the transversalis, and in part to the rectus muscle. Its anterior border is lost in the linea alba; the posterior is attached to the spinous apophyses of the two last lumbar vertebræ and two first pieces of the sacrum; the superior, to the cartilage of the four last false ribs; the inferior, to the three anterior fourths of the crest of the ilium, and terminates at the pubis by forming the greatest portion of the crural or Fallopiian ligament.

Direction.—Oblique from below upwards, and from behind forwards.

Structure and uses.—Aponeurotic behind and in front, where the aponeurosis forms two layers, which embrace the rectus abdominis; fleshy in the rest of its extent, it has the same uses as the external oblique.

TRANSVERSALIS.

(*Lombo-abdominal.*)

Situation and figure.—Broad, flat, quadrilateral, situated on the anterior and lateral portions of the abdomen.

Extent.—From the linea alba to the lumbar vertebræ and from the last ribs to the ilium.

Division.—An external surface, covered by the internal oblique, sacro-lumbalis and longissimus dorsi; an internal surface, applied to the peritoneum, quadratus lumborum, and to a portion of the rectus muscle. Its anterior border is lost in the linea alba; the posterior is attached to the spinous apophyses of the four first lumbar vertebræ; the superior, to the internal part of the seven last ribs, in uniting by digitations with the diaphragm; the inferior to the three anterior fourths of the crest of the ilium, and terminates at the pubis.

Direction.—Transverse.

Structure and uses.—Aponeurotic in front and behind, where the aponeurosis forms three layers, and fleshy in the interval. It compresses the abdomen.

RECTUS ABDOMINIS.

(*Sterno-pubien.*)

Situation and figure.—Flat, elongated, situated on the anterior and middle portion of the abdomen.

Extent.—From the environs of the xiphoid cartilage to the pubis.

Division.—The anterior and posterior surfaces are both covered by the aponeuroses of the other muscles of the abdomen, which enclose it like a sheath. Its internal border corresponds to the linea alba; the external, to the aponeuroses of the other abdominal muscles. The superior extremity is attached to the external surface of the cartilages of the three last true ribs, and to the adjoining portion of the sternum; the inferior, to the body of the pubis.

Direction.—Vertical.

Structure and uses.—Tendinous at its extremities; in addition, it presents in front four or five tendinous intersections, placed transversely at a distance of four or five fingers' breadth. It draws the chest towards the pelvis, and approximates the latter to the chest, by compressing the abdominal cavity.

PYRAMIDALIS.

(*Pubio-sous-umbilical.*)

Situation and figure.—Flat, triangular, situated on the anterior and inferior part of the abdomen.

Extent.—From the pubis to four or five fingers' breadth along the linea alba.

Division.—An anterior surface, covered by the aponeuroses of the other muscles of the abdomen; a posterior surface applied to the rectus muscle. Its internal border is lost in the linea alba; the external is free. The inferior extremity is attached to the pubis; the superior remains applied upon the rectus.

Direction.—Vertical.

Structure and uses.—Aponeurotic inferiorly, fleshy in the rest of its extent; it aids, in a feeble manner, the uses of the rectus abdominis.

From the general disposition of the muscles of the bas-ventre, and the particular direction of the fibres composing them, there results a mechanism by means of which the abdominal cavity is completely closed in every possible point of its extent, without the action of one of the muscles interfering, in the slightest degree, with that of the other. This action occurs especially during the efforts made to evacuate the fœces, during the operation of labor, and, in a less decided manner, during expiration, and the excretion of urine. I do not speak here of the uses of the position of these

muscles, which is to form the free and flexible parois of the abdominal cavity, and by which they may, conjoined with their alternate motion of slight contraction and relaxation, exercise a gentle and constant pressure on the abdominal viscera.

By an arrangement as wise as it is necessary, and which we should understand, we perceive that, at the point at which we observe the aponeuroses of one of the muscles of the bas-ventre, fleshy portions of another muscle are likewise remarked, whence it results that the whole of the abdominal parietes is thus provided with an equal quantity of fleshy and aponeurotic fibres, so that the same force of action during the contraction of the muscles, and of resistance, during their relaxation, exists in all the extent of the abdominal covering. Two remarkable circumstances can alone derange this harmony, which is so necessary; these are, ascites, or excessive pregnancy, or even dropsy of the uterus. The muscles of the bas-ventre, in these different circumstances, distended beyond their natural limits, are restored to their original condition with great difficulty, even when the causes which distended them have ceased; or, not being able to oppose the passage of some of the floating particles contained in the abdomen, through their fibres, more or less separated, give rise to hernia, the extent and danger of which will be in proportion to the degree of relaxation or resistance of the fibres of the abdominal muscles.

THIRD REGION.

Thoracic.

Muscles on the anterior part of the chest.

In this section we comprise the pectorales major and minor, and subclavius.

Anatomical Preparation.

Pectoralis major.—Prolong the incision of the integuments from the xiphoid appendix to the symphysis of the chin; divide it into two others, by a second transverse incision, which follows nearly the direction of the clavicles to the omoplate: detach the inferior flap from within outwards, and from above downwards, so that the pectoralis major, a large portion of the serratus magnus and of the deltoid be exposed. In order to render this preparation more easy, turn the arm outwards and detach the skin as far as the insertion of the tendon of the pectoralis major into the humerus; but preserve it in its place, until the dissection of the muscles of the arm, in order to see in what manner this tendon, as likewise those of the latissimus dorsi and teres major muscles are fixed in the bicipital groove of the humerus. It is not, however, absolutely necessary to delay, until the dissection of the muscles of the arm, examining the particular disposition of the tendon of the pectoralis major, relatively to the bicipital groove. But it is indispensable, after having studied this muscle, to cut it at four or six fingers' breadth from its insertion into the humerus, in order to leave its tendon in place, until we shall commence the examination of the muscles of the arm.

It is for this reason that I recommend to the student, to be content, for the moment, with merely exposing it as much as possible; which will be the more easily effected by moving, from time to time during its preparation, the arm upwards and outwards. This, by separating the clavicle from the first rib, likewise influences the subclavius by elongating and exposing it sufficiently to permit an examination of it without breaking the clavicle.

Pectoralis minor.—Cut the pectoralis major from the point at which its superior border ceases to be attached to

the clavicle, as low down as its inferior border; turn the flaps, the one inwards, the other outwards; in this dissection we must remove a large quantity of cellular tissue, which is found particularly towards the superior part, in order to expose the tendon of the pectoralis minor, which is attached to the coracoid apophysis.

Subclavius—The removal of the pectoralis major is indispensable, in order to bring the subclavius into view; but it is not equally necessary to detach the pectoralis minor. To have a perfect view of the subclavius, we should remove the loose and abundant cellular tissue, which conceals it under the clavicle. Great care must be taken not to open the axillary artery and veins of the arm, placed above the pectoralis minor, if we desire to preserve the relations of its different parts.

As the subclavius is in great part concealed under the clavicle, we may defer its description until after the muscles of the neck, because, in order to see it satisfactorily, it will be necessary to saw the clavicle through its middle. It may, however, rigorously speaking, be studied *in situ*.

Description.

OF THE PECTORALIS MAJOR.

(*Sterno-humeral.*)

Situation and figure.—Broad, flat, triangular, situated on the anterior and superior part of the chest.

Extent—From the sternum, clavicle, and seven first ribs to the humerus.

Division.—An anterior surface, covered by the integuments; a posterior surface, which covers from within outwards the seven first ribs, the corresponding intercostal muscles, pectoralis minor, subclavius, axillary vessels, and brachial plexus. The superior border is attached to the

inferior side of the two internal thirds of the clavicle; in the rest of its extent, it is parallel to the anterior border of the deltoid, from which it is separated only by the cephalic vein; the inferior border is free, and forms posteriorly the anterior border of the axilla; the internal border is attached to the sternum. From the superior and inferior borders there results a tendinous extremity, which is inserted into the anterior edge of the bicipital groove of the humerus.

Direction.—The superior fibres are oblique from above downwards, the inferior from below upwards, and the middle have a transverse direction.

Structure and uses.—Aponeurotic at its attachments, except at the humerus, where it presents a broad tendon, fleshy in the rest of its extent, it draws the arm towards the chest, and *vice versa*.

PECTORALIS MINOR.

(*Costo-coracoidien.*)

Situation and figure.—Broad, flat, triangular, situated on the anterior and superior part of the chest.

Extent.—From the third, fourth, and fifth true ribs, to the coracoid apophysis.

Division.—An anterior surface, covered by the pectoralis major; a posterior, applied to the third, fourth, and fifth ribs. The superior and inferior borders do not present any thing worthy of attention; the internal (base) is attached to the ribs already named; the summit to the coracoid apophysis.

Direction.—Similar to that of the pectoralis major.

Structure and uses.—Aponeurotic at its attachments to the ribs, tendinous on the scapula, fleshy in the rest of its extent, it draws the shoulder forwards, and elevates the first ribs.

SUBCLAVIUS.

(*Costo-claviculaire.*)

Situation and figure.—Elongated, placed under the clavicle.

Extent.—From the cartilage of the first rib to the clavicle.

Division.—Placed under the clavicle, it is entirely covered by it, and its figure, slightly rounded, does not admit of any other relations. The internal extremity is attached to the cartilage of the first rib; the external, to the inferior part of the humeral extremity of the clavicle.

Direction.—Transverse.

Structure and uses.—Slightly tendino-aponeurotic at its extremities, fleshy in the rest of its extent, it draws the first rib towards the clavicle.

Although the muscles of this region are not numerous, their uses, however, are multiplied and well worthy the attention of the anatomist. The two pectoral muscles spread over nearly the whole of the ribs, place them to a certain extent beyond the danger of percussion from external agents, and moreover protect the viscera contained in the cavity of the thorax. But it is on the arm, a part essentially moveable in man, that their action is particularly remarkable: when, in fine, the arm is more or less distant from the body, they draw it towards the trunk and fix it firmly to its sides, aided in this action by the latissimus dorsi; like this last they allow the individual to raise himself on his wrists or elbows, and act especially when the individual draws a heavy body, ascends a ladder, climbs a tree, &c. The pectoralis minor, besides the rotatory motions it imparts to the scapula, contributes to increase the strength of the pectoralis major.

The pectoralis major, in the luxation of the arm down.

wards and forwards, draws the head of the humerus in this direction, and then conceals it, as it were, in the hollow of the arm-pit.

The subclavius does not participate in these different actions; it fixes the first rib on the clavicle, especially during inspiration, and thus becomes the remote cause of the successive elevation of the seven or eight first ribs. These are the constant uses of the subclavius which, in the contest between Amberger and Haller, respecting the uses of the internal intercostals, have contributed very much to decide the question in favor of the latter.

FOURTH REGION.

Lombo-abdominale.

Profound muscles of the abdomen and generation.

In this section, we comprise the two psoas muscles, iliacus internus, quadratus lumborum and diaphragm, for the abdominal cavity.

The muscles of generation are, on the one hand, the ischio-cavernous, bulbo-cavernous and transversalis; on the other, the two sphincters, the levator ani, and ischio-coxycygen. The three first do not exist in the female.

Anatomical preparation.

After having finished the muscles of the bas-ventre and those of the chest, we then penetrate the abdomen: all the viscera and other soft parts contained in this cavity must be removed. For this purpose, we place a ligature around the œsophagus about two fingers' breadth below the diaphragm, in pulling upon the stomach; it is then cut above the ligature, and we detach, from above downwards, the intestinal canal, liver, spleen, pancreas, kidneys and ureters, so that all make but one mass, which is thus brought down

as far as the environs of the pelvis. Then the rectum is to be tied at its origin in two places, and the intestine is cut between the ligatures, in order to remove entirely all those objects.

The two psoas and quadratus lumborum.—When the viscera of the abdomen have all been removed, the preparation of the psoas and quadratus lumborum is, as it were, accomplished. It will suffice to expose them perfectly, to free them from the peritoneum and loose cellular tissue, which still cover them.

Iliacus.—The preparation of the psoas necessarily includes that of the iliacus, which is even the more easy, as being attached to the internal iliac fossa, we may limit ourselves to removing the loose cellular tissue, which covers it towards its internal border. Near the crural arcade, it is united principally to the two psoas, and the tendons of these two muscles, becoming confounded with each other, are inserted into the trochanter minor. We may defer the dissection of these tendons, until we are occupied with examining the muscles of the internal part of the thigh; and it will be proper to pass immediately to the preparation of the diaphragm, which cannot be done at a future time.

Diaphragm.—We may employ two different methods for the purpose of preparing this muscle. The first consists in doing, for the cavity of the chest, what has just been directed for the abdomen, namely, to remove the heart, lungs, and all the other soft parts contained in the chest, so as to expose perfectly the thoracic surface of the diaphragm; but the ribs being necessarily removed in order to afford a better view of the convex surfaces of the diaphragm, it will be proper to sustain, by artificial means, the portion of the asternal ribs which still continue to be connected with this muscle, in order to maintain it *in situ*; this incon-

venience may be avoided by proceeding in a different manner, which I shall now describe.

For this purpose, we will open the abdomen, and remove the viscera contained in it, as was before directed; this preliminary preparation will absolutely suffice, for then the diaphragm is properly stretched, and in its natural situation; and moreover, its dissection is then extremely easy. When, on the contrary, the chest is opened, it is almost impossible to dissect it properly. Moreover, its inferior or abdominal surface is that which demands the most care and attention. In this way, we may defer, until another time, the examination of its superior or thoracic surface.

Muscles of Generation.—The ischio-cavernous, bulbo-cavernous, and transversalis-perinei, require to be prepared at the same time, for it would be difficult to dissect one of the three without exposing the others. The preparation is to be made in the following manner:—place the subject on the back, bend the thighs upon the abdomen, and the legs upon the thighs, separating at the same time the knees; raise the scrotum, and make an incision on each side, in the direction of the rami of the pubis and ischium; dissect the skin from without inwards, as far as the raphe, which, from the anus, extends to the scrotum. The adipose and cellular tissue abound in this spot; this must be removed in order to bring into view the deep-seated muscles; the transversalis demands especially, more than the other two, great care and attention. The ischio-cavernous is easiest to isolate, because it adheres, in nearly all its extent, to the rami of the pubis and ischium. The bulbo-cavernous, not being attached to any solid part, is much less so, on account of the difficulty of fixing it; it can only be accomplished by raising firmly the scrotum, and also the penis towards

the pubis. In order to render this dissection more easy, place a piece of linen, or any similar body in the interior of the pelvis, for the purpose of protruding the anus and skin of the perineum. This is indispensable for the preparation of the sphincters and levator ani. Notwithstanding all these precautions, it will be difficult to distinguish the bulbo-cavernous, on account of the uniformity of its color with that of the spongy portion of the urethra and bulb; this slight inconvenience may in part be removed, by passing a sponge several times over these parts.

The two sphincters, levator ani, and ischio-coccygien.—The preparation of these four muscles requiring that the situation of the cadaver and the other directions be the same as in the preceding preparation, I have not thought it necessary to separate their description, as I have done for the muscles of generation. If for these it is convenient to place the cadaver on the back, it is indispensable for the former, to lay it on the abdomen, and elevate the inferior part of the trunk as much as possible; this may be affected by placing a block, stone, or log under the belly of the cadaver, or even by putting the cadaver in the position necessary for the operation of fistula, namely, the abdomen and chest flat upon the table, the legs and thighs hanging. It is also necessary to place in the interior of the pelvis a body destined to protrude the whole region of the perineum and anus. The parts being thus stretched, we must remove the thin skin circumscribing the inferior opening of the rectum, and some reddish and circular fibres will be brought into view, which belong to the cutaneous or external sphincter. After having examined their figure and relations with the bulbo-cavernous, we should proceed to the preparation of the levator ani, which is situated much more deeply; it will be exposed by removing cautiously all the adipose substance

found in the space circumscribed by the anus, coccyx and ramus of the ischium. By the same method, we will also expose the ischio coccygien, more external and less voluminous than the levator ani, and which is situated between the coccyx and neighboring part of the haunch bones. But, I repeat, there will be an impossibility of preparing properly, these different muscles, if the region of the perineum and anus is not distended by pieces of linen, or wet paper placed in the interior of the pelvis and rectum, after having removed all the soft parts, and leaving nothing in fact but the species of floor formed by the skin, levator ani, and ischio-coccygien muscles.

The internal sphincter is nothing more than the termination of the rectum; it is placed above the cutaneous sphincter, and does not demand any other attention than that indicated for the other muscles of the perineum and anus.

Description.

DIAPHRAGM.

(*Idem.*)

Situation and figure.—Broad, flat, nearly circular: it separates the thoracic and abdominal cavities.

Extent.—From the xiphoid cartilage to the lumbar vertebræ, and from the six last ribs of the one side to the corresponding ones on the other.

Division.—A superior, thoracic, convex surface, corresponding to the heart, lungs, and pleura. An inferior, abdominal, concave surface, corresponding to the liver, stomach, spleen, the two kidneys, pancreas, and peritoneum. Its circumference is attached in front to the xiphoid appendix; on the sides, to the six right and left ribs, contracting adhesions with the transversalis by reciprocal digitations. Behind, the diaphragm is fixed to the first lum.

bar vertebræ; at this part, it gives rise to two elongated portions, called pillars of the diaphragm; the right is the longest, and is attached to the bodies of the three first lumbar vertebræ; the left is shorter, and is fixed to the bodies of the two preceding.

Direction.—The fibres, generally horizontal, radiate from the centre towards the circumference.

Structure and uses.—In great part fleshy; a broad aponeurosis in form of a clover leaf, called *tendinous centre*, is observed on its middle portion, and tendons at the extremities of its pillars.

The diaphragm is pierced by three openings, one of which is large and in the *tendinous centre*, for the passage of the vena cava; the two others are observed between the pillars: the anterior gives passage to the œsophagus, and the posterior to the aorta.

By the effect of respiration, it enlarges and contracts alternately the pectoral and abdominal cavities.

PSOAS MAGNUS.

(*Prè-lombo-trochantinien.*)

Situation and figure.—Elongated, rounded, situated on the lateral part of the cavity of the abdomen and pelvis.

Extent.—From the lumbar vertebræ to the trochanter minor.

Division.—An anterior portion, covered by the diaphragm, kidney, and psoas parvus; a posterior portion, applied to the quadratus lumborum, transverse apophyses of the lumbar vertebræ, and iliacus internus muscle. Its superior extremity is attached to the lateral portions of the body of the first lumbar vertebræ; the inferior, confounded with that of the iliacus, is fixed to the trochanter minor.

Direction.—Vertical.

Structure and uses.—Slightly aponeurotic at its superior extremity, tendinous at its inferior, and fleshy in the rest of its extent, it bends the thigh on the pelvis, the pelvis on the thigh, and maintains the equilibrium of the trunk in standing and walking.

PSOAS PARVUS.

(*Pre-lombo-pubien.*)

Situation and figure.—Elongated and narrow, situated on the preceding.

Extent.—From the last dorsal vertebra to the pubis.

Division.—An anterior surface, covered by the diaphragm, emulgent vessels, and external iliac artery. An internal surface, applied to the psoas magnus. Its superior extremity is attached to the body of the last dorsal; the inferior, to the ileo-pectineal eminence, and body of the pubis.

Direction.—Somewhat oblique, from above downwards, and from without inwards.

Structure and uses.—Tendinous inferiorly, fleshy in the rest of its extent, it has the same uses as the psoas magnus, except that it does not act on the thigh.

ILIACUS INTERNUS.

(*Iliaco-trochantinien.*)

Situation and figure.—Flat, radiated, triangular, and situated in the internal iliac fossa.

Extent.—From the ilium to the trochanter minor.

Division.—An internal surface, covered on the right by the cœcum, on the left by the *S* of the colon. An external surface, applied to the internal iliac fossa. The internal border is confounded with the psoas; the external, free above, is covered below by the sartorius; the supe-

rior, or base, is attached to the internal lip of the crest of the ilium. Its inferior extremity, tendinous, is united to those of the two psoas muscles, and is attached to the trochanter minor.

Direction.—Oblique from above downwards, and from without inwards.

Structure and uses.—Tendinous inferiorly, fleshy in the rest of its extent, it bends the thigh on the pelvis, and the pelvis on the thigh.

QUADRATUS LUMBORUM.

(*Ilio-costal.*)

Situation and figure.—Flat, quadrilateral, situated on the lateral and inferior portions of the trunk.

Extent.—From the last rib to the ilium.

Division.—A posterior surface, covered immediately by the middle aponeurosis of the transversalis, and by the fleshy mass of the sacro-lumbalis and longissimus dorsi. An anterior surface, covered by the kidney, colon, and aponeurosis of the transversalis. Its external border is free, and concealed in the separation of the aponeuroses of the transversalis; the internal is attached to the transverse apophyses of the four first lumbar vertebræ; the inferior to the posterior fourth of the crest of the ilium, and the superior to the inferior edge of the last rib.

Direction.—Slightly oblique from above downwards, and from within outwards.

Structure and uses.—Aponeurotic at its attachments, fleshy in the interval, it draws the last rib downwards, and bends the pelvis upon the trunk.

ISCHIO-CAVERNOUS.

(Ishio sous-pubien.)

Situation and figure.—Elongated, thin, situated at the inferior part of the trunk.

Extent.—From the ischium to the corpora cavernosa.

Division.—An external portion, applied to the branch of the ischium; an internal portion, which corresponds to the transversalis and bulbo-cavernous. The inferior extremity is attached to the internal lip of the tuberosity of the ischium; the superior to the root of the corpus cavernosum.

Direction.—Oblique from below upwards, and from without inwards.

Structure and uses.—Tendino-aponeurotic inferiorly, fleshy in the rest of its extent, it draws the penis downwards.

BULBO-CAVERNOUS.

(Bulbo-urétral.)

Situation and figure.—Elongated, thin, situated at the inferior part of the trunk.

Extent.—From the bulb of the urethra to the root of the penis.

Division.—An inferior surface, covered by the skin; a superior surface applied to the bulb and urethra, and a portion of the corpus cavernosum. The internal border is confounded with the muscle of the opposite side, the external adheres to the external membrane of the corpus cavernosum. Its posterior extremity is confounded with the external sphincter; the anterior terminates near the root of the penis.

Direction.—Horizontal.

Structure and uses.—Entirely fleshy, it compresses the

canal of the urethra, and accelerates the course of the urine and semen.

TRANSVERSALIS.

(*Ischio-périnéal.*)

Situation and figure.—Flat, triangular, situated at the inferior part of the trunk.

Extent.—From the ischium to the urethra.

Division.—An anterior surface, covered by the ischio and bulbo-cavernous muscles, together with cellular and adipose tissue ; a posterior surface, which corresponds to the levator ani, and is traversed by the profound branch of the pubic artery. Its external border is attached to the tuberosity and branch of the ischium ; the internal is confounded with its fellow, in the space between the bulb of the urethra and anus ; the posterior is free under the skin.

Direction.—Transverse.

Structure and uses.—Aponeurotic at its insertion into the ischium, fleshy in the rest of its extent, it compresses the canal of the urethra.

EXTERNAL SPHINCTER.

(*Coccygio-anal.*)

Situation and figure.—Flat, nearly circular, and pierced in its centre ; situated at the inferior part of the trunk, around the anus.

Extent.—From the coccyx to the perineum.

Division.—An inferior surface, covered by the thin skin of the anus ; a superior, corresponding to the levator ani, ischio and bulbo-cavernous muscles. It is attached behind to the coccyx, and in front it is lost in the bulbo-cavernous muscle.

Direction.—In concentric arcs from the circumference to the centre.

Structure and uses.—Entirely fleshy, it corrugates the skin around the anus, and contracts the rectum.

INTERNAL SPHINCTER.

(*Coccigio-anal.*)

Situation and figure.—Thin, circular, in the form of a ring; situated at the inferior part of the trunk, and at the extremity of the rectum.

Division.—An external portion, lost in the rectum; an internal, covered by the internal membrane of the same intestine. Its superior border is confounded with the inferior extremity of the rectum; the inferior separated about one finger's breadth from the preceding, is confounded with the external sphincter.

Direction.—The fibres are all circular.

Structure and uses.—Fleshy, it constricts the intestine.

ISCHIO-COCCYGIEN.

(*Coccigio-anal.*)

Situation and figure.—Flat, triangular, situated at the inferior part of the trunk.

Extent.—From the ischium to the coxycx and sacrum.

Division.—A posterior surface, covered by the skin and sacro-sciatic ligaments; an anterior surface corresponding to the rectum. The superior border is fixed to the ischium, the inferior is confounded with the levator ani; the base, turned backwards, is fixed to the coxycx and sacrum; the summit to the ischium.

Direction.—The fibres diverge from the ischium to the coxycx.

Structure and uses.—Mixture of fleshy and aponeurotic fibres, it sustains the weight of the fœcal matter.

LEVATOR ANI.

(Souspubio coccygien.)

Situation and figure.—Flat, thin, quadri-lateral, situated at the inferior part of the trunk.

Extent.—From the ischium to the coccyx and rectum.

Division.—An external surface, applied to the lateral portions of the pelvic excavation; it also corresponds to the internal obturator and gluteus maximus: an internal surface, corresponding to the bladder and rectum. The superior border is attached to the upper part of the excavation of the pelvis; the inferior is confounded with that of the opposite side, from the coccyx to the rectum; the posterior is united to the ischio-coccygien muscle; the anterior to that of the opposite side, in embracing the rectum.

Direction.—Oblique from above downwards, and from before backwards.

Structure and uses.—Slightly aponeurotic above, fleshy in the rest of its extent, it sustains the rectum in the expulsion of the fœcal matter; it raises it and then restores it to its natural situation.

Of all the regions of myology, there is none that presents such variety, relatively to the uses of the muscles, as that we have just described. The diaphragm does not confound its action with that of the psoas, iliacus and quadratus lumborum, nor these with the muscles of the perineum and generation.

The diaphragm, whose action is not absolutely dependent on the will, although it has all the characters of muscles of the life of relation, is situated so as to form a kind of moveable floor, interposed between the chest and abdomen, the respective organs of which it separates very accurately. Enjoying an alternative motion of contraction

and relaxation, it augments in the first case the capacity of the chest, facilitates the admission of air into the pulmonary cells, and thus becomes one of the chief agents of respiration. It forces, at the same instant, the abdominal viscera downwards and forwards, in compelling the parietes of the bas-ventre to aid in this movement, and in this way it increases equally the pectoral and abdominal cavities. During its relaxation, the diaphragm ascends towards the lungs, adds to the expiratory power of these organs, and allowing the abdominal muscles to return upon themselves, favors the action of these last on the abdominal viscera.

When speaking of the uses of the muscles of the bas-ventre, I mentioned the active part which the diaphragm took during the evacuation of fœces and the expulsion of urine, as also during accouchement.

The psoas and iliacus muscles have a simultaneous action. Their particular uses are to maintain the equilibrium of the trunk on the inferior extremities in the ordinary standing position, by preventing the trunk from falling backwards; but when this is the fixed point they draw the thighs and the totality of the inferior member on the pelvis, which is particularly observed in progression, during which the alternative displacement of each abdominal extremity requires, in the first place, its elevation from the ground, and a slight flexion; they are the congénères of the glutei muscles; like these last, they can draw the pelvis on the thigh, but in an opposite direction, that is to say, in front and in flexing the trunk, particularly the psoas magnus, which facilitates progression, whether it be slow or rapid. Behold the traveller, after a long walk, or who wishes to accelerate his gait, far from holding himself upright, he is, on the contrary bent forward.

The quadratus lumborum, isolated, as it were, in the abdominal cavity, a portion of whose walls it forms, contributes in a feeble manner to the phenomena of respiration, by drawing down the last rib, and exerting upon it, but in a contrary direction, the same action as the subclavius on the first rib; it also contributes to draw the trunk to one side, and thus becomes the antagonist of its fellow, of which it is the congénère at the moment of inspiration.

As regards the muscles whose general uses it remains for us to examine, it will be necessary to establish a difference between those of the margin of the anus and those of generation. Sometimes, indeed, these different organs have simultaneous actions, but most frequently they act separately, and it is under the latter point of view that we shall now examine them.

The object of the levator ani is not exclusively, as its name indicates, to raise the inferior extremity of the rectum, but to form, conjointly with the ischio-coëcygien, the inferior floor of the abdominal cavity, as the diaphragm forms the superior, and in this way to sustain, at the time of a deep inspiration, the weight of the abdominal viscera, which are carried in this direction by the powerful action of the diaphragm.

During the efforts of the child's head, at the moment of accouchement and in the expulsion of fœces, the two muscles in question support the violence of these efforts, oppose the laceration of the perineum in the first case, and the complete protrusion of the anus in the other. The two sphincters, congénères of these last under almost all circumstances, have for an additional use to keep the inferior extremity of the rectum continually closed, and to prevent the discharge of fœces, either liquid or solid, through

this opening, except at the time of the natural expulsion of the fœcal matter.

The uses of the muscles of generation are not in proportion to the energy and vivacity of the generative functions. Here the muscular action is too weak; nature requires a power very differently organized. The general disturbance of the whole machine, the disorder in the sensations, the convulsive exaltation of all the vital forces are scarcely sufficient for the violence of desire in the accomplishment of the act of generation. Under these circumstances what could be effected by the feeble and uncertain action of the transversalis perinei, or bulbo-cavernous? Let us, however, examine the uses of these muscles.

Of these three muscles, the ischio-cavernous alone has distinct uses; those of the other two are more obscure. We know, in fine, that the ischio-cavernous draws the penis downwards when it is in a state of erection; that it dilates at the same time the canal of the urethra, which affords a free passage to the urine, and a still greater facility to the emission of the semen; that it is consequently the antagonist of the bulbo-cavernous, whose action is limited to exerting pressure on the canal of the urethra, without, however, drawing the penis in any particular direction.

The uses of the transversalis appear to be to draw slightly, in a contrary sense, the portion of the canal of the urethra, to which it is inserted, and to facilitate the flow of the urine.

FIFTH REGION.

(*Costo-Thoracique.*)

Muscles on the sides of the trunk.—These muscles are the serratus magnus, the external and internal intercostals.

Anatomical Preparation.

Serratus magnus.—The pectoralis major and the muscles on the posterior part of the trunk being removed, the serratus magnus will be readily perceived by raising the omoplate. The cellular tissue found between this last and the subscapularis must be removed, as also that which is interposed between the posterior part of the ribs and serratus magnus. This muscle must not be entirely detached from these same ribs, but we may disarticulate the humerus and clavicle, and thus move the detached arm in different directions, which will afford an opportunity of seeing the serratus magnus in all its different relations. In the study of this muscle, we should always approximate as much as possible the head of the humerus to the glenoid cavity, in order to have an idea of the whole of its description.

External and internal intercostals.—After having detached the arm from the body, and removed the clavicle, as also all the superficial muscles of the trunk, the ribs and corresponding intercostal muscles will be exposed. Nothing, under these circumstances, can interfere with the study of these muscles; it is true, however, that the external only are perceived at first, but the preparation of the internal requires but very little trouble. For this purpose, we remove the fibres of the external intercostals, until those of the internal are brought into view; these last go in an opposite direction. The layers formed by both the external and internal fibres are not very thick, and they are separated only by a small quantity of cellular tissue. The two intercostals, occupying nearly all the space of each rib, it is indispensable to examine them from the anterior to the posterior part; for which purpose, as has already been stated, it will be necessary to remove all the muscles covering the trunk. It will also be necessary to penetrate the interior

of the chest, in order to have a better view of the internal intercostals; but as the triangular section of the sternum has not yet been made, we may dispense with this examination for the moment, and continue it after that of the superficial muscles on the anterior part of the neck.

Description.

SERRATUS MAGNUS.

(*Costo-Scapulaire.*)

Situation and figure.—Broad, flat, quadrilateral, situated on the lateral portions of the trunk.

Extent.—From the omoplate to the eight first ribs.

Division.—An external surface, covered by the subscapularis, a portion of the pectoralis major and minor, latissimus dorsi, and integuments. An internal surface, which covers the seven or eight first ribs, and the corresponding intercostal muscles. Its superior border, the shortest, and its inferior, do not present any thing remarkable. The posterior is fixed to the base of the omoplate; the anterior is attached to the seven or eight first ribs, by digitations, the inferior of which become confounded with those of the external oblique.

Direction.—The more oblique from behind forwards, and above downwards, as we examine the muscle nearer its inferior portion.

Structure and uses.—Slightly aponeurotic at its different attachments, fleshy in the rest its extent, it draws the omoplate forwards and upwards, and in some cases elevates the ribs.

EXTERNAL INTERCOSTALS.

(*Idem.*)

Situation and figure.—Flat, thin, situated in the space between the ribs.

Extent.—From the posterior to the anterior part of the intercostal spaces.

Division.—An external surface, covered by the pectorales major and minor, the three serrati, obliquus externus of the abdomen, sacro-lumbalis and longissimus dorsi; an internal surface, applied to the internal intercostals, and pleura posteriorly. The superior border is attached to the rib which is above, and the inferior to that which is below.

Direction.—Oblique from above downwards, and from behind forwards.

Structure and uses.—Slightly aponeurotic at their attachments, fleshy in the rest of their extent, they elevate the ribs.

INTERNAL INTERCOSTALS.

(*Idem.*)

Situation and figure.—Flat, thin, situated in the space between the ribs.

Extent.—From the posterior to the anterior part of this space.

Division.—An external surface, covered by the external intercostals; and internal surface, applied to the pleura. The superior border is attached to the rib above, and the inferior, to the one below.

Direction.—Oblique from above downwards, and from before backwards.

Structure and uses.—Slightly aponeurotic at their attachments, fleshy in the rest of their extent, they elevate the ribs.

The uses of the serratus magnus in man are rather limited. It approximates the shoulder to the trunk, and in this way imparts more energy to the motions of the arm; on the other hand, it acts on the chest, which it di-

lates feebly when the thoracic members are in repose ; such is, in a word, its physiological history. But if we study it in birds, whose flight extends to the highest regions, we will observe very important uses attached to it. In raising the ribs of these animals, it increases very considerably the dilatation of the chest, permits the entrance of a great quantity of air into this cavity, and thus contributes to give them that extraordinary power, by the aid of which they are enabled to sustain themselves in their flight.

The external and internal intercostals, whose uses have excited so much discussion, are at the present day much better understood than they were in the middle of the last century. We now are aware that they have a simultaneous action ; that the seven or eight first, counting from above downwards, elevate the superior ribs, and that the four or five last draw down the inferior ribs so that the whole chest is thus equally enlarged from above downwards. The first are aided in their action by the posterior and superior serratus minor, and the last by the posterior and inferior serratus major.

SIXTH AND SEVENTH REGIONS.

Muscles of the summit of the head and face.—I have included, in the same article, the preparation and study of the muscles of these two regions, because it is difficult to separate them. These muscles are, for the summit of the head, the occipito-frontalis, three auricular, corrugator supercillii and pyramidalis ; those of the face are, the orbicularis palpebrarum, levator labii superioris alæque nasi, levator labii superioris proprius, triangularis nasi, the two zygomatici, caninus, triangularis menti, quadratis, myrtiformis, buccinator, and orbicularis labiorum.

Anatomical Preparation.

The preparation of the muscles of the head and face has always been regarded as one of the most delicate and difficult in myology. Some of them are enveloped by fat, others repose under dense and compact cellular tissue, and others again are covered only by a cutaneous envelope, so thin, that it is difficult to separate the interval which separates them; all these considerations, therefore, render the dissection of the muscles of the face extremely difficult. But a circumstance entirely independent of these first inconveniences may render the preparation of these muscles still more embarrassing; it is the bad quality of *the subject*. In a word, we cannot say to what degree the difficulty will extend of dissecting the muscles of the face in subjects that are infiltrated, or in such as have perished by a violent death, strangulation, apoplexy, &c., and it would be advisable, in these cases, to defer this dissection until another period, rather than consume time unprofitably, for I defy the most skilful anatomist to dissect and isolate exactly the muscles of the face in a subject that has been *infiltrated*. An excessive quantity of fat will also render the dissection difficult and disagreeable; the disposition of these muscles explains, to a certain degree, the nature and cause of all these inconveniences; all of them extend to the skin, follow its movements, and, like it, are obedient to the agents which distend it. Lost in fat, cellular tissue or effused fluid, they cannot be seized but with great difficulty, and the student cannot possibly fix them in any steady position. For this reason, it is usual to place in the mouth, and between the lips and gums, bodies more or less hard and solid, which, by raising the external parts, offer a point of support, difficult to obtain without this precaution. Further remarks on this subject would be of but

little avail in removing the difficulties attending this dissection—they will be made to disappear more effectually by indicating the manner of dissecting each of these muscles in particular.

Occipito-frontalis.—It is very common for students, who undertake to prepare this muscle for the first time, to raise it with the skin of the cranium. It is so intimately connected with it, and the muscle itself so thin, that the fault is excusable. In order, however, to avoid this error, the following precautions must be observed:—instead of opening the skin, from the root of the nose to the external occipital protuberance, as authors recommend, commence, on the contrary, this incision towards the auricular region, as if proceeding to open the cranium, but do not carry the scalpel too deep, and be particular not to cut any thing but the integuments, because, in order to avoid the inconvenience of cutting the occipito-frontalis by the ordinary incision, you would necessarily divide the auricular muscles, which are even more delicate. It is true that at this point the layer of cellular tissue is somewhat more abundant, and on this account there is less risk.

From the middle of the first incision we should make a second, extending to the summit of the head, so as to have two flaps, one of which is thrown forwards and the other backwards. But we should not detach the skin, which is to form one or other flap, except in proportion as the muscle is exposed; or we may, after the first incision indicated above, remove the whole of the skin of the cranium from before backwards—cutting it in the middle—in proportion as it is detached. After all this difficulty and care, we have only one muscle exposed; but he who, for the first time, will have succeeded in exposing well the

occipito-frontalis, will already have made great progress in the art of dissecting.

Auriculares.—In removing the skin from the cranium, in order to see the occipito-frontalis, we necessarily expose a great portion of the auricular muscles, which demand the more care, as they are sometimes so very pale and thin, that they can scarcely be rendered visible, even with the most scrupulous attention. In order to observe their traces the more easily, it will be proper to draw the whole ear in different directions, and study them all at the same moment, for in a short time they become dry, and do not re-appear.

Corrugator supercilii.—Make a longitudinal incision from the frontal protuberance, to the extremity of the nose, and even to the chin. Then detach the skin, from within outwards, and from above downwards, in an indeterminate extent, for the dissection of all the muscles of the face requires it to be removed, as far down as the chin. But for the corrugator, it will suffice to expose a portion of the orbicularis palpebrarum; the occipito-frontalis should be cut across the middle of the superciliary ridge; the instrument must be carried with care in this place, for the corrugator is below. It will be necessary to turn up the divided portions of the occipito-frontalis, in order to study the corrugator, the fibres of which run in the direction of the superciliary ridge itself; it is the only mode of observing it correctly.

Pyramidalis.—This small muscle being nothing more than a prolongation of the occipito-frontalis, in order to see it, it will suffice to remove the skin which covers the latter

on the root of the nose ; but without some attention, we will remove it with the integuments. To have a good view of it, it will be necessary to pull the occipito-frontalis upwards, of which it is merely a prolongation.

Orbicularis Palpebrarum.--The difficulty attending the preparation of this muscle is owing to its strong adhesion to the skin, and the great laxity of the latter. The muscle itself and skin become so thin towards the free border of the eyelids, that it requires much skill in dissection to preserve the orbicularis uninjured ; and if, as sometimes happens, the eye-lids are bloated, the difficulties will still be increased : perhaps it would be as well to employ a more delicate scalpel than we are in the habit of using for the rest of myology. We proceed to the dissection of the skin, placing it in the most perfect tension ; at the same time, we should draw downwards the free border of the superior eyelid, and continue the separation of the skin, as far as the great angle of the eye : after this, the dissection is to be continued from above downwards, from within outwards, and, in this way, we expose at the same time the transversalis nasi and levatores labii, and outwardly, the zygomatici, especially if the separation of the skin be carried somewhat low down.

It would even be proper to prepare all the muscles of the face at one time, for the study of each one of them in particular, after the dissection of the integuments, is easily made, and the numerous relations which they present require that they should be seen together. Remove, therefore, all the skin from the face ; this must be done cautiously, for it is loose, abounding in cellular tissue and fat, and the muscles are sometimes very pale.

✓ *Levator labii superioris alæque nasi, and levator labii superioris proprius.*—These two muscles are slightly covered at their superior part by the orbicularis, which it will be necessary to raise and carry upwards in order to have a good view of them. For the purpose of distinguishing the two levators, it will be proper to draw the free border of the lip downwards; sometimes they can be easily separated; frequently, however, there is difficulty in effecting this.

Transversalis nasi.—In part concealed by the two preceding muscles, it is situated on the lateral portions of the nose. If we do not study this muscle the moment it is exposed, it becomes dry and disappears; we should, therefore, hasten to examine it, drawing in an opposite direction and downwards the alæ of the nose, which will render the fibres of this muscle more apparent.

Zygomatici.—Like the levatores the Zygomatici are slightly covered outwardly by the orbicularis at their superior portion; we will be enabled to isolate these muscles sufficiently well, by drawing the integuments downwards and inwards, which may be done by placing a hook in the angle of the mouth.

Caninus.—Remove, or rather separate, without detaching them, the preceding muscles; dissect away the fat enveloping the Caninus and expose this muscle, which is situated in the canine fossa; nothing can be easier than this preparation, when the other muscles of the face have been already dissected.

Myrtiformis.—The student who is not guided in the preparation of this muscle will not be able to find it, be-

cause he constantly looks for it where it is not, and in fact removes it when he is merely seeking for its situation: it must not be exposed externally, but on the internal side of the superior lip. This lip, therefore, is to be raised and carried upwards, we are then to divide with caution, at its middle part, the membrane covering its internal surface; here, will be found the two small myrtiforme muscles, nearly united to each other, and separated only by a very small space.

Triangularis menti.—Placed on the inferior maxilla, it will suffice to remove the skin by which it is covered in order to have a view of it; a small quantity of cellular tissue is found interposed. If the free border of the inferior lip be drawn upwards, it will facilitate the dissection of the triangularis.

Quadratus menti.—The preparation of the triangularis exposes the quadratus, which is in part covered by it, and demands the same precautions.

✓
Buccinator.—In order to have a perfect view of this muscle, we must, of necessity, place in the mouth, and on the sides principally, paper, linen, or some other body, which will render the skin of the cheeks prominent; by this simple means, we shall observe the greatest portion of the buccinator, whose points are inserted into the two maxillæ; but its posterior part, concealed under the masseter, cannot be well seen until this last has been removed; it is, therefore, necessary to abandon the preparation of it until after that of the masseter; this is the more necessary, as we should endeavor to seize this opportunity of observing the direction of the parotid canal, which terminates nearly

in the middle of the buccinator, and which it is important to preserve.

Orbicularis labiorum.—If it is proper to place something in the mouth or between the lips, for the preparation of some of the muscles of the face, it is absolutely indispensable to do so for the orbicularis labiorum; without this precaution, it would be almost impossible to make a preparation of it. The skin covering the lips is so thin, that in endeavoring to dissect it, we always remove a greater or less portion of the orbicularis. This muscle itself is nothing more than the result of the disposition of the other muscles of the face, which form it in great part, in extending to the lips. In order to prepare it, it is essential to place the lips in the most perfect tension, and remove the skin with much caution.

DESCRIPTION.

Occipito-frontalis.

(*Idem.*)

Situation and figure.—Thin, quadrilateral, situated on the superior part of the head.

Extent.—From the superciliary ridges and root of the nose, to the superior line of the occiput.

Division.—Superior surface, covered by the integuments. Inferior surface, applied to a portion of the frontal, parietal, and occipital bones. Its internal border is confounded with that of the opposite side; the external with the auricular muscles; the anterior with the orbicularis, pyramidalis, and corrugator supercillii; the posterior is parallel to the superior curved line of the occiput.

Direction.—Horizontal.

Structure and uses.—Aponeurotic at its middle portion, fleshy in the rest of its extent, it corrugates the skin of the head, and draws that of the forehead upwards.

AURICULARIS ANTERIOR.

(*Zygomato-Auriculaire.*)

Situation and figure.—Thin, triangular, situated on the temple.

Extent.—Between the ear and external orbital angle.

Division.—External surface covered by the integuments; internal surface applied to the temporal muscle. The inferior border is free; the superior is confounded with the superior auricular; the anterior, or base, loses itself partly in the occipito-frontalis; the summit is fixed to the helix.

Direction.—Horizontal.

Structure and uses.—Slightly aponeurotic at its base and summit, fleshy in the rest of its extent, it draws the ear forwards.

AURICULARIS SUPERIOR.

(*Temporo-auriculaire.*)

Situation and figure.—Thin, triangular, situated on the temporal region.

Extent.—From the superior part of the ear to the neighboring portion of the occipito-frontalis.

Division.—External surface, covered by the integuments, internal surface applied to the aponeurosis of the temporalis. The anterior border is confounded with the anterior auricularis; the posterior with the auricularis of the same name; the superior, or base, with the occipito-frontalis; the summit loses itself in the cartilage of the ear.

Direction.—Radiated from the cartilage of the ear to the adjacent part of the occipito-frontalis.

Structure and uses.—Slightly aponeurotic at its base and summit, fleshy in the rest of its extent, it raises the ear.

AURICULARIS POSTERIOR.

(*Mastoïdo auriculaire.*)

Situation and figure.—Thin, elongated, situated on the mastoid region.

Extent.—From the ear to the mastoid apophysis.

Division.—External surface, covered by the integuments; internal surface, applied to the os-temporale. It is fixed on the one hand to the posterior portion of the ear, and, on the other, to the mastoid apophysis.

Direction.—Horizontal.

Structure and uses.—Similar to the two preceding as regards its structure, it carries the ear backwards.

CORRUGATOR SUPERCILII.

(*Fronto Surcilier.*)

Situation and figure.—Elongated, narrow, situated on the superior part of the face.

Extent.—From the environs of the internal orbital angle to the distance of two fingers' breadth outwardly.

Division.—Anterior surface, covered by the occipito-frontalis; posterior surface applied to the os-frontis. The internal extremity is fixed to the internal portion of the superciliary ridge; the external loses itself in the orbicularis and occipito-frontalis, two or three fingers' breadth from the first insertion.

Direction.—Transverse.

Structure and uses.—Entirely fleshy, it approximates the eye-brows, and draws them downwards.

PYRAMIDALIS.

(Fronto-nasal.)

Situation and figure.—Elongated, narrow, situated at the superior part of the nose.

Extent.—From the root to the middle of the nose.

Division.—Anterior surface, covered by the integuments; posterior surface, applied to the bones of the nose. The superior extremity, a continuation of the occipitofrontalis, is fixed to the root of the nose; the inferior to its middle portion.

Direction.—It follows that of the dorsum of the nose.

Structure and uses.—Aponeurotic inferiorly, fleshy in the rest of its extent, it corrugates the skin of the nose.

ORBICULARIS PALPEBRARUM.

(Nazo-palpebral.)

Situation and figure.—Thin, broad, oval, and open in the centre; it is situated at the superior part of the face, in the substance of the eye-lids.

Extent.—From the great orbital angle to the temple, and from the eye-brow to the region of the cheeks.

Division.—Anterior surface covered by the skin of the eye-lids; posterior surface, which covers the corrugator supercilii, zygomatici, levatores labiorum, and the ligaments and cartilages of the eye-lids. Its great circumference commences at the internal orbital angle, extends over the eyebrow, descends towards the temple, and continues its direction downwards and inwards passing over the zygomatici and levatores labii superioris, and terminates at the internal orbital angle. Its small circumference accompanies the free border of the eye-lids.

Structure and uses.—Two tendons are remarked at its internal portion; one, direct, is fixed to the great angle;

the other, reflected, is lost on the lachrymal sac ; it approximates the two eye-lids.

LEVATOR LABII SUPERIORIS ALÆQUE NASI.

(*Grand sus-maxillo-labial.*)

Situation and figure.—Thin and elongated ; situated on the middle portion of the face.

Extent.—From the ascending apophysis of the maxillary bone, to the superior lip.

Division.—Anterior surface, covered superiorly by the orbicularis, and by the skin in the rest of its extent ; posterior surface, applied to the maxillary bone ; it is united externally with the levator labii superioris proprius. Its superior extremity is fixed to the ascending apophysis of the maxillary bone, near the internal orbital angle ; the inferior is lost, on the one hand, in the wing of the nose, and, on the other, in the upper lip

Direction.—Nearly vertical.

Structure and uses.—Slightly aponeurotic superiorly, fleshy in the rest of its extent, it elevates the wing of the nose and superior lip.

LEVATOR LABII SUPERIORIS PROPRIUS.

(*Moyen sus-maxillo-labial.*)

Situation and figure.—Thin, elongated, situated on the middle portion of the face.

Extent.—From the orbit to the superior lip.

Division.—Anterior surface, covered above by the orbicularis and by the skin in the rest of its extent ; posterior surface, applied to the maxillary bone. The superior extremity is attached to the base of the orbit ; the inferior is lost in the superior lip.

Direction.—Nearly vertical.

Structure and uses.—Slightly aponeurotic superiorly, fleshy in the rest of its extent, it elevates the upper lip.

ZYGOMATICI.

(*Grand et petit zygomato labiax.*)

Situation and figure.—Elongated, narrow, situated on the middle and lateral portions of the face.

Extent.—From the malar bone to the upper lip.

Division.—Anterior portion, covered above by the orbicularis, and by the skin in the rest of their extent; posterior portion, which covers a part of the cheek bone and buccinator. The superior extremity is fixed to the cheek bone, that of the small within, and that of the large without; the inferior is lost in the commissure of the lips.

Direction.—Oblique from above downwards, and from without inwards.

Structure and uses.—Slightly aponeurotic above, fleshy in the rest of their extent, they draw the commissure of the lips upwards and outwards.

CANINUS.

(*Petit sus-maxillo-labial.*)

Situation and figure.—Thin, elongated, situated on the middle portion of the face.

Extent.—From the canine fossa to the upper lip.

Division.—Anterior surface, covered by the levator labii superioris proprius and by a quantity of fat; posterior surface, applied to the maxillary bone. The superior extremity is fixed in the bottom of the canine fossa; the inferior loses itself in the upper lip, near the commissure.

Direction.—Slightly oblique from above downwards, and from within outwards.

Structure and uses.—Fleshy, it elevates the superior lip, and draws its commissure inwardly.

TRANSVERSALIS NASI.

(*Sus-maxillo-nasal.*)

Situation and figure.—Very thin, flat and triangular, situated on the side of the nose.

Extent.—From the canine fossa to the nose.

Division.—Anterior surface, covered by the levatores : posterior surface, applied to the maxillary bone. The external extremity is fixed in the canine fossa ; the internal to the dorsum of the nose.

Direction.—Transverse.

Structure and uses.—Slightly aponeurotic within, and fleshy in the rest of its extent ; its uses are uncertain ; according to some, it dilates the nose, and to others, it contracts it. It is probable that it serves the former purpose.

MYRTIFORMIS.

(*Sous-maxillo-nasal.*)

Situation and figure.—Thin, flat, situated on the middle portion of the face.

Extent.—From the maxillary bone to the superior lip and wing of the nose.

Division.—Concealed by the superior lip, it is entirely covered by it : it is fixed, on the one hand, to the maxillary bone, above the dentes incisores, and, on the other, to the cartilages of the wing and septum of the nose.

Direction.—Vertical.

Structure and uses.—Entirely fleshy, it depresses the wing of the nose, and contracts its orifice.

TRIANGULARIS MENTI.

(Maxillo-labial.)

Situation and figure.—Thin, flat, triangular, situated on the inferior and lateral portions of the face.

Extent.—From the base of the under jaw bone to the inferior lip.

Division.—Anterior surface, covered by the skin; posterior surface, applied to the quadratus. The inferior extremity, called the base, is fixed to the external oblique line of the inferior maxillary bone; the superior, or summit, is lost in the commissure of the lips: here, its fibres become confounded with those of the caninus and zygomatici.

Direction.—Vertical.

Structure and uses.—Altogether fleshy, it draws the commissure of the lips downwards.

QUADRATUS MENTI.

(Mento-labial.)

Situation and figure.—Thin, flat, quadrilateral, situated at the inferior part of the face.

Extent.—From the base of the jaw to the inferior lip.

Division.—Anterior surface, covered by the triangularis, platysma myoides and skin; posterior surface, applied to the jaw. The internal border is confounded with that of the opposite side; the external is free; the inferior is fixed to the base of the jaw; the superior loses itself in the inferior lip.

Direction.—Slightly oblique from below upwards, and from without inwards.

Structure and uses.—Entirely fleshy, it depresses the inferior lip.

HOUPPE DU MENTON.

(*Comprised in the Mento-labial.*)

Situation and figure.—Conical, situated at the inferior and middle portion of the face.

Extent.—From the inferior maxillary bone to the integuments of the chin.

Division.—It has a base united to the quadratus muscle, and terminating in the skin of the chin; a summit fixed in the fossette observed below the inferior dentes incisores.

Direction.—Its fibres diverge from the summit to the base.

Structure and uses.—Entirely fleshy, it renders the chin prominent.

BUCCINATOR.

(*Bucco-labial.*)

Situation and figure.—Thin, flat, quadrilateral, situated in the substance of the cheek.

Extent.—From one alveolar border to the other, and from their posterior part to the commissure of the lips.

Division.—External surface, covered by the masseter, zygomaticus major, triangularis, and parotid duct, which traverses it from without inwards; internal surface, applied to the internal membrane of the mouth. The superior and inferior borders are fixed to the alveolar borders of each jaw; the posterior is united to the pharygean membrane; the anterior loses itself in the commissure of the lips.

Direction.—The superior fibres are oblique from behind forwards, and from above downwards; the inferior likewise from behind forwards, and from below upwards: the middle are transverse.

Structure and uses.—Entirely fleshy, it draws the commissure outwards ; it also acts during mastication, and the use of wind instruments.

ORBICULARIS LABIORUM.

(*Labial.*)

Situation and figure.—Oval, flat, situated in the substance of the lips.

Extent.—From one commissure to the other.

Division.—Composed of all the muscles going to the lips, the orbicularis presents an anterior surface, covered by the skin ; a posterior, applied to the internal membrane of the mouth ; a great circumference, confounded with the muscles of the lips ; a small circumference, forming the free border of the lips.

Direction.—The fibres form concentric lines, which, from one commissure to the other, pass from the great to the small circumference.

Structure and uses.—Entirely fleshy, it approximates the lips, and contracts the orifice of the mouth. It likewise serves for the prehension of food, and the articulation of sounds.

The muscles of the face and head in general greatly excel, as regards expression, vivacity and variety of action, all the other muscles of the animal economy. I shall not attempt to describe their numerous attributes ; such an undertaking would oblige me to exceed the limits which I have proposed in this work. I shall merely indicate their principal uses. In civilized man, the auriculares and occipito-frontalis have obscure and limited movements ; it is only in the heat of passion, under some alarming excitement, or in consequence of the effects of long habit, that

they enjoy a certain action, and that their contraction becomes more or less manifest.

The anterior portion of the occipito-frontalis is alone an exception to this general law. It is this which, by imparting continual wrinkles to the skin of the forehead, gives rise to those depressions, which become lasting in proportion as age advances; the portion of the occipito-frontalis, extending to the nose, under the name of pyramidalis, produces similar effects at the root of the nose; the corrugator supercilii, in hatred, anger, sadness, &c., causes the longitudinal wrinkles, observed on the forehead, and which ultimately become permanent in persons of a grave, fierce, and passionate character.

The orbicularis palpebrarum, by bringing the two eye-lids towards each other, opposes the admission of the luminous rays, when we are exposed to a vivid light; in sleep and in drunkenness, its action is very trifling; but on the contrary, it is very lively whilst awake; it is in consequence of this action that the eye-lids, rapidly approximated to each other, cause their internal surface to traverse the globe of the eye, remove the small ambient corpus cules which would otherwise have remained there, and contribute in this way to give it that polish, and brilliancy necessary for the integrity and perfection of vision. To the physiological history of the orbicularis is joined that of the levator palpebræ superioris which, the antagonist of the first, separates the superior eye-lid from the inferior, permits the entrance of the rays of light into the globe of the eye, and thus favors the phenomena of vision. The other muscles of the face refer more or less to the action of the lips in the prehension of food, in the articulation of sounds, and also in the sad or lively affections, with which we are so often affected.

EIGHTH REGION.

Temporo-zygomatique.

Muscles on the lateral portions of the head, and those which surround the articulation of the inferior maxilla.—These muscle are :—the masseter, zygomaticus or temporalis, and the two pterygoidei.

Anatomical Preparation.

We should not proceed to the dissection of these muscles until after having performed a section, which will very much facilitate their preparation. But this section, rigorously speaking, is only necessary for the study of the pterygoid muscles, for we can dispense with it for the temporalis and masseter.

Masseter.—In order to prepare this muscle, we should detach the skin from the lateral portions of the face; expose the parotid gland, and pursue its excretory duct, which passes across the masseter, near the zygomatic arcade, and pierces the buccinator. The dissection of the masseter must be continued, and after having examined it, we should remove the parotid gland lodged in the space between the branch of the inferior jaw and the external auditory conduit; this is necessary in order to proceed to the examination of the temporalis.

Temporalis.—Placed immediately under the skin of the lateral regions of the head, the temporalis is one of the easiest muscles to prepare, at least as regards its superior portion. If the auricular muscles, which have been described, are well removed, the temporalis will be exposed as far as the zygomatic arcade. The remainder of the muscle concealed by this arcade should not be prepared until after the pterygoidei. We are, therefore, to be satisfied with isolating well its superior portion, as likewise the

skin, the auriculares, and the cellular tissue as far as the arcade: the external aponeurosis must be preserved, and we should then proceed immediately to the dissection of the pterygoid muscles.

The two pterygoidei.—We should remove the masseter from the side on which we wish to prepare these muscles, and break the zygomatic apophysis; we can then terminate the study of the temporalis, the tendon of which is attached to the coronoid apophysis of the under jaw. The jaw-bone must then be sawed at the point, at which the body is united to the branches; if we remove outwardly the portion which is behind, in disarticulating the condyle, we shall bring into view the large pterygoideus, which is only separated from the pharynx by a small quantity of fat and loose cellular tissue. This muscle is in every respect similar to the masseter, with the only difference that one is within and the other without. The small pterygoideus is more difficult to prepare. Some anatomists recommend to cut the large pterygoideus cross-wise in order to have a good view of the small one; this is a bad procedure. The following directions should be pursued:—saw that portion of the under jaw to which the pterygoideus is attached; raise that part which corresponds to the condyle, and remove the abundant fat found beneath, and which separates the two pterygoid muscles; in this way, we shall destroy nothing, and have an opportunity of observing the large and small pterygoids in place. The rule just given for the preparation of these muscles is as easy and convenient, as the one laid down by Lieutaud is defective and embarrassing.

The pterygoids may likewise be seen, when occupied with the muscles of the pharynx. If the piece on which we study the pharynx and muscles attached to the styloid

apophysis, is well arranged, and if the section of it has been well executed, it must be admitted that the pterygoid muscles can then be advantageously viewed. But by this latter method the student is obliged to interrupt the order of study as regards the muscles of mastication. This latter inconvenience would make me prefer the directions, which I previously indicated, at least for the first year. At a later period, the student may follow either method.

Description.

MASSETER.

(*Zygomato-Maxillaire.*)

Situation and figure.—Flat, thick and quadrilateral; situated on the lateral portions of the face.

Extent.—From the zygomatic apophysis to the under jaw.

Division.—External surface, covered by the skin, the duct of the parotid gland, a portion of this gland and platysma muscle; internal surface, which covers the branches of the lower jaw, and a portion of the temporal and buccinator. The posterior border corresponds to the parotid gland; the anterior is free under the fat of the cheeks. The superior extremity is attached to the external surface of the zygomatic apophysis; the inferior to the external surface and lower border of the branches of the jaw.

Direction.—Vertical.

Structure and uses.—Aponeurotic at its attachments, and broad aponeuroses intermix with the fleshy fibres placed in the interval. It elevates the lower jaw.

TEMPORALIS.

(Temporo-maxillaire.)

Situation and figure.—Flat, radiated, and triangular; situated on the lateral portions of the head.

Extent.—From the temporal region to the coronoid apophysis of the under jaw.

Division.—External surface, covered by the three auricular muscles, skin, zygomatic apophysis, and a portion of the masseter. Internal surface, applied to the temporal fossa. Its anterior and posterior borders are free, and present nothing remarkable. The base, turned upwards, follows the direction of the curved temporal line; the summit, resulting from the anterior and posterior borders, attaches itself, after passing behind the zygomatic arcade, to the coronoid apophysis of the inferior maxillary bone.

Division.—The anterior fibres are oblique from above downwards, and from before backwards; the posterior from above downwards, and from behind forwards; the middle are vertical.

Structure and uses.—A tendon is remarked at its inferior extremity; two aponeuroses, the one superficial, the other profound, enclose between them the fleshy fibres of the temporalis. It elevates the inferior jaw, applies it against the superior, and, like the masseter, acts with much force during mastication.

PTERYGOIDEUS MAJOR.

(Grand pterigo-maxillaire.)

Situation and figure.—Flat, thick, and quadrilateral; situated on the lateral portions of the face, within the jaw.

Extent.—From the pterygoid fossa to the lower jaw.

Division.—External surface, which corresponds above to the small pterygoideus, below to the internal part of the

branches of the inferior maxilla, from which it is separated by the inferior dental vessels and a quantity of fat. Internal surface, applied above to the external peristaphylin and constrictor; below, to the maxillary gland. The superior extremity is attached in the pterygoid fossa to the two wings of the apophysis of the same name; the inferior to the internal part of the lower jaw, like the masseter to the external.

Direction.—Vertical.

Structure and uses.—The structure of this muscle is nearly similar to that of the masseter, and its uses are the same.

PTERYGOIDEUS MINOR.

(*Petit ptèrigo-maxillaire.*)

Situation and figure.—Very slightly elongated, thick and triangular; situated in the zygomatic fossa.

Extent.—From the zygomatic fossa to the neck of the condyle of the jaw.

Division.—External surface, covered by the temporal muscle. Internal surface, applied to the large pterygoideus and maxillary vessels. Superior surface, lodged in the zygomatic fossa. The superior extremity, or base, is attached to the external wing of the pterygoid apophysis; the inferior, or summit, to the anterior part of the neck of the condyle of the lower jaw.

Direction.—Oblique from before backwards, and from within outwards.

Structure and uses.—Aponeuroses are intermixed with the numerous fleshy fibres. It carries the lower jaw forwards and laterally.

The action of these four muscles is exclusive and well determined; they perform the function of mastication.

tion, and suffice for all the efforts required by this operation, so necessary to the great act of digestion. The buccinator, although really a stranger to mastication, contributes, however, to render it more perfect, by pressing on the food, and placing it continually under the action of the molar teeth.

Although it is very evident that the muscles in question elevate the inferior maxilla and apply it strongly against the superior, it is yet true that in the complete luxation of the lower jaw, so far from being able to bring this in apposition with the upper, they maintain it, on the contrary, in its forced descent and in this way oppose its reduction.

NINTH REGION.

SUPERFICIAL CERVICAL.

Muscles on the anterior part of the neck.

These muscles are:—the platysma myoides, sternocleido-mastoideus, digastricus, mylo-hyoideus, genio-hyoideus, omoplate-hyoideus, sterno-hyoideus, sterno-thyroideus, and hyo-thyroideus.

Platysmia-myoides.—Here commences the preparation of the superficial muscles on the anterior part of the neck. Remove, carefully the skin of the neck, which must be dissected from above downwards, from the chin to below the superior extremity of the sternum; detach the flap from within outwards, and from above downwards, but care must be taken not to remove with it the platysma muscle, which is very thin and pale, and which is intimately united to it. There are some subjects in which it is more red and apparent, but in general it is very difficult to dissect it properly. This muscle is like a second skin, beneath which are placed all the muscles of the neck, which may even be perceived across the very thin tissue

of the platysma. It is very important to remove this muscle immediately after its preparation, because it will become dry, and then it will no longer be possible to detach it. In isolating it, it will be necessary to remove a quantity of cellular tissue, and even fat, placed between the platysma and muscles situated beneath; then we shall see, proceeding from above downwards, the digastricus, mylo-hyoideus, stylo-hyoideus, the maxillary gland, carotid artery, external jugular vein, omoplate-hyoideus, sterno-hyoideus, sterno-thyroideus, hyo-thyroideus, sterno-cleido-martoideus, and the thyroid gland.

Sterno-cleido-mastoideus.—It will suffice to separate the skin in order to expose this muscle, which has, at its superior part, very intimate connexions with the splenius, and to which the skin is very strongly united. It is this muscle, which forms under the skin on the lateral portions of the neck, that elongated and prominent band which is distinctly perceived in the expression of the passions, in lean and aged persons, and such as are deprived of embonpoint. After having exposed the sterno-cleido-mastoideus, it will be proper to cut it across, and turn the two flaps above and below, in order to pass to the digastricus, which it in part covers.

Digastricus.—This muscle, lying on the whole length of the inferior border of the jaw, is easily distinguished; after having removed the sterno-cleido-mastoideus, it only remains to isolate well the tendinous portion from the cellular tissue, which envelopes it, and which contracts adhesions with the stylo-hyoideus, near the os-hyoides. It is important to examine this disposition, on account of the circumstances resulting from it as regards the action of the digastric muscle; in fine, it is in passing into the species of pulley, which the stylo-hyoideus presents to it in this place, that the digastricus, changing its direction in

order to go to the under jaw, imparts to this last a movement of descent, which otherwise would not take place.

Mylo-hyoideus.—For an exact view of this muscle, we must detach the digastricus at its insertion into the jaw, and turn it over on the os-hyoides; we should remove the cellular tissue, and, in order to render the mylo-hyoideus more visible, carry the under jaw upwards.

Genio-hyoideus.—Detach the mylo-hyoideus from the under jaw from behind forwards, and turn it over on the os-hyoides; and if, with this muscle, we remove the fat and sub-lingual gland, the genio-hyoideus will be exposed. We shall also see in this preparation the great hypo-glossal nerve, a large whitish cord, which proceeds transversely from behind forwards, and from without inwards; in addition, the lingual and submental arteries. I would recommend to leave for a moment the preparation of the genio-glossus, placed beneath the preceding; it will be described in the article consecrated to the muscles of the tongue, for which we shall indicate a particular dissection.

Omoplate-hyoideus.—This small slender muscle is exposed by the detachment of the inferior flap of the sternocleido-mastoideus, and this is the only preparation it requires. We may, in preparing the other muscles of the superficial part of the neck, leave it in place or cut it. It is true that the portion of this muscle, which extends to the omoplate, is not exposed by this procedure; but as it would be necessary, in order to come to it, to cut several other muscles which the student is not yet acquainted with, and which it is important not to touch, I would advise to defer a further examination of it, until he shall enter on the preparation of the muscles of the shoulder.

Sterno-hyoideus.—This muscle, placed on the inferior half of the median line of the neck, immediately beneath

the platysma myoides, is exposed the instant this last is removed, and the facility of isolating it, in raising it without detaching it, renders its preparation extremely easy.

Sterno thyroideus.—Cut transversely through the middle of the preceding; reverse the two flaps, the inferior of which covers in part the sterno-thyroideus, and the superior the hyo-thyroideus. The sterno-thyroideus is applied on the thyroid gland, the color of which, sometimes resembling that of the muscle, may deceive us: by raising this last, and cutting it cross-wise at its middle portion, on one side only, we shall avoid all error on this subject.

Hyo-thyroideus.—This small muscle, lying on the thyroid cartilage, and concealed, in part, by the sterno-hyoideus, is one of the least difficult to prepare, since it is sufficient to have removed this last in order to bring it perfectly into view.

The dissection of the muscles appertaining to the tongue, velum palati, pharynx and larynx will be described in a subsequent chapter.

Description.

PLATYSMA MYOIDES.

(*Thoraco-facial.*)

Situation and figure.—Thin, flat, quadrilateral; situated on the anterior and lateral part of the neck.

Extent.—From the inferior maxilla to the superior portion of the thorax and region of the shoulder.

Division.—External surface, covered by the skin; internal surface, applied to all the objects forming the superficial plane of the anterior and lateral portions of the neck. The anterior border is confounded with that of the opposite side; the posterior is free, and extends from the shoulder to the under jaw; the superior is confounded, on the body

of the under jaw, with the triangularis and quadratus menti, and the inferior loses itself in the cellular tissue at the superior part of the thorax.

Direction.—Oblique from without inwards, and from below upwards.

Structure and uses.—Entirely fleshy, it wrinkles the skin on the neck.

STERNO-CLEIDO-MASTOIDEUS.

(*Idem.*)

Situation and figure.—Elongated and somewhat flat; situated on the lateral portions of the neck.

Extent.—From the mastoid apophysis to the clavicle and sternum.

Division.—External surface, covered by the skin, the platysma myoides being interposed. Internal surface, covering above and below the digastricus, carotid artery, eighth pair of nerves, omoplate-hyoideus, internal jugular vein, and quite low down, the sterno-thyroid, and sterno-hyoid muscles. The borders, free under the skin, present nothing remarkable. The superior extremity is attached to the mastoid apophysis, the inferior is double, and is attached to the superior part of the sternum, and to the sternal extremity of the clavicle.

Direction.—Oblique from above downwards, and from behind forwards.

Structure and uses.—Aponeurotico-tendinous at its attachments, fleshy in the rest of its extent, it draws the head to one side, in making it execute a movement of rotation from the side opposite its insertion.

OMOPLATE-HYOIDEUS.

(Scapulo-hyoidien.)

Situation and figure.—Thin, elongated, situated on the anterior and lateral portions of the neck.

Extent.—From the os-hyoides to the omoplate.

Division.—External surface, covered by the platysma-myoides, sterno-cleido-mastoideus and clavicle; internal surface, which covers a portion of the sterno-thyroideus and hyo-thyroideus, the scaleni, carotid artery and internal jugular vein. The free borders do not present any thing worthy of attention. The anterior extremity is attached to the middle and inferior portion of the os-hyoides; and the posterior to the superior border of the omoplate.

Direction.—Oblique from above downwards, and from before backwards.

Structure and uses.—Aponeurotic at its extremities, tendinous at its middle portion, and fleshy in the intervals, it draws the os-hyoides downwards.

STERNO-HYOIDEUS.

(Idem.)

Situation and figure.—Elongated, flat, situated at the anterior and middle part of the neck.

Extent.—From the sternum to the os-hyoides.

Division.—Anterior surface, covered by the platysma-myoides and sterno-cleido-mastoideus; posterior surface, applied to the thyroid gland, sterno-thyroideus, crico-thyroideus, and thyro-hyoideus. The superior extremity is attached to the inferior part of the body of the os-hyoides; the inferior to the superior and internal part of the sternum.

Direction.—Vertical.

Structure and uses.—Aponeurotic at its attachments,

fleshy in the rest of its extent, it draws the os-hyoides downwards and inwards.

STERNO-THYROIDEUS.

(*Idem.*)

Situation and figure.—Elongated, flat, situated at the anterior and middle part of the neck.

Extent.—From the sternum to the thyroid cartilage.

Division.—Anterior surface, covered by the sterno-hyoideus, platysma-myoides, and sterno-cleido-mastoideus; posterior surface, applied to the trachea, thyroid gland, and cartilage. The superior extremity is fixed to the anterior and middle part of the thyroid cartilage; the inferior, to the superior and internal part of the sternum, more within than the preceding.

Direction.—Vertical.

Structure and uses.—Aponeurotic at its attachment, fleshy in the interval, it draws the thyroid cartilage downwards.

HYO-THYROIDEUS.

(*Idem.*)

Situation and figure.—Thin, flat, quadrilateral; situated at the anterior and superior part of the neck.

Extent.—From the thyroid cartilage to the os-hyoides.

Division.—Anterior surface, covered by the sterno-hyoideus, omoplate-hyoideus and platysma myoides; posterior surface, applied to the thyroid cartilage. The internal and external borders do not present any thing remarkable. The superior extremity is fixed to the os-hyoides, and the inferior to the thyroid cartilage,

Direction.—Vertical.

Structure and uses.—Entirely fleshy it draws the os-hyoides downwards, and the thyroid cartilage upwards.

DIGASTRICUS.

(*Mastoido-génien.*)

Situation and figure.—Elongated transversely; situated at the superior and lateral portion of the neck.

Extent.—From the digastric groove to the inferior maxillary bone, passing on its way through the stylo-hyoides.

Division.—External portion, covered in front by the platysma myoides and sterno-cleido-mastoideus; behind, by the splenius. Internal portion, applied to the stylo-hyoideus, stylo-glossus and stylo-pharyngeus, and in front to the mylo-hyoideus. The posterior extremity fixes itself in the digastric groove of the temporal bone, and the anterior to the inferior and middle part of the under jaw.

Direction.—Transverse.

Structure and uses.—Aponeurotic at its attachments, tendinous in the centre, fleshy in the two intervals, it draws down the under jaw, and, according to some anatomists, elevates the upper,

MYLO-HYOIDEUS.

(*Idem.*)

Situation and figure.—Thin, flat, triangular, situated at the superior and anterior part of the neck.

Extent.—From the body of the under jaw to the os-hyoides.

Division.—External surface, covered by the platysma myoides and digastricus; internal surface, applied to the genio-hyoides, genio-glossus, sublingual gland and lingual nerve. The external border is free; the internal is con-

founded with that of the opposite side: the superior is fixed to the mylo-hyoidean line of the inferior maxilla. From the external and internal borders there results an extremity, which is attached to the os-hyoides.

Direction.—Oblique from above downwards, and from without inwards.

Structure and uses.—Slightly aponeurotic at its attachments, fleshy in the rest of its extent, it draws the os-hyoides upwards and forwards, and the inferior maxilla downwards.

GENIO-HYOIDEUS.

(*Idem.*)

Situation and figure.—Elongated, thin, situated at the superior, middle, and anterior part of the neck.

Extent.—From the inferior maxilla to the os-hyoides.

Division.—External surface, covered by the mylo-hyoideus; internal surface, applied to that of the opposite side and to the genio-glossus. The superior extremity is fixed to the apophysis of the chin, and the inferior to the os-hyoides.

Direction.—Vertical.

Structure and uses.—Slightly aponeurotic at its attachments, fleshy in the rest of its extent, it elevates the os-hyoides, in carrying it forwards, and depresses the under jaw.

Among the muscles of this region, there are only the platysma myoides and sterno-cleido-mastoideus, which do not associate their action with that of the other muscles of the same region. The first, weak, and superficial in man, slightly corrugates the skin on the anterior part of the neck; stronger, and more extensive in certain animals, it produces in them effects much more remarkable. The

second imparts to the head those great movements, by which it is carried quickly and forcibly towards the sides, inclines forwards and counterbalances the action of the muscles placed on the posterior part of the neck, such as the trapezius, complexus, &c. The other muscles of the ninth region are so situated that they produce the descent, at first of the larynx and os-hyoides and afterwards of the under jaw, which necessarily draws down the orifice of the mouth; but when this last is closed, and deglutition is going on, the muscles placed between the lower jaw and os-hyoides draw the latter upwards and forwards, and carry the larynx in the same direction—a movement which increases the capacity of the isthmus of the throat, the occlusion of the glottis and dilatation of the pharynx.

TENTH AND ELEVENTH REGIONS.

Lingual.—Staphylo-pharyngienne.

Muscles of the tongue, pharynx and velum palati.—These muscles are for the tongue;—the genio-glossus, hyo-glossus, stylo-glossus and lingualis; it is necessary to add the stylo-hyoideus, although it does not appertain to the tongue. Those of the pharynx are:—the three constrictors and stylo-pharyngeus; those of the velum palati are:—the two peri-staphylin, the palato-staphylin, the pharyngo-staphylin and glosso-staphylin.

Anatomical Preparation.

We cannot but admit that the preparation of the muscles, which are about to occupy our attention, is difficult, and that it requires great care and attention; I shall endeavor, however, to diminish the difficulties, by the precision with which I shall describe the various rules necessary to be adopted in order to accomplish their dis-

section. Cut the trachea at its middle portion; raise the superior flap; remove the loose cellular tissue, which unites this part to the vertebral column; carry this separation nearly as far as the base of the cranium, dividing on the sides the cellular tissue from the carotid arteries, eighth pair of nerves, scaleni muscles, internal jugular vein, &c.; having arrived at the superior part, pass the scalpel between the styloid apophysis and adjoining portion of the temporal bone, so as to preserve this apophysis in its integrity, as also the muscles which are attached to it; then carry the saw between the vertebral column and piece which is to become the object of attention. In sawing, it is rare that we do not remove the whole or part of the small anterior recti muscles of the neck. I cannot conceive it possible to avoid this inconvenience. We should divide the osseous parts as far as the root of the nose: after this, another section must be made, by carrying the saw from before backwards, from the middle of the nose, in order to fall perpendicularly on the first division; we then remove the piece, and proceed to prepare the different parts. In order to render the work easier, it will be proper to pull constantly on the two extremities of the piece in contrary directions, for the purpose of establishing a point of support necessary in this preparation. The first muscles, with which we should occupy ourselves, are those of the tongue and styloid apophysis; those of the pharynx and velum palati come next, and we terminate with those of the larynx. The muscles of the tongue are:—the genio-glossus, hyo-glossus, lingualis and stylo-glossus.

Genio-glossus.—Remove the genio-hyoideus, cutting it cross-wise, and turn its two flaps upwards and downwards. Immediately beneath, the genio-glossus is observed, a

fleshy mass somewhat considerable, which, from the apophysis of the chin, extends to the tongue, increasing in width as it goes along. In continuing to isolate it, we must attend to the connexions which it contracts outwardly with the hyoglossus, as well as with its fellow near the tongue. In drawing this last out of the mouth, we shall render the preparation of the muscle in question much more easy, as also that of the others.

Hyo-glossus.—Placed on the outer side of the preceding, and internal to the stylo-glossus, it is less extensive, but thicker than the genio-glossus. We must remove the sub-lingual gland, fat, and cellular tissue; keep the parts on a stretch, retain the tongue out of the mouth, and even saw the jaw at its middle portion; separate its branches, and by these different means, we shall be enabled to pursue the hyo-glossus which, from the os-hyoides, extends to the lateral portions of the tongue, where it terminates.

Lingualis.—This muscle composes in great part the proper substance of the tongue; it is placed along the whole length of this organ, between the two preceding, and cannot be seen until after removing the body of the jaw-bone, so as to be enabled to divide the inferior part of the tongue in its whole extent. It is proper to remark, that we must not attempt to terminate the preparation of the muscles of the tongue definitively, if we have not previously removed those of the pharynx and velum palati, whose preparation is more minute than embarrassing; and we cannot undertake them until after those of the tongue, whence results the necessity of studying all these muscles at one time. We may, however, remark that we cannot acquire, in the first dissection, as perfect a knowledge of the muscles of the series, which we are now considering, as those of the back or extremities.

Stylo-hyoideus.—Although this small muscle has been for some time exposed by all the preceding preparations, I thought proper not to describe it, until we could take into consideration the two other muscles, likewise attached to the same apophysis. The stylo-hyoideus is the most superficial and easy to dissect of the three; the mere separation of the digastricus and sterno-cleido-mastoideus brings it perfectly into view. But as it is not necessary to divide and remove the muscles on both sides at once, we may leave one of the sterno-mastoids in place, and not detach it until prepared to dissect the stylo-hyoideus. The name of this muscle indicates sufficiently well the direction necessary to be taken, and renders its recognition easy. We should not neglect to observe the manner in which it divides near the os-hyoides, in order to receive the tendon of the digastricus.

Stylo-glossus.—This is situated nearly behind the preceding; but it is deeper, and ascends higher up, for the purpose of going to the tongue. A great quantity of cellular tissue surrounds them near the styloid apophysis, as also the stylo-pharyngeus; but at a little distance from this apophysis, the three separate, and go in different directions to their destination. The stylo-glossus enlarges considerably in proportion as it approaches the tongue, in which it soon loses itself. It is unnecessary to pursue its dissection farther than its entrance into this organ, its fibres becoming confounded with those of the hyo-glossus. It is very essential to separate it carefully from the adjoining parts, which are very numerous; it is true that by the section, which we have indicated, the numerous relations of this muscle are reduced to a trifle; but such is the lot of anatomical preparations, that some

of them cannot be accomplished but at the expense of certain sacrifices inseparable from such an operation.

Stylo-pharyngeus.—The particular care taken to remove the cellular tissue, which interfered with the preparation of the two preceding muscles, will render that of the stylo-pharyngeus very easy; it occupies the base of the styloid apophysis, and extends lower down and farther back than the other two; it is necessary to prepare it at the posterior part of the piece. The loose cellular tissue which surrounds it is very trifling, and it can be separated with facility. Like the stylo-glossus, it becomes larger in proportion as it approaches the pharynx, in which it is lost about two or three inches from its origin, confounding its fibres very intimately with those of this muscular bag.

The three constrictors.—Writers admit three muscles in the pharynx; but dissection does not recognize this distinction, or, rather, it confounds them in the same operation—the preparation of one of the constrictors necessarily involving that of the two others. After having distended the pharynx, by stuffing it with linen or wet paper, we should carefully detach the cellular tissue found on its posterior and lateral portions; the three constrictors will then be as well prepared as an ordinary study of their parts will require. But if we desire to see the line, which separates them, we shall find it difficult and sometimes impossible to attain this object. Some modern anatomists have done away with these useless divisions, by embracing the muscular bag of the pharynx in one entire muscle. I admit this innovation the more readily, as it is well founded, and as it dispenses with a considerable sacrifice of time.

In order to judge of the difference between the directions I have given, and what the modern anato-

mists, particularly Lieutaud, have written on this subject, it will only be necessary to throw a coup d'œil over the preparation of the pharynx, and all the muscles attached to it. Lauth has passed this article by in silence; Lieutaud, himself, has been so diffuse, that it is impossible to profit by his advice. I think I have gained an advantage over all these anatomists, which no doubt will be appreciated; it is, that I have exposed the preparation proper to each part, in the order necessary to be pursued for its anatomical study.

The two peristaphylin muscles.—Cut the pharynx longitudinally at its posterior part, which will bring into view the posterior nares, velum palati, posterior opening of the mouth, called the isthmus of the throat, the Eustachian tubes, larynx, and the whole interior of the pharynx. An abundant mucosity is sometimes found on all these parts, it must be removed in order to pass to the preparation of the peristaphylin muscles; we first meet with the internal, which is under the base of the cranium. Commence by cutting with caution the mucous membrane on the posterior part of the velum palati; in slightly separating the borders of the incision, we shall observe in the interval distinct muscular fibres, extending somewhat cross-wise; they are those of the internal peristaphylin, which it will be necessary to expose more and more, by drawing the pharynx outwards, as far as its superior part, near the insertion of the pterygoideus major into the sphenoid bone; then the internal peristaphylin will be entirely uncovered. Remove the prolongation of the internal membrane of the mouth, which envelopes all the objects placed in the interior of the pharynx, and refer frequently to the description of the parts, in order to have a more perfect idea of their position. The external peristaphylin is more extensive and more profoundly seated than

the preceding. It is lodged in the space, which separates the pterygoideus externus, from the external side of the pharynx; we must likewise look for it on the inferior surface of the petrous bone, and in the pterygoid fossa of the sphenoid, the whole course of which it travels. Draw from time to time the velum palati in a contrary direction, in order to observe the passage of the tendon of the external peristaphylin over the external wing of the pterygoid apophysis, and which goes from hence to the velum palati.

Azygos uvulæ, constrictor isthmii faucium, palato-pharyngeus.—The azygos uvulæ muscles are lodged in the velum palati, of which they form the largest portion, and only require to be freed from the internal membrane of the mouth, which covers them. The constrictor isthmii faucium and palato-pharyngeus form, the first, the anterior pillar of the velum palati, and the last, the posterior pillar, the description of which indicates more particularly the extent and relations.

Description.

GENIO-GLOSSUS.

(*Idem.*)

Situation and figure.—Flat, triangular, situated on the anterior and superior part of the neck.

Extent.—From the under jaw to the os-hyoides and tongue.

Division.—External surface, covered by the mylo-hyoideus, sublingual gland and hyo-glossus. The internal surface corresponds with the muscle of the opposite side. The inferior border is covered by the genio-hyoideus; the superior, by the superior membrane of the tongue; the

base extends along the whole length of the tongue; the summit is fixed to the apophysis of the chin.

Direction.—Resembling a fan in form, it extends from the os-hyoides to the apophysis of the chin, and thence to the whole inferior portion of the tongue.

Structure and uses.—Entirely fleshy, it carries the tongue forwards and backwards, by the varied direction of its fibres, so that in some cases it can cause it to extend beyond the mouth, and in others it draws it back into the bottom of the throat.

HYO-GLOSSUS.

(*Idem.*)

Situation and figure.—Flat, quadrilateral, situated on the anterior and superior part of the neck.

Extent.—From the os-hyoides to the tongue.

Division.—External surface, covered by the mylo-hyoideus, maxillary gland, digastricus and genio-hyoideus. Its internal surface corresponds to the genio-glossus and lingualis. It is fixed, on the one hand, to the body and great cornua of the os-hyoides, and, on the other, to the posterior and lateral part of the tongue.

Direction.—Nearly vertical.

Structure and uses.—Entirely fleshy, it carries the tongue backwards and downwards, and the os-hyoides upwards.

LINGUALIS.

(*Idem.*)

Situation and figure.—Elongated, situated at the inferior part of the tongue.

Extent.—From the base to the apex of the tongue.

Division.—Its external surface corresponds to the hyo-

glossus; the internal, to the genio-glossus. Its superior and inferior borders are covered by the internal membrane of the mouth.

Direction.—Horizontal.

Structure and uses.—Entirely fleshy, it shortens the tongue and curves it upon itself.

STYLO-HYOIDEUS.

(*Idem.*)

Situation and figure.—Elongated, thin, situated on the superior and lateral part of the neck.

Extent.—From the styloid apophysis to the os-hyoides.

Division.—Outwardly, it is covered by the digastricus; inwardly, it covers the stylo-glossus, stylo-pharyngeus and hyo-glossus; the superior extremity is attached to the styloid apophysis; the inferior, to the anterior part of the body of the os-hyoides: it divides near this bone into two portions for the passage of the tendon of the digastricus.

Direction.—Oblique from above downwards, and from behind forwards.

Structure and uses.—Tendinous at its attachments, fleshy in the rest of its extent, it elevates the os-hyoides and carries it forwards. It may also elevate the superior maxillary bone, and in this way contribute to carry the head somewhat backwards, when the mouth is considerably open.

STYLO-GLOSSUS.

(*Idem.*)

Situation and figure.—Elongated, flat, situated on the lateral portions of the neck.

Extent.—From the styloid apophysis to the tongue.

Division.—External surface, covered by the digastricus and maxillary gland; internal surface, applied to the constrictors of the pharynx, to the hyo-glossus and lingualis. Its superior extremity is attached to the styloid apophysis, between the stylo-hyoideus and stylo-pharyngeus; the inferior terminates on the lateral portions of the tongue, and is lost in this organ.

Direction.—Oblique from behind forwards, and from above downwards.

Structure and uses.—Aponeurotic posteriorly, fleshy in the rest of its extent, it carries the tongue on the sides.

STYLO-PHARYNGEUS.

Idem.

Situation and figure.—Elongated, flat, situated on the lateral portions of the neck.

Extent.—From the styloid apophysis to the pharynx.

Division.—External portion covered by the stylo-hyoideus and external carotid artery; internal portion, which covers the internal carotid artery, internal jugular vein and palato-pharyngeus muscle. The superior extremity is attached to the base of the styloid apophysis; the inferior is confounded with the pharynx, and contracts some adhesions with the thyroid cartilage.

Direction.—Oblique from behind forwards, and from above downwards.

Structure and uses.—Aponeurotic posteriorly, fleshy in the rest of its extent, it elevates the pharynx.

THE THREE CONSTRICTORS.

(Idem.)

Situation and figure.—Flat, thin, quadrilateral, in their *ensemble*, situated at the superior, middle and inferior part of the pharynx, a great part of which they form.

Extent.—From the posterior nasal spine to the uvula.

Division.—Its anterior and posterior surfaces are covered by the internal membrane of the mouth. Its superior extremity is fixed to the posterior nasal spine and to the membrane of the velum; the inferior loses itself in the uvula.

Direction.—Vertical.

Structure and uses.—Entirely fleshy, it elevates the uvula.

CONSTRUCTOR ISTMII FAUCIUM.

(*Idem.*)

Situation and figure.—Elongated, thin, situated on the lateral portions of the velum palati.

Extent.—From the anterior pillar of the velum to the base of tongue.

Division.—The anterior and posterior parts are covered by the internal membrane of the mouth; in addition, the posterior part corresponds to the amygdal gland. The superior extremity is lost in the anterior pillar of the velum, which it in part forms; the inferior is fixed to the lateral parts of the base of the tongue.

Direction.—Nearly vertical.

Structure and uses.—Entirely fleshy, it elevates the base of the tongue and contracts the throat.

PALATO-PHARYNGEUS.

(*Idem.*)

Situation and figure.—Elongated, thin, situated on the lateral portions of the velum palati.

Extent.—From the posterior pillar of the velum to the larynx.

Division.—The anterior and posterior parts are imme-

diately covered by the internal membrane of the mouth. The superior extremity is fixed to the palatine arch, and contracts adhesions with the tensor palati; the inferior is lost in the pharynx, in the environs of the cricoid cartilage.

Direction.—Nearly vertical.

Structure and uses.—Entirely fleshy, it depresses the velum palati, and elevates the pharynx.

Of all the organs provided with muscular fibres, the tongue is that whose motions are the most varied and rapid. The tongue, in a word, is entirely fleshy, and it may be drawn forwards, and even out of the mouth, by the action of the posterior fibres of the genio-glossus, and backwards by the anterior fibres of the same muscle, as also by the lingualis; it may also carry itself in all other directions; to the right and left by the action of the stylo-glossus and lingualis; under the whole arch of the osseous palate, by the lingualis; finally, downwards and backwards, by the hyo-glossus.

The action of the levator palati, tensor palati and other muscles of the velum palati, as also that of the constrictors and other muscles of the pharynx, is much more complicated and demands greater attention in order to have a clear idea of them.

Ten muscles, five on each side, are particularly interested in the function of deglutition;—the levator and tensor palati by drawing the velum palati outwards and upwards, and the azygos uvulæ directly backwards and upwards; the constrictor isthmii faucium and palato-pharyngeus by drawing upwards, the first, the tongue, and the second the pharynx, do nothing more than favor the action of the muscles of the velum, and thus all of them contribute to

enlarge the isthmus of the throat, during the passage of the food through this opening.

The constrictors have an action tending to the same object, but it does not occur in all at the same time. Their uses are to contract the pharynx from above downwards, in proportion as the food passes through this muscular bag, and as it approaches the œsophagus, into which it is finally forced by the successive action of the three constrictors.

TWELFTH REGION.

Laryngean.

Muscles of the larynx.—These muscles are : the crico-thyriodeus, posterior crico-arytenoideus, lateral crico-arytenoideus, thyro-arytenoideus and ary-arytenoideus.

Anatomical Preparation.

Muscles of the larynx.—These do not present much difficulty, because they have a determinate extent, and fixed points of insertion. In order to prepare them, we must separate the larynx from the surrounding parts, being careful to preserve only the larynx properly so called, and a small portion of the trachea ; we should then carefully remove a quantity of loose cellular tissue applied on a thick membrane, which immediately covers the muscles of the larynx, but which can be removed without difficulty. We should commence with the crico-thyriodeus, placed at the anterior part, and which, of all, is the easiest to dissect ; we are then to pass to the posterior part, where will be found first the posterior crico-arytenoideus and lateral crico-arytenoideus, and more profoundly the thyro-arytenoideus and ary-arytenoideus.

We must admit that the partial dissection of the muscles of the larynx gives rise to great inconvenience, for

the study of these muscles cannot be separated either from the general history of the cartilages on which they are placed, or from the particular uses of the larynx; but usage has prevailed, and we conform to it.

Description.

CRICO-THYROIDEUS.

(*Idem.*)

Situation and figure.—Flat, thin, situated on the anterior part of the larynx.

Extent.—From the cricoid to the thyroid cartilage.

Division.—Anterior surface, covered by the thyroid gland and sterno-thyroideus muscle; posterior surface, applied to the thyroid and cricoid cartilages. The superior extremity is fixed to the inferior part of the thyroid cartilage; the inferior, to the anterior part of the cricoid cartilage.

Direction.—Oblique from below upwards, and from within outwards.

Structure and uses.—Entirely fleshy, it elevates the cricoid cartilage, and depresses the thyroid.

POSTERIOR CRICO-ARYTENOIDEUS.

(*Idem.*)

Situation and figure.—Flat, thin, situated on the posterior part of the larynx.

Extent.—From the cricoid to the arytenoid cartilage.

Division.—Posterior surface, covered by the mucous membrane of the internal part of the pharynx; anterior surface, applied to the cricoid cartilage.

Direction.—Oblique from below upwards, and from within outwards.

Structure and uses.—Entirely fleshy, it draws the arytenoid cartilage outwards and backwards.

LATERAL CRICO-ARYTENOIDEUS.

(*Idem.*)

Situation and figure.—Thin, flat, situated on the posterior and lateral part of the larynx.

Extent.—From the cricoid to the arytenoid cartilage

Division.—External surface, covered by the thyroid cartilage and crico-thyroid muscle; internal surface, applied to the membrane of the larynx. It is fixed, on the one hand, to the superior and lateral part of the cricoid cartilage; and on the other, to the base of the arytenoid.

Direction.—Oblique from below upwards, and from before backwards.

Structure and uses.—Tendinous at its superior attachment, fleshy in the rest of its extent, it draws the arytenoid cartilage outwards, and enlarges the glottis.

THYRO-ARYTENOIDEUS.

(*Idem.*)

Situation and figure.—Elongated, thin, flat, situated on the posterior and superior portion of the larynx.

Extent.—From the thyroid to the arytenoid cartilage.

Division.—External surface, covered by the mucous membrane of the internal part of the pharynx; internal surface, by that of the larynx. It is fixed, on the one hand, to the posterior part of the thyroid cartilage; on the other, to the arytenoid cartilage, below the lateral crico-arytenoid.

Direction.—Horizontal.

Structure and uses.—Entirely fleshy, it draws the arytenoid cartilage forwards.

ARY-ARYTENOIDEUS.

(*Idem.*)

Situation and figure.—Thin, flat, quadrilateral; situated at the posterior and superior part of the larynx.

Extent.—From one of the arytenoid cartilages to that of the opposite side.

Division.—Posterior surface, covered by the mucous membrane of the pharynx; anterior surface, applied to the arytenoid cartilages. It is fixed, on the one hand, to the base of one of the arytenoid cartilages, and, on the other, to the summit of that of the opposite side.

Direction.—Oblique from below upwards, and from without inwards.

Structure and uses.—Entirely fleshy, it approximates the arytenoid cartilages, and contracts the glottis.

The action of the muscles of the larynx is entirely relative to the phenomena of the voice in its different modifications, but it is not easy to determine the particular uses of these muscles, nor the more or less active part, which each of them takes in the production of sound. According to the system of Ferrein the uses of these muscles are reduced to a trifle, since this Anatomist makes the grave or acute tone consist in the greater or less tension of certain membranous productions situated transversely in the interior of the larynx, and since called *the vocal cords of Ferrein*. Dardart, on the contrary, likening the larynx to a wind instrument, contended that the formation of sounds and their difference from grave to acute tones, were owing to the greater or less degree of opening of the glottis, determined by the combined action of the muscles of the larynx. This latter opinion has prevailed among physiologists, although we cannot explain all the varieties and modifications of

which the voice is susceptible, by the simple and ordinary action of the laryngeal muscles.

THIRTEENTH REGION.

Profound cervical.

Deep-seated muscles on the anterior part of the neck.—These muscles are :—the scaleni, lateral rectus, great and small anterior recti, and longus colli. We must also add to these the triangularis sterni.

Anatomical Preparation.

Scaleni.—After having removed the muscles of the posterior part of the trunk, and performed the necessary section for the muscles of the tongue, pharynx, &c., the scaleni remain isolated on the lateral portions of the neck; the axillary artery and brachial plexus traverse them; we must not remove these latter objects; but in order to have a correct idea of the scaleni, and observe them properly in their whole extent, we should disarticulate the clavicle, and detach the arm of the same side from the trunk.

Lateral rectus.—Remove the cellular tissue and fat, which conceal the space separating the lateral portions of the first cervical vertebra from the neighboring part of the occiput; here we will find a small fleshy mass, situated very profoundly; it is the lateral rectus. In order to render this small muscle more apparent, incline the head and vertebral column in opposite directions. After the preparation of the lateral rectus succeeds that of the muscles called inter-transversales colli, but these cannot be seen until after the dissection of the Scaleni, which entirely conceal them.

Small and large anterior recti colli, and longus colli.—The section of the pharynx will expose these three

muscles; the two last are slightly concealed in their inferior portion by the thorax, which, however, cannot yet be removed, on account of the *triangularis sterni*; we must, therefore, be content with separating them from the cellular tissue, if any remains. It is rare, in the section made for the pharynx, not to remove the small anterior rectus, either in part or totally, and I admit that it is difficult to avoid this inconvenience; the only means of preventing it, would be to sacrifice the pharynx, or to make the section of it at the superior part of the head; but the muscle in question is of too little importance to require such precautions. The *rectus major* is also sometimes interfered with by the saw; but it is only at its superior portion, and this does not injure the study of it. The *longus colli* is never included, unless the saw should be directed by an unskilful hand, which will not be the case in following exactly the precepts, which I have already given for the section of the pharynx.

Triangularis sterni.—After removing the clavicle, saw the first ribs in their middle portion, and reverse the sternum from above downwards; detach the anterior mediastinum and accidental adhesions of the other parts in the interior of the chest. It will be important to preserve the attachments of the diaphragm, in order to see its connexion with the *triangularis*, which is now perfectly exposed.

Description.

RECTUS-LATERALIS.

(*Inter-trachèlien.*)

Situation and figure.—Flat, quadrilateral, situated on the superior and lateral portions of the neck.

Extent.—From the occiput to the first cervical.

Division.—Anterior surface, corresponding to the internal jugular vein; posterior surface, to the vertebral

artery. It is fixed above to the occiput, behind the jugular fossa; below, to the transverse apophysis of the first cervical vertebra.

Direction.—Vertical.

Structure and uses.—Slightly aponeurotic at its attachments, fleshy in the rest of its extent, it inclines and draws the head to one side.

SCALENUS ANTERIOR.

(*Costo-trachélien.*)

Situation and figure.—Elongated, situated on the lateral portions of the neck.

Extent.—From the third, fourth, fifth, and sixth vertebræ, to the first rib.

Division.—Anterior side, corresponding to the sternomastoid, omoplate-hyoid, and internal jugular vein; posterior side, separated from the posterior scalenus by the subclavian artery and brachial plexus. The superior extremity is attached to the transverse apophysis of the third cervical vertebra; the inferior, to the middle portion of the first rib.

Direction.—Oblique from above downwards, and from behind forwards.

Structure and uses.—Tendinous at its attachments, fleshy in the rest of its extent, it inclines the head to one side, and slightly elevates the first rib.

SCALENUS POSTERIOR.

(*Costo-trachélien.*)

Situation and figure.—Elongated, situated on the lateral portions of the neck.

Extent.—From the six last cervical vertebræ to the two first ribs,

Division.—Anterior side, separated from the preceding by the subclavian artery and brachial plexus; posterior side, covered by the sacro-lumbalis, angularis, transversalis, and splenius. The superior extremity is attached to the transverse apophysis of the second cervical vertebra; the inferior, to the two first ribs, by two distinct portions.

Direction.—Oblique from above downwards, and from behind forwards.

Structure and uses.—Tendinous at its attachments, fleshy in the rest of its extent, it inclines the head and neck to one side, and elevates the two first ribs.

INTER-TRANSVERSALES COLLI.

Situation and figure.—Thin, quadrilateral, distinguished into anterior and posterior, situated between the transverse apophyses of the vertebræ of the neck.

Division.—The anterior surface of the first corresponds with the rectus anterior colli major: the posterior surface of the last with the transversalis, splenius and sacro-lumbalis; the space between them is occupied by the posterior branches of the cervical nerves. They are all inserted into the superior and inferior sides of the transverse apophyses of the cervical vertebræ.

Direction.—Vertical.

Structure and uses.—Very slightly tendinous at their attachments, fleshy in the rest of their extent, they contribute to the lateral inflexions of the neck.

TRIANGULARIS STERNI.

(*Sterno-costal.*)

Situation and figure.—Triangular, flat, situated on the anterior and internal portion of the chest.

Extent.—From the sternum to the third, fourth, fifth, and sixth true ribs.

Division.—Anterior portions corresponding to the sternum and cartilages of the true ribs; posterior surface, corresponding to the pleura. The inferior extremity, or base, is united to the transversalis abdominis; the superior, or summit, is attached to the cartilage of the third rib.

Structure and uses.—Aponeurotic at its attachments, fleshy in the rest of its extent, it acts on the anterior extremity of the third, fourth, fifth, and sixth ribs, and on the corresponding cartilages, which it draws inwards.

RECTUS COLLI ANTERIOR MAJOR.

(*Grand trachélo-sous occipital.*)

Situation and figure.—Elongated, flat, situated on the anterior and profound portion of the neck.

Extent.—From the occiput to the sixth cervical vertebra.

Division.—Anterior surface, corresponding to the pharynx; posterior surface, applied to the bodies of the six first cervical vertebræ. The superior extremity is attached to the basilar apophysis of the occiput; the inferior is fixed to the body of the sixth cervical vertebra.

Direction.—Parallel to the vertebral column.

Structure and uses.—Tendinous at its attachments, fleshy in the interval, it bends the head on the vertebral column.

RECTUS COLLI ANTERIOR MINOR.

(*Petit trachélo-sous occipital.*)

Situation and figure.—Elongated, narrow, and thin, situated on the anterior, superior and profound portion of the neck.

Extent.—From the occiput to the first vertebra of the neck.

Division.—Anterior surface, covered by the rectus major, carotid artery and ninth pair of nerves; posterior surface, applied to the capsule of the articulation of the occiput and first cervical vertebra. The superior extremity is attached to the basilar apophysis of the occiput, more externally than the rectus major; the inferior, to the anterior and external surface of the first cervical vertebra.

Direction.—Oblique from above downwards, and from within outwards.

Structure and uses.—Tendinous at its extremities, fleshy in the interval, it draws the head forwards, and maintains its rectitude on the vertebral column.

LONGUS COLLI.

(*Prè-dorso-atloïdien.*)

Situation and figure.—Elongated, flat, situated on the anterior and profound portion of the neck.

Extent.—From the first cervical vertebra to the third dorsal.

Division.—Anterior surface, covered by the rectus major, pharynx, eighth pair of nerves, and the great sympathetic; posterior surface, applied to the bodies of the six last cervical vertebræ and three first dorsal. The superior extremity is fixed, with that of the opposite muscle, to the anterior tubercle of the first cervical vertebra (*atlas*;) the inferior, to the anterior portion of the body of the third dorsal vertebra.

Structure and uses.—Tendinous at its attachments, fleshy in the intervals, it maintains the rectitude of the vertebral column, and opposes its falling backwards.

The two scaleni and rectus lateralis, as also the inter-

transversales, sometimes *congénères* of the quadratus lumborum, act especially in all the motions of lateral inflexion.

The anterior recti majores and minores, as likewise the longus colli, maintain on the one hand, the equilibrium of the head on the spinal column, and, on the other, fix the cervical vertebræ together, in opposing the falling backwards of that portion of the column on which they are applied.

FOURTEENTH AND FIFTEENTH REGIONS.

Scapulo-humèrale-humèrale.

Muscles of the shoulder and arm.—These muscles are :—the deltoid, supra and infra-spinatus, sub-scapularis teres major and minor for the shoulder ; the biceps, coraco-brachialis, brachialis anterior and triceps brachialis for the arm.

Anatomical Preparation.

After having terminated the dissection of the muscles of the trunk and head, and passing to the examination of those of the extremities, the student is astonished at the facility and rapidity of his anatomical labors. These advantages, it is true, are due to the nature of the preparations, which are extremely easy ; but the skill which he has acquired at this period of his dissections is the real cause. I shall, therefore, limit myself in this place to the description of that only which is absolutely indispensable, passing rapidly over the details, which would now be superfluous.

Although I recommended the student to separate the superior extremity from the trunk, in order to study the serratus major, it will be more convenient for it to be attached to the trunk, for the dissection of the muscles of the shoulder ; their relations will be more advantageously seen, and their general situation much better appreciated. However, no matter what the state

of the parts may be, the preparation of these different muscles remains always the same, and is only a little more or less difficult. For their preparation, it will be necessary to make, through the integuments of the shoulder and arm, a longitudinal incision extending from the highest portion of the shoulder to the fold of the arm.

Deltoid.—The skin, which covers this muscle is sometimes abundantly furnished with adipose matter, which in some degree interferes with its preparation, without however, rendering it very difficult. We should carry the instrument in the direction of the fibres, and draw the flap of the integuments in a contrary direction, which will afford much facility in removing it. We should make a free incision with the scalpel, for there is considerable difference, as regards the preparation, between these muscles and those of the face or generation. The free borders of the deltoid indicate the point at which we should discontinue the separation of the skin; but, in general, it will always be better to uncover a larger surface than that of the muscle we are about to study, and we should not commence the examination of a part until after having properly isolated those, which surround it. The muscles of the arm, as likewise those of the fore-arm, are in part covered by a common aponeurosis, which is especially seen behind on the triceps, and in front on the biceps and fold of the arm. Its glossy aspect, its whiteness and tension cause it to be easily recognized. It is proper to leave it in situ in the dissection of the integuments, and we should not remove it until after having studied it in place.

Supra-spinatus.—The posterior part of this muscle is exposed in the preparation of the deltoid, and what remains to be done, as also for the most part of the other

muscles of the shoulder, is to cut across the deltoid at its middle portion, and detach its superior flap, in separating it exactly from the humerus, in order to leave it fixed only to the clavicle and spine of the scapula; by this mode the supra spinatus is perfectly exposed; the portion which goes alone to the humerus is still covered by the species of arcade formed by the coracoid and acromion apophyses, together with their ligaments. It is indispensable to break these apophyses, when we wish to examine the manner in which the tendons of the supra-spinatus, infra-spinatus, &c. are fixed to the head of the humerus; but this should not be done until after the preparation of the other muscles of the shoulder; we may be content with breaking the acromion apophysis only, and with cutting the triangular ligament, in order to observe in what way these tendons are inserted into the humerus. A considerable quantity of fatty matter and loose cellular tissue surrounds the articulation of the humerus with the omoplate, pass over the muscles, and keep them in part concealed; we should remove these different objects before proceeding to their examination.

Infra-spinatis.—Like the preceding, it is somewhat concealed by the the deltoid, but in a great part of its extent it is naked under the skin, and is immediately covered by nothing more than a small aponeurosis, which can be removed without difficulty. The portion going to the humerus likewise passes under the arcade of which we have spoken; before breaking it, and pursuing the ulterior dissection of these two muscles, those of the shoulder should be terminated.

Sub-scapularis.—We must dissect the integuments as far as possible from the shoulder and backwards, raise the omoplate from before backwards, carry the arm outwards,

remove the abundant cellular tissue placed between the sub-scapularis and trunk ; and we must delay the dissection of that portion which goes to the humerus, until the preparation of the other muscles is finished.

Teres major and minor.—In detaching the skin for the purpose of seeing the sub-scapularis, we likewise expose these two last muscles ; it is here that the cellular tissue abounds, and it becomes necessary to remove a great quantity of it. The *teres major* is easily recognized by its broad tendon, which passes to the humerus ; the *teres minor* is more difficult to discover, it is concealed by the *infra-spinatus*, *sub-scapularis*, and *teres major*. The track of the aponeuroses separating these different muscles, will aid us in recognising them. The long portion of the *triceps brachialis* passes upwards between the *teres major* and *minor*, and leaves a space between them ; but towards the inferior portion of the *omoplate*, these two latter muscles are so united together, as also to the *sub-scapularis*, that it is impossible to separate them.

When the *teres major* and *minor* muscles are prepared, we may, after having taken a good view of the manner in which the tendons of the *latissimus dorsi*, *pectoralis* and *teres major*, pass and become inserted into the humerus ; we may, I say, separate the superior extremity from the trunk, and break or saw the species of arch, below which pass the tendons of the *supra* and *infra-spinatus* muscles. We must isolate them very carefully from the cellular tissue, which surrounds them, and avail ourselves of this occasion to observe the relations of these tendons, as likewise that of the *teres minor*, with the capsule of the *scapulo-humeral* articulation.

Biceps.—This muscle lies under the skin on the internal part of the arm, and the precautions it demands relate

only to the disposition of the tendons at its two extremities. The superior has two, one of which travels the whole length of the bicipital groove; arrived at the articulation, it pierces the capsule, and is placed from right to left, on the circumference of the glenoid cavity. Follow, therefore, the distribution just indicated; open the capsule, in order to observe the direction of the tendon, and this circumstance must not be forgotten, in looking at its situation and relations. The other division of the superior extremity of the biceps, called its short portion, is inserted into the coracoid apophysis of the scapula; it is confounded in a great part of its length with the coraco-brachialis. It is unnecessary to attempt their separation. The inferior extremity of the same muscle, on the contrary, has but one tendon which is concealed below the fold of the arm, under several other muscles. We should be content with removing the cellular tissue, which covers it in part, and defer examining its insertion into the radius, until dissecting the muscles of fore-arm.

Coraco-brachialis, and brachialis anterior.—The first, placed on the internal side of the biceps, is applied in all its length to the humerus. Detach the skin on the inside of the arm; remove the vessels and cellular tissue, which cover a portion of the coraco-brachialis at its superior part. We should not attempt to separate its superior extremity from the short portion of the biceps, for they are naturally united; but the latter should be cut across at its middle, and its portions reversed, in order to see the brachialis anterior, which the inferior portion of the biceps partly covers. It is not necessary to carry the dissection of the inferior extremity of the brachialis farther than the environs of the articulation.

Triceps brachialis.—This muscle occupies all the posterior part of the humerus, and by merely removing the skin, we will be enabled to see it in its whole extent : we must be particular to separate the three portions, which terminate it superiorly, the longest of which is attached to the scapula, between the two teres muscles. It is scarcely necessary to observe to the student the propriety of always reserving a portion of the integuments, in order to cover the muscles which have been dissected, that they may be properly preserved.

Description.

DELTOID.

(*Sus-acromio-humèral.*)

Situation and figure.—Flat, triangular, situated at the superior part of the arm and shoulder.

Extent.—From the humerus to the clavicle and scapula.

Division.—External surface, covered by the integuments ; internal surface, which covers the superior third of the humerus, scapulo-humeral articulation, supra and infra-spinatus, coraco-brachialis, a portion of the triceps and the tendon of the pectoralis major. The posterior border is free ; the anterior corresponds to the pectoralis major ; the basilic vein alone separates them ; the superior, or base, is attached to the external third of the clavicle and all the spine of the omoplate ; the summit is inserted into the superior third of the humerus.

Direction.—The anterior fibres are oblique from above downwards, and from within outwards ; the posterior from without inwards, and the middle are vertical.

Structure and uses.—Tendinous inferiorly, aponeurotic at its superior attachments, and fleshy in the interval, it

elevates the arm, and, in this situation, it may carry it forwards or backwards, according to the fibres that act.

SUPRA-SPINATUS.

(*Petit-sus-scapulo-trochiterian.*)

Situation and figure.—Elongated, nearly round, situated in the fossa supra-spinata.

Extent.—From the base of the omoplate to the humerus.

Division.—Posterior portion, covered by the trapezius and deltoid; anterior portion, entirely lodged in the fossa supra-spinata. The posterior extremity is attached to the superior third of the base of the omoplate; the anterior, to the great tuberosity of the humerus.

Direction.—Horizontal.

Structure and uses.—Tendino-aponeurotic at its attachment to the humerus, fleshy in the rest of its extent, it elevates the head of the humerus, and causes it to execute a movement of bascule, by which it draws it backwards.

INFRA-SPINATUS.

(*Grand sus-scapulo-trochiterien.*)

Situation and figure.—Flat, triangular, situated in the fossa infra-spinata.

Extent.—From the fossa infra-spinata to the humerus.

Division.—Posterior surface, covered by the deltoid, trapezius, a small portion of the latissimus dorsi and integuments; anterior surface, which occupies the entire fossa infra-spinata. The superior border passes in a direction parallel to the spine of the omoplate; the anterior corresponds to the teres major and minor; the posterior, or base, is fixed to the two inferior thirds of the base

of the omoplate; the summit is attached to the great tuberosity of the humerus.

Direction.—Slightly oblique from below upwards, and from behind forwards.

Structure and uses.—Tendinous at its summit, fleshy in the rest of its extent, it draws the humerus backwards, and causes it to turn on its axis.

SUB-SCAPULARIS.

(*Sous-scapulo-trochinien.*)

Situation and figure.—Flat, triangular, situated in the fossa sub-scapularis.

Extent.—From the fossa sub-scapularis to the humerus.

Division.—Posterior surface, lodged in the fossa sub-scapularis; anterior surface, which corresponds to the serratus magnus, axillary vessels, five or six first ribs, and corresponding intercostal muscles. The anterior border is attached to the internal lip of the rib of the omoplate; the posterior, confounded, with the serratus magnus, is attached to the base of the same bone; the superior goes in the direction of its superior border; a large extremity results from the superior and anterior borders, and is attached to the small tuberosity of the humerus.

Direction.—Oblique from below upwards, and from behind forwards.

Structure and uses.—A broad tendon is observed at its attachment to the humerus; and aponeuroses are remarked in the proper substance of the muscle, which is fleshy in the rest of its extent; it turns the humerus on its axis, and fixes it on the trunk.

TERES MAJOR.

Scalpulo-humèral.

Situation and figure.—Elongated, flat, situated at the inferior part of the shoulder.

Extent.—From the omoplate to the humerus.

Division.—Posterior surface, covered by the latissimus dorsi and integuments ; anterior surface, which covers the sub-scapularis, biceps, coraco-brachialis and brachial vessels. The inferior border corresponds to the teres minor below, and triceps above ; the superior, free under the integuments, forms, with the latissimus dorsi, the posterior fold of the axilla. The inferior extremity is fixed to the inferior angle of the omoplate ; the superior, to the posterior border of the bicipital groove of the humerus.

Direction.—Oblique from below upwards, and from within outwards.

Structure and uses.—A broad tendon, united to that of the latissimus dorsi, is observed at its superior extremity ; in the rest of its extent, it is fleshy ; it draws the arm inwards and backwards and causes it to turn on its axis.

TERES MINOR.

(Le plus petit sus-scapulo-trochitèrien.)

Situation and figure.—Elongated, slightly rounded, situated at the inferior part of the shoulder.

Extent.—From the rib, or anterior border of the omoplate, to the humerus.

Division.—Posterior side, covered by the deltoid and integuments ; anterior side, which is fixed to the rib of the omoplate ; superior side, which corresponds to the infraspinatus ; inferior side, to the teres major and triceps. The inferior extremity is fixed to the rib of the omoplate ; the superior, to the great tuberosity of the humerus.

Direction.—Oblique from below upwards, and from within outwards.

Structure and uses.—A tendon is remarked at its attachment to the humerus ; it is fleshy in the rest of its extent ; it separates the arm from the trunk and slightly raises it.

BICEPS.

(*Scapulo-radial.*)

Situation and figure.—Elongated, rounded, situated on the anterior part of the arm, and divided superiorly into two portions.

Extent.—From the omoplate to the radius.

Division.—Anterior portion, covered above by the deltoid and pectoralis major, and by the integuments in the rest of its extent ; posterior portion, applied to the humerus, coraco-brachialis and brachialis anterior. The inferior extremity is fixed to the bicipital tuberosity of the radius ; the superior, double, is attached, on the one hand, to the coracoid apophysis, and on the other, is lost on the contour of the glenoid cavity of the omoplate.

Direction.—Vertical.

Structure and uses.—Tendinous at its extremities, fleshy in the rest of its extent, it flexes the arm on the forearm, and this on the arm.

CORACO-BRACHIALIS.

(*Idem.*)

Situation and figure.—Elongated, narrow, situated on the internal portion of the arm.

Extent.—From the humerus to the omoplate.

Division.—Internal surface, covered by the biceps, pectoralis major and integuments ; external surface, appli-

ed to the humerus. The superior extremity is fixed to the coracoid apophysis of the omoplate; the inferior, to the middle of the internal portion of the humerus.

Direction.—Vertical.

Structure and uses.—Tendinous superiorly, aponeurotic inferiorly, and fleshy in the interval, it approximates the arm to the trunk.

BRACHIALIS ANTERIOR.

(*Humèro-cubital.*)

Situation and figure.—Elongated, flat, situated on the anterior and inferior portion of the arm.

Extent.—From the humerus to the cubitus.

Division.—Anterior surface, covered by the biceps; posterior surface, applied to the humerus and the articulation of the arm with the fore-arm. The superior extremity is fixed below the insertion of the deltoid to the humerus; the inferior, to the coronoid apophysis of the cubitus.

Direction.—Vertical.

Structure and uses.—Tendinous inferiorly, fleshy in the rest of its extent, it flexes the fore-arm on the arm, and this on the fore-arm.

TRICEPS-BRACHIALIS.

(*Scapulo-humèro-olécranien.*)

Situation and figure.—Thick, elongated, situated on the posterior part of the arm, and divided superiorly into three portions.

Extent.—From the humerus and omoplate to the cubitus.

Division.—Posterior surface, covered by the deltoid and integuments; anterior surface, applied to the posterior surface of the humerus. The inferior extremity is attach-

ed to the olecranon apophysis; the superior, triple, is attached, the long portion to the rib of the omoplate, and the two others to the humerus.

Direction.—Vertical.

Structure and uses.—A broad tendon is observed at its inferior extremity, and aponeuroses in the thickness of the muscle, which is fleshy in the rest of its extent. It extends the fore-arm on the arm, and this on the fore-arm, and in addition, it draws the omoplate to the humerus.

The muscles of the extremities enjoying, as it were, movements of flexion and extension only, and their mechanism being easily determined, I have not thought it necessary to enter into any general considerations of their uses, as I have done for the muscles of the trunk, head, face and neck.

SIXTEENTH REGION.

RADIO-CUBITAL.

Muscles of the fore-arm.

The muscles of the fore-arm are divided into those of the posterior and those of the anterior region. The posterior region forms two layers, and the anterior four. The muscles of the posterior region are :—1st, The supinator longus, two radials, extensor communis digitorum, extensor proprius minimi digiti, cubitalis posterior, and anconeus,—2d, The supinator brevis, abductor pollicis longus, extensor pollicis longus and brevis, and extensor proprius indicis manus. The muscles of the anterior region are :—the pronator teres, radialis anterior, palmavis brevis, and cubitalis anterior ;—2d, The sublimis ;—3d, The profundus and flexor pollicis longus ;—4th, Pronator quadratus.

Anatomical Preparation.

The preparation of the muscles of the fore-arm requires such little care, that the student the least acquainted with anatomical dissections may accomplish it. It will suffice to remove carefully the integuments, which cover them, commencing at the posterior part. An aponeurosis, tolerably thick, is spread over all these muscles, principally those of the posterior part; we should leave it in place in the dissection of the integuments, and it should not be removed until after having properly studied it. But this aponeurosis being strongly attached to the muscles at their superior part, we cannot detach it, without removing at the same time the proper fibres of the muscles, which should not be done. The muscles themselves are very intimately united to each other towards their common insertion into the external tuberosity of the humerus; aponeurotic partitions indicate sufficiently well their lines of demarcation; but it is impossible to separate them as far as their superior attachment. Inferiorly, on the contrary, they are separated by considerable intervals, and nothing is easier than to recognize them. I shall merely make a few rapid reflections on the preparation of each of them in particular, in the order of their respective study.

POSTERIOR PART.

1st, *Supinator longus*—The first and one of the most superficial muscles of this region, is the supinator longus. The integuments of the fore-arm having been divided posteriorly in their whole length, from the elbow nearly to the fingers, the two flaps must be separated with caution; outwards and somewhat in front is found the supinator longus, which is easily recognised by its attachments; it

must be carefully isolated from the two radial muscles, and its inferior attachment accurately exposed.

The two radial muscles.—These are placed on the side and externally to the preceding, from which they can only be separated at their inferior portion. The two radial muscles themselves are sometimes so united to each other, that we have at first some difficulty in distinguishing them; but their point of lower insertion taking place at different parts, it is here that we should endeavor to isolate them from each other, as far as two or three fingers' breadth from their superior attachment.

Extensor communis digitorum.—This muscle, which is confounded above with the preceding, as likewise with those which we are soon to describe, is free and distinct only towards the middle of the fore-arm; we must not mistake for separate muscles the two or three portions, which terminate it inferiorly. Its passage under the annular ligament, which must be preserved, will cause it to be readily recognised; it is lodged there with the tendon of the extensor proprius minimi digiti; but the direction and course of this last cannot lead us into error. The tendons of the extensor communis go on and are attached to the third phalanges; it is, therefore, necessary to pursue the dissection of the integuments thus far; this may be accomplished by carrying the scalpel longitudinally over the whole length of the four fingers, which follow the thumb, this last having its proper muscles. We should not remove the species of aponeurotic sheath, which surrounds and retains the tendons in place, after finishing the preparation of the muscles of the fore-arm; we may, however, expose one of them, in order to observe the disposition and manner in which all the other muscles are attached to the phalanges.

Extensor proprius minimi digiti.—This small muscle is nearly always confounded with the preceding in its whole length, at least as far as its passage under the annular ligament; but beyond this, and on the dorsum of the hand, it may be easily distinguished, and its separation continued to the little finger. When difficulty is experienced in isolating it from the extensor communis, above the annular ligament, we should abandon the dissection of it, and be content with studying it thus confounded with the preceding.

Posterior cubital.—Placed immediately below the integuments and on the inside of the fore-arm, it will suffice to have removed this last to see the cubital in its whole extent. We should leave in place the aponeurosis, which covers it superiorly, and not seek to divide its connexions with the preceding muscles and anconeus; its situation on the cubitus, and its insertion into the os pisiforme will cause it to be readily distinguished.

Anconeus.—Different from the preceding muscles, inasmuch as it is extremely short, the anconeus is observed at the most elevated part of the posterior portion of the fore-arm. We should study it in place, and not endeavor to remove it or detach it from the situation it occupies. The common aponeurosis which covers it, as also the cubital, conceals the lines of demarcation, which separate it from the neighboring parts; but this aponeurosis is easily removed; the anconeus is then perfectly exposed, and requires no other preparation.

2d, *Supinator brevis.*—Here commence the muscles of the second layer, which cannot be seen until after having removed those of the preceding; but it is not necessary to detach entirely these last; it will suffice, on the contrary, to cut them across, at their inferior third, and turn

the flaps above and below. If, by this simple process, we do not uncover entirely the muscles of the second layer, we may then detach the preceding as far as their superior part. The first which it is necessary to examine, and which is the most external, is the supinator brevis, which embraces almost the totality of the superior half of the radius. It is indispensable to pursue the separation of the supinator longus and the two radial muscles nearly to their insertion into the humerus. A thin aponeurosis covers the supinator brevis in a great part of its extent; it is unnecessary to remove it, for it forms an integral part of the muscle.

Abductor longus pollicis, extensor longus and brevis pollicis.—These three muscles, thin and elongated, are placed on the side and within the preceding, and are, as it were, united to each other. It is sometimes rather difficult to recognise them, when we have not taken the precaution of separating them at their inferior part. The abductor longus does not present the same difficulties; its tendon is larger, and does not descend as low as the two others, which are thin. It is true that the tendon of the abductor longus and extensor brevis pass together in the same groove, which furnishes a means of recognising this last, and of distinguishing it from the extensor longus.

Extensor proprius indicis manus.—This is the last of the second layer and situated farthest inwards. It demands the same precautions, in order to be isolated from the others; but its tendon which goes to the index finger, will be a sure guide by which it will be distinguished. It passes in the same groove with the extensor communis digitorum, with which it contracts adhesions, by means of loose cellular tissue, from which it may be readily detached. We should neither remove nor cut the different liga-

ments, which retain the tendons in their respective grooves; if we commit this error, the preparation of the muscles of the fore-arm will be nothing but confusion and disorder.

ANTERIOR PART.

The muscles on the anterior part of the fore-arm form four layers, the distribution of which must be preserved, when we wish to prepare them. As for the rest, this preparation is still easier than that of the preceding muscles, because those of the anterior part are less numerous, their mass in general is more considerable, and they are separated from each other in the totality of their extent. These muscles are:—1st, The pronator teres, radialis anterior, palmaris brevis, and cubitalis posterior;—2d, Flexor sublimis;—3d, Flexor profundus, flexor longus pollicis;—4th, Pronator quadratus.

1st, *Pronator teres*.—This muscle which is the first of those fixed in the internal tuberosity of the humerus is placed immediately under the integuments; at its superior part, it is united rather strongly to the radialis anterior; but outwardly it is free and only requires, in order to be exposed, to have the integuments and cellular tissue covering it removed. Between this muscle and the supinator longus there is observed, at their superior portion, a depression rather remarkable, in which is lost the inferior extremity of the biceps. The pronator longus is the shortest of the superficial muscles on the anterior part of the fore-arm, in the middle of which it terminates, going obliquely from the internal tuberosity of the humerus, to the middle and external portion of the radius.

Radialis anterior.—After removing carefully the integuments from the anterior part of the fore-arm, the radialis anterior, like the other muscles of this layer, will be perfectly exposed; we must be particular not to confound it

with the cubital of the same region ; its direction being more outwards, and its course along the radius will prevent this error.

Palmaris brevis.—This small muscle is sometimes wanting, and when it does exist, is very trifling ; it is placed between the anterior radial and cubital, and its tendon, which occupies nearly its whole length, will enable us to distinguish it without any difficulty. It is necessary to observe the manner in which this tendon forms inferiorly the palmar aponeurosis, and it should be kept in place until the examination of this last.

Cubitalis posterior.—This is the last and most internal of this layer ; placed along the cubitus, it is fixed below to the os-pisiforme, and only requires to be separated from a small quantity of fat, which covers it inferiorly.

After having studied the muscles of this superficial layer, we should cut them cross-wise at their middle, and turn the ends above and below, in order to examine the two flexors which are placed beneath, as also the long flexor of the thumb.

2d, *Flexor sublimis.*—The flaps of the muscles of the preceding layer being turned upwards and downwards, the sublimis will be found beneath. We must distinguish it from the profundus, which is placed on the side, but more internally, and the superior attachment of which is to the cubitus. We should detach the muscles of the first layer as far as their superior part, in order to observe the sublimis in its whole extent. We should likewise expose the inferior portion of this muscle ; it is formed of four tendons, which go to the four fingers following the thumb. For the purpose of tracing them, we are obliged to dissect all the integuments of the hand, and examine, before removing them, the palmar aponeurosis, which is composed in part

of the tendon of the palmaris brevis; but we should not disturb the anterior annular ligament of the carpus, beneath which pass the tendons of the sublimis, as also those of the profundus. We may defer the ulterior preparation of these tendons until engaged in the dissection of the profundus, to which we shall now pass.

3d, *Flexor profundus*.—In order to prepare this muscle, it is not necessary to detach the preceding, but merely separate it, without cutting it, for the relations of both are very numerous; we must be particular to observe what appertains to one and the other. Each of them soon divide into two, and sometimes into three portions; but after passing under the annular ligament, their tendons are isolated and distinct. We must remove the small quantity of fat and cellular tissue found between the two muscles and the different parts, which form them; we may then even cut away all the muscles of the first layer, as they are no longer of indispensable necessity for the study of the last. Beyond the annular ligament, the tendons are placed above each other, and continue in this way until they nearly reach the second phalanges, where those of the sublimis, which were until then placed above, pass below, traversing a species of groove, presented to them by the tendons of the profundus. It will suffice to follow, with some little attention, the course of the tendons of the two muscles, in order to acquire a perfect knowledge of the manner in which they are respectively distributed.

Flexor pollicis longus.—This muscle lies along the radius. It will be necessary to raise the sublimis in order to see it, and this is the only preparation it exacts, until its passage under the annular ligament, which it passes in

company with the sublimis and profundus. Here is found a soft and loose substance, which unites feebly these different parts; it must be removed, and we should pursue the tendon of the flexor pollicis longus, which is concealed in the thickness of the short flexor, in order to arrive at the last phalanx of the thumb, to the internal part of which it is fixed.

4th, *Pronator quadratus*.—We may either leave in place or remove the preceding muscles, in order to observe the pronator quadratus, which is placed beneath, at the inferior portion of the two bones of the fore-arm. This is the only preparation required by this small muscle, and its examination as well as its dissection are easy.

Description.

SUPINATOR LONGUS.

(*Humero-sus-radial.*)

Situation and figure.—Elongated, situated on the external part of the fore-arm.

Extent.—From the humerus to the radius.

Division.—External portion, covered by the integuments; internal portion, which covers the brachialis anterior, sublimis, flexor pollicis longus, supinator brevis, and the first radialis externus. The superior extremity, more voluminous, is attached outwardly to the inferior fourth of the humerus; the inferior, more thin, is fixed to the anterior border of the radius, near its inferior extremity.

Direction.—Vertical.

Structure and uses.—Fleshy in its superior third, tendinous in its two inferior thirds, it produces the supination of the hand, and extends the fore-arm on the arm.

FIRST RADIALIS EXTERNUS.

(Humero-sus-métacarpien.)

Situation and figure.—Elongated, flat, situated on the external part of the fore-arm.

Extent.—From the humerus to the radius.

Division.—External portion, covered by the supinator longus, and below by the tendons of the abductor longus pollicis and of its short extensor; internal portion, placed on the articulation of the arm with the fore-arm and on the second radialis externus. The superior extremity, more thick, is attached to the most elevated part of the external tuberosity of the humerus; the inferior, more thin, to the posterior and superior part of the second metacarpal bone.

Direction.—Vertical.

Structure and uses.—Fleshy in its superior half, tendinous in its inferior, it produces the supination of the hand; it may also extend the fore-arm on the arm.

SECOND RADIALIS EXTERNUS.

(Epicondilo-sus-métacarpien.)

Situation and figure.—Elongated, flat, situated on the external and posterior part of the fore-arm.

Extent.—From the humerus to the radius.

Division.—External surface, covered above by the supinator longus, in the rest of its extent by the first radial muscle and the tendons of the abductor longus pollicis and of its short extensor; internal surface, placed on the supinator brevis and radius. The superior extremity, more voluminous, is attached to the external tuberosity of the humerus, below that of the first radialis externus; the inferior, more thin, to the posterior and superior part of the third metacarpal bone.

Direction.—Oblique from above downwards, and from without inwards.

Structure and uses.—Tendinous at its two extremities, fleshy in the interval, it draws the hand outwards, and produces supination; it may also extend the fore-arm on the arm.

EXTENSOR COMMUNIS DIGITORUM.

(*Epicondilo-sus-phalangettien commun.*)

Situation and figure.—Elongated, rounded, divided into four portions inferiorly; situated on the posterior part of the fore-arm.

Extent.—From the humerus, to the four fingers which follow the thumb.

Division.—Posterior portion, covered by the anti-brachial aponeurosis and integuments; anterior portion, applied to the supinator brevis, abductor longus, short and long extensors of the thumb, the articulation of the hand and posterior part of the four fingers, which follow the thumb. The superior extremity is attached to the external tuberosity of the humerus, between the radial muscles and extensor of the little finger; the inferior, divided into four tendons, is attached to the posterior part of the third phalanges.

Direction.—Vertical.

Structure and uses.—Aponeurotic at its superior extremity, it is terminated below by four tendons, which ascend very high in the fleshy fibres; it extends the third phalanges on the second, these on the first, and the whole of the hand on the fore-arm.

EXTENSOR MINIMI DIGITI.

(*Epicondilo-sus-phalange-tien du petit doigt.*)

Situation and figure.—Thin, elongated, situated on the posterior part of the fore-arm.

Extent.—From the humerus to the little finger.

Division.—Posterior portion, covered by the anti-brachial aponeurosis and integuments; anterior surface, placed on the supinator brevis, abductor longus, short and long extensors of the thumb and extensor indicis manus. The superior extremity is fixed to the external tuberosity of the humerus, between the extensor communis and cubitalis; the inferior is attached to the two last phalanges of the little finger.

Direction.—Vertical.

Structure and uses.—Aponeurotic at its superior extremity, it is terminated below by a long tendon, and the fleshy fibres are found in the interval; it extends the last phalanges of the little finger on the first.

CUBITALIS POSTERIOR.

(*Cubito-sus-metacarpien.*)

Situation and figure.—Elongated, situated on the posterior part of the fore-arm.

Extent.—From the humerus to the fifth metacarpal bone.

Division.—Posterior portion, covered by the integuments and anti-brachial aponeurosis; anterior portion, placed above on all the muscles of the second layer, and in the rest of its extent on the cubitus. The superior extremity is attached to the external tuberosity of the humerus, between the extensor proprius minimi digiti and anconeus; the inferior, to the posterior and superior part of the fifth metacarpal bone.

Direction.—Nearly vertical.

Structure and uses.—Aponeurotic superiorly, tendinous at its inferior extremity, and fleshy in the interval; it has the same uses as the radialis posterior.

ANCONEUS.

(*Epicondilo-cubital.*)

Situation and figure.—Flat, triangular, situated on the posterior and superior part of the fore-arm.

Extent.—From the humerus to the cubitus.

Division.—Posterior surface, covered by the integuments and ante-brachial aponeurosis; anterior surface, placed on the articulation of the arm with the fore-arm, and on a portion of the cubitus. Its internal border is free, the external is confounded with the cubitalis. The base is attached to the external tuberosity of the humerus; the summit, or inferior extremity, is fixed to the superior fourth of the cubitus.

Direction.—Oblique from above downwards, and from without inwards.

Structure and uses.—Tendino-aponeurotic at its extremities, fleshy in the interval, it contributes to extend the fore-arm on the arm, and reciprocally the arm on the fore-arm.

SUPINATOR BREVIS.

(*Epicondilo-radial.*)

Situation and figure.—Elongated, flat, situated on the posterior and superior portion of the fore-arm.

Extent.—From the humerus and cubitus to the radius.

Division.—External surface, covered by all the muscles of the superficial layer on the posterior part of the fore-arm; internal surface, applied to the cubitus and

radius. The superior extremity, called its base, is attached to the external tuberosity of the humerus, below the preceding, and also to a portion of the posterior surface of the cubitus; the inferior is fixed to the middle portion of the external surface of the radius, below the pronator teres.

Direction.—Oblique from above downwards, from without inwards, and from behind forwards.

Structure and uses.—A broad tendon, reaching nearly as far as its inferior extremity, originates from its superior attachment; fleshy fibres occupy the rest of the muscle; it produces the supination of the fore-arm.

ABDUCTOR LONGUS POLLICIS.

(*Cubito-sus-métacarpien du pouce.*)

Situation and figure.—Elongated, flat, situated on the posterior and external portion of the fore-arm.

Extent.—From the cubitus and radius to the metacarpal bone, which sustains the thumb.

Division.—Posterior surface covered by most of the muscles of the superficial layer; anterior surface, applied to a portion of the cubitus, interosseous ligament and radius. The superior extremity is fixed to the superior part of the posterior surface of the cubitus; the inferior, to the superior and posterior part of the first metacarpal bone.

Direction.—Oblique from above downwards, and from within outwards.

Structure and uses.—A long tendon is observed at its inferior portion: it is fleshy in the rest of its extent; it draws the thumb outwards and backwards.

EXTENSOR POLLICIS BREVIS.

(*Cubito-sus-phalangien du pouce.*)

Situation and figure.—Elongated, narrow, situated on the posterior and external portion of the fore-arm.

Extent.—From the cubitus and radius to the first phalanx of the thumb.

Division.—Posterior surface, covered by most of the muscles of the superficial layer; anterior surface, covering a portion of the cubitus, interosseous ligament, radius, and the first metacarpal bone. The superior extremity is fixed to the superior and posterior part of the cubitus beneath the preceding; the inferior is attached to the superior and posterior part of the first phalanx of the thumb.

Direction.—Oblique from above downwards, and from within outwards.

Structure and uses.—A long and thin tendon terminates it inferiorly; it is fleshy in the rest of its extent; it extends the first phalanx of the thumb on the metacarpal bone.

EXTENSOR LONGUS POLLICIS.

(*Cubito-sus-phalangettien du pouce.*)

Situation and figure.—Elongated, flat, situated on the posterior and external portion of the fore-arm.

Extent.—From the cubitus to the last phalanx of the thumb.

Division.—Posterior surface, covered by most of the muscles of the superficial layer; anterior surface, applied to the cubitus, radius, first metacarpal bone, and the first phalanx of the thumb. The superior extremity is attached to the superior third of the cubitus, lower down than the preceding; the inferior, to the posterior part of the last phalanx of the thumb.

Direction.—Oblique from above downwards, and from within outwards.

Structure and uses.—A long tendon terminates it inferiorly; it is fleshy in the rest of its extent; it extends the last phalanx of the thumb on the first.

EXTENSOR PROPRIUS INDICIS MANUS.

(*Cubito-sus-phalangettien de l'index.*)

Situation and figure.—Thin, elongated, situated on the posterior portion of the fore-arm.

Extent.—From the cubitus to the two last phalanges of the index finger.

Division.—Posterior surface, covered by the extensor communis digitorum and the extensor of the little finger; anterior surface, which covers a portion of the cubitus, inter-osseus ligament, radius and the second metacarpal bone. The superior extremity is fixed to the middle part of the posterior surface of the cubitus; the inferior, tendinous, passes in a groove common to the extensor communis digitorum, and is fixed to the posterior part of the two last phalanges of the index finger.

Direction.—Oblique from above downwards, and from within outwards.

Structure and uses.—It is terminated inferiorly by a long tendon, and it is fleshy in the rest of its extent. It extends the last phalanges of the index finger on the first, and contributes to the extension of the hand.

PRONATOR TERES.

(*Epitroclo-radial.*)

Situation and figure.—Elongated, rounded, and situated on the anterior part of the fore-arm.

Extent.—From the humerus to the radius.

Division.—Anterior portion, covered by the integuments, anti-brachial aponeurosis, supinator longus and the two radial muscles; posterior surface, which covers the brachialis anterior and sublimis. Its internal side is united in all its extent to the brachialis anterior; its external side corresponds to the supinator longus and two radial muscles. Its superior extremity is fixed to the internal tuberosity of the humerus, and to the neighboring part of the coronoid apophysis of the cubitus; the inferior extremity, to the middle portion of the external surface of the radius.

Direction.—Oblique from above downwards, and from within outwards.

Structure and uses.—Tendinous at its extremities, fleshy in the rest of its extent, it produces the pronation of the fore-arm and hand.

RADIALIS ANTERIOR.

(*Epitroclo-métacarpien.*)

Situation and figure.—Elongated, situated on the anterior part of the fore-arm.

Extent.—From the humerus to the second metacarpal bone.

Division.—Anterior surface, covered in part by the supinator longus, anti-brachial aponeurosis and integuments; posterior surface, applied to the sublimis and flexor longus pollicis. Its superior extremity is fixed to the internal tuberosity of the humerus, between the preceding and palmaris brevis; the inferior is attached to the anterior and superior part of the second metacarpal bone.

Direction.—Oblique from above downwards, and from within outwards.

Structure and uses.—Tendinous at its extremities, fleshy in the interval, it flexes the hand on the fore-arm.

PALMARIS BREVIS.

(*Epitroclo-palmaire.*)

Situation and figure.—Thin, narrow, elongated; situated on the anterior part of the fore-arm.

Extent.—From the humerus to the palmar aponeurosis.

Division.—Anterior surface, covered by the aponeurosis of the fore-arm and integuments; posterior surface, placed on the sublimis. The superior extremity, situated between the radialis anterior and cubitalis internus, is fixed to the internal tuberosity of the humerus. The inferior is lost in the palmar aponeurosis.

Direction.—Vertical.

Structure and uses.—It is terminated inferiorly by a long and small tendon, which in great part forms it; it presents a small fleshy portion at its superior part; it extends the palmar aponeurosis.

CUBITALIS ANTERIOR.

(*Cubito-carpien.*)

Situation and figure.—Elongated; situated on the anterior and internal portion of the fore-arm.

Extent.—From the humerus to the os-pisiforme.

Division.—Anterior surface, covered by the integuments and ante-brachial aponeurosis; posterior surface which covers the profundus and pronator quadratus. The superior extremity is fixed within to the internal tuberosity of the humerus; the inferior to the os-pisiforme, which it embraces in its whole extent.

Direction.—Vertical.

Structure and uses.—Tendinous at its two extremities, fleshy in the interval, it flexes the hand.

SUBLIMIS.

(*Epitroclo-phalangien commun.*)

Situation and figure.—Elongated, thick, situated on the anterior portion of the fore-arm and hand; divided into four portions inferiorly.

Extent.—From the humerus to the four fingers, which follow the thumb.

Division.—Anterior surface, covered by the pronator teres, radialis anterior, and palmaris brevis; posterior surface, placed on the profundus and flexor longus pollicis. The superior extremity is fixed to the internal tuberosity of the humerus, and to the neighboring part of the coronoid apophysis of the cubitus; the inferior, divided into four portions, passes under the anterior annular ligament of the carpus, and thence attaches itself to the anterior portion of the second phalanges of the four last fingers, by as many tendons.

Direction.—Vertical.

Structure and uses.—Its superior extremity is slightly tendinous; the inferior, on the contrary, presents four tendons, which ascend high up in the fleshy fibres; it flexes the second phalanges on the first, and bends the whole of the hand.

PROFUNDUS.

Cubito-phalangettien commun.

Situation and figure.—Elongated, very thick, situated on the anterior part of the fore-arm and hand; divided into four portions inferiorly.

Extent.—From the cubitus to the third phalanges of the four last fingers.

Division.—Anterior surface, covered by the sublimis and cubitalis anterior; posterior surface, placed on the anterior portion of the cubitus and on the pronator quadratus. The superior extremity is attached below the coronoid apophysis of the cubitus; the inferior, divided into four tendons, passes with the sublimis under the anterior annular ligament of the carpus, and thence attaches itself to the anterior part of the third phalanges of the four last fingers.

Direction.—Vertical.

Structure and uses.—Aponeurotic superiorly, it presents at its inferior extremity four tendons, which ascend very high up in the fleshy fibres; it flexes the third phalanges on the second, these on the first, and produces the complete flexion of the hand.

FLEXOR LONGUS POLLICIS.

(*Radio-phalangezien du pouce.*)

Situation and figure.—Elongated, flat, situated on the anterior and external portion of the fore-arm.

Extent.—From the radius to the last phalanx of the thumb.

Division.—Anterior surface, covered by the sublimis and radialis anterior; posterior surface, applied to the three inferior fourths of the radius, the articulation of the hand and flexor pollicis brevis. The superior extremity is attached to the upper fourth of the anterior surface of the radius; the inferior, to the anterior surface of the last phalanx of the thumb.

Direction.—Oblique from above downwards, and from within outwards.

Structure and uses.—It is terminated inferiorly by a long tendon, and is fleshy in the rest of its extent. It flexes the last phalanx of the thumb on the first.

PRONATOR QUADRATUS.

(*Cubito radial.*)

Situation and figure.—Flat, quadrilateral, situated on the anterior and inferior portion of the fore-arm.

Extent.—From the radius to the cubitus.

Division.—Anterior surface, covered by the profundus and flexor longus pollicis; posterior surface, placed on the inferior fourth of the radius and cubitus, and on the corresponding portion of the inter-osseous ligament. The superior and inferior borders do not present any thing remarkable. The external is attached to the inferior fourth of the external border of the radius; the internal, to the inferior fourth of the internal border of the cubitus.

Direction.—Transverse.

Structure and uses.—Aponeurotic at its attachments, fleshy in the interval, it effects the pronation of the hand.

SEVENTEENTH REGION.

(*Carpo-métacarpienne.*)

Muscles on the palmar and dorsal surfaces of the hand.

—The muscles of this region are divided into those of the palma and those of the dorsum of the hand. The muscles of the palm of the hand are distinguished into those of the thenar and those of the hypo-thenar eminence. The names of all these muscles, in the order of their preparation and study, are:—the abductor brevis pollicis, flexor brevis pollicis, opponens, and abductor pollicis, the flexor brevis minimi digiti, abductor and opponens minimi digiti; the cutaneous palmar is likewise included among them

The lumbricales are four in number, which are distinguished by the numerical terms of first, second, &c. commencing at the thumb. The inter-osseous muscles are seven in number, distinguished into palmar and dorsal. Of the former there are four, and of the latter three, counting from the thumb.

Anatomical Preparation.

The muscles of the hand are very numerous, but they are themselves of small size, and occupy but little space: approximated to each other and touching at all their different points, their preparation, in this respect, presents some difficulty; in fine, no matter what care may be taken in their dissection, we cannot succeed in isolating them, as we did with those of the arm and fore-arm. The skin of the hand, like that of the foot, adheres strongly to the subjacent parts, particularly in that portion which is called the palm of the hand, beneath which is found the palmar aponeurosis, of which we should have a correct idea before proceeding to the preparation of the muscles situated below it. If we employ, for the muscles of the hand, the same extremity on which we studied those of the fore-arm, the integuments of the palm and back of the hand having been removed as far as the fingers, in order to follow the tendinous termination of many of the muscles of the fore-arm, a portion of the labor attending the dissection of the muscles of the hand will already have been accomplished; but in proceeding in this way, we shall sacrifice the palmar-aponeurosis, and a very small muscle, called palmar cutaneous, which is seen by very few students, because they do not preserve untouched one of the sides of the part which they prepare, for the purpose of avoiding the inconvenience of which we have just spoken. For the dissection, therefore, of this series of muscles, we should employ a

hand, all the portions which are still enveloped by the integuments, in order that we may have a more exact idea of the preparation of each part. Things thus arranged, we should commence by dividing the integuments of the palm of the hand, as far as the palmar aponeurosis, which should not be removed until after having been examined, as also the palmar cutaneous, which, it is true, does not always exist, but which it is proper to preserve when it is present. It is placed on the hypothenar eminence, and its fibres, extremely pale, render its preparation rather difficult. But we should do every thing in order to see it, and not pass to the particular dissection of each of the muscles of the hand until after having studied it.

Abductor pollicis brevis.—This muscle is the most external of those of the thenar eminence; and although confounded with the others of the thumb, it may be distinguished without much difficulty, by searching cautiously for its line of separation, which is indicated by a slight trace of cellular tissue, placed between this muscle, the opponens, and flexor pollicis brevis.

Opponens pollicis.—It is not so easy to discover the separation of this muscle and of the flexor brevis, as it was for the preceding. There are certain subjects especially in which these two muscles are so united and confounded together, that it is impossible to isolate them from each other. The only mode of forming an idea of it, when this circumstance exists, is to take for the opponens nearly the fourth of the fleshy mass, placed below the abductor brevis, and to preserve the remainder for the flexor brevis.—In order to render the task still less embarrassing, we may cut the abductor brevis crosswise, and separate the ends. The opponens is ordinarily placed under the preceding, although the abductor brevis likewise covers a part of

the flexor brevis, which is the largest of all those of the thenar eminence.

Flexor brevis.—When nature herself indicates the separation of the opponens and flexor brevis, or when the scalpel has supplied this omission, it will be very easy to expose this last muscle; for the adductor, with which it has some relations, has a direction, and is placed in such a manner as to leave no doubt as to the place of their separation. The flexor brevis likewise possesses a character, which will aid us very materially in recognising it; it is the species of groove in its middle portion for the passage of the tendons of the flexor longus pollicis, a circumstance which we had occasion to advert to before when describing the preparation of this last muscle. The three small muscles of the thumb having their points of superior insertion partly in the anterior annular ligament of the carpus, we are obliged to preserve it entire, not only for the preceding muscles, but likewise for those of the little finger.

Adductor pollicis.—This is situated on the thenar eminence, but it advances somewhat in the palm of the hand; and in order to have a good view of it, we should remove the tendons of the great flexors of the fingers, and the cellular tissue, which covers it in part. The flexor pollicis brevis also conceals it to a certain extent. The integuments, between the thumb and index finger, adhere rather intimately to this muscle; it will not be sufficient to expose it in front, we must also dissect it posteriorly; in fine, in order to do it successfully, it will be necessary to carry the index finger firmly inward, and the thumb outward.—In attending to these simple directions, its preparation will be rendered easy.

Abductor minimi digiti.—This muscle is to the little finger what the abductor brevis is to the thumb. The one

separates the little finger from the other fingers, in carrying it inwards; the other produces the same effect on the thumb, carrying it outwards; both form the most prominent portion of that species of *mollet*, which is remarked in the inside of the hand, in the direction of these two fingers. The precepts given for the preparation of the abductor pollicis brevis apply, therefore, to that of the abductor minimi digiti.

After having recognized its separation, by the trace of cellular tissue, which always exists, we should cut it across at its middle portion, and pass to the preparation of the other muscles of the same finger.

Flexor brevis minimi digiti—opponens minimi digiti.—These muscles present, as regards their preparation, nearly the same difficulties as the corresponding muscles of the thumb, with this difference, however, that here the flexor brevis is situated nearly parallel to the abductor, and the opponens is placed behind these two muscles; this last, although attached superiorly to the same parts on the flexor brevis, does not descend so low down, for its inferior insertion is into the fifth metacarpal bone, whilst the two others go as far as the first phalanx of the little finger.

Lumbricales.—These small muscles are attached to the tendons of the profundus; they are placed in the palm of the hand, and their preparation consists in isolating the tendons of the muscle to which they are attached. We should observe that their inferior termination abandons this muscle, in order to fix itself to the posterior and external portion of the first phalanges of the four fingers, which follow the thumb.

Inter-ossei.—Nature has dissected these muscles; the scalpel of the anatomist adds nothing to their preparation, but it is necessary to free them from the objects, which ob-

scure them at first view. The integuments alone cover the dorsal inter-osseals; the palmar muscles are enveloped by the lumbricales and muscles of the thenar and hypothenar eminences. This operation being achieved, all the inter-osseal muscles remain perfectly isolated in the interval of the metacarpal bones, which they occupy in their whole extent. A small tendon, which terminates them inferiorly, fixes itself, according to the inter-osseal to which it appertains, sometimes to the internal side, sometimes to the external side of the first phalanges of the four last fingers.

Description.

ABDUCTOR POLLICIS BREVIS.

(*Carpo-sus-phalangien du pouce.*)

Situation and figure.—Elongated, slightly rounded, and situated on the thenar eminence.

Extent.—From the anterior ligament of the carpus to the first bone of the metacarpus.

Division.—Anterior surface, covered by the integuments; posterior surface, applied to the opponens pollicis, and a small portion of the flexor brevis. The superior extremity is attached to the external portion of the anterior annular ligament of the carpus, and to the os-scaphoides; the inferior, to the external side of the superior extremity of the first phalanx of the thumb.

Direction.—Oblique from above downwards, and from within outwards.

Structure and uses.—Aponeurotico-tendinous at its extremities, and fleshy in the interval, it draws the thumb outwards and forwards.

OPPONENS POLLICIS.

(*Carpo metacarpien du pouce.*)

Situation and figure.—Elongated, rounded, situated on the thenar eminence.

Extent.—From the annular ligament of the carpus, to the first metacarpal bone.

Division.—Anterior surface, covered by the abductor brevis pollicis and integuments ; posterior surface, applied to the whole anterior surface of the first metacarpal bone, and to the flexor brevis, to which the opponens is sometimes intimately united. The superior extremity is fixed to the anterior part of the annular ligament, and to the os-trapezium ; the inferior, to the external part of the inferior extremity of the first metacarpal bone.

Direction:—Nearly vertical.

Structure and uses.—Aponeurotic at its attachments, fleshy in the interval, it draws the first metacarpal bone outwards and forwards, and, by a rotatory movement, opposes the thumb to the other fingers.

FLEXOR BREVIS POLLICIS.

(*Carpo-phalangien du pouce.*)

Situation and figure.—Elongated, thick, flat ; situated on the thenar eminence.

Extent.—From the annular ligament to the first phalanx of the thumb, more inwards than the preceding muscles.

Division.—Anterior surface, covered from without inwards by the abductor brevis pollicis, the tendon of the flexor longus pollicis, the tendons of the profundus, and by the two first lumbricales ; posterior surface, applied to the first inter-osseals. Its external side corresponds to the abductor pollicis, and the internal to the adductor pollicis. The superior extremity, divided into two portions, is fixed on the one hand, to the anterior part of the annular ligament and os-trapesium, and, on the other, to the os magnum and third metacarpal bone ; the inferior extremity,

likewise divided into two portions, is attached, on the one hand, to the external part of the superior extremity of the first phalanx of the thumb, and, on the other, to the internal part of the same phalanx.

Direction.—Oblique from above downwards, and from within outwards.

Structure and uses.—Tendinous at its extremities, and fleshy in the interval. Its uses are sufficiently indicated by its name.

ADDUCTOR POLLICIS.

(*Metacarpo-phalangien du pouce.*)

Situation and figure.—Flat, triangular, situated in the palm of the hand.

Extent.—From the third metacarpal bone, to the first phalanx of the thumb.

Division.—Anterior surface, covered by the integuments, the tendons of the profundus and by the two first lumbricales; posterior surface, which corresponds to the first dorsal and palmar inter-osseals. The external border corresponds to the flexor brevis; the inferior is free under the integuments; the internal, or base, is attached to the anterior surface of the third metacarpal bone; the summit, resulting from the inferior and external borders, is attached to the internal portion of the superior extremity of the first phalanx of the thumb.

Direction.—Transverse.

Structure and uses.—Slightly tendinous at its attachments, fleshy in the rest of its extent, it approximates the thumb to the fingers.

PALMARIS CUTANEUS.

(*Comprised in the carpo phalangien du petit doigt.*)

Situation and figure.—Very thin, flat; situated on the superior and internal part of the hand,

Extent.—From the annular ligament of the carpus to the neighboring part of the palmar aponeurosis.

Division.—Anterior surface, covered by the integuments; posterior surface, applied to the flexor brevis and abductor minimi digiti. It is fixed, on the one hand, to the annular ligament of the carpus, and, on the other, to the neighboring part of the palmar aponeurosis and to the integuments of the hand.

Direction.—Transverse.

Structure and uses.—Nearly fleshy in its whole extent, and very pale, it corrugates the skin on the palm of the hand, the concavity of which it augments.

ABDUCTOR MINIMI DIGITI.

(*Comprised in the carpo-phalangiën du petit doigt.*)

Situation and figure.—Elongated, somewhat flat, situated on the hypothenar eminence.

Extent.—From the os-pisiforme to the first phalanx of the little finger.

Division.—Anterior surface, covered by the cutaneous palmaris and integuments; posterior surface applied to the opponens of the same finger. The superior extremity is attached to the os-pisiforme; the inferior, to the internal portion of the superior extremity of the first phalanx of the little finger.

Direction.—Vertical.

Structure and uses.—Aponeurotic at its attachments, fleshy in the rest of its extent, it draws the little finger inwards.

FLEXOR BREVIS MINIMI DIGITI.

(*Comprised in the carpo phalangiën du petit doigt.*)

Situation and figure.—Elongated, thin, and narrow; situated on the hypothenar eminence.

Extent.—From the annular ligament of the carpus, to the first phalanx of the little finger.

Division.—Anterior surface, covered by the palmaris cutaneus and integuments; posterior surface, applied to the opponens of the same finger. The superior extremity is fixed to the annular ligament of the carpus, and to the neighboring portion of the os-unciforme; the inferior, to the internal portion of the superior extremity of the first phalanx of the little finger.

Direction.—Vertical.

Structure and uses.—Slightly tendinous at its extremities, fleshy in the rest of its extent, it flexes the little finger.

OPPONENS MINIMI DIGITI.

(*Carpo métacarpien du petit doigt.*)

Situation and figure.—Elongated, situated on the hypothenar eminence.

Extent.—From the annular ligament, to the fifth metacarpal bone.

Division.—Anterior surface, covered by the two preceding muscles; posterior surface, applied to the fifth metacarpal bone. The superior extremity is fixed to the annular ligament of the carpus, and to the neighboring portion of the os-unciforme; the inferior, to the internal and inferior portion of the fifth metacarpal bone.

Direction.—Vertical.

Structure and uses.—Slightly tendinous at its attachments, fleshy in the interval, it draws the little finger forwards and outwards, and contributes to form the hollow of the hand, vulgarly called *gobelet of Diogenes*.

LUMBRICALES.

(Palmi-phalangiens.)

Situation and figure.—Elongated, slightly flat; situated in the palm of the hand, along the tendons of the profundus.

Extent.—From the tendons of the profundus, to the phalanges of the four last fingers.

Division.—Anterior portion, covered by the tendons of the sublimis; posterior portion, corresponding to the inter-osseous muscles. The superior extremity is fixed to the tendons of the profundus; the inferior, to the posterior and external part of the first phalanges of the four last fingers.

Direction.—Vertical.

Structure and uses.—A small tendon is observed at their inferior extremity, and in the rest of their extent they are fleshy, they are auxiliaries of the flexor profundus.

INTER-OSSEI.

They are seven in number, divided into four dorsal and three palmar: they are distinguished by the numerical names of first, second, &c., commencing with the thumb.

DORSAL INTER-OSSEALS.

(Métacarpo-phalangiens-lateraux-sous-palmaires.)

Situation and figure.—Elongated, flat, situated on the posterior part of the hand, between the metacarpal bones.

Extent.—From the space between the metacarpal bones, to the first phalanges of the four last fingers.

Division.—Posterior surface, covered by the integuments; anterior surface, which corresponds to the palmar inter-osseals. In the first only, this surface is covered by the abductor brevis pollicis and the flexor brevis pollicis.

The superior extremity, divided into two portions, is fixed to the most elevated portion of the metacarpal bones; the inferior, terminated by a small tendon, is fixed to the lateral portions of the first phalanges of the four last fingers.

Direction.—It follows that of the space between the metacarpal bones.

Structure and uses.—Tendinous inferiorly, and fleshy in the rest of their extent. The first dorsal inter-osseal draws the index finger outwards; the second, the great finger outwards; the third, the same finger inwards; the fourth, the ring finger likewise inwards.

PALMAR INTER-OSSEALS.

(*Metacarpo-phalangiens-lateraux-palmaires.*)

Situation and figure.—Elongated, situated in the palm of the hand, between the metacarpal bones, like the dorsal inter-osseals.

Extent.—From the space between the metacarpal bones, the first excepted, to the first phalanges of the three last fingers.

Division.—Posterior portion, in relation with the three last dorsal inter-osseals; anterior portion, covered by the muscles of the thenar and hypothenar eminences; and, in addition, by the tendons of the profundus and lumbricales. The superior extremity is attached to the most elevated portion of the corresponding metacarpal bones; the inferior, tendinous, is fixed to the lateral portions of the first phalanges of the index, ring, and auricular fingers.

Direction.—It follows that of the spaces between the metacarpal bones.

Structure and uses.—A long and small tendon is remarked at the inferior extremity ; they are fleshy in the rest of their extent. The first palmar inter-osseal draws the index finger inwards ; the second, the ring finger outwards ; the third, the small finger outwards.

EIGHTEENTH REGION.

Coxo-femorale.

Muscles on the posterior part of the pelvis, and superior and posterior part of the thigh.—These muscles are :—the three glutei, divided into maximus, medius, and minimus ; pyramidalis, gemini, the two obturators and the quadratus ; the biceps, semi-tendinosus, and semi-membranosus.

Anatomical preparation.

The greater part of the muscles of the thigh have a point of insertion in the trunk, and their length, as also their mass, is very considerable. If we except the profound muscles of the buttocks, all the others, in their preparation, are more embarrassing on account of their volume than situation. Enveloped in a great quantity of fat and cellular tissue, they produce, in this respect, despair among the students ; and I have frequently known them to abandon an examination of them, fatigued with the obligation of removing the fat. But, I repeat it, patience is indispensable for the anatomist, and it is especially at the commencement of his studies that he should arm himself with it.

The general preparation of the muscles on the posterior part of the pelvis and thigh, requires that the subject be placed on the abdomen, and all the inferior part of the trunk should be elevated, which is indispensable for the

dissection of the muscles of this series. The incision of the integuments is to be made so as to form one broad flap, having the figure of a lozenge, one of the acute angles of which corresponds to the third or fourth lumbar vertebra, and the other loses itself in the skin of the perineum. For this purpose, we must prolong an incision which, from the third or fourth lumbar vertebra, will go to the environs of the anterior and superior spinous process of the ilium, and terminate in the middle of the posterior part of the thigh. The same rule must be followed on the opposite side; we will then detach the flap, which results from these two incisions, from above downwards, and from without inwards, so as to have a species of hood (*capuchon*,) which we employ at pleasure for the purpose of covering the muscles we have just prepared. We should be careful not to leave any fat, and it should be removed in detaching the flap in question. We should isolate it well, especially from the posterior and inferior part of the sacrum and coxycy, and, if possible, not a particle of fat should be suffered to remain on these bones. If the general preparation of the integuments, such as has just been indicated, be well made, it will facilitate that of the muscles which are covered by them.

Gluteus maximus.—This muscle, without contradiction, is that which is covered by the largest quantity of fatty matter; indeed, it completely surrounds it; and if we should ever be tempted to give to any one the name of *dé-graisseur de muscles*, it should certainly be to him who dissects the *gluteus maximus*, as likewise all the other muscles on the posterior part of the thigh. Be this as it may, with the integuments we should remove all the subjacent adipose matter, and endeavor to follow, in this preparation, the direction of the fibres of the *gluteus maximus*,

commencing at its superior and anterior part, in order to terminate posteriorly and inferiorly. It is especially in the environs of the anus and perineum that this muscle requires the most care and patience, for at this point it is not supported, and it is difficult to retain it under the instrument. It is, however, essential to expose it completely before passing to its examination, for, in general, nothing is more unpleasant to behold than these dissections but half terminated, which occasion considerable difficulty, and which afford but a poor opportunity of observing the situation and relations of the parts.

In the interval of the fibres of the gluteus maximus there are sometimes mingled considerable masses of fatty matter; it is unnecessary to attempt to remove them, they form part of the muscle; it will suffice to have removed them, as much as possible, from its external surface, and to have isolated properly its terminations. We may then, particularly if we have prepared the two glutei at one time, cut that of one side across, at its middle portion. One of the flaps is thrown towards the ilium, and the other turned over on the thigh. As this muscle is very thick, we may carry the scalpel boldly through its tissue, proceeding from within outwards, as far as the aponeurosis which unites it to the gluteus medius in front, and which should be left entire.— It would perhaps be still better to detach the gluteus maximus at its connexions with the sacrum and ilium. There is a great quantity of loose cellular tissue between the gluteus maximus and medius; it must be entirely removed, in order to pass afterwards to the preparation of the gluteus medius.

Gluteus medius.—This muscle, placed nearly altogether under the preceding, occupies the greatest part of the ex,

ternal iliac fossa, from which it is separated only by the gluteus minimus; its dissection is entirely accomplished, after having detached the portions of the gluteus maximus which covered it; it is especially towards the great trochanter that it is necessary to separate it more completely, in order to expose it perfectly.

Gluteus minimus.—This is the last of the muscles situated in the external iliac fossa. When compared to the gluteus maximus, it will be found that a great difference exists between them. The gluteus minimus is entirely covered by the medius, and, in order to expose it, we must cut this last across at its middle portion, and raise the flaps as was done for the gluteus maximus, or even detach it, like this last, at its upper points of insertion. The same as the medius, the gluteus minimus is prepared, when we have completely removed the preceding; we may even leave it until the examination of the other muscles on the superior part of the thigh, for it does not interfere with their preparation; its presence, on the contrary, contributes to show more clearly the relations of these different muscles.

Pyramidalis, gemini, and quadratus.—The preparation of these different muscles should be simultaneous; they are so approximated to each other, and touch by such numerous points, that many anatomists have confounded and described them as one and the same mass.—We shall, however, preserve the division of these muscles, such as we have just indicated above. Entirely covered by the gluteus maximus, they are separated from it only by a large quantity of cellular tissue, very abundant in these regions. All these muscles go from the pelvis, to the digital cavity of the great trochanter: the first which presents itself for study is the pyramidalis, a portion of which

is enclosed in the interior of the pelvis. We must reserve for another time the preparation of this portion; outwards, it occupies the most elevated part of the digital cavity. The two gemini are found beneath; one comes from the spine of the ischium, and the other from the tuberosity of the same name. They are separated by the tendon of the internal obturator, with which they contract strong adhesions, which must be partly destroyed, in order to isolate the gemini, but without detaching them entirely. The preparation of the internal obturator, external obturator and pyramidalis, cannot be accomplished until after that of all the muscles of the thigh; because, in order to see them well, we must disarticulate the pelvis, and free the first from many objects, whose presence is a great obstacle to their preparation. The quadratus femoris is the last and lowest of this deep-seated layer, and it cannot be seen without the precaution of detaching completely the gluteus maximus, which covers it. It is parallel, by its inferior border, to the third adductor of the thigh, with which it is sometimes intimately united. This circumstance is of but little importance, and does not prevent us from recognising the quadratus, which is never more than three fingers' breadth from above downwards. It should not be forgotten, in the preparation of all these muscles, that they should be left in place after having employed all the proper means of observing them, and that the great ischiatic nerve should likewise be preserved; this passes from the pelvis to the thigh, lying on the posterior portion of these muscles.

Biceps, semi-tendinosus, semi-membranosus.—I include these three muscles in the same preparation, because it is difficult to dissect them separately. We must prolong an incision of the integuments below the ham,

and turn the two flaps outwards and inwards ; in this space just exposed are found these three muscles—the biceps outwardly, and the two others inwardly. A broad aponeurosis, called *fascia lata*, covers them almost immediately ; it should be removed with the integuments in order to pass to the dissection of the muscles. Their superior portion being concealed by a part of the gluteus maximus, it is indispensable to separate this last completely, in order to see the others in all their extent. There is a great quantity of fat on these muscles, as likewise in the space which separates them ; the labor necessary to remove it is long and fatiguing ; it is worthy of remark, that this fat, as abundant as it is, preserves the form of the parts, retains the muscles in their respective position, and conveys an accurate idea of their absolute situation.—In removing it, all these advantages will be sacrificed.—The student, therefore, before proceeding with it, should take a general survey of the parts. The muscles, once separated from the fat, no longer preserve their relations, and if the precautions we have just mentioned be not followed, we shall have but a very imperfect idea of these different objects. These three muscles have a common superior origin : the semi-tendinosus and semi-membranosus especially are intimately connected, and we should not attempt to separate them. Their inferior extremity, on the contrary, going in different directions, does not present the same arrangement.

It is easy enough to pursue and obtain a correct view inferiorly of the insertion of the biceps and semi-membranosus, because they are fixed, the first to the superior extremity of the peroneus, and the second to that of the tibia. In removing the integuments at this point, the insertion of

both is perfectly exposed, but the inferior extremity of the semi-tendinosus passes the articulation of the thigh and leg, and goes to the anterior and internal portion of the tibia, five or six fingers' breadth from the superior extremity of this bone. We may be content, for the moment, to prepare the portion of the muscle which occupies the posterior part of the thigh, abandoning the examination and study of its tendon, until we shall dissect the sartorius and rectus internus, with both of which it contracts strong adhesions, and in addition contributes to form with them an aponeurotic expansion, called *la patte d'oie*, and which is observed at the superior and internal portion of the tibia.

Description.

GLUTEUS MAXIMUS.

(*Sacro-fémoral.*)

Situation and figure.—Broad, thick, flat, quadrilateral; situated on the posterior part of the pelvis and superior of the thigh.

Extent.—From the ilium, sacrum and coxycy, to the femur.

Division.—Posterior surface, covered by the integuments, beneath which is observed a great quantity of fat; anterior surface, which covers a portion of the ilium, sacrum, all the muscles of the deep-seated layer, and the superior part of the three muscles on the posterior portion of the thigh. The superior border extends obliquely from the ilium to the great trochanter, passing on the gluteus medius; the inferior, the longest and thickest of all, extends obliquely from the coxycy to the superior part of the femur; the external is united to the gluteus medius, by means of a strong aponeurosis, and it goes from the

ilium to the great trochanter; the internal passes from the ilium to the sacrum and coxycy, and is united strongly to the aponeuroses of the sacro-lumbalis and longissimus dorsi. From the external and inferior borders there results an elongated and tendinous portion, which embraces the entire of the great trochanter.

Direction.—Oblique from above downwards, and from within outwards.

Structure and uses.—It is aponeurotic at its attachments to the ilium, sacrum, and coxycy; the portion attached to the femur presents a broad and thick tendon, which is continuous with the aponeurosis of the fascia lata; in the rest of its extent, it is composed of fleshy fasciculi, separated by bands of fatty cellular tissue; it extends the pelvis on the thigh, and the thigh on the pelvis, drawing the point of the foot outwards.

GLUTEUS MEDIUS.

(*Grand ilio trochantérien.*)

Situation and figure.—Broad, flat, radiated; situated on the posterior part of the pelvis, and superior of the thigh.

Extent.—From the external iliac fossa to the great trochanter.

Division.—External surface, covered by the gluteus maximus behind, and by the integuments in front; internal surface, applied to the ilium and gluteus minimus. The anterior border extends from the superior spine of the ilium to the great trochanter; the posterior, from the ilium, to the great trochanter likewise, following the direction of the pyramidalis; the superior, or base, is fixed to the su-

perior curved line of the ilium; the summit, to the superior border of the great trochanter.

Direction.—The fibres converge from the os-iliac towards the great trochanter.

Structure and uses.—Aponeurotic at its attachments to the ilium, a broad and thick tendon terminates it inferiorly, and in the rest of its extent it is fleshy: it has the same uses as the gluteus maximus.

GLUTEUS MINIMUS.

(*Petit-ilio-trochantérien.*)

Situation and figure.—Broad, flat, radiated; situated on the posterior part of the pelvis, and the superior of the thigh.

Extent.—From the ilium to the great trochanter.

Division.—External surface, entirely covered by the gluteus medius; internal surface, which covers a portion of the external iliac fossa and the ileo-femoral articulation. The anterior and posterior borders, parallel to those of the gluteus medius, but shorter, present nothing remarkable; the superior, or base, is fixed to the inferior curved line of the ilium; the summit, to the anterior border of the great trochanter.

Direction.—Similar to that of the gluteus medius.

Structure and uses.—The structure and uses of this muscle do not differ from those of the gluteus medius.

PYRAMIDALIS.

(*Sacro-trochantérien.*)

Situation and figure.—Elongated, flat, triangular; situated on the posterior and internal part of the pelvis, and superior of the thigh,

Extent.—From the excavation of the pelvis to the great trochanter.

Division.—Posterior surface, applied on part on the sacrum, and covered in the rest of its extent by the gluteus maximus and medius; anterior surface, covered in the pelvis by the rectum and sciatic plexus, and placed, out of the pelvis, on the gluteus minimus and ilium. The superior border is parallel to the posterior border of the gluteus medius; the inferior is confounded with the superior geminus. The base is placed in the pelvis in the environs of the sacral foramina; the summit is attached to the most elevated portion of the digital cavity on the great trochanter, near the gluteus medius.

Direction.—Slightly oblique from above downwards, and from within outwards.

Structure and uses.—It is terminated outwardly by a long tendon, and is fleshy in the rest of its extent; it rotates the thigh outwardly.

SUPERIOR GEMINUS.

(Comprised in the *Ischio-trochantérien*.)

Situation and figure.—Elongated, flat, situated on the posterior portion of the pelvis.

Extent.—From the ischiatic spine to the great trochanter.

Division.—Posterior surface, covered by the gluteus maximus and great sciatic nerve; anterior surface, applied on the haunch bones. The superior border is parallel to the pyramidalis; the inferior is confounded with its fellow and the tendon of the obturator internus. The internal extremity is fixed to the sciatic spine; the external, in the digital cavity of the great trochanter, below the pyramidalis.

Direction.—Transverse.

Structure and uses.—Tendinous at its femoral or external portion, fleshy in the rest of its extent, its uses are the same as those of the pyramidalis.

INFERIOR GEMINUS.

(*Comprised in the Ischio trachantérien.*)

Situation and figure.—Elongated, flat, situated on the posterior part of the pelvis.

Extent.—From the ischiatic tuberosity, to the great trochanter.

Division.—Posterior surface, covered by the gluteus maximus and great sciatic nerve; anterior surface, applied on the haunch bones. The superior border is parallel to the superior geminus, and the inferior to the quadratus. The internal extremity is attached to the tuberosity of the ischium; the external is fixed in the digital cavity of the great trochanter, beneath the preceding and obturator internus.

Direction.—Transverse.

Structure and uses.—A tendon is remarked at its external extremity; in the rest of its extent, it is fleshy. It has the same uses as the preceding.

OBTURATOR INTERNUS.

(*Sous-pubio-trochantérien-interne.*)

Situation and figure.—Elongated, flat, triangular; situated in the excavation of the pelvis and on the superior part of the thigh.

Extent.—From the obturator fossa, to the great trochanter.

Division —Internal surface, which corresponds to the pelvis; it is covered by the levator ani and numerous vessels; external surface, applied to the obturator fossa. The superior and inferior borders, placed in great part within the pelvis, as also the base of the muscle, circumscribe the circumference of the obturator foramen; the external extremity is tendinous, and is placed between the two gemini; is fixed to the posterior part of the great trochanter.

Direction.—Transverse.

Structure and uses.—A long tendon is remarked outwardly; in the rest of its extent it is fleshy. Its uses are the same as those of the preceding muscles.

QUADRATUS.

(*Ischio-sous-trochantérien.*)

Situation and figure.—Flat, quadrilateral; situated on the posterior and superior part of the thigh.

Extent.—From the ischium to the great trochanter.

Division.—Posterior surface, covered by the gluteus maximus, great sciatic nerve, and a small portion of the semi-membranosus; anterior surface, applied to the external obturator. The superior border is parallel to the inferior geminus, and the inferior to the third adductor; the internal is fixed to the tuberosity of the ischium in front of the semi-membranosus; the external, to the inferior part of the posterior border of the great trochanter.

Direction.—Transverse.

Structure and uses.—Very slightly tendinous at its attachments, fleshy in the interval, it has the same uses as the preceding.

All the muscles of this region, if we except the three glutei, produce on the thigh a movement of rotation, by

which the point of the foot is turned outwards; under some circumstances, they move the pelvis on the thigh.

BICEPS.

(*Ischio-fémoro-péronien.*)

Situation and figure.—Elongated; situated along the whole extent of the posterior and external part of the thigh; divided into two portions at its superior part.

Extent.—From the tuberosity of the ischium to the peroneus.

Division.—Posterior surface, covered above by the gluteus maximus, and by the integuments in the rest of its extent; anterior surface, which covers, from above downwards, the semi-membranosus, cruralis, third adductor and external gemellus of the leg. The superior extremity is divided into two portions: the long portion is attached to the tuberosity of the ischium, in uniting with the semi-tendinosus; the short portion is fixed to the inferior part of the linea aspera of the femur; its inferior extremity is attached to the upper portion of the peroneus.

Direction.—Nearly vertical.

Structure and uses.—Tendinous at its extremities, fleshy in the interval, it flexes the leg on the thigh, and this on the leg.

SEMI-TENDINOSUS.

(*Ischio-prè-tibial.*)

Situation and figure.—Elongated; situated along the whole extent of the posterior and internal portion of the thigh.

Extent.—From the tuberosity of the ischium to the tibia.

Division.—Posterior surface, covered above by the gluteus maximus, and in the rest of its extent by the integuments; anterior surface, applied in part to the semi-membranosus. The superior extremity is attached to the tuberosity of the ischium; the inferior, to the internal and superior part of the tibia.

Direction.—Oblique from above downwards, from behind forwards, and from without inwards.

Structure and uses.—It is terminated inferiorly by a long tendon, and is fleshy in the rest of its extent. It flexes the leg on the thigh, and this on the leg.

SEMI-MEMBRANOSUS.

(*Ischio-popliti-tibial.*)

Situation and figure.—Elongated, flat; situated along the whole extent of the posterior and internal part of the thigh.

Extent.—From the tuberosity of the ischium to the tibia.

Division.—Posterior surface, covered above by the gluteus maximus, semi-tendinosus, biceps, and by the integuments in the rest of its extent; anterior surface, which covers above a portion of the quadratus and third adductor. The superior extremity is fixed to the tuberosity of the ischium, below the attachment of the semi-tendinosus: the inferior is fixed to the posterior part of the internal tuberosity of the tibia.

Direction.—Nearly vertical.

Structure and uses.—This muscle is terminated above and below by a broad aponeurosis; in the interval, there are fleshy fibres obliquely situated; it has the same uses as the preceding

NINETEENTH AND TWENTIETH REGIONS.

Anterior and internal femoral.

There is only one muscle observed on the external portion of the thigh—it is the muscle of the *fascia-lata*; those of the anterior part are—the sartorius, rectus anterior, and triceps cruralis. On the internal part—the rectus internus, pectineus, three adductors, and obturator externus.

Anatomical Preparation.

As great as were the difficulties in the preparation of the muscles on the posterior part of the thigh, we must not flatter ourselves that we shall be more favored in undertaking those on the anterior and internal part. The fat and cellular tissue, it is true, are not in such abundance as on the posterior portion, but the muscles are more numerous; they touch each other by multiplied points, and their reciprocal separation is often impossible. The large vessels of the thigh are found continually under the scalpel, and the blood which escapes from them on all sides contributes to render the preparation of these muscles troublesome and fatiguing. Notwithstanding the inconveniences which result from it, I think that the student, who has not yet had much practice in dissection, should remove the crural vessels, before proceeding to the preparation of the muscles with which they are in contact; for this, it will be necessary, after having cut them near the ilium and under the ham, to remove them from above downwards, being careful to separate them from the surrounding parts. The dissection and study of myology are sufficiently long and encumbered with details, without being obliged to examine all the parts, which have relations with the muscles.

Sartorius.—If, for the examination of the muscles on the anterior part of the thigh, we make use of the extremity which has served for those of the posterior, it will be necessary to pursue the dissection of the integuments from behind forwards, until we arrive at the sartorius, and continue the preparation of this muscle, as will be hereafter indicated: in the contrary case, we should proceed in the following manner:—Make an incision of the integuments which is prolonged obliquely inwards, from the superior spine of the ilium, to the superior portion of the tibia. This incision indicates precisely the course of the sartorius; in fine, if we separate inwards and outwards the two flaps of the integuments, we shall see this muscle exposed in its whole extent; it must be freed from the fat which covers it; but we should not remove it from that on which it reposes, and by means of which we observe very well its absolute position and numerous relations; for, the fat once removed, and the muscle separated from the subjacent parts, we will have but an imperfect idea of these two important circumstances.

Rectus anterior.—After preparing the sartorius, a great part of the rectus anterior will be exposed. Placed immediately under the integuments, like the preceding, nothing can be easier than its dissection: it occupies the anterior portion of the thigh, and goes from the inferior spine of the ilium to the rotula, on which its tendon expands after the manner of a capsule. It should not be forgotten that it furnishes a tendon above, which is lost in the coxo-femoral articulation, which we ought to observe accurately before passing to the preparation of the other muscles of the thigh. We should not attempt to separate it too low down

from the cruralis, to which it is intimately united in its inferior portion.

Cruralis.—We may leave the sartorius in place in order to dissect the rectus anterior; but we must necessarily cut both across in order to pass to the preparation of the cruralis; it is then that we must remove the quantity of fat found in these regions, particularly on the superior and internal part of the thigh. Here also are found the crural vessels, inguinal glands, and a quantity of cellular tissue; the whole should be removed with precaution, and the muscles freed from them with all possible care. The cruralis occupies the whole body of the femur, except the posterior part, where are remarked the three adductors and biceps; this large fleshy mass forms three portions very distinct, at least at its middle part; however, it is not absolutely necessary to consider the cruralis as composed of three portions; there are some subjects in which this distinction is quite apparent; but in one or the other case, the study of these different parts refers merely to one muscle. It is easy enough to dissect outwardly what is termed the vastus externus; but the internal portion is much more difficult, because it is in part concealed by the adductors, and above by the pectineus. In consequence of this, it would perhaps be well not to dissect the cruralis until after having removed all the other muscles of the thigh.

Fascia lata.—It alone occupies the external region of the thigh, at the superior part of which it is situated. Concealed in the duplicature of the aponeurosis of the same name, it can be separated from it but with difficulty, particularly at its internal part. We must, therefore, be content with examining its external surface, and leave it applied to the profound feuillet of the aponeurosis. Not hav-

ing much extent, and its volume being inconsiderable, more ample details as regards its preparation would be superfluous.

Rectus internus.—Like the sartorius, it is placed under the incision of the integuments, when we commence the study of the muscles of the thigh, along the whole extent of which the rectus internus is situated. As with the sartorius, we must at first be content with exposing its superficial part, and afterwards take a survey of its absolute situation and different relations. It may then be separated from the fat and other parts with which it has connexions. We may also, after this, cut it across at its middle portion, in order to pass to the preparation of the pectineus and adductors; but, before doing this, we should examine the arrangement of the tendons of the rectus internus, semi-tendinosus, and sartorius. They form, in the superior and internal portion of the tibia, four or five fingers' breadth from its superior extremity, what is termed the *patte d'oie*, which is situated immediately under the integuments, and which gives origin to the tibial aponeurosis.

Pectineus.—This muscle, as also the three adductors, occupies all the internal and profound part of the thigh.—As these different muscles are intimately united to each other, their preparation, in this respect, presents some difficulty. The pectineus is the first with which we should occupy ourselves; its situation demands this. It goes from the ileo-pectineal eminence to the small trochanter, placed behind the femoral vessels, glands and abundant cellular tissue, which surrounds these parts. When we have not taken the precaution of previously removing all these objects, and of frequently absorbing with a sponge the blood and other effused fluids, the preparation of the

pectineus and adductors is one of the most fatiguing and vexatious. It is easy to recognize the pectineus in front ; but it is more difficult to observe posteriorly the line, which separates it from the first adductor. We must recollect that the pectineus originates from the horizontal branch of the pubis, and that it scarcely ever descends lower than the small trochanter, whilst the first adductor, which is attached above to the body of the pubis descends as far down as the linea aspera of the femur.

The three adductors.—Immediately below and behind the preceding, is observed the first adductor, which is larger and longer than the pectineus. What we have already said respecting the difficulty of finding the line, which separates it from the first adductor, applies very well to this last and to the second adductor ; both are attached to the body and descending branch of the pubis, and both go to the linea aspera of the femur, into which they are implanted conjointly with the third adductor. We may, with some care, find above the trace of separation of the two first adductors ; but we shall in vain look for the same result below, where their common insertion into the femur is so confounded, that the three muscles appear to be one and the same mass. The third adductor, the largest of the three, and one of the most considerable of the whole economy, is more embarrassing on account of its volume and great extent, than from any difficulty of following its course. When we have had the precaution to remove the fat, which enveloped the other muscles of the thigh, which must also be removed, after having studied them, except the triceps cruralis, which it is necessary to preserve, we may then more easily prepare the three adductors. The third extends from the tuberosity of the ischium, the neigh-

boring part of the femur, and the whole length of its linea aspera, nearly as far as the internal tuberosity of the same bone; very broad and voluminous at its superior part, it is terminated below by a species of aponeurotic band, across which passes the crural artery four or five fingers' breadth above the ham. We should not fail to observe accurately this disposition, as also the connexions of the third adductor, with the short portion of the biceps.

We may, after the preparation of the three adductors, detach them as near as possible to the femur, without absolutely removing them, and examine, for a moment, the arrangement of the three portions of the cruralis, particularly at their superior part, where they were in great measure, concealed by the abductors and pectineus: finally, this once achieved, we should proceed to the preparation of the two obturators, which it would have been difficult and even impossible to prepare before, especially the external.

The two obturators.—These two muscles occupy the obturator foramen, one within, the other without the pelvis, but they cannot be well dissected, until after the examination of all the other muscles of the thigh, and after having performed a particular section, which consists in separating the pelvis at its middle portion from before backwards; or, we may simply divide the symphysis pubis with a scalpel, and by drawing in a contrary direction the divided pubes, rupture posteriorly the sacro iliac symphysis of the side on which we wish to dissect the obturators. After this preliminary step, we should carefully remove all the soft parts which conceal internally the obturator internus, and then pursue its dissection as far as the great trochanter. The obturator externus is very profoundly situated, and absolutely concealed by the pectineus and first ad-

ductors. We must, therefore, remove all these muscles, as also the rectus internus and rectus anterior, if we have not already done it. Such is the easiest and most simple mode of preparing the muscles of the thigh.

Description.

THE MUSCLE OF THE FASCIA LATA.

(*Ilio-aponeurotic-fémoral.*)

Situation and figure.—Elongated, flat, situated on the superior and external part of the thigh.

Extent.—From the ilium, to six or eight fingers' breadth below.

Division.—Its external and internal surfaces are in relation with the two feuilletts of the aponeurosis of the fascia lata, in which the muscle is completely lodged. Its borders, concealed by the aponeurosis, present nothing remarkable. The superior extremity is fixed to the superior spine of the ilium; the inferior loses itself in the duplication of the aponeurosis.

Direction.—Vertical.

Structure and uses.—Tendino-aponeurotic at its superior extremity, fleshy in the rest of its extent, it extends the aponeurosis of the fascia lata, and may also draw the thigh outwardly.

SARTORIUS.

(*Ilio-prè-tibial.*)

Situation and figure.—Elongated, narrow, flat; situated on the internal part of the thigh, and superior and internal of the leg.

Extent.—From the ilium to the tibia.

Division.—External surface, covered by the integuments; internal surface, which covers a portion of the ilia-

cus, triceps cruralis, third adductor and rectus internus.—The borders offer nothing particular. The superior extremity is fixed to the superior spine of the ilium; the inferior, to the superior and internal portion of the tibia, in confounding itself with the inferior extremities of the semitendinosus and rectus internus, for the formation of the *patte d'oie*.

Direction.—Oblique from above downwards, and from without inwards.

Structure and uses.—Tendinous inferiorly, fleshy in the rest of its extent, it bends the leg on the thigh, in drawing it towards that of the opposite side.

RECTUS ANTERIOR.

(*Ilio-rotulien.*)

Situation and figure.—Elongated, flat, situated on the anterior portion of the thigh.

Extent.—From the ilium to the rotula and tibia.

Division.—Anterior surface, covered by the integuments and aponeurosis of the fascia lata; posterior surface, applied to the middle portion of the cruralis, with which it contracts strong adhesions below. The borders present nothing particular. The superior extremity is fixed on the one hand, to the anterior and inferior spine of the ilium; and, on the other, to the circumference of the ileo-femoral articulation; the inferior is expanded on the rotula, and embraces on the right and left the superior extremity of the tibia.

Direction.—Vertical.

Structure and uses.—Strong tendons are remarked at its two extremities; broad aponeuroses originate from these tendons, and partly envelope the muscle; the interval is

occupied by short and abundant fleshy fibres. It extends the leg on the thigh, and draws the pelvis and thigh on the leg.

TRICEPS CRURALIS.

(*Tri-femoro-rotulien.*)

Situation and figure.—Broad, thick, flat; situated on the anterior, internal, and external part of the thigh, and divided superiorly into three portions.

Extent.—From the environs of the trochanters to the rotula and tibia.

Division.—Anterior surface, covered outwardly by the muscle of the fascia-lata, and the aponeurosis of the same name; inwardly by the sartorius, rectus internus; and at its middle portion, by the rectus anterior; posterior surface, applied in its whole extent on the femur. The external border is fixed to the external lip of the linea aspera; the internal, to the internal lip. The superior extremity, divided into three portions, is attached to a rough impression below the trochanters; the inferior, united in one mass, is attached to the superior part of the rotula, and also to the external and internal tuberosities of the tibia.

Direction.—The fibres, in the internal portion, are oblique from above downwards, and from within outwards; in the external portion, oblique from above downwards, and from without inwards, and vertical in the middle portion.

Structure and uses.—Broad aponeuroses are observed in the three portions; a broad and thick tendon terminates them inferiorly, and fleshy fibres occupy the interval. It extends the leg on the thigh, and reciprocally the thigh on the leg.

RECTUS INTERNUS.

(Sous-pubio-pré-tibial.)

Situation and figure.—Elongated, flat; situated on the internal parts of the thigh, superior and internal of the leg.

Extent.—From the body of the pubis to the tibia.

Division.—Internal surface, covered by the integuments; external surface, applied on the three adductors. The borders have nothing worthy of remark. The superior extremity, thin and flat, is attached to the body of the pubis and to the branch of the ischium; the inferior, tendinous, is fixed to the superior and internal portion of the tibia, and contributes to the formation of the *patte d'oie*.

Direction.—Vertical.

Structure and uses.—A long tendon terminates it inferiorly, and it is fleshy in the rest of its extent; it flexes the leg on the thigh, and draws it towards that of the opposite side.

PECTINEUS.

(Sous-pubio-trochantinien.)

Situation and figure.—Elongated, thick, flat; situated on the superior and internal portion of the thigh.

Extent.—From the pubis to the femur, below the small trochanter.

Division.—Anterior surface, covered by the integuments; posterior surface, applied on the obturator externus and one of the adductors; the superior extremity is fixed to the pubis, near the ileo-pectineal eminence; the inferior, below the small trochanter.

Direction.—Oblique from above downwards, and from before backwards.

Structure and uses.—Tendinous inferiorly, fleshy in the rest of its extent, it flexes the thigh on the pelvis, and

approximates it to that of the opposite side, in turning it outwards.

ADDUCTOR PRIMUS.

(*Pubio-fémoral.*)

Situation and figure.—Elongated, thick, flat; situated on the internal and superior part of the thigh.

Extent.—From the pubis to the linea aspera of the femur.

Division.—Anterior surface, covered by the sartorius and integuments; posterior surface, placed on the femur and third adductor. The superior extremity is fixed to the body of the pubis; the inferior is attached to the middle portion of the linea aspera, and becomes confounded with the third adductor.

Direction.—Oblique from above downwards, and from before backwards.

Structure and uses.—Tendino-aponeurotic at its extremities, fleshy in the interval, it flexes the thigh on the pelvis and draws it towards that of the opposite side, in turning it outwards.

ADDUCTOR SECUNDUS.

(*Sous-pubio-fémoral.*)

Situation and figure.—Elongated, thick, flat; situated on the superior and internal portion of the thigh.

Extent.—From the body and branch of the pubis to the linea aspera.

Division.—External portion, covered by the adductor primus; internal portion, which corresponds to the tendon of the psoas and obturator externus. The superior extremity is attached to the body and branch of the pubis; the inferior, to the superior third of the linea aspera.

Direction.—Oblique from above downwards, and from before backwards.

Structure and uses.—Similar to the adductor primus, as regards its structure and uses.

ADDUCTOR TERTIUS.

(*Ischio-fémoral.*)

Situation and figure.—Broad, thick, flat; situated along the whole extent of the internal portion of the thigh.

Extent.—From the ischium to the internal tuberosity of the femur.

Division.—Anterior surface, covered by the two first adductors; posterior surface, covered by all the muscles on the posterior part of the thigh. The internal border is covered by the rectus internus; the external is fixed to the external ridge of the superior bifurcation of the linea aspera, at its interstice, and to the internal ridge of the inferior bifurcation. This border presents, at its inferior third, an opening for the passage of the crural artery.—The superior extremity, called the base, is attached to the tuberosity of the ischium, to the branch of the pubis, and to the adjoining part of the femur, below the great trochanter; the inferior is fixed to the internal tuberosity of the femur.

Direction.—The fibres are the more oblique from above downwards, and from within outwards, as we examine the muscle nearer its inferior portion.

Structure and uses.—Tendinous inferiorly, aponeurotic at its attachments to the line of the femur, and fleshy in the interval. Its uses are the same as those of the two first adductors.

more less, always towards the anterior and from

OBTURATOR EXTERNUS.

(*Idem.*)

Situation and figure.—Broad, flat, nearly triangular; situated on the superior and internal portion of the thigh.

Extent.—From the obturator foramen to the femur.

Division.—Anterior surface, covered by the second adductor; posterior surface, applied on the obturator foramen. The internal extremity is fixed to the pubis and ischion; the external, is attached to the inferior part of the great trochanter.

Direction.—Transverse.

Structure and uses.—Aponeurotic at its attachment to the pubis and ischium, tendinous at its attachment to the femur, and fleshy in the interval; its uses are analogous to those of the gemini, iliacus, and obturator internus.

TWENTY-FIRST AND TWENTY-SECOND REGIONS.

Anterior tibial.—*Posterior tibial.*

Muscles of the anterior and posterior part of the leg.
—The muscles of the anterior part are:—the tibialis anticus, extensor communis digitorum pedis, extensor proprius pollicis pedis, and the peroneus anticus. The muscles of the external region are:—the two peronei, distinguished into long and short; those of the posterior part are more numerous. Authors are in the habit of distinguishing them into several layers, placed in the following manner:—1st, gemelli, or gastrocnemii; 2d, plantaris; 3d, Soleus and popliteus; 4th, flexor pollicis pedis, flexor communis digitorum, and tibialis posticus.

Anatomical Preparation.

The preparation of the muscles of this region, do not present any very great difficulty. The skill, which the student has acquired in dissection by this time, should be considered as the principal cause. He now finds the preparation of these parts comparatively easy; but they would have been extremely embarrassing if he had commenced his anatomical labors with them. It is, however, true that he owes a part of this facility to the disposition of the muscles themselves, separated as they are from each in nearly their whole extent, possessing but an inconsiderable volume, and deprived of that mass of fat, which rendered the preparation of the muscles of the thigh so inconvenient; those of the leg, on the contrary, present, in this respect, the most favorable circumstances for their dissection.

The muscles of the anterior and external part being few in number, should be prepared the first. Divide, therefore, the integuments of the anterior part of the leg from the knee to the back of the foot, and turn the flaps outwards. The muscles are immediately covered by a thick and tense aponeurosis; it should be left in place, in order to get an idea of its relations with them; it is then to be removed, commencing at its inferior part, and pursuing the dissection as high up as possible: but it adheres so intimately to the muscles at their superior part, that it is impossible to free them from it; we should not even attempt it. The muscles thus exposed, the first requiring our attention, is the *tibialis anticus*.

Tibialis anticus.—Placed at the internal portion of the muscles of this region, it will be readily recognised by its volume, which is more considerable than that of the other muscles; by its superior insertion, which is into both the

tibia and fibula ; and by the strong tendon, which terminates it inferiorly. In order to observe the trace, which separates it from the adjoining muscles, we should commence below, where this separation is well marked, and pursue it as high up as possible ; but we should not carry it as far as the most elevated part of the leg, where the union of the different muscles of this region is very intimate.

Extensor communis digitorum pedis.—Although this is situated more outwardly than the extensor proprius pollicis pedis, it should be prepared before this last, which is concealed and covered by it and the tibialis anticus ; in the preparation of the extensor communis digitorum pedis, we should be careful to separate accurately its tendons at the inferior portion ; preserve the annular ligament under which they pass ; and we should not forget to distinguish and separate the peroneus anticus from the extensor communis ; they pass under the annular ligament together, and frequently the fibres of the two muscles become intimately confounded : but the different insertion of their inferior extremity furnishes means of distinguishing them—the extensor communis terminating at the toes, and the peroneus at the superior and posterior part of the fifth metatarsal bone.

Extensor proprius pollicis pedis—This muscle, as has already been remarked, is entirely covered, at its superior part, by the tibialis and extensor digitorum pedis ; we must separate both one and the other, in order to see it. The insertion of its inferior extremity into the last phalanx of the great toe, serves as a means of recognising it.

Peroneus anticus.—It has already been observed that this muscle is often united rather intimately to the extensor

digitorum pedis, so that it cannot be separated from this last except at its inferior insertion ; this is the only means by which it may be known. The muscles on the anterior part of the leg, the tibialis excepted, are sometimes so thin, that it is as well not to attempt to separate them too nicely, with a view of making a vain parade of skill in dissection.

The two peronei.—Placed at the external side of the tibialis, they are at this point so approximated to each other, that they cannot be separated except at their inferior part, where their respective tendons separate for the purpose of going to their different points of insertion. One, in fine, the peroneus longus, leaves the leg to be inserted into the first metatarsal bone, passing obliquely under the sole of the foot ; the other, on the contrary, limits its march to the fifth metatarsal bone, to which it is fixed. We should not, for the moment, endeavor to pursue the termination of the peroneus longus : this should be reserved until we prepare the muscles on the sole of the foot, and we should limit ourselves merely to that portion of the muscle, which travels along the tibia.

After the preparation and examination of the peronei, we proceed to the muscles of the posterior part of the leg, for which it will suffice to pursue the separation of the integuments posteriorly, and to free the whole of the leg from them.

Gastrocnemii.—These muscles, placed immediately under the skin, form the calf, particularly the internal portion. A part of these muscles was exposed in the preparation of those in the posterior region of the thigh ; it will merely be necessary to pursue the division of the integuments, as far as the heel, and to turn the flaps

outwards and inwards, or even to remove them entirely from the leg. As I just observed, a quantity of adipose cellular tissue is found at the superior part of these muscles and in the hollow of the ham; a quantity not less considerable is likewise remarked at the inferior part, and surrounds the tendo Achillis. All this cellular tissue must be removed, and the gemelli muscles accurately exposed; but the aponeuroses, which cover them above and below, are not to be touched. We should not attempt to separate these muscles from the soleus and tibialis parvus, which are placed beneath, before having studied them properly; and we should preserve, if convenient, the popliteal vessels, lodged in the space between these muscles at their superior portion.

Soleus and tibialis parvus.—Cut the gemelli across at their superior third, and turn the flaps in a contrary direction, in order to expose the soleus and tibialis placed immediately beneath; a very small quantity of cellular tissue covers these muscles; towards their superior part is likewise found the small popliteal muscle. The tibialis parvus is only remarkable for its extreme smallness and the excessive length of its tendon; it is sometimes wanting, but rarely. It is situated along the internal portion of the soleus, intimately united, at its inferior part, to the tendon of Achilles; sometimes, however, it does not adhere to it. Its fleshy fibres do not occupy superiorly more than three or four fingers' breadth.

The soleus is too voluminous and distinct, to render it necessary to point out here any characters by which it may be recognized. It adheres strongly at its superior part to the tibia and fibula, which it soon abandons in or-

der to contribute, with the gemelli and tibialis parvus, to the formation of the tendo Achillis, where these three muscles are absolutely confounded together.

To the preparation of the soleus and tibialis parvus, is connected that of the popliteal muscle, united in nearly its whole extent to the hard parts, on which it is situated. It is seen at the posterior part of the articulation of the leg and thigh. It will suffice to remove the small quantity of cellular tissue, which covers it; not being susceptible of detachment from the place it occupies, it does not require any preparation.

Flexor longus digitorum pedis communis—flexor longus pollicis pedis—tibialis posticus.—The preparation of these three muscles should be made simultaneously, at least for the portion, which corresponds to the leg. One circumstance alone renders it somewhat embarrassing—it is that we must either sacrifice nearly all the muscles of the foot in order to see the inferior termination of those of the leg, or we must only study at first that portion of these muscles, which travels along the posterior part of the leg, and reserve the preparation of what is to follow, until after that of the muscles of the foot. I would advise the student to adopt the latter mode; he will depart, it is true, from the order most generally adopted in books on anatomy, but he will follow more accurately the correct mode of dissecting. Let him commence, in the first place, with the flexor longus digitorum pedis, which is within, and pass afterwards to the flexor longus pollicis pedis, which is without. The tibialis posticus is in part concealed by the preceding. In order not to be deceived as regards these muscles, and not to mistake one for the other, it will be necessary to pull alternately on their re-

spective tendons, and examine what part they set in motion. All three of them pass through the large groove on the calcaneum in order to go to the foot; in this place they are covered by a quantity of adipose cellular tissue, from which it will be proper to free them. We shall return to this subject after the preparation of the muscles of the foot.

Description.

TIBIALIS ANTICUS.

(*Tibio-sus-tarsien.*)

Situation and figure.—Elongated, flat in different directions; situated on the anterior part of the leg, and superior of the foot.

Extent.—From the tibia to the first os-cuneiforme.

Division.—Anterior portion, covered in its whole extent by the integuments; internal portion, applied on the tibia; external portion, united above to the extensor communis digitorum pedis, and below to the extensor pollicis pedis; posteriorly, this muscle contracts adhesions with the interosseous ligament. The superior portion is attached to the external tuberosity of the superior extremity of the tibia; the inferior, to the superior surface of the first os-cuneiforme.

Direction.—Vertical.

Structure and uses.—A long tendon terminates it inferiorly, and it is fleshy in the rest of its extent. It flexes the foot on the leg, and this on the foot. In its action on the foot, it elevates particularly its internal border, and draws its point inwards.

(Extensor proprius pollicis pedis.)

Situation and figure.—Elongated, slightly flat; situated on the anterior part of the leg, and superior of the foot.

Extent.—From the peroneus, to the last phalanx of the great toe.

Division.—Internal surface, which corresponds to the tibialis anticus; external surface, to the extensor communis digitorum pedis. It is concealed in front by these two last muscles; posteriorly, it corresponds to the fibula above, and to the inter-osseous ligament below. The superior extremity is attached to the superior third of the fibula; the inferior, to the superior and posterior part of the first phalanx of the great toe.

Direction.—Oblique from above downwards, and from without inwards.

Structure and uses.—Tendinous inferiorly, fleshy in the rest of its extent, it extends successively the phalanges of the great toe on the metatarsal bones, and may afterwards contribute to produce the flexion of the whole foot.

EXTENSOR COMMUNIS DIGITORUM PEDIS.

(Péronéo-sus-phalangettien commun.)

Situation and figure.—Elongated, slightly flat; situated on the anterior part of the leg, and superior of the foot.

Extent.—From the tibia, to the first and second phalanges of the four last toes.

Division.—Internal portion, in correspondence with the tibialis anticus and extensor pollicis pedis; external portion, which corresponds successively to the three peronei. It is covered in front by the integuments, and be-

hind it is attached to the fibula and inter-osseous ligament. The superior extremity is fixed to the external tuberosity of the tibia, between the tibialis and peroneus longus; the inferior, divided into four tendons, is attached to the first and second phalanges of the four last toes.

Direction.—Vertical.

Structure and uses.—The tendons, which terminate it inferiorly, ascend very high up in the fleshy fibres, which compose the rest of the muscle. It produces the successive extension of the phalanges on the metatarsal bones, and may, like the preceding, flex the foot on the leg.

PERONEUS ANTICUS.

(*Petit-périnéo-sus-métatarsien.*)

Situation and figure.—Elongated, thin, flat; situated on the anterior part of the leg, and superior of the foot.

Extent.—From the fibula, to the fifth metatarsal bone.

Division.—External portion, covered by the integuments; internal portion, united to the preceding; it is attached posteriorly to the two inferior thirds of the fibula.—The superior extremity, confounded with the extensor digitorum pedis, is fixed to the internal surface of the fibula, towards the superior part of its middle third; the inferior, to the posterior part of the fifth metatarsal bone.

Direction.—Nearly vertical.

Structure and uses.—The structure does not differ from that of the preceding muscles; it flexes the foot on the leg.

PERONEUS LONGUS LATERALIS.

(Péronéo-sous-tarsien.)

Situation and figure.—Elongated; situated on the external lateral portions of the leg, and at the inferior part of the foot.

Extent.—From the tibia and fibula to the first metatarsal bone.

Division.—External portion, covered in the whole length of the leg by the integuments, and in the rest of its extent by the muscles of the superficial layer on the sole of the foot; internal portion, placed above on the fibula, and below on the peroneus lateralis brevis. It corresponds posteriorly to the soleus and flexor longus pollicis pedis; anteriorly, to the extensor digitorum pedis and peroneus anticus. The superior extremity is fixed to the most elevated portion of the fibula, and to the adjacent part of the tibia; the inferior, in crossing obliquely the sole of the foot, becomes attached to the inferior part of the first metatarsal bone.

Direction.—Vertical on the leg, obliquely horizontal on the foot.

Structure and uses.—A long tendon which terminates inferiorly, ascends very high up in the fleshy fibres, which form the rest of the muscle. It extends the foot on the leg, and reciprocally this on the foot.

PERONEUS BREVIS LATERALIS.

(Grand péronéo-sur-métatarsien.)

Situation and figure.—Elongated, flat; situated on the lateral portions of the leg.

Extent.—From the fibula to the fifth metatarsal bone.

Division.—External surface, covered by the peroneus lo

gus; internal surface, fixed to the two inferior thirds of the fibula. The superior extremity is attached to the external surface of the fibula, between the superior and middle third; the inferior, tendinous, passes behind the malleolus external, and is attached to the posterior part of the fifth metatarsal bone.

Direction.—Vertical on the leg, horizontal on the foot.

Structure and uses.—Its structure and uses are the same as those of the peroneus longus lateralis.

GEMELLI OR GASTROCNEMIUM.

(*Bi-fémoro-calcaneum.*)

Situation and figure.—Elongated, slightly flat; situated on the posterior part of the leg.

Extent.—From the condyles of the femur to the calcaneum.

Division.—Posterior surface, covered by the integuments; anterior surface, placed on the tibio-femoral articulation, tibialis parvus, popliteus and soleus. The borders form within and without the prominences of the calf. The superior extremity consists of two portions; the internal, the largest and longest, is fixed to the posterior part of the internal condyle of the femur, and the external, to the posterior part of the external condyle.—These two portions, between which are observed the popliteal vessels, united at a few fingers' breadth from their insertion, form a common mass, the inferior extremity of which contributes to the formation of the tendo Achillis, which is attached to the posterior part of the calcaneum.

Direction.—Vertical.

Structure and uses.—Two short and thick tendons are observed at the two superior extremities; a broad aponeurosis covers posteriorly and anteriorly a great part of the

fleshy mass placed in the interval, and they are terminated inferiorly by a long and strong tendon. The gemelli extend the foot on the leg, flex this on the thigh, and reciprocally this last on the leg.

TIBIALIS PARVUS.

(*Petit-fémoro-calcanien.*)

Situation and figure.—Elongated, very thin; situated on the posterior part of the leg.

Extent.—From the external condyle of the femur to the calcaneum.

Division.—Posterior surface, covered by the gemelli; anterior surface, placed on the soleus, along the internal border of which it passes. The superior extremity is attached to the posterior part of the external condyle of the femur; the inferior is confounded with the tendons of the gemelli and soleus, and contributes to the formation of the tendo Achillis.

Direction.—Slightly oblique from above downwards, and from without inwards.

Structure and uses.—The fleshy fibres are scarcely three or four inches in length; the rest of the muscle is formed by a long and thin tendon. It aids, but feebly, the action of the gemelli and soleus.

SOLEUS.

(*Tibio-calcanien.*)

Situation and figure.—Elongated, thick, flat; situated on the posterior part of the leg.

Extent.—From the tibia and fibula to the calcaneum.

Division.—Posterior surface, covered by the gemelli and tibialis parvus; anterior surface, which covers a por-

tion of the fibula and tibia, the flexor longus digitorum, tibialis posticus and flexor longus pollicis pedis. The superior extremity, narrow and pointed, is attached to the posterior surface of the fibula, near its superior extremity; the inferior contributes to the formation of the tendo-Achillis, and is fixed to the posterior part of the calcaneum.

Direction.—Vertical.

Structure and uses.—Broad aponeuroses are observed on the posterior surface and in the interval of the fleshy fibres; a long tendon, intimately united to that of the gemelli, terminates the muscle inferiorly. Its uses are the same as those of the gemelli, but it does not act on the thigh.

POPLITEUS.

(*Fémoro-popliti-tibial.*)

Situation and figure.—Flat, thin, and triangular; situated on the posterior and superior part of the leg.

Extent.—From the external condyle of the femur to the tibia.

Division.—Posterior surface, covered by the gemelli; anterior surface, applied on the femoro-tibial articulation. The external border is parallel to the soleus; the internal is free along the superior part of the internal border of the tibia; the superior is fixed to the tibia and fibula. A species of summit terminates this muscle on the posterior part of the external condyle of the femur.

Direction.—Oblique from above downwards, and from without inwards.

Structure and uses.—Tendinous at its attachment to the femur, aponeurotic posteriorly, fleshy in the rest of its extent, it flexes the thigh on the leg, and this on the thigh.

FLEXOR LONGUS COMMUNIS DIGITORUM PEDIS.*(Tibio-phalangettien-commun.)*

Situation and figure.—Elongated, flat, situated on the posterior part of the leg, and inferior of the foot.

Extent.—From the tibia to the last phalanges of the four last toes.

Division.—Posterior surface, covered by the soleus; anterior surface, applied on the tibia. The superior extremity is attached to the superior part of the posterior surface of the tibia; the inferior, after having passed under the arch of the calcaneum, advances under the sole of the foot, becomes united to the square portion, and divides into four small tendons which, traversing the openings presented to them by those of the flexor brevis, are attached to the inferior part of the last phalanges.

Direction.—Vertical on the leg, horizontal on the foot.

Structure and uses.—Tendinous inferiorly, fleshy in the rest of its extent, it flexes successively the phalanges on each other, and extends the whole of the foot.

FLEXOR LONGUS POLLICIS PEDIS.*(Péronéo-sous-phalangettien du pouce.)*

Situation and figure.—Elongated, flat, situated on the posterior part of the leg, and inferior of the foot.

Extent.—From the fibula to the last phalanx of the great toe.

Division.—Posterior portion, covered by the soleus; anterior portion, applied on the posterior surface of the fibula. The superior extremity is fixed to the superior part of the fibula; the inferior passes under the arch of the calcaneum, crosses the direction of the preceding, and

is attached to the inferior part of the last phalanx of the great toe.

Direction.—Oblique from above downwards, and from without inwards.

Structure and uses.—A tendon, concealed very high up in the fleshy fibres, terminates this muscle inferiorly; it is fleshy in the rest of its extent; it flexes the great toe, and, like the preceding, extends the foot.

TIBIALIS POSTICUS.

(*Tibio-sous-tarsien.*)

Situation and figure.—Elongated, situated on the posterior part of the leg, and inferior of the foot.

Extent.—From the tibia and fibula to the os-scaphoides.

Division.—Posterior portion, covered by the two preceding muscles and the soleus; anterior portion, attached to the posterior surface of the tibia and inter-osseous ligament.—The superior extremity, bifurcated for the passage of the anterior tibial vessels, is attached to the superior part of the fibula and tibia; the inferior traverses the arch of the calcaneum, and is fixed to the inferior surface of the scaphoides.

Direction.—Slightly oblique from above downwards, and from without inwards.

Structure and uses.—Tendinous inferiorly, fleshy in the rest of its extent, it extends the foot on the leg, and this on the foot, raising this last from within outwards.

TWENTY-THIRD REGION.

Tarso-métatarsienne.

Muscles on the back and sole of the foot.—The muscles of the foot are distinguished into those of the

back and sole: one muscle only is found on the back—it is the extensor brevis digitorum pedis. The muscles of the sole of the foot are more numerous, and are divided into several layers:—1st, Adductor pollicis pedis, flexor brevis digitorum, abductor minimi digiti pedis; 2d, Flexor accessorius; lumbricales; 3d, Flexor brevis pollicis pedis, abductor obliquus pollicis pedis, transversalis digitorum, flexor brevis minimi digiti pedis; 4th, Seven inter-ossei, of which there are four dorsal and three plantar.

Anatomical Preparation.

Extensor brevis digitorum pedis.—Divide the integuments on the back of the foot in their whole length; turn the flaps inwards and outwards, and this muscle is, as it were, prepared. It will suffice to expose its posterior attachment, and pursue the tendons, which terminate it at the toes. No muscle is near it or conceals it; nor is it enveloped by any membrane; being alone under the integuments, it reposes on most of the tarsal and metatarsal bones, and its preparation merely requires that we isolate it from the place it occupies.

The muscles on the sole of the foot are much more difficult to prepare, as well on account of their number, as of their intimate approximation, and the aponeurotic bands, which keep them united and almost confounded with each other. The skin itself covering them is hard and callous; their preparation is rendered difficult and fatiguing by a fatty and very dense cellular tissue. In order to remove this tissue, we must prolong an incision from the heel to the toes; we must remove with the integuments the cellular tissue until we come to an aponeurosis, which will be recognized by its texture and shining aspect. It will be

necessary to expose this aponeurosis very accurately, in order to study it ; it covers almost immediately the three muscles, which form the first layer of those on the sole of the foot, and at its posterior part, it cannot be separated from them. We should afterwards pass to the preparation of the muscles, which this preliminary dissection will have very materially facilitated. We may, in order to remove the skin from the sole of the foot, cut it in its whole circumference, and then remove it. This latter mode is perhaps preferable to the former.

Adductor pollicis pedis.—This muscle is placed on the internal side of the foot : it may be easily separated outwardly from the flexor brevis communis digitorum ; but in its progress it becomes united to the short flexor of the same toe, and the two muscles appear to make only one. We should, therefore, be content with removing all the fatty cellular tissue, which could interfere with the examination of the adductor ; and this last must be left in place until we are ready to prepare the flexor brevis pollicis pedis.

Abductor minimi digiti pedis.—After the preparation of the preceding, we then pass to that of the abductor minimi digiti pedis, and leave, for a moment, the flexor brevis, which will soon be dissected with the termination of the flexor longus, flexor accessorius, and lumbricales, the preparation of which cannot be separated. The abductor minimi digiti pedis, placed on the external side of the foot, resembles very much the adductor pollicis pedis, and its preparation presents the same circumstances. We must, therefore, observe with regard to this last what we did for the preceding.

Flexor brevis digitorum.—It is especially on this muscle that the plantar aponeurosis is expanded, and it will be necessary to remove it, if this has not already been done.—We may likewise cut across the adductor pollicis pedis, in order to terminate the preparation of the flexor longus, which it covers in part, and the tendons of which have numerous relations with the flexor brevis, as also with the accessorius: for this purpose, we must remove the fatty and abundant cellular tissue, which occupies the arch of the calcaneum, and leave in place the annular ligament under which passes the flexor longus.

Flexor accessorius and lumbricales.—We cannot pursue the ulterior dissection of the long and short flexors, until we have accomplished the preparation of the accessorius and lumbricales. For the first of these muscles, it is absolutely necessary to cut across the flexor brevis, and draw backwards its posterior flap, which conceals in this place the attachment of the accessorius. We must, however, preserve in place the tendons of these different muscles, in order to observe their distribution and numerous relations. The lumbricales, being placed on the continuity of the tendons of the flexor longus, require no other preparation than that demanded by the preceding muscles.

Flexor brevis pollicis pedis.—This muscle, concealed in great part by the adductor of the same toe, demands some little attention in its dissection; but within, it is so united to the adductor, that it is almost impossible to separate it. It is essential to distinguish accurately the point of its posterior insertion, which is into the anterior portion of the calcaneum, and neighboring part of the ossa-cuneiformia.

Flexor brevis minimi digiti pedis.—It will be necessary to pass immediately to the preparation of this muscle, before undertaking the two others placed in the interval.

The flexor brevis minimi digiti pedis, concealed in part by the abductor of the same toe, presents in its preparation the same difficulties as the preceding. We should endeavor, therefore, to distinguish its posterior attachment, which is found at the posterior part of the fifth metatarsal bone.

Abductor obliquus pollicis pedis—abductor transversalis pollicis pedis.—These two muscles are placed between the two preceding, and are entirely concealed by all those of which we have just spoken. The abductor obliquus, situated more posteriorly, is more voluminous than the transversalis, and is easily recognized. Such is not the case with the transversalis, a small elongated muscle, concealed under the heads of the metatarsal bones, and whose insertion into the great toe is confounded with the abductor, and even with the adductor and flexor brevis of the same toe. In order to render the preparation of these two muscles the easier, it will be proper to remove the flexor brevis digitorum, the accessorius, the tendons of the flexor longus, and the lumbricales; these different objects should be detached especially from the heads of the metatarsal bones, and from the first phalanges, to which they are rather intimately united.

Inter-ossei.—As in the hand, the inter-osseous muscles of the foot are placed in the interval of the metatarsal bones, and do not require any other preparation than the entire separation of all the other muscles of the foot. This is more minute than difficult, and only needs time and patience.

Here we terminate the dissection of myology; the muscles of the eye will be treated of under the head of these organs.

Description.

EXTENSOR BREVIS DIGITORUM PEDIS.

(*Calcanéo-sus-phalangeitien commun.*)

Situation and figure.—Flat, thin, divided into four portions anteriorly; situated on the dorsum of the foot.

Extent.—From the calcaneum to the four first toes.

Division.—Its superficial surface is immediately covered by the integuments; its deep-seated surface is applied on the dorsal part of the tarsal bones. The posterior extremity is attached to the anterior part of the external surface of the calcaneum, and to the neighboring part of the astragalus; the anterior is divided into four portions, each of which is terminated by a small tendon, which is fixed, the first to the first phalanx of the great toe, and the three following to the three phalanges of the next three toes.

Structure and uses.—Aponeurotic at its posterior part, tendinous anteriorly, fleshy in the rest of its extent, it aids the extension of the four first toes.

ADDUCTOR POLLICIS PEDIS.

(*Calcanéo-sous-phalangiien du pouce.*)

Situation and figure.—Elongated, flat, situated on the internal part of the sole of the foot.

Extent.—From the calcaneum to the first phalanx of the great toe.

Division.—Inferior surface, covered by the plantar aponeurosis and integuments; superior surface, placed under the flexor brevis pollicis pedis and flexor accessorius.

The posterior extremity is fixed to the internal and posterior part of the calcaneum; the anterior, to the internal and posterior part of the first phalanx of the great toe.

Direction.—Horizontal.

Structure and uses.—Tendinous anteriorly, very slightly aponeurotic posteriorly, and fleshy in the rest of its extent, it draws the great toe inwards and slightly flexes it.

FLEXOR BREVIS DIGITORUM PEDIS.

(*Calcanéo-sous phalangenien commun.*)

Situation and figure.—Elongated, flat, situated on the middle part of the sole of the foot, and divided into four portions anteriorly.

Extent.—From the calcaneum to the second phalanges of the four last toes.

Division.—Inferior surface, covered by the plantar aponeurosis and integuments; superior surface, placed under the accessorius. The posterior extremity is fixed to the posterior part of the calcaneum; the anterior is divided into four tendons, which, pierced near the first phalanges to admit the passage of those of the flexor longus, go to attach themselves to the inferior part of the second phalanges.

Direction.—Horizontal.

Structure and uses.—Four tendons terminate this muscle anteriorly; posteriorly, it is aponeurotic, and fleshy in the rest of its extent. It contributes to the flexion of the phalanges on each other.

ABDUCTOR MINIMI DIGITI PEDIS.

(*Calcanéo-sous phalangien du petit doigt.*)

Situation and figure.—Elongated, flat, situated on the external part of the sole of the foot.

Extent.—From the calcaneum to the first phalanx of the small toe.

Division.—Inferior surface, covered by the plantar aponeurosis and integuments ; superior surface, placed under the flexor brevis of the same toe, and the accessorius of the flexor longus. The posterior extremity is fixed to the posterior and external part of the calcaneum ; the anterior, to the posterior and external part of the first phalanx of the small toe.

Direction.—Horizontal.

Structure and uses.—The structure is similar to that of the adductor pollicis pedis ; it draws the small finger outwards and slightly flexes it.

ACCESSORIUS OF THE FLEXOR LONGUS.

(Comprised in the tibio-phalangettien commun.)

Situation and figure.—Flat, quadrilateral ; situated on the sole of the foot.

Extent.—From the calcaneum to the tendons of the flexor longus.

Division.—Inferior surface, placed on the three preceding muscles ; superior surface, applied on the abductor pollicis pedis. Its borders offer nothing remarkable. It is fixed, on the one hand, to the calcaneum, more in front than the flexor brevis ; and, on the other, it is confounded with the tendon of the flexor longus.

Direction.—Oblique from behind forwards, and from without inwards.

Structure and uses.—Its two extremities are terminated by very small tendons ; fleshy fibres occupy the interval. It aids the action of the flexor longus, in correcting its obliquity.

LUMBRICALES.

(Planti-sous-phalangiens.)

Situation and figure.—Elongated, situated on the sole of the foot.

Extent.—From the tendons of the flexor longus to the four last toes.

Division.—Their inferior portion corresponds to the plantar aponeurosis; their superior portion to the transversalis digitorum pedis. The posterior extremity is fixed to the tendons of the flexor longus; the anterior, to the first phalanges.

Direction.—Horizontal.

Structure and uses.—A long and very small tendon terminates anteriorly each of these muscles, which are fleshy in the rest of their extent. They effect, but feebly, the flexion of the first phalanges.

FLEXOR BREVIS PRIMI DIGITI PEDIS.

(Tarso-sous-phalangien du pouce.)

Situation and figure.—Elongated, flat, situated on the internal side of the sole of the foot.

Extent.—From the calcaneum to the first phalanx of the great toe.

Division.—Inferior surface, placed on the abductor of the great toe; in addition, it presents a depression which lodges the tendon of the flexor longus pollicis pedis; superior surface, placed in the whole extent of the inferior surface of the first metatarsal bone. The posterior extremity is fixed to the anterior part of the calcaneum, and to the neighboring part of the ossa-cuneiformia; the anterior, divided into two portions, is attached to the internal and external tubercles of the posterior part of the first phalanx.

Direction.—Horizontal.

Structure and uses.—Tendinous at its two extremities, fleshy in the interval, it flexes the first phalanx of the great toe.

ABDUCTOR POLLICIS PEDIS.

(*Mètatarso-sous-phalangien du pouce.*)

Situation and figure.—Flat, triangular, situated on the middle portion of the sole of the foot.

Extent.—From the cuboides to the first phalanx of the great toe.

Division.—Inferior surface, placed on the flexor longus, accessorius and lumbricales; superior surface, which corresponds to the interossei; it is fixed, on the one hand, to the cuboides, the neighboring portion of the metatarsal bones, and, on the other, to the internal tubercle of the posterior extremity of the first phalanx.

Direction.—Oblique from behind forwards, and from without inwards.

Structure and uses.—Very slightly tendinous at its extremities, and fleshy in the interval, it draws the great toe outwards.

TRANSVERSALIS DIGITORUM PEDIS.

(*Mètatarso-sous-phalangien transversal du pouce.*)

Situation and figure.—Elongated, situated under the heads of the metatarsal bones.

Extent.—From the metatarsal bones to the first phalanx of the great toe.

Division.—Inferior surface, placed on the tendons of the long and short flexors; superior surface, which corresponds to the inter-osseous muscles. It is attached, on the one hand, to the last metatarsal bones, near their head,

and, on the other, to the external tubercle of the first phalanx of the great toe, uniting intimately with its abductor.

Direction.—Transverse.

Structure and uses.—Almost entirely fleshy, it draws the great toe outwards, and approximates the metatarsal bones to each other.

FLEXOR BREVIS MINIMI DIGITI PEDIS.

(*Tarso-sous-phalangien du petit doigt.*)

Situation and figure.—Elongated, situated on the external part of the sole of the foot.

Extent.—From the fifth metatarsal bone to the first phalanx of the small toe.

Division.—Inferior surface, placed on the abductor minimi digiti pedis; superior surface, which corresponds to the fifth metatarsal bone. The posterior extremity is attached to the posterior part of the fifth metatarsal bone; the anterior, to the base of the first phalanx of the small finger.

Direction.—Horizontal.

Structure and uses.—Tendinous at its extremities, fleshy in the rest of its extent, it flexes the first phalanx of the small toe.

INTER-OSSEI.

They are seven in number, divided into four dorsal and three plantar; and are distinguished by the numerical names of first, second, &c. commencing with the great toe.

DORSAL INTER-OSSEI.

(*Mètatarso-phalangiens-latéraux-sus-plantaires.*)

Situation and figure.—Elongated, flat, situated in the interval of the metatarsal bones.

Extent.—From the interval of the metatarsal bones to the first phalanges of the four last toes.

Division.—Superior surface, covered by the integuments; inferior surface, which corresponds to the plantar inter-ossei; in the first only, this surface corresponds to the abductor pollicis pedis. The posterior extremity, divided into two portions, is fixed to the most remote part of the metatarsal bones; the anterior, terminated by a small tendon, is fixed to the lateral portions of the first phalanges of the four last fingers.

Direction.—It follows that of the interval of the metatarsal bones.

Structure and uses.—Tendinous anteriorly, fleshy in the rest of their extent. The first dorsal inter-osseous draws the second toe inwards, the second draws the same toe outwards, the third draws the third toe outwards, and the fourth draws the toe of the same name outwards.

PLANTAR INTER-OSSEI.

(*Métatarso-phalangiens-latéraux-sous-plantaires.*)

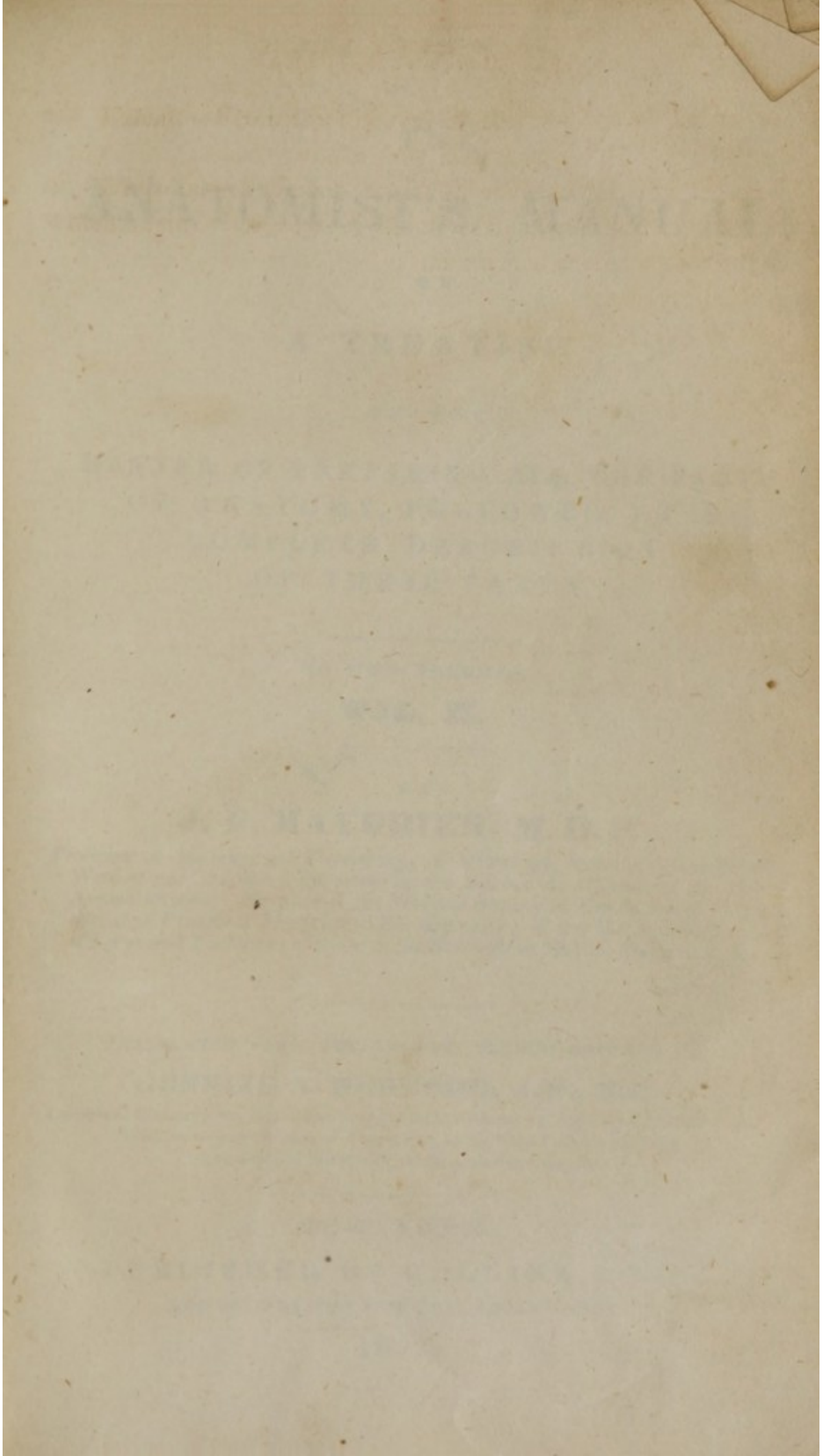
Situation and figure.—Elongated; situated on the sole of the foot.


Extent.—From the interval between the metatarsal bones, the first interval excepted, to the first phalanges of the three last toes.

Division.—Superior surface, in relation with the dorsal inter-ossei; inferior surface, which corresponds to the flexor brevis and transversalis. The posterior extremity is attached to the posterior part of the interval between the metatarsal bones; the anterior is fixed to the lateral parts of the three first phalanges of the toes.

Direction.—It follows that of the interval between the metatarsal bones.

Structure and uses.—Tendinous anteriorly, fleshy in the rest of their extent. The three plantar inter-ossei draw the three last toes inwards.





THE
ANATOMIST'S MANUAL:

OR

A TREATISE

ON THE

MANNER OF PREPARING ALL THE PARTS
OF ANATOMY, FOLLOWED BY A
COMPLETE DESCRIPTION
OF THESE PARTS.

IN TWO VOLUMES.

VOL. II.

BY

J. P. MAYGRIER, M. D. P.

Professor of Anatomy and Physiology; of Midwifery, and the Diseases of Women and Children; Physician to the Bureau de Charité of the 10th Arrondissement; Member of the Medical Society of Emulation of Paris, of that of *Practical Medicine* in the same city; of the Medical Societies of Liège and Toulouse; of those of *the Sciences* in Maçon, Marseilles, &c.

TRANSLATED FROM THE FOURTH FRENCH EDITION, BY

GUNNING S. BEDFORD, A.M., M.D.

Lecturer on Obstetrics, &c. in the New-York School of Medicine; Member of the Medical Society of the City and County of New-York; of the New-York Literary and Philosophical Society; of the Historical Society, &c.

NEW-YORK:

PUBLISHED BY COLLINS & CO.,

AND SOLD BY THE PRINCIPAL BOOKSELLERS.

1832.

THE
ANATOMIST'S MANUAL

A TREATISE

ON THE
MANNER OF PREPARING AND THE PARTS
OF ANATOMY, INCLUDING
A COMPLETE DESCRIPTION
OF THESE PARTS

IN TWO VOLUMES

VOL. II.

J. P. MAYER, M.D.

Professor of Anatomy and Physiology, University of Pennsylvania, Philadelphia, Pa.
Author of "Anatomical Dissections, as Applied to Surgery and Medicine," "Anatomical
Anatomical, &c.," "Anatomical, &c.," "Anatomical, &c.," "Anatomical, &c.," "Anatomical, &c.,"
of the "Anatomical, &c.," "Anatomical, &c.," "Anatomical, &c.," "Anatomical, &c.," "Anatomical, &c.,"
of the "Anatomical, &c.," "Anatomical, &c.," "Anatomical, &c.," "Anatomical, &c.," "Anatomical, &c.,"

NEW YORK
GUNNISON & BEDFORD, 111 N. 3RD ST.

PUBLISHED BY GUNNISON & BEDFORD

1852

THE
ANATOMIST'S MANUAL.

—
SPLANCHNOLOGY.

Preliminary Exposition.

SKELETOLOGY and Myology form, as it were, only the mechanical part of the individual. Their presence is undoubtedly necessary in order to constitute man an admirable and perfect being; but the action of each of these systems may be suspended momentarily, or even entirely annihilated, without essentially altering life and the different functions, which sustain it. Several animals have no osseous system, and others, in small number, it is true, appear to be deprived of muscularity. But wherever life is supported, in all beings in which it is in exercise, we find viscera, vessels, and nerves. These three orders of organs appear, therefore, to be more intimately connected with the maintenance of life; and it is also true that death is always the result of a grave and profound lesion of some of the viscera, and especially the heart, lungs, and brain.

Splanchnology is that part of anatomy, which treats of the viscera or splanchnic organs. These organs are placed in the great cavities of the human body; according to their situation, they may be distinguished into cephalic, thoracic, abdominal, and genital. But this division is not founded on any philosophical arrangement, and is at variance absolutely with the principles of modern physiology

9027

In order to conform in this respect to the views of the most celebrated physiologists, and preserve in this work the plan and distribution which I have constantly followed in my lectures on anatomy and physiology, I shall divide the study and preparation of the viscera, according to their uses and the order in which their different functions are developed and connected. It is indeed time that the vigorous hand of analysis should preside over the labors of anatomists; for too long a period its negligence or forgetfulness has exposed the science of man to all the caprices of human conceptions.

In taking an attentive survey of the various functions of the animal economy, we will be struck with the great difference which exists among them. Some, in a word, whose action appears to be concentrated within the individual, are more particularly connected with the maintenance of life; the others, on the contrary, situated, as it were, out of ourselves, are destined to place us in relation with the bodies or beings which surround us. The action of the former cannot be suspended, annihilated, or even troubled, without there resulting a derangement more or less marked in the general health. The others, on the contrary, have periods of intermission, moments of repose, necessary to maintain their perfect equilibrium. Some, especially destined to assimilate the food, are likewise engaged in separating the superfluous or injurious parts, in order to effect their expulsion. The others, which preside over the locomotive movements, and the formation of sounds, have under their empire the noble attributes of the brain, and the ingenious perceptions of the senses.

The immortal Bichât, whose superior genius had seized all the developements of this great idea, has denominated

the first, functions of organic life, and the second, functions of animal life. These expressions have undergone some modifications, but their application is always the same. Thus, Mr. Richerand, who published at the same time his *Nouveaux Elemens de Physiologie*, calls those functions assimilative, interior, which Bichât denominates functions of organic life; and relative, external functions, those which the same physiologist denominates functions of animal life.

But whatever names we may adopt or prefer, the distinction of the two lives should be rigorously preserved.

Independently of the functions proper to the maintenance of the life of each individual, there are others which assure him the faculty of reproducing his fellow-being, and of creating new individuals. These functions, which require the union of the two sexes, are called generative.—The male and female co-operate equally in the great work of generation, and possess for this purpose different organs, which it is indispensable to examine in both one and the other.

The order, which we shall adopt, demands that we commence with the examination of the digestive organs; to these will succeed the urinary apparatus: its situation in the abdomen, its numerous relations with the organs of digestion, will not permit us to reserve their study for any other place. The product of digestion passing immediately from the chyliferous ducts and thoracic canal into the left subclavian vein, which transmits it to the heart, this course will naturally conduct us to the consideration of the organs situated in the thorax. When the functions of the different organs, which we have just enumerated, are in

perfect equilibrium, and when the organs themselves enjoy all their integrity, life is assured. But in order to endow these parts with sensibility—the precious faculty without which every thing in the economy would be in confusion—the brain and its radiations become indispensable; the senses, those ministers of the intellectual functions, are equally necessary. The study of these different parts will follow, therefore, immediately after that of the organs contained in the abdomen and chest, recollecting, however, that taste and smell are too intimately connected with the history of digestion and respiration, to admit of a separation. Finally, the organs of generation will terminate the table of splanchnology: intended merely for the reproduction of the species, their presence is not rigorously necessary for the maintenance of the individual life. Developed very late in both sexes, and their action being of short duration, their absence or presence does not influence the action of other organs or the *ensemble* of life so immediately, as that the individual could not sometimes be deprived of them, without fatal consequences. Eunuchs furnish numerous examples of this truth, and I possess in my collection the generative organs of a female advanced in age, in whom the uterus was absolutely wanting, and the vagina terminated in a broad *cul-de-sac*, two fingers' breadth from its external orifice.

Such is the most natural and easy mode of studying splanchnology. It now remains for me to give some general precepts respecting the preparation of this part of anatomy, reserving the description of the particular dissection required by each set of organs, until these objects shall present themselves to our notice.

Particular preparation of Splanchnology.

The dissection of splanchnology differs materially from that of myology. This latter is subjected to general precepts, from which we must never depart. We have the same principles, nearly the same instruments, and, as it were, always the same course to pursue. He who can dissect one muscle well, will be enabled, without difficulty, to dissect them all equally well; the manner alone of exposing them differs, as also the particular sections required by some of them. Splanchnology, on the contrary, irregular in the disposition of the parts composing it, presents as many different preparations as there are organs to examine. We cannot do more than give general precepts on this subject, each one being permitted to change, at pleasure, the manner of exposing such and such organs, provided he shall be enabled, by the method he has adopted, to acquire a perfect knowledge of them. We shall not, therefore, give in this place a detailed exposition of the different modes of preparing the organs: we shall content ourselves with indicating, with as much precision as possible, those rules, which have been in general use, and by means of which we will be enabled to expose an organ with greatest facility. The study of splanchnology is very long, particularly when we wish to acquire a perfect knowledge of it, and join to a knowledge of the organs that of their functions. I shall merely remark that most of these organs being situated in cavities more or less profound, which sometimes cannot be reached but with great difficulty, the essential point is to execute accurately the opening of the cavity in which the parts we are about to study are enclosed: we should preserve their relations, either with the surrounding parts, or with themselves: we should be

careful not to divide, rupture, or lacerate the large vessels which penetrate them, or the membranes which cover them; we should obtain a just and precise idea of their situation, figure, color, and density, before subjecting them to any alteration, proper to demonstrate more completely their intimate organization; in fine, we should have at our disposition, and under our hand, the instruments and other objects necessary for their preparation. It is true that, in their ordinary examinations, students do not need so many precautions, since splanchnology is, of all the parts of anatomy, that which they study with the most success.— However, it cannot be denied that it is only by ingenious dissections, that the student will be enabled to have a perfect knowledge, not of the figure of the organs, but of their numerous relations and of the different situations they may affect in such or such position assumed by the individual.

We cannot determine precisely what instruments are necessary for the study and preparation of splanchnology: they are numerous, and their figure very varied; this, moreover, will depend on the person who dissects. I shall merely remark that we must have all the different kinds of scalpels, several hooks, scissors, saw, mallet and chissel; pipes, sponges, thread, bellows, and some other articles less important, which will be mentioned when it becomes more particularly necessary to speak of them.

DIGESTIVE ORGANS.

These organs are composed, 1st, of the mouth, which contains the organs for the prehension of the food, mastication, salivation, and deglutition; 2d, of the alimentary canal, composed of the esophagus, stomach and intestines; 3d, of the liver, organ for the secretion of bile; 4th, of

the pancreas, organ for the secretion of the pancreatic juice ; 5th, of the spleen, the uses of which are unknown ; 6th, of the urinary organs, consisting of the kidneys, ureters, bladder, and urethra ; 7th, of the peritoneum, from which originate the mesentery and epiploons.

1st,—THE MOUTH AND ITS ACCESSORIES.

The mouth may be distinguished into anterior and posterior. The anterior comprehends the lips, teeth, gums, palate and its membrane, as also the glands which cover it, the tongue and salivary glands properly so called. In the posterior, called *arrière-bouche* or pharynx, are observed the isthmus of the throat, the velum palati and uvula, the pillars of the velum, the amygdalous glands, and eustachian tubes. Such is the order in which the different parts of the mouth are to be studied.

ANTERIOR MOUTH.

Anatomical Preparation.

Lips.—They do not exact any preparation ; placed on the exterior, it will suffice to throw the eye over these parts in order to have a knowledge of their situation and relations. To the study of the lips, we should join that of the cheeks, and beard which is found in great part spread over these different objects. Females being deprived of this latter, it would be well to procure a head of both sexes, in order to appreciate the differences, which characterize them in this particular.

Teeth and gums.—It is indispensable to separate the lips in order to perceive the objects concealed by them.—In addition to this, we should make an incision from right to left in the direction of the commissure of the lips, for the

purpose of rendering the teeth and gums more apparent.— It will be necessary, as far as this will be possible, to have a head, the jaws of which are furnished with all their teeth : this is the best means of forming an accurate idea of the arrangement of these little bones, of their uses, and especially of the necessity of their presence to the perfection of the mouth. If we wish merely to acquire a knowledge of the human teeth, it will suffice to procure heads of individuals of different ages ; but if it should be desired to make comparisons between those of man and animals, we should obtain heads or jaws of those the most known— such as the dog, cat, horse, &c., nothing being more varied and interesting than the anatomical and physiological history of the teeth, in all animals furnished with them. We may, for the same reasons, plunge the teeth into certain acids and allow them to remain some time in order to appreciate their intimate structure.

Palate and glands.—The palatine membrane being exactly applied over the bones, we can study it in place with great facility, and comprehend, in this examination, that which covers the osseous palate, as well as that which, under the name of membrane of the gums, envelopes a part of the teeth and encloses them solidly in their alveolar processes. Such is not the case with the palatine, buccal, and molar glands, with which this membrane is so abundantly furnished : frequently they cannot be perceived but with the aid of a magnifying glass. In order to render them more sensible, we may macerate, for some time, a portion of this membrane in ordinary water, or plunge the parts to which it adheres, into boiling water, which will be found to be more expeditious. They may likewise be examined in a living animal, that has suffered for a long time

from hunger, and to which food, at various periods, has been presented, but continually withdrawn.

Tongue.—This part is exposed by prolonging the incision of the commissure of the lips posteriorly; and drawing its point outwards. The glands covering it may be examined with the glass, although they are in general larger and more prominent than those of the palatine membrane, which circumstance will permit us to study them with the naked eye.

Salivary glands.—They are three in number—the parotid, maxillary, and sublingual. The first is placed in the depression of the same name, which is observed behind the branch of the inferior maxillary bone. In order to expose it, make a longitudinal incision of the integuments, as in preparing the masseter muscle; in separating the flaps, this gland will be recognized by its very pale red color, irregular form, &c. Its excretory duct travels parallel to the zygomatic apophysis, one or two fingers' breadth below. When once exposed and recognized, it will be followed without difficulty as far as its entrance into the integuments of the cheeks, which it pierces, as well as the buccinator muscle, nearly as high up as third superior molar tooth.

The *maxillary* gland, concealed under the angle of the inferior jaw, is not as voluminous as the preceding; but its form and color are the same. It is sometimes united to the *sublingual*, which is placed under the body of the jaw, and covered by the mylo-hyoid muscle. An incision of the integuments, in the direction of the digastric muscle, will suffice to expose both of them. It then only remains to follow the excretory duct of the *maxillary*, which passes across the *sublingual*, opens into the point of the tongue,

and pierces at this spot the internal membrane of the mouth. We sometimes observe, in the living subject, the saliva flow from the two tubercles, which terminate the salivary ducts of this gland.

The *sublingual* has several small excretory ducts, which become lost in that of the *maxillary*, and which cannot be distinctly seen except by the aid of an injection made with mercury.

Description.

THE MOUTH.

Os. of the Latins, *Stoma.* of the Greeks.

Situation and relations.—Placed at the upper portion of the alimentary canal, the mouth, of a quadrilateral form, corresponds in front to the lips, behind to the isthmus of the throat, and velum palati, above to the palatine arch, below to the tongue, and on the sides, to the internal portion of the cheeks.

Division.—Anterior paroi, formed by the lips, distinguished into superior and inferior; and by the teeth the description of which belongs to osteology (see Vol. I. p. 56); posterior paroi, formed by the velum palati, its pillars, the uvula and isthmus of the throat, the description of which will be given farther on; superior paroi, formed by the palatine arch and membrane which covers it; inferior paroi, on which is observed the tongue (*lingua* of L., *glossa* of G.,) a soft, flat organ, elongated from behind forwards, thick at its posterior part, which is called its base; thin and pointed at its anterior part, called the summit or apex. Its superior surface is covered by a thick membrane, on which are observed numerous glands termed papillæ; its inferior portion, occupied by the muscles which form it in great part, is free in front, and presents the orifice of the

excretory ducts of the maxillary and sublingual glands. Its base sustains the larynx, its apex is free. The tongue is the organ of taste, and one of the most powerful agents in deglutition. The lateral parois of the mouth are formed by the integuments of the cheeks, and present at the height of the third molar tooth of the upper jaw, the orifice of the excretory duct of the parotid gland.

Structure and uses.—The maxillary bones, superior and inferior, and those of the palate, as also the teeth, constitute the solid parts of the mouth. Its whole interior is furnished by the palatine membrane, of a mucous nature; soft and flexible on the internal part of the cheeks, this membrane is hard and resisting on the alveolar processes, where it forms the gums; rough and thick on the tongue, numerous glands cover the whole of its free surface; they bear the names of buccal, palatine, lingual, according to the place they occupy; they secrete a thick, viscid humor, proper to keep up the suppleness and humidity of the different parts of the mouth, and to mix with the food during mastication.

The uses of the mouth are to serve for the prehension of food by the lips, mastication by the teeth, the commencement of deglutition by the tongue, and the retention of the food until it becomes mixed with the saliva; finally, for the articulation of sounds. The organ of taste is not found exclusively in the tongue or its membrane, but the whole interior of the mouth is provided with it in a greater or less degree.

SALIVARY GLANDS.

The parotid.—*Situation and relations.* Placed in the parotid depression, between the branch of the inferior jaw and the neighboring part of the mastoid apophysis, it is in

relation at its superficial portion with the integuments, and at its deep-seated with the pterigoid muscles, temporal artery, and facial nerve. An excretory duct proceeds from its anterior part, and terminates at the height of the third superior molar tooth, piercing the integuments of the cheeks at this point, as also the buccinator muscle.

Structure and uses.—Several glandular grains, of extreme smallness, give rise to lobulated masses, the union of which constitute the *ensemble* of the gland. It furnishes an abundant fluid, called saliva, which penetrates the food during mastication, aids its conversion into a paste, which facilitates its deglutition, and imparts to it the first degree of animalization.

The maxillary.—Situation and relations.—This gland, placed under the angle of the inferior jaw, is covered, on the one hand, by this bone, and, on the other, is supported on the digastricus. An excretory duct arises from its anterior portion, travels along the body of the jaw, passes through the sublingual gland, and pierces the internal membrane of the mouth at the side of the frenum of the tongue.

Structure and uses.—Perfectly similar to the parotid gland as regards its structure and uses; but as it is less voluminous, it furnishes less saliva.

The sublingual.—Situation and relations.—Of a more irregular form than the two preceding, the sublingual is placed behind the body of the jaw, between the mylo-hyoideus and genio glossus. Its excretory ducts, very delicate, are difficult to perceive; some of them are lost in the duct of the maxillary, the others pierce the internal membrane of the mouth.

Structure and uses.—The same as in the two preceding glands.

ARRIÈRE-BOUCHE.

Anatomical preparation.

The *arrière-bouche* is that large cavity, which is observed beyond the isthmus of the throat. It still bears the name of pharynx. Its extent, from six to eight fingers' breadth, measures from the base of the cranium to the height of the larynx.

In order to see the *arrière-bouche* distinctly, it will be necessary to make a section similar to the one indicated for the preparation of the muscles of the pharynx and velum palati (*see Vol. I. p. 264 et seq.*). In this section, we also remove the larynx, which certain anatomists describe immediately after the pharynx. It cannot be denied that this method presents some advantages; but it interrupts all the physiological connexion, and deviates too much from the plan we have adopted; we, therefore, feel ourselves authorised to reserve the study and preparation of the larynx until we shall speak of the respiratory organs.

The section indicated above being executed, we must carefully remove the cellular tissue, and cut the pharynx in the whole extent of its posterior part. This incision will permit us to see, in a general manner, and in their *ensemble*, all the parts which compose the *arrière bouche*, which are: above and in front, the opening of the posterior nares, as also the eustachian tubes; lower down, the velum palati, its pillars, the amygdalous glands and uvula; still lower, the isthmus of the throat, the base of the tongue, and superior orifice of the larynx, called glottis, which is covered by a species of thin, moveable cartilage, called epiglottis. These different objects do not require any preparation; it is their respective situations which it is most important for us to understand. The lateral and posterior

parts are formed by the constrictors, the description of which will be found in *Vol. I. page 264, et seq.*

Description.

ARRIÈRE-BOUCHE, OR PHARYNX.

Os. posterius, Guttur L.

Situation and relations.—Placed at the posterior part of the mouth properly so called, the pharynx occupies the superior portion of the neck, and corresponds above to the base of the cranium, below to the esophagus, behind to the vertebral column, in front to the posterior nares, velum palati and larynx, and on the sides to the carotid arteries and internal jugular veins.

Division.—Posterior paroi, muscular, formed by the constrictors, and offers nothing remarkable: anterior paroi, where are observed the velum palati, its pillars, and the amygdalous glands; above and on the sides, the orifice of the eustachian tubes.

The velum palati (*septum staphylin*) is a moveable, fleshy, quadrilateral partition, interposed between the anterior and posterior mouth, formed by several muscles, the extreme mobility of which makes it perform a very interesting part in deglutition. Above, the velum is attached to the palatine arch; below, it is free and presents in the centre a fleshy button, called the uvula; on the sides, it offers two fleshy bands, called its pillars, distinguished into anterior and posterior, in the interval of which is observed the amygdalous gland, reddish, and of an elongated form; it secretes a viscid fluid, proper to lubricate the surrounding parts, and to facilitate the passage of the food during deglutition.

Structure and uses.—The pharynx is almost entirely muscular. Its internal surface is covered by a membrane of variable thickness, partaking of the nature of mucous membranes, and continually lubricated with an abundant fluid. Exteriorly, the pharynx is united to the neighboring parts by cellular tissue. Its uses are numerous and very important, and all refer to deglutition.

2d. ALIMENTARY CANAL.

It is composed of the Esophagus, stomach, and intestines.

Anatomical Preparation.

Esophagus.—This portion of the alimentary canal is the most embarrassing to prepare, on account of its profound situation and the organs behind which it is placed. We cannot expose perfectly the Esophagus, without sacrificing in part the lungs and heart. I am in the habit of abandoning the preparation and study of it until after those of the organs contained in the chest. No matter which rule is adopted, the following are the precautions necessary to be taken.

The Esophagus and pharynx constitute one and the same canal, the division of which is arbitrary, and the line of demarcation difficult to determine. The one commences where the other terminates, and this distinction occurs nearly at the height of the inferior part of the larynx.—We will recognise the Esophagus by the narrowness of its canal, compared to the capacity of the pharynx, by its external aspect being less red, and its separation from the surrounding parts. It measures from the termination of the pharynx to the stomach. In its course it is applied constantly on the vertebral column, concealed in the neck by the trachea, and in the chest by the heart and left lung.

It will be necessary, therefore, to open this cavity in order to have a good view of it, to raise the heart and left lung, and draw these latter to the right without detaching them.

If we decide to remove the lungs and heart, the preparation of the Esophagus will offer more interest, and will leave nothing further to desire. In this case, make a sort of circular section of the whole anterior paroi of the chest, which must extend as far as the abdomen; the lungs and heart are then easily removed; but we should leave in place the large vessels, as also the trachea, in order that we may have an idea of the relations existing between these parts and the Esophagus.

We may, in order to lose none of the relations of the Esophagus, expose it at its posterior portion. For this purpose, we must saw the ribs near the transverse apophyses of the vertebræ, separate the seventh cervical from the sixth, and the last dorsal from the first lumbar; the portion of the vertebral column, which we have just isolated is then to be removed; in this way, we shall observe all the relations of the Esophagus. We shall even have a more exact idea of its passage through the diaphragm, but this preparation is long and difficult, and requires that we should sacrifice several cadavera in order to accomplish it.

Stomach.—The preparation of this musculo-membranous bag, absolutely requires that we open the abdominal cavity as was indicated (*Vol. I. p. 162*). In separating the superior flap of the left side, we shall have the major part of the stomach exposed. But in order to have a perfect idea of its situation and relations, it will be necessary, in addition, to detach the four or five last false ribs, under which it is concealed in its state of vacuity. The liver also covers it in part on the right side; such are its relations when emp-

ty ; but when we blow into it, it then assumes a greater capacity, proceeds from beneath the ribs and liver, and presents in a more exact manner the figure peculiar to it. I would not advise, however, to dilate the stomach before taking a general view of the intestines, and even of all the organs situated in the abdominal cavity. The great extension of the stomach and intestinal tube when inflated deranges the relations which these parts have with each other and those surrounding them, and there is nothing but confusion in the future examination of the abdominal organs. Such is not the case, when these preliminary precautions have been taken ; it then becomes indispensable to inflate the intestinal tube ; we shall even derive several advantages from it, which its examination will make us fully appreciate. Thus, we shall readily see, by this process, the manner in which the stomach, progressively inflated with air, distends the two feuilletts of the epiploon, and thus approximates its vessels, which ultimately are applied on itself. The same thing is observed between the stomach and spleen, which, more or less remote from the great cul-de-sac of the stomach, when this is empty, approaches it in proportion as it is distended with air, so as to be immediately applied on this organ.

Before passing to the preparation of the intestines, we should distinguish accurately the two orifices of the stomach ; the superior, or cardiac, merely presents arbitrary distinctions ; the inferior, on the contrary, possesses a character which is peculiar to it ; it is recognised by a species of circular bourrelet, which forms its line of demarcation between the stomach and first of the small intestines ; it is the pylorus.

We should likewise examine the interior of the stomach, which cannot be done without opening it to an extent more or less considerable. The arrangement of its different tunics should not be neglected. There are no precepts to be given for the first object, but for the second it is absolutely necessary that the stomach be considerably distended; without this precaution it will be impossible to attain it.— However, for both one and the other, we must wait until after having examined the entire alimentary canal.

Intestines.—The preparation of the stomach leaves scarcely any thing else to be done for the intestinal tube. Exposed by opening the abdominal cavity, it only remains for us to recognise the six divisions, and preserve the place and relations, which nature has assigned them. The first, called duodenum, occupies the profound part of the epigastric region; it is concealed by a portion of one of the large intestines, called transverse colon, which we must move upwards, as also the liver and stomach; we should pull gently downwards the jejunum and ileum, and then follow the duodenum, which proceeds at first parallel to a glandular body (the pancreas), and afterwards travels along the vertebral column, and loses itself in the jejunum, after a length of twelve fingers' breadth.

The duodenum will be recognised by its capacity, greater than that of the following intestines, by its profound situation and the insertion of the ductus choledochus and pancreaticus, which takes place on the right side of the intestine, two or three fingers' breadth from the pyloric orifice of the stomach.

The other intestines do not present any very great difficulties. The jejunum and ileum, the longest of all, occupy the umbilical and hypogastric regions. The fourth,

(the cœcum) first of the large intestines, is nothing more than a species of bag, or cul-de-sac, lodged entirely in the right iliac cavity. The fifth, (the colon) rather considerable in length, surrounds, as it were, the whole abdominal cavity : it terminates towards the left side of the pelvis by the rectum, placed in the whole extent of the middle portion of the sacrum ; the name indicates its direction.

Several valves are found in the cavity of the intestines ; the pyloric valve, and that of the cœcum or of Bauhin, are the most remarkable. The best mode of observing them is to inflate the intestinal tube, and allow it to dry in this state for two or three days, and then to open the tube, regarding more particularly the pyloric valve and that of Bauhin, which is found between the cœcum and colon, and which forms their line of separation. We may also, by plunging perpendicularly a portion of the intestines into water, render sensible any of the different valves, and principally that of the cœcum.

But if we wish to have a more exact idea of it, we may remove the intestinal portion found between the termination of the ileum and the commencement of the colon.— This latter must have a ligature passed around it, and then the piece distended by blowing into that portion of the ileum, which has been cut ; the whole must be allowed to dry, and then opened cautiously, making the incision from the colon to the cœcum, on the right side. On looking into the interior, we shall see a broad semilunar fold ; it is the cœcal valve.

The inflation of the intestines and their state of dryness will also render the examination of their different tunics easy ; it would answer the same purpose, to introduce a circular and solid body into a portion of the intestinal tube,

and use it as a point of support for the dissection of the different tunics.

The mesentery and epiploons do not require any preparation ; the former is the common link, which retains the intestines in their respective position ; the latter, three in number, are expanded : the first (the large epiploon) over the mass of intestines ; the second, under the name of gastro-hepatic epiploon, between the liver, stomach, and arch of the colon ; the third, the smallest of all, is observed in the right iliac region : it bears the name of colic epiploon.

In the preparation of the intestines, I have not alluded to the manner of exposing the ductus choledochus, as also the pancreaticus, which likewise empties into the duodenum ; but this shall be indicated when we describe the liver and pancreas, to which they appertain. I shall only remark, that we should leave the duodenum in place, even after its examination, in order to have a more correct idea of the direction and relations of the two ducts, which penetrate its interior, and especially of the ductus choledochus.

Description.

ESOPHAGUS.

Gula, L. Oisophogos, G.

Situation and relations.—Along the vertebral column, between the pharynx and stomach, behind the trachea in the neck, the left lung and head in the chest.

Figure.—Elongated, cylindrical, slightly flat from before backwards.

Structure and uses.—Three tunics enter into its composition. The first, external, common, cellular ; the second, muscular, divided into two planes, one, external, formed of longitudinal fibres ; the other, internal, of trans-

verse fibres ; the third, internal, membranous, villous, partaking of the nature of mucous membranes. Each of the tunics is separated by a layer of cellular tissue, and their interior is furnished with numerous glands.

The uses of the Esophagus are—to transmit the food from the pharynx to the stomach, which is precipitated not by its specific weight, but pushed downwards by the successive contractions of this canal.

STOMACH.

Ventriculus, L. Gaster, G.

Situation and relations.—In the abdominal cavity, of which it occupies the left hypochondriac region ; in front, it corresponds to the last false ribs, liver and abdominal parietes ; behind, to the pancreas and aorta ; above, to the liver and diaphragm ; below, to the arch of the colon ; on the left, to the spleen, and on the right, to the liver.

Figure.—Somewhat similar to a cone curved from right to left, the base of which corresponds to the left, and the summit to the right.

Division.—Superior portion, inclined forwards ; inferior portion, inclined backwards. Anterior border, called the great curvature of the stomach, which receives the insertion of the large epiploon ; posterior border, called the small curvature, which receives that of the small epiploon. A large extremity, turned to the left, corresponding to the spleen ; a small extremity turned to the right, and corresponding to the duodenum. In addition, there are two orifices— one, superior, called cardiac, is continuous with the Esophagus, and corresponds to the middle and superior part of the large extremity of the stomach ; the other, inferior, called pyloric, is continuous with the duodenum, and establishes

very exactly the line of demarcation between this intestine and the stomach.

Structure and uses.--A number of tunics equal to that of the Esophagus enters into the composition of the stomach. But here, what is termed the external tunic is nothing more than a prolongation of the peritoneum; it is the serous tunic of the moderns. The muscular tunic offers a third plane of fibres, which, under the figure of two long fleshy bands, are thrown around the large extremity, likewise called cul-de-sac of the stomach. Finally, the mucous tunic presents several remarkable dispositions:—1st, its internal surface, continually lubricated by an abundant mucous fluid, is, in its natural state, of a reddish color, interspersed with several bluish spots; 2d, this internal surface likewise presents several folds, which are the result of the contractions of the muscular tunic; 3d, there are observed on it numerous villousities, or common rendezvous for the vessels of the stomach and numerous orifices, some of which are the orifices of the absorbents, and the others correspond to the mucous follicles, situated in this tunic.

Among the folds or *rides* on the internal surface of the stomach, there is none more considerable than that on the inferior extremity of this viscus; it is called the pyloric valve: it is formed, not only by a prolongation of the mucous tunic, but there is also a fibrous *bouirelet* of a circular form, in which anatomists have supposed they recognized fleshy fibres.

The uses of the stomach are very numerous, and from their accomplishment result the most important phenomena of digestion. The food, brought through the Esophagus into the stomach, there undergoes an infinity of changes,

all of which tend to transform it into a homogeneous mass, of a grayish, lactescent white, proper to pass through the pyloric orifice. Several combined causes effect these great changes; the most important are, heat, humidity, the presence of different fluids, the gastric in particular, the contractions of the stomach, aided and rendered more efficacious by those of the diaphragm and abdominal muscles, &c.

INTESTINES.

General considerations.

They form, in their *ensemble*, the intestinal canal, the length of which is very considerable, and is six or seven times that of the individual to whom they belong. The intestines occupy nearly the whole of the abdominal cavity, and they are folded on themselves several times; they commence at the pylorus and terminate at the anus. The difference in the size of this portion of the alimentary canal, has induced authors to distinguish it into several parts, all of which bear different names. The first intestines, more delicate, called small intestines, have received the names of duodenum, jejunum, and ileum. Their absolute length exceeds considerably that of the others. These, called large intestines, bear the names of cæcum, colon, and rectum, and they form scarcely a fifth of the whole length of the intestinal canal.

The mass of intestines is attached to the vertebral column and neighboring parts, by means of a duplicature of the peritoneum, called mesentery, the description of which, as also that of the peritoneum itself, and epiploons emanating from it, will be found at the end of the article on the digestive organs.

DUODENUM.

Situation and relations.—In the epigastric region: from the pylorus to the second lumbar vertebra, forming several curvatures. It corresponds with the colon and liver in front; with the pancreas, and inferior vena cava behind; on the right, with the gall bladder and kidney of the same side; on the left, with the pancreas and ductus choledochus and pancreaticus.

Figure.—Elongated, cylindrical.

Structure and uses.—See Vol. I. page 320.

JEJUNUM.

Situation and relations.—In the umbilical region, beneath the arch of the colon, above the ileum, behind the abdominal parietes, in front of the mesentery and vertebral column.

Figure.—Elongated, cylindrical.

Structure and uses.—See Vol. I. p. 320.

ILEUM.

Situation and relations.—In the hypogastric region, beneath the jejunum, above the bladder and rectum; behind the abdominal parietes, in front of the vertebral column and mesentery.

Figure.—Similar to the two preceding.

Structure and uses.—See Vol. I. page 320.

CÆCUM.

Situation and relations.—In the right iliac fossa, beneath the ascending colon and ileum.

Figure.—A species of cul-de-sac, of an irregular form, larger than that of the colon and ileum, with which it is

continuous. This intestine offers, in addition, a vermiforme appendage, four or five fingers' breadth in length, which originates from its inferior portion.

Structure and uses.—See Vol. I. page 320.

COLON.

Situation and relations.—This intestine takes its origin from the cœcal valve, ascends the right lumbar region, as far as the liver, then proceeds transversely along the great curvature of the stomach, from which it is separated by the great epiploon, as far as the neighboring part of the spleen, descends into the left lumbar region, in front of the kidney of the same side, to the superior part of the sacrum, where it terminates; whence result four portions, which bear different names. The first, which is on the right, is called ascending colon, or right lumbar portion; the second, the arch of the colon, or transverse colon; the third, which is on the left, descending colon, or left lumbar portion; finally, the fourth, which from the left iliac fossa terminates in the rectum, the iliac colon, or S of the colon.

The relations of these four portions of the same intestine with the surrounding parts, are as follow:—

The ascending colon extends from the cœcum to the gall bladder; it corresponds in front to the small intestines, behind to the quadratus muscle and right kidney, and within to a duplicature of the mesentery.

The arch of the colon extends from the environs of the gall bladder to the large extremity of the stomach; it corresponds above to the stomach, below to the small intestines, in front to the great epiploon, and behind to the mesentery.

The descending colon extends from the environs of the spleen to the right iliac fossa: it corresponds in front to the jejunum, behind to the quadratus muscle and left kidney, and within to the mesentery.

The S of the colon extends from the commencement of the left iliac fossa to the superior part of the sacrum, forming several curvatures.

Figure.—Similar to that of the other intestines.

Structure and uses.—See Vol. I. p. 320.

RECTUM.

Situation and relations.—The rectum, the last of the large intestines, forms the termination of the intestinal canal. It is situated in the excavation of the pelvis, and extends from the end of the S of the colon to the anus. Behind, it corresponds to the sacrum, of which it occupies the whole anterior surface; in front, to the bladder in the male, and to the uterus in the female.

Figure.—Similar to that of the other intestines.

Structure and uses.—Here will be given all that we have to say concerning the structure and uses of the intestines in general.

The organization of the intestines is nearly the same in all; however, it presents some differences, which it is important to mention. All, except the duodenum, possess an external, serous tunic, which is a prolongation of the peritoneum. The absence of this tunic in a great part of the duodenum, permits this intestine to assume a considerable volume, for which reason the name of second stomach (*ventriculus succenturiatus*), has been given to it.—This disposition, favorable to the accomplishment of diges-

tion, permits the food to remain a longer time in the duodenum, and to undergo the alterations and changes effected by the biliary and pancreatic fluids.

This tunic furnishes to the colon three species of bands, which pervade nearly its whole length, and which give rise to several projections, from which this intestine derives one of its principal characteristics. The cœcum presents the same disposition. In the other intestines, this tunic offers nothing remarkable; but it must not be forgotten that it does not envelope the intestines in their whole extent, and that the place through which the vessels penetrate is deprived of it.

The muscular tunic does not present any sensible difference in the extent of the intestinal tube; it is composed of two planes of fibres, which, in the external, proceed longitudinally, and, in the internal, circularly. The length of both is very variable, and difficult to determine. The inferior extremity of the rectum is deprived of them; but they are replaced by two muscles; these are the sphincters, which were described in the chapter on myology.

The third and last tunic is that which authors denominate villous; but more exact ideas concerning its uses have given to it, in these latter times, the name of mucous membrane. It lines the whole interior surface of the intestines, and presents, in each of them, certain peculiarities worthy of notice.

In the duodenum, besides several villosities, this membrane offers a number of folds, called *valvulæ conniventes*. We likewise observe in it numerous glands, which bear the name of *glands of Brunner*. Finally, two or three fingers' breadth from its origin, the duodenum presents interiorly an oblong tubercle, pointed at its extremity, which is the

common orifice of the ductus choledochus and pancreaticus. In the jejunum and ileum the valvulæ conniventes, at first very numerous, become more and more rare, in proportion as they are examined in the ileum. The glands covering them are called the *glands of Peyer*. As for the rest, the number and disposition of the villosities are nearly the same as in the duodenum.

As we advance in the examination of the internal tunic of the large intestines, we perceive that it is less abundantly furnished with villosities, valves, and especially glands: these last are there separated, and their volume is more considerable than in the small intestines; but we should not omit seeing the form and disposition of the cæcal valve, and of the appendage of the same intestine: these different objects claim all the attention of the anatomist.

The uses of the intestines are the more important to be known, as it is during its sojourn in these organs, that the food is definitively elaborated, and that, under the form of a white, sweet, lactescent fluid, it is more especially destined to the nutrition of the individual; finally, in passing from the stomach into the duodenum, it there is subjected to the powerful action of the biliary and pancreatic juices, and it is, during its passage into the intestine, as well as into the jejunum and ileum, that it abandons the greatest part of its nutritive elements. Arrived in the cæcum, the alimentary paste is, in great part, deprived of its chyliferous and nutritive particles, on which account it acquires a greater degree of consistence and solidity. This residue of the food proceeds gradually through the cæcum and colon. The cæcal valve, which permits the passage of this material from the cæcum into the colon, opposes a regur-

gitation, and forces it to travel by degrees through the whole extent of the colon, and to precipitate itself *en masse* into the rectum, from which it is expelled by the simultaneous action of the muscles of the bas-ventre and diaphragm. At this time, the fœces are hard, dry, exhaling a fetid odor, and completely deprived of nutritive fluids. Such is, in a few words, the accomplishment of digestion, the the product and result of which is the nutrition of the individual.

The expulsion of urine, which always accompanies that of the fœces, is produced by the same causes. The formation of urine, like that of the fœces, is the result of digestion, and both the one and the other are its residue. It is for this reason that we have thought proper to connect the study of the urinary and digestive organs, not, as some anatomists have done, because the organs belonging to both are situated in the same cavity, but because their functions are similar, and have the same principles for their cause.

3d, 4th, AND 5th BILIARY AND PANCREATIC ORGANS.

We shall here describe the liver, pancreas and spleen.

Anatomical Preparation.

Liver.—This is one of the easiest organs to examine, after having opened the abdominal cavity. Concealed in part by the last ribs of the right side, it will suffice to break them, and carry them outwards in order to see the entire of the liver; but it is also the viscus, the relations of which are the most numerous and important to understand. Its diseases, the influence it exerts on the surrounding

parts, its volume, weight, and important functions will always render its examination as curious as profitable. The anatomist, the surgeon, and especially the physician, may fall into serious errors, and commit unpardonable faults, by neglecting to study this viscus.

As I have already remarked, the liver will be perfectly exposed, after having removed the last false ribs. But this superficial knowledge will not suffice; we must examine with care its extent, from above downwards, and from right to left; we must also see the ligaments by which it is attached and fixed in place. They will be found on its convex surface, in its great fissure, and on its two extremities. The first bears the name of coronary ligament; the second is the suspensory or falciforme ligament; the two lateral have no particular names. We should next examine the relations of the liver with the stomach, spleen, transverse colon, pancreas, and right kidney. These different parts do not require any particular preparation. Such, however is not the case as regards its excretory duct, the objects placed on the posterior surface, and especially its intimate structure. The preparation of the hepatic duct is so exceedingly difficult, that many students frequently neglect to examine it. In order to find it, we should draw upwards and to the right the inferior and cutting border of the liver; the colon and stomach should be pulled at the same time in a contrary direction; if then we cautiously detach the loose cellular tissue found in the interval, as also a portion of the gastro-hepatic epiploon, we shall have the hepatic duct under the scalpel. A yellowish taint, the consequence of an exudation of bile, spread on the surrounding parts, will indicate the place in which it is to be found.

This duct and the choledochus, preserve very intimate relations with the vena portæ and hepatic artery. We will rarely err, if it be remembered that the vena portæ is very voluminous, bluish, and situated much more profoundly; that the artery is placed on the left of the duct, which it in part covers; but the best means of recognising it, is to take it at its insertion into the duodenum, and thus follow it in a retrograde manner to the liver, observing that it unites on its way with the cystic duct. It is the union of the latter with the hepatic that forms the ductus choledochus.

The simple inspection of the gall-bladder will suffice to convey an idea of its situation and relations. It requires no preparation; it is merely necessary to examine accurately the direction of its duct, as also its union with that of the liver for the formation of the ductus choledochus.

When satisfied with all these preparations, we may remove the liver, and detach it from the objects with which it contracts very strong adhesions, in order to study more advantageously its details, and especially those of its concave surface, which are very numerous.

The minute preparations of the liver consist in injecting its different vessels and duct with mercury. We may likewise make these injections with alcohol or resinous substances, not forgetting to color them, in order that we may follow the direction of the injected vessels; thus we may inject the arteries with red, the veins with black, the hepatic duct with blue, &c. The object of these injections is to examine the manner in which the sanguineous vessels anastomose, and in what way these last combine with the extremities of the biliary ducts.

As, in these latter times, a new membrane has been discovered in the liver it becomes indispensable to point out the manner of rendering it visible. An attentive dissection is necessary to discover it. For this purpose, we must cautiously divide that portion of the peritoneum, which covers the liver at the point in which the suspensory ligament is inserted into this organ. Then, in gently raising the peritoneum with the handle of the scalpel or simply with the fingers, we shall observe beneath the membrane in question, which is evidently cellular.

Spleen.—If we raise the stomach, and draw it forwards and to the right, we shall discover the spleen without difficulty: but in this way, its situation is changed, and we shall have but an imperfect idea of its relations. It is better to leave the stomach in place, break the false ribs of the left side, as was done on the right for the liver, and then the spleen will be exposed. The size and extent of this viscus vary considerably. Sometimes reduced to a very small volume, the spleen appears to be nothing more than a small inorganic mass applied to the large extremity of the stomach; sometimes thick, elongated, and very broad, it occupies a considerable space. No matter how numerous its varieties may be, we should not lose sight of the principal object in its examination—viz., its numerous relations with the stomach, as well by its situation, as the communications established between these two organs by means of *short vessels*, which should be preserved. This object will not be attained if, taking these vessels for cellular tissue, we lacerate them under the pretext of getting a better view of the spleen. In examining the interior of a spleen inflated and somewhat dry, we will find it composed of cells communicating with each

other; these cells themselves communicating with the veins, as is proved by the passage of the air from one into the other; we may be convinced of this by repeating this experiment, or even by injecting the spleen with the substances ordinarily used in such cases.

Pancreas.—This gland, situated in the profoundest portion of the epigastrium, is concealed by the liver, stomach and colon, and cannot be seen until these different objects have been previously removed. This is the last organ we should occupy ourselves with, and I would recommend to defer its preparation until after the definitive examination of all the other abdominal viscera. It will be necessary only to leave the portion of the duodenum, into which the excretory duct of the pancreas is inserted; the same thing was done for the ductus choledochus. These two ducts sometimes open into the intestine at the same point; at other times they pierce it in different places, but always near to each other.

The pancreas is the more difficult for the young anatomist to expose accurately, as it sometimes presents a soft, and, as it were, cellular consistence, which causes it to be confounded with the surrounding cellular tissue which is very abundant in this place. Its situation is not fixed in the spot it occupies, and we frequently remove it when detaching the parts by which it is covered. Notwithstanding these slight inconveniences, we will succeed in exposing it perfectly, by moving at the same time the stomach, liver, and colon in different directions; the pancreas occupies the space exposed by this process; it lies across the vertebral column, and does not measure more than eight to ten fingers' breadth in extent. It will be recognised by its very pale-red color, and by the slight irregularity of

its exterior. When we are assured of its presence and the place it occupies, and when we have examined its situation and various relations, we should remove cautiously the parts which conceal it, leaving nothing but the portion of duodenum, receiving the pancreatic duct ; which must be done by tying, before cutting them, the two extremities of this intestine.

The dissection of the excretory duct of the pancreas presents some difficulties, as well on account of its diminutive size, as its situation, concealed as it is in the substance of this gland. It originates by very fine radicles from its splenic extremity, and proceeds in a serpentine course from left to right, in order to enter the duodenum four or five fingers' breadth from the pylorus. It will be readily found by raising in thin, successive layers, the anterior portion of the pancreas. After having arrived at a certain depth, this serpentine duct is observed in the substance of the organ. In order, however, to see it still more advantageously we should not seek it at its origin, but, on the contrary, commence with it at its union with the choledochus, or at its insertion into the intestine, and then pursue it in a retrograde manner. This is the only means of avoiding cutting or rupturing it, which will infallibly happen if we attempt to expose it from left to right, and from its origin to its insertion.

Description.

LIVER.

Iecur. L. hepar. G.

Situation and relations.—In the entire right hypochondrium, epigastric region, and even a portion of the left hypochondrium ; in front of the vertebral column,

where are found the esophagus, aorta, vena cava ascendens and the pillars of the diaphragm ; behind the false ribs on the right side, beneath the diaphragm, above the stomach, colon, duodenum, middle epiploon and right kidney. The situation and relations of the liver present in addition certain varieties depending on particular circumstances. When the stomach is empty, the liver descends considerably ; the contrary is observed when the stomach is filled with aliments ; standing or sitting, the liver descends equally ; it ascends when the individual is in the recumbent posture ; when on the right side, it is supported on the ribs, does not interfere with any viscus, and sleep is then calm and undisturbed ; if the individual changes to the left side, it rests on the stomach, compresses it, renders digestion difficult, especially after a hearty meal, and troubles the sleep.

Figure.—Elongated from right to left, thick superiorly, thin and cutting inferiorly.

Division.—Superior convex surface united to the diaphragm by the coronary ligament ; inferior concave surface, on which is observed the following objects, proceeding from right to left:—1st, two slight depressions which correspond, the one to the right kidney, the other to the colon ; 2d, the gall bladder ; 3d, the longitudinal fissure, in which is remarked the insertion of the hepatic artery, vena portæ, hepatic duct, and suspensory ligament of the liver ; 4th, the transverse fissure ; 5th, the lobe of Spigelius, or small lobe of the liver, and the two portal eminences ; 6th, a large depression, which corresponds to the stomach. Its posterior border is inclined upwards ; on it, is observed the insertion of the hepatic veins ; its inferior border, inclined downwards, is thin, cutting, and pro-

foundly divided in the middle portion, for the insertion of the suspensory ligament of the liver; its two extremities present nothing particular.

GALL BLADDER.

(*Vesicula-cistis.*)

Situation and relations.—In the hypochondrium of the right side; below the great lobe of the liver, to which it adheres; above the colon and duodenum.

Figure.—Pyriforme.

Division.—A large extremity, called the fundus, situated downwards and forwards; it exceeds the boundary of the liver when the vesicle is full, but it is concealed by it in the contrary case; small extremity, called the neck, turned upwards and backwards, and terminated by the cystic duct.

Structure and uses.—The color of the liver, a melange of biliary juices and of a black and abundant blood, is of an obscure red, mixed with yellow.

Its intimate structure results from the disposition and combination of a great number of sanguineous vessels, arterial and venous, nerves, biliary ducts and lymphatic vessels, which are completely enveloped by two very thin membranes. One of these membranes is of a serous nature, external and a prolongation of the peritoneum; it is extremely thin, and may be detached from the liver with great facility. The most remarkable sanguineous vessels are, the vena portæ which takes its origin in the intestines, epiploons, stomach, spleen, pancreas, and which ramifies infinitely in the interior of the liver. Each of its numerous divisions, in this organ, is accompanied by an artery, branch of the hepatic, by a nerve and biliary duct,

the fluid of which proceeds in a direction contrary to that of the sanguineous vessels. A membrane, called the membrane of *Clisson*, immediately envelopes these different objects, accompanies them to their utmost ramifications, and thus prevents them from adhering to the proper substance of the liver. The hepatic veins, on the contrary, deprived of this sheath, adhere strongly to the liver and proceed in a direction opposed to the first vessels. This disposition is very accurately seen in cutting the liver by layers, which leave the hepatic veins comprised in the section we have made, exposed and bent.

A cellular layer has lately been discovered, which envelops the liver immediately beneath the serous membrane, and which is even found where this latter does not exist, such as the point occupied by the gall bladder, and also that in which the coronary ligament is observed. This third membrane of the liver has been called cellular membrane.

The gall bladder presents a very different structure. There are only two membranes found in it, the external is of a serous nature, rather dense, and a prolongation of the peritoneum. The internal, mucous, is that which some anatomists term the villous membrane; in the cadavera, these two membranes are yellow and strongly impregnated with bile; but in the living subject, their color is whitish.

The uses of the liver are by no means equivocal. It is the organ for the secretion of bile, and it furnishes this fluid in great abundance. Contained at first in the radicles of the biliary ducts, it soon proceeds to the principal divisions, and finally collects in the common trunk, called the hepatic duct. After arriving a short distance from the liver, the bile meets with the duct of the gall bladder

(ductus cysticus) penetrates this bag, remains there for some time, and then proceeds to the duodenum, traversing anew the cystic duct, which transmits it into the choledochus. The bile pursues the first route we have just indicated, when digestion is not going on, and the second when this is in operation.

SPLEEN.

Splen. G.

Situation and relations.—In the profoundest part of the left hypochondrium, below the diaphragm, above the kidney of the same side, between the false ribs of the left side and the large extremity of the stomach, to which it is united in this place by means of the short vessels. This circumstance explains the numerous changes, which the spleen may undergo in its situation and relations.

Figure.—Ovoid, flat, and elongated from above downwards.

Division.—External convex surface, which corresponds to the ribs; internal concave surface, contiguous to the stomach by means of the short vessels. It presents in addition a longitudinal fissure, by which the splenic nerves and vessels are introduced into its interior. Its anterior and posterior borders, its superior and inferior extremities offer nothing peculiar.

Structure and uses.—The structure and uses of the spleen are unknown, and we can advance nothing but conjecture in our attempts to explain either the one or the other. All that we can say with certainty, is that the spleen is of a deep red color, of a consistence sometimes soft and easy to lacerate, sometimes hard and of a more dense tissue; that it is penetrated by a great number of

blood vessels ; that its parenchyma appears to be exclusively formed of them, and its external membrane is very delicate ; finally, the spleen, lightly pressed, allows a black and abundant fluid to escape.

PANCREAS.

Situation and relations.—Situated transversely in the profoundest part of the epigastric region, as high as the twelfth dorsal vertebra ; beneath the stomach, above the duodenum, in front of the vertebral column, aorta and vena cava ; between the spleen and duodenum.

Figure.—Elongated, flat, and curved on itself, in order to be accommodated to the prominence of the vertebral column.

Division.—Superior surface, inclined forwards ; inferior surface, inclined backwards. The posterior and anterior borders offer nothing remarkable. The left extremity, called the tail (queue) of the pancreas, corresponds to the spleen ; the right extremity, called the head, frequently presents a prolongation, which has been termed the small pancreas.

Structure and uses.—The pancreas resembles the salivary glands as regards its structure and uses. Like them, it is of a grayish color, and granulated ; it is composed of lobes, lobules, formed of glandular grains, in which are found a nerve, artery, vein, and a radicle of the excretory duct, which takes its origin from the left extremity, proceeds, increasing in size, towards the head of the pancreas, and pierces the duodenum, sometimes conjointly with the choledochus, by uniting with it, and sometimes separately.

The pancreas secretes a fluid, very analogous to the

saliva; it mixes in the duodenum with the bile, and contributes to the accomplishment of digestion, by moderating, according to some physiologists, the excessive action of the biliary juice.

6th, PERITONEUM, MESENTERY, AND EPIPLOONS.

Situation and relations.—The peritoneum forms the common envelope for all the abdominal viscera, if we except the kidneys, and lines, moreover, the cavity in which they are contained. The mesentery and epiploons are merely prolongations of this membrane. Its relations with the organs contained in the abdomen are the following:—the middle portion, in proceeding from the environs of the umbilicus, lines the transverse muscles, gets into both lumbar regions, covers the whole anterior and posterior outer part of the ascending and descending colon, passes over the kidneys, advances towards the vertebral column, meets the mesenteric artery, applies itself to the right and left on this artery, thus forms the two feuilletts of the mesentery, and finally terminates on the ileum and jejunum.

The inferior portion proceeds from the umbilicus, developing itself on the umbilical arteries and ouraque, as far as the bladder, of which it covers only the posterior part, as well as vesiculæ seminales, is reflected thence on the rectum, ascends to the right and left, covers the cœcum on one side, and the S of the colon on the other, and also the sacral, hypogastric and iliac vessels, and becomes confounded with the middle portion.

In the female, it is reflected from the bladder to the uterus, covers the anterior, superior and posterior part of this latter, and then proceeds as we have just described.

The superior portion, which gives origin to the falci-forme ligament, extends from the umbilicus to the diaphragm, which it covers; is reflected from the right side on the liver and gall bladder; and from the left side, on the stomach; it forms at the two extremities of the liver its lateral ligaments; in addition, it covers the spleen on the left, gives rise to the gastro-hepatic epiploon and to the great epiploon; finally it passes beneath the pancreas and duodenum, and becomes continuous with the two feuilletts of the mesentery.

Structure and uses.—The peritoneum is a serous membrane, diaphanous, smooth, and shining on the surface regarding the abdominal cavity, constantly lubricated, on this portion, by a lymphatic fluid; its elasticity is extreme, as is proved by pregnancy, certain hydropsies, &c.; its uses are, to maintain the abdominal viscera in their natural situation, furnish them an external covering, and to secrete an abundant fluid, intended to prevent their adhesions.

7th, URINARY ORGANS.

General considerations.

The urinary organs are composed of the kidneys, ureters, bladder, urethra, and renal capsules, although it is not proved that these last appertain to the urinary apparatus, their functions being unknown.

Among the urinary organs, some are situated within the abdomen, and others out of this cavity. The kidneys, destined to secrete the urine, are placed profoundly in the lumbar regions, and are protected from the influence of external bodies, by the hard parts which are near them; the ureters are merely canals of communication,

which proceed from the kidneys to the bladder by the most direct and shortest route. The urine, continually secreted, passes without interruption from the kidneys to the bladder by these canals. The bladder is contained within the cavity of the pelvis, in which it may, without inconvenience and even without effort, acquire a considerable volume, proportionate to the quantity of urine it contains. Without the medium of the bladder, the urine would be transmitted directly from the ureters to the canal of the urethra, and would thus oblige the individual to void it continually; a dreadful inconvenience, of which the incontinence of urine gives us some idea. Remaining, on the contrary, in the bladder, it is not excreted through the urethra except at distinct periods, and it is easily expelled by the tonic action of the bladder. Every thing in this function inspires the greatest interest—the form, composition, and situation of the organs, the fluid which they secrete, the mode of its secretion, its sojourn in a cavity proper to contain it, without its presence, when even prolonged, giving rise to any alteration, except in case of disease of the bladder; the mechanism of its expulsion; finally, the numerous complicated diseases, which may occur to some of the urinary organs.

Anatomical Preparation.

Kidneys and capsulæ renales.—In removing from the abdomen all the organs, which form the digestive apparatus, there then only remain in this cavity the kidneys, ureters and bladder, and nothing is easier at this time than the preparation of the first of these objects; it will suffice to free them from the loose and very abundant cellular tissue, which envelopes them on all sides. The volume of the kidneys, and their hardness will not permit us to

mistake them. They are profoundly situated in both lumbar regions, and covered immediately by the right and left colon.

The student, in dissecting them, should preserve their vessels, which go to the aorta, on the one hand, and to the vena cava, on the other: and it is not until after having accurately studied the situation and relations of these organs, that we can remove them in order to examine them in their isolated state, which will enable us to acquire a more perfect idea of their form, color and density. For the purpose of seeing their internal structure, we must open them on their posterior and convex part, and thus arrive at their fissure. It is unnecessary to employ an instrument in order to divide the kidneys in their whole extent; but we should tear their tissue with the fingers, commencing at the convex border, after having cut it one half only with the scalpel, in its whole length.

We should likewise examine the capsulæ renales before removing the kidneys. These glandular bodies, much smaller than the kidneys, are situated on their superior and internal part. Their color, of a pale red, their triangular, flattened, lobular form, and their soft consistence, will render it easy to recognize them, provided we have not removed them with the intestines, as very frequently is the case. One thing we should not neglect before removing the kidneys, in order that we may study their organization the more conveniently, is, to isolate the ureters, which will be seen, with a little attention, to proceed from their internal and inferior portion, continue along the vertebral column, and enter the pelvis towards the sacro-iliac symphises, for the purpose of penetrating the

bladder, at its posterior and inferior portion. Their volume is nearly that of an ordinary writing quill, and they are attached but feebly to the surrounding parts; they have a quantity of loose cellular tissue around them; it may be raised with great ease; but it is in the pelvis that it is most difficult to pursue them. The section we shall now indicate for the examination of the bladder will obviate this inconvenience.

Bladder.—Before performing this section, we should examine the relations of the bladder with the surrounding parts; at first empty, effaced, afterwards distended, either by introducing into the urethra a small tube, quill, or even a straw in lieu of a more appropriate instrument, and then blowing into it. A ligature should be placed around the urethra after having inflated the bladder; or it will suffice to press it forcibly in order to prevent the air from escaping. After having performed these preliminaries, we make the necessary section for the purpose of understanding more thoroughly all the details; it consists in sawing the horizontal branches of the pubes three fingers' breadth from the symphysis, and also the descending branches of the same bone. The ureters should be cut at a certain distance, and then detach with the scalpel the piece, which is held together merely by the soft parts. For this purpose, we should draw it forwards in proportion as we detach it, and be particularly careful to protect the inferior portion of the bladder, which adheres more strongly to the neighboring parts. Here are found the vesiculæ seminales, which must be preserved, although their preparation is not essentially necessary for the study of the bladder. The piece completely removed, we may then inflate the bladder again, if it is

not sufficiently so ; this is the only means of obtaining an idea of its figure and degree of extension. Detach it from the body of the pubes, or rather divide their symphises, in order to separate the branches, and in this way we shall arrive at the bladder, which should be incised in its superior and anterior portion ; by doing this, we shall discover its interior, which it is important to examine. Our attention should be fixed especially on the opening, which is found below and in front ; this is the neck of the bladder ; somewhat posteriorly is observed a triangular space, slightly elevated, called the vesical trigone. The ureters, after having travelled for some time in the proper substance of the bladder, pierce this organ and open in its cavity, at the extremity of the lateral angles of the trigone ; they will be seen without any difficulty, and a small stilet can be easily introduced into their interior. We should not fail to do it ; it is the only way in which we can have an idea of the course of these canals.

The inflation of the bladder is necessary in order to examine its different tunics ; thus, we shall easily perceive, in this manner, that the peritoneum does not envelope this organ at its anterior part ; indeed, it does not need it, as it is united to the posterior part of the body of the pubis, by means of a loose and abundant cellular tissue.

We shall not describe here the mode of preparing the urethra ; this will be mentioned, when we treat of the organs of generation.

Description.

KIDNEYS.

Renes. L. Nephroi. G.

Situation and relations.—In the profoundest part of the lumbar region, on the vertebral column, and the two last false ribs. The right corresponds above to the liver, below to the cæcum, in front to the ascending colon; the left corresponds above to the spleen, below to the *S* of the colon, and in front to the descending colon.

Figure.—Spheriodal, elongated.

Division.—Anterior surface, covered in both loins, by the colon; posterior surface, which corresponds to the body of the lumbar vertebræ, and to the internal surface of the two last false ribs. The external border is convex, smooth, directed slightly backwards; the internal border presents a profound notch (echancrure) into which are inserted the renal vein above, the artery of the same name in the middle, and below, the commencement of the ureter. Of the two extremities, one is superior and more voluminous; the other is inferior.

Structure and uses.—The consistence of the kidneys is firm, and their color of a reddish brown. We distinguish on them an external, cortical substance, two lines in thickness, beneath which is observed a tubular substance, which terminates by the mamelonnée, admitted by some anatomists, rejected by others, who regard it as the termination of the faisceaux of the tubular substance. Between these different objects and the fissure, is perceived the pelvis, in which are found the vessels of the kidney, as also the ureter. The kidney is the organ for the secretion of urine.

RENAL CAPSULES.

Situation and relations.—In the lumbar region, above and within the kidneys, the superior extremity of which they embrace.

Figure.—Triangular.

Division.—Anterior surface, covered by the abdominal soft parts; posterior surface applied on the body of the vertebræ.

Structure and uses.—The color of the capsules is yellow bordering on brown. Interiorly, they appear formed of lobules, composed themselves of smaller grains. Their uses are unknown.

URETERS.

Oureter. G.

Situation and relations.—The portion of the ureters placed in the abdomen is situated on the sides of the vertebral column, and that which is in the pelvis, on the lateral portions of the bladder.

Extent.—From the kidneys to the bladder.

Figure.—Elongated, cylindrical.

Structure and uses.—Three tunics enter into the composition of the ureters; one exterior, cellular; a middle, more consistent; and an internal, mucous, a continuation of that which lines the interior of the bladder. The ureters transmit the urine from the kidneys to the bladder.

BLADDER.

Vesica. L. Cistis. G.

Situation and relations.—In the cavity of the pelvis, behind the body of the pubes, in front of the rectum in

the male, and the uterus in the female ; beneath the intestinal paquet ; above the vesiculæ seminales and vasa deferentia.

Figure.—Ovoid, slightly flattened from before backwards.

Division.—Anterior surface, which corresponds to the pubis ; posterior surface, corresponding to the rectum in the male, and the uterus in the female. The superior extremity is called the summit of the bladder, to which corresponds the ouraque ; the inferior, called the base, is composed of the neck in front, and the bas-fond posteriorly.

Structure and uses.—The bladder offers three tunics ; an external, prolongation of the peritoneum, which covers the superior, posterior and lateral portions ; a middle, muscular ; and an internal, mucous. On this last are observed, below and in front, the vesical trigone and the orifice of the ureters. Several duplicatures are also remarked in the interior of the bladder ; they are the result of a folding of the mucous membrane, occasioned by the contractions of the muscular tunic. The bladder receives and contains the urine, which is continually poured into it by the ureters, and finally expels it, when its quantity, having become too considerable and fatiguing, forces the bladder to contract in order to empty itself.

RESPIRATORY AND CIRCULATORY ORGANS.

General considerations.

These organs are contained in great part in the chest, whose structure is admirably adapted to their mode of action. Endowed with an alternate and continual movement, they require that the cavity enclosing them, should

enjoy at the same time a degree of suppleness necessary for their free exercise, and resistance sufficient to protect them from the influence of external bodies.

In the chest are found the organs of respiration and those of circulation. The first are composed of the larynx, trachea, bronchiæ and lungs, to which we must add the thymus and thyroid glands. The heart alone constitutes the great agent of circulation: the vessels which emanate from it and divide into numerous branches, in proportion as they proceed throughout the different portions of the individual, should be considered merely as a means of transmitting the blood. If the most remarkable phenomena of circulation occur in the heart, the results, the object of this circulation can be perceived only at the extremities of the capillary tubes belonging to the arterial system. The most perfect knowledge of the course and principal divisions of the arteries, gives but a very feeble idea of this function. The most important escapes our observation, and takes place out of the canals, which the scalpel of the anatomist cannot expose.

Anatomical Preparation.

Before passing to the preparation and study of the organs contained in the chest, and even before we occupy ourselves with the larynx, thymus and thyroid gland, we should examine the mammæ, which, however, can be advantageously studied only in a female. The preparation required by these glandular bodies is of the simplest kind, when we desire merely to understand their general form, situation and relations. But we should not limit ourselves to this superficial study of the mammæ, for it is necessary to examine also their interior and particular structure.

There is found, under the integuments of the mammæ, an abundant cellular tissue, which forms part of the gland; in examining this gland attentively in front we will find that it is composed of numerous ducts folded several times on themselves, larger at the base of the mammæ, and which constantly contract as they proceed towards the nipple, where they amount only to fifteen. In order to render these ducts more apparent, it is necessary to inject mercury into one of them; soon all the others will be filled with it, and thus they will be seen very distinctly. The organization of the mammary glands could be studied with much more advantage, if it were possible to examine them in a female recently delivered, who had died, for example the second or third day after her accouchement.

Larynx, thymus and thyroid gland.—The piece, which has served for the study of the pharynx, may also answer for the larynx; but it would be much better to examine this latter in place. For this purpose, we make a longitudinal incision into the integuments of the neck; in the middle part, is found the larynx, placed beneath the os-hyoides, and above, the trachea, which is the continuation of it. Certain muscles, described in myology, are applied immediately on the larynx; they may be either removed, or left in place; they do not interfere with its examination: but, in this manner, we shall observe only the exterior of the larynx, and it is highly important to understand its internal structure, which can only be done by detaching and removing it from the place it occupies; this, however, should not be done, until after having exposed the thyroid gland, which embraces the larynx at its inferior part. It will be known by its

volume, its soft and spongy consistence, its reddish color, and its division into two portions of equal volume. The thymus is not very apparent except in the infant; it scarcely exists in the adult. It is found, in the former, placed behind the sternum, at the entrance of the chest, in the *ecartment* of the anterior mediastinum. Its consistence is soft in the fœtus and infant; but it increases in the adult and aged. Its color of a pale red in the fœtus, becomes yellow in the adult. When we cannot procure a very young subject in order to examine it, it is better to proceed immediately to open the chest, as was indicated Vol. I. p. 162, and to study the organs contained in it.

Lungs and Trachea.—If we wish to prepare the lungs properly, we must study them in place. For this purpose, it will be necessary to open the chest as largely as possible.

We should also, in this preparation, examine the manner in which the pleura is arranged at the posterior part of the sternum, in order to form what is termed the *anterior mediastinum*. With this view the chest must be opened, as was described Vol. I. p. 162. The sternum is then to be removed, either from above downwards, or from below upwards, and in detaching it successively from the two prolongations of the pleura which adhere to its posterior part, we should observe the *ecartment* resulting from them, it is the anterior mediastinum.

After removing the sternum, we observe, in front of the pericardium, the two duplicatures of the two pleuræ, cut in the direction of their length, representing tolerably well the figure X, the inferior branches of which are more distant than the superior. The reader will find more

ample details respecting this subject, at the end of this article. We shall now proceed to the preparation of the lungs.

Having removed the sternum with the intercostal cartilages, we should break the ribs as near as possible to their articulation with the vertebral column; then, we should carefully remove all the soft parts, muscles, vessels, and cellular tissue covering the objects about to be examined. In this way, we shall see the union of the larynx with the trachea, the division of the latter into two principal trunks called bronchiæ; and the more numerous divisions of the bronchiæ in the proper substance of the lungs; in this way also, we shall observe the disposition and distribution of the pulmonary artery, its relations with the aorta and trachea. This, however will be more advantageously seen if we inject the pulmonary artery with tallow, resin, wax, &c. This preparation will render it very apparent, and we shall not be liable to error by confounding its two first branches with the bronchiæ. If the student should desire, before opening the chest, to assure himself that there does not exist a vacuum between the pulmonary and costal pleura, and that there is no bubble of air in the interval, he may remove, with some care, several of the intercostal muscles, as far as the portion of the corresponding costal pleura; this latter, however, must not be interfered with. It will then be very easy to convince himself that the lungs, which will be distinctly seen through the transparency of the costal pleura, are applied, without adhering to it, to the latter, and that there does not exist any vacuum between these two parts.

We may, still more successfully perform the same experiment on a living animal, with this difference that when

we have arrived at the costal pleura, it will be necessary to divide it in a small space ; in an instant, the column of external air precipitating itself between the costal pleura and lungs, presses the latter, and then permits a vacuum, which, consequently did not previously exist.

Heart.—We should not separate the preparation of the heart from that of the respiratory organs: like these latter it requires the chest to be opened. Placed in the interval of the two pleuræ and between the two lungs, a little to the left, the heart is enveloped by a bag peculiar to it, called pericardium. If we cut this bag, we shall have the heart exposed to view, and we can then examine its exterior, together with its different relations. All these indications having been fulfilled, we may then take up the particular consideration of each of the organs, which were at first studied in situ, and after having detached them from their situation, examine the various parts in detail. Thus, it will become necessary to divide the larynx at its anterior part, and separate its two divided portions in order to have a view of their interior. The same thing will be required for the trachea and bronchiæ. We may also detach the lungs from the thoracic cavity, cut them in different directions, press them under the fingers, examining attentively their organization, and follow, as far as possible, the divisions of the bronchiæ.

In order to acquire a perfect knowledge of the intimate structure of the lungs, it would be necessary to inject the trachea and the principal trunks of its arterial and venous vessels, with substances differently colored. The heart requires, more than any other organ, to be separated from the large vessels which emanate from it; these vessels are eight in number; they may be very well distinguish-

ed, when even the heart is in place. The largest and most external is the aorta, the parois of which are likewise thicker; below is observed the pulmonary artery, which soon divides into two principal branches; on the right and in front are two large bluish vessels, one of which is the superior or ascending vena cava, and the other the inferior or descending vena cava, both of which go to the right auricle. In raising the heart by the apex, we shall observe on the left four vessels, smaller than the first, all of which enter the left auricle; these are the pulmonary veins.

We may examine without difficulty the disposition of the two venæ cavæ relatively to the right auricle, which they penetrate, and also the extent of this latter. Such, however, is not the case with the pulmonary veins, and especially with the left auricle, which receives the blood brought by these veins from the lungs. After having raised the point of the heart, as was just indicated, we may cut the auricle transversely at its posterior part, and introduce the finger into its cavity, in order to ascertain its extent and depth; or rather, after cutting the aorta and pulmonary artery four fingers' breadth from the heart, turn them over on its anterior part, and then open the left auricle at its superior portion.

When we have decided to remove the heart, we should cut its vessels as far as possible from their egress from this organ, wash this latter and free it from the blood. We may then cut it lengthwise on its lateral portions; at first through the auricles which are above, afterwards through the ventricles, which occupy its inferior part. We should not injure the point of internal separation between the auricles and ventricles; and the mitral and tricuspid valves should be accurately distinguished; they are situat-

ed on the parois of the two ventricles, and may be raised by passing the handle of a scalpel between them and the ventricles. We must not lose the opportunity of seeing the three sigmoid valves of the aorta and pulmonary artery, which may be done by incising the arterial tube, from its cut extremity, towards the heart. These valves are most generally applied on the parois of the artery; they may easily be brought into view with the handle of the scalpel.

It now remains for me to say a word respecting the pleura and the two mediastinums. The pleura is to the chest and the organs contained in it, what the peritoneum is to the abdomen. We can without difficulty detach the first from the thoracic parois, and this simple procedure will suffice for its preparation. Such, however is not the case as regards the mediastinums, which are nothing more than a consequence of the manner in which the pleura develops itself in the chest and on its organs. In order to have a view of them, it will be necessary in the first place to proceed as if we wished to remove the sternum, afterwards we should detach the ribs as near as possible to the vertebral column, leaving the sternum in place, take the lungs from their respective cavities, wash the parts and free them from the blood which flows on all sides; then, in removing the sternum, we shall see that it gives attachment to a double prolongation of the pleura. The interval forms the anterior mediastinum, in which are contained the heart, large vessels and pericardium. Behind the heart, the two prolongations are applied against each other, and separate anew on the vertebral column; this second interval forms the posterior mediastinum, in which

are situated the aorta, esophagus, eighth pair of nerves, or pneumogastric, and the thoracic canal.

Such are the preparations of the different parts enclosed in the chest.

Description.

LARYNX.

Situation and relations.—On the anterior and middle portion of the neck, below the os-hyoides and tongue, and above the trachea; in front it is covered by the integuments of the neck and some interposed muscles; behind, it corresponds to the pharynx.

Figure.—Elongated, cylindrical.

Division.—Five cartilages, one of which is above and in front, called thyroid, on account of its resemblance to a shield; one below, circular, and called cricoid, on account of its resemblance to a ring: two above and behind, called arytenoid, which may be compared to species of funnels; the fifth and last, above, developed in form of a tongue, called epiglottis. From the arrangement and disposition of these cartilages there results a sort of elongated box, the superior opening of which, called glottis, corresponds to the base of the tongue. The inferior opening, which has not received any particular name, is continuous with the trachea. The interior of the larynx presents, above and below, species of ligamentous cords, in the interval of which are the ventricles. The inferior ligaments bear the name of the vocal cords of Ferrein.

Structure and uses.—The parts which form the larynx are of a cartilaginous nature. The interior is lined by a mucous membrane, the continuation of that of the trachea

and bronchiæ, and which is constantly moistened with a humor of the same nature. The uses of this tube are not merely to afford a passage to the air, but by the mobility with which its component parts are endowed, this fluid undergoes, in traversing it, different modifications, whence result the formation of sounds and their numerous modulations.

THYROID GLAND.

Situation and relations.—On the anterior and inferior portion of the larynx, behind the sterno-thyroid, sterno-hyoid and sterno-cleido-mastoid muscles: in front of the larynx and trachea in its middle portion; the carotids, jugular veins and eighth pair of nerves correspond to its lateral portions.

Figure.—It is of a crescent shape.

Division.—A middle portion, very narrow, called the isthmus of the thyroid gland; lateral portions, voluminous, oblong, of equal size and perfectly resembling each other.

Structure and uses.—The thyroid gland, of a soft consistence, and of a brownish red color, presents an organization difficult to demonstrate. Its uses are unknown; it is presumed that it furnishes a humor proper to lubricate the interior of the larynx.

TRACHEA.

Situation and relations.—On the inferior and anterior portion of the neck; from the larynx to the second or third dorsal vertebra, where it divides into two branches, called bronchiæ; in front of the vertebral column and esophagus; behind the integuments of the neck and the interposed muscles.

Figure.—Elongated, cylindrical.

Division.—Several cartilages (from sixteen to twenty in number) compose the trachea. As a whole they form a species of cylindrical funnel, the posterior fourth of which has been cut off. Each of the cartilaginous circles is separated by a small ligamentous band, which affords considerable mobility to the different parts of the trachea.

Structure and uses.—The cartilages of the trachea do not differ, as regards their organization, from other parts of the same kind. Their consistence is weak in infancy but it increases with age; the membranous portion which separates them in front, exists alone at the posterior part, where there is no trace of cartilage observed. The interior is lined by a prolongation of the mucous membrane, which continues into the bronchiæ. The trachea can merely be considered as a tube affording passage to the air.

ORGANS APPERTAINING ESPECIALLY TO THE CHEST.

Mammæ.

Situation and relations.—On the anterior, superior and lateral portion of the chest; covered immediately by the integuments, which, in this place, are soft to the touch, and white, except towards the summit of the gland, where a bluish circle, called areola, is observed, in the centre of which there is a small projecting portion, red in virgins, and brown in women who have borne children, termed nipple.

Structure and uses.—The mammæ are formed of one gland, enveloped by a great quantity of cellular tissue. In order to see the intimate structure of this gland, we should, if possible, examine it on a female who may have died during lactation; we shall then observe a great number of tubes, called lactiferi, which unite as they approach the

nipple, to the number of fifteen or twenty, under the name of the excretory milk ducts. The uses of the mam-mæ, in the female, are not equivocal; they are destined to secrete milk in such as have just been delivered. This nourishment of first infancy is mild and sweet, and accommodates itself very happily to the weakness of its organs. In imparting to the infant the facility of seizing and embracing the nipple, nature appears to have intended that the nutritive fluid, furnished by the mother, should not be exposed to the contact of the air. This simple mechanism destroys all the reasons adduced in favor of artificial lactation.

THYMUS.

Situation and relations.—On the superior part of the chest, behind the sternum, between the two folds of the mediastinum.

Figure.—Oblong, similar, in some respects, to the thyroid gland.

Structure and uses.—Possessing a soft consistence, and a brownish red color, the thymus, which is not very apparent except in early infancy, and which disappears with age, does not present any other considerations relative to its uses, which are unknown.

LUNGS.

Situation and relations.—In the chest, of which they occupy nearly the whole cavity. They are two in number, one on the right, which is the most voluminous, the other on the left. They correspond in their whole extent to the ribs and corresponding inter-costal muscles, from which they are separated only by the pleura. The heart

reposes on the anterior portion of the left lung, which is separated from that of the right side by the two folds of the mediastinum.

Figure.—It corresponds to that of the cavity in which the lungs are enclosed, and somewhat resembles an irregular cone, the base of which is below and the summit above.

Division.—External, convex surface, which corresponds to the ribs; internal, concave surface, contiguous to the heart. The external surface of the left lung presents a tolerably deep fissure, which divides it into two lobes; that of the right lung presents two of them, which divide it into three lobes. The base turned downwards, corresponds to the diaphragm; the summit, turned upwards, extends a little above the first rib.

Structure and uses.—The structure and uses of the lungs present great differences, and are not the same in the fœtus and adult; these differences are relative to their color, density and volume.

Color.—It is livid in the fœtus; vermillion red, when the infant has respired; greyish in the adult, and more or less covered with bluish spots, which become more numerous and larger in old age.

Density.—It is considerable in the fœtus; but in proportion as the air penetrates and dilates the lungs of the new-born infant, in which respiration is well established, the density always diminishes more and more, so that in the adult the lungs are soft, swollen with air, and their specific gravity is less than the water into which they are plunged.

Volume.—Reduced to the smallest possible size in the fœtus, the lungs present a considerable developement and mass in the adult; but their weight is scarcely increased,

the introduction of the air into their cells being the principal cause of this augmentation.

The lungs are composed of blood-vessels, arterial and venous air-ducts, and an abundant cellular tissue. Nerves, lymphatic vessels and glands likewise enter into their composition. An external, serous membrane, which is a prolongation of the pleura, constitutes their general covering.

The pulmonary artery, divided into two principal trunks, both of which penetrate the lungs, ramifies in them and gives origin to the first radicles of the pulmonary veins which by their successive re-union, form the trunks of the four veins of the same name.

The trachea is divided at first into two principal branches, called bronchiæ; these last multiply their divisions in proportion as they advance in the lungs, and each of the infinitely small air tubes resulting from them terminates in a very fine membranous cell, having a figure difficult to determine, and which has been considered as a species of ampoule, to which has been given the name of air vesicle. Several of these cells communicate with each other; their re-union forms lobules, these lobules lobes, and the assemblage of these last constitutes the entire mass of the lungs. A mucous membrane lines the interior of all the air tubes.

The lungs are the principal agents in respiration, which is effected by the alternate admission and expulsion of the air in their cells. Respiration has for its object to operate changes in the blood by the presence of atmospheric air, so that from being black when it enters the lungs, it becomes vermilion on leaving them. This new quality acquired by the blood in passing through the lungs, renders it

proper for the nutrition of the individual, and for the maintenance of a degree of heat suited to his mode of existence.

HEART.

Situation and relations.—A hollow viscus, situated obliquely in the chest and enclosed in the pericardium, together with the trunks of the large vessels, which emanate from it. Placed in the separation of the two folds of the mediastinum, between the two lungs, the heart corresponds in front to the sternum and cartilages of the last true ribs on the left side; behind, to the esophagus, descending aorta and vertebral column; below, to the diaphragm; above, to the aorta and pulmonary artery.

Figure.—Conoid, flat posteriorly; the base of the heart is above, inclined to the right and somewhat backwards; its summit is below, to the left and inclined forwards.

Division.—Superior convex surface, inclined forwards and to the right; inferior flat surface, inclined backwards and to the left, and reposes in part on the diaphragm. The right border, turned forwards, is pointed and longer than that of the opposite side; the left border, turned backwards, is thick and shorter; the base, turned upwards, is inclined backwards and to the right; the summit, turned downwards, is inclined forwards and to the left. It is this portion of the heart, which strikes the space between the fifth and sixth ribs in its pulsations. This division of the heart appertains merely to its external conformation, and gives no idea of that resulting from the arrangement and disposition of its different parts. In a word, if we examine the heart more attentively, we shall find that it is composed of two orders of cavities, the two superior of which, one on the right and the other on

the left, are called auricles; and the two inferior, also one on the right, and the other on the left, bear the name of ventricles.

The right auricle, turned forwards, larger than the left, from which it is separated by a thin partition, receives above the superior vena cava, and below the inferior vena cava, and also the two coronary veins. It corresponds to the superior part of the ventricle of the same side. At the mouth of the inferior vena cava, we observe the eustachian valve, a sort of moveable partition, having the form of a crescent, whose functions seem to be intended to prevent the blood contained in the auricle, from regurgitating into the inferior vena cava; the left auricle, smaller than the right, and turned backwards, receives the four pulmonary veins, two of which are on the right, and two on the left; it corresponds to the superior part of the left ventricle.

Both of the auricles present externally an appendage, resembling a dog's ear, from which circumstance they have received their name; their interior is furnished with fleshy pillars, the number of which varies.

The right ventricle is situated below the auricle of the same side; it is larger than the left, but its parois are less thick. It is separated from the auricle by an opening termed auricular, and furnished, in this spot, with a tricuspid valve. The interior presents a great quantity of fleshy pillars, the direction of which is parallel to that of the ventricle; from its superior and left portion originates the pulmonary artery.

The left ventricle, smaller than the right, but more elongated, is situated below the auricle of the same side, from which it is separated by an opening also called auricular, and furnished with a mitral valve. Its parois are

much thicker than those of the right ventricle, and its fleshy pillars, less numerous, are in general larger. Near the mitral valve, and to the right of the ventricle, originates the aorta. The two ventricles are separated by a partition much thicker than that of the auricles. Their auricular opening is likewise surrounded by a species of whitish cord, called tendinous zone. The aorta and pulmonary artery which, in their origin, present nearly the same dispositions, are each supplied with three valves, called sigmoid, much smaller and differently conformed from those of the ventricles. The aorta presents, between its origin and the point at which its sigmoid valves are inserted, two small openings, which are the orifices of the two coronary arteries.

Structure and uses.—There is no organ that has excited so much research and discussion as the heart; however, we know but little of its structure, and authors do not agree respecting its uses. All that we can advance with certainty on this subject is, that the parts composing it enjoy an extreme irritability, which has given rise to the belief that they were fleshy fibres. Red at first sight, their continued immersion in water, gives them a white appearance. It is evident that the heart is the great agent of circulation; but there is difference of opinion respecting a number of phenomena, which cannot be examined in this place. Let us now see what is the course of the blood through the four cavities of the heart.

The blood being thrown into the right auricle by the *venæ cavæ* and coronaries passes into the ventricle of the same side; the slight contractions of the auricle, the weight of the liquid and the vacuity of the ventricle, are the laws in virtue of which it is conveyed into it.

By a strong and energetic contraction of the right ventricle, it is pushed into the pulmonary artery. By this mechanism, the mass of the fluid is carried into the lungs, which produce certain changes in it by which it acquires new properties; taken up by the pulmonary veins, it is brought into the left auricle, which transmits it to the left ventricle, from which it is forced into the aorta. This second part of the circulation pursues the same laws, and is effected by the same mechanism as the first, with this difference, that the blood pushed into the aorta is carried by this artery to all the parts of the economy for the purpose of vivifying them.

PLEURA, MEDIASTINUM AND PERICARDIUM.

Situation, relations and uses.—The pleura, a membrane common to all the thoracic viscera, lines the cavity in which they are contained. When it has reached the vicinity of the vertebral column, it becomes reflected from behind forwards in order to form the mediastinum, which, on the other hand, is implanted into the posterior part of the sternum. It is formed of two laminæ, one of which appertains to the prolongation of the pleura on the right side, and the other to the prolongation of the same membrane on the left. There result from them two portions, one behind and the other in front. The posterior mediastinum lodges the aorta, esophagus and eighth pair of nerves; the anterior the heart, large vessels and thymus gland.

The pericardium is a membranous sac, which encloses the heart, and, like this last, is situated in the anterior septum of the mediastinum. Its figure resembles that of the heart; its external surface corresponds to the lungs

on the sides, to the sternum in front, and below to the diaphragm, to which it adheres rather firmly. Interiorly the pericardium corresponds to the heart, from which it is separated by an abundant serosity.

Structure and uses.—What we have said of the peritoneum, as regards the abdominal viscera, will apply to the pleura for those of the chest; it forms, in addition, in the middle of the chest, a partition which sustains the lungs, and prevents them from compressing each other. The septum presented by this partition anteriorly and posteriorly, is destined to receive different objects, and to protect them from the influence of the surrounding parts.

The pericardium, which appertains to the pleura by its organization, is intended to enclose the heart without interfering with its movements, and to furnish a quantity of serosity, which prevents this bag from adhering to it.

ENCEPHALIC ORGANS—ORGANS OF SENSE.

General Considerations.

Here commences the study of the organs of animal life: the functions which depend on them are more or less under the influence of the will; and we can, to a certain extent, increase or diminish their energy at pleasure.

Those organs, which belong to the intellectual functions, and which preside over the senses, may be considered under two points of view. The first are enclosed in osseous cavities, which remove them entirely from our sight; the second, in part concealed, like the first, are however in part easy to perceive. The internal organs are the encephalon or brain, which is divided into cerebrum, cerebel-

lum and medulla oblongata. The external organs are those of sight, hearing, smell, taste, and touch, to which is given the name of *senses*. We cannot sufficiently admire the wisdom of nature in the distribution she has made of the sensorial organs; in a word, the most precious of these organs are contained in a cavity, whose parois being extremely solid, place them beyond injury from external agents. Receiving merely insensible impressions, it can without trouble or effort, fulfil its wonderful functions. It is pretended that these are the more extensive as the mass of the brain is more considerable. This opinion has very celebrated partizans; however, there are so many particular facts, which seem to destroy this general principle, that we cannot admit it in all its extent. It is an incontestible truth, that the brain diminishes in all animals, in proportion as, by their conformation, they become farther removed from that of man. But the degree of their intelligence is far from being in correspondence with the volume of their cerebral mass; whence it may be concluded that the brilliant views of modern physiologists, respecting the developement of the facial angle, can have no real object, at least as regards animals.

Man alone possesses, in a high degree of perfection, the organs of sense, the extent of which he increases by means, which his intelligence suggests. In him, the organ of sight is placed at the most elevated part of his body; those of smell and taste are very near them, and that of hearing is found on the lateral portions of the head; but this circumstance, far from diminishing its energy or extent, appears, on the contrary, to fulfil in a more perfect manner the views of nature. Touch alone, extended over the whole external surface of the body, is carried to the greatest degree of

perfection on the internal part of the hand, and on the extremity of the fingers. It is the touch, which rectifies the errors of all the other senses, especially of the sight, which, perceiving the surrounding bodies at very great distances, cannot judge of their exact form, density, or of any other of their attributes, a knowledge of which the sense of touch alone will communicate. It is true that this sense cannot be exercised successfully except on the external surface of bodies, the dimensions of which it determines with the greatest accuracy; but when we wish to know the intimate composition of these bodies, judge of their smell, or taste, the touch becomes useless; it is to the senses of smell and taste that we must have recourse in order to have these properties revealed to us.

The brain, as also the heart, gives origin to prolongations which, distributed throughout the different parts of the body, are as it were executors of its orders, and communicate, with the rapidity of lightning, to the common centre, the sensations produced by the surrounding bodies on the exterior of the individual. These prolongations, termed *nerves*, are not of two kinds, as is the case with the sanguineous vessels; but they are equally susceptible of transmitting feeling, and of serving the different sensations. Their origin is in the brain, and their radiations on the organs of sense. However, notwithstanding the order of this distribution, we shall occupy ourselves in this place with the brain and organs of sense only, reserving the exposition of the nerves until we shall have described the blood vessels. This course, moreover, is adopted by all anatomists, and in fact we should not pursue any other. Without rejecting absolutely the ideas of Dr. Gall, respect-

ing the distribution of the nerves, I have not adopted them in this work.

ENCEPHALON.

It is composed of the cerebrum, cerebellum and medulla oblongata, as also its prolongation, called spinal marrow. We must join to these first objects the meninges or membranes of the brain. We shall pursue, for the brain and its membranes, the same course which we have adopted for the organs in the other cavities of the body; that is to say, we shall in the first place occupy ourselves with the whole cerebral mass, including the spinal marrow, and we shall not describe the membranes of the brain until after having examined the organs which they envelope.

Anatomical Preparation.

Cerebrum, cerebellum, medulla oblongata.—The preparation of the brain requires that we should perform the section indicated in Vol. I. but here there are certain precautions to observe, which may be neglected when we open the cranium merely for the purpose of examining the derangements occasioned by certain diseases. We should not, for example, select a subject that has died of apoplexy, or in consequence of a violent blow on the head, but we should procure, if possible, an adult, who has died of a disease of several days' standing. The bones are to be sawed regularly, and the instrument should not be carried to the interior of the cranium, for it is very rare that the membranes are not lacerated, and the brain more or less injured. In order to avoid this inconvenience, we should saw only a portion of the substance of the bones, and terminate their definitive separation with the chisel and mallet; in this way, we shall not risk tearing the dura mater, and the brain

will be more secure. We shall not be in danger of either lacerating the dura mater, or injuring the brain if, instead of the saw, we employ a hammer for the purpose of opening the cranium. vide Vol. I.

When we have completely separated the arch of the cranium, it should be cautiously removed from before backwards. The dura mater is frequently very adhering to it, especially at the portion corresponding to the parietal suture and foramen cœcum; in order to do away with this adhesion, we should pass the handle of a scalpel or a chisel of sufficient length, between the bones of the cranium and dura mater, and detach, in proportion as we raise the arch of the cranium, the vessels which are the principal cause of this adhesion. This preliminary preparation being achieved, we will have a good view of the manner in which the dura mater envelops the brain; but we will not be able to pursue its different prolongations, a knowledge of which is highly important; it is for this reason that we advise to defer an examination of them until after that of the brain. In following a different course, it will be impossible to form an idea of the disposition of this membrane, as regards the brain. We may, it is true, examine its external conformation, such as its color, density, thickness, &c.; but we must afterwards sacrifice it in order to pass to the study of the brain. For this purpose we should cut it circularly on a level with the bones of the cranium, and we expose the brain, in raising the dura mater on its summit; then in detaching it from the crista galli apophysis, it is to be drawn from before backwards, and then abandoned in this place. We shall find no difficulty in thus isolating it; for the serous humor with which its internal surface is continually lubricated, permits it to move freely on the cerebral mass.

Such is not the case as regards the other two membranes applied immediately on the brain, and termed arachnoidea and pia-mater ; both of these are extremely thin compared to the first. The arachnoidea, especially, presents very great difficulty in its preparation ; it does not dip between the convolutions of the brain, but it proceeds without stopping, over its whole external surface, adhering intimately to the pia-mater, from which it cannot be detached but with much trouble except towards the base of the brain, where their separation is more sensible, and where the arachnoidea can be distinctly seen ; however, if we should wish to see it on the summit of the brain, we should gently raise, either with the small dissecting forceps, or with the point of a scalpel, the smallest portion of membrane perceptible—it is the arachnoidea. The pia-mater is beneath ; it is a species of cellular network, interspersed with a great quantity of blood-vessels ; it must be raised with the dissecting forceps, and detached with caution, because it dips down between the convolutions of the brain, and in drawing forcibly on it we frequently remove with it the substance of this organ. At the end of this article, there will be found more ample details respecting the preparation of the three membranes of the brain. When we have thus removed the membranes, which cover the brain, this latter remains exposed, and presents to the eye its numerous convolutions, which have been compared to those of the intestines. We should, in the first place, and before proceeding to its ulterior study, examine its form, volume, consistence and color : this last is not the same on its external surface and in its interior. In order to assure ourselves of the fact, we should cut a portion of its substance from the sides at the depth of about

an inch, and we shall then judge not only of this difference of color, grey without and white within, but likewise of the thickness of that which is external, and which measures nearly two lines. The first bears the name of cineritious or cortical, and the other that of medullary substance.

We then pass to the particular examination of the brain. This is long and difficult, and will require considerable patience. It must not be forgotten that its study and preparation should go together. The impossibility of preserving the objects in place, in proportion as they are exposed, is the principal cause.

It is not an unfrequent circumstance for the brain, on which we are about to make the necessary researches, to be of a soft consistence, which interferes considerably with the preparation of the different parts composing it. In order to render it more firm and thus preserve it for a longer time, we should put it for twelve or fifteen hours into a solution of the muriate of mercury, or into a mixture of water and some acid ; but we must not allow it to remain too long in contact with these reactives. The solution of the muriate of mercury imparts to the whole cerebral mass a dull white color ; and the acids, a black color, very unfavorable to the study of the brain. Let the student commence by removing the portion of this organ situated above the horizontal and circular section of the bones of the cranium, and from this will result what anatomists call the oval centre of Vieussens. In this section the brain is to be removed by masses, so as to leave untouched an elongated, whitish body, which occupies the centre of the two hemispheres of the encephalic organ, and termed corpus callosum ; in separating carefully the substance of the two hemispheres,

and viewing the interval, we shall see very distinctly the corpus callosum.

In order to examine the objects placed below, which are numerous, we should carry cautiously the point of the scalpel on the sides and along the whole extent of the corpus callosum. We will know that it is completely divided, when, in endeavoring to raise it, we perceive a species of arch below. Then with the handles of two scalpels, we raise it on its lateral portions, in order to get a view of a very thin medullary body, placed immediately below ; it is the *septum lucidum* (*septum medium*) the transparency of which we should not neglect to notice. The *corpus callosum* and *septum lucidum* being carried backwards, we shall see that the latter reposes on a medullary prolongation, called the arch with three pillars, which is applied immediately over a species of triangular cavity, termed the lateral ventricles. In order to expose them, it will be necessary to remove the arch with three pillars, which must be carried backwards, as also two reddish bodies, a species of vascular network, called plexus choroides. These different operations require considerable address and a certain delicacy in the manner of raising and removing the objects already examined, the presence of which interferes with the study of those which are placed beneath.

The lateral ventricles, freed from the corpus callosum, the transparent partition, the arch and plexus choroides, present the following objects, proceeding from before backwards :

1st. Two bodies rather voluminous, greyish, and of an ovoid form, called corpora striata, occupying the whole anterior part of the space, which has been exposed.

2d. The thalami nervorum opticorum, placed between the former, and connected to each other, of a whitish color, and separated from the corpora striata by a medullary bandelette, which is prolonged backwards, and termed *tænia semi circularis*.

In separating the thalami of the optic nerves, we perceive in the interval a small cavity, called third ventricle; at the extremities of this species of groove, there are two openings, above which we remark two medullary cordons placed cross-wise, termed anterior and posterior commissures, the extent and direction of which we should observe, in removing the portion of the cerebral mass, which covers them on the two sides.

The anterior opening leads to the pituitary tube and gland; the posterior to the fourth ventricle. But before passing to the examination of these different objects, we should first complete the inspection of every thing to be seen in the lateral ventricles. We must, therefore, continue our researches behind and on the sides, separating more and more the cerebral mass in the direction of the semi-circular bandelette. In this way we will penetrate the profoundest part of the lateral ventricles; in order to arrive at this point, we must be guided by the presence of a flat medullary body, which appears to be continuous with the posterior prolongations of the arch with three pillars, and which is termed the feet of Hippocampus, one of the borders of this broad medullary bandelette is as it were scolloped. Anatomists have termed this portion, *corpora fimbriata, striata*. When these objects have been seen and recognized properly, we should then pass to an examination of the others. In raising more and more, and drawing backwards the posterior part of the arch with three pillars,

we will perceive four whitish tubercles, integral parts of the brain, in the middle of which is observed a small greyish body, which is sometimes removed with the arch with three pillars, when we do not attend to this circumstance, or when dissecting too rapidly; it is the peneal gland, in which is constantly found small gravel, of which we can assure ourselves by pressing it between the fingers, after having obtained an idea of its situation and relations; here terminates the examination of the objects placed on the lateral ventricles.

In separating the thalami nervorum opticorum, we shall observe a cavity extending from before backwards—it is the third ventricle. If we follow the anterior opening, we shall reach the *infundibulum*, a species of funnel, at the bottom of which there is a small greyish prolongation, which continues as far as the sella turcica; it is the pituitary tube, leading to the gland of the same name; but in order to have a better view of these objects, we must gently raise the brain at its anterior part; or cut two whitish cords, which pass over the sella turcica and conceal them from our view: in this way, we shall arrive without difficulty at the pituitary gland, which is profoundly lodged in the fossa of the same name.

The posterior opening of the third ventricle leads to the fourth, which cannot be distinctly seen until after having removed the entire mass of the cerebellum, the medulla oblongata, and remaining portion of the cerebrum. For this purpose, we must cut in its whole circumference that portion of the dura mater, placed between the cerebrum and cerebellum; we must then remove the two hemispheres of the cerebellum from the occipital fossæ, and in carrying a scalpel as far forwards as possible in to the spinal

canal, we separate the prolongation of the medulla oblongata; finally, with the scissors, we should destroy, in proportion as the whole is raised, the vessels, nerves, and every thing, that could oppose the free passage of the encephalic mass, which should be placed upon the table, in order to continue our researches. The first objects to examine are, the cerebellum, its prolongations towards a medullary body, situated between the cerebrum and cerebellum, and called medulla oblongata, annular protuberance, (méso-céphale.) It appears to give origin to four prolongations, two for the cerebrum and two for the cerebellum; they are termed the arms and legs of the medulla oblongata; their re-union bears the name of pons varolii.

Between the cerebellum and medulla oblongata, is remarked the fourth ventricle, the different objects of which may be seen, by raising a species of medullary tail (queue,) which terminates the medulla oblongata, and which is the commencement of the vertebral or rachidien medulla. The first thing presenting itself to view is a species of groove, called *calamus scriptorius*, farther on, a small medullary partition (valve of Vieussens) beyond which is found the aqueduct of Sylvius; and if we carry our researches still farther, we will arrive at the posterior opening of the third ventricle, precisely at the spot at which we had abandoned the examination of the cerebrum, in order to pass to that of the cerebellum, which presents nothing peculiar in its interior, if we except the disposition of the two grey and white substances, the particular arrangement of which, no matter in what direction it may be cut, gives rise to what is termed the arbor vitæ.

The spinal marrow is contained in the canal of the same name, and extends from the medulla oblongata to the in-

ferior portion of the sacral canal. It cannot be exposed, except by removing the posterior part of the vertebræ in the whole extent of the spine. We must proceed in the following manner : the posterior part of the vertebral column being completely freed from its muscles, we must remove, with the chisel and mallet, the whole posterior portion of the vertebræ, which will perfectly expose the spinal marrow. However, we should not touch that part of the canal through which pass the vertebral nerves, which originate on the sides of the spinal marrow, and emerge from the canal in the same direction. We should likewise avoid injuring the spinal marrow and membranes enveloping it : but in order to render this preparation more complete, it will not be sufficient to have the vertebral canal exposed in its whole length ; it will likewise be necessary to have all the posterior part of the bones of the cranium removed, which will be done with a saw, chisel, or with a sharp-pointed hammer. We will perceive by this, that it is difficult for one head to suffice for the study of the encephalic organ ; but this inconvenience, if it be one, furnishes us the means of seeing the origin of the nerves, with which it is not possible to occupy ourselves in the special preparation of the brain.

If we have properly prepared the spinal marrow, we shall perceive that it is enveloped by a prolongation of the membranes of the brain, which should be cut in their whole posterior portion. A space, which is rather considerable is remarked between the membranes and medulla ; sometimes a small quantity of water is found contained in it ; more frequently, however, there is none. In the spot at which the spinal marrow leaves the annular protuberance, it is as it were surrounded by four *renflemens*, to

which have been given the names of olivary and pyramidal eminences. The spinal marrow descends into the vertebral canal, preserving a volume nearly relative to the cavity in which it is enclosed; it terminates towards the first lumbar vertebra, and, at this place, gives origin to a quantity of nervous cords, which prolong into the vertebral canal, and accompany it to the bottom of the sacrum; it is the *Cauda Equina*.

Preparation of the Membranes.

The preparation of the spinal marrow, such as we have just indicated, has an additional advantage of furnishing us with the means of observing the arrangement of the membranes of the brain; but if we could procure the head of a child, it would be preferable, on account of the facility of sawing, or even of cutting the bones. We should proceed as follows: were move on the right and left, from the superior part of the head, a portion of the bones of the cranium, in form of a lozenge, the great diameter of which proceeds from before backwards. Its extent must measure from the environs of the frontal protuberance, to the external occipital prominence, and from the temporal fossa to within two fingers' breadth of the section on the opposite side; in this way, there remains in the centre and in the same extent, a species of osseous band, which follows pretty correctly the direction of the superior longitudinal sinus, and which sustains it. Having removed the bones, we should open the dura mater on a level with the section, and the brain is to be expelled through the this opening; the same thing should be done for the cerebellum through the foramen occipitale, and, in this way, the dura mater will be preserved in its integrity. We shall

then see, in front, that portion of this membrane, which is placed between the two hemispheres, and which is termed the falx of the brain; lower down and behind there is a species of floor formed by this same membrane, which marks the separation between the cerebrum and cerebellum; it is the tentorium; and below is observed the falx of the cerebellum. This is not all; the dura mater likewise forms sinuses or veins of the brain, the volume of which is considerable, and the number multiplied. The head, which has served for the preparation of the brain, will also answer for that of these sinuses.

The longest and most considerable is the superior longitudinal sinus, which is lodged in the groove of the same name. We should break the bones of the cranium, in this spot, in order to pursue it; it is for this reason that it would be preferable to have the head of a young subject. Along the inferior border, and free from the falx, is another sinus, much smaller than the preceding, which is termed the inferior longitudinal sinus. Both of them reach a third, which appertains in part to the tentorium, and which is called the right sinus. Nearly in the same place, the superior sinus divides into two branches, which pass into the lateral grooves and form the lateral sinuses.

Another mode of seeing the longitudinal sinus is to remove the top of the cranium, without interfering with the dura mater. The sinus continues along the superior part of the head, and it can be traced in its whole length with great facility.

The other sinuses of the dura mater, more numerous, are smaller and shorter than the preceding. They are the superior and inferior petrous sinuses, which proceed

along the superior and inferior borders of the petrous portion of the temporal bone, and lose themselves in the lateral sinuses. On the lateral portions of the body of the sphenoid, and around the sella turcica are observed the cavernous and coronary sinuses. In fine, the occipital sinuses are distinguished into superior and transverse. The first, two in number, go along the lateral portions of the internal occipital crest, and are lost in the gulf of the jugular vein; the second, more numerous, are placed across the vertebral groove, and communicate with the inferior petrous sinuses.

We must, with the point of a scalpel or scissors, open these different sinuses in their whole extent, in order to examine their interior, and follow more exactly their course; they are ordinarily filled with thick blood of a deep red color.

Description.

BRAIN.

Encephalon G. ; Cerebrum L.

Situation and Relations.—In the interior of the cranium, the greatest part of which it occupies; in relation with the bones of this cavity, except posteriorly and below, where it corresponds to the cerebellum.

Figure.—It is relative to that of the cavity in which it is enclosed, and represents tolerably well an ovoid body, the inferior portion of which is flat.

Division.—Superior surface, which is in correspondence with the parietal bones and a portion of the frontal: inferior surface, occupying the internal part of the base of the cranium, and presenting three tubercles, divided into anterior, middle, and posterior. Lateral regions, lodged in great part in the parietal fossa, and having a profound fissure at this point, called the fissure of *Silvius*. The

posterior extremity, large, is received in the superior occipital fossæ; the anterior extremity, corresponds to the coronal fossæ. The whole external surface of the brain is immediately covered by the pia-mater and arachnoidea, and is in relation with the internal surface of the dura mater.

But this division appertains only to the external conformation of the brain, and does not point out the numerous objects, which result from the arrangement of its different parts. We should, therefore, remark that the general mass of the brain is divided into two equal portions, one on the right, the other on the left, called hemispheres of the brain; in the interval of the two hemispheres, there is a profound depression, which lodges the falx of the brain.—Each of the hemispheres presents in addition circumvolutions and imfractuositities, the figure and extent of which are variable. In separating the two hemispheres, and in performing the section already mentioned, in order to form the oval centre of *Vieussens*, we will observe successively the following objects:—

1st. The corpus callosum, a species of medullary floor, elongated from before backwards, broader posteriorly than in front; its superior surface is furnished in its whole length with the callous arteries, and it presents at its middle portion a slight depression; its inferior surface reposes on the transparent septum; its lateral portions are confounded with the cerebral mass.

2d. The *septum lucidum* sustains the corpus callosum, on the one hand, and reposes on the arch with three pillars on the other. This septum is formed by the *adossement* of two medullary lames in the interval of which is

remarked a cavity, which most generally contains a variable quantity of serosity.

3d. The arch with three pillars is the portion which presents itself after having removed the corpus callosum and septum. It is a medullary triangle, placed between the above objects and lateral ventricles. Above, the arch corresponds to the septum; below, it reposes on the thalami nervorum opticorum in front, and on the lateral ventricles behind; the anterior angle, formed by two cords, which continue to separate more and more, loses itself in the cerebral mass; the posterior angles dip down into the lateral ventricles, and form the *corpora fimbriata*; the lateral portions are embraced by the choroid plexus.

4th. These plexuses are two reddish membrano-vascular productions, which extend from the environs of the thalami nervorum opticorum to the posterior part of the lateral ventricles.

5th. The lateral ventricles cannot be seen until all the objects just described have been removed. We will find there from before backwards the corpora striata formed of a greyish substance externally, and of lamæ alternately grey and white internally; piriforme eminences, the large extremities of which, turned forwards touch each other in this place, and present posteriorly an interval in which the optic nerves are lodged.

The thalami nervorum opticorum, ovoid, placed in the interval of the corpora striata, correspond above to the arch and corpus callosum, below to the annular protuberance, on the sides to the corpora striata and cerebral mass; within, they are thrown against each other, contiguous in their whole extent, except in the middle portion and somewhat anteriorly where there is observed a medullary cord, which passes from one thalamus to the other.

There is remarked, between the corpora striata and thalami nervorum opticorum, a slight depression which lodges a whitish cord, known under the name of semi-circular bandelette, and which, from the anterior part continues posteriorly as far as the fundus of the ventricles.

The horns of Ammon, feet of Hippocampus, are two medullary prolongations, which seem to be the continuation of the posterior angles of the arch with three pillars, and which extend to the deepest portion of the lateral ventricles, the course and direction of which they follow. The anterior extremity, lower than the posterior, is terminated by two, three, or four tubercles. The color of these prolongations, white externally, is grey and of an ash hue internally.

On the internal and concave part of the feet of Hippocampus there is a medullary lame scoloped on its free border, and termed *corpus fimbriatum*. This body is nothing more than the continuation of the posterior pillars of the arch; but it does not accompany the feet of Hippocampus to their termination.

On the external side of the feet of Hippocampus, and nearly at the middle portion, there is a tubercle called ergot; its form is similar to that of the cavity in which it is enclosed, and it is curved in a sense contrary to the peduncles, on which it borders. Its extent is not very considerable, and its color is altogether similar to that of the horns of Ammon, the bandelette, &c.

6th. To these different objects, we must join a description of the tubercula quadrigemina, and pineal gland, although they do not appertain especially to the lateral ventricles.

The tubercula quadrigemina, placed under the arch

with three pillars and at its posterior part, are arranged in pairs, and distinguished into superior and inferior. They sustain in their interval a greyish body, enveloped by a prolongation of the choroid plexus, termed pineal gland.

This pretended gland is of a very soft tissue, breaks easily under the finger, and then leaves a quantity of small gravel, the presence of which cannot be attributed to any known cause, and does not appear to have any particular object.

7th. In separating the thalami nervorum opticorum, the eye falls on a cavity elongated from before backwards—it is the third ventricle. It presents two openings; the posterior is surmounted by a medullary cord placed crosswise, called the posterior commissure, the extent of which in the cerebral mass is considerable; it is on the posterior part of this commissure that repose the tubercula quadrigemina and pineal gland; this opening leads to the fourth ventricle. The anterior is, like the preceding, also surmounted by a medullary cord, situated transversely; it communicates with a conduit, which from its figure has received the name of funnel, at the bottom of which is remarked the pituitary tige and the gland of the same name; this last is lodged on the sella turcica, the cavity of which it occupies: widened on the side at which it corresponds to the os-sphenoides, it is terminated above by a prolongation, which has scarcely less than three lines in length, called pituitary tige. The color of the gland is yellowish externally, and greyish internally; its consistence is soft and friable.

8th. The aqueduct of Silvius and valve of Vieussens terminate the description of the cerebrum. The first of

these objects is a conduit placed between the posterior commissure, tubercul quadrigemina and annular protuberance, and terminates in the fourth ventricle. The second is a greyish medullary lame, termed valve of Vieussens; it is very thin, and resists feebly any shock imparted to the brain.

CEREBELLUM.

Situation and figure.—In the posterior fossæ of the base of the cranium, below the tentorium.

Division.—Like the cerebrum, it is formed of two hemispheres, and its figure resembles somewhat an ellipsis, the great diameter of which is transverse. We consider in the cerebellum a superior surface, on which is observed the superior vermicular eminence; an inferior surface, which corresponds to the bones of the base of the cranium, and presents the inferior vermicular eminence; in addition, we remark on this region, and in the interval of the two hemispheres, a species of crucial eminence, the lateral branches of which are lost in the cerebellum; the posterior is free, and the anterior is confounded with the annular protuberance.

The whole external surface of the cerebellum presents a great number of convolutions, which give it the appearance of being composed of lames united to each other; in cutting it by slices, the interior presents species of arborescent branches, which has acquired for it the name of *arbor vitæ*.

CEREBRAL PROTUBERANCE.

Situation and relations.—Placed between the cerebrum and cerebellum, of which it is the point of communi-

cation, the cerebral protuberance occupies the basilar depression, on which it is sustained on the one hand, and, on the other, corresponds to the cerebrum and cerebellum. The following objects are presented :—

1st. The mamillary eminences, which, from the pituitary tige, extend to the anterior part of the protuberance.

2d. The prolongations of the cerebrum and cerebellum, to which have been given the names of arms and legs of the medulla oblongata, are four large medullary cords which, from the protuberance, proceed, the anterior towards the cerebrum, and the posterior towards the cerebellum.

3d. The pous varolii, or annular protuberance, a common rendezvous of the four above prolongations, quadrilateral, corresponds above to the aqueduct of *Silvius*, and below to the occipital depression. There is remarked at its middle portion a groove, which lodges the basilar artery. In front it is free; behind, it gives rise to the vertebral or spinal marrow. It is composed of medullary substance, mixed with a small quantity of greyish material.

SPINAL MARROW.

Rachidienne.

Situation and relations.—Its length is considerable, and extends from the posterior and inferior part of the protuberance to the top of the first lumbar vertebra. Its figure resembles tolerably well the cavity in which it is enclosed; however, it appears in general slightly flat from before backwards. Constantly in relation with the vertebral canal, it is separated from the bones which form it, by the presence of three membranes, prolongations of those of the brain.

Division.—Anterior portion, which, at its origin, pre-

sents the olivary and pyramidal eminences, separated by a depression which continues along its whole length, and which makes it appear like the result of the *adossement* of the two medullary cords. This opinion is not unfounded, and I have frequently succeeded in isolating these two cords for several inches. The posterior part likewise presents a depression, which is more superficial than the preceding. The lateral portions give origin to the cerebral nerves which, at their commencement, present an anterior and posterior faisceau. Above, the spinal marrow corresponds to the cerebral protuberance of which it is the prolongation; below, it terminates at the first lumbar vertebra, where commences the cauda equina, which continues down the rest of the vertebral canal.

Structure and uses.—If we are content with simply inspecting the external aspect of the encephalic mass, we will observe that it is composed of two substances differently arranged; one, more abundant, is white or medullary; the other greyish. The name of cortical which has been given to this last, cannot be applied to it in all the parts of the brain where it is found, for it is sometimes situated externally, and sometimes concealed in the interior. Some anatomists have pretended, without foundation, that its color was due to the quantity of vessels with which this substance is furnished: an attentive examination will serve to destroy this assertion. Neither can any inference be drawn from the diversity of arrangement in the two substances. It appears probable that the medullary which is also the most abundant, possesses more extensive properties. A late opinion seems to take these properties from it in order to give them to the cortical substance. Dr.

Gall, by recent researches, appears to have demonstrated that the nerves, of which the medullary substance is nothing more than the assemblage, originated in the greyish substance.

Great obscurity still prevails respecting the uses of the brain: it is, as is generally said, the organ of sensation and motion; but we cannot determine in what way these phenomena of life act. Its soft and friable consistence, the extreme tenuity of its parts explain, to a certain degree, the subtilty of the operations, which are effected in it. This is all that physiology can explain in reference to the functions of the brain. But to seek to understand the uses of the different parts contained in its interior, and to unfold the arrangement of these parts, is an undertaking, which so far proved unavailing.

The opinion of the ancients, respecting the secretion of a cerebral fluid, admitted for many ages, afterwards abandoned, and again resumed in our times, is far from being based on constant and positive facts. Let us hope, however, that time, the labor of anatomists, the experiments of physiologists, and the repeated observations of the derangement of the brain, will unveil the mystery which conceals from our observation its wonderful functions.

MENINGES OR MEMBRANES OF THE BRAIN.

(*Meninges G.*)

Situation and relations.—Three in number, contained in the cavity of the cranium and vertebral canal, and serving as an envelope and support to the different parts of the cerebral mass: they should be examined separately.

1st, *Dura Mater.*—This is the most external, as well as the thickest of the three. It is applied, on the one hand,

to the internal surface of the bones of the cranium, with which it contracts more intimate adhesions at the base, and in the environs of the foramina and sutures; on the other hand, it corresponds to the arachnoidea, but so far from adhering to it, it is on the contrary separated from it by an abundant serosity, which renders its surface smooth and polished. It is to the numerous vessels which, from this membrane, enter the bones of the cranium, that is due the adhesion which cannot be overcome except by lacerating them. The drops of blood with which the dura mater is covered, after having removed the summit of the cranium, leaves no doubt as to the truth of this assertion.

The dura mater is of a pearl white color, and composed of two lamæ united to each other by a very dense cellular tissue. It furnishes three prolongations, which are: 1st, the falx cerebri, situated between the two hemispheres, having a figure nearly similar to the instrument from which it receives its name. Its superior border forms in part the superior longitudinal sinus, and the inferior the sinus of the same name. In front, the falx is attached to the apophysis *christa galli*; behind, it corresponds to the internal occipital protuberance. 2d, The tentorium cerebelli, situated transversely, separates the cerebrum from the cerebellum. Its figure, difficult to determine, is relative to the organs with which it is in contact: superiorly, it supports the posterior lobes of the cerebrum: inferiorly, it reposes on the cerebellum. Its circumference is attached to the borders of the lateral depressions on the occiput, and, at this place, it contributes to the formation of the lateral sinuses. 3d, The falx cerebelli, similar to the falx cerebri,

but infinitely smaller, is placed in the interval of the lobes of the cerebellum.

The uses of these different folds of the dura mater are evident, and do not require any explanation; but besides these folds, the dura mater forms sinuses, real venous conduits, which, receiving the blood from the arteries of the brain, deposit it in the internal jugular veins. These veins are: 1st, The superior longitudinal, which is also the most considerable. It extends from the foramen cœcum to the internal occipital protuberance. Its figure is triangular; narrow at its origin, which is in front, it becomes broader in proportion as it is examined towards its posterior part, where it bifurcates, and forms the lateral sinuses, which are the continuation of it.

2d. The lateral sinuses. These are received in the lateral depressions, and lodged in the cavity presented by the circumference of the tentorium cerebelli. They extend from the protuberance to the foramina lacera posteriora. Of these two sinuses, the right is ordinarily the largest.

3d. The inferior border of the falx cerebri lodges the inferior longitudinal sinus, the extent and volume of which are not very considerable. It loses itself in the right sinus.

4th. This bears the name of the Press of Herophilus. It extends from the tentorium cerebelli to the occipital protuberance. It opens, on the one hand, into the inferior longitudinal sinus, and, on the other, loses itself most commonly in the right lateral sinus.

5th. The superior petrous sinuses are situated in the groove on the superior border of the petrous portion

of the temporal bone, and lodged in a portion of the circumference of the tentorium cerebelli. Anteriorly they sometimes communicate with the cavernous sinus, and open posteriorly into the lateral sinuses.

6th. The inferior petrous sinuses are situated in the inferior petrous grooves: narrower than the preceding, they communicate in front with the cavernous sinuses, and open behind into the lateral sinuses.

7th. The cavernous sinuses are lodged in the carotid grooves, and extend from the internal orifice of the carotid canal to the anterior clinoid apophyses. Their interior, very ample, is filled with a spongy tissue, not unlike that of the corpora cavernosa; they contain, in addition, the carotid artery and the nerve of the sixth pair. They receive, in front, the blood brought by the ophthalmic veins, and communicate posteriorly with the petrous sinuses.

8th. The coronary or circular sinuses surround the sella turcica, and open into the cavernous sinuses.

9th. The superior occipital sinuses, or sinuses of *Duverney*, are situated on the lateral portions of the internal occipital crest. They open on the one hand into the lateral sinuses, and, on the other, into the gulf of the jugular veins.

10th. The inferior or transverse occipital sinuses, usually two in number, are placed crosswise on the basilar depression of the occiput, and lose themselves in the petrous sinuses.

2d. *Arachnoidea*.—This second membrane of the brain, excessively thin and transparent, is situated between the dura mater and pia mater: it envelops the entire cere-

bral mass, without penetrating its interior. On the one hand, it corresponds to the dura mater without adhering to it, and is continually lubricated in this place by an abundant serosity; on the other hand, it is applied on the pia mater, from which it is rather difficult to separate it, except at the base of the cranium, where these two membranes offer an adhesion less intimate.

3d. *Pia mater*.—This membrane, very thin, is applied immediately on the brain, of which it covers not only the external surface, but likewise dips down between the convolutions of this organ, and penetrates its cavities.

This membrane is furnished with a great quantity of vessels, which accompany it in the brain, and of which it is the envelope and support.

The spinal marrow is enveloped by a prolongation of the three membranes of the brain. The most external is the dura mater, and it is thicker than on the brain; the second is the arachnoidea, placed between the preceding and the pia mater, and very distinct from both of them; the third is the pia mater, excessively thin, and applied immediately on the medullary substance.

This description of the membranes, very short it is true, is conformable to what is presented on an inspection of the cadaver, and to what modern authors have given in their works.

Structure and uses.—The structure of the different membranes of the brain does not appear to be the same. The first appertains to the order of the fibrous, the second to that of the serous; as regards the third, it is not yet satisfactorily demonstrated that it is a membrane. The multiplicity of the vessels, with which it is furnished, seems

to indicate that it is merely a cellular net-work, destined to serve as a support to these vessels, and to accompany them in the soft and pulpy mass of the brain.

Their uses are less equivocal. All anatomists agree that they serve as an envelope for the nerves, which emanate from the brain and spinal marrow; that the first of these membranes, the thickest and most solid, is a sort of protection against any violence done to the cerebral mass; that the arachnoidea embraces more directly the brain, and connects, as it were, its different parts: it, moreover, serves for the secretion of a humor, which lubricates its internal surface; finally, that the pia mater envelops the vessels of the brain, sustains and favors their small divisions.

THE EYE AND ITS APPENDAGES.

General considerations.

The exposition of the organ of vision is not limited to the parts constituting the globe of the eye; we likewise embrace under this head the lachrymal organs, as also the muscles of the eye, the eye-lids, and eye-brows. The anatomical arrangement requires that we should first study the eye-brows, then the eye-lids, and afterwards pass to the lachrymal organs, to the muscles of the globe of the eye, and to that of the superior eye-lid, in order to terminate by the globe itself.

Anatomical Preparation.

Eye-brows.—Placed above the orbits, the eye-brows do not require any preparation. The only remarkable circumstance which they present, is the manner in which they are inserted into the integuments of the forehead,

and the direction they effect externally ; it should not be forgotten that they are placed immediately above the corrugator supercillii, the functions of which are entirely relative to the motions imparted to them by this muscle.

Eye-lids.—We must consider in the eye-lids the skin which covers them, the cartilages which form them, the lashes with which their free borders are furnished, the muscles which cause their motion ; and finally the membrane by which they are lined internally.

The skin is a continuation of that of the cheeks and forehead ; it is very thin, and the cellular tissue which is interposed is but little abundant and dense, for which reason we must expose them slowly and cautiously. When deprived of their external covering, we will see the cartilage or broad ligament which forms them in part ; it descends from the orbital border to the environs of another thicker cartilage, which is found along the free border of each eye-lid, and which is termed the tarsal cartilage. This cartilage permits us to see without difficulty, on the side of the free border of the eye-lid, a number of little eminences (from 30 to 40) placed perpendicularly by the side of each other ; they are called the glands of *Meibomius*. At their extremities are remarked the eye-lashes, the number and length of which are very variable. We should also examine the manner in which they are retained on the free border of the eye-lids, which may be easily done. The conjunctiva is the common and external membrane of the eye and lachrymal organs. It may be readily examined with the naked eye, on the internal surface of the eye-lids ; but it is very difficult to recognize it on the globe, where it is extremely thin ; nothing but maceration or ebullition will render it visi-

ble. The levator palpebræ superioris will be described hereafter.

Lachrymal Organs.

They are composed of the lachrymal gland, puncta lachrymalia, caruncula lachrymalis, sac and nasal duct.

Lachrymal Gland.—It is situated in the external orbital angle, and lodged in a depression presented by the orbital arch. In order to expose it to view, we should divide the conjunctiva, and remove the cellular tissue; we shall then arrive at a reddish body, elongated from before backwards: it is the lachrymal gland. It is pierced by several openings, which permit the tears to escape, but it has no particular excretory duct; when closed, the eye-lids form a triangular canal which takes its place.

Towards the internal orbital angle, at the free border of each eye-lid, is a small fleshy button, pierced in the centre—it is the punctum lachrymale, which will be rendered very apparent by turning the eye-lids outwards. We will be enabled to follow the trajet of these small canals, by introducing into each punctum a hog's bristle, the course of which, different in the superior and inferior, indicates the direction which they take in order to arrive at the lachrymal sac.

The semilunar valve (*plica semilunaris*) is nothing more than a very small duplication of the conjunctiva, placed at the internal commissure. Not very apparent in man, it presents a considerable extent in several animals. In order to render it more sensible, we should draw the globe of the eye inwards; this is the only preparation it requires.

The caruncula lachrymalis is that reddish tubercle, placed in its internal commissure, the preparation of which it is difficult to indicate. When accurately examined, it

will be found to consist of a group of sebaceous glands, of which, according to some writers, there are seven, ranked two in a row, and one on the top of the others. In general, the different objects just mentioned should be examined with a magnifying glass.

The lachrymal sac is situated below and more profoundly than the parts already described. In order to expose it, we will have to remove cautiously the semilunar valve and caruncula; and leave in place the puncta and lachrymal ducts, as also the bristles introduced into these latter. In proceeding thus, we will arrive at a small cavity the bottom of which is reddish, and into which penetrate the bristles, which were introduced into the lachrymal ducts. On the other hand, the lachrymal sac communicates with the nasal duct, the preparation of which will be reserved until that of the nasal fossæ.

Muscles of the Eye.

They are eight in number, if we comprehend among them the orbicularis palpebrarum and levator palpebræ superioris. The first has already been described, the others require the following precautions:—we should select, for the preparation of the muscles of the eye, a head, which has served for the examination of the brain. We then have nothing more to do than to carry the saw from above downwards in the direction of the two orbital angles, so that the two portions of the saw unite posteriorly in the environs of the foramen opticum; we must push forwards, in breaking the bony pieces which resist, the species of angle resulting from the operation, and we shall have exposed the levator palpebræ superioris, which is covered by an expansion of the dura mater. This

muscle should be exposed and left in place. Beneath, is found the superior straight muscle of the globe of the eye, surrounded by a quantity of fatty matter. In order to pursue the dissection of the other muscles of the eye, I would advise the student to remove the portion of bone which has been sawed; the levator palpebræ superioris may be left in place, or it may be removed with the sawed portion. The muscles of the eye are enveloped in a great quantity of fat, of which it will be necessary to free them, sometimes with the scalpel, but more frequently with the scissors. One of them will require more particular attention—it is the great oblique, which takes its origin, like the four straight muscles, posteriorly in the environs of the foramen opticum, then travels along the internal paroi of the orbit, and, after arriving at the internal orbital angle, degenerates in a tendon which is received into a species of cartilaginous pulley; thence, it becomes fleshy and is reflected in order to become implanted on the globe of the eye. The inferior oblique arises from the environs of the nasal duct, and goes to the inferior part of the eye. The four straight muscles extend from the environs of the foramen opticum towards the globe, continuing always to separate more and more from each other. Nothing interferes with their dissection; the fat surrounding them is easily removed, and there remains nothing after the preparation of the muscles, but the globe of the eye, which exacts a special examination.

Globe of the eye.—After having acquired a correct idea of its situation, form, and relations with the surrounding parts, we should remove it from the orbital cavity; in order that we may pass to an examination of its constituent portions. It will be proper, in order to have a

more distinct view of them, to use the eyes of an ox, calf, or sheep, in which the different objects, being more developed, are likewise more easily recognized. It is indispensable to have several of them at our disposition, for the sections are numerous, the fluids quickly escape, the membranes are multiplied, and some possess extreme tenuity. The first thing, which strikes our observation is the difference between the two external membranes, one of which, called sclerotica, opaque, has considerable extent; it forms the three posterior fourths of the globe of the eye. The other, placed in front, occupying comparatively but a small space, is called the transparent cornea. In order to see the union of these two membranes, we must examine them both externally and internally. In this latter sense, the cornea appears as if encased in the sclerotica. It is easy to separate them from each other; for this purpose, they should macerate for some days in cold water, or be plunged into boiling water; a few hours will suffice to effect their separation. These two membranes envelope the globe of the eye. The objects they enclose are, proceeding from before backwards, the aqueous humor, iris, ciliary ligament and processes, cristalline lens, vitreous humor, retina, and choroides.

If it should be desired to prepare these different objects in the order in which they have just been mentioned, considerable difficulty will be experienced; however, it may be accomplished by proceeding in the following manner: remove, without compressing the globe of the eye, the transparent cornea alone, and the aqueous humor should not be allowed to escape until we have had an idea of its quantity; next is observed a blackish partition—the iris which, by its great circumference,

adheres to the ciliary ligament. It will be necessary to cut the opaque cornea, in proportion as we advance in the preparation of the parts. The iris, after the evacuation of the aqueous humor, touches and is applied on a very white lenticular body, called the cristalline lens. We should pass the point of a scalpel or of its handle between the cristalline and iris, and raise this membrane in order to appreciate more thoroughly its particular form and disposition. On the side at which it corresponds to the cristalline are found the ciliary processes, species of membranous feuillets, disposed in radii, the assemblage of which constitutes the ciliary body; but it is difficult to have a good view of them in proceeding as we have just indicated.

Behind the iris, is observed the cristalline lens, which is itself received in a depression presented to it by the vitreous body. At this stage of the dissection, we should remove the vitreous body and lens, by pressing on the globe of the eye; once evacuated, they can be studied to much more advantage, and we may then see the two proper membranes of the eye, the retina and choroides, placed behind the vitreous body. The first presents itself under the form of a pulpy pellicle, which is very easily detached from the choroides placed behind and applied immediately on the internal surface of the opaque cornea. This latter will be recognized by its dark color, with shades of green and blue.

The preparation of the eye, such as we have just described, will not answer for all the parts of this organ; the iris requires a more attentive examination; the retina and choroides may be seen more advantageously by examining them differently; the ciliary processes, the

body and circle of the same name are scarcely perceived, and these different objects inspire considerable interest, and excite our curiosity. But, we repeat it, it will be necessary to have a number of eyes; we should multiply the sections, and spare nothing in the study of an organ, admirable in its composition, and presenting the richest phenomena of optics.

One of the best modes of viewing the choroid, is to remove with great care the sclerotica without touching the choroides. For this purpose, we must have an entire eye, and we must commence outwards at the posterior portion. We shall observe, in this manner, what is termed the external surface of the choroides; its internal surface will be exposed, by cutting the eye circularly in the direction and somewhat in front of the ciliary ligament; all the humors of the eye must be evacuated by pressing lightly on the globe; we remove the retina, and in reversing the bag like the finger of a glove, we will have a perfect view of the internal surface of the choroides. It terminates, in front, behind the ciliary ligament, which it in part forms.

The retina may be examined in the same way but we should have an eye prepared as was described farther back, in order to see the manner in which it disposes itself around the optic nerve.

As for the iris, it will be necessary to make a first circular section of the eye, in front of, and quite near this membrane, being careful not to embrace it, and then perform a second some lines beyond; we should evacuate the aqueous humor, crystalline lens and vitreous body, and plunge the remaining portion into water. The iris will float in the liquid and it will be seen to advantage. We may afterwards examine the disposition of the ciliary ligament.

A small canal is observed between the cristalline lens and vitreous humor ; we should carry the point of the scalpel into a part of the interval which separates them ; introduce, if possible, a small straw into the opening, or even blow into it ; we shall then observe a small renflement of the hyaloid membrane developed ; it is the trace of the canal, discovered by Petit de Namur.

We cannot isolate the cristalline lens from the vitreous humor, until after having lacerated the small membrane which unites it to this body ; it has received the name of cristalline membrane, the division of which is made by carrying the point of the scalpel on the cristalline lens ; it should merely glance over its external surface. If we then press the vitreous humor carefully, the cristalline membrane will be immediately torn, and we shall observe the escape of the lens, the transparency of which, remarkable in a young subject, disappears in proportion as age advances, and is succeeded by a yellow hue more less marked.

The vitreous humor likewise presents considerable transparency, and a whiteness which is not changed by age. We should examine its consistence and cellular disposition, by piercing it in several places, and introducing a straw into the orifices in order to distend it. We should also examine the comparative density of the three humors, their weight, their form, and the place occupied by each of them in the globe of the eye.

If we examine the eye in very cold weather, we should endeavor to have it frozen. In this way, we will be enabled to see in what manner the iris comports itself relatively to the aqueous humor and cristalline lens, which may be done by performing on the frozen eye a

perpendicular section from before backwards, and dividing it into two or three equal portions. We may, by these means, examine whether the iris is immediately applied on the lens, as some anatomists have falsely advanced, or whether it divides the aqueous humor into two unequal portions, as is demonstrated by anatomical dissection.

It would have been an easy matter to present a more minute description of the eye, but this would have occasioned considerable loss of time to the student, who is just commencing the study of anatomy; for he would not have made much progress in his knowledge of this important organ, if it had been charged with too much detail. The student will hope in vain to have a perfect acquaintance with the eye and brain during his first winter of dissection; let him, therefore, be satisfied with the limited notions he may acquire of these precious organs, by the aid which we offer him, in pointing out in this treatise the most simple and easy preparation of the eye. Had we been more minute or entered more largely into detail, we should have opposed the student's progress, by the embarrassment and confusion necessarily attending such descriptions. When his experience and sagacity will permit him to advance with bolder steps in the prosecution of his anatomical studies, he can then act in opposition to our present advice.

Description.

THE EYES.

This description comprehends, besides the globe of the eye, the eye-brows and eye-lids, as also the lachrymal organs, which are the accessory parts.

1st. *Eye-brows.* *Situation and relations.*—Prominent portions, situated above the orbits, elongated in form

of arcades from within outwards ; and bordered with hair, the quantity, color, and length of which are variable.

Extent.—From the root of the nose to the environs of the temple.

Direction.—We consider in the *ensemble* of the eye-brows, a bony portion, appertaining to the frontal bone (superciliary ridge) ; the muscle of the same name which has been already described ; a very small layer of cellular tissue ; a portion of the integuments of the forehead, and the hair of the brows ; this is longer in the male than in the female, passes in a direction more or less oblique, from within outwards.

Structure and uses.—Here the hair alone merits particular attention ; their structure will be described in a subsequent chapter. The eye-brows impart beauty to the visage, divert the perspiration, which falls from the forehead, moderate the impression of a too intense light, and, in their expressive movements, indicate the passions which agitate us.

2d. *Eye-lids. Situation and relations.*—Two in number, moveable, situated in front of the globe of the eye, which they cover when they are relaxed or closed, and which they leave exposed when they are separated, and, as is commonly said, open.

Extent.—The superior, the largest, arises from the base of the orbit, and in its progress covers three-fourths of the globe of the eye ; the inferior is smaller, has the same origin, and is scarcely elevated to its inferior fourth.

Division.—Anterior surface, covered by the common integuments, on which are observed transverse folds, which increase with age ; posterior surface, smooth and polished, applied to the globe of the eye. There

is an adhering border, which is attached to the base of the orbit, and a free border, on which the eye-lashes are implanted. The reunion of the two free borders of the eye-lids forms a triangular canal, more narrow towards the lachrymal gland, broader towards the puncta lachrymalia; the tears travel through it, in their passage from the lachrymal gland to the puncta lachrymalia, which they penetrate.

Structure and uses.—The eye-lids are formed of a part of the skin of the face, thin, elastic, and under which there is never any fatty matter collected; of a broad ligament, of a tarsal cartilage, and its pretended glands, called glands of *Meibomius*; of the eye-lashes and a mucous membrane, termed conjunctiva, which covers their posterior surface.

Broad ligament.—This is a cellulo-membranous production, extending from the contour of the orbit to the tarsus in each eye-lid; on the superior eyelid, this ligament is placed between the orbicularis muscle and levator palpebræ; and on the inferior, it is between the orbicularis and conjunctiva.

Tarsal cartilages.—They occupy the free border of the eye-lids. The superior is more extensive and broader than the inferior. Their color is yellowish; on their posterior part are observed prominent lines, which have been regarded as the excretory ducts and pretended glands, called the glands of *Meibomius*. These ducts, from twenty to thirty in number, emit, towards the free border of the eye-lids, an unctuous humor, destined to prevent or moderate the friction of the free border of the eye-lids on each other. When this humor collects between the eye-lashes of infants, it constitutes what is called the *yeux chassieux*,

Eye-lashes.—Double range of hairs, placed on the free borders of the eye-lids; more numerous and longer on the superior than on the inferior. Their direction is such, that on the superior eye-lid they are curved from below upwards, and on the inferior from above downwards. Their uses are to moderate the impression of too intense light, and to prevent the ambient corpuscles from being introduced between the eye-lids and the globe of the eye.

Conjunctiva.—It extends from the free border of one eye-lid to that of the other, in passing over the globe of eye. On the one hand, it corresponds to the internal surface of the eye-lids, and to the external part of the globe of the eye; on the other, it is free.

The conjunctiva is thin, transparent, formed of a very dense cellular tissue, which is traversed by vessels but little apparent in a state of health, but which are rapidly developed in inflammatory diseases of the eye: it is the means of union between the eye-lids and eye.

The uses of the eye-lids are to cover the globe of the eye, and protect it and preserve the suppleness of the cornea, by extending uniformly the humor of the tears over its surface.

Lachrymal Organs.

They are composed of the lachrymal gland, and of the caruncula of the same name; of the lachrymal ducts and puncta; of the lachrymal sac and nasal duct.

1st. *Lachrymal gland.*—Situated in the external orbital angle, it corresponds, on the one hand, to the globe of the eye; on the other, to the os-frontis. It is formed of glandular grains, which become united in a small mass, the length of which is about ten lines, the breadth four. Its color, density, and external form are analogous to the

salivary glands. It has no particular excretory duct ; but six or seven orifices throw out upon the globe of the eye an abundant humor, which is that of the tears, and which serves to lubricate the cornea and preserve its suppleness.

2d. *Lachrymal caruncle*.—Species of conical tubercle, situated towards the internal commissure of the eye-lids. Its base, turned inwards, is adhering ; its summit directed outwards is free, rounded, and regards the interval of the two puncta lachrymalia. Red in sanguineous persons, remarkably pale in hydropics, the lachrymal caruncle is composed of follicles attached to each other, and furnished with some hairs on their exterior. It causes the tears to pass into the puncta lachrymalia.

The semilunar valve, not very apparent in man, is a small duplication of the conjunctiva, placed towards the internal commissure ; it facilitates the motions of the eye-ball.

3d. *Puncta lachrymalia and ducts*.—Two in number, placed on the free borders of the eye-lids, one or two lines from the internal commissure. The orifice, which is always open, will scarcely permit the introduction of a very small stylet. The ducts empty into the lachrymal sac. They are destined to convey the humor of the tears to the sac, which transmits them to the nasal duct.

4th. *Lachrymal sac*.—A small membranous bag, of an oblong figure, placed in the great orbital angle. On the one hand, and within, the sac adheres to the lachrymal groove ; outwardly, it corresponds to the lachrymal ducts, and in this place it is covered by the tendons of the orbicularis palpebrarum ; below, it is contiguous to the nasal duct. Its structure is membranous. It receives the humor of the tears, and transmits it to the nasal duct

5th. *Nasal duct.*—It extends from the lachrymal sac to the nasal fossæ. Its length is from four to five lines, and its diameter measures nearly one line. Its superior opening communicates with the lachrymal sac. Its inferior opening corresponds in the nasal fossæ, above the inferior turbinated bone, to the anterior part of the inferior meatus. It is in part formed of osseous parois, covered by two membranes adhering to the bones, the one fibrous, and the other mucous. Its uses are to transmit the tears from the lachrymal sac to the nasal fossæ.

Globe of the Eye.

The description of the eye should be preceded by that of its muscles, to which should be added the levator palpebræ superioris. These muscles are, the four straight, the great and small oblique.

The levator palpebræ superioris, elongated, flat, extends from the circumference of the foramen opticum to the tarsal cartilage of the upper eye-lid. It corresponds above to the orbital arch; below, to the levator oculi. Its uses are to raise the upper eye-lid, and to draw it slightly backwards.

The four straight muscles, distinguished into superior, inferior, internal, and external, proceed in a diverging manner from the environs of the foramen opticum to the globe of the eye. They are, in general, elongated, thin, and flat. They are attached, on the one hand, to the summit of the orbit; and, on the other, they spread, under the form of an aponeurosis, over the sclerotica, at the distance of nearly two lines from the cornea.

The great oblique, elongated, thin, and rounded, extends from the summit of the orbit to the internal orbital angle,

and thence to the external part of the globe of the eye, passing across a cartilaginous pulley, which permits it to retrograde and reflect itself on the globe. It is horizontal along the internal pari of the orbit, and reflected from before backwards, from without inwards, and from above downwards in the rest of its extent.

The small oblique, elongated, thin and narrow, extends from the anterior and internal part of the floor of the orbit, to the posterior and external portion of the globe of the eye.

The organization of the muscles of the eye is the same in all; almost entirely fleshy, short aponeuroses are observed at their two extremities. The great oblique alone presents a tendon at its middle portion, which gives it the appearance of being composed of two muscles. Their uses all refer to the motions of the eye. The four straight muscles draw it backwards, when their contractions are simultaneous, and each of them imparts to the eye a peculiar movement, in virtue of which this organ is drawn in the direction of the muscle under contraction. The two oblique muscles turn the eye on itself, drawing it obliquely outwards in the sense of their direction.

The eye is composed of humors which it encloses, and of membranes which envelope them. These last are divided into external and internal. The first are the sclerotica and cornea; the second, the choroid, retina, and iris. The humors of the eye are the vitreous, cristalline, and aqueous.

2d. *The Sclerotica. Situation and relations.*—It forms the greatest part of the external envelope of the globe of the eye, and occupies the three posterior fourths of it.

Division.—Its posterior surface, convex, corresponds to

a very abundant layer of fat, and to the muscles of the eye; its anterior surface, concave, is applied on the posterior surface of the choroides. In front it is united, by its circumference, to the cornea; posteriorly, it offers an opening through which passes the optic nerve.

Structure and uses.—The color of the sclerotica is milk white, its thickness and density are considerable; but its intimate organization is difficult to determine. It contains the humors of the eye, and serves as a support to all the parts of this organ.

3d. *Cornea. Situation and relations.*—It forms all the transparent portion of the globe of the eye.

Division.—Anterior convex surface, covered immediately by the expansion of the conjunctiva; posterior concave surface, which corresponds to the aqueous humor; its circumference is united to the sclerotica, by which it is covered.

Structure and uses.—Extremely transparent, the cornea is less dense, but thicker than the sclerotica; it is formed of lamæ applied on each other, the existence of which is easily demonstrated by maceration; its uses are to permit the luminous rays to pass into the interior of the globe, and to refract them in drawing them nearer the perpendicular.

4th. *Choroides. Situation and relations.*—In the interior of the globe of the eye, of which it occupies the whole posterior portion; between the sclerotica and retina.

Division.—Posterior convex surface, applied on the anterior surface of the sclerotica, to which it is united by means of numerous vessels; anterior concave surface, simply contiguous to the retina. In front, the choroides is united intimately to the ciliary body, and thence passes to

the posterior part of the iris, in contributing to the formation of the ciliary body and processes.

Structure and uses.—The choroides is very thin and is easily lacerated. The fibres which form it are bordering on black. It appears destined to absorb the luminous rays which are unnecessary for vision.

5th. *The Retina. Situation and relations*—On the posterior part of the globe of the eye, between the choroides and vitreous humor.

Division.—Posterior surface, contiguous to the choroides; anterior surface, contiguous to the vitreous humor. Its circumference terminates at the ciliary ligament without adhering to it.

Structure and uses.—The retina, of a greyish white color, and of extreme softness, appears to be nothing more than the expansion of the optic nerve, under a pulpy form. All physiologists agree in regarding it as the immediate seat of vision.

6th. *Iris. Situation and relations.*—Species of partition floating in the aqueous humor, which it separates in order to form two chambers, an anterior and posterior, the former of which is the largest.

Division.—The anterior surface corresponds to the anterior chamber; the posterior surface, to the chamber of the same name. The first of these surfaces presents two species of rings, formed of radiated fibres converging towards the pupil. Numerous blood-vessels are observed on this portion of the iris, and impart to it its peculiar color. The posterior surface likewise presents two sorts of rings, and traces of the ciliary processes; in addition, this surface is covered by a black and very tenacious humor.

The large circumference of the iris is united to the ciliary ligament and processes, and also to the choroides. Its small circumference constitutes the pupil.

Structure and uses.—The iris appears to be nothing more than an assemblage of nerves and vessels; the existence of its muscular fibres is yet a problem. Its functions are of the highest importance in the accomplishment of vision; by its dilatation or contraction, it permits or opposes the admission of a greater or less quantity of the luminous rays.

7th. *The Ciliary Ligament and Processes. Situation and relations.*—The one is the continuation of the other. The ligament is the whitish circle, one line in width, which unites in front the choroides with the sclerotic; it is situated behind the circumference of the iris. The ciliary processes appear to arise from the ciliary ligament; they spread themselves, under the form of radiated feuillets, over the posterior surface of the iris, and advance from without inwards.

A dark and tenacious humor is observed on their posterior surface. The intervals correspond to the ciliary processes.

Structure and uses.—The ciliary ligament and processes appear to be composed of a very thin cellular membrane, to which pass a great quantity of sanguineous vessels and nerves. The functions of these parts cannot be exactly determined.

8th. *Aqueous humor. Situation and relations.*—In the anterior part of the globe of the eye, between the crystalline lens and cornea. The anterior chamber consists of the space between the iris and cornea; and the posterior chamber is that which is found between the iris and lens.

The aqueous humor occupies the two chambers, which are separated by the iris. The quantity of this fluid is about four grains, of which not more than the sixth part is contained in the posterior chamber. It is not so transparent as the vitreous humor. It is contained in a membrane peculiar to it, and which is extremely thin.

Cristalline lens. Situation and relations.—It occupies the centre of the globe in the direction of its horizontal diameter; it is situated between the aqueous and vitreous humors. Its form is that of a lentil, the diameter of which is from twelve to fourteen lines, and its greatest thickness measures about two lines and a half. Its anterior surface regards the iris, from which it is separated by the posterior chamber; its posterior surface is received in a depression of the vitreous humor. The cristalline lens is also enveloped in a membrane peculiar to it; its transparency is perfect until the middle period of life; it diminishes in proportion as age advances, and becomes yellowish in old persons. It is formed of concentric lames rendered visible by ebullition.

Vitreous humor. Situation and relations.—It occupies a great part of the globe, at the posterior portion of of which it is situated, between the cristalline lens and retina. Its volume is considerable, when compared to that of the aqueous humor, for its weight is more than a hundred grains. Its consistence is that of melted glass, and its transparency equals that of the most limpid water. The membrane, which is proper to it, bears the name of hyaloid. It covers not only all the external surface of the vitreous humor, but it likewise penetrates its interior, and forms small cells in which is contained the humor of the vitreous body.

Uses of the humors of the eye.—Without them the mechanism of vision could not take place; they direct, as it were, the luminous rays, which the internal membranes of the eye modify in order to produce the phenomena of vision. Received into the aqueous humor, these luminous rays experience a sensible divergence; but, reassembled again by the density and convexity of the cristalline lens, they approach the perpendicular, and thus arrive in the vitreous body, which, less dense than the cristalline lens, permits them to separate a little; thence they are transmitted to the retina, on which they trace the figure of the particular object from which they emanated.

ORGAN OF HEARING.

General Considerations.

Of all the senses, that of hearing is the least understood. The mechanism of hearing has so far escaped the researches of physiologists.

The ear, which is the organ of hearing, is distinguished into external and internal. The external ear is that prominent portion situated on the sides of the head, which is not concealed by any object, and which is seen without difficulty. The internal ear, on the contrary, comprehends the objects placed in the interior, and which the eye of the anatomist cannot distinguish except by long and minute dissections.

The external ear is composed of the pavillion and auditory conduit. The internal presents a greater number of objects. It comprehends the cavity of the tympanum, and the labyrinth, composed itself of the vestibulum, cochlea and the three semi-circular canals.

Anatomical Preparation.

EXTERNAL EAR.

Pavillion.—This part does not require any preparation, and nothing can be easier than its examination. Such, however, is not the case with its internal muscles; their small size, and extreme paleness render their dissection very embarrassing; indeed, they are not always found to be present. The subject on which we attempt to prepare them should be stout and vigorous, and the muscles themselves well marked; in the contrary case, our time will most likely be employed in vain: frequently we are unable to recognize them, notwithstanding the most scrupulous attention. I have repeatedly experienced great difficulty in meeting with them, and the parts which I took for these muscles were so little apparent, that I would recommend to the student not to occupy himself with an examination of them when he encounters such difficulty in rendering them visible. However, if the student is absolutely desirous of making these researches, he should select a muscular subject, and examine with great attention the prominent parts of the pavillion, where he will find small reddish productions, which are the muscles in question; they are the large and small muscles of the helix, the muscle of the tragus, that of the anti-tragus, and the transversalis. This last is placed on the internal portion of the pavillion; it presents the same difficulties.

The cartilage of the pavillion, after having been examined externally, should be exposed. For this purpose, we should remove the thin and dense skin which covers it; it preserves nearly the same form that it had before; but it presents several eminences and cavities, which have received particular names. The first are the helix, anti-he-

lix, tragus and anti-tragus; the second are the great fissure of the helix, fossa navicularis and concha. The soft portion, which terminates the ear below, is called the lobe.

External auditory conduit.—It extends from the concha to the membrane of the tympanum. It may be studied at first on the temporal bone, deprived of its soft portions, and then examined in connection with its different parts. If a more minute preparation is desired, it will be necessary to saw the petrous portion of the temporal bone lengthwise, passing the saw over the middle portion of the conduit; but the advantages resulting from this operation will be no compensation for the trouble in performing it. Moreover, the preparation of the internal ear will present frequent occasion to examine the auditory conduit, and the parts which cover it.

INTERNAL EAR.

The preparation of the internal ear is, without contradiction, the most difficult of all those in splanchnology. I am so well convinced of this difficulty for the student who is commencing the study of anatomy, that I would advise him to procure internal ears already prepared, rather than to attempt to prepare them himself. All the professors of anatomy and many of the prosecteurs possess them. The public schools preserve them in wax. I think, therefore, it would be better to have recourse to such sources for information on the subject. No matter what care may be taken to indicate the preparations of the various parts of the internal ear, I do not believe that the student will receive much advantage. Considerable time would, moreover, be consumed to no purpose; the student would become impatient and fatigued at his want of success, and perhaps be induced to abandon the study of the internal ear, which merits the greatest attention.

In order, however, not to make the difficulties greater than they really are, and to inspire the student with a desire to obtain a more particular knowledge of the ear, I shall describe the most common preparations, those which may be performed by the great majority of students, observing at the same time that these preparations will not be sufficient for him, who may desire a perfect acquaintance with the structure of the internal ear.

If it is more convenient to prepare the internal ear on the bones of an adult, it is more easy on those of a fœtus; we should commence with these latter; they yield more easily to the instruments, and there are fewer objects to be removed: it is worthy of remark that the organs of sense in general, vision and hearing in particular, are very much developed in the infant.

Remove, therefore, all the soft parts, and observe that the temporal bones of the fœtus have no external auditory conduit; it is replaced by an osseous circle, which is enclosed by the membrane of the tympanum. We should be careful not to interrupt this membrane; it is important to leave it in place, and to study it in this situation. It is not even necessary to rupture it in order to see the cavity of the tympanum, for this can be arrived at by removing with a scalpel or a knife, a part of the superior surface of the petrous portion. This section will permit us to view not only the extent and form of the cavity, but also the four small bones of the ear in place. It will serve, in addition, to bring into view certain objects, which could not have been seen without it. Of the four small bones, the *malleus* is applied, on the one hand, on the internal surface of the membrane of the tympanum; on the other, it is articulated with the *incus*, one of the branches of which passes down-

wards in order to unite with the *stapes*. Between these two bones, is observed the *os-orbiculare*, which is extremely small. The *stapes* itself, at its base, closes an opening called *fenestra ovalis*, on the side of which there is remarked another termed *fenestra rotunda*. In the interval is a small eminence, the pyramid. Behind, is observed the entrance to the mastoid cells, and, in front, the conduit of the eustachian tube.

The other parts of the internal ear are the cochlea, and the three semi-circular canals; their *ensemble* constitutes what is called the labyrinth. The first of these parts occupies nearly the middle of the superior surface of the petrous portion. It may be exposed in the same way as the cavity of the tympanum, that is, we should cautiously remove with a scalpel or knife, the external lamæ of the petrous portion, until we discover a species of *spirale* (formed of an osseous lamæ and a double groove) called the steps; one of them, the external, communicates with the vestibulum; the internal extends to the *fenestra rotunda*.

We must look for the three semi-circular canals on the posterior and internal parts of the cavity—and they should be exposed in the manner just indicated. Each of them describes a particular curve, so that, originating at the vestibulum, they enter there, after having traversed the thickness of the petrous portion at its posterior part, in forming a species of *ovale*.

It is in the interval of the cochlea and the three semi-circular canals, and at the internal part of the cavity, that the vestibulum is found; it is so called, because it forms, as it were, the entrance to the two former parts. The mode of exposing it is the more difficult to indicate, as we cannot assign any particular figure to it; it is only by

an exact knowledge of all the other parts of the ear, that we can form an idea of the vestibulum, and especially of its numerous communications, with the cavity, or the semi-circular canals. We can here only give some general precepts respecting such a preparation, and it is only by time and great tact for this sort of work, that the student will succeed in a faithful preparation of the internal ear. The muscles and nerves, situated in this organ, although very small and delicate, have particular names, and perform functions, which excite the most lively interest on account of the exalted idea which the uses of these parts give us of the Divine Hand that formed them. The *malleus* has two small muscles, one of which passes by the fissure of Glaser, and comes from the summit of the petrous portion, crossing the small cavity, called the *bec de cuiller*, in order to pass to the *malleus*. The *stapes* likewise has a small muscle, which is inserted into the pyramid, and thence goes to embrace the neck of the *stapes*. Two nerves, the acoustic and facial, enter through the internal auditory foramen; the acoustic passes to the steps of the cochlea, and the facial, after having traversed the aqueduct of Fallopius, goes to the lateral parts of the face. This last gives off a branch in the interior of the ear, called *chorda tympani*, which arises in the environs of the pyramid, turns around the *incus* and *malleus*, and passes out of the ear by the fissure of *Glaser*.

Minute osteology points out two openings, one in the middle of the posterior surface of the petrous portion called the aqueduct of the vestibulum, and the other on the posterior border of the same bone, called the aqueduct of the cochlea: these two openings communicate in the vestibulum. We may, with the aid of a very fine probe, with

a hog's bristle or with mercury, traverse the trajet of these cavities.

Description.

EXTERNAL EAR.

It is composed of the pavillion and external auditory conduit.

Pavillion. Situation and relations.—This is what is commonly called the ear; this part, elongated from above downwards, and flattened, is situated on the lateral portions of the head; its figure is oval.

Division.—External surface, on which are observed four eminences, which are the helix behind, somewhat more forwards the anti-helix, the tragus and anti-tragus around the *concha*. Three cavities separate these parts; the first called rainure of the helix, the second fossa navicularis, and the third concha.

The internal surface corresponds to the bones of the cranium, from which it is separated in the greatest part of its extent. Its circumference presents, below, a soft portion, called lobule.

The five small muscles move, though feebly, the different parts of the external ear. The most considerable is the great muscle of the helix; it arises from the helix, in the environs of the tragus, and terminates, after a trajet of three or four lines, at the anterior part of the helix.

The second is the small muscle of the helix, which arises from the part of the helix dividing the concha.

The third is the muscle of the tragus, which arises from the base of this eminence and terminates at its summit; it is the most apparent of the three.

The fourth is the muscle of the anti-tragus. It arises

from the posterior border of this eminence, and loses itself in the environs of the anti-helix.

The fifth is the transversalis, situated on the internal part of the pavillion. It arises from the convexity of the concha, and terminates on that of the fossa navicularis.

Structure and uses.—A cartilage which has the same figure as the pavillion of the ear, three ligaments which fix it on the lateral parts of the head, some muscular portions, a prolongation of the integuments, sebaceous glands, and vessels enter into the composition of the pavillion. Its uses are to concentrate the sonorous rays and direct them to the auditory conduit.

External auditory conduit. Situation and relations. From the concha to the membrane of the tympanum, going from without inwards, and from behind forwards; its length is from ten to twelve lines, and its width is more considerable at its two extremities than in the middle.

Structure and uses.—The conduit is composed of an osseous portion, which appertains to the temporal bone; of a cartilage which has the form of the conduit, and of a thin membrane enclosing cerumineous glands. The humor which they secrete preserves the suppleness of the internal parts of the conduit, and prevents the ingress of external objects.

INTERNAL EAR.

Membrane of the tympanum. Situation and relations. It is placed at the bottom of the external auditory conduit, which it separates from the cavity of the tympanum.

Division.—It has an external surface which corresponds to the external conduit; and an internal surface, which is observed in the cavity of the tympanum and to which the handle of the malleus is applied. Its circumference is received in a small groove of the temporal bone.

Cavity of the tympanum. Situation and relations.—In the hard portion of the temporal bone, at the internal part of the external auditory conduit, and at the external part of the labyrinth.

Division.—Externally it corresponds to the membrane of the tympanum; internally we perceive two holes separated by a prominence; the first is called the fenestra ovalis, and is closed by the stapes; the second is the fenestra rotunda and is closed by a delicate membrane; the prominence is called the promontory.

The circumference presents, on its upper and posterior portion, the pyramid which lodges the muscle of the stapes; more posteriorly, is observed the entrance to the mastoid cells; a little anteriorly the fissure of Glaser; above, the eustachian tube, and the *bec de cuiller*. In the cavity of the tympanum are contained the four bones of the ear, which are the hammer, (malleus,) the anvil (incus,) the stirrup (stapes,) the os-orbiculare and the small muscles of the bones of the ear.

The hammer, (malleus,) is most external and corresponds on one side to the membrane of the tympanum, and on the other to the incus. It is divided into a head which is articulated with the incus; a neck from which a delicate process arises, to which is attached its anterior muscle, and a handle the point of which is applied to the centre of the membrane of the tympanum. At the origin of the handle is a process to which is attached the internal muscle of the malleus.

The incus is placed between the malleus and stapes. It is divided into a body, which is articulated with the malleus, and two branches, of which the one, superior and posterior, is placed near the entrance of the mastoid cells, and the other, inferior, is articulated with the os-orbiculare.

The os-orbiculare is the smallest of the bones of the ear, and is situated between, and articulated with, the incus and stapes.

The stapes is situated horizontally between the os-orbiculare and the fenestra ovalis, which it in a great measure closes. It is divided into a head which is articulated with the os-orbiculare; a neck which gives attachment to the muscle of the stapes, and a body which has the form of a stirrup, the base of which is situated over the fenestra ovalis. A delicate membrane which has by the generality of anatomists been called periosteum, and by Bichât mucous, is reflected over all the parts contained in the cavity of the tympanum; it fixes the bones in their natural position and is extended into the mastoid cells and eustachian tube.

The muscles of the bones of the ear are three in number, viz. : the muscle of the stapes, and the internal and anterior muscles of the malleus.

The muscle of the stapes arises from the base of the pyramid, is inserted into the neck of the stapes, and gives this bone a see-saw motion.

The internal muscle of the malleus arises from that rough portion of the temporal bone which is seen in front of the internal auditory hole; this muscle passes into the internal ear, enclosed in a bony canal, and is inserted into the handle of the malleus; when it acts it draws this bone inwards and makes the membrane of the tympanum more tense.

The anterior muscle of the malleus is much smaller than the preceding; it passes from the spinous process of the sphenoid bone, and from the neighboring part of the cartilage of the eustachian tube, to the Glaserian fissure,

which it traverses, in order to penetrate the cavity of the tympanum and be inserted into the small process of the malleus. It relaxes the membrane of the tympanum by drawing it outwards.

Vestibulum. Situation and relations.—It is situated on the internal side of the cavity of the tympanum, behind the cochlea, and in front of the three semi-circular canals; we see on it the orifices of these canals; and, in addition, the opening of the fenestra ovalis, that of the external part of the cochlea, and that of the aqueduct of the vestibulum. The interior of the vestibulum is lined by a delicate periosteum.

Cochlea. Situation and relations.—It is situated below the superior surface of the petrous portion of the temporal bone, and on the external side of the other parts of the labyrinth.

Division.—The cochlea is composed of a common centre, from which proceed two osseous laminae, between which are seen the two steps, divided into external, which is longer, less broad, and bordering on the vestibule; and one internal, which is broader, shorter, and terminates on the fenestra rotunda. The interior of the cochlea is lined by a prolongation of the periosteum of the vestibulum.

Semi-circular canals. Situation and relations.—These three canals arise from the vestibulum and open into it again after having described in the petrous portion of the temporal bone semi-oval curvatures. They are divided into superior vertical, posterior vertical, and horizontal vertical. They are likewise lined by a prolongation of the periosteum of the vestibulum.

Structure and uses.—The auricular muscles, the muscles of the pavillion and its cartilage, those of the small

bones, the bones themselves, a very delicate membrane, and the pulpy expansion of the acoustic nerve, are the parts which enter into its composition. Its uses are to serve the purposes of hearing. The mechanism is imperfectly understood. It is said, however, that the sonorous rays, or which is the same thing, the air put in motion by the sonorous and vibrating bodies, is precipitated into the auditory conduit, and excites the membrane of the tympanum; this is communicated to the small bones of the internal ear, which transmit it through the vestibule into the slopes of the cochlea, from whence it comes in contact with the pulpy portion of the auditory nerve which carries the impression to the sensorium commune, where sound is perceived.

Description.

N O S E .

Situation and relations.—The nose is situated on the middle part of the face, above the mouth and below the forehead. Its figure is pyramidal with the base downward.

Division.—Lateral surfaces, broader below than above, divided by a furrow at their inferior part; anterior border, called the dorsum of the nose, the superior portion of which loses itself in the forehead, and is termed the summit or root. Its base has two openings which are termed nostrils, and are separated from one another by a cartilaginous partition. Posteriorly it corresponds with the nasal fossæ.

Structure and uses.—The nose is formed by the ossa nasi, the nasal processes of the superior maxillary bones, five cartilages, and some muscles, the whole covered with a delicate integument in which fat never accumulates.

The cartilages of the nose are five in number, and are divided into the proper lateral cartilages, and into the cartilages of the wings of the nose; the fifth belongs to the partition which separates the nares from one another.

NASAL FOSSÆ.

Situation and relations.—The nasal fossæ are two in number, and are separated from one another by a cartilaginous partition, and the perpendicular lamina of the vomer and ethmoid bone. They are placed at the middle and posterior part of the face, below the anterior portion of the base of the cranium, above the superior part of the mouth, behind the nose, and in front of the pharynx.

Figure.—Quadrilateral.

Division.—The nasal fossæ have a superior wall which is formed by the ethmoid bone, an inferior which is formed by the maxillary and palate bones, a posterior which corresponds with the posterior nares, an anterior which is concealed by the nose, and an internal which is formed by the partition between the two nares. An external wall on which are seen the following objects, viz.: upwards and backwards, the superior turbinated bone; downwards, the meatus of the same name, into which open the posterior ethmoidal cells and the internal orifice of the sphenopalatine hole; still lower is seen the inferior turbinated bone, and below it, the meatus of the same name, at the anterior part of which is remarked the inferior orifice of the nasal canal, which commences below the lachrymal sac, and after a trajet of five or six lines terminates in the nasal fossæ. From its situation and uses, the description of the nasal canal belongs equally to that of the lachrymal ducts and nasal fossæ.

Structure and uses.—The solid part of the nasal fossæ is formed by the maxillary, palate, lachrymal, nasal, inferior turbinated, ethmoid and sphenoid bones; and by the vomer, the cartilaginous partition which divides the nasal fossæ, and the lateral cartilages. The nasal fossæ are lined by a thick membrane which secretes mucous, and has been called the pituitary membrane. The nose and its appendages fulfil several functions. It is a portion of the tube which allows the passage of air to the lungs during respiration. As the organ of smell it receives the impression of odors, and by its nerves transmits them to the brain. In giving to the nose this double faculty, nature has exhibited another evidence of her foresight and infinite wisdom. In fact, without air, respiration could not be effected; it is in the air that the aroma of odorous bodies is diffused; and it is the vehicle in which this aroma is developed with the greatest facility; what, therefore, could be more simple, or more ingenious than to place the organ of smell at the entrance of the tube through which air is conveyed to the lungs. In this respect the nose is, in animals which respire, a sentinel always active, who instructs them with regard to the deleterious or healthy condition of the surrounding air. Under another point of view, smell is to man a source of agreeable and delightful sensations.

The physiological order would render it necessary for us, in this place, to treat of the sense of touch, and of the skin; but as this would interfere with our anatomical arrangements we shall omit it until we have finished splanchnology.

GENITAL ORGANS OF THE MALE AND FEMALE.

General Considerations.

The genital organs, appertain to the life and preservation of the species. Nature, in endowing these parts with an action of but short duration, has imparted to them, during its existence, a degree of extraordinary activity.

Before the time of puberty, individuals of both sexes are capricious and irresolute, and with regard to their physical and intellectual qualities are mere children; and between the child of three or four years of age, and the child of ten or twelve, the difference is inconsiderable.

But when the organs are fully developed, and when the male or female can no longer question the purpose for which they were created, a remarkable energy is perceptible in all their movements, and a considerable increase is remarked in all their organs; finally, their intellectual operations become so vigorous as no longer to admit of a doubt of the rank they should hold among their fellows. Of all the organs of the animal economy these are the ones which exercise a more marked influence on certain acts of life; and still the male or female may be deprived of them without any very grave consequences resulting from their loss. On the contrary, it has been remarked that, under certain circumstances, their too frequent use has been often the cause of dangerous maladies, such as phthisis, loss of memory, emaciation, and tabes dorsalis, which could be attributed to no other cause, than an excessive loss of the seminal fluid, which appears to indicate as a means of cure, the removal of these organs.

These organs being different in the two sexes, both in their structure and actions, we are obliged to study them separately. In beginning with the male, we must consider

those which prepare the seminal fluid, and those by which it is preserved, and, perhaps, endowed with new properties; finally, those parts by which it is carried without the body. According to this arrangement the male organs of generation are divided into the testicles and their envelopes, the vasa deferentia, vesiculæ seminales, ejaculatory ducts, the penis and the urethra.

Those of the female refer to generation, conception and pregnancy. They are naturally divided into two classes; in the first are found the external or preparatory organs; the second embraces the internal organs or those in which the act of generation is consummated. The first are composed of the mons veneris, the *pudendum* or vulva, the labia, the vestibulum, the clitoris, the *albia minoræ* or nymphæ, the meatus urinarius, the external orifice of the vagina, the hymen, the carunculæ myrtiformes, the fossa navicularis, and the fourchette or posterior commissure, to which may be added the perineum. The vagina, the uterus, and its appendages constitute the second.

MALE ORGANS OF GENERATION.

Anatomical Preparation.

Testicles.—These glandular bodies are enclosed in a pouch formed by the skin, which has received the name of scrotum. This term is confined to the integument which constitutes the exterior or common envelope of the testicles; it is remarkable only for its laxity, its exterior is rugous, and is covered with hair after the age of puberty. Immediately beneath this is found what has been by anatomists called the dartos.

In order to expose the dartos, make an incision through

the integument of the scrotum; a reddish cellular expansion will be perceived, and which may be easily elevated—it is the dartos.

Independently of the envelopes common to both testicles, viz: the dartos, and the tunica vaginalis, each testicle is surrounded with another coat, and is suspended by a cord which enters the inguinal canal and passes into the abdomen. On the external side of this cord is a muscle of three or four fingers' breadth in length, which appears to come from the oblique muscles, and is called the cremaster; from its reddish appearance it may be recognised with facility.

When we divide the tunica vaginalis, we perceive the testicle in its cavity; we should here observe the difference between the two portions of this tunic. It envelopes equally the testicle and cord, without any communication existing between them. This membrane is reflected on itself in such a manner as to form two little sacs, which are without an opening. This is also the case with the pleura, the peritoneum, and, in general, with all serous, and synovial membranes. By dividing the testicle longitudinally, we are enabled to see its color, and the form, and arrangement of the seminiferous canals. To make them more distinct we may adopt two modes of proceeding; the first of which consists in injecting water into the testicles through an opening made in the tunica albuginea; or in macerating them for some time in the same fluid. We may also render them apparent by injecting mercury through the vas deferens, at a certain distance from the testicle, which should be suspended in order to favor the passage of the mercury through the seminiferous canals.

We should examine that elongated reddish body, which is situated on the superior part of the testicle, and which ap-

pears to have been superadded to this gland, it is called the epididymis; and observe that the special covering of the testicle is here quite dense and tendinous; here we find the corpus highmorianum, communicating with the epididymis, which continues with the cord; this latter should be pursued to the interior of the abdomen. When the cord has arrived behind the abdominal ring, the artery, vein, and nerve, of which it is composed, pass beyond the pelvis to join their respective trunks; whilst another portion, the vas deferens, plunges into the pelvis, passes behind the bladder and terminates at the anterior part of an elongated, irregular body, which is called the vesicula seminalis.

When the trajet of the vas deferens has been observed—to study successfully the remaining organs of generation it will be necessary to prepare the bladder after the manner which has been indicated elsewhere.

The intestinum rectum should be cautiously detached, that the vesiculæ seminales be uninjured; in preparing these parts it is advisable to remove the whole of the rectum which, when the bladder has been filled with air, may with more ease be separated from it, for without this precaution, you will have much difficulty in finding the vesiculæ, and the canal which empties into them. In this dissection be careful not to puncture the bladder, for the escape of the urine will obscure the view of the objects to be studied. From these parts we must pass to the examination of the urethra, and ejaculatory ducts, and finish by examining the penis.

In studying these organs the method which I conceive to be preferable is to commence with the penis, and leave the urethra and ejaculatory ducts for the last. By proceeding in this manner nothing is cut unne-

cessarily, and the preparation of one part does not cause the destruction of the other. Moreover, in order to prepare the urethra, we are obliged to sacrifice the scrotum, which should be preserved for the examination of the penis.

In examining the penis, we are to observe the remarkable laxity of the integuments, and the manner in which they are reflected over the glans to form the prepuce and its frenum. The formation of the glans, and the delicacy of the skin which covers it should also be observed. We should now expose the suspensary ligament of the penis, which, on the one hand, is inserted on its superior and posterior part, and, on the other, is lost on the body of the pubis. The internal structure of the penis should not be studied until the urethra has been examined.

In order to examine the urethra it should be divided through its whole length. Observe carefully the fossa navicularis, situated immediately under the glans, and those contractions which are sometimes remarked in its continuity and which are the result of disease; this canal presents differences of structure, to distinguish which, it has been divided into three portions; the first of which is of considerable extent, and has been denominated the spongy portion; the second portion is smaller, lies immediately under the skin of the perineum, and is called the membranous portion; the third, opens into the bladder, is three fingers' breadth in extent, and has, as yet, received no particular name. This latter is embraced by the prostate, a glandular body, which surrounds the commencement of the urethra. In order to see these parts advantageously, the pubis should be divided at the symphysis, and totally removed; we must remember that the ejaculatory ducts open into the urethra, a few lines from its origin; to see them, we must divide the urethra through

its superior portion, and seek them on the lateral parts of an elongated body, which is placed longitudinally in the urethra, and which is called the verumontanum; they are about an inch in length, and, with a fine probe or bristle, they may be traced to their entrance into the vesiculæ seminales. This is the only mode of appreciating their direction, and the manner in which they communicate with the vesiculæ. They may be injected with mercury, or melted wax, by forcing the injection through the vas deferens into the vesiculæ, by compressing which the injection will be pushed through the ejaculatory ducts.

The penis is composed, interiorly, of two large canals, which are called the cavernous bodies; they are filled with a firm and dense cellular tissue, and are divided, the one from the other by a membranous partition.

To see their interior structure, they should be divided through their whole length; they are always found filled with dark thick blood, which is readily washed away, and the cellular tissue is observed to have its usual whitish appearance.

Description.

MALE ORGANS OF GENERATION.

These organs are: the testicles, the vas deferens, the vesiculæ seminales, and the ejaculatory ducts. The appendages of the testicles are—the scrotum, which is a tunic common to both, the dartos, the cremaster muscle, and the tunica vaginalis, which are proper coats. The tunica albuginea, belongs to the testicle itself, and is independent of the others.

Scrotum. Situation and relations.—The scrotum is a kind of pouch formed by a prolongation of the skin which covers the thighs, and is situated below the perineum and penis.

Division.—It is divided into an external surface, which is rugous and hairy after the age of puberty, and is traversed by a fold of the skin, which is called its raphe, and is continuous with the integument covering the penis and perineum; the internal surface of this fold is united to the dartos.

Structure and uses.—Its use is to envelope the testicles; it differs from the general integument, of which it is a prolongation, in being very lax.

Dartos. Situation and relations.—The dartos are situated immediately under the scrotum, with which they are loosely connected; they correspond to the tunica vaginalis; they are also united to form a partition, which separates the testicles from one another.

Structure and uses.—The structure of the dartos is imperfectly understood. Their tissue has, by some, been pronounced muscular, others, on the contrary, assert that they are formed of very dense cellular tissue. Their use appears to be to compress the testicles and assist in the expulsion of the semen.

Cremasters. Situation and relations.—They cover the spermatic cord, and extend from the internal oblique and transversalis muscles, to the external surface of the tunica vaginalis. Externally, they are covered by the dartos and integument; internally, they are in contact with the tunica vaginalis.

Structure and uses.—Many anatomists make no distinction between the cremaster muscle and the red or érythroid tunic. It is doubtless a muscle, the fibres of which are extremely pale; its uses are to suspend the testicle, and to assist in the expulsion of the seminal fluid.

Tunica Vaginalis. Situation and relations.—It is the last proper envelope of the testicle. Externally, it is

in contact with the dartos, and a portion of the cremaster muscle; internally, it is contiguous to the testicle, and is constantly moistened with a lymphatic fluid, which prevents the formation of adhesions. When this fluid accumulates in the sac formed by the tunica vaginalis, and its absorption is not in a ratio with its secretion, it constitutes the disease called hydrocele.

Structure and uses.—The tunica vaginalis does not differ in structure from the peritoneum, of which it is a prolongation; it encloses the testicle, and its particular use appears to be to furnish a lubricating fluid, which increases the mobility of the testicle, prevents the formation of adhesions, and assists its important functions.

Testicles. Situation and relations.—The testicles are two in number, and are each contained in a pouch formed by the tunica vaginalis, they are oval, and elongated, antero-posteriorly, and are surmounted at their superior portion by the epididymis and corpus highmorianum placed below, which extend down their whole length. The anterior extremity of the epididymis, which is called its head, communicates with the corpus highmorianum by ten or twelve little canals; its posterior extremity, or tail, gives origin to the vas deferens.

Structure and uses.—The tunica albuginea, an external coat, which is white and smooth, encloses the proper tissue of the testicle, which consists of a number of fine tubes called the seminiferous ducts, and which terminate in the corpus highmorianum. The testicles secrete the seminal fluid.

Vas deferens. Situation and relations.—The vas deferens passes from the testicles to the vesiculæ seminales through the abdominal ring. Without the abdomen, it is enclosed in the sheath which envelopes the spermatic

vessels, which sheath is a prolongation of the peritoneum. When it enters the pelvis it runs along the lateral parts of the bladder to its *bas fond*, and opens into the *vesiculæ seminales*.

Figure.—Elongated, cylindrical.

Structure and uses.—The *vas deferens* has two coats, the external, dense and white, and the internal, mucous; the use of this duct is to transmit the seminal fluid from the testicles, where it is secreted, to the *vesiculæ seminales*.

Vesiculæ Seminales. Situation and relations.—These organs are situated at the inferior part of the bladder, between it and the rectum. Posteriorly, they are considerably separated from each other; anteriorly, they are so much approximated as barely to permit the passage of the *vasa deferentia*, which open into their anterior extremities.

Figure.—Elongated, tortuous, and irregular.

Structure and use.—They are in structure similar to the *vasa deferentia*. The use of these organs, is to serve as reservoirs for the seminal fluid, and to allow it to escape during coition.

Penis, and its appendages. Situation and relations.—It is placed below the *symphysis pubis*, and above the testicles.

Figure.—Elongated.

Division.—It is divided into a superior surface, which is called its back, and an inferior surface along which runs the canal of the urethra. Into a posterior extremity or root, adhering to the pubis, and supported by the suspensory ligament, and an anterior extremity, terminated by the glans, which appears to be superadded to the penis. This glans is pierced at its free extremity by an opening,

which is the termination of the urethra, and is ordinarily covered by a fold of integument, called prepuce.

Structure and uses.—The principal part of the penis is formed by the union of two membranous canals, containing very dense cellular tissue, and called the cavernous bodies: they are separated from one another by a membranous partition, and are covered by loose skin. The use of the penis is to carry the seminal fluid into the genital organs of the female.

The appendages of the penis are the prostate gland, the ejaculatory ducts, and the urethra.

¶ The prostate is a glandular body, which surrounds the commencement of the urethra; it corresponds superiorly to the inferior portion of the pubis, and inferiorly, to the intestine rectum. Its texture is firm, and its color greyish; its organization and functions are unknown. The ejaculatory ducts traverse it from behind forwards, and from without inwards.

The *ejaculatory ducts* may be considered as the terminations of the vasa deferentia, and vesiculæ seminales; they are about two lines in length, and open into the urethra on the lateral and anterior parts of the verumontanum. Their use is to conduct the seminal fluid from the vesiculæ seminales into the urethra at the time of coition.

The *urethra* is a canal which extends from the urinary bladder to the extremity of the penis. It is from ten to twelve inches in length; it commences at the neck of the bladder, traverses the prostate gland, is applied to the symphysis pubis, and in the remainder of its trajet, it is contained in the groove which is formed by the union of the two cavernous bodies, at their inferior surfaces.

The urethra is divided into three portions: the first, an inch and half in length, has not received any particular

name ; it is very thin, and is sustained by the prostate ; the second, is about an inch in length, and is called its membranous portion ; at this part the urethra is covered solely by the integuments, and is extremely weak ; the third portion occupies the remainder of the penis, and is called its spongy portion. The bulb of the urethra is near the origin of this portion of the canal. The anterior extremity of the urethra traverses the glans, the opening of which is called the meatus urinarius, immediately below which is found the fossa navicularis. The urethra is lined by a mucous membrane, which at its origin has an elevation to which the name verumontanum has been applied, on the lateral portions of which are seen the orifices of the ejaculatory ducts. Through the canal of the urethra are transmitted the urine and semen.

FEMALE GENITAL ORGANS.

For the convenience of studying them they are divided into external and internal ; but this division is arbitrary, and entirely conventional.

Anatomical Preparation.

Those organs which are called external, require no preparation ; with some trifling precautions, they may be studied with facility. The subject being placed in the position which is adopted for observing the muscles of the perineum, we should separate the labia majora, having previously observed their relations ; in the interval which is called the pudendum, you see from before backwards the clitoris, partially covered by the union of the nymphæ ; about an inch below is observed the meatus urinarius. We should study the relative situation of these two parts, as they are

frequently, mistaken for each other, in introducing the catheter.

Below the meatus urinarius, is seen the exterior orifice of the vagina, which in young girls is partially closed by a membrane called the hymen, which is of a crescent shape.

The existence of this membrane is not chimerical, as has been asserted. Many pupils have seen at my amphitheatre this membrane in a female of advanced age. The knowledge of the existence of this membrane, should prevent us from using force, when examining some females.

Below the hymen, is seen the posterior commissure. When, in consequence of violence, the hymen has been destroyed, it is replaced by tubercles, which might be mistaken for the consequences of venereal disease.

In examining the internal parts of generation, more care is necessary. The parts should be prepared as for examining the bladder, ; leave the bladder and rectum in position, which last, should be tied four fingers' breadth from the anus, and divided above the ligature ; remove the whole with care, wash it, and observe the relation which exists between the uterus, bladder, and rectum, and the ligaments which arise from the lateral parts of the former. The ligaments of the uterus are divided into the broad, which do not extend beyond the pelvis, and the round which pass through the abdominal ring, and are lost on the internal parts of the thighs. It is difficult to preserve the round ligaments, they should be studied in position, before the pubis is divided. They are the least important of the appendages of the uterus. Those parts, which do not belong to the genital apparatus, as also the cellular tissue, should be removed, that the view

be not obscured. The symphysis pubis should be cut through, and the bladder divided through its whole length, that we may observe the relation it bears to the uterus, particularly at its neck.

Divide the vagina, through its anterior parietes, in the same direction as the bladder; separate the divided parts, and you perceive the neck of the uterus, which must be left until the vagina has been studied. We may now separate these parts from the pubis, but I prefer leaving them in situ, until the uterus is to be studied particularly, which should be also divided longitudinally, in the same manner as the vagina. When the parts have been prepared in the manner indicated, nothing prevents us from studying them. The broad, and what remains of the round ligaments, should be extended on the table and placed in position. The latter do not require particular examination. The broad ligaments, on the contrary, require especial attention; the length of the Fallopian duct, and the ligament which sustains the ovarium, should be studied, as well as the manner in which they unite at their respective extremities. The tube of Fallopius is a conduit, the calibre of which, at its opening into the uterus, is so small as to admit with difficulty the finest probe. By partially dividing the tube, a bristle may be introduced into its cavity. The ovaria do not require any preparation; the appearances so much insisted on, by different anatomists, are often illusory.

Description.

FEMALE ORGANS OF GENERATION.

Proceeding from above downwards, and from before backwards, we find:

1st. The mons veneris, which is a greater or less elevation, according to the disposition of the bones of the pubis, and the lax and abundant cellular tissue which covers them; this part at the age of puberty is covered with hair.

2d. Below the mons veneris are the labia majora, which are united anteriorly and posteriorly. Their points of union are called the commissures, and the space between the commissures the vulva or pudendum; looking from before backwards, we perceive the vestibulum, which is placed between the anterior commissure and the clitoris. The clitoris is a body more or less projecting, and is ordinarily concealed by the nymphæ; the labia minora or nymphæ which are united at the clitoris, diverge from one another, in proportion as they proceed posteriorly, and terminate on the lateral parts of the vagina. Between the nymphæ, and below the clitoris, is seen the meatus urinaris, or the external orifice of the urethra, which is about one inch in length; below it, is the external orifice of the vagina, partially closed by the hymen in persons who have not copulated, nor had it destroyed by external violence. Behind, the vulva terminates at the posterior commissure, within which is seen the fossa navicularis. The space which is comprised between the anus and posterior commissure is called the perineum. Cellular tissue in great quantity, numerous glands and a mucous membrane, compose in great measure the parts just described. They are the preparatory organs of generation the accomplishment of which is effected in the uterus.

3d. Vagina. *Situation and relations.* This canal, vulvo-uterine, is from four to five inches in length and extends from the vulva to the uterus, over the neck of which it is reflected.

Figure. Elongated, and flattened antero-posteriorly.

Division. Anteriorly, it adheres intimately to the bladder, posteriorly it adheres to the rectum, inferiorly it terminates by an opening called its external orifice, which is narrower than the rest of the canal, posteriorly it is connected with the neck of the uterus. Internally it is constantly bedewed with mucous, and has on its surface many wrinkles or folds, the developement of which at the moment of parturition, singularly favor this painful process. The external coat of the vagina is a prolongation of the peritoneum, its internal coat is mucous, and is a continuation of that which covers the external parts of generation; the vagina likewise contains a great number of glands, and a peculiar tissue, which, by some anatomists, is considered muscular. Be this as it may, all admit the existence of two muscles which are placed at the entrance of the vagina, and which are called constrictors.

4. Uterus. *Situation and relations.* It is situated in the lesser pelvis, between the rectum and uterus.

Figure. Pyriforme, elongated from above downwards and flattened from before backwards.

Division. It is divided into a body and neck. Its two superior thirds compose its body, which is entirely covered by the peritoneum. Its interior, which would with difficulty contain a French bean, has three openings, two superior which communicate with the Fallopian tubes, and one inferior at its neck. The neck of the uterus is placed below its body, and is about one inch in length, it has a superior orifice which opens into the cavity of the uterus, and an inferior which opens into the vagina, the first is called the internal or uterine, and the other is called the inferior or vaginal orifice. The organization of the uterus resembles very much that of the vagina; like it, it has a peritoneal cove-

ring, and an internal mucous membrane, between which is a tissue, which is generally considered muscular. On the interior of the uterus are the orifices of the uterine sinuses, which are very considerably developed during pregnancy. The uterus is the principal organ of reproduction.

The appendages of the uterus are the broad and round ligaments.

The *round ligaments* arise from the superior and lateral parts of the body of the uterus, before and a little below the origin of the Fallopian tubes; they pass through the inguinal rings, and are lost in the neighborhood of the labia majora. The tissue of these ligaments is membranous, but their use is little understood.

The broad ligaments are formed by the Fallopian tubes anteriorly, and posteriorly by the ovaria and their ligaments. The Fallopian tubes are two ducts which extend from the lateral parts of the uterus to the sides of the pelvis, they terminate by a kind of funnel shaped fringe, which is inclined towards the ovaria; they communicate with the uterus by a narrow orifice, on the one side, and with the cavity of the abdomen on the other, which explains the possibility of extra uterine gestation. They have an external or peritoneal coat, and an internal mucous coat, which is continuous with that which lines the uterus; although ordinarily the calibre of these tubes is very small, still in certain cases they become much enlarged, as in the case of extra uterine conceptions, in which the ovum remains in the Fallopian tube. These ducts appear to be intended to allow the generative fluids to reach the ovaria, and to transmit the product of fecundation to the uterus.

The ovaria and their ligaments are placed below, and a

little behind the Fallopian tubes. The ligaments are not remarkable, the bodies which terminate them are ovoid, whitish, and adhere to the fringed extremities of the Fallopian tubes; externally they are covered by the peritoneum; their internal structure is imperfectly known: in it we find many vesicles filled with water, which physiologists have looked upon as eggs. The use of the ovaria is not known; in the system of the ovarists these organs are very important, but the precise function they are intended to fulfil is far from being satisfactorily ascertained.

S K I N.

The common integument is not composed exclusively of the skin; the nails and hair are considered as parts of it; the fat and cellular tissue are throughout the animal economy contiguous to its internal surface. The integuments shall now be examined, not only as the external covering of the body, but as the organ of the sense of touch.

Anatomical Preparation.

The skin can be prepared but imperfectly by students, the instruments and necessary agents being usually wanting. In despite of these inconveniences, they can generally by simple means acquire a sufficient knowledge of it. In fact, without the assistance of physical or chemical agents, the color, density, and thickness of this common envelope can be easily determined. Its elasticity, which is its most astonishing property, can be appreciated without the assistance of the scalpel. The observation of certain vital phenomena are sufficient to convince us of it but imperfectly; the same is the case with regard to its sensibility. There is nothing surprising in this when we remember that the skin is the organ of touch; and that this

sense, which is generally diffused over its whole surface, is extremely perfect at the extremities of the fingers. But this general knowledge of its properties and functions is not sufficient; it being indispensably necessary to become acquainted with its intimate structure. By maceration we may arrive at some knowledge of its texture. When we plunge a portion of skin into boiling water, the epidermis is observed to elevate itself, and the fatty matter it contains to melt. This procedure is sufficient to show us that the epidermis is an over skin, the texture and functions of which differ from the rest of the common integument, and that the fat is not an integrant part, but is a kind of cushion which is interposed between the skin and the parts which it covers.

After the epidermis is detached, there remains that portion of the integuments which is called the chorion, in which is found the reticular body, which appears to be a congeries of vessels, the number and direction of which, appear to be beyond the power of the anatomist to determine. On the surface of the chorion are perceived a number of little eminences which are called papillæ. The greater number of anatomists agree in considering these bodies as the terminations of the nerves, although it is impossible to trace the nerves into them; this opinion appears to be well founded. The great sensibility of this part, and the extreme pain which is felt when the chorion is exposed by some external agent, as a burn or blister, leave little doubt of the fact.

The hair and nails are considered as belonging to the skin, the former of which are spread profusely over the whole exterior surface of the animal economy, very abundant in certain places, and scarcely to be observed in others. Although they exist, their extreme minuteness renders it

difficult to perceive them. When we macerate or boil the skin, they do not leave the chorion, even after the epidermis is detached, which proves that they merely traverse this latter envelope, and that they are implanted into the chorion; by examining attentively the skin after long maceration, they may be traced in the chorion, and their bulbs or roots perceived. We must proceed in the same manner to observe the mode in which the nails are implanted on the extremities of the fingers; when we plunge these latter into boiling water, or cautiously expose them to the action of fire, we perceive that they are composed of scales, laid one upon another, which leads us to believe that the nails are composed of the thickened epidermis, and what appears to establish the fact, is the facility with which they are renewed.

Although a kind of analogy exists between the epidermis and the nails, their texture is not absolutely the same, and this should be attributed to the difference in form and organization of the subjacent parts with which these tissues are in relation.

Description.

S K I N .

Situation and relations.—The skin envelops the body generally, and occupies its exterior surface. Externally it is in contact with the atmosphere; internally it corresponds to different parts, which are more or less solid, as muscles, tendons, aponeuroses, bones, vessels of all kinds, &c. Between the skin and the subjacent parts, a quantity of cellular tissue is always interposed.

Structure and use.—The skin is composed of three distinct parts, which are the chorion, the reticular body, and the epidermis, to which last is added the hair and nails.

The former of these parts, viz. the chorion, is situated below the two others, and is the part of the skin which remains, after the different preparations to which it has been subjected. The second has been called the mucous or reticular body; experiments have proved that this body is composed of a congeries of vessels, placed between the epidermis and chorion. The third and last is the epidermis.

The hair has received different names, as the beard, eyelashes, generally we distinguish in a hair a stem and a root, the former is the portion exposed, it is elongated, cylindrical, and apparently composed of two membranes, in the interior of which is seen a little cylindrical canal. The root is enclosed in a kind of bulb, or membranous sac implanted on the chorion.

The nails are only seen at the extremities of the fingers and toes, they have the appearance of hard, whitish, and transparent laminae. They are divided into a root which is implanted on the proper substance of the skin, and a body, which forms all their visible portion. The reddish color which the nails ordinarily present, depends on the vessels which are below them.

The uses of all these parts are numerous and various; the skin in general defends the exterior surface of the body, from the too strong impression of surrounding bodies. The epidermis in particular moderates the too lively sensibility of the chorion, and permits us to approach and seize certain bodies, the immediate impression of which on the chorion would be too painful. The skin is the organ of touch, of the secretion of sweat, of insensible transpiration, and of cutaneous absorption. The nails and the hair appear to be intended to moderate the impression of hard and solid bodies, and to prevent their too lively percussion on the body.

ANGEOLOGY.

Preliminary Exposition.

Angeology is that part of anatomy which treats of the sanguineous vessels. We divide these vessels into arterial and venous; the former proceed from the heart to all parts of the body, and are infinitely divided; the second arise from the capillary extremities of the former, and proceed to the heart, having united their numerous divisions into two principal trunks. The arteries receive from the heart and transmit to all parts of the body a vermilion colored blood, which is light, and well oxygenated, and which contains the element necessary for the support of life. The veins on the contrary return, slowly, towards the principal organ of the circulation, blood, which is black, thick, containing no oxygen, and surcharged with azote and hydrogen: the first kind of blood contains the elements of nutrition and life, and the second contains agents which are destructive to this precious faculty. The course of the liquid likewise presents important considerations. On leaving the heart, the blood is propelled by lively and periodical shocks, which are equally and almost simultaneously felt in every part of the body. This motion is called *sistole*, when the heart contracts and expels the blood it contained; and when it relaxes it is called *diastole*. This alternating motion is felt throughout the arteries, and constitutes what is called the pulsation. The veins have no perceptible motion, and the blood traverses them slowly and imperceptibly.

The arteries and veins differ in structure, which difference is explained by their functions. The blood is driven

with force through the arteries, the coats of which are firm and resisting, the veins destined merely to contain the blood, which exerts little pressure on them, their walls are not so solid. The arteries are composed of several coats, laid one upon another, the number of which anatomists have not agreed upon; they generally admit the existence of an exterior coat, formed by the neighboring cellular tissue, but which does not appear to be essential to the walls of the arteries; below this is found what is called the membranous coat, which is laid on a third or muscular coat; finally, there is a fourth or internal coat, which is fine, reddish, smooth and polished. We count the same number of coats in the veins, but they are infinitely less thick, and their existence is not admitted by all anatomists.

In the exposition of Angeology, we shall pursue the following order: we shall first occupy ourselves with the arteries, and then we shall pass to the veins. The arteries shall be described in the order in which they arise from the principal trunks; thus the carotids, and their divisions shall be studied; the first, the sub-clavians shall follow them, those of the trunk shall come next, and we shall finish by those of the inferior extremities. The dissection of these parts, and the anatomical studies observed in the amphitheatres, do not allow us to pursue any other course. The veins require a different exposition: those of the head, and superior extremities, are to be studied first, then all the divisions of the superior or ascending cava, and then we shall pass to that portion of the venous system which appertains to the descending or inferior cava. The system of the vena porta shall terminate angeology, which we shall consider, to a certain degree, as a distinct portion of Veniolygy, as its different ramifications do not communicate directly with the inferior vena cava.

Particular dissection of Angeology.

Angeology and Neurology are those parts of anatomy which require much patience and dexterity on the part of the student, particularly when he wishes to dissect the more minute divisions of this part of the economy. It is true that the injections which are pushed into the veins and arteries to render them more distinct, facilitates singularly the study; but in despite of this advantage there are no parts which are worse dissected, and more frequently destroyed. In a preparation of Angeology, made by one not accustomed to dissect, arteries are divided at each stroke of the scalpel; the trunks are cut at their origin, the branches at their divisions, and it is not known to which of the trunks the ramifications belong.

To dissect well in Angeology, it is necessary to have evinced some ability in the dissection of the muscles: many arteries traverse the muscles, and loose themselves in their tissue, and if we are not well acquainted with these last and have not prepared them with care, the dissection of the arteries will be difficult and embarrassing. I have already mentioned that the instruments necessary for Angeology should be smaller and more delicate than those used for the muscles. Certain arteries are destined for the bones and traverse their holes or canals, it is necessary to follow them with the saw, mallet, and chissel, or, we can make these vessels more apparent by plunging the bones into some reagent, which will remove their earthy matter, and leave in the midst of their parenchyma, the vessels of bones, or, at least, traces of the coloring matter which has penetrated them; but this mode of preparing the vessels can scarcely be employed by students, they want time and the necessary apparatus for the operation. All the

precepts therefore which we could give on this subject would be of no avail. We must also acknowledge that the most minute preparations bring to light parts the knowledge which is, at least, superfluous to the student, who has just commenced the study of anatomy. Being farther advanced, and better instructed, his own genius and experience will assist more than books. M. Duméril, who has entered into very extensive details on all points concerning the art of anatomy, observes, in speaking of the variety and modifications of instruments, that "these modifications may appear minute: they depend on the experience of the anatomist, and on circumstances in which he is compelled to imagine them." The student will have completely fulfilled the task which is imposed on him, if he carefully dissects the principal arteries, those for example, which carry the blood to the viscera and which penetrate them, and, particularly, those which traverse the length of the extremities. If these last are not the most difficult to discover, they are, at least, more interesting to know, and, consequently, deserve more time and study, in their investigation. To prepare them properly and not to cut them, nor change their situation and relations, we must commence by a careful dissection of the muscles, divide those which interfere with the view of the vessels, and separate such as conceal the arteries; we should then pursue the arteries from trunk to branches, and from branches to ramifications; we must be particular to isolate these last from every thing which conceals them, and not to seize them with the forceps, as they are torn with facility; sometimes we may use the handle of the scalpel, but it is better not to touch them.

It remains for me to say something on the composition

of injections and the manner of injecting in general : this object moreover requires some precaution, and is not exempt from many inconveniences, which it will not be useless to allude to here. All subjects are not proper for the study of angeology, and the disadvantages which they present relate to the difficulty of injecting on the one hand, and that of dissecting them on the other. There is no part of anatomy which is more embarrassing than that of Angeology ; the subject may be bad, the injection may be unsuccessful, or, pushed with too great violence, it may have ruptured the arteries of the abdomen, and the injection extravasated into its cavity, the vessels of the extremities remaining empty. Those subjects which are fat, infiltrated, and of large stature, are, most frequently, improper. It is rare that the injection penetrates all the parts equally ; in addition to this first inconvenience, these subjects are embarrassing, difficult to dissect and require too much time in order to pursue the arteries ; for here it is neither the size nor extent of the vessels that it is important to see, but it is their situation, relations, and distribution that most interest us. As it will require much longer time to expose the brachial artery of a very long upper extremity, than it will for that of a thin and small arm, it will be admitted that a young subject, *cæteribus paribus*, will be more favorable for Angeology, than an individual of a high and robust stature. Let the student, therefore, select, if it be possible, a thin and young subject, from six, eight, twelve to eighteen years of age. The parts, in general softer, are more flexible, and will permit the injection to traverse more freely the principal arteries and their numerous divisions.

The study of anatomy is generally pursued during cold

weather; this circumstance is unfavorable to the success of injections. The parts are stiff, contracted, and sometimes even, more or less, frozen: in this case, the injection is arrested in its course, and scarcely fills the large arterial branches. It is for this reason that we are in the habit, as far as practicable, of placing the cadaver, intended to be injected, in warm water; the limbs then become supple, all the parts are relaxed, and the injection reaches without difficulty the smallest divisions. When this advantage cannot be enjoyed, we should relax the subject, at least in part, by moving the cadaver in all directions, and by putting in brisk motion its different articulations; it should then be placed horizontally on its back, the shoulders gently raised, by means of a solid body placed beneath, so that the head may fall easily backwards, by which the injection will be made to traverse the arteries of the superior parts with greater facility; we should separate the superior extremities from the trunk, and the inferior from each other, by drawing the feet outwards, and then we should be prepared to inject. In some schools, they are in the habit of injecting at two different times; this is objectionable and presents serious inconveniences; at Paris, the injection is made at one time; and this method, preferable in all respects, offers great advantages. For this purpose, the student removes, with the chisel and mallet, a portion of the sternum at its superior part, measuring about four or five inches in length, and an inch and a half in breadth; care must be taken not to carry the instrument too deep, for fear of wounding the aorta, which is found just under that portion of the sternum which has been removed, and also that we may avoid the internal mammary arteries, which are distributed under the

intercostal cartilages, very near their articulation with the sternum. The first object that presents itself is the pericardium, which must be carefully divided, in order afterwards to raise the aorta and pulmonary artery, which may be easily distinguished by the difference of their tissue and size. The first is ordinarily placed on the second; but, in order to avoid confounding the two, we need only pull gently on one of them, in order to perceive the direction taken by the tractions; when we pull on the aorta, the lateral parts of the neck are more or less agitated, which arises from tiraillement of the carotids. We then pass a scalpel between these two arteries, the superior of which, larger and thicker, is the aorta, which must be divided in its length, as near as possible to the heart in an extent of six or eight lines. It is in this opening that we should place the tube, around which the artery is to be tied; in it we fix the barrel of the syringe filled with the injection. This latter is composed of fatty materials, to which should be added some solid materials, such as colophony and the different kinds of resins. The following is a receipt published by M. Duméril, it is not expensive, and is very easily procured :

Tallow,	5 parts.
Burgundy pitch,	2 "
Olive or nut oil,	2 "
Liquid turpentine and coloring matter dissolved in volatile oil,	1 "

In all the private amphitheatres, they put still less polishing matter : 2 pounds of tallow, 6 ounces of resin or Burgundy pitch, one dram of ivory black, compose the matter injected; sometimes the ivory black is diluted in

three or four ounces of the oil of turpentine, which is injected first, in order to color the walls of the arteries; afterwards, the boiling injection is passed through the linen, which was used to receive the oil of turpentine and coloring matter; in this way its black color will be sufficiently marked to enable us to follow the arterial divisions. Whatever mode of injecting we may adopt, and whatever be the matter constituting the basis of our injection, we must always pass the boiling liquid through a linen sufficiently thick to retain the gross particles, which, without this precaution, would be pushed into the arteries, and arrest the injection; frequently too, they would cause the rupture of the vessels in which they penetrate. When we desire to make very nice injections, we will have to vary the ingredients. I deem it proper to pass this over in silence, for it would lead me into details which cannot have a place here, and for which the student may consult the work of M. Duméril, who has left nothing to be desired in this respect, and also that of M. Marjolin.

THE ARTERIES IN PARTICULAR.

In this description we shall expose the origin of the aorta and the first divisions parting from it. These divisions constitute what is called the ascending aorta; they are the carotids and subclavians, and also their different portions.

The carotids, called at first primitive, divide at several fingers' breadth from their origin, into external and internal. The principal branches of the first are, the superior thyroid, lingual, labial, occipital, posterior auricular, pharyngeal, temporal and internal maxillary; but one remarkable branch is given off from the internal carotid—it is the ophthalmic.

Anatomical Preparation.

Primitive carotids.—We must remove nearly the whole of the sternum, and also the internal portion of the clavicles, which are to be carried outwards; there remains a large space, in which are found the arch of the aorta, and the four arteries arising from it. We must not detach the clavicles at their humeral articulation, for we should destroy the transverse cervical arteries. A quantity of loose cellular tissue covers all these parts; it must be removed. We soon arrive at the jugular and subclavian veins, which will be readily recognized by their bluish color and easy compression—they must not be destroyed. Beneath these veins, is observed the arch of the aorta, from the convexity of which originate four arteries; those which go directly from below upwards, on the sides of the trachea, are the primitive carotids, which preserve this name as high up as the inferior jaw, where they divide into two branches. We cannot pursue the primitive carotids properly without commencing in the first place with the preparation of the muscles situated on the anterior part of the neck, such as the sterno-mastoideus, sterno-thyroideus, and hyoideus, and also the omo-hyoideus. We should not cut the muscles in question until we have a correct idea of the relations they bear to the arteries; we should leave in place the eighth pair of nerves, which is situated on the external side of the carotids, and also the recurrent, likewise situated on their external side, but at their inferior portion only, for it passes under these arteries in order to reach the larynx. We next pass to the divisions of the external carotid artery, which should be dissected at one time, except the internal maxillary, which must be left for the last, and which at this stage of our examination, it is

impossible to see, for it is absolutely concealed by the internal part of the branches of the lower jaw. It alone will be the object of a particular preparation.

External carotid.—As high up as the lower jaw, the primitive carotids divide into two branches; that which is most inwards is the external carotid; the other is the internal. As soon as the separation of these two arteries takes place, the external furnishes, within, a branch which descends towards the thyroid gland, it is the superior thyroïdal; it will suffice to separate, without removing them, the sterno-thyroid and sterno-hyoid muscles, in order to have a perfect view of the distribution of this artery, which may be followed without difficulty to the thyroid gland. Two other arteries arise from the external carotid, almost immediately after the origin of the thyroid; the one which is most outwards, is the external maxillary or facial; the other is the lingual. We must commence with the facial, for its superficial situation will not permit us to follow any other course; it travels, in a winding manner, towards the angle of the jaw, covered by the digastricus, a small portion of the stylo-hyoideus, and by the maxillary gland, on the external side of which it is found. It is, therefore, essential to expose these different objects, the preliminary preparation of which will favor singularly the study of the maxillary in this place. It is there seen to pass beneath the jaw in order to place itself in a slight depression, which is remarked on the inferior border, and anterior surface of the lower jaw, in the spot at which the body of this bone unites with the branches; it then passes, in a serpentine course, toward the commissure of the lips, where it divides into two branches, which proceed along both lips. As the flexuosities of the labial are very numerous,

and the integuments of the cheeks flaccid, it frequently happens that it is cut, when it is not dissected with attention. In order to avoid this inconvenience, we should place a wrapper of linen or paper in the mouth, and draw the integuments of the cheeks in different directions; in this way the parts will be made tense, which will assist very much in the dissection of this artery.

Lingual.—This artery, immediately after its origin, dips down between the genio-glossus and hyo-glossus, on the inside of the sublingual gland. In order to follow its distribution, we must saw the body of the lower jaw, at its middle portion, separate the two fragments, and then draw the tongue outwards and upwards. That this last operation may be rendered easier, we should cut the buccinopharyngeal aponeurosis; it will then be easy to follow the course of the lingual artery, the trunk of which goes particularly towards the base of the tongue. Having arrived there, this trunk divides into three branches, which may be pursued without any difficulty, being careful to keep the tongue in a degree of tension which will permit us to dissect the muscles of which it is composed. Of the three branches, that which proceeds posteriorly, and which passes on the base of the tongue, is called the dorsal artery of the tongue: the two others proceed towards the point of the tongue, and are called sublingual and ranine; this last marches parallel to that of the opposite side, in order to reach the point of the tongue together.

Occipital and posterior auricular.—The dissection of the one facilitates considerably that of the other; the occipital is the largest. Both of them may be readily recognized by their direction; immediately after their origin,

they pass backwards, profoundly concealed ; the occipital especially, by the sterno cleido-mastoideus, digastricus, splenius, &c. In order to follow the distribution of this last, we should cut the sterno-mastoideus at its middle portion, and separate the two extremities, as also those of the digastricus. Then, in following the occipital, we shall perceive it dip down in the space comprised between the transverse apophysis of the first cervical vertebræ, and the mastoid process, covered in this place by the digastricus, the eighth pair of nerves, and somewhat more posteriorly, by the sterno-mastoideus ; the occipital passes under the splenius, which must be cut across in order to expose it ; but it soon becomes subcutaneous, and may then be pursued with great ease. The preparation required for the study of the occipital has exposed the posterior auricular, which passes over the mastoid process, and the two surfaces of the pavillion of the ear, anastomosing frequently with the preceding.

Temporal.—After the preparation and study of the arteries already mentioned, it then remains to dissect the termination of the external carotid. Some regard the temporal as the continuation and termination of the carotid ; others, on the contrary, state it to be the internal maxillary. I shall not now undertake to decide this question, which after all, is unimportant ; it is our business to indicate the particular course to be followed by the student in their respective preparation : anatomical arrangements, claims the priority for the temporal ; this artery ascends in the direction of the external carotid, in the space comprised between the ear and lower jaw, beneath and enveloped by the parotid gland, which must be carefully dissected in order to expose the temporal. Having arrived at the

height of the zygomatic apophysis, it furnishes the transverse artery of the face, which is also covered in part by the parotid gland; it will now be extremely easy to follow the divisions of the temporal, which are distributed over all the lateral portions of the head.

Internal maxillary.—This artery, is beyond doubt, one of the most difficult to prepare, and requires considerable care and patience in its examination. We cannot recommend too strongly to the student, to have continually under his eye a dry head and its lower jaw, and also, if possible, different sections of heads. Without this aid and the exact knowledge of the foramina and conduits, through which the divisions of the internal maxillary pass, it will be very difficult to form a correct idea of this artery. For this preparation, the following precautions must be observed: saw the jaw on the side of the symphysis of the chin; break the zygomatic arcade, posteriorly near its root, and in front, along a line which proceeds from the superior to the inferior angle of the malar bone; detach the masseter from above downwards, and leave it united to the portion of the zygomatic arcade into which it is inserted; carry the whole posteriorly, and then saw the branch of the under jaw below the neck of the condyle and coronoid apophysis; detach the temporal muscle from above downwards; draw the whole somewhat backwards, and make an osseous lambeau of the entire exposed surface, the summit of which is found at the sphenopalatine foramen; the internal maxillary will be seen situated profoundly between the small pterygoid muscle and branch of the lower jaw. But it is unnecessary to pursue farther the preparation of this artery, until we have previously studied. 1st, The pterygoids, goids, small arteries, which are lost in the muscles of the

same name; 2d, the buccal, which passes on the internal membrane of the mouth, below the buccinator muscle; 3d, the alveolar, situated a little lower down, but which proceeds in the same direction, applied on the maxillary tuberosity, and covered by a quantity of fatty matter, which must be removed; 4th, the inferior dental, which penetrates the canal of the same name, and which there is danger of lacerating, if the branch of the lower jaw be carried too suddenly outwards; 5th, the masseter artery, which turns around the sigmoid depression on the branches of the lower jaw, in order to lose itself in the masseter muscle. It frequently happens that this artery is ruptured, notwithstanding the care taken in the section, necessary for the examination of the internal maxillary.

After the study of these different arteries, the student should proceed with the temporal, which require, on the one hand, as has been already remarked, the removal of the temporal muscle from above downwards, and, on the other, it will be necessary to break a portion of the cheek bone, in order to expose the anterior profound temporal; 2d, the infra-orbital, which arises nearly on a level with the alveolar, but which travels in a different direction, and reaches the infra-orbital foramen, united in this place to the nerve of the same name. If the student desire to pursue this artery more minutely, it will be necessary to expose the floor of the orbit, break a portion of the maxillary bone, and terminate its examination by following it on the face, under the canine muscle.

The palatine, vidian, pterigo-palatine and spheeno-palatine arteries cannot be traced without breaking nearly the entire of the upper jaw; we will then observe each of these arteries, proceed through a particular canal, the direction of

which will be brought to mind by recurring to our knowledge of Osteology ; for, I repeat it, without this knowledge, it will be very difficult to prepare these arteries. It may, however, be remarked that the palatine passes through the palatine canal, and re-appears on the arch of the same name, concealed by the palatine membrane, which must be removed ; that the spheno-palatine penetrates the foramen of the same name, in order to reach the pituitary membrane, and is afterwards found in the interior of the nasal fossæ ; that the superior pharyngeal, and pterygoid, or vidian of some authors, proceed to a canal bearing their respective names ; finally, that the pterigo-palatine, which is regarded as the termination of the internal maxillary, enters and traverses the canal of the same name. I place here the spheno-spinous, although, in the order of origin, it is the first of which authors make mention. As it cannot be studied until after the preparation of all the others, its divisions being distributed in the cranium, we must of necessity saw through this osseous box in order to follow them. We may, therefore, either proceed at once to open the cranium, in order to study the spheno-spinous, or wait until we are ready for the preparation of the internal carotid, which requires the same preliminary operation.

Having reached the interior of the cranium, it is placed in a groove, which is seen on the internal portion of the anterior and inferior angle of the parietal bone. Hence it is distributed over the whole external surface of the dura mater, and produces by its numerous divisions, over the whole concave part of the parietal bone, those hollow lines in form of grooves, which assume an arborescent appearance.

When we detach the dura mater from the internal portion of the bones of the cranium, the divisions of the sphenospinous artery remain applied on the external surface of this membrane, on which they may be traced without difficulty.

Description.

PRIMITIVE CAROTIDS.

(CEPHALIC TRUNK.)

Situation.—On the lateral and inferior portions of the neck.

Extent.—From the arch of the aorta, to the thyroid cartilage.

Direction.—Slightly oblique from below upwards, from within outwards, and from before backwards.

Relations.—They correspond with the platysma myoides, sterno-mastoideus, sterno and thyro-hyoidei in front, and with the vertebral column posteriorly; internally, with the trachea and larynx; externally, with the internal jugular veins, the great sympathetic and par vagum.

Divisions.—They do not give off any branches, but terminate by two large trunks, called the external and internal carotids.

EXTERNAL CAROTID.

(*Facial.*)

Situation.—On the lateral and superior portions of the neck.

Extent.—From the termination of the primitive carotid, to the condyle of the lower jaw.

Direction.—Vertical.

Relations.—In front, with the platysma myoides at first, then with the digastric muscle, ninth pair of nerves and stylo-hyoideus, and superiorly with the parotid gland; internally, with the stylo-pharyngeus and stylo-glossus.

Division.—1st, Superior thyroïdal, destined for the gland of the same name, and which in its trajet sends a small branch to the larynx, called laryngeal.

2d, Labial (palato-labial,) which ascends in a serpentine course on the body of the jaw, and furnishes, before arriving there, the submental; it is flexuous as far as the commissure of the lips, divides into the coronaries, and anastomoses, under the name of angular, with the termination of the ophthalmic.

3d, Lingual, which goes to the tongue, furnishes the sublingual, and dorsal branch of the tongue, and terminates by the ranine.

4th, Occipital, which, deep seated, proceeds to the posterior part of the head, posterior and superior of the neck.

5th, Posterior auricular, which advances towards the internal part of the ear, and sends off in its course, the stylo-mastoïdeus, the branches of which are lost in the external auditory conduit, in the aqueduct of Fallopius and mastoid apophysis.

6th, Inferior pharyngeal, which ascends along the vertebral column, behind the pharynx, and furnishes branches which go, on the one hand, to the eustachian tube, and, on the other, penetrate the cranium by the posterior foramen lacerum.

7th, Temporal, which ascends, in the direction of the principle trunk, towards the temple, and gives off, on a level with the zygomatic apophysis, the transverse artery of the face, and distributes numerous branches on the superior, anterior, and posterior portions of the head.

8th. Internal maxillary, which, from the condyle of the lower jaw, ascends to the summit of the zygomatic fossa, and furnishes the following arteries :

The *spheno-spinous*, which proceeds directly from below upwards to the spheno-spinous foramen, which it traverses in order to penetrate the cranium, and divides into numerous branches on the external surface of the dura mater.

The *inferior dental*, which is directed from above downwards, and from behind forwards; penetrates the dental canal of the under jaw, through the foramen of the same name, traverses its whole extent, gives off branches in its course for all the teeth, and passes out through the mental foramen, in order to lose itself in the quadratus and triangularis muscles of the face.

The *profound temporals*, two in number, distinguished into anterior and posterior. Both of them pass under the temporal muscle, between this muscle and the fossa temporalis.

The *buccal*, which proceeds transversely from behind forwards, and loses itself in the buccinator muscle.

The *alveolar*, which goes in the same direction as the preceding, marching along the alveolar border of the superior jaw, on which it ramifies.

The *masseter*, which is inconsiderable, and proceeds, after a short trajet, from within outwards, towards the sigmoid notch of the lower jaw, and thence penetrates the masseter muscle, in which it is lost.

The *pterygoids*, two in number, which travel a very short distance, and then reach the pterygoid muscles in which they lose themselves.

The *infra-orbital*, which reaches the bottom of the zygomatic fossa, and then places itself in a notch, presented to it by the posterior part of the orbital surface of the superior maxillary bone; thence it travels forwards,

lodged in a groove of the maxillary bone, and passes out through the infra-orbital-foramen, in order to expand itself on the muscles of the face.

The *superior palatine*, which proceeds towards the superior part of the posterior palatine canal, which it traverses in its whole extent; it passes out through its inferior orifice, and ramifies on the palatine membrane.

The *vidian*, which divides into two branches; the first traverses the canal at the base of the pterygoid apophyses, proceeds from before backwards, and reaches a small canal on the temporal bone, and penetrates this bone through the hiatus Fallopii; the second, which may be termed the superior pharyngeal, loses itself in the parois of the pharynx and eustachian tube.

The *pterigo-palatine*, which passes across a small canal formed by the articulation of the vomer and os-sphenoides, and expends itself on the most elevated portion of the pharynx.

The *spheno-palatine*, which proceeds from without inwards, and penetrates through the spheno-palatine foramen, the interior of the nasal fossæ, on the lateral portions of which it ramifies.

INTERNAL CAROTID.

It furnishes the ophthalmic, the communicans, the artery of the corpus callosum, and that of the lobe of the brain.

Anatomical Preparation.

Internal carotid.—This artery is destined for the brain and the organ of vision. The different preparations already made, will have exposed that portion of it situated without the cranium, so that no additional dissection will be required; but it is indispensable to open the head in order to follow it in the brain; we are even obliged to combine its

examination with that of the vertebral artery, although this latter arises from the subclavian, because these two arteries frequently anastomose with each other, and it is from their *ensemble* that the brain receives all its arteries. As the vertebral artery, from its origin, penetrates a canal formed by the cervical vertebræ, it will suffice to commence with it at its entrance into the cranium, and to follow its distribution conjointly with that of the internal carotid. It will, therefore, be readily conceived that, for the preparation of either of these two arteries, it will be necessary to open the cranium; we should avail ourselves of this opportunity to study the meningeal artery, destined principally for the nourishment of the dura mater. It is for this reason, that we should remove the top of the cranium cautiously, and leave for the moment, the dura mater untouched on the brain; it is the only mode by which we shall be enabled to obtain a good view of the course and distribution of the meningeal artery. When this is accomplished, we should cut this membrane in the direction of the superior longitudinal sinus, and separate the flaps, in order that we may completely expose the brain, the entire mass of which must be removed by commencing at the base of the cranium. We should proceed from before backwards; and, in proportion as it is thus turned up, we should cut first the ophthalmic arteries, at some lines from the foramen of the same name; more posteriorly, the trunk of the two carotids; finally, the vertebrals, as much in front as possible, in the vertebral canal; we should then remove the brain, which should be placed carefully on the table, or received in the top of the cranium. A great number of vessels are observed at the base of the brain; posteriorly, are the two vertebrals, which unite in a common trunk,

which receives, in front, two branches from the carotid, called communicating arteries. The branches which originate from the lateral parts of the basilar trunk are the superior and inferior arteries of the cerebellum, the posterior arteries of the cerebrum, and the spinal arteries. In front, the trunk of the carotids furnishes the arteries of the corpus callosum, which we should pursue by turning over the brain, and separating its two hemispheres. There likewise go off from it two other branches which dip into the fissure of the brain, but which have not received any particular names.

Ophthalmic.—In consequence of the preparation which we have been obliged to make, the ophthalmic artery is cut at the entrance of the foramen opticum. This artery furnishes a number of branches, which it is not always easy to perceive, because it frequently happens that the injection does not penetrate them all equally; be this as it may, we must perform, for the preparation of the ophthalmic, the same section that was indicated for the preparation of the muscles of the eye. We should then push forward the portion of the orbit that has been sawed; preserve the infra-orbital artery, one of the first branches given off by the ophthalmic, and proceed at once to the preparation of the others. The best mode of doing this, is to proceed, as if we intended to study the muscles of the eye, and respect all the branches that are found under the scalpel. When we have properly removed the fat, we will then see without difficulty the lachrymal branch, which expends itself on the gland of the same name; the muscular, two in number, the two palpebral, the two ethmoidal, the central artery of the retina, the ciliary arteries, the nasal and frontal; each of these arteries proceeds to a distinct

part, which renders their examination much easier; but we shall not be able to have a good view of these arteries, if we do not free them from the abundant fatty matter which envelopes the globe of the eye and the surrounding parts. This dissection is an affair of patience and skill; the arteries to be prepared are numerous and very near to each other, which often causes some of them to be cut; this will occasion confusion, and will tend to increase the difficulties.

Description.

INTERNAL CAROTID.

(Anterior Cerebral.)

Situation.—On the lateral portions of the neck, and in the interior of the brain.

Extent.—From the primitive carotid to the carotid foramen, and thence to the orbit and the whole cerebral mass.

Direction.—Vertical.

Relations.—On the neck, it corresponds inwardly to the pharynx, outwardly to the internal jugular vein, posteriorly to the vertebral column, and in front to a portion of the external carotid, and pharynx; in the cranium, it is at first contained in the carotid canal; lodged afterwards in the cavernous sinus, it makes a posterior curve, and goes to communicate with the basilar trunk.

Divisions.—1st, Ophthalmic, which arises from the bend formed by the carotid, on leaving the cavernous sinus; it penetrates the orbit on the external side of the optic nerve, and furnishes the following branches:—the lachrymal, supra-orbital, centralis retinæ, ciliary, muscular, palpebral, ethmoidal, frontal, and nasal, which forms

the termination of it, and anastomoses with the angular, a branch and termination of the labial; 2d, Arteria communicans, which arises posteriorly near the pons varolii, and soon anastomoses with the branches of the basilar trunk; 3d, The carotid then divides into two branches, one of which, called the artery of the corpus callosum, travels forward between the hemispheres of the brain, and the other, longer and larger, dips down into the fissure of Sylvius.

SUBCLAVIANS.

These two arteries likewise originate from the arch of the aorta, but at some distance from each other; destined for the superior extremities, they proceed immediately towards these parts, and change their name in proportion as they recede from their origin. Thus, both of the subclavians become axillaries under the arm-pit, brachial or humeral along the arm, radial and cubital on the forearm, and palmar on the hand. We shall now describe successively each of these divisions.

Anatomical Preparation.

Subclavians.—The preparation of the carotids has achieved part of the work necessary for that of the subclavians. In a word, a portion of the clavicles has already been removed, and also the greatest part of the sternum; the cellular tissue has likewise been taken away; the internal jugulars are isolated, and, finally, the origin of the subclavians is exposed; nothing then remains but to pursue them. We will observe, before going farther, that, of the two subclavians, the right originates from a common trunk with the carotid of the same side; that it is also

placed more forwards than the left subclavian, which is rather deep-seated, and arises from the most distant part of the arch of the aorta. These two arteries scarcely proceed two fingers' breadth, when they furnish several branches, all of which are remarkable for their great extent, and the frequent anastomoses they form in their course. One of the first is the internal mammary, which passes under the sternum, and anastomoses under the parois of the abdomen with a branch of the external iliac. I am in the habit of commencing *Angeology* with the exposition of the mammary and epigastric. If we do not commence with these, we shall probably not have an opportunity of seeing their connection. In order to have a good view of them, it will be necessary to saw the whole of the sternum in its length, open the parois of the abdomen as far as the pubis, and turn the divided parts outwards; on looking within, and without the aid of any dissection, we will perceive the course and anastomoses of the two arteries; and once recognized, we may trace them in all their divisions.

Somewhat posteriorly to the mammary, originate the superior intercostal arteries, which must be left for the instant, in order to return to them after the study of all the branches of the subclavian. Nearly at the same place is observed the inferior thyroïdal, which will be easily recognized by its direction towards the gland of the same name. A little more profoundly and above the vertebral arises a large branch, which immediately penetrates the canal formed by the cervical vertebræ, and which may be followed to its entrance into the cranium, breaking, as we proceed, the transverse apophyses of these vertebræ; more externally, the subclavian furnishes the ascending

cervical, the transverse cervical, the profunda, and, finally, the superior scapular. As these different arteries lose themselves in the muscles or dip down under their mass, we must, before proceeding with their examination, expose these muscles and dissect them, in great part, as was pointed out in Myology; this is, without doubt, the best way of enabling ourselves to follow the arteries as far as their importance demands; we should early accustom ourselves to trace an artery very minutely, especially when the injection will permit us to do it with success.

Axillary.—In emerging from the scaleni muscles, the subclavian loses its name and assumes that of axillary. This latter requires us to proceed to the dissection of the pectoralis major, which must be cut across in order to expose the artery. This will not be sufficient; the muscles of the arm should likewise be dissected in part, the deltoid especially, for, although the extent of the axillary is not considerable, yet it dips down deep into the hollow of the axilla; there it is surrounded by a quantity of cellular tissue, and sometimes it is concealed by the axillary glands; all these objects should be removed, and we should follow the trajet of the artery in order to see how it mingles with the brachial plexus, which must be preserved. Placed at first above this plexus, and covered by the axillary vein, it soon passes through the branches of the plexus, and is, as it were, surrounded by it. This distribution should be followed; the difficulties are not very great, we only require patience and attention.

When we have properly separated the axillary artery from the surrounding parts, and if we should succeed in not cutting the vessels it sends off, we will observe that it furnishes to the pectoral muscle and neighboring parts

three or four branches, called thoracic, the distribution of which is not very important; but externally and posteriorly, it gives off two remarkable branches, one of which goes to the deltoid, and called acromial, the other proceeds under the scapula, and is termed the common scapular artery. We should not be too much in a hurry to pursue these two arteries; we can return to them again in a short time, for it is better, at this stage of the dissection, to detach the superior extremity from the trunk, in order to examine with greater facility the arteries distributed on it, and during which it is necessary to turn the limb sometimes in one, sometimes in another position. The clavicle and scapula should remain attached to the upper extremity, and should not be separated until a much later period. Before proceeding farther, we may examine the superior intercostals, placed under the two first ribs, and which nothing now prevents us from studying with all possible care. The arm, thus isolated, will permit us to expose to much greater advantage two other arteries, branches of the axillary, which, encircling the neck of the humerus in its whole circumference, have received the name of circumflex, one of them (the external) passes under the deltoid, which must be cut crosswise, in order to raise the superior flap, which covers it; the other, more voluminous, proceeds under the triceps in order to anastomose with the preceding; it is now easy to perceive what course is to be taken for the purpose of following these two arteries. The axillary artery at this period loses its name, and assumes that of brachial or humeral.

Brachial.—The dissection of the muscles of the arm, of the biceps especially, will suffice for the study of the brachial artery. The branches which it furnishes in its

progress to the bend of the arm, are lost in the muscles, and, with the exception of two which are more considerable, they have not received any particular names. Those to which I allude are the collateral, one of which (the external) arises very high up, dips down under the triceps, and re-appears on the external and lower portion of the humerus, in order to lose itself in the articulation of the fore-arm, in anastomosing with the recurrents; the other (the internal) arises very low down from the brachial, proceeds immediately towards the articulation, and likewise anastomoses with the recurrents. The brachial artery is constantly accompanied by the median nerve, which we must be careful not to cut, but which, on the contrary, should be preserved in order that we may examine the relations of these different parts.

Radial and Cubital.—Below the bend of the arm the brachial divides into two branches, one of which (the radial) proceeds down the external side of the fore-arm, and the other (the cubital) down the internal side. In order to examine these arteries, as also the numerous branches which they furnish at the bend of the arm, we should, after having laid open the integuments of the fore-arm in their whole extent, occupy ourselves in the first place with the radial, which proceeds under the skin, in the direction of the radius; we should leave it near the hand, in order to return to the cubital, which travels in the direction of the cubitus; but this latter is more deeply seated; in order to follow it, it will be necessary to dissect the biceps, pronator teres and the other muscles on the anterior part of the fore-arm. It is only after having travelled for sometime under these muscles and crossed them in their direction, that we perceive it re-appear very low down,

placed on the external side of the anterior cubital ; it then passes towards the wrist, where we should abandon it in order to return to the articular branches furnished by the radial and cubital, and which are called recurrents ; these arteries are four in number, two radials and two cubitals, which are distinguished into superior and inferior ; each of them surrounds the articulation, and it will be easy to follow them when we have recognised their trunk. In proceeding with care, we will reach without difficulty the termination of these arteries, which, although small, demand considerable attention. Surgery will derive the greatest advantages from an exact knowledge of them.

Independently of the recurrents, the cubital furnishes an artery, called interosseous, which divides into two branches, one for the anterior portion of the interosseous ligament, and the other for the posterior portion : we must seek for these arteries, by separating the muscles, which were previously dissected ; they may be traced as far as the wrist, where they terminate by anastomosing with the palmar arteries ; but the posterior interosseous furnishes the posterior radial recurrent ; this must not be forgotten, otherwise we might look for it in vain elsewhere.

The Palmar arches.—They are distinguished into superficial and profound ; the first is the continuation of the cubital, the second of the radial. Their dissection demands great attention, for their divisions are numerous, and so arranged that they intermingle with a regularity which it is highly important to understand. In following the cubital in the hand, we will perceive that it forms the superficial palmar arch. In order to see it, it will be only necessary to remove the integuments of the palm of the hand and the palmar aponeurosis ; but if we should desire

to pursue it in its distributions to the fingers, we must necessarily free these latter from their integuments.

The deep-seated palmar arch requires more care and presents greater difficulties; it is on the posterior part of the thumb, between this last and the index finger, that the trunk of the radial dips down under the adductor of the thumb, in order to become deep-seated in the hollow of the hand, and effect, in this place, the same disposition as the superficial palmar arch. It will be readily conceived that its dissection cannot be exact, if we do not remove the greater part of the muscles on the palm of the hand; and let the student remember that, in this preparation, he must proceed with the greatest possible care, otherwise he will most probably spend his time to no advantage.

Description.

SUBCLAVIANS.

(Brachial trunks.)

Situation.—At the superior portion of the chest and inferior of the neck.

Extent.—From the arch of the aorta to the first rib.

Direction.—Oblique from within outwards, and from below upwards, forming a curve, the convexity of which is above.

Relations.—The right subclavian corresponds in front, to the vein of the same name, to the sterno-hyoid and sterno-thyroid muscles, and to the clavicle; posteriorly, to the trachea and vertebral column. The left subclavian corresponds, in front, to the left lung, to the vein of the same name, and to the clavicle; posteriorly, to the vertebral column.

Divisions.—1st, The vertebral, which arises from their superior portion, traverses the canal formed by the cervical vertebræ, and penetrates the cranium, where it forms the basilar trunk, which gives off the superior and inferior arteries of the cerebellum, and also the anterior and posterior spinal; the basilar anastomoses with the communicating arteries, after having furnished the posterior artery of the cerebrum; 2d, The inferior thyroïdal, which ascends towards the thyroid gland and loses itself in it, in anastomosing with its fellow and also with the superior thyroïdal; 3d, The superior scapular, which proceeds posteriorly towards the scapula, passes on its superior border, and expends itself on the supra and infra-spinatus muscles; 4th, The transverse cervical, which travels on the inferior lateral portions of the neck, below the muscles of this part, and loses itself in the muscles of the superior portion of the back and inferior of the neck; 5th, The internal mammary, which arises from the inferior part of the subclavian, passes under the cartilages of the ribs, furnishes in its course the diaphragmatic, proceeds onwards under the intercostal cartilages, giving small branches to all the ribs, and anastomoses with the epigastric and anterior iliac; 6th, The superior intercostal, which proceeds, immediately after its origin, under the neck of the first rib, and divides into two branches, destined for the two upper ribs.

AXILLARY.

(*Idem.*)

Situation.—In the hollow of the axilla.

Extent.—From the first rib, below the head of the humerus.

Direction.—Oblique from within outwards, and from above downwards.

Relations.—In front, with the clavicle, the great and small pectoral muscles; posteriorly, with the brachial plexus; above, with the integuments and platysma myoides; below, with the first rib, on which it leaves a remarkable depression; afterwards with the second rib.

Divisions.—1st, Three or four thoracic arteries, which proceed forwards, and lose themselves in the mammæ, pectoral muscles, great serratus and intercostals; 2d, Acromial, which passes outwards towards the articulation, and gives branches to the deltoid and pectoral muscles; 3d, Common scapular, which arises from the posterior part of the axillary, proceeds towards the subscapularis, and furnishes this muscle with numerous branches; it then divides into two principal branches, one within, and the other above the scapula, and it expends itself on the muscles covering this bone; 4th, Circumflex, the last branches given off by the axillary, and which are distinguished into anterior, very small, and into posterior, which is larger. The first proceeds below the deltoid, furnishes branches to this muscle, to the biceps and to the articulation; it then turns around the humerus from without inwards, in order to anastomose with the posterior circumflex; this passes under the great and small round muscles, proceeds between the triceps and humerus, gives off branches to these different parts, and anastomoses with the preceding.

BRACHIAL.

(*Humeral.*)

Situation.—On the internal and anterior part of the arm.

Extent.—From the axilla to the bend of the arm.

Direction.—Oblique from above downwards, and from within outwards.

Relations.—In front, with the common integuments; behind, with the triceps brachialis above, and the brachialis anterior below; within, with the median nerve; without, with the internal border of the biceps.

Divisions.—1st, External or superior collateral, which arises from the internal and superior part of the brachial; accompanied by the radial nerve it turns around the humerus, passing under the three portions of the triceps brachialis, and descends towards the external tuberosity of the humerus, in order to anastomose with the radial recurrents; 2d, Internal collateral, which arises very low down from the brachial, and proceeds towards the internal tuberosity of the humerus, in order to anastomose with the cubital recurrents.

R A D I A L .

(*Idem.*)

Situation.—On the anterior and external part of the fore-arm.

Extent.—From the fold of the arm, to the palm of the hand.

Direction.—Parallel to that of the radius.

Relations.—In front, with the integuments; behind, it reposes on the pronator teres, sublimis, profundus, and pronator quadratus muscles.

Divisions.—1st, Anterior radial recurrent, which arises from the superior part of the radial, turns around the articulation, and furnishes branches to the neighboring muscles and articulations; it anastomoses with the external collateral, a branch of the brachial; 2d, In its course, the

radial sends off several small branches to the muscles of the fore-arm; after arriving at the palm of the hand, it furnishes it with one, which is destined to anastomose with the end of the superficial palmar arch; it then passes outwards and gets between the thumb and index finger; before arriving there, it gives off the dorsal branch of the thumb, and thence proceeds between the first and second metacarpal bones, and forms the deep-seated palmar arch, the termination of which anastomoses with the superficial palmar arch. From this arch originates an infinity of branches which expend themselves on the neighboring parts; the largest of them reach the sides of the fingers, and are termed collaterals.

CUBITAL.

(*Idem.*)

Situation.—On the anterior and internal portion of the fore-arm.

Extent.—From the bend of the arm to the palm of the hand.

Direction.—Parallel to that of the cubitus.

Relations.—In front, with the pronator teres, radialis anterior, palmaris parvus, flexor sublimis, cubitalis internus, and below with the integuments; behind, with the cubitus and pronator quadratus; within, with the cubital nerve, and, externally, with the sublimis.

Divisions.—1st, Cubital recurrents, distinguished into anterior and posterior. They arise very high up from the cubital, encircle the articulation in front and posteriorly; they furnish branches to the articulation and neighboring parts, and terminate by anastomosing with each other as well

as with the internal collateral; 2d, interosseous, distinguished into anterior and posterior, which proceed to the interosseous ligament, and terminate by anastomosing with both of the palmar arcades. The posterior interosseous gives off in addition, at its superior portion, the posterior radial recurrent, which, in its distribution, does not differ from the other branches of the same name; 3d, In the rest of its course, the cubital furnishes several small branches to the muscles of the fore-arm; finally, having arrived at the palm of the hand it forms the superficial palmar arcade, which is covered by the integuments only, and which is distributed to the surrounding parts, in the same way as the radial.

DESCENDING AORTA.

After sending off the carotids and subclavians, the aorta descends in the chest; it passes through the diaphragm, and traverses the abdominal cavity; having arrived at the last or next to the last lumbar vertebra, it divides into two branches, called primitive iliacs. In this long trajet, it gives off the coronary, intercostals, pericardiacs, œsophageal, bronchial, mediastins, diaphragmatics, the cœliac trunk, the superior mesenteric, the capsular, renal, spermatics, and inferior mesenteric.

Anatomical Preparation.

Some are in the habit of commencing the study of the arteries just enumerated by the cœliac trunk; several books on anatomy even begin with its description when treating of Angeology. This method is by no means unreasonable; in following it, they remove the soft parts contained in the abdomen, the putrefaction of which is

much more rapid than the other parts of the cadaver; but, on the other hand, the great facility which students now enjoy of procuring subjects for the various parts of anatomy, the different ingredients composing the injections, the nature of which opposes, to a certain degree, the developement of decomposition, and the season even, may authorise a different course. We should, therefore, commence by the thoracic or pectoral aorta, the preparation of which is not attended with any difficulty. For this purpose, we should open the chest in the usual manner, if this has not already been done; we should be careful with the ribs, and break them only in a portion of their extent, or even they may be left untouched, in order that we may have a better view of the intercostals; we should raise, without detaching it, the lung of the left side; if we turn it over into the right portion of the thorax, we will see, without difficulty, the aorta, considerably developed by the injection, descending along the vertebral column, inclined slightly to the left side; we will, moreover, observe the small arteries, which, from its anterior portion, proceed to the esophagus and mediastinum; in addition, from its lateral portions, more considerable branches are given off, placed with a sort of regularity above each other; they are nine in number, and are destined for the nine intercostal spaces; their course may be followed without any other preparation than that which we have indicated for the aorta. When we desire to examine them more particularly, it will be necessary to remove the portion of pleura which covers them, which may be done with facility. The right intercostal arteries are longer than the left, in consequence of the situation of the thoracic aorta.

Celiac trunk.—This artery, profoundly situated, and

of moderate extent, is remarkable only on account of the branches which it furnishes ; they all go to important viscera, and their distribution merits especial attention, and presents great interest. After having opened the abdomen in a considerable extent, we should seek for the interval between the liver and stomach ; the loose cellular tissue should be removed cautiously, and then by plunging the fingers towards the spinal column to seek for the aorta, we will meet with the cœliac artery, which arises from the aorta almost immediately after its passage through the diaphragm ; it is by no means the most difficult part to find the cœliac trunk, but we must trace the three branches which it gives off, and which are destined for the stomach, liver and spleen, under the names of gastric, hepatic and splenic. It is at the moment of their entrance into each of these viscera, that we must commence with them, in order afterwards to follow them in a retrograde manner towards their common trunk. In order to render this operation the more easy, we may break the last false ribs, which will give us the advantage of turning the liver and stomach outwards, and of exposing a large space between them. We should be careful in using the scalpel not to cut any of the principal arteries, which are here very numerous. The first and smallest is the gastric, which proceeds towards the commencement of the lesser curvature of the stomach, on the left side, and traverses it in its whole extent. In order that we may have a more advantageous view of the divisions of this artery, we should inflate the stomach, which presents an interesting and at the same time instructive appearance. Another branch of the cœliac trunk goes on the right to the liver ; this is the hepatic, which furnishes another considerable branch,

that proceeds towards the right portion of the stomach, towards the greater curvature, and also to the pancreas, under the name of right gastro-epiploic artery; it likewise sends a small branch to the pylorus. The splenic artery, which is the largest of the three, proceeds transversely under the stomach, in order to reach the spleen. In tracing it from this latter viscus to the common trunk, we should be careful, in raising the stomach in order to render it more apparent, not to injure the numerous vessels which proceed from the spleen to the stomach, under the name of vasa brevia, and likewise a branch, which passes to the greater curvature of the stomach, and is called left gastro-epiploic artery. It is also at this stage of the dissection that we should occupy ourselves with the inferior diaphragmatic arteries, which require but a very slight preparation. In a word, we should raise, as much as possible, the anterior part of the circumference of the diaphragm; and depress, on the other hand, the stomach, liver, and spleen, when we will readily perceive the arteries in question ramify on the inferior surface of the diaphragm. We can, in this way, follow them in their distributions, and arrive without difficulty to the trunk from which they originate. We should next pass to the preparation of the mesenterics, renal, capsular and spermatics, before terminating the study of the arteries of the abdomen.

Mesenterics.—Of the two mesenterics, the superior arises very near the cœliac trunk; its numerous branches extend to a great distance, and are distributed to almost all the intestines. It is rather difficult to indicate, in a precise manner, the means of properly recognizing the principal branches, and the remarkable divisions furnished by the

superior mesenteric. They are numerous, and this circumstance alone renders their study very embarrassing. It is indispensable, however, that we examine the distribution of the branches called colic. In order to do this, we should raise the epiploon, which is to be turned over on the sides, as well as the transverse colon, and the other intestines should be carried downwards to form with the colon a species of circle, with which we surround the abdominal cavity, and which should be enlarged as much as possible; in the interval are found the jejunum and ileum, which should be carried somewhat to the left; we then expose, on the right side, three large branches which originate from the concavity of the mesenteric. These three branches are the colics, each of which divides into two other principal branches, destined to anastomose with each other. We should be particular to have a good view of the celebrated anastomosis of the two mesenterics, which takes place on the left side, between the right superior colic branch of the great superior mesenteric, and the left superior colic, a branch of the inferior mesenteric. The numerous branches (15 to 20) which arise from the convexity of the great mesenteric, have not received any particular names, notwithstanding their large size; they are distributed, in great part, on the jejunum and ileum.

The inferior mesenteric arises very low down from the aorta, and at a short distance only from its bifurcation; much less considerable than the superior, its distributions are less extensive and numerous; but, like the superior, it describes a species of curve the convexity of which is on the left, and furnishes three branches, called the left colics; the superior anastomoses, as has already been remarked, with the superior mesenteric. We should

extend the colon, draw it outwards and thus isolate properly the left colics and branches which part form its concavity, the distribution of which is precisely the same as in the superior mesenteric. After this operation, which is long and even embarrassing, we may inflate the intestinal paquet, and then remove it cautiously, together with the mesenterics; but the capsular, renal, and spermatic arteries must be left untouched; we may also remove the liver, spleen and stomach.

Capsular, renal, and spermatic arteries.—The first of these arteries have but little extent, and their volume is inconsiderable. They arise from the aorta between the superior mesenteric and renal, and proceed towards the glandulæ renales, on which they are expended. It will suffice to free them from the loose cellular tissue, which sometimes conceals them from view. They do not require any other preparation.

The renal arteries are very large and cannot be mistaken. They are both accompanied by veins of the same name; in addition, the right renal is, in part, covered by the inferior vena cava. They are sometimes covered by a loose and abundant cellular tissue, which should be removed. It often happens that the renal divides into two and even three principal branches, and that it thus penetrates the kidney at different points more or less distant from each other; sometimes, the capsular are furnished by the renal arteries. These different varieties might prove embarrassing if the student were not apprised of them. In general, the renal arteries, and even all those of the abdomen, present numerous anomalies.

The spermatics arise from the anterior portion of the aorta, between the renal and inferior mesenteric, and pro-

ceed as far as the testicles without furnishing any branches. It must be remembered that these arteries pass through the ring in order to reach their destination, and that they contribute to the formation of the spermatic cord; in the abdomen, there is no obstacle to their preparation; without this cavity, they are accompanied by a nerve, vein, and by the vas deferens, but united to these parts in so loose a manner, that they may be examined with facility in their whole extent.

Lumbar and middle sacral.—We cannot examine these arteries until after having removed the intestinal paquet, and also the kidneys. It is necessary only to preserve the rectum, around the superior portion of which we should pass a ligature; then, in removing the remaining cellular tissue, we will readily expose the origin and course of the lumbar arteries, which will be found in the intervals of the lumbar vertebræ.

The anterior sacral is a small artery, which arises from the bifurcation of the aorta, and is distributed on the anterior and middle portion of the sacrum. It is extremely small, and cannot be seen until we have removed the layer of cellular tissue by which it is concealed. The rectum, when left in place, will likewise frequently prevent our seeing it.

Here we terminate the dissection of the arteries of the chest and abdomen, the study of which cannot be separated, and which we shall now describe in the order of their preparation.

Description.

DESCENDING AORTA.

It is divided into two portions: that which is contained

in the chest bears the name of descending thoracic or superior aorta; the portion below the diaphragm is called the descending abdominal or inferior.

DESCENDING THORACIC AORTA.

Situation.—In the cavity of the chest, along the vertebral column.

Extent.—From the left ventricle to the diaphragm.

Direction.—From the ventricle to the third dorsal vertebra, it presents a remarkable curve, called the arch of the aorta, which proceeds at first from below upwards, and from behind forwards: afterwards from above downwards, from before backwards, and from right to left; in the rest of its extent, it follows nearly the direction of the spinal column, but lies evidently to the left.

Relations.—It corresponds, posteriorly, to the left lateral portion of the bodies of the vertebræ; in front, to the esophagus; on the sides, to the two laminæ of the mediastinum; and, in addition, the vena azygos and thoracic duct are situated on its left side.

Divisions.—1st, The coronary (*cardiac*) two in number, destined for the head; 2d, the bronchial, one on the right and the other on the left, which proceed towards the bronchiæ, continue with them to the lungs, and expend themselves on the substance of these organs; 3d, the esophageal, three, four, five or six in number, which pass from the anterior portion of the aorta to the esophagus; they penetrate this canal and there ramify; 4th, the mediastins, the number of which varies; they are lost on the mediastinum; 5th, the intercostals or aortics, usually nine in number. They arise from the lateral portions of the aorta, then proceed immediately to the articulation of the ribs with the vertebræ, and there send off a twig which pene-

trates the vertebral canal ; they then continue along the ribs, dividing into two branches, one of which, the smallest, passes along their superior border ; and the other, which is, as it were, the continuation of the principal trunk, travels along their inferior border ; they ultimately anastomose with the internal mammary.

INFERIOR DESCENDING OR ABDOMINAL AORTA.

Situation.—In the abdominal cavity, along the vertebral column.

Extent.—From the diaphragm to the fourth lumbar vertebræ.

Direction.—Vertical.

Relations.—Posteriorly, it is supported on the bodies of the lumbar vertebræ ; in front, it corresponds to the liver, stomach, pancreas, duodenum, jejunum and ileum ; the inferior vena cava lies along its right side.

Divisions.—Inferior phrenics, celiac trunk, superior mesenteric, capsular, renal, spermatic, inferior mesenteric, lumbar and middle sacral, all of which require a particular description.

INFERIOR PHRENICS.

Situation.—In the abdominal cavity, below the diaphragm.

Extent.—From the aorta to the inferior surface of the diaphragm.

Direction.—Oblique from within outwards.

Divisions.—Each of the phrenics, after arriving at the diaphragm, divides into two branches, one of which is internal and the other external ; they pass on the diaphragm, and anastomose with each other.

CÆLIAC TRUNK.

Situation.—On a level with the last dorsal vertebra between the pillars of the diaphragm.

Extent.—It scarcely measures half an inch from its origin at the anterior and left portion of the aorta to its trifurcation.

Relations.—In front, it is concealed by the liver and stomach.

Divisions.—1st, the coronary or gastric, which proceeds, on the left, to the superior orifice of the stomach, sends a small branch to the esophagus, makes a bend to the right, traverses the lesser curvature of the stomach, ramifies on its two surfaces, and anastomoses with the pyloric, a branch of the hepatic; 2d, the hepatic, larger than the preceding, which travels, on the right, towards the liver, and sends off, at the inferior orifice of the stomach, the pyloric, and a little further on the right gastro-epiploic; it then places itself in front of the abdominal vena portæ and behind the hepatic duct, in dividing into two branches, which reach the transverse fissure of the liver; that which is on the left penetrates the lobe of the same side; the right branch furnishes the artery of the gall bladder, called cystic, and expends itself on the lobe of the same side; 3d, the splenic, which, in the adult, is the largest of the three: it proceeds from right to left, under the stomach, and reaches the spleen, after forming numerous flexuosities; it penetrates this viscus by four, five, or six large branches: towards the large extremity of the stomach, it furnishes several twigs which go to this organ, under the name of vasa brevia, and a little further on, the

left gastro-epiploic artery, destined, with that of the right side, to traverse the greater curvature of the stomach.

The gastric and two gastro-epiploic arteries send off, in their course, numerous twigs, which ramify on the two sides of the stomach, and form frequent anastomoses with each other.

THE SUPERIOR MESENTERIC.

Situation.—In the profound part of the epigastric region, almost immediately below the cæliac.

Extent.—From the aorta to the colon, jejunum and ileum.

Direction.—Oblique from above downwards, and from left to right, forming a great curvature, the convexity of which is to the left, and the concavity to the right.

Divisions.—Into three considerable branches, called right colics, which originate from its concavity, distinguished into superior, middle and inferior; each divides into two twigs, which, anastomosing with the neighboring twigs, form arches, whence are given off new branches, which again form new arches, giving birth to other twigs, which proceed towards the colon, on which they ramify; 3d, into fifteen or twenty branches which go off from its convexity, and which, after having formed different arches, finally terminate in the jejunum, ileum, and a portion of the duodenum.

INFERIOR MESENTERIC.

Situation.—In the hypogastric region, between the spermatics and primitive iliacs.

Extent.—From the inferior part of the aorta to the lower extremity of the rectum.

Direction.—Oblique from above downwards, and from

left to right, forming a curvature, the convexity of which is to the left and the concavity to the right.

Divisions.—1st, into three principal branches, called left colics, each of which divides into two large twigs, which anastomosing with each other, form arches, from which originate additional twigs, giving rise to other arches, the ramifications of which are lost in the tunics of the colon and rectum.

CAPSULAR ARTERIES.

Situation.—In the abdominal cavity, above the superior mesenteric.

Extent.—From the aorta to the glandulæ renales.

Direction.—Transverse.

Divisions.—Of middling size, their divisions are limited to a few twigs, which are sent to the neighboring parts; they there expend themselves on the glandulæ renales.

RENAL ARTERIES.

Situation.—On a level with the kidneys, below the capsular.

Extent.—From the aorta to the kidneys.

Direction.—Transverse.

Relations.—Posteriorly, with the vertebral column; in front, with the renal vein. The vena cava partly covers the right renal artery.

Divisions.—They do not give off any twigs, but proceed immediately to the kidneys, which they penetrate by two, three or four branches.

SPERMATICS.

Situation.—In the abdominal cavity, below the renal, and above the inferior mesenteric.

Extent.—From the anterior part of the aorta to the testicles.

Direction.—Slightly oblique from above downwards, and from within outwards.

Relations.—In their trajet, they are placed on the psoas muscle, in the abdominal cavity; and pass through the plexus, formed by the spermatic veins. After arriving at the ring, they traverse it, accompanied by the ureter, the spermatic vein and nerve; they there descend to the testicles, which they penetrate, by dividing into two fasciculi, one of which goes to the epididymis, and the other to the testicle.

MIDDLE SACRAL.

Situation.—On the anterior and middle portion of the sacrum.

Extent.—From the bifurcation of the aorta to the inferior part of the coccyx.

Direction.—Vertical.

Relations.—Posteriorly with the sacrum; in front, with the rectum.

Divisions.—There arise from the lateral parts of the middle sacral some small branches, one of which, more considerable than the others, forms the last lumbar; the others anastomose with the lateral sacral; it forms in addition, at its termination, species of arches which are lost on the coccyx. The aorta furnishes four lumbar arteries on each side, which arise from its lateral portions. After arriving at the root of the transverse apophyses of the vertebræ, they send off, posteriorly, a twig which expends itself on the muscles of the back, and sends a small branch to the vertebral canal; finally, they advance towards the integuments of the abdomen, on which they are expended.

THE ARTERIES WHICH ARISE FROM THE BIFURCATION
OF THE AORTA AS FAR AS THE CRURAL.

The arteries which arise from the bifurcation of the aorta, bear the name of primitive iliacs until their division into external and internal iliac. The first is the continuation of the primitive iliac, and marches in the same direction; the second plunges into the pelvis, and sends off a considerable number of branches; the most remarkable are: the ileo-lumbar, lateral sacral, obturator, posterior iliac and gluteal, ischiatic, internal pudic, middle hemorrhoidal, vesical, uterine and vaginal.

Anatomical Preparation.

Primitive and external iliac.—When we have arrived at the bifurcation of the aorta it is easy to follow its principal branches, as far as the passage of the external iliac under the crural arch. The precaution which was taken of removing the intestinal paquet will very much favor this preparation. They are covered in part by cellular tissue, which must be removed, as well as every thing else, which could possibly obstruct the proper exposition of these arteries. At the junction of the sacrum with the haunch bones, the primitive iliac gives off a considerable branch, called the hypogastric or internal iliac, to which we shall return after a few moments. In continuing to expose and isolate the external iliac, we shall arrive at the crural arch; at this place, and before passing under the arch, the external iliac sends off two very remarkable branches, one of which, called epigastric, proceeds under the internal portion of the abdominal walls; and the other, known under the name of anterior iliac, passes outwards. These two arteries require to be prepared before proceeding with

the hypogastric and its branches. We should be particular to expose their origin properly, and then to follow them in apart of their extent. The student will remember that the epigastric anastomoses with the internal mammary; but a very important point in the examination of this artery, and which should not be neglected, is to have a clear idea of its relations with the inguinal ring and spermatic cord, in order that we may make a practical application of our knowledge in case of an operation for hernia.

Hypogastric and its branches.—This artery is said to be very difficult to prepare; to a certain extent this is true. The causes of this difficulty are owing to the great number of branches it furnishes, to the concealed situation of many of them, to the want of a point of support for the soft parts contained in the pelvis, and to the confusion of their different branches. I shall now endeavor to remove these inconveniences, at least in part.

It is essential to free the origin of the hypogastric from the cellular tissue, which conceals it, and likewise from the blood which escapes from the divided veins. Water and other liquids are sometimes effused in the bottom of the pelvis; they must be removed with a sponge, and every thing else that can at all interfere with the dissection. These arteries arise from the hypogastric, at the moment it plunges into the pelvis; one is the ilio-lumbar, which proceeds posteriorly and outwardly; the second, is the lateral sacral which passes to the sacrum; the third, is the obturator, which proceeds through the foramen of the same name. The ilio-lumbar is observed in the depression found between the last lumbar vertebræ and internal iliac fossa. It is concealed, especially at its origin, by a quantity of cellular tissue, which it will be necessary

to remove. The psoas muscle covers it in great part in its distributions; it should be dissected with care, and pushed to one side without entirely detaching it. The sacral or lateral sacral arteries are concealed by the rectum. The preparation of the middle sacral will have exposed a great part of these arteries, and their origin is nearly as high up as the preceding. The obturator arises from the anterior part of the hypogastric, and proceeds in the direction of the border of the pelvis, but somewhat lower down, in order to reach the obturator foramen. The nerve of the same name, which accompanies it, should be preserved. Beyond the obturator foramen, it loses itself in the muscles of the thigh; and as it would be necessary to sacrifice the external pudic in order to see its distribution, we had better reserve its study until we shall have finished with these arteries; it is the same with the internal pudic. When we have terminated the preparation of these three arteries, we should pass immediately to the small branches furnished by the hypogastric, and which proceed to the bladder in the male and female; and we should, moreover, occupy ourselves with the uterine and vaginal in the latter; but as it is always more or less difficult to carry the instruments to the bottom of the pelvis, and as the parts are extremely loose and without support, it will be proper to divide the pelvis, by separating, on the one hand, the body from one of the pubes, at an inch from the symphysis, in order to leave untouched the organs of generation, for the study of the internal pudic; and, on the other, that of the posterior symphysis, on the side opposite to the arteries which we are about to examine; then, if we follow the course of the hypogastric, we shall observe that it is divided into two principal branches, which proceed to the

posterior and inferior part of the pelvis. The most elevated of these two branches is the posterior iliac and gluteal; the other is the ischiatic. From this last arise the small branches of which I have spoken. But before leaving the pelvis, the ischiatic furnishes an artery, which it is important to understand—the internal pudic. It is essential that we prepare at once the branches furnished by the ischiatic, as it is necessary to cut them and remove the organs to which they are destined. The interior of the pelvis being thus emptied, it will be much easier to follow the course of those that remain. We should observe particularly the place of their exit from the pelvis. The pyramidal muscle, which serves as a guide, separates the gluteal, which is above, from the ischiatic which is below. Out of the pelvis, they can be seen only by turning over the subject, and carefully dissecting the gluteus maximus, which should be pushed over towards the anus, after having detached it from the great trochanter. Beneath the great gluteal muscle we remark the ischiatic; but we cannot perceive the posterior iliac until after having removed the middle gluteal muscle in the same manner. This being done, we should follow the distribution of these arteries, being careful to cut as few of the branches which they furnish as possible.

Internal pudic.—This should be reserved for the last, and its preparation requires considerable care and attention. It arises, as was before said, from the ischiatic, at the time this last leaves the pelvis. Like the ischiatic, it abandons the pelvis a little above the sacro-ischiatic ligament; but it soon re-enters the pelvis through the small sacro-ischiatic notch, in order to proceed between the tuberosity of the ischion and anus; it is here that it is important to recognise all its divisions. At this stage of his labors, I would advise the student to proceed to the careful

dissection of the muscles of the perineum and penis, and to pass on to this artery, between the ischion and anus, in order to follow it in its divisions, which go to the perineum, scrotum, penis, and to the environs of the organs of generation. But if the student is not particular to make the section of the bones of the pelvis, as was directed a moment since, he will necessarily destroy some interesting branches of this artery, of which he can form but an inexact idea.

Description.

PRIMITIVE ILIACS.

Situation.—At the inferior part of the abdomen.

Extent.—From the bifurcation of the aorta to the top of the sacro-iliac symphises.

Direction.—Oblique from above downwards, and from within outwards.

Relations.—Posteriorly, they are supported on the vertebral column, and repose on the veins of the same name; anteriorly, they correspond to the intestinal packet, and are crossed by the ureter at an acute angle.

Divisions.—Into external and internal iliacs.

EXTERNAL ILIAC.

Situation.—On the lateral parts of the pelvis.

Extent.—From the union of the sacrum with the haunch bones to the crural arch.

Direction.—Oblique from above downwards, and from within outwards.

Relations.—Within, it corresponds to the iliac vein; without, to the psoas muscle.

Divisions.—1st, Epigastric, which arises from its

internal part, near the crural arch, ascends behind the rectus muscle, on the internal side of the spermatic cord, and, after reaching the umbilicus, it anastomoses with the branches of the internal mammary. 2d, Anterior iliac (circumflexa ilii) which arises, externally, on a level with the epigastric, proceeds towards the anterior spine of the ileum, and divides into two branches, which are lost in the muscles of the abdomen.

INTERNAL ILIAC OR HYPOGASTRIC.

Situation.—In the cavity of the pelvis, in front of the sacro-iliac symphysis.

Extent.—From the union of the sacrum with the haunch bones to the distance of two or three fingers' breadth within the interior of the pelvis.

Direction.—Slightly oblique from above downwards, and from behind forwards.

Division.—1st, Ileo-lumbar, which arises very near the origin of the hypogastric, proceeds outwards and upwards, concealed by the psoas muscle, and soon divides into two branches, the one ascending and the other transverse, which are lost in the adjoining parts.

2d, Lateral sacral, which travels on the anterior surface of the sacrum in front of the sacral nerves; gives off twigs which, on the one hand, penetrate the vertebral canal by the sacral foramina, and on the other, anastomose frequently with those of the middle sacral.

3d, Obturator, which proceeds along and below the border of the pelvis, accompanied by the obturator nerve, as far as the foramen of the same name, through which it passes at its superior part, and divides into two branches, the twigs of which are lost in the superior portion of the muscles of the thigh.

4th, Vesical, the origin of which presents considerable variety, but which most generally arises from the hypogastric, and proceeds to the inferior part of the bladder, sending off twigs to the vesiculæ seminales, prostate, vas deferens, and ureter.

5th, In the female, the hypogastric furnishes, in addition, the uterine and vaginal; the first travels on the lateral and inferior portions of the uterus, and expends itself on this organ; the second is placed likewise on the lateral parts of the vagina, advances as far as its anterior portion, and is lost in its cellular tissue.

These different arteries offer so many varieties, both as regards their origin and distributions, that we can scarcely find two subjects in which they present the same results.

After having furnished these arteries, the hypogastric divides into three principal branches, viz: the posterior iliac, ischiatic, and internal pudic.

POSTERIOR ILIAC.

Situation.—At the posterior and inferior part of the pelvis, and superior and posterior of the thigh.

Extent.—From the cavity of the pelvis to the superior region, of the buttock, passing through the ischiatic notch above the pyramidal muscle.

Direction.—Oblique from within outwards, and from below upwards.

Relations.—In the pelvis, it is situated between the last lumbar and first sacral pairs; out of the pelvis, its divisions pass between the great and middle glutei muscles.

Divisions.—Into two principal branches, destined for the glutei muscles, and some of those on the posterior part of the trunk.

ISCHIATIC.

Situation.—At the inferior part of the pelvic cavity and posterior of the thigh.

Extent.—From the pelvic cavity to the posterior part of the thigh, passing through the ischiatic notch, below the pyramidal muscle.

Relations.—It is accompanied by the great sciatic nerve in the most considerable portion of its extent.

Division.—Into a number of twigs, which lose themselves in the muscles of the buttock, and in those of the posterior and superior part of the thigh; one of these is more remarkable than the others, and always accompanies the sciatic nerve.

INTERNAL PUDIC.

Situation.—At the inferior part of the pelvic cavity and in the region of the perineum.

Extent.—From the pelvic cavity to the perineum and organs of generation.

Relations.—In the pelvis, it is situated in front of the sciatic plexus and pyramidal muscle; after leaving the pelvis, it passes through the small sciatic notch, proceeds in the space comprised between the tuberosity of the ischion and anus, and expends itself on the adjoining parts.

Division.—In its trajet to the transverse muscle, it sends off a great number of twigs, which go to the bladder, ureter, vesiculæ seminales, glutei, gemelli, &c.; it afterwards divides into two branches, one inferior and the other superior; the first is called the artery of the perineum, the second that of the penis.

ARTERIES OF THE INFERIOR EXTREMITIES.

These arteries are: the crural, popliteal, posterior tibial, peroneal, anterior tibial, and plantar.

Anatomical Preparation.

Crural artery.—At its passage under the crural arch, the external iliac changes its name in order to assume that of crural, which it preserves as far as the ham, where it takes that of popliteal. The crural artery, properly so called, is not very difficult to prepare; in general its situation is very superficial, at least at its superior part, and this circumstance renders its dissection and examination the more easy. In order to see it we should make an incision on the integuments of the thigh, which, from their superior and middle part, should be directed obliquely to their inferior and posterior portion, as far as the hollow of the ham; we should then separate the flaps in a contrary sense, and the crural artery will be found almost naked, placed at the internal side of the sartorius muscle, which it abandons at the three inferior fourths of the thigh, in order to pass through the third adductor, and then show itself, in the ham, under the name of popliteal. In its course, it sends off several branches, the most considerable of which is the profunda or small crural, which gives origin to two circumflex arteries; the other branches, less remarkable, arise from the most elevated portion of the crural, and are known under the name of external pudic. I cannot recommend too strongly the greatest attention in the preparation of all these arteries, for their knowledge is very important in the treatment of certain diseases of the extremities, and especially in some operations, in which the life of the patient is often compromised.

The best and most certain mode of effecting a proper preparation of the arteries of the thigh, is to proceed at first with the dissection of the muscles of this part, taking care not to injure any of the branches which may be met

with in the course of this operation. The first proceed transversely inwards and outwards to the superior part of the thigh; those of the internal part are less extensive, but they are situated more profoundly than the external, one of which, especially, proceeds along the thigh, passing under the external parts of the femur, in order to anastomose with the arteries of the articulation of the knee.

The small crural or profunda arises from the posterior part of the great crural, a little above the small trochanter, between the adductors and rectus internus. This circumstance will explain the necessity of a preliminary preparation of these muscles in order to have a good view of the artery. This preparation should even be sufficiently minute to afford us an opportunity of following three or four branches of this artery, which lose themselves, under the name of perforating, in the adductors, and particularly in the third. At its superior part, the profunda sends off the circumflex branches, which are in the same relation to the thigh, that those of the same name are to the arm; but if we do not take the precaution of removing from the muscles of the thigh the abundant fat, which envelopes them on all sides, if we do not completely isolate these muscles, we will in vain endeavor to prepare the divisions of the crural artery.

Popliteal artery.—Concealed profoundly in the hollow of the ham, this artery is enveloped by a quantity of fatty matter, and demands considerable patience in its dissection. We should lay open the integuments in a great extent, remove the abundant cellular tissue and fat, dissect the muscles and cut them at four fingers' breadth above the articulation; we should turn downwards, in separating them cautiously, the inferior portions of the cut muscles; in this way,

we will arrive with more facility at the popliteal artery, which is found, as it were, attached to the nerve and vein of the same name. These different objects should be isolated but not cut: we should separate them in order to follow with more advantage the small branches given off from the lateral portions of the popliteal, called articular. The inferior articulars cannot be seen properly, until after having dissected and removed a part of the gemelli, in the interval of which these arteries are situated.

Arteries of the leg and foot.—The dissection of the gemelli and other muscles of the posterior part of the leg will permit us to pursue the continuation of the popliteal, as far as its division into posterior tibial and peroneal; the popliteal sends off from its anterior portion, an artery which pierces the inter-osseous ligament, in order to proceed to the anterior portion of the leg, under the name of anterior tibial; its ulterior preparation should be abandoned, in order to pass to those of the posterior part. These require that we remove the superficial layer of muscles in order to get a good view of them, for they travel, as it were, on the tibia and fibula; the branches which they furnish, although numerous, not having received any particular names, do not merit a special preparation; one only is worthy of attention, it is that given off by the tibial for the tibia itself, which penetrates through the nutritious foramen of this bone.

After having traced these arteries to the inferior part of the leg, we should abandon them there, and return to the anterior tibial, a division of the popliteal, the origin of which takes place at the posterior part of the leg, situated more profoundly than the two preceding. It dips down immediately between the two bones of the leg, above the

inter-osseous ligament, which it pierces in order to show itself at the anterior portion, between the tibialis anterior, and extensor communis digitorum pedis. The preparation and study of this artery require, like the preceding, that we proceed at first to the dissection of the muscles. In proportion as it passes downwards, this artery becomes more and more superficial, and reaches in this way the dorsum of the foot; we should then return to the plantars, the termination and divisions of the posterior tibial.

In order to diminish the difficulties attending the preparation of the plantars, we may disarticulate the foot, and preserve for their examination, this portion only of the inferior extremities. It will be conceived that, before doing this, we must have achieved the examination of the arteries of the leg. The common trunk of the two plantars must be looked for under the arch of the calcaneum; but at this part are likewise found the tendons of several muscles, also nerves, and a quantity of dense cellular tissue, and consequently the difficulties will be increased. We should isolate the arteries as carefully as possible, and once exposed, we should follow their course and divisions, cutting every thing that opposes their preparation, preserving merely their smallest twigs, for each one of them demands particular attention.

Description.

CRURAL.

Situation.—On the anterior and internal portion of the thigh.

Extent.—From the crural arch to the inferior and posterior part of the femur, four fingers' breadth from the articulation.

Direction.—Oblique from above downwards, and from before backwards, following the trajet of the sartorius.

Relations.—In proceeding from above downwards, this artery is covered, in front, by the integuments, the sartorius, and by the aponeurosis of the fascialata: posteriorly, it corresponds, from above downwards to the united tendons of the psoas and iliacus, to the pectineus and first adductor: outwardly, it corresponds to the crural nerve, sartorius and vastus internus: within, it corresponds to the crural vein, pectineus and first adductor.

Divisions.—1st, External pudics, two in number, which arise from the internal part of the crural artery, proceed, within, the one more superficially, the other more profoundly. The twigs which these two branches furnish, pass to the pubes, and scrotum, and anastomose with the branches of the internal pudic; in addition, there sometimes arises from the crural a very small artery, under the name of integumental artery, which expends itself outwardly on these parts; 2d, Profunda, which merits a particular description.

PROFUNDA OR SMALL CRURAL.

Situation.—On the internal and posterior part of the thigh.

Extent.—From the posterior part of the crural, near the small trochanter, to the inferior portion of the femur, passing at this place, across the third adductor.

Direction.—Oblique from above downwards, and from within backwards.

Relations.—In its course, it is almost always placed between the adductors and vastus internus.

Divisions.—1st, The circumflex, distinguished into external and internal; the first, more considerable, proceeds

outwardly, and furnishes two branches, one of which, transverse, turns around the femur; it gives off twigs to the articulation and some of the adjoining muscles, and anastomoses with the internal circumflex. The second branch passes outwards and downwards, as far as the articulation, in order to anastomose with the articulars. The internal circumflex, larger than the preceding, likewise turns around the femur, in order to get to the external circumflex and anastomose with it. In its trajet, it sends off two branches, which are lost in the neighboring parts, principally in the muscles of the posterior and superior parts of the thigh. 2d, The perforating, which are three or four in number: these arteries, situated very profoundly, are destined for the muscles of the whole posterior part of the thigh; and they pierce the adductors in a very remarkable manner. It is the second perforating artery which furnishes a twig that penetrates the superior nutritious foramen in the femur: the inferior foramen receives the small artery that traverses it from the termination of the profunda.

POPLITEAL.

Situation.—In the hollow of the ham.

Extent.—From the inferior part of the thigh, to the superior portion of the leg.

Direction.—Nearly vertical.

Relations.—In front, it is supported on the inferior fourth of the femur, on the articulation of the knee, and lower down on the popliteus: posteriorly, it is covered at first by the semi-membranosus, afterwards by fatty cellular tissue, and, on the leg, by the gemelli and soleus;

inwardly and outwardly, it corresponds to the condyles of the femur and tibia; and, in addition, its external side is bordered by the vein and nerve of the same name.

Divisions.—The articulares, five in number, of which three are superior and two inferior; the first arise from the popliteal, almost immediately after the passage of the crural through the third adductor. These arteries encircle the articulation, supply the adjoining parts, and anastomose with the profunda and external circumflex, as well as with the inferior articulares. Of the three superior articular arteries, one differs in its situation and distribution: it occupies the middle and posterior part of the articulation of the knee, and supplies, in great part, this articulation.

The inferior articulares arise at two or three fingers breadth from the preceding, proceed obliquely downwards, in encircling the articulation, and act in the same way as the superior articulares, with which they anastomose in a very remarkable manner.

ANTERIOR TIBIAL.

Situation.—On the anterior part of the leg.

Extent.—From the superior union of the two bones of the leg to the superior part of the foot.

Direction.—Slightly oblique from above downwards, and from without inwards.

Relations.—It pierces, at the posterior part of the leg, the tibialis posterior and inter-osseous ligament; along the leg, it is constantly between the tibialis anterior which is within, and the peroneous anterior which is without; posteriorly, it reposes on the inter-osseous ligament, and, below, on the tibia; in front, it is covered not only by the preceding muscles, but likewise by the extensor pollicis pedis, and extensor communis digitorum pedis.

Divisions.—A great number of twigs, destined for the muscles, arise from the anterior tibial in its course, as far as the lower portion of the leg, where it gives off two, one within, and the other without, which we may denominate the malleolar arteries; they anastomose with the posterior tibial and peroneal.

The anterior tibial continues on the foot, under the name of pedal artery.

P E D A L A R T E R Y .

Situation.—On the superior part of the foot.

Extent.—From the annular ligament of the foot, to the first metatarsal bone.

Direction.—Horizontal from behind forwards.

Relations.—On the one hand, it is covered by the integuments, by the tendons of the extensor communis digitorum, and by the pedal arteries; on the other, it reposes on the bones of the tarsus.

Divisions.—1st, Near its origin, it gives off twigs more or less considerable, which proceed inwards and outwards, and are distributed to the neighboring parts. 2d, Somewhat outwards, originates the artery of the tarsus and that of the metatarsus; the first, nearer the origin of the pedal, proceeds on the external side of the foot, and anastomoses with the external plantar, after having furnished a great number of twigs to the adjoining parts; the second, which arises more in front than the artery of the tarsus, forms a curve, the convexity of which, turned forwards, gives rise to branches which pass between the metatarsal bones, and which may be called interosseal arteries; the rest of this artery goes to the neighboring parts; 3d, having arrived at the anterior extremity of the first metatarsal bone, it dips under the foot, and anastomoses with the internal plantar artery.

PERONEAL ARTERY.

Situation.—On the posterior and external part of the leg.

Extent.—From the end of the popliteal to the external malleolus.

Direction.—Slightly oblique from above downwards, and from within outwards.

Relations.—Posteriorly, it is covered by the soleus and long flexor of the great toe: in front, it reposes above, on the tibialis posterior, and below, on the inter-osseous ligament.

Divisions.—In its course, as far as the inferior part of the leg, it merely gives off branches destined for the muscles; near the malleolus, it divides into two branches, one for the external side of the foot, and the other, which pierces the inter-osseous ligament, expands itself on the superior portion of the foot.

POSTERIOR TIBIAL ARTERY.

Situation.—On the posterior and internal part of the leg.

Extent.—From the end of the popliteal to the arch of the calcaneum.

Direction.—Oblique from above downwards, and from without inwards.

Relations.—Posteriorly, it is covered above by the gemelli and soleus; below, by the integuments; in front, it is supported on the tibialis anterior, the flexor longus communis digitorum pedis, and on the tibia; its external side is bordered by the external popliteal sciatic nerve.

Divisions.—Considerable twigs, which are distributed to all the muscles on the posterior part of the leg; among them, one penetrates the tibia through the nutritious fora-

men. Arrived under the arch of the calcaneum, the tibial divides into the plantars, one of which is internal and the other external.

INTERNAL PLANTAR.

Situation.—At the inferior part, and on the internal side of the foot.

Extent.—From the division of the tibial, to the neighborhood of the great toe.

Relations.—It is, in great part, covered by the adductor muscle of the great toe, and the short common flexor of the toes.

Divisions.—The branches it furnishes are lost in the adjoining muscles, plantar aponeurosis, and periosteum; it terminates by anastomosing with the collaterals of the great toe.

EXTERNAL PLANTAR ARTERY.

Situation.—At the inferior and external part of the foot.

Extent.—From the division of the tibial, to the posterior extremity of the fifth metatarsal bone.

Direction.—Oblique from behind forwards, and from within outwards.

Relations.—In its oblique course, it is covered, on the one hand, by the short flexor of the toes, and, on the other, it is supported on the abductors of the great and small toe.

Divisions.—Several branches proceed to the superficial muscles on the sole of the foot; but, after arriving at the fifth metatarsal bone, it dips down under the bottom of the foot, proceeds from without inwards, in order to anastomose with the pedal, and form the plantar arch, from which

arise numerous twigs which pass forwards, backwards, upwards, and downwards. The anterior branches are the most remarkable, and they are destined to form the collaterals of the toes.

PULMONARY ARTERY.

Situation.—In the chest, at the height of the third dorsal vertebra.

Extent.—From the superior and left portion of the right ventricle to the lungs.

Relations and divisions.—It reposes at first on the aorta, but soon becomes posterior to it; and after proceeding about two inches, it divides into two branches, one on the right, larger and shorter, for the right lung, and the other on the left, smaller and longer, for the left lung. These two arteries penetrate these organs by an indeterminate number of branches, which ramify in their tissue.

VEINS.

The exposition of the veins appertains to Angiology, and their distribution presents the same considerations as those of the arteries. Like these last, the veins offer trunks, which furnish branches, whence arise twigs and ramifications, the ultimate divisions of which escape the eye of the anatomist. The veins do not present as much interest as the arteries; the slowness of the circulation of the fluid which traverses them, the nature of this fluid, the uncertainty of their relations and divisions, the slight influence they exert over the entire functions of the economy, will explain the indifférence with which they inspire us, and the little inducement which students have to study them.

We must, however, except the system of the vena portæ, which calls for our serious attention, and presents the most instructive as well as interesting details. I shall, therefore, limit myself to indicate, for the veins, the most general preparation, and their description will occupy but little space.

The manner of injecting them differs from that of the arteries; we must not proceed with this operation by the large trunks, but we should, on the contrary, commence with the last ramifications of the two venæ cavæ, and make a separate injection for both. The valves with which the veins are supplied, the use of which is to facilitate the flow of blood to the heart, in opposing its return to the extremities, will explain the reason of this difference. It is on the back of the hand that we should inject the veins of the upper extremities; for this purpose, we must employ a tube, the calibre of which should be proportioned to the size of the vein in which it is introduced. In this way, it is true, the jugular veins and those of the face will be swelled with great difficulty by the injection; but they scarcely need it. The large size of the first, the origin of which corresponds with the sinus of the brain, and the superficial situation of the second, will, to a certain extent, dispense with the necessity of injecting them. Such, however, is not the case as regards the abdominal extremities, and the whole inferior venæ cavæ.

The injection, pushed in sufficient quantity into one of the veins of the foot, will fill all the divisions of this vein. Those of the vena portæ are difficult to inject, but they do not require it; we may follow their divisions without this aid, unless we should wish to pursue them in their distribution in the liver: for, then, it would be indispensable to

inject the portion of this vein which proceeds to this organ. In the private amphitheatres the veins are very rarely injected. It is true that a knowledge of the arteries will greatly facilitate that of the veins, which almost always accompany these last in their distribution.

Jankius is not the only one, as is pretended, who has succeeded in passing the injection of the arteries into the veins. Chance has more than once effected this for other anatomists. One of my ancient colleagues in the Marine hospital, Doctor Brunel, the same who contrived an apparatus for fractures of the limbs, since made perfect by Professor Boyer, has frequently shown me upper extremities, the arteries and veins of which had been injected by the same coup de piston, and which presented absolutely the same results which have been since obtained by Jankius.

The blood returns to the heart by two principal veins, which are the superior or ascending vena cava, and the inferior or descending vena cava. The first carries to the heart the blood from the head, neck, and superior extremities; the second brings it from the inferior extremities and some of the organs of the bas-ventre. The veins of the other viscera of this cavity unite in one common trunk, called vena portæ, which enters the liver, and is entirely expended in it.

The veins of the chest empty, in great part, into one, sometimes into two large trunks, isolated and distinct, which bear the name of azygos veins.

SUPERIOR VENA CAVA.

Anatomical Preparation.

The superior portion of the venous system is in part already known, since the student understands the sinuses of

the brain, which constitute, as it were, its origin. The internal jugular vein, which is a continuation of them, and the external jugular, a common rendezvous for the veins of the face, are very voluminous, and we may follow them to their junction nearly on a level with the clavicle. It is essential to open the chest and separate the clavicle, in order to observe these veins, thus united, proceed to the heart, and receive, before arriving there, the subclavians. The disposition is somewhat different on the right and left sides. As it is on the right side that the auricle is situated, into which the two cavæ empty, it follows that the jugular and subclavian of the left side have a greater distance to go in order to arrive at the vena cava. If the veins are injected, this will be readily perceived; in the contrary case, we must proceed cautiously for fear of opening one of the veins, for the blood will run in abundance; and then no matter what care may be taken to remove it, it will always interfere with the dissection. Moreover, the veins will be more or less effaced, and this will render their study the more disagreeable.

The veins of the arm, those at least which it is important to understand, are superficial, and we may pursue them in either direction. They are two in number, the cephalic and basilic, the multiplied divisions of which have not received any particular names, except at the fold of the arm, where each of them gives off a second; this makes four principal veins for this part, which bear the names of cephalic, median, basilic, and cubital, proceeding from without inwards. When we have arrived at the hollow of the axilla, it will require somewhat more attention to disengage the axillary vein from the artery and brachial plexus; and without attempting to dissect the

branches of the axillary, we should pass immediately to the subclavian in order to terminate by the vena cava.

For the inferior extremities, we must in the first place occupy ourselves with the preparation of the great vein, which, from the internal malleolus, proceeds along the leg and thigh, in order to empty, under the name of the great saphena, into the crural vein; we should next pass to the study of this latter, which follows absolutely the course and distributions of the artery of the same name. The small saphena, placed on the external side of the leg, loses itself in the popliteal vein, which is itself the continuation of the crural.

But in order to study the inferior vena cava, we must have previously examined and removed the vena portæ. We should, therefore, proceed to the study of this last, the preparation of which consists particularly in exposing the common trunk of the branches, which form its origin, and of those which are distributed in the liver. This trunk will be found in the fasciculi of the vessels of the liver, situated a little posteriorly and to the right. Its volume and bluish color will not permit us to mistake it. This great trunk will have been frequently met with during the examination of the ductus choledochus and hepatic artery. We may afterwards pursue the branches, which come from the abdominal viscera, and those which are distributed in the liver. If we have the time and means, we may inject the trunk of the vena portæ, push the injection to the liver, the artery and duct of which should be filled with materials of a different color; this will give us the advantage of following, in the interior of this viscus, the course of its different vessels. But this operation is long and demands considerable care; the student alone cannot undertake it.

When the vena portæ and its principal divisions are known, it will be necessary to remove the intestinal packet with the usual precautions, but, in addition, it is indispensable not to touch the vena cava, which is placed on the vertebral column, and to the right. The crural, iliac, and hypogastric veins should not be interfered with; if they are opened, the blood will flow in abundance and soil the different parts. The liver and kidneys should remain in place. It may be observed that the preparation of the inferior vena cava in its whole extent requires very great attention and cleanliness. It is especially when it leaves the liver in order to enter the right auricle, in receiving the hepatic veins, that it is more difficult to expose it, for it is entirely concealed by this organ; but it will be readily discovered, by raising the liver, which we may even dispense with removing, in order to study this vein. Another vein yet remains to be seen; it is the azygos. Contained in the chest, it travels on the vertebral column by the side of the aorta, from which it is easily distinguished by its color; this vein, which arises from the inferior vena cava, nearly on a level with the first lumbar vertebra, loses itself in the same cava, near the heart, and forms, in this way, a long curvature, the convexity of which is to the left.

Description.

SUPERIOR OR ASCENDING VENA CAVA.

Situation.—In the right lateral and superior part of the chest.

Extent.—From the right auricle, to the cartilage of the first rib.

Direction.—Slightly oblique from below upwards, and from right to left.

Relations.—Contained at first in the pericardium, to the right of the aorta, it leaves it after having traversed a space of two inches, and soon divides into two large branches, which are the subclavians.

SUBCLAVIANS.

Situation.—In the superior part of the chest, inferior and lateral of the neck.

Extent.—From the termination of the vena cava to the superior surface of the first rib.

Direction.—It is different in the two subclavians; the right, shorter, ascends obliquely from within outwards, and from before backwards; the left, longer, proceeds transversely.

Relations.—The right is placed in front of the artery of the same name; the left passes in front of the aorta, subclavian arteries, and left carotid.

Divisions.—1st, Inferior thyroïdal, superior intercostal and vertebral, which follow the course and distribution of the arteries of the same name; 2d, Jugular, distinguished into external and internal; 3d, In addition, the left subclavian gives off the internal mammary. In fine, each subclavian vein terminates by giving birth to the axillary veins.

EXTERNAL JUGULAR.

Situation.—On the lateral parts of the neck.

Extent.—From the superior part of the subclavian to the parotid.

Directions.—Very slightly oblique from above downwards, and from behind forwards.

Relations.—Between the platysma myoides which is in front, and the sterno-mastoid muscle posteriorly.

Divisions.—Into numerous branches, which are distributed to all parts of the face, under the names of posterior auricular, internal maxillary, temporal, frontal, superciliary and palpebral.

INTERNAL JUGULAR.

Situation.—On the lateral and profound portions of the neck.

Extent.—From the subclavian to the posterior foramen lacerum.

Direction.—Slightly oblique from below upwards, and from before backwards.

Relations.—It is placed on the external side of the internal carotid, covered by the sterno-mastoid, sterno-hyoid, and sterno-thyroid muscles.

Divisions.—1st, Superior thyroïdal, lingual, pharyngeal, facial, occipital, internal maxillary and temporal, the course and divisions of which correspond with those of the arteries; 2d, After arriving at the posterior foramen lacerum, the internal jugular loses itself in the sinuses of the brain. It furnishes, in addition, the ophthalmic vein, the divisions and anastomoses of which with the tibial vein are similar to those of the artery of the same name.

AXILLARY VEIN.

Situation.—In the hollow of the axilla.

Extent.—From the environs of the scalenus muscle to the superior part of the arm.

Direction.—Oblique from before backwards, and from above downwards.

Relations.—Similar to those of the artery of the same name.

Divisions.—1st, The cephalic, which arises from the axillary, on a level with the head of the humerus, gains the interval between the deltoid and great pectoral muscles, descends along the arm, on the external side of the biceps, gives off, at the fold of the arm, the median cephalic, and continues to travel along the external part of the fore-arm, in order to lose itself on the back of the hand; 2d, basilic, which arises from the axillary, like the preceding, reaches the fold of the arm, gives off the median basilic, and divides into two principal divisions, which descend along the internal part of the fore-arm, in order to expend themselves on the back of the hand; 3d, In addition, the axillary furnishes the veins which accompany the brachial artery, as well as the veins of the radial and cubital arteries.

INFERIOR OR ABDOMINAL VENA CAVA.

Situation.—In the thoracic and abdominal cavities.

Extent.—From the right auricle to the fourth or fifth lumbar vertebra.

Direction.—Parallel to the vertebral column.

Relations.—On leaving the pericardium, it traverses the diaphragm, places itself behind the liver, which embraces it on all sides, and accompanies the aorta in the rest of its extent, placed at its external side; it is covered by the mass of intestines in the cavity of the abdomen.

Divisions.—1st, Inferior diaphragmatics or phrenics, the distributions of which follow those of the arteries; 2d, Hepatics, three or four in number, distinguished into right, larger, and left, smaller; they penetrate the liver, and lose themselves in its substance; 3d, Renal, which ramify in the kidneys; the right is the shorter, and passes

on the artery of the same name; the left is longer, and proceeds on the aorta; 4th, Capsular, the left of which arises from the renal vein of the same side; 5th, Spermatics, which arise, the right from the vena cava, the left from the renal vein; they descend on the spsoas muscle, and form, in this place, a net-work, called the pampiniforme plexus; they traverse the inguinal canal, and proceed to the testicles; 6th, Lumbar and middle sacral, which do not present any thing particular.

PRIMITIVE ILIAC.

Situation.—In the lower part of the abdominal cavity.

Extent.—From the bifurcation of the vena cava to the union of the sacrum with the haunch bones.

Divisions.—1st, Hypogastric, the divisions of which are similar, as to the number and course, to the arteries whose name they bear. The vesical veins form, in addition, a plexus on the inferior and posterior parts of the bladder, from which pass off branches for the organs of generation; 2d, External iliac, from which proceed the epigastric and anterior iliac or circumflex.

CRURAL VEIN.

Situation.—On the anterior and internal part of the thigh.

Extent.—From the ligament of *Fallopian*, to the hollow of the ham, where it takes the name of popliteal.

Direction and relations.—Similar to those of the crural artery.

Divisions.—Great saphena, which arises from the internal part of the crural, descends under the skin parallel to the sartorius muscle, passes behind the internal condyle

of the femur, and proceeds on the leg; it gets in front of the internal malleolus and loses itself on the foot; 2d, The crural vein, after arriving at the fold of the ham, takes the name of popliteal, places itself on the external side of the artery, and, an inch below, furnishes the anterior tibial, and then divides into the posterior tibial and fibular, the distributions of which correspond with the arteries of the same name. In addition, the popliteal gives off the small saphena, which descends under the skin along the external part of the leg, passes in front of the external malleolus, and loses itself on the back of the foot.

VENA PORTÆ.

This great vein, which forms a particular system of circulation, has its roots from most of the abdominal viscera, and is distributed in the liver. The common trunk of all these veins occupies the interval between the liver and pancreas. Its size is considerable, and its direction, on leaving the liver, is oblique from above downwards, and from right to left. The branches it sends to the liver are the hepatic portal veins, the number and course of which correspond with the arteries. The branches or roots which form it are, the superior mesenteric, gastric, splenic, and inferior mesenteric, as also some other small branches, which come from the duodenum and pancreas.

SUPERIOR MESENTERIC.

Situation.—This vein arises from the ventral vena portæ, of which it appears to be the continuation; situated at first behind the pancreas, it passes in front of the transverse portion of the duodenum, and soon meets with the

superior mesenteric artery, the direction and distributions of which it follows.

Divisions.—1st, Right gastro-epiploic, which arises from its right side, supplies the pancreas and duodenum, and expends itself on the great curvature of the stomach, in anastomosing with the left gastro-epiploic; 2d, Three right colic veins which go to the small intestines, and comport, in their distributions, like the arteries of the same name; 3d, Several branches which arise from its left side, and which are destined for the small intestines.

GASTRIC.

Situation.—It arises from the ventral vena portæ, near the pancreas, marches at first along the superior border of this gland, and thence reaches the cardiac or esophageal orifice of the stomach, on which it expends itself.

Divisions.—1st, Twigs, destined for the inferior part of the esophagus; 2d, The trunk continues along the small curvature of the stomach, on the two surfaces of which the gastric vein ramifies, and anastomoses with the right and left gastro-epiploics.

The duodenal vein likewise arises from the ventral vena portæ, near the gastric, and loses itself in the duodenum and right portion of the pancreas.

SPLENIC VEIN.

Situation.—Smaller than the mesenteric, the splenic vein, situated behind the pancreas, marches in a flexuous manner from right to left, parallel to this gland, and is accompanied by the artery of the same name; it loses itself in the spleen.

Divisions.—1st, Inferior mesenteric, of which we shall speak hereafter. 2d, Left gastric or small coronary, destined for the same parts as the great coronary. 3d, Left gastro-epiploic, which travels along the great curvature of the stomach, and anastomoses with the right gastro-epiploic. 4th, Several small branches, which go to the large extremity of the stomach, under the name of vasa brevia.

INFERIOR MESENTERIC.

Situation.—This vein travels from the commencement of the splenic, along the left of the aorta, to the posterior part of the rectum, as far down as the anus.

Divisions.—1st, From its left side, it gives off three colics, distinguished into superior, middle and inferior, which go to the colon, and follow the course of the arteries of the same name. 2d, Several branches for the S of the colon and rectum, which they accompany as far as its inferior extremity.

SOME OTHER VEINS, THE DESCRIPTION OF WHICH IS NOT FOUND IN THE HISTORY OF THE TWO VENÆ CAVÆ AND VENA PORTÆ.

Azygos.—It arises from the superior part of the vena cava, descends along the vertebral column, by the side of the aorta, passes through the diaphragm, and, not far from this, loses itself, sometimes in the inferior vena cava, sometimes in one of the renal veins. In its course, it supplies the bronchiæ, mediastinum, and aorta; in addition, it furnishes the semi-azygos, the course of which is parallel to its own; it usually gives off the intercostals, and loses itself, like the first, sometimes in the vena cava, and sometimes in the left renal vein.

Pulmonary veins.—They are four in number, two on the right and two on the left; from the left auricle they pass to the lungs, where they ramify. These veins carry from the lungs to the heart vermilion blood, which, from its properties, has all the characters of arterial blood.

Veins of the heart.—The principal vein of this organ is called coronary, it traverses the heart in nearly its whole extent, and anastomoses frequently with some other smaller branches of the same organ.

NEUROLOGY.

Preliminary Exposition.

Neurology is that part of anatomy which treats of the nerves. Among these, some appertain to the organs of motion and sensation; the others are destined principally for the viscera of the neck, chest and abdomen. Both one and the other differ in their origin and structure; the first part from the brain and medulla oblongata, and exhibit themselves under the form of whitish cords, of a firm and dense consistence; in general they diminish in size in proportion as the branches recede from the trunks, and the twigs from the branches. Organs of motion and sensation, they proceed to the extremities where their divisions are very numerous; and, in general, to the whole external surface of the body; these are what *Bichât* has called the nerves of animal life.

The second, on the contrary, enclosed in the great cavities of the chest and abdomen, and profound part of the neck, have no fixed or determinate origin; they appear to originate from renflemens of middling size, called ganglions, and to which has been given the name of small brains;

they are of a reddish color, and soft consistence. Destined for the viscera of the chest, abdomen and neck, they appear to have functions distinct and independent of the first; *Bichât* calls them the nerves of organic life. These ingenious distinctions, on which modern physiology has drawn so largely, are far from reposing on solid foundations. Rigid anatomy, which scorns the false éclat of a vivid imagination, and which rejects the systems fostered by this latter, respects neither the hypotheses, nor the brilliant applications which have flown from it. Nature amuses herself with physiological arrangements, and in her most evident, as well as in her most obscure operations, the real object escapes our intelligence. What appears to us complicated and incomprehensible, is perfectly plain to nature. It is with the scalpel in hand that anatomy can demonstrate that the nerves of the brain and those of the ganglions become confounded with each other, cross their twigs, give mutual birth to each other, and go indifferently to the same parts. The eighth pair of nerves (pneumo-gastric) is an example of this for the nerves of the brain; and for the nerves of the ganglions we have an instance in the numerous connections of the branches of the great sympathetic with that of the cervical, dorsal, and sacral nerves. Let it not, therefore, be said that anatomy is a dry nomenclature of words and facts; a profound knowledge of this science, is, on the contrary, the most certain guide which the physiologist, physician and surgeon can employ in order to avoid errors.

Particular dissection of Neurology.

It is very wise to terminate our anatomical labors with Neurology. It cannot be denied that its preparation is

very difficult, and requires great care and address. But the skill which the student will have acquired at this period of his anatomical studies will furnish him with the means of easily surmounting the obstacles presented by neurology. Thus, the student, who has prosecuted with success the first divisions of anatomy, should not hesitate to undertake the dissection of Neurology. However, it must be admitted that he will have to arm himself with great courage and patience. Nothing is more difficult to prepare than the nerves of the head: the cervical, cardiac, and pulmonary plexuses do not present less difficulty. The nerves of the extremities, on the contrary, are the more easy to dissect as the parts which they traverse are better known and more distinct in their distributions.

Every thing among us contributes to remove, or at least to diminish the obstacles—the excellence of the instruments, the elegance of their form, appropriate to the kind of work for which they are intended. Glasses, in order to magnify certain nerves or ganglions, which the eye alone can perceive but imperfectly; a gouge, mallet, hammer, hooks, sponges, &c. should be continually in action, in order to second the efforts of the student. An advantage enjoyed in the dissection of Neurology is that the cords composing it offer a certain resistance, and we may pull upon and raise them without interfering with the precision of their study. Their color, constantly white, likewise furnishes us with a means of pursuing them with certainty.

But, we repeat, without a precise knowledge of the osteology of the head, we will endeavor in vain to obtain an accurate idea of the nerves of this part. Without this knowledge, we shall consume considerable time in exposing objects, which would have been found without

difficulty, if a profound study of the bones of the head had preceded that of the other parts of anatomy. It is said that the angeology and neurology of the head are difficult, without recollecting that these difficulties are most generally owing to negligence in studying the bones of the cranium.

I will now terminate the precepts respecting the dissection of Neurology with the two following passages from the essay of M. Duméril :

“Thus, for example, in order to render the vessels of the bones more visible, we may plunge these latter into a weak mineral acid, which, by completely dissolving the earthy salt, will leave the vessels in position and sensible, through the fibrous tissue of the bones, changed in their nature and almost gelatinous. On drying this mucous body, it will acquire a transparency which will exhibit the distribution of the vessels by which they are penetrated.”

“We may plunge the piece into a weak solution of the carbonate of potash, or into soap water, in order to neutralize the acid with which the bone is impregnated, for it would injure the steel instruments, and blacken their surface. We will then pursue the nervous ramifications with great facility.”

It is especially for Neurology that it is important to select a subject the most fit for the examination of this part of anatomy. In general, children, young people and females are more proper for the preparation of Neurology, than men and old persons of either sex. The nerves, *cæteribus paribus*, are larger and more easy to expose in the former than in the latter individuals. But, no matter what may be the age or sex of the subject, it should be remembered that such as are infiltrated, *maigre*, and

have a white skin, are best suited for the preparation of Neurology. I have likewise remarked that a commencement of putrefaction, far from interfering with the preparation of the nerves, will, on the contrary, favor it. The nerves, like the tendons, arteries, &c. resist the effects of putrefaction; and whilst the cellular tissue, muscles, and most of the viscera are in part destroyed by putrid decomposition, the nerves continue in a state of integrity. The anatomist, however, should adopt such precautions as are required by prudence and the preservation of his health.

NERVES IN PARTICULAR.

The anatomical order, followed by almost all the professors of anatomy, as well as in all the works treating of this science, require that we should occupy ourselves first with the nerves of the head and extremities, and terminate with those of the thoracic and abdominal cavities; we shall follow this course, but we have made slight changes, which the dissection of these parts renders indispensable.

NERVES OF THE BRAIN.

Anatomical Preparation.

The preparation of the nerves of the head should be divided, as it were, into three periods; in the first period, we should see the nerves in place, which may be done by raising the cerebral mass from before backwards, and cutting them as we proceed, at an equal distance from the brain and foramina of the cranium, through which they pass. The portion attached to the brain will serve as a guide to the anatomist when endeavoring to see their origin, this will constitute the second period; it is equally necessary to preserve the second portion in order that

they may be followed out of the cranium, and not be confounded with each other : this latter operation, the longest and most difficult, completes the preparation of the cerebral nerves, and constitutes the third period. It is highly important that the student should never commence the study of a nerve at a distance from its origin. This mode of examining the nervous system is extremely objectionable, and will result in very superficial knowledge.

First Period.—After having sawed the head, as for the study of the brain, we should raise this last from before backwards, and incline the head in the same direction ; in this way, the brain, although sustained by its numerous vessels, is sufficiently separated from the bones of the cranium, and thus leaves an interval which permits us to get a satisfactory view of the nerves in the order of their origin. We may, in order not to lose any nervous twig, detach the integuments, before sawing the cranium, in the following manner : Make a longitudinal incision from the root of the nose to the occipital protuberance ; this incision should penetrate to the bones ; we should then detach, from each side, with the handle of a scalpel, all the soft parts, and even the periosteum, as far as the half of the temporal fossa. In this manner, we shall be enabled to pursue the smallest divisions of the nerves, which go to the integuments of the head. In whatever way we may open the cranium, by reversing cautiously the brain from before backwards, we shall see successively all the nerves of the head. The first which present themselves to view are the olfactories, or first pair of nerves ; they are pulpy and soft, and are easily broken ; the portion that corresponds to the brain is applied to the inferior part of its anterior lobes ; posteriorly to this, there is a

broad medullary production, which soon divides into two large cords, which lose themselves in the optic foramina; these are the optic nerves: they may be cut on a level with the optic foramina, through which they pass. As they are very short, it is essential to leave them as much as possible on the side of the brain, in order to appreciate better their origin. A little posteriorly and outwardly are seen the nerves of the third pair, which are small in comparison with the preceding, although their length is more considerable; they proceed from behind forwards, and enter the orbit through the sphenoidal fissure; their great extent will permit us to cut them where we think proper; there always remains sufficient of them on either side, either to trace their origin in the brain or follow their distributions out of the cranium. On the side of these last and outwardly, we perceive two long and very small filets, coming from behind, turning on the arms of the medulla oblongata, and proceeding parallel to the superior border of the petrous portion of the temporal bone, in order to penetrate the orbit through the sphenoidal fissure: at first lower than the nerves of the third pair, they become superior to them when they enter the orbit; these are the nerves of the fourth pair; near these but more externally, numerous filets coming from the lateral parts of the left of the medulla oblongata, unite into one large flat cord, which places itself on the middle of the superior border of the petrous bone, and thence proceeds to the middle fossæ of the cranium, where it divides into three portions; it is the fifth pair of nerves, or trifacial. The first branch bears the name of ophthalmic, the second that of superior maxillary, and the third is called inferior maxillary. More posteriorly, inferiorly, and more internally, there is observed, on

each side of the basilar groove, a long nerve, the size of which is between that of the third and fourth pair of nerves; it enters the cavernous sinus, nearly an inch below the posterior clinoid apophyses, in order to penetrate the orbit through the sphenoidal fissure, under the name of the sixth pair or motor externus: on the external of the preceding, there are two cords, of a different size and consistence, which pass outwardly, and after a short trajet, penetrate the petrous portion of the temporal bone through the acoustic foramen; these are the seventh pair of nerves. The first portion is called the acoustic nerve, the other the portio dura or facial nerve.

At this period of our examination of the nerves, the greatest portion of the cerebral mass is out of the cranium, and thrown backwards: we should be particular when taking it entirely from the cranium, and be careful to prevent, if possible, any derangement of it; we then proceed, and, not far from the seventh pair of nerves, we will perceive several filets unite in order to form two cords, which proceed upwards and outwards in order to reach the foramen lacernum posterius; they leave the cranium through this foramen, under the name of the eighth pair of nerves; it is easy to distinguish the two cords, which compose it; the anterior smaller, bears the name of glosso-pharyngeal; and the posterior, larger, that of pneumo-gastric. The filets of which they are composed, arises, as is easily seen, from the lateral and superior parts of the tail of the medulla oblongata, a little posterior to the seventh pair. Finally, the ninth pair of nerves arise by ten or twelve filets from the tail (queue) of the medulla oblongata, and proceed immediately to the anterior condyloid foramina, which they traverse in order to reach the tongue: the trajet of these nerves can be seen only

by separating the brain, and examining the commencement of the vertebral canal.

Second period.—Origin of the nerves.—This preliminary examination of the nerves being achieved, we should cut the medulla oblongata below the origin of the ninth pair of nerves, and remove the brain, in order to place it on the table with its base upwards, and then proceed to the study of their origin. Some will be found, perhaps, to censure the course I adopt in preparing the nerves of the brain; they will advance, with some appearance of reason, that it is difficult to recognise, after having cut them, the filets which give birth to the majority of the nerves; that these filets are not very evident on the brain, and that great confusion ensues when we do not study them immediately after having cut them. I avow that, instructed by my own experience, I was desirous of being able to indicate a mode of preparing them which would have removed this inconvenience. I have, in fine, very frequently remarked, and my students who were present at these experiments have remarked the same thing, that on cutting a nerve with a metallic instrument, no matter of what kind, it would retire, with a species of fremissement towards the cerebral mass, adhering intimately to this last, and ultimately disappear altogether; I have likewise demonstrated to these same students, that, when employing scissors or a scalpel in order to cut these nerves, their retraction was both more lively and complete, and I was of opinion that there was some analogy between these phenomena which chance caused me to observe before the discovery of galvanism, and which are produced by the most simple means, and those which this same galvanism developes, aided by its instruments and apparatus. I now return to the preparation of the nerves.

Notwithstanding the inconveniences connected with the plan which I advise in the study of these parts, I am of opinion that it should be adhered to, because there is none preferable to it. We should now occupy ourselves with the origin of the nerves, in the same order in which they have been exposed.

First pair,—*Olfactories*.—It arises posteriorly from the anterior lobes of the brain by two roots, one of which passes in the direction of the common trunk, and the other, longer, proceeds outwards, and dips down into the fissure, which separates the anterior lobe of the brain from its middle lobe. We should carefully pursue this different course of the two roots, and follow them as far as possible. This will be the more easy, as the roots of the olfactory nerve present greater density as they proceed in the substance of the brain. But, in general, these minute researches of the origin of the nerves, which excite such lively interest in the rigid anatomist, merely tend to embarrass the student, and cause him to lose much precious time, which might be advantageously employed in the examination of other parts.

Second pair,—*Optics*.—The origin of these nerves is perceived without difficulty; they arise from the inferior and posterior part of the thalami nervorum opticorum, and unite at a short distance from them. It is likewise easy to see that the origin of the optic nerves takes place beyond the thalamus of the same name. Of this we may assure ourselves by cutting it in its length, which will permit us to follow the optic cord to the environs of the tubercula quadri-gemina.

Third pair,—*Motores communes*.—We must look for the origin of these at the posterior part of the anterior prolongations of the medulla oblongata. There, they are ob-

served to arise by several filets, which soon unite in one rounded fasciculus, in order to proceed in the direction above indicated. But when we wish to pursue the origin of the third pair of nerves still farther, we will experience great difficulty, for they are very easily taken up with the pia-mater; being very thin at their origin, they abandon without difficulty the cerebral substance.

Fourth pair,—*Pathetici*.—These nerves, although very delicate, proceed for a long distance before leaving the cranium. They arise near the union of the tubercula quadrigemina; when pursued to these eminences, they will be seen to make a considerable circuit around the arm of the medulla oblongata, and annular-protuberance.

Fifth pair,—*Trigemina-Trifacial*.—Several filets arise from the legs of the medulla oblongata, at their union with the protuberance, and unite in a large flat cord, in order to form the tri-facial, which soon places itself on the superior border of the petrous bone, in order afterwards to proceed to the depression found in front of this bone, and form what is called the *pes anserinus*.

In order to have a good view of the disposition of this nerve in front of the temporal, and to follow more easily the branch given off from it, we should remove the dura mater, which, in this place, adheres very strongly to these nerves.

Sixth pair,—*Motores externi*.—These take origin from the groove that separates the protuberance from the tail of the medulla oblongata, by a few filets feebly united to each other.

Seventh pair,—*Acoustic and facial*.—These two nerves have a different origin. The portio mollis (acoustic) arises more posteriorly from the back part of the tail of the medulla oblongata, and the portio dura (facial,) higher up, and in front, of the prolongation of the cerebellum.

Eighth pair,—*Pneumo-gastric and glosso-pharyngeal*.—These two nerves have a common origin, and they are seen to arise from the superior and lateral parts of the tail of the medulla oblongata, by a great number of filets, isolated at first; then united, and forming two cords, one of which, anterior, is the smaller of the two, and is called pneumogastric.

Ninth pair,—*Hypo-glossus*.—Ten or twelve filets take their origin from the fissure which separates the olivary and pyramidal eminences, and separate themselves from the numerous vessels found in this place, in order to unite in one cord under the name of great hypo-glossus.

Such is the order of the nerves furnished by the brain, the annular protuberance, and commencement of the medulla oblongata. We may next pass to their definitive preparation, and follow them out of the cranium in the order nearly of their origin, but with the modifications required by their different distributions and their mode of preparation.

Third period,—Special preparation.—*First and second pairs*.—The student is arrested the moment he begins to occupy himself with the first pair of nerves, as he must necessarily sacrifice a part of those which enter the orbit, or at least interfere singularly with their preparation, in order to study the olfactories. These considerations are more directly applicable to the second pair, which penetrate the orbit, and which cannot be studied until after those with which we shall occupy ourselves immediately. We may then return to the first pair, and give to them all the attention they require.

I shall now, however, indicate in two words what the student will have to do at a later period for the examination of these nerves, unless he should have a number of heads,

which would supercede the necessity of deferring the preparation of the two first pairs.

The first is much more difficult than the second; this latter not undergoing any division in its course, and passing directly from its origin to the posterior part of the sclerotica, through which it introduces itself in order to form the retina, does not require much time for its preparation. It will suffice to break the posterior part of the orbit, in order to expose the portion of nerve that passes to the sclerotica, and examine the manner in which it penetrates this membrane.

The pulpy consistence of the olfactory nerves being the principal cause of the difficulty attending their dissection, it would, perhaps, be proper in order to diminish this difficulty, to plunge the superior nasal fossæ into an acid, or even into a small portion of alcohol diluted with water.

We should then seek for the divisions of the olfactory nerves, which are distributed principally on the superior and lateral portions of the nasal fossæ. We may even content ourselves with scraping, with the back of the scalpel, the surfaces on which they are perceived to spread themselves.

Third, fourth, sixth pairs, and first branch of the fifth.— These different nerves should be prepared at the same time. They all penetrate the orbit through the sphenoidal fissure, in order to go for the most part to the muscles of the eye and upper eye-lid. The first that presents itself to our study is the ophthalmic; next comes the fourth; the third follows, and we terminate with the sixth. In order to proceed with method, we should act in the following manner: make with the saw two sections at the orbital arch, from before backwards, which represents a V, the base of which is in front, and the summit behind. One of these sections must commence at the root of the nose, the other on

the temporal region ; we should turn forwards, without detaching it completely, the portion of the orbital arch comprised in the two cuts of the saw ; a blow with the mallet will suffice for this. In this way, the eye will be exposed, as also the soft parts covering it. We should divide the portion of dura mater expanded over these objects ; when we remove it, we shall see immediately below the principal divisions of the first branch of the fifth pair. But before proceeding to the ulterior study of the nerves that go to the orbit, it is indispensable to determine the respective entrance of each of them into this cavity, in order not to confound them with each other ; it is for this reason that, in taking them at their entrance into the orbit, we find that the optic nerve, the largest of all, is situated at first above the others, and at their internal part, but soon it is covered by them. Farther backwards is observed the third pair, situated at first above the fourth, but which soon becomes inferior to it. A little more posteriorly, and externally, is observed the fourth pair, which is very delicate ; it may be found without difficulty, by following the duplication furnished by the dura mater, in order to form the superior petrous sinus ; lower down than the two preceding is remarked the first branch of the fifth pair, which likewise penetrates the orbit ; below all these nerves, and in the interior of the cavernous sinus, is the sixth pair, which cannot be seen properly until after the examination of all the others. All these nerves, before entering the orbit, are so firm and united among themselves by the dura mater that it would be almost impossible to separate them ; it would be much better to take them in the orbit, in the order in which they present themselves. It is, therefore, with the first branch of the fifth pair that we should commence ; it

divides itself into three principal branches. Two of these divisions distribute themselves on the levator palpebræ superioris, one of which, the larger of the two, goes to the supra-orbital foramen, and the other, much smaller, proceeds to the lachrymal gland. In order to expose this branch, we should commence with it on the side of the gland, and follow it in a retrograde manner towards the common trunk. The other loses itself in the integuments of the forehead, and it may be followed without difficulty. A branch, under the name of frontal nerve, leaves the orbit, towards the internal orbital angle.

We should next pass to the last branch of the ophthalmic called nasal; it will be found below the levatores palpebræ superioris, of that of the globe of the eye, and above the rectus internus and obliquus magnus. It will suffice to separate these muscles without cutting them; we readily see the branch in question proceed obliquely from behind forwards, and from without inwards, towards the orbital foramina through which the divisions penetrate, and ramify on the pituitary membrane. In gently separating the great oblique and internal straight muscles, we will observe a division of the nasal, travelling along the internal wall of the orbit, and proceeding outwardly in order to anastomose with the frontal. But it is important to remember, in the examination of the nasal, that, in passing over the optic nerve, it gives off a retrograde branch, which reaches the nerve of the third pair and contributes to the formation of the ophthalmic ganglion. We will return to this farther on.

The fourth pair, of which we must free ourselves before passing to the third pair, must be taken at the great oblique muscle, in which this nerve loses itself; its small size, its interlacement with the other nerves, would render its preparation extremely difficult in commencing with it in

any other manner: as for the rest, the student may pursue it posteriorly as far as his patience and intelligence will permit him. In examining this nerve in the great oblique muscle, we should pursue its multiplied divisions, by separating the fibres of the muscle.

In order to have a satisfactory view of the divisions of the third pair, we should, as far as practicable, commence by exposing its ganglion. I have rarely failed in finding it, by looking, in the first place, at the posterior part of the globe, and on its external side, for very small branches which it furnishes under the name of ciliary nerves, and in following them posteriorly, until I observed a small reddish body, placed on the external side of the optic nerve, and always enveloped by a great quantity of fat, from which it must be cautiously freed. If we have been fortunate enough to find this ganglion, we will then readily perceive the branch of the nasal nerve, which contributes to its formation; we will likewise perceive the large and short filet, which the third pair of nerves sends to it posteriorly and inferiorly; from its anterior part arise the twigs which proceed along the optic nerve, in order to penetrate the globe, under the name of ciliary nerves.

The other branches of the third pair do not merit so much attention; they go to the muscles, and the dissection of these will suffice for them. The muscles in which the branches of the third pair are lost, are the superior rectus and levator palpebræ superioris, for the superior branch, and the inferior rectus, rectus externus, and obliquus parvus, for its three inferior branches.

The sixth now remains; we must commence with this nerve in the cavernous sinus. We should observe that it is enclosed with the carotid artery, on the external side of which it is situated. It will be recognised by its white co-

lor; we should pursue it towards the orbit; it loses itself in the external straight muscle. In passing over the carotid foramen, the sixth pair sends off a twig which descends through the foramen, and contributes, it is said, to the formation of the great sympathetic; its small size and great tenuity almost always interfere with its examination; the best way to see it, is to raise, with a hook, the trunk of the sixth pair, and to carry carefully the instrument beneath, in order to remove the parts which conceal it. We might likewise have an opportunity of seeing this filet, during the preparation of the superior branch of the superior cervical ganglion, into which it throws itself. This requires considerable patience. I shall refer to it again.

Second branch of the fifth pair.—We must commence with this nerve at its entrance into the superior maxillary foramen, and follow it to the zygomatic fossa, breaking the portion of bone by which it is covered; it is not necessary to touch either the superior maxillary or petrous portion of the temporal bone; but we should remove the abundant fat, which is found in the zygomatic fossa, when we have exposed it, nearly in the spot at which the infra-orbital canal commences: we must then endeavor to find the branches, which dip down behind the maxillary bone, and expose the spheno-palatine ganglion, which is found two or three lines below, concealed under a quantity of fat, which it will be necessary to remove. Three principal branches arise from this ganglion: one passes through the posterior palatine foramen, and is distributed under the internal membrane of the osseous palate: the slightest knowledge of Osteology will suffice to enable us to pursue it. In order to expose this twig properly, it will be necessary to saw the nasal fossæ longitudinally, remove

the pituitary on a level with the posterior palatine conduit, and also the osseous plate which separates it. The palatine apophysis being next broken, the palatine membrane remains, and we perceive on its superior surface the termination of the palatine twig. The second branch arises from the internal part of the ganglion, penetrates the interior of the nasal fossæ through the sphenopalatine foramen, and anastomoses with the nasal furnished by the first branch of the fifth pair, and also with the olfactory, with which the student should not occupy himself, as has already been remarked, until after having completed all the nerves of the head. But the sphenopalatine ganglion furnishes a third branch, remarkable on account of its small size and the difficulty of following it; it is the pterygoid nerve. It arises from the posterior part of the ganglion, and immediately dips down, proceeding directly backwards, into the pterygoid canal, which it will be necessary to break in its whole extent in order to see it. When we have succeeded in exposing the pterygoid canal and nerve, we will perceive it proceed from before backwards as far as the summit of the petrous bone, where it divides into very fine branches, one of which, the inferior, passes out through the anterior foramen lacerum, in order to contribute with the fillet of the sixth pair, to the formation of the superior cervical ganglion, and which we may trace without much difficulty, with the necessary time and patience; the other branch, enveloped by a fold of the dura mater, continues to march through a canal on the superior surface of the petrous bone, and loses itself in the *hiatus Fallopii*, which terminates this canal.

After having seen the branches which form the sphenopalatine ganglion, we must return to the trunk of the supe-

rior maxillary, which is lodged in the commencement of the infra-orbital canal, in which it continues to descend more and more, and re-appears on the face passing out through the infra-orbital foramen. We should remove all the soft parts contained within the orbit, and even break, if it be deemed expedient, the portion of the maxillary bone, which conceals the course of this nerve, and dissect with care the caninus and levator labii superioris, in which it in great measure loses itself.

Third branch of the fifth pair.—This nerve requires of us to sacrifice all the parts of which we have so far spoken ; we must, by a section of the bones of the cranium, remove every thing that conceals this nerve, as far as its exit through the foramen ovale. This section is made by carrying the saw from the root of the nose to the point of the petrous bone, on the one hand ; and from the temporal region transversely, to the same place, on the other. When we have removed the parts comprised in the two sections, there results a triangular space, in the bottom of which is observed the trunk of the third branch of the fifth pair. We should preserve for a moment this piece in place, in order to see a particular branch which distributes itself towards the mouth, under the name of buccinator nerve. The other filets, which the third branch of the fifth pair furnishes, lose themselves in the temporal and masseter muscles ; we recognise these nerves by their transverse direction from within outwards, and by their small size ; it is the same with the pterygoids, which are still smaller, and which dip down profoundly in the muscles of the same name.

After we have terminated the study of these nerves, we must continue the dissection of the two principal branches, known, the one, under the name of inferior maxillary or

dental, which loses itself in the under jaw ; and the other, the lingual, is destined for the tongue : these two branches are less difficult to follow and dissect than the others, because they are larger, and their division is better characterised. It is necessary to commence by sawing the under jaw at its middle ; we must draw the fragments in different directions, and the tongue should be pulled outwards in order to lengthen it and render the lingual nerve more apparent. In this way, we may continue the dissection of the two branches of which we have just spoken ; it is also at this time that we should look for the articular, which presents great difficulty ; it proceeds backwards, and reaches the articulation of the under jaw, in turning around the neck of the bone. When following the branch which loses itself in the under jaw, we must attend to some twigs which it furnishes in its course, and which lose themselves in the muscles of the anterior and profound part of the neck, among which we should distinguish the mylo-hyoideus, which is constant, and expends itself on the muscle of the same name.

The trunk of the dental or inferior maxillary, after having traversed the entire body of the under jaw, passes out through the mental foramen, which is observed at the anterior portion of this bone ; we may commence with it there in order to follow it in the muscles and integuments of the face, where it frequently anastomoses with the portio dura of the seventh pair.

Seventh pair.—The two nerves of which it is composed penetrate the petrous portion of the temporal bone through the acoustic foramen. The portio mollis remains in this bone, and distributes itself, under a pulpy form, on the cochlea. The portio dura traverses the aqueduct of Fallopius, gives off some small branches in the interior of the

petrous portion, among others the chorda tympani, and passes out through the stylo-mastoid foramen. I would not advise the student to attempt to follow this nerve in the petrous portion of the temporal bone, for it will be attended with great difficulty; he should content himself to commence with it at its exit through the stylo-mastoid foramen.

The portio dura of the seventh pair, at its passage from the cranium, is seen at the external orifice of the stylo-mastoid foramen, which is the termination of the aqueduct of Fallopius, consequently very profoundly situated, and requiring great care for its preparation. We should commence by dividing the integuments from above downwards in the direction of the under jaw; we should draw the flaps outwards, and leave the ear in situ, as well as the parotid gland; we must carefully remove the cellular tissue which covers this gland, without touching the numerous branches, which arise from the seventh pair. We should remove particularly the cellular tissue which is found in the depression comprised between the branch of the under jaw and adjoining part of the temporal bone; it is in the bottom of this space that we find the origin of the seventh pair. When we have arrived at its principal trunk, it will be easy to follow the numerous divisions, which are distributed more especially on the lateral portions of the face, neck, and even of the cranium; but it will be necessary, after attaining this point of its preparation, to remove a part of the parotid gland, which conceals the trajet of this nerve, the numerous distributions of which are made particularly on the superficial parts of the face.

The seventh pair likewise furnishes a remarkable branch which proceeds behind the ear, on the mastoid re-

gion, under the name of posterior auricular nerve; this branch is very delicate and loses itself almost entirely in the integuments of these parts by very fine filets; it requires considerable care. After having divided the integuments of the posterior part of the ear, we seize some twigs of this branch, which will serve as guides in order to arrive at its origin, which takes place at the posterior part of the trunk of the seventh pair. It should be remembered that this branch, as well as the others of which I have already spoken, are situated very superficially, and anastomose frequently with the anterior and subcutaneous branches of the first cervical pair.

Eighth pair.—This nerve, one of the most extensive of those furnished by the brain, does not present much difficulty in its preparation; a tolerably exact knowledge of the organs with which it holds relations, will facilitate its study; destined for the tongue, the lateral portions of the neck, lungs, heart, and stomach, it is easy to follow its distribution, although they are somewhat minute. At its exit through the posterior foramen lacerum, this nerve is found profoundly situated on the lateral and superior portions of this part. In order to find it, we must cut the integuments of the neck from the region of the ear to a level with the ribs. I shall indicate immediately the manner of tracing it in the chest. We must remove all the soft parts which are found interposed as far as the posterior foramen lacerum. But in order to have a perfect view of the eighth pair as it passes out of the cranium, we must saw this latter in front and behind, at about an inch from the posterior foramen lacerum, that it may be completely exposed. Without this preliminary operation, nothing is more difficult than to arrive at the bottom of the notch formed by the maxillary bone, on the one part, and the

mastoid region, on the other, in which is found the posterior foramen lacerum. In proceeding, on the contrary, as I have just indicated, we will have the advantage not only of seeing the eighth pair properly, but we shall likewise perceive the two other branches, which pass out at the foramen lacerum with the eighth, which are the glosso-pharyngeal, and accessory of Willis, or spinal; we shall also observe the great hypo-glossal nerve, which, at its exit from the cranium, contracts with the preceding, adhesions which it is absolutely necessary should be known.

As it passes from the cranium, the eighth pair is confounded with the accessory of Willis, the ninth pair and glosso-pharyngeal, which has always been regarded as a branch of the eighth; it is easy to recognise each of these nerves by the different direction they assume; for the trunk of the eighth pair is placed, from above downwards, on the lateral parts of the neck, and external side of the carotid artery: the accessory of Willis, which likewise passes through the foramen lacerum with the eighth, forms with it a very acute angle, in order to proceed to the posterior part of the neck, below the sterno-cleido mastoideus, but which may be pursued still farther if it be deemed expedient: we will then observe its twigs lose themselves in the muscles of the posterior part of the neck and back, and anastomose with twigs of the first cervical nerves.

The ninth pair, or great hypo-glossal, which leaves the cranium through the anterior condyloid foramen, is observed at first below and behind the eighth pair; but it soon becomes superior to it in order to pass to the tongue. If the size of the ninth pair is equal to the trunk of the eighth, it is much greater than that of the glosso-pharyngeal, which is situated considerably higher. After having determined the situation, direction, and relations of the eighth

pair, accessory of Willis, glosso-pharyngeal, and ninth pair, we may proceed with the definitive preparation of each of these nerves, commencing with that which is most convenient. I am of opinion that it would be more advantageous to begin the study with the glosso-pharyngeal, and then pass to the ninth pair, before terminating the rest of the eighth, unless we should desire to defer, as was recommended a few moments since, the ulterior examination of the accessory.

Glosso-pharyngeal.—This nerve, a pretended branch of the eighth, leaves the cranium, as also this latter, through the posterior foramen lacerum: it separates from the preceding as soon as it has passed out, in order to go to the posterior part of the tongue, and lose itself in this organ with the lingual and great hypo-glossal. In commencing with it at its exit from the cranium, we can trace it with facility as far as the tongue, dissecting carefully the parts through which it proceeds in order to reach its destination. This nerve sends off and receives some twigs from the neighboring nerves, the description of which will point out their distribution.

Ninth pair.—This leaves the cranium through the anterior condyloid foramen. Immediately after its exit, it turns on the eighth pair, and from having been posterior, it becomes anterior and superior; it is then placed between the carotid, the eighth pair, and internal jugular; it will be recognized by its size, its direction, and termination in the tongue; it passes principally on its inferior surface and towards its point. Its preparation is not very embarrassing, especially after the study of the glosso-pharyngeal, and superior portion of the eighth pair.

We should not neglect to observe the branches that pass off from its inferior part, and which form, in front of the

neck, anastomoses with the first and second cervical pairs, among which there is one more remarkable than the others, which describes an arch the convexity being below.

Spinal or accessory of Willis.—This does not arise from the brain; it originates, on the contrary, from the spinal marrow, and its origin cannot be seen until after the study of nearly all the nerves; but in commencing with it at its exit from the cranium through the posterior foramen lacerum, we will soon observe it pass under the sternocleido mastoideus, from which we must detach its superior part; it then continues to the lateral and posterior portion of the neck, and superior of the back, without furnishing any remarkable branch. Its dissection is the more easy, as the branches it furnishes lose themselves in the broad muscles of the back.

Progress of the eighth pair.—When the nerves of which we have just spoken have been studied, it will be necessary to follow the trunk of the eighth pair, which travels along the lateral portions of the neck, and furnishes an infinity of small branches, which must be dissected with care. Among these, there is one larger than all the others, which proceeds to the larynx, under the name of laryngeal nerve: it will be recognised by its size, its direction towards the larynx, and especially by its profound situation; it arises very high up from the eighth pair, and is found, immediately after its origin, behind the internal carotid artery, and consequently below all the other parts of which we have already spoken, and immediately on the vertebral column; when it has reached the larynx, it is very easy to follow its distribution.

In fine, the trunk of the eighth pair, arrived at the inferior part of the neck and superior of the chest, penetrates this cavity; in order to follow it, it is absolutely necessary

to open the chest, so as to expose, the pericardium and diaphragm; when this is accomplished, we must, before going farther, proceed to the preparation of the two recurrents, right and left, which arise from the trunk of the eighth pair the moment it enters the chest; the right is below the subclavian artery of the same side, and the left below the arch of the aorta.

Immediately after being separated from the common trunk, the two recurrents dip down deeply, as if they were destined to penetrate the chest; but they soon take a retrograde course, in turning, one on the subclavian artery, and the other on the aorta; they are then observed, placed on the lateral portions of the trachea, to continue from below upwards, to the inferior portion of the larynx; they lose themselves in this cavity just like the laryngeal: it will suffice to separate the carotid and draw the trachea in different directions, in order to see their distribution. It will be necessary to remove a quantity of loose cellular tissue, which is remarked at this place.

As soon as the eighth pair has given off the recurrents, it then becomes more difficult to follow its distribution; this however may be done by raising the left lung, and carrying it to the right side, so as to expose the esophagus. We then observe, on removing the cellular tissue by which they are covered in their trajet, the two trunks of the eighth pair descend along this canal. They furnish some twigs which go to the lungs, and others to the heart, in order to contribute to the formation of the cardiac and pulmonary plexuses: it is below these parts that the nerves of the eighth pair turn around the esophagus in order to lose themselves on the stomach; if we inflate this organ, we shall be enabled to follow their distribution without difficulty. We should divide the diaphragm in the point at

which the esophagus enters the abdomen, and, on separating each of these parts, we shall then see the trunk of the eighth pair distributed on the stomach, and going particularly to its inferior orifice in order to lose itself in the solar and other plexuses of the abdomen.

Description.

FIRST PAIR.—OLFACTORIES.—ETHMOIDAL.

Situation.—In the interior of the cranium; under the anterior lobes of the brain.

Extent.—From the interval of the anterior and middle lobes of the brain to the nasal fossæ.

Direction.—Horizontal, from behind forwards.

Relations.—On the one hand, they are covered by the anterior lobes; on the other, they repose on the superior surface of the sphenoid bone, and on a portion of the cribriforme plate of the ethmoid.

Divisions.—Into a considerable and indeterminate number of very fine twigs, which are expended on the pituitary membrane, and particularly on that which lines the partition and superior and lateral walls of the nose.

SECOND PAIR.—OPTICS—OCULAR.

Situation.—Under the middle portion of the brain.

Extent.—From the thalami nervorum opticorum to the globe of the eye.

Direction.—Oblique, from behind forwards and from without inwards; finally, from within outwards, and always from behind forwards until it reaches the globe.

Relations.—Covered by the brain, the optic nerves repose in part on the sella turcica, and in part on the superior surface of the small wings of the sphenoid bone; the

ophthalmic artery proceeds on their external and inferior portion, and penetrates the orbit in company with these nerves.

Divisions.—Arrived at the globe of the eye, the optic nerves, after having penetrated through the sclerotica, expand themselves under the form of a soft and pulpy membrane, which is the immediate organ of vision—it is the retina.

THIRD PAIR.—MOTORES COMMUNES—OCULO-MUSCULAR.

Situation.—Under the middle portion of the brain, a little externally.

Extent.—From the arms of the medulla oblongata to most of the muscles of the eye.

Direction.—Slightly oblique from behind forwards, from within outwards, and from above downwards.

Relations.—Free under the brain, as far as the posterior clinoid apophysis; they then pass into a species of sheath formed by the dura mater, strongly united in this place with the fourth pair and first branch of the fifth, which at first are inferior to them, but which become superior at their entrance into the cranium.

Divisions.—Into two branches, 1st, A superior, which reaches the superior straight muscle of the eye, and thence gives off a twig, which loses itself in the levator palpebræ superioris; 2d, An inferior, more considerable, placed on the external side of the optic nerve, and divides into three branches: an internal, which passes under the optic nerve, and loses itself in the internal straight muscle; a middle, which proceeds directly to the inferior straight muscle; an external, more considerable, destined for the small oblique; from this branch, there arises, within, a large and short twig, which aids in forming the ophthalmic ganglion.

FOURTH PAIR.—PATHETICI—INTERNAL OCULO-MUSCULAR.

Situation.—Under the brain, a little more external than the third pair.

Extent.—From the environs of the tubercula quadrigemina to the great oblique muscle, describing a long circuit around the annular protuberance and arms of the medulla oblongata.

Direction.—Similar to that of the third pair.

Relations.—Covered by the brain in the greatest part of their extent, they pass into the sheath common to the third pair and first branch of the fifth; they then lose themselves entirely in the great oblique muscle, passing above the levators of the globe of the eye and superior eye-lid.

FIFTH PAIR.—TRIGEMINA.—TRIFACIAL.

Situation.—Under the lateral and middle parts of the brain.

Extent.—From the legs of the medulla oblongata, near the protuberance, to all the parts of the face.

Direction.—Oblique from within outwards, and from above downwards, passing on the middle part of the superior border of the petrous bone.

Relations.—Covered by the cerebral mass and tentorium cerebelli; in a small portion of their extent, they are seen to ascend on the superior border of the petrous bone, and then precipitate themselves immediately to the bottom of the internal temporal fossæ.

Divisions.—Into three remarkable branches.

First branch. *Ophthalmic.*—It is the smallest of the three; it proceeds from behind forwards, and from below upwards, passes into the sheath common to the third and fourth pair, proceeds below these nerves, and gains the orbital arch: there it divides into three twigs, two of

which are superior and one inferior; of the two superior, the internal, called supra-orbital or frontal, is larger than the external, and passes out of the orbit through the infra-orbital foramen; the external, lachrymal, is very delicate and loses itself in the lachrymal gland. In its course, it furnishes some small twigs to the neighboring parts, and among them there is one more considerable than the rest, which pierces the malar bone, in order to proceed to the temporal fossa, where it is expended. The inferior or nasal twig travels obliquely towards the internal paroi of the orbit, passing above the optic nerve, and penetrates the nasal fossæ through the internal orbital foramina, after having furnished a branch which proceeds parallel to the internal paroi of the orbit, and leaves this cavity near the internal orbital angle. On a level with the optic nerve, the nasal sends off posteriorly and outwardly a delicate filet, which contributes to the formation of the ophthalmic ganglion; this ganglion, of a reddish color, and triangular figure, is situated on the external side of the optic nerve and gives off from its anterior angle two fasciculi of nerves, called ciliary, which travel parallel to the optic nerve, pierce the sclerotica, pass towards the ciliary ligament, and distribute themselves in the form of rays on the iris.

Second branch. *Superior maxillary*.—This is situated and arises between the ophthalmic and inferior maxillary; it passes immediately through the foramen bearing its name; it thence goes to the superior part of the zygomatic fossæ, as far as the commencement of the infra-orbital canal, which it traverses in its whole extent, in connection with the orbital filet, which travels along the external paroi of the orbit, and anastomoses with the lachrymal nerve, after having given off the posterior dental branches; it leaves this canal through the infra-orbital foramen, and

loses itself, by multiplied divisions in form of plexuses, in nearly all the muscles of the face, after furnishing the anterior dental nerves.

Before entering the infra-orbital canal, the superior maxillary gives off two twigs from its inferior part, which, after having traversed an extent of two or three lines, form the sphenopalatine ganglion; its reddish color will enable us to distinguish it in the midst of the abundant fat, which surrounds it on all sides. This ganglion, equalling a large lentil in size, is situated so that its internal surface corresponds to the sphenopalatine foramen; the external surface is covered with a quantity of fatty matter. Three branches arise from this ganglion: an inferior, called the posterior palatine, which descends in the canal of the same name, and exhibits itself under the palatine arch; it is situated, in its distribution, between the palatine membrane and superior maxillary bone; a second branch is called the sphenopalatine, which penetrates through the foramen of the same name, to the nasal fossæ and there ramifies, principally on their lateral walls; a third branch has received the name of vidian or pterygoid; it traverses the foramen of the same name, passes on the anterior foramen lacerum, sends off in this place a filet, which passes out of the cranium through this foramen, and proceeds to the superior cervical ganglion; the vidian then reaches the summit of the petrous bone, passes into a canal hollowed on one of its surfaces, and penetrates this bone by the hiatus Fallopii.

Third branch. *Inferior maxillary*.—This branch is the largest and most posterior of the three; it passes immediately through the inferior maxillary foramen, and places itself in the bottom of the zygomatic fossa; in this place, it gives off six or seven twigs, under the names of

profound temporal, buccal, masseter, auricular and pterygoid; the inferior maxillary next divides into two principal branches; one of them is called the lingual nerve, and the other inferior maxillary or dental. The former receives, in the first place, the chorda tympani, which passes out through the fissure of Glaser; it then proceeds, from behind forwards, and from above downwards, between the branch of the jaw and the great pterygoid muscle, and reaches the lateral portions of the tongue, in which it entirely expends itself. The second appears to be the continuation of the principal trunk, and travels on the side of the lingual; a little outwardly, it is situated between the branch of the under jaw and great pterygoideus, and presents itself at the posterior orifice of the dental canal. In this place, it gives off a twig, which proceeds in a fissure on the body of the jaw; it then penetrates the dental canal, traverses it in its whole extent, and supplies the teeth of the under jaw; it passes out through the mental foramen, in order to lose itself in the muscles of the under jaw.

SIXTH PAIR. EXTERNAL OCULO-MUSCULAR.

Situation.—Under the inferior and posterior parts of the cerebral mass.

Extent.—From the medulla oblongata to the external straight muscle.

Direction.—Oblique from behind forwards, and from below upwards, passing by the cavernous sinus.

Relations.—Posteriorly, they are placed between the annular protuberance and basilar groove; after arriving in the environs of the posterior clinoid apophysis, they enter the cavernous sinus, place themselves on the external side of the carotid artery, and penetrate the orbit, in order to lose themselves in the external straight muscle.

SEVENTH PAIR, DIVIDED INTO ACOUSTIC AND FACIAL.

ACOUSTIC.

This nerve penetrates the labyrinth, with the facial, through the internal auditory foramen; thence, under a pulpy form, it expends itself on the walls of the vestibulum, cochlea, and semicircular canals.

FACIAL.

Situation.—Under the middle portions of the cerebral mass.

Extent.—From the lateral parts of the protuberance, to those of the head, face and neck, traversing the internal ear.

Relations.—Until its entrance into the internal ear, the facial nerve is placed above the acoustic; it then abandons it, and traverses the aqueduct of Fallopius, passes out of this canal through the stylo-mastoid foramen, and is distributed on the lateral portions of the face, after having traversed the parotid gland.

Divisions.—1st, Into some inconsiderable twigs, which, in the interior of the petrous bone, proceed to the malleus, stapes, and membrane of the tympanum, under the name of chorda tympani; 2d, Immediately after its exit from the cranium, it gives off the posterior auricular nerve, and some other small twigs, which are lost in the mylo-hyoid and digastric muscles; 3d, Beyond the parotid gland, the facial divides into two branches, one of which is superior, and forms on the temple a species of *patte d'oie* (pes anserinus), whence are given off the temporal, malar, and buccal twigs; the other is inferior, and descends along the rami of the jaw; it divides into four principal twigs, which have not received any particular names.

EIGHTH PAIR. PNEUMO-GASTRIC AND GLOSSO-PHARYNGEAL.

Pneumo gastric.—*Situation.*—In the neck, on the lateral portions of the vertebral column; in the chest, in the posterior mediastinum.

Extent.—From the medulla oblongata to the stomach and most of the abdominal viscera.

Direction.—Longitudinal, but somewhat oblique from above downwards, and from without inwards.

Relations.—In the cranium, the eighth pair and glosso-pharyngeal have very intimate connections; when they pass through the posterior foramen lacerum, these nerves are in addition united to the spinal nerve. Out of the cranium, the eighth pair detaches itself from the two preceding, passes behind the ninth pair, and descends along the neck, in front of the anterior straight muscle of the neck, behind and on the external side of the carotid artery. In penetrating the chest, the eighth pair passes, on the right, in front of the right subclavian artery, and, on the left, in front of the aorta and behind the subclavian vein of the same side. In the rest of their extent, the two trunks of the eighth pair approach the esophagus, in turning on this canal in such a manner that the left becomes anterior, and the right posterior.

Divisions.—1st, Into the laryngeal nerve, which proceeds from above downwards, and from behind forwards, passing behind the internal carotid artery, in order to reach the larynx, and divide into two twigs, one of which penetrates this air tube, and the other loses itself on the soft parts covering it; 2d, Into several filets destined for the formation of the cardiac plexuses, and some others which pass to the great sympathetic; 3d, before entering the chest, a large cord arises from the eighth pair, called

recurrent, which ascends on the lateral portions of the trachea, reaches the larynx, and distributes itself there after the manner of the laryngeal nerve; 4th, In the rest of its extent on the esophagus, the eighth pair furnishes several filets to this organ, and it likewise gives off others, which contribute to the formation of the cardiac and pulmonary plexuses; finally, the trunks of the eighth pair are distributed on the stomach, form the anterior and posterior gastric nerves, and ultimately lose themselves in the abdominal plexuses.

GLOSSO-PHARYNGEAL.

Situation.—Similar to that of the eighth pair in the cranium; but out of this cavity, this nerve is situated on the superior and profound portions of the neck.

Extent.—From the medulla oblongata to the tongue.

Direction.—Oblique from above downwards, and from behind forwards.

Relations.—In the cranium, it is united to the nerve of the eighth pair; but out of this cavity, it is separated from it, at first by the internal jugular vein; afterwards it proceeds on the internal carotid artery, passes between the stylo-pharyngeus and stylo-glossus, and advances forwards and inwards, in order to lose itself in the posterior part of tongue.

Divisions.—The filets which it furnishes or receives come from the seventh and eighth pairs. Among these filets, one more remarkable than the rest, descends along the internal carotid artery, in order to aid in forming the cardiac plexuses; some others unite with those furnished by the superior cervical ganglion, for the purpose of forming a species of plexus for the branches of the **external** carotid artery.

NINTH PAIR.—GREAT HYPO-GLOSSALS.

Situation.—At the posterior part of the cerebral mass, and on the lateral, superior, and anterior portions of the medulla oblongata.

Extent.—From the medulla oblongata to the tongue.

Direction.—Similar to that of the preceding.

Relations.—At its exit from the cranium, the hypo-glossal is situated at the posterior part of the eighth pair, and afterwards corresponds with the anterior part of the superior cervical ganglion; it then becomes situated, in proceeding towards the tongue, in front of the internal carotid, behind the jugular vein, and getting more and more superficial, places itself behind the sterno-mastoid muscle; it loses itself on the lateral and inferior part of the tongue, about an inch from its point.

Divisions.—They are limited to a few filets, which contribute with similar filets of the first cervical pairs, to the formation of a very remarkable nervous portion. From the convexity of this species of arcade are given off twigs for the neighboring parts. In the rest of its extent, the ninth pair furnishes numerous twigs to all the muscles on the anterior and profound part of the neck.

INTERCOSTAL.—GREAT SYMPATHETIC.

(*Trisplanchnic.*)

Its study cannot be divided into several sections; it must, on the contrary, be pursued in a general and continued manner. This is the nerve, which, according to Bichât, furnishes all those of organic life, and which he considers as not having any relation with the nerves of the brain; but, independently of what we have already said, the experiments of M. Gallois demonstrate that the great sympathetic derives its nervous principle from the spinal marrow,

and seem to destroy the hypotheses of Bichât respecting the difference of the nerves of organic and of animal life.

Anatomical Preparation.

This nerve is more embarrassing on account of its extent and numerous distributions, than on account of the difficulty attending its preparation. In fine, the dissection of the eighth and ninth pairs have already familiarized the student with this nerve, which proceeds nearly to the same parts, and in the same directions as the former.

The trisplanchnic arises from the lateral and superior part of the neck, by a swollen, reddish portion, called the superior cervical ganglion. This ganglion is seen on a level with the first cervical vertebra, on which it is immediately applied, a little to the external side of the carotid artery, united very frequently to the eighth and ninth pairs by cellular tissue, which should be entirely destroyed in order to have a better view of it. When we have succeeded in exposing it, it will be easy to pursue it, for its situation does not change, and it adheres, as it were, to the parts on which it is found. We must absolutely aid ourselves with a description, for a great quantity of filets given off and received, which go alternately to the eighth and ninth pairs, and likewise to the cervical nerves, which should be carefully preserved, in order to understand something about the distribution of the trisplanchnic.

As in the preparation of the great sympathetic nerve there is nothing which will require to be preserved, we should do every thing in order to see the superior filets, which, from the cervical ganglion, pass to the vidian nerve and sixth pair. It will be necessary, for this purpose, to break the portions of the bones of the cranium, which are in the neighborhood of the anterior foramen lacerum, and

expose the foramen itself, with the precautions required in so minute an operation. It is scarcely necessary to recommend to the student to be careful with the trunks of the vi-dian and sixth pair, which, once destroyed, will not permit us to see the filets in question.

The student should not be discouraged, when, after having reached the preparation of that portion of the trisplanchnic, situated in the abdomen, this nerve seems to disappear; it will always be found somewhat lower down, but it requires patience and time.

Having arrived below the first rib, it dips down deeply into the chest, and applies itself on the tuberosity of the ribs. It will be necessary to raise the lungs, the liver even, and also the intestines; they should be carried to the side opposite to that on which we study this nerve; the cavity of the chest and abdomen must consequently be exposed, and we must remove the fold of the pleura by which this nerve is immediately covered. Towards the fourth, fifth, or sixth vertebra we should notice a sort of division of this nerve into two remarkable branches, one of which, the larger, passes on the bodies of the vertebræ as far as the last dorsal, where it terminates by forming the *semi-lunar ganglion*; the other, smaller, terminates in the kidneys, under the name of *small splanchnic*. After having examined this distribution we must return to the semi-lunar ganglion, and free it from the cellular tissue which unites it to the neighboring parts; we must follow cautiously the twigs furnished by this ganglion; it will not be difficult to trace them if we have a tolerable acquaintance with ange-ology, for these numerous twigs form, around the arteries of the principal organs of the abdomen, species of interlace-ments known under the name of *plexuses*: it will suffice

therefore, to take the arteries at their origin, and follow them to the organ on which they are distributed, being careful to preserve the white filets which accompany them, and which are furnished by these plexuses. The origin of the cæliac trunk demands especial attention, for the filets are very numerous there, and the network which they form, known as the *solar plexus*, appears to give birth to all the others, which it will then be necessary to follow.

After we have seen the distribution of the two splanchnics, we remove every thing that is found in the chest and abdomen, in order to proceed at our ease with what remains of the intercostal; it will be found sometimes higher up, sometimes lower down; it then approximates more and more to the vertebral column, applied immediately on the bones that form it; it may be pursued in this way into the pelvis, in attending to the same precautions to which we have already alluded: in fine, it disappears in this osseous cavity, without our being able to assign to it any precise termination; but in the preparation of the trisplanchnic we should not limit ourselves to those operations which would be necessary for us to study it in an isolated manner, and as if this nerve had no relation with adjoining ones. There are, on the contrary, continual and very numerous connections from its origin to its termination. We should, therefore, not abandon the great sympathetic without having seen, along the vertebral column, the filets furnished to this nerve by the cervical, dorsal, lumbar, and sacral pairs, and which, by their union with the sympathetic, give rise to renflemens known as the dorsal, lumbar, and sacral ganglions.

NERVES OF THE SPINAL MARROW,—CERVICAL,—DORSAL,
LUMBAR AND SACRAL.*Anatomical Preparation.*

These are the most difficult nerves to prepare, especially the first pair, which requires considerable patience, and a certain portion of skill in dissection; but there is nothing which cannot be accomplished by continued assiduity. The student, in commencing the study of these nerves, should be apprised that they divide, at their exit through the spinal foramina, into two branches, one anterior, and the other posterior; that the posterior is much less considerable, and presents less interest than the anterior; that all the posterior branches are lost in the muscles of the posterior part of the trunk, and that they do not present the same difficulties in their preparation as the anterior.

The first cervical pair requires us to remove or separate the sterno-mastoid muscle at its superior part, and expose the space comprised between the transverse apophysis of the first cervical vertebra, and the mastoid apophysis of the temporal bone: this preparation likewise requires that we remove a part or totality of the anterior straight muscle of the neck, of the lateral and superior oblique of the head; it is in the most profound part of this space that we find the first cervical pair. Its distribution can now be followed without much trouble, especially if we do not hurry; the other cervical pairs are infinitely less difficult, on account of their size, which is more considerable, and of their situation which is less concealed; we shall arrive at them the more easily if we have been exact in removing the sterno-mastoid muscle, as well as the scaleni which partly cover them.

In following the external border of the sterno-mastoideus, and seeking the interval between each vertebra, we will

find without much difficulty the trunk of the other cervical pairs; and leaving for a moment the anterior branches, we should pursue the posterior, which, as has already been remarked, lose themselves entirely in the muscles of the posterior part of the neck and back; a description of them will convey a still better idea of their distribution. As to the dorsal, lumbar, and sacral pairs, their preparation rests on the same principles, and requires the same precautions. It is only the brachial, lumbar and sacral plexuses that require much detail. We shall speak of them farther on.

Description.

GREAT INTERCOSTAL OR SYMPATHETIC.

(*Trisplanchnic.*)

Situation.—On the anterior and lateral portions of the whole vertebral column and sacrum.

Extent.—From the environs of the external orifice of the carotid canal to the inferior part of the sacrum.

Direction.—Parallel to the vertebral column.

Relations.—In the neck, this nerve is placed immediately on the anterior straight muscles of the neck, behind the carotid artery, and on the internal side of the eighth and ninth pair; in the chest, it is placed in front of the posterior extremity of the ribs, behind the pleura, and is covered by the mass of the lungs; in the abdomen, it approximates the vertebral column, on the lateral portions of which it is situated, concealed by the intestinal packet; in addition, the trisplanchnic, on the right side, is covered by the inferior vena cava, and, on the left, by the aorta; in the pelvis, this nerve reposes on the sacrum, on the one part, and corresponds to the rectum, on the other.

Divisions.—Into cervical, thoracic and abdominal portions.

1st, *Cervical portion*.—It commences above by the superior cervical ganglion, the extent of which equals about three fingers' breadth. Its superior part receives or gives off filets, which go to the sixth and fifth cerebral pairs; its inferior part is continuous with the common trunk, which, arrived on a level with the fifth cervical vertebra, forms the middle cervical ganglion, which is much smaller than the preceding one, and is sometimes wanting; at a short distance from it and near its entrance into the chest, the trisplanchnic gives birth to a third ganglion, called inferior cervical; in all this trajet, this nerve furnishes numerous twigs from its anterior, posterior, internal, and external parts, some of which anastomose with similar ones given off by the eighth, ninth, and glosso-pharyngeal; the others aid in forming the cardiac, pulmonary, and cervical plexuses; and there are others again, which proceed backwards and anastomose frequently with the anterior branches of the cervical pairs.

2d, *Thoracic portion*.—It commences below the inferior cervical ganglion, and terminates when the trisplanchnic passes through the diaphragm; in this course, this nerve receives from each dorsal pair a twig, which increases its size, and appears to determine, in this place, the formation of a small ganglion. At the root of the lungs, there are some filets which pass on the divisions of the pulmonary artery, and form the pulmonary plexus; lower down, and on a level with the fifth dorsal vertebra, the trisplanchnic affords origin to a long cord (the great splanchnic) which proceeds from above downwards and from without inwards, in order to pass between the pillars of the diaphragm, and lose itself immediately below, in a reddish body, of a crescent shape, called semi-lunar ganglion. Somewhat lower down there arises a nerve nearly similar to the preceding (the small splanchnic) which goes from the chest to the abdomen,

passing on the external side of the pillars of the diaphragm and loses itself in the renal plexus.

3d, *Abdominal portion*.—After giving off these two nerves, the trisplanchnic seems to disappear, and again shows itself on the vertebral column, approximating more and more to that of the opposite side, in order to pass together into the pelvis, and terminate at the inferior part of the sacrum; in the whole of this course, the anterior branches of the lumbar and sacral nerves each send a twig to the trisplanchnic for the formation of a ganglion, much larger than in the chest.

The largest of all is that in the abdominal cavity, below the diaphragm, called the semi-lunar; its figure is that of a crescent, the convexity of which is below and the concavity above. From this ganglion go off a quantity of very delicate filets which pass to the aorta, cœliac trunk, and superior mesenteric, forming a large plexus, called *solar*. The divisions of this plexus proceed to all the viscera of the bas-ventre, following the divisions of their principal arteries, and forming numerous additional plexuses, whence are given off new divisions, which penetrate the organs supplied by these arteries.

VERTEBRAL NERVES.

The spinal marrow furnishes, from its lateral portions in the whole extent of the vertebral canal, on a level with the spinal foramina, two nervous trunks, which soon divide into two branches, the one anterior, and the other posterior; their absolute number is thirty-one pairs,—eight cervical, twelve dorsal, five lumbar, and six sacral.

First cervical pair.—It arises between the occiput and first cervical vertebra. After leaving the vertebral canal, it divides into two branches, one of which is anterior

and the other posterior. The posterior proceeds backwards and divides into three twigs, which lose themselves in the neighboring parts: the anterior passes behind the vertebral artery, then turns on the transverse apophysis of the first cervical vertebra, in order to form with the anterior branch of the second, a nervous pulp, which embraces the base of this apophysis, and from which pass off filets to the great sympathetic, the eighth and ninth pairs.

Second cervical pair.—It passes out between the first and second cervical vertebræ, and divides, like the preceding, into two branches, one of which is posterior, and proceeds to the muscles of the posterior part of the neck; the other is anterior, and is divided into three twigs, which lose themselves in the eighth, ninth, and trisplanchnic nerves. One of its twigs ascends towards the transverse apophysis of the first cervical vertebra, in order to form the pulp, of which we have spoken.

Third cervical branch.—It does not differ from the two preceding pair, as regards its origin and principal distributions.

Fourth cervical pair.—Besides its conformity in origin and distribution with the three preceding, the fourth gives rise to a nerve, which proceeds downwards and reaches the diaphragm under the name of diaphragmatic or phrenic nerve.

This nerve derives its principal origin from the fourth cervical pair, descends along the neck, passes between the subclavian artery and vein, penetrates the chest, places itself in the interval of the mediastinum, and travels on the diaphragm in the substance of which it is lost.

The first cervical pairs, with the exception of the first, unite in order to form the cervical plexus, the numerous divisions of which proceed towards the integuments of the lateral portions of the neck.

Fifth, sixth, seventh, eighth cervical pairs, and first dorsal.—These five pairs of nerves present traits of resemblance which are not found in the others; all have a posterior branch, like the preceding, the distributions of which are remarked in the muscles of the posterior and superior part of the back; but their anterior branches have for their chief object the formation of the brachial plexus, whence arise the nerves of the superior extremities.

The following eleven dorsal pairs present a similar origin and distribution. Their posterior branch loses itself in the muscles of the posterior part of the trunk: the anterior branch, after having given communicating twigs to the trisplanchnic, furnishes a large branch which places itself in the interval of the ribs, the whole length of which it traverses, marching parallel to their inferior border; another branch, less voluminous, and which may be called external, pierces the intercostal muscles, in order to distribute itself on the anterior part of the chest.

Lumbar pairs.—Five in number: the first passes out between the first and second lumbar vertebræ, and the fifth between the last vertebra and sacrum. These nerves arise from the spinal marrow, on a level with the last dorsal and first lumbar vertebræ, by two fasciculi of filets, which are very broad, and pass obliquely downwards in order to pass out of the vertebral canal, in such a way as to be very remote from the place of their origin. The four last form a part of the fasciculus, called the cauda equina. All these pairs send off behind a branch, which loses itself in the muscles of the posterior and inferior part of the trunk; their anterior branches, with the exception of the last, contribute to the formation of the crural plexus: independently of this remarkable distribution, the anterior branches of the lumbar nerves send off many other twigs,

some of which communicate with the great sympathetic, and the others lose themselves in the psoas muscle and neighboring parts.

Sacral pairs.—They are six in number : the first passes out between the first and second pieces of the sacrum, and the last through the notches observed on the lateral and superior portions of the coccyx. The size of these nerves, which is considerable in the first pair, continues to diminish to the last. They arise by two fasciculi of filets, descend perpendicularly down the vertebral canal, and form, with the last lumbar pairs, what is termed the *cauda equina*. Of the two branches furnished by each sacral pair, the anterior is considerable, and the posterior very small. The first, in all the sacral pairs, sends a communicating filet to the trisplanchnic, and contributes, in the first, second, third and fourth, with the two last lumbar, to the formation of the sciatic plexus. In addition, the anterior branch of the third and fourth sacral, furnishes some twigs to form the hypogastric plexus, a nervous interlacement difficult to describe, the ramifications of which proceed to the inferior part of the rectum, to the bladder, uterus and vagina.

The posterior branches of the sacral nerves lose themselves in the soft parts on the posterior portion of the pelvis.

BRACHIAL PLEXUS, AND NERVES OF THE SUPERIOR EXTREMITIES.

Anatomical Preparation.

The operations performed in the study of the eighth pair (pneumo-gastric,) trisplanchnic, cervical and dorsal pairs, have exposed in part the brachial plexus : we have only to continue the preparation of this plexus ; in the contrary case, we should remove the clavicles, and even the first

rib, free the space, comprised between these objects and the axilla, of all the superficial soft parts which conceal it from our researches ; we should preserve the axillary artery and vein, the march of which, at this place, is through the inextricable network formed by the brachial plexus : in this way, we shall be enabled to see without difficulty the branches which form it, as also those which pass off under the arm pit, in order to go to the different parts of the superior extremity. For this, it will be necessary for us to lay open the integuments as far as the fold of the arm, and to separate their flaps in proportion as we pursue the nerves to the inferior parts. We should be careful not to embrace the remarkable branches, which lose themselves in the proper tissue of the integuments inwardly and outwardly. The muscles of the arm must be dissected in order to follow more advantageously the nerves which traverse them or travel in a direction parallel to their length. When this is accomplished, we should endeavor, before passing to the particular dissection of the nerves of the arm, to recognise them at their origin, and to assign to each the rank and place it occupies, so that they may not be confounded by mistaking one for the other.

The brachial plexus at first sends off towards the anterior part of the chest several inconsiderable filets, under the name of thoracic nerves : posteriorly, it gives off another, somewhat larger, which goes to the scapula, and is called supra-scapular ; it then furnishes six remarkable branches, through which passes the axillary artery.

Four of these nerves are placed in front of the artery and two behind it. The four first are, commencing from within outwards, the internal cutaneous, cubital, median and external cutaneous ; the two last are the radial and axillary or articular. But in the study of these nerves, it is

much better to commence with the two cutaneous, then pass to the median, and terminate with the cubital. It is not until after this examination, that we should occupy ourselves with the radial, and afterwards with the axillary.

The two cutaneous nerves lose themselves almost entirely on the internal part of the integuments of the arm and forearm; we must necessarily dissect these latter in their whole extent, in order to pursue the numerous filets of the two cutaneous branches; the median will be recognised by its size, the place it occupies in the midst of the others, and by its termination, which takes place on the four first fingers. We will likewise observe that the median does not furnish any branches down to the fold of the arm. The cubital, destined for the two last fingers, travels along the internal part of the arm, and places itself behind the internal tuberosity of the humerus. Nothing is easier than the dissection of these nerves, when we have properly recognised their origin; it would only consume unnecessarily the time and patience of the student to indicate to him minutely the mode of preparing each of the nerves of the arm. I think, therefore, that I may dispense with this, and proceed immediately with their description.

Description.

NERVES OF THE SUPERIOR EXTREMITIES.

Four nerves are placed in front of the axillary artery, and two behind it. The internal cutaneous, musculo-cutaneous, median and cubital, form the anterior plane; the radial and axillary, the posterior plane; we must add to these the thoracic nerves, and the supra-scapular.

THORACIC NERVES.

Situation.—On the lateral and anterior parts of the chest.

Extent.—From the brachial plexus to the chest.

Direction.—From without inwards, and above downwards.

Relations.—Always covered by the integuments, they recede from the plexus, by passing, some before and others behind the axillary artery, in order to reach the muscles of the chest.

Divisions.—They form three branches, an anterior which loses itself in the great and small pectoral muscles; a middle for the great serratus, and a posterior for the latissimus dorsi.

SUPRA-SCAPULAR NERVE.

Situation.—On the superior part of the shoulder.

Extent.—From the brachial plexus to the superior and posterior part of the scapula.

Direction.—Oblique from before backwards, and from above downwards.

Divisions.—From the superior part of the brachial plexus, it proceeds backwards, reaches the notch remarked on the superior border of the scapula, and divides into two branches, which lose themselves in the infra-spinatus, subscapularis and teres minor muscles.

INTERNAL CUTANEOUS NERVE.

Situation.—On the internal part of the integuments of the arm and fore-arm.

Extent.—From the brachial plexus to the environs of the carpus.

Direction.—Parallel to the internal portion of the arm and fore-arm.

Relations.—Covered by the integuments of the internal part of the arm, on the one hand; and, on the other, applied on the neighboring muscles, almost always accompanied by the basilic vein.

Divisions.—Into two branches, the one external, which travels parallel to the internal border of the biceps, and loses itself on the anterior part of the fore-arm; the other, internal, is more considerable, and descends along the internal part of the arm and fore-arm; it expends itself on the integuments of these parts.

MUSCULO-CUTANEUS NERVE.

Situation.—On the anterior part of the arm, and external of the fore-arm.

Extent.—From the brachial plexus to the carpus.

Direction.—Oblique from above downwards, turning from within outwards on the superior extremity.

Relations.—From its origin it pierces the coraco-brachialis muscle, then passes between the biceps and brachialis anterior, in order to place itself, like the preceding, between the integuments of the anterior and external part of the arm and fore arm, and the neighboring muscles.

Divisions.—In its course, it sends, first, a filet to the median nerve, then it gives several to the coraco-brachialis, and biceps; it expends itself, by numerous divisions, on the integuments of the external and posterior part of the fore-arm.

MEDIAN NERVE.

Situation.—On the anterior and middle part of the arm, fore-arm and hand.

Extent.—From the brachial plexus to the inferior part of the four first fingers.

Direction.—Parallel to the superior extremity.

Relations.—On the arm, this nerve descends between the brachial artery, within, and the biceps without; on the fore-arm, it is placed on its middle portion, and, dipping down somewhat between the muscles of this region, it passes under the annular ligament of the carpus, places itself be-

tween the tendons of the sublimis and those of the profundus, and becomes sub-cutaneous in the rest of its extent.

Divisions.—1st, It does not give off any ramifications as far as the fold of the arm: below, and even in the palm of the hand, it furnishes a number of twigs to the muscles of the fore-arm; 2d, arrived at the superior extremity of the metacarpal bones, it divides into five branches, which are destined for the external and internal sides of the four first fingers, except the fourth, on the internal side of which it does not give off any branch; this is supplied by the cubital. Each of these branches divides into two twigs, except the first, which loses itself in the muscles of the thenar eminences.

CUBITAL NERVE.

Situation.—At the internal part of the arm, internal and posterior of the fore-arm.

Extent.—From the brachial plexus to the fourth and fifth fingers.

Direction.—From above downwards, turning on the posterior part of the fore-arm.

Relations.—It descends in the first place attached to the internal part of the triceps brachialis, passes behind the tuberosity of the humerus, between this eminence and the olecranon, turns on the anterior and internal part of the fore-arm, placed between the cubital and profundus, at the internal part of the cubital artery, and then reaches the palm of the hand, in passing between the annular ligament and integuments.

Divisions.—1st, In its course, it furnishes only a few inconsiderable twigs to the neighboring muscles; 2d, arrived within two inches of the carpus, it sends off a considerable branch, which goes to the back of the hand, and divides into two twigs for the little finger, ring and middle fingers;

3d, having reached the palm of the hand, the cubital divides into two branches, a profound one for the inter-osseous muscles, and a superficial one for the little finger, ring and middle fingers.

RADIAL NERVE.

Situation.—On the whole posterior part of the superior extremity.

Extent.—From the brachial plexus to the posterior part of the four first fingers.

Direction.—Parallel to the superior extremity, in turning around the humerus from above downwards, from before backwards, and from within outwards.

Relations.—Immediately after its origin, it proceeds, posteriorly, between the three portions of the triceps and humerus; it then passes between the supinator longus and brachialis anterior, and divides into two branches.

Divisions.—1st, It gives off first some twigs for the triceps brachialis; a little lower down, it furnishes a branch destined for the integuments on the posterior part of the fore-arm, and which descends to the environs of the carpus; 2d, arrived at the superior extremity of the radius, it divides into two branches, one posterior, which descends very low down, and loses itself in the soft parts on the posterior portion of the fore-arm; the other, anterior, is destined principally for the external and internal sides of the four first fingers.

AXILLARY NERVE.

Situation.—In the hollow of the axilla.

Extent.—From the brachial plexus to the muscles of the shoulder.

Direction.—Oblique from before backwards, and from above downwards.

Relations.—Placed at first under the sub-scapular mus-

cle, it afterwards dips down between the great and small teres, and turns on the superior part of the humerus, covered by the long portion of the triceps.

Divisions.—Into numerous twigs for the muscles of the shoulder.

LUMBAR PLEXUS.

Anatomical Preparation.

It is behind the psoas muscle that we find this plexus, which is formed by the anterior branches of the four first lumbar pairs. It will suffice, therefore, to dissect this muscle with care, and to separate it, from within outwards, from the vertebral column, without detaching it, in order that we may perceive the more easily the lumbar plexus, which is much smaller than the brachial, and the preparation of which is likewise less difficult. Two nerves only part from this plexus: these are the obturator and crural. They are observed at first to travel along the psoas muscle, partly concealed by it: when they are once disengaged from the muscle, we can easily follow them until the moment at which each of them proceeds to its particular destination. The crural must be dissected and studied the first, the obturator being entirely concealed by two divisions of the crural.

In proceeding with some caution, we will readily pursue the divisions of the crural, because they are superficial, and expend themselves on the muscles, the position and relations of which are known.

The obturator, arrived in the environs of the sacro-iliac symphysis, descends slightly in the pelvis and places itself on the bones of this cavity, the contour of which it pursues as far as the obturator foramen. Its preparation, during this course, does not present any difficulty: but when it has traversed the obturator foramen, it is

profoundly concealed by the superficial muscles of the thigh. We should, therefore, dissect these muscles; and commence with the trunk of the obturator at its exit through the foramen of the same name, and follow its divisions, which proceed to the muscles on the internal part of the thigh.

Description.

CRURAL NERVE.

Situation.—On the internal part of the thigh.

Extent.—From the lumbar plexus to the inferior and internal part of the leg.

Direction.—Parallel to the internal portion of the inferior extremity.

Relations.—In the abdomen, it is concealed by the psoas muscle, and becomes sub-cutaneous along the internal part of the inferior extremity.

Divisions.—Into superficial and profound twigs. The first distribute themselves on the integuments of the internal part of the thigh and leg; the second may be distinguished into external, which lose themselves in the muscles of the superior and external part of the thigh; and into internal, which accompany the crural artery, among which, one more considerable than the others, under the name of saphena, becomes sub-cutaneous, accompanies the vein of the same name, and loses itself on the internal part of the back of the foot.

OBTURATOR NERVE.

Situation.—On the internal and superior part of the thigh.

Extent.—From the lumbar plexus to the adductor muscles of the thigh.

Direction.—Parallel to the psoas muscle.

Relations.—In the abdomen, it corresponds to the internal side of this muscle, and is found in the pelvis, between

the obturator artery, which is superior to it, and the vein of the same name, which is inferior to it: out of the pelvis it is situated between the pectineus and first adductor.

Divisions.—Into anterior and posterior branches, which lose themselves in the adductor muscles.

SCIATIC PLEXUS.

Anatomical Preparation.

The sciatic plexus, one of the largest in the human system, is observed on the sides of the excavation of the pelvis. Its volume, and the size of the branches which form it, will cause it to be easily recognised. I shall, therefore, merely remark in this place, that we should separate one of the inferior extremities from the other, in order to expose this plexus completely. The section necessary for this operation does not differ from that, which we indicated for the preparation of the hypogastric artery. Once freed from the soft parts which cover it, we will readily perceive it at the posterior part of the thigh. To follow its trunk and numerous divisions will not be difficult for the student who has been zealous and careful in his previous dissections.

Description.

The sciatic plexus furnishes first the pudic and small sciatic nerve. The first passes out under the pyramidal muscle, proceeds between the two sacro-sciatic ligaments, with the internal pudic artery, and divides into two branches, which lose themselves in the organs of generation.

The small sciatic nerve passes out of the pelvis, below the pyramidal muscle, with the great sciatic, on the external side of which it is situated. It then proceeds to the gluteus maximus, and divides into two branches, one of

which goes to the perineum, and the other descends along the posterior part of the thigh and leg, in order to lose itself in the integuments of these regions.

GREAT SCIATIC NERVE.

Situation.—On the posterior part of the thigh.

Extent.—From the sciatic plexus to the hollow of the ham.

Direction.—Parallel to the posterior part of the thigh.

Relations.—At its exit from the pelvis, this nerve is situated in front of the gluteus maximus, and behind the gemelli and quadratus muscles; a little lower down, it is found behind the third adductor, in front of the long portion of the biceps and of the neighboring part of the semitendinosus; in the hollow of the ham, the aponeurosis of the *fascia lata* and integuments alone cover it.

Divisions.—1st, Into twigs, which lose themselves in the muscles on the posterior part of the thigh; 2nd, At a few fingers' breadth above the ham, it divides into two large branches, which bear the names of external sciatic popliteal, and internal sciatic popliteal.

EXTERNAL SCIATIC POPLITEAL.

Situation.—On the external posterior part of the leg.

Extent.—From the hollow of the ham to the superior part of the toes.

Direction.—Parallel to the leg, in turning round this part, from behind forwards, on its external side.

Relations.—Below the ham, it is placed between the long portion of the biceps and external gemellus, and more outwardly between the fibular and long lateral peroneal muscle.

Divisions.—1st, Into inconsiderable twigs, which are

lost in the neighboring parts; 2d, Towards the superior extremity of the fibular, it divides into two branches, one external, called the musculo-cutaneous nerve, which expends itself on the integuments of the leg by filets, which turn around this part, from without inwards, and which terminate on the back of the foot; the other, internal, is called anterior tibial, and follows the trajet of the tibial artery; it divides on the back of the foot into two branches, one of which passes on the external side of the foot, and the other on the internal.

INTERNAL SCIATIC POPLITEAL.

Situation.—On the posterior and internal part of the leg.

Extent.—From the hollow of the ham to the arch of the calcaneum.

Direction.—Oblique from above downwards, and from without inwards.

Relations.—In the hollow of the ham, it is placed behind the popliteal vessels, and on the external side of the semi-membranosus; below, it passes between the articulation and gemelli muscles; still lower down, it gets between the popliteus and soleus, and descends along the posterior part of the tibia, under the name of posterior tibial nerve, which continues to proceed to the inferior part of the leg in order to reach the arch of the calcaneum; it divides into branches called plantar, distinguished into internal and external. In its course the internal sciatic popliteal gives off numerous twigs to all the parts which surround the superior extremity of the leg; among these, there is a considerable one, called external saphena, which accompanies the vein of the same name, and loses itself on the external and superior part of the foot.

Internal plantar nerve.—It is larger than the external, and proceeds directly from behind forwards; it is placed above the adductor of the great toe, on the side of the tendon of its long flexor, and soon divides into four branches, destined for the four first toes; they are distributed in the same manner as the arteries of these parts.

External plantar nerve.—This proceeds obliquely from behind forwards, and from within outwards, between the short flexor of the toes, and the accessory of the long flexor; it soon divides into two branches, one profound, which supplies the muscles of the sole of the foot, and the other superficial, destined for the two last toes.

LYMPHATIC VESSELS.

SEROUS DUCTS, LYMPHATIC VESSELS.—ABSORBENT VESSELS.

General Considerations.

The part of anatomy concerning the lymphatic vessels is, without doubt, that which is involved in most doubt and uncertainty as regards its mode of preparation and study. This must be attributed to the extreme smallness of the vessels, which contain the lymph; as well as to the pellucid character of their parois, which will not permit us to penetrate them by the injection of materials proper to demonstrate their existence, and to enable us to pursue them at a distance. The easy evaporation of the fluid, which the lymphatic vessels contain during life, likewise becomes an obstacle to their dissection. The means generally employed in the preparation of the lymphatic system are: 1st, to follow with the naked eye, or with the aid of some in-

strument, the vessels of this system, without any other guide than the uncertain course of their numerous divisions: 2d, to cause, by the sole law of gravity, certain colored fluids, such as water, milk, tallow, fat, a solution of gum, or mercury, to enter some one point of the economy, whence it is supposed that this metal will be gradually introduced into all the ramifications of the lymphatic system; 3d, to plunge a viscus, a separated limb, or any other part distinct and isolated from the rest of the body, into a colored liquid, possessing a moderate heat. The liquid gradually penetrates by this sort of maceration, through the tissue of the piece, insinuates itself into all the parts, and fills equally the lymphatics of the piece on which we are about to study them.

If it were possible to recognise, by characters drawn from their form and structure, the lymphatics wherever they were met with, there is no doubt that the first mode of preparing them would be preferable. We would at least, by this process, have the certainty of not mistaking other parts for the lymphatic vessels; and we would be enabled to pursue them where it is even supposed they do not exist. This mode of preparation would have still another advantage, which we enjoy in the examination of the nerves, viz. we would be enabled to study the lymphatic system in its ensemble, in commencing with one or more common centres, in order afterwards to pass to their respective divisions. These inconveniences have induced the use of mercury, which is introduced into some determinate point on the external surface of the body, deprived of its integuments, in order to make it penetrate the lymphatic vessels, which are found in the course of the metal. We may aid the progressive march of the mercury, and its passage into the greatest number of branches, either by pushing it

through their calibre by some mechanical force or in suspending the part so that the mercury, obedient to the laws of gravity, will introduce itself by its own weight into the vessels which we wish it to penetrate. This latter mode is the more expeditious; and, in supposing the possibility or certainty of its passage into all the neighboring lymphatics, we may then, by an attentive dissection, follow the vessels filled and enlarged by this metal. It will be observed that they dilate more considerably in the intervals of the valves; hence result those nodosities, which serve as a guide to distinguish them from other vessels equally delicate. Several inconveniences follow this mode of preparing the lymphatics. In the first place, by this method we can inject only an isolated portion of the lymphatic system; and moreover, besides that the mercury swells these vessels considerably, it likewise frequently ruptures them, and thus produces great confusion.

It is for the purpose of avoiding, in part, the derangement produced by the mercury, that many content themselves with plunging into some colored fluid the pieces on which they are about to examine the lymphatics.

However, it cannot be denied that the injection of mercury presents great advantages; thus, this latter mode is preferable for the extremities, whilst the naked dissection is better suited to the lymphatics of the trunk and head, or when we wish to examine these vessels in an isolated piece, after having plunged them, as has already been remarked, into some proper fluid.

The lymphatic system presents, in all the parts of the body, and at distances more or less approximated to each other, species of knots or lymphatic plexuses, to which has been given the name of glands, and which are a common ren-

deztous for the neighboring lymphatics. These parts, distinct and of a certain size, may be easily perceived, either by simple dissection, or by the aid of mercury, which, from the vessels, passes to the common centre, or by immersion in water. However, in order to have a good view of the lymphatic glands, we must necessarily choose a young subject. There is no species of organ, the volume and developement of which vary so much according to age. Infancy is the only period, in which all the glands are well marked. In manhood, they diminish in number; in old age, they are to be found only in the extremities of the limbs.

It is for these different reasons that it is indispensable to select a subject, in which we propose to study the whole or a part of the lymphatic system. We may likewise add, that there is no branch of anatomy in which this precaution is so necessary as in the study of this system.

The cadavera of infants, those of females, or those of emaciated individuals, are in general the best suited for this examination. We may likewise employ with advantage children that have died with some obstruction, with scrofula, or with a venereal disease in which there has been a prodigal use of mercury.

It now remains for me to say a word in reference to the manner of exposing the *ensemble* of the lymphatic system, and proceeding to its dissection. This will differ according to the parts we wish to study, for there are some which do not require any dissection, properly so called.

The lymphatics of the abdomen are easily exposed, and become sufficiently apparent, by injections pushed into the belly of an animal, either living or recently dead, without requiring the aid of dissection. We may say the same

thing of the large viscera, when they have been plunged into colored warm water for a sufficient length of time to allow their lymphatics to be penetrated with it.

Such, however, is not the case with the lymphatics of the extremities, which may be in part followed by the naked eye, when they have been injected with mercury, but which it is necessary to dissect in order to get an exact idea of them.

We cannot insist too much on the delicacy of the instruments, the course of which must be directed by means of glasses.

But of all the parts of the lymphatic system, there is none more important to understand than the large trunk known as the thoracic duct.

It is well known that there exists on the whole surface of the alimentary canal, and its dependencies, an order of vessels called lacteals; that these vessels proceed ultimately to a species of *empoule*, observed in the environs of the pillars of the diaphragm, and which is the origin of the thoracic duct, situated to the right of the aorta, and behind the renal vessels. The varieties of the thoracic duct are very numerous; two or three are sometimes found, which communicate together by a great number of small vessels, arranged cross-wise, but which unite in a common trunk.

In order to see the course pursued by the chyle, and to expose the vessels which carry it, it will be necessary to lay open the abdomen of a living animal, which has eaten two or three hours previously. We may, in order to render the thing more sensible, after having fed a dog, for example, give him at one time a large quantity of milk, and open him immediately afterwards. We may likewise color the food, and even the milk. In order that the lac-

teal vessels and thoracic duct should not empty themselves, it will be necessary to place ligatures on them: cold weather, which condenses the fluids, is also very favorable for these kind of researches.

We can even inject the thoracic duct with colored materials, such as tallow, gum, &c. We should take it above the opening of the diaphragm, in front of the lumbar vertebræ. It is at this point that we must introduce the tube of a small syringe, filled with the liquid in question, which will be carried without difficulty in the whole extent of the thoracic duct.

It is the same with regard to the lymphatic trunk of the right side. We inject it through branches, which are found sufficiently large for this purpose in the axilla, between the great and small pectoral muscles, and on the sides of the neck.

I shall now pass to the exposition of the lymphatic system.

SUMMARY EXPOSITION OF THE LYMPHATICS.*

The lymphatics or absorbents are small, delicate, pellucid, membranous vessels, which, taking *lymph* to all the surfaces, in all the cavities, bring it back to the general centre of the circulation, and form a particular system, distinct from the other vessels, by their origin, course, termination, action, and uses. They arise by radicles or small cylindrical canals, which open on the surface of the membranes, hollow organs, splanchnic, cellular, areolar cavities, and there form *pores*, villosities, which, by their alternate action of dilatation and contraction, take up the

* A great part of this general matter is extracted from the lectures and works of Professor Chaussier.

fluids which touch their orifices, and are thus the organs of absorption.

These absorbing radicles, which are so near together and of such remarkable tenuity, that they escape the naked eye, assemble by fasciculi, unite by collateral ramusculi, and by frequent and reciprocal anastomoses, whence results a very delicate net-work, from which are given off branches which, after having passed under the integuments and tunics of the viscera, into the laminæ of cellular tissue which separates the different layers of muscles, and affords an envelope to the nerves and sanguineous vessels, unite successively and form branches which enlarge in their course, in consequence of the number of small twigs which proceed to them.

The lymphatics, thus formed by the successive re-union of different branches, accompany almost all the veins, and, like these, are directed towards the general centre of circulation; but, 1st, They are not numerous; in a word, besides that each vein is accompanied by several lymphatics, we observe throughout two planes of them, distinct by their position; some are superficial, subcutaneous, and are distributed under the integuments; the others, profound, inter-muscular, are disseminated in the tissue of the organ, and in the interstices of the muscles; 2d, They anastomose frequently among themselves; thus, in one part, the superficial lymphatics communicate with the profound, the superior with the inferior, those of the right with those of the left side—an arrangement which affords several different routes to the lymph in its course; 3d, In their trajet they always form, either plexuses or glandiforme agglomerations, more or less voluminous, which are called conglobate or lymphatic glands.

These glands which constitute an essential part of the lymphatic system, are produced by the assemblage of different lymphatic branches, which, in approximating each other, divide, interlace, turn on themselves, unite together, become confounded in different parts, and form, in their *plicatures*, in their different windings, contractions, alternative dilatations which have the appearance of cells or separate vesicles, and produce anew other branches, less numerous but larger, which pass upwards and continue towards the general centre of circulation; a very delicate cellular tissue unites and sustains this lymphatic ganglion; it is covered by a membrane, which preserves its form. Finally, sanguineous vessels are observed on its surface, penetrate its interior, and are distributed there by ramusculi of extreme delicacy, which appear to furnish a secretion. The form, volume, consistence, and color of these lymphatic glands or ganglions, differ very material according to the age, situation, and condition of the parts; their number is very considerable, they amount to at least six or seven hundred, but are not equally distributed all over the body; in the limbs, they are not numerous, and are separated by considerable intervals; in the neck, thorax, and abdomen, they are multiplied, approximated, and even heaped on each other in some places; they are all connected together by lymphatic plexuses, which are elevated above each other and form a continued series.

These different glands have been designated by names derived from their situation; the principal are in the abdominal extremities, three or four popliteal glands, from eight to ten inguinal, some of which are superficial, and the others profound; in the abdomen, there is a numerous series of glands, arranged around the aorta and

abdominal vena cava ; on the bodies of the lumbar vertebræ, eight or ten iliacs, which, on the one hand, are attached to the inguinal, and, on the other, to the lumbar ; there are more than a hundred mesenterics, about sixty mesocolics, a series of small sub-hepatics, splenics and pancreatics, which are connected with the mesenterics ; six to ten gastrics, arranged on the curvatures of the stomach ; finally, in the cavity of the pelvis, there is a score of pelvic glands which are attached to the iliacs, lumbar, and mesocolics. In the thorax, a series of dorsal glands, which, on the one hand, are connected with the lumbar, and, on the other, to that of the neck ; twelve intercostals on each side ; some diaphragmatics, mediastins, sub-sternal, which are united to each other ; a great number of bronchial, pulmonary glands, situated among the divisions of the bronchiæ, on the circumference, and at the summit of the lungs ; several cardiacs situated under the arch of the aorta ; on the head and neck, two or three mastoidean, parotidean, sub-zygomatic, maxillary, and sub-lingual ; a numerous series of trachelian glands, and some cervical ; finally, in the thoracic extremities, four or five humero-cubital, six or eight axillaries, some supra-scapular and subclavians, which, by their plexuses, are united to the sub-sternal, dorsal, and especially to the trachelian. It is after having passed by one or several series of these glands, and having formed plexuses, and successive re-unions, that the lymphatics, which arrive from the different parts, all meet in a manner more or less direct, at two principal vessels, which, by their disposition, and size, correspond in some manner to the two venæ cavæ ; they are the trunks of all the lymphatics, and the general depot for all the lymph.

One of these trunks, the longest, and most considerable

discovered by Pecquet, in 1649, is called the thoracic duct, or left trunk; it arises on the body of the third lumbar vertebra, by the successive re-union of the lymphatics, which come from the abdominal extremities, pelvic viscera, and from nearly all those of digestion; it passes into the thorax, is situated on the bodies of the vertebræ, and traverses the whole extent of this cavity, inclining somewhat to the left; it then elevates itself on the trachelian surface of the neck, and terminates, by opening into the subclavian portion of the left brachial vein; this canal, so remarkable for its extent, situation, and direction, and which presents such numerous varieties in its origin, course, and termination, receives the greater number of the lymphatics of the thorax, and all those of the left side of the head, neck, and left arm.

The other trunk, indicated by Stenon, is very short and small; it is called the right trunk or brachio-cephalic; it is situated obliquely to the right on the trachelian apophysis of the [six or seventh cervical vertebra, and empties into the subclavian portion of the right brachial vein; this trunk, which has several anastomotic connections with the trachelian extremity of the thoracic duct, receives the lymphatics of the right side, of the head, neck, those of the right arm, and some which come from the thorax and liver.

In order to appreciate the particular disposition of the different lymphatics, and in order to draw inductions applicable to the knowledge of the phenomena of health and disease; we should consider, in each part, their number, trajet, direction, and their successive re-union with the various kinds of glands; thus, the study of this order of vessels is divided into several sections, viz:

Section 1.

LYMPHATICS OF THE ABDOMINAL EXTREMITIES.

1. *The Crural.*
2. " *Femoro-sub-pubien.*
3. " *Femoro-popliteal.*
4. " *Gluteal.*

Section 2.

LYMPHATICS OF THE ABDOMINAL PAROIS.

1. *The Supra-umbilical.*
2. " *Infra-umbilical.*
3. " *Circumflex of the ilium.*
4. " *Ileo-lumbar.*
5. " *Lumbar.*
6. " *Sacral.*

Section 3.

LYMPHATICS OF THE PELVIC VISCERA.

1. *The Sub-cutaneous of the perineum and anus.*
2. " *Sub-cutaneous of the penis.*
3. " *Deep-seated of the penis.*
4. " *Scrotal.*
5. " *Testicular.*
6. " *Vesical, prostatic.*

Section 4.

LYMPHATICS OF THE ORGANS OF THE ADBOMEN, EXTERNAL TO THE PERITONEUM.

1. *The Renal.*
2. " *Ureteric.*
3. " *Surrenal.*

Section 5.

LYMPHATICS OF THE DIGESTIVE ORGANS CONTAINED IN THE ABDOMEN.

1. *The Epiploics.*
2. " *Gastric.*

3. *The Splenic.*
4. " *Pancreatic.*
5. " *Hepatic.*
6. " *Mesenteric.*
7. " *Meso-colic.*

Section 6.

LYMPHATICS OF THE PAROIS OF THE THORAX.

1. *The Cutaneous of the sterno-costal surface of the thorax.*
2. " *Cutaneous of the back.*
3. " *Sub-sternal.*
4. " *Intercostal.*
5. " *Diaphragmatic.*

Section 7.

LYMPHATICS OF THE ORGANS CONTAINED IN THE THORAX.

1. *The Thymic.*
2. " *Mediastins, pericardiacs.*
3. " *Cardiacs.*
4. " *Pulmonary.*
5. " *Esophageal.*

Section 8.

LYMPHATICS OF THE HEAD AND NECK.

1. *The Epicranial.*
2. " *Subcutaneous of the face.*
3. " *Lingual, palatine, nasal, orbital, and pharyngeal.*
4. " *Trachelian.*
5. " *Thyroidal.*
6. " *Sub-cutaneous cervical.*

Section 9.

LYMPHATICS OF THE THORACIC EXTREMITIES.

1. *The Brachial.*
2. " *Humero-olecranien.*
3. " *Scapular.*

Section 1.

LYMPHATICS OF THE ABDOMINAL EXTREMITIES.

1st. *The Crural* arise from the glands placed behind the Fallopian ligament, accompany the crural artery and vein, and penetrate the inguinal glands. In addition, these glands, situated behind the ligament, furnish lymphatics to the epigastric and anterior iliac arteries.

2d. *The Femoro-sub-pubic* arise from the inguinal glands, and distribute themselves on the penis, integuments of this part and prepuce.

3d. *The Femoro-popliteal* are those which are distributed on the thigh and leg; they come from the superficial inguinal glands. They are distinguished into superficial and profound; the first distribute themselves on the inferior extremity, forming by their anastomoses a species of network, which envelopes all the parts of the thigh, leg and foot. The profound, less numerous, pass off from the inguinal glands, and accompany the crural artery and vein, and afterwards those of the ham and leg.

4th. *The Gluteal.*—These, surrounded by a quantity of fat, communicate with each other from one side to the other of each buttock, some winding on the external part, and others on the internal part of the thigh; they anastomose with the absorbents of this limb and those of the perineum. Some of them re-unite in the superficial lymphatics of the liver.

Section 2.

LYMPHATICS OF THE ABDOMINAL PAROIS.

1st, The *Supra-umbilical* are two fasciculi, which come from the lymphatics of the thorax. One of these fasciculi is external; it follows the trajet of the external branch of the mammary artery, and distributes itself with it in the muscles of the abdomen; the other accompanies the internal branch of this artery, traverses the fibres of the diaphragm, behind the xiphoid appendage, and distributes itself on the muscles and integuments of the bas-ventre.

2d, The *Infra-umbilical* pass off from the glands, which are situated behind the Fallopiian ligament; they accompany the anterior iliac and epigastric arteries, and are distributed on the broad muscles of the bas-ventre, peritoneum and integuments.

3d, The *Circumflex ilii* come from the hypogastric plexus and glands situated at the inferior part of the pelvis; they are distributed on the haunch bones, and muscles on their posterior part.

4th, The *Ileo-lumbar* likewise come from the hypogastric plexus and glands [situated near the sacro-iliac articulation. These vessels are distributed on the psoas and iliac muscles, and enter the vertebral canal, through the last spinal foramen.

5th, The *Lumbar*.—These come from the glands situated on the bodies of the lumbar vertebræ, and then proceed, conjointly with the lumbar arteries, to the psoas muscles; after this they divide into two fasciculi, one of which goes to the vertebral canal and lumbar muscles, and the other distributes itself on the muscles of the bas-ventre, quadratus lumborum and peritoneum.

6th, The *Sacral* arise from the hypogastric plexus,

and accompany the lateral sacral artery; they are distributed on the anterior surface of the sacrum and interior of the sacral canal.

Section 3.

LYMPHATICS OF THE PELVIC VISCERA.

1st, *Sub-cutaneous of the perineum and anus.*—These come from the glands situated at the inferior part of the pelvis, whence they pass out through the ischiatic notch; they are distributed on the parts which surround the anus, and form the profound lymphatics of the penis.

2d, *The Sub-cutaneous of the penis,* furnished by those of the abdominal extremity, become confounded in the inguinal glands.

3d, *The Profound of the penis* come from the hypogastric plexus, and follow the trajet of the internal pudic artery.

4th, *The Scrotal.*—Several of these are furnished by the preceding, the others, confounded with the testicular, follow their disposition.

5th, *The Testicular.*—The absorbent vessels of the testicles coming from the glands situated in front of the aorta and vena cava, descend in front of the psoas, pass through the inguinal ring, and contribute to form the spermatic cord; their number varies from six to twelve.

6th, *The Vesical, prostatic* pass from the inferior hypogastric plexus; they distribute themselves on the prostate gland and vesiculæ, and do not present any thing remarkable.

Section 4.

LYMPHATICS OF THE ABDOMINAL ORGANS SITUATED OUT OF THE PERITONEUM.

1st, *Renal.*—The lymphatic vessels of the kidneys may be divided into superficial and profound. The super-

facial spread themselves under the membrane of the kidney, and penetrate the substance of this organ in uniting with the deep-seated ones; these dip down into the fissure of the kidney, and are distributed in the pelvis of this organ, and likewise in its substance.

2d, The *Ureterics* envelope the ureters in their whole trajet, and communicate above with the absorbents of the kidneys, and below with those of the bladder.

3d, The *Sur-renal*.—Those of the right side pass off from some glands situated under the liver around the vena cava. The left come from the glands situated in front of the left pillar of the diaphragm, and all of them proceed to the sur-renal capsules, the exterior of which they cover, and penetrate their internal tissue.

Section 5.

LYMPHATICS OF THE DIGESTIVE ORGANS CONTAINED IN THE ABDOMEN.

1st, The *Epiploics* come from the glands, which are found along the great curvature of the stomach; they ramify on the epiploon, and accompany the arteries received by this membranous fold.

2d, The *Gastrics*.—The lymphatic vessels of the stomach arise from the inferior extremity of the thoracic duct: they form two fasciculi, one of which traverses the glands situated on the lesser curvature of the stomach, with which they form a plexus, which continues in the whole extent of this curvature. This plexus furnishes a great number of twigs, which are distributed on the membranous and internal tunics.

The second fasciculus accompanies the right and left gastro-epiploic arteries, traverses the glands from the greater curvature of the stomach, and forms with them a plexus like that of the first fasciculus. In leaving these

glands, the gastrics are likewise distributed on the membranous and internal tunics of the stomach.

3d, *The Splenics*.—The absorbents of the spleen come from the thoracic duct, and follow the trajet of the hepatic artery; arrived at the fissure of the spleen, they divide into two planes; one, superficial, which ramifies under the membrane of this viscus; the other, profound, penetrates the substance of the spleen. These two fasciculi have several anastomoses among themselves.

4th, *The Pancreatics* have nothing remarkable; arising from the gastric and splenic plexuses, they dip down into the pancreas, and follow the direction of the sanguineous vessels, which penetrate this glandular body.

5th, *The Hepatics*.—No organ contains more of them than the liver; they are distinguished into superficial and profound. The first appertain to the superior and inferior surface of the organ.

The superficial of the superior surface are distinguished into those of the right lobe and those of the left lobe.

The absorbents of the right lobe form four different fasciculi: 1st, Those which arise in the interval of the feuilletts of the suspensory ligament, ascend on this ligament, enter the thorax by the triangular opening situated behind the xiphoid appendage, traverse one and sometimes two of the glands of the mediastinum, and then divide in order to unite with several of the thoracic absorbents, and they finally terminate in the thoracic duct.

The second fasciculus arises on the right of the first; it proceeds between the laminæ of the right lateral ligament of the liver, and there divides into two orders: some of them traverse the diaphragm, expand on the superior surface of this muscle, return to the abdomen through the aortic orifice and then terminate in the glands situated between the aorta

and vena cava, confounding themselves with the intercostal absorbents. The inferior likewise traverse the diaphragm towards the last ribs, and are distributed on its sides: there they become confounded with the intercostal absorbents.

The third fasciculus ramifies on the posterior part of the liver; the trunks which it forms unite partly with the hepatic absorbents at their entrance into the abdomen, and the others terminate in the thoracic duct, re-united to the absorbents of the aorta and esophagus.

The fourth fasciculus is situated on the anterior part of the right lobe: it furnishes absorbents, which go to unite with the first fasciculus, and others which descend in the fissure of the liver, in order to communicate with the profound fasciculi.

The absorbents of the superior surface of the left globe constitute three orders: those of the first order unite with first fasciculus of the right lobe.

The second cover the whole surface of the left lobe, and ramify behind the stomach, and on the concave surface of the diaphragm; they afterwards unite with some splenic absorbents, in order to pass with them into the plexuses, which surround the aorta and inferior vena cava.

The absorbents of the third order are situated quite in front of the left lobe between the suspensory and left lateral ligaments; they then descend along the esophagus in order to lose themselves in the glands on the lesser curvature of the stomach.

The superficial absorbents of the inferior surface divide into those of the right and those of the left lobe. The first are divided into three orders of branches.

1st, Some of them arise between the circumference of

the liver and gall bladder, and terminate in the neighboring glands of the aorta and vena cava.

2d, Those of this order ramify on the gall bladder, between its base and the thin border of the liver, and terminate above the duodenum.

3d, These last arise between the and gall bladder longitudinal fissure, and go to unite with the preceding.

The absorbents of the left lobe cover the whole extent of this lobe and that of Spigelius, and are confounded with the preceding and deep-seated ones.

The profound absorbents arise in the whole extent of the liver; they accompany the sanguinous vessels, those of the biliary duct, and pass out with them in order to reach the glands of the lesser curvature of the stomach; they descend behind this organ, and unite finally with the intestinal and splenic absorbents.

The mesenterics.—These are a fasciculus formed by the lymphatics of the small intestines; it traverses the packet of glands situated at the origin of the mesentery, whence pass off a great quantity of lymphatic branches, which ramify in all the parts of this membranous fold; these branches advance towards the intestinal conduit, and there divide into superficial and profound; the first ramify on the membranous tissue; the second on the internal tunic.

The *Meso-colics.*—These proceed from the fasciculus, which accompanies the superior mesenteric artery, travel between the laminae of the transverse meso-colic, and pass to the glands situated along the posterior border of the colon. The absorbents of the left and iliac lumbar colon as well as those of the rectum, come from the glands which are found in front of the vertebral column and aorta, and from those comprised between the two laminae of the meso-rectum.

Section 6.

LYMPHATICS OF THE THORACIC PAROIS.

1st, The *Cutaneous of the sterno-costal surface of the thorax*.—The axillary glands furnish the superficial vessels of the thoracic parois. Among these vessels, some ramify on the anterior surface of the great pectoral muscle; a few branches emanating from these likewise go to the inferior part of the neck, and to the deltoid; others turn around the inferior border of the pectoral. The other absorbents ramify on the great dorsal, great serratus and external oblique muscles.

2d, The *Cutaneous of the back* likewise come from the axillary glands; the superior pass between the great dorsal and great round muscles, proceed under the infraspinatus, where they encounter some glands which they traverse; they then are distributed on the trapezius and integuments which cover it. The middle arise like the preceding, and ramify on the great dorsal, on the extremity of the trapezius, and corresponding integuments. The inferior, united at first to the middle absorbents, near the insertion of the great dorsal, ramify on the whole extent of this muscle.

3d, The *Infra-sternal* come from the thoracic duct; they are united to the absorbents of the neck, throw themselves into the inferior glands of this part, descend behind and on the sides of the sternum, following the internal mammary artery; they traverse the opening situated behind the sternal appendage, in order to anastomose with the epigastric absorbents.

4th, The *intercostals*.—These, arising from the lateral parts of the thoracic duct, are directed from within outwards, after having traversed the glands situated in front of the dorsal vertebræ; they form different plexuses, after

which they pass through the glands which are perceived near the articulation of the ribs with the vertebræ; from these glands there pass off a multitude of branches, some of which go to the vertebræ and muscles of the back; the others follow the inferior border of the ribs, and distribute themselves on the intercostal muscles, pleura, and on the muscles and integuments of the chest.

5th, The *diaphragmatics*:—The absorbents of the diaphragm become confounded with the intercostals, hepatics, and the other abdominal absorbents; their principal trunks occupy the convex surface of the muscle, and are found between it and the pleura.

Section 7.

LYMPHATICS OF THE ORGANS CONTAINED IN THE THORAX.

1st, The *Thymics* are few in number; they proceed from the glands placed above the arch of the aorta.

2d, The *Mediastins and pericardiacs*.—The first proceed from the glands situated in the superior part of the mediastinum, and from those which are found above the arch of the aorta, and are distributed on the substance of this partition. The others, emanating from the same place, ramify on the parois of the pericardium.

3d, The *Cardiacs*.—The lymphatic vessels of the heart come from the glands situated above the arch of the aorta, and descend, some of them on the superior surface, after having passed in front of the aorta and pulmonary artery; the others descend behind the aorta and ramify on the inferior surface of the neck.

4th, The *Pulmonaries*.—The lymphatics of the lungs have not the same origin. Those of the right lung come from the absorbents of the superior extremity of this side; those of the left proceed from the thoracic duct. These

vessels unite on each side in a fasciculus, which traverses the bronchial glands, and forms with them a plexus in which the lymphatics of the right lung communicate with those of the left lung. From these glands pass off two planes of vessels; one, superficial, which ramifies under the external membrane of the lung; the other, profound, penetrates the substance of the organ.

5th, The *Esophageal* come from the glands situated above the arch of the aorta.

Section 8.

LYMPHATICS OF THE HEAD AND NECK.

1st. The *Epicranial* proceed from the glands, which surround the internal jugular vein, and which are situated between the trapezius and sterno-mastoideus. Some proceed posteriorly on the trapezius; others surround the pavillion of the ear; they all ramify under the integuments.

2d, The *Sub-cutaneous of the face* take their origin on the glands found in front of the pavillion of the ear, and in the parotid notch, or from those situated at the base of the lower jaw; some of them, united with several absorbents of the cranium, proceed to the fore-head and external half of the eye-lids; the others, united into two principal trunks, follow the trajet of the facial vein, and ramify on the nose, the internal half of the eye-lids, and on the middle of the fore-head.

3d, The *Lingual, palatine, nasal, orbital, and pharyngeal*:—The absorbents of the tongue come from the jugular glands, and follow the direction of the vessels which proceed thither. Those of the palate and nasal fossæ come from the jugular glands at the superior and lateral part of the neck; it is the same thing with regard to the

absorbents of the superior part of the pharynx. Those of the inferior part come from the inferior glands of the neck. The lymphatics of the orbit are furnished by the glands placed in the bottom of the parotid notch, follow the trajet of the sanguineous vessels, and enter the orbital cavity by the same opening.

4th, The *Thyroids* proceed from the glands placed on the trajet of the internal jugular vein, and from the inferior jugular glands.

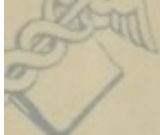5th, The *Cervical cutaneous* come from the glands which occupy the triangular space formed by the trapezius and sterno-mastoid muscles, and from those which surround the jugular and subclavian veins.

Section 9.

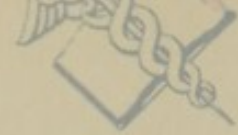LYMPHATICS OF THE THORACIC EXTREMITIES.

1st. The *Brachial*.—The absorbents of the superior extremity are divided into two orders—the superficial and profound. The first, arise from the axillary glands, pass along the internal part of the arm, and approximate at its anterior and inferior part; there, they furnish the lymphatics of the fore-arm, which are distributed to its anterior and posterior parts; then several of them proceed under the annular ligament in order to supply the palm of the hand, whilst others ramify on the back of the hand and fingers.

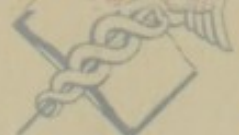



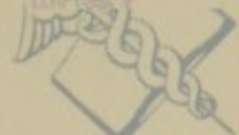Washington



Department of



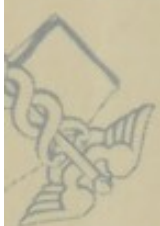Washington



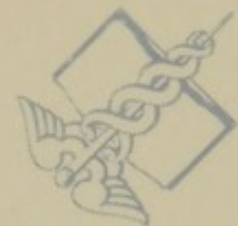Department of



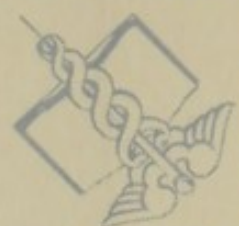MEDICINE NATIONAL LIBRARY OF MEDICINE NATIONAL LIBRARY OF M



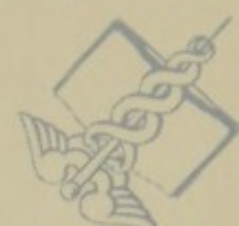Health Service



Health, Education,



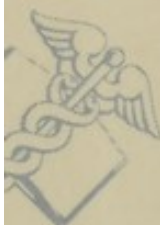
Health Service



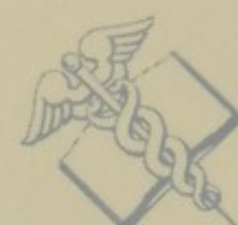Health, Education,



NATIONAL LIBRARY OF MEDICINE NATIONAL LIBRARY OF MEDICINE



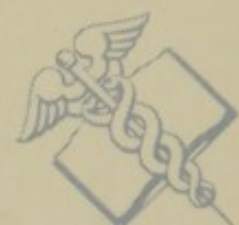and Welfare, Public



and Welfare, Public



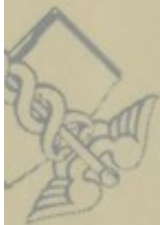and Welfare, Public



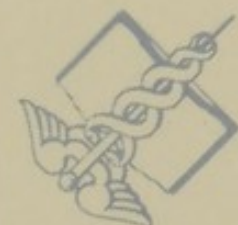and Welfare, Public



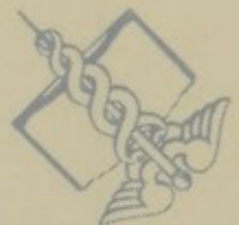MEDICINE NATIONAL LIBRARY OF MEDICINE NATIONAL LIBRARY OF M



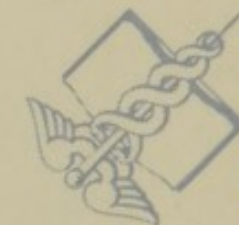Health, Education,



Health Service



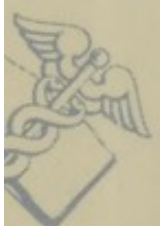Health, Education,



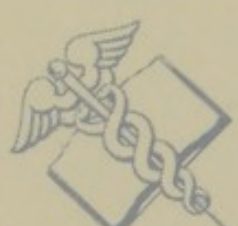Health Service



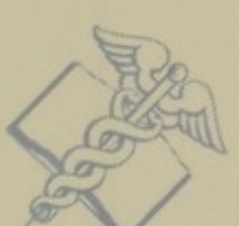NATIONAL LIBRARY OF MEDICINE NATIONAL LIBRARY OF MEDICINE



U.S. Department of



Washington, D.C.



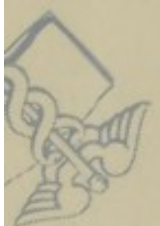U.S. Department of



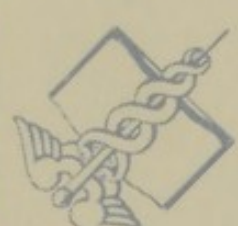Washington, D.C.



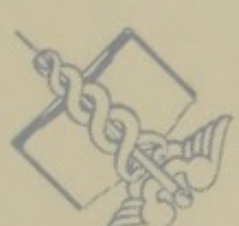MEDICINE NATIONAL LIBRARY OF MEDICINE NATIONAL LIBRARY OF M



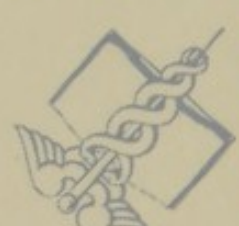Washington, D.C.



U.S. Department of



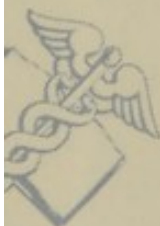Washington, D.C.



U.S. Department of



NATIONAL LIBRARY OF MEDICINE NATIONAL LIBRARY OF MEDICINE



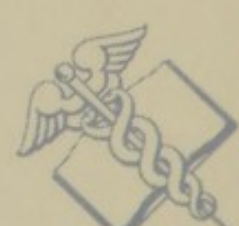Health Service



Health, Education,



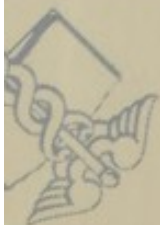Health Service



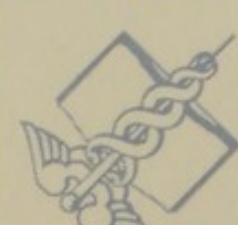Health, Education,



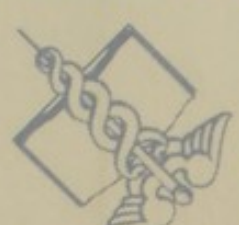MEDICINE NATIONAL LIBRARY OF MEDICINE NATIONAL LIBRARY OF M



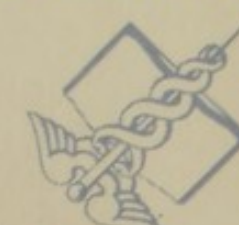and Welfare, Public



and Welfare, Public



and Welfare, Public



and Welfare, Public



OF MEDICINE NATIONAL LIBRARY OF MEDICINE NATIONAL LIBRARY OF M

Washing

NATIONAL LIBRARY OF MEDICINE NATIONAL LIBRARY OF MEDICINE

Health Service

NATIONAL LIBRARY OF MEDICINE NATIONAL LIBRARY OF MEDICINE

and Welfare, Public

NATIONAL LIBRARY OF MEDICINE NATIONAL LIBRARY OF MEDICINE

Health, Education,

NATIONAL LIBRARY OF MEDICINE NATIONAL LIBRARY OF MEDICINE

U.S. Department of

NATIONAL LIBRARY OF MEDICINE NATIONAL LIBRARY OF MEDICINE

Washington, D.C.

NATIONAL LIBRARY OF MEDICINE NATIONAL LIBRARY OF MEDICINE

Health Service

NATIONAL LIBRARY OF MEDICINE NATIONAL LIBRARY OF MEDICINE

and Welfare, Public

NATIONAL LIBRARY OF MEDICINE NATIONAL LIBRARY OF MEDICINE

APR 27 1962

NATIONAL LIBRARY OF MEDICINE NATIONAL LIBRARY OF MEDICINE

NATIONAL LIBRARY OF MEDICINE



NLM 01001560 9