

On coxalgia, or hip disease / by Alden March.

Contributors

March, Alden, 1795-1869.
American Medical Association.
National Library of Medicine (U.S.)

Publication/Creation

Philadelphia : T.K. and P.G. Collins, printers, 1853.

Persistent URL

<https://wellcomecollection.org/works/cfsue87b>

License and attribution

This material has been provided by This material has been provided by the National Library of Medicine (U.S.), through the Medical Heritage Library. The original may be consulted at the National Library of Medicine (U.S.) where the originals may be consulted.

This work has been identified as being free of known restrictions under copyright law, including all related and neighbouring rights and is being made available under the Creative Commons, Public Domain Mark.

You can copy, modify, distribute and perform the work, even for commercial purposes, without asking permission.



Wellcome Collection
183 Euston Road
London NW1 2BE UK
T +44 (0)20 7611 8722
E library@wellcomecollection.org
<https://wellcomecollection.org>

MARCH (ALDEN)

With respect to the author

ON

COXALGIA, OR HIP DISEASE.

BY

ALDEN MARCH, M. D.,

OF ALBANY, NEW YORK.


PRESENTED TO THE AMERICAN MEDICAL ASSOCIATION,

AT ITS SESSION OF MAY, 1853.

PHILADELPHIA:

T. K. AND P. G. COLLINS, PRINTERS.

1853.



ON

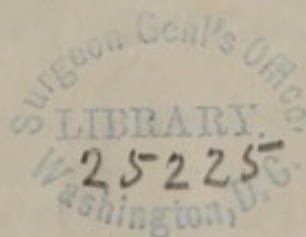
COXALGIA, OR HIP DISEASE.

BY

ALDEN MARCH, M. D.,

OF ALBANY, NEW YORK.


PRESENTED TO THE AMERICAN MEDICAL ASSOCIATION,
AT ITS SESSION OF MAY, 1853.



PHILADELPHIA:

T. K. AND P. G. COLLINS, PRINTERS.

1853.



ON

COXALGIA, OR HIP DISEASE.

THE views which I am about to present concerning the pathological condition of the hip-joint, when occupied by the affection commonly called "hip disease," and its treatment, I am fully aware will differ widely from the commonly expressed opinion of almost all surgical writers and teachers.

Nearly every surgical author *assumes* that *spontaneous dislocation* of the hip is not unfrequently the result of *absorption, ulceration, or destruction* of the ligaments of the joint and of the acetabulum, and of contraction of the muscles surrounding the joint.

I shall take the position that *spontaneous dislocation* of the hip (as *purely the result of morbid action unaided by superadded violence*) *seldom or never takes place*. I also propose to point out a mode of treatment by which *progressive absorption* of the acetabulum and head of the bone may be arrested, before the life of the patient is endangered by the progress of the disease.

About the year 1845 or 1846, I was led to entertain views upon this subject, as I believe, nearly if not quite peculiar to myself, from the examination of the bony specimens of the hip-joint, of two or three persons, who had evidently died while labouring under a severe form of hip disease.

After making this examination, I came to the conclusion that all the usual symptoms of a dislocation, such as are commonly relied on, during life, as diagnostic of an idiopathic dislocation, could be accounted for, and satisfactorily explained, at least to my mind, in the strongly marked organic changes in the form and relations of the head of the femur and acetabulum, without the existence of such an accident.

If it should be asked, upon what ground I found the proof and argument to sustain my doctrine; and why I dare oppose the weight of the highest surgical authority on this subject: I will answer, that my convictions are based upon actual observation and personal examination of about forty pathological museums in this country and in Europe.

Of the pathological museums in the United States, I have examined *three* in the city of New York—*three* in Philadelphia—*one* in Baltimore—*one* in Washington—*two* in Boston—*one* in Richmond, Va.—*one* in Hanover, N. H.—*one* in Cincinnati—and *two* in Albany, N. Y.

In the year 1848, I visited and examined the following in Europe, viz.: Pathological Museum of Paris—London University Hospital Museum—Guy's Hospital Museum—London Hospital Museum—St. Thomas's Hospital Museum—St. Bartholomew's Hospital Museum—Middlesex Hospital Museum—St. George's Hospital Museum—College of Surgeons Museum—King's College Museum—Edinburgh Royal Infirmary Museum—Royal College of Surgeons' Museum—Edinburgh University College Museum—Glasgow Hunterian Museum—Belfast College of Surgeons' Museum—Stevens's Hospital Museum, Dublin—Richmond Hospital Museum, Dublin—Dublin College of Surgeons' Museum—Park Street School of Medicine Museum, Dublin—University of Leyden (Holland) Pathological Museum—Amsterdam Pathological Museum—Heidelberg Pathological Museum—Friburg (Germany) Pathological Museum—Berne (Switzerland) Museum of Natural History—Zurich Pathological Museum—Brussels (Belgium) Anatomical Museum.

It will appear by the above catalogue, that I have visited and made personal examination of over forty different anatomical and pathological museums; nor can it be said that I visited these places out of mere curiosity, and without having any specific object in view.

I made it my business to examine critically every morbid specimen of the hip-joint, and with paper and pencil in hand, made a record on the spot of the number of specimens, whether dried or wet; and classified them according to the nature of their respective organic changes.

From the examination of the collections of the above institutions, I have had an opportunity of personally examining about two hundred specimens of what I took to be "hip disease," and as I learned

to be such, from observation and the evidence of the curators and of the catalogues of the museums.

To insure a ready comprehension and proper appreciation of the pathological views I propose to explain and illustrate by specimens, I shall be under the necessity of presenting a brief description of the most important anatomical structure of the hip-joint; dry and uninteresting as such a matter-of-fact statement must be to the veteran surgeon and general practitioner.

The osseous structure of the hip-joint is made up of the *os innominatum* and head of the *os femoris*, which is received into a deep cavity of the former, called the acetabulum, or cotyloid cavity, by that species of articulation denominated *enarthrosis*, or ball-and-socket joint.

The transverse and vertical diameter at the brim of the acetabulum in the dried skeleton, varies, in the adult male, from an inch and seven-eighths to two inches; and in depth from eleven-twelfths of an inch to an inch. The diameter of the female acetabulum varies from an inch and five-eighths to an inch and seven-eighths. The depth being but little less than that of the male. These measurements must vary, of course, according to the different periods of life at which they are taken.

The texture of the head of the bone, and of the innominatum, is a loose, cancellous material; quite vascular, and subject to inflammation.

The acetabulum is lined with cartilage at all parts, except at a circular pit (*fundus acetabuli*), which is situated at the lower part of the general cavity near the notch. The cartilaginous articulating surface of the head of the bone forms something more than half a segment of a sphere; and upon its face that looks towards the cavity of the pelvis, there is a deep pit into which is inserted the ligamentum teres.

The appropriate ligaments of the hip-joint, are the *capsular*, the *ilio-femoral*, the *teres*, the *cotyloid*, and the *transverse*.

The *cotyloid* ligament is a prismoidal cord of fibro-cartilage, which surmounts and is attached to the brim of the acetabulum, by which the latter is deepened.

The *capsular* ligament is attached to the outer border of the acetabulum and outer face of the cotyloid ligament above; below, it is fixed into the inter-trochantral line and neck of the bone. It is much thicker, and more extensively attached at its upper part, where strength and security seem to be needed.

The *ilio-femoral* ligament is accessory to the capsular, and extends from the anterior inferior spinous process of the ilium to the anterior inter-trochantral line, by which the capsular ligament is greatly strengthened in that direction.

The *ligamentum teres* is attached by a round apex to the depression just below the middle of the head of the femur, and by its base into the borders of the notch of the acetabulum. It is covered by the synovial membrane.

The *transverse* ligament is continuous with the cotyloid, extending from one point of the notch to the other, completing the circle of the cotyloid ligament, and converting the notch into a foramen, through which the bloodvessels enter to supply the interior of the joint.

The synovial membrane is quite extensive, lining the capsular ligament, the free surface of the cotyloid, the ligamentum teres, and the cartilages of the head of the bone.

The muscles about the hip-joint, the active agents in producing distortion, are the flexors, adductors, and rotators.

I believe all authors describe two principal forms of morbus coxarius, or hip disease; one, in which the inflammation commences in the cartilage; and the other, when the cancellous structure of the bone is the primary seat of the affection. In either case, the result may involve all parts of the joint, and prove equally destructive. That form of it in which the cartilage is the first part attacked, is not unfrequently met with in adults; whereas the scrofulous form, the other variety, is mostly confined to children, and persons under the age of puberty.

The hip-joint may be subject to other forms or varieties of disease: rheumatic inflammation, interstitial absorption, porcelaneous deposit, etc. But it is believed that the changes of structure consequent upon these affections do not often simulate or counterfeit the symptoms of dislocation. I shall, therefore, confine my remarks mostly to the subject of *ulcerative absorption*, by which such changes have resulted in the articulation as have too often been called *dislocation*.

I presume it will hardly be denied that surgical authors, and even the most experienced practical men, support the doctrine of spontaneous luxation of the head of the os femoris as a result of "hip disease." And yet, to prove this point, it is deemed important to make brief extracts and quotations from such surgical works as are contained in my own library, which are all of modern date, as well as to refer to those of a more remote period.

I shall not confine myself to any chronological order in my quotations. It will be sufficient if it be shown that the same opinions are entertained, whether they have been borrowed from one or another, whether from a predecessor or contemporary; or whether the erroneous notion of dislocation (as I have deemed proper to call it) has been derived from the mere observation of the symptoms in any given case during life.

In the work entitled *The Principles and Practice of Modern Surgery*, by Robert Druitt, will be found the following, under the head of Diseases of the Hip-joint: "But if the disease proceed, it is succeeded by another kind of shortening, caused either by the destruction of the neck of the femur by caries, or (as is more commonly the case) by the destruction of the acetabulum and capsular ligament, and *dislocation* of the bone upwards by the muscles." To illustrate the deformity and dislocation, the author gives a sketch, or wood-cut, taken from a patient under the care of Mr. Fergusson, in the King's College Hospital. In the position which I take in order to disprove the doctrine of spontaneous dislocation of the hip-joint, without accident or superadded violence, I shall rely upon nothing but *post-mortem ocular demonstration*; so I shall require the same proof to show the existence of a spontaneous luxation.

At the time the sketch was taken of Mr. Fergusson's patient, upon which Mr. Druitt relies for proof of dislocation, the case was under treatment, the patient was not dead, nor was the figure drawn from *post-mortem* appearances of the dissected parts.

This is a pretty fair example of proof, upon which the profession at large and authors rely to sustain their position on this subject.

James Miller, in his *Practice of Surgery*, remarks on this subject, under the head of Morbus Coxarius: "As disorganization advances within, the joint becomes more and more loose; and *dislocation* may occur by *muscular action alone*, without the intervention of a fall, or other injury. The dislocation is usually upwards on the dorsum of the ilium." Here the principle of *dislocation* is boldly recognized; but does the author give any evidence of its existence by a *post-mortem* dissection?

Sir Charles Bell, in his *Institutes of Surgery*, in speaking of morbus coxarius, remarks: "Another peculiarity in the position of the patient with diseased hip, is that of throwing the thigh of the affected side over the other, that the head of the thigh-bone may be raised, so as to relieve the inflamed socket. The thigh-bone becomes as a lever, loaded at the lower end, by which the upper end is raised, and

the pressure taken off the inflamed glenoid cavity. It is a position of great relief; but the consequence is *actual dislocation in extreme cases.*"

It has been my privilege to examine the specimens of this affection in the London University Hospital Museum, where many of Mr. Bell's morbid specimens are deposited, and yet I could discover no preparation of "hip disease," where it appeared in the least degree as though the head of the femur was luxated during the life of the patient.

Baron Dupuytren, on the *Injuries and Diseases of the Bones*, under the head of Congenital Dislocation, observes: "Whatever importance may be attached to this dislocation in the abstract, it is deserving of still more attention on account of its presenting all the signs of luxation consequent on disease of the hip-joint, with which it has *always been confounded.*" After giving the diagnostic symptoms of the two diseases, and the different distinctive marks of each, the author remarks: "For it (congenital dislocation) does not include that painful and cruel disease of the hip-joint which usually issues in *spontaneous dislocation of the femur.*"

Here the doctrine of spontaneous dislocation of the femur is recognized, and yet it is not supported by any proof from *post-mortem* examinations.

J. M. Chelius, a professor of surgery in Heidelberg, and author of a *System of Surgery*, speaks of dislocation of the head of the thigh-bone, in coxalgia, as *accidental and rare*, rather than as a *common occurrence*. He says: "Dislocation of the head of the thigh-bone is not a necessary phenomenon in the third stage of coxalgia; it is rather accidental, and depends on the position of the diseased extremity, on the motions of the patient, and other influences during the relaxation of the muscles, and on the relaxation and destruction of the ligaments, especially of the round ligament."

In Pirrie's *System of Surgery*, under the head of Morbus Coxarius, we find the principle of spontaneous dislocation recognized. He says: "When dislocation takes place, which, however, is not always the case, the head of the femur is usually drawn upwards and outwards on the dorsum of the ilium." He adds: "It may be found in other directions, but very rarely indeed." A figure of a patient of the author's is given, with the following note of explanation: "A drawing, exhibiting the great shortening of the limb, and the alteration in the form of the hip in the advanced stage of morbus

coxarius, subsequent to spontaneous dislocation, from a patient in my surgical ward at the hospital." It will be observed that the author does not make his drawing from the dissected bones of the diseased hip-joint. Because the limb is two or three inches shorter than the other, and because the leg is flexed on the thigh, the thigh on the pelvis, with inversion of the foot and great adduction of the limb, and projection of the trochanter-major, the author seems to take it for granted that there is a dislocation. I propose to demonstrate from the actual morbid specimens, hereafter, that all these symptoms can and do exist in a great majority of the fatal cases of hip disease, without dislocation.

The late Robert Liston, in his *Elements of Surgery*, after giving a description of the changes in the osseous parts of the joint, caused by ulcerative absorption and destruction, says: "From such changes in the osseous parts of the articulation, the limb is shortened, sometimes to a great degree, though no dislocation has occurred." He adds, "indeed, dislocation is by no means so frequent a cause of the shortening as is *generally believed*." All this, thus far, goes to support the point I am aiming to establish; and coincides with my views as to the cause of the *shortening* and *distortion* of the *limb*. But the author puts forth another doctrine, in relation to this subject, to which I cannot subscribe. It shows, however, that he regards luxation as a legitimate result of what he calls morbus coxarius. He says: "A portion of the *dorsum* of the *ilium*, upward and backward, which is the most frequent distortion in this disease, is thus gradually absorbed so as to form a cavity for the reception of the femur, the extremity of which becomes *more solid* in texture and *more smooth* in its articular surface. Whilst a depression is thus formed, new bone is deposited round its margins, whereby the cavity is increased in depth, and resembles the original acetabulum; the new deposits having become smooth and of a regular form. In many cases the new acetabulum is almost entirely formed by the deposition of new bony matter, which gradually adapts itself to the extremity of the femur."

This is undoubtedly true in cases of idiopathic dislocation; and something of a similar result may take place in *interstitial absorption* at one part, and in *interstitial accumulation* in another—in the porcelaneous deposits and changes that take place in old age; and sometimes from a contusion upon the trochanter major.

But I deny that any such result ever has, or can take place in genuine ulcerative absorption with more or less destruction of the

head of the femur and acetabulum. When the cartilage is destroyed, and a portion of the head of the bone has been carried away, it is either in a naked carious condition, or it is vascular and covered with coagulable lymph. In the latter case, if it were applied to a similar surface, and the parts kept in easy apposition, and perfectly at rest, the anastomosing bloodvessels might shoot from surface to surface, by which a circulation between the two parts would be maintained, of which, under otherwise favourable circumstances, ankylosis would be the result. If the head of the bone, thus changed in its organization, could rest upon a perfectly healthy cartilaginous surface, it is possible, indeed it is very likely, that we might in a few instances, with the head of the bone healed over, hardened and polished, have a considerable degree of freedom of motion. But when the *ulcerated spongy head*, or what remains of it, is thrown (if it ever is) upon the periosteum of the dorsum of the ilium, I do not believe that any such result as that described by Mr. Liston can take place.

In a recently published work on *Congenital Dislocations of the Head of the Femur*, by John Murray Carnochan, M. D., under the head Diagnosis, in comparing the symptoms of *spontaneous* with those of *congenital* dislocation, he remarks: "The occurrence of spontaneous dislocation—which as a result of ulceration of the border of the acetabulum, sometimes takes place, although rarely, in morbus coxarius; it is exceedingly rare for the malady to occur symmetrically and simultaneously on both sides—a circumstance which is of common occurrence in the congenital dislocation of the femur."

Samuel Cooper, in his work entitled *The First Lines of the Theory and Practice of Surgery*, says: "In the second stage of this disease, the acetabulum is either widened, or parts of its brim destroyed, while the head of the femur is more or less diminished, and both the ligamentum teres and the synovial membrane are sometimes nearly annihilated. Hence, the most frequent cause of the shortening of the limb in the second stage of the disease, and shortening not dependent upon actual dislocation, which, however, sometimes occurs, as was the case in a patient under my care last spring (1839) in University College Hospital, and the specimen taken from which is now preserved in the museum of the same College." In 1848, nine years after the deposit of the specimen, I examined the University College Hospital Museum, most thoroughly and minutely, and am sure that it did not then contain a single specimen of what I regarded a spontaneous dislocation of the head of the femur as the

result of ulcerative absorption. In some of the specimens, the head of the bone was almost or entirely absorbed, while the acetabulum in some was elongated upwards and backwards; in others, enlarged in three-fourths of its circumference; and in others deepened, and even largely perforated. In one specimen, I observed that the head of the bone was entirely destroyed, while the neck occupied the hole, caused by ulceration at the bottom of the acetabulum, and presented towards the cavity of the pelvis.

From Prof. Wm. Gibson's work, entitled *Institutes and Practice of Surgery*, I select the following quotation, for the purpose of showing that he regarded spontaneous luxation of the hip consequent upon ulceration as of frequent occurrence. The author remarks: "Sometimes the foot and limb, instead of being turned inwards, are directed outwards. This will depend I imagine (he continues), in some measure, upon the position the patient has been accustomed to lie in, and in others upon the direction the head of the bone or its remains may happen to take after *abandoning the acetabulum*; for among the numerous morbid specimens contained in my cabinet, I find the upper extremity of the shaft resting upon the obturator opening in some, in others upon the *tuber ischii*, in others upon the *pubis*, but generally on the *dorsum ilii*. Occasionally, it happens that the head of the thigh slips from the acetabulum, before it has undergone any important change; the capsule, round ligament, and cartilages of the cup have been previously destroyed by ulceration. At other times the bony texture of the acetabulum is destroyed by caries, and the head of the thigh-bone, or its shaft, enters the pelvis."

So far as the change and destruction of the bony texture of the joint are concerned, all this is true; but let us examine the facts in relation to the *frequency* and *variety* of *spontaneous dislocation*, or "abandoning the acetabulum."

In February, 1848, I visited the Pennsylvania University College Museum, after having listened to a lecture from the Professor of Anatomy, by whom, at my request, I was shown the museum, and sought, by his aid, to examine all the specimens of hip disease, or ulcerative absorption of more or less of the head of the thigh-bone, and of the acetabulum. It was agreed, both by the professor and myself, that we did not find a single specimen of a well-marked case of the disease under consideration. When I called to mind the language of Professor Gibson, as above quoted, I must confess I was

not a little surprised that I could not find a few "among the numerous morbid specimens contained in his cabinet."

At the time of my visit, Professor Gibson was too ill to lecture, or to be at his room in the college, which of course deprived me of the privilege of conversing with him on the chief object of my visit, and of his valuable aid in making an examination of the morbid specimens of the museum. But when I reflected that the "numerous specimens," to which he refers in his surgical work, might be in his private room among other morbid specimens which he was in the regular habit of using in the course of his lectures for demonstration and illustration, I was disposed to believe that they were "numerous," and that it would be a rich treat to get access to them. To the anatomist, who politely showed me the "Wisterian" or general museum, I expressed my regret at not being able to see Professor Gibson, and explain to him my views on the subject of spontaneous dislocation; yet he was sure that it was of common occurrence, for he had seen it in patients treated for hip disease by himself. To this remark I replied: "Doctor, was your diagnosis verified by a *post-mortem* examination?" To which he replied: "No; the patients did not die." I thought too much of the age and standing of the professor, to put the question which would naturally follow: "How, then, did you ascertain that luxation existed during life?"

In January, 1853, I revisited the medical colleges and anatomical and pathological museums of Philadelphia, when I was fortunate in meeting with Professor Gibson, and to whom I broached my favourite subject of inquiry in something of the following language: "Doctor, I desire to examine your specimens of hip disease (ulcerative absorption), to see whether the oft-repeated assertion of authors, that spontaneous dislocation results from this affection, be verified in the condition of the parts after death." To which the professor replied: "You may look in vain—you never see them." The professor's private collection of fractures, and other morbid specimens in osteology, was extensive and interesting; among them we found four or five genuine cases of caries, or ulcerative absorption of the bony structure of the hip-joint; and yet not in a single instance did we meet with a case that appeared in the least like a dislocation, as though the altered and half-destroyed head of the bone had ever played or rotated on the "*dorsum ilii*, upon the *obturator opening*, upon the *tuber ischii*, or upon the *pubis*."

In the Jefferson Medical College Museum, Philadelphia, there are four or five good specimens of genuine hip disease, if we include one

in which there is an ankylosis of the hip-joint—one of the two out of nearly two hundred specimens of hip disease I have examined, that would favour the doctrine of spontaneous dislocation. In this instance, the head of the bone was not much altered in shape or diminished in size, while it rested on the margin of the upper and back part of the acetabulum, slightly projecting over a pretty deep and rough acetabulum, where it had become ankylosed by bony deposit.

Sir Astley Cooper, in his *Treatise on Dislocations and Fractures of the Joints*, under the head of Dislocation from Ulceration, says:—

“Dislocations may arise from ulceration, by which the ligaments are detached, and the bones become altered in their form. We frequently find this state of the parts in the hip-joint; the ligaments ulcerated, the edge of the acetabulum absorbed, the head of the thigh-bone changed both in its magnitude and figure, *escaping from the acetabulum* upon the ilium, and there forming for itself a new socket.” It will be observed, that here the doctrine of spontaneous dislocation of the hip-joint is recognized and taught by the highest and most weighty surgical authority of modern times.

For many years, I have looked upon the writings of Sir Astley Cooper as the most reliable of any in the English language. He was my oracle; and I almost venerated the man for the clear, concise, and honest manner in which he was accustomed to present his views on the various subjects of surgical science.

He never appeared to be at a loss for an appropriate case for the illustration of his subject; nor did he appear to be satisfied with a mere superficial examination of the subject under investigation. His deductions and conclusions were commonly founded on anatomical and pathological demonstrations. Nevertheless, with all this rare combination of a variety of talents, it is possible that even a great and a good man may be mistaken.

To illustrate the subject of spontaneous dislocation, Mr. Cooper gives the following case. He says: “Mr. White, of Parliament Street, had under his care a patient in the Westminster Hospital, who was the subject of dislocation of the os femoris on the dorsum of the ilium, from ulceration. He sawed off the head of the femur, and the patient was restored to a very useful motion of the limb.” With regard to the formation of a “new socket,” as asserted by Mr. Cooper, and as repeated by Mr. Liston, I have already stated such pathological objections as seem to me conclusive against the doctrine of the formation of a new joint. And, besides, in all the specimens

of the numerous pathological museums I have examined, no evidence in the preparation itself has been discovered to show any such result. In *Braithwaite's Retrospect*, No. 22, January 7, 1851, at page 196, there is a synopsis of a case of removal of the head of the femur, at St. Bartholomew's Hospital, by Mr. Skey, in a case of "hip disease." After giving the history of the disease, the age of the patient, being thirteen years old, her condition on admission to the hospital, &c., the account says: "The left femur was *dislocated* on the *dorsum ilii*, the *limb shortened*, and the *leg and thigh flexed*." After consultation, "it was considered that removing the *head of the bone* would give the patient the best chance of recovery." Next, follows a description of the operation; and lastly, the morbid appearance and organic changes of the joint. The report states that "the *acetabulum* was found to have been *enlarged* by *absorption*, and was *extended* in a direction *upwards* and *backwards*, as if an attempt had been made by nature to form a *new joint in this direction*. The *head of the femur* had been *entirely absorbed*; a portion of the neck remained, which, with the great trochanter, was the part removed." Now, if "the head of the femur had been entirely absorbed," how does it happen that "the left femur was dislocated on the *dorsum ilii*?" Or, if "only a portion of the neck remained," under what conceivable circumstances could there be a dislocation of what did not exist? Now, at the risk of being charged with a degree of temerity unbecoming my rank and position in surgical science, I venture to suggest, in the case of the patient of Mr. White, reported by Sir A. Cooper, "who was the subject of *dislocation* of the *os femur* on the *dorsum of the ilium* from *ulceration*," that there might have been "entire absorption of the head of the bone, and a portion of the neck." If so, where is the evidence that the patient "was the subject of dislocation of the *os femur* on the *dorsum of the ilium* from *ulceration*?"

Mr. Fergusson reports a case of excision of the upper end of the femur in *morbus coxarius*, an abstract of which is given in *Braithwaite*, 1845, where it is said, "the head of the femur was *displaced* on the *dorsum ilii*, and could be felt by the finger to have passed into a large sinus." I apprehend the "large sinus," into which the head of the bone had "passed, and that could be felt by the finger," was nothing more nor less than an *enlarged acetabulum upwards and backwards*, a *recession* of the attachment of the *capsular ligament*, its *thickened state*, and *deposit of lymph and serum between it and the cellular tissue and muscles covering it*. In the abstract

above referred to, no account is given of the pathological condition of the diseased bones, on examination at the time, or after the operation.

It is proposed next briefly to examine some of the cases bearing upon the subject under investigation, presented by Sir Benjamin Brodie, in his work entitled *Pathological and Surgical Observations on the Diseases of the Joints*, published in 1834; and also his *Lectures* on the same subject published at a subsequent period. When we consider that Sir Benjamin Brodie stands pre-eminently at the head of the surgical profession on this subject, if not in general surgical science, it is with feelings of great diffidence that I attempt to examine the testimony, and collect the reported cases for analysis, of this truly great and practical surgeon. The first case selected is under the head of inflammation of the Synovial Membranes of the Joints. Master L—, about eight years of age, in September, 1824, was attacked with symptoms of hip disease, and for such affection was treated for some time by his attending surgeon. "In March, 1825, it was discovered that the limb was shortened." In November, 1825, Mr. Brodie was consulted respecting the patient. "At this time," Mr. Brodie says, "there were all the marks of a dislocation of the hip upwards and outwards. The limb was shortened, the toes turned inwards, and the head of the femur was distinctly to be felt on the posterior part of the ilium above the margin of the acetabulum." In this case it will be observed that there was no *post-mortem* examination; and I shall attempt to show hereafter that all the above symptoms of dislocation can be explained in the changed and destructive condition of the parts of the joint. In this instance it would appear, according to the views of Mr. Brodie, that the disease commenced in the synovial membrane, and that it resulted in ulceration of the cartilages and ulcerative absorption of more or less of the head of the bone without suppuration; as it is distinctly stated that "a swelling, which at one time appeared to be an abscess, disappeared." In support of this view of the case, Mr. Brodie remarks: "In whatever way the ulceration of the articular cartilage is produced, there is this remarkable difference between it and the ulceration of the soft parts; suppuration seldom takes place while the ulcer of the cartilage is small; and often the disease proceeds so far as to cause caries of the bones to a great extent without *matter being found in the joint*. Under the head of Ulceration of the Articular Cartilages, Mr. Brodie gives the following case for the illustration of his subject; and it is presented not only to show that

Mr. Brodie believes that spontaneous dislocation does take place; but also, to show the precise pathological condition of all the parts of the joint as I have viewed them for a long time past; such as will account for all the symptoms of a dislocation, when in fact none exists; at least, in the common acceptation of the term, as we are in the habit of using it in relation to an idiopathic dislocation. "A middle-aged man was admitted into St. George's Hospital in the autumn of 1805, on account of a disease of his left hip. He laboured also under other complaints; and died in the February following. On inspecting the body, the soft parts in the neighbourhood of the joint were found slightly inflamed, and coagulated lymph had been effused into the cellular membrane round the capsular ligament. There were no remains of the round ligament. The cartilages had been destroyed by ulceration except in a few spots. The bones, on their exposed surfaces, were carious; but they retained their natural form and size. The acetabulum was almost completely filled with pus and coagulated lymph; the latter adhering to the carious bone, and having become highly vascular. *The head of the femur was lodged on the dorsum of the ilium.* The capsular ligament and synovial membrane were much dilated, and at the superior part their attachment to the bone was thrust upward, so that, although the head of the femur was no longer in the acetabulum, it was still within the cavity of the joint." Mr. Brodie next explains how dislocation was effected in this case. He says: "It was produced in consequence of the destruction of the round ligament, and of the head of the femur having been first pushed outwards by the coagulated lymph and pus which occupied the cavity of the joint, and then drawn upwards by the action of the muscles inserted into the great trochanter." Hereafter, I shall make some practical deductions in relation to my mode of treatment, from the pathological condition above detailed. In a note at the bottom of the page, Mr. Brodie says: "This case affords one example of the *dislocation of the hip from an internal cause*, which some surgical writers have described." Mr. Brodie says: "*The head of the femur was still within the cavity of the joint.*" If this be true, how could the head of the femur be "lodged on the dorsum of the ilium?" Mr. B. explains: he says the head of the bone had left the acetabulum, but had not escaped from the cavity of the joint. If this be a satisfactory definition or explanation of a *spontaneous dislocation* resulting from hip disease, then all I can say is, that it differs altogether from the relation of the head of the bone and the capsular ligament in idiopathic dislocation, where there must be,

either extensive detachment of the capsular ligament from the margin of the acetabulum, or a wide slit through it, at the point forcibly pressed upon by the head of the bone in the act of displacement.

I shall next make a few extracts from Mr. Brodie's lectures, which will go still farther to confirm his views of *spontaneous dislocation*, and of the pathological conditions of the joint upon which the dislocation depends.

In speaking of inflammation of the synovial membrane, he says:—

“A girl was seized with an attack of what was supposed to be rheumatic fever. In the course of two or three days the fever was excessive. She lay in a state of delirium for several days, which seemed, as it were, to supersede the local symptoms which existed in the first instance. She nearly died; but, by and by, things took a favourable turn, and she recovered. After her recovery, her friends looked to the limb, and, to their surprise, found it very much distorted. Mr. Earl and myself (Brodie) saw the girl under these circumstances, and we found that *the head of the bone was lodged in the dorsum of the ilium.*” In this case there is no demonstrative evidence, from an examination of the diseased joint, instituted after death, “that the head of the bone was lodged on the dorsum of the ilium.”

Under the head of Scrofulous Disease of the Hip, I select the following for the purpose of showing the views of the author concerning the manner in which dislocation takes place. He says: “When an abscess presents itself externally from this disease, there is invariably another change in the condition of the limb. It becomes shortened; and this occurs in two different ways. If the *head* and *neck* of the bone be *destroyed*, and especially if the margin of the acetabulum be *destroyed* also, it is no matter of wonder that the muscles should pull up the thigh bone, and that the limb should be shortened. In these cases, the limb is shortened just in the same way in which it would be shortened in a case of *fracture* of the *neck* of the *femur*. The toes, if left to themselves, turn outward, and the thigh may remain in a line with the trunk. But, at other times, the shortening of the limb takes place in another way. The cavity of the acetabulum is filled up with lymph or pus, or with lymph and pus altogether; the capsular ligament of the joint in consequence is dilated, the patient having undergone a great deal of suffering from the tense state of the capsule previously. Then the round ligament is destroyed by the ulceration which has already consumed the cartilage. The head of the femur is pushed from the joint until it passes

from beyond the margin of the acetabulum, and then the muscles pull it upwards, and lodge it on the dorsum of the ilium. Sometimes when the head of the femur is dislocated, it will be nearly entire; in other cases, it is partly absorbed. The dislocation is generally in the same direction; and here, as in those other cases in which dislocation arises as a consequence of inflammation of the synovial membrane, the dislocation being upwards and outwards, the limb is much shortened, and the toes are turned inward. There is one circumstance which favours the escape of the head of the femur from the socket of the acetabulum, and also favours the escape of the remains of the neck, wherever the head has been destroyed; and that is the position in which the child generally lies if left to himself, with his knee bent inwards so as to cross the sound limb."

I think it has been fully shown, from the extended references and quotations of authors on this subject, that the notion or doctrine of spontaneous luxation in hip disease is the prevailing opinion, and that, in the majority of the works referred to, no proof from dissection has been adduced. It is proposed next to examine the morbid changes of the joint in an advanced stage of the disease, and demonstrate from the specimens of *post-mortem* examinations or dissections. I have already quoted, from the writings of Sir Benjamin Brodie, a minute and graphic description of the diseased appearances of the joint—to which nothing can be added except my views in relation to the condition of the capsular ligament as it is attached to the os innominatum. "In the advanced and ulcerative stage of the disease, the round ligament is destroyed, the cotyloid detached and carried away from the margin of the acetabulum, and the capsule, greatly thickened and softened, recedes from the margin of the acetabulum, and seeks new attachments, as ulcerative absorption of the acetabulum encroaches on its natural boundaries. This new attachment of the capsular ligament to the dorsum of the ilium, and the thickened state of the periosteum, is shown in the rough surface; and, in some instances, in spiculæ of bone, occupying a space of considerable distance all around the enlarged acetabulum.

Wherever a chronic periostitis has existed for some time, it is well known that the thickened membrane is much more firmly adherent to the rough surface of bone to which it is attached, than in the normal condition. If this be true, as we meet with periostitis on the tibia, for instance, why may it not be equally true in the case of the innominatum around the acetabulum in hip disease? If this point

be conceded, it will be obvious that it presents a strong barrier against the doctrine of spontaneous luxation.

Mr. Brodie says: "If the *head* and *neck* of the bone be destroyed, and especially if the margin of the acetabulum be destroyed also, it is no matter of wonder that the muscles should pull up the thigh-bone, and that the limb should be shortened." If there should be inversion of the foot, and strong adduction and flexion of the limb, as most likely there would be, all the well-marked symptoms of an upward and backward dislocation would be present, and yet the head and even the neck of the bone cannot be dislocated because they do not exist. The pathological condition of the textures, both *osseous*, *cartilaginous*, and *ligamentous*, which enter into the formation of the hip-joint, in *morbis coxarius*, have been minutely and truthfully described by many writers; with the single exception of the relation of the head of the bone to the attachment of the capsular ligament to the outer face of the innominatum surrounding the *elongated and enlarged acetabulum*.

In as few words as possible, and by the aid of the pathological specimens of the hip-joint, I now propose to explain, and even *demonstrate*, how all the symptoms of a dislocation can be present during life when, in reality, on making a dissection after death, the head of the bone is not found lodged on the dorsum of the ilium.

The cartilage is absorbed, the round ligament is destroyed, and three-fourths of an inch of the upper part of the head of the bone has been carried away by ulcerative absorption. Simultaneously, the cartilage of the acetabulum is disposed of in the same way; the cotyloid ligament, at the upper and back part, is destroyed or removed from the margin of the acetabulum, and the socket is elongated or enlarged three-fourths of an inch in the upward and backward direction. By the action of the forepart of the *gluteus medius*, which lies in juxtaposition with the upper and back part of the capsular ligament, and by the *tensor vagina femoris*, when aided by the action of the *psoas magnus* and *iliacus internus* muscles, the *foot is inverted*, and the *thigh is flexed on the pelvis and strongly adducted*, by which the *trochanter major* is made to project, and to occupy a position nearer the *anterior superior spinous* process of the ilium than in the normal condition; and by the thickening of the capsular ligament, and by effusion of serum and lymph in the cellular tissues, and in the *glutei muscles*, a prominence is observed which has been regarded as the head of the bone *lodged on the dorsum of the ilium*.

By the destruction of three-fourths of an inch of the head of the

bone, and by absorption and elongation of the acetabulum upward and backward to the same amount, if these two parts remain in contact, as it is contended they do, by the action of the glutei muscles, then we have an inch and a half of shortening of the limb. The other symptoms of a dislocation have already been explained.

I have quoted from more than a dozen authors who have written on this subject, and, without a single exception, all admit and sustain the doctrine of spontaneous dislocation in hip disease. It is true, two or three of them regard it as occurring very rarely. All affirm the doctrine, but very few give any proof of it, by an actual examination of the dissected parts. I have selected the strongest marked cases, and have shown in most of them that the diagnosis was founded on *anti-mortem examinations*—the *appearances during life*, as in the case presented by Mr. Fergusson, and one by Sir Benjamin Brodie. Mr. S. Cooper gives a case of dislocation, which was preserved in the London University Hospital Museum, in the year 1839; but in 1848, I could find no specimen in that museum which appeared at all like a spontaneous luxation.

Mr. White's case, reported by Sir A. Cooper, in which the head of the dislocated bone was sawed off, might have been of the character of Mr. Skey's, in which he performed the operation for the removal of a *dislocation* of the head of the bone upward and backward, when, in the course of the operation, he found that all of the head and a portion of the neck had been removed by absorption. It will also be borne in mind that Mr. Brodie gives a case in which "the head of the femur was lodged on the dorsum of the ilium, and yet it was still in the cavity of the joint."

This is a summing up of all the *demonstrative testimony* on the subject of spontaneous dislocation of the hip-joint, caused by ulcerative absorption.

It is possible, and perhaps probable, that a different construction may be given to the term *dislocation*. Indeed, this is to be inferred from the remark of Mr. Brodie, in relation to one of his reported cases; in which he says, "the head of the femur was lodged on the dorsum of the ilium, and yet it was still in the cavity of the joint."

Luxation, which signifies "to put out of place," is defined to be "a displacement of a part from its proper situation." In this sense, the change of *form and position* of the acetabulum, as in cases of ulcerative absorption, might be called a luxation. And yet, surgeons never speak of a luxated or dislocated acetabulum. The most common idea attached to the term "luxation," is, that it is a putting out

of joint—a breaking up and destruction of the natural relations of two or more bones at an articulation, which can be accomplished only by the laceration of ligaments. Now, it has not been shown, in a single instance, of what has been regarded a case of spontaneous luxation, so far, at least, as my investigations go, that the head of bone had been thrust through a *rent* in the *capsular ligament*, or that it had *been detached from the bone and carried sufficiently far back on the dorsum of the ilium to permit the head of the bone to occupy the space between its attachment and the margin of the acetabulum*. To this statement I must, however, make an exception, if it can be so considered. I find, on referring to my notes taken in the summer of 1848, at St. Bartholomew's Hospital Museum, the following memorandum: "Wet specimens of hip disease, 13; one of which, No. 17, appeared to be more like a spontaneous luxation from hip disease than any I had seen, or afterwards saw, in all of my researches."

Dr. Scoon, a graduate of the Albany Medical College, some four years since reported the following case to me: A lad, fourteen years of age, was attacked with the ordinary symptoms of hip disease, and while under the care of one or two physicians of the country town in which he resided, at the end of six or eight months, there began to be shortening of the limb, inversion of the foot, flexion and adduction of the thigh, and preternatural prominence of the trochanter major. Next, an abscess formed, which was opened; at length, the patient became troubled with a cough, and other symptoms of disease of the lungs, and in about twelve or fifteen months died. Three out of the four physicians who saw the patient during life, were firm in the belief that there was a dislocation of the hip upwards and backwards, and, without doubt, would have reported it as such, had not a *post-mortem* examination proved the contrary. Dr. Scoon, who was thoroughly imbued with my notions of the pathological conditions of hip disease, contended that there was no dislocation. He made the *post-mortem* examination in the presence of the three gentlemen, who called it a case of spontaneous luxation. The soft parts were carefully thrown aside, and on exposing the interior of the joint, the round ligament was found shrunken, though not detached either from the acetabulum or head of the bone—the articulating surface of the acetabulum, that which is naturally covered with cartilage, *destroyed, and elongated upwards and backwards nearly three-fourths of an inch*—the cartilage was removed from the upper part of the head of the bone, where it was a little flattened by ulcerative absorption. The capsular ligament was thickened, but still attached to the border

of the *enlarged acetabulum* and face of the ilium; and not the slightest evidence appeared, to show that the head of the bone had ever occupied the dorsum of the ilium. It is not my design to expose the errors in diagnosis of physicians and surgeons, in relation to the form of disease of the hip, now under consideration; but I have known several instances of hip disease, pronounced idiopathic luxation, the pulleys applied, and a vigorous attempt made to reduce the supposed dislocation. I am sustained in my views, as respects spontaneous dislocation of the hip, by one of the most *minute, experienced, and accurate* pathologists in the United States. I refer to Dr. J. B. S. Jackson, of Boston, who has in his pathological cabinet four or five strongly marked specimens of hip disease, and in almost every respect corresponding with my own, and those of the College of Physicians and Surgeons of New York. The specimens of Dr. Jackson and my own were exhibited to a portion of the members of the American Medical Association, at the rooms of Dr. Jackson, while the Association was in session in Boston, in May, 1849.

Having occupied so much time in investigating the subject of spontaneous luxation, and the pathology of the joint in hip disease, I must hasten to a brief consideration of what I stated at the commencement of this article, a mode of treatment that was new, and nearly or quite peculiar to myself. But I find, in looking over the *Medical Examiner*, published in Philadelphia, January 19, 1839, that William Harris, M. D., has anticipated, and put into practice my theory in the treatment of four cases of morbus coxarius, without giving any explanation of the theory or principles upon which the practice is founded. In the third or fourth case treated by Dr. Harris, he speaks of *dislocation* in familiar terms, and as though it followed, as a matter of course, that there was a *dislocation*, because the *symptoms were present during life*. In no case, however, does he speak of a dislocated hip, demonstrated by a *post-mortem examination*. Dr. Harris's new, and, as I deem, important practice in the treatment of hip disease after *distortion*, and, as he believed, *dislocation*, had taken place, consisted in the use of *extension* and *counter-extension*, by means of Physick's long splint, modified by Professor Gibson. There seems to be nothing new in the *medical* treatment of the four cases reported as being successfully treated on the principle of extension and counter-extension.

The first, and as Mr. Brodie says, *a most*, but I say *the* most important part of the treatment of morbus coxarius, consists in the keeping of the joint in a *perfect state of repose*. For a long time

before the republication of Mr. Brodie's lectures in this country, and of course, before I saw his work, I was in the habit of explaining and illustrating this important principle in my lectures, in nearly the same language as that adopted by Mr. Brodie. My illustration has been this: "Suppose you had a severe burn, or an ulcer on the back of one hand, and with the other were to rub it a dozen or twenty times a day, how long do you think it would take to heal such a sore, under such treatment?" Mr. Brodie says: "If your leg were inflamed, and you were to rub it a dozen times every day, would you not make the inflammation worse? If your leg were ulcerated, and you were to rub it in the same manner, would you not prevent the ulcer from healing? Nay, rather, would you not make the ulcer spread? If the hip-joint, then, be inflamed, and you move it several times a day, will not the inflammation be kept up? If the cartilages or bones or both are ulcerated, and the joint be moved, and the ulcerated surfaces rubbed against each other, is it not to be expected that the disease will be aggravated?" Mr. Brodie adds: "It matters not how trifling the disease may be, your *first duty* to your patient is to make him lie down at once, and keep the hip-joint in a perfect state of immobility.

It is proposed next to show how *extension* and *counter-extension*, the mode of treatment which I believed was peculiar to myself, as it is not to be found in any of our systems of surgery, can be explained on pathological principles. In the advanced stage of the disease, the cartilages of the acetabulum and of the head of the bone are destroyed; the carious and loose spongy bony tissue is covered with coagulated lymph, and this adhering to the surfaces of the bones, becomes highly vascular. Now, if these two surfaces thus covered with *organized* or *organizable* matter, could be kept in easy apposition and at rest—without too much pressure on the one hand, and on the other without exerting too much separating or sundering force, in many instances a bony ankylosis would be the result. By the *pressure* of the muscles that act on the head of the bone and acetabulum, in addition to *ulcerative absorption*, we get *progressive absorption*, and hence the great destruction of the osseous parts of the joint. Experienced surgeons know very well that, if a dossil of lint be too bulky, or too much compression be applied to a healthy granulating ulcer, absorption of the granules will be the result. Extension and counter-extension are used with a view to prevent *undue pressure* on the delicate and tender surfaces of the diseased bones. This treatment of hip-disease can be used to advantage in an advanced state of

the affection, as is shown in the case treated by Dr. Harris. In the early stage of the disease, before shortening or distortion of the limb takes place, it will be important to resort to the use of the long splint, to maintain the joint in a state of rest, that the inflammation may subside.

The late Sir Charles Bell, who was a man of genius, and really a medical philosopher, in speaking of the position of the limb of the patient with diseased hip, says: "The thigh of the affected side is thrown over the other, that the head of the thigh-bone may be raised, so as to relieve the inflamed socket." From this hint or remark, we infer the propriety of making use of *extension* and *counter-extension* to afford the same relief to the inflamed socket, without endangering an "actual dislocation in extreme cases," of which there would seem to be danger, in the estimation of Mr. Bell. I have used the long splint in several cases in the treatment of hip disease, where there did not appear to be much or any shortening. In only two cases have I used the long splint with efficient *extension* and *counter-extension*, to overcome what appeared to be a permanent and unfortunate distortion. In one case the leg was flexed on the thigh, the thigh on the pelvis, and the femur rigidly fixed in such a state of adduction, as would carry it nearly across the opposite limb above the knee. The inflammation was so acute, the affected part so tender, and the patient so sensitive and irritable, that it was impossible to place even a small pillow between his knees and the lower part of his thighs. I was sure that if the limb should become ankylosed in that position, as there was good reason to apprehend that it would, it would be almost a useless appendage as an organ of locomotion.

To obviate, or prevent such a result, I conceived to be my duty, if practicable. Accordingly, I put my patient under the full influence of ether, and proceeded to *extend* and *abduct* the limb, by bringing it along the side of the other, and to which I applied the long splint, and made use of extension from the ankle, and counter-extension from the perineum. Before the influence of the ether had entirely subsided, I gave the patient a full dose of morphia, which was repeated three or four times a day, for two or three days; till some of the soreness, caused by the operation, had passed off, and he became accustomed to the mechanical power applied to the limb. In a few days, I began to give the patient, at night, a powder, composed of calomel, jalap, and Dover's powder, which insured a good night's rest, and generally purged in the morning. The splint was

used eleven or twelve weeks, and under this mode of treatment the boy seemed to recover, if not with great freedom of motion in the joint, at least with a limb nearly as long as the other, and in a vertical position, or that which corresponded with the other limb when standing upon his feet. The patient continued to improve for several months, when at last, by over-exercise and imprudence, suppuration was brought on, and an abscess was opened at the inner and upper part of the thigh. This was not followed by any more shortening or malposition of the limb. It is now a little shorter, and nearly ankylosed.

In another case, in which extension and counter-extension were employed, the patient was about fifteen years of age; and previous to the attack was considered healthy. In the latter part of April, 1852, he waded into the river, where he remained for a short time, which was supposed to be the origin of his disease. In a week after the exposure he was attacked with a hard chill, which was followed by a high fever, when very soon severe inflammation fixed in the left hip, which continued without any abatement for eight or ten weeks. I was informed by the mother of the boy that the physician who first attended him regarded the affection as inflammatory rheumatism. In ten or twelve days from the commencement of the disease the limb began to contract, being strongly everted, the leg flexed on the thigh, and the thigh very much flexed on the pelvis, and greatly *abducted* or *carried off* from the other knee. When the patient stood erect on the well limb, the other could not be brought within a foot of touching the ground, nor could the two knees be made to touch by about the same distance. All motion at the hip-joint appeared to be lost. The health of the boy seemed in every respect good. Such was the condition of the patient on the 23d of October, 1852, when I was consulted upon the *possibility* and *propriety* of fetching the diseased limb into a position, by which it could be used as an organ of locomotion. From the little experience I had had in the treatment of the case already briefly noticed, which was in some respects analogous, although it had existed a less number of weeks than the case now under consideration had months, and from the strong anxiety of the boy to be relieved, and with the full consent of his parents, even though I had no *book authority* for my proposed plan of procedure, I resolved to make an effort to place the limb in a position favourable for walking.

It will be observed that from about the last of April, the time of the attack of the disease, to the 23d of October, the day of the

operation, nearly six months had elapsed—long enough for pretty strong adhesion to take place between the head of the bone and acetabulum, capsular ligament, etc. consequent on acute inflammation of all parts of the joint. The patient was taken into the theatre of the Albany Medical College, before the medical pupils of the institution, and by the counsel and aid of a few physicians, placed under the influence of ether, when my assistants fixed by their hands the pelvis, while I embraced the limb above the ankle with one hand, and the thigh just above the knee with the other, by which I was enabled to produce a rotating motion of the limb, breaking up the adhesion of the head of the bone, and carrying the knee inwards towards the other, so that the head of the bone was observed to move outwards and backwards. As the adhesions yielded to the force applied, a distinct *crackling* or *crumping crepitus* was very perceptible. In the distorted position of the limb, the head of the bone appeared to rest on the anterior or pubic side of the acetabulum, and pressing firmly on the anterior or pubic wall of the capsular ligament. The limb was *extended*, *adducted*, and brought so as to lie parallel to the other in the extended position, and within about an inch of being as long as the other, where it was fixed by a perineal belt, long splint, compress and roller, after the manner of treating fracture of the thigh on the principle of permanent extension. The patient was conveyed in the horizontal position to his lodgings in the city, where he remained with the splint applied for two weeks without much suffering or medication. At the end of the two weeks he was removed to the country, six miles; and on the second day after reaching home the splint was removed and not again replaced. The patient soon after began to move about on crutches; and now (Feb. 26) I find him able to walk very well without the use of a crutch or even a cane. The limb appears to be an inch or an inch and a half shorter than the other—but by the aid of a high-heeled boot, which he is having constructed, he anticipates skipping about as lively as other boys.

It will be observed that in this case there was no suppuration or abscess, which is another instance, among quite a number that have fallen under my observation, of absorption of the head of the bone, “showing (as Mr. Brodie says) that ulceration may take place without the formation of pus.”

I believe it is a conceded point, by all pathologists and surgeons, that the muscles are the inherent, internal disturbing agents of displacement in fractures—that the lesion in the broken bone, and the

irritation of the muscles in juxtaposition result in *inflammation* and *spasmodic contraction*. I believe, also, that another point in relation to hip disease is equally well settled; it is, that the muscles about the joint are the active agents in producing distortion. The inflammation of the several parts of the joint extends to the muscles more or less, by which they are stimulated to act either continuously or spasmodically, fixing the limb in its malposition. I have seen a case of white swelling of the knee-joint (ulceration of the cartilages), where the spasm of the hamstring muscles would raise the joint from six to eight inches from its resting-place; and in a case, too, where binding the limb to a fixed Amesbury's splint, did not prevent the motion of the joint caused by involuntary contraction of the muscles.

I shall quote once more from Mr. Brodie, to show the comparison which he institutes between the condition of the hip-joint, in the advanced stage of morbus coxarius, and fracture of the neck of the thigh-bone.

Mr. Brodie says: "At the conclusion of this investigation you will ask, 'What becomes of a joint of which the cartilage has been destroyed by ulceration?'" He replies: "If it be extensively destroyed without suppuration, the case may be *compared to one of simple fracture*; and, if there be suppuration, it may be compared to one of *compound fracture*; and in either instance the ulcerated surfaces of the bone come together, and ultimately become united. Bony ankylosis, however, takes place very slowly in the scrofulous disease which I described in the last lecture; the bond of union being for a very long time nothing but a soft ligamentous substance. But in other cases, where the cartilage is ulcerated without scrofulous disease of the bone, bony ankylosis takes place, I believe, readily enough."

Now I would most respectfully ask Sir Benjamin Brodie, or any other experienced and prudent surgeon, if he should be called upon to treat a case of "simple fracture" of the neck of the thigh-bone, whether he would not employ suitable means, if bony union was desired, to elongate the shortened limb, and to maintain the extremities of the fractured bone in contact.

If there is some analogy between the condition of the hip-joint in morbus coxarius, and fracture of the neck of the bone, why should there not be some similarity in the mode of treatment?

If the operation of excision of the carious head and neck of the thigh-bone in morbus coxarius be an established practice, resting on high authority; and if the result of the operation be favourable in

re-establishing the health of the patient, and restoring the limb to more or less utility, may we not make a practical application of these facts in sustaining the principle of extension and counter-extension?

I do not believe there ever was a case in which the head of the bone was excised in a carious condition without there was a similar state of disease in the acetabulum. Removing the head, therefore, does not remove all of the disease. In all of the specimens of ulcerative absorption of the head of the thigh-bone that I have ever examined, I have uniformly noticed quite as much disease and organic change in the acetabulum. The disease commences quite as early in the acetabulum as it does in the head of the bone.

In my notes, taken from the examination of the specimens of hip disease in Guy's Hospital Museum, I find the following observations: "I saw one wet preparation where the *acetabulum* was *perforated*, and the *abscess communicated* with the rectum. Also, a specimen of a young child, in which the acetabulum was *ulcerated*, and *even perforated*, through which a *probe was passed*, while the *head of the bone was in its normal state*."

If the carious head of the bone, when disturbed by the movements of the limb, or by the *contraction* of the muscles about the joint, be not the source of *irritation*, and the *cause* of the extension of the disease, how does it happen that excision ever succeeds when so much disease is left in the acetabulum?

Besides, if a compound fracture be much more dangerous and troublesome to treat than a simple fracture; and if we regard the hip-joint, in morbus coxarius, as it has been by Mr. Brodie, in the light of simple and compound fracture, would it not be far better to remove the *cause* of the *continuance* and *extension* of the disease without converting a simple into a compound fracture? Would not *extension* and *counter-extension* be attended with far less pain, and suffering, and danger to the patient, than excision of the head of the bone?

In comparing my mode of treatment of the advanced stage of hip disease with that employed by Dr. Harris, I find that the *principle* of extension and counter-extension is the same; and the *practice* differs only in this respect, viz., I accomplish at once, by the aid of ether or chloroform, what took Dr. Harris some days or weeks to effect. It will be remembered, however, that Dr. Harris's cases, reported in 1839, were treated before the discovery and introduction into practice of either ether or chloroform.

I find I must bring my lengthy paper to a close; and will only add that my aim has been to establish two points—the pathological condition of the head of the bone and acetabulum, and their relation to each other in the condition that has been so universally regarded as luxation; and the principle of treatment by extension and counter-extension explained and founded on the laws of ulcerative and progressive absorption. If my views are sustained by ascertained facts, and by demonstration from the morbid specimens of the hip-joint—if the theory of practice, upon the plan of *permanent extension*, should become an established *principle* in the treatment of hip disease, in an advanced stage, or even before any great organic change has taken place in the joint, I shall have accomplished my object; and I trust have contributed a trifle to the advancement of surgical science. If I am in error in the views I entertain on this subject, I will sincerely say that I am open to conviction. I solicit the attention of the profession to the investigation of the subject; and desire it to be either proved or disproved by dissection and demonstration after death.

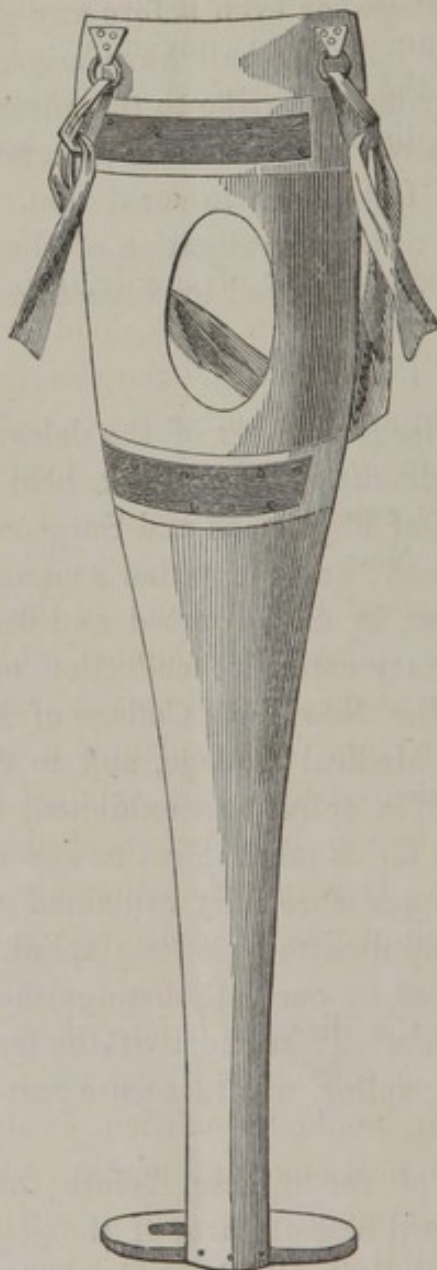
At a meeting of a large number of the delegates of the Association, and citizen physicians of New York, held at the Anatomical Theatre of the College of Physicians and Surgeons, a synopsis of the foregoing Essay was read; and the author's views of the pathological condition of the disease, in an advanced and destructive stage, demonstrated from a pretty extensive collection of specimens of hip disease, belonging to the New York College of Physicians and Surgeons, to the Albany Medical College, and to the author. At the same time the model of a splint was exhibited, which was designed to treat the disease, so far as mechanical means are concerned, upon the pathological principles more fully explained in the Essay.

The treatment of hip disease by a long splint, I believe, was first suggested and employed by our late distinguished countryman, Dr. Physick, of Philadelphia. It seems that the only object he had in view, in using the long splint, was to secure rest and perfect immobility of the joint.

In the early stage of the disease, before there is any organic change either in the hard or soft parts of the joint, *rest alone*, even without the aid of a splint, would be sufficient to answer one of the first and most important indications; and perhaps the resolution and moral discipline of an adult might be relied on without the use of a splint. But in restless children, Dr. Physick's mechanical restraint

was absolutely necessary in order to insure the most favourable and successful result. If, however, my views are correct in supposing that pressure produces absorption of the organized and organizable matter on the head of the bone, and the cup of the acetabulum, after destruction of their cartilages, then the principle of extension and counter-extension, as first employed by Dr. Harris, is highly important to prevent *progressive absorption*.

Dr. Physick's long splint, as used by Dr. Harris, was calculated to fulfil a part of the indication—relief from pressure of the upper part



of the head of the bone, and the upper and marginal part of the acetabulum. But in fixing it to the whole length of the limb, and to the trunk nearly as high up as the axilla, there must necessarily be

a considerable amount of pressure on the outer face of the trochanter-major, the tendency of which would be to produce absorption of the head of the bone occupied by the attachment of the ligamentum teres, and of the deep part of the acetabulum, so that the diminished head and neck of the bone might be thrust through into the cavity of the pelvis, which I have actually seen.

The structure of the splint exhibited to the members of the Association is designed to obviate all pressure on the trochanter-major.

The accompanying drawing, made by Mr. Daniels, of New York, will convey a better idea of its design than can be explained in words only. Its length, breadth, &c., must be adapted to the age and size of the patient.

The apparatus is simple, and consists, as will be observed, of a long leg and foot-piece, and a perineal belt or strap. In having the upper portion of the splint broad, and moulded to the trunk, and the extremities of the perineal strap attached to the anterior and posterior angles of the same, the extending and counter-extending force can be made to act very much in a line with the axis of the limb; a circumstance of considerable importance in the treatment of fracture of the neck of the femur.

The long splint may be made of thin wood, and moulded to the shape of the patient's limb. The foot-piece projects to an equal distance on each side, so that the splint may answer for either side. The extension may be made by straps attached to the ankle and lower portion of the leg, and fixed to the foot-piece.

It will be observed that I have hardly alluded to the *early diagnostic* symptoms of morbus coxarius, nor to the *general plan* of treatment. These points I propose to take up hereafter.

to Philadelphia & return

Very truly
Yours
J. J.