

**On gunshot wounds of arteries, traumatic hemorrhage, and traumatic aneurism / by John A. Lidell.**

**Contributors**

Lidell, John A.  
National Library of Medicine (U.S.)

**Publication/Creation**

Washington, D.C. : McGill & Witherow, printers and stereotypers, 1863.

**Persistent URL**

<https://wellcomecollection.org/works/vz6a6d2v>

**License and attribution**

This material has been provided by This material has been provided by the National Library of Medicine (U.S.), through the Medical Heritage Library. The original may be consulted at the National Library of Medicine (U.S.) where the originals may be consulted.

This work has been identified as being free of known restrictions under copyright law, including all related and neighbouring rights and is being made available under the Creative Commons, Public Domain Mark.

You can copy, modify, distribute and perform the work, even for commercial purposes, without asking permission.

LIDELL (J. A.) *transid.*  
*from the Author*

CCCCXXXIV.

ON GUNSHOT WOUNDS

OF ARTERIES,

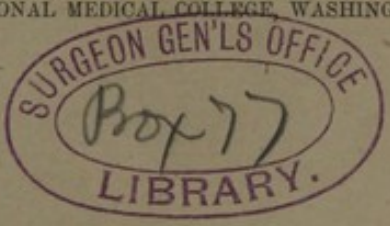
TRAUMATIC HEMORRHAGE AND TRAUMATIC  
ANEURISM.

BY

JOHN A. LIDELL, M. D.,

SURGEON U. S. VOLUNTEERS,

PROFESSOR OF ANATOMY IN THE NATIONAL MEDICAL COLLEGE, WASHINGTON.



WASHINGTON, D. C.:

McGILL & WITHEROW, PRINTERS AND STEREOTYPERS.

1863.

# ON GUNSHOT WOUNDS OF ARTERIES

TRAUMATIC HEMORRHAGE AND VASCULAR ANEURISM

BY JOHN A. LIBELL, M.D.

LECTURE 2. A. B. 1887

PROFESSOR OF SURGERY IN THE UNIVERSITY OF CALIFORNIA

## CASE I.

General account showing the ordinary course and unusual the  
traumatic nature of rupture of the artery, circumstances of  
acute hemorrhage occurring on the first day, history of  
the aneurism extending to the subcutaneous level, the date  
of rupture, and its course.

Case I. John F. Jones, Company "B," 15th California Coy.  
After (rebel) and 21 years and of sound constitution was  
admitted to Stanton Hospital Jan. 23, 1867. He had been  
wounded two days before (Jan. 21) in action near Middle-  
burgh, Va., by a shot from a rifle. The bullet which  
the eye, was central in shape, penetrated the posterior  
muscle of the left eye at a point on a level with the orbit,  
and about one and one-half inches from the margin of  
the pupil passed directly back wards beneath the shoulder,  
wounding the artery together with the distal portion  
of nerve and vessel behind. Patient said he lost a great  
deal of blood immediately after the wound was inflicted, as  
much indeed that he fainted, when the hemorrhage ceased, and  
had not since returned.

On admission to hospital his left eye exhibited some swelling  
by enlargement in diameter, and its lower side was easily  
moved nearly down to the eye joint. It was also painful,  
the loss of both sensibility and mobility being complete.  
There was no radial pulse in that arm, and pulsation could not  
be detected in the brachial or any other artery there. From  
this we inferred that the axillary artery had been severed by  
the bullet. The temperature of the limb was not below the  
normal standard; on the contrary, we thought it to be some-  
what warmer than the limb of the opposite side. There was

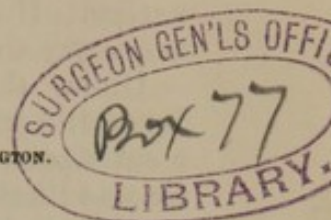
# ON GUNSHOT WOUNDS OF ARTERIES,

TRAUMATIC HEMORRHAGE AND TRAUMATIC ANEURISM.

BY JOHN A. LIDELL, M. D.,

SURGEON U. S. VOLUNTEERS,

PROFESSOR OF ANATOMY IN THE NATIONAL MEDICAL COLLEGE, WASHINGTON.



## CASE I.

*Gunshot wound dividing the axillary artery, and injuring the brachial plexus of nerves, of the left side, circumscribed traumatic aneurism occurring on the twenty-first day, ligature of the subclavian external to the scalenus, death forty-six days afterwards from exhaustion.*

CAPT. JOHN F. JORDAN, Company "B," 13th Virginia Cavalry, (rebel,) aged 31 years, and of sound constitution, was admitted to Stanton Hospital June 23, 1863. He had been wounded two days before, (June 21,) in action near Middleburgh, Va., by a shot from a carbine. The bullet, which, by the way, was conical in shape, penetrated the pectoralis major muscle of the left side, at a point on a level with the axillary artery, and about one and one half inches from the margin of the arm-pit, passed directly backwards beneath the shoulder, wounding the axillary artery together with the brachial plexus of nerves, and escaped behind. Patient said he lost a great deal of blood immediately after the wound was inflicted, so much indeed that he fainted, when the hemorrhage ceased, and had not since returned.

On admission to hospital his left arm exhibited some swelling œdematous in character, and its inner side was ecchymosed nearly down to the elbow joint. It was also paralyzed, the loss of both sensibility and mobility being complete. There was no radial pulse in that arm, and pulsation could not be detected in the brachial or any other artery thereof. From this we inferred that the axillary artery had been severed by the bullet. The temperature of the limb was not below the normal standard: on the contrary, we thought it to be somewhat warmer than the limb of the opposite side. There was

nothing remarkable in the appearance of the wound. The patient's general condition was good. He did not look as if he had suffered from hemorrhage. The bowels were constipated : ordered a saline purge together with a spare diet, and, with a view to lessen the tendency to secondary hemorrhage, he was directed to remain quiet in bed, to exert himself as little as possible, and to have ice applied constantly over the injured artery. He was also directed to take morphine at night if necessary to procure rest.

Under this treatment the patient progressed without an unfavorable symptom ; the wound cleaned itself and closed up in a satisfactory manner, and we congratulated the patient in that he was likely to get well without suffering the terrible secondary hemorrhage, which frequently attends gunshot wounds of the axillary artery. The limb continued to be completely paralyzed as to motion, but sensation had gradually been restored to the fingers, hand, and fore-arm.

On the 12th of July (morning) we noticed the appearance of a small rounded circumscribed swelling of the size of an egg, at the seat of injury to the artery. The scar of the anterior orifice of the gunshot wound was exactly on the summit of the convexity of the swelling, as the patient lay in bed. The tumor was tense in feel, and pulsated distinctly and synchronously with the heart. There was, however, an entire absence of the aneurismal thrill and aneurismal bruit. By compressing the subclavian artery against the first rib, the tumor became soft, much less in size, and ceased to pulsate : on withdrawing compression the tumor speedily filled up, became tense, and pulsated again. Patient stated that during the preceding night he felt something " give way " in his left arm-pit while attempting to change the position of that arm by the aid of the right hand. During the day the aneurism increased rapidly in size, and in the evening was fully twice as large as when first noticed in the morning.

*July 13*—The aneurism continued to increase steadily in size, and in the evening was about half as large as the clenched fist.

*July 14*—The aneurism had grown but little since previous day ; it was still rounded, distinctly circumscribed, and somewhat oval in shape : by compressing the subclavian, it ceased to pulsate, became soft and much shrunken, but the prior condition of things was restored speedily on withdrawing compression ; as on a previous occasion, there was still no thrill or bruit.

*Diagnosis : circumscribed traumatic aneurism of the axillary artery.* From the entire absence of pulsation in all the arteries beyond the aneurism, which existed even at the time of admission to hospital, and the complete want of thrill and bruit in the aneurism itself, we believed that the aneurism had

been developed from the proximal end of the severed artery, and that opinion was strengthened by the fact that the swelling had not expanded outwards and downwards into the armpit, where there was but little in the anatomical structure of the parts to obstruct its growth, any more rapidly than it had done in another direction, where it was covered over and bound down by the pectoral muscles. The swelling had expanded so equally in all directions, that the scar of the anterior wound still remained exactly over the centre of the tumor, as when we first saw it.

The aneurism was so distinctly circumscribed, that although its origin was traumatic, it was deemed advisable to attempt a cure of it by the Hunterian method. As there was not sufficient space to secure the artery below the clavicle without opening the sac, I proceeded to tie the left subclavian artery external to the scalenus, on the afternoon of that day, (July 14.) The patient being under sulphuric ether, that operation was performed without difficulty by the ordinary method. On tightening the ligature the tumor ceased to pulsate, shrunk a good deal, and became soft.

The left arm was directed to be wrapped in cotton wool, and to be kept warm by the further aid of bottles of warm water, to be renewed from time to time as occasion might require. A full dose of morphia was prescribed. He was enjoined to preserve the recumbent posture, and to avoid exertion of every kind. A milk diet was allowed.

*July 15*—Patient had a comfortable night; temperature of arm not diminished; discontinued the warm water.

*July 16*—Patient doing well in every respect; arm warm; color thereof good; discontinued the cotton wool.

*July 17*—Bowels being confined, he took Magnes. Sulph.  $\bar{\text{ʒ}}\text{ij}$ .

*July 19*—Aneurismal sac opened spontaneously last night through the anterior scar of the gunshot wound, and discharged two or three ounces of very dark-colored blood, mixed with pus. Suppuration of the sac had been threatened ever since the day after the operation. He was allowed a full diet.

*July 20*—A moderate discharge of old blood and pus, accompanied with a gradual diminution in the size of the aneurism, and but a moderate degree of inflammation of the sac continued on this and several days following, the patient's condition being unexceptionable all the while.

*July 27*—The aneurismal swelling had entirely disappeared; suppuration of the sac, moderate in quantity, still continued, the pus being of a good quality.

*August 1*—*The ligature separated and was removed to-day, without the occurrence of hemorrhage or any other difficulty; discharge from sac good in quality and steadily diminishing in quantity; discovered some excoriation at the inner side of the left elbow, occasioned probably by pressure, the patient having*

followed very closely the injunction to keep as still as possible in the recumbent posture; directed a stimulating plaster to be applied, and the pressure to be removed to other situations by arranging pillows.

*August 5*—Discharge from sac had subsided to a small quantity of healthy pus, and the orifice was manifestly contracting. We hoped that adhesion of the sac was taking place. Patient's condition seemed to be favorable in every respect, except that he had been losing flesh for several days past without obvious cause. For want of any other reason, we attributed it to the extreme heat of the weather, the temperature both day and night having been unprecedented ever since July 25th, the mercury at mid-day ranging from 90° to 100°, and seldom falling below 80° at night.

*August 6*—A profuse flow of blood from the sac came on this morning without warning; the loss of blood being so rapid as to threaten speedy death. The officer of the day was close at hand, and stopped the bleeding by injecting about one ounce of liquor ferri persulph. into the bottom of the sac, through a female catheter, introduced for the purpose. The hemorrhage ceased immediately. We had been emboldened to use the persulphate of iron freely in this way, because we had a few weeks before (June 22) stopped a troublesome secondary flow, in alarming quantity, of arterial blood from the cavity of a large abscess, associated with gunshot fracture of the right thigh, by injecting about two drachms of liquor ferri persulph. through a catheter, carried into the neighborhood of the supposed source of the hemorrhage, a branch of the profunda artery, and no unpleasant effect of any kind followed it. Again, about the same time, we had been troubled to manage a case of general oozing of blood from the cut surface of a thigh, amputated secondarily for gunshot injury. After trying exposure to the air, ice water, and even ice, without effect, we stopped this bleeding immediately by covering the end of the stump with pledgets of lint soaked in liquor ferri persulph. Aside from pretty severe pain, which soon subsided, no unpleasant consequence of any kind followed. We did not discover any evidence of even the feeblest action as an escharotic, and even have since thought that the case progressed better than other amputations of the same class.

In consequence of the secondary hemorrhage and the efforts to repress it, the aneurismal sac became filled up again to the original size.

*August 10*—Another severe hemorrhage occurred from the same orifice; it was readily stopped by again injecting persulphate of iron in solution.

*August 11*—Profuse hemorrhage occurred to-day through the opening of the posterior orifice made by the bullet, after it had been healed for more than a month. This bleeding was also

suppressed immediately, by injecting liquor ferri persulph. through a catheter. After this there was no more hemorrhage. During the next few days he seemed to rally from the depression produced by these repeated losses of blood. He was ordered to have wine, and anything in the line of supporting treatment that he would take.

*August 18*—The aneurismal sac has again suppurated, and there is a profuse discharge of dark-colored and very offensive pus.

*August 25*—Patient failing rapidly: suppuration very profuse and extremely offensive in character.

*August 29*—He died worn out with the suppuration and the hemorrhages forty-six days after the operation, and twenty-eight days after the ligature came away.

*Autopsy eighteen hours after death*: Emaciation extreme: rigor mortis moderate: a large elongated cavity, with ragged dark-colored walls, occupies the original seat of the aneurism, and extends beyond it outwards into the axilla: the axillary artery is found to have been severed obliquely by the bullet about one and one half inches above its termination in the brachial: the divided extremities are separated widely apart, (to the extent of about three inches): the distal end appears to have been pushed away from the proximal end, either by the original aneurism, or the subsequent hemorrhages and suppuration: the proximal end is oblique and closed, while the bruised and lacerated portion of it appears about to be cast off by the ulcerative process, as a distinct line of demarcation has been formed: the distal end is oblique and unclosed, but the calibre of the artery is contracted down to about a line in diameter, and it is blocked up by a coagulum three eighths of an inch long: the branches of the axillary given off above the point of injury, especially the superior thoracic and the acromial thoracic are much enlarged: the axillary vein is greatly diminished in size about the track of the bullet, but it is still pervious: the brachial plexus of nerves was also wounded by the bullet, all the trunks being cut off except that of the musculo-spiral and circumflex nerves. The extremities of the divided trunks (proximal) were somewhat bulbous.

At the seat of the operation the wound which, at one time was nearly closed, is now open quite down to the artery at the point of ligation, the new granulations having been re-absorbed to that extent, but the artery for a distance on each side thereof is surrounded by a dense mass of new cellular tissue, so thick and dense as to make it a little difficult to get at and remove the specimen without injury. On the proximal side of the ligature the vessel is blocked up to a distance of about five eighths of an inch: on the other side of the ligature it is blocked up to the extent of about two eighths of an inch.

In the cavity of the thorax we find old pleuritic adhesions on



both sides, and old tuberculous cicatrices at the apex of each lung ; but both lungs are now entirely free from tuberculous deposits : abdomen not opened.

The following specimens belonging to this case were sent to the Army Medical Museum, Sept. 10, 1863 :

1st. The ligature.

2d. The artery extending from a distance within the seat of ligature down to the point of severance by the bullet, showing effects of ligature, etc.

3d. A piece of the artery from the distal side of the wound, showing its diminished calibre, obstruction, etc.

4th. The brachial plexus, showing those trunks which were severed by the bullet.

#### TRAUMATIC HEMORRHAGE.

This case deserves more than a passing notice. It illustrates several surgical themes of great interest, and therefore will repay attentive study. In the first place it invites our attention to the subject of hemorrhage, and especially to that form of it which is occasioned by wounds of the larger arteries. The principal danger attending the wounds of all arteries, arises from the loss of blood ; and the greater danger which attends wounds of the larger arteries, is due to the fact that the loss of blood from them may be so rapid as to destroy life before effective assistance can be obtained. Incised wounds severing any of the larger arteries are always speedily fatal unless the hemorrhage chances to be arrested by art. Thus, the suicide cuts his throat so as to sever the carotid artery, or gashes his thigh, so as to sever the femoral artery, or the homicide stabs his victim in such way as to cut across the axillary artery, and he bleeds to death in from five to ten minutes, unless the hemorrhage be retarded or arrested by extraneous aid. In all such cases nature unassisted is powerless to prevent a fatal result.

But such an issue does not necessarily follow gun-shot severance of an artery belonging to the class above mentioned, as the history of Jordan's case abundantly proves. The autopsy showed that the carbine shot had divided the axillary artery completely, and the patient's statement showed that the hemorrhage from the wound, which was very profuse at the outset, soon ceased spontaneously, and did not recur. Moreover, the loss of blood was not so great as to be noticeable in his appearance two days afterwards, when he was admitted to hospital. Now it becomes a matter of surgical interest to inquire into the reason why nature unaided can stop the hemorrhage from a large artery, severed by a gunshot, and cannot stop it in case of clean division by a cutting instrument. The foregoing case will, I think, if studied closely, afford a satisfactory explanation. The carbine shot bruised and lacerated the coats of the

artery as it passed athwart them : the roughly divided arterial tunics retracted within the sheath, and contracted upon themselves immediately, by virtue of the elasticity of the middle coat, and thus a lodgment for clot was formed in the bruised extremity of the artery. But while this was taking place the patient lost blood so rapidly as to become faint, (he said he fainted,) whereby the tendency of the blood to coagulate (coagulability) was increased ; the volume and firmness of the clot being proportionately increased, and the force of the circulation diminished all at the same time. In this way nature unassisted plugged up the severed artery with a coagulum, so as to stop the effusion of blood speedily. It appears, on the other hand, that in case of the severance of a large artery by an incised wound, the hemorrhage does not cease spontaneously, for want of a place of lodgment for a coagulum sufficient to stop up effectually the bleeding orifice : and moreover, that spontaneous occlusion of an incised wound of an artery, by coagulum, is never effectual to stop the hemorrhage, except the artery be a small one, such as the anterior temporal, (branch,) and even then complete division is essential to success, as observation has abundantly shown. Observation has also shown that the greater the amount of the contusion and laceration inflicted upon an artery, the smaller is the quantity of hemorrhage, other things being equal or, in other words, that the more an artery is bruised and torn, the more readily is a lodgment afforded for such a coagulum as will restrain bleeding : vide cases of limbs torn off by cannon shot and machinery, scattered everywhere through the annals of modern surgery.

There is another interesting feature connected with the topic under consideration. This man was struck by a carbine-shot, fired at short range, the projectile having therefore the maximum of velocity, or nearly so, and consequently the extremities of the severed artery were contused and lacerated proportionably less than they would have been by a similar bullet moving at a slower rate of speed. This view is corroborated by the appearance of the wounds of entrance and exit, and by the cleanness with which the trunks of the brachial plexus were divided. When exposed at the autopsy, they looked as if they might have been cut off with a knife, instead of a gun-shot. It is therefore clear that the artery was not severed under circumstances the most favorable for affording a lodgment to the clot, and for the spontaneous arrest of the hemorrhage. Now, it becomes highly probable that the result achieved by nature, unaided, in this case, is not at all an exceptional one ; and, viewed in this light, the examples of similar wounds of the femoral and other arteries, not fatal from primary hemorrhage, reported by Guthrie and others, lose the surprising features of their character, and become simple illustrations of what nature habitually accomplishes under similar circumstances.

These remarks apply only to cases of hemorrhage occurring from *completely divided arteries*. If, on the other hand, the artery be but *partially divided*, (for example, to the extent of one fourth or one half its circumference) the hemorrhage becomes much more dangerous in character; for, retraction within the sheath being impossible on the part of the arterial tunics, the orifice in the artery gapes open, and assumes a round or oval shape, according to the extent to which the division has been carried, which allows a free escape of the blood, and presents no facilities for plugging up the bleeding orifice with an efficient coagulum.

In this way, hemorrhage from small arteries, when but partially divided, may become troublesome to stanch, and even fatal to life, if the exact character of the wound of the artery is not recognized in season. This statement obtains whether the wound be incised or gun-shot, in both cases alike. I have seen instances of obstinate primary hemorrhage, occurring in connection with partial division, by musket-shot, of such arteries as the radial, the ulnar, and the anterior tibial. Now, either one of these arteries would not have bled much, if at all, provided it had been completely divided by the bullet in the first instance.

It is well known that in cases of hemorrhage from partial division, with a cutting instrument, of such an artery as the temporal, the bleeding can be stopped at will by completing the division and applying a moderate amount of pressure. The rationale of arteriotomy as an operation is founded entirely upon this knowledge.

With regard to the *surgical treatment of hemorrhage* from an artery partially divided by a gun-shot, I believe, from observation, that the best course to pursue is, in case the artery be a small one, first to try the hemostatic effect of pressure, evenly and carefully applied at the seat of injury to the vessel; and, if the bleeding continue or recur, then enlarge the wound and tie the artery on both the proximal and distal sides of the orifice. But if the bleeding artery be a large one, there is then no time to be lost in trying pressure. The track of the bullet should, without delay, be dilated by incision, so as to expose the wounded vessel, which should then be tied, both on the proximal and distal side of the aperture in it, after the method recommended by John Bell, and earnestly enjoined by Guthrie. For such cases, I believe that any treatment less thorough than this, even when promptly applied, is inefficient and reprehensible, because it exposes the patient's life to unnecessary danger. If the bullet pass through a limb in a very oblique direction, wounding its principal artery, it may be deemed advisable to cut directly down upon the vessel, at the seat of injury to it, instead of dilating the track of the bullet; but such a case has never come under my observation. I can, however, readily

conceive that it may occur ; and if it should, I would have no hesitation in cutting directly down upon the vessel and securing it by two ligatures, one placed on the proximal and the other on the distal side of the wound in it, although the original injury would thus be complicated with an additional wound of operation ; for simple-incised wounds of the extremities, even when very large, almost always do well. Next to the application of ligatures to both the proximal and distal sides of wounds of arteries, I consider it a matter highest in importance, in all cases of hemorrhage from a probable lesion of a large artery, to *dilate the wound without delay and secure the bleeding vessel by ligature*. If reliance be placed upon plugging up the track of the bullet, and upon applying pressure on the outside, and such treatment be put in practice where a large artery has been wounded, the patient will be likely to die, sooner or later, exhausted by repeated hemorrhages, and infiltration of the parts bordering upon the wound with blood, while, at the same time, if the hemorrhage had been treated by tying the artery on the principles above advocated, recovery would have taken place without difficulty.

But at the same time that we are prompt in taking whatever measures may be advisable to arrest hemorrhage from a wounded artery, we should carefully abstain from performing any operation upon a wounded artery for hemorrhage unless it bleed at the time ; for it frequently happens, even in apparently unpromising cases, that a hemorrhage stopped spontaneously or by simple means, does not return. To ligate the artery in such a case, would be to inflict unnecessary torture upon the sufferer.

#### ANEURISMAL BRUIT AND THRILL.

Again, this case is unique in that the aneurism, which made its appearance July 12th, was developed from the *extremity* of a severed artery. I certainly have never seen, and do not remember ever to have heard or read, of another case, where a pulsating tumor filled with blood, and communicating with an artery, was developed otherwise than in the continuity of the blood vessel. This terminal development of the aneurism probably accounts for the absence of the aneurismal bruit, and the aneurismal thrill, as this origin does not, under ordinary circumstances, seem to admit of such disturbance of the undulations in the circulating blood as to cause them to recoil upon each other ; thus destroying the rythm of the undulations, and producing discords, (jarring vibrations,) cognizable by the senses of touch and hearing. On the other hand, if an aneurism of the variety called fusiform,\* be developed in the continuity of an artery, the rough, warty, and granular lining of the expanded vessel appears to be capable of producing such a dis-

---

\* We follow Mr. Erichsen's classification.

turbance in the wave-like current of the passing blood as to grate harshly on the touch and ear. But, in order for this to take place, it is necessary that the blood should pass beyond the aneurism through a continuous tube, otherwise the current would be stopped in the aneurism, or would not move with sufficient velocity into and through the aneurism to produce a thrill, or a rasping sound.

In the variety of spontaneous aneurism denominated *sacculated*;\* the murmur and thrill are generally quite as well marked as in the variety denominated *fusiform*. But here the disturbance in the undulation of the circulating blood is produced in a different manner. In the case of the *sacculated* aneurism, at each contraction of the heart a portion of the blood contained in the affected artery is forced out through the hole, aperture, or opening, in its side, into the aneurismal pouch connected with it, and thus the rhythm of the undulations is effectually broken at the point of communication between the vessel and the aneurismal pouch, and likewise throughout the pouch itself. The undulations are broken, not by the roughened lining of the extended artery, but by the outflow of a stream of blood from the side of the vessel, at a right angle with the general direction of the current of the blood, into the aneurismal pouch.

Inasmuch as the structure and shape of no two aneurisms is exactly alike, it follows that in no two cases are the undulations of the circulating blood disturbed in precisely the same manner, and to precisely the same extent. And, furthermore, that in no two cases are the tones of the aneurismal bruit precisely the same. In fact, clinical observation has shown not only that this bruit is never exactly the same in different cases, but that it exhibits a very wide range as to tone, varying from a harsh rasping sound on the one hand, to a faint bellow's murmur on the other.

Besides, on account of the abrupt termination of the current of the circulating blood in the aneurismal sac, from want of continuity in the vessel beyond it, the aneurismal thrill and the aneurismal bruit may be absent, because the sac is filled up with coagulated blood, so as to take part no longer in the undulations communicated by the heart to the whole vascular system. This happens most frequently in the variety of aneurism called *false*, (*sacculated*,) and then the tumor continues to pulsate, not on account of any movement in its contents, but on account of the impulse communicated to it, externally, from the artery. But the aneurismal bruit and thrill were not absent in Jordan's case, because the sac was filled with coagulated blood, for, on stopping the flow of blood into it, by compressing

---

\*Still following Mr. Erichsen's classification.

the subclavian artery over the first rib, it became much shrunken and soft in a little time, and on withdrawing the compression it gradually became filled up to the original size and tense again, thus showing conclusively the liquid character of its contents.

Again, a narrowness of the aperture in the artery did not cause the aneurismal bruit and thrill to be absent, for the tumor pulsated strongly and expansively, outwards in various directions from its centre, which decidedly implied that free communication existed between the cavity of the aneurism and the artery. Furthermore, I think that the blood would be likely to flow into an aneurism developed from the end of a divided artery with a noise, (bruit,) synchronous with the contractions of the heart, if the vessel were suddenly narrowed, constricted, or otherwise obstructed at its point of termination in the aneurism, for such obstruction would disturb the equability of the flow of the blood past it, to greater or less extent, according to the amount of the obstruction, and would, to the same extent, disturb the wave-like motion of the blood, at and beyond the point of obstruction. It, therefore, appears to be philosophical to infer that in the case of Jordan, the extremity of the axillary artery, from which the aneurism was developed, was not obstructed in any way of importance.

#### PATHOLOGY.

The pathological history of the aneurism was probably as follows: its development commenced by the yielding of the yet imperfectly organized plug or scar, at the end of the cardiac portion of the severed artery. As the blood pushed the scar gradually before it out in every direction, the cellular tissue, already more or less thickened by inflammatory exudation in and about the track of the bullet, was gathered together by degrees before it, so as to form a sac of considerable thickness and strength. As the tumor grew larger and spread beyond the limits of the inflammatory exudation, the uninjured areolar tissue also was progressively condensed on the exterior of the forming sac, and thus it happened that the walls of the sac remained strong, and retained about the same thickness, notwithstanding the comparatively rapid development of the swelling.

We may state in a general way that the walls of the aneurism were formed by the coalescence of cellular tissue, a part of which had been more or less consolidated by plastic exudation thrown out in its meshes. The singularly rounded shape, and distinctly circumscribed character of the swelling, were probably due to the thickening of the areolar tissue in the gunshot wound, more especially in the neighborhood of the ends of the severed artery.

Areolar tissue coalescing in this way to wall in and circum-

scribe a gradual outflow of blood from an artery, or to form an envelope for a chronic swelling of any kind, generally exhibits but little tendency to ulceration, and, therefore, I would not have been inclined to hasten to operate, had it not been that the scar in the track of the bullet was likely to give way in a short time, on account of the constant outward pressure of the blood in the aneurism.

#### TREATMENT.

Another important topic suggested by this case is the *surgical treatment* appropriate for *traumatic aneurism*. All cases of this disease are classified under the one or the other of two heads: 1st, *diffused traumatic aneurism*, and 2d, *circumscribed traumatic aneurism*. With regard to the *diffused* form, there can be no doubt as to the best course to be pursued. The artery should be exposed at the seat of injury by an incision sufficiently free for the purpose, and a ligature be applied to both the proximal and the distal side of the bleeding orifice. It should be treated on precisely the same principles as any other artery of the same magnitude which may happen to be wounded and bleeding. For in the one case the blood flows out through an external opening, and in the other case it flows into the areolar tissue, where it accumulates for want of an external opening through which to escape; but so far as the lesion of the artery is concerned, there is no essential difference between them. After securing the vessel by ligatures, both proximal and distal, the cavity of the diffused aneurism should be laid freely open, and all the coagulated blood should be carefully removed, otherwise offensive and tedious suppuration will be likely to occur.

With regard to the treatment of *circumscribed* traumatic aneurism, there is, however, more room for difference of opinion. This disease presents the same general features as the\* false variety of the spontaneous aneurism, and, in many instances, especially those cases which progress but slowly, closely resembles it in every respect, except that the origin is traumatic, and that no arterial coat enters into the formation of the sac.

This close similarity in appearance naturally suggests to the surgeon a similarity in treatment, and hence it has been recommended by high authority that the circumscribed traumatic aneurism should be treated by ligating the vessel before it reaches it, or in other words, by cutting off its supply of blood, and trusting that a cure will take place in the same way as in spontaneous aneurism. But it sometimes happens that a cure fails to take place, for the following among other reasons: 1st, the occurrence of *gangrene* in the parts beyond the aneurism, and 2d, the *spontaneous opening of the aneurismal sac*, followed

---

\* After Erichsen's classification.

by *secondary hemorrhage* and *exhausting suppuration*. Now it seems to me that the risk of the occurrence of a fatal result in either of these ways, may be considerably diminished by laying open the sac freely, and tying the vessel at the seat of injury, placing a ligature on both the proximal and distal sides of it, instead of securing the vessel by a single ligature at a remote point. There is no doubt in my mind that by this operation the danger from the spontaneous opening of the sac, with its subsequent hemorrhage and exhausting suppuration, would be greatly diminished, if not almost entirely removed: for the sac having been opened and emptied of its contents, would be converted into a simple wound, and would be likely to heal kindly from the bottom: and the distal part of the artery being secured by a ligature, the blood could not escape backwards into the open sac: also, the proximal part of the artery being secured by a ligature applied directly to it, the blood could not flow from it into the open sac, on the establishment of the collateral circulation with vessels given off from the artery between the seat of deligation in its continuity and the aneurism.

Again, the risk of the occurrence of gangrene would be diminished in this way: all the branches given off from the artery, before reaching the point of communication with the aneurismal sac, could be utilized for the purpose of establishing and carrying on the collateral circulation: but this cannot be done if the artery be tied at a distance from the aneurism.

These observations are not directly applicable to the treatment of spontaneous aneurism, because in such cases the artery is always more or less diseased (atheromatous) throughout the neighborhood of the aneurismal sac, and may be so much weakened on this account as not to hold a ligature safely in that locality. But it is possible that if the vessel could be secured at the point of communication with the aneurismal sac, by one ligature placed on the proximal side, and another on the distal side of it, the treatment of the spontaneous variety of aneurism would be much more successful than it now is. It is also possible that the old operation for the cure of aneurism, known as the method of Antyllus, may again come into vogue in certain cases of spontaneous aneurism.

Again, to counterbalance the important advantages in the treatment of circumscribed traumatic aneurism, obtained by laying the sac open, and tying the artery both proximally and distally at the seat of injury to it, there is but a single disadvantage. The operation is attended with the loss of a good deal of blood in all cases where one of the larger arteries is involved. This, however, in skillful hands, is unattended with danger, and, on that account a matter of but little consequence in the instances of the femoral, the brachial, and kindred arteries, because pressure can readily be so applied as to con-



trol effectually the circulation of the blood in them. In case of either of these arteries, dangerous or even very profuse hemorrhage would be inexcusable. In such cases, most of the blood that is lost, if the operation be properly performed, belongs to the aneurismal sac or to the limb itself, not having been introduced into the limb subsequent to the commencement of the operation.

---

## CASE II.

*Immense pouch-shaped aneurism of the femoral artery, produced by gunshot injury, treated by tying the vessel on both the proximal and the distal side of the orifice, with a good result. Compression of the artery had been tried forty-six hours without effect.*

July 16, 1863—I was called by DR. G. B. HAMMOND, ACTING ASSISTANT SURGEON, U. S. A., in charge of the Post Hospital at Camp Barry, to see a soldier named JOHN WILSON, of the 27th N. Y. Battery, aged 26 years, of strong constitution, and a patient in that hospital on account of a large traumatic aneurism of the left thigh, with the following history :

He had been wounded by a pistol-shot, May 26th, 1863. The bullet entered the front of the left thigh at about its middle, and passing backwards close to the femoral vessels, lodged so deeply that it could not be extracted. The track of the bullet healed kindly. An abscess, however, formed in the back part of the thigh about three weeks afterwards, which was opened, explored with Nelaton's probe, and the presence of the bullet being detected by it, the opening was enlarged, a finger introduced, and then the bullet was readily removed. The abscess also healed kindly.

About a week after he was wounded, an aneurismal swelling, connected with the femoral artery, appeared directly in the track of the bullet. It increased in size but slowly, until about the 1st of July, "when its enlargement became quite rapid." On the 16th of June, two weeks after its commencement, Dr. Mursick reported it to be about as large as a hen's egg. On the 10th of July, compression of the artery on the cardiac side of the aneurism was resorted to as a means of cure, and was persisted in forty-six hours, when the patient had a convulsion, and the compression was discontinued, without, however, having produced any perceptible effect upon the tumor.

Four days afterwards, July 16th, when I first saw the case, the aneurism was very large, and occupied a great part of the antero-inner face of the left thigh. It was flattened in shape,

and the pulsation and the aneurismal bruit were distinctly perceptible, upwards to within two inches of Poupart's ligament, and downwards to within four inches of the knee-joint. We decided to secure the femoral artery by ligature, in the neighborhood of the seat of injury. The aneurism appeared to be sacculated and developed exclusively from the inner side of the vessel. Dr. Hammond attempted to apply a ligature to the artery, on the proximal side of the aperture, without opening the sac, but failed, because the sac burst open from the necessary manipulations. The femoral artery had previously been compressed upon the pubis by the fingers of an assistant. The ruptured opening in the sac was then dilated by incisions, and the vessel tied from within the sac, on both the proximal and distal sides of the orifice, without difficulty, by Dr. Hammond.

I observed, when the sac was first opened, that it contained but little coagulum, notwithstanding that the artery had been compressed for forty-six hours only a few days before. After the proximal ligature had been applied, it was attempted to prevent hemorrhage from the distal side, until the distal ligature could be applied, by compressing the popliteal artery with a tourniquet and a large compress. But this failing, I readily controlled the distal bleeding by pressing against the side of the artery with a finger applied near the orifice and from within the sac. While the proximal ligature was being applied, I readily restrained the hemorrhage by pressing firmly against the aperture in the vessel with a piece of sponge. The aperture embraced about one half the circumference of the artery. It was oval in shape; the long diameter corresponding with the course of the vessel. The interior of the sac was smooth in feel throughout its whole extent. The sac itself was very large in point of size, as it extended, when filled, from about two inches below Poupart's ligament down to within four inches of the knee-joint. It was bounded in front by the *fascia lata*, and behind by the *adductor muscles*. It appeared to consist of condensed areolar tissue. The blood, both fluid and coagulated, was carefully removed by wiping with a sponge, and the edges of the wound drawn together and retained in apposition by three points of interrupted suture and strips of adhesive plaster. The amount of blood lost during the operation was estimated at 32 oz., a large part of which belonged to the sac and not to the general circulation. The ligatures came away on the fourteenth day, July 30. The wound healed almost entirely by the first intention. The patient did well in every respect. There was not even coldness of the extremity after the operation. The femoral vein was not injured. The proximal ligature was applied at some distance from the orifice, which however was not measured. The patient began to do light duty seven weeks after the operation; and he is now, three months after the operation, as well, apparently, as he ever was. The scar of the

wound of operation was measured by Medical Cadet Gail, October 25th, and found to be six and a half inches in length.

This case illustrates well what I consider to be the proper surgical treatment of that form of traumatic aneurism ; and, an attentive consideration of the difficulties which presented themselves in the course of the operation, suggests to me the following method as one which may be followed with advantage in similar cases, viz : 1st, arrest the influx of blood by compressing the artery completely and reliably, either by the fingers of an assistant, or by a tourniquet, on the cardiac side of the aneurism ; 2d, lay open the sac freely enough to afford room, at the outset, to work without embarrassment ; 3d, next find the aperture in the artery, by carrying the finger along the part of the sac in immediate relation with the artery, and by careful exploration in this locality it will seldom fail to be quickly discovered ; 4th, now place the finger of an assistant so as to compress the vessel laterally from within the sac, both above and below the orifice in it, and the blood belonging in the limb will immediately cease to flow out into the sac—the more freely the sac has been opened, the more readily of course can this important step be accomplished ; 5th, now remove the coagula, and sponge out the sac cleanly, this exposes the aperture in the artery to view ; then open the sheath of the artery close to the hole in it on the proximal side thereof, and pass a ligature round it with Mott's aneurism needle. As soon as this ligature has been tied, the assistant's fingers, compressing the proximal part of the vessel from within the sac, should be withdrawn. This will give more room for applying a ligature on the distal side of the orifice, which should now be done. Open the sheath of the artery carefully, near the orifice on its distal side, and pass the ligature again with Mott's needle. Tie the ligature, withdraw the assistant's fingers from compressing the distal part of the artery, and the operation is completed.

The facility of performing this operation depends mainly upon opening the sac at the commencement by a sufficiently free incision, and upon discovering promptly the precise locality of the opening of communication between the artery and the sac, and upon the assistant's fingers compressing the vessel carefully from within the sac, on both the proximal and the distal sides of the orifice, thus preventing the flow of any blood into the sac, which, if permitted, would obscure the parts, and of necessity delay the application of the ligatures.

This operation should not be undertaken without the aid of competent assistants, if such are within reach ; for in no other operation is such aid more important when a large artery is involved. I have taken the liberty of stating the method of performing it at considerable length, because the steps of the operation, which may become important and difficult of execu-

tion in the case of any large vessel, have not been laid down by writers on operative surgery. I am also confident that this discussion will prove useful to the surgeon who is about to undertake the performance of this operation, and at the same time tend somewhat, I hope, to dispel the dread of hemorrhage, which seems to appertain to the performance of this operation, especially for traumatic aneurism connected with a large artery.

By the time that the distal ligature has been tightened, it will be seen that the sac has become much contracted. Now sponge out carefully any blood, whether fluid or coagulated, that there may be in it; draw the free ends of the ligatures out; approximate the edges of the wound, and secure them with a few points of interrupted suture and strips of adhesive plaster. A roller bandage should not, under ordinary circumstances, be employed as a part of the dressing; because by constricting the limb it would tend to embarrass the establishment of the collateral circulation. If it were not applied tightly enough to do that, it would be useless as a dressing, and on that account should not be kept on the wound. The temperature of the limb should be maintained by the application of artificial warmth, if necessary, as was done in the case of Capt. Jordan. Care should be taken that the bottles of water, or the bricks employed for the purpose, are not so hot as to burn the limb.

But in case of traumatic aneurism of the *axillary* artery, the surgical treatment becomes more difficult, because, in the first place, of the proximity to the centre of the circulation; and, in the second place, because external pressure cannot be applied in a way to shut off the flow of blood to the aneurism, with certainty, as readily as in many other parts of the body; for the subclavian artery as it passes over the first rib lies deep down behind the clavicle. In Jordan's case, I tied the artery as near as possible to the aneurism on the side next to the heart, because it is the operation which is sanctioned by authority, and because it was recommended by a consultation of my colleagues, all of whom are military surgeons of experience. It was my opinion then, which was also fully expressed at the consultation, that the best procedure would be to compress the subclavian artery on the first rib as carefully as possible, then to open the sac freely by incision, and to secure the bleeding end of the severed artery with a ligature; but I was not yet impressed strongly enough with the correctness of this view to put it into practice against the advice of my colleagues intrenched behind the teachings of authority. However, after following the case attentively to its fatal close, by secondary hemorrhage and exhausting suppuration, and after making the autopsy, I have no doubt that his chance of recovery would have been, to say the least, better if that operation had been

performed. The principal advantage of the operation proposed over the operation performed, is, in the first place, that it overcomes the danger arising from exhausting suppuration of the sac for the most part; for by it the sac is converted into a simple wound, with a strong tendency to heal from the bottom; and, in the second place, it does away almost entirely with the risk of secondary hemorrhage, for it leaves no vessels with unclosed mouths in the sac, ready to bleed as soon as the collateral circulation is sufficiently established.

The disadvantage of the proposed operation is the risk arising from the hemorrhage (primary) attending the operation itself: but I am now inclined to believe that by compressing the subclavian artery against the first rib, according to the method recommended by Guthrie, this risk is more apparent than real, even on the supposition that very great difficulty be experienced in discovering the ends of the severed artery. It seems to me that a fair statement of the matter would be this: the operation performed afforded the patient a *reasonable chance* of recovery, while the operation proposed would have made recovery *nearly certain*. Guthrie proposed to compress the subclavian artery with the thumb piece of the screw of an ordinary tourniquet, wrapped up in a piece of bandage so as not to injure the skin, and press firmly downwards and backwards behind the clavicle. The inverted tourniquet would afford an excellent hold for the hands of the assistant, if compression were required to be continued for a long time. In this way any *competent assistant* would be able to effectually control the circulation of blood in the subclavian artery, in ordinary cases. We should, however, state before leaving this part of the subject, that there is no doubt but that *the treatment of traumatic aneurism should be modified according to the peculiarities of each case*, especially with respect to the situation of the aneurism, and the character of the parts overlying and surrounding it. For example, we would not treat an aneurism of the ulnar arch in the palm of the hand by opening the sac and tying the artery from within it, until other means, such as compression, etc., had failed, because the operation would require the division of the annular ligament, and consequently would produce permanent impairment of the function of the hand. The duration of a traumatic aneurism may also call for modification in the surgical treatment. The slower its development and the longer it lasts, the more closely it resembles a spontaneous aneurism, and the more amenable it becomes to the treatment successful in spontaneous cases. It appears further that the more chronic a traumatic aneurism is in respect to growth, the more likely it is to undergo a spontaneous cure, by the filling up of the sac with laminated fibrin, or with coagulated blood.

## THE WOUNDED NERVES.

Hitherto we have considered Jordan's case only so far as the wounded axillary artery is concerned. Let us now devote a little time to the wounded brachial plexus of nerves. The autopsy showed that all the trunks of that plexus were divided except the trunk of the musculo-spiral and circumflex nerves, and that their extremities were separated so widely from each other (about three inches), that it was impossible for them ever to unite again. Under these circumstances, if the patient had recovered from the aneurism, he would have always had a useless arm dangling by his side. No portion of it would have ever been of any advantage to him, and amputation of it would have been advisable as soon as the true condition of the brachial plexus became known. Now, if the operation proposed had been performed, this hopelessly damaged condition of the nerves would have been discovered, and the useless limb could have been amputated at once. Without cutting down upon these nerves, all one could say with regard to their condition was, that they had suffered some kind of injury, whereby the arm was paralyzed: it might be concussion, it might be contusion, it might be division, or it might be a combination of all three forms of injury. Without an explorative incision an exact diagnosis was impossible. It is worthy of further remark in relation to the injured nerves, that *he suffered but little pain*, which is different from what is usually stated by writers as appertaining to such injury of nerves.

The reader will observe that the musculo-spiral nerve suffered only from concussion, and that sensation returned to many of the parts supplied by it.

## MODUS OPERANDI OF THE AFTER BLEEDING.

The *pathology* of the *secondary hemorrhage*, which occurred in Jordan's case, is also an interesting subject, and next demands our attention. Did the blood escape from the distal or the proximal end of the severed artery? It is a fact well established by observation, that secondary hemorrhage from wounded arteries generally takes place from the distal side of the wound, because of the feeble adhesion and the imperfect closure of the artery on that side of the wound in it: and when the collateral circulation comes to be sufficiently established, the blood flowing backward in the distal portion of the vessel, readily overcomes the feeble union at the seat of injury, and makes its escape therefrom. It is this inability on the part of the reparative process unaided by art, to securely close the artery on the distal side of the wound, which makes the application of a distal ligature a matter of so much importance in all cases of wounds involving arteries of magnitude. But the secondary bleeding in the case under consideration,

probably did not take place from the distal end of the artery. For, at the autopsy, this part of the vessel was found to be very much contracted, its caliber being reduced to about a line in diameter, and this extreme degree of contraction existed not only at the end, but continued as far as the vessel was examined, which was a distance of two or three inches. Now, the distal part of the artery thus diminished in size, was entirely too small to supply the quantity of blood which was poured out on either of the three occasions, when secondary hemorrhage occurred. Moreover, the shrunken vessel was blocked up by a coagulum for a distance of nearly half an inch, commencing a little way within its wounded extremity. For these two reasons I think that the secondary bleeding could not have taken place from the distal end of the severed artery.

But, at the autopsy, we found that the proximal portion of the vessel was not diminished in size, and what was still more important, that its branches, such as the thoracica acromialis and the superior and the inferior thoracics, were very much enlarged. Their increased size was apparently connected with the establishment of the collateral circulation, and on that account they probably performed an important part in the production of the secondary hemorrhage. The initial one of the three secondary bleedings occurred, in all probability, from the proximal end of the artery, and in this way: the collateral circulation having been established, the blood flowed backwards, through the branches above mentioned, into the part of the axillary artery embraced between the seat of the ligature and the point of division by the bullet, with sufficient force to overcome the adhesions, which had again closed the proximal end of the vessel, subsequent to the deligation of the subclavian artery. Thus, these adhesions being overcome, the blood found its way readily into the aneurismal sac, which was not yet obliterated, and escaped externally through the opening into the sac which was not yet closed.

One of the subsequent hemorrhages may have been occasioned by ulceration of the subscapular artery; for, while making the autopsy, I noticed that this vessel was wanting, having apparently been destroyed by extension of the ulcerative process from the suppurating sac.

It is probable that the radical surgical treatment advocated in the preceding pages is more essential to the ultimate recovery of the patient from traumatic aneurism of the *axillary artery*, than from the same lesion involving almost any other artery of similar magnitude in the whole body. This necessity of ligating a wounded axillary artery at the seat of injury to it, always, not even making an exception when a circumscribed traumatic aneurism is the subject of treatment, is occasioned by the intimate vascular relations which exist between this

vessel and the neighboring parts. It will be remembered that the great artery of the upper extremity, while passing outwards behind the pectoral muscles, and beneath the clavicle and the shoulder, gives off no less than six branches of considerable size, between the inferior border of the first rib and the fold of the armpit, all within the space of a few inches. These branches inosculate freely below the axillary region, both in front and externally, with branches of the internal mammary and intercostal arteries, and also above and behind that region with branches of the supra and posterior scapular arteries. It will thus be perceived that, in the case of an aneurism of the axillary artery, treated by ligature of the subclavian in the third part of its course, or even by ligature of the axillary itself near its commencement, if perchance the sac should suppurate and its contents be discharged externally, secondary hemorrhage of a dangerous character is almost sure to follow, as soon as the collateral circulation is sufficiently established; and even then the bleeding may not take place from the distal portion of the vessel, as usually happens in cases of secondary hemorrhage produced by traumatic lesion of arteries, but from the proximal portion of the vessel, as happened in Jordan's case. From these considerations it seems to me that, without doubt, the most rational and effectual way of preventing such secondary hemorrhage is to secure the vessel by ligatures, applied at the seat of the original injury, one on each side of it, instead of tying the artery at some distant point.

Furthermore, statistics\* show that the sac is much more liable to suppurate in cases of aneurism of the axillary artery than it is in cases of the same disease involving any other vessel. Now, without stopping to inquire into the cause of this special tendency to suppuration of the sac, and consequent secondary hemorrhage, I think that the existence of such a tendency makes it still more the duty of the surgeon to tie the vessel both proximally and distally at the seat of injury in *all cases of traumatic aneurism of the axillary artery*; and I believe that an attempt should be made to secure the vessel in this way in all such cases, unless it is certain that the arterial tunics are softened, expanded, or otherwise metamorphosed, so that they will not hold a ligature or permit the application of one at the seat of injury to the artery, and this can only happen when the aneurism, growing but slowly, has existed a long time, or when there was preëxisting disease of the coats of the vessel at the point of injury.

While writing the preceding pages, I was not yet acquainted with the daring and brilliant operations performed by Mr. Syme, for rupture of the axillary artery, for traumatic aneurism of the common carotid, and for aneurism (spontaneous I

---

\* Erichsen's Surgery, pp. 557, 558.



presume) of the iliac artery. These operations sanction the leading views heretofore expressed in this paper, concerning the surgical treatment of aneurism, with the name of that great surgeon. No apology, therefore, is necessary for stating them at some length. My attention has been directed to them by Prof. Stephen Smith, of New York.

## 1.—OPERATION FOR RUPTURE OF THE AXILLARY ARTERY.

(Quoted from Holmes' Surgery, Vol. iii, p. 473. London, 1862.)

"Chloroform having been administered, I made an incision along the outer edge of the sterno-mastoid muscle, through the platysma myoides and fascia of the neck, so as to allow a finger to be pushed down to the situation where the subclavian artery issues from under the scalenus anticus, and lies upon the first rib. I then opened the tumor, when a tremendous gush of blood showed that the artery was not effectually compressed; but while I plugged the aperture with my hand, Mr. Lister, who assisted me, by a slight movement of his finger, which had been thrust deeply under the upper edge of the tumor, and through the clots contained in it, at length succeeded in getting command of the vessel. I then laid the cavity freely open, and with both hands scooped out nearly seven pounds of coagulated blood, as was ascertained by measurement. The axillary artery appeared to have been torn across, and as the lower orifice still bled freely I tied it in the first instance. I next cut through the lesser pectoral muscle close up to the clavicle, and holding the upper end of the vessel between my finger and thumb passed an aneurism needle so as to apply a ligature about half an inch above the orifice."

One step in this operation appears to me to be new and valuable, viz: The incision along the posterior border of the sterno-mastoid muscle, made with a view to compress the subclavian artery upon the first rib more certainly and more effectually. I believe that this precaution should be taken, whenever the old operation for aneurism of the axillary artery is attempted, if the clavicle be pushed upwards to any extent by the tumor, or if, for any other cause, the subclavian artery cannot be effectually compressed by the ordinary method.

## 2. OPERATION FOR TRAUMATIC ANEURISM OF THE COMMON CAROTID ARTERY BY THE OLD METHOD.

(Quoted from Holmes' Surgery, Vol. iii, p. 488, et. seq. London, 1862.)

"The treatment of aneurism at the root of the neck, at least when it follows a wound, has been lately successfully carried out by Mr. Syme, on the old method, by laying open the tumor and searching for both ends of the vessel. An abridged ac-

count of this daring operation is appended ; the reader, however, can have no idea of the risks and difficulties of such a proceeding, without perusing the fuller account in the original, and even then his idea will be but a faint and imperfect one.

“The operation performed by Mr. Syme may be thus summarially described : The patient had been stabbed in the root of the neck about two months before, and an aneurism had formed connected with the lower part of the left common carotid. This had been advancing rapidly under compression applied to the tumor, so that it was necessary to do something. Mr. Syme made a small opening into the pulsating tumor with a bistoury, and then passed in his finger so as to plug the puncture, and felt about till he got upon the spot where pressure controlled the pulsation, and where, therefore, the opening lay. Keeping this point firmly compressed, he laid the sac freely open, and sponged out the clots. A smooth serous surface was exposed, with no trace of artery or vein. The skin and sternal portion of the sterno-mastoid having been divided by a transverse incision, (pressure being still kept on the opening with the finger,) the edge of the slit in the artery which lay under the finger, was caught with catch forceps, and the vessel drawn towards the trachea ; it was then carefully scratched with a knife, till the arterial coat was brought into view on the external edge, and a ligature passed around it above the aperture. The same proceeding was repeated below the opening ; and now the finger could be withdrawn without the tremendous gush of blood which had before followed its displacement.

“It is clear that such an operation as this can be successfully performed (that is to say, performed without death resulting) only by a surgeon who possesses a large share of that fertility of resource and dexterity in operating which Mr. Syme showed in so great a degree in this case. On the general question as to whether a case like the above ought to be treated on Brasdor’s plan or as Syme treated it, it would be rash to affect to give a positive opinion ; much would depend upon the confidence of the surgeon in himself. If he felt able to carry out to a successful conclusion so difficult an operation, he would probably imitate Dr. Syme’s practice ; if not, he might try the distal ligature of the carotid. Should Brasdor’s operation fail to check the progress of the tumor, the old operation might be tried, and even a faint prospect of life might remain to the patient from an attempt made to secure the artery after the aneurism had burst.

“The above operation indicates so clearly the steps that should be taken in securing the *carotid* on account of a wound that no further description of that proceeding is necessary.”

### 3.—OPERATION FOR A LARGE ANEURISM SITUATED AT THE BIFURCATION OF THE PRIMITIVE ILIAC ARTERY.

(Quoted from Holmes' Surgery, Vol. iii., note opposite p. 1. London, 1862.)

"This operation, which may be characterized without hesitation as one of the most daring and brilliant ever performed by any surgeon, consisted in laying open the sac of a large aneurism situated at the bifurcation of the common iliac artery, the circulation in the aorta being controlled by Mr. Lister's horse-shoe clamp, and tying the arteries which communicated with the sac, viz., the common, internal, and external iliac. The patient recovered."

The account of these great operations of Mr. Syme is copied from the source above-mentioned, because I do not have access to the volumes of the Medico-chirurgical Transactions, in which they were originally published.

A description of the clamp is subjoined in Mr. Lister's own words: "For the purpose of compressing the aorta with precision and efficacy, I have had a large horse-shoe clamp constructed, with one end expanded and covered with soft material for application to the back, while the other end receives a screw, which presses down an appropriate pad. This being gradually screwed down, at a point a little above and to the left of the umbilicus, I find that the pulsation in both femoral arteries can be completely abolished, without any serious uneasiness or unpleasant consequence."—*Holmes' Surgery, Vol. 3, p. 90*; London, 1862.

WASHINGTON, D. C., November 15, 1863.

MEMORANDUM FOR THE DIRECTOR OF THE BUREAU OF REVENUE  
FROM THE CHIEF OF THE DIVISION OF TAXATION

The following information was received from the  
Director of the Bureau of Internal Revenue  
on the subject of the proposed amendment to the  
Internal Revenue Code, which would increase the  
tax on the income of corporations from 15% to 20%.  
It is suggested that the proposed amendment be  
approved and the necessary regulations be issued  
thereunder.

Very respectfully,  
[Signature]